A 58-year-old male presents with a history of left-sided chest pain on exertion. He has a 30-pack-year history of smoking. Physical examination reveals blood pressure (BP) 98/65 mmHg, pulse 88 beats/min and respiratory rate 14/min. There is a delayed carotid upstroke, sustained apex beat, normal 1st heart sound, the aortic component of the 2nd heart sound is soft and the 4th heart sound is audible.

Investigations:

ECG	Left ventricular hypertrophy
Chest X-ray	Normal
Echocardiography	Calcific aortic stenosis with valve surface area of 0.5cm^2 and peak systolic gradient of 90 mmHg

The patient undergoes coronary angiography that reveals 80% stenosis

The patient undergoes coronary angiography that reveals 80% stenosis in the proximal left anterior descending (LAD) artery.

Which of the following is the best management option for this patient?

A	Balloon aortic valvotomy plus angioplasty and stenting of the LAD
B	Angioplasty and stenting of the LAD followed by aortic valve replacement (AVR)
C	AVR and bypass grafting of the LAD using the left internal mammary artery (LIMA)
D	AVR and LAD bypass grafting using saphenous vein graft
E	Saphenous vein grafting followed by balloon valvotomy

C AVR and bypass grafting of the LAD using the left internal mammary artery (LIMA)

This patient has severe symptomatic aortic stenosis, which is an indication for aortic valve replacement. He also has LAD stenosis. As the patient is to have AVR, a concomitant bypass grafting of the LAD using the LIMA is the most appropriate option. The long-term patency of the LIMA is superior to that of a saphenous vein graft.

B Angioplasty and stenting of the LAD followed by aortic valve replacement (AVR)

This combines two separate treatment episodes, when both the CABG and valve replacement can be carried out in one operation, with superior outcomes.

A Balloon aortic valvotomy plus angioplasty and stenting of the LAD

A	Balloon aortic valvotomy plus angioplasty and stenting of the LAD

This potentially combines two inferior approaches, both with respect to fixing the aortic valve stenosis and relieving myocardial ischaemia.

D	AVR and LAD bypass grafting using saphenous vein graft

Outcomes are slightly less good when a vein graft rather than a LIMA graft is employed.

E	Saphenous vein grafting followed by balloon valvotomy

Saphenous vein grafting is inferior to LIMA grafting, and balloon valvotomy is inferior to surgical valve replacement.

7428

Rate this question:

A general practitioner (GP) calls you up. He is asking for advice regarding a 25-year-old Caucasian man who came to his surgery complaining of chest pain, which was subsequently diagnosed as musculoskeletal in origin. During his initial assessment the patient's blood pressure was 150/105 mmHg and on subsequent checks it has remained around this level. His BMI is normal at 23 and he works out at the gym each day. There is a strong family history of ischaemic heart disease and hypertension. The GP wants advice regarding treating his blood pressure.

What is your advice to the GP?

A	Start amlodipine
B	Arrange a 24 h ABPM to decide on the best therapeutic intervention
C	Start ramipril
D	Start bendroflumethiazide

During his initial assessment the patient's blood pressure was 150/105 mmHg and on subsequent checks it has remained around this level. His BMI is normal at 23 and he works out at the gym each day. There is a strong family history of ischaemic heart disease and hypertension. The GP wants advice regarding treating his blood pressure.

What is your advice to the GP?

A	Start amlodipine
B	Arrange a 24 h ABPM to decide on the best therapeutic intervention
C	Start ramipril
D	Start bendroflumethiazide
E	Start atenolol

diagnosed as musculoskeletal in origin. During his initial assessment the patient's blood pressure was 150/105 mmHg and on subsequent checks it has remained around this level. His BMI is normal at 23 and he works out at the gym each day. There is a strong family history of ischaemic heart disease and hypertension. The GP wants advice regarding treating his blood pressure.

What is your advice to the GP?

Your answer was correct

A Start amlodipine

B Arrange a 24 h ABPM to decide on the best therapeutic intervention

C Start ramipril

D Start bendroflumethiazide

E Start atenolol

B Arrange a 24 h ABPM to decide on the best therapeutic intervention

In this patient, where there are no obvious risk factors for hypertension, 'white coat syndrome' should be avoided first. NICE guidelines therefore recommend ambulatory blood pressure monitoring.

A Start amlodipine

Calcium channel blockers are the first-line intervention of choice for patients of Afro-Caribbean ethnic origin and those who are above 55 years of age.

C Start ramipril

ACE inhibition would only be recommended in this situation once hypertension has actually been confirmed by ambulatory blood pressure monitoring. Urea and electrolytes should of course be

recommended in this situation once hypertension has actually been confirmed by ambulatory blood pressure monitoring. Urea and electrolytes should of course be checked first before starting therapy.

D Start bendroflumethiazide

Thiazides are no longer recommended first-line agents for the treatment of hypertension, because of the negative effects on glucose tolerance over the longer term.

E Start atenolol

Beta blockers are not a first-line intervention for hypertension, and are best avoided in young men because of possible negative effects on erectile function.

7677

Rate this question:

A 26-year-old male is referred by his general practitioner for an electrocardiogram (ECG) abnormality discovered on routine pre-employment check-up. The ECG reveals a prolonged QT interval (QTcF) of 0.52 s. The patient has no history of palpitations or syncope and has no family history of sudden cardiac death. The physical examination is unremarkable and blood chemistry shows normal levels of potassium and magnesium. The patient is not taking any drugs and leads a sedentary life. An exercise test does not reveal shortening of the QT interval with increased heart rate.

What is the best management for this patient?

A	Left stellate cardiac ganglionectomy
B	Atenolol 50 mg a day
C	Dual chamber pacemaker

of sudden cardiac death. The physical examination is unremarkable and blood chemistry shows normal levels of potassium and magnesium. The patient is not taking any drugs and leads a sedentary life. An exercise test does not reveal shortening of the QT interval with increased heart rate.

What is the best management for this patient?

A	Left stellate cardiac ganglionectomy
B	Atenolol 50 mg a day
C	Dual chamber pacemaker
D	Implantable cardioverter defibrillator (ICD)
E	Implantable cardioverter defibrillator (ICD) and atenolol

general practitioner for an electrocardiogram (ECG) abnormality discovered on routine pre-employment check-up. The ECG reveals a prolonged QT interval (QTcF) of 0.52 s. The patient has no history of palpitations or syncope and has no family history of sudden cardiac death. The physical examination is unremarkable and blood chemistry shows normal levels of potassium and magnesium. The patient is not taking any drugs and leads a sedentary life. An exercise test does not reveal shortening of the QT interval with increased heart rate.

What is the best management for this patient?

Your answer was correct

A Left stellate cardiac ganglionectomy

B Atenolol 50 mg a day

C Dual chamber pacemaker

B Atenolol 50 mg a day

Beta blockers are the mainstay of therapy for asymptomatic, as well as symptomatic, patients with idiopathic long QT syndrome. Beta blockers decrease sympathetic activation from the left stellate ganglion (which drives QT prolongation). They also decrease the maximal heart rate achieved during exertion and thereby prevent exercise-related arrhythmic events that occur in long QT syndrome.

A Left stellate cardiac ganglionectomy

Left stellate cardiac ganglionectomy is an invasive procedure and results in Horner syndrome. It is performed in patients who have symptoms despite beta blockers and have frequent shocks with ICD.

C Dual chamber pacemaker

Dual-chamber pacing might be beneficial in the subset of patients with long QT syndrome type 3 (resulting from a mutation in the alpha subunit of the sodium channel).

D	Implantable cardioverter defibrillator (ICD)

An ICD isn't usually used as a single intervention in managing long QT syndrome, but may be implanted in conjunction with starting of beta blocker therapy in very high-risk patients.

E	Implantable cardioverter defibrillator (ICD) and atenolol

In a patient without history of collapse, atenolol as a single intervention is appropriate.

7434

Rate this question:

A 64-year-old woman is referred by her general practitioner for review. She has felt 'washed-out' over the past few weeks and has suffered a number of fevers and chills. There is a past medical history of Sydenham's chorea, and a dental extraction was carried out around 2 months ago. Examination reveals the murmur of mitral regurgitation. She has peripheral splinter haemorrhages. Blood cultures are taken.

Investigations:

Hb	9.0 g/l
MCV	92.0 fl
WCC	12.5×10^9/l
neutrophils	10.5×10^9/l
Platelets	190×10^9/l
ESR	95 mm/hr

Which one of the following stems represents the best choice for initial management?

WCC	$12.5 \times 10^9/l$
neutrophils	$10.5 \times 10^9/l$
Platelets	$190 \times 10^9/l$
ESR	95 mm/hr

Which one of the following stems represents the best choice for initial management?

A	IV corticosteroids
B	IV benzylpenicillin
C	Check autoimmune profile
D	Endoscopy to investigate anaemia
E	Commence ferrous sulphate

B IV benzylpenicillin

This patient has a history of Sydenham's chorea, a condition associated with rheumatic fever, and a recent history of dental extraction. It is likely that there has been some long-standing damage to the valve as a result of the rheumatic fever, and that the dental extraction has introduced infection resulting in endocarditis. The history of fever and malaise, normochromic, normocytic anaemia and markedly raised erythrocyte sedimentation rate (ESR) associated with the murmur of mitral regurgitation and splinter haemorrhages (signifying immune complex deposition) points towards a diagnosis of endocarditis. The key to establishing a microbiological diagnosis is the taking of multiple sets of blood cultures from multiple sites. Empirical antibiotic therapy should be started as soon as possible, even before echocardiography if there is any delay in performing this, in the face of such strong evidence pointing

face of such strong evidence pointing to the diagnosis. The most likely infective agent in this case would be *Streptococcus viridans*. Combination therapy with benzylpenicillin and gentamicin was the previous intervention of choice, although modern thinking is that gentamicin adds little in terms of efficacy at the expense of increased therapy related adverse events.

A	IV corticosteroids

Corticosteroids may accelerate progression of endocarditis; they are therefore an inappropriate option here.

C	Check autoimmune profile

Anti-nuclear antibodies may be elevated in rheumatic fever, although they wouldn't confirm or refute the diagnosis of subacute bacterial endocarditis.

D	Endoscopy to investigate

C	Check autoimmune profile

Anti-nuclear antibodies may be elevated in rheumatic fever, although they wouldn't confirm or refute the diagnosis of subacute bacterial endocarditis.

D	Endoscopy to investigate anaemia

This patient has a normochromic normocytic anaemia, not consistent with iron deficiency anaemia.

E	Commence ferrous sulphate

The anaemia is as a result of endocarditis, not iron deficiency, ferrous sulphate is therefore not of value here.

32285

Rate this question:

100% 12:11
tps://mypastest.pastest.com 10

A 78-year-old woman has been admitted four times this year with pulmonary oedema. She has an ejection systolic murmur on examination with a slow rising pulse, and is breathless on minimal exertion. She has a history of previous CABG some 20 years ago.

A recent angiogram revealed 50% stenosis in the circumflex, the right coronary artery is occluded but the graft to the RCA is patent. An echocardiogram shows good LV function, with aortic valve area 0.42 cm^2 and a gradient across the valve of 72 mmHg.

What is the best management option for this patient?

A	Graft to her circumflex artery
B	Stenting of her RCA

function, with aortic valve area 0.42 cm^2 and a gradient across the valve of 72 mmHg.

What is the best management option for this patient?

A	Graft to her circumflex artery
B	Stenting of her RCA
C	Stenting of her circumflex
D	Treatment of her pulmonary oedema, optimisation of her medication and a review in 3 months
E	Referral for aortic valve replacement

2346

Submit

admitted four times this year with pulmonary oedema. She has an ejection systolic murmur on examination with a slow rising pulse, and is breathless on minimal exertion. She has a history of previous CABG some 20 years ago.

A recent angiogram revealed 50% stenosis in the circumflex, the right coronary artery is occluded but the graft to the RCA is patent. An echocardiogram shows good LV function, with aortic valve area 0.42 cm^2 and a gradient across the valve of 72 mmHg.

What is the best management option for this patient?

Your answer was correct

A	Graft to her circumflex artery
B	Stenting of her RCA
C	Stenting of her circumflex

E Referral for aortic valve replacement

This woman has symptomatic severe aortic stenosis (AS). The risks of both conservative and surgical management are high. With such severe AS, the risk associated with conservative management approaches 40–50% combined with a poor quality of life, and hence on balance, the surgical option of aortic valve replacement represents the best option. A redo thoracotomy with valve replacement carries a risk of up to 10%. The surgeon will decide whether to graft the circumflex at the time of surgery. It is the appearance of symptoms that is most closely associated with mortality in AS, such that it is this which drives surgical intervention rather than valve gradient alone. Trans-catheter aortic valve implantation (TAVI) represents an alternative management option, which has shown great promise in recent trials such as PARTNER and SURTAVI, and may, in time, become the standard of care for high-risk surgical

Given the severity of this woman's aortic stenosis, she should be referred for aortic valve replacement; isolated grafting to her circumflex without intervention on her valve is unlikely to provide long-term symptom relief.

B	Stenting of her RCA

We are told that the previous graft to her RCA is patent, and therefore stenting of her native RCA would not provide additional benefit and does not represent optimal management in this case.

C	Stenting of her circumflex

Given the severity of this woman's aortic stenosis, she should be referred for aortic valve replacement; isolated PCI to her circumflex without intervention on her valve is unlikely to provide long-term symptom relief. Additionally, the surgeon performing her aortic valve replacement could

provide long-term symptom relief. Additionally, the surgeon performing her aortic valve replacement could make a decision to graft the circumflex at the time of valve surgery.

D	Treatment of her pulmonary oedema, optimisation of her medication and a review in 3 months

This patient is severely symptomatic, and has been admitted four times already this year. Given the clinical and echocardiographic severity of her aortic stenosis, medication alone is unlikely to provide long-term symptom relief, and referral for valve replacement represents the most appropriate management option here.

2346

Rate this question:

A 55-year-old accountant with a history of hypertension and duodenal ulceration presents with tearing interscapular back pain and a new early diastolic murmur. Aortic dissection involving the aortic root and disrupting the aortic valve is confirmed on CT scan. The patient undergoes urgent operative intervention with replacement of the aortic root with a Dacron graft and replacement of the valve with a metallic prosthesis.

After excellent postoperative recovery, he returns for a follow-up appointment complaining of increasing lethargy, exertional dyspnoea and palpitations. His medication includes warfarin, methyldopa, nifedipine and ranitidine.

Physical examination reveals a small haematoma related to his sternal scar, sinus tachycardia, an ejection systolic murmur and pale mucous membranes.

Investigations:

Hb	5.7 g/dl
WCC	12.0 × 10^9/l

murmur and pale mucous membranes.

Investigations:

Hb	5.7 g/dl
WCC	12.0 × 10^9/l
PLT	486 × 10^9/l
MCV	69 fl
ESR	27 mm/h
INR	3.3
Direct Coombs test	Negative
Faecal occult blood	Negative
Serum transferrin-receptor assay	Increased
Fibrin degradation products	Increased

What is the most likely diagnosis?

A Peptic ulceration

INR	3.3
Direct Coombs test	Negative
Faecal occult blood	Negative
Serum transferrin-receptor assay	Increased
Fibrin degradation products	Increased

What is the most likely diagnosis?

A Peptic ulceration

B Autoimmune haemolysis

C Over-anticoagulation

D Prosthetic valve dysfunction

E Valve haemolysis

methyldopa, nifedipine and ranitidine.

Physical examination reveals a small haematoma related to his sternal scar, sinus tachycardia, an ejection systolic murmur and pale mucous membranes.

Investigations:

Hb	5.7 g/dl
WCC	12.0 × 10^9/l
PLT	486 × 10^9/l
MCV	69 fl
ESR	27 mm/h
INR	3.3
Direct Coombs test	Negative
Faecal occult blood	Negative
Serum transferrin-receptor assay	Increased
Fibrin degradation products	Increased

E Valve haemolysis

Fragmentation of erythrocytes on a prosthetic valve is an unusual complication of valve replacement, but doesn't necessarily imply haemodynamic dysfunction of the valve. It tends to manifest as low-grade iron deficiency anaemia but occasionally causes a clinically important anaemia. The increased fibrin degradation products also fit with the possibility of valve haemolysis.

A Peptic ulceration

The negative faecal occult blood test makes this a less likely diagnosis.

B Autoimmune haemolysis

A negative Coombs test excludes autoimmune haemolysis (which in this case could have been related to methlydopa treatment).

B Autoimmune haemolysis

A negative Coombs test excludes autoimmune haemolysis (which in this case could have been related to methlydopa treatment).

C Over-anticoagulation

The negative faecal occult blood test, and INR of 3.3 (target 2–3), make this a less likely diagnosis.

D Prosthetic valve dysfunction

This patient's significant anaemia and increased fibrin degradation products make valve haemolysis a more likely diagnosis than valve dysfunction.

2339

Rate this question:

Next Question

A 65-year-old known chronic obstructive pulmonary disease (COPD) patient has been treated for recurrent chest infections over the last month with courses of co-amoxiclav and clarithromycin by his general practitioner (GP).

On a review consultation the GP notices a high-pitched diastolic murmur on auscultation and refers the patient for echocardiographic assessment. This shows a normal left ventricle with good function and trivial mitral regurgitation. The right ventricle is reported as at the upper limits of normal, with evidence of increased pressures and pulmonary regurgitation.

A week later the patient is due to undergo root canal treatment by his dentist.

Which of the following measures would you advise?

A	No need for antibiotic prophylaxis

regurgitation.

A week later the patient is due to undergo root canal treatment by his dentist.

Which of the following measures would you advise?

A	No need for antibiotic prophylaxis
B	Amoxicillin 3 g orally prior to the procedure
C	Amoxicillin 1 g IV and gentamicin 120 mg IV prior to the procedure
D	Clindamycin 600 mg orally prior to the procedure
E	Amoxicillin 3 g orally prior to the procedure and 4 h following the procedure

A No need for antibiotic prophylaxis

This patient's echocardiogram shows trivial mitral regurgitation (which is a normal finding) and pulmonary regurgitation which is secondary to elevated pulmonary pressures, most likely due to his chronic obstructive pulmonary disease (COPD). Although antibiotic prophylaxis was previously indicated in cases of structural pulmonary valve disease, recent NICE guidelines (see weblink below) indicate that no antibiotic prophylaxis is required for dental procedures, stating that 'Antibiotic prophylaxis against infective endocarditis is not recommended routinely for people undergoing dental procedures.'

B Amoxicillin 3 g orally prior to the procedure

Antibiotic prophylaxis is no longer routinely recommended for dental procedures. Amoxicillin is active against Gram-positive bacteria such as

against Gram-positive bacteria such as *Enterococcus faecalis*, *Staphylococcus* spp., *Streptococcus* spp., *Streptococcus pneumoniae* and Gram-negative bacteria including *Escherichia coli*, *Haemophilus influenzae*, *Proteus mirabilis* and *Neisseria gonorrhoeae*. Amoxicillin is also active against *Helicobacter pylori* but it is not effective against *Pseudomonas*, *Klebsiella*, *Serratia*, *Citrobacter* and some Gram-negative aerobes.

C	Amoxicillin 1 g IV and gentamicin 120 mg IV prior to the procedure

Antibiotic prophylaxis is no longer routinely recommended for dental procedures. Amoxicillin is active against Gram-positive bacteria such as *Enterococcus faecalis*, *Staphylococcus* spp., *Streptococcus* spp., *Streptococcus pneumoniae* and Gram-negative bacteria including *Escherichia coli*, *Haemophilus influenzae*, *Proteus mirabilis* and *Neisseria gonorrhoeae*. Amoxicillin is also active against

Helicobacter pylori but it is not effective against *Pseudomonas*, *Klebsiella*, *Serratia*, *Citrobacter* and some Gram-negative aerobes. Gentamicin is bactericidal and is active against many strains of Gram-positive and -negative pathogens including species of *Escherichia*, *Enterobacter*, *Klebsiella*, *Salmonella*, *Serratia*, *Shigella*, *Staphylococcus aureus*, some *Proteus* and against *Pseudomonas aeruginosa*. Gentamicin is often effective against strains of these organisms which are resistant to other antibiotics such as streptomycin, kanamycin and neomycin. Gentamicin is effective against penicillin-resistant *Staphylococci*, but rarely effective against *Streptococci*.

D	Clindamycin 600 mg orally prior to the procedure

Antibiotic prophylaxis is no longer routinely recommended for dental procedures. Clindamycin is active against *Bacteroides fragilis*, *P. jiroveci*, *Toxoplasma gondii*, *Clostridium*,

against *Bacteroides fragilis*, *P. fjroveci*, *Toxoplasma gondii*, *Clostridium*, *Corynebacterium acnes* and *Pneumocystis carinii*. It is thus useful in the treatment of abdominal and pelvic abscess, respiratory tract infections including lung abscess, and skin and soft-tissue infections.

E	Amoxicillin 3 g orally prior to the procedure and 4 h following the procedure

Antibiotic prophylaxis is no longer routinely recommended for dental procedures. Amoxicillin is active against Gram-positive bacteria such as *Enterococcus faecalis*, *Staphylococcus* spp., *Streptococcus* spp., *Streptococcus pneumoniae* and Gram-negative bacteria including *Escherichia coli*, *Haemophilus influenzae*, *Proteus mirabilis* and *Neisseria gonorrhoeae*. Amoxicillin is also active against *Helicobacter pylori* but it is not effective against *Pseudomonas*, *Klebsiella*, *Serratia*, *Citrobacter* and some Gram-negative aerobes.

A 28-year-old woman attends the emergency department complaining of pleuritic chest pain. The pain is central and retrosternal and is relieved by sitting forward. She has recently returned from Australia and has a history of viral infection and flu-like symptoms. There appears to be a friction rub on auscultation, the electrocardiogram reveals saddle-shaped ST elevation, and blood testing reveals normal D-dimers.

What diagnosis fits best with this clinical picture?

A	Acute pericarditis
B	Pulmonary embolus
C	Myocarditis
D	Myocardial infarction
E	Viral pleurisy

A 28-year-old woman attends the emergency department complaining of pleuritic chest pain. The pain is central and retrosternal and is relieved by sitting forward. She has recently returned from Australia and has a history of viral infection and flu-like symptoms. There appears to be a friction rub on auscultation, the electrocardiogram reveals saddle-shaped ST elevation, and blood testing reveals normal D-dimers.

What diagnosis fits best with this clinical picture?

Your answer was correct

A	Acute pericarditis
B	Pulmonary embolus
C	Myocarditis
D	Myocardial infarction

A Acute pericarditis

The presenting symptoms are typical of pericarditic pain. The normal D-dimer and ECG changes (saddle-shaped ST elevation) also point more towards a diagnosis of acute pericarditis vs pulmonary embolus. Viral infections, bacterial sepsis, fungal infections and tuberculosis may all cause acute pericarditis. Other causes include acute myocardial infarction, malignancy, autoimmune disease, granulomatous disease, hypothyroidism, drugs such as hydralazine, and trauma and radiotherapy. The mainstay of therapy for acute pericarditis is pain relief with non-steroidal anti-inflammatory agents; a trial of prednisolone may be useful if pain fails to settle within 48 h.

B Pulmonary embolus

In this instance you would expect the D-dimer to be elevated. The ECG changes are also not typical. A large

changes are also not typical. A large PE is associated with a sinus tachycardia and ECG features of right ventricular strain. Shortness of breath is also common in this instance.

C	Myocarditis

This condition is caused by myocardial inflammation and patients may again present with atypical chest pain and shortness of breath. Patients with myocarditis can either have inflammation limited to the myocardium or it may also extend to involve the pericardium (myopericarditis). Widespread T-wave inversion or saddle-shaped ST segments are common ECG changes. The diagnosis of myocarditis or myopericarditis is based on the presence of there being evidence of myocardial involvement in the inflammatory process; an elevated troponin ± evidence of systolic dysfunction on the echocardiogram or cardiac MRI scan demonstrates myocardial inflammation.

D	Myocardial infarction

The pain in the above case is atypical, rather than being suggestive of ischaemia. The universal definition of myocardial infarction requires detection of a rise and/or fall of cardiac biomarker values [preferably cardiac troponin (cTn)] with at least one value above the 99th percentile upper reference limit (URL) and with at least one of the following:

- Symptoms of ischaemia
- New or presumed new significant ST-segment–T wave (ST–T) changes or new left bundle branch block (LBBB)
- Development of pathological Q waves in the ECG
- Imaging evidence of new loss of viable myocardium or new regional wall motion abnormality
- Identification of an intracoronary thrombus by angiography or autopsy.

autopsy.

ECG changes in the case of an acute myocardial infarction are characterised by ST-segment elevation in the distribution of the affected coronary artery.

E	Viral pleurisy

Pleurisy denotes inflammation of the lining of the lungs. Lone viral pleurisy (not involving the pericardium) is not associated with ECG changes. A pleural 'friction rub', associated with pleurisy, is a squeaking/grating noise caused by inflammation of the pleura. It is characterised by a rub audible during inspiration/expiration – whenever the chest moves. In contrast, a pericardial friction rub is caused by inflammation of the pericardium. In this case the rub is audible each time the heart moves (i.e. with every heartbeat) and is still audible during cessation of breathing.

A 71-year-old man is referred to the rapid access clinic with exertional breathlessness over the last 2 months. A chest X-ray ordered by the general practitioner (GP) 3 weeks ago has been reported as consistent with a small degree of left ventricular failure. The GP has started the patient on furosemide 40 mg OD, with complete resolution of symptoms.

On examination the patient looks well, with a blood pressure of 135/85 mmHg and a heart rate of 65 beats/min. There is a loud ejection systolic murmur on auscultation of his heart that radiates to the carotids. The chest is clear on auscultation.

On close questioning he denies any pre-syncopal episodes or any angina. There is no history of rheumatic fever in childhood and no recent history of pyrexial illnesses or dental procedures. The patient undergoes an echocardiogram that is reported as showing critical aortic stenosis with a valve area of 0.5 cm^2 and a pressure gradient of 120 mmHg. The left ventricle shows concentric

ventricle shows concentric hypertrophy, with mild impairment of function.

What is the most appropriate next step in the management?

A	Initiation of angiotensin-converting enzyme (ACE) inhibitor therapy in addition to the regular furosemide
B	Prophylactic antibiotic advice and arrangement for regular follow-up with repeat echocardiograms
C	Outpatient cardiothoracic referral
D	Urgent outpatient coronary angiogram
E	Admission to hospital for inpatient coronary angiogram and cardiothoracic opinion

E	Admission to hospital for inpatient coronary angiogram and cardiothoracic opinion

The clinical state of this patient appears stable. However, the objective investigations reported in the vignette highlight that there is critical aortic stenosis associated with associated symptoms (exertional breathlessness). The risk of sudden death is high in such a patient, and he requires an urgent inpatient work-up for valve replacement.

A	Initiation of angiotensin-converting enzyme (ACE) inhibitor therapy in addition to the regular furosemide

ACE inhibitors are generally considered contraindicated in aortic stenosis. This is due to concerns that the use of a vasodilator may reduce coronary perfusion pressure. As such, they are not a recommended treatment. Additionally, such pharmacologic management is

coronary perfusion pressure. As such, they are not a recommended treatment. Additionally, such pharmacologic management is insufficient for this degree of valve disease.

B	Prophylactic antibiotic advice and arrangement for regular follow-up with repeat echocardiograms

Prophylactic antibiotics are not recommended for valvular lesions. There is no significant evidence to support a reduction in the rate of infective endocarditis when treated with prophylactic antibiotics. Regular follow-up is insufficient as this patient has critical aortic stenosis and needs urgent therapy.

C	Outpatient cardiothoracic referral

Outpatient management is insufficient in this case due to the risk of acute

follow-up is insufficient as this patient has critical aortic stenosis and needs urgent therapy.

C	Outpatient cardiothoracic referral

Outpatient management is insufficient in this case due to the risk of acute deterioration and sudden death.

D	Urgent outpatient coronary angiogram

Coronary angiography is required in the work-up of patients requiring a valve replacement. Assessment of the coronary arteries allows for planning of a combined CABG and valve replacement if necessary. However, outpatient management in this case is insufficient.

6914

Rate this question:

A 71-year-old man is admitted to the Emergency Department with shortness of breath. He had taken his dog for a walk 2 h ago when he started having palpitations, felt very dizzy and short of breath. He sat down and dialled 999 for an ambulance. He has a past medical history of two myocardial infarctions sustained over the previous couple of years, and heart failure. He is on the following medications: bisoprolol 2.5 mg od, spironolactone 25 mg od, ramipril 2.5 mg od and aspirin 75 mg od.

On examination, he is breathless with a blood pressure of 86/50 mmHg, pulse of >100/min and respiratory rate of 28/min. His jugular venous pulse is raised and he has pedal oedema. First, second and third heart sounds are heard producing a gallop rhythm. Respiratory examination reveals bibasal crackles.

His ECG reveals a broad complex tachycardia and you decide that he needs a direct current (DC) shock. You DC cardiovert him and he reverts back to sinus rhythm. His blood pressure

His ECG reveals a broad complex tachycardia and you decide that he needs a direct current (DC) shock. You DC cardiovert him and he reverts back to sinus rhythm. His blood pressure rises to 110/60 mmHg and his pulse to 82/min and regular.

What measure is most likely to prolong this gentleman's life?

A	Start him on furosemide
B	Start him on amiodarone
C	Start him on flecainide
D	Start him on procainamide
E	Insert an implanted cardioverter defibrillator

9484

Submit

E Insert an implanted cardioverter defibrillator

The patient has had scar tissue-related ventricular arrhythmia. This fits the criteria for the insertion of a secondary prevention ICD. As we were not informed of his LV function and resting ECG morphology, we do not know whether he would fit the criteria for biventricular pacing (CRT). Therefore, the use of an ICD is the most appropriate in this instance. ICDs have been shown to prolong life in patients with left ventricular dysfunction and sustained ventricular arrhythmias. Patients with an ejection fraction higher than 35% did no better with an ICD than with drug treatment.

A Start him on furosemide

Furosemide is useful to treat the symptoms of heart failure via diuresis. However, it does not confer any prognostic benefit for patients.

B Start him on amiodarone

Amiodarone is a class III antiarrhythmic drug which works by slowing the conduction rate and prolonging the refectory period of the SA and AV nodes. Pharmacological therapy with amiodarone to terminate or prevent recurrence in the acute setting is effective, but in terms of secondary prevention and long-term outcomes, ICD is superior to amiodarone. Therefore, ICD is indicated in this patient.

C Start him on flecainide

Flecainide is contraindicated in patients with coronary artery disease. The Cardiac Arrhythmia Suppression Trial (CAST) revealed that when encainide and flecainide were used to prevent arrhythmias in patients post-myocardial infarction, these drugs were detrimental to survival.

D Start him on procainamide

A 39-year-old lady is referred to the cardiology department by her general practitioner (GP) because of the finding of a diastolic murmur on auscultation. She denies any history of rheumatic fever as a child. She has lost about 8 kg in weight over the last 6 months and she has had a couple of episodes when she fainted suddenly.

On examination there is finger clubbing, but no splinter haemorrhages or any petechial haemorrhages. There is a diastolic murmur on auscultation of the heart, which varies greatly with her sitting forward and is associated with a friction rub. Her chest is clear on auscultation.

Investigations by the GP:

Hb	10.1 g/dl
WCC	12.6×10^9/l
PLT	353×10^9/l
Na+	136 mmol/l
K+	4.8 mmol/l

K+	4.8 mmol/l
Creatinine	99 µmol/l
MCV	85 fl
ESR	47 mm/h
Urea	5.0 mmol/l
CXR	Intracardiac calcification

Which one of the following diagnoses could account for all these findings?

A	Tuberculosis
B	Subacute Infective Endocarditis.
C	Rheumatic mitral valve disease.
D	Systemic lupus erythematosus (SLE)
E	Atrial myxoma

auscultation. She denies any history of rheumatic fever as a child. She has lost about 8 kg in weight over the last 6 months and she has had a couple of episodes when she fainted suddenly.

On examination there is finger clubbing, but no splinter haemorrhages or any petechial haemorrhages. There is a diastolic murmur on auscultation of the heart, which varies greatly with her sitting forward and is associated with a friction rub. Her chest is clear on auscultation.

Investigations by the GP:

Hb	10.1 g/dl
WCC	12.6×10^9/l
PLT	353×10^9/l
Na+	136 mmol/l
K+	4.8 mmol/l
Creatinine	99 μmol/l
MCV	85 fl
ESR	47 mm/h

E Atrial myxoma

Although rare (2 per 100,000 with a female:male ratio of 2:1), the diagnosis of atrial myxoma should be considered in a person who presents with finger clubbing, normocytic anaemia, a positional murmur and intracardiac calcification on the chest X-ray. The history of fainting spells suggests transient left ventricular (mitral valve) inflow obstruction. The patient should undergo urgent echocardiography and be referred for surgery if the diagnosis of myxoma is confirmed, as complete removal is curative.

A Tuberculosis

TB pericarditis may be associated with pericardial, rather than intracardiac, calcification. A diastolic murmur is not associated with uncomplicated TB pericarditis.

B Subacute Infective Endocarditis

Although subacute bacterial endocarditis can cause native aortic valve endocarditis, which may be associated with aortic incompetence, the murmur associated with this lesion (early or holo-diastolic) does not vary significantly and is not associated with a friction rub or intracardiac calcification.

C	Rheumatic mitral valve disease.

Mitral valve stenosis is associated with a mid-diastolic murmur, though in the absence of endocarditis would not be associated with a raised ESR or clubbing.

D	Systemic lupus erythematosus (SLE)

SLE may be associated with a raised ESR, but the cardiac and extracardiac features described above are not associated with SLE.

A 72-year-old man is admitted with worsening congestive heart failure over the past 4 weeks. He is known to have dilated cardiomyopathy, which has been stabilised on drugs. His medication includes digoxin 0.125 mg OD, carvedilol 6.25 mg OD, frusemide 40 mg OD and losartan 50 mg OD.

On examination, his blood pressure is 105/60 mmHg and his pulse rate is 102 bpm, regular. His JVP is raised and he has peripheral oedema. His respiratory rate is 25 breaths/min and he has bilateral crepitations.

What is the most appropriate management option for this patient?

A	β-blockers should be permanently stopped
B	Increase the dose of digoxin
C	Add spironolactone (25 mg od) to his medication

40 mg OD and losartan 50 mg OD.

On examination, his blood pressure is 105/60 mmHg and his pulse rate is 102 bpm, regular. His JVP is raised and he has peripheral oedema. His respiratory rate is 25 breaths/min and he has bilateral crepitations.

What is the most appropriate management option for this patient?

A	β-blockers should be permanently stopped
B	Increase the dose of digoxin
C	Add spironolactone (25 mg od) to his medication
D	Stop digoxin
E	Reduce the dose of losartan to 25 mg OD

A 72-year-old man is admitted with worsening congestive heart failure over the past 4 weeks. He is known to have dilated cardiomyopathy, which has been stabilised on drugs. His medication includes digoxin 0.125 mg OD, carvedilol 6.25 mg OD, frusemide 40 mg OD and losartan 50 mg OD.

On examination, his blood pressure is 105/60 mmHg and his pulse rate is 102 bpm, regular. His JVP is raised and he has peripheral oedema. His respiratory rate is 25 breaths/min and he has bilateral crepitations.

What is the most appropriate management option for this patient?

Your answer was correct

A	β-blockers should be permanently stopped
B	Increase the dose of digoxin
C	Add spironolactone (25 mg

C Add spironolactone (25 mg od) to his medication

The RALES trial showed that spironolactone (25 mg OD) reduced mortality by 30% when added to conventional therapy. Recent evidence has supported the use of spironolactone in resistant hypertension, (PATHWAY-2), showing it as the most effective BP-lowering medication in doses up to 50 mg. COPERNICUS (Carvedilol Prospective Randomised Cumulative Survival Trial) showed that carvedilol did improve survival and was well tolerated in patients with severe heart failure. The SOLVD trial (Studies Of Left Ventricular Dysfunction) showed that enalapril improved survival in patients with heart failure.

A β-blockers should be permanently stopped

There has been some debate about whether the beta-blocker should be

but evidence (from the B-CONVINCED trial) suggests that they can be continued without significantly worsening shortness of breath.

B	Increase the dose of digoxin

The recommended dose of digoxin in the treatment of heart failure (for patients in sinus rhythm) is 62.5–125 micrograms OD. Increasing digoxin dose does not represent the best next step in this case.

D	Stop digoxin

Results of the DIG (Digitalis Investigation Group) trial showed no difference in survival between the treatment arm and placebo, but did reveal an increased hospitalisation and mortality rate following the withdrawal of digoxin.

E	Reduce the dose of losartan to 25 mg OD

Results of the DIG (Digitalis Investigation Group) trial showed no difference in survival between the treatment arm and placebo, but did reveal an increased hospitalisation and mortality rate following the withdrawal of digoxin.

E	Reduce the dose of losartan to 25 mg OD

Given this patient's evidence of worsening heart failure, current evidence recommends the addition of spironolactone as the next best step. Losartan is known to have beneficial haemodynamic effects, with greater benefit at 50 than 25 mg, and reduction in losartan dose therefore does not represent the most appropriate management option for this patient.

2518

Rate this question:

A 35-year-old man who has recently returned from a holiday abroad presents to the Emergency Department with a history of general malaise, weight loss and arthralgia. He also describes episodes of waking up at night feeling really hot. On close questioning he mentions visiting a tattooing parlour and having an erythematous skin rash around the tattoo site.

On examination, he is found to be pyrexial at 38.1°C and tachycardic at 120 beats/min. On inspection there are petechial haemorrhages in his conjunctival and buccal membranes. Auscultation of his heart reveals no murmurs and his chest is clear.

Electrocardiogram (ECG) shows a sinus tachycardia with a PR interval of 220 ms.

Urinary dipstick is positive for blood.

Investigations:

Hb	14.1 g/dl
WCC	15.6×10^9/l

WCC	$15.6 \times 10^9/l$
PLT	$153 \times 10^9/l$
Na^+	136 mmol/l
K^+	4.8 mmol/l
Creatinine	83 μmol/l
Urea	5.0 mmol/l
CRP	135 mg/dl

Which of the following is the most likely diagnosis?

A Pyelonephritis

B Infective endocarditis

C Viral haemorrhagic fever

D Malaria

E Rheumatic fever

Department with a history of general malaise, weight loss and arthralgia. He also describes episodes of waking up at night feeling really hot. On close questioning he mentions visiting a tattooing parlour and having an erythematous skin rash around the tattoo site.

On examination, he is found to be pyrexial at 38.1°C and tachycardic at 120 beats/min. On inspection there are petechial haemorrhages in his conjunctival and buccal membranes. Auscultation of his heart reveals no murmurs and his chest is clear.

Electrocardiogram (ECG) shows a sinus tachycardia with a PR interval of 220 ms.

Urinary dipstick is positive for blood.

Investigations:

Hb	14.1 g/dl
WCC	15.6×10^9/l
PLT	153×10^9/l
Na^+	136 mmol/l

B Infective endocarditis

Infective endocarditis should be considered as a diagnosis in patients with chronic fever, weight loss and malaise even in the absence of murmurs. Conjunctival petechial haemorrhages are far more common than the classical skin signs of splinter haemorrhages, Osler's nodes and Janeway lesions. The presence of a first-degree atrioventricular block (PR interval 220 ms) suggests the involvement of conducting tissue while dipstick haematuria, indicating renal embolic phenomena, should also point towards subacute bacterial endocarditis. The history of skin infection suggests a *Staphylococcus* species as the probable culprit organism.

A Pyelonephritis

In pyelonephritis the urine dipstick usually tests positive for leucocytes/nitrites. Dysuria, abdominal and flank pain are common symptoms

C Viral haemorrhagic fever

Viral haemorrhagic fevers are a group of illnesses caused by RNA families of viruses, including Ebola and Marburg, Lassa fever and yellow fever. Fever and bleeding are common presenting symptoms. It is important to obtain an accurate travel history as some of the viruses are more prevalent in certain countries. Blood tests frequently demonstrate lymphopenia, thrombocytopenia, deranged LFTs and clotting.

D Malaria

A mosquito-borne infectious disease, it can present with flu-like symptoms and acute febrile illness associated with *paroxysms* (shivering followed by fever and sweating occurring every 2-4 days). Splenomegaly is common. Thin and thick blood films are used in the diagnostic work-up.

E Rheumatic fever

D	Malaria

A mosquito-borne infectious disease, it can present with flu-like symptoms and acute febrile illness associated with *paroxysms* (shivering followed by fever and sweating occurring every 2-4 days). Splenomegaly is common. Thin and thick blood films are used in the diagnostic work-up.

E	Rheumatic fever

This typically occurs 2-4 weeks following a streptococcal throat infection. It is characterised by fever, painful joints, Sydenham's chorea and erythema marginatum. Rheumatic heart disease, resulting in fibrosis and scarring of heart valves, may be a long-term complication of rheumatic fever.

6926

Rate this question:

A 35-year-old man is being treated for end-stage cardiomyopathy following viral infection. His current medication includes aspirin, bisoprolol, ramipril and furosemide. There is still evidence of cardiac failure. Echocardiography 3 months earlier revealed an ejection fraction of only 31%.

Which of the following medications has the best evidence with respect to a survival benefit

A	Spironolactone
B	Digoxin
C	Bendrofluazide
D	Warfarin
E	Bumetanide

A Spironolactone

For patients with chronic heart failure with NYHA II–IV already taking a β-blocker, angiotension-converting enzyme (ACE) inhibitor and loop diuretics, an aldosterone antagonist such as spironolactone is recommended. The RALES study demonstrated benefit of adding spironolactone in these patients with severe heart failure and ejection fraction below 35%. The study showed a relative risk of 0.7 for all-cause mortality in the group taking spironolactone. The study used low-dose spironolactone at a dose of 25 mg per day.

The PARADIGM-HF study demonstrated benefit of dual inhibition of the renin–angiotensin–aldosterone system and neprolysin inhibition compared with ACE inhibitors alone. The dual inhibitors better known as Entresto (valsartan/sacubitril) represent a major development in heart failure treatment; the new combination can be used instead of an

blocker for treatment of patients with heart failure with reduced ejection fraction.

B	Digoxin

Digoxin is indicated in patients with an ejection fraction <40%, NYHA II–IV and on optimal dose of β-blocker, ACE inhibitor or ARB, and aldosterone antagonist. Therefore, addition of spironolactone is recommended before digoxin. Digoxin is also indicated in patients with atrial fibrillation, particularly if ventricular rate at rest is >80 bpm or at exercise is >110–120 bpm.

C	Bendrofluazide

Diuretics are used for symptomatic relief and clinical signs of pulmonary and systemic venous congestion. Loop diuretics are usually required in moderate to severe heart failure. Thiazide diuretics may be used in addition to a loop diuretic for resistant

Thiazide diuretics may be used in addition to a loop diuretic for resistant oedema; typically metolazone is cautiously used in this instance.

D	Warfarin

Warfarin has no role in the management of heart failure alone, it may be considered in patients with a diagnosis of atrial fibrillation as stroke prophylaxis.

E	Bumetanide

Bumetanide is a loop diuretic and can be used instead of furosemide given its increased bioavailability; however it is used for relief of symptoms and signs of congestion rather than to improve the ejection fraction. In patients with NYHA II–IV and left ventricular ejection fraction <35% together with a QRS duration >120 ms, cardiac resynchronisation therapy (CRT) may be considered following specialist review (see NICE guidelines for full criteria).

A 38-year-old builder presents to the Emergency Department with his girlfriend. He has had rapid palpitations that began some 6–8 h after a heavy alcohol binge.

Past medical history of note includes recently diagnosed hypertension, for which he takes 5 mg ramipril. He works as a builder, often having to lift heavy pallets of brick.

On examination, he is in atrial fibrillation (AF), with a blood pressure (BP) of 120/70 mmHg and a pulse rate of 130 bpm. He has no heart murmurs and is not in heart failure.

Investigations:

Haemoglobin (Hb)	12.9 g/dl
White cell count (WCC)	5.0×10^9/l
Platelets (PLT)	299×10^9/l
Sodium (Na)	140 mmol/l
Potassium (K)	4.1 mmol/l
Creatinine (Cr)	110 μmol/l

Creatinine (Cr)	110 µmol/l
Electrocardiogram (ECG)	Fast AF with otherwise unremarkable findings
Chest X-ray	No acute changes

Which of the following is the most appropriate treatment?

A	Amiodarone
B	Adenosine
C	Flecainide
D	Vagal manoeuvres
E	Digoxin

(BP) of 120/70 mmHg and a pulse rate of 130 bpm. He has no heart murmurs and is not in heart failure.

Investigations:

Haemoglobin (Hb)	12.9 g/dl
White cell count (WCC)	5.0×10^9/l
Platelets (PLT)	299×10^9/l
Sodium (Na)	140 mmol/l
Potassium (K)	4.1 mmol/l
Creatinine (Cr)	110 µmol/l
Electrocardiogram (ECG)	Fast AF with otherwise unremarkable findings
Chest X-ray	No acute changes

Which of the following is the most appropriate treatment?

Your answer was incorrect

C Flecainide

Flecainide is a class Ic anti-arrhythmic agent used to prevent and treat tachyarrhythmias. However, study results have shown that it should not be used in patients with a previous history of ischaemic or structural heart disease, as it may lead to increased mortality rates. Where structural heart disease exists, cardioversion may be the better option.

A Amiodarone

There is no suggestion of structural heart disease here, and the most likely cause of his presentation with fast AF is his alcoholic binge. Amiodarone and flecainide are all potential options for rhythm control, although, out of these, flecainide is associated with the highest percentage chance of conversion to sinus rhythm. Amiodarone is often used when prior drugs have been ineffective or when other drugs are contraindicated.

B Adenosine

Intravenous (IV) administration of adenosine causes transient heart block in the atrioventricular (AV) node. Treatment with adenosine is not indicated in the treatment of AF but is instead used for the rapid reversion to sinus rhythm in patients with paroxysmal supraventricular tachycardia.

D Vagal manoeuvres

Vagal manoeuvres, such as that of Valsalva, are used against spontaneous supraventricular tachycardias where they are efficacious in terminating about one-quarter of cases. Such manoeuvres may also be used to temporarily slow AF. However, the conversion of AF to sinus rhythm is usually not achieved with vagal manoeuvres. Thus, AF is classically treated with medications or electrical cardioversion.

paroxysmal supraventricular tachycardia.

D	Vagal manoeuvres

Vagal manoeuvres, such as that of Valsalva, are used against spontaneous supraventricular tachycardias where they are efficacious in terminating about one-quarter of cases. Such manoeuvres may also be used to temporarily slow AF. However, the conversion of AF to sinus rhythm is usually not achieved with vagal manoeuvres. Thus, AF is classically treated with medications or electrical cardioversion.

E	Digoxin

Digoxin can be used to achieve rate control in non-paroxysmal AF. Given the acute nature and reversible cause associated with this patient's AF, medical cardioversion with flecainide is preferable.

A 45-year-old male was diagnosed with idiopathic dilated cardiomyopathy 8 years ago. Two months ago he was admitted with decompensated congestive heart failure (CHF), and an echocardiogram performed at that time revealed an ejection fraction of 20%. He was discharged on furosemide 60 mg (morning) and 40 mg in (afternoon), enalapril 10 mg twice daily and digoxin 125 mcg daily.

He now presents to the Emergency Department with progressively increasing swelling of the lower limbs and shortness of breath over one week. He has a blood pressure of 130/90 mmHg, a heart rate of 105/min, jugular venous distension, a third heart sound gallop and diffuse crackles all over the chest. He improves after receiving morphine 5 mg and two boluses of furosemide 60 mg intravenously. An ECG reveals sinus tachycardia.

Investigations:

Na^+	122 mmol/l
K^+	3.7 mmol/l

Investigations:

Na^+	122 mmol/l
K^+	3.7 mmol/l
Creatinine	130 mmol/l
Chloride	92 mmol/l
Bicarbonate	21 mmol/l

Which of the following is the most appropriate step in correcting this patient's hyponatraemia?

A Fluid restriction

B Stop furosemide

C Administer hypertonic saline

D Start lithium 100 mg TID

E Administer normal saline

with idiopathic dilated cardiomyopathy 8 years ago. Two months ago he was admitted with decompensated congestive heart failure (CHF), and an echocardiogram performed at that time revealed an ejection fraction of 20%. He was discharged on furosemide 60 mg (morning) and 40 mg in (afternoon), enalapril 10 mg twice daily and digoxin 125 mcg daily.

He now presents to the Emergency Department with progressively increasing swelling of the lower limbs and shortness of breath over one week. He has a blood pressure of 130/90 mmHg, a heart rate of 105/min, jugular venous distension, a third heart sound gallop and diffuse crackles all over the chest. He improves after receiving morphine 5 mg and two boluses of furosemide 60 mg intravenously. An ECG reveals sinus tachycardia.

Investigations:

Na^+	122 mmol/l
K^+	3.7 mmol/l

A Fluid restriction

Hyponatraemia is a frequent finding in patients with advanced heart failure and is associated with poor outcomes in terms of both morbidity and mortality. Patients with congestive heart failure (CHF) have decreased cardiac output and effective blood circulating volume. This results in activation of the renin–angiotensin system and release of antidiuretic hormone (ADH) in an attempt to preserve blood pressure, and subsequent retention of water and sodium. The overall effect is one of raised total sodium, but disproportionately increased total body water, leading to dilutional hyponatraemia.

Fluid restriction is the first-line and mainstay of therapy in hyponatraemic patients with CHF, though compliance with strict restriction of 1 l/day can limit the efficacy of this approach. Daily weights are recommended to assess response to therapy, and it may take several days of fluid restriction

before meaningful progress is seen.

ESC guidelines in the management of heart failure suggest that AVP antagonists such as tolvaptan can also be considered in the management of hyponatraemic patients with volume overload. In refractory or severe cases, IV intotropic support and/or ultrafiltration can be considered.

B	Stop furosemide

As per ESC guidelines, in the context of heart failure and volume overload, furosemide should be increased, not withheld.

C	Administer hypertonic saline

It is inadvisable to provide additional fluid loading to a patient who is overloaded in the absence of symptomatic hyponatraemia.

D	Start lithium 100 mg TID

The use of lithium is limited by

A 45-year-old woman of no fixed abode is brought to the Emergency Department by police officers. She was found lying on a bench at the railway station. She is a poor historian and has only complained of several episodes of loose bowel motions and vomiting. She denies any other symptoms.
On examination, she is dehydrated with a blood pressure of 100/55 mmHg and a regular pulse of 104/min. There are no cardiac murmurs and her chest is clear. She has slight abdominal tenderness on deep palpation but no organomegaly. There are no gross neurological abnormalities.

Investigations:

Hb	15.8 g/dl
WCC	11.0×10^9/l
PLT	210×10^9/l
Na^+	136 mmol/l
K^+	2.4 mmol/l
Creatinine	131 μmol/l

Creatinine	131 μmol/l
MCV	88.6 fl
Urea	9.7 mmol/l
Mg^{2+}	0.71 mmol/l
CXR	Normal
ECG	Sinus rhythm with features suggestive of severe hypokalaemia

Which of the following ECG changes is indicative of severe hypokalaemia?

A Delta waves

B Short QT interval

C U waves

D Tall, tented T waves

E Long ST segment

C U waves

This patient is clearly dehydrated and hypokalaemic. The significance of the hypokalaemia is reflected in the prominence of U waves on the ECG. The U wave is produced by slow and late repolarisation of the intraventricular Purkinje system and follows the T wave. It is usually best seen in leads V_4–V_6.

The causes of prominent U waves are:

- Hypokalaemia
- Cardiovascular drugs, e.g. digitalis, quinidine, amiodarone
- Psychotropic drugs, e.g. phenothiazines, tricyclic antidepressants.

Other ECG changes seen in hypokalaemia may include:

- ST depression
- Small T waves
- Large P waves

- PR prolongation
- QRS prolongation
- T wave inversion
- Ectopic beats.

Hypokalaemia has the potential to produce arrhythmias such as atrial fibrillation/flutter, ventricular fibrillation, ventricular tachycardia, and torsades.

A	Delta waves

Delta waves are associated with Wolff–Parkinson–White syndrome.

B	Short QT interval

Short QT interval is associated with hypercalcaemia.

D	Tall, tented T waves

Tall, tented T waves are associated with hyperkalaemia. Hypokalaemia is associated with small T waves.

Parkinson–White syndrome.

B Short QT interval

Short QT interval is associated with hypercalcaemia.

D Tall, tented T waves

Tall, tented T waves are associated with hyperkalaemia. Hypokalaemia is associated with small T waves.

E Long ST segment

Long ST segment is associated with hypocalcaemia. In severe hypokalaemia there may be ST segment depression.

9499

Rate this question:

You are reviewing a 70-year-old lady who you had seen in the cardiology clinic last week. You had requested for a 24 h Holter monitor for her. She had an inferior myocardial infarction that was thrombolysed 4 weeks ago. She had recovered uneventfully and was discharged on the fifth day post-myocardial infarction (MI). She came to your clinic last week with symptoms of palpitations and dizziness occurring simultaneously. She would get those episodes about twice a day in the preceding 2 weeks. On examination, her blood pressure is 130/70 mmHg, her pulse 72/min and regular. Her jugular venous pressure is not raised, first and second heart sounds are heard and there are no murmurs. Her chest is clinically clear. Her full blood count and blood biochemistry are normal.

Investigations:

Chest X-ray	Normal
	Normal sinus rhythm with Q

Electrocardiogram (ECG)	Normal sinus rhythm with Q waves in II, III and aVF. The PR interval is prolonged.
Echocardiography	Normal findings
24 h Holter monitor	Two episodes of bradycardia with a heart rate of 30/min; during these periods P waves appear unrelated to the QRS complexes. These episodes coincided with the symptoms

How are you going to manage this lady?

A Calcium channel blocker

B Permanent pacemaker

24 h Holter monitor	a heart rate of 30/min; during these periods P waves appear unrelated to the QRS complexes. These episodes coincided with the symptoms

How are you going to manage this lady?

A Calcium channel blocker

B Permanent pacemaker

C Do nothing

D Electrophysiology studies

E Start a beta-blocker

7556

Submit

Electrocardiogram (ECG)	Normal sinus rhythm with Q waves in II, III and aVF. The PR interval is prolonged.
Echocardiography	Normal findings
24 h Holter monitor	Two episodes of bradycardia with a heart rate of 30/min; during these periods P waves appear unrelated to the QRS complexes. These episodes coincided with the symptoms

How are you going to manage this lady?

Your answer was incorrect

A	Calcium channel blocker

You are reviewing a 70-year-old lady who you had seen in the cardiology clinic last week. You had requested for a 24 h Holter monitor for her. She had an inferior myocardial infarction that was thrombolysed 4 weeks ago. She had recovered uneventfully and was discharged on the fifth day post-myocardial infarction (MI). She came to your clinic last week with symptoms of palpitations and dizziness occurring simultaneously. She would get those episodes about twice a day in the preceding 2 weeks. On examination, her blood pressure is 130/70 mmHg, her pulse 72/min and regular. Her jugular venous pressure is not raised, first and second heart sounds are heard and there are no murmurs. Her chest is clinically clear. Her full blood count and blood biochemistry are normal.

Investigations:

Chest X-ray	Normal
	Normal sinus rhythm with Q

B Permanent pacemaker

This lady has symptomatic complete heart block and she would definitely benefit from a pacemaker. The frequency of events and the heart rate fit best with complete heart block rather than episodes of ischaemia.

C Do nothing

This patient has symptomatic complete heart block; doing nothing will not be appropriate as her symptoms will persist.

A Calcium channel blocker

Calcium channel blockers are negatively inotropic and may cause third-degree heart block; these therefore have no role in this scenario as this patient has symptomatic complete heart block.

D Electrophysiology studies

third degree heart block, these therefore have no role in this scenario as this patient has symptomatic complete heart block.

D	Electrophysiology studies

Electrophysiological studies are minimally invasive procedures that test the electrical conduction system of the heart to assess its electrical activity and conduction pathways. The 24 h Holter readings are already consistent with complete heart block, so there is no need for electrophysiology studies.

E	Start a beta-blocker

This patient already has bradycardia, and therefore adding a beta-blocker will exacerbate problem and will be potentially harmful.

7556

Rate this question:

A 42-year-old man who was previously fit and well developed short-lived pleuritic-sounding chest pain while playing squash one evening. The following morning he attends the Emergency Department at the insistence of his wife. Investigation shows a normal electrocardiogram (ECG), creatine kinase (CK) and troponin T. Chest X-ray is unremarkable.

What diagnosis fits best with this clinical picture?

A	Non-cardiac chest pain
B	Unstable angina
C	Stable angina
D	STEMI
E	N-STEMI

9:57
:tps://mypastest.pastest.com
13

A 42-year-old man who was previously fit and well developed short-lived pleuritic-sounding chest pain while playing squash one evening. The following morning he attends the Emergency Department at the insistence of his wife. Investigation shows a normal electrocardiogram (ECG), creatine kinase (CK) and troponin T. Chest X-ray is unremarkable.

What diagnosis fits best with this clinical picture?

Your answer was incorrect

A Non-cardiac chest pain

B Unstable angina

C Stable angina

A Non-cardiac chest pain

Normal ECG, CK and troponin T makes the diagnosis of cardiac chest pain very unlikely. If high-sensitivity troponin is negative at 12 hours it indicates a very low cardiovascular risk. Troponin elevation is correlated to myocardial necrosis and most commonly associated with acute coronary syndrome, however it can also be elevated in heart failure, tachyarrhythmias and other conditions such as sepsis, therefore its interpretation must be taken in context. The presence of pleuritic pain also suggests a respiratory or musculoskeletal cause.

C Stable angina

Typical angina exhibits a constricting discomfort in the front of the chest, precipitated by exertion, relieved by rest or GTN and often involves a crescendo of pain. A pleuritic pain which reaches maximal intensity fast is

which reaches maximal intensity fast is more likely to be a respiratory or neuromuscular cause.

B	Unstable angina

In patients with ischaemic pain but without a rise in cardiac biomarkers, the diagnosis of unstable angina may be made. Usually a history of previous stable angina and in the presence of cardiovascular risk factors intimates at this diagnosis. The clinical history suggests a non-cardiac origin for the pain.

D	STEMI

Diagnosis is made with typical acute chest pain and persistent ST-elevation on the ECG, representing an epicardial coronary occlusion.

E	N-STEMI

Acute chest pain but without ST-elevation on ECG. ECG changes may

without a rise in cardiac biomarkers, the diagnosis of unstable angina may be made. Usually a history of previous stable angina and in the presence of cardiovascular risk factors intimates at this diagnosis. The clinical history suggests a non-cardiac origin for the pain.

D	STEMI

Diagnosis is made with typical acute chest pain and persistent ST-elevation on the ECG, representing an epicardial coronary occlusion.

E	N-STEMI

Acute chest pain but without ST-elevation on ECG. ECG changes may include ST-depression, T-wave inversion or T-wave abnormalities. A rise in cardiac biomarkers with the above presentation indicates a N-STEMI diagnosis.

6556

Rate this question:

An 88-year-old man is taken to the Emergency Department by his daughter as he had been feeling unwell that day with chest pains.

An electrocardiogram (ECG) reveals that he is suffering an inferior myocardial infarction. He has a heart rate of 33 beats per minute and a blood pressure of 90/60 mmHg. He is given 600 mcg of atropine, to no effect; this is repeated up to 3 mg.

Your local hospital does not have an out-of-hours PCI service and you commence an infusion of TPA, but his rate is not immediately improving.

Which of the following treatments would be most suitable to use for his arrhythmia?

A	Adrenaline
B	Glucagon
C	Temporary pacing

blood pressure of 90/60 mmHg. He is given 600 mcg of atropine, to no effect; this is repeated up to 3 mg.

Your local hospital does not have an out-of-hours PCI service and you commence an infusion of TPA, but his rate is not immediately improving.

Which of the following treatments would be most suitable to use for his arrhythmia?

A	Adrenaline
B	Glucagon
C	Temporary pacing
D	Isoprenaline
E	Implantation of a permanent pacemaker

An 88-year-old man is taken to the Emergency Department by his daughter as he had been feeling unwell that day with chest pains.

An electrocardiogram (ECG) reveals that he is suffering an inferior myocardial infarction. He has a heart rate of 33 beats per minute and a blood pressure of 90/60 mmHg. He is given 600 mcg of atropine, to no effect; this is repeated up to 3 mg.

Your local hospital does not have an out-of-hours PCI service and you commence an infusion of TPA, but his rate is not immediately improving.

Which of the following treatments would be most suitable to use for his arrhythmia?

Your answer was incorrect

A	Adrenaline
B	Glucagon

C Temporary pacing

This patient has had an inferior myocardial infarction. The 'inferior' territory is supplied by the right coronary artery, which also supplies the sino-atrial and atrioventricular nodes. As such, inferior myocardial infarction commonly results in conduction deficits and heart block. Heart block and bradycardia are often temporary and can resolve with prompt treatment for the myocardial infarction. Temporary pacing is the correct option, as it will allow appropriate control of heart rate once inserted without precipitating further ischaemia.

B Glucagon

Glucagon is used in cases of β-blocker overdose. Glucagon activates adenyl cyclase and is theoretically able to exert a chronotropic effect not dependent on the adrenergic pathway. However, the evidence for

effectiveness even in β-blocker overdose is limited.

A Adrenaline

Adrenaline acts as a non-selective adrenoceptor agonist. Administration would increase the patient's heart rate. However, it will also increase myocardial oxygen requirements due to the positive inotropic effect. As such, adrenalin may worsen myocardial ischemia in this case.

D Isoprenaline

Isoprenaline acts as a β_1-agonist and has a positive chronotropic effect. It is often utilised in patients with complete heart block or bradycardia as a bridging therapy to allow time for a pacing system to be implanted. However, it should not be used in patients with a myocardial infarction as it can worsen ongoing myocardial ischaemia.

A 54-year-old man is referred by his general practitioner (GP). He is a smoker of 20 cigarettes per day and has suffered from exertional angina for the past few months. On this occasion he has been referred after a collapse at a wedding. Atenolol has not improved his symptoms of angina and the GP is looking for further advice. On examination in the clinic his blood pressure is 165/120 mmHg, his pulse is 80/min and regular and he has an ejection systolic murmur radiating to the carotids.

What is the next stage in the management of this patient?

A	Echocardiography
B	Add isosorbide dinitrate
C	Add amlodipine
D	Refer for exercise rehabilitation

a wedding. Atenolol has not improved his symptoms of angina and the GP is looking for further advice. On examination in the clinic his blood pressure is 165/120 mmHg, his pulse is 80/min and regular and he has an ejection systolic murmur radiating to the carotids.

What is the next stage in the management of this patient?

A	Echocardiography
B	Add isosorbide dinitrate
C	Add amlodipine
D	Refer for exercise rehabilitation
E	Refer for smoking cessation

A Echocardiography

The rapidly increasing angina symptoms, syncopal attack and ejection systolic murmur point to the possibility of aortic stenosis. Assessment of valve status is essential as a range of interventions may exacerbate symptoms in critical valve stenosis.

In this age group, aortic stenosis is most likely to be due to congenital bicuspid aortic valve. In the over-70 age group, aortic stenosis is more likely to be due to senile valvular degeneration. Assessment for valve replacement depends on comorbidity and flow gradient across the aortic valve, as assessed by echocardiography and cardiac catheterisation. In general, surgical mortality from aortic valve replacement in patients with normal left ventricular function is less than 5%.

B Add isosorbide dinitrate

Nitrates may significantly reduce ventricular filling pressure, reducing cardiac output to a critically low level because of valve stenosis.

C	Add amlodipine

This patient may benefit from improved blood pressure control, but with respect to triaging interventions, aortic stenosis should be excluded first.

D	Refer for exercise rehabilitation

Although this has been shown to improve prognosis in angina, significant aortic stenosis will limit its impact. Hence an ECHO is the required next step.

E	Refer for smoking cessation

Smoking cessation is important in managing future risk of ischaemic cardiovascular events, although it

A 70-year-old man presents to the Emergency Department with recurrent episodes of transient right hemiparesis. These episodes last up to 10 minutes and they have occurred five times over the past four weeks. He has a 50-pack-year smoking history and his blood pressure is 155/100 mmHg.

Carotid Doppler ultrasound scan report: good proximal flow in both common carotid arteries; there is 85% stenosis in the right internal carotid artery and 90% stenosis in the left internal carotid artery.

Which of the following vascular lesions is the most likely cause of this patient's symptoms?

A	Small vessel disease
B	Left internal carotid stenosis
C	Right common carotid stenosis

Carotid Doppler ultrasound scan report: good proximal flow in both common carotid arteries; there is 85% stenosis in the right internal carotid artery and 90% stenosis in the left internal carotid artery.

Which of the following vascular lesions is the most likely cause of this patient's symptoms?

A	Small vessel disease
B	Left internal carotid stenosis
C	Right common carotid stenosis
D	Left vertebral artery stenosis
E	Right vertebral artery stenosis

6816

Submit

A 70-year-old man presents to the Emergency Department with recurrent episodes of transient right hemiparesis. These episodes last up to 10 minutes and they have occurred five times over the past four weeks. He has a 50-pack-year smoking history and his blood pressure is 155/100 mmHg.

Carotid Doppler ultrasound scan report: good proximal flow in both common carotid arteries; there is 85% stenosis in the right internal carotid artery and 90% stenosis in the left internal carotid artery.

Which of the following vascular lesions is the most likely cause of this patient's symptoms?

Your answer was correct

A	Small vessel disease
B	Left internal carotid stenosis
C	Right common carotid stenosis

B Left internal carotid stenosis

The contralateral clinical signs are consistent with this vascular lesion. The hemiparesis fits with an anterior territory stroke due to a left internal carotid stenosis. NICE guideline CG68 (see below) recommends carotid imaging within 1 week of onset of symptoms for patients with TIA or non-disabling stroke. Those who have >50% stenosis, according to the North American Symptomatic Carotid Endarterectomy Trial criteria (or >70% stenosis according to the European Carotid Surgery Triallists criteria), should be considered for carotid endarterectomy, in addition to medical treatments (anti-platelets, statins and blood pressure optimisation).

A Small vessel disease

This is more likely to be associated with gradual deterioration in cognitive function and limited weakness rather than right hemiparesis.

This is more likely to be associated with gradual deterioration in cognitive function and limited weakness rather than right hemiparesis.

C	Right common carotid stenosis

The clinical signs should be contralateral to the vascular lesion. Hence a right common carotid stenosis cannot be responsible for the symptoms seen here.

D	Left vertebral artery stenosis

The clinical signs are consistent with internal carotid occlusion. Vertebral artery occlusion is more likely to be associated with transient decreased consciousness, vomiting and vertigo, rather than the hemiparesis seen here.

E	Right vertebral artery stenosis

The clinical signs are consistent with internal carotid occlusion. No

A 68-year-old man, a known hypertensive, presents to the Emergency Department with a two-day history of severe breathlessness. He says that this has started suddenly and is getting progressively worse. He describes a slight cough with no sputum production. He denies any fevers or chest pains. There is no known history of heart failure or ischaemic heart disease.

On examination he appears grossly overweight, with a blood pressure of 130/85 mmHg and a heart rate of 100 beats/min. His respiratory rate is 30/min and his saturations on air are 90%. His jugular venous pressure is raised, at 4 cm. There are no added sounds on auscultation of his heart and his chest is clear. A bedside qualitative troponin assay is positive.

Electrocardiogram (ECG) shows sinus tachycardia with right bundle branch block. Chest X-ray shows enlarged cardiac shadow but clear lung fields.

Which is the most likely diagnosis in this case?

troponin assay is positive.

Electrocardiogram (ECG) shows sinus tachycardia with right bundle branch block. Chest X-ray shows enlarged cardiac shadow but clear lung fields.

Which is the most likely diagnosis in this case?

A	Atypical pneumonia
B	Myocardial infarction
C	Pulmonary embolism
D	Primary pulmonary hypertension
E	Left ventricular failure

6924

Submit

A 68-year-old man, a known hypertensive, presents to the Emergency Department with a two-day history of severe breathlessness. He says that this has started suddenly and is getting progressively worse. He describes a slight cough with no sputum production. He denies any fevers or chest pains. There is no known history of heart failure or ischaemic heart disease.

On examination he appears grossly overweight, with a blood pressure of 130/85 mmHg and a heart rate of 100 beats/min. His respiratory rate is 30/min and his saturations on air are 90%. His jugular venous pressure is raised, at 4 cm. There are no added sounds on auscultation of his heart and his chest is clear. A bedside qualitative troponin assay is positive.

Electrocardiogram (ECG) shows sinus tachycardia with right bundle branch block. Chest X-ray shows enlarged cardiac shadow but clear lung fields.

Which is the most likely diagnosis in this case?

C Pulmonary embolism

This clinical vignette is suggestive of a PE. Sinus tachycardia is the most common arrhythmia seen in patients with a PE. The presence of RBBB may be chronic; however, acute RBBB may suggest increased right ventricular pressures secondary to a large PE. Additionally the raised JVP suggests right ventricular strain.

D Primary pulmonary hypertension

Typically this condition presents with progressive breathlessness associated with features of right heart failure. Although there are features of acute right ventricular strain, the speed of onset is not supportive of this diagnosis.

A Atypical pneumonia

The presence of breathless and tachycardia may raise suspicion of this

tachycardia may raise suspicion of this diagnosis. However, the lack of sputum production points away from this diagnosis. Additionally, there are no signs on respiratory auscultation to support this diagnosis.

B	Myocardial infarction

A raised troponin highlights the presence of myocardial damage but is not specific for a myocardial infarction. Although overweight, no other risk factors for ischaemic heart disease are presented here. Furthermore, the ECG does not support the diagnosis and he does not report chest pain. If a PE was ruled out following appropriate investigations, then this diagnosis could be reconsidered.

E	Left ventricular failure

Clinical examination revealed no features supportive of this on assessment of either the cardiovascular or respiratory system.

not specific for a myocardial infarction. Although overweight, no other risk factors for ischaemic heart disease are presented here. Furthermore, the ECG does not support the diagnosis and he does not report chest pain. If a PE was ruled out following appropriate investigations, then this diagnosis could be reconsidered.

E	Left ventricular failure

Clinical examination revealed no features supportive of this on assessment of either the cardiovascular or respiratory system. For left ventricular dysfunction to have resulted in significant breathlessness and hypoxia, respiratory auscultatory features would be expected.

6924

Rate this question:

A 62-year-old man presents with fatigue. He reports periods in the day when he feels absolutely washed out. He tries to keep himself fit, walking several miles every day, but is finding it virtually impossible to keep up his usual exercise schedule. He denies loss of consciousness or dizziness. Medication of note includes amlodipine and indapamide for hypertension. On examination his BP is 125/75 mmHg, with pulse 75/min and regular. Cardiovascular and respiratory examination is unremarkable.

Investigations:

Hb	12.3 g/dl
WCC	5.4×10^9/l
PLT	205×10^9/l
Na^+	140 mmol/l
K^+	4.8 mmol/l
Creatinine	110 μmol/l
	Three periods of complete heart block,

K^+	4.8 mmol/l
Creatinine	110 μmol/l
72 h ECG	Three periods of complete heart block, each occurring while asleep, with pauses lasting for 3 s or longer, one as long as 5 s

Which of the following is the most appropriate intervention?

A Stop amlodipine

B Arrange review in 6 months time

C Admit for permanent pacing

D Start midodrine

E Stop indapamide

C Admit for permanent pacing

Although this patient has not yet had a syncopal episode, he has significant pauses lasting for greater than 3 s associated with episodes of complete heart block. Therefore the most appropriate management is permanent pacing.

A Stop amlodipine

Calcium channel blockers may be associated with complete heart block, but this is more likely with non-dihydropyridine agents such as verapamil and diltiazem. Therefore stopping amlodipine is unlikely to resolve the problem.

B Arrange review in 6 months time

No intervention would leave this patient with a life-threatening arrhythmia and potential for sudden cardiac death

B Arrange review in 6 months time

No intervention would leave this patient with a life-threatening arrhythmia and potential for sudden cardiac death.

D Start midodrine

This is an a1 agonist used in the treatment of orthostatic hypotension. There would be no indication for its use in this scenario.

E Stop indapamide

This medication may be associated with hyponatraemia and the consequent symptoms, but is not known to cause heart block.

21276

Rate this question:

Next Question

You are a care of the elderly senior house officer in clinic. A 70-year-old man comes to see you in clinic. Looking through his medical notes you see that he has had a single ventricular lead (VVIR) pacemaker implanted 6 years previously for episodes of sinus arrest. At the time he had symptoms of sudden collapse with pre-syncope. Since the pacemaker he has not experienced such symptoms but on occasions he has been tired and listless, with a feeling of pounding in the neck or chest. His wife says that she can sometimes see large, pulsating veins in his neck. The symptoms last only a matter of seconds and are associated with chest pain or palpitations. He has mentioned this on several occasions in previous clinics but has always been reassured that nothing was wrong, and to sit down when it occurs. Otherwise, he is well in himself with a mild degree of prostatism.

On examination, there is nil of note in his cardiovascular or respiratory characteristics. In his neurological

On examination, there is nil of note in his cardiovascular or respiratory characteristics. In his neurological system, the power is equal in both upper and limbs with intact reflexes. His plantar responses are down-going.

The interrogation of the pacemaker has shown no adverse complications. The battery life is good and the lead impedance is satisfactory.

What is your advice to this gentleman?

A	He needs his VVIR pacemaker box changed
B	He needs repositioning of his pacemaker lead
C	He needs a DDDR upgrade of the VVIR pacemaker
D	He needs a tilt test
E	He needs treatment with amiodarone

C He needs a DDDR upgrade of the VVIR pacemaker

This is pacemaker syndrome. The VVIR prefix denotes a single ventricular lead pacemaker, which senses and paces the ventricle and inhibits responses to a sensed event. An untimely contraction of the atria caused by retrograde conduction of the ventricular pacemaker impulse mimics complete heart block, and the pounding is the feeling of atria contracting against a closed tricuspid valve causing cannon waves in the neck. The treatment is to upgrade the system to a dual-chamber pacemaker, which allows the atria to sense any retrograde electrical impulse and thus inhibiting native atrial depolarisation.

A He needs his VVIR pacemaker box changed

Changing the VVIR pacemaker box for another one won't impact on the risk of pacemaker syndrome, and it is

of pacemaker syndrome, and it is therefore not advised.

B	He needs repositioning of his pacemaker lead

It isn't failure of capture that is driving pacemaker syndrome but retrograde conduction of the ventricular pacemaker impulse, and hence lead repositioning won't resolve the problem.

D	He needs a tilt test

The tilt table test is used to diagnose syncope related to autonomic nervous system dysfunction.

E	He needs treatment with amiodarone

Only a dual-chamber pacemaker will lead to resolution of this patient's symptoms.

7675

A 54-year-old man with a history of hypertension managed with indapamide 1.5mg daily, who smokes 40 cigarettes per day presents to the Emergency Department complaining of feeling faint. He has been unwell with diarrhoea and vomiting over the past few days. Other history of note includes reactive depression after separating from his wife, for which he has been commenced on amitriptyline. On examination in the Emergency room his blood pressure is 110/70 mmHg. Blood testing in the Emergency department reveals the following results:

Na^+	140 mmol/l
K^+	3.1 mmol/l
Creatinine	170 micromol/l
Urea	13.1 mmol/l

His ECG is shown below:

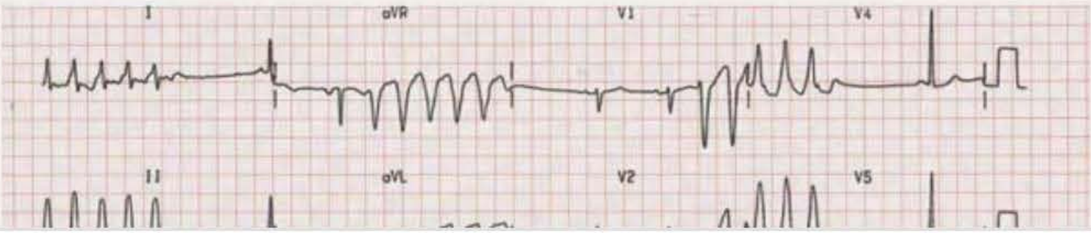

His ECG is shown below:

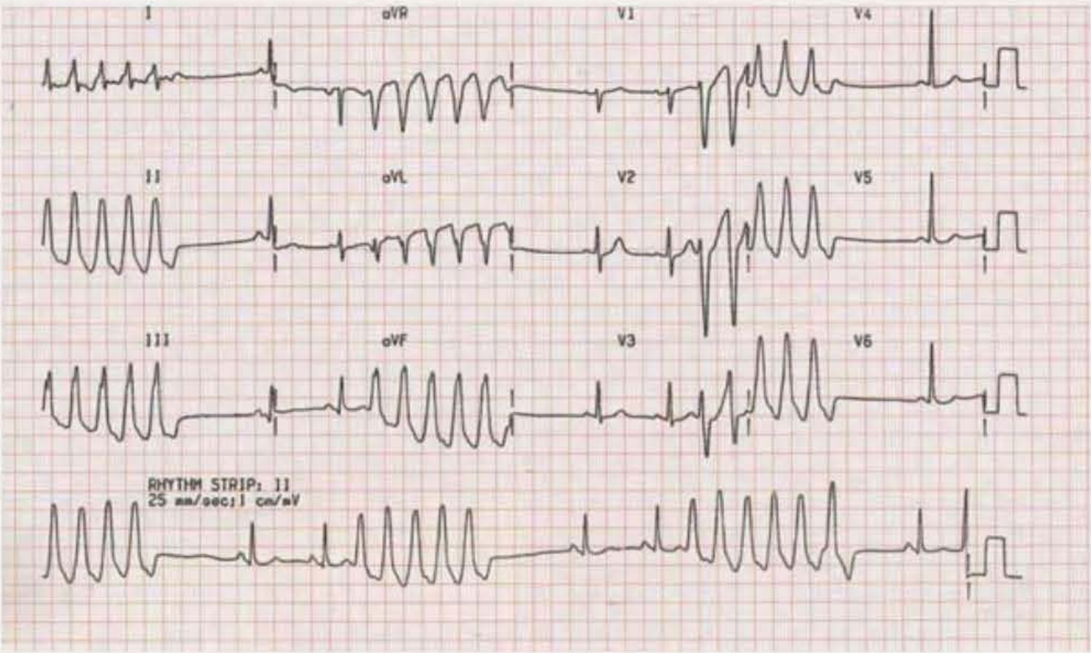

Which of the following is the most appropriate first-line treatment?

A	Flecainide IV
B	Amiodarone IV
C	Sotalol IV
D	5% dextrose fluid replacement
E	Normal saline with potassium and magnesium fluid replacement

E	Normal saline with potassium and magnesium fluid replacement

This ECG shows short self terminating runs of ventricular tachycardia. Hypokalaemia as a result of diarrhoea and vomiting plus concurrent use of indapamide will almost certainly be pro-arrhythmogenic. Additionally, significant magnesium loss occurs in association with diarrhoea. This can cause self-terminating VT which should resolve on correction of the electrolytes. Hypokalaemia is commonly associated with hypomagnesemia, therefore, both electrolytes should be replaced.

Appropriate fluid replacement to reverse electrolyte imbalances is the mainstay of initial therapy. If there is no improvement then amiodarone or lignocaine would be reasonable next options.

Sympathomimetics, tricyclic anti-depressants, digoxin, aminophylline and caffeine may all increase the

depressants, digoxin, aminophylline and caffeine may all increase the propensity to develop the condition, as such after the acute event it would be sensible to review use of amitriptyline and consider either discontinuing it or changing to an alternative anti-depressant.

A Flecainide IV

Flecainide is normally used for supraventricular tachycardia. In this case, the presence of broad complexes makes it most likely to be ventricular in origin. Therefore, flecainide has limited use in this context.

B Amiodarone IV

Amiodarone could be used to terminate sustained ventricular arrhythmia in the acute setting. The ECG is showing self-terminating episodes of VT which could be treated by removing the precipitant which in this case is electrolyte imbalance. Therefore, the more appropriate first

Therefore, the more appropriate first line treatment would be to correct the electrolyte abnormalities. Amiodarone could be considered if the patient continues to have arrhythmia despite correction and withholding precipitating drugs.

C	Sotalol IV

Sotalol could be used as an antiarrhythmic drug. Given the episodes are self-terminating, reversible causes should be treated first before considering other pharmacological therapy.

D	5% dextrose fluid replacement

With hishistory of diarrhoea and vomiting, it is very likely that the patient is volume depleted. However, it is unlikely for volume depletion to lead to self-terminating VT. Therefore, the better treatment would be to treat the underlying electrolyte imbalance whilst providing fluid resuscitation.

A 21-year-old medical student is admitted by ambulance to the Emergency Department. He was found by a passer-by in a state of undress and was unresponsive.

On admission to the Emergency Department, he has a GCS of 4, with unresponsive dilated pupils. Core temperature is measured at 28 ºC, and re-warming is commenced. Some 10 minutes after admission to the department he develops ventricular fibrillation.

Which of the following fits best with the treatment of pulseless ventricular arrhythmia in this case?

A	Amiodarone is likely to be effective
B	Lignocaine is likely to be effective
C	Repeated defibrillation is likely to be required

re-warming is commenced. Some 10 minutes after admission to the department he develops ventricular fibrillation.

Which of the following fits best with the treatment of pulseless ventricular arrhythmia in this case?

A	Amiodarone is likely to be effective
B	Lignocaine is likely to be effective
C	Repeated defibrillation is likely to be required
D	Prolonged cardiopulmonary resuscitation is likely to be required
E	Defibrillation at voltages higher than 360 V is recommended

A 21-year-old medical student is admitted by ambulance to the Emergency Department. He was found by a passer-by in a state of undress and was unresponsive.

On admission to the Emergency Department, he has a GCS of 4, with unresponsive dilated pupils. Core temperature is measured at 28 ºC, and re-warming is commenced. Some 10 minutes after admission to the department he develops ventricular fibrillation.

Which of the following fits best with the treatment of pulseless ventricular arrhythmia in this case?

A	Amiodarone is likely to be effective
B	Lignocaine is likely to be effective
C	Repeated defibrillation is likely to be required

fibrillation.

Which of the following fits best with the treatment of pulseless ventricular arrhythmia in this case?

A	Amiodarone is likely to be effective
B	Lignocaine is likely to be effective
C	Repeated defibrillation is likely to be required
D	Prolonged cardiopulmonary resuscitation is likely to be required
E	Defibrillation at voltages higher than 360 V is recommended

18525

Submit

and was unresponsive.

On admission to the Emergency Department, he has a GCS of 4, with unresponsive dilated pupils. Core temperature is measured at 28 ºC, and re-warming is commenced. Some 10 minutes after admission to the department he develops ventricular fibrillation.

Which of the following fits best with the treatment of pulseless ventricular arrhythmia in this case?

Your answer was correct

A	Amiodarone is likely to be effective
B	Lignocaine is likely to be effective
C	Repeated defibrillation is likely to be required
D	Prolonged cardiopulmonary

D Prolonged cardiopulmonary resuscitation is likely to be required

At core temperatures of less than 30 °C, treatment of ventricular arrhythmia with medical therapy is largely ineffective, and electrical cardioversion is less effective than in normothermic patients. For this reason, a prolonged period of CPR may be required until core temperature is above 30 ºC. Defibrillation should be limited to three shocks, and drugs should be withheld at temperatures below 30°C. Between 30–35 °C, the intervals between drug doses should be doubled when compared with normothermia intervals. Where available, for a long period of cardiac arrest, cardiopulmonary bypass may be effective, although practically this is possible in only a handful of centres within the UK.

A Amiodarone is likely to be effective

In hypothermic arrest, drugs are less effective - metabolism is slowed and there is the possibility of accumulation to toxic levels - and prolonged resuscitation with re-warming is the management of choice.

B	Lignocaine is likely to be effective

In hypothermic arrest, drugs are less effective - metabolism is slowed and there is the possibility of accumulation to toxic levels - and prolonged resuscitation with re-warming is the management of choice.

C	Repeated defibrillation is likely to be required

Defibrillation is less effective in hypothermia. For ventricular fibrillation/ventricular tachycardia (VF/VT), defibrillation can be tried up to three times but should then not be tried until the temperature reaches 30°C.

resuscitation with re-warming is the management of choice.

C	Repeated defibrillation is likely to be required

Defibrillation is less effective in hypothermia. For ventricular fibrillation/ventricular tachycardia (VF/VT), defibrillation can be tried up to three times but should then not be tried until the temperature reaches 30°C.

E	Defibrillation at voltages higher than 360 V is recommended

Defibrillation is less effective in cases of hypothermia - re-warming and prolonged CPR is the management of choice. Defibrillation can be tried if VF/VT is present, but should be performed as per standard life support guidelines and not at an increased voltage.

A 32-year-old physiotherapist presents with a 2-week history of increasing shortness of breath and leg swelling. Previously well, she gave birth 8 weeks ago by planned Caesarean section and is breast-feeding. Over the last 4 weeks, she became progressively breathless, and developed a dry cough and swollen ankles. She smoked in her teenage years.

On examination, she is afebrile with a pulse of 108 bpm and irregular. Her blood pressure is 85/53 mmHg and her respirations at rest are 16 breaths/min, which increased to 24 on light exercise. Jugular venous pressure is elevated at 5 cm and she has pitting oedema of both lower limbs to mid-shin. A pan-systolic murmur, loudest at the apex, and a third heart sound can be heard. Percussion note is dull at the right base and is associated with decreased air entry. Coarse crackles are present at the left base. Her liver is mildly tender and enlarged 3 cm below the right costal margin. Chest X-ray shows a pleural effusion at the right base, a blunted left costophrenic angle

base, a blunted left costophrenic angle, alveolar shadowing at both bases and large pulmonary vessels. Atrial fibrillation with an occasional ectopic beat is evident on ECG.

Investigations:

Hb	112 g/l
WCC	12.5×10^9/l
PLT	246×10^9/l
Na^+	132 mmol/l
K^+	3.8 mmol/l
Creatinine	84 μmol/l
Urea	4.5 mmol/l
Bilirubin	20 μmol/l
Albumin	36 g/l
ALT	106 U/l
ALP	121 U/l
CRP	34 mg/l
TSH	1.23 mU/l

ALT	106 U/l
ALP	121 U/l
CRP	34 mg/l
TSH	1.23 mU/l
Free T_4	18.2 nmol/l
MCV	84.3 fl

What is the most likely diagnosis?

A	Atypical pneumonia
B	Pulmonary embolus
C	Peripartum cardiomyopathy
D	Subacute bacterial endocarditis
E	Primary pulmonary hypertension

with a 2-week history of increasing shortness of breath and leg swelling. Previously well, she gave birth 8 weeks ago by planned Caesarean section and is breast-feeding. Over the last 4 weeks, she became progressively breathless, and developed a dry cough and swollen ankles. She smoked in her teenage years.

On examination, she is afebrile with a pulse of 108 bpm and irregular. Her blood pressure is 85/53 mmHg and her respirations at rest are 16 breaths/min, which increased to 24 on light exercise. Jugular venous pressure is elevated at 5 cm and she has pitting oedema of both lower limbs to mid-shin. A pan-systolic murmur, loudest at the apex, and a third heart sound can be heard. Percussion note is dull at the right base and is associated with decreased air entry. Coarse crackles are present at the left base. Her liver is mildly tender and enlarged 3 cm below the right costal margin. Chest X-ray shows a pleural effusion at the right base, a blunted left costophrenic angle, alveolar shadowing at both bases and

C Peripartum cardiomyopathy

Peripartum cardiomyopathy is an idiopathic condition occurring in the last month of pregnancy or in the first five months postpartum. It presents with heart failure secondary to left ventricular systolic dysfunction. The clinical vignette describes a patient with significant heart failure, and this is the most likely underlying diagnosis. Heart failure should be managed with β-blockade and diuretics, and ACE inhibitors can be considered postpartum. In many cases cardiac function recovers, but if it remains poor then heart transplant should be considered.

B Pulmonary embolus

The risk of pulmonary embolism increases in pregnancy and should be considered in peripartum individuals with dyspnoea. A large pulmonary embolism would lead to features of right-sided heart failure, including a

raised JVP and peripheral oedema. However, typically with a pulmonary embolism there would be limited chest findings.

A	Atypical pneumonia

The chest findings reported here could be confused with an atypical pneumonia, but the bilateral nature and the systemic features in keeping with heart failure make this less likely.

D	Subacute bacterial endocarditis

This diagnosis should be considered in all patients with a new pan-systolic murmur. However, there are no additional features to suggest this diagnosis. The pan-systolic murmur present here is likely caused by mitral regurgitation secondary to left ventricular dilatation rather than endocarditis. However, in both cases an echocardiogram would be the next investigative option.

D	Subacute bacterial endocarditis

This diagnosis should be considered in all patients with a new pan-systolic murmur. However, there are no additional features to suggest this diagnosis. The pan-systolic murmur present here is likely caused by mitral regurgitation secondary to left ventricular dilatation rather than endocarditis. However, in both cases an echocardiogram would be the next investigative option.

E	Primary pulmonary hypertension

This condition normally presents over a longer time-frame than indicated in this case. Furthermore, the primary features are of dyspnoea with right-sided heart failure signs and symptoms developing. Examination of the chest is usually normal, as left ventricular function is often preserved.

2311

Rate this question:

A 59-year-old man presents to the Emergency Room with central crushing chest pain radiating to both arms. He is sweaty and vomiting. There is a past history of hypertension, for which he takes ramipril 10 mg daily, and he smokes 20 cigarettes per day. On examination his BP is 110/70 mmHg, with pulse 62/min. He has clinical evidence of pulmonary oedema.

Investigations:

Hb	13.1 g/dl
WCC	5.0×10^9/l
PLT	199×10^9/l
Na^+	139 mmol/l
K^+	4.9 mmol/l
Creatinine	120 μmol/l
ECG	Widespread ST elevation

He undergoes stenting of the LAD and is recovering on the CCU when you are asked to see him by the nurses. There is persistent slowing of his pulse to 40 and his blood pressure is 80/40. A repeat ECG demonstrates complete heart block and resolved ST elevation. You give him atropine 3 mg, but it makes little difference.

Which of the following is the most appropriate intervention?

A	External pacing
B	Further atropine 1 mg
C	Adrenaline
D	Isoprenaline
E	Temporary pacing wire

ECG	Widespread ST elevation

He undergoes stenting of the LAD and is recovering on the CCU when you are asked to see him by the nurses. There is persistent slowing of his pulse to 40 and his blood pressure is 80/40. A repeat ECG demonstrates complete heart block and resolved ST elevation. You give him atropine 3 mg, but it makes little difference.

Which of the following is the most appropriate intervention?

Your answer was correct

A	External pacing
B	Further atropine 1 mg
C	Adrenaline
D	Isoprenaline

E Temporary pacing wire

Unfortunately in this case there is a significant likelihood of permanent complete heart block. Whereas in the context of inferior MI, heart block may just be indicative of temporary ischaemia and may thus resolve after supportive management and revascularisation, in anterior MI it is indicative of extensive infarction. Therefore rather than attempting external pacing it is most appropriate to manage him with a temporary pacing wire, which may need to be converted to permanent pacing after a few days.

A External pacing

External pacing is less reliable than transvenous pacing and is uncomfortable for the patient. It can be used as an emergency temporising measure but, in this case, where transvenous pacing is available, this represents a more suitable

B Further atropine 1 mg

Current Resuscitation Council brady-arrhythmia guidelines recommend atropine to a maximum of 3 mg. As he has not responded to this dose and he is demonstrating haemodynamic instability, further doses of atropine would not represent appropriate management.

C Adrenaline

This patient is demonstrating haemodynamic instability and has failed to respond to medical management with atropine. Definitive management is insertion of a temporary pacing wire.

D Isoprenaline

This patient is demonstrating haemodynamic instability and has failed to respond to medical management with atropine. Definitive management is the insertion of a

C Adrenaline

This patient is demonstrating haemodynamic instability and has failed to respond to medical management with atropine. Definitive management is insertion of a temporary pacing wire.

D Isoprenaline

This patient is demonstrating haemodynamic instability and has failed to respond to medical management with atropine. Definitive management is the insertion of a temporary pacing wire. Also note that, while representing a suitable stabilising agent in the management of complete heart block, recent myocardial infarction is a contraindication to the use of isoprenaline.

21030

Rate this question:

Next Question

A 19-year-old man presents to the Emergency Department of a small district general hospital in the early hours of the morning, complaining of severe epigastric and retrosternal pain. He gives a history of a pyrexial illness over the preceding few days, which he thought was 'the flu'. He has not been able to sleep as he finds lying down extremely uncomfortable.

On examination he is pyrexial at 38°C, with a blood pressure of 135/85 mmHg and a heart rate of 90 beats/min. Saturations are 100% on room air. There is a friction rub heard over the precordium and the chest is clear on auscultation.

Investigations:

Hb	13.1 g/dl
WCC	11.6×10^9/l
PLT	253×10^9/l
Na^+	138 mmol/l
K^+	4.7 mmol/l
[illegible]	[illegible]

A 68-year-old lady is referred to the cardiology department with intermittent palpitations. She describes episodes of 'feeling flushed' associated with a fluttering feeling in the chest. She denies any chest pain or breathlessness. There are no risk factors for ischaemic heart disease or any history or rheumatic fever. She is also suffering from paroxysms of diarrhoea.

On examination she appears well in herself. There are prominent v-waves noted on inspection of the jugular venous pulse. A pansystolic murmur is audible at the left sternal edge. The chest is clear on auscultation. A pulsatile liver is felt 2 cm below the costal margin on palpation of the abdomen.

Which of the following investigations is most likely to yield the underlying diagnosis?

A	24 h urine collection for 5-hydroxyindoleacetic acid (5-HIAA)

noted on inspection of the jugular venous pulse. A pansystolic murmur is audible at the left sternal edge. The chest is clear on auscultation. A pulsatile liver is felt 2 cm below the costal margin on palpation of the abdomen.

Which of the following investigations is most likely to yield the underlying diagnosis?

A	24 h urine collection for 5-hydroxyindoleacetic acid (5-HIAA)
B	Echocardiogram
C	24 h electrocardiogram (ECG)
D	Chest X-ray
E	Abdominal ultrasound

A 24 h urine collection for 5-hydroxyindoleacetic acid (5-HIAA)

This patient presents with features of carcinoid syndrome. This is a paraneoplastic syndrome secondary to a carcinoid tumour. The most common locations for a carcinoid tumour are in gut and arise from the enterochromaffin cells. Carcinoid tumours secrete serotonin, which is metabolised by the liver. If the carcinoid tumour metastasises to the liver, serotonin enters the systemic circulation. Release of circulation is associated with flushing, diarrhoea and bronchoconstriction. Continued serotonin exposure can result in restrictive cardiomyopathy secondary to fibrosis. This can lead to valvular pathology (in this case the tricuspid valve). 5-HIAA is a degradation product of serotonin, which is excreted in the urine. A level of >25 mg per 24 is diagnostic.

B	Echocardiogram

This patient likely has tricuspid regurgitation secondary to the restrictive cardiomyopathy seen in 50% of cases of serotonin syndrome. The echocardiogram would likely demonstrate these cardiac abnormalities. However, it is not the investigation of choice to reveal the underlying cause.

C	24 h electrocardiogram (ECG)

Although this patient reports symptoms suggestive of palpitations ('fluttering feeling in the chest'), there are no features suggestive of a sinister arrhythmic event. This patient likely has carcinoid syndrome, which does not commonly affect cardiac conduction.

D	Chest X-ray

Carcinoid syndrome can occur secondary to a carcinoid tumour in the

D	Chest X-ray

Carcinoid syndrome can occur secondary to a carcinoid tumour in the lungs (a common extra-GI site for primary carcinoid tumours). However, the features supporting tricuspid regurgitation point towards a liver metastasis as the serotonin source. A chest X-ray in this patient may only show non-specific changes or appear normal.

E	Abdominal ultrasound

This patient has an enlarged liver on clinical examination. This may be due to hepatic metastatic spread of a GI carcinoid tumour or secondary to the apparent tricuspid regurgitation. An abdominal ultrasound may show a hepatic tumour, but it is unlikely to be able to differentiate between a carcinoid tumour and a metastatic adenocarcinoma. Although it is an important investigation, it is unlikely to be the key to the underlying diagnosis.

A 72-year-old man is referred to the cardiology clinic because of two syncopal episodes over the past month. Both episodes have happened while he had been doing some chores around the house. His past medical history is unremarkable and he is not on any medication. On each occasion he has noticed a feeling of sounds becoming muffled, a sensation that his heart is pounding, some nausea and then his vision going black before collapsing to the ground. His wife has witnessed one episode and said that he was very pale and rather clammy, he recovered consciousness within a few seconds of falling and within less than a minute was back to his normal self. His physical examination is essentially normal and there is no postural drop in his blood pressure.

Investigations:

Hb	12.8 g/dl
PLT	240×10^9 /l
WCC	12.1×10^9 /l

postural drop in his blood pressure.

Investigations:

Hb	12.8 g/dl
PLT	240×10^9 /l
WCC	12.1×10^9 /l
Na+	141 mmol/l
K+	3.8 mmol/l
Urea	7.1 mmol/l
Creatinine	78 µmol/l
Lipids	Normal
Liver function tests	Normal
Thyroid function tests	Normal
ECG	Sinus rhythm, old inferior MI
Echocardiogram	Normal

What would you advise this gentleman?

tests	Normal
ECG	Sinus rhythm, old inferior MI
Echocardiogram	Normal

What would you advise this gentleman?

A	Sit down whenever he feels dizzy
B	He needs an angiogram
C	He needs a computed tomography (CT) scan of his chest
D	He needs a CT scan of his head
E	He needs Dopplers of his carotids

A Sit down whenever he feels dizzy

In dealing with blackouts, it is vital to establish what the patient means by 'blackout'. You need to take a detailed history from both the patient and the witness. The differential diagnosis is wide and includes vasovagal syncope, situational syncope, epilepsy and Stokes–Adams attacks, to mention only a few. The detailed history should be able to narrow down the likely diagnosis, which in the above patient is vasovagal syncope. Onset is over a few seconds and is often preceded by sweating, pallor and visual field defects. The patient falls to the ground and is unconscious for about 2 min. Incontinence of urine is rare, there is no tonic-clonic sequence and there is no prolonged confusion or amnesia. It is rare for anyone to faint through vasovagal mechanisms while seated or lying flat (such an occurrence being suggestive rather of a possible cardiac cause). If symptoms persist, then a tilt-table test may be sensible.

B	He needs an angiogram

There is no indication this may be related to coronary ischaemia. We would expect an abnormal electrocardiogram or chest pain if angina was suspected. The most common symptom of myocardial infarction is central chest pain that radiates to the left shoulder, arm, back, neck or jaw. It lasts for more than a few minutes and is associated with autonomic symptoms such as heartburn, shortness of breath, nausea, pre-syncope or lethargy. About 30% of patients have atypical symptoms – these may include little or no history of symptoms.

C	He needs a computed tomography (CT) scan of his chest

There is no indication that any intra-thoracic lesion may be responsible, and so any dissection would cause severe chest pain. Intra-thoracic lesions that may lead to syncope

lesions that may lead to syncope include dissecting aorta. However, dissecting thoracic aorta will present with central chest pain that would radiate to the back, often described as a 'tearing' pain. There are other symptoms such as vomiting, sweating and nausea. Other symptoms may manifest from decreased blood supply, such as stroke or mesenteric ischaemia.

D	He needs a CT scan of his head

It is unlikely to be an intracranial lesion as there is no seizure or fitting. Neurological disorders associated with seizures may manifest with a variety of presentations, from brief unconsciousness to prolonged periods of uncontrollable shaking. There may be associated incontinence of urine or faeces. Some seizures may occur without any warning, whilst in others focal seizures are often preceded by certain experiences known as auras, where there may be visual, hearing or

presentations, from brief unconsciousness to prolonged periods of uncontrollable shaking. There may be associated incontinence of urine or faeces. Some seizures may occur without any warning, whilst in others focal seizures are often preceded by certain experiences known as auras, where there may be visual, hearing or abnormal olfactory sensations.

E	He needs Dopplers of his carotids

There is no indication of carotid abnormality, such as dizziness on head turning or carotid bruit heard on examination. Carotid insufficiencies may cause transient ischaemic attacks. These may present with sudden, severe headache of unknown cause, dizziness or loss of balance and there may be weakness in the limbs or temporary loss of vision.

7491

Rate this question:

A 63-year-old male with ischaemic cardiomyopathy presents for a follow-up visit. He has been diabetic for the last 5 years and had an anterior myocardial infarction 4 years ago. Subsequent coronary angiography revealed three-vessel disease and he underwent coronary artery bypass grafting. One year ago he was admitted with a history of palpitations, and electrocardiogram (ECG) showed atrial fibrillation but no ST segment changes. Serial cardiac enzymes were normal and echocardiography showed an ejection fraction of 23%. He was started on amiodarone and warfarin. Other medications include carvedilol 25 mg twice daily, fosinopril 20 mg/day, furosemide 40 mg twice daily, digoxin 0.25 mg/day and pravastatin 40 mg/day. Over the last one year he has had two recurrences of atrial fibrillation. Physical examination reveals a regular pulse of 68/min and no evidence of fluid retention.

Investigations show:

Sodium	135 mmol/l

Potassium	4.5 mmol/l
Urea	8 mmol/l
Creatinine	70 µmol/l
Haemoglobin	14 g/dL
White cell count	10×10^9/L
Digoxin Level	In therapeutic range
Thyroid function tests	normal
Electrocardiogram (ECG)	sinus rhythm with no QT prolongation
Holter monitor	no evidence of atrial fibrillation but two episode of non-sustained ventricular tachycardia (VT) each lasting 4 s and a few premature ventricular beats. The

Holter monitor	each lasting 4 s and a few premature ventricular beats. The patient had no symptoms during the period of Holter monitoring

What is the next best step in management of this patient?

A	Discontinue amiodarone
B	Discontinue warfarin
C	Discontinue warfarin and amiodarone
D	Refer the patient for electrophysiological study
E	Discontinue warfarin, amiodarone and digoxin

up visit. He has been diabetic for the last 5 years and had an anterior myocardial infarction 4 years ago. Subsequent coronary angiography revealed three-vessel disease and he underwent coronary artery bypass grafting. One year ago he was admitted with a history of palpitations, and electrocardiogram (ECG) showed atrial fibrillation but no ST segment changes. Serial cardiac enzymes were normal and echocardiography showed an ejection fraction of 23%. He was started on amiodarone and warfarin. Other medications include carvedilol 25 mg twice daily, fosinopril 20 mg/day, furosemide 40 mg twice daily, digoxin 0.25 mg/day and pravastatin 40 mg/day. Over the last one year he has had two recurrences of atrial fibrillation. Physical examination reveals a regular pulse of 68/min and no evidence of fluid retention.

Investigations show:

Sodium	135 mmol/l
Potassium	4.5 mmol/l

White cell count	$10 \times 10^9/L$
Digoxin Level	In therapeutic range
Thyroid function tests	normal
Electrocardiogram (ECG)	sinus rhythm with no QT prolongation
Holter monitor	no evidence of atrial fibrillation but two episode of non-sustained ventricular tachycardia (VT) each lasting 4 s and a few premature ventricular beats. The patient had no symptoms during the period of Holter monitoring

What is the next best step in

D Refer the patient for electrophysiological study

Patients with heart failure are at increased risk of sudden cardiac death from ventricular arrhythmias. Implantable cardioverter defibrillator devices (ICD) are indicated for primary prevention of sudden cardiac death in patients who have history of prior myocardial infarction and all of the following:

- non-sustained ventricular tachycardia (VT)
- inducible arrhythmias on electrophysiological testing
- left ventricular ejection fraction of less than 35% and no worse than New York Heart Association Class III functional classification of heart failure.

ICD is also recommended in familial cardiac conditions with high risk of sudden cardiac death such as long QT

ICD is also recommended in familial cardiac conditions with high risk of sudden cardiac death such as long QT syndrome, hypertrophic cardiomyopathy, Brugada syndrome, arrhythmogenic right ventricular dysplasia and following repair of tetralogy of Fallot. Therefore, this patient should be evaluated by electrophysiological studies (EPS) and if inducible arrhythmias are documented an ICD should be placed. Some trials like MADIT II have also found that ICD implantation in such patients without EPS also leads to reduction in mortality, although guidelines are yet to completely reflect this information.

A Discontinue amiodarone

Amiodarone can reduce the paroxysms of atrial fibrillation and is usually well tolerated in patients with heart failure.

B Discontinue warfarin

A 60-year-old man on long-term haemodialysis presents with chest pain and a troponin of 1.2. He is next due to dialyse the following morning. There is T-wave inversion in the lateral leads which was not present on a 12-lead ECG from 2 months earlier. He does not have pulmonary oedema. The pain is only partially relieved by a small dose of intravenous (IV) diamorphine.

Which would be the most appropriate acute cardiovascular management for this man?

A	Aspirin and iv nitrates
B	Aspirin, iv nitrates and abciximab
C	Ticagrelor, aspirin, iv nitrates, iv furosemide and treatment dose LMWH
D	Ticagrelor, aspirin, iv nitrates and unfractionated heparin

not have pulmonary oedema. The pain is only partially relieved by a small dose of intravenous (IV) diamorphine.

Which would be the most appropriate acute cardiovascular management for this man?

A	Aspirin and iv nitrates
B	Aspirin, iv nitrates and abciximab
C	Ticagrelor, aspirin, iv nitrates, iv furosemide and treatment dose LMWH
D	Ticagrelor, aspirin, iv nitrates and unfractionated heparin
E	Reassure the patient that the raised troponin level is due to his kidney disease

A 60-year-old man on long-term haemodialysis presents with chest pain and a troponin of 1.2. He is next due to dialyse the following morning. There is T-wave inversion in the lateral leads which was not present on a 12-lead ECG from 2 months earlier. He does not have pulmonary oedema. The pain is only partially relieved by a small dose of intravenous (IV) diamorphine.

Which would be the most appropriate acute cardiovascular management for this man?

Your answer was incorrect

A	Aspirin and iv nitrates
B	Aspirin, iv nitrates and abciximab
C	Ticagrelor, aspirin, iv nitrates, iv furosemide and treatment dose LMWH

D Ticagrelor, aspirin, iv nitrates and unfractionated heparin

This man is on long-term haemodialysis, and his new ECG changes raise the possibility of an NSTEMI. Current ESC guidelines recommend aspirin, ticagrelor and fondaparinux in patients presenting with NSTEMI. Fondaparinux is not recommended in patients with eGFR <20; in such patients, options include LMWH (with dose reduction to 1 mg/kg OD; not recommended if eGFR <15) or unfractionated heparin, which does not require a dose reduction. Ticagrelor was evaluated in the PLATO trial, which demonstrated reduced rates of cardiovascular mortality, MI, stroke and all-cause mortality when compared with clopidogrel, without an associated increase in major bleeding side effects.

C Ticagrelor, aspirin, iv nitrates, iv furosemide and treatment dose LMWH

C Ticagrelor, aspirin, iv nitrates, iv furosemide and treatment dose LMWH

The longer patients are on dialysis the less likely they will be passing urine. Furosemide would not off-load the patient unless he was passing urine. In any respect, he is not in failure. Given his kidney disease, treatment dose LMWH would not be an appropriate option either, with ESC guidelines recommending a dose reduction for those with stage IV CKD, and stating that LMWH is not recommended for those with stage V CKD.

A Aspirin and iv nitrates

Nitrates are useful for pain in this case but do not impact on overall prognosis. Nitrates and aspirin alone would not represent an adequate combination of therapies for this patient.

B Aspirin, iv nitrates and

combination of therapies for this patient.

B	Aspirin, iv nitrates and abciximab

Per the ESC guidelines, there are no specific recommendations for the use of abciximab, or for dose adjustment in the case of kidney disease. Careful evaluation of haemorrhagic risk is needed. In any case, current guidance states that it is not recommended to administer GPIIb/IIIa inhibitors in patients in whom coronary anatomy is not known.

E	Reassure the patient that the raised troponin level is due to his kidney disease

This patient has ongoing chest pain, ECG changes and a raised troponin. It would be inappropriate to reassure without further investigation and treatment.

A 72-year-old man comes for a review in the cardiology clinic. He had an inferolateral myocardial infarction that was thrombolysed 4 weeks ago. He had recovered uneventfully and was discharged on the fifth day post-myocardial infarction (MI). Now he comes to your clinic and he is asymptomatic. Regular medication includes atenolol 100 mg and ramipril 10 mg. On examination his blood pressure is 135/80 mmHg and his pulse is 40/min and regular.

Investigations:

Echocardiogram	Normal
Electrocardiogram (ECG)	Sinus bradycardia with RR interval of 2.0 s, Q waves in leads II, III, aVF, V5–V6

What would you do for this patient?

A	Give adrenaline

Investigations:

Echocardiogram	Normal
Electrocardiogram (ECG)	Sinus bradycardia with RR interval of 2.0 s, Q waves in leads II, III, aVF, V5–V6

What would you do for this patient?

A	Give adrenaline
B	Give atropine
C	Give isoprenaline
D	Insert a permanent pacemaker
E	Reduce his atenolol

A 72-year-old man comes for a review in the cardiology clinic. He had an inferolateral myocardial infarction that was thrombolysed 4 weeks ago. He had recovered uneventfully and was discharged on the fifth day post-myocardial infarction (MI). Now he comes to your clinic and he is asymptomatic. Regular medication includes atenolol 100 mg and ramipril 10 mg. On examination his blood pressure is 135/80 mmHg and his pulse is 40/min and regular.

Investigations:

Echocardiogram	Normal
Electrocardiogram (ECG)	Sinus bradycardia with RR interval of 2.0 s, Q waves in leads II, III, aVF, V5–V6

What would you do for this patient?

A	Give adrenaline

Investigations:

Echocardiogram	Normal
Electrocardiogram (ECG)	Sinus bradycardia with RR interval of 2.0 s, Q waves in leads II, III, aVF, V5–V6

What would you do for this patient?

A	Give adrenaline
B	Give atropine
C	Give isoprenaline
D	Insert a permanent pacemaker
E	Reduce his atenolol

A 72-year-old man comes for a review in the cardiology clinic. He had an inferolateral myocardial infarction that was thrombolysed 4 weeks ago. He had recovered uneventfully and was discharged on the fifth day post-myocardial infarction (MI). Now he comes to your clinic and he is asymptomatic. Regular medication includes atenolol 100 mg and ramipril 10 mg. On examination his blood pressure is 135/80 mmHg and his pulse is 40/min and regular.

Investigations:

Echocardiogram	Normal
Electrocardiogram (ECG)	Sinus bradycardia with RR interval of 2.0 s, Q waves in leads II, III, aVF, V5–V6

What would you do for this patient?

Your answer was incorrect

E Reduce his atenolol

This man is likely to be over-beta-blocked. Management of choice would be to reduce his atenolol to 50 mg and arrange follow-up with his GP.

D Insert a permanent pacemaker

Pacemaker insertion may be used for treatment of symptomatic complete heart block. In this scenario, the heart rate would improve with reduction in atenolol. There is no heart block here.

A Give adrenaline

Adrenaline is given in a number of conditions, including anaphylaxis, cardiac arrest and superficial bleeding. Side effects include shakiness, anxiety and sweating. It is not a cardiac arrest situation in this scenario and therefore adrenaline is the wrong option.

conditions, including anaphylaxis, cardiac arrest and superficial bleeding. Side effects include shakiness, anxiety and sweating. It is not a cardiac arrest situation in this scenario and therefore adrenaline is the wrong option.

B Give atropine

Atropine is given for reversing bradycardia and hypotension in beta-blocker overdose. This patient's blood pressure is normal, and therefore although he is over-beta-blocked there is no need for urgent reversal; instead, reduction in atenolol will be sufficient.

C Give isoprenaline

Isoprenaline is a medication used for treatment of bradycardia, heart block and rarely for asthma. This patient's blood pressure is normal, and therefore although he is over-beta-blocked, there is no need for urgent reversal; instead, reduction in atenolol will be sufficient.

A 45-year-old male presents with history of left precordial pain that started 2 hours ago when he was watching television after dinner. The pain is moderate in intensity, radiates to ulnar aspects of both arms and is associated with nausea and one episode of vomiting. He is an accountant and has a 20 pack-year history of smoking. He consumes 3–4 glasses of wine each week and generally has a sedentary lifestyle. Physical examination reveals a pulse rate of 77/min, blood pressure 150/90 mmHg and respiratory rate of 14/min. There is no jugular venous distension, heart sounds are normal and lungs are clear to auscultation. A chest X-ray is normal.

A 12-lead electrocardiogram (ECG) is obtained and is shown below.

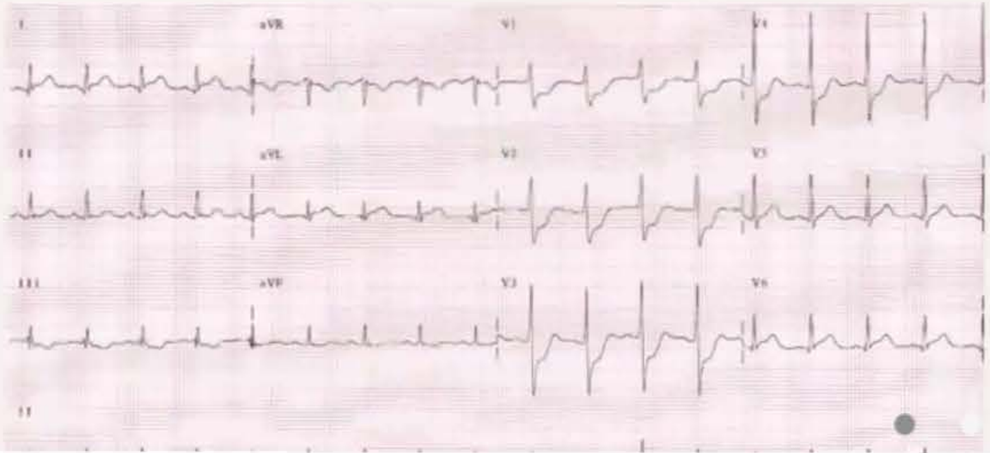

Calculator

Normal Values

A 12-lead electrocardiogram (ECG) is obtained and is shown below.

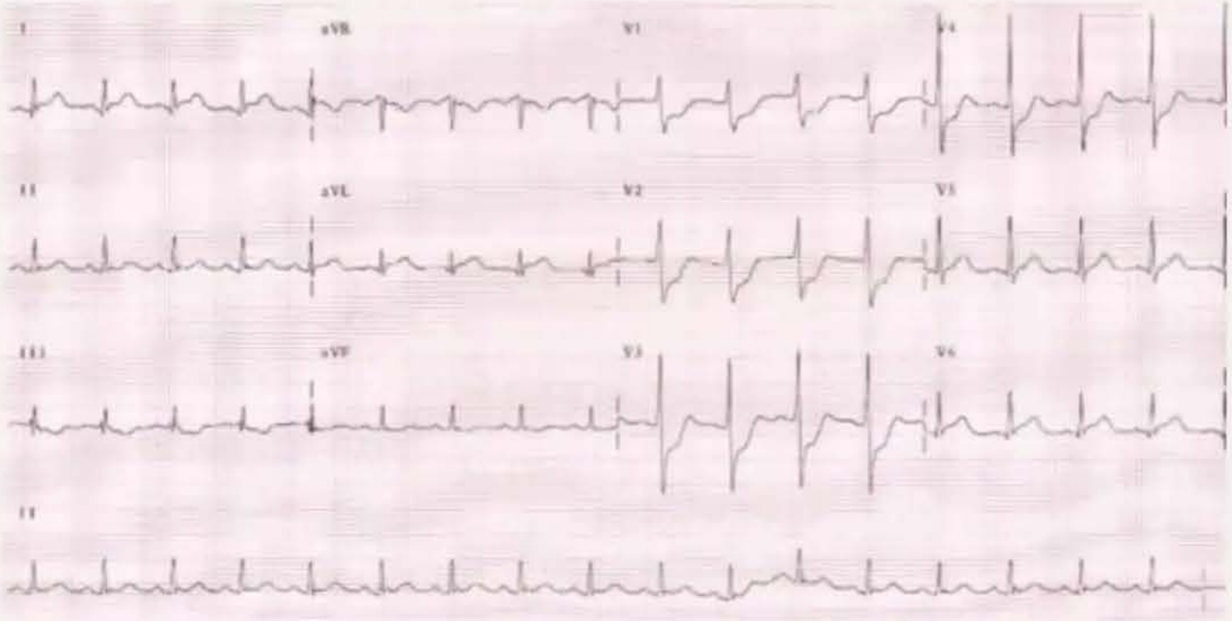

What is the coronary artery that supplies most of the affected territory?

A Left main coronary artery

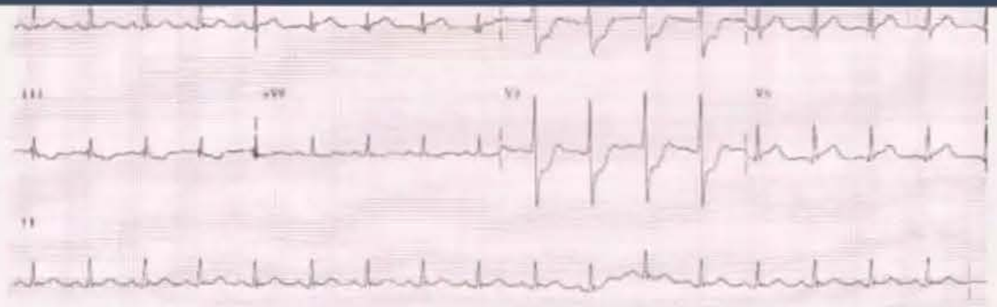

What is the coronary artery that supplies most of the affected territory?

A	Left main coronary artery
B	Left circumflex artery
C	Left anterior descending artery
D	Right coronary artery
E	Ramus/intermediate artery

Explanation

D Right coronary artery

This patient has presented with typical features suggestive of an acute coronary syndrome. The ECG shows ST-depression in the anterior chest leads (V_1-V_4), upright T-waves and prominent R-waves. These features highlight a posterior myocardial infarction. The posterior aspect of the myocardium is normally supplied by the right coronary artery (right coronary artery supply of the posterior aspect is present in 70% of patients). If the ECG of this patient was repeated with the leads V_1-V_6 repositioned on the posterior aspect of the chest (labelled as V_7-V_{12}), then a ST-elevation picture is seen (as shown in the figure below).

B Left circumflex artery

The left circumflex artery supplies the lateral aspect of the left ventricle. This is represented in the ECG by leads I, V_5 and V_6. There are no lateral changes seen in the above ECG.

A Left main coronary artery

The left coronary artery supplies the septal, anterior and lateral aspects of the left ventricle. In most cases it bifurcates into the left anterior descending artery and the left circumflex artery. Obstruction of this artery would present typically with widespread changes across

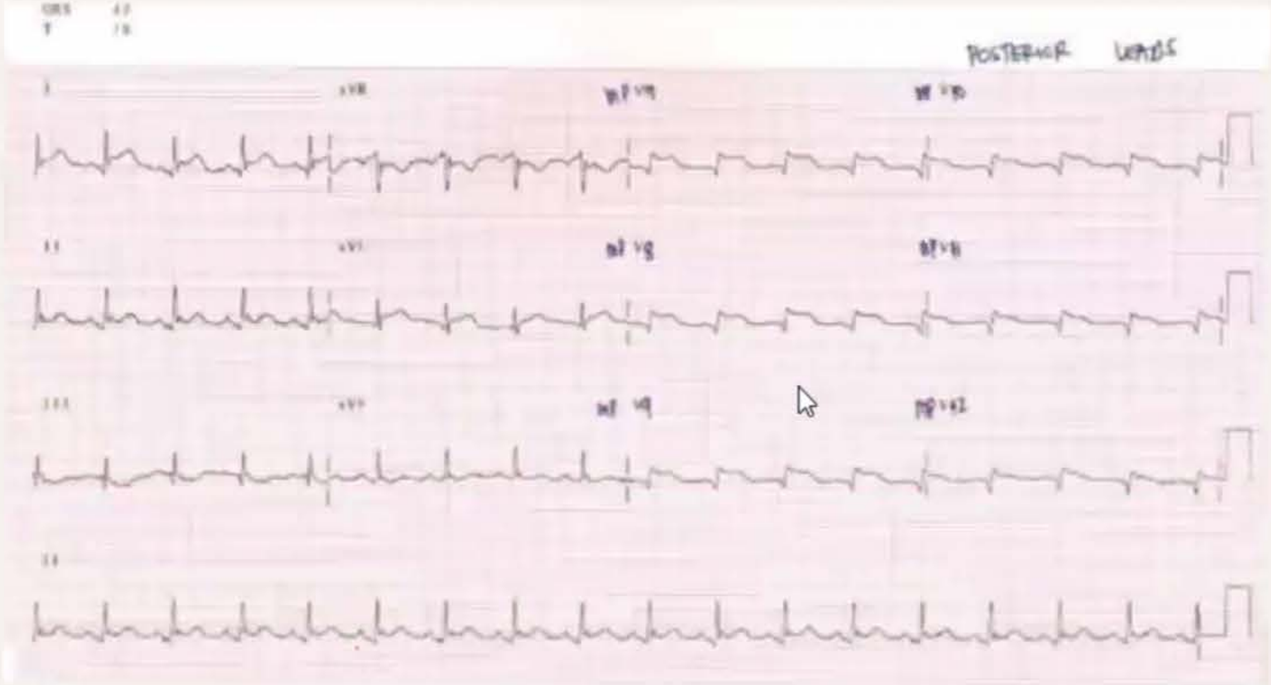

70194

Rate this question:

The left coronary artery supplies the septal, anterior and lateral aspects of the left ventricle. In most cases it bifurcates into the left anterior descending artery and the left circumflex artery. Obstruction of this artery would present typically with widespread changes across the ECG.

C Left anterior descending artery

The left anterior descending artery supplies the anterior aspect of the left ventricle and the anterior 2/3 of the interventricular septum. This is represented on the ECG as leads V_1-V_4. The above ECG could be confused as an NSTEMI in the anterior septal region. However, the prominent R-waves and upright T-waves should point you towards a posterior MI.

E Ramus/intermediate artery

The intermediate artery is an additional artery that can form as a trifurcation where the left main stem splits into the left anterior descending artery and the left circumflex artery. It is present in around 20% of the population and can supply variable extents of the anterior and lateral aspects of the left ventricle.

Calculator

Normal Values

You are a cardiology senior house officer in the outpatient department. A 66-year-old woman comes for her annual review. She had a mechanical valve replacement 4 years ago, for severe aortic stenosis. She has been well until 3 weeks ago. Her present complaint is that of weight loss, poor appetite and breathlessness. She reports that the symptoms started after she attended a general surgical appointment for rectal bleeding.

On examination she is thin with conjunctival pallor. There is evidence of splinter haemorrhages on both hands. A metallic valve click is not audible at the bedside and on auscultation of the heart sounds, a normal first sound is heard with a soft metallic second sound. There is an ejection systolic murmur at the second right intercostal space, right sternal edge. There is also an early diastolic murmur at the lower left sternal edge accentuated by forced expiration.

You arrange urgent admission for this lady with a diagnosis of infective endocarditis on the metallic valve prosthesis. A trans-oesophageal echocardiogram is awaited.

Which of the following investigations is most important in guiding further management?

A Urinalysis

B Blood cultures

sound. There is an ejection systolic murmur at the second right intercostal space, right sternal edge. There is also an early diastolic murmur at the lower left sternal edge accentuated by forced expiration.

You arrange urgent admission for this lady with a diagnosis of infective endocarditis on the metallic valve prosthesis. A trans-oesophageal echocardiogram is awaited.

Which of the following investigations is most important in guiding further management?

A	Urinalysis
B	Blood cultures
C	12-lead ECG
D	Urgent abdominal ultrasound
E	Urgent colonoscopy

Explanation

B Blood cultures

This lady is unwell with prosthetic valve endocarditis, as evident by the examination findings mentioned in the question stem. While all the above tests are reasonable, the question is for the investigation most important in guiding further management.

Blood cultures is the correct answer because these will enable antibiotic therapy to be targeted within 48 h of starting treatment. Because bacteraemia may be periodic, blood cultures should be taken from separate sites, ideally 1 h apart if possible.

E Urgent colonoscopy

Intra-abdominal pathology, including colonic carcinoma, is a possible source of infecting organisms in this case, namely *Streptococcus gallolyticus* (formerly *S. bovis*). However, blood cultures would be the way to confirm the infecting organism in question.

A Urinalysis

B Blood cultures

This lady is unwell with prosthetic valve endocarditis, as evident by the examination findings mentioned in the question stem. While all the above tests are reasonable, the question is for the investigation most important in guiding further management.

Blood cultures is the correct answer because these will enable antibiotic therapy to be targeted within 48 h of starting treatment. Because bacteraemia may be periodic, blood cultures should be taken from separate sites, ideally 1 h apart if possible.

E Urgent colonoscopy

Intra-abdominal pathology, including colonic carcinoma, is a possible source of infecting organisms in this case, namely *Streptococcus gallolyticus* (formerly *S. bovis*). However, blood cultures would be the way to confirm the infecting organism in question.

A Urinalysis

This will help to confirm the diagnosis in mind but not alter the management plan.

This will help to confirm the diagnosis in mind but not alter the management plan.

C 12-lead ECG

First-degree heart block, if new, might suggest aortic root abscess with AV nodal injury. While this information will certainly help us gauge the severity of the infection, it will not guide our choice of antibiotics.

D Urgent abdominal ultrasound

It may help to detect evidence of septic emboli, for example splenic infarction, it will not indicate the organism responsible for targeted treatment.

32316
Rate this question:

A 38-year-old female presents with history of progressive shortness of breath of 3 months' duration. She gets short of breath on ordinary physical activity at home. She has also noticed swelling of the feet and abdomen. On physical examination her pulse rate is 96/min, and she has a regular blood pressure 110/70 mmHg and respiratory rate of 20/min. She has jugular venous distension, bibasilar inspiratory crepitations, diminished first heart sound and widely split second heart sound with loud pulmonary component. A rumbling diastolic murmur is heard at the apex.

Calculator

Normal Values

Investigations show:

Sodium	135 mmol/l
Potassium	4.5 mmol/l
Urea	8 mmol/l
Creatinine	70 µmol/l
Haemoglobin	14 g/dL
White cell count	10x 10^9/L
Electrocardiogram (ECG)	Left atrial hypertrophy, right ventricular hypertrophy and right axis deviation

A 38-year-old female presents with history of progressive shortness of breath of 3 months' duration. She gets short of breath on ordinary physical activity at home. She has also noticed swelling of the feet and abdomen. On physical examination her pulse rate is 96/min, and she has a regular blood pressure 110/70 mmHg and respiratory rate of 20/min. She has jugular venous distension, bibasilar inspiratory crepitations, diminished first heart sound and widely split second heart sound with loud pulmonary component. A rumbling diastolic murmur is heard at the apex.

Calculator

Normal Values

Investigations show:

Sodium	135 mmol/l
Potassium	4.5 mmol/l
Urea	8 mmol/l
Creatinine	70 µmol/l
Haemoglobin	14 g/dL
White cell count	10x 10^9/L
Electrocardiogram (ECG)	Left atrial hypertrophy, right ventricular hypertrophy and right axis deviation

Chest X-ray	Straightening of the left heart border and prominent pulmonary arteries and Kerley B lines
Echocardiogram	Heavily calcified mitral leaflets, mitral area 0.9 cm^2 and pulmonary hypertension

What is the most appropriate management of this patient?

A Observe and follow up in clinic in 2 weeks

B Mitral valve replacement

C Blood cultures and intravenous antibiotics

D Medical therapy

E Percutaneous mitral valvotomy

Explanation

B Mitral valve replacement

This patient has severe symptomatic mitral stenosis and therefore should have either valvotomy or mitral valve replacement. Most of these patients can be managed with percutaneous mitral balloon valvotomy unless they have contraindications. Contraindications to percutaneous balloon valvotomy include:

- moderate to severe mitral regurgitation
- left atrial thrombus
- heavily calcified mitral valve
- concomitant coronary artery or other valve disease requiring surgery.

These patients should undergo mitral valve replacement.

A Observe and follow up in clinic in 2 weeks

This patient has severe symptomatic mitral stenosis and therefore to merely observe the patient will not suffice as symptoms will worsen.

A Observe and follow up in clinic in 2 weeks

This patient has severe symptomatic mitral stenosis and therefore to merely observe the patient will not suffice as symptoms will worsen.

C Blood cultures and intravenous antibiotics

There is no suspicion of bacterial endocarditis therefore blood cultures and intravenous antibiotics is inappropriate. For bacterial endocarditis in addition to a new onset murmur there may be fever, Janeway lesions and Roth's spots.

D Medical therapy

This patient has severe symptomatic mitral stenosis therefore surgery is in preference to medical therapy. Medical management is reserved for patients who are asymptomatic or mitral stenosis is not severe.

E Percutaneous mitral valvotomy

This patient has a contraindication to valvotomy because she has a heavily calcified mitral

There is no suspicion of bacterial endocarditis therefore blood cultures and intravenous antibiotics is inappropriate. For bacterial endocarditis in addition to a new onset murmur there may be fever, Janeway lesions and Roth's spots.

D Medical therapy

This patient has severe symptomatic mitral stenosis therefore surgery is in preference to medical therapy. Medical management is reserved for patients who are asymptomatic or mitral stenosis is not severe.

E Percutaneous mitral valvotomy

This patient has a contraindication to valvotomy because she has a heavily calcified mitral valve.

7470

Rate this question:

Next Question

Calculator

Normal Values

A 23-year-old trainee solicitor comes to the Emergency Department with his third episode of paroxysmal supraventricular tachycardia (SVT) in the last 3 months. He has recently been diagnosed with Wolff–Parkinson–White (WPW) syndrome. He doesn't drink alcohol but drinks up to four cups of coffee per day. On this occasion he collapsed while giving a presentation at his office. He is already taking a moderate dose of sotalol as prophylaxis against further events. His BP is 95/60 mmHg, with pulse 160/min and regular. He is electrically cardioverted.

Which of the following is the most appropriate next step?

A	Add amiodarone
B	List for implantable cardioverter defibrillator
C	Refer for electrophysiology studies
D	Switch to verapamil
E	Teach him to use the Valsalva manoeuvre

Heart rhythm conditions over...
pathways.nice.org.uk/pathways/h...

Explanation

C Refer for electrophysiology studies

Given that this man remains symptomatic despite treatment with a b-blocker, sotalol, he is very likely to have further episodes of supraventricular tachycardia (SVT). The episodes are significantly impacting on his ability to do his job, and hence a definitive intervention is required. Electrophysiology studies (option C) followed by consideration of radiofrequency ablation is the logical next step.

A Add amiodarone

Amiodarone is occasionally used in tachyarrhythmias, including WPW, but would not be indicated in this situation.

B List for implantable cardioverter defibrillator

An implantable cardioverter defibrillator (ICD) is not indicated for WPW syndrome. The indications for insertion are clear and outlined in NICE guidance.

Given that this man remains symptomatic despite treatment with a b-blocker, sotalol, he is very likely to have further episodes of supraventricular tachycardia (SVT). The episodes are significantly impacting on his ability to do his job, and hence a definitive intervention is required. Electrophysiology studies (option C) followed by consideration of radiofrequency ablation is the logical next step.

A Add amiodarone

Amiodarone is occasionally used in tachyarrhythmias, including WPW, but would not be indicated in this situation.

B List for implantable cardioverter defibrillator

An implantable cardioverter defibrillator (ICD) is not indicated for WPW syndrome. The indications for insertion are clear and outlined in NICE guidance.

D Switch to verapamil

Switching anti-arrhythmics from sotalol to verapamil is unlikely to change this patient's

indicated in this situation.

B List for implantable cardioverter defibrillator

An implantable cardioverter defibrillator (ICD) is not indicated for WPW syndrome. The indications for insertion are clear and outlined in NICE guidance.

D Switch to verapamil

Switching anti-arrhythmics from sotalol to verapamil is unlikely to change this patient's symptoms. Verapamil may increase the ventricular rate in WPW and is best avoided here.

E Teach him to use the Valsalva manoeuvre

Teaching him vagal manoeuvres to abort the rhythm disturbance is a poor substitute for definitive treatment. It would be reasonable if he had very infrequent episodes of arrhythmia.

Rate this question:

A 54-year-old man with a past history of hypertension and smoking presents to the Emergency department. He has suffered central chest pain radiating to his back for 2h prior to presenting at the emergency department. He is hypotensive with a blood pressure of 80/60 mmHg and has a pulse of 105/min. There are bilateral basal crackles on auscultation of the chest. Electrocardiogram (ECG) shows evidence of inferior ST elevation. Transoesophageal echocardiogram reveals a double lumen in the ascending aorta.

Calculator

Normal Values

Which diagnosis fits best with this clinical picture?

A	Aortic dissection
B	Degenerative thoracic aneurysm
C	Inferior myocardial infarction
D	Anterior myocardial infarction
E	Haemopericardium

A Aortic dissection

With the history of chest pain radiating to the back and haemodynamic compromise, aortic dissection is the top of the differential diagnosis. Risk factors include male, hypertension and smoking. The presence of double lumen in the ascending aorta is indicative of aortic dissection. Inferior ST elevation indicates the involvement of the RCA due to the extension of the dissection proximally towards the coronary sinus.

Case series of dissecting aneurysms put 5-year survival in the region of 70–80% with optimal medical/surgical input in a centre of excellence. Aortic dissections which compromise the coronary arteries present a particular challenge. They are usually managed with an endovascular stenting approach but where hypotension and ischaemia exist as here, prognosis is particularly poor.

B Degenerative thoracic aneurysm

Degenerative thoracic aneurysm is unlikely to present acutely unless the aneurysm ruptured or dissected.

C Inferior myocardial infarction

description of chest pain radiating to the back makes it more likely to be dissection and this is confirmed with TOE.

D Anterior myocardial infarction

ST elevation was present in the inferior leads, therefore making anterior MI unlikely.

E Haemopericardium

Haemopericardium could be present due to leaking of blood from the ruptured aorta and could lead to haemodynamic compromise. However, in the absence of trauma, the most likely cause would be a ruptured aortic dissection.

Rate this question:

Next Question

C Inferior myocardial infarction

The presence of inferior ST elevation makes this a possible differential diagnosis and it would be impossible to differentiate without the findings on echocardiogram. However, the description of chest pain radiating to the back makes it more likely to be dissection and this is confirmed with TOE.

D Anterior myocardial infarction

ST elevation was present in the inferior leads, therefore making anterior MI unlikely.

E Haemopericardium

Haemopericardium could be present due to leaking of blood from the ruptured aorta and could lead to haemodynamic compromise. However, in the absence of trauma, the most likely cause would be a ruptured aortic dissection.

Rate this question:

Next Question

A 23-year-old woman presents with worsening shortness of breath. Past medical history of note includes laparoscopic appendicectomy 6 months earlier, complicated by intra-abdominal haemorrhage and admission to ITU. She has suffered multiple admissions over the past months for cardiac failure and has been noted to have pulmonary hypertension on echocardiogram. On examination she is apyrexial, BP 162/90 mmHg and pulse 90/min. A murmur is heard over the left groin.

Calculator

Normal Values

Investigations:

R. atrial pressure	15 mmHg
Saturation	91% in IVC
Mean pulmonary artery pressure	38 mmHg

What is the most likely underlying cause?

A Congenital AV malformation

B Patent ductus arteriosus

investigations:

R. atrial pressure	15 mmHg
Saturation	91% in IVC
Mean pulmonary artery pressure	38 mmHg

What is the most likely underlying cause?

A Congenital AV malformation

B Patent ductus arteriosus

C ASD

D Iatrogenic AV fistula

E VSD

A 23-year-old woman presents with worsening shortness of breath. Past medical history of note includes laparoscopic appendicectomy 6 months earlier, complicated by intra-abdominal haemorrhage and admission to ITU. She has suffered multiple admissions over the past months for cardiac failure and has been noted to have pulmonary hypertension on echocardiogram. On examination she is apyrexial, BP 162/90 mmHg and pulse 90/min. A murmur is heard over the left groin.

Investigations:

R. atrial pressure	15 mmHg
Saturation	91% in IVC
Mean pulmonary artery pressure	38 mmHg

What is the most likely underlying cause?

Your answer was correct

Difficulty: Average

Peer Responses %

Session Progress

Responses Correct:	4
Responses Incorrect:	2
Responses Total:	6

Explanation

D Iatrogenic AV fistula

Central venous catheterisation is a rare cause of iatrogenic AV fistula. Central venous catheterisation has likely led to a fistula between the IVC and the iliac artery, with the consequence that right-sided circulatory pressures are significantly increased. The treatment of choice is stent repair of the iliac artery, which is likely to lead to resolution of her symptoms. Significantly raised right-sided cardiac pressures are also seen as a natural rather than an iatrogenic phenomenon in patients with significant arterio-venous malformations.

A Congenital AV malformation

While congenital AV malformation could lead to raised right-sided pressures, the recent onset of symptoms and history of ITU admission make iatrogenic AV fistula a more likely diagnosis.

B Patent ductus arteriosus

Patent ductus arteriosus is associated with a dilated and hypertrophied left ventricle, and

make iatrogenic AV fistula a more likely diagnosis in this case.

E	VSD

Depending on size, VSDs often present in childhood with dyspnoea and failure to thrive. They are associated with a pansystolic murmur at the lower left sternal border. While VSDs can be associated with pulmonary hypertension, and subsequent Eisenmenger syndrome, the history of recent ITU admission and murmur over the groin make iatrogenic AV fistula a more likely diagnosis in this case.

32345

Rate this question:

Next Question

You are running in the local park when a 58-year-old man training next to you suddenly clutches his chest and sits down. He complains of central crushing chest pain.

While you are talking to him he collapses. He is pulseless, unconscious and making no respiratory effort. The park is empty apart from you and him.

Which of the following is the most appropriate next step?

Calculator

Normal Values

A	Give a precordial thump
B	Look for a defibrillator
C	Shout for help/call 999
D	Start chest compressions
E	Start mouth-to-mouth

Explanation

C	Shout for help/call 999

The guidelines for basic life support (BLS) are clear and simple to follow. The key first step is to enlist help/ensure that someone dials 999 or attempts to find an automated external defibrillator (AED). Many public areas are equipped with this type of equipment because time to defibrillation is crucial with respect to survival.

The four key steps of the Resuscitation Council 'chain of survival' are:

1. Early recognition and call for help
2. Early bystander CPR
3. Early defibrillation
4. Early advance life support and standardised post-resuscitation care.

A	Give a precordial thump

Give a precordial thump, is no longer recommended as part of the guidelines. To be successful it needs to be delivered within 2–3 s of the onset of ventricular fibrillation (VF) or ventricular tachycardia (VT) and has a very low success rate.

External Links

Resuscitation guidelines
resus.org.uk/resuscitation-guideli...

You have just finished resuscitating a 69-year-old lady who was in ventricular fibrillation (VF). You managed to cardiovert her back to sinus rhythm after three shocks at 360 J. This is the second time she has had VF. The first time was about 6 h ago and she was cardioverted back to sinus rhythm. This lady had suffered an anterior myocardial infarction (MI) and was thrombolysed two days previously. She is taking aspirin 75 mg, isosorbide mononitrate 30 mg bd and atenolol 50 mg od.

Calculator

Normal Values

Investigations:

Haemoglobin (Hb)	14.1 g/dl
White cell count (WCC)	12.3×10^9
Platelets	203×10^9
Mean corpuscular volume (MCV)	80.1 fl
Sodium	132 mmol/l
Potassium	4.1 mmol/l
Urea	7.2 mmol/l
Creatinine	121 µmol/l

Creatinine	121 µmol/l
$P(O_2)$	23 kPa
$P(CO_2)$	3.1 kPa
PH	7.29

What prophylactic medication would you start her on to prevent further arrhythmias?

A Amiodarone infusion

B Flecainide

C Lidocaine infusion

D Propafenone

E Verapamil

Explanation

A Amiodarone infusion

Amiodarone infusion should be started (300 mg over the first hour and then 900 mg over the next 23 h), and then oral doses should be continued.

B Flecainide

Flecainide has been shown to be associated with increased mortality in studies that have been done in patients with arrythmias post-myocardial infarction. and should be avoided.

C Lidocaine infusion

Lignocaine is negatively inotropic and would therefore be a subsidiary choice in this situation.

D Propafenone

Propafenone has been shown to be associated with increased mortality in studies that have

been done in patients with arrythmias post-myocardial infarction. and should be avoided.

C Lidocaine infusion

Lignocaine is negatively inotropic and would therefore be a subsidiary choice in this situation.

D Propafenone

Propafenone has been shown to be associated with increased mortality in studies that have been done in patients with arrythmias post-myocardial infarction, and should be avoided.

E Verapamil

Verapamil is negatively inotropic, so would not be a good choice in this scenario.

7554

Rate this question:

Next Question

A 19-year-old student with no past medical history is admitted from home with palpitations. He does not admit to having taken any alcohol or illicit drugs. On further questioning he states he has suffered palpitations on two or three occasions at night over the past few months, but says that these resolved spontaneously. On one occasion he went to A&E and underwent an ECG, but was discharged without further investigation. On examination on this admission he has a BP of 110/70 mmHg, with a pulse of 170/min. There are no features of cardiac failure on examination.

Calculator

Normal Values

Investigations:

Hb	12.9 g/dl
WCC	5.2 x10⁹/l
PLT	195 x10⁹/l
Na+	140 mmol/l
K+	4.9 mmol/l
Creatinine	100 µmol/l
ECG	Regular narrow complex tachycardia, ventricular rate 170/min (previous ECG

A 19-year-old student with no past medical history is admitted from home with palpitations. He does not admit to having taken any alcohol or illicit drugs. On further questioning he states he has suffered palpitations on two or three occasions at night over the past few months, but says that these resolved spontaneously. On one occasion he went to A&E and underwent an ECG, but was discharged without further investigation. On examination on this admission he has a BP of 110/70 mmHg, with a pulse of 170/min. There are no features of cardiac failure on examination.

Calculator

Normal Values

Investigations:

Hb	12.9 g/dl
WCC	5.2 x10⁹/l
PLT	195 x10⁹/l
Na+	140 mmol/l
K+	4.9 mmol/l
Creatinine	100 µmol/l
ECG	Regular narrow complex tachycardia, ventricular rate 170/min (previous ECG showed normal sinus rhythm)

Creatinine	100 µmol/l
ECG	Regular narrow complex tachycardia, ventricular rate 170/min (previous ECG showed normal sinus rhythm)

Attempts at cardioversion with vagal manoeuvres have failed.

Which of the following is the most appropriate next management step?

A	Verapamil
B	DC cardioversion
C	Bisoprolol
D	Amiodarone
E	Adenosine

Explanation

E Adenosine

Current Resuscitation Council guidelines advocate an ABCDE approach to the initial management of tachycardia. Initial assessment should be made for adverse features including shock, heart failure, reduced conscious level and myocardial ischaemia. If these are present, management should be with synchronised DC cardioversion in the first instance.

In this case, the patient demonstrates a regular narrow complex tachycardia, without evidence of adverse features. Here, guidelines recommend vagal manoeuvres, followed by 6 mg adenosine if vagal manoeuvres fail to induce cardioversion. This can be followed by 12 mg adenosine if this is unsuccessful, and a further 12 mg should this prove unsuccessful. Adenosine has a number of contraindications including asthma.

A Verapamil

In cases of atrial fibrillation, diltiazem may be considered for rate control in the absence of evidence of heart failure; verapamil does not feature in current tachyarrythmia guidelines. Adenosine is the recommended first-line agent in the case of regular, narrow-complex tachycardia.

DC cardioversion is recommended in cases of instability, indicated by: reduced conscious level; systolic BP < 90; myocardial ischaemia; or features of heart failure.

C Bisoprolol

Beta-blockers may be considered for rate control in cases of atrial fibrillation, but adenosine is the recommended first-line agent for regular narrow-complex tachycardia.

D Amiodarone

Amiodarone may be considered in cases of unstable tachycardia unresponsive to DC cardioversion; pre-excited AF; VT; and AF if features of heart failure are present. Current Resuscitation Council guidelines recommend adenosine as first line in the case of narrow-complex regular tachycardia.

20950

Rate this question:

Next Question

Rajaa Adris' screen

Calculator

Normal Values

A 55-year-old male presents to the Emergency Department with a history of severe substernal chest pain of 4 h duration. He has been diabetic for five years, on metformin 500 mg three times per day and has a 20-pack year history of smoking. Apart from this, he has no past medical history of note.

He appears sweaty and anxious. His heart rate is 108 bpm, with blood pressure 75/50 mmHg. There is jugular venous distension and crepitations up to the lower end of the scapulae and S3 gallop. An electrocardiogram (ECG) shows 2 mm ST-segment elevation in leads V1–V5 and 2 mm ST-segment depression in leads II, III and aVF. Chest X-ray shows cardiomegaly and pulmonary congestion without any evidence of mediastinal widening or pericardial effusion. He is given chewable aspirin.

He remains hypotensive at 85/60 mmHg post-angioplasty and still has signs of heart failure.

Which of the following is the optimal way to manage his blood pressure?

A	Intra-aortic balloon pump
B	Fluid loading
C	IV adrenaline infusion

scapulae and S3 gallop. An electrocardiogram (ECG) shows 2 mm ST-segment elevation in leads V1–V5 and 2 mm ST-segment depression in leads II, III and aVF. Chest X-ray shows cardiomegaly and pulmonary congestion without any evidence of mediastinal widening or pericardial effusion. He is given chewable aspirin.

He remains hypotensive at 85/60 mmHg post-angioplasty and still has signs of heart failure.

Which of the following is the optimal way to manage his blood pressure?

A	Intra-aortic balloon pump
B	Fluid loading
C	IV adrenaline infusion
D	IV noradrenaline infusion
E	IV furosemide infusion

A 55-year-old male presents to the Emergency Department with a history of severe substernal chest pain of 4 h duration. He has been diabetic for five years, on metformin 500 mg three times per day and has a 20-pack year history of smoking. Apart from this, he has no past medical history of note.

He appears sweaty and anxious. His heart rate is 108 bpm, with blood pressure 75/50 mmHg. There is jugular venous distension and crepitations up to the lower end of the scapulae and S3 gallop. An electrocardiogram (ECG) shows 2 mm ST-segment elevation in leads V1–V5 and 2 mm ST-segment depression in leads II, III and aVF. Chest X-ray shows cardiomegaly and pulmonary congestion without any evidence of mediastinal widening or pericardial effusion. He is given chewable aspirin.

He remains hypotensive at 85/60 mmHg post-angioplasty and still has signs of heart failure.

Which of the following is the optimal way to manage his blood pressure?

Your answer was incorrect

A Intra-aortic balloon pump

B Fluid loading

Difficulty: Average

Peer Responses %

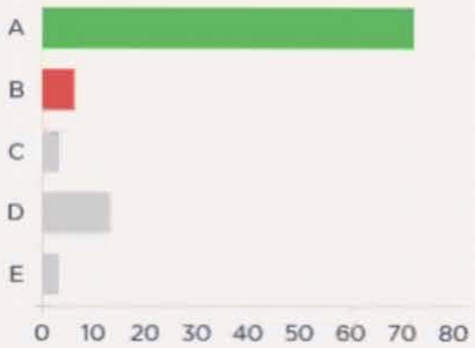

Session Progress

Responses Correct:	7
Responses Incorrect:	3
Responses Total:	10
Responses - % Correct:	70%

Explanation

A Intra-aortic balloon pump

This patient has presented with acute anterior myocardial infarction complicated by cardiogenic shock. Cardiogenic shock occurs in about 7% of cases of acute myocardial infarction; of these, 10% have this condition at admission and 90% develop it in hospital. Cardiogenic shock carries a high mortality. Management of cardiogenic shock in this setting involves circulatory support in the form of vasopressors such as IV dopamine and IABP, although evidence is weak for vasopressors in this scenario. Given, however, that his symptoms have not significantly improved post-revascularisation, he has a poor prognosis. One thing that is established beyond doubt is that angioplasty is superior to thrombolysis in this situation.

B Fluid loading

Given there is already jugular venous distension, fluid loading is less likely to be of benefit. It may indeed further worsen heart failure compared to using an IABP in this situation.

C IV adrenaline infusion

B Fluid loading

Given there is already jugular venous distension, fluid loading is less likely to be of benefit. It may indeed further worsen heart failure compared to using an IABP in this situation.

C IV adrenaline infusion

IV adrenaline in this scenario may improve BP in the short term, although it significantly increases the risk of arrhythmia and worsening of ischaemia.

D IV noradrenaline infusion

Like IV adrenaline, IV noradrenaline runs the risk of further worsening of ischaemia and the risk of rhythm disturbance.

E IV furosemide infusion

IV furosemide infusion may lead to further worsening of hypotension and threaten acute kidney disease in this situation.

A 48-year-old builder was admitted with chest pain which came on after carrying a pile of bricks. 48 hours later he is pain free. His electrocardiogram shows T-wave inversion in leads V2 to V6. Troponin T was 0.07 (normal <0.05)

Which of the following represents the best management for this patient?

Calculator

Normal Values

A	Arrange coronary angiogram
B	Arrange inpatient excercise stress test
C	Start to mobilise and if he is pain free he can be discharged
D	Discharge now and see him in clinic 4–6 weeks' time
E	Arrange outpatient treadmill test (stress test) in 4–6 weeks' time and discharge him now

Explanation

A Arrange coronary angiogram

This patient has an abnormal troponin T, which at above 0.05 now puts him into the range considered to be a myocardial infarction, with the T-wave inversion indicating a non-ST elevation event. Percutaneous coronary intervention (PCI) is recommended for NSTEMI and unstable angina (NICE, CG94: Unstable angina and NSTEMI: early management). Ideally, he should be subject to definitive coronary artery evaluation and the best way to do this is via coronary angiography following a careful risk benefit analysis after risk stratification (GRACE score).

B Arrange inpatient excercise stress test

In view of the abnormal troponin T, inpatient exercise testing should be avoided; this has been endorsed by recent NICE guidance.

C Start to mobilise and if he is pain free he can be discharged

A 60-year-old man presents to the casualty department with a history of headaches and palpitations. He has mild bilateral ankle swelling. Three weeks previously he was diagnosed by his GP as having hypertension and started on a new medication for this according to current guidelines.

Calculator

Normal Values

Investigations:

Hb	12.1 g/dl
WCC	5.0 x10⁹/l
PLT	220 x10⁹/l
Na^+	140 mmol/l
K^+	4.5 mmol/l
Creatinine	102 µmol/l

Given his new symptoms, which of the following is the most likely medication that he was commenced on?

Na^+	140 mmol/l
K^+	4.5 mmol/l
Creatinine	102 µmol/l

Given his new symptoms, which of the following is the most likely medication that he was commenced on?

A	Atenolol
B	Prazosin
C	Amlodipine
D	Bendroflumethiazide
E	Ramipril

Explanation

C Amlodipine

Amlodipine is a calcium antagonist, and is a first-line agent for the treatment of hypertension in this age group (>55 years). It is also most likely to cause ankle swelling, therefore making it the most probable agent here.

An ACE inhibitor is recommended as first-line treatment of hypertension in patients under 55 years; for patients >55 years, or for black patients of any age, a calcium antagonist should be chosen as a first step.

A Atenolol

Beta-blockers are not a preferred initial therapy for hypertension, though they may be considered in younger people such as women of child-bearing age. Beta-blockers are also strongly recommended in the treatment of hypertension in those with recent MI, and preferred in patients with other IHD.

B Prazosin

Beta-blockers are not a preferred initial therapy for hypertension, though they may be considered in younger people such as women of child-bearing age. Beta-blockers are also strongly recommended in the treatment of hypertension in those with recent MI, and preferred in patients with other IHD.

B Prazosin

This is an alpha-blocker used in the management of BPH, and in combination with other drugs in the treatment of resistant hypertension. It is not recommended as a first line anti-hypertensive agent.

D Bendroflumethiazide

This is a thiazide diuretic and is not a first-line anti-hypertensive choice. NICE recommend that a thiazide-like diuretic, such as chlortalidone or indapamide, should be given in preference to a conventional thiazide diuretic such as bendroflumethiazide or hydrochlorothiazide. While CCB is the first-line recommendation, if there is intolerance to CCB or evidence or risk of heart failure, then a thiazide-like diuretic would be a suitable first-line choice.

B Prazosin

This is an alpha-blocker used in the management of BPH, and in combination with other drugs in the treatment of resistant hypertension. It is not recommended as a first line anti-hypertensive agent.

D Bendroflumethiazide

This is a thiazide diuretic and is not a first-line anti-hypertensive choice. NICE recommend that a thiazide-like diuretic, such as chlortalidone or indapamide, should be given in preference to a conventional thiazide diuretic such as bendroflumethiazide or hydrochlorothiazide. While CCB is the first-line recommendation, if there is intolerance to CCB or evidence or risk of heart failure, then a thiazide-like diuretic would be a suitable first-line choice.

E Ramipril

This is an ACE inhibitor and would be a suitable choice as first-line agent for those under 55 years of age. As this patient is 60, current guidelines recommend use of a calcium channel blocker as first line.

systolic murmur which appears loudest over the thoracic spine. He has bilateral basal crackles consistent with heart failure, and mild pitting ankle oedema. A plain chest radiograph appears to show evidence of notching of the posterior ribs.

Which of the following is the most likely diagnosis?

Your answer was correct

A	Hypertrophic obstructive cardiomyopathy
B	Mitral regurgitation
C	Coarctation of the aorta
D	Ostium secundum atrial septal defect
E	Aortic stenosis

Explanation

Session Progress

Responses Correct:	10
Responses Incorrect:	3
Responses Total:	13
Responses - % Correct:	77%

Rajaa Adris' screen

E Aortic stenosis

Explanation

C Coarctation of the aorta

Whilst the classical sign of coarctation of the aorta is said to be radio-femoral delay, or differential blood pressures, we are not given this information here. Hence we have to make our diagnosis on the fairly limited information given. We are told that he is a traveller, which opens up a number of options with respect to congenital heart disease diagnoses, given that his mother did not wait for a paediatric check on the child and he has not used health services since. We are told that there is a late systolic murmur, loudest over the thoracic spine, and this is indeed a characteristic feature of coarctation of the aorta. Scalloping of the posterior ribs on CXR is another feature of long-standing coarctation. Echocardiography, coupled with magnetic resonance angiography, would be appropriate radiological investigations.

A Hypertrophic obstructive cardiomyopathy

Signs would typically include large a waves in the JVP, a double apex impulse, loud S4, the presence of S3 and a late systolic murmur due to outflow tract obstruction (± mitral

Explanation

C Coarctation of the aorta

Whilst the classical sign of coarctation of the aorta is said to be radio-femoral delay, or differential blood pressures, we are not given this information here. Hence we have to make our diagnosis on the fairly limited information given. We are told that he is a traveller, which opens up a number of options with respect to congenital heart disease diagnoses, given that his mother did not wait for a paediatric check on the child and he has not used health services since. We are told that there is a late systolic murmur, loudest over the thoracic spine, and this is indeed a characteristic feature of coarctation of the aorta. Scalloping of the posterior ribs on CXR is another feature of long-standing coarctation. Echocardiography, coupled with magnetic resonance angiography, would be appropriate radiological investigations.

A Hypertrophic obstructive cardiomyopathy

Signs would typically include large a waves in the JVP, a double apex impulse, loud S4, the presence of S3 and a late systolic murmur due to outflow tract obstruction (± mitral regurgitation), which increases in intensity with valsalva.

B Mitral regurgitation

This would classically produce a 'blowing' pansystolic murmur, often with a reduced or absent S1, heard loudest at the apex with radiation to the axilla. It may be associated with signs such as atrial fibrillation and ventricular hypertrophy.

D Ostium secundum atrial septal defect

Patients are often asymptomatic during early life and present in their 3rd or 4th decade. It is associated with right ventricular heave, a murmur loudest in the pulmonic area (which is usually a flow murmur related to excess volume over a normal pulmonary valve), and a split S2.

E Aortic stenosis

This would classically produce an ejection systolic murmur heard loudest in the aortic area with radiation to the carotids. There may be associated signs such as a 'heaving' apex beat, slow rising pulse or the presence of an S4.

0555
Rate this question:

A 47-year-old man is referred to the emergency department by his general practitioner because of a very high blood pressure. He is complaining of a severe headache and has vomited. He was being investigated for hypertension and is not on any medication.

On examination, he has mild dyspnoea with a blood pressure (BP) of 200/105 mmHg and a pulse of 90/min. Jugular venous pressure is not raised. First and second heart sounds are heard and there are no murmurs. There are bibasal crackles consistent with hypertensive left ventricular failure.

The other systems are entirely normal. The following results are obtained:

Chest X-ray	Normal
ECG	Sinus rhythm
Fundoscopy	Grade 2 hypertensive retinopathy
FBC, U/Es, LFTs, urinalysis and lipid profile	are within normal range

What is the best initial step in managing this patient's blood pressure?

A IV sodium nitroprusside

Chest X-ray	Normal
ECG	Sinus rhythm
Fundoscopy	Grade 2 hypertensive retinopathy
FBC, U/Es, LFTs, urinalysis and lipid profile	are within normal range

What is the best initial step in managing this patient's blood pressure?

A IV sodium nitroprusside

B Sublingual nifedipine

C Oral atenolol

D Oral captopril

E Reassurance and monitoring

Explanation

A IV sodium nitroprusside

This man has markedly elevated blood pressure and evidence of decompensation with evidence of LVF. IV sodium nitroprusside titrated for gradual BP reduction is an ideal choice for intervention. It leads to significant vasodilatation and will not only reduce blood pressure but will have a positive impact on the mild LVF seen here.

B Sublingual nifedipine

Sublingual nifedipine can reduce BP rapidly, although it has a short half-life, which can lead to rapid rebound in blood pressure. For this reason nitroprusside, which can be delivered as a continuous infusion, is preferred.

C Oral atenolol

Although atenolol will reduce blood pressure, it has a long half-life and may exacerbate cardiac failure; as such other interventions are preferred.

D Oral captopril

D Oral captopril

Like nifedipine, oral captopril has a relatively short half-life, nitroprusside as a titratable infusion is therefore the better option.

E Reassurance and monitoring

This patient is at risk of worsening left ventricular failure and / or an acute stroke due to his hypertension. Reassurance alone is therefore inappropriate.

A 62-year-old accountant presents with history of pain in both calves. The pain starts after walking three blocks and is described as cramping, and is relieved by rest. He has been a known hypertensive for the last 10 years, which is well controlled on ramipril. He has a 40-pack year history of smoking. A treadmill exercise test done two years ago was normal. He does not have any other past medical history of note.
On physical examination he has body mass index of 26, blood pressure of 125/75 mmHg, heart rate 75 beats/min, bilateral femoral bruits and absent dorsalis pedis pulses. Examination of the heart and respiratory system is normal.

Lipid profile results:

Total cholesterol	5.6 mmol/l
Low-density lipoprotein (LDL) cholesterol	3.5 mmol/l
High-density lipoprotein (HDL) cholesterol	1.2 mmol/l
Triglycerides	2.8 mmol/l

He is advised to continue bisoprolol 10 mg per day, and is also started on aspirin 100 mg per day, cilostazol 100 mg twice per day, low-fat diet and a supervised exercise training programme. On follow-up visit three months later his symptoms have improved and he is now able to walk five blocks without symptoms.

Calculator

Normal Values

High-density lipoprotein (HDL) cholesterol	1.2 mmol/l
Triglycerides	2.8 mmol/l

He is advised to continue bisoprolol 10 mg per day, and is also started on aspirin 100 mg per day, cilostazol 100 mg twice per day, low-fat diet and a supervised exercise training programme. On follow-up visit three months later his symptoms have improved and he is now able to walk five blocks without symptoms.

Repeat lipid profile:

Total cholesterol	6.0 mmol/l
Low-density lipoprotein (LDL) cholesterol	3.7 mmol/l
High-density lipoprotein (HDL) cholesterol	1.3 mmol/l
Triglycerides	2.4 mmol/l

Which of the following is the next best step in this patient's management?

A	Start a statin with an LDL target of <1.8 mmol/l
B	Stop bisoprolol

Low-density lipoprotein (LDL) cholesterol	3.7 mmol/l
High-density lipoprotein (HDL) cholesterol	1.3 mmol/l
Triglycerides	2.4 mmol/l

Which of the following is the next best step in this patient's management?

A Start a statin with an LDL target of <1.8 mmol/l

B Stop bisoprolol

C Start amlodipine with a BP target of 120/80 mmHg

D Start isosorbide mononitrate

E Start a statin with an LDL target of <3.0 mmol/l

A Start a statin with an LDL target of <1.8 mmol/l

Patients with peripheral arterial disease have an increased risk of adverse cardiovascular event and frequently have coexistent coronary and cerebrovascular atherosclerosis; therefore it is considered a coronary artery disease equivalent. Current ESC guidelines on cardiovascular disease prevention recommend in patients at very high CV risk, an LDL-C goal of <1.8 mmol/l (<70 mg/dl) or a reduction of at least 50% if the baseline is between 1.8 and 3.5 mmol/l (70 and 135 mg/dl). For this reason an appropriate statin should be commenced.

E Start a statin with an LDL target of <3.0 mmol/l

This would be an appropriate target for patients who are not at very high or high CV risk (for whom separate targets exist).

B Stop bisoprolol

Beta-blockers do not significantly impair the walking capacity in most patients, and considering their favourable effect on coronary artery disease, need not be stopped. Cardioselective beta blockers such as bisoprolol have a better side effect profile in this respect

commenced.

E Start a statin with an LDL target of <3.0 mmol/l

This would be an appropriate target for patients who are not at very high or high CV risk (for whom separate targets exist).

B Stop bisoprolol

Beta-blockers do not significantly impair the walking capacity in most patients, and considering their favourable effect on coronary artery disease, need not be stopped. Cardioselective beta blockers such as bisoprolol have a better side effect profile in this respect.

C Start amlodipine with a BP target of 120/80 mmHg

Current ESC guidelines on cardiovascular disease prevention recommend that based on current data, it may still be prudent to recommend lowering SBP/DBP to values within the range 130–139/80–85 mmHg, and possibly close to the lower values in this range, in all hypertensive patients (specific targets for elderly and diabetic patients are available in the weblink).

respect.

C Start amlodipine with a BP target of 120/80 mmHg

Current ESC guidelines on cardiovascular disease prevention recommend that based on current data, it may still be prudent to recommend lowering SBP/DBP to values within the range 130–139/80–85 mmHg, and possibly close to the lower values in this range, in all hypertensive patients (specific targets for elderly and diabetic patients are available in the weblink).

D Start isosorbide mononitrate

ISMN is not indicated in the treatment of peripheral arterial disease, and in any case this patient remains symptom free on his current therapy.

Rate this question:

Next Question

A 55-year-old Nigerian male presents with a history of progressive swelling of his feet of 3 months' duration. He has also noticed gradually increasing abdominal distension. He has no history of chest pain, orthopnoea or paroxysmal nocturnal dyspnoea. He has been diabetic for the past 2 years, well controlled on metformin 850 mg twice daily. Physical examination reveals a pulse rate of 85/min, blood pressure 115/95 mmHg with a systolic postural drop of 20 mmHg and jugular venous distension. Heart sounds are normal and the chest is clear on auscultation. The liver edge is palpable 3 cm below the costal margin. There is bilateral pitting oedema up to the knees.

Calculator

Normal Values

Investigations:

WCC	10×10^9/l
Hb	12.5 g/dl
PLT	165×10^9/l
Na^+	138 mmol/l
K^+	4.0 mmol/l
Creatinine	129 mmol/l
Urea	3.8 mmol/l
Ca^{2+}	2.32 mmol/l

pitting oedema up to the knees.

Investigations:

WCC	$10 \times 10^9/l$
Hb	12.5 g/dl
PLT	$165 \times 10^9/l$
Na^+	138 mmol/l
K^+	4.0 mmol/l
Creatinine	129 mmol/l
Urea	3.8 mmol/l
Ca^{2+}	2.32 mmol/l
Chest X-ray	Normal cardiothoracic ratio and clear lung fields

The electrocardiogram (ECG) is shown below:

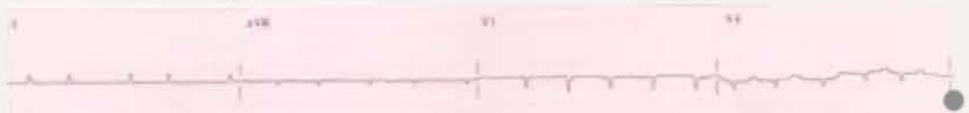

The electrocardiogram (ECG) is shown below:

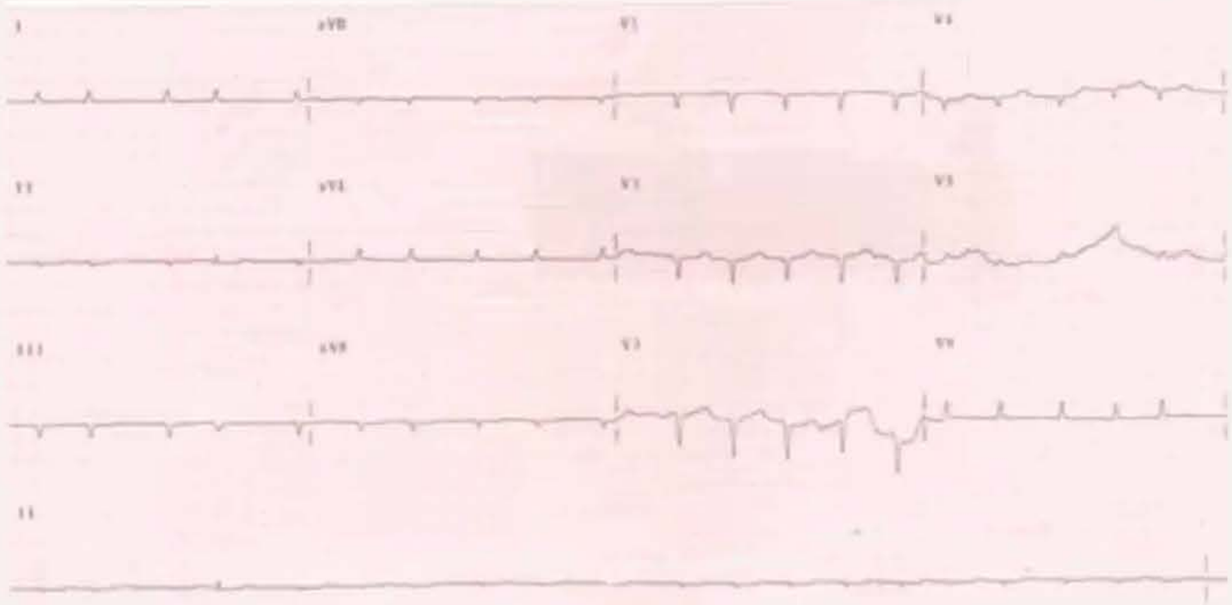

This shows mild dilatation of the atria, concentric left ventricular thickening, impaired diastolic relaxation and an ejection fraction of 55%.

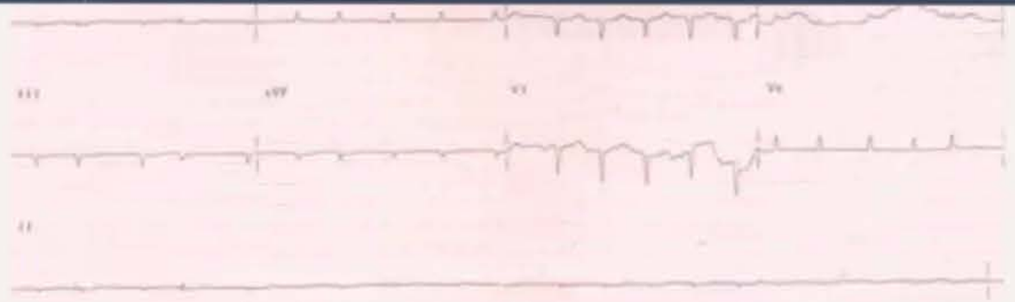

This shows mild dilatation of the atria, concentric left ventricular thickening, impaired diastolic relaxation and an ejection fraction of 55%.

Which of the following is the most likely diagnosis in this patient?

A	Cardiac amyloidosis
B	Haemochromatosis
C	Cardiac sarcoidosis
D	Diabetic nephropathy

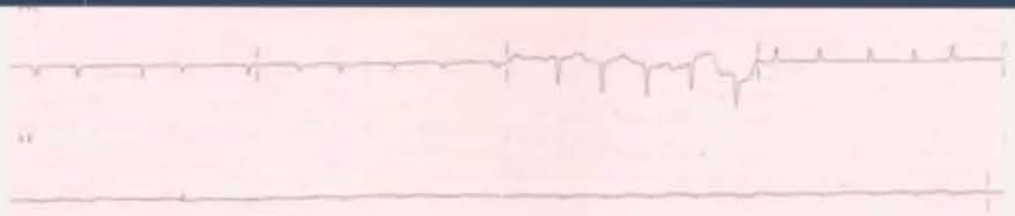

This shows mild dilatation of the atria, concentric left ventricular thickening, impaired diastolic relaxation and an ejection fraction of 55%.

Which of the following is the most likely diagnosis in this patient?

A	Cardiac amyloidosis
B	Haemochromatosis
C	Cardiac sarcoidosis
D	Diabetic nephropathy
E	Ischaemic cardiomyopathy

Explanation

A Cardiac amyloidosis

Cardiac amyloidosis most commonly presents as restrictive cardiomyopathy. The clinical findings are those of right heart failure, i.e. jugular venous distension and peripheral oedema, whereas orthopnoea and paroxysmal nocturnal dyspnoea are typically absent. In more advanced stages, systolic dysfunction also occurs. Postural hypotension can occur as a result of poor ventricular filling or associated autonomic neuropathy. The combination of low-voltage ECG and thickened ventricular walls is one of the characteristic features of cardiac amyloidosis. Other echocardiographic abnormalities include atrial dilatation, thickened interatrial septum, diastolic dysfunction and small-volume ventricles. The most distinctive feature of cardiac amyloidosis is a sparkling, granular appearance of the myocardium, but this is a relatively insensitive feature occurring only in about 25% of cases.

B Haemochromatosis

Haemochromatosis can cause a restrictive cardiomyopathy, but the combination of ventricular wall thickness and low-voltage ECG makes the diagnosis of cardiac amyloidosis more likely. There are also no other features in the scenario, apart from diabetes, to suggest

Ca^{2+}	2.32 mmol/l
Chest X-ray	Normal cardiothoracic ratio and clear lung fields

The electrocardiogram (ECG) is shown below:

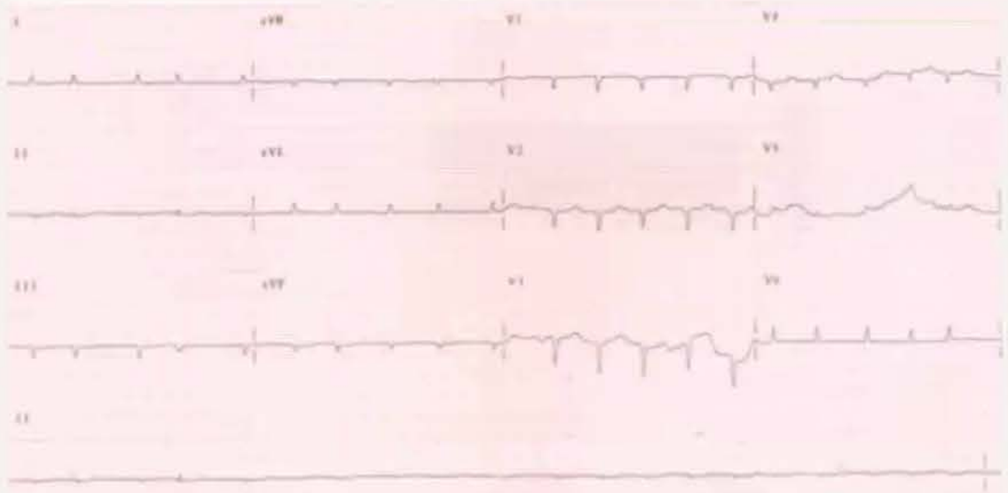

This shows mild dilatation of the atria, concentric left ventricular thickening, impaired diastolic relaxation and an ejection fraction of 55%.

Which of the following is the most likely diagnosis in this patient?

ventricular wall thickness and low-voltage ECG makes the diagnosis of cardiac amyloidosis more likely. There are also no other features in the scenario, apart from diabetes, to suggest haemochromatosis, and the condition is much rarer in patients of African origin.

C Cardiac sarcoidosis

Like haemochromatosis, sarcoidosis is associated with a restrictive cardiomyopathy, although there is an absence of other features suggestive of sarcoidosis, including a dry cough or hypercalcaemia.

D Diabetic nephropathy

Although this causes peripheral oedema, it wouldn't account for the ECG and ECHO findings seen here.

E Ischaemic cardiomyopathy

There is no history of previous ischaemic heart disease to suggest a diagnosis of ischaemic cardiomyopathy.

You review a 78-year-old woman who has collapsed while at morning service in church. This has been her third episode of collapse in recent months. On admission to the Emergency Department she is hypotensive at 90/70 mmHg and has a pulse rate of 38 bpm. Electrocardiogram (ECG) reveals atrial fibrillation with a ventricular rate of 40 bpm. There is a past medical history of hypertension and chronic obstructive airway disease. Medication includes seretide inhaler and ramipril for blood pressure. Review of previous casualty cards reveals one other documented bradycardic collapse and an admission with fast atrial fibrillation at a ventricular rate of 135 bpm.

Calculator

Normal Values

Which of the following represents the most appropriate long-term therapy for this lady?

A Verapamil

B Sotalol

C Amiodarone

D Permanent pacemaker

Calculator

Normal Values

You review a 78-year-old woman who has collapsed while at morning service in church. This has been her third episode of collapse in recent months. On admission to the Emergency Department she is hypotensive at 90/70 mmHg and has a pulse rate of 38 bpm. Electrocardiogram (ECG) reveals atrial fibrillation with a ventricular rate of 40 bpm. There is a past medical history of hypertension and chronic obstructive airway disease. Medication includes seretide inhaler and ramipril for blood pressure. Review of previous casualty cards reveals one other documented bradycardic collapse and an admission with fast atrial fibrillation at a ventricular rate of 135 bpm.

Which of the following represents the most appropriate long-term therapy for this lady?

A Verapamil

B Sotalol

C Amiodarone

D Permanent pacemaker

E Digoxin

Explanation

D Permanent pacemaker

The patient has sinus node dysfunction or 'sick sinus syndrome' as the cause for her atrial arrhythmia and episodes of bradycardia and tachycardia. In this condition, symptomatic bradycardia and syncope are both ESC Class I indications for a permanent implantable pacemaker. Dual-chamber pacemakers (DDD) are usually implanted, however patients with atrial fibrillation usually receive a single chamber device (VVI).

A Verapamil

Verapamil is a rate-limiting calcium channel blocker, therefore it would worsen the bradycardia and so is not a suitable option for treatment.

B Sotalol

Sotolol is a non-competitive β-blocker which exhibits Class III anti-arrhythmic actions. Adverse effects include bradycardia, therefore it would not be appropriate in this case of

A 63-year-old known diabetic presents to the Emergency Department with sudden onset of severe breathlessness. He says he was feeling completely normal during his evening meal but he suddenly broke out in a cold sweat and felt that he had a major problem in catching his breath. He denies any history of pain or previous episodes of breathlessness. He is on metformin and gliclazide for his diabetes, as well as perindopril for mild hypertension.
On arrival in the resuscitation area he is profoundly diaphoretic and looks unwell. His blood pressure is 145/95 mmHg and his heart rate is 120 beats/min. His oxygen saturations are 86% on room air and improve to 95% on inspired oxygen via a reservoir bag. Auscultation of his heart reveals a third heart sound, and there are widespread wheezes and crackles on auscultation of his chest.
A bedside glucose test shows a blood glucose concentration of 13.6 mmol/l. His electrocardiogram (ECG) shows ST elevation of 3 mm in leads V_4–V_6.

Calculator

Normal Values

What is the most appropriate course of action with respect to his long-term outcome?

A	Furosemide 80 mg intravenous (IV) and continuous glyceryl trinitrate iv infusion
B	Aspirin 300 mg stat, IV GTN, and referral for urgent PCI
C	Furosemide 80 mg IV and insulin IV sliding scale

MyPastest
Pastest LTD [GB] https://mypastest.pastest.com/Secure/TestMe/Browser/718301

A 63-year-old known diabetic presents to the Emergency Department with sudden onset of severe breathlessness. He says he was feeling completely normal during his evening meal but he suddenly broke out in a cold sweat and felt that he had a major problem in catching his breath. He denies any history of pain or previous episodes of breathlessness. He is on metformin and gliclazide for his diabetes, as well as perindopril for mild hypertension.
On arrival in the resuscitation area he is profoundly diaphoretic and looks unwell. His blood pressure is 145/95 mmHg and his heart rate is 120 beats/min. His oxygen saturations are 86% on room air and improve to 95% on inspired oxygen via a reservoir bag. Auscultation of his heart reveals a third heart sound, and there are widespread wheezes and crackles on auscultation of his chest.
A bedside glucose test shows a blood glucose concentration of 13.6 mmol/l. His electrocardiogram (ECG) shows ST elevation of 3 mm in leads V_4–V_6.

Calculator

Normal Values

What is the most appropriate course of action with respect to his long-term outcome?

A Furosemide 80 mg intravenous (IV) and continuous glyceryl trinitrate iv infusion

B Aspirin 300 mg stat, IV GTN, and referral for urgent PCI

C [illegible] mg IV and insulin IV sliding scale

Rajaa Adris' screen

pressure is 145/95 mmHg and his heart rate is 120 beats/min. His oxygen saturations are 86% on room air and improve to 95% on inspired oxygen via a reservoir bag. Auscultation of his heart reveals a third heart sound, and there are widespread wheezes and crackles on auscultation of his chest.

A bedside glucose test shows a blood glucose concentration of 13.6 mmol/l. His electrocardiogram (ECG) shows ST elevation of 3 mm in leads V_4–V_6.

What is the most appropriate course of action with respect to his long-term outcome?

A	Furosemide 80 mg intravenous (IV) and continuous glyceryl trinitrate iv infusion
B	Aspirin 300 mg stat, IV GTN, and referral for urgent PCI
C	Furosemide 80 mg IV and insulin IV sliding scale
D	Salbutamol nebuliser and IV hydrocortisone
E	Non-invasive ventilation (NIV) using a continuous positive airway pressure mask

Explanation

B Aspirin 300 mg stat, IV GTN, and referral for urgent PCI

The ECG presented here demonstrates an acute anterior ST-elevation myocardial infarction. Diabetic patients often present with atypical features of myocardial ischemia (including a lack of pain). Aspirin should be given immediately. GTN infusion will reduce cardiac afterload by causing peripheral vasodilation. This should reduce myocardial oxygen requirements and reduce further myocardial injury. However, urgent PCI is required to stent the lesion. This has been shown to have improved outcomes over other treatment options.

A Furosemide 80 mg intravenous (IV) and continuous glyceryl trinitrate iv infusion

This patient has clinical features suggestive of left ventricular failure, including the new respiratory auscultatory findings. The use of furosemide to reduce circulating volume may clinically improve the patient. GTN infusion will reduce peripheral resistance and thus cardiac afterload. Together, these two agents may acutely improve the clinical situation. However, neither deals with the underlying ST-elevation myocardial infarction clearly indicated by the ECG. It is probably this event which is causing the left ventricular dysfunction. Treating the coronary artery occlusion is vital to improving the patient's

D Salbutamol nebuliser and IV hydrocortisone

The widespread wheeze on respiratory auscultation may be suggestive of an exacerbation of asthma or COPD. However, neither of these diagnoses explains the remaining findings or the ECG changes. The wheeze is probably 'cardiac asthma' secondary to left ventricular failure.

E Non-invasive ventilation (NIV) using a continuous positive airway pressure mask

NIV can be of benefit in patients with significant heart failure, and may be necessary here. However, an underlying cause must be sought for the acute left ventricular dysfunction suggested by the clinical picture. The ECG is supportive of a diagnosis of myocardial infarction. As such, acute angiography ± angioplasty is required to investigate and treat this diagnosis, which will probably improve cardiac function.

Rate this question:

Next Question

A 69-year-old woman is admitted to the Emergency Department with palpitations. The palpitations started while she was doing some house chores 2 h ago. There is no associated shortness of breath but she is just uncomfortable, being aware of her heart beating fast. She has had palpitations in the past, but these have been brief and lasted for only a very short time. A previous Holter has captured periods of SVT with aberrant conduction. She has a past medical history of hypertension for which she takes 10 mg of amlodipine.

On examination, she is anxious, with a blood pressure of 130/70 mmHg, pulse rate of 143/min and a respiratory rate of 22/min. Her oxygen saturation is 99% on air and her chest is clinically clear. Her jugular venous pulse is not raised and there is no peripheral oedema. The first and second heart sounds are heard but you are not sure whether there is a third heart sound.

Investigations:

ECG	Broad complex tachycardia, QRS complex >140 ms, but you are not sure whether this is a supraventricular or a ventricular tachycardia
CXR	Appears normal

Calculator

Normal Values

The first and second heart sounds are heard but you are not sure whether there is a third heart sound.

Investigations:

ECG	Broad complex tachycardia, QRS complex >140 ms, but you are not sure whether this is a supraventricular or a ventricular tachycardia
CXR	Appears normal

What is the most appropriate next step?

A	Adenosine IV
B	Amiodarone IV
C	DC cardioversion
D	Esmolol IV

MyPastest
Pastest LTD [GB] https://mypastest.pastest.com/Secure/TestMe/Browser/718301

ECG	Broad complex tachycardia, QRS complex >140 ms, but you are not sure whether this is a supraventricular or a ventricular tachycardia
CXR	Appears normal

What is the most appropriate next step?

A	Adenosine IV
B	Amiodarone IV
C	DC cardioversion
D	Esmolol IV
E	Observation

Explanation

A Adenosine IV

This patient is haemodynamically stable but has a broad complex tachycardia. It is not always easy to tell whether the broad complex tachycardia is of ventricular or supraventricular origin, but the safest course of action is to consider a drug like adenosine, which will cause short-lived AV block in SVT but not in VT. It is the presence of aberrant conduction which can lead to diagnostic confusion. The haemodynamic status has little bearing in distinguishing whether it is of ventricular or supraventricular origin. Chemical cardioversion would be appropriate in this patient, who is haemodynamically stable.

B Amiodarone IV

Amiodarone may be an appropriate next step for cardioversion, once the underlying rhythm has been elucidated.

C DC cardioversion

has been elucidated.

C DC cardioversion

Progressing directly to DC cardioversion isn't warranted given that this patient has a stable blood pressure. Determining the underlying rhythm with adenosine first is appropriate.

D Esmolol IV

Esmolol is appropriate for rhythm control in paroxysmal VT, although adenosine is easier to administer in the Emergency Room setting and is therefore the preferred option.

E Observation

Due to the risk of sudden deterioration, either in heart rate or blood pressure, observation is not appropriate here.

70922

Rate this question:

Next Question

A 62-year-old heavy smoker presents to the Emergency Department with a history of very severe central chest pain radiating to the back. Past medical history of note includes hypertension controlled with ramipril and atenolol, and a transient ischaemic attack some 6 months earlier. Examination reveals a difference in blood pressure of 35/10 mmHg between the two arms. There are signs of aortic regurgitation and a pericardial friction rub. The electrocardiogram reveals evidence of inferior ST elevation and atrial fibrillation, with a ventricular rate of 90/min. His BP is 125/75 mmHg.

Calculator

Normal Values

Which one of the following options represents optimal initial management of this case?

A IV thrombolysis

B Beta-blockade

C Low-molecular weight heparin

D Aspirin

E ACE inhibition

Explanation

B Beta-blockade

The clinical signs in this patient point towards a diagnosis of aortic dissection. It is likely that the electrocardiogram signs of inferior myocardial infarction are due to the dissection having compromised the right coronary artery ostium. Key management considerations are reduction of blood pressure (with IV b-blockade) and pain relief. Contrast computed tomography (CT) scanning is necessary to assess the extent of dissection and suitability for surgery, and early consultation with a cardiothoracic surgeon is advised. Mortality for untreated aortic dissection is 25–30% at 24 h and 65–70% at 2 weeks; dissections confined to the descending aorta are associated with better survival (80%).

A IV thrombolysis

Given the difference in blood pressure between the arms, and the fact the pain radiates to the back, dissection should be ruled out before considering thrombolysis or anti-coagulation.

A 62-year-old heavy smoker presents to the Emergency Department with a history of very severe central chest pain radiating to the back. Past medical history of note includes hypertension controlled with ramipril and atenolol, and a transient ischaemic attack some 6 months earlier. Examination reveals a difference in blood pressure of 35/10 mmHg between the two arms. There are signs of aortic regurgitation and a pericardial friction rub. The electrocardiogram reveals evidence of inferior ST elevation and atrial fibrillation, with a ventricular rate of 90/min. His BP is 125/75 mmHg.

Which one of the following options represents optimal initial management of this case?

Your answer was correct

A IV thrombolysis

B Beta-blockade

C Low molecular weight heparin

Difficulty: Average

Peer Responses %

Session Progress

Responses Correct:	15
Responses Incorrect:	5
Responses Total:	20

Rajaa Adris' screen

Explanation

B Beta-blockade

The clinical signs in this patient point towards a diagnosis of aortic dissection. It is likely that the electrocardiogram signs of inferior myocardial infarction are due to the dissection having compromised the right coronary artery ostium. Key management considerations are reduction of blood pressure (with IV b-blockade) and pain relief. Contrast computed tomography (CT) scanning is necessary to assess the extent of dissection and suitability for surgery, and early consultation with a cardiothoracic surgeon is advised. Mortality for untreated aortic dissection is 25–30% at 24 h and 65–70% at 2 weeks; dissections confined to the descending aorta are associated with better survival (80%).

A IV thrombolysis

Given the difference in blood pressure between the arms, and the fact the pain radiates to the back, dissection should be ruled out before considering thrombolysis or anti-coagulation.

9:43

A 23-year-old homeless patient comes to the Emergency Department. She has been feeling sick for some considerable time with fevers and rigors and has now begun to develop a rash.

On examination, she is pyrexial 38.1 °C. She has splinter haemorrhages on examination of her finger nails and a generalized purpuric rash. Further examination reveals injection sites on both forearms and evidence that she has tried to inject into her femoral vein.

Investigations:

Hb	10.0 g/dl
WCC	12.4×10^9/l
PLT	35×10^9/l
Na^+	139 mmol/l
K^+	4.5 mmol/l
Creatinine	152 µmol/l
ESR	70 mm/hr
Blood cultures x3	No growth so far
Urine	Blood +
CXR	Cavitating lesions both lower lobes

Which of the following is the most appropriate next investigation?

A Further blood cultures

B CT thorax

C Trans-oesophageal echocardiogram

Rana Alnasser's screen

9:44
On ...
625-262-0256
Leave

Investigations:

Hb	10.0 g/dl
WCC	12.4×10^9/l
PLT	35×10^9/l
Na^+	139 mmol/l
K^+	4.5 mmol/l
Creatinine	152 µmol/l
ESR	70 mm/hr
Blood cultures x3	No growth so far
Urine	Blood +
CXR	Cavitating lesions both lower lobes

Which of the following is the most appropriate next investigation?

A Further blood cultures

B CT thorax

C Trans-oesophageal echocardiogram

D Urine cultures

E ANA

Submit

Audio Video Share Participants More

9:47

The clinical situation portrayed here is that of infective endocarditis. This is supported by the raised ESR, clinical history, and splinter haemorrhages on examination. The injection marks suggest that the patient has a substance abuse problem (likely using heroin). The use of dirty needles or less clean injection sites (eg the femoral vein) increases the risk of introducing bacteria into the blood stream.

Given the history of injectable drug use and the cavitating lesions on chest X-ray, Staphylococcus aureus is the most likely diagnosis; blood cultures will likely confirm this. A trans-oesophageal echocardiogram is required as part of the Duke criteria (see table 1) for diagnosing endocarditis and is the most important next investigations (although in most hospitals, a trans-thoracic echocardiogram will likely be performed first); especially as the patient likely has a right-sided valvular infection.

Major Criteria	Minor Criteria
Blood cultures positive for typical microorganisms consistent with endocarditis from two different blood cultures.	Predisposing heart condition or intravenous drug use
Evidence of endocardial involvement on echocardiogram	Temperature > 38.0 °C
	Vascular phenomena (eg septic emboli, intracranial haemorrhage, Janeway's lesions)

Rana Alnasser's screen

Major Criteria	Minor Criteria
Blood cultures positive for typical microorganisms consistent with endocarditis from two different blood cultures.	Predisposing heart condition or intravenous drug use
Evidence of endocardial involvement on echocardiogram	Temperature > 38.0 °C
	Vascular phenomena (eg septic emboli, intracranial haemorrhage, Janeway's lesions)
	Immunologic Phenomena (eg Osler's nodes, glomerulonephritis)
	Positive blood cultures which do not meet the major criterion level
	Echocardiographic evidence for endocarditis not sufficient to meet the major criterion

Table 1: Duke criteria for the diagnosis of endocarditis. For a positive diagnosis, a patient requires two major criteria, one major and three minor criteria, or five minor criteria. Adapted from: Durack DT, Lukes AS, Bright DK. New criteria for diagnosis of infective endocarditis: utilization of

echocardiogram	
	Vascular phenomena (eg septic emboli, intracranial haemorrhage, Janeway's lesions)
	Immunologic Phenomena (eg Osler's nodes, glomerulonephritis)
	Positive blood cultures which do not meet the major criterion level
	Echocardiographic evidence for endocarditis not sufficient to meet the major criterion

Table 1: Duke criteria for the diagnosis of endocarditis. For a positive diagnosis, a patient requires two major criteria, one major and three minor criteria, or five minor criteria. Adapted from: Durack DT, Lukes AS, Bright DK. New criteria for diagnosis of infective endocarditis: utilization of specific echocardiographic findings. Duke Endocarditis Service. *American Journal of Medicine*. 1994;96(3):200-9.

A Further blood cultures

Three blood cultures from different sites taken at different times are a primary investigation for infective endocarditis (the likely diagnosis in this case). However, sufficient cultures have already been taken in this case. Cultures can take a number of days to become positive and further cultures at this time are unnecessary.

B CT thorax

The cavitating lesions on chest X-ray likely represent emboli from a right sided valvular lesion. This is particularly common in Staphylococcus aureus endocarditis.

A CT thorax would elucidate the nature of the cavitations further, but will not help with the underlying diagnosis. A CT thorax combined with FDG-PET can be used to look for inflammation on cardiac valves if the echocardiogram is non-diagnostic.

D Urine cultures

The source of infection in this patient is likely to be endocarditis. Urine culture may be appropriate if further investigations for endocarditis are negative, but further imaging of the heart are required initially.

E ANA

This would be an important test if a diagnosis of systemic lupus erythematosus (SLE) was being considered. SLE can lead to a form of non-infective endocarditis (Libman-Sacks endocarditis). However, the history of intravenous drug use makes infective endocarditis a more likely diagnosis. As such, cardiac imaging with a trans-thoracic echocardiography is required.

Rate this question:

Next Question

Previous Q... Tag Questi... Feedback End Session

9:49

A 57-year-old man underwent angioplasty and stenting for myocardial ischaemia some 12 months earlier. He has presented three times since then to the Emergency Department complaining of different atypical chest pain. Each time there have been no significant ECG changes and serial serum troponin levels have been normal.

Which of the following options is the best to further investigate his symptoms?

A	CT coronary angiography
B	Invasive coronary angiography
C	Trans-oesophageal echocardiogram
D	Thallium myocardial perfusion scan
E	Tissue Doppler echocardiography

71469

Submit

Previous Q... Skip Questi...

© Pastest 2019

Rana Alnasser's screen

D Thallium myocardial perfusion scan

E Tissue Doppler echocardiography

Explanation

D Thallium myocardial perfusion scan

This case illustrates a common cardiology presentation of a patient presenting with atypical chest pain against a background of known coronary artery disease. The next investigation would ideally be a low-risk procedure that can demonstrate continued patency of the previously stented coronary artery. Angiography modalities (CT and invasive catheter coronary angiography), Dobutamine-atropine stress echocardiography, thallium perfusion scanning and myocardial contrast perfusion echocardiography are all capable of localising areas of myocardial ischaemia.

In patients with coronary stents, stress imaging is preferred over CT coronary angiogram due to possible artifact.

E Tissue Doppler echocardiography

Doppler assessment is used in echocardiography to assess blood velocity and direction of flow, as well as the movement of myocardium if used with the tissue Doppler modality. This enables further assessment of ventricular systolic and diastolic function, as an adjunct to standard echocardiographic measurements.

A CT coronary angiography

This will provide angiographic detail of coronary anatomy and is first-line in current NICE guidelines in stable angina. However, in patients with coronary stents, artifact can

This will provide angiographic detail of coronary anatomy and is first-line in current NICE guidelines in stable angina. However, in patients with coronary stents, artifact can obscure the diagnosis of true stenosis.

B Invasive coronary angiography

This is of course the gold standard for the assessment of coronary artery disease, but it does not come without risks. In this patient with atypical chest pain, we would ideally aim for an investigation with lower risk but with sufficient sensitivity to exclude ischaemia as a cause for his symptoms.

C Trans-oesophageal echocardiogram

Trans-oesophageal echocardiogram can provide further information on left ventricular function and valvular function when trans-thoracic echocardiogram imaging is suboptimal. However, it will not help us with the exclusion of ongoing ischaemia.

Rate this question:

© Pastest 2019

A 68-year-old male is admitted to hospital with progressively severe shortness of breath of two days' duration. He is known to have ischaemic cardiomyopathy and an ejection fraction of 30%. On arrival his respiratory rate is 35/minute; oxygen saturation by pulse oximetry is 81% and chest X-ray shows bilateral pulmonary infiltrates and cardiomegaly. He is intubated, mechanically ventilated and started on IV infusion of furosemide 6 mg/h and nitroglycerine 25 µg/min. Over the next three days he achieves a negative fluid balance of 3.2 l and chest X-ray shows decrease in pulmonary infiltrates. Serial cardiac enzymes are normal except for slightly elevated troponin T. However, the next day when extubation is planned he becomes hypotensive, blood pressure 80/50 mmHg and the infiltrates on chest X-ray worsen. You note that his bloods that morning have revealed a CRP of 189 mg/l, and neutrophils are above the upper limit or normal.

A Swan–Ganz catheterisation is performed and reveals:

Pulmonary capillary wedge pressure (PCWP)	8 mmHg
Cardiac output	5 l/min
Cardiac index	3 l/min/m^2
Systemic vascular resistance	650 dynes s/cm–5 (700–1100)

Furosemide and nitrates are stopped but blood pressure fails to improve.

Which of the following is the most appropriate next step in the management of this patient?

A	Haemodialysis
B	Normal saline 500 ml IV bolus

progressively severe shortness of breath of two days duration. He is known to have ischaemic cardiomyopathy and an ejection fraction of 30%. On arrival his respiratory rate is 35/minute; oxygen saturation by pulse oximetry is 81% and chest X-ray shows bilateral pulmonary infiltrates and cardiomegaly. He is intubated, mechanically ventilated and started on IV infusion of furosemide 6 mg/h and nitroglycerine 25 µg/min. Over the next three days he achieves a negative fluid balance of 3.2 l and chest X-ray shows decrease in pulmonary infiltrates. Serial cardiac enzymes are normal except for slightly elevated troponin T. However, the next day when extubation is planned he becomes hypotensive, blood pressure 80/50 mmHg and the infiltrates on chest X-ray worsen. You note that his bloods that morning have revealed a CRP of 189 mg/l, and neutrophils are above the upper limit or normal.

A Swan-Ganz catheterisation is performed and reveals:

Pulmonary capillary wedge pressure (PCWP)	8 mmHg
Cardiac output	5 l/min
Cardiac index	3 l/min/m²
Systemic vascular resistance	650 dynes s/cm-5 (700-1100)

Furosemide and nitrates are stopped but blood pressure fails to improve.

Which of the following is the most appropriate next step in the management of this patient?

Your answer was incorrect

A Haemodialysis

B Normal saline 500 ml IV bolus

A
B
C
D
E
0

Res
Res
Res
Res

B Normal saline 500 ml IV boluS

The haemodynamic parameters in this patient - low systemic vascular resistance and normal cardiac index and cardiac output - are suggestive of septic shock. This is probably secondary to ventilator-associated pneumonia. It occurs 48–72 h after admission, and worsening pulmonary infiltrates despite negative fluid balance are suggestive of chest infection. Appropriate management is fluid resuscitation to achieve optimal left heart filling pressure, and IV antibiotics.

D IV Dopamine infusion

Renal-dose dopamine was commonly used to manage acute renal impairment associated with sepsis, although controlled trials suggest it has limited efficacy. In this situation fluid replacement and IV antibiotics are more appropriate first steps.

A Haemodialysis

Haemodialysis would be considered in the event that renal function deteriorated despite optimal fluid management and IV antibiotic therapy.

C IV Dobutamine infusion

Inotropes are generally avoided if possible in patients with ischaemic cardiomyopathy because of the risk of worsening LV function as a result of negatively impacting on ischaemia.

E Left ventricular assist device (LVAD)

An LVAD might be considered once fluid replacement and IV antibiotic therapy have been optimised, in the event that blood pressure and urine output are both suboptimal.

A 24-year-old woman presents to Accident and Emergency (A&E) following an episode of collapse preceded by palpitations. She has recently completed a course of amoxicillin for a chest infection prescribed by her GP, but has no other medical history of note.

On examination, she is found to have a heart rate of 100, and clear lungs.

Investigations:

Hb	12.2 g/dl
WCC	13.0×10^9/l
PLT	250×10^9/l
K^+	5.6 mmol/l
Na^+	138 mmol/l
Mg^{2+}	1.2 mmol/l
Ca^{2+}	2.3 mmol/l
eGFR	> 60

While in A&E, an ECG is captured which demonstrates a self-terminating episode of torsades de pointes.

Which one of the following is this patient's most significant risk factor for torsades de pointes?

A	Hyperkalaemia
B	Tachycardia
C	Hyponatraemia
D	Recent beta-lactam antibiotic use

Mg^{2+}	1.2 mmol/l
Ca^{2+}	2.3 mmol/l
eGFR	> 60

While in A&E, an ECG is captured which demonstrates a self-terminating episode of torsades de pointes.

Which one of the following is this patient's most significant risk factor for torsades de pointes?

A Hyperkalaemia

B Tachycardia

C Hyponatraemia

D Recent beta-lactam antibiotic use

E Female sex

2515

Submit

Previous Q... Skip Questi...

© Pastest 2019

Rana Alnasser's screen

Explanation

E Female sex

Torsades de pointes is a form of polymorphic VT associated with QT prolongation, in which the QRS complexes 'twist' around the isoelectric line. Other risk factors include: hypocalcaemia, congestive heart failure, digitalis therapy, subclinical long-QT syndrome, baseline QT prolongation, severe alkalosis, recent conversion from atrial fibrillation, and a range of drugs such as sotalol and macrolides that cause QT prolongation. Female sex is a powerful predictor of the risk of torsade de pointes in patients with congenital and acquired long-QT syndrome. How or whether variability in the expression of genes that determine normal cardiac electrophysiology explains the sex-dependent risk of torsade de pointes is not yet clear.

A Hyperkalaemia

It is hypokalaemia that causes QT prolongation, and thus increases the risk of torsades de pointes.

B Tachycardia

It is bradycardia, not tachycardia, that represents increased risk of torsades de pointes. With decreased heart rate, the QT lengthens and vice versa.

C Hyponatraemia

It is hypomagnesaemia that causes QT prolongation, and thus increases the risk of torsades de pointes.

D Recent beta-lactam antibiotic use

It is macrolides (particularly erythromycin and clarithromycin) that are associated with QT prolongation

10:06

A 78-year-old man is referred to the Cardiology Clinic complaining of increased tightness in his chest. He gets chest tightness and shortness of breath on walking up a hill and going out in very cold weather. His exercise tolerance has been reduced over the past few months but he is still easily able to walk his dog. He has a past medical history of angina although he has never had any diagnostic tests.

He has been using his GTN spray two times per day over the past six months, which has prompted his general practitioner (GP) to add a long-acting nitrate preparation. Other medication includes ramipril, aspirin and atorvastatin.

On examination, he is comfortable at rest with a blood pressure of 135/80 mmHg and pulse of 72 bpm and regular. He has no peripheral oedema and his jugular venous pulse is not raised. First and second heart sounds are heard and there are no murmurs. His chest is clinically clear.

Investigations:

ECG	Sinus rhythm with Q waves in the inferior leads
Chest X-ray	Normal
Full blood count (FBC)	U/Es and lipid profile are within normal range

What is the next step in the treatment of this gentleman?

A	Further medical management for angina
B	Angiography
C	Technetium scan
D	Exercise stress testing

Rana Alnasser's screen

angina although he has never had any diagnostic tests.

He has been using his GTN spray two times per day over the past six months, which has prompted his general practitioner (GP) to add a long-acting nitrate preparation. Other medication includes ramipril, aspirin and atorvastatin.

On examination, he is comfortable at rest with a blood pressure of 135/80 mmHg and pulse of 72 bpm and regular. He has no peripheral oedema and his jugular venous pulse is not raised. First and second heart sounds are heard and there are no murmurs. His chest is clinically clear.

Investigations:

ECG	Sinus rhythm with Q waves in the inferior leads
Chest X-ray	Normal
Full blood count (FBC)	U/Es and lipid profile are within normal range

What is the next step in the treatment of this gentleman?

A	Further medical management for angina
B	Angiography
C	Technetium scan
D	Exercise stress testing
E	Positron emission tomography

10:09

B Angiography

C Technetium scan

D Exercise stress testing

E Positron emission tomography

Explanation

A Further medical management for angina

From the history, this patient has stable angina with good exercise tolerance. He is already on the appropriate medications, i.e. aspirin, ACE-I and statin as per NICE guidelines (see first weblink below). Medical management with anti-anginals would be the first step. Beta-blocker or calcium channel blockers are recommended by NICE. Long-acting nitrates could be used if either of the drugs is not tolerated or insufficient. If the patient continues to have chest pain despite being on optimal medical therapy, then he should be considered for revascularisation with PCI or CABG.

B Angiography

Given that the patient has stable angina, the first line would be to use medical therapy. If we are unable to control his symptoms with medical therapy, then angiography should be the next investigation to plan revascularisation strategy with either PCI or CABG.

C Technetium scan

This patient clearly has stable angina and therefore does not need further investigations to confirm that. Should the

Rana Alnasser's screen

10:10

MyPastest
https://mypastest.pastest.com

Pastest+

A 78-year-old man is referred to the Cardiology Clinic complaining of increased tightness in his chest. He gets chest tightness and shortness of breath on walking up a hill and going out in very cold weather. His exercise tolerance has been reduced over the past few months but he is still easily able to walk his dog. He has a past medical history of angina although he has never had any diagnostic tests.

He has been using his GTN spray two times per day over the past six months, which has prompted his general practitioner (GP) to add a long-acting nitrate preparation. Other medication includes ramipril, aspirin and atorvastatin.

On examination, he is comfortable at rest with a blood pressure of 135/80 mmHg and pulse of 72 bpm and regular. He has no peripheral oedema and his jugular venous pulse is not raised. First and second heart sounds are heard and there are no murmurs. His chest is clinically clear.

Investigations:

ECG	Sinus rhythm with Q waves in the inferior leads
Chest X-ray	Normal
Full blood count (FBC)	U/Es and lipid profile are within normal range

What is the next step in the treatment of this gentleman?

Your answer was incorrect

A Further medical management for angina

A
B
C
D
E
0

Res
Res
Res
Res

Stab
nice.
Che
nice.

10:10

C Technetium scan

This patient clearly has stable angina and therefore does not need further investigations to confirm that. Should the patient warrant further investigations to diagnose significant coronary artery disease, the use of CT coronary angiogram is recommended as first line followed on by non-invasive functional testing (stress echo, MPS or stress CMR).

D Exercise stress testing

As above, ETT has grown out of favour in diagnosing/ruling out coronary artery disease due to its poor sensitivity. However, it can still be used to guide prognosis and treatment of patients with established ischaemic heart disease.

E Positron emission tomography

Cardiac PET scanners are not widely available in the UK; these are currently used mostly in the research setting and are useful in identifying coronary artery disease and how it affects myocardial blood flow. Therefore, PET plays a role in a specialist setting to determine whether interventions would be beneficial for some groups of patients.

Rate this question:

Next Question

Previous Q... Tag Questi... Feedback End Session

Rana Alnasser's screen

A 48-year-old postmenopausal women presents with a history of severe retrosternal chest pain of 2 h duration. ECG reveals ST segment depression in leads I, II and aVF. Serial cardiac markers show elevated creatine kinase and cardiac troponin T. She is treated with aspirin, clopidogrel, IV heparin infusion and beta-blockers. She undergoes coronary angiography 48 h later that shows a mid-right coronary artery stenosis, which is stented. Two weeks later she notices gum bleeding after brushing her teeth. The next day she is found by her husband in a confused state, and absence of spontaneous movements of the right arm and leg is noticed. On arrival at the Emergency Department she has a pulse rate of 100 beats/min, respiratory rate of 18/min, blood pressure of 110/60 mmHg and temperature of 38.2°C. She is confused and has right-sided hemiparesis. An emergency brain CT excludes the presence of haemorrhage.

Investigations:

Hb	9.2 g/dl
WCC	18×10^9/l
PLT	40×10^9/l
Na^+	139 mmol/l
K^+	5.0 mmol/l
Creatinine	152 μmol/l
Bicarbonate	20 mmol/l
Chloride	98 mmol/l

Which is the most appropriate next investigation for this patient?

A Cerebral angiography

B Lumbar puncture

of 38.2°C. She is confused and has right-sided hemiparesis. An emergency brain CT excludes the presence of haemorrhage.

Investigations:

Hb	9.2 g/dl
WCC	18×10^9/l
PLT	40×10^9/l
Na^+	139 mmol/l
K^+	5.0 mmol/l
Creatinine	152 μmol/l
Bicarbonate	20 mmol/l
Chloride	98 mmol/l

Which is the most appropriate next investigation for this patient?

A Cerebral angiography

B Lumbar puncture

C Peripheral blood film

D Coagulation screen

E Coombs' test

Submit

E Coombs' test

Explanation

C Peripheral blood film

This patient has developed fever, altered mental status, right hemiparesis, anaemia, thrombocytopenia and renal impairment 2 weeks after being started on clopidogrel. The most likely diagnosis is secondary thrombotic thrombocytopenic purpura. This disorder can occur in less than 1% of patients receiving clopidogrel or ticlodipine. The condition is a micro-angiopathic haemolytic anaemia, and peripheral blood film reveals fragmented RBCs (schistocytes, e.g. spherocytes, segmented RBCs, burr cells or helmet cells). While further imaging with MRI would certainly be indicated, cerebral angiography would not be performed here as a next step, and in any case the low platelet count would give cause for caution with invasive procedures including lumbar puncture. Other side effects reported with the use of clopidogrel include rash, urticaria, pruritis and gastrointestinal upset.

D Coagulation screen

The patient's symptoms and temporal relationship to clopidogrel imply TTP as the underlying diagnosis. In this case, a coagulation screen is likely to be normal, and would be non-diagnostic.

A Cerebral angiography

Scroll capture Draw Crop

case, a coagulation screen is likely to be normal, and would be non-diagnostic.

A Cerebral angiography

The patient's symptoms and temporal relationship to clopidogrel imply TTP as the underlying diagnosis, rather than a primary intra-cerebral cause.

B Lumbar puncture

Given the temporal relationship between commencing clopidogrel and her symptoms, her confusion and neurological symptoms are more likely to be related to TTP than a primary intra-cerebral cause. In addition, her low platelets are a contraindication to an invasive procedure such as this.

E Coombs' test

This will be negative in TTP, and is unlikely to be of diagnostic benefit.

7456

Rate this question:

© Pastest 2019

A 76-year-old man who is known to have ischaemic heart disease, suffers a collapse and cardiac arrest whilst out walking his dog with his daughter. On arrival in the Emergency Department, he has already been intubated and CPR has commenced. He is pulseless with no respiratory effort. ECG on the defibrillator reveals small complexes with a normal morphology (PEA).

Which of the following is recommended as part of Advanced Life Support (ALS) 2015 guidelines?

A	Adrenalin 3mg repeated every 2 minutes
B	Amiodarone 300mg IV bolus
C	Adrenalin 1mg repeated every 3-5 minutes
D	Atropine 3mg repeated every 2 minutes
E	rTPA IV bolus

34144

Submit

Previous Q... Skip Questi...

© Pastest 2019

D Atropine 3mg repeated every 2 minutes

E rTPA IV bolus

Explanation

C Adrenalin 1mg repeated every 3-5 minutes

In the presence of a non-shockable rhythm as in this case, the use of adrenaline (1mg) every alternate cycle of CPR is recommended. It should be given once IV or IO access is attained.

The problem of designing ALS guidelines is that randomised controlled trial evidence is obviously difficult to obtain. Despite this, based on animal experience and the known alpha adrenergic agonist activity of adrenaline, use is still recommended in pulseless electrical activity (PEA) and asystole, every 3-5 minutes (alternate cycles of cardiopulmonary resuscitation (CPR)), and in ventricular fibrillation (VF)/ventricular tachycardia (VT) which is non-responsive to shocking, also every 3-5 minutes.

A Adrenalin 3mg repeated every 2 minutes

In the presence of a non-shockable rhythm as in this case, the use of adrenaline (1mg not 3mg) every alternate cycle of CPR is recommended.

B Amiodarone 300mg IV bolus

The use of amiodarone is only recommended in a shockable rhythm after 3 unsuccessful shocks.

Scroll capture Draw Crop

fibrillation (VF)/ventricular tachycardia (VT) which is non-responsive to shocking, also every 3-5 minutes.

A Adrenalin 3mg repeated every 2 minutes

In the presence of a non-shockable rhythm as in this case, the use of adrenaline (1mg not 3mg) every alternate cycle of CPR is recommended.

B Amiodarone 300mg IV bolus

The use of amiodarone is only recommended in a shockable rhythm after 3 unsuccessful shocks.

D Atropine 3mg repeated every 2 minutes

The use of atropine is not indicated in ALS guidelines for PEA arrest. Atropine was recommended until 2005, but several studies since then have not supported it's use, it is therefore no longer recommended.

E rTPA IV bolus

The use of thrombolysis is not indicated in ALS guidelines for PEA arrest. In the context of a MI causing the initial cardiac arrest, PCI should be considered if feasible.

Rate this question:

Next Question

Previous Q... Tag Questi... Feedback End Session

A 19-year-old woman presents with exertional breathlessness and palpitations. On examination there are giant v waves on inspection of her jugular venous pulse (JVP) and a left parasternal heave on palpation of her chest. There is a systolic murmur on auscultation and mild pitting oedema of both ankles.
She undergoes an echocardiogram that confirms the presence of elevated right-sided pressures with tricuspid regurgitation.

She undergoes a left and right heart catheter, which yields the following data:

Sample site	Oxygen saturations (%)
Inferior vena cava	62
Superior vena cava	58
Right atrium	80
Right ventricle	78
Pulmonary artery	78
Arterial saturation	97

Given these data, which is the likeliest diagnosis?

A Patent ductus arteriosus

B Primary pulmonary hypertension

C Patent foramen ovale

D Mitral stenosis

E Chronic pulmonary thromboembolism

B Primary pulmonary hypertension

C Patent foramen ovale

D Mitral stenosis

E Chronic pulmonary thromboembolism

Explanation

C Patent foramen ovale

The oxygen saturation data show a step-up in the saturations between the vena cava and the right atrium. This signifies the existence of a left-to-right shunting of oxygenated blood at the level of the atrium. This could be a result of an atrial septal defect (ASD) or a patent foramen ovale (PFO). PFOs are relatively common in younger patients. Autopsy studies have shown a prevalence of up to 30%. Opinion is divided on whether ASD represents an increased risk of stroke secondary to a paradoxical embolus. The presence of ASD is also thought to be associated with the development of migraine in some patients.

A Patent ductus arteriosus

A patent ductus is associated with a systolic machinery murmur, and the cardiac catheterisation confirms that the shunt is at the level of the atrium.

B Primary pulmonary hypertension

Primary pulmonary hypertension isn't associated with a shunt at the level of the atria, although it is associated with right-sided cardiac failure

A patent ductus is associated with a systolic machinery murmur, and the cardiac catheterisation confirms that the shunt is at the level of the atrium.

B Primary pulmonary hypertension

Primary pulmonary hypertension isn't associated with a shunt at the level of the atria, although it is associated with right-sided cardiac failure.

D Mitral stenosis

Mitral stenosis is associated with a diastolic murmur; tricuspid regurgitation is associated with a systolic murmur. It is also not associated with the atrial shunt seen here.

E Chronic pulmonary thromboembolism

In chronic PE, pulmonary hypertension would be expected although an atrial shunt would not be seen.

Rate this question:

Next Question

Previous Q... Tag Questi... Feedback End Session

Blog About Pastest Contact Us Help

© Pastest 2019

A 55-year-old homeless man is brought into the accident and emergency department having been found collapsed in an alley. On admission he is unconscious with a pulse rate of 50/min and a blood pressure of 110/70 mmHg. Pupils are equal and reactive and the tone is normal in all four limbs. A 12-lead shows an AV junctional rhythm, prominent J-waves in the precordial leads and a corrected QT interval of 0.64 s. There are no acute ischaemic changes.

Initial blood results are shown below:

WCC	4.5×10^9/l
Hb	13.6 g/dl
Urea	9 mmol/l (2.5–7.5)
Creatinine	120 mmol/l (60–110)
Potassium	3.2 mmol/l (3.5–4.9)
Sodium	136 mmol/l (137–144)
Blood alcohol level	100 mg/dl
Troponin-I	Normal

What is the cause of the prolonged QT interval?

A Hypokalaemia

B Hyperthermia

C Alcohol

D Hypothermia

E Intracranial haemorrhage

10:27

C Alcohol

D Hypothermia

E Intracranial haemorrhage

Explanation

D Hypothermia

The presence of J-waves, QTc of 640ms and junctional rhythm is typical of hypothermia. With a normal neurological examination and relatively normal blood tests, this is the most likely cause of the presentation of this gentleman.

The typical ECG features of hypothermia are J-waves, prolonged QT interval and AV junctional rhythm. J-waves are positive deflections in the terminal portion of the QRS complex and are highly sensitive and specific for hypothermia. Other causes of J-waves include hypercalcemia and intracranial pathology like subarachnoid haemorrhage.

A Hypokalaemia

Hypokalaemia is one of the causes of prolonged QT. ECG changes of hypokalaemia includes prolonged PR, flattened T waves and presence of U wave (best seen in chest leads). These are not present in this patient.

B Hyperthermia

Hyperthermia normally causes the tachycardia and hypertension instead of the bradycardia seen in this patient.

Rana Alnasser's screen

10:28
On ...
625-262-0256
Leave

Hyperthermia normally causes the tachycardia and hypertension instead of the bradycardia seen in this patient.

C Alcohol

Even though the blood alcohol level of the patient is raised, it is not at the level which you would expect it to be at for a patient to be in a comatose state. Alcohol consumption or intoxication is more commonly associated with tachyarrhythmias like atrial fibrillation.

E Intracranial haemorrhage

Although intracranial haemorrhage can cause reduced consciousness and J waves on ECG, with the normal neurological examination, it is very unlikely.

Elevated intracranial pressure, for instance in the setting of an intracranial haemorrhage, is also a potential cause for QT prolongation and would need to be considered along with electrolyte abnormalities if treatment of the patient's hypothermia did not improve his condition.

Rate this question:

© Pastest 2019

Audio Video Share Participants More

10:28

A 25-year-old woman who is 24 weeks pregnant presents to the Emergency Department with sudden-onset left-sided pleuritic chest pain. She is obese, but has no previous medical history, and until now her pregnancy has gone very well. On examination she is dyspnoeic, her BP is 115/70 mmHg, pulse is 110/min and regular. Heart sounds are normal and her chest is clear. O_2 saturations are 92% on air. Her legs appear grossly normal.

Investigations:

Hb	11.4 g/dl
WCC	7.8 x10^9/l
PLT	201 x10^9/l
Na^+	137 mmol/l
K^+	4.4 mmol/l
Creatinine	100 micromol/l
CXR	Clear lung fields

Which of the following is the most appropriate diagnostic investigation for this patient?

A D-dimer

B CTPA

C V/Q scan

D Bilateral lower limb Doppler ultrasound

E Echocardiogram

Rana Alnasser's screen

Explanation

C V/Q scan

The history of acute-onset dyspnoea, pleuritic chest pain and pregnancy should raise the suspicion of acute pulmonary embolism.

ESC guidelines on the investigation and management of pulmonary embolism state that exposure of the foetus to ionizing radiation is a concern when investigating suspected PE during pregnancy, although this concern is largely overruled by the hazards of missing a potentially fatal diagnosis. This is particularly true for pregnant patients with suspected high-risk PE. Moreover, erroneously assigning a diagnosis of PE to a pregnant woman is also fraught with risks, since it unnecessarily exposes the mother and foetus to the risks of anticoagulant treatment and will impact on delivery plans, future contraception and thromboprophylaxis during future pregnancies. Therefore, investigations should aim at diagnostic certainty.

While CTPA and V/Q scanning offer comparable diagnostic accuracy in pregnancy, and are both below acceptable foetal radiation exposure limits (with the main risk being a small increase in childhood cancers), CTPA provides a significantly increased radiation dose to maternal breast tissue, with a subsequent increase in breast cancer risk. Therefore the RCOG 2015 guidelines for thromboembolic disease in pregnancy state that 'It would be prudent to recommend that lung perfusion scans should be considered the investigation of first choice for young women, especially if there is a family history of breast cancer or the patient has had a previous chest CT scan'.

Additionally, if the CXR is normal, the ventilation component of V/Q scanning can often be omitted thereby further minimising the radiation dose for the foetus.

A D-dimer

This is a young patient with a normal chest X-ray and, as such, V/Q scanning would be the recommended diagnostic modality. CT scanning represents a higher radiation dose to maternal breast tissue, and subsequent increase in breast cancer risk.

D	Bilateral lower limb Doppler ultrasound

In the presence of symptoms and signs of DVT, compression duplex ultrasound should be undertaken. In this case, there is no clinical evidence of DVT and therefore Doppler ultrasound is not the most appropriate diagnostic option.

E	Echocardiogram

While echocardiogram may be useful as an urgent investigation in cases of suspected massive/life-threatening PE to guide decisions regarding thrombolysis, in this case where the patient is haemodynamically stable, echocardiography is a less diagnostically appropriate investigation than CTPA or V/Q imaging.

Rate this question:

Next Question

Previous Q... Tag Questi... Feedback End Session

Blog About Pastest Contact Us Help

© Pastest 2019

Explanation

C	Start pegylated interferon

The patient has eAg-negative chronic hepatitis B. The eAg negativity indicates there is not active viral replication, but the raised ALT and high viral tires indicate chronic active infection, which is confirmed on biopsy and therefore necessitates treatment. NICE guidelines now recommend treatment in patients who meet the following criteria:

- Adults >30 years with HBV DNA >2000 IU/ml and abnormal ALT (>30 IU/ml in males and >19 IU/ml in females) on 2 consecutive tests, 3 months apart.
- Adults <30 years with HBV DNA >2000 IU/ml and abnormal ALT (>30 IU/ml in males and >19 IU/ml in females) on 2 consecutive tests, 3 months apart if there is evidence of necro-inflammation or fibrosis on liver biopsy or transient elastography score >6 kPa.
- Adults who have HBV DNA >20,000 IU/ml and abnormal ALT (>30 IU/ml in males and >19 IU/ml in females) on 2 consecutive tests conducted 3 months apart regardless of age or the extent of liver disease.
- Patients without a liver biopsy to adults with a transient elastography score >11 kPa.

NICE recommends first-line treatment with Peginterferon alfa-2a in patients with compensated liver disease for 48 weeks. Entecavir and tenofovir are offered as second-line treatments where PEG-interferon therapy has failed or is not tolerated.

A	Close monitoring of liver function test

The patient has chronic hepatitis B with histological evidence of early cirrhosis, making treatment an imperative to avoid progression to further fibrosis and to reduce hepatocellular carcinoma risk.

B	Repeat biopsy in 2 years

Having established that the patient has early cirrhosis, it is clear

9:39
On 594-042-7551 Leave

A 48-year-old woman with a mitral valve prosthesis for the last 5 years presents with severe shortness of breath. The shortness of breath started a few days ago but has rapidly worsened for past 2 hours. The patient had not taken her warfarin for the past 5 days. On examination the patient is sitting up in the bed, pulse rate is 110 bpm, blood pressure 78/55 mmHg; jugular venous pulsations are seen up to the angle of the jaw, heart sounds are muffled and inspiratory crackles can be heard all over the chest. Urgent transthoracic echocardiography is ordered; though the visualisation is poor, it suggests a thrombus attached to the mitral prosthesis.

What is the next management step for this patient?

A	IV alteplase
B	IV heparin infusion
C	Immediate valve replacement
D	Transoesophageal echocardiography (TEE)
E	Check her international normalised ratio (INR)

Submit

Audio Video Share Participants More

9:42

last 5 years presents with severe shortness of breath. The shortness of breath started a few days ago but has rapidly worsened for past 2 hours. The patient had not taken her warfarin for the past 5 days. On examination the patient is sitting up in the bed, pulse rate is 110 bpm, blood pressure 78/55 mmHg; jugular venous pulsations are seen up to the angle of the jaw, heart sounds are muffled and inspiratory crackles can be heard all over the chest. Urgent transthoracic echocardiography is ordered; though the visualisation is poor, it suggests a thrombus attached to the mitral prosthesis.

What is the next management step for this patient?

Ses
Respons
Respons
Respons
Respons

Your answer was incorrect

A	IV alteplase
B	IV heparin infusion
C	Immediate valve replacement
D	Transoesophageal echocardiography (TEE)
E	Check her international normalised ratio (INR)

Explanation

A IV alteplase

The patient has a prosthetic valve thrombosis (PVT) resulting in shock. This complication occurs in 0.03–5.5% annually with equal frequency in bioprosthesis and mechanical valves. It is more common in mitral prosthesis

A IV alteplase

The patient has a prosthetic valve thrombosis (PVT) resulting in shock. This complication occurs in 0.03–5.5% annually with equal frequency in bioprosthesis and mechanical valves. It is more common in mitral prosthesis and with subtherapeutic anticoagulation. If the patient is haemodynamically unwell (ie pulmonary oedema or hypotension) and no immediate surgery is available, thrombolytic therapy should be given. Serial echocardiography should be performed, and if the response is inadequate repeat thrombolytic therapy can be given.

B IV heparin infusion

If patients are haemodynamically stable and have a subtherapeutic anticoagulation in the context of a prosthetic valve thrombosis, Heparin ± aspirin can be administered with regular follow-up if successful. In this case however, the patient is haemodynamically unstable due to a prosthetic valve thrombosis secondary to likely subtherapeutic anticoagulation; therefore urgent thrombolysis should be considered.

C Immediate valve replacement

In stable patients, surgery is a better option for left-sided PVT, while right-sided PVT should be treated with thrombolytic agents. Surgery may be considered if patients are critically ill and immediate surgery is available; however an evaluation of risks and benefits must be sought, and in this acute scenario thrombolytic therapy should be administered.

D Transoesophageal echocardiography (TEE)

While TEE is the best diagnostic modality, transthoracic

A IV alteplase

The patient has a prosthetic valve thrombosis (PVT) resulting in shock. This complication occurs in 0.03–5.5% annually with equal frequency in bioprosthesis and mechanical valves. It is more common in mitral prosthesis and with subtherapeutic anticoagulation. If the patient is haemodynamically unwell (ie pulmonary oedema or hypotension) and no immediate surgery is available, thrombolytic therapy should be given. Serial echocardiography should be performed, and if the response is inadequate repeat thrombolytic therapy can be given.

B IV heparin infusion

If patients are haemodynamically stable and have a subtherapeutic anticoagulation in the context of a prosthetic valve thrombosis, Heparin ± aspirin can be administered with regular follow-up if successful. In this case however, the patient is haemodynamically unstable due to a prosthetic valve thrombosis secondary to likely subtherapeutic anticoagulation; therefore urgent thrombolysis should be considered.

C Immediate valve replacement

In stable patients, surgery is a better option for left-sided PVT, while right-sided PVT should be treated with thrombolytic agents. Surgery may be considered if patients are critically ill and immediate surgery is available; however an evaluation of risks and benefits must be sought, and in this acute scenario thrombolytic therapy should be administered.

D Transoesophageal echocardiography (TEE)

While TEE is the best diagnostic modality, transthoracic

9:44

A 28-year-old man presents to the Emergency Department after collapsing at a swimming pool. He cannot recall any detail of the collapse. Collateral history confirmed that he collapsed after swimming and there was no seizure activity after the collapse. A rapid heart rate was detected by the first attender at the scene. He has no past medical history, drug history or history of alcohol or drug abuse. He confirmed a family history of unexplained sudden death. The 12-lead electrocardiogram showed a sinus rhythm with corrected QT interval of 0.5 s.

What is the most likely cause of his collapse?

A	JLN1 mutation
B	JLN2 mutation
C	LQT1 mutation
D	LQT3 mutation
E	LQT7 mutation

Submit

Previous Q... Skip Questi...

A 28-year-old man presents to the Emergency Department after collapsing at a swimming pool. He cannot recall any detail of the collapse. Collateral history confirmed that he collapsed after swimming and there was no seizure activity after the collapse. A rapid heart rate was detected by the first attender at the scene. He has no past medical history, drug history or history of alcohol or drug abuse. He confirmed a family history of unexplained sudden death. The 12-lead electrocardiogram showed a sinus rhythm with corrected QT interval of 0.5 s.

What is the most likely cause of his collapse?

Diff

Pee

Ses

Respons

Respons

Respons

Respons

Your answer was correct

A	JLN1 mutation
B	JLN2 mutation
C	LQT1 mutation
D	LQT3 mutation
E	LQT7 mutation

Explanation

C LQT1 mutation

Romano-Ward syndrome (LQT 1-6 mutations) can present with recurrent syncopal episodes precipitated by emotions or physical activities such as swimming. LQT1 and 2 make up the majority of cases of long QT (around 90% of the

Explanation

C LQT1 mutation

Romano-Ward syndrome (LQT 1-6 mutations) can present with recurrent syncopal episodes precipitated by emotions or physical activities such as swimming. LQT1 and 2 make up the majority of cases of long QT (around 90% of the total).

A JLN1 mutation

Jervell-Lange-Nielsen syndrome (JLN 1 and 2 mutations) is rare and is usually associated with deafness. It has a markedly higher incidence in Scandinavia (particularly Norway and Sweden).

B JLN2 mutation

Jervell-Lange-Nielsen syndrome (JLN 1 and 2 mutations) is rare and is usually associated with deafness. JLN2 is seen even less frequently than JLN1 mutation (making up around 10% of cases of the syndrome).

D LQT3 mutation

LQT3 mutations usually have tachy-arrhythmic events during sleep, as this is usually triggered by bradycardia. Cardiac pacing is potentially helpful. LQT3 mutations are a less frequent (7%) cause of long QT, but are more frequently lethal.

E LQT7 mutation

Anderson syndrome is extremely rare. It is associated with skeletal abnormalities and periodic episodes of muscle

A JLN1 mutation

Jervell-Lange-Nielsen syndrome (JLN 1 and 2 mutations) is rare and is usually associated with deafness. It has a markedly higher incidence in Scandinavia (particularly Norway and Sweden).

B JLN2 mutation

Jervell-Lange-Nielsen syndrome (JLN 1 and 2 mutations) is rare and is usually associated with deafness. JLN2 is seen even less frequently than JLN1 mutation (making up around 10% of cases of the syndrome).

D LQT3 mutation

LQT3 mutations usually have tachy-arrhythmic events during sleep, as this is usually triggered by bradycardia. Cardiac pacing is potentially helpful. LQT3 mutations are a less frequent (7%) cause of long QT, but are more frequently lethal.

E LQT7 mutation

Anderson syndrome is extremely rare. It is associated with skeletal abnormalities and periodic episodes of muscle weakness, as well as long-QT syndrome.

Rate this question:

Next Question

Previous Q... Tag Questi... Feedback End Session

9:49

A 59-year-old man presents to the Emergency Department with profuse sweating and central, crushing chest pain. He has a history of smoking 30 cigarettes per day and hypertension, which is managed with ramipril and amlodipine. On examination he has a BP of 70/50 mmHg and pulse of 22 beats per minute. There are no significant murmurs on auscultation of his heart. His CXR reveals no mediastinal widening. He has already been given 1 mg of atropine by the paramedic staff.

His ECG is shown below.

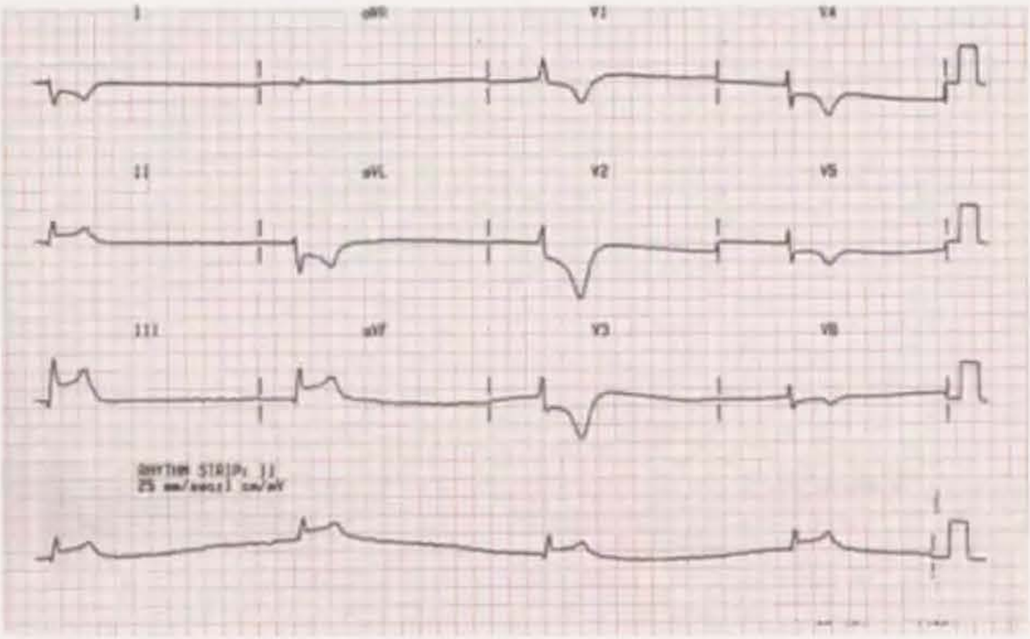

Which of the following is the most likely diagnosis?

A	Complete heart block with anterior MI
B	1st degree heart block with inferior MI
C	2nd degree heart block with inferior MI
D	2nd degree heart block with anterior MI
E	Complete heart block with inferior MI

Rana Alnasser's screen

9:52
On 594-042-7551 Leave

Explanation

E	Complete heart block with inferior MI

He has an inferior myocardial infarction with clear evidence of ST elevation in the inferior leads (II, III, aVF). Additionally there is complete heart block with significant circulatory compromise. It is unlikely that further atropine would improve the bradycardia seen, given that there has been no significant response to 1 mg. The debate is between progressing straight to PCI or considering temporary transvenous pacing before commencing the procedure. Given that the systolic BP is only 70 mmHg, temporary pacing is the prudent next option.

A	Complete heart block with anterior MI

While the ECG shown demonstrates complete heart block, the ST elevation seen corresponds to an inferior, not an anterior, MI.

B	1st degree heart block with inferior MI

While the ECG shown demonstrates ST elevation consistent with MI, there is no correlation between atrial and ventricular activity, suggestive of complete heart block. In 1st degree HB there is prolongation of the PR interval but a preserved 1:1 relationship between P waves and QRS complexes.

C	2nd degree heart block with inferior MI

While the ECG shown demonstrates ST elevation consistent with inferior MI, there is no correlation between atrial and ventricular activity, suggestive of complete heart block. In 2nd degree HB there is either progressive prolongation of the PR interval before a dropped

Audio Video Share Participants More

Touc... 00:06 9:54

A 75-year-old retired accountant is on warfarin 4 mg per day, which was started a year ago when he had a stroke and was found to have chronic atrial fibrillation. His only other medication is amlodipine 10 mg per day for isolated systolic hypertension. He now presents with a history of minor gum bleeding of one day's duration. On examination he appears well and has a blood pressure of 165/85 mmHg with no postural drop, a pulse rate of 73/min and respiratory rate of 18/min. The rest of his physical examination is unremarkable except for mild right-sided hemiparesis.

Investigations:

Sodium	135 mmol/l
Potassium	4.5 mmol/l
Urea	10 mmol/l
Creatinine	70 µmol/l
International normalised ratio (INR)	9
Dipstick urine	2+ blood

What is the most appropriate next step in the management of this patient?

A Stop warfarin and administer fresh-frozen plasma 10 ml/kg

B Stop warfarin and administer phytomenadione (vitamin K1) 5 mg IV

C Stop warfarin and administer phytomenadione 1 mg IV

D Stop warfarin and administer prothrombin complex concentrate

Rana Alnasser's screen

9:55
On 594-042-7551 Leave

Sodium	135 mmol/l
Potassium	4.5 mmol/l
Urea	10 mmol/l
Creatinine	70 µmol/l
International normalised ratio (INR)	9
Dipstick urine	2+ blood

What is the most appropriate next step in the management of this patient?

A Stop warfarin and administer fresh-frozen plasma 10 ml/kg

B Stop warfarin and administer phytomenadione (vitamin K1) 5 mg IV

C Stop warfarin and administer phytomenadione 1 mg IV

D Stop warfarin and administer prothrombin complex concentrate

E Stop warfarin and restart when the INR is less than 5

Submit

Audio Video Share Participants More

A 75-year-old retired accountant is on warfarin 4 mg per day, which was started a year ago when he had a stroke and was found to have chronic atrial fibrillation. His only other medication is amlodipine 10 mg per day for isolated systolic hypertension. He now presents with a history of minor gum bleeding of one day's duration. On examination he appears well and has a blood pressure of 165/85 mmHg with no postural drop, a pulse rate of 73/min and respiratory rate of 18/min. The rest of his physical examination is unremarkable except for mild right-sided hemiparesis.

Investigations:

Sodium	135 mmol/l
Potassium	4.5 mmol/l
Urea	10 mmol/l
Creatinine	70 µmol/l
International normalised ratio (INR)	9
Dipstick urine	2+ blood

What is the most appropriate next step in the management of this patient?

Your answer was incorrect

A Stop warfarin and administer fresh-frozen plasma 10 ml/kg

B Stop warfarin and administer phytomenadione (vitamin K1) 5 mg IV

C Stop warfarin and administer phytomenadione 1

Session

Responses C

Responses In

Responses To

Responses -

9:56

Explanation

C	Stop warfarin and administer phytomenadione 1 mg IV

The *British National Formulary (BNF)* recommends that patients with minor or no bleeding with an international normalised ratio (INR) above 8 should have their warfarin stopped and restarted when the INR is below 5. However, for patients who are at increased risk of bleeding, it recommends phytomenadione to be administered 5 mg orally or 1-3 mg by slow IV injection. IV administration is recommended because it is not subject to the variance seen with oral absorption, and will achieve reversal more rapidly.

A repeat dose of phytomenadione can be given if the INR remains too high after 24 h.

D	Stop warfarin and administer prothrombin complex concentrate

Prothrombin complex concentrate is reserved for cases of life-threatening bleeding, otherwise giving phytomenadione and stopping warfarin is sufficient.

A	Stop warfarin and administer fresh-frozen plasma 10 ml/kg

Fresh frozen plasma is used for emergent reversal of warfarin overdose - for example, patients who are suffering from life-threatening bleeding, such as an actively bleeding peptic ulcer with high INR.

B	Stop warfarin and administer phytomenadione

9:58
On 594-042-7551 Leave

(vitamin K1) 5 mg IV

For patients who are at increased risk of bleeding, BNF recommends that phytomenadione be administered 5 mg orally or 1-3 mg by slow IV injection - not 5 mg IV.

E Stop warfarin and restart when the INR is less than 5

The patient is still at risk of bleeding with high INR, and therefore a reversal treatment is required, such as phytomenadione, instead of just stopping warfarin. Risk factors that put a patient at increased risk of bleeding with warfarin therapy include:

- age above 70 years
- hypertension particularly if systolic BP is above 160 mmHg
- previous history of stroke
- increased intensity of anticoagulation (INR >3)
- combination therapy with warfarin and aspirin.

Rate this question:

Next Question

Previous Q... Tag Questi... Feedback End Session

© Pastest 2019

Audio Video Share Participants More

9:59

Cal

Norm

A 79-year-old woman attends the cardiology clinic complaining of recurrent syncopal attacks. She has had two severe fainting episodes when she felt her heart was beating slowly. Although she had a myocardial infarction 10 years earlier she has been relatively well since, and is currently taking ramipril 10mg daily and bendroflumethiazide 2.5mg daily. On examination she has a blood pressure of 130/80 mmHg with a pulse of 70/min, although there are regular dropped beats.

Her ECG is shown below;

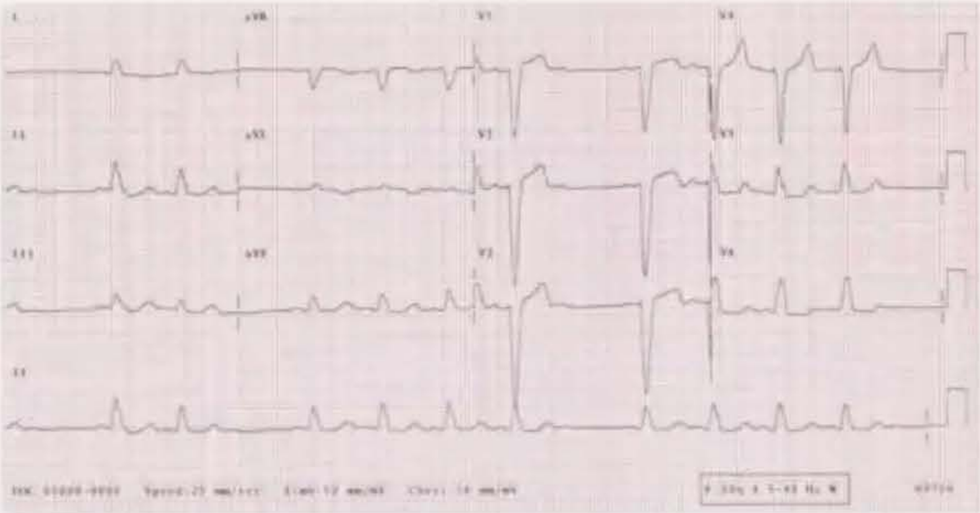

Which of the following is the most appropriate management for her?

A	Atropine IV
B	Isoprenaline IV
C	Reassurance and discharge from the clinic
D	See in 6 months with a 24hr holter monitor before clinic
E	Referral for permanent pacemaker

Rana Alnasser's screen

currently taking ramipril 10mg daily and bendroflumethiazide 2.5mg daily. On examinatio blood pressure of 130/80 mmHg with a pulse o although there are regular dropped beats.

Her ECG is shown below;

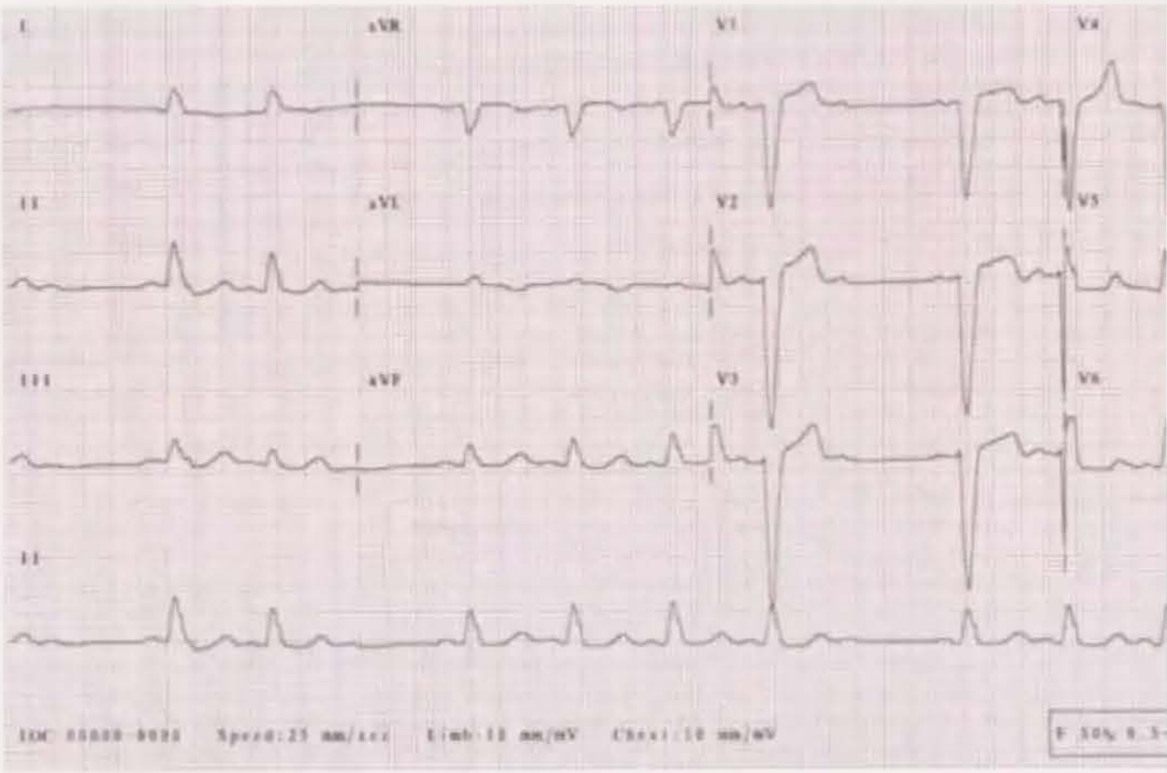

Which of the following is the most appropriate management for her?

A	Atropine IV
B	Isoprenaline IV
C	Reassurance and discharge from the clin
D	See in 6 months with a 24hr holter moni

10:06
On 594-042-7551 Leave

E Referral for permanent pacemaker

Explanation

E Referral for permanent pacemaker

Mobitz Type 2 is a high risk bradyarrhythmia and her syncopal attacks are almost certainly related to the ECG changes seen here. Optimal management is therefore referral for permanent pacing. If she were managed with digoxin, beta-blockers or calcium antagonists, then discontinuation of these therapies or dose reduction would be an appropriate strategy before moving to permanent pacing, although the absence of these medications in this case, would leave progression to permanent pacing as the most appropriate option.

A Atropine IV

The ECG shows Mobitz Type 2 Av block. This is an indication for pacing. In the absence of haemodynamic compromise, the use of atropine is not required. According to the ALS peri-arrest guidelines 2015, the use of atropine is indicated for patients with bradycardia and evidence of haemodynamic compromise i.e. shock, syncope, myocardial ischemia and heart failure

B Isoprenaline IV

The ECG shows Mobitz Type 2 Av block. This is an indication for pacing. In the absence of haemodynamic compromise, the use of isoprenaline is not required. In the ALS peri-arrest guidelines, the use of isoprenaline should only be considered after the use of atropine with inadequate response.

Audio Video Share Participants More

has mild pitting oedema affecting both ankles.

Investigations:

Hb	12.9 g/dl
WCC	6.4 $\times 10^9$/l
PLT	189 $\times 10^9$/l
Na^+	137 mmol/l
K^+	5.0 mmol/l
Creatinine	115 micromol/l
Glucose	5.1 mmol/l
CXR	Cardiomegaly
Echocardiogram	Left ventricular ejection fraction 32%
ECG	Sinus rhythm with poor R-wave progression

Which of the following is the most appropriate next step to improve mortality?

A Cardiac resynchronisation therapy (CRT)

B Increase furosemide

C Increase spironolactone

D Start digoxin

E Start ivabradine

Submit

E Start ivabradine

Explanation

E Start ivabradine

This case is one of a patient with significant heart failure on a wide range of medications appropriate for their clinical case. Despite this, they have continued to deteriorate. Ivabradine acts as an inhibitor of the I_f current within the myocardium. This current, particularly present in the sino-atrial and atrio-ventricular nodes, acts as the cardiac pacemaker. By inhibiting this current, ivabradine reduces the heart rate without impacting the force of cardiac contraction. This has been shown to reduce heart failure hospitalisation and mortality in patients already on maximum medical therapy. Due to its mechanism, ivabradine is only effective in patients in sinus rhythm.

A Cardiac resynchronisation therapy (CRT)

CRT is a type of cardiac device designed to stimulate the septal and lateral walls of the left ventricle to contract at the same time. This improves cardiac output and results in improved heart failure symptoms in some patients. This is only a benefit when the contraction of the patinet's left ventricle is dys-synchronous prior to device implantation. Ventricular dys-synchrony is suggested by an ECG showing a broad QRS complex (especially LBBB). Because this is not demonstrated here, implantation of such a device is not indicated.

B Increase furosemide

overloaded. Furosemide improves heart failure symptom burden but does not improve survival in heart failure. Given a lack of significant fluid overload, up-titration of furosemide is unlikely to improve the clinical situation significantly.

C Increase spironolactone

Use of K^+-sparing diuretics (e.g. spironolactone) in heart failure has been shown to improve mortality in those already on maximal tolerated doses of both an ACE inhibitor and β-blocker. Spironolactone at 25 mg OD is the standard dose for this medication in heart failure. There is no significant evidence to suggest that an increase in dose improves outcomes in heart failure patients. In this particular patient, the K^+ concentration is already on the upper limit of normal and increasing this diuretic may further increase this level.

D Start digoxin

Digoxin decrea force of contraction thr $^+$ ATPase. Digoxin has bee admissions for patients with heart failure but does not improve mortality. In clinical practice it is primarily used in patients with heart failure and atrial fibrillation (not present in this case).

Rajaa Adris joined

Rana Alnasser's screen

A 48-year-old man is admitted for investigation following three episodes of collapse over the past month. The episodes were self-limiting, each lasting 2–3 min and associated with some twitching of the limbs. There was no tongue biting or loss of continence and he was not confused after the attacks. On examination, he has an ejection systolic murmur at the right sternal border and reversed splitting of S2. His electrocardiogram (ECG) shows sinus rhythm with left ventricular hypertrophy and strain. Chest X-ray shows an area of calcification overlying the cardiac silhouette.

Which diagnosis fits best with this clinical picture?

A	Aortic stenosis
B	Aortic regurgitation
C	Hypertrophic cardiomyopathy
D	Coarctation of the aorta
E	Aortic sclerosis

32353

Submit

A 48-year-old man is admitted for investigation following three episodes of collapse over the past month. The episodes were self-limiting, each lasting 2–3 min and associated with some twitching of the limbs. There was no tongue biting or loss of continence and he was not confused after the attacks. On examination, he has an ejection systolic murmur at the right sternal border and reversed splitting of S2. His electrocardiogram (ECG) shows sinus rhythm with left ventricular hypertrophy and strain. Chest X-ray shows an area of calcification overlying the cardiac silhouette.

Which diagnosis fits best with this clinical picture?

Your answer was correct

A Aortic stenosis

B Aortic regurgitation

C Hypertrophic cardiomyopathy

D Coarctation of the aorta

E Aortic sclerosis

Explanation

A Aortic stenosis

The signs of aortic stenosis include: an ejection systolic murmur, loudest in the aortic area, which radiates to the carotids and axilla; a slow rising, small volume pulse; and, in severe stenosis, there may be reversed splitting of S2. LVH and strain on ECG shows the compensatory mechanism the heart has developed to cope with the aortic stenosis

Explanation

A Aortic stenosis

The signs of aortic stenosis include: an ejection systolic murmur, loudest in the aortic area, which radiates to the carotids and axilla; a slow rising, small volume pulse; and, in severe stenosis, there may be reversed splitting of S2. LVH and strain on ECG shows the compensatory mechanism the heart has developed to cope with the aortic stenosis. Calcification on CXR is an indication that the valve is heavily calcified.

Aortic stenosis may be asymptomatic. Symptoms include syncope, angina and dyspnoea although the classical presentation with all 3 is only found in 30-40% of individuals with aortic stenosis.

The patient in this case is describing typical cardiogenic syncope with unprovoked attacks and generally quick recovery periods.

When symptoms appear, survival without surgery is only on average 2-3 years and is therefore an indication for surgical intervention. Sudden death occurs in 1-2% of asymptomatic patients per year. Causes of aortic stenosis include congenital or rheumatic heart disease, bicuspid valve, degenerative calcification and hypertrophic obstructive cardiomyopathy. In asymptomatic patients, the valve is usually replaced when the pressure gradient across the valve exceeds 50 mmHg.

B Aortic regurgitation

Aortic regurgitation causes a diastolic murmur and other signs like collapsing pulse which is not present in this patient. It causes LV dilatation instead of hypertrophy as it causes a volume overload state.

C Hypertrophic cardiomyopathy

The presence of LVH with strain could be an indication of HCM. The murmur could only be present if there is LV outflow tract obstruction as in the case of hypertrophic obstructive cardiomyopathy (HOCM). With the presence of calcification on CXR, it makes it more likely to be valve calcification as the cause.

D Coarctation of the aorta

Coarctation of aorta produces a late systolic murmur and radio-femoral delay. Rib notching present on chest x-ray is due to pressure erosion from enlarged collateral vessels. Patients may present with hypertension, headaches, nose bleeds, cold peripheries or intermittent claudication

E Aortic sclerosis

Aortic sclerosis is the presence of calcification on aortic valve with no outflow tract obstruction. It will produce the systolic murmur and CXR findings but would not cause the splitting of S2, LVH on ECG or the symptoms the patient is experiencing.

Rate this question:

Next Question

Previous Q... Tag Questi... Feedback End Session

Blog About Pastest Contact Us Help

© Pastest 2019

A 32-year-old man with a history of Marfan's disease comes to the Emergency Department. He is complaining of severe central chest pain radiating to his back. He has a previous lens dislocation and takes beta-blockers to reduce the risk for aortic dissection. He smokes ten cigarettes per day and has a family history of hypercholesterolaemia.

Examination reveals a blood pressure (BP) of 132/80 mmHg and a pulse of 90 bpm and regular, and he is in pain. His chest is clear.

Investigations:

Haemoglobin (Hb)	13.1 g/dl
White cell count (WCC)	8.2×10^9/l
Platelets (PLT)	193×10^9/l
Sodium (Na)	137 mmol/l
Potassium (K)	4.3 mmol/l
Creatinine	100 μmol/l
Chest X-ray	Moderate mediastinal widening, in keeping with chest X-ray findings from 6 months previously
Electrocardiogram (ECG)	Inferior T-wave inversion

Which of the following is the most appropriate next step?

A	Aspirin, fondaparinux and clopidogrel
B	Computerised tomography (CT) angiogram of the aorta
C	Observation pending troponin result

Creatinine	100 μmol/l
Chest X-ray	Moderate mediastinal widening, in keeping with chest X-ray findings from 6 months previously
Electrocardiogram (ECG)	Inferior T-wave inversion

Which of the following is the most appropriate next step?

A Aspirin, fondaparinux and clopidogrel

B Computerised tomography (CT) angiogram of the aorta

C Observation pending troponin result

D Transthoracic echocardiography

E Urgent percutaneous coronary intervention (PCI)

390

Submit

Explanation

B	Computerised tomography (CT) angiogram of the aorta

The answer is Computerised tomography (CT) angiogram of the aorta (Option B).

This patient presents with clinical features highly suggestive of an aortic dissection. The typical symptoms of severe chest pain radiating to the back are demonstrated here. Furthermore, this patient has a history of Marfan's disease, a significant risk factor for aortic dissection. CT angiogram of the aorta is the gold standard imaging technique for the diagnosis of aortic dissection and should be undertaken urgently. This will be able to identify an aortic dissection and characterise whether it involves the ascending aorta.

A	Aspirin, fondaparinux and clopidogrel

Aspirin, fondaparinux and clopidogrel (Option A) is incorrect.

There are some features here that may suggest an acute coronary syndrome, including central chest pain and T-wave inversion on the ECG. However, this case highlights that aortic dissection can present similarly. It is vital to exclude the diagnosis of aortic dissection in this patient before giving either antiplatelet or anticoagulant agents, as these may be fatal if a dissection is present.

C	Observation pending troponin result

Observation pending troponin result (Option C) is incorrect.

A rise in troponin suggests damage to the myocardium and is primarily used in the diagnosis of a myocardial infarction. This patient does have features suggestive of a possible acute coronary syndrome, but an aortic dissection must be

myocardium requires approximately 10–12 hours to reach a peak, and waiting before obtaining a troponin result would be wasting valuable time in this patient. Furthermore, an aortic dissection can increase cardiac strain and lead to a positive troponin result, making the test non-specific for differentiating between these diagnoses.

D	Transthoracic echocardiography

Transthoracic echocardiography (Option D) is incorrect.

The likely diagnosis in this patient is aortic dissection. Echocardiography can reveal a dissection flap in the ascending aorta that would point towards a type A dissection. However, if no features of a dissection are revealed on echocardiography, this cannot rule out a dissection. As such, it is not the most appropriate next step in this patient.

E	Urgent percutaneous coronary intervention (PCI)

Urgent percutaneous coronary intervention (PCI) (Option E) is incorrect.

If this patient has an acute coronary syndrome, they may benefit from PCI. However, there is no evidence of ST-elevation on the ECG to suggest a full-thickness infarct of the myocardium that necessitates urgent PCI. An aortic dissection must be ruled out in this patient initially. If there is no dissection, then PCI could be considered for a possible non-ST-elevation acute coronary syndrome. On angiography, a dissection flap can be visualised in some cases when an aortogram is undertaken.

Rate this question:

Next Question

Annotation Stop Share

10:19

A 66-year-old man, admitted with infective endocarditis caused by *Streptococcus faecalis*, was treated with intravenous antibiotics for 6 weeks. He had a prosthetic metallic aortic valve put in 3 years ago for significant aortic stenosis.

Investigations:

Repeated blood cultures	-
Inflammatory markers (after 5 weeks' antibiotics)	Upper end of the normal range
Most recent trans-oesophageal echocardiogram (after 6 weeks' antibiotics)	Some tiny vegetations on the prosthetic aortic valve

How should this patient be managed?

A Change to oral antibiotics for another two weeks

B Discharge the patient

C Continue intravenous antibiotics for another week

D Do a trans-thoracic echocardiogram

E Replace the metallic aortic valve

Submit

Skip Questi...

Annotation Stop Share

Rana Alnasser's screen

intravenous antibiotics for 6 weeks. He had a prosthetic metallic aortic valve put in 3 years ago for significant aortic stenosis.

Investigations:

Repeated blood cultures	-
Inflammatory markers (after 5 weeks' antibiotics)	Upper end of the normal range
Most recent trans-oesophageal echocardiogram (after 6 weeks' antibiotics)	Some tiny vegetations on the prosthetic aortic valve

How should this patient be managed?

Your answer was correct

A Change to oral antibiotics for another two weeks

B Discharge the patient

C Continue intravenous antibiotics for another week

D Do a trans-thoracic echocardiogram

E Replace the metallic aortic valve

A
B
C
D
E
0

Resp
Resp
Resp
Resp

Explanation

B Discharge the patient

The patient could be discharged and followed up as an outpatient. Stratification of patients into groups that are at high and low risk for heart failure, systemic embolisation, need for surgical intervention and death, based on the presence or absence of vegetations, remains controversial

10:23

B Discharge the patient

The patient could be discharged and followed up as an outpatient. Stratification of patients into groups that are at high and low risk for heart failure, systemic embolisation, need for surgical intervention and death, based on the presence or absence of vegetations, remains controversial. In this patient, whose inflammatory markers have returned to normal, he could be followed as an outpatient because this indicates that it is unlikely there has been a further resurgence of infection. If there was a para-prosthetic leak or obstruction of the valve, the patient would probably need surgical intervention.

A Change to oral antibiotics for another two weeks

Inflammatory markers have returned to normal, and there is no evidence that continuing antibiotics is beneficial. The patient has completed the course.

C Continue intravenous antibiotics for another week

Inflammatory markers have returned to normal, and there is no evidence that continuing antibiotics is beneficial. The patient has completed the course.

D Do a trans-thoracic echocardiogram

Trans-oesophageal echo is more sensitive in picking up micro-vegetations than trans-thoracic echo.

E Replace the metallic aortic valve

In this patient, whose inflammatory markers have returned to normal, he could be followed as an outpatient because this indicates that it is unlikely there has been a further resurgence of infection. If there was a para-prosthetic leak

Annotation Stop Share

A Change to oral antibiotics for another two weeks

Inflammatory markers have returned to normal, and there is no evidence that continuing antibiotics is beneficial. The patient has completed the course.

C Continue intravenous antibiotics for another week

Inflammatory markers have returned to normal, and there is no evidence that continuing antibiotics is beneficial. The patient has completed the course.

D Do a trans-thoracic echocardiogram

Trans-oesophageal echo is more sensitive in picking up micro-vegetations than trans-thoracic echo.

E Replace the metallic aortic valve

In this patient, whose inflammatory markers have returned to normal, he could be followed as an outpatient because this indicates that it is unlikely there has been a further resurgence of infection. If there was a para-prosthetic leak or obstruction of the valve, the patient would probably need surgical intervention.

Rate this question:

Next Question

Previous Q... Tag Questi... Feedback End Session

Annotation Stop Share

Blog About Pastest Contact Us Help

A 71-year-old woman comes to the Hypertension Clinic for review. Her general practitioner (GP) is struggling to manage her hypertension, which is still poorly controlled despite treatment with ramipril 10 mg OD and amlodipine 5 mg OD.

On examination, her blood pressure is 155/95 mmHg, with pulse 65/min and regular. There are bibasal crackles on auscultation. There is no ankle swelling. Her abdomen is soft and non-tender with no palpable masses. Her body mass index (BMI) is 31 kg/m^2.

Investigations:

Hb	130 g/l
WCC	7.1 × 10^9/l
PLT	203 × 10^9/l
Na^+	140 mmol/l
K^+	4.9 mmol/l
Creatinine	112 µmol/l
Glucose	6.5 mmol/l

Which of the following is the most appropriate next step?

A Add atenolol

B Add bendroflumethiazide

C Add doxazosin

D Add indapamide

E Increase amlodipine to 10 mg OD

B Add bendroflumethiazide

C Add doxazosin

D Add indapamide

E Increase amlodipine to 10 mg OD

Explanation

D Add indapamide

This patient presents with significant ongoing hypertension. Along with other risk factors reported in the clinical vignette, she has a significant risk of vascular complications from her hypertension, which should be controlled aggressively. She is already on an ACE inhibitor and calcium channel blocker. The next step recommended in the NICE guideline (see below) would be to add a thiazide-like diuretic (such as indapamide).

A Add atenolol

Atenolol is a non-selective β-blocker. β-blockade is not recommended for routine treatment of hypertension, due to the limited benefit compared with other agents. Additionally, in this patient with a raised BMI, β-blockade is known to impair glucose tolerance.

B Add bendroflumethiazide

Bendroflumethiazide is a thiazide diuretic. Although commonly used for the treatment of hypertension, it is no longer recommended in current NICE guidance.

C Add doxazosin

10:27

A Add atenolol

Atenolol is a non-selective β-blocker. β-blockade is not recommended for routine treatment of hypertension, due to the limited benefit compared with other agents. Additionally, in this patient with a raised BMI, β-blockade is known to impair glucose tolerance.

B Add bendroflumethiazide

Bendroflumethiazide is a thiazide diuretic. Although commonly used for the treatment of hypertension, it is no longer recommended in current NICE guidance.

C Add doxazosin

Doxazosin is an α-blocker - these agents are not recommended for the routine treatment of hypertension. In the case of this patient, her previous MI increases the risk of heart failure, which would be worsened by the use of an α-blocker.

E Increase amlodipine to 10 mg OD

Up-titration of amlodipine to 10 mg OD is likely to result in only a modest reduction in systolic blood pressure (by ≤ 5 mmHg). As such, the patient will still require a further agent. Additionally, increasing the dose of amlodipine may increase the risk of adverse effects occurring (including ankle swelling).

Rate this question:

Next Question

Rana Alnasser's screen

10:27

A 54-year-old publican is admitted with shortness of breath and increasing peripheral oedema. He has extremely limited exercise tolerance and is barely able to move around the pub. On examination he has signs of chronic liver disease and biventricular cardiac failure. His blood pressure is 110/70 mmHg, with a pulse of 85/min. You diagnose cardiomyopathy. He admits that he is unable to reduce his consumption of alcohol.

Which of the following will have the biggest impact on his prognosis?

A	Alcohol cessation
B	Bisoprolol
C	Furosemide
D	Ramipril
E	Valsartan / sacubitril

70806

Submit

Previous Q... Skip Questi...

Rana Alnasser's screen

A Alcohol cessation

This patient has alcoholic cardiomyopathy, where the patient can gain rapid improvement in their symptoms as long as they give up alcohol. This improves ejection fraction, exercise tolerance and ultimately mortality. Unfortunately, with continued symptoms of heart failure, annual mortality approaches 20%.

E Valsartan / sacubitril

Valsartan/sacubitril does improve cardiac output and mortality in patients with dilated cardiomyopathy and is an important addition to alcohol cessation in improving outcomes, but is the second step in managing the condition after giving up alcohol.

B Bisoprolol

Heart failure associated with alcohol abuse is often low-output/hypotensive heart failure, meaning that there is a more limited role for beta blockade.

C Furosemide

Fluid offloading with loop diuretics is important in the management of alcoholic cardiomyopathy, although giving up alcohol is more important with respect to outcome.

D Ramipril

ACE inhibitors do have a positive impact on outcomes in alcoholic cardiomyopathy, although lower blood pressure and decreased renal perfusion associated with continued alcohol abuse may limit their effectiveness.

A 51-year-old man is referred to the cardiology clinic with palpitations. The palpitations have been there for 6 months. He gets palpitations every other day and they last for up to a minute. The palpitations are not associated with shortness of breath, chest pain or dizziness and there is no obvious precipitating factor. His past medical history is unremarkable and he is not on any medication.

On examination, he is comfortable with a blood pressure of 132/72 mmHg and pulse rate of 66/min. Apex beat is in the 5th intercostal space in the mid-clavicular line and the jugular venous pressure is not raised. First and second heart sounds are heard, and there is a mid-systolic click with a late systolic murmur of grade 2/6 radiating to the axilla. Respiration, abdominal and central nervous systems are all normal.

Investigations:

ECG	sinus rhythm
Chest X-ray	normal
FBC, U/Es, LFTs, TFTs and lipid profile	are within normal range
24-hour tape	sinus rhythm throughout except four separate episodes of premature ventricular ectopics (PVEs). These episodes comprised 4–9 PVEs/minute
Echocardiogram	normal left ventricular function with an ejection fraction of 74%. There is mitral valve prolapse with mild to moderate mitral regurgitation

Which one of the following is the most appropriate initial intervention in this patient?

A Mitral valve replacement

jugular venous pressure is not raised. First and second heart sounds are heard, and there is a mid-systolic click with a late systolic murmur of grade 2/6 radiating to the axilla. Respiration, abdominal and central nervous systems are all normal.

Investigations:

ECG	sinus rhythm
Chest X-ray	normal
FBC, U/Es, LFTs, TFTs and lipid profile	are within normal range
24-hour tape	sinus rhythm throughout except four separate episodes of premature ventricular ectopics (PVEs). These episodes comprised 4–9 PVEs/minute
Echocardiogram	normal left ventricular function with an ejection fraction of 74%. There is mitral valve prolapse with mild to moderate mitral regurgitation

Which one of the following is the most appropriate initial intervention in this patient?

A Mitral valve replacement

B Mitral valvuloplasty

C Bisoprolol

D Coronary angiogram

E Amiodarone

LFTs, TFTs and lipid profile	are within normal range
24-hour tape	sinus rhythm throughout except four separate episodes of premature ventricular ectopics (PVEs). These episodes comprised 4–9 PVEs/minute
Echocardiogram	normal left ventricular function with an ejection fraction of 74%. There is mitral valve prolapse with mild to moderate mitral regurgitation

Which one of the following is the most appropriate initial intervention in this patient?

Your answer was incorrect

A Mitral valve replacement

B Mitral valvuloplasty

C Bisoprolol

D Coronary angiogram

E Amiodarone

Explanation

C Bisoprolol

Bisoprolol is used for the suppression of ectopy. Mitral valve prolapse (MVP) affects about 5% of the general population and is more common in females. This man has

Explanation

C Bisoprolol

Bisoprolol is used for the suppression of ectopy. Mitral valve prolapse (MVP) affects about 5% of the general population and is more common in females. This man has mild to moderate mitral regurgitation on examination, and investigations are otherwise all normal apart from some PVEs on the 24 h tape. Crucially, his ejection fraction is normal.

Beta blockade is the initial treatment of choice for palpitations precipitated by PVEs. These work by reducing the occurrence and symptoms of the PVEs.

E Amiodarone

Amiodarone is effective in suppressing ectopy but is only indicated if this is associated with significant haemodynamic compromise. We also need to consider the risk of substantial side effects with long-term amiodarone. Beta blockade is therefore the initial treatment of choice.

A Mitral valve replacement

Mitral valve replacement is only indicated in severe mitral regurgitation or if there are signs of concomitant LV compromise (reduced ejection fraction or new dilatation of the LV). This patient will need follow-up in clinic with repeat echocardiograms to monitor progression.

B Mitral valvuloplasty

This is a treatment for mitral stenosis and might worsen mitral regurgitation.

10:37

haemodynamic compromise. We also need to consider the risk of substantial side effects with long-term amiodarone. Beta blockade is therefore the initial treatment of choice.

A Mitral valve replacement

Mitral valve replacement is only indicated in severe mitral regurgitation or if there are signs of concomitant LV compromise (reduced ejection fraction or new dilatation of the LV). This patient will need follow-up in clinic with repeat echocardiograms to monitor progression.

B Mitral valvuloplasty

This is a treatment for mitral stenosis and might worsen mitral regurgitation.

D Coronary angiogram

This patient has no regional wall-motion abnormality or history to suggest significant ischaemic heart disease. Coronary angiogram is therefore not indicated. However, if in the future a surgical mitral valve replacement were indicated, coronary angiogram would be part of the pre-op work-up for potential concomitant coronary artery bypass grafting.

Rate this question:

Next Question

Previous Q... Tag Questi... Feedback End Session

Rana Alnasser's screen

9:37
On
594-042-7551
Leave
MyPastest
https://mypastest.pastest.com

A 56-year-old gentleman developed acute severe shortness of breath 4 days after a ST-elevation myocardial infarction. On examination, his blood pressure is 99/50 mmHg and similar on both arms. Pulse is 110 beats per minute and respiratory rate is 28 breaths per minute. He has elevated jugular venous pressure, a soft systolic murmur heard loudest at the apex and bi-basal crackles, which extend up to mid-zones.

What diagnosis fits best with this clinical picture?

A	Ventricular septal defect
B	Mitral regurgitation
C	Aortic dissection
D	Aortic regurgitation
E	Atrial septal defect

6564

Submit

Previous Q...

Skip Questi...

Audio
Video
Share
Participants
More

9:39
On
594-042-7551
Leave

A 56-year-old gentleman developed acute severe shortness of breath 4 days after a ST-elevation myocardial infarction. On examination, his blood pressure is 99/50 mmHg and similar on both arms. Pulse is 110 beats per minute and respiratory rate is 28 breaths per minute. He has elevated jugular venous pressure, a soft systolic murmur heard loudest at the apex and bi-basal crackles, which extend up to mid-zones.

What diagnosis fits best with this clinical picture?

Your answer was correct

A Ventricular septal defect

B Mitral regurgitation

C Aortic dissection

D Aortic regurgitation

E Atrial septal defect

Explanation

B Mitral regurgitation

This occurs due to papillary muscle rupture usually presents from 1 to 14 days after a myocardial infarction. The pan-systolic murmur is usually loudest at the apex,

Audio Video Share Participants More

E Atrial septal defect

Explanation

B Mitral regurgitation

This occurs due to papillary muscle rupture usually presents from 1 to 14 days after a myocardial infarction. The pan-systolic murmur is usually loudest at the apex, although its absence does not exclude this diagnosis. The abrupt onset of acute pulmonary oedema and rapid progression to cardiogenic shock should prompt investigations to look for an acute mitral regurgitation or a ventricular septal defect. Inferior and posterior T-wave changes may be seen.

A Ventricular septal defect

This is an important differential diagnosis in this context, but the pan-systolic murmur is usually loudest at the lower left sternal edge and is accompanied by a parasternal thrill. In contrast, the pan-systolic murmur that is associated with acute mitral regurgitation is usually loudest at the apex without a thrill. It is important to note that the murmur is not always easy to detect, especially in patients presenting with cardiogenic shock.

C Aortic dissection

Type A aortic dissection can cause myocardial infarction by impairing the perfusion of the right coronary artery, but it would not fit this presentation.

D Aortic regurgitation

Aortic regurgitation presents with a diastolic murmur. It [illegible] aortic dissection but not a

Rana Alnasser's screen

A 76-year-old male presents with history of retrosternal chest pain of 20 min duration. The pain started while he was going for his morning walk and was associated with sweating and nausea. He is known to have diabetes mellitus for 15 years and hypertension for 5 years. His current medications include metformin 850 mg twice daily, 20 units per day of insulin glargine and indapamide 1.5 mg daily. On physical examination he is anxious and sweating. His pulse rate is 48/minute, blood pressure 145/85 mmHg and respiratory rate 20/min. He has an ejection systolic murmur localised at the aortic area, and brisk carotid upstroke.

His chest X-ray is normal and electrocardiogram (ECG) whilst in pain is shown below.

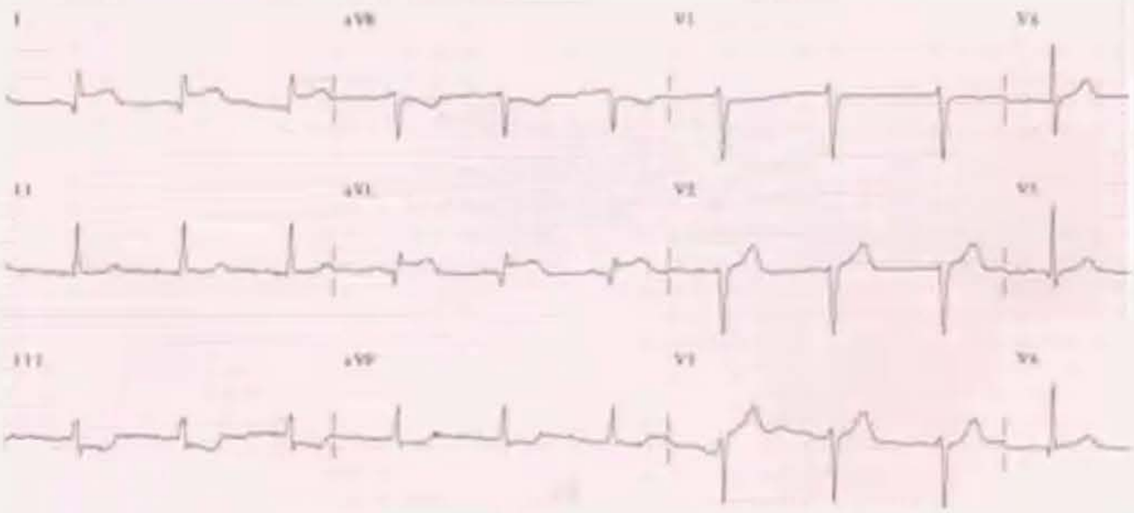

What is the most likely diagnosis?

A	Inferior transmural MI
B	Inferior subendocardial MI
C	Anterior transmural MI
D	Lateral transmural MI
E	High lateral wall MI

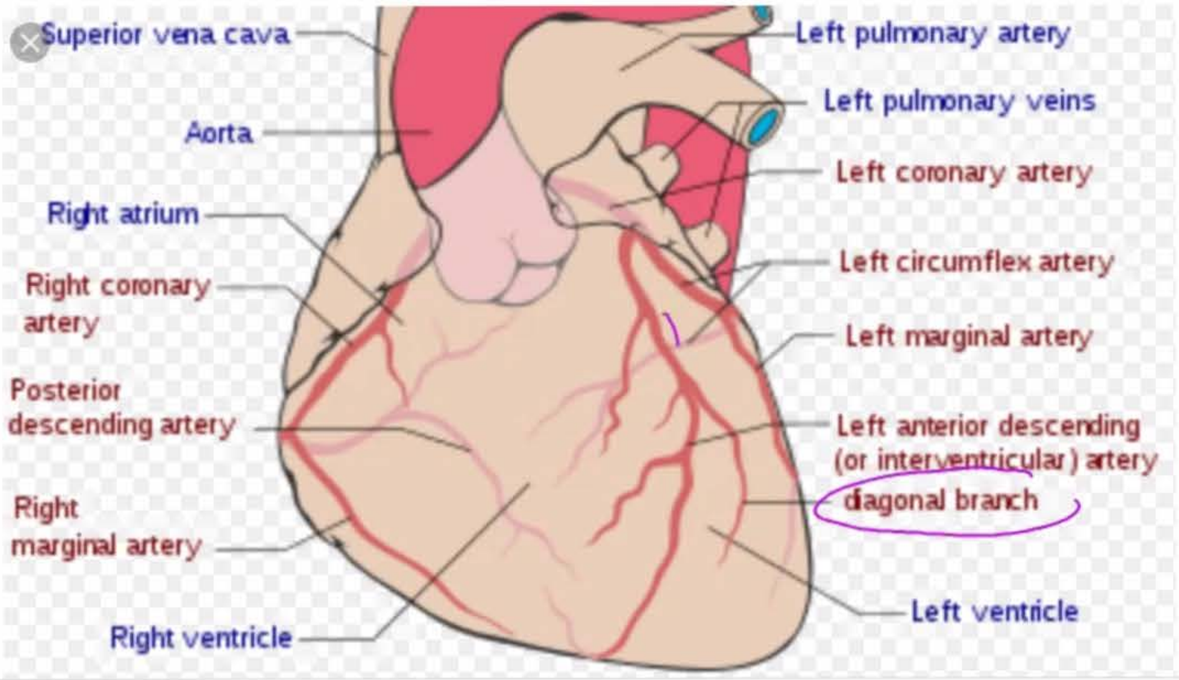

Wikipedia

Coronary circulation - Wikipedia

Coronary arteries.svg

Images may be subject to copyright. Learn more

RELATED IMAGES

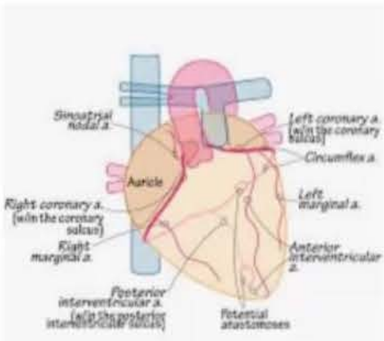

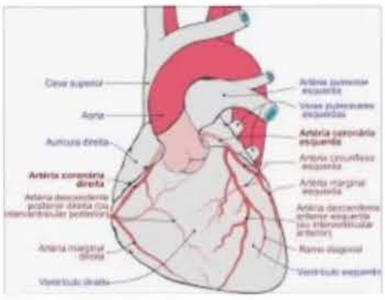

File:Coronary arteries pt.svg - Wikimedia Co...
commons.wikimedia.org

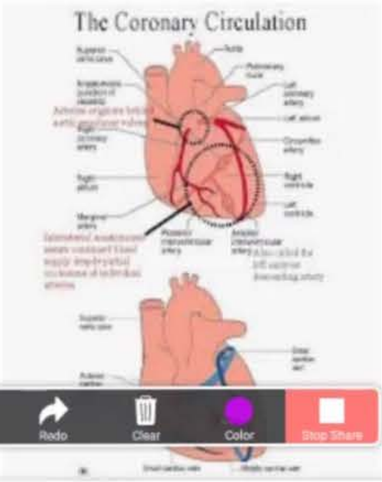

Product

Stop Annotation Spotlight Pen Highlighter Line Rectangle Oval Undo Redo Clear Color Stop Share

Discover Updates Search Recent More

9:47
On
594-042-7551
Leave

E High lateral wall MI

ST segment elevation in leads I and aVL is termed as high lateral wall MI, and is usually the result of occlusion of the first diagonal branch of the left anterior descending artery, though occlusion of other arteries like branches of the left circumflex or a short left anterior descending artery may cause the same picture. As the patient has ST elevation with ongoing chest pain, he should be referred for urgent PCI. He is relatively bradycardic, but this is likely to be related at least in part to ischaemia and should resolve after reperfusion occurs. The murmur may well be related to long-standing aortic stenosis and be unconnected to the acute presentation seen here. The ST depression in the lateral leads is likely to represent ischaemia due to low flow rather than acute occlusion.

A Inferior transmural MI

This would be associated with ST elevation in the inferior leads, (II, III and aVF).

B Inferior subendocardial MI

This would be associated with ST depression in the inferior leads, but the ST elevation in I and aVL seen here would not be expected.

C Anterior transmural MI

In this situation ST elevation in leads V1-V4 would be expected.

D Lateral transmural MI

A lateral transmural MI would usually be associated with ST elevation in V5 and V6

Audio Video Share Participants More

9:48

A 68-year-old man with a history of ankylosing spondylitis is referred to the Cardiology Department following the discovery of a diastolic murmur by the GP. He does not describe any chest pain or breathlessness, but he has experienced some palpitations over the last six months. His blood pressure (BP) is 175/95 mmHg with a heart rate of 100 bpm at rest. Clinical examination reveals a collapsing pulse, cardiac apex displaced to the anterior axillary line and a diastolic murmur. The chest is clear on auscultation and there is no peripheral oedema. Electrocardiogram (ECG) shows sinus rhythm with ventricular ectopics and left ventricular hypertrophy. Chest X-ray shows cardiomegaly with clear lung fields. An echocardiogram confirms the presence of aortic regurgitation with a vena contracta of 7 mm, LVEDD of 80 mm and an ejection fraction of 50%. A 24 h ECG shows sinus rhythm with frequent ventricular ectopics that correspond to the patient's experienced palpitations.

Which of the following is the most appropriate management option?

A	Start ramipril
B	Start bisoprolol
C	Start furosemide
D	Annual echocardiogram follow-up
E	Referral for consideration of aortic valve replacement

8529

Submit

Rana Alnasser's screen

pulse, cardiac apex displaced to the anterior axillary line and a diastolic murmur. The chest is clear on auscultation and there is no peripheral oedema. Electrocardiogram (ECG) shows sinus rhythm with ventricular ectopics and left ventricular hypertrophy. Chest X-ray shows cardiomegaly with clear lung fields. An echocardiogram confirms the presence of aortic regurgitation with a vena contracta of 7 mm, LVEDD of 80 mm and an ejection fraction of 50%. A 24 h ECG shows sinus rhythm with frequent ventricular ectopics that correspond to the patient's experienced palpitations.

Which of the following is the most appropriate management option?

Your answer was incorrect

A Start ramipril

B Start bisoprolol

C Start furosemide

D Annual echocardiogram follow-up

E Referral for consideration of aortic valve replacement

Explanation

E Referral for consideration of aortic valve replacement

This patient, although relatively asymptomatic, needs to be considered for valve replacement given the echocardiographic findings of severe aortic regurgitation

9:57
On
594-042-7551
Leave

and a dilated left ventricle. In the case of regurgitant murmurs, patients tend to be relatively asymptomatic till later on in the course of the disease, so regular echocardiographic follow-up is required to pick up individuals with early features of left ventricular failure (LVF) that would benefit from valve replacement.

The current 2017 ESC guidelines on valvular disease make the following recommendations for consideration of referral for surgery in the case of aortic regurgitation:

A) Significant enlargement of the ascending aorta (regardless of AR severity)
B) Symptomatic severe aortic regurgitation
C) Asymptomatic severe aortic regurgitation with
Ci) LVEF ≤50% or
Cii) LVEDD >70 mm
Ciii) LVESD >50 mm.

Surgery should also be considered if significant changes in LV or aortic size occur during follow-up.

B Start bisoprolol

Start bisoprolol is an appropriate management option for patients with heart failure, but this patient meets the echocardiographic criteria for consideration of valve replacement.

A Start ramipril

Whilst ACE inhibitor therapy represents a component of the management of aortic regurgitation (and would have an important anti-hypertensive effect), this patient meets the echocardiographic criteria for consideration of valve replacement.

C Start furosemide

Audio
Video
Share
Participants
More

9:57
On 594-042-7551 Leave

Whilst ACE inhibitor therapy represents a component of the management of aortic regurgitation (and would have an important anti-hypertensive effect), this patient meets the echocardiographic criteria for consideration of valve replacement.

C Start furosemide

Start furosemide would be an appropriate management option for heart failure/pulmonary oedema. This patient does not have clinical features of fluid overload, and meets the echocardiographic criteria for consideration of valve replacement.

D Annual echocardiogram follow-up

This patient already has an echo suggestive of severe aortic regurgitation with secondary dilation of the LV. He already meets echocardiographic criteria for consideration of valve replacement; it would be inappropriate to wait for his echo features to worsen prior to referral.

Rate this question:

© Pastest 2019

Audio Video Share Participants More

9:57

A 76-year-old man with a history of hypertension and type 2 diabetes mellitus is reviewed in the cardiology clinic. His GP has referred him having noted an irregular pulse at a routine check-up. Current medication includes ramipril, indapamide, atorvastatin and aspirin. On examination his blood pressure is 132/88 mmHg, with pulse 82/min, irregular. His chest is clear and there is no ankle swelling. His abdomen is soft and non-tender and he has a BMI of 28kg/m^2.

Investigations:

Hb	12.8 g/dl
WCC	5.6 x10^9/l
PLT	203 x10^9/l
Na^+	137 mmol/l
K^+	4.3 mmol/l
Creatinine	123 micromol/l
Glucose	5.9 mmol/l
Echocardiogram	Increased left atrial size, left ventricular ejection fraction 37%
ECG	AF with changes consistent with an old inferior infarct

Which of the following is the most appropriate intervention with respect to stroke prophylaxis?

A Add clopidogrel to aspirin

B Add dipyridamole to aspirin

C Continue aspirin

Rana Alnasser's screen

irregular. His chest is clear and there is no ankle swelling. His abdomen is soft and non-tender and he has a BMI of 28kg/m^2.

Investigations:

Hb	12.8 g/dl
WCC	5.6 x10^9/l
PLT	203 x10^9/l
Na^+	137 mmol/l
K^+	4.3 mmol/l
Creatinine	123 micromol/l
Glucose	5.9 mmol/l
Echocardiogram	Increased left atrial size, left ventricular ejection fraction 37%
ECG	AF with changes consistent with an old inferior infarct

Which of the following is the most appropriate intervention with respect to stroke prophylaxis?

A Add clopidogrel to aspirin

B Add dipyridamole to aspirin

C Continue aspirin

D Switch aspirin to clopidogrel

E Switch aspirin to apixaban

D Switch aspirin to clopidogrel

E Switch aspirin to apixaban

Explanation

E Switch aspirin to apixaban

This patient has non-valvular atrial fibrillation. His CHA_2DS_2-VASc score is 5 (age >75 years, heart failure, diabetes mellitus and hypertension). This patient requires anticoagulation for stroke prophylaxis. Both NICE and European Society of Cardiology guidelines suggest that direct-action oral anticoagulants should be initiated. Apixaban is a factor-X inhibitor (others include rivaroxaban and edoxaban).

A Add clopidogrel to aspirin

This patient has atrial fibrillation and requires anticoagulation rather than antiplatelet therapy. Both clopidogrel and aspirin are antiplatelet agents and, as such, neither is appropriate as management for this patient.

B Add dipyridamole to aspirin

Both of these medications are anti-platelet agents and, as such, are not appropriate for this patient. Atrial fibrillation requires anticoagulation as stroke prophylaxis.

C Continue aspirin

Aspirin was previously considered appropriate treatment for patients with atrial fibrillation thought to have a low-moderate risk of stroke. However, this is no longer considered appropriate as the bleeding risk with aspirin

B Add dipyridamole to aspirin

Both of these medications are anti-platelet agents and, as such, are not appropriate for this patient. Atrial fibrillation requires anticoagulation as stroke prophylaxis.

C Continue aspirin

Aspirin was previously considered appropriate treatment for patients with atrial fibrillation thought to have a low-moderate risk of stroke. However, this is no longer considered appropriate as the bleeding risk with aspirin outweighs any reduction in stroke risk.

D Switch aspirin to clopidogrel

Switching between antiplatelet agents will have no significant benefit in this patient. The increased risk of stroke in atrial fibrillation should be managed through anticoagulation. As such, the use of antiplatelet agents is not sufficient or appropriate.

Rate this question:

Next Question

© Pastest 2019

10:00

A 32-year-old Romanian man presents to the Emergency Department complaining of shortness of breath and tiredness. He tells you that this has been increasing over the past six months. He also complains of a chronic cough.

On examination, his body mass index (BMI) is 21 and he looks tired. His blood pressure (BP) is 110/70 mmHg and his resting pulse is 80/min. He has bilateral ankle oedema.

Investigations:

Hb	10.5 g/dl
WCC	11.6×10^9/l
PLT	201×10^9/l
Na^+	138 mmol/l
K^+	4.5 mmol/l
Creatinine	120 µmol/l
ECG	Low voltage complexes, nil else of note
ECHO	pericardial effusion
Effusion fluid	Lymphocytes ++

Which of the following is the most likely diagnosis?

A Autoimmune pericarditis

B Viral pericarditis

C Restrictive cardiomyopathy

D Tuberculous pericarditis

E Amyloidosis

Rana Alnasser's screen

10:02

D Tuberculous pericarditis

E Amyloidosis

Explanation

D Tuberculous pericarditis

Worldwide, tuberculous (TB) pericarditis is the commonest cause of constrictive pericarditis. There is a higher prevalence of TB in eastern Europe, when combined with the history of cough this is suggestive of this diagnosis. The presence of lymphocytes in the effusion fluid is further supports this diagnosis. A chest X-ray and tuberculosis cultures would be required as part of the diagnostic work-up.

A Autoimmune pericarditis

Autoimmune pericarditis is primarily a condition secondary to systemic autoimmune disease (eg systemic lupus erythematosus, rheumatoid arthritis). There are no features to suggest such a background condition in this case.

B Viral pericarditis

Although viral pericarditis can become chronic, it is normally a self-limiting condition that presents with chest pain as a primary symptom.

C Restrictive cardiomyopathy

This rare condition can lead to symptoms of heart failure which could explain the ankle oedema and chronic cough. However, it does not typically present with pericardial

Rana Alnasser's screen

A Autoimmune pericarditis

Autoimmune pericarditis is primarily a condition secondary to systemic autoimmune disease (eg systemic lupus erythematosus, rheumatoid arthritis). There are no features to suggest such a background condition in this case.

B Viral pericarditis

Although viral pericarditis can become chronic, it is normally a self-limiting condition that presents with chest pain as a primary symptom.

C Restrictive cardiomyopathy

This rare condition can lead to symptoms of heart failure which could explain the ankle oedema and chronic cough. However, it does not typically present with pericardial effusion.

E Amyloidosis

Cardiac amyloid can present with signs of heart failure. However, the echocardiogram (ECG) would normally show significant pseudo-hypertrophy and a speckled appearance. Further, conduction deficits on the ECG are common in cardiac amyloid.

Rate this question:

Next Question

Previous Q... Tag Questi... Feedback End Session

Rana Alnasser's screen

A 25-year-old man presents with history of ingestion of unknown quantity of digoxin. His pulse rate is 95 bpm and blood pressure 105/65 mmHg.

His investigations reveal:

K^+	5.2 mmol/l
Na^+	139 mmol/l
Cl^-	99 mmol/l
Bicarbonate	22 mmol/l
Creatinine	99 µmol/l
Digoxin	8.5 nmol/l

Electrocardiogram (ECG): sinus rhythm rate of 95 pbm and multiple premature ventricular beats.

The patient is administered charcoal and digoxin-specific Fab fragment. After 10 minutes the ECG monitor shows ventricular tachycardia (VT). The patient is dizzy and sweaty, his blood pressure is 105/80 mmHg.

What is the most appropriate further treatment for this patient?

A Synchronised direct current (DC) cardioversion

B Asynchronised DC cardioversion

C IV procainamide

D IV amiodarone

E IV lidocaine

Cl^-	99 mmol/l
Bicarbonate	22 mmol/l
Creatinine	99 µmol/l
Digoxin	8.5 nmol/l

Electrocardiogram (ECG): sinus rhythm rate of 95 pbm and multiple premature ventricular beats.

The patient is administered charcoal and digoxin-specific Fab fragment. After 10 minutes the ECG monitor shows ventricular tachycardia (VT). The patient is dizzy and sweaty, his blood pressure is 105/80 mmHg.

What is the most appropriate further treatment for this patient?

Your answer was correct

A Synchronised direct current (DC) cardioversion

B Asynchronised DC cardioversion

C IV procainamide

D IV amiodarone

E IV lidocaine

Explanation

E IV lidocaine

The patient has ventricular tachycardia (VT) secondary to digoxin toxicity. The patient has been given digibind,

10:04

MyPastest
https://mypastest.pastest.com

A Synchronised direct current (DC) cardioversion

B Asynchronised DC cardioversion

C IV procainamide

D IV amiodarone

E IV lidocaine

Explanation

E IV lidocaine

The patient has ventricular tachycardia (VT) secondary to digoxin toxicity. The patient has been given digibind, therefore any cardiovascular instability is likely to improve significantly over several minutes. With the patient's blood pressure above 100, IV lidocaine (lignocaine) is the most appropriate management option. Phenytoin may also be used as an alternative to lidocaine (both are class IB agents) if immune therapy is unsuccessful or unavailable in the treatment of tachyarrhythmias secondary to digoxin toxicity.

A Synchronised direct current (DC) cardioversion

DC cardioversion is less successful in the setting of digoxin toxicity, although it may be considered in the event of significant cardiovascular instability.

A Synchronised direct current (DC) cardioversion

DC cardioversion is less successful in the setting of digoxin toxicity, although it may be considered in the event of significant cardiovascular instability.

B Asynchronised DC cardioversion

Synchronisation prevents the shock occurring on the T-wave (during repolorisation) therefore precipitating VF (ventricular fibrillation). Unsynchronised DC cardioversion may occur if the patient is pulseless or unstable and the defibrillator will not synchronise.

C IV procainamide

While IV procainamide can be used for management of ventricular tachycardia its limited availability makes it a less suitable choice in this scenario.

D IV amiodarone

Amiodarone should be used cautiously due to its cutaneous effects and serious consequences if extravasation occurs; therefore administration should be via a central venous if possible. The therapeutic effects of amiodarone compared with other anti-arrhythmic agents may take longer, in addition to the potential toxic effects of amiodarone. Therefore, IV lidocaine is preferable.

Rate this question:

Next Question

A 16-year-old female presents with a history of palpitations of 1 year's duration. The palpitations are felt as a very rapid pounding of the heart and are associated with light-headedness. The episodes usually last for a few minutes. However, she states that she has now had an episode associated with a syncopal attack. Physical examination reveals a thin female with heart rate of 70/min, blood pressure 120/88 mmHg and respiratory rate of 16/min. Both heart sounds are normal, jugular venous pulsations are normal and the chest is clear to auscultation.

A 12-lead ECG is taken and is shown below.

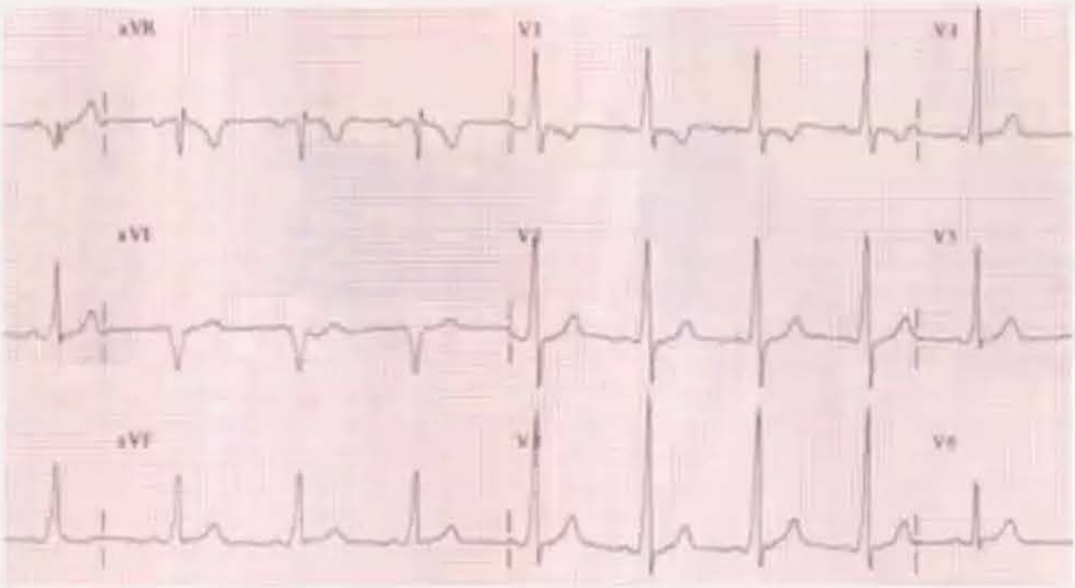

What is the most likely diagnosis?

A	Brugada syndrome
B	Wolff-Parkinson-White syndrome type A
C	Wolff-Parkinson-White syndrome type B
D	Right bundle branch block
E	Arrhythmogenic right ventricular dysplasia

10:07
On 594-042-7551 Leave

ness. The episodes usually last for a few minutes.
r, she states that she has now had an episode
ed with a syncopal attack. Physical examination
a thin female with heart rate of 70/min, blood
e 120/88 mmHg and respiratory rate of 16/min.
art sounds are normal, jugular venous pulsations
nal and the chest is clear to auscultation.

d ECG is taken and is shown below.

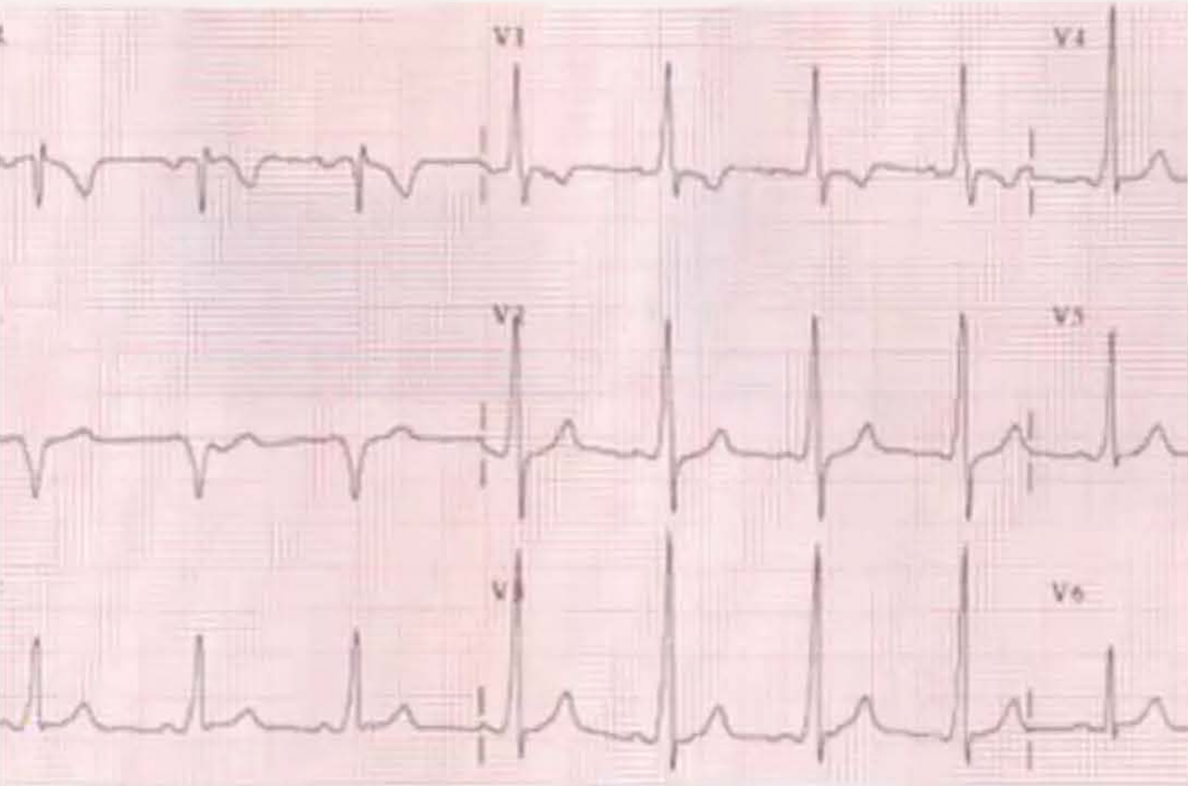

the most likely diagnosis?

Brugada syndrome

Wolff-Parkinson-White syndrome type A

Spotlight Pen Highlighter Line Rectangle Oval Undo Redo Clear

Wolff-Parkinson-White syndrome type B

Audio Video Share Participants More

10:15
75% 08:15
Wolff–Parkinson–White syndrome - Wikipedia
https://en.m.wikipedia.org

WPW may be associated with PRKAG2, a protein kinase enzyme encoded by the *PRKAG2* gene.[7]

Bundle of Kent

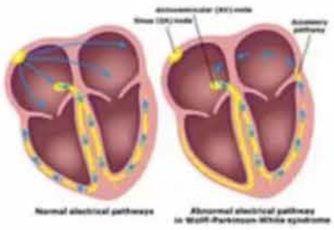

Graphic representation of the bundle of Kent in Wolff–Parkinson–White syndrome

The bundle of Kent is an abnormal extra or accessory conduction pathway between the atria and ventricles that is present in a small percentage (between 0.1 and 0.3%) of the general population.[8][9][10] This pathway may communicate between the left atrium and the left ventricle, in which case it is termed a "type A pre-excitation", or between the right atrium and the right ventricle, in which case it is termed a "type B pre-excitation".[11] Problems arise when this pathway creates an electrical circuit that bypasses the AV node. The AV node is capable of slowing the rate of conduction of electrical impulses to the ventricles, whereas the bundle of Kent lacks this capability. When an aberrant electrical connection is made via the bundle of Kent, tachydysrhythmias may therefore result.

Diagnosis

WPW is commonly diagnosed on the basis of the electrocardiogram in an asymptomatic individual. In this case, it is manifested as a delta wave, which is a slurred upstroke in the QRS complex that is associated with a short PR interval. The short PR interval and slurring of the QRS complex are reflective of the impulse making it to the ventricles early (via the accessory pathway) without the usual delay experienced in the AV node.

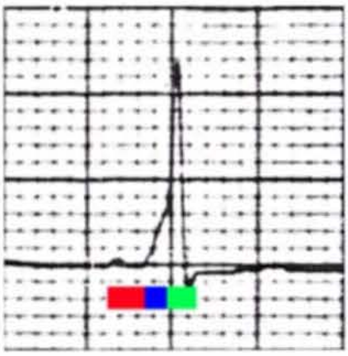

One beat from a rhythm strip in V_2 demonstrating characteristic finding in Wolff–Parkinson–White syndrome. Note the characteristic delta wave (above the blue bar), the short PR interval (red bar) of 80 ms, and the long QRS complex (blue bar plus green

If a person with WPW experiences episodes of atrial fibrillation, the ECG shows a rapid polymorphic wide-complex tachycardia (without *torsades de pointes*). This combination of atrial fibrillation and WPW is considered dangerous, and most antiarrhythmic drugs are contraindicated.

E Arrhythmogenic right ventricular dysplasia

Explanation

B Wolff-Parkinson-White syndrome type A

The ECG shows a short PR interval and a delta wave (slurred upstroke of the QRS complex), best seen in leads aVF and V4. A dominant R wave in lead V1 is consistent with a diagnosis of Wolff-Parkinson-White (WPW) syndrome type A. Other causes of tall R wave in V1 include posterior myocardial infarction, right bundle branch block and dextrocardia; however, in all of these cases the PR interval is normal and a delta wave is not seen. This patient has frequent palpitations and a syncopal event; therefore she should undergo electrophysiological studies and possible radiofrequency ablation of the accessory pathway if one is identified. This procedure has a high success rate and low incidence of complications, and is considered by most to be preferable to a long-term commitment to anti-arrhythmic therapy.

C Wolff-Parkinson-White syndrome type B

In WPW type B, a predominantly negative delta wave is seen in V_1 and V_2.

A Brugada syndrome

The ECG in Brugada syndrome is characterised by right bundle branch block and persistent ST elevation in leads V_1–V_3.

D Right bundle branch block

Rana Alnasser's screen

A 55-year-old man presents to the Emergency Department with acute onset of crushing retrosternal chest pain that started 3 h ago and has become much worse in the last 30 min. Other than hypertension, he has no past medical history of note. He has a pulse of 40 beats/min, blood pressure (BP) of 104/63 mmHg, jugular venous pulsation is seen up to 3 cm above the sternal notch and the chest is clear to auscultation.
An electrocardiogram (ECG) shows narrow QRS complexes with 2 mm ST segment elevation in leads II, III and aVF, as well as complete heart block (CHB). He is given aspirin and clopidogrel.

Which of the following is the most appropriate way to manage this patient?

A	IV streptokinase
B	IV Reteplase
C	Subcutaneous fondaparinux
D	Temporary transvenous pacemaker
E	Urgent PCI

32295

Submit

A 55-year-old man presents to the Emergency Department with acute onset of crushing retrosternal chest pain that started 3 h ago and has become much worse in the last 30 min. Other than hypertension, he has no past medical history of note. He has a pulse of 40 beats/min, blood pressure (BP) of 104/63 mmHg, jugular venous pulsation is seen up to 3 cm above the sternal notch and the chest is clear to auscultation.

An electrocardiogram (ECG) shows narrow QRS complexes with 2 mm ST segment elevation in leads II, III and aVF, as well as complete heart block (CHB). He is given aspirin and clopidogrel.

Which of the following is the most appropriate way to manage this patient?

Your answer was correct

A IV streptokinase

B IV Reteplase

C Subcutaneous fondaparinux

D Temporary transvenous pacemaker

E Urgent PCI

Explanation

E Urgent PCI

Conduction abnormalities are common in patients wi

E Urgent PCI

Explanation

E Urgent PCI

Conduction abnormalities are common in patients with inferior myocardial infarction (MI), as the right coronary artery (RCA) supplies the sinoatrial (SA) node (60% of people), atrioventricular (AV) node (90% of people) and His bundle. Complete heart block (CHB) in association with inferior MI is often associated with narrow complex escape rhythm, rarely progresses to asystole, and usually resolves within one week. If escape rhythm is more than 40 beats/min with normal blood pressure, treatment is not required. Urgent PCI is the best option, as reperfusion of the RCA is likely to restore AV node function.

A IV streptokinase

IV streptokinase is of course now superseded by PCI and by TPA where PCI is not available or is inappropriate. It is still used in the treatment of complicated empyema, where any abscess might be multi-loculated.

B IV Reteplase

TPA is only considered an option for patients where PCI is either inappropriate or unavailable.

C Subcutaneous fondaparinux

Fondaparinux is the anticoagulant of choice for NSTEMI, which is ruled out by the inferior lead ST elevation seen here.

Rana Alnasser's screen

inferior MI is often associated with narrow complex escape rhythm, rarely progresses to asystole, and usually resolves within one week. If escape rhythm is more than 40 beats/min with normal blood pressure, treatment is not required. Urgent PCI is the best option, as reperfusion of the RCA is likely to restore AV node function.

A IV streptokinase

IV streptokinase is of course now superseded by PCI and by TPA where PCI is not available or is inappropriate. It is still used in the treatment of complicated empyema, where any abscess might be multi-loculated.

B IV Reteplase

TPA is only considered an option for patients where PCI is either inappropriate or unavailable.

C Subcutaneous fondaparinux

Fondaparinux is the anticoagulant of choice for NSTEMI, which is ruled out by the inferior lead ST elevation seen here.

D Temporary transvenous pacemaker

Given this patient's systolic blood pressure is above 100 mmHg and pulse is 40, there is no indication at this stage to introduce a temporary pacemaker. It's better to progress directly to PCI.

32295

Rate this question:

Next Question

Annotation Stop Share

Rana Alnasser's screen

10:20

An 81-year-old woman is admitted to hospital with a fractured pubic ramus sustained in a fall. She undergoes successful surgery, but you are asked to see her by the orthopaedic team some 36 h after admission as she has suffered increasing breathlessness and left-sided pleuritic chest pain. She is rather confused and the nursing staff have measured her saturations at 94% on 8 litres oxygen. Her pulse is 110/min and regular and her BP is 110/60 mmHg. Her chest is clear on auscultation.

Which of the following tests would be most definitive in identifying the cause of the breathlessness?

A	12-lead ECG during the breathlessness
B	D-dimer
C	CT pulmonary angiogram
D	CXR
E	Troponin

32350

Submit

Annotation Stop Share
Rana Alnasser's screen

10:20
On
594-042-7551
Leave

An 81-year-old woman is admitted to hospital with a fractured pubic ramus sustained in a fall. She undergoes successful surgery, but you are asked to see her by the orthopaedic team some 36 h after admission as she has suffered increasing breathlessness and left-sided pleuritic chest pain. She is rather confused and the nursing staff have measured her saturations at 94% on 8 litres oxygen. Her pulse is 110/min and regular and her BP is 110/60 mmHg. Her chest is clear on auscultation.

Which of the following tests would be most definitive in identifying the cause of the breathlessness?

Your answer was correct

A 12-lead ECG during the breathlessness

B D-dimer

C CT pulmonary angiogram

D CXR

E Troponin

Explanation

C CT pulmonary angiogram

This is a very common clinical scenario. Because this patient is likely to be rather inactive given her pubic ramus fracture, but markedly increased risk of pulmonary embolus. CT pulmonary angiogram is the most appropriate

Audio Video Share Participants More

10:21

Explanation

C	CT pulmonary angiogram

This is a very common clinical scenario. Because this patient is likely to be rather inactive given her pubic ramus fracture, she is at markedly increased risk of pulmonary embolus. CT pulmonary angiogram is the most appropriate definitive investigation in this context. CTPA is a fast and readily available test, with increased sensitivity compared to V/Q testing, and shows superior ability to demonstrate alternative causes of symptoms such as pneumonia. However, it has a high radiation dose delivered to breast tissue vs V/Q scanning, making it a less attractive choice for pregnant women or women of childbearing age. It also has a higher risk of inducing nephropathy due to IV contrast than V/Q scanning, making it a less attractive choice in patients with moderate-severe renal impairment.

A	12-lead ECG during the breathlessness

The patient does not have a history of cardiac chest pain, and a 12-lead ECG is only likely to be abnormal (right ventricular strain pattern) in the presence of a large pulmonary embolus.

B	D-dimer

This would likely be raised secondary to her fracture, and thus would not be diagnostic if positive. Given the high pre-test possibility of PE, this would be a less appropriate investigation than CTPA.

D	CXR

Rana Alnasser's screen

A 19-year-old university student presents with history of ingestion of 60 tablets of digoxin which he stole from his grandmother. On arrival his pulse rate is 44/min and regular, blood pressure 95/55 mmHg, no jugular venous distension, normal heart sounds and clear chest. He receives atropine 0.5 mg IV and his pulse rate increases to 58/min, with blood pressure improving to 105/60 mmHg. The patient is admitted to the coronary care unit, a nasogastric tube is placed and 75 g charcoal is administered through it.

Investigations:

Potassium	4.8 mmol/l
Sodium	139 mmol/l
Chloride	99 mmol/l
Bicarbonate	22 mmol/l
Creatinine	99 µmol/l
Digoxin	10.5 nmol/l
ECG	Sinus bradycardia, 55/min

After 30 min the patient feels dizzy and heart rate drops to 35/min; another IV atropine 0.5 mg improves his heart rate to 55/min and symptoms resolve.

What is the most appropriate further treatment for this patient?

A Isoproterenol infusion

B Adrenaline infusion

C Transcutaneous pacemaker

D Temporary transvenous pacemaker

58/min, with blood pressure improving to 105/60 mmHg. The patient is admitted to the coronary care unit, a nasogastric tube is placed and 75 g charcoal is administered through it.

Investigations:

Potassium	4.8 mmol/l
Sodium	139 mmol/l
Chloride	99 mmol/l
Bicarbonate	22 mmol/l
Creatinine	99 µmol/l
Digoxin	10.5 nmol/l
ECG	Sinus bradycardia, 55/min

After 30 min the patient feels dizzy and heart rate drops to 35/min; another IV atropine 0.5 mg improves his heart rate to 55/min and symptoms resolve.

What is the most appropriate further treatment for this patient?

A Isoproterenol infusion

B Adrenaline infusion

C Transcutaneous pacemaker

D Temporary transvenous pacemaker

E Digoxin-specific Fab fragment

D Temporary transvenous pacemaker

E Digoxin-specific Fab fragment

Explanation

E Digoxin-specific Fab fragment

This patient has symptomatic recurrent bradycardia because of digoxin toxicity. Although he has responded to atropine, Fab fragment should be administered to prevent recurrent bradycardia, as the effect of atropine will subside quickly. Given the digoxin level, there is also a very high risk of ventricular arrhythmias.

Indications for administration of digoxin-specific Fab fragment are:

- Haemodynamic instability
- Life-threatening arrhythmias
- Serum potassium >5 mmol/l in acute toxicity
- Plasma digoxin level >13 nmol/l
- Ingestion of >10 mg digoxin in adults and 4 mg in children
- Recurrent bradycardia.

D Temporary transvenous pacemaker

Given the availability of digoxin-specific Fab fragments, these are preferred versus the delay and potential morbidity associated with pacemaker insertion. Pacemakers are also less effective in the context of digoxin overdose.

A Isoproterenol infusion

A Isoproterenol infusion

Isoprenaline infusion is an option for symptomatic bradycardia, although in this case reversal of the effect of digoxin is the more appropriate intervention.

B Adrenaline infusion

Adrenaline infusion will elevate both blood pressure and heart rate, but runs a significant risk of ventricular arrhythmias.

C Transcutaneous pacemaker

Transcutaneous pacemaker is appropriate as an emergency intervention for bradycardia in the event that digoxin-specific Fab fragment antibodies are unavailable.

This patient has symptomatic recurrent bradycardia because of digoxin toxicity, although he has responded to atropine, Fab fragment should be administered to prevent recurrent bradycardia, as the effect of atropine will subside quickly.

Indications for administration of Digoxin specific Fab Fragment are:

- Haemodynamic instability
- Life-threatening arrhythmias
- Serum potassium >5 mmol/l in acute toxicity
- Plasma digoxin level >13nmol/l
- Ingestion of more than 10 mg digoxin in adults and 4 mg in children
- Recurrent bradycardia

Rate this question:

An anxious 31-year-old barrister presents to his GP complaining of fainting episodes which have a recent onset. He does not attribute his faints to any particular activity, and sometimes he has noticed light-headedness even as he has changed position at rest. On further questioning, he admits to having felt increasingly tired and short of breath with minimal exertion. His appetite has decreased and he has lost about 5 kg of weight in the preceding 2 months. He had been otherwise fit and well and is not on any medication. He is a non-smoker. He admits to being very concerned since his father died suddenly at a similar age to himself, but he does not know the cause of death. Positive findings on examination of the patient include clubbing of his fingers and a raised JVP. Auscultation of the heart reveals a loud first heart sound, a third heart sound and a systolic murmur at the apex. His blood pressure is 142/82 mmHg. Neurological examination is normal.

What is the most likely diagnosis?

A	Infective endocarditis
B	Takayasu's disease
C	Rheumatic fever
D	Atrial myxoma
E	Bornholm disease

Submit

questioning, he admits to having felt increasingly tired and short of breath with minimal exertion. His appetite has decreased and he has lost about 5 kg of weight in the preceding 2 months. He had been otherwise fit and well and is not on any medication. He is a non-smoker. He admits to being very concerned since his father died suddenly at a similar age to himself, but he does not know the cause of death. Positive findings on examination of the patient include clubbing of his fingers and a raised JVP. Auscultation of the heart reveals a loud first heart sound, a third heart sound and a systolic murmur at the apex. His blood pressure is 142/82 mmHg. Neurological examination is normal.

What is the most likely diagnosis?

Your answer was correct

A Infective endocarditis

B Takayasu's disease

C Rheumatic fever

D Atrial myxoma

E Bornholm disease

Explanation

D Atrial myxoma

An atrial myxoma is the most common primary heart tumour and produces symptoms either through distant embolisation or mechanical interference with cardiac function. Three-quarters of cases of atrial myxoma occur in

Rana Alnasser's screen

Explanation

D Atrial myxoma

An atrial myxoma is the most common primary heart tumour and produces symptoms either through distant embolisation or mechanical interference with cardiac function. Three-quarters of cases of atrial myxoma occur in females, and sudden death may occur in 15% of patients. Patients may experience symptoms related to left- or right-sided heart failure. Exertional dyspnoea is present in three-quarters of patients. Dizziness or syncope results from the atrial myxoma obstructing the mitral valve. The patient may also have constitutional symptoms that include fever, weight loss and arthralgias. On examination, a loud first heart sound is often heard due to a delay in mitral valve closure due to the prolapse of the tumour into the mitral valve orifice. However, atrial myxoma can cause a variety of findings on cardiac ausculation: for example, diastolic tumour 'plop', systolic murmur if tricuspid regurgitation occurs, or a diastolic rumble if mitral valve obstruction is present. Although most cases of atrial myxoma are sporadic, an autosomal dominant variety may also exist within families.

A Infective endocarditis

The more prolonged period of symptoms seen here, without more marked features of sepsis, is less consistent with a diagnosis of infective endocarditis versus atrial myxoma.

B Takayasu's disease

Takayasu's arteritis is an idiopathic arteritis causing narrowing of the proximal innominate, carotid and subclavian arteries and commonly affects females.

A Infective endocarditis

The more prolonged period of symptoms seen here, without more marked features of sepsis, is less consistent with a diagnosis of infective endocarditis versus atrial myxoma.

B Takayasu's disease

Takayasu's arteritis is an idiopathic arteritis causing narrowing of the proximal innominate, carotid and subclavian arteries and commonly affects females.

C Rheumatic fever

There is no history of antecedent streptococcal infection to suggest rheumatic fever.

E Bornholm disease

Bornholm's disease is intercostal muscle pain associated with Coxsackie B virus infection.

Rate this question:

© Pastest 2019

10:28
On
594-042-7551
Leave

A 28-year-old man presents for follow up after two episodes of collapse. The Cardiology Clinic arranged a 24-h tape which reveals one episode of nocturnal paroxysmal atrial fibrillation with a maximal ventricular rate of 145 bpm. PR interval is 140 ms and the QT interval is normal. Echocardiography is unremarkable. Thyroid function testing is unremarkable.

Which of the following treatments is most appropriate in this case?

A	Electrophysiological studies and ablation
B	Disapyramide
C	Amiodarone
D	Digoxin
E	Diltiazem

6562

Submit

Previous Q... Skip Questi...

© Pastest 2019

Audio Video Share Participants More

10:30
On
594-042-7551
Leave

A 28-year-old man presents for follow up after two episodes of collapse. The Cardiology Clinic arranged a 24-h tape which reveals one episode of nocturnal paroxysmal atrial fibrillation with a maximal ventricular rate of 145 bpm. PR interval is 140 ms and the QT interval is normal. Echocardiography is unremarkable. Thyroid function testing is unremarkable.

Which of the following treatments is most appropriate in this case?

Your answer was correct

- A Electrophysiological studies and ablation
- B Disapyramide
- C Amiodarone
- D Digoxin
- E Diltiazem

Explanation

A Electrophysiological studies and ablation

Bisoprolol is recommended as initial prophylaxis against further episodes of paroxysmal atrial fibrillation by both NICE and the European Society of Cardiology. However many patients do not, however, want to commit to long-term medical therapy, and for this reason electrophysiological studies coupled with possible ablation

Audio Video Share Participants More

10:30
On
594-042-7551
Leave

E Diltiazem

Explanation

A Electrophysiological studies and ablation

Bisoprolol is recommended as initial prophylaxis against further episodes of paroxysmal atrial fibrillation by both NICE and the European Society of Cardiology. However many patients do not, however, want to commit to long-term medical therapy, and for this reason electrophysiological studies coupled with possible ablation is an increasingly popular option. This can be used in combination with Class Ic agents, eg propafenone or flecainide, to control ventricular rates if atrial fibrillation evolves into atrial flutter.

B Disapyramide

Disopyramide is an anti-arrhythmic medication used for treatment of ventricular tachycardia due to its Class Ia properties.

C Amiodarone

This is useful in acute management; however, due to its side-effects from long-term use, amiodarone is not the most appropriate choice.

D Digoxin

Digoxin is pro-fibrillatory and therefore should not be used in paroxysmal atrial fibrillation or if DC cardioversion is planned.

Audio Video Share Participants More

10:37
On
594-042-7551
Leave

69% 08:37

Favours Rate Control	Favours Rhythm Control
• Persistent AF • Less symptomatic • Aged ≥ 65 years • Hypertension • No history of CHF • Previous antiarrhythmic drug failure • Patient preference • High stroke risk with cardioversion	• Paroxysmal AF • Newly detected AF • More symptomatic • Aged < 65 years • No hypertension • HF clearly exacerbated by AF • No previous antiarrhythmic drug failure • Patient preference • Low stroke risk with cardioversion

Abbreviations: AF = atrial fibrillation; CHF = congestive heart failure; HF = heart failure.
Adapted from: Gillis AM, et al. Canadian Cardiovascular Society Atrial Fibrillation Guidelines 2010: Rate and Rhythm Management. Canadian Journal of Cardiology 2011;27:47-59.

Government of B.C.

Atrial Fibrillation - Diagnosis and Management - Province of ...

STEP 3: Is this a rate or rhythm control strategy?

Images may be subject to copyright. Learn more

RELATED IMAGES



mEHRA score	Symptoms	Description
1	None	
2a	Mild	Normal daily activity not affected. symptoms not troublesome to patient
2b	Moderate	Normal daily activity not affected but patient troubled by symptoms
3	Severe	Normal daily activity affected
4	Disabling	Normal daily activity discontinued

Modified EHRA (mEHRA) classification | Dow...
researchgate.net

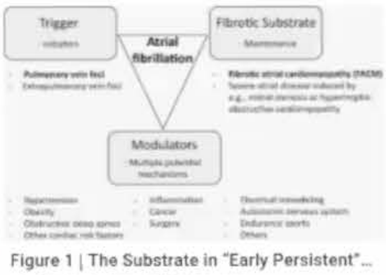

Figure 1 | The Substrate in "Early Persistent"...
electrophysiology.onlinejacc.org

Arrhythmias and Antiarrhythmic Drugs - ppt ...
slideplayer.com

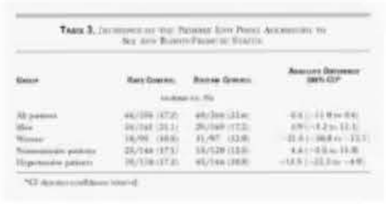

A Comparison of Rate Control and Rhythm C...
nejm.org

FAVOURING RATE CONTROL	FAVOURING RHYTHM CONTROL
Persistent AF	Paroxysmal AF or newly detected AF
Less symptomatic	More symptomatic
Age ≥ 65 y	Age < 65 y
Hypertension	No hypertension
No history of HF	HF clearly exacerbated by AF
Previous failure of antiarrhythmic drug	No previous failure of antiarrhythmic drug
Patient preference	Patient preference

AF = atrial fibrillation, HF = heart failure.
Data from Gillis et al.[1]

Factors favouring rate versus rhythm control...
researchgate.net

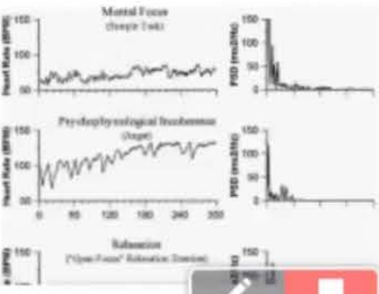

Discover
Updates
Search
Recent
More
Annotate
Stop Share
Audio
Video
Share
Participants
More

10:37

A 61-year-old man with a history of type 2 diabetes and hypertension attends clinic for his annual assessment. His diabetes is currently managed with 1 g of metformin BD, and he was diagnosed 1 year earlier. His abdomen is soft and non-tender; BMI is raised at 32. Fundoscopy is normal and routine bloods including serum creatinine are unremarkable.

Which of the following would be an appropriate blood pressure target for this patient?

A	145/85 mmHg
B	130/80 mmHg
C	140/80 mmHg
D	135/85 mmHg
E	150/80 mmHg

Submit

Rana Alnasser's screen

C 140/80 mmHg

The NICE guideline for type 2 diabetes in adults (NG28) recommends a blood pressure target of 140/80 mmHg in patients without evidence of kidney, eye or cerebrovascular damage.

D 135/85 mmHg

This is incorrect. The NICE guideline for type 2 diabetes in adults (NG28) recommends a blood pressure target of 140/80 mmHg in patients without evidence of kidney, eye or cerebrovascular damage. This target is lowered to 130/80 mmHg if there is evidence of the above.

A 145/85 mmHg

This target BP is too high for patients with type 2 diabetes and hypertension. The BP target of 145/85 mmHg is the NICE recommended target for patients above 80 years of age.

B 130/80 mmHg

The NICE guideline for type 2 diabetes in adults (NG28) recommends a lower blood pressure target of 130/80 mmHg in patients with evidence of kidney, eye or cerebrovascular damage.

E 150/80 mmHg

This target BP is too high for patients with type 2 diabetes and hypertension, it is even considered too high a target for patients above 80 years.

10:39

A 62-year-old man presents with central crushing chest pain radiating to his left arm. He has a history of hypertension, hypercholesterolaemia and Type 2 diabetes and is managed with ramipril 10mg daily, atorvastatin 40mg, metformin 1g BD, glargine insulin 40U daily.

3 months earlier he presented to the Emergency room with an anterolateral NSTEMI and received a drug eluting stent.

On examination he has a BP of 148/90mmHg, pulse 78/min regular and looks pale and sweaty.

Investigations:

Hb	14.0 g/dl
WCC	5.8 x10^9/l
PLT	295 x10^9/l
Na^+	140 mmol/l
K^+	5.0 mmol/l
Creatinine	130 µmol/l
ECG	Inferior ST elevation

You take him to the cardiac catheterisation lab for further intervention. **Which of the following is the most likely cause of his symptoms?**

A Stent thrombosis / blockage

B New myocardial infarction

C Worsening angina

D Coronary artery dissection

Rana Alnasser's screen

10:42
On 594-042-7551 Leave

E Pericarditis

Explanation

B New myocardial infarction

The multiple cardiovascular risk factors and presence of ST elevation in the inferior leads indicate that it is very likely the RCA is now affected.

Management of choice would be angioplasty and stenting if required. Data also suggests that post-stenting in patients with Type 2 diabetes and that dual anti-platelet therapy should be continued for approximately 1 year.

A Stent thrombosis / blockage

Stent thrombosis / blockage is incorrect. The areas affected on the ECG (see investigations) are different from where the previous stent was inserted. Therefore, it is unlikely that this is due to a stent thrombosis.

C Worsening angina

Worsening angina is incorrect. Angina does not present with ST elevation on ECG. It typically presents with chest pain on exertion (stable angina) and at rest (unstable angina) with no ECG changes or change in troponin level.

D Coronary artery dissection

Coronary artery dissection is incorrect. Coronary artery dissection more commonly affects females of childbearing age without the typical cardiovascular risk factors, and is therefore less likely in this patient. A thrombotic event is more likely although dissection remains a differential.It can

Audio Video Share Participants More

pain on exertion (stable angina) and at rest (unstable angina) with no ECG changes or change in troponin level.

D Coronary artery dissection

Coronary artery dissection is incorrect. Coronary artery dissection more commonly affects females of childbearing age without the typical cardiovascular risk factors, and is therefore less likely in this patient. A thrombotic event is more likely although dissection remains a differential.It can present like ACS with acute chest pain and can only be diagnosed on coronary angiography.

E Pericarditis

Pericarditis is incorrect. Pericarditis will show widespread ST changes with PR depression. The pain will be characteristically worse on lying flat and improved on sitting forward. The mainstay treatment for pericarditis is NSAIDs or colchicine with advice to patients to reduce physical activity for the acute period (3 months for athletes and shorter for non-atheletes).

Rate this question:

Next Question

Previous Q... Tag Questi... Feedback End Session

Blog About Pastest Contact Us Help

© Pastest 2019

Rana Alnasser's screen

You are called to a cardiac arrest on the cardiac unit. A 58-year-old man was admitted 2 days previously with an anterior myocardial infarction; the nurses tell you that he was making a reasonable recovery until the onset of chest pain 30 minutes ago. As the ward doctor was reviewing, he went into ventricular fibrillation. You give an initial cycle of one shock at 360 J followed by 2 min of CPR, and he becomes asystolic. Blood gases taken peri-arrest reveal a pH of 6.9 and potassium of 4.9 mmol/l. Adrenaline 1 mg IV is given.

Which of the following is the optimal next step in his management?

A	Give sodium bicarbonate 8.4% IV
B	Give sodium bicarbonate 1.2% IV
C	Continue CPR
D	Give amiodarone 300mg IV
E	Give IV fluids

Submit

year-old man was admitted 2 days previously with an anterior myocardial infarction; the nurses tell you that he was making a reasonable recovery until the onset of chest pain 30 minutes ago. As the ward doctor was reviewing, he went into ventricular fibrillation. You give an initial cycle of one shock at 360 J followed by 2 min of CPR, and he becomes asystolic. Blood gases taken peri-arrest reveal a pH of 6.9 and potassium of 4.9 mmol/l. Adrenaline 1 mg IV is given.

Which of the following is the optimal next step in his management?

Your answer was correct

A	Give sodium bicarbonate 8.4% IV
B	Give sodium bicarbonate 1.2% IV
C	Continue CPR
D	Give amiodarone 300mg IV
E	Give IV fluids

Explanation

C	Continue CPR

This man is now in asystole. The non-shockable algorithm of the ALS guidelines should therefore be followed. This emphasises high-quality CPR with adjunctive adrenaline.

A	Give sodium bicarbonate 8.4% IV

The use of sodium bicarbonate is no longer recommended

emphasises high-quality CPR with adjunctive adrenaline.

A Give sodium bicarbonate 8.4% IV

The use of sodium bicarbonate is no longer recommended as part of the ALS algorithm drawn up by the UK resuscitation council. It may, however, still be considered in cases of profound hyperkalaemia or where there is overdose of tricyclic antidepressants.

B Give sodium bicarbonate 1.2% IV

The use of sodium bicarbonate is no longer recommended as part of the ALS algorithm drawn up by the UK resuscitation council. It may, however, still be considered in cases of profound hyperkalaemia or where there is overdose of tricyclic antidepressants.

D Give amiodarone 300mg IV

This man is in asystole, and the non-shockable algorithm should be followed. There is no place for amiodarone in this context.

E Give IV fluids

Where there is suspicion of hypovolaemia, e.g. after massive blood loss due to trauma, then IV fluids may be of value, but there is no suggestion that this is the case here.

Rate this question:

Next Question

10:07

MyPastest
https://mypastest.pastest.com

You have been called to the ward to review a patient who has suddenly changed condition. You quickly browse through the medical notes of the patient while walking up to his bed. He is a 60-year-old man who was admitted the previous day with an acute coronary syndrome.

His troponin was 0.03 IU (normal range < 0.01) and his admission electrocardiogram (ECG) showed an ST segment depression of 1.0 mm in the inferior leads. He was started on aspirin 300 mg, glyceryl trinitrate (GTN) spray prn and enoxaparin 80 mg bd. His full blood count and urea and electrolytes are within normal limits.

When you examine him, he is dyspnoeic, his pulse is 140/min and his blood pressure (BP) is 90/45 mmHg. His chest is clinically clear and he is on high-flow oxygen (15 l). You give him 6 mg of adenosine, without any response. You repeat the same dose of 6 mg and then increase it to 12 mg. With the 12 mg dose, the heart rate (HR) on the monitor slows down to 105/min. A 12-lead ECG is taken at the same time.

Investigations:

Electrocardiogram (ECG)	Flutter waves best seen in the inferior leads and V1

After a couple of minutes, the HR shoots back to 150/ min. You recheck his BP that is still low at 92/50 mmHg. The patient starts complaining of chest tightness.

How would you control this man's tachycardia?

A	DC cardioversion
B	Beta-blockers

Annotation Stop Share
Rana Alnasser's screen

10:08
Pastest 594-042-7551 Question 1 of 120 Leave

prn and enoxaparin 80 mg bd. His full blood count and urea and electrolytes are within normal limits.

When you examine him, he is dyspnoeic, his pulse is 140/min and his blood pressure (BP) is 90/45 mmHg. His chest is clinically clear and he is on high-flow oxygen (15 l) You give him 6 mg of adenosine, without any response. Yo repeat the same dose of 6 mg and then increase it to 12 mg. With the 12 mg dose, the heart rate (HR) on the monitor slows down to 105/min. A 12-lead ECG is taken at the same time.

Investigations:

Electrocardiogram (ECG)	Flutter waves best seen in the inferior leads and V1

After a couple of minutes, the HR shoots back to 150/ min. You recheck his BP that is still low at 92/50 mmHg. The patient starts complaining of chest tightness.

How would you control this man's tachycardia?

A	DC cardioversion
B	Beta-blockers
C	Digoxin
D	Intravenous (IV) flecainide
E	Verapamil

7550
Submit
Audio Video Share Participants More

chest is clinically clear and he is on high-flow oxygen (15 l). You give him 6 mg of adenosine, without any response. You repeat the same dose of 6 mg and then increase it to 12 mg. With the 12 mg dose, the heart rate (HR) on the monitor slows down to 105/min. A 12-lead ECG is taken at the same time.

Investigations:

Electrocardiogram (ECG)	Flutter waves best seen in the inferior leads and V1

After a couple of minutes, the HR shoots back to 150/ min. You recheck his BP that is still low at 92/50 mmHg. The patient starts complaining of chest tightness.

How would you control this man's tachycardia?

Your answer was correct

A DC cardioversion

B Beta-blockers

C Digoxin

D Intravenous (IV) flecainide

E Verapamil

Explanation

A DC cardioversion

DC cardioversion is the therapy of choice as flutter can be resistant to pharmacological therapy. Additionally, given [illegible] with ACS and his initial systolic

Rana Alnasser's screen

B Beta-blockers

C Digoxin

D Intravenous (IV) flecainide

E Verapamil

Explanation

A DC cardioversion

DC cardioversion is the therapy of choice as flutter can be resistant to pharmacological therapy. Additionally, given that he has been admitted with ACS and his initial systolic was only 90 mmHg, cardioversion versus flecainide or verapamil would be the most appropriate option. This patient would need to be sedated or have general anaesthesia before cardioverting him. Very low energies are needed for cardioversion (50–100 J).

B Beta-blockers

Beta-blockers would slow down the rate but would not cardiovert the patient, and therefore this is an incorrect option.

C Digoxin

Flutter can be resistant to pharmacological therapy, and therefore digoxin would not be the appropriate treatment.

D Intravenous (IV) flecainide

Rana Alnasser's screen

Given that he has a history of myocardial ischaemia

B Beta-blockers

Beta-blockers would slow down the rate but would not cardiovert the patient, and therefore this is an incorrect option.

C Digoxin

Flutter can be resistant to pharmacological therapy, and therefore digoxin would not be the appropriate treatment.

D Intravenous (IV) flecainide

Given that he has a history of myocardial ischaemia, flecainide should be avoided.

E Verapamil

Given that he has been admitted with ACS, and his initial systolic was only 90 mmHg, verapamil would not be a good option compared with cardioversion.

© Pastest 2019

A pre-registration house officer asks for advice about an ECG recording he has been shown from a young 20-year-old female patient admitted unconscious after taking a paracetamol overdose. The ECG showed sinus rhythm, but with a P-axis of +120 degrees and prominent QRS amplitudes in the right leads that diminish in size over the left precordial leads. No other abnormalities were noted. After seeing the ECG the registrar becomes interested in examining the patient.

Which of the following is seen with increased frequency in patients with her underlying condition?

A	Colon cancer
B	Bronchiectasis
C	Haemolytic anaemia
D	Hypertrophic obstructive cardiomyopathy
E	Wolff-Parkinson-White syndrome

Submit

Previous Q... Skip Questi...

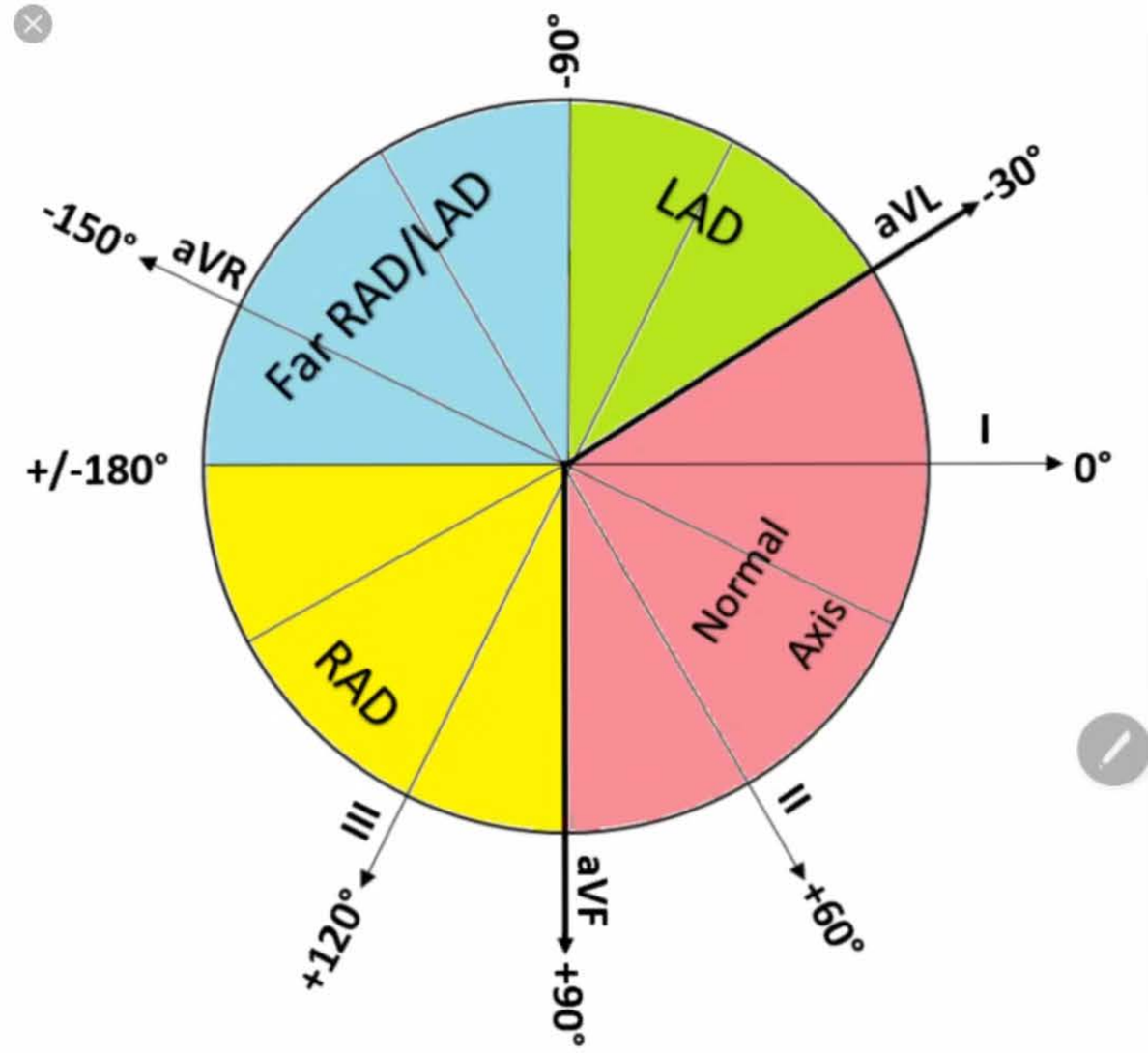

The Student Physiologist

Determining Cardiac Axis – The Student Physiologist

Screenshot (53)

Images may be subject to copyright. Find out more

RELATED IMAGES

Rana Alnasser's screen

10:15
594-042-7551 Leave

A pre-registration house officer asks for advice about an ECG recording he has been shown from a young 20-year-old female patient admitted unconscious after taking a paracetamol overdose. The ECG showed sinus rhythm, but with a P-axis of +120 degrees and prominent QRS amplitudes in the right leads that diminish in size over the left precordial leads. No other abnormalities were noted. After seeing the ECG the registrar becomes interested in examining the patient.

Which of the following is seen with increased frequency in patients with her underlying condition?

Your answer was correct

A	Colon cancer
B	Bronchiectasis
C	Haemolytic anaemia
D	Hypertrophic obstructive cardiomyopathy
E	Wolff-Parkinson-White syndrome

Explanation

B Bronchiectasis

This patient has dextrocardia, and so the cardiac apex now

Audio Video Share Participants More

10:15

D	Hypertrophic obstructive cardiomyopathy
E	Wolff-Parkinson-White syndrome

Explanation

B	Bronchiectasis

This patient has dextrocardia, and so the cardiac apex now points rightwards with the morphological right atrium and right ventricle now being on the left. It is commonly associated with reversal in the position of the abdominal organs, known as situs inversus. Dextrocardia is a rare condition and occurs with equal frequency in males and females. The classical features on an ECG are inverted P-waves in lead I, a shift of the P-axis (usually about +120 degrees) and reversed R-wave progression. Reverse placement of the precordial leads on the right chest at sites corresponding to the left chest positions corrects this trend. Typically patients have a normal life expectancy if no cardiac anomalies are present. Bronchiectasis is seen with increased frequency in patients with dextrocardia, as part of Kartagener syndrome, which is the combination of bronchiectasis, chronic sinusitis, subfertility and situs inversus with dextrocardia.

A	Colon cancer

Colon cancer is associated with a number of adenomatous polyposis syndromes such as Gardener, which follows an autosomal dominant pattern of inheritance.

C	Haemolytic anaemia

Haemolytic anaemia is associated with a range of inherited conditions including hereditary spherocytosis, elliptocytosis and G6PD deficiency

Rana Alnasser's screen

10:15
594-042-7551 Leave

cardiac anomalies are present. Bronchiectasis is seen with increased frequency in patients with dextrocardia, as part of Kartagener syndrome, which is the combination of bronchiectasis, chronic sinusitis, subfertility and situs inversus with dextrocardia.

A Colon cancer

Colon cancer is associated with a number of adenomatous polyposis syndromes such as Gardener, which follows an autosomal dominant pattern of inheritance.

C Haemolytic anaemia

Haemolytic anaemia is associated with a range of inherited conditions including hereditary spherocytosis, elliptocytosis and G6PD deficiency.

D Hypertrophic obstructive cardiomyopathy

HOCM is not associated with dextrocardia although pulmonary hypertension may be, because of chronic chest disease due to immotile cilia.

E Wolff-Parkinson-White syndrome

WPW syndrome and other conditions associated with tachyarrhythmias are not seen with increased frequency in dextrocardia.

Rate this question:

Next Question

Previous Q... Tag Questi... Feedback End Session

Audio Video Share Participants More

A 62-year-old woman with a history of type 2 diabetes presents feeling faint, sweaty and unwell. She is currently managed with metformin 1g BD and ramipril 10mg daily.

On examination, she looks unwell and has a blood pressure of 100/60 mmHg. Her chest X-ray shows left ventricular hypertrophy and bilateral interstitial shadowing consistent with pulmonary oedema. The admission ECG is shown below. The nurse has already given her 300 mg soluble aspirin.

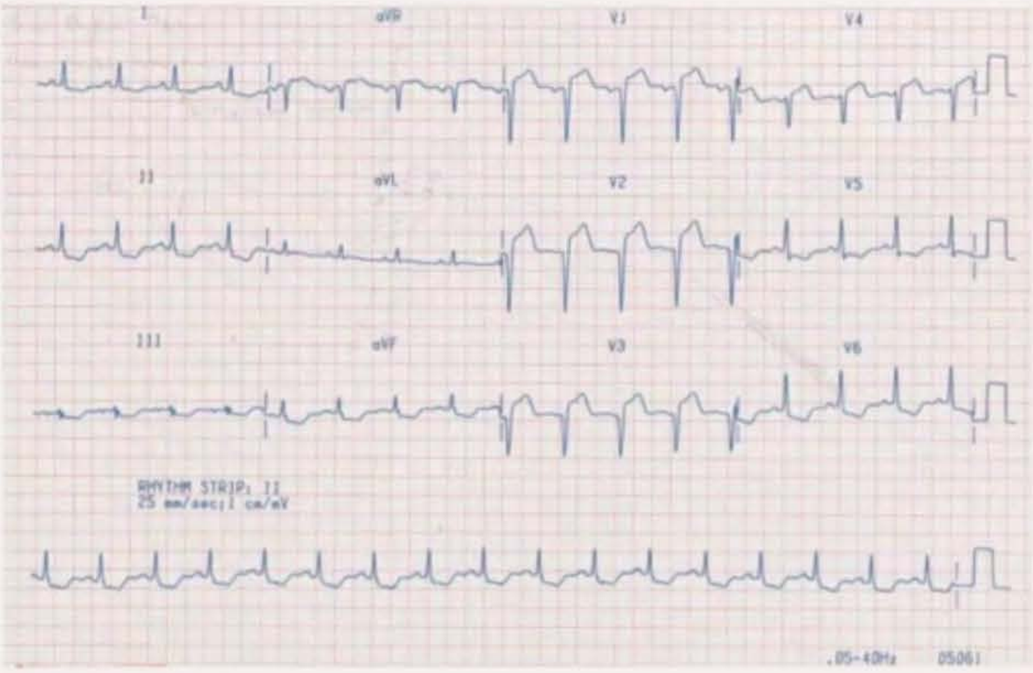

She undergoes acute angioplasty and makes a good recovery. Her HbA1c is measured at 63.93 mmol/mol (8.0%). She is treated with insulin during the initial period but then switched back to metformin on day 3.

What additional therapy should you commence for long-term blood glucose control?

A	Basal bolus insulin
B	Pioglitazone
C	Repaglinide

10:18
594-042-7551
Leave

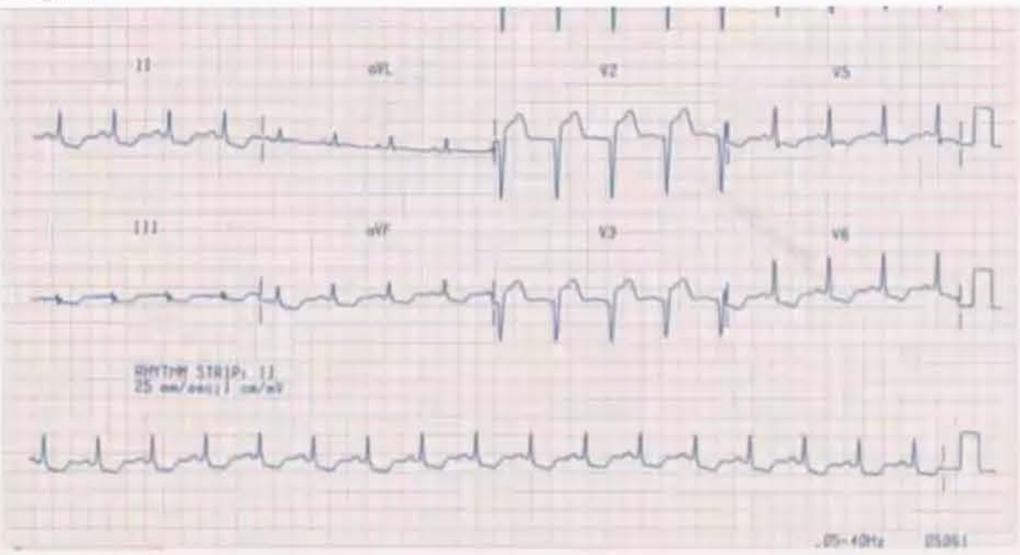

She undergoes acute angioplasty and makes a good recovery. Her HbA1c is measured at 63.93 mmol/mol (8.0%). She is treated with insulin during the initial period but then switched back to metformin on day 3.

What additional therapy should you commence for long-term blood glucose control?

A	Basal bolus insulin
B	Pioglitazone
C	Repaglinide
D	Long acting Insulin
E	Gliclazide

Submit

Audio
Video
Share
Participants
More

10:21

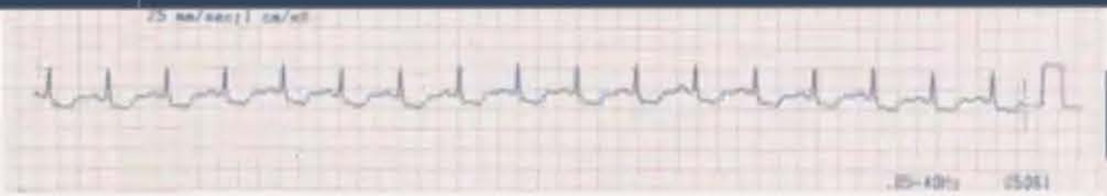

She undergoes acute angioplasty and makes a good recovery. Her HbA1c is measured at 63.93 mmol/mol (8.0%). She is treated with insulin during the initial period but then switched back to metformin on day 3.

What additional therapy should you commence for long-term blood glucose control?

Your answer was correct

A	Basal bolus insulin
B	Pioglitazone
C	Repaglinide
D	Long acting Insulin
E	Gliclazide

Explanation

E	Gliclazide

Whilst the DIGAMI-1 study appeared to show a survival advantage when insulin was initiated post myocardial infarction, this was not confirmed in the DIGAMI-2 study. Some problems were however identified with the DIGAMI-2 study, in that a substantial proportion of the control group were insulin users. In spite of this, a post-hoc analysis of insulin patients in the DIGAMI-2 study demonstrated an increased risk for myocardial ischaemic events. Further

Rana Alnasser's screen

Gliclazide

Whilst the DIGAMI-1 study appeared to show a survival advantage when insulin was initiated post myocardial infarction, this was not confirmed in the DIGAMI-2 study. Some problems were however identified with the DIGAMI-2 study, in that a substantial proportion of the control group were insulin users. In spite of this, a post-hoc analysis of insulin patients in the DIGAMI-2 study demonstrated an increased risk for myocardial ischaemic events. Further data from the ACCORD and VADT studies has suggested increased risk of cardiac death when very tight glycaemic control is targeted. This was not however reflected in the ADVANCE study which utilised sulphonylureas.

This patient has inadequate control of her BM. NICE guidelines suggests aiming for an HbA1C of 7% or 54mmol/mol. Therefore, further pharmacological therapy should be initiated. The use of insulin should be considered after a trial with 2 or more oral therapy.

NICE guidelines suggest that intensification therapy should occur if HbA1C is not under control. After the use of metformin, a further agent should be added i.e. DPP4 inhibitor, sulphonylurea or glitazone. Of all the options, there is gliclazide (sulphonylurea) and pioglitazone. Glitazones are contraindicated in heart failure and this leaves gliclazide as the only viable option.

NICE guidelines (updated April 2017) have now added the new SGLT-2 inhibitors in the guidelines to consider for intensification therapy if sulphonylurea is not tolerated or patients who are at significant risk of hypoglycaemia or its consequences. SGLT-2 inhibitors block reabsorption of glucose from the renal tubules which promote excretion of glucose from the kidneys, thereby reducing blood sugar level.

GLP-1 mimetic can be used after triple therapy with metformin + 2 other oral hypoglycaemics is ineffective. GLP-1 increases insulin secretion by the pancreas.

A Basal bolus insulin

Rana Alnasser's screen

10:24
594-042-7551 Leave

failure and therefore is not a good option in this patient. Pioglitazone may cause fluid retention and should be avoided in the immediate period post MI, a specific caution is given for patients with a past history of ischaemic heart disease.

C Repaglinide

Repaglinide belongs to the drug class of meglitinides. It works by stimulating beta pancreatic cells to produce insulin. Repaglinide is most useful in the early period after diagnosis of diabetes, particularly when post prandial hyperglycaemia is a problem. This is not one of the classes mentioned in NICE guidelines and therefore is not the correct response.

D Long acting Insulin

This patient has inadequate BM control and therefore requires intensification of her medications. The use of insulin should be considered after a trial with 2 or more oral therapy.

Rate this question:

© Pastest 2019

Audio Video Share Participants More

10:24

A 74-year-old man with a known history of ischaemic heart disease is brought to the Emergency Department by ambulance after collapsing in the local supermarket. On arrival in the department his BP is 90/50 mmHg, and he looks grey and sweaty. He has very rapid, regular palpitations. On auscultation of the chest there are bilateral crackles consistent with heart failure. ECG shows ventricular tachycardia with a ventricular rate of around 230 bpm.

Investigations (arterial blood gas):

pH	7.40
pO_2	8.9 kPa
pCO_2	4.4 kPa
Na^+	138 mmol/l
K^+	4.5 mmol/l
Urea	6.0 mmol/l
Bicarbonate	21 mmol/l

Which of the following is the most appropriate next step?

A IV magnesium sulphate

B IV calcium gluconate

C IV lignocaine

D IV amiodarone

E Synchronised DC cardioversion

Rana Alnasser's screen

10:26
594-042-7551
Leave

D IV amiodarone

E Synchronised DC cardioversion

Explanation

E Synchronised DC cardioversion

This man has an unstable ventricular tachycardia with cardiovascular compromise – he is hypotensive with evidence of heart failure. He is at imminent risk of pulseless ventricular tachycardia (VT) or a ventricular fibrillation (VF) arrest. Management of this situation is covered by the Rescusitation Council guidance for peri-arrest arrhythmias. As the patient is unstable, the immediate management is synchronised DC cardioversion rather than waiting for anti-arrhythmics to take effect. Therefore option E, synchronised DC cardioversion, is correct.

A IV magnesium sulphate

IV magnesium is used in the treatment of torsades de pointes VT, which usually accompanies QT prolongation. A dose of 2 g is given IV over 10 min. Electrolyte abnormalities should also be corrected.

B IV calcium gluconate

IV calcium gluconate is occasionally used in cardiac arrest but is not included in any of the guidelines. It works as a positive inotrope. If this patient were found to be calcium deplete, it would certainly be worth correcting this.

C IV lignocaine

Audio Video Share Participants More

10:26
594-042-7551
Leave

A 74-year-old man is admitted after a collapse. He has a history of ischaemic heart disease and chronic obstructive pulmonary disease. According to his daughter who comes to the Emergency department soon after he is brought in, he has recently been started on some new medication by his GP for a respiratory tract infection. On examination his BP is 80/60 mmHg, he looks grey and sweaty. There are bilateral crackles and wheeze on auscultation of the chest. The monitor shows runs of torsades de pointes VT.

Which of the following medications is most likely to have precipitated this event?

A	Co-amoxiclav
B	Erythromycin
C	Ramipril
D	Spironolactone
E	Theophylline

34146

Submit

Previous Q... Skip Questi...

Blog About Pastest Contact Us Help
Audio Video Share Participants More

10:26
594-042-7551
Leave

A 74-year-old man is admitted after a collapse. He has a history of ischaemic heart disease and chronic obstructive pulmonary disease. According to his daughter who comes to the Emergency department soon after he is brought in, he has recently been started on some new medication by his GP for a respiratory tract infection. On examination his BP is 80/60 mmHg, he looks grey and sweaty. There are bilateral crackles and wheeze on auscultation of the chest. The monitor shows runs of torsades de pointes VT.

Which of the following medications is most likely to have precipitated this event?

Your answer was correct

A	Co-amoxiclav
B	Erythromycin
C	Ramipril
D	Spironolactone
E	Theophylline

Explanation

B Erythromycin

Torsades de pointes VT is associated with hypokalaemia, hypomagnaesaemia and drugs which prolong the QT interval, which of course include the macrolides, such as erythromycin and clarithromycin. Other drugs known to

Audio
Video
Share
Participants
More

10:27
594-042-7551
Leave

Explanation

B Erythromycin

Torsades de pointes VT is associated with hypokalaemia, hypomagnaesaemia and drugs which prolong the QT interval, which of course include the macrolides, such as erythromycin and clarithromycin. Other drugs known to lead to prolong QT include agents such as domperidone and ketoconazole.

Treatment is to correct electrolyte abnormalities and withhold offending drugs. It is usually self-limiting and IV magnesium is commonly used to stabilise the rhythm. However, in patients who are haemodynamically compromise, DC cardioversion may be the treatment of choice.

A Co-amoxiclav

Co-amoxiclav is not a drug that commonly causes long QT which could've precipitated torsade.

C Ramipril

Ramipril is not a drug that causes prolonged QT and can sometimes cause hyperkalaemia instead of hypokalaemia which can also precipitate Torsades.

D Spironolactone

Spironolactone does not cause QT prolongation and causes hyperkalaemia.

E Theophylline

Whilst theophylline is known to precipitate hypokalaemia, it is likely to have been used chronically in this case rather

Audio Video Share Participants More

10:27

Treatment is to correct electrolyte abnormalities and withhold offending drugs. It is usually self-limiting and IV magnesium is commonly used to stabilise the rhythm. However, in patients who are haemodynamically compromise, DC cardioversion may be the treatment of choice.

A Co-amoxiclav

Co-amoxiclav is not a drug that commonly causes long QT which could've precipitated torsade.

C Ramipril

Ramipril is not a drug that causes prolonged QT and can sometimes cause hyperkalaemia instead of hypokalaemia which can also precipitate Torsades.

D Spironolactone

Spironolactone does not cause QT prolongation and causes hyperkalaemia.

E Theophylline

Whilst theophylline is known to precipitate hypokalaemia, it is likely to have been used chronically in this case rather than to have been started acutely.

Rate this question:

Next Question

Previous Q... Tag Questi... Feedback End Session

Rana Alnasser's screen

10:27
594-042-7551
Leave

An 18-year-old man is referred to the hospital clinic complaining of severe headaches. The GP notes that he is hypertensive with a blood pressure of 155/80 mmHg. He has suffered nose bleeds and feels too fatigued to perform any physical exercise. On examination there appears to be radiofemoral delay and a late systolic murmur is heard on auscultation. Chest X-ray shows cardiac enlargement with evidence of rib-notching.

Which of the following diagnoses fits best with this clinical picture?

A	Congenital aortic stenosis
B	Congenital mitral regurgitation
C	Coarctation of the aorta
D	Transposition of the great vessels
E	Atrial septal defect

9284

Submit

Blog About Pastest Contact Us Help
Audio Video Share Participants More

An 18-year-old man is referred to the hospital clinic complaining of severe headaches. The GP notes that he is hypertensive with a blood pressure of 155/80 mmHg. He has suffered nose bleeds and feels too fatigued to perform any physical exercise. On examination there appears to be radiofemoral delay and a late systolic murmur is heard on auscultation. Chest X-ray shows cardiac enlargement with evidence of rib-notching.

Which of the following diagnoses fits best with this clinical picture?

Your answer was correct

A	Congenital aortic stenosis
B	Congenital mitral regurgitation
C	Coarctation of the aorta
D	Transposition of the great vessels
E	Atrial septal defect

Explanation

C Coarctation of the aorta

Coarctation of aorta produces a late systolic murmur and radio-femoral delay. Rib-notching present on chest X-ray is due to pressure erosion from enlarged collateral vessels.

This is a narrowing of the aorta, usually found just distal to

Explanation

C Coarctation of the aorta

Coarctation of aorta produces a late systolic murmur and radio-femoral delay. Rib-notching present on chest X-ray is due to pressure erosion from enlarged collateral vessels.

This is a narrowing of the aorta, usually found just distal to the origin of the left subclavian artery. It represents 5–10% of all congenital cardiac lesions and patients repaired before the age of 14 years have a 20-year survival of 91%. Survival rates then steadily fall, the later repair is attempted. Associated conditions include Turner syndrome. Older patients may present with hypertension, headaches, nose bleeds, cold peripheries or intermittent claudication. A continuous or late systolic murmur is heard on auscultation.

A Congenital aortic stenosis

Congenital aortic stenosis accounts for 3-6% of congenital heart disease. Clinical examination findings include ejection-systolic murmur and a narrow pulse pressure. It does not cause a radio-femoral delay and therefore is not the answer in this case.

B Congenital mitral regurgitation

This produces a pan-systolic murmur on auscultation. It does not cause radio-femoral delay.

D Transposition of the great vessels

Transposition of the great vessels is one of the commonest cyanotic congenital heart diseases. Patients who are not treated have a high mortality rate - 30% in the first week,

10:28

does not cause a radio-femoral delay and therefore is not the answer in this case.

B Congenital mitral regurgitation

This produces a pan-systolic murmur on auscultation. It does not cause radio-femoral delay.

D Transposition of the great vessels

Transposition of the great vessels is one of the commonest cyanotic congenital heart diseases. Patients who are not treated have a high mortality rate – 30% in the first week, 50% in the first month and 90% in the first year. Treatment is surgical, commonly with an arterial switch procedure.

E Atrial septal defect

ASD is commonly associated with Down syndrome and Ebstein anomaly. Clinical examination findings include fixed splitting of the second heart sound, which does not change with respiration.

Rate this question:

© Pastest 2019

Rana Alnasser's screen

You are asked to review a man who has been transferred to the ward from Coronary Care. He is day 3 post-thrombolysis after an inferior myocardial infarction.

A routine electrocardiogram (ECG) was requested by the team but was not reviewed, as it was done late during the day. The nurse in charge bleeps you to say the ECG looks abnormal. The nurse reports the patient is eating his dinner at present, and his blood pressure (BP) is a little low at 95/50 mmHg, with a pulse of 48 bpm.

He is on aspirin, metoprolol 25 mg three times daily, atorvastatin 40 mg daily and ramipril 5 mg twice daily.

The ECG is shown below.

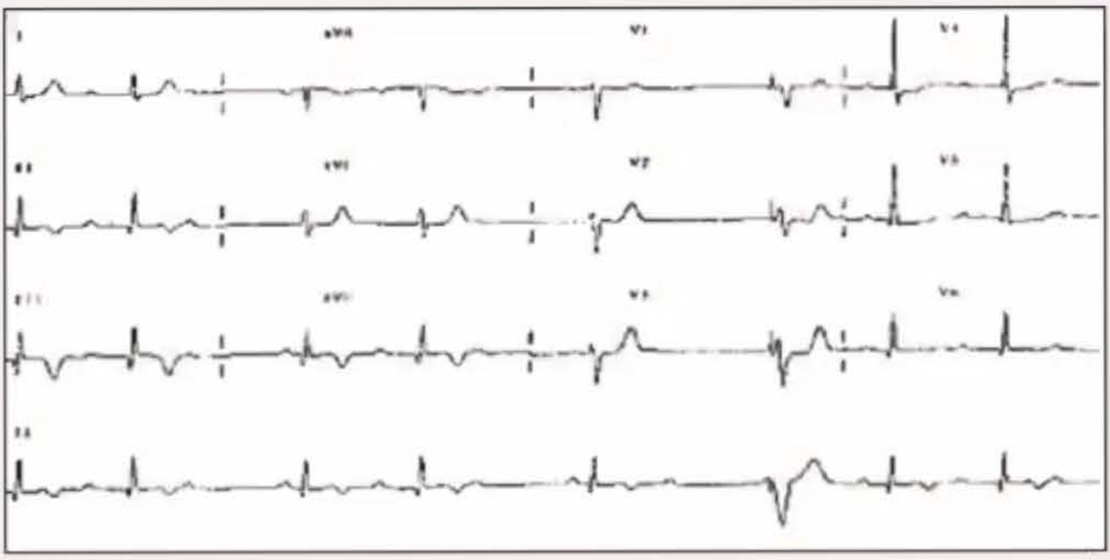

What is your next step in management?

A	The patient needs a temporary pacemaker inserted
B	The patient needs a permanent pacemaker the following day
C	The patient needs a stat dose of intravenous atropine 0.3 mg
D	You reassure the nurse in charge and do nothing

He is on aspirin, metoprolol 25 mg three times daily, atorvastatin 40 mg daily and ramipril 5 mg twice daily.

The ECG is shown below.

What is your next step in management?

A The patient needs a temporary pacemaker inserted

B The patient needs a permanent pacemaker the following day

C The patient needs a stat dose of intravenous atropine 0.3 mg

D You reassure the nurse in charge and do nothing

E You reassure the nurse in charge and reduce the dose of metoprolol

Submit

Rana Alnasser's screen

C The patient needs a stat dose of intravenous atropine 0.3 mg

D You reassure the nurse in charge and do nothing

E You reassure the nurse in charge and reduce the dose of metoprolol

Explanation

E You reassure the nurse in charge and reduce the dose of metoprolol

Adjusting the dose of metoprolol while keeping the patient on a heart monitor will most likely be enough for the low pulse rate and blood pressure to recover.

A The patient needs a temporary pacemaker inserted

This is a second-degree atrioventricular (AV) block. It is usually a transient and benign rhythm, following an inferior infarct involving the AV nodal artery. It is not an indication for pacing.

B The patient needs a permanent pacemaker the following day

At this stage, insertion of a pacemaker is unnecessary. If following the infarct, there is development of a higher degree of block, then a permanent pacemaker may be required.

Rana Alnasser's screen

usually a transient and benign rhythm, following an inferior infarct involving the AV nodal artery. It is not an indication for pacing.

B The patient needs a permanent pacemaker the following day

At this stage, insertion of a pacemaker is unnecessary. If following the infarct, there is development of a higher degree of block, then a permanent pacemaker may be required.

C The patient needs a stat dose of intravenous atropine 0.3 mg

In this scenario, the patient is obviously well and does not need urgent treatment with atropine. He should, however, be kept on ECG telemetry.

D You reassure the nurse in charge and do nothing

The findings are likely due to drug toxicity from beta-blockade. Unless appropriate interventions are implemented to his pharmacological treatment, his bradycardia and hypotension will persist and may deteriorate.

A 52-year-old man with type 2 diabetes calls the ambulance service due to new-onset central chest pain.

On arrival of the paramedics, he is found to have anterior ST elevation and is transferred directly to the local Percutaneous Coronary Intervention (PCI) Centre. On angiography, he is found to have a lesion of his left anterior descending (LAD) coronary artery, and treatment is planned.

What is the best way to treat this patient and minimise the risk of restenosis?

A	Bare-metal stent (BMS) insertion
B	Drug-eluting stent (DES) insertion
C	Bare-metal stent and pioglitazone
D	Thrombolysis
E	Coronary artery bypass graft (CABG)

71460

Submit

E Coronary artery bypass graft (CABG)

Explanation

B Drug-eluting stent (DES) insertion

The correct answer is Drug-eluting stent (DES) insertion (Option B).

DES were seen in a 2004 meta-analysis to reduce the relative risk of restenosis in diabetic patients by around 80%, as compared to BMS, in the first year of follow-up. There is a further reduced incidence of restenosis when second-generation DES are compared to first-generation DES.

A Bare-metal stent (BMS) insertion

Bare-metal stent (BMS) insertion (Option A) is incorrect.

Studies have shown that in patients with type 2 diabetes, coronary stents are liable to a high rate of restenosis at a rate of 40–50% by the end of a 6-month follow-up period. Predictors of restenosis include small vessel size, increased stented length, complex lesion morphology, diabetes mellitus and prior bypass surgery.

C Bare-metal stent and pioglitazone

Bare-metal stent and pioglitazone (Option C) is incorrect.

Pioglitazone has been shown to reduce in-stent restenosis, but given that it is a cause of fluid retention and may worsen heart failure, particularly when combined with insulin, any effect on stent restenosis is subsidiary to the increased risk of heart failure.

Rana Alnasser's screen

but given that it is a cause of fluid retention and may worsen heart failure, particularly when combined with insulin, any effect on stent restenosis is subsidiary to the increased risk of heart failure.

D	Thrombolysis

Thrombolysis (Option D) is incorrect.

Given that the patient has presented at a PCI Centre, treatment with stent insertion is the recommended therapy.

The National Institute for Health and Care Excellence (NICE) guidelines recommend the following approach for the acute management of myocardial infarction with ST-segment elevation.

Offer coronary angiography, with follow-on primary PCI if indicated, as the preferred coronary reperfusion strategy for people with acute ST-elevation myocardial infarction (STEMI) if:

- presentation is within 12 hours of onset of symptoms and
- primary PCI can be delivered within 120 minutes of the time when fibrinolysis could have been given.

E	Coronary artery bypass graft (CABG)

Coronary artery bypass graft (CABG) (Option E) is incorrect.

In most cases, PCI or fibrinolysis can usually restore flow to the ischaemic myocardium more quickly than CABG, largely attributable to delays in getting the patient to the operating room and the time it takes to complete the bypass surgical procedure. Thus, CABG is uncommonly used as the reperfusion strategy of choice in STEMI; it is estimated that CABG is performed in < 5% of cases. NICE guidelines do not recommend the use of CABG in the acute

for people with acute ST-elevation myocardial infarction (STEMI) if:

- presentation is within 12 hours of onset of symptoms and
- primary PCI can be delivered within 120 minutes of the time when fibrinolysis could have been given.

E	Coronary artery bypass graft (CABG)

Coronary artery bypass graft (CABG) (Option E) is incorrect.

In most cases, PCI or fibrinolysis can usually restore flow to the ischaemic myocardium more quickly than CABG, largely attributable to delays in getting the patient to the operating room and the time it takes to complete the bypass surgical procedure. Thus, CABG is uncommonly used as the reperfusion strategy of choice in STEMI; it is estimated that CABG is performed in < 5% of cases. NICE guidelines do not recommend the use of CABG in the acute management of STEMI.

Rate this question:

Next Question

Previous Q... Tag Questi... Feedback End Session

Blog About Pastest Contact Us Help

© Pastest 2019

10:35
594-042-7551
Leave

A 32-year-old woman is being prepared for surgery for medullary carcinoma of the thyroid. She also has a history of poorly controlled hypertension, and a preoperative abdominal CT raises the possibility of a left phaeochromocytoma. Her BP is 165/90 mmHg, with pulse 85/min and regular.

Which of the following is the optimal initial intervention with respect to controlling her BP preop?

A	Atenolol
B	Amlodipine
C	Indapamide
D	Phenoxybenzamine
E	Ramipril

Submit

© Pastest 2019

Audio Video Share Participants More

A 32-year-old woman is being prepared for surgery for medullary carcinoma of the thyroid. She also has a history of poorly controlled hypertension, and a preoperative abdominal CT raises the possibility of a left phaeochromocytoma. Her BP is 165/90 mmHg, with pulse 85/min and regular.

Which of the following is the optimal initial intervention with respect to controlling her BP preop?

Your answer was correct

A Atenolol

B Amlodipine

C Indapamide

D Phenoxybenzamine

E Ramipril

Explanation

D Phenoxybenzamine

This patient has a phaeochromocytoma, a neuroendocrine tumour of the adrenal medulla that secretes catecholamines (primarily nor-adrenaline). Blockade of adrenoceptors is thus required to control blood pressure. α-Blockade should be initiated first; if beta-blockade is undertaken initially, this can lead to unopposed alpha stimulation and precipitate a hypertensive crisis. The presence of medullary-type carcinoma of the thyroid

D Phenoxybenzamine

This patient has a phaeochromocytoma, a neuroendocrine tumour of the adrenal medulla that secretes catecholamines (primarily nor-adrenaline). Blockade of adrenoceptors is thus required to control blood pressure. α-Blockade should be initiated first; if beta-blockade is undertaken initially, this can lead to unopposed alpha stimulation and precipitate a hypertensive crisis. The presence of medullary-type carcinoma of the thyroid combined with phaeochromocytoma should raise the possibility of multiple endocrine neoplasia type 2.

A Atenolol

Atenolol is a selective β_1 antagonist. If β-blockade is undertaken as initial therapy in a phaeochromocytoma, unopposed alpha-receptor stimulation by circulating nor-adrenaline can result in a hypertensive crisis. β-Blockade, usually with a selective β_1 antagonist, can be considered during surgical resection of the tumour.

B Amlodipine

Amlodipine is a dihydropyridine-type calcium channel blocker. Phaeochromocytomas result in elevated circulating levels of catecholamines and it is through this mechanism that hypertension results. As such, α-blockade should be the primary mechanism by which hypertension is controlled in this patient. Calcium channel blockade can be undertaken if further therapy is required to control blood pressure.

C Indapamide

Indapamide is a thiazide-like diuretic. α-Blockade is required to counteract the high circulating levels of

blocker. Phaeochromocytomas result in elevated circulating levels of catecholamines and it is through this mechanism that hypertension results. As such, α-blockade should be the primary mechanism by which hypertension is controlled in this patient. Calcium channel blockade can be undertaken if further therapy is required to control blood pressure.

C	Indapamide

Indapamide is a thiazide-like diuretic. α-Blockade is required to counteract the high circulating levels of catecholamines secondary to the phaeochromocytoma. Indapamide has no central role in the treatment of hypertension in this situation.

E	Ramipril

Ramipril is an ACE-inhibitor. Although it has a central role in the management of hypertension within the general hypertensive population, it is not used as a primary antihypertensive agent in those with phaeochromocytoma.

36484

Rate this question:

Next Question

Previous Q... Tag Questi... Feedback End Session

Blog About Pastest Contact Us Help

© Pastest 2019

Rana Alnasser's screen

10:36

A 32-year-old woman presents to the clinic with increasing shortness of breath. She has returned to work after the birth of her second child but is breathless climbing the stairs or even on running only a few yards to catch the bus. She has been previously well, and was a keen half marathon runner in her 20's before she started having her family. On examination her BP is 125/72 mmHg, pulse is 62/min and regular. There is a loud second heart sound, but the lungs are clear. She has bilateral pitting lower limb oedema. Abdomen is soft and non tender, her BMI is 22.

Investigations:

Hb	13.1 g/dl
WCC	9.3 $\times 10^9$/l
PLT	199 $\times 10^9$/l
Na^+	138 mmol/l
K^+	4.2 mmol/l
Creatinine	110 micromol/l
CXR	Unremarkable
Echo	Elevated estimated pulmonary artery pressure (no signs of right / left shunt / atrial septal defect (ASD))
CTPA	No evidence of pulmonary emboli
Catheterisation - Pulmonary artery pressure	38mmHg
Acute vasoreactivity testing	positive

Which of the following is the most appropriate first line therapy for her?

Rana Alnasser's screen

K	4.2 mmol/l
Creatinine	110 micromol/l
CXR	Unremarkable
Echo	Elevated estimated pulmonary artery pressure (no signs of right / left shunt / atrial septal defect (ASD))
CTPA	No evidence of pulmonary emboli
Catheterisation - Pulmonary artery pressure	38mmHg
Acute vasoreactivity testing	positive

Which of the following is the most appropriate first line therapy for her?

A Amlodipine

B Diltiazem

C Bosentan

D Iloprost

E Sildenafil

Submit

B Diltiazem

The vasoreactivity being positive makes CCB the better choice of treatment for PPH. However, with her HR of 62BPM, diltiazem is a less favourable option compared to non-rate limiting CCB.

C Bosentan

Bosentan is an oral active dual endothelin receptor type A and B antagonist and it is used for patients who are not vasoreactive. It can also be used as a combination therapy in patients who have not responded to high dose CCB.

D Iloprost

Iloprost is a prostacyclin analogue and is used for patients who are not vasoreactive. It can also be used as a combination therapy in patients who have not responded to high dose CCB.

E Sildenafil

Sildenafil is an oral selective inhibitor of phosphodiesterase type 5 and is used for patients who are not vasoreactive. It can also be used as a combination therapy in patients who have not responded to high dose CCB.

Rate this question:

Next Question

Previous Q... Tag Questi... Feedback End Session

10:39

MyPastest
https://mypastest.pastest.com

A 27-year-old man is admitted to the Emergency Department from a nightclub. He does not consume alcohol but admits to having used amphetamines and to having snorted one line of cocaine. He tells you that his heart is thumping and he feels faint and light headed. On examination he has a blood pressure of 115/60 mmHg and a regular tachycardia of approximately 150 beats/minute. He is not in cardiac failure.

His ECG is shown below.

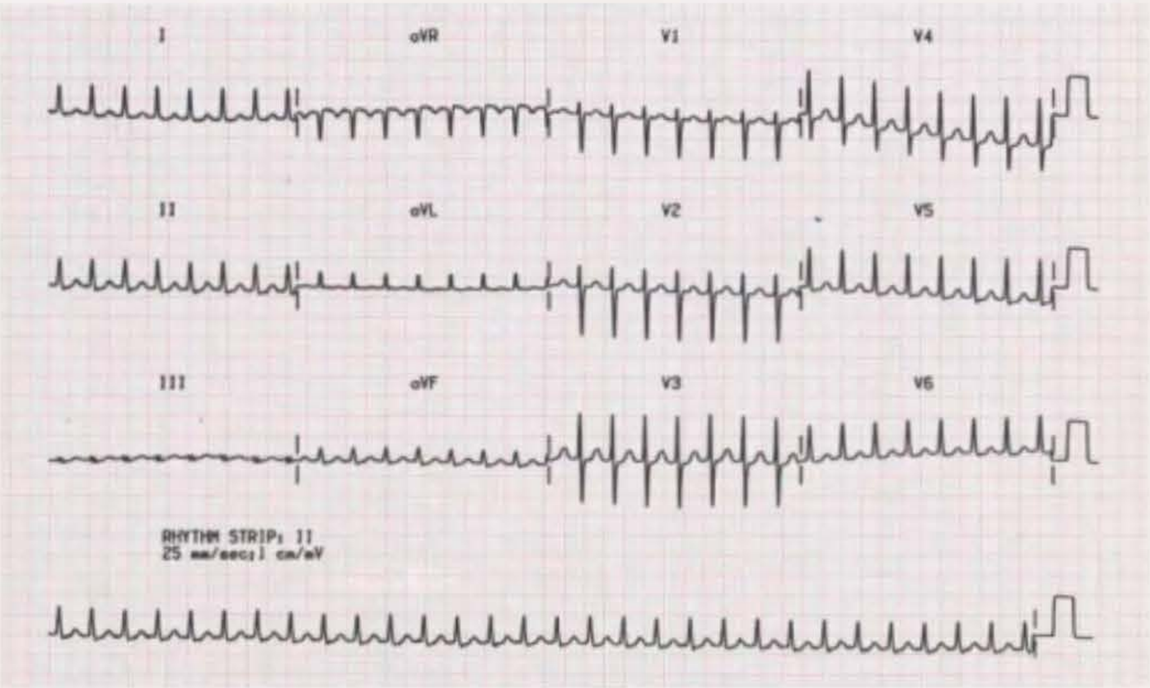

Which of the following is the most likely diagnosis?

A	Paroxysmal ventricular tachycardia
B	Sinus tachycardia
C	Multi-focal atrial tachycardia
D	Atrial flutter

Department from a nightclub. He does not consume alcohol but admits to having used amphetamines and to having snorted one line of cocaine. He tells you that his heart is thumping and he feels faint and light headed. On examination he has a blood pressure of 115/60 mmHg and a regular tachycardia of approximately 150 beats/minute. He is not in cardiac failure.

His ECG is shown below.

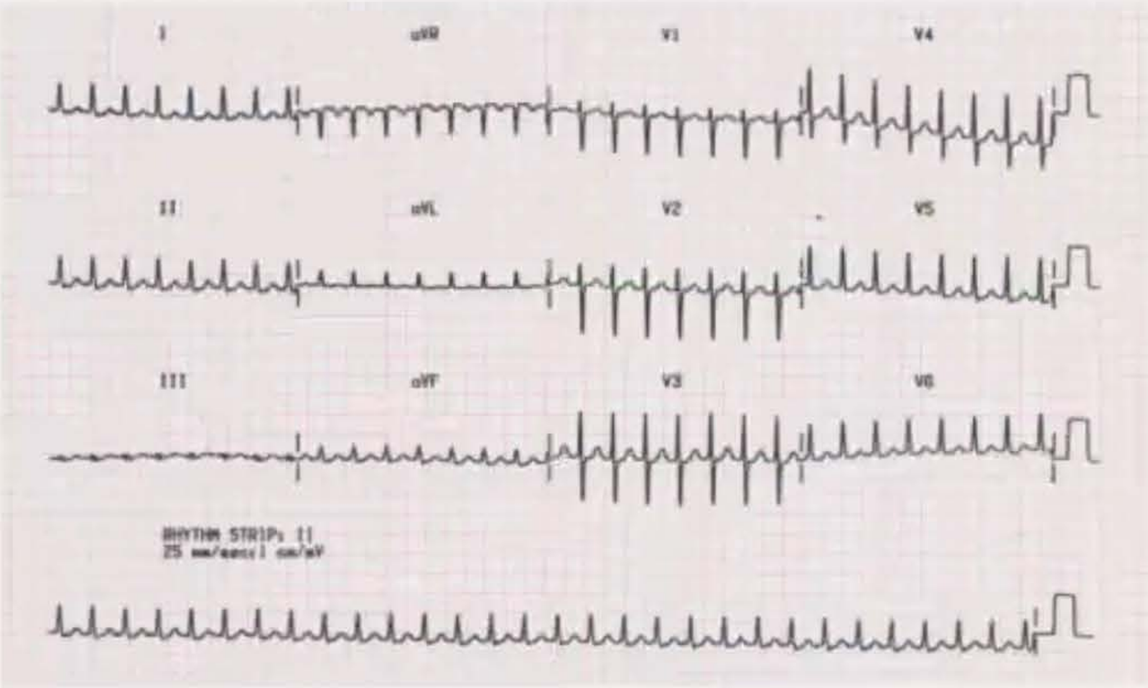

Which of the following is the most likely diagnosis?

A	Paroxysmal ventricular tachycardia
B	Sinus tachycardia
C	Multi-focal atrial tachycardia
D	Atrial flutter
E	AV nodal re-entrant tachycardia

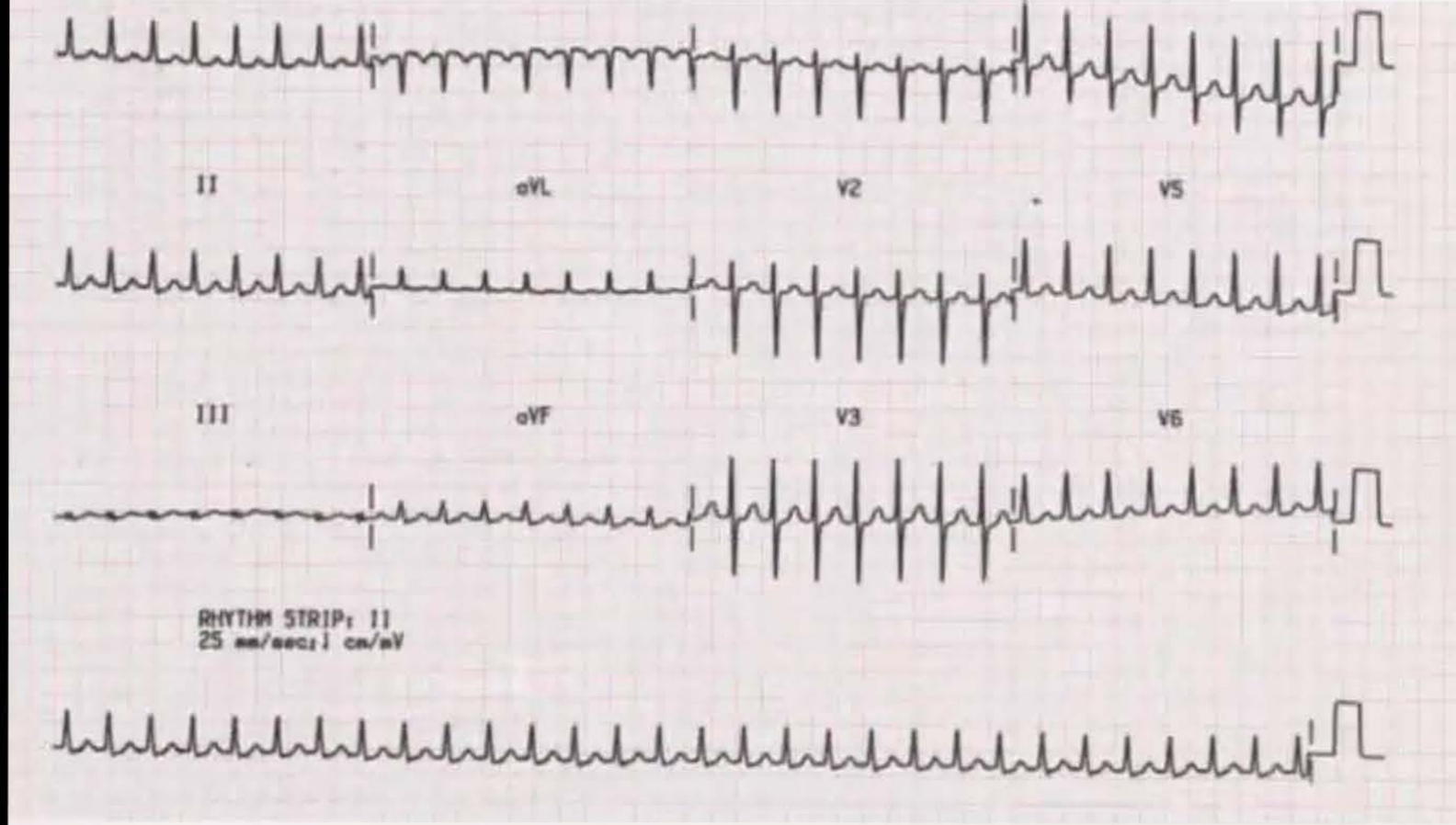

Which of the following is the most likely diagnosis?

A. Paroxysmal ventricular tachycardia

Rana Alnasser's screen

10:43

Explanation

E	AV nodal re-entrant tachycardia

The presence of pseudo R' wave in V1 and the absence of P waves on the ECG makes the diagnosis of AVNRT the most likely.

This is the most commontype of re-entrant SVT, which may occur both in young healthy patients and in those with structural heart disease. The usual cause is the presence of dual AV nodal pathways (slow and fast pathways within the AV node). Patients may present at any time from the teenage years, to even as late as the seventh decade. It is likely that use of amphetamine and cocaine has precipitated this presentation.

Vagal manoeuvres could be attempted to cardiovert the patient. If it fails, the use of IV adenosine in the presence of appropriate resuscitation facility would be appropriate. Ensure that the patient is being monitored whilst adenosine is given so the underlying rhythm canbe captured. This cansometimes uncover underlying atrial flutter when the rate slows.

Calcium antagonists such as verapamil are the initial pharmacological therapy of choice if cardioversion does not work as beta blockade may lead to worsening of myocardial ischaemia in the context of cocaine overdose.

A	Paroxysmal ventricular tachycardia

The ECG shows a narrow complex tachycardia and therefore it is unlikely to be ventricular in origin.

B	Sinus tachycardia

There is no evidence of clear F -waves on the ECG

Rana Alnasser's screen

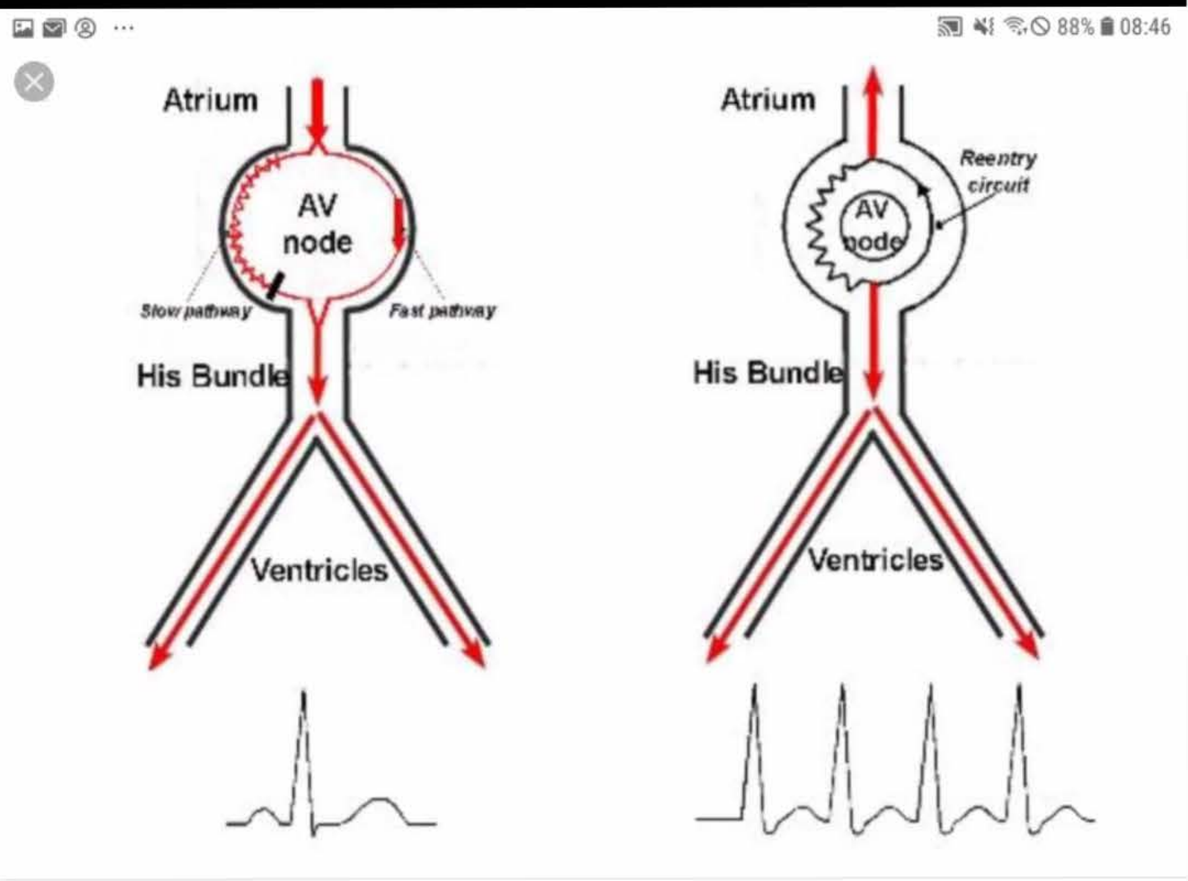

Washington Heart Rhythm Associates

Treatment for AV Nodal Reentrant Tachycardia (AVNRT) in Washington ...

AV Nodal Reentrant Tachycardia (AVNRT)

Images may be subject to copyright. Find out more

RELATED IMAGES

SEE MORE

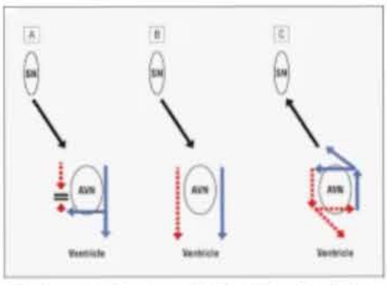

The Irregular Tachycardia That Was Not Atria...

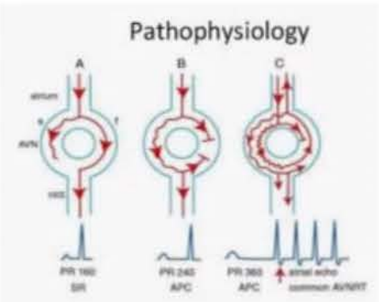

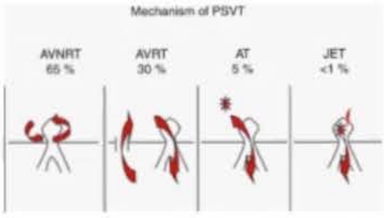

How to Differentiate Between AVRT, AT, AVN...

link.springer.com

Discover Updates Search Recent

11:01
594-042-7551
Leave

A 63-year-old male presents to the Emergency Department with a 3 h history of central crushing chest pain. His ECG on arrival shows ST elevation of 3 mm in the anterior leads consistent with an anterior myocardial infarction. He is sent for primary PCI and recovers well after angioplasty and stenting, being discharged from hospital some 5 days later. Two months following discharge from hospital the same patient presents to hospital complaining of palpitations and dizziness. An ECG shows a broad complex tachycardia. Following emergency treatment with synchronised DC cardioversion, an echocardiogram is performed that shows a hypokinetic anterior wall with an EF of 30%.

Which one of the following is the treatment of choice?

A	Amiodarone 200 mg tds
B	Automated ICD
C	Mexiletine 200 mg OD
D	Amiodarone 200 mg OD
E	Sotalol 80 mg OD

32338

Submit

Audio
Video
Share
Participants
More

Calculator

Normal Values

ts to the Emergency Department
l crushing chest pain. His ECG
on of 3 mm in the anterior leads
myocardial infarction. He is sent
rs well after angioplasty and
from hospital some 5 days later.
harge from hospital the same
l complaining of palpitations
ws a broad complex tachycardia.
ment with synchronised DC
iogram is performed that shows
with an EF of 30%.

g is the treatment of choice?

g tds

OD

g OD

32338

Submit

Skip Questi...

CHF

19 QRS

EF < 30 %

RCT + DF

QRS < 150

QRS > 150

ghlighter Line Rectangle Oval Undo Redo Clear Color Stop Share
ntact Us Help

with a 3 h history of central crushing chest pain. His ECG on arrival shows ST elevation of 3 mm in the anterior leads consistent with an anterior myocardial infarction. He is sent for primary PCI and recovers well after angioplasty and stenting, being discharged from hospital some 5 days later. Two months following discharge from hospital the same patient presents to hospital complaining of palpitations and dizziness. An ECG shows a broad complex tachycardia. Following emergency treatment with synchronised DC cardioversion, an echocardiogram is performed that shows a hypokinetic anterior wall with an EF of 30%.

Which one of the following is the treatment of choice?

Your answer was incorrect

A Amiodarone 200 mg tds

B Automated ICD

C Mexiletine 200 mg OD

D Amiodarone 200 mg OD

E Sotalol 80 mg OD

Explanation

B Automated ICD

The development of late-onset ventricular tachycardia following an ischaemic event, coupled with the finding of left ventricular impairment on the echocardiogram, is an indication for the implantation of an automated defibrillator. Studies have demonstrated t[illegible] is a superior strategy with respect to survival versus long-term

The development of late-onset ventricular tachycardia following an ischaemic event, coupled with the finding of left ventricular impairment on the echocardiogram, is an indication for the implantation of an automated defibrillator. Studies have demonstrated that this is a superior strategy with respect to survival versus long-term anti-arrhythmic therapy with an agent such as amiodarone or the other options listed. MADIT-II showed a reduction in all-cause mortality with ICD implantation vs conventional medical therapy (14.2% vs. 19.8%) in the context of post-MI patients with HFrEF. This was almost completely attributable to a reduction in sudden cardiac death (3.8% vs. 10.0%).

A Amiodarone 200 mg tds

Studies show that, in the context of ventricular tachyarrhythmias following MI in patients with decreased LV function, patients do significantly better with ICD implantation than with amiodarone.

C Mexiletine 200 mg OD

Mexiletine is a class 1B anti-arrhythmic agent. It is no longer licensed in the UK and therefore not an appropriate choice in this case.

D Amiodarone 200 mg OD

Studies show that, in the context of ventricular tachyarrhythmias following MI in patients with decreased LV function, patients do significantly better with ICD implantation than with amiodarone.

E Sotalol 80 mg OD

Annotation Stop Share

Studies show that in the context of VT following MI, in

or the other options listed. MADIT-II showed a reduction in all-cause mortality with ICD implantation vs conventional medical therapy (14.2% vs. 19.8%) in the context of post-MI patients with HFrEF. This was almost completely attributable to a reduction in sudden cardiac death (3.8% vs. 10.0%).

A Amiodarone 200 mg tds

Studies show that, in the context of ventricular tachyarrhythmias following MI in patients with decreased LV function, patients do significantly better with ICD implantation than with amiodarone.

C Mexiletine 200 mg OD

Mexiletine is a class 1B anti-arrhythmic agent. It is no longer licensed in the UK and therefore not an appropriate choice in this case.

D Amiodarone 200 mg OD

Studies show that, in the context of ventricular tachyarrhythmias following MI in patients with decreased LV function, patients do significantly better with ICD implantation than with amiodarone.

E Sotalol 80 mg OD

Studies show that in the context of VT following MI, in patients with heart failure, ICD is the management of choice

Rate this question:

Next Question Annotation Stop Share

A 57-year-old man presents to the GP with tiredness. He had a prosthetic aortic valve replacement 6 months ago. The procedure itself was uneventful, but he now feels increasingly tired and lethargic. He takes warfarin and a recent INR was 3.0. On examination he looks pale, BP 105/70 mmHg, pulse 90/min. On auscultation the prosthetic valve is easily audible. There are bilateral coarse crackles at both lung bases consistent with mild LVF.

Investigations:

Hb	9.7 g/dl
MCV	105 fl, reticulocytosis, decreased haptoglobins
WCC	5.0×10^9/l
PLT	155×10^9/l
Na^+	139 mmol/l
K^+	5.0 mmol/l
Creatinine	120 µmol/l
ESR	15 mm/hr
Alb	39 g/l
ALT	45 U/l
Bilirubin	86 µmol/l

Which of the following is the most likely diagnosis?

A Subacute bacterial endocarditis

B Gastrointestinal haemorrhage

C Valve haemolysis

recent INR was 3.0. On examination he looks pale, BP 105/70 mmHg, pulse 90/min. On auscultation the prosthetic valve is easily audible. There are bilateral coarse crackles at both lung bases consistent with mild LVF.

Investigations:

Hb	9.7 g/dl
MCV	105 fl, reticulocytosis, decreased haptoglobins
WCC	5.0×10^9/l
PLT	155×10^9/l
Na^+	139 mmol/l
K^+	5.0 mmol/l
Creatinine	120 µmol/l
ESR	15 mm/hr
Alb	39 g/l
ALT	45 U/l
Bilirubin	86 µmol/l

Which of the following is the most likely diagnosis?

A Subacute bacterial endocarditis

B Gastrointestinal haemorrhage

C Valve haemolysis

D Liver abscess

E Warfarin-related haemolytic anaemia

Explanation

C Valve haemolysis

Valve haemolysis is associated with prosthetic valve replacement. It occurs because of mechanical destruction of red cells and leads to anaemia, with increased reticulocyte count and decreased haptoglobins. The bilirubin elevation is likely to be due to a rise in unconjugated bilirubin because of haemolysis.

A Subacute bacterial endocarditis

This can present with fatigue, but there tend to be other features such as fever, new or changing heart murmur, weight loss and vascular and immunologic phenomena. Staphylococci and bacteria of the HACEK group (*Haemophilus*, *Actinobacillus*, *Cardiobacterium*, *Eikinella* and *Kingella*) are more common causative organisms in prosthetic valve endocarditis than native valve.

B Gastrointestinal haemorrhage

This should be suspected in any patient presenting with occult anaemia, including in this case. However, blood loss tends to cause a microcytic anaemia and haptoglobins would be normal.

D Liver abscess

This condition presents with fever, right upper quadrant pain, anorexia and malaise. There are variable changes in liver function tests, with hypoalbuminaemia and elevated alkaline phosphatase being the most typical.

E Warfarin-related haemolytic anaemia

unconjugated bilirubin because of haemolysis.

A Subacute bacterial endocarditis

This can present with fatigue, but there tend to be other features such as fever, new or changing heart murmur, weight loss and vascular and immunologic phenomena. Staphylococci and bacteria of the HACEK group (*Haemophilus*, *Actinobacillus*, *Cardiobacterium*, *Eikinella* and *Kingella*) are more common causative organisms in prosthetic valve endocarditis than native valve.

B Gastrointestinal haemorrhage

This should be suspected in any patient presenting with occult anaemia, including in this case. However, blood loss tends to cause a microcytic anaemia and haptoglobins would be normal.

D Liver abscess

This condition presents with fever, right upper quadrant pain, anorexia and malaise. There are variable changes in liver function tests, with hypoalbuminaemia and elevated alkaline phosphatase being the most typical.

E Warfarin-related haemolytic anaemia

Warfarin is not known to cause a haemolytic anaemia, though may be associated with occult blood loss and consequent anaemia.

215.21

Rate this question:

Next Question

11:10

MyPastest
https://mypastest.pastest.com

Pastes+

A 54-year-old man presents to the Emergency Department with palpitations and dizziness. One month ago, he underwent primary coronary intervention for an anterior ST-elevation myocardial infarction. His echocardiogram at discharge showed antero-septal hypokinesis with an ejection fraction of 38%. Twelve-lead ECG confirms monomorphic ventricular tachycardia; he is electrically cardioverted and returns to sinus rhythm and Q waves in leads V1-V4.

Which one of the following is the long-term treatment indicated?

A	Amiodarone 200 mg tds
B	Amiodarone 20o mg od
C	Sotalol 80 mg bd
D	Automated implantable cardiac defibrillator
E	Mexiletine

6907

Submit

Previous Q...

Skip Questi...

11:12

MyPastest
https://mypastest.pastest.com

A 54-year-old man presents to the Emergency Department with palpitations and dizziness. One month ago, he underwent primary coronary intervention for an anterior ST-elevation myocardial infarction. His echocardiogram at discharge showed antero-septal hypokinesis with an ejection fraction of 38%. Twelve-lead ECG confirms monomorphic ventricular tachycardia; he is electrically cardioverted and returns to sinus rhythm and Q waves in leads V1-V4.

Which one of the following is the long-term treatment indicated?

Your answer was correct

A Amiodarone 200 mg tds

B Amiodarone 20o mg od

C Sotalol 80 mg bd

D Automated implantable cardiac defibrillator

E Mexiletine

Explanation

D Automated implantable cardiac defibrillator

Studies have shown that implantable cardioverter-

11:12

MyPastest
https://mypastest.pastest.com

D Automated implantable cardiac defibrillator

Studies have shown that implantable cardioverter-defibrillators are superior to anti-arrhythmic in patients with a history of life-threatening ventricular arrhythmias. Studies suggest they are associated with a reduction in absolute mortality of 7.9%.

A Amiodarone 200 mg tds

Studies have shown that implantable cardioverter-defibrillators (ICDs) are superior to anti-arrhythmic drugs in patients with a history of life-threatening ventricular arrhythmias. Amiodarone can be considered in patients where ICDs are not appropriate, or in addition where patients have frequent episodes of VT.

B Amiodarone 20o mg od

Studies have shown that implantable cardioverter-defibrillators (ICDs) are superior to anti-arrhythmic in patients with a history of life-threatening ventricular arrhythmias. Amiodarone can be considered in patients where ICDs are not appropriate. This is also the maintenance dose, and a higher loading dose would usually be administered first.

C Sotalol 80 mg bd

Studies have shown that implantable cardioverter-defibrillators are superior to anti-arrhythmic in patients with a history of life-threatening ventricular arrhythmias. Although sotolol is a class III anti-arrhythmic, it isn't a usual first-choice option for patients with VT and LV dysfunction.

patients with a history of life-threatening ventricular arrhythmias. Amiodarone can be considered in patients where ICDs are not appropriate. This is also the maintenance dose, and a higher loading dose would usually be administered first.

C	Sotalol 80 mg bd

Studies have shown that implantable cardioverter-defibrillators are superior to anti-arrhythmic in patients with a history of life-threatening ventricular arrhythmias. Although sotolol is a class III anti-arrhythmic, it isn't a usual first-choice option for patients with VT and LV dysfunction.

E	Mexiletine

Mexiletine is structurally similar to lidocaine, a class Ib orally active antiarrhythmic drug acting on sodium channel blockade. Its use is not recommended in this context as it may provoke more frequent, and often more difficult to cardiovert, episodes of sustained VT, and can exacerbate LV dysfunction.

© Pastest 2019

11:14
594-042-7551
Leave

Table 1. Classification of Antiarrhythmic Drugs*

Class	Electrocardiographic Effect	Membrane Effect	Examples of Drugs
Vaughan Williams			
IA	↑ QRS and ↑ Q-T intervals	Sodium channel block; intermediate kinetics potassium channel block	Quinidine Procainamide hydrochloride Disopyramide
IB	↓ Q-T interval	Sodium channel block; rapid kinetics	Lidocaine Tocainide Mexiletine hydrochloride
IC	↑↑ QRS interval	Sodium channel block; slow kinetics	Flecainide acetate Propafenone hydrochloride Moricizine
II	↓ Heart rate; ↑ P-R interval	β-adrenergic receptor inhibition	Propranolol hydrochloride and others
III	↑ Q-T interval	Potassium channel block; slow sodium channel facilitator	*N*-acetyl-procainamide Sotalol hydrochloride Amiodarone Ibutilide fumarate
IV	↓ Heart rate; ↑ P-R interval	Calcium channel block	Verapamil Diltiazem hydrochloride
Digitalis	↑ P-R interval; ↓ Q-T interval	Na^+, K^+-ATPase inhibition	Digoxin Digitoxin
Adenosine	↓ Heart rate; ↑P-R interval	Purinergic receptor agonist	Adenosine

*↑ *indicates increased;* ↓, *decreased. Adapted with permission from Siddoway.*[3]

JAMA Network
Pharmacological Effects of Antiarrhythmic Drugs: Review and Update ...
Classification of Antiarrhythmic Drugs*
Images may be subject to copyright. Learn more
Stop Annotation Spotlight Pen Highlighter Line Rectangle Oval Undo Redo Clear Color Stop Sha
Discover Updates Search Recent More
Audio Video Share Participants More

11:15

A 59-year-old lady attends the Emergency Department complaining of severe indigestion-like pain. An electrocardiogram (ECG) shows ST elevation in the inferior leads. The patient goes for emergency PCI and is then admitted for monitoring in the coronary care unit. An hour after PCI she is noted to have a bradycardia that does not respond to atropine. Her blood pressure is around 100 mmHg systolic.

Which one of the following would be an indication for temporary pacing wire insertion?

A	Ventricular rate of 43 bpm
B	Type 1, second-degree heart block
C	Frequent ventricular ectopics
D	Junctional rhythm with a QRS of 160 ms
E	First-degree heart block with a PR of 240 ms

32335

Submit

Previous Q... Skip Questi...

Rana Alnasser's screen

E First-degree heart block with a PR of 240 ms

Explanation

D Junctional rhythm with a QRS of 160 ms

A widening QRS indicates a more extensive ischaemic territory affecting the conducting bundles. Temporary pacing wire insertion can be used as a holding measure to allow the myocardium time to recover. Bradycardias/heart block in the context of anterior myocardial infarction carry a much greater prognostic significance and are an indicator of extensive infarction.

B Type 1, second-degree heart block

Asymptomatic patients with Wenckeback phenomenon do not usually require intervention, as this rhythm is at lower risk of progression to complete heart block than type 2, second-degree heart block. Symptomatic patients can be treated with atropine, and in some cases pacing.

A Ventricular rate of 43 bpm

Bradycardias are quite common in the context of inferior myocardial infarctions and they are not considered to be of any prognostic significance. This is because the right coronary artery, which is the commonest culprit artery in inferior myocardial infarctions, also gives branches to the sinoatrial (SA) and atrioventricular (AV) nodes. In the absence of haemodynamic compromise, no specific intervention would be required.

C Frequent ventricular ectopics

a much greater prognostic significance and are an indicator of extensive infarction.

B Type 1, second-degree heart block

Asymptomatic patients with Wenckeback phenomenon do not usually require intervention, as this rhythm is at lower risk of progression to complete heart block than type 2, second-degree heart block. Symptomatic patients can be treated with atropine, and in some cases pacing.

A Ventricular rate of 43 bpm

Bradycardias are quite common in the context of inferior myocardial infarctions and they are not considered to be of any prognostic significance. This is because the right coronary artery, which is the commonest culprit artery in inferior myocardial infarctions, also gives branches to the sinoatrial (SA) and atrioventricular (AV) nodes. In the absence of haemodynamic compromise, no specific intervention would be required.

C Frequent ventricular ectopics

Ectopics are common following MI, and may represent reperfusion rhythm. In the absence of haemodynamic compromise, no specific intervention would be required. The CAST trial examined suppression of ventricular ectopics with class 1 anti-arrhythmics following MI, but was stopped early due to evidence of harm.

E First-degree heart block with a PR of 240 ms

First-degree heart block does not require specific intervention apart from observation.

Rate this question:

A 32-year-old man who has had diabetes mellitus for 27 years comes to the clinic for review. He has bilateral lower limb sensory loss consistent with peripheral neuropathy and background diabetic retinopathy, but is otherwise well.

Current insulin regime is 8 U TDS of short-acting insulin (Actrapid®) with 20 U/ day of long-acting insulin (Insulotard®). Apart from recurrent nocturnal hypoglycaemia (4 times/week), he feels he is doing well. His BP is 135/70 mmHg, with pulse 80/min and regular. His BMI is 23. HbA1c is 66 mmol/mol (8.2%) and a recent creatinine was measured at 135 micromol/l. Morning glucoses are in the range of 6–22 mmol/l.

Which of the following is the most appropriate change in his regimen?

A	Reduce his Actrapid® by 6 units/day
B	Reduce his Insulotard® by 6 units/day
C	Change his Insulotard® to insulin glargine at 20 units/day
D	Increase his Actrapid® by 6 units/day
E	Change his regime to 12 units of Mixtard® twice/day

9:22

A 71-year-old lady is brought to the Emergency Department by an ambulance because of altered consciousness. Her husband gave a history that she had not been herself that morning. She had complained of a headache and some blurred vision earlier, before she stopped communicating and her right arm started shaking uncontrollably. She has osteoarthritis for which she takes ibuprofen 200 mg tid.

On examination, she is drowsy with a Glasgow Coma Scale (GCS) of 13/15. Her blood pressure (BP) is 220/115 mmHg, pulse 81/min and regular. Her respiratory rate is 20/min and her chest is clinically clear. Her jugular venous pulse is just visible, first and second heart sounds are heard with no added murmurs. There is no focal neurology.
Investigations:

ECG	sinus rhythm with left ventricular strain pattern
Chest X-ray	Cardiomegaly
Fundoscopy	papilloedema
FBC, U/Es, LFTs, TFTs, urinalysis and lipid profile	are within normal range
CT brain	normal

Which one of the following interventions would you immediately start for this patient?

A Sodium nitroprusside

B Nifedipine

C Methyldopa

D Clonidine

Rana Alnasser's screen

not been herself that morning. She had complained of a headache and some blurred vision earlier, before she stopped communicating and her right arm started shaking uncontrollably. She has osteoarthritis for which she takes ibuprofen 200 mg tid.

On examination, she is drowsy with a Glasgow Coma Scale (GCS) of 13/15. Her blood pressure (BP) is 220/115 mmHg, pulse 81/min and regular. Her respiratory rate is 20/min and her chest is clinically clear. Her jugular venous pulse is just visible, first and second heart sounds are heard with no added murmurs. There is no focal neurology.

Investigations:

ECG	sinus rhythm with left ventricular strain pattern
Chest X-ray	Cardiomegaly
Fundoscopy	papilloedema
FBC, U/Es, LFTs, TFTs, urinalysis and lipid profile	are within normal range
CT brain	normal

Which one of the following interventions would you immediately start for this patient?

A Sodium nitroprusside

B Nifedipine

C Methyldopa

D Clonidine

E Ramipril

A Sodium nitroprusside

This patient mostly likely has hypertensive encephalopathy. Usually this is of gradual onset and may present with headache, nausea, vomiting, confusion and hypertensive retinopathy. The lack of focal neurology and normal CT head is reassuring with respect to ruling out a cerebral infarct and, more importantly, any haemorrhage/space-occupying lesion. The goal of therapy is to reduce the mean arterial pressure by approximately 25% over the first 24-48 h. An intra-arterial line can be helpful for continuous BP monitoring.

Sodium nitroprusside is a popular first-line agent for treating malignant hypertension and is given by continuous infusion. Its short-acting nature allows almost minute-by-minute titration according to response. Another popular first-line agent is IV labetalol, which is a combined alpha and beta receptor-blocker. It has the added benefit of easy IV to oral transition.

B Nifedipine

Other forms of IV calcium channel blockers (like nicardipine or diltiazem) are sometimes considered as alternatives if the first-line options are unsuitable.

C Methyldopa

Again this is not first-line therapy but could be considered in pregnancy along with hydralazine if other treatments like labetalol are ineffective. There is, however, a risk of worsening ischaemia.

D Clonidine

While this is an effective antihypertensive agent, it is not

9:24

A 74-year-old man with a history of ischaemic heart disease presents to the Emergency Department at 5 am with acute shortness of breath. The paramedics had recorded oxygen saturations of 90% on air when they initially attended him at home.

His current medications include ramipril 10 mg, bisoprolol 5 mg, aspirin 75 mg, atorvastatin 10 mg and furosemide 40 mg. On examination, his BP is 165/100 mmHg, with pulse 100 bpm and regular. He has crackles consistent with left ventricular failure (LVF) throughout both lung fields. Bloods available from 2 weeks earlier show a creatinine of 150 micromol/l.

Investigations (venous blood gas):

Hb	13.2 g/dl
Na^+	137 mmol/l
K^+	5.0 mmol/l
Urea	9.2 mmol/l
pH	7.35
Bicarbonate	22 mmol/l

ECG: sinus tachycardia, lateral ST depression.

Oxygen therapy has been commenced by ambulance staff.

Which of the following is the most appropriate next intervention?

A IV dobutamine

B IV furosemide

C Continuous positive airway pressure (CPAP)

D IV nitrate

Audio Video Share Participants More

initially attended him at home.

His current medications include ramipril 10 mg, bisoprolol 5 mg, aspirin 75 mg, atorvastatin 10 mg and furosemide 40 mg. On examination, his BP is 165/100 mmHg, with pulse 100 bpm and regular. He has crackles consistent with left ventricular failure (LVF) throughout both lung fields. Bloods available from 2 weeks earlier show a creatinine of 150 micromol/l.

Investigations (venous blood gas):

Hb	13.2 g/dl
Na^+	137 mmol/l
K^+	5.0 mmol/l
Urea	9.2 mmol/l
pH	7.35
Bicarbonate	22 mmol/l

ECG: sinus tachycardia, lateral ST depression.

Oxygen therapy has been commenced by ambulance staff.

Which of the following is the most appropriate next intervention?

A IV dobutamine

B IV furosemide

C Continuous positive airway pressure (CPAP)

D IV nitrate

E IV diamorphine

Rana Alnasser's screen

B IV furosemide

This patient is hypertensive with signs of pulmonary oedema. The key to improving his symptoms will be to offload fluid with a loop diuretic, in this case IV furosemide (option B). Although both urea and creatinine are elevated, a small rise in both consequent to diuretic use is acceptable because of the accompanying likely improvement in LVF symptoms.

C Continuous positive airway pressure (CPAP)

Non-invasive ventilation such as CPAP is also not routinely advocated, because of a recent study which showed no improvement in mortality or need for invasive ventilation versus standard medical therapy alone. Its use is no longer recommended by NICE, but it may be of symptomatic benefit and its use would be at the clinician's discretion.

A IV dobutamine

Dobutamine is an inotrope used in low-cardiac output states secondary to myocardial infarction (MI), cardiac surgery, cardiomyopathy, sepsis and in cardiac stress testing. Its use is restricted to the ITU/CCU.

D IV nitrate

IV nitrate, is often used alongside diuresis in clinical practice, titrated according to blood pressure. However, this is not recommended routinely by NICE (see weblink below).

E IV diamorphine

The use of diamorphine in acute pulmonary oedema is

Non-invasive ventilation such as CPAP is also not routinely advocated, because of a recent study which showed no improvement in mortality or need for invasive ventilation versus standard medical therapy alone. Its use is no longer recommended by NICE, but it may be of symptomatic benefit and its use would be at the clinician's discretion.

A IV dobutamine

Dobutamine is an inotrope used in low-cardiac output states secondary to myocardial infarction (MI), cardiac surgery, cardiomyopathy, sepsis and in cardiac stress testing. Its use is restricted to the ITU/CCU.

D IV nitrate

IV nitrate, is often used alongside diuresis in clinical practice, titrated according to blood pressure. However, this is not recommended routinely by NICE (see weblink below).

E IV diamorphine

The use of diamorphine in acute pulmonary oedema is contentious, as there have been outcome data published suggesting that opiates may be associated with increased need for intervention with respect to ventilation. Again, this is no longer part of the recommended management of acute pulmonary oedema.

36024

Rate this question:

Next Question

9:31

A 52-year-old man with a history of diabetes mellitus had a bare metal stent inserted after an inferior myocardial infarction. Three months later he is admitted with a further episode of chest pain. Troponin at 12 h is negative. On examination his BP is 140/82 mmHg, his pulse 72/min and regular. He is not clinically in heart failure. An exercise test is performed, which reveals inferolateral ST depression.

Which of the following is the most likely diagnosis?

A	In-stent thrombosis
B	New coronary artery disease distal to the stent
C	Coronary artery emboli
D	In-stent re-stenosis
E	Coronary artery vasospasm

21225

Submit

Previous Q... Skip Questi...

© Pastest 2019

Audio Video Share Participants More

A 52-year-old man with a history of diabetes mellitus had a bare metal stent inserted after an inferior myocardial infarction. Three months later he is admitted with a further episode of chest pain. Troponin at 12 h is negative. On examination his BP is 140/82 mmHg, his pulse 72/min and regular. He is not clinically in heart failure. An exercise test is performed, which reveals inferolateral ST depression.

Which of the following is the most likely diagnosis?

Your answer was correct

A	In-stent thrombosis
B	New coronary artery disease distal to the stent
C	Coronary artery emboli
D	In-stent re-stenosis
E	Coronary artery vasospasm

Explanation

D	In-stent re-stenosis

Bare metal stent re-stenosis occurs more commonly in patients with diabetes mellitus. Coated or drug-eluting stents are now recommended for use in patients with cardiac risk factors, such as diabetes.

Coated stents may also be associated with late re-stenosis in diabetes mellitus, particularly in the context of discontinuation of clopidogrel (in patients who are aspirin

D In-stent re-stenosis

Bare metal stent re-stenosis occurs more commonly in patients with diabetes mellitus. Coated or drug-eluting stents are now recommended for use in patients with cardiac risk factors, such as diabetes.

Coated stents may also be associated with late re-stenosis in diabetes mellitus, particularly in the context of discontinuation of clopidogrel (in patients who are aspirin resistant). It is also advised that dual anti-platelet therapy with both aspirin and clopidogrel should be continued for at least a year after the procedure.

A In-stent thrombosis

This is more common in diabetic patients and with bare metal stents than with coated stents. It is less common at this quite early stage post-procedure, and tends to coincide with cessation of anti-platelet medication.

B New coronary artery disease distal to the stent

This is unlikely given the short time frame, though longer term in such a patient with significant risk factors, this could become a problem. Indeed, the presence of a stent in a coronary artery may induce inflammatory changes in the vessel wall that make subsequent CABG higher risk.

C Coronary artery emboli

These are more common in atrial fibrillation. There is, in fact, a lower prevalence of classical cardiac risk factors such as hypertension, diabetes mellitus, smoking and dyslipidaemia in coronary emboli than other causes of myocardial ischaemia and infarction (see reference below).

A 62-year-old woman is admitted as an emergency suffering from extreme headache, nausea, vomiting and increasing drowsiness. Her blood pressure on admission is 185/130 mmHg and she has grade IV hypertensive retinopathy. Electrolyte testing reveals potassium 3.8 mmol/l, sodium 134 mmol/l and creatinine 158 mmol/l, and you admit her to the HDU.

Which one of the following is the most appropriate way to manage her blood pressure?

A	IV sodium nitroprusside
B	Oral amlodipine
C	Oral atenolol
D	Oral ramipril
E	Oral furosemide

Submit

© Pastest 2019

A 62-year-old woman is admitted as an emergency suffering from extreme headache, nausea, vomiting and increasing drowsiness. Her blood pressure on admission is 185/130 mmHg and she has grade IV hypertensive retinopathy. Electrolyte testing reveals potassium 3.8 mmol/l, sodium 134 mmol/l and creatinine 158 mmol/l, and you admit her to the HDU.

Which one of the following is the most appropriate way to manage her blood pressure?

Your answer was correct

A IV sodium nitroprusside

B Oral amlodipine

C Oral atenolol

D Oral ramipril

E Oral furosemide

Explanation

A IV sodium nitroprusside

This patient has hypertensive encephalopathy with a deteriorating level of consciousness. Her condition is too severe for oral therapy and she requires IV blood pressure lowering therapy with sodium nitroprusside. The aim of treatment is to lower blood pressure to around 110–115 mmHg diastolic within 2–4 h, and nitroprusside can be

Explanation

A IV sodium nitroprusside

This patient has hypertensive encephalopathy with a deteriorating level of consciousness. Her condition is too severe for oral therapy and she requires IV blood pressure lowering therapy with sodium nitroprusside. The aim of treatment is to lower blood pressure to around 110–115 mmHg diastolic within 2–4 h, and nitroprusside can be titrated to target. Nitroprusside therapy may be accompanied by IV furosemide. Where there is significant neurology, CT is also an important part of the work-up. Acute blood pressure lowering may result in an extension of deficit in the event of a proven stroke. Late features of hypertensive encephalopathy may include fits and coma.

B Oral amlodipine

Although amlodipine may lower blood pressure, acute effects are likely to be modest and amlodipine is long-acting, meaning that it can't be easily titrated.

C Oral atenolol

Oral atenolol may precipitate cardiac failure in patients with hypertensive crisis, and it is long-acting, preventing easy titration of the dose.

D Oral ramipril

Oral ramipril is occasionally used as initial therapy for marked hypertension in patients with probable autosomal dominant polycystic kidney disease, although in this case with hypertensive encephalopathy, nitroprusside is more appropriate.

E Oral furosemide

A 56-year-old man is reviewed on the cardiology ward. He is currently prescribed vancomycin 500 mg BD for bacterial endocarditis, and his trough vancomycin levels are available for your review. He is responding to therapy, blood pressure is 122/72 mmHg, with pulse 70/min and regular. He has a murmur consistent with mitral regurgitation, and has not spiked a fever over the past 24 h. His eGFR is 50 ml/min and the trough vancomycin level is measured at 35 mg/l.

Which of the following is the correct course of action?

A	Increase dose to 750 mg BD
B	Increase dose to 1 g BD
C	Omit dose and restart when level <15 mg/l
D	Omit single dose and continue at 500 mg BD in 12 h
E	Reduce dose to 250 mg OD

70597

Submit

A 56-year-old man is reviewed on the cardiology ward. He is currently prescribed vancomycin 500 mg BD for bacterial endocarditis, and his trough vancomycin levels are available for your review. He is responding to therapy, blood pressure is 122/72 mmHg, with pulse 70/min and regular. He has a murmur consistent with mitral regurgitation, and has not spiked a fever over the past 24 h. His eGFR is 50 ml/min and the trough vancomycin level is measured at 35 mg/l.

Which of the following is the correct course of action?

Your answer was correct

A	Increase dose to 750 mg BD
B	Increase dose to 1 g BD
C	Omit dose and restart when level <15 mg/l
D	Omit single dose and continue at 500 mg BD in 12 h
E	Reduce dose to 250 mg OD

Explanation

C	Omit dose and restart when level <15 mg/l

Vancomycin is an antibiotic used systemically to treat methicillin-resistant *Staphylococcus aureus* infections. IV administration is necessary for systemic treatment as vancomycin is not absorbed from the intestine. The trough

C Omit dose and restart when level <15 mg/l

Vancomycin is an antibiotic used systemically to treat methicillin-resistant *Staphylococcus aureus* infections. IV administration is necessary for systemic treatment as vancomycin is not absorbed from the intestine. The trough level listed above is significantly higher than the toxic threshold (30 mg/l). As such, dose omission is required to reduce the risk of significant complications (including ototoxicity and nephrotoxicity). The BNF recommends trough levels of 15-20 mg/l for endocarditis. Specific protocols for the dosing of vancomycin differ between NHS trusts, but all should suggest omission if the trough level is as high as documented here. Re-initiation once in range should be in consultation with the microbiology team.

A Increase dose to 750 mg BD

The trough level described in this vignette is much higher than the therapeutic range. Increasing the dose in this situation will only make the situation worse.

B Increase dose to 1 g BD

This will further increase the circulating levels of vancomycin, increasing the risk of significant adverse effects.

D Omit single dose and continue at 500 mg BD in 12 h

The half-life of vancomycin is highly variable and dependent on renal function. It is possible that the concentration of vancomycin may have reached a normal level after 12 h; however, further trough levels should be taken to confirm this before re-initiating.

A 71-year-old lady is admitted to the Emergency Department with severe central chest pain. The chest pain has been there for 40 min and is also felt in the arms and jaw. There is associated shortness in breath. Her past medical history includes: hypertension, osteoarthritis and diet-controlled diabetes mellitus. She is on the following medications: bendrofluazide 2.5 mg od, amlodipine 10 mg od and paracetamol 500 mg prn. She takes occasional alcohol and has smoked since she was 16 years of age (about 10 cigarettes/day).

On examination, she is distressed with a blood pressure of 90/45 mmHg, pulse of 38/min and regular. Her jugular venous pressure is raised to 7 cm with intermittent cannon waves. Her heart sounds are heard with a variable first heart sound. Her respiratory rate is 26/min and her chest is clinically clear.

Investigations:

Blood gases on 60% oxygen:	
pH	7.45
$p(O_2)$	15.10 kPa
$p(CO_2)$	3.77 kPa

Bicarbonate	22.4 mmol/l
Haemoglobin	15.8 g/dl
Mean Cell Volume	88.6 fl
Platelets	250×10^9 /l
White cell count	13.1×10^9 /l
Sodium	136 mmol/l
Potassium	4.1 mmol/l
Urea	7.7 mmol/l
Creatinine	121 µmol/l

White cell count	13.1×10^9 /l
Sodium	136 mmol/l
Potassium	4.1 mmol/l
Urea	7.7 mmol/l
Creatinine	121 µmol/l
Magnesium	0.81 mmol/l
Electrocardiogram (ECG)	More than 2 mm of ST elevation in II, III, aVF and ST depression in V1–V3, complete heart block
Chest X-ray	Normal

You instigate a fluid bolus

Which of the following other treatments would you plan for next?

A Nitrate infusion

B Thrombolysis

C PCI

D Transvenous Pacing

E IV furosemide

Submit

Urea	7.7 mmol/l
Creatinine	121 µmol/l
Magnesium	0.81 mmol/l
Electrocardiogram (ECG)	More than 2 mm of ST elevation in II, III, aVF and ST depression in V1–V3, complete heart block
Chest X-ray	Normal

You instigate a fluid bolus

Which of the following other treatments would you plan for next?

Your answer was correct

A Nitrate infusion

B Thrombolysis

C PCI

D Transvenous Pacing

E IV furosemide

Explanation

C PCI

This patient has right ventricular infarction and complete heart block. Right ventricular (RV) infarction results in elevated right-sided pressures and low left-sided pressures. Nitrates and diuretics should be avoided as they reduce preload and can worsen hypotension. The aim is to

C PCI

This patient has right ventricular infarction and complete heart block. Right ventricular (RV) infarction results in elevated right-sided pressures and low left-sided pressures. Nitrates and diuretics should be avoided as they reduce preload and can worsen hypotension. The aim is to maintain a high right ventricular preload by an initial fluid bolus. This patient has complete heart block, although this should resolve once revascularisation is achieved via PCI. If not, then temporary venous pacing would be a logical addition to therapy.

A Nitrate infusion

Nitrate infusion can further reduce preload and drive significant hypotension, and thus it should be avoided here.

B Thrombolysis

PCI has superior outcomes to thrombolysis in this situation and is therefore the preferred option.

D Transvenous Pacing

Heart block often resolves in right ventricular infarction after the acute ischaemia is relieved, and hence pacing may not be required.

E IV furosemide

In this situation diuretics may reduce right ventricular filling pressure and further exacerbate hypotension.

32306

Rate this question:

A 25-year-old male presents to the Emergency Department complaining of central chest pain which is made worse by coughing and deep inspiration. On examination, he has low-grade pyrexia at 37.9°C. A friction rub is heard over the left sternal edge and his chest is clear. A 12-lead ECG shows widespread saddle-shaped ST changes. CXR is unremarkable. A blood sample is sent for D-dimer analysis and is reported as negative. A bedside echocardiogram does not detect any significant abnormality.

What is the most likely diagnosis?

A	Lower respiratory tract infection
B	Myocardial infarction
C	Pulmonary embolism
D	Atypical pneumonia
E	Pericarditis

52341

Submit

A 25-year-old male presents to the Emergency Department complaining of central chest pain which is made worse by coughing and deep inspiration. On examination, he has low-grade pyrexia at 37.9°C. A friction rub is heard over the left sternal edge and his chest is clear. A 12-lead ECG shows widespread saddle-shaped ST changes. CXR is unremarkable. A blood sample is sent for D-dimer analysis and is reported as negative. A bedside echocardiogram does not detect any significant abnormality.

What is the most likely diagnosis?

Your answer was correct

A	Lower respiratory tract infection
B	Myocardial infarction
C	Pulmonary embolism
D	Atypical pneumonia
E	Pericarditis

Explanation

E	Pericarditis

This patient presents with symptoms and signs consistent with a diagnosis of acute pericarditis. The diagnosis can be made based on the triad of chest pain, pericardial friction rub and ECG changes. A common complication of pericarditis is the development of pericardial effusion. This

E Pericarditis

This patient presents with symptoms and signs consistent with a diagnosis of acute pericarditis. The diagnosis can be made based on the triad of chest pain, pericardial friction rub and ECG changes. A common complication of pericarditis is the development of pericardial effusion. This can present as breathlessness. An echocardiogram is used to confirm this and look for evidence of haemodynamic compromise. High dose aspirin or non-steroidal anti-inflammatories is the treatment of choice. A number of viruses including Coxsackie B, mumps and influenza are recognised as possible causes.

A Lower respiratory tract infection

Clear chest on examination, the presence of a pericardial rub and the ECG changes seen make this a less likely diagnosis than pericarditis. For an LRTI significant enough to cause symptoms, one would expect a degree of change on the CXR.

B Myocardial infarction

The pleuritic nature of his chest pain and the widespread nature of his ECG changes make this a less likely diagnosis in this case. Typically, one would expect ECG changes such as ST elevation or depression in the area served by a given coronary territory.

C Pulmonary embolism

The negative D-dimer result makes this diagnosis significantly less likely than the other options here.

D Atypical pneumonia

A 21-year-old student presents to the Emergency Department complaining of palpitations. These started suddenly an hour ago and she describes them as fast and irregular. She has had a couple of short-lived episodes in the past but she has not sought medical advice about them. On examination she is found to have a blood pressure of 105/65 mmHg and a heart rate of 170 beats/min. A 12-lead ECG shows a supraventricular tachycardia with randomly changing QRS width. She is cardioverted and suspected to have Wolff -Parkinson-White syndrome.

Which of the following is the most appropriate long-term management option?

A	Amiodarone
B	Flecainide
C	Mexiletine
D	Bisoprolol
E	Radiofrequency ablation

32343

Submit

A 21-year-old student presents to the Emergency Department complaining of palpitations. These started suddenly an hour ago and she describes them as fast and irregular. She has had a couple of short-lived episodes in the past but she has not sought medical advice about them. On examination she is found to have a blood pressure of 105/65 mmHg and a heart rate of 170 beats/min. A 12-lead ECG shows a supraventricular tachycardia with randomly changing QRS width. She is cardioverted and suspected to have Wolff -Parkinson-White syndrome.

Which of the following is the most appropriate long-term management option?

Your answer was correct

A	Amiodarone
B	Flecainide
C	Mexiletine
D	Bisoprolol
E	Radiofrequency ablation

Explanation

E	Radiofrequency ablation

The best long-term management option for Wolff-Parkinson-White (WPW) syndrome patients is referral for

E Radiofrequency ablation

The best long-term management option for Wolff–Parkinson–White (WPW) syndrome patients is referral for electrophysiological studies and radiofrequency ablation of the accessory pathway. This can be a curative procedure and is therefore preferable to a lifetime of anti-arrhythmic therapy. Out of the medical options given, amiodarone and flecanide have a significant body of evidence in prophylaxis against atrial fibrillation in WPW. Sotalol is another agent that prolongs myocardial refractiveness and may be used in some patients.

A Amiodarone

While amiodarone is a suitable pharmacological option, radiofrequency ablation represents a potentially curative procedure and represents the best long-term management option, particularly given this patient's young age.

B Flecainide

While flecainide is a suitable pharmacological option, radiofrequency ablation offers a potentially curative procedure and represents the best long-term management option, particularly given this patient's young age.

C Mexiletine

It is a class 1b anti-arrythmic which is not currently licensed, but can be obtained from 'special-order' manufacturers and used for life-threatening ventricular arrhythmias.

D Bisoprolol

Drugs which act primarily on the AV node, such as

10:01

A Amiodarone

While amiodarone is a suitable pharmacological option, radiofrequency ablation represents a potentially curative procedure and represents the best long-term management option, particularly given this patient's young age.

B Flecainide

While flecainide is a suitable pharmacological option, radiofrequency ablation offers a potentially curative procedure and represents the best long-term management option, particularly given this patient's young age.

C Mexiletine

It is a class 1b anti-arrythmic which is not currently licensed, but can be obtained from 'special-order' manufacturers and used for life-threatening ventricular arrhythmias.

D Bisoprolol

Drugs which act primarily on the AV node, such as verapamil and adenosine, should be avoided as these may lead to preferential conduction down the accessory pathway and precipitate VF.

32343

Rate this question:

Rana Alnasser's screen

A 42-year-old man with a history of asthma presents to the Emergency Room with palpitations and light-headedness. He has had two previous episodes of asthma which required admission to the Intensive Therapy Unit, and he is currently managed on salmeterol/fluticasone combination therapy 500/50 BD and salbutamol PRN.

On examination he has a pulse of 160/min, with a BP of 89/60 mmHg. There are bibasal crackles on auscultation of the chest. You try the Valsalva manoeuvre, which fails.

Investigations:

Hb	13.4 g/dl
WCC	5.7 $\times 10^9$/l
PLT	301 $\times 10^9$/l
Na^+	139 mmol/l
K^+	4.9 mmol/l
Creatinine	100 µmol/l
ECG	Supraventricular tachycardia, lateral ST depression

Which one of the following is the most appropriate option in this case?

A	IV sotalol
B	IV adenosine
C	DC cardioversion
D	IV verapamil
E	IV amiodarone

WCC	5.7 x10⁹/l
PLT	301 x10⁹/l
Na^+	139 mmol/l
K^+	4.9 mmol/l
Creatinine	100 µmol/l
ECG	Supraventricular tachycardia, lateral ST depression

Which one of the following is the most appropriate option in this case?

Your answer was correct

A IV sotalol

B IV adenosine

C DC cardioversion

D IV verapamil

E IV amiodarone

Explanation

C DC cardioversion

This patient has an episode of paroxysmal SVT and is relatively decompensated, with a systolic of 89 mmHg and bilateral basal crackles. As such, electrical cardioversion is the most appropriate management option.

the most appropriate management option.

A IV sotalol

We are told this patient has a history of asthma, and thus beta blockade is contra-indicated here. We are also told he is relatively decompensated, and therefore electrical cardioversion is the most appropriate management strategy.

B IV adenosine

Adenosine can precipitate bronchoconstriction, and it is contra-indicated in chronic obstructive lung disease (including asthma).

D IV verapamil

This patient is decompensating, with a reduced BP and evidence of pulmonary congestion. While verapamil represents an appropriate choice for chemical cardioversion, the precarious nature of this patient's situation warrants an attempt at rapid cardioversion electrically.

E IV amiodarone

This patient is decompensating, with a reduced BP and evidence of pulmonary congestion. While IV amiodarone represents an appropriate choice for chemical cardioversion, the precarious nature of this patient's situation warrants an attempt at rapid cardioversion electrically. Alternatives to amiodarone include non-dihydropyridine calcium antagonists such as verapamil.

Rate this question:

10:04

You are asked to review a 48-year-old woman who has been treated for hypertension, diabetes managed with diet, well-controlled atrial fibrillation, has had two failed cardioversions, and has a ventricular rate of 75 beats/min. An echocardiogram reveals a structurally normal heart. She is worried about having a stroke. She has no other significant past medical history.

What is the treatment intervention for her?

A Warfarinisation

B Aspirin

C Clopidogrel

D Aspirin and clopidogrel concurrently

E Reassurance

7036

Submit

Previous Q... Skip Questi...

© Pastest 2019

10:06

You are asked to review a 48-year-old woman who has been treated for hypertension, diabetes managed with diet, well-controlled atrial fibrillation, has had two failed cardioversions, and has a ventricular rate of 75 beats/min. An echocardiogram reveals a structurally normal heart. She is worried about having a stroke. She has no other significant past medical history.

What is the treatment intervention for her?

Your answer was correct

A	Warfarinisation
B	Aspirin
C	Clopidogrel
D	Aspirin and clopidogrel concurrently
E	Reassurance

Explanation

A Warfarinisation

NICE guidelines suggest that warfarinisation is the optimal management for patients with persistent atrial fibrillation and who are at risk of embolic stroke according to their algorithm. CHADS2-VASc supports the use of warfarin: with a score of 3, it incorporates female sex, presence of CHF, blood pressure, age, diabetes mellitus and presence of a prior stroke or TIA. ESC guidelines also promote

A Warfarinisation

NICE guidelines suggest that warfarinisation is the optimal management for patients with persistent atrial fibrillation and who are at risk of embolic stroke according to their algorithm. CHADS2-VASc supports the use of warfarin: with a score of 3, it incorporates female sex, presence of CHF, blood pressure, age, diabetes mellitus and presence of a prior stroke or TIA. ESC guidelines also promote progression to warfarin.

B Aspirin

Anti-platelet therapy alone is inadequate to reduce stroke risk versus anti-coagulation in this patient.

C Clopidogrel

Although in a secondary prevention population clopidogrel reduced the absolute risk of major adverse cardiovascular events by 0.5% versus aspirin alone, it's still inferior to anti-coagulation in patients with chronic atrial fibrillation.

D Aspirin and clopidogrel concurrently

The MATCH trial in a high-risk secondary prevention population didn't offer a significant advantage with respect to event prevention versus either agent alone, but did increase the risk of bleeding. Anti-platelet agents are known to be ineffective versus anti-coagulation in patients with chronic AF.

E Reassurance

This patient's CHADS2-vasc score is significantly elevated, driving the need for anti-coagulation.

10:08
594-042-7551
Leave

NC ···
54% 20:08

Score	Risk	Anticoagulation Therapy
0 (male) or 1 (female)	Low	No anticoagulant therapy
1(male)	Moderate	Oral anticoagulant should be considered
2 or greater	High	Oral anticoagulant is recommended

EMNote.org - EMNote

EMNote.org - EMNote

Picture

Images may be subject to copyright. Learn more

RELATED IMAGES

	Condition	Points
C	Congestive heart failure	1
H	Hypertension	1
A_2	Age ≥ 75 years	2
D	Diabetes Mellitus	1
S_2	Prior Stroke or TIA or Thromboembolism	2
V	Vascular disease	1
A	Age 65-74 years	1
Sc	Sex category (female gender)	1

Chads Vasc Calculator | World of Printable a...

Letter	Clinical Characteristic	Score (if present)
C	Congestive heart failure	1
H	Hypertension	1
A	Age 75+	1
D	Diabetes	1
S	Prior Stroke or TIA	2
	Total $CHADS_2$ Score	Maximum score = 6

Atrial Fibrillation - Diagnosis and Manageme...
www2.gov.bc.ca

Comparison of CHADS 2 and CHA 2
researchgate.net

Table 2a: CHADS2

Discover Updates Search Recent More

Audio Video Share Participants More

10:10

A 38-year-old man is admitted with palpitations and an episode of pre-syncope. He had completed a half-marathon for charity that afternoon and had since been drinking beer with friends to celebrate. He estimates that he has consumed some 6–8 pints of lager over the past 5 h. On examination his BP is 110/60 mmHg, with pulse 150/min. His chest is clear, with no signs of left ventricular failure (LVF).

Investigations:

Hb	13.2 g/dl
WCC	8.1 x10^9/l
PLT	200 x10^9/l
Na^+	138 mmol/l
K^+	3.9 mmol/l
Creatinine	110 micromol/l
ECG	Atrial flutter with 2:1 block
CXR	No evidence of cardiomegaly or heart failure

Which of the following is the most appropriate intervention?

A IV flecainide

B IV digoxin

C IV verapamil

D IV amiodarone

E IV esmolol

Rana Alnasser's screen

WCC	8.1 x10⁹/l
PLT	200 x10⁹/l
Na^+	138 mmol/l
K^+	3.9 mmol/l
Creatinine	110 micromol/l
ECG	Atrial flutter with 2:1 block
CXR	No evidence of cardiomegaly or heart failure

Which of the following is the most appropriate intervention?

Your answer was correct

A IV flecainide

B IV digoxin

C IV verapamil

D IV amiodarone

E IV esmolol

Explanation

A IV flecainide

This patient is fit and healthy, with no history of previous ischaemic heart disease or evidence of structural heart disease. As such, pharmacological cardioversion with flecainide is indicated and is associated with the greatest

Explanation

A	IV flecainide

This patient is fit and healthy, with no history of previous ischaemic heart disease or evidence of structural heart disease. As such, pharmacological cardioversion with flecainide is indicated and is associated with the greatest chance of attaining sinus rhythm.

B	IV digoxin

IV digoxin, is less frequently used in clinical practice now. It provides rate control and is a weakly positive inotrope, although it may be associated with increased cardiovascular risk. This has niched its use to the elderly with symptoms despite other interventions. IV digoxin and verapamil achieve rate control rather than attaining sinus rhythm.

C	IV verapamil

IV verapamil, is used for urgent rate control in acute atrial fibrillation (AF) as an alternative to b-blockade. It can also be administered alongside an agent for rhythm control, such as flecainide. A contraindication to its use as monotherapy in this situation is the high likelihood of successful cardioversion

D	IV amiodarone

IV amiodarone, would be the correct agent for pharmacological cardioversion in the presence of structural heart disease, and is indeed an alternative to flecainide even with a structurally normal heart.

IV digoxin, is less frequently used in clinical practice now. It provides rate control and is a weakly positive inotrope, although it may be associated with increased cardiovascular risk. This has niched its use to the elderly with symptoms despite other interventions. IV digoxin and verapamil achieve rate control rather than attaining sinus rhythm.

C IV verapamil

IV verapamil, is used for urgent rate control in acute atrial fibrillation (AF) as an alternative to b-blockade. It can also be administered alongside an agent for rhythm control, such as flecainide. A contraindication to its use as monotherapy in this situation is the high likelihood of successful cardioversion

D IV amiodarone

IV amiodarone, would be the correct agent for pharmacological cardioversion in the presence of structural heart disease, and is indeed an alternative to flecainide even with a structurally normal heart.

E IV esmolol

Esmolol, is a short-acting beta-blocker used in the treatment of paroxysmal supraventricular tachycardia (SVT) such as AF or atrial flutter. Its use is not routinely recommended in this situation where cardioversion may be possible.

Rate this question:

10:18

NC ...

A 45-year-old male is admitted to the coronary care unit with a history of retrosternal chest pain of 1 h duration associated with sweating and nausea. His initial electrocardiogram (ECG) shows ST segment elevation in inferior leads. His blood pressure is 110/60 mmHg, pulse rate 60 beats/min and respiratory rate of 18/min. His chest and cardiac examination is unremarkable. He undergoes urgent PCI with angioplasty and stenting of the right coronary artery. After 3 h the blood pressure recorded is 85/55 mmHg and pulse rate is 88/min. He has low-volume peripheral pulses, jugular venous distension, normal first and second heart sounds and a pansystolic murmur best heard at the left sternal edge. The lung fields are clear to auscultation.

Which of the following is the most useful next investigation for this patient?

A	CT pulmonary angiogram
B	Ventilation/perfusion scan
C	Swan-Ganz catheterisation
D	Echocardiography
E	Repeat troponin

32297

Submit

10:22

A 45-year-old male is admitted to the coronary care unit with a history of retrosternal chest pain of 1 h duration associated with sweating and nausea. His initial electrocardiogram (ECG) shows ST segment elevation in inferior leads. His blood pressure is 110/60 mmHg, pulse rate 60 beats/min and respiratory rate of 18/min. His chest and cardiac examination is unremarkable. He undergoes urgent PCI with angioplasty and stenting of the right coronary artery. After 3 h the blood pressure recorded is 85/55 mmHg and pulse rate is 88/min. He has low-volume peripheral pulses, jugular venous distension, normal first and second heart sounds and a pansystolic murmur best heard at the left sternal edge. The lung fields are clear to auscultation.

Which of the following is the most useful next investigation for this patient?

Your answer was correct

A	CT pulmonary angiogram
B	Ventilation/perfusion scan
C	Swan-Ganz catheterisation
D	Echocardiography
E	Repeat troponin

Explanation

D Echocardiography

Inferior wall myocardial infarction (MI) is associated in one third of cases with right ventricular myocardial infarction

Rana Alnasser's screen

10:22

D Echocardiography

Inferior wall myocardial infarction (MI) is associated in one third of cases with right ventricular myocardial infarction (RVMI). RVMI leads to reduced right ventricle compliance and stroke volume, which in turn leads to reduced left ventricle filling and low cardiac output. VSD or acute mitral regurgitation may lead to a pansystolic murmur, and an echocardiogram will inform most quickly as to the underlying diagnosis. The murmur is most likely to be a function of tricuspid regurgitation secondary to a hypokinetic dilated right ventricle. The most likely diagnosis here is acute tricuspid regurgitation due to right ventricular dilatation.

A CT pulmonary angiogram

Pulmonary embolism (PE) can also have similar physical findings: jugular venous distension, hypotension and clear lung fields. A PE might be seen in the setting of an acute MI, but would be more usual during the recovery period, particularly when patients take a few days to mobilise.

B Ventilation/perfusion scan

There is a very low probability of a PE occurring in the setting of an acute MI, and these symptoms are more likely to be due to a right ventricular infarct.

C Swan-Ganz catheterisation

Swan-Ganz catheterisation may be useful in predicting requirements for fluid replacement and guiding any use of inotropes, although in the first instance an ECHO is more important to confirm the underlying diagnosis.

Rana Alnasser's screen

A 34-year-old patient is admitted with an episode of cardiac chest pain lasting 40 minutes, which resolved just before admission. He has a history of coarctation of the aorta, which was repaired some years ago. He has been well since this time, taking minimal medication for the treatment of hypertension. He is haemodynamically stable with a blood pressure (BP) of 115/70 mmHg and a pulse of 75 bpm.

Investigations:

Hb	12.1 g/dl
WCC	5.0×10^9/l
PLT	230×10^9/l
Na^+	139 mmol/l
K^+	4.5 mmol/l
Creatinine	120 µmol/l
ECG	No acute changes
Chest X-ray	unremarkable

Which of the following is the most appropriate initial course of action?

A Trans-oesophageal echocardiogram

B 3 h high-sensitivity troponin

C Discharge

D Exercise tolerance test

E CT Thorax

WCC	5.0×10^9/l
PLT	230×10^9/l
Na^+	139 mmol/l
K^+	4.5 mmol/l
Creatinine	120 µmol/l
ECG	No acute changes
Chest X-ray	unremarkable

Resp
Resp
Resp
Resp

Which of the following is the most appropriate initial course of action?

Your answer was correct

A Trans-oesophageal echocardiogram

B 3 h high-sensitivity troponin

C Discharge

D Exercise tolerance test

E CT Thorax

Explanation

B 3 h high-sensitivity troponin

Due predominantly to changes in blood flow after coarctation repair, patients may suffer accelerated coronary artery disease quite late after surgery. As such, given that the pain has now gone and the ECG shows no acute changes, this patient should at least be observed

B 3 h high-sensitivity troponin

Due predominantly to changes in blood flow after coarctation repair, patients may suffer accelerated coronary artery disease quite late after surgery. As such, given that the pain has now gone and the ECG shows no acute changes, this patient should at least be observed until a 3 h troponin is available. Other possibilities include late presenting re-coarctation; as such, if the troponin is normal, this patient may well progress to angiography anyway.

A Trans-oesophageal echocardiogram

While it may prove appropriate to perform a TOE later in this patient's work-up, it would not be the most appropriate initial test and may not be required if a TTE were to prove diagnostic.

C Discharge

This patient has presented with acute chest pain in the context of previous surgery. Despite the resolution of his symptoms, it would be appropriate to undertake a period of investigation and perform a troponin.

D Exercise tolerance test

While it may prove appropriate to perform an ETT later in the course of this patient's work-up, it would not prove the most valuable initial test.

E CT Thorax

While it may prove appropriate to perform a CT thorax to rule out re-coarctation, it would seem prudent to await a troponin prior to considering further imaging. There is

10:28

MyPastest
https://mypastest.pastest.com

coronary artery disease quite late after surgery. As such, given that the pain has now gone and the ECG shows no acute changes, this patient should at least be observed until a 3 h troponin is available. Other possibilities include late presenting re-coarctation; as such, if the troponin is normal, this patient may well progress to angiography anyway.

A Trans-oesophageal echocardiogram

While it may prove appropriate to perform a TOE later in this patient's work-up, it would not be the most appropriate initial test and may not be required if a TTE were to prove diagnostic.

C Discharge

This patient has presented with acute chest pain in the context of previous surgery. Despite the resolution of his symptoms, it would be appropriate to undertake a period of investigation and perform a troponin.

D Exercise tolerance test

While it may prove appropriate to perform an ETT later in the course of this patient's work-up, it would not prove the most valuable initial test.

E CT Thorax

While it may prove appropriate to perform a CT thorax to rule out re-coarctation, it would seem prudent to await a troponin prior to consideration of further imaging. There is no suggestion from this patient's history of dissection, etc, that would warrant urgent imaging.

Rana Alnasser's screen

10:28

A 72-year-old woman who has known biventricular failure and left atrial dilatation on ECG, COPD and peripheral vascular disease is admitted in fast AF with a ventricular rate of 154/min. In view of low chances of successful chemical cardioversion you elect to begin treatment with digoxin. You load her with 500 micrograms digoxin IV and then a further 250 micrograms over 6 h. On examination her BP is 132/72 mmHg, her heart rate is now 128/min and she feels well.

Investigations:

Hb	12.8 g/dl
WCC	4.9 x10^9/l
PLT	206 x10^9/l
Na^+	141 mmol/l
K^+	4.9 mmol/l
Creatinine	132 µmol/l

What is the most appropriate option with respect to her digoxin dosing?

A	Stop the digoxin and commence metoprolol
B	Initiate digoxin 125micrograms PO OD
C	Give a further loading dose of digoxin 250 micrograms IV
D	Add amiodarone 200 mg TDS to the regimen
E	Give a further loading dose of digoxin 500 micrograms IV

Rana Alnasser's screen

C Give a further loading dose of digoxin 250 micrograms IV

Digoxin helps control ventricular rate in atrial fibrillation through competitive blockade of the K^+ site on the Na^+/K^+ ATPase. This slows conduction through the AV node. Digoxin has a high volume of distribution and long half-life (36-48 h), which means that loading doses are required to allow the drug to reach a steady-state concentration more quickly. Although this patient has symptomatically improved, her heart rate remains elevated and a further loading dose of digoxin is required.

B Initiate digoxin 125micrograms PO OD

Digoxin has a high volume of distribution and a long half-life (36-48 h). In this patient the half-life is likely to be further elongated due to her renal dysfunction. If initiated on a maintenance dose of digoxin at this point, it will take several days to reach a steady state. Digoxin dose should be titrated to heart rate in atrial fibrillation; this patient's heart rate remains elevated and it is likely that the plasma concentration of digoxin remains insufficient. As such, a further loading dose is required.

A Stop the digoxin and commence metoprolol

Metoprolol is a beta-blocker which can be used for rate control of atrial fibrillation in some patients. This patient has a background of COPD; the use of a beta-blocker in this group may exacerbate her COPD and reduce the effectiveness of salbutamol reliever inhalers. Metoprolol is a beta-1 selective antagonist and has a quite low incidence of causing bronchospasm. However, given this patient also has heart failure, digoxin probably is a better choice - especially since she has already been started on it. The dose should be optimised prior to changing therapy.

further loading dose is required.

A	Stop the digoxin and commence metoprolol

Metoprolol is a beta-blocker which can be used for rate control of atrial fibrillation in some patients. This patient has a background of COPD; the use of a beta-blocker in this group may exacerbate her COPD and reduce the effectiveness of salbutamol reliever inhalers. Metoprolol is a beta-1 selective antagonist and has a quite low incidence of causing bronchospasm. However, given this patient also has heart failure, digoxin probably is a better choice - especially since she has already been started on it. The dose should be optimised prior to changing therapy.

D	Add amiodarone 200 mg TDS to the regimen

The main role of amiodarone in the management of atrial fibrillation is through chemical cardioversion to sinus rhythm. This is unlikely to occur in a patient with significant left atrial dilatation. Furthermore, the use of amiodarone in conjunction with digoxin can increase the plasma levels of digoxin (by impairing renal digoxin clearance), which will already be elevated in this patient with reduced renal function.

E	Give a further loading dose of digoxin 500 micrograms IV

A further loading dose of digoxin is required. Digoxin is almost exclusively renally cleared; as a result, this patient's renal impairment will significantly alter the half-life of this medication. Given the significant benefit the patient has already obtained from the current doses and the narrow therapeutic range of digoxin, the use of a 250 microgram loading dose is the more appropriate option.

10:39

A 78-year-old man attends the Emergency Department complaining of palpitations. He describes these as fast and regular, and of sudden onset and termination. He describes a particularly bad episode when he almost lost consciousness. He knows he is on warfarin 'to thin the blood' but is unsure about the rest of his medications. He says that in the past he has suffered from an irregular heartbeat, and that he has recently been prescribed a course of antibiotics for a chest infection. He is allergic to penicillin, smokes 10 a day and drinks very occasionally. He denies any recent alcohol binges.

On examination he appears comfortable, with a heart rate of 85 beats/min and a blood pressure of 144/89 mmHg. His heart sounds are normal and his chest is clear.

A 12-lead electrocardiogram (ECG) shows sinus rhythm with normal QRS complexes. The PR interval is 0.16 s and the QTc interval is 0.52 s.

Investigations:

Hb	14.1 g/dl
WCC	9.6×10^9/l
PLT	253×10^9/l
Na^+	138 mmol/l
K^+	4.2 mmol/l
Urea	4.7 mmol/l
Creatinine	103 µmol/l
TSH	3 mU/l

Which one of the following is most likely to account for the ECG findings in this case?

A Amoxicillin

B Ciprofloxacin

Rana Alnasser's screen

On examination he appears comfortable, with a heart rate of 85 beats/min and a blood pressure of 144/89 mmHg. His heart sounds are normal and his chest is clear.
A 12-lead electrocardiogram (ECG) shows sinus rhythm with normal QRS complexes. The PR interval is 0.16 s and the QTc interval is 0.52 s.

Investigations:

Hb	14.1 g/dl
WCC	9.6×10^9/l
PLT	253×10^9/l
Na^+	138 mmol/l
K^+	4.2 mmol/l
Urea	4.7 mmol/l
Creatinine	103 μmol/l
TSH	3 mU/l

Which one of the following is most likely to account for the ECG findings in this case?

A Amoxicillin

B Ciprofloxacin

C Doxycycline

D Erythromycin

E Cephalexin

D Erythromycin

This gentleman has QT prolongation and he is at risk of atypical ventricular tachycardia (VT) (torsades de pointes). Although there are some rare congenital causes of long-QT syndrome, these are unlikely to present so late in life and it is most likely that this is iatrogenic in origin. Out of the antibiotics described, erythromycin is recognised to result in long-QT syndrome. Other drugs causing a long QT include anti-arrhythmics (amiodarone, procainamide, disopyramide, quinidine, sotolol and bretylium), psychotropics (phenothiazines, tricyclic antidepressants, lithium and haloperidol), quinine, tacrolimus and cisapride.

A Amoxicillin

Amoxicillin is not associated with cardiovascular adverse events and, given this patient's penicillin allergy, would not have been prescribed.

B Ciprofloxacin

From the cardiovascular point of view, the main concern with respect to ciprofloxacin use in the frail elderly is its interference with theophylline metabolism that can precipitate potentially life-threatening hypokalaemia.

C Doxycycline

Doxycycline is not associated with rhythm disorders. It is associated with gastro-oesophageal reflux, which can lead to tolerability issues for some patients.

E Cephalexin

Cefalexin is well tolerated and is not associated with increased risk of cardiac rhythm disorders.

A 55-year-old male is referred by his general practitioner for evaluation of syncope, which occurred during his brisk morning walk. The patient is known to have hypercholesterolaemia and is taking simvastatin 20 mg OD. He is a lifelong non-smoker and has no family history of coronary artery disease. On further questioning he admits to passing out on two previous occasions over the past 3 months. He weighs 72 kg and his height is 170 cm. His blood pressure (BP) is 110/90 mmHg, carotid pulse is slow rising and apex beat is palpable at the 5th intercostal space. The first heart sound is normal, the second heart sound is soft; there is an ejection systolic murmur at the 2nd right intercostal space, radiating to both carotids.

Investigations:

Total cholesterol	6.4 mmol/l
Low-density lipoprotein (LDL)	3.8 mmol/l
High-density lipoprotein (HDL)	1.05 mmol/l

Electrocardiogram (ECG) reveals left ventricular hypertrophy. Chest X-ray is unremarkable. Echocardiogram reveals mean aortic valve area of 0.5 cm^2 and peak transvalvular gradient of 80 mmHg.

What is the next step in this patient's management?

A Percutaneous aortic balloon valvulotomy

B Aortic valve replacement

C Treadmill stress test

D Coronary angiography

E Start an ACE inhibitor

10:46

2nd right intercostal space, radiating to both carotids.

Investigations:

Total cholesterol	6.4 mmol/l
Low-density lipoprotein (LDL)	3.8 mmol/l
High-density lipoprotein (HDL)	1.05 mmol/l

Electrocardiogram (ECG) reveals left ventricular hypertrophy. Chest X-ray is unremarkable. Echocardiogram reveals mean aortic valve area of 0.5 cm^2 and peak transvalvular gradient of 80 mmHg.

What is the next step in this patient's management?

Your answer was correct

A Percutaneous aortic balloon valvulotomy

B Aortic valve replacement

C Treadmill stress test

D Coronary angiography

E Start an ACE inhibitor

Explanation

D Coronary angiography

This patient has severe symptomatic (syncope) aortic stenosis (AS) as shown by the mean aortic valve area of 0.5 cm^2 and mean peak transvalvular gradient of 80 mmHg. All symptomatic patients with severe AS should

Rana Alnasser's screen

D Coronary angiography

This patient has severe symptomatic (syncope) aortic stenosis (AS) as shown by the mean aortic valve area of 0.5 cm^2 and mean peak transvalvular gradient of 80 mmHg. All symptomatic patients with severe AS should undergo aortic valve replacement, as prognosis without surgery is poor. Coronary artery disease (CAD) is common in patients with AS and this patient's age, sex and hypercholesterolaemia put him at risk of CAD. Therefore he should undergo cardiac angiography to assess the need for revascularisation at the time of surgery, in the form of coronary artery bypass grafting.

A Percutaneous aortic balloon valvulotomy

Balloon valvotomy is inferior with respect to outcomes versus surgical valve replacement. It may be considered as a bridge to surgery in unstable patients.

B Aortic valve replacement

Progressing straight to aortic valve replacement is not advised; significant coronary artery disease should be ruled out first, as CABG may be required at the same time as valve replacement.

C Treadmill stress test

In a patient with severe aortic stenosis, a treadmill stress test may precipitate a syncopal episode and should therefore be avoided.

E Start an ACE inhibitor

This risks a significant reduction in ventricular filling pressure and increases the risk of collapse.

A 72-year-old woman is admitted to the Emergency Department after collapsing in church; this is her second such episode in the last year. A parishioner who felt her neck at the time reports that the woman was pulseless for a few seconds. She quickly recovers on admission to the department and is discharged home. Holter monitor and MIBI (2-methoxyisobutyl isonitrile) scan as an outpatient are unremarkable. You arrange a tilt-table test, during which carotid sinus massage results in a 4 s asystolic episode with syncope.

What is the best choice for management of this patient?

A	Fludrocortisone
B	Single-chamber pacemaker
C	Dual-chamber pacemaker
D	Compression stockings
E	Midodrine

7032

Submit

A 72-year-old woman is admitted to the Emergency Department after collapsing in church; this is her second such episode in the last year. A parishioner who felt her neck at the time reports that the woman was pulseless for a few seconds. She quickly recovers on admission to the department and is discharged home. Holter monitor and MIBI (2-methoxyisobutyl isonitrile) scan as an outpatient are unremarkable. You arrange a tilt-table test, during which carotid sinus massage results in a 4 s asystolic episode with syncope.

What is the best choice for management of this patient?

Your answer was incorrect

A Fludrocortisone

B Single-chamber pacemaker

C Dual-chamber pacemaker

D Compression stockings

E Midodrine

Explanation

C Dual-chamber pacemaker

This patient has carotid sinus hypersensitivity, demonstrating an exaggerated response to carotid sinus stimulation. The diagnosis is only made after ischaemic heart disease or rhythm disturbance have been reasonably

C Dual-chamber pacemaker

This patient has carotid sinus hypersensitivity, demonstrating an exaggerated response to carotid sinus stimulation. The diagnosis is only made after ischaemic heart disease or rhythm disturbance have been reasonably excluded, as in this case. CSH may be predominantly cardio-inhibitory (the most common form, resulting in bradycardia), predominantly vasodepressor (resulting in hypotension with a drop in blood pressure ≥50 mmHg) or a mixture of the two.

ESC guidelines recommend insertion of a dual-chamber pacemaker for those with dominant cardio-inhibitory carotid sinus syndrome (Class 1B), but this has no effect on the vasodepressor component of carotid sinus hypersensitivity.

Vasodilatory CSH is can be managed with support stockings, fludrocortisone and midodrine, though no agent has been definitively proven to provide benefit in this patient group.

B Single-chamber pacemaker

In the case of cardio-inhibitory carotid sinus hypersensitivity, dual-chamber pacing is the recommended management option.

A Fludrocortisone

In the case of cardioinhibitory carotid sinus hypersensitivity, dual-chamber pacing is the recommended management option. Fludrocortisone can be trialled as a management option in vasodepressor-type carotid sinus hypersensitivity.

D Compression stockings

10:51

Google

chamber pacemaker

ES SHOPPING VIDEOS NEWS MAPS BOOKS FLIGHTS TABL

F HD Product

ay ecg cxr temporary single chambe

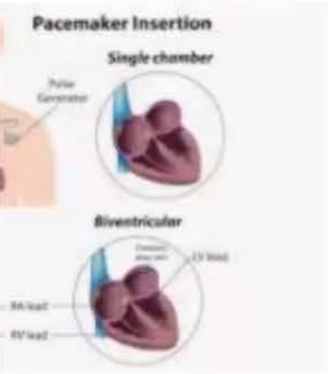

ation - Why it's ...

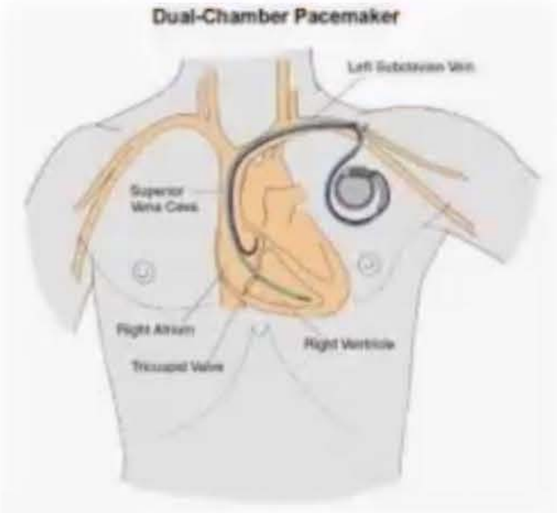

Dual-Chamber Pacemaker commonly treats ...
pinterest.co.uk

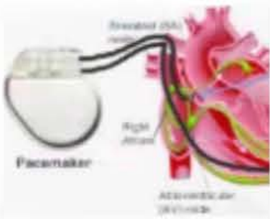

dual chamber pacema
researchgate.net

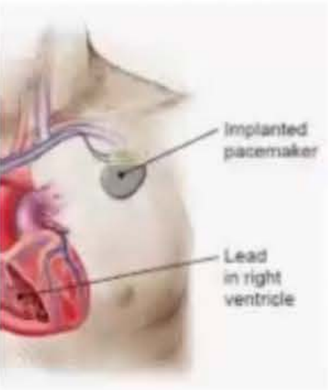

Vork - Boston Scientific

Dual-chamber pacema
researchgate.net

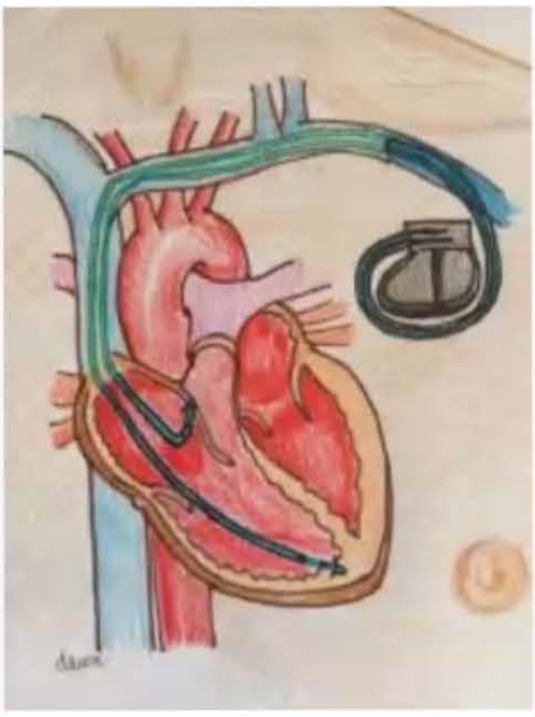

Dual chamber pacemaker illustration ...
ecgguru.com

Pacemaker Double Ch
indiamart.com

apture Draw Crop

Rana Alnasser's screen

10:51
594-042-7551
Leave
MyPastest
https://mypastest.pastest.com

hypersensitivity, dual-chamber pacing is the recommended management option. Fludrocortisone can be trialled as a management option in vasodepressor-type carotid sinus hypersensitivity.

D Compression stockings

In the case of cardio-inhibitory carotid sinus hypersensitivity, dual-chamber pacing is the recommended management option. Compression stockings can be trialled in patients with vasodepressor carotid sinus hypersensitivity.

E Midodrine

In the case of cardio-inhibitory carotid sinus hypersensitivity, dual-chamber pacing is the recommended management option. Midodrine can be trialled in patients with vasodepressor carotid sinus hypersensitivity.

Rate this question:

Next Question

Previous Q... Tag Questi... Feedback End Session

Blog About Pastest Contact Us Help

© Pastest 2019

Audio Video Share Participants More

10:51

You are called to a cardiac arrest on the Orthopaedic Ward. A 70-year-old man is 5 days post-left total hip replacement and has collapsed on the toilet.

When you arrive, basic life support is in progress and defibrillator pads are attached. These show pulseless ventricular tachycardia (VT). He undergoes 6 minutes of cardiopulmonary resuscitation (CPR) with three defibrillator shocks. He is given adrenaline and a bolus of intravenous (IV) fluid. Spontaneous circulation returns, although his blood pressure is measured at 80/60 mmHg and pulse 110 bpm.

He still requires ventilatory support and is intubated and ventilated before transfer to the Intensive Therapy Unit (ITU) with 50% oxygen. His chest appears clear on auscultation.

Investigations:

Haemoglobin (Hb)	11.2 g/dl
White cell count (WCC)	6.1×10^9/l
Platelets (PLT)	201×10^9/l
Sodium (Na)	137 mmol/l
Potassium (K)	4.3 mmol/l
Creatinine	110 μmol/l
$p(O_2)$	9.1 kPa
$p(CO_2)$	5.6 kPa
Portable chest X-ray	Endotracheal tube in position, no signs of heart failure

Which of the following is the most appropriate next step?

Rana Alnasser's screen

observe for 12 hours

He still requires ventilatory support and is intubated and ventilated before transfer to the Intensive Therapy Unit (ITU) with 50% oxygen. His chest appears clear on auscultation.

Investigations:

Haemoglobin (Hb)	11.2 g/dl
White cell count (WCC)	6.1×10^9/l
Platelets (PLT)	201×10^9/l
Sodium (Na)	137 mmol/l
Potassium (K)	4.3 mmol/l
Creatinine	110 µmol/l
$p(O_2)$	9.1 kPa
$p(CO_2)$	5.6 kPa
Portable chest X-ray	Endotracheal tube in position, no signs of heart failure

Which of the following is the most appropriate next step?

A Inotropic support and observe for 12 hours

B Portable echocardiography on the ITU

C Thrombolysis

D Coronary angiography

E Computerised tomography pulmonary angiogram (CTPA)

B Portable echocardiography on the ITU

This patient has had a cardiac arrest following an orthopaedic procedure. Following return of circulation and ventilator support, this patient's $p(O_2)$ remains low. Given this clinical scenario, the most likely diagnosis is a large pulmonary embolism (PE), likely occupying the bifurcation of the pulmonary trunk (a 'saddle' PE). Direct visualisation of the PE may be possible on an echocardiogram, and if not directly visualised, right ventricular dysfunction is likely to provide significant support for this diagnosis. If the clinical suspicion for PE remains high following an echocardiogram, thrombolysis would be appropriate in this patient.

C Thrombolysis

This clinical scenario strongly supports the presence of a large 'saddle' PE, and thrombolysis may well be beneficial if this diagnosis is correct. However, it is important to note that the patient is only 5 days post-operative from an orthopaedic procedure. As such, his risk for bleeding is high, and the diagnosis should be further investigated before thrombolysis is employed. If return of circulation had not been reached, then urgent thrombolysis without further investigation may have been appropriate.

A Inotropic support and observe for 12 hours

Inotropic support may be necessary to maintain blood pressure. However, this does not deal with any underlying diagnosis that has caused a cardiac arrest in this post-operative patient. It may be necessary, but it is not the most appropriate next step.

D Coronary angiography

This patient is haemodynamically compromised and would

most appropriate next step.

D	Coronary angiography

This patient is haemodynamically compromised and would be unsuitable for transfer from the ITU at this time. Additionally, the underlying diagnosis points towards a large PE, based on the clinical history and arterial blood gas, rather than an acute coronary event. If further investigation does not support a diagnosis of PE, then this investigation should be reconsidered once the patient is stabilised.

E	Computerised tomography pulmonary angiogram (CTPA)

CTPA is a first-line investigation for PE in most patient groups. However, this would require transfer to Radiology and for the patient to be placed in a small CT scanner. There is a high risk for a further cardiac arrest or deterioration acutely in this patient and, as such, this would not be an appropriate initial investigation at this time.

Rate this question:

Next Question

Previous Q... Tag Questi... Feedback End Session

Blog About Pastest Contact Us Help

© Pastest 2019

11:00

MyPastest
https://mypastest.pastest.com

Pastest+

A 66-year-old man was admitted to Coronary Care 2 days ago following an anterior myocardial infarction. He was successfully re-perfused with thrombolysis prior to arrival and has been pain free since admission. Aspirin, atenolol, ramipril, atorvastatin and prophylactic low-molecular weight heparin have been started. His latest ECG shows Q waves across the anterior chest leads.
You are fast-bleeped to coronary care and on arrival the sister tells you that the patient has suddenly become extremely breathless, but has had no chest pain. He is hypotensive and tachycardic – blood pressure is 80/60 mmHg and heart rate 138 beats/min. Looking through his admission notes there is nil of note on examination and his chest X-ray showed only minimal basal pleural effusions.

On examination, he looks unwell and feels clammy to touch, his jugular venous pressure is elevated and the apex beat is diffuse but not displaced. The heart sounds are difficult to hear, but there is no overt murmur. There is very little to find on respiratory examination other than tachypnoea. He has passed 500 ml of urine over the last 10 h.

You request an urgent ECG, which shows Q waves in the anterior chest leads but no evidence of acute ischaemia. There appears to be electrical alternans in the rhythm strip.

What is the most appropriate management option?

A	Give 50 mg IV furosemide and organise an urgent chest X-ray
B	Start intravenous inotropes
C	Immediate cardioversion with 200J synchron shock

You are fast-bleeped to coronary care and on arrival the sister tells you that the patient has suddenly become extremely breathless, but has had no chest pain. He is hypotensive and tachycardic – blood pressure is 80/60 mmHg and heart rate 138 beats/min. Looking through his admission notes there is nil of note on examination and his chest X-ray showed only minimal basal pleural effusions.

On examination, he looks unwell and feels clammy to touch, his jugular venous pressure is elevated and the apex beat is diffuse but not displaced. The heart sounds are difficult to hear, but there is no overt murmur. There is very little to find on respiratory examination other than tachypnoea. He has passed 500 ml of urine over the last 10 h.

You request an urgent ECG, which shows Q waves in the anterior chest leads but no evidence of acute ischaemia. There appears to be electrical alternans in the rhythm strip.

What is the most appropriate management option?

A	Give 50 mg IV furosemide and organise an urgent chest X-ray
B	Start intravenous inotropes
C	Immediate cardioversion with 200J synchronised shock
D	Intra-aortic balloon pump insertion
E	Pericardiocentesis

7579

Submit

E Pericardiocentesis

The diagnosis is cardiac tamponade, a known complication of an acute myocardial infarction. The clues in this question are sudden onset of breathlessness with clear lung fields, cardiogenic shock and electrical alternans, consistent with ventricular rupture. In this case the patient is shocked and needs haemodynamic support, but the definitive treatment is drainage of the pericardial sac with emergency ventricular repair. An aortic balloon pump is often used in conjunction with inotropes and colloid replacement to stabilise the patient before a pericardiocentesis takes place.

A Give 50 mg IV furosemide and organise an urgent chest X-ray

IV furosemide would be the treatment of choice for pulmonary oedema and his blood pressure precludes this.

B Start intravenous inotropes

While inotropes such as dopamine and dobutamine can be used as stabilising agents, they do not represent the definitive management in cases of cardiac tamponade.

C Immediate cardioversion with 200J synchronised shock

Electrical alternans does not represent a shockable arrhythmia; this is a rare phenomenon seen in cases of pericardial effusion in which consecutive QRS complexes alternate in height or direction, and is related to movement of the heart within a fluid-filled pericardial sac.

D Intra-aortic balloon pump insertion

11:06
594-042-7551
Leave

A Give 50 mg IV furosemide and organise an urgent chest X-ray

IV furosemide would be the treatment of choice for pulmonary oedema and his blood pressure precludes this.

B Start intravenous inotropes

While inotropes such as dopamine and dobutamine can be used as stabilising agents, they do not represent the definitive management in cases of cardiac tamponade.

C Immediate cardioversion with 200J synchronised shock

Electrical alternans does not represent a shockable arrhythmia; this is a rare phenomenon seen in cases of pericardial effusion in which consecutive QRS complexes alternate in height or direction, and is related to movement of the heart within a fluid-filled pericardial sac.

D Intra-aortic balloon pump insertion

While a balloon pump may be considered as a stabilising measure, it does not represent the definitive management in cases of cardiac tamponade.

Rate this question:

Audio Video Share Participants More

11:06

A 72-year-old male presents with a history of passage of two black tarry stools over the last day. He is known to have idiopathic dilated cardiomyopathy and his current medications include lisinopril 20 mg/day, furosemide 40 mg twice daily, carvedilol 12.5 mg twice daily and warfarin 3 mg/day. He has never had any rhythm disturbances, stroke or history of venous or arterial thromboembolism. He has not used any painkillers recently, but admits to drinking 5-8 pints of beer per day. Other recent history includes two admissions to the casualty unit after falls. His last echocardiography 3 months ago revealed global hypokinesia and an ejection fraction of 18%. Physical examination shows blood pressure 98/48 mmHg, pulse 110/min and respiratory rate 18/min. There is no jugular venous distension, and lung fields are clear to auscultation. Per rectal examination reveals black stool.

Investigations:

Hb	11 g/dl
Platelets	155×10^9/l
International normalised ratio (INR)	2.8
Electrocardiogram (ECG)	Sinus tachycardia
Chest X-ray	Cardiomegaly with clear lung fields

He is administered intravenous fluids, vitamin K and fresh-frozen plasma. An upper gastrointestinal endoscopy shows a clean-based duodenal ulcer and no active bleeding. Biopsy specimen for Helicobacter pylori is positive. The patient recovers well and is begun on eradication therapy for H. pylori.

What is the most appropriate step in managing the anticoagulation in this patient?

Rana Alnasser's screen

A. Restart warfarin therapy after confirming

venous distension, and lung fields are clear to auscultation. Per rectal examination reveals black stool.

Investigations:

Hb	11 g/dl
Platelets	155 × 10^9/l
International normalised ratio (INR)	2.8
Electrocardiogram (ECG)	Sinus tachycardia
Chest X-ray	Cardiomegaly with clear lung fields

He is administered intravenous fluids, vitamin K and fresh-frozen plasma. An upper gastrointestinal endoscopy shows a clean-based duodenal ulcer and no active bleeding. Biopsy specimen for Helicobacter pylori is positive. The patient recovers well and is begun on eradication therapy for H. pylori.

What is the most appropriate step in managing the anticoagulation in this patient?

A Restart warfarin therapy after confirming eradication of *H. pylori* with a target INR of 1.5-2.0

B Restart warfarin therapy after one month with a target INR of 1.5 to 2

C Restart warfarin therapy after one month with a target INR of 2-3

D Restart warfarin therapy after confirming eradication of *H. pylori* with a target INR 2-3

E Do not restart warfarin

11:11

MyPastest
https://mypastest.pastest.com

A 72-year-old male presents with a history of passage of two black tarry stools over the last day. He is known to have idiopathic dilated cardiomyopathy and his current medications include lisinopril 20 mg/day, furosemide 40 mg twice daily, carvedilol 12.5 mg twice daily and warfarin 3 mg/day. He has never had any rhythm disturbances, stroke or history of venous or arterial thromboembolism. He has not used any painkillers recently, but admits to drinking 5-8 pints of beer per day. Other recent history includes two admissions to the casualty unit after falls. His last echocardiography 3 months ago revealed global hypokinesia and an ejection fraction of 18%. Physical examination shows blood pressure 98/48 mmHg, pulse 110/min and respiratory rate 18/min. There is no jugular venous distension, and lung fields are clear to auscultation. Per rectal examination reveals black stool.

A
B
C
D
E

Investigations:

Hb	11 g/dl
Platelets	155×10^9/l
International normalised ratio (INR)	2.8
Electrocardiogram (ECG)	Sinus tachycardia
Chest X-ray	Cardiomegaly with clear lung fields

He is administered intravenous fluids, vitamin K and fresh-frozen plasma. An upper gastrointestinal endoscopy shows a clean-based duodenal ulcer and no active bleeding. Biopsy specimen for Helicobacter pylori is positive. The patient recovers well and is begun on eradication therapy

Rana Alnasser's screen

E Do not restart warfarin

The objective of this question is to know the indications of anticoagulation in patients with heart failure. Anticoagulation should be considered for patients with heart failure and a low ejection fraction, particularly in those who have any of the following:

- A previous thromboembolic event
- Intracardiac thrombus
- Left ventricular aneurysm

He does, however, admit to relatively significant alcohol use, and two admissions to the casualty unit with falls, and therefore the benefit risk profile of warfarin use means it is probably not appropriate to continue therapy in this case, although the falls themselves may have been related to LV dysfunction/rhythm disturbance.

D Restart warfarin therapy after confirming eradication of *H. pylori* with a target INR 2-3

Due to the alcohol use and recurrent falls, restarting warfarin is high risk in this scenario.

A Restart warfarin therapy after confirming eradication of *H. pylori* with a target INR of 1.5-2.0

Due to the alcohol use and recurrent falls, restarting warfarin is high risk in this scenario.

B Restart warfarin therapy after one month with a target INR of 1.5 to 2

Scroll capture Draw

10:01

You review a 52-year-old farmer who rarely consults with medical services. He complains of ocular pain and loss of vision. High magnification slit lamp examination reveals neovascular tufts of capillaries at the pupillary margin. The pupil is poorly reactive. Retinal photography reveals bilateral cotton wool spots, hard exudates, aneurysms and small dot-and-blot haemorrhages. He has a past history of diabetes and hypothyroidism. You suspect rubeosis iridis and subsequent glaucoma. His blood pressure is 135/82 mmHg. The most recent HbA1c is measured at 61 mmol/mol, and his TSH is 2.5.

Which of the following is the most important preventative intervention to reduce the risk of glaucoma in this patient?

A	Tighter control of blood pressure
B	Tighter control of blood glucose
C	Increased thyroxine dose
D	Pan-retinal photocoagulation
E	Oral acetazolamide

Submit

Previous Q... Skip Questi...

Rana Alnasser's screen

Explanation

D Pan-retinal photocoagulation

An important part of the work-up of rubeosis iridis is with fluorescein angiography to assess the extent of retinal ischaemia, and ultrasound. Once eye disease has progressed to rubeosis, the mainstay of therapy is pan-retinal photocoagulation to reduce the area of viable retina. Anti-VEGF agents and topical steroids may also be of value, but ultimately the prognosis is poor because of late stage at presentation.

B Tighter control of blood glucose

HbA1c, like blood pressure, is only slightly above target, hence any impact of tightening of blood glucose control on disease progression will be limited.

A Tighter control of blood pressure

There is limited scope to further improve blood pressure control here, and the patient already has advanced retinal disease, meaning any impact of improved blood pressure control on disease progression will be limited.

C Increased thyroxine dose

TSH is in the normal range, meaning there is gain to be had from increasing thyroxine.

E Oral acetazolamide

This is a potential intervention for acute glaucoma.

Rate this question:

A 28-year-old single man with type 1 diabetes presents for review. His HbA1c is 50.82 mmol/mol (6.8%) yet he is concerned that morning sugars are occasionally as high as 24 mmol/l. He is also suffering from frequent nightmares.

He is currently managed on a basal bolus insulin regime. His blood pressure is 112/82, with pulse 67 and regular. Creatinine is normal and he has 1+ of protein on urine testing.

Which of the following is most appropriate for his further management?

A	Increase his nocturnal dose of long-acting insulin
B	Switch his nocturnal long-acting insulin to morning dosing
C	Divide his nocturnal long-acting insulin into morning and evening doses
D	Add in an extra dose of short-acting insulin with a snack at 10 pm
E	Arrange for continuous glucose monitoring

52906

E Arrange for continuous glucose monitoring

His long-term blood glucose control is excellent, and his occasional high morning sugars are suggestive of the Somogyi effect, related to nocturnal hypoglycaemia, reactive release of counter-regulatory hormones such as adrenaline and rebound hyperglycaemia. Continuous glucose monitoring would be useful in producing a 72 h profile of glucose excursions to rule out nocturnal hypoglycaemia. In the event that a significant problem with morning dipping in glucose is revealed, then his long-acting insulin dose will require a reduction, as may his short-acting evening insulin dose.

See also *The Lancet* 1980, Gale *et al.*, 316(8189):279-282.

C Divide his nocturnal long-acting insulin into morning and evening doses

Steady state dosing and long-half-life insulin mean that there is only a minor impact on blood glucose levels from splitting the dose.

A Increase his nocturnal dose of long-acting insulin

Until nocturnal hypoglycaemia is excluded, increasing his nocturnal dose of long-acting insulin risks life-threatening hypoglycaemia.

B Switch his nocturnal long-acting insulin to morning dosing

Modern long-acting insulin analogues should not have a significant variance in their effect if they are dosed in the morning or the evening, because of their long half-life and ability to reach steady state. As such, there is no value in switching the timing of the dose.

A 52-year-old electrician is referred to the Outpatient Clinic complaining of pain in his feet and difficulty in walking. On more detailed questioning, he reports noticing numbness over the soles of his feet for the past 10 months. He has been troubled by a 'pins and needles' sensation and, more recently, burning pains in both his feet. He also reports that his legs 'seem weaker' and that his walking has become increasingly unsteady such that he has recently given up work.

He takes no regular prescription medications, although he has been purchasing increasing quantities of painkillers from the supermarket for symptom relief. He has smoked 20 cigarettes a day for the past 35 years and admits to spending more time in the pub since giving up work.

Examination reveals symmetrical distal sensory loss in the lower limbs. Ankle reflexes are absent even with reinforcement. There is no significant postural drop in his blood pressure.

Investigations:

Haemoglobin (Hb)	11.8 g/dl
White cell count (WCC)	6.4×10^9/l
Haematocrit (Hct)	0.465
Mean corpuscular volume (MCV)	101.6 fl
Platelets	287×10^9/l
Sodium	137 mmol/l
Potassium	4.4 mmol/l
Urea	4.1 mmol/l
Creatinine	71 µmol/l
Bilirubin	30 mmol/l
Alanine aminotransferase	82 U/l
[illegible]	43 U/l

Rana Alnasser's screen

10:39

A 72-year-old woman was admitted to the Emergency Department with her second fall in three months. She was discharged home, but an astute SHO ordered a 24-h tape as an outpatient.

You review her in the clinic. She has a history of hypertension which is managed with ramipril and indapamide and she reports episodes of dizziness and fast palpitations over the past few months.

On examination, she looks slim, her blood pressure (BP) is 155/84 mmHg, pulse is 82/min sinus rhythm. She is not in cardiac failure.

Investigations:

Hb	12.4 g/dl
WCC	5.1×10^9/l
PLT	198×10^9/l
Na^+	140 mmol/l
K^+	4.9 mmol/l
Creatinine	110 μmol/l
TSH	2.5 U/l
Resting ECG	Sinus rhythm, no acute changes but inferior Q waves identified
24-h tape	Short periods of paroxysmal AF, pauses of up to 4 s

How would you plan to initially manage the patient with respect to her rhythm disturbance?

A	Aspirin
B	Digoxin

Rana Alnasser's screen

10:40

On examination, she looks slim, her blood pressure (BP) is 155/84 mmHg, pulse is 82/min sinus rhythm. She is not in cardiac failure.

Investigations:

Hb	12.4 g/dl
WCC	5.1×10^9/l
PLT	198×10^9/l
Na^+	140 mmol/l
K^+	4.9 mmol/l
Creatinine	110 µmol/l
TSH	2.5 U/l
Resting ECG	Sinus rhythm, no acute changes but inferior Q waves identified
24-h tape	Short periods of paroxysmal AF, pauses of up to 4 s

How would you plan to initially manage the patient with respect to her rhythm disturbance?

A Aspirin

B Digoxin

C Amiodarone

D Bisoprolol

E Referral for pacemaker

Rana Alnasser's screen

WCC	5.1×10^9/l
PLT	198×10^9/l
Na^+	140 mmol/l
K^+	4.9 mmol/l
Creatinine	110 µmol/l
TSH	2.5 U/l
Resting ECG	Sinus rhythm, no acute changes but inferior Q waves identified
24-h tape	Short periods of paroxysmal AF, pauses of up to 4 s

How would you plan to initially manage the patient with respect to her rhythm disturbance?

Your answer was correct

A Aspirin

B Digoxin

C Amiodarone

D Bisoprolol

E Referral for pacemaker

Explanation

E Referral for pacemaker

This patient has atrial fibrillation (AF) with associated

10:41

E Referral for pacemaker

This patient has atrial fibrillation (AF) with associated pauses. Pauses of up to 3 s are common, especially when spontaneously cardioverting from AF to sinus rhythm. However, pauses longer than this may suggest the presence of sinus node disease. Given her history of falls, she requires the implantation of a pacemaker. This will then allow for the use of negatively chronotropic agents (eg beta-blockers) for the treatment of her paroxysmal AF.

Further, the patient's CHA_2DS_2-VASc score is 3 and she requires anticoagulation with a vitamin-K antagonist (eg warfarin) or an non-vitamin K antagonist anticoagulant (eg dabigatran, rivaroxaban, apixaban, edoxaban).

A Aspirin

The primary issue present here is the presence of likely sinus node disease, and this need to be addressed first. Aspirin has no role in the treatment of atrial fibrillation. Although it was previously considered appropriate to reduce the risk of stroke in low-risk patients (not the case in the patient), evidence has shown that the increase is bleeding risk outweighs any stroke-reduction benefit.

B Digoxin

Digoxin may be an appropriate for the rate control of atrial fibrillation. However, the presence of significant pauses on the 24-h tape suggests that the patient is at risk of developing significant heart block. Providing an agent that acts by inhibiting the depolarisation of the AV node will increase the risk of heart block in this patient. They instead require a pacemaker implanted prior to initiating any negatively chronotropic agent.

C Amiodarone

Rana Alnasser's screen

10:42

A 50-year-old man comes to the Cardiology Clinic for follow-up. He has been annually followed up in the clinic for 10 years for his aortic stenosis. He informs you that his exercise tolerance has decreased. He gets some chest discomfort and dizziness on strenuous exertion.

On examination, he is comfortable, with a blood pressure of 125/85 mmHg and a pulse of 76 and regular. His jugular venous pressure is not raised; there are bibasal crackles on auscultation of the chest. First and second heart sounds are heard, and there is an ejection systolic murmur grade 3/6 in the aortic distribution. An echocardiogram reveals a peak gradient of 32 mmHg across the aortic valve, with generalised poor left ventricular (LV) function and an ejection fraction of 35%.

How should this patient be managed?

A	Continue yearly follow-ups
B	Isolated replacement of the aortic valve
C	Discharge the patient from clinic
D	Start the patient on digoxin
E	Replacement of the aortic valve ± coronary artery bypass graft (CABG)

7496

Submit

Rana Alnasser's screen

A 50-year-old man comes to the Cardiology Clinic for follow-up. He has been annually followed up in the clinic for 10 years for his aortic stenosis. He informs you that his exercise tolerance has decreased. He gets some chest discomfort and dizziness on strenuous exertion.

On examination, he is comfortable, with a blood pressure of 125/85 mmHg and a pulse of 76 and regular. His jugular venous pressure is not raised; there are bibasal crackles on auscultation of the chest. First and second heart sounds are heard, and there is an ejection systolic murmur grade 3/6 in the aortic distribution. An echocardiogram reveals a peak gradient of 32 mmHg across the aortic valve, with generalised poor left ventricular (LV) function and an ejection fraction of 35%.

How should this patient be managed?

Your answer was incorrect

A Continue yearly follow-ups

B Isolated replacement of the aortic valve

C Discharge the patient from clinic

D Start the patient on digoxin

E Replacement of the aortic valve ± coronary artery bypass graft (CABG)

Explanation

E Replacement of the aortic valve ± coronary artery bypass graft (CABG)

E Replacement of the aortic valve ± coronary artery bypass graft (CABG)

Normally, a gradient of between 50 and 60 mmHg is required for surgical intervention of a stenotic aortic valve, but in this case, the gradient across the aortic valve would not be the sole determinant. Since the patient is symptomatic, there is a high likelihood of LV dysfunction, hence the lower-than-expected aortic gradient.

B Isolated replacement of the aortic valve

Aortic valve replacement would help restore valvular function. However, the patient would also need an angiogram to determine the patency of his coronary arteries before surgery. If there were any coronary artery disease, both valve replacement and bypass surgery could be carried out at the same time.

A Continue yearly follow-ups

Given the fact that the patient has now become symptomatic, he requires an intervention in an attempt to improve his quality of life and halt any further deterioration of his ventricular function.

C Discharge the patient from clinic

The fact that the patient has become symptomatic can lead to a reduced quality of life and an increased mortality. He requires an intervention to improve his quality of life and halt any further deterioration of his ventricular function.

D Start the patient on digoxin

A Continue yearly follow-ups

Given the fact that the patient has now become symptomatic, he requires an intervention in an attempt to improve his quality of life and halt any further deterioration of his ventricular function.

C Discharge the patient from clinic

The fact that the patient has become symptomatic can lead to a reduced quality of life and an increased mortality. He requires an intervention to improve his quality of life and halt any further deterioration of his ventricular function.

D Start the patient on digoxin

Treatment with digoxin would not be treating his underlying problem (aortic stenosis). In addition, even though digoxin was commonly used in the past for the treatment of heart failure, it is no longer considered the first choice, as it may increase the risk of death.

Rate this question:

Next Question

Previous Q... Tag Questi... Feedback End Session

Blog About Pastest Contact Us Help

© Pastest 2019

A 26-year-old man was admitted to the Emergency Department with worsening shortness of breath. Previously fit and well, his past medical history is unremarkable. He gives a three-day history of central chest pain, fever and shortness of breath. Initially he had generalised muscle pains; he then developed chest pain and a cough productive of yellowish sputum. The chest pain radiated to his back and the shortness of breath was progressive. At presentation, he could not complete a sentence in one breath because of breathlessness. Clinically he was in severe acute decompensated heart failure with pulmonary oedema.

Investigations:

Hb	15.8 g/dl
WCC	18×10^9/l
PLT	210×10^9/l
Na+	136 mmol/l
K+	4.1 mmol/l
Creatinine	131 µmol/l
MCV	88.6 fl
Urea	9.7 mmol/l
Mg^{2+}	0.61 mmol/l
Hs-troponin	>10,000 units (normal <35)
ECG	Sinus rhythm with a right bundle branch block at a rate of 130/min
CXR	Enlarged, globular heart with evidence of pulmonary oedema

The patient was stabilised with oxygen therapy, IV diuretics and a brief period of CPAP and inotropic therapy in CCU. A

MCV	88.6 fl
Urea	9.7 mmol/l
Mg^{2+}	0.61 mmol/l
Hs-troponin	>10,000 units (normal <35)
ECG	Sinus rhythm with a right bundle branch block at a rate of 130/min
CXR	Enlarged, globular heart with evidence of pulmonary oedema

The patient was stabilised with oxygen therapy, IV diuretics and a brief period of CPAP and inotropic therapy in CCU. A bedside trans-thoracic echocardiogram was performed which showed a small pericardial effusion with normal left ventricular size but very poor global left ventricular function. The ejection fraction was 15%.

His unsupported blood pressure is now 112/69 mmHg, with an NYHA symptom class of III-IV. There is still evidence of peripheral and some pulmonary oedema which is gradually improving on the ongoing IV furosemide therapy.

What is the most appropriate next step in this patient's management?

A	Refer for coronary angiography
B	Start low-dose beta-blocker
C	Start nitrate therapy
D	Refer for assessment of cardiac transplantation
E	Start low-dose ACE inhibitor

E Start low-dose ACE inhibitor

This patient presented with cardiogenic shock probably secondary to acute viral myocarditis. The management is focused on best supportive care while instituting evidence-based therapy to assist recovery of left ventricular function. Diuretic therapy should be continued to achieve euvolaemia, and serial echocardiograms performed to monitor progress.

B Start low-dose beta-blocker

While beta-blockers are evidenced-based treatments for heart failure, we would not want to introduce this while the patient has ongoing symptoms of acute decompensated heart failure. This can be introduced at a later stage when the patient is stable.

A Refer for coronary angiography

This young patient with no prior cardiac history is unlikely to have significant coronary artery disease leading to his presentation. This might be considered if the patient were older with more in the history to suggest concomitant ischaemic heart disease, but even then would only be considered when the patient is more clinically stable.

C Start nitrate therapy

This is a useful adjunct to temporarily "offload" patients with acute decompensated heart failure in addition to standard diuretic and supportive therapy. There are ongoing symptoms of heart failure but the patient is currently improving with diuretics and will now require therapies to help with the recovery of his ventricular function.

heart failure. This can be introduced at a later stage when the patient is stable.

A Refer for coronary angiography

This young patient with no prior cardiac history is unlikely to have significant coronary artery disease leading to his presentation. This might be considered if the patient were older with more in the history to suggest concomitant ischaemic heart disease, but even then would only be considered when the patient is more clinically stable.

C Start nitrate therapy

This is a useful adjunct to temporarily "offload" patients with acute decompensated heart failure in addition to standard diuretic and supportive therapy. There are ongoing symptoms of heart failure but the patient is currently improving with diuretics and will now require therapies to help with the recovery of his ventricular function.

D Refer for assessment of cardiac transplantation

This might be considered if the patient deteriorates despite best supportive care. Reintroduction of inotropic support, intra-aortic balloon pump insertion or use of left ventricular assist devices might be considered while awaiting cardiac transplantation.

32325

Rate this question:

Rana Alnasser's screen

10:50

A 26-year-old man was admitted to the Emergency Department with worsening shortness of breath. Previously fit and well, his past medical history is unremarkable. He gives a three-day history of central chest pain, fever and shortness of breath. Initially he had generalised muscle pains; he then developed chest pain and a cough productive of yellowish sputum. The chest pain radiated to his back and the shortness of breath was progressive. At presentation, he could not complete a sentence in one breath because of breathlessness. Clinically he was in severe acute decompensated heart failure with pulmonary oedema.

A
B
C
D
E

Investigations:

Hb	15.8 g/dl
WCC	18×10^9/l
PLT	210×10^9/l
Na+	136 mmol/l
K+	4.1 mmol/l
Creatinine	131 µmol/l
MCV	88.6 fl
Urea	9.7 mmol/l
Mg^{2+}	0.61 mmol/l
Hs-troponin	>10,000 units (normal <35)
ECG	Sinus rhythm with a right bundle branch block at a rate of 130/min
CXR	Enlarged, globular heart with evidence of pulmonary oedema

The patient was stabilised with oxygen therapy, IV diuretics and a brief period of CPAP and inotropic therapy in CCU. A

Rana Alnasser's screen

A 27-year-old male comes to the Emergency Department complaining of palpitations. In the past year, he has had some occasional palpitations only lasting a few seconds. This particular episode is different because it has been going on for about 45 min. He also complains of worsening shortness of breath. He was diagnosed with Wolff-Parkinson-White (WPW) syndrome a year ago when he presented with similar symptoms.
On examination, he is apprehensive, his pulse is 130/min and his blood pressure is 90/70 mmHg. There are crackles on auscultation at both lung bases.

Investigations:

Urea and electrolytes	Normal
Full blood count	Normal
Chest X-ray	Normal
Electrocardiogram (ECG)	Narrow complex regular tachycardia with heart rate of 150/min

What is the next appropriate immediate step in his management?

A	Digoxin
B	DC cardioversion
C	Infusion of amiodarone
D	Intravenous (IV) flecainide
E	IV verapamil

Parkinson-White (WPW) syndrome a year ago when he presented with similar symptoms.
On examination, he is apprehensive, his pulse is 130/min and his blood pressure is 90/70 mmHg. There are crackles on auscultation at both lung bases.

Investigations:

Urea and electrolytes	Normal
Full blood count	Normal
Chest X-ray	Normal
Electrocardiogram (ECG)	Narrow complex regular tachycardia with heart rate of 150/min

What is the next appropriate immediate step in his management?

Your answer was correct

A Digoxin

B DC cardioversion

C Infusion of amiodarone

D Intravenous (IV) flecainide

E IV verapamil

Explanation

B DC cardioversion

DC cardioversion should be used early if the tachycardia is

B DC cardioversion

DC cardioversion should be used early if the tachycardia is causing haemodynamic compromise. The presence of a low systolic blood pressure and bibasal crackles on auscultation indicate that cardioversion is the most appropriate intervention here.

A Digoxin

Digoxin should be avoided as it may accelerate conduction down the accessory pathway. This could potentially lead to further cardiovascular compromise. It is also highly unlikely to achieve sinus rhythm.

C Infusion of amiodarone

Amiodarone is slightly less effective in achieving cardioversion in this situation than flecainide, and DC cardioversion is preferred given the systolic blood pressure.

D Intravenous (IV) flecainide

Intravenous flecainide or disopyramide should be used for chemical cardioversion, but it is not the treatment of choice if, as here, there is haemodynamic compromise.

E IV verapamil

IV verapamil should be avoided as it may accelerate conduction down the accessory pathway. This could potentially lead to a further increase in pulse rate, risk of ventricular tachycardia, and cardiac arrest.

Rate this question:

10:56

A 69-year-old woman is assessed in the Emergency Department after an episode of retrosternal chest pain while mopping her floors; the pain lasted for 30 minutes.

She has a past history of rheumatic fever and hypertension, but nil else of note. The pain started 5 hours ago, and she is now pain-free.

On examination, she is obese with a body mass index (BMI) of 34 kg/m^2; her blood pressure is 147/82 mmHg, controlled with ramipril and bendroflumethiazide.

An electrocardiogram (ECG) reveals broad P waves, but nil else of note, and a chest X-ray reveals evidence of old tuberculosis.

What is the management of choice in this patient?

A	Admit for 12-hour highly sensitive troponin T test
B	Observe in the Emergency Department and await 3-hour highly sensitive troponin T test
C	Discharge
D	Commence intravenous (IV) heparin
E	Commence IV IIB/IIIA antagonist therapy

Submit

Rana Alnasser's screen

She has a past history of rheumatic fever and hypertension, but nil else of note. The pain started 5 hours ago, and she is now pain-free.

On examination, she is obese with a body mass index (BMI) of 34 kg/m²; her blood pressure is 147/82 mmHg, controlled with ramipril and bendroflumethiazide.

An electrocardiogram (ECG) reveals broad P waves, but nil else of note, and a chest X-ray reveals evidence of old tuberculosis.

What is the management of choice in this patient?

Your answer was correct

A	Admit for 12-hour highly sensitive troponin T test
B	Observe in the Emergency Department and await 3-hour highly sensitive troponin T test
C	Discharge
D	Commence intravenous (IV) heparin
E	Commence IV IIB/IIIA antagonist therapy

Explanation

B	Observe in the Emergency Department and await 3-hour highly sensitive troponin T test

This patient has at least two risk factors for cardiac chest pain: obesity and hypertension. As such, she should be screened for cardiac chest pain. A high-sensitivity troponin at this point in her presentation is sufficient to determine the presence of an ischaemic event with myocardial damage. As this patient's pain started > 7 hours ago, a

B Observe in the Emergency Department and await 3-hour highly sensitive troponin T test

This patient has at least two risk factors for cardiac chest pain: obesity and hypertension. As such, she should be screened for cardiac chest pain. A high-sensitivity troponin at this point in her presentation is sufficient to determine the presence of an ischaemic event with myocardial damage. As this patient's pain started > 3 hours ago, a single troponin test is sufficient to exclude acute myocardial infarction.

A Admit for 12-hour highly sensitive troponin T test

Modern practice with high-sensitivity troponin now dictates that troponin assays at 3 and 6 hours from the onset of chest pain are adequate to determine whether myocardial damage has occurred.

If a single test at > 6 hours away is not elevated, then this is strong evidence for the absence of cardiac ischaemia.

C Discharge

The patient has presented with 30 minutes of cardiac-sounding chest pain and therefore warrants further investigation. With serial ECGs being unremarkable, troponin assays are required to exclude myocardial ischaemia, and therefore, discharge would not be appropriate.

D Commence intravenous (IV) heparin

IV heparin use has largely been superseded by low-molecular-weight heparin and factor Xa inhibitors such as fondaparinux, due to practicalities of administration and the narrow therapeutic window (activated partial thromboplastin time (APTT)) required with IV heparin.

investigation. With serial ECGs being unremarkable, troponin assays are required to exclude myocardial ischaemia, and therefore, discharge would not be appropriate.

D	Commence intravenous (IV) heparin

IV heparin use has largely been superseded by low-molecular-weight heparin and factor Xa inhibitors such as fondaparinux, due to practicalities of administration and the narrow therapeutic window (activated partial thromboplastin time (APTT)) required with IV heparin.

E	Commence IV IIB/IIIA antagonist therapy

IIB/IIIA receptor antagonist therapy would not be indicated, unless significant ECG changes occurred or there was the presence of elevated troponins. Its use is predominantly in 'upstream' management of acute coronary syndromes or as an adjunct during percutaneous coronary intervention. IIB/IIIA receptor antagonists are usually combined with a suitable anticoagulant.

Rate this question:

© Pastest 2019

A 58-year-old male presents with history of pain and swelling of his left calf of three days' duration. He denies any shortness of breath, fever or trauma, and has not had any joint pain previously. The only past medical history of note is diabetes mellitus of 6 years' duration. He does not have any obvious risk factors for venous thrombosis and has no family history of such disorder either. Physical examination is normal except for a swollen, warm left leg.

Investigations:

Hb	13.1 g/dl
WCC	27.4×10^9/l; 81% lymphocytes, small mature lymphocytes seen on film
PLT	193×10^9/l
PT	19.2 s (11.5–15.5)
PTT	23.9 s (24–35)
INR	1.1
Urea	Normal
Urine dipstick	SG 1.020, pH 6, Glucose +++
ECG	Normal
CXR	Normal
LDH	455 U/l (480–550)
Abdomen ultrasound	No intra-abdominal lymphadenopathy
Repeat complete blood count	WBC 34.3×10^9/l with 86% lymphocytes
Doppler ultrasound of lower limbs	Thrombosis of tibial and popliteal veins on the left

What one of the following is the most appropriate way to

PTT	23.9 s (24–35)
INR	1.1
Urea	Normal
Urine dipstick	SG 1.020, pH 6, Glucose +++
ECG	Normal
CXR	Normal
LDH	455 U/l (480–550)
Abdomen ultrasound	No intra-abdominal lymphadenopathy
Repeat complete blood count	WBC 34.3 × 10^9/l with 86% lymphocytes
Doppler ultrasound of lower limbs	Thrombosis of tibial and popliteal veins on the left

What one of the following is the most appropriate way to manage this patient's long-term anti-coagulation?

A Warfarin for life

B Warfarin for 6 months

C Low-molecular weight (LMW) heparin

D Warfarin for 3 months

E Dabigatran

32298

INR	1.1
Urea	Normal
Urine dipstick	SG 1.020, pH 6, Glucose +++
ECG	Normal
CXR	Normal
LDH	455 U/l (480–550)
Abdomen ultrasound	No intra-abdominal lymphadenopathy
Repeat complete blood count	WBC 34.3 × 10^9/l with 86% lymphocytes
Doppler ultrasound of lower limbs	Thrombosis of tibial and popliteal veins on the left

What one of the following is the most appropriate way to manage this patient's long-term anti-coagulation?

Your answer was correct

A Warfarin for life

B Warfarin for 6 months

C Low-molecular weight (LMW) heparin

D Warfarin for 3 months

E Dabigatran

Explanation

C Low-molecular weight (LMW) heparin

This patient has a proximal DVT and potential underlying chronic lymphocytic leukaemia with increased risk of further venous thromboembolism. As such, long-term anti-coagulation is required. LMW heparin has the least potential for drug interaction or for its effect to be modulated by hepatic dysfunction (resulting from chemotherapy interventions), and is therefore the optimal choice here.

A Warfarin for life

Warfarin has the potential for drug-drug interactions with a range of chemotherapy agents used in the treatment of haematological malignancy and thus should be avoided here.

B Warfarin for 6 months

Six months' anticoagulation is likely to be inadequate in the context of underlying CLL, and because of drug-drug interaction potential, and any effects on INR of hepatic dysfunction as result of therapy, it should be avoided here.

D Warfarin for 3 months

Three months' anticoagulation is inadequate in this situation and warfarin should be avoided here.

E Dabigatran

Although modern anticoagulants such as Factor Xa inhibitors could in theory be used in the context of underlying haematological malignancy, there isn't a substantial body of evidence to support a positive benefit risk in this population.

A 73-year-old lady comes to the Cardiology Clinic for follow-up. Her general practitioner referred her to the Cardiology Clinic when she was found to have isolated systolic hypertension 3 months ago. Her systolic blood pressure (BP) ranged between 155 and 188 mmHg and her diastolic BP ranged between 70 and 82 mmHg. She was not started on medication and was encouraged to reduce her salt intake, lose some weight and start exercising. She now comes to your clinic and her BP is 180/75 mmHg. She had been taking a series of BPs at home, with systolic ranging from 150 to 180 mmHg and diastolic ranging from 65 to 75 mmHg.

How would you manage this lady?

A	Amlodipine
B	Bendroflumethiazide
C	Bisoprolol
D	Continue lifestyle measures
E	Valsartan

Submit

A 73-year-old lady comes to the Cardiology Clinic for follow-up. Her general practitioner referred her to the Cardiology Clinic when she was found to have isolated systolic hypertension 3 months ago. Her systolic blood pressure (BP) ranged between 155 and 188 mmHg and her diastolic BP ranged between 70 and 82 mmHg. She was not started on medication and was encouraged to reduce her salt intake, lose some weight and start exercising. She now comes to your clinic and her BP is 180/75 mmHg. She had been taking a series of BPs at home, with systolic ranging from 150 to 180 mmHg and diastolic ranging from 65 to 75 mmHg.

How would you manage this lady?

Your answer was correct

A Amlodipine

B Bendroflumethiazide

C Bisoprolol

D Continue lifestyle measures

E Valsartan

Explanation

A Amlodipine

This patient has isolated systolic hypertension, and according to NICE guidelines this should be managed in

Explanation

A Amlodipine

This patient has isolated systolic hypertension, and according to NICE guidelines this should be managed in the same way as hypertension where both the systolic and diastolic blood pressure are elevated. Given that she is over 55 years, amlodipine is an appropriate initial therapy.

B Bendroflumethiazide

Thiazide diuretics are no longer a first-line intervention for the treatment of hypertension in patients with diabetes. They were shown in a meta-analysis to be associated with increased risk of incident type 2 diabetes.

C Bisoprolol

Either ACE inhibitors or calcium channel blockers are the preferred first option for the treatment of hypertension according to NICE guidance.

D Continue lifestyle measures

Given this lady's marked elevation in systolic blood pressure, pharmacological intervention is required.

E Valsartan

ARBs are not recommended as initial therapy unless other options including ACE inhibitors are not tolerated, and should not be used according to NICE guidance in combination with ACE inhibitors.

Rate this question:

A 58-year-old man had a 2-h history of chest pain while exercising at the gym. An ambulance was called to the scene and upon arrival of the paramedics the patient was witnessed to clutch his chest and collapse. A defibrillator trace showed ventricular fibrillation (VF). The paramedics gave a 150 J direct current (DC) shock in the ambulance, followed by 3 min of cardio-pulmonary resuscitation (CPR) en route to the hospital. On arrival, he remains in VF.

What is your immediate management step?

A	Adrenalin IV
B	Calcium chloride IV
C	Sodium bicarbonate IV
D	Further 3 minutes CPR then reassess the rhythm
E	Repeat DC shock at 360J

Submit

Previous Q... Skip Questi...

© Pastest 2019

A 58-year-old man had a 2-h history of chest pain while exercising at the gym. An ambulance was called to the scene and upon arrival of the paramedics the patient was witnessed to clutch his chest and collapse. A defibrillator trace showed ventricular fibrillation (VF). The paramedics gave a 150 J direct current (DC) shock in the ambulance, followed by 3 min of cardio-pulmonary resuscitation (CPR) en route to the hospital. On arrival, he remains in VF.

What is your immediate management step?

Your answer was correct

A Adrenalin IV

B Calcium chloride IV

C Sodium bicarbonate IV

D Further 3 minutes CPR then reassess the rhythm

E Repeat DC shock at 360J

Explanation

E Repeat DC shock at 360J

The 2005 Resuscitation (UK) guidelines recommend alterations in the traditional resuscitation protocol based on experimental studies in cardiac arrest. First DC shocks in witnessed ventricular tachycardia (VT)/VF arrests are highly successful at restoring rhythm, but a palpable pulse may not be felt for some time. During this time CPR is now

E Repeat DC shock at 360J

The 2005 Resuscitation (UK) guidelines recommend alterations in the traditional resuscitation protocol based on experimental studies in cardiac arrest. First DC shocks in witnessed ventricular tachycardia (VT)/VF arrests are highly successful at restoring rhythm, but a palpable pulse may not be felt for some time. During this time CPR is now considered safe and will aid myocardial perfusion whether normal rhythm is restored or not. Suspension of CPR while rhythm and pulse is checked after a shock will increase myocardial hypoxia and make the cardiac muscle more refractory to further DC shocks. Escalation of shocks has also been found no more effective than a single biphasic (150–360 J) or monophasic (360 J) shock and therefore single shock protocols have been adopted by the resuscitation council.

In a witnessed VF arrest the guidelines now suggest that a single DC shock is given (either biphasic or monophasic) followed by immediate chest compressions (without feeling for a pulse or reassessing rhythm). After 2 min of CPR the rhythm should be reassessed and if still VF a further DC shock should be given. After a further 2 min of CPR of VF persist iv adrenaline should be given followed by a further DC shock.

Calcium chloride and bicarbonate are recommended only for the treatment of hyperkalaemia in this setting and should be considered only once a biochemical diagnosis has been made.

A Adrenalin IV

Adrenal IV is appropriate if defibrillation is unsuccessful, followed by a further cycle of CPR.

B Calcium chloride IV

3G 11:10

or not. Suspension of CPR while
d after a shock will increase
ke the cardiac muscle more
ocks. Escalation of shocks has
ffective than a single biphasic
(360 J) shock and therefore
been adopted by the

e guidelines now suggest that a
ther biphasic or monophasic)
st compressions (without
essing rhythm). After 2 min of
reassessed and if still VF a
given. After a further 2 min of
line should be given followed

bonate are recommended only
alaemia in this setting and
once a biochemical diagnosis

defibrillation is unsuccessful,
of CPR.

VF
CPR
+
DC shock
CPR
R. ossess
VF
CPR
DC shock
CPR
VF
adrenaline
DC shock

ghlighter Line Rectangle Oval Undo Redo Clear Color Stop Share

PR, rather than instead of,
patient collapsed as the gym

Rana Alnasser's screen

11:18
On
594-042-7551
Leave

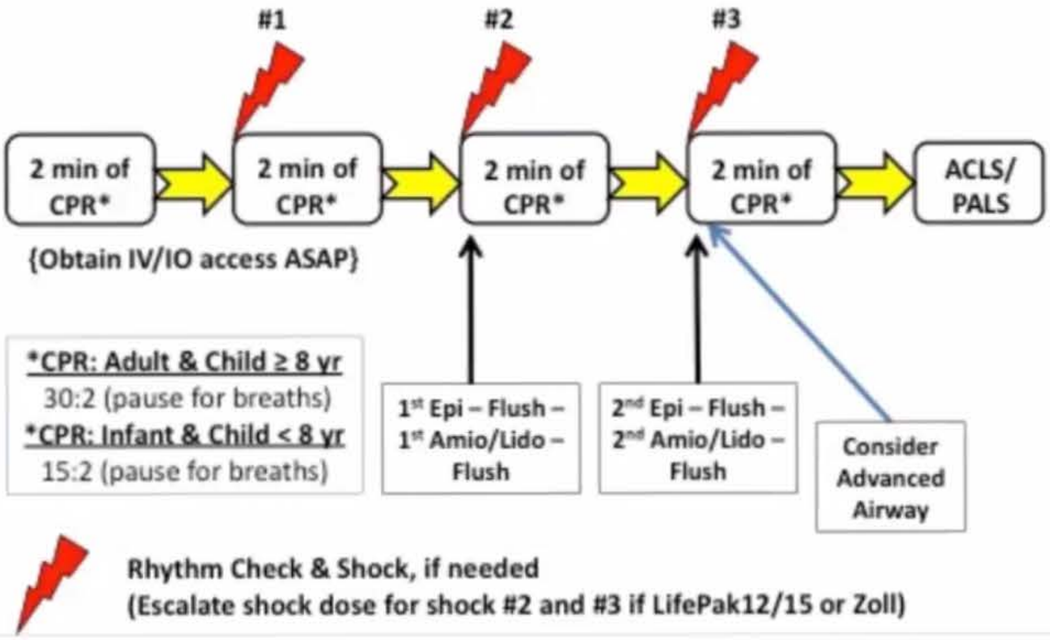

BioTel

UTSW/BioTel 2014 Guidelines for Therapy - Ventricular Fibrillation ...

UTSW/BioTel 2014 Guidelines for Therapy - Ventricular Fibrillation and Pulseless Ventricular Tachycardia

Images may be subject to copyright. Learn more

RELATED IMAGES

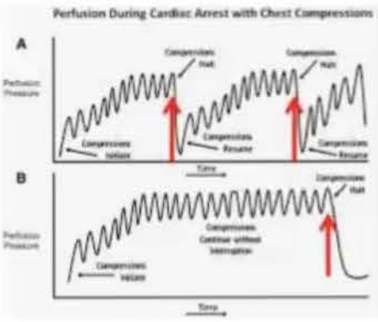

Beyond ACLS: CPR, Defibrillation, and Epinep...
rebelem.com

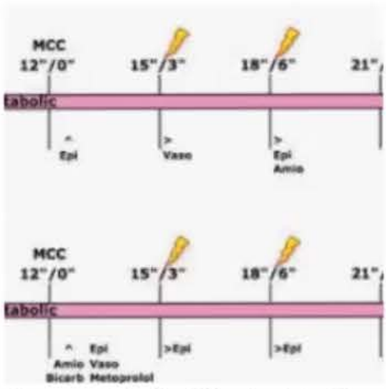

Experimental timeline. EPI—epinephrine, VA...
researchgate.net

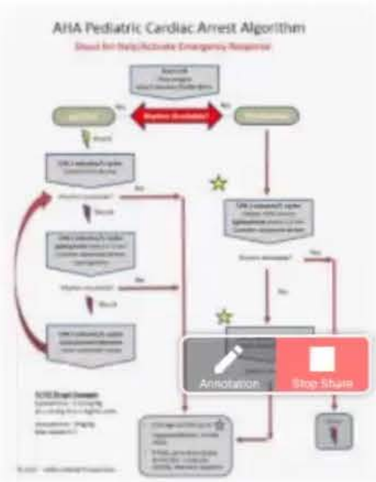

Discover
Updates
Search
Recent
More

Audio
Video
Share
Participants
More

A 58-year-old female presents with history of fever of one week's duration associated with rhinorrhoea, headache and cough productive of yellowish sputum. She has had type 2 diabetes for 8 years, complicated by painful peripheral neuropathy. Her present medications include gliclazide 40 mg twice daily, metformin 500 mg three times a day and amitriptyline 75 mg at bedtime. Physical examination reveals temperature 38°C, respiratory rate 18/min, blood pressure 110/70 mmHg, mild posterior pharynx erythema, tenderness over the maxillary sinus and fine inspiratory crackles at the right lung base.

Investigations:

Hb	11.0 g/dl
WCC	9.0×10^9/l
Reticulocytes	6%
Na^+	132 mmol/l
K^+	4.0 mmol/l
Chloride	98 mmol/l
Bicarbonate	22 mmol/l
Bilirubin	40 µmol/l
CXR	Infiltrates at R. lower zone

Which of the following drugs should be used to treat this patient?

A Erythromycin

B Levofloxacin

reveals temperature 38°C, respiratory rate 18/min, blood pressure 110/70 mmHg, mild posterior pharynx erythema, tenderness over the maxillary sinus and fine inspiratory crackles at the right lung base.

Investigations:

Hb	11.0 g/dl
WCC	9.0×10^9/l
Reticulocytes	6%
Na^+	132 mmol/l
K^+	4.0 mmol/l
Chloride	98 mmol/l
Bicarbonate	22 mmol/l
Bilirubin	40 µmol/l
CXR	Infiltrates at R. lower zone

Which of the following drugs should be used to treat this patient?

A Erythromycin

B Levofloxacin

C Co-amoxiclav

D Doxycycline

E Rifampicin

D Doxycycline

This patient has pneumonia and evidence of haemolysis (reticulocytosis and hyperbilirubinaemia). This suggests *Mycoplasma pneumoniae* as a possible aetiological agent. Macrolides, and fluoroquinolones such as levofloxacin and doxycycline, can all be used to treat *Mycoplasma*. However, this patient is taking amitriptyline that can cause prolongation of the QT interval. Prescribing another agent that can also prolong the QT interval, such as macrolides or levofloxacin. can be hazardous. Hence, doxycycline is the best therapy for this patient. Other antimicrobial agents that can cause prolongation of the QT interval include:

- Pentamidine
- Spiramycin
- Chloroquine
- Halofantrine
- Mefloquine.

Management of drug-induced long-QT syndrome is to stop the precipitating drug, correction of any electrolyte disturbance such as hypokalaemia or hypomagnesaemia, and treatment of associated ventricular arrhythmia. First-line pharmacological therapy for drug-induced long-QT syndrome is intravenous magnesium sulphate 2 g administered as a bolus over 1–2 min, followed by another bolus in 15 min if required, or continuous infusion at a rate of 5–20 mg/min.

A Erythromycin

As a macrolide, erythromycin has been linked to QT prolongation and torsades, and should thus be avoided in the context of concomitant amitriptyline administration. Erythromycin is indicated for susceptible infections in patients with penicillin hypersensitivity (e.g. respiratory

A 27-year-old man is referred to the Emergency Department by his general practitioner (GP) after having collapsed at home. This event had happened earlier in the day while he was sitting on the couch listening to music. He does not remember having any chest pains or shortness of breath. He just passed out and this was the first time it had ever happened. He has never had any serious illness in the past and his family history is unremarkable. He is not on any medication and he is not allergic to any medication. On examination, he is alert, comfortable, his blood pressure is 125/70 mmHg and his pulse is 74/min and regular. First and second heart sounds are heard and there is no murmur. His chest is clear. His central nervous system and abdomen are normal. His full blood count and biochemistry are normal.

Investigations:

Electrocardiogram (ECG)	ST elevation in V1–V3 and right bundle branch block (RBBB)
Chest X-ray	Normal
Echocardiography	Normal
Troponin T	Normal

What is the likely diagnosis?

A	Acute anterior myocardial infarction
B	Arrhythmogenic right ventricular dysplasia (ARVD)
C	Early repolarisation variant
D	Brugada syndrome (BrS)
E	Primary pulmonary hypertension

D Brugada syndrome (BrS)

In 1992, Brugada et al. described this novel clinical entity. It is an inherited form of cardiac arrhythmia, presenting with a typical electrocardiogram (ECG) pattern of ST segment elevation in leads V1–V3 and incomplete or complete right bundle branch block (RBBB). The underlying cause of BrS is a genetic defect in the SCN5A gene, which encodes the sodium channel controlling the depolarisation phase of the cardiac action potential. There are usually no structural abnormalities in Brugada syndrome (BrS) patients, and the disease may be defined as a pure electrical abnormality of myocardial cells. BrS manifests with syncope and cardiac arrest, typically occurring in the third or fourth decade of life, and usually at rest or during sleep. The implant of an implantable cardiac defibrillator (ICD) may markedly improve quality of life. Studies suggest that the majority of BrS patients are likely to remain asymptomatic and are at relatively low risk of relapsing.

A Acute anterior myocardial infarction

An anterior myocardial infarction will have electrocardiogram findings of ST elevation in leads V1–V6 with later pathological Q waves in the precordial leads V2 to V4–V5. Therefore in this scenario, the electrocardiogram is not consistent.

B Arrhythmogenic right ventricular dysplasia (ARVD)

ST segment elevation in right precordial leads and right RBBB has rarely been reported in arrhythmogenic right ventricular dysplasia (ARVD). Morphological analysis of the right ventricle should be carried out by echo and nuclear magnetic resonance (NMR) in order to exclude the presence of a structural cardiac abnormality.

11:25
On
594-042-7551
Leave

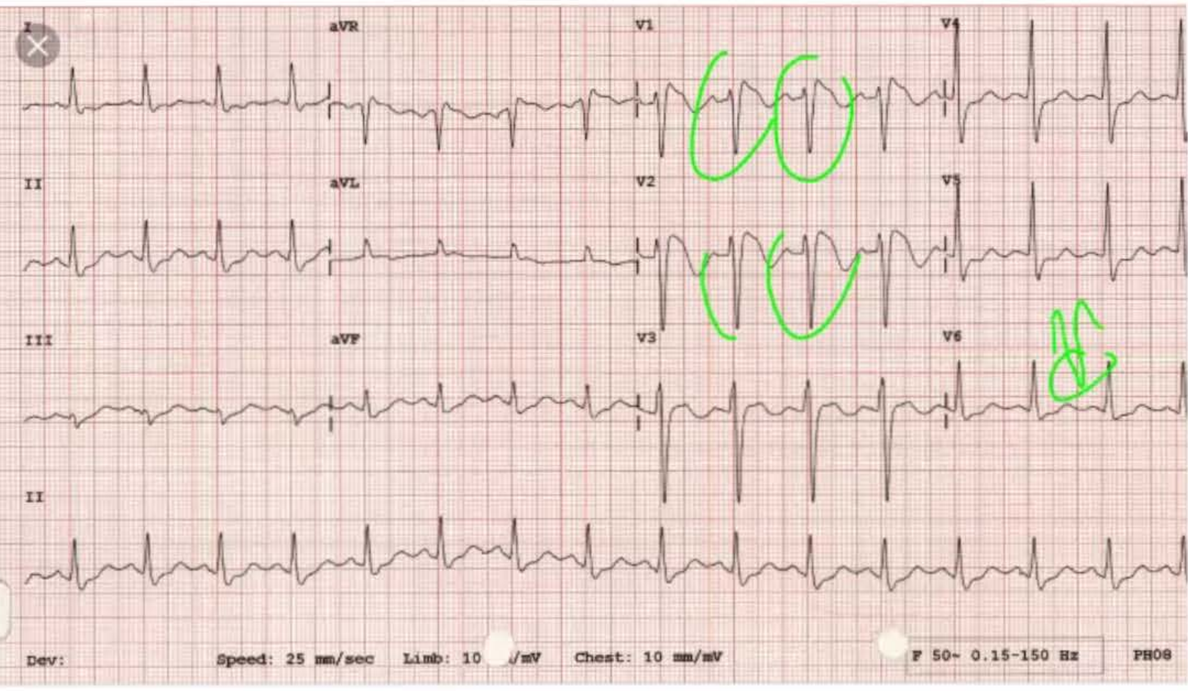

Life in the Fast Lane

Brugada Syndrome

Stop Annotation
Spotlight
Pen
Highlighter
Line
Rectangle
Oval
Undo
Redo
Clear
Color

Images may be subject to copyright. Learn more

RELATED IMAGES

Posterior STEMI - REBEL EM - Emergency M...
rebelem.com

Dr. Smith's ECG Blog: Young man with synco...
hqmeded-ecg.blogspot.com

Product
SVT – ECG quest
ecgquest.net

EKG showing sinus rhythm with right bundle ...
researchgate.net

Heart Tests for Brugada Syndrome | Health ...
health.tips.fm

Brugada Syndrome – The Student
thephysiologist.org

Discover
Updates
Search
Recent
More

Audio
Video
Share
Participants
More

11:28

A 28-year-old woman is referred by the casualty department after suffering an attack of paroxysmal atrial fibrillation. The casualty officer noticed that she had a mid-systolic murmur, loudest in the pulmonary area, and fixed splitting of the second heart sound. He also noticed that the pulmonary arterial tree appeared particularly prominent on chest X-ray. He was concerned about a valve defect. The electrocardiogram reveals right bundle-branch block and right-axis deviation. Routine bloods are unremarkable.

What diagnosis fits best with this clinical picture?

A	Mitral regurgitation
B	Mitral stenosis
C	Ventricular septal defect
D	Atrial septal defect
E	Subacute bacterial endocarditis

7029

Submit

Rana Alnasser's screen

A 28-year-old woman is referred by the casualty department after suffering an attack of paroxysmal atrial fibrillation. The casualty officer noticed that she had a mid-systolic murmur, loudest in the pulmonary area, and fixed splitting of the second heart sound. He also noticed that the pulmonary arterial tree appeared particularly prominent on chest X-ray. He was concerned about a valve defect. The electrocardiogram reveals right bundle-branch block and right-axis deviation. Routine bloods are unremarkable.

What diagnosis fits best with this clinical picture?

Your answer was correct

A	Mitral regurgitation
B	Mitral stenosis
C	Ventricular septal defect
D	Atrial septal defect
E	Subacute bacterial endocarditis

Explanation

D	Atrial septal defect

ASD is often first diagnosed in adulthood and represents one-third of all adult congenital heart disease. It is two to three times more common in women compared to men. Communication at the level of the atria allows left-to-right

11:29
On
594-042-7551
Leave

D Atrial septal defect

ASD is often first diagnosed in adulthood and represents one-third of all adult congenital heart disease. It is two to three times more common in women compared to men. Communication at the level of the atria allows left-to-right shunting of blood, leading to considerable increase in right heart output. Eventually this results in pulmonary hypertension. Patients often present with atrial fibrillation. There is fixed splitting of S2 on auscultation, and a mid-systolic murmur loudest in the pulmonary area. Chest X-ray may reveal pulmonary plethora, and the electrocardiogram shows right bundle-branch block. Significant ASDs should be repaired below the age of 10 years, or as soon as possible if diagnosed in adulthood.

A Mitral regurgitation

Mitral regurgitation results in a pan-systolic murmur and left ventricular failure, rather than the picture seen here.

B Mitral stenosis

Mitral stenosis has a loud opening snap and a mid-diastolic rumbling murmur, loudest at the left sternal edge.

C Ventricular septal defect

VSDs result in a pan-systolic murmur, with haemodynamically significant VSDs presenting earlier than age 28.

E Subacute bacterial endocarditis

There is nothing in the history to suggest subacute bacterial endocarditis, and the normal urinalysis screen also

Audio Video Share Participants More

A Mitral regurgitation

Mitral regurgitation results in a pan-systolic murmur and left ventricular failure, rather than the picture seen here.

B Mitral stenosis

Mitral stenosis has a loud opening snap and a mid-diastolic rumbling murmur, loudest at the left sternal edge.

C Ventricular septal defect

VSDs result in a pan-systolic murmur, with haemodynamically significant VSDs presenting earlier than age 28.

E Subacute bacterial endocarditis

There is nothing in the history to suggest subacute bacterial endocarditis, and the normal blood screen also makes this less likely as the underlying diagnosis.

Rate this question:

Next Question

© Pastest 2019

11:30

A 54-year-old man presents to the Emergency Room with central crushing chest pain. He is a smoker of 40-50 cigarettes per day and suffers from hypertension for which he takes ramipril 10 mg daily. He also uses aspirin 75 mg/day and atorvastatin 10 mg. On examination his BP is 90/60 mmHg, with pulse 105/min. He is in gross left ventricular failure and has cool peripheries. His ECG reveals inferior T-wave inversion.

From the options given below, which parameter fits most closely with the clinical history given?

A	Right atrial pressure 6 mmHg
B	Cardiac index 1.8 l/min/m^2
C	Cardiac index 2.9 l/min/m^2
D	Mean arterial pressure 105 mmHg
E	Ejection fraction 54%

32331

Submit

Rana Alnasser's screen

11:37
On
https://mypastest.pastest.com
594-042-7551
Leave

B Cardiac index 1.8 l/min/m²

This man is in cardiogenic shock and it is therefore to be expected that his cardiac index would be below 2 l/min/m². Cardiac index relates cardiac output to body surface area and is calculated by CO/BSA. Normal range is approximately 2.5-4.0 l/min/m². Management in this situation would involve inotropic support with an agent such as dobutamine, and ideally mechanical support with the insertion of an intra-aortic balloon pump (IABP).

A Right atrial pressure 6 mmHg

We would expect there to be back pressure, consistent with his pulmonary oedema, leading to significantly elevated RAP. Six is a normal reading, and would be unexpectedly low in the case of such a patient.

C Cardiac index 2.9 l/min/m²

This patient is in cardiogenic shock and we would therefore expect his cardiac index to be below 2.

D Mean arterial pressure 105 mmHg

Given that we are told his BP is 90/60, a mean arterial pressure of 105 would be impossibly high. The equation for MAP is [SBP + (2 × DBP)]/3 (in this case, 70).

E Ejection fraction 54%

In the face of such a degree of cardiogenic shock, an ejection fraction of 54% would be unexpectedly high.

Audio
Video
Share
Participants
More

A 56-year-old Indian male presents with a history of shortness of breath on exertion of three months' duration. For the last month, he has been unable to walk one block without getting short of breath. He has also noticed swelling of his feet.

On physical examination, he has jugular venous distension, low-volume pulse of 95/min, blood pressure 95/60 mmHg, a harsh ejection systolic murmur at the aortic area, left-sided third heart sound (S3) gallop and inspiratory crackles at both lung bases.

He has been diabetic and hyperlipidaemic for the past 6 years, and his medications include aspirin 75 mg aper day, fosinopril 20 mg per day and metformin 850 mg three times per day.
An echocardiogram is ordered, which reveals severe left ventricular dysfunction with an ejection fraction of 28%, a calcified aortic valve with a calculated aortic valve area of 0.6 cm^2 and a trans-aortic gradient of 30 mmHg.

What is the next best step in this patient's management?

A	Aortic valve replacement
B	Aortic balloon valvotomy
C	Discontinue fosinopril
D	Repeat echo with dobutamine infusion
E	Add bisoprolol and furosemide to his current therapy and repeat echo in 6 months

Submit

D Repeat echo with dobutamine infusion

This patient has severe left ventricular dysfunction, and calculated valve area in such patients can be falsely low because low cardiac output reduces the valve opening forces. It is important to distinguish patients with true severe aortic stenosis with secondary LV dysfunction from those who have a falsely low calculated aortic valve area because of low cardiac output. An important method of distinguishing between the two conditions is to assess the haemodynamics after increasing the cardiac output by dobutamine infusion during echocardiography or cardiac catheterisation. Patients with truly severe AS manifest an increase in trans-aortic pressure gradient while the valve surface area remains the same during dobutamine infusion; while those with falsely low calculated valve area manifest an increase in calculated valve surface area. Dobutamine echocardiography is also important to assess LV contractile reserve. Patients who have 20% or more increase in stroke volume after dobutamine infusion have a much better prognosis after surgery compared to those who do not have LV contractile reserve.

A Aortic valve replacement

Due to this patient's low ejection fraction, it is uncertain whether this is true aortic stenosis or pseudo-severe AS due to reduced LV function. It is appropriate to perform dobutamine echo to confirm before referral for intervention.

B Aortic balloon valvotomy

Due to this patient's low ejection fraction, it is uncertain whether this is true aortic stenosis or pseudo-severe AS due to reduced LV function. It is appropriate to perform dobutamine echo to confirm before referral for intervention.

11:47
On
594-042-7551
Leave

Due to this patient's low ejection fraction, it is uncertain whether this is true aortic stenosis or pseudo-severe AS due to reduced LV function. It is appropriate to perform dobutamine echo to confirm before referral for intervention.

B Aortic balloon valvotomy

Due to this patient's low ejection fraction, it is uncertain whether this is true aortic stenosis or pseudo-severe AS due to reduced LV function. It is appropriate to perform dobutamine echo to confirm before referral for intervention.

C Discontinue fosinopril

Fosinopril is indicated in the treatment of hypertension and as an adjunctive therapy in heart failure. There is no indication to stop it here. This patient should undergo dobutamine echo to confirm whether this is true AS or pseudo-severe AS due to poor LV function.

E Add bisoprolol and furosemide to his current therapy and repeat echo in 6 months

While these would be important therapies in the treatment of heart failure, confirmation of this patient's aortic valve status is required. This is best performed by stress echo to confirm whether this is true AS or pseudo-severe AS due to poor LV function.

Rate this question:

Next Question

Audio Video Share Participants More

11:49

MyPastest
https://mypastest.pastest.com

A 54-year-old company director presents to the Emergency Department with an episode of retrosternal chest pain lasting 15 minutes while playing squash. He went home after the event but his wife persuaded him to attend. There have been two similar episodes, one 6 months ago when he was walking the dog on a cold morning, and another 3 months ago when he got a short period of indigestion type pain while running on the treadmill. He stopped smoking 3 years ago but has no other specific past medical history.

Review 12 hours after presentation shows:

ECG	T wave inversion v4 – v6
creatine kinase	420 u/l
3 hour troponin	<0.03

Which of the following diagnoses fit best with this clinical picture?

A	Non-cardiac chest pain
B	N-STEMI
C	STEMI
D	Stable angina
E	Unstable angina

Rana Alnasser's screen

home after the event but his wife persuaded him to attend. There have been two similar episodes, one 6 months ago when he was walking the dog on a cold morning, and another 3 months ago when he got a short period of indigestion type pain while running on the treadmill. He stopped smoking 3 years ago but has no other specific past medical history.

Review 12 hours after presentation shows:

ECG	T wave inversion v4 – v6
creatine kinase	420 u/l
3 hour troponin	<0.03

Which of the following diagnoses fit best with this clinical picture?

Your answer was correct

A Non-cardiac chest pain

B N-STEMI

C STEMI

D Stable angina

E Unstable angina

Explanation

D Stable angina

Angina pectoris is described as a constricting discomfort experienced retrosternally or in the jaw, shoulders, arms or

D Stable angina

Angina pectoris is described as a constricting discomfort experienced retrosternally, or in the jaw, shoulders, arms or neck. It is precipitated by exertion and relieved by rest or GTN. Creatine kinase while raised is not specific for cardiac muscle damage, and can be associated with vigorous exercise. Troponin, on the other hand, is specific for cardiac muscle. Levels depend upon local biochemistry departments, with high levels indicating varying degrees of myocardial necrosis and should drive further investigations/more aggressive management in accordance with NICE guidelines CG126: Stable angina management. In the context of a troponin here which is less than 0.03 (ie negative), it is likely that the electrocardiogram changes are reflective of stable angina; it is the troponin which stratifies him in the lower risk group.

A Non-cardiac chest pain

The differential diagnosis for chest pain is extensive with respiratory, gastrointestinal, neuromusculoskeletal and psychogenic causes to be considered. In this scenario, retrosternal chest pain precipitated by exertion in a patient with a significant smoking history and resting ECG changes consistent with ischaemia, cardiac investigation and management should be initiated. Non-cardiac chest pain is a diagnosis of exclusion.

B N-STEMI

The European Society of Cardiology defines NSTEMI as acute chest pain but without persistent ST-elevation. ECG changes may resemble ST depression, T-wave inversion, T-wave flattening or no ECG changes. If the troponin is elevated or shows a significant rise, then non-ST elevation myocardial infarction is diagnosed. In this clinical case, while ECG changes are present, normal troponins exclude

retrosternal chest pain precipitated by exertion in a patient with a significant smoking history and resting ECG changes consistent with ischaemia, cardiac investigation and management should be initiated. Non-cardiac chest pain is a diagnosis of exclusion.

B N-STEMI

The European Society of Cardiology defines NSTEMI as acute chest pain but without persistent ST-elevation. ECG changes may resemble ST depression, T-wave inversion, T-wave flattening or no ECG changes. If the troponin is elevated or shows a significant rise, then non-ST elevation myocardial infarction is diagnosed. In this clinical case, while ECG changes are present, normal troponins exclude the diagnosis of NSTEMI

C STEMI

ST-elevation myocardial infarction (STEMI) is defined by the European Society of Cardiology as typical acute chest pain and persistent (>20 minutes) ST elevation on the ECG. Urgent intervention is required with reperfusion therapy.

E Unstable angina

Unstable angina is similar to the NSTEMI definition of acute chest pain but without persistent ST-elevation; however patients have negative cardiac biomarkers. This patient is experiencing chest pain typically on exertion, whereas unstable angina may present at rest, with increasing frequency/severity and may last longer than stable angina.

Rate this question:

Next Question

11:52
On ···
594-042-7551
Leave

A 53-year-old man has been referred to the Cardiology Clinic by his GP for an abnormal pulse. The man had gone to see his GP for a regular check-up when he was found to have an incidental abnormal heart rhythm. This has not caused him any symptoms at present, and he remains at work. His past medical history is unremarkable and he is not on any regular medication. He does not smoke and takes about 7 units of alcohol per week. On examination, he is comfortable at rest with a blood pressure of 125/65 mmHg and a pulse of 68/min, which is irregularly irregular. His jugular venous pressure is not raised and his chest is clinically clear. He has a variable S1 but no murmurs. Full blood count, urea and electrolytes, thyroid function tests, liver function tests, lipids and echocardiogram are all within normal limits. ECG shows atrial fibrillation.

Which one of the following medications would you start this patient on?

A	NOAC with a view to elective cardioversion
B	Diltiazem
C	Digoxin
D	Bisoprolol
E	Amiodarone

Submit

Audio Video Share Participants More

caused him any symptoms at present, and he remains at work. His past medical history is unremarkable and he is not on any regular medication. He does not smoke and takes about 7 units of alcohol per week. On examination, he is comfortable at rest with a blood pressure of 125/65 mmHg and a pulse of 68/min, which is irregularly irregular. His jugular venous pressure is not raised and his chest is clinically clear. He has a variable S1 but no murmurs. Full blood count, urea and electrolytes, thyroid function tests, liver function tests, lipids and echocardiogram are all within normal limits. ECG shows atrial fibrillation.

Which one of the following medications would you start this patient on?

Your answer was incorrect

A NOAC with a view to elective cardioversion

B Diltiazem

C Digoxin

D Bisoprolol

E Amiodarone

Explanation

A NOAC with a view to elective cardioversion

This is a young patient with no previous medical history and no obvious precipitant of his new-onset atrial fibrillation. Current NICE guidelines on the management of atrial fibrillation state that rate control [should be offerred] as the first-line strategy to people with atrial fibrillation, except in those (1) whose atrial fibrillation has a reversible

A NOAC with a view to elective cardioversion

This is a young patient with no previous medical history and no obvious precipitant of his new-onset atrial fibrillation. Current NICE guidelines on the management of atrial fibrillation state that rate control [should be offerred] as the first-line strategy to people with atrial fibrillation, except in those (1) whose atrial fibrillation has a reversible cause; (2) who have heart failure thought to be primarily caused by atrial fibrillation; (3) with new-onset atrial fibrillation; (4) with atrial flutter and whose condition is considered suitable for an ablation strategy to restore sinus rhythm; and (5) for whom a rhythm control strategy would be more suitable based on clinical judgement.

It would therefore seem appropriate in this case to offer elective cardioversion after a period of anticoagulation (minimum 3 weeks).

D Bisoprolol

While a beta blocker (other than sotalol) represents an appropriate rate control choice for patients with atrial fibrillation, this patient's young age and new-onset atrial fibrillation make rhythm control an appropriate management option.

B Diltiazem

While a rate-limiting calcium channel blocker such as diltiazem or verapamil represents an appropriate rate control choice for patients with atrial fibrillation, this patient's young age and new-onset atrial fibrillation make rhythm control an appropriate management option.

C Digoxin

Current NICE guidelines state that digoxin monotherapy is

12:00
On ...
594-042-7551
Leave

fibrillation make rhythm control an appropriate management option.

B Diltiazem

While a rate-limiting calcium channel blocker such as diltiazem or verapamil represents an appropriate rate control choice for patients with atrial fibrillation, this patient's young age and new-onset atrial fibrillation make rhythm control an appropriate management option.

C Digoxin

Current NICE guidelines state that digoxin monotherapy is suitable for people with non-paroxysmal atrial fibrillation only if they are sedentary (do no or very little physical exercise). This patient's young age and new-onset AF make rhythm control an appropriate management option.

E Amiodarone

While amiodarone represents an appropriate choice for pharmacological cardioversion and rate control, the uncertain onset of this patient's atrial fibrillation makes it an inappropriate choice prior to the initiation of suitable anticoagulation due to the risk of precipitating thromboembolic events if he were to cardiovert.

7489
Rate this question:

Audio Video Share Participants More

12:00

A 52-year-old male presents with a history of intermittent chest pain of three months' duration. The pain is perceived as a burning sensation, at times associated with epigastric fullness. It responds partially to antacids and for the last 10 days he has been taking lansoprazole 30 mg per day, but the frequency of chest pain has not decreased. He says it also sometimes comes on after exercise. The patient is a known hypertensive on indapamide 1.5 mg per day. He is a lifelong non-smoker and has no family history of premature coronary artery disease. A lipid profile checked a year ago was normal. His body mass index is 29. He has blood pressure of 140/85 mmHg, pulse rate of 88/min and respiratory rate of 12/min; examination of the cardiovascular system is normal.

Investigations:

Sodium	135 mmol/l
Potassium	4.5 mmol/l
Urea	8 mmol/l
Creatinine	120 µmol/l
Haemoglobin	14 g/dl
White cell count	10×10^9/l
Cardiac markers	Normal
Chest X-ray	Normal
Electrocardiogram (ECG)	Right bundle branch block (also seen in ECGs performed a year ago).

What is the next best step in the evaluation of this patient?

A 24 h oesophageal PH monitoring

B Thallium myocardial perfusion imaging

Rana Alnasser's screen

pressure of 140/85 mmHg, pulse rate of 88/min and respiratory rate of 12/min; examination of the cardiovascular system is normal.

Investigations:

Sodium	135 mmol/l
Potassium	4.5 mmol/l
Urea	8 mmol/l
Creatinine	120 µmol/l
Haemoglobin	14 g/dl
White cell count	10×10^9/l
Cardiac markers	Normal
Chest X-ray	Normal
Electrocardiogram (ECG)	Right bundle branch block (also seen in ECGs performed a year ago).

What is the next best step in the evaluation of this patient?

A 24 h oesophageal PH monitoring

B Thallium myocardial perfusion imaging

C Dobutamine stress echocardiography

D Exercise electrocardiography

E Oesophagoscopy

B Thallium myocardial perfusion imaging

This patient has an intermediate likelihood of coronary artery disease (CAD. His chest pain is atypical but as he is above 40 years and is hypertensive, he should be evaluated for coronary artery disease. Because exercise electrocardiography is not useful in this patient (see below), myocardial perfusion imaging is the preferred modality for evaluation of CAD. This patient has right bundle branch block. Exercise-induced ST segment depression in leads V_1 to V_4 is common in these patients, even in the absence of myocardial ischaemia. This reduces the specificity of stress electrocardiography as a diagnostic tool in such patients. Pharmacological stressors such as dobutamine or thallium can be used for myocardial perfusion. When comparing dobutamine stress versus thallium scanning, thallium has greater sensitivity, versus greater specificity for dobutamine with respect to coronary artery disease. As such, in this case with intermediate-likelihood CAD, thallium is the preferred option rather than dobutamine stress echocardiography. You may like to refer to the reference below for further information.

C Dobutamine stress echocardiography

Pharmacological stress in the form of dobutamine can be used in patients who are unable to exercise because of stroke, peripheral vascular disease or arthritis, although it should be avoided in WPW syndrome, patients with conduction abnormalities and those with ischaemia on resting ECG. When comparing dobutamine stress versus thallium scanning, thallium has greater sensitivity, versus greater specificity for dobutamine with respect to coronary artery disease. As such, in this case with intermediate-likelihood CAD, thallium is the preferred option rather than dobutamine stress echocardiography.

A 24 h oesophageal pH monitoring

determine whether the symptoms are definitely caused by reflux or by myocardial ischaemia.

D Exercise electrocardiography

Exercise electrocardiography is not useful in patients with any of the following:

- conduction abnormalities
- resting electrocardiogram (ECG) abnormalities such as ST-segment depression of >1 mm
- Wolff–Parkinson–White syndrome
- those taking digitalis
- those with ventricular paced rhythm.

E Oesophagoscopy

This patient might have gastro-oesophageal reflux disease; however, oesophagoscopy cannot determine whether the symptoms are definitely caused by reflux or by myocardial ischaemia.

Rate this question:

Next Question

Previous Q... Tag Questi... Feedback End Session

Blog About Pastest Contact Us Help

© Pastest 2019

12:09

MyPastest
https://mypastest.pastest.com

Pastest+

A 71-year-old man is admitted to the Emergency Department with cardiac failure. He suffered a myocardial infarction 6 weeks earlier and current medication includes ramipril 10 mg daily, aspirin 75 mg and atorvastatin 40 mg daily. Other past medical history of note includes severe COPD and chronic renal impairment. He appears lucid, although he is extremely short of breath and wants to discuss his resuscitation status.

Which of the following would have the most impact on the decision regarding a DNACPR order in this case?

A	Age
B	Co-morbidities
C	Patient's wish to be resuscitated no matter what
D	The patient's family's wishes
E	The views of his power of attorney

Submit

Previous Q...

Skip Questi...

12:11

MyPastest
https://mypastest.pastest.com

A 71-year-old man is admitted to the Emergency Department with cardiac failure. He suffered a myocardial infarction 6 weeks earlier and current medication includes ramipril 10 mg daily, aspirin 75 mg and atorvastatin 40 mg daily. Other past medical history of note includes severe COPD and chronic renal impairment. He appears lucid, although he is extremely short of breath and wants to discuss his resuscitation status.

Which of the following would have the most impact on the decision regarding a DNACPR order in this case?

Your answer was correct

A	Age
B	Co-morbidities
C	Patient's wish to be resuscitated no matter what
D	The patient's family's wishes
E	The views of his power of attorney

Explanation

B Co-morbidities

Whilst selected elderly patients may do as well as younger patients post-resuscitation, those with co-morbidities have

B Co-morbidities

Whilst selected elderly patients may do as well as younger patients post-resuscitation, those with co-morbidities have a survival to hospital discharge of only around 5%. The key is in open discussion with the patient and their family, in order to reach a shared decision. This is emphasised by the recent court cases of Tracey vs Cambridge University Hospitals NHSFT [2014] and Winspear v City Hospitals Sunderland NHSFT [2015].

A Age

While it can be considered as part of the decision-making prcess, the BMA/RCN/Resus Council Guidance is clearthat "blanket policies that deny CPR or apply CPR to groups of people, for example to all patients above or below a certain age, are unethical and probablu unlawful. It is imprtant to consider the patient as a whole and not make decisions solely based on factors such as age.

C Patient's wish to be resuscitated no matter what

While it is, of course, vitally important to take into consideration the views of the patient, if it is felt that resuscitation would be futile on clinical grounds, or not in your patient's best interests, there is no obligation on the treating team to offer it.

D The patient's family's wishes

While it is, of course, vitally important to take into consideration the views of the patient's family (and particularly where these differ from those of the patient, careful discussion is key), if it is felt that resuscitation would be futile on clinical grounds, or not in your patient's best interests, there is no obligation to offer it.

consideration the views of the patient, if it is felt that resuscitation would be futile on clinical grounds, or not in your patient's best interests, there is no obligation on the treating team to offer it.

D The patient's family's wishes

While it is, of course, vitally important to take into consideration the views of the patient's family (and particularly where these differ from those of the patient, careful discussion is key), if it is felt that resuscitation would be futile on clinical grounds, or not in your patient's best interests, there is no obligation to offer it.

E The views of his power of attorney

We are told that this patient is lucid and keen to discuss his recuscitation status. We are not given any indication that he lacks capacity, which is the point at which a power of attorney would take effect. However, it remains important that the views of those close to the patient are sought and considered in the decision-making process.

Rate this question:

Next Question

Previous Q... Tag Questi... Feedback End Session

Blog About Pastest Contact Us Help

© Pastest 2019

Rana Alnasser's screen

You are a care of the elderly senior house officer. The Emergency Department registrar refers an 80-year-old man to you, who presented with light-headedness and palpitations. He gives a 2-year history of palpitations associated with dizziness that can occur any time during the day. He cannot identify any associated aggravating or alleviating factors. There is a history of hypertension and benign prostatic hypertrophy. His current medications are bendroflumethiazide 2.5 mg daily, atenolol 100 mg daily and tamulosin 0.4 mg daily. The presentation electrocardiogram (ECG) shows sinus rhythm with a rate of 56 beats/min. A lying and standing blood pressure shows 5 mmHg systolic variation.

You decide to admit this man for observations and you ask the nurses to keep him on cardiac telemetry.

The following morning you review the overnight rhythm strips (selected portions above) and are surprised to find the significant changes.

What is the next step in your management?

A	Add digoxin to the current regime
B	Reduce the dose of beta blocker and review in 6 weeks
C	Stop the beta blocker and review in 6 weeks

the nurses to keep him on cardiac telemetry.

The following morning you review the overnight rhythm strips (selected portions above) and are surprised to find the significant changes.

What is the next step in your management?

A	Add digoxin to the current regime
B	Reduce the dose of beta blocker and review in 6 weeks
C	Stop the beta blocker and review in 6 weeks
D	Reduce the dose of atenolol and arrange for a 72h Holter monitor
E	Reduce the dose of atenolol and arrange for pacemaker insertion

Submit

Rana Alnasser's screen

Explanation

E	Reduce the dose of atenolol and arrange for pacemaker insertion

This man has sick sinus syndrome – there is sinus bradycardia with episodes of atrial fibrillation in the rhythm strips. The treatment is insertion of a dual-chamber pacemaker. The high dose of atenolol may also have contributed to his symptoms of syncope, and can potentially be reduced to 50 mg.

A	Add digoxin to the current regime

Digoxin won't reduce the risk of paroxysmal AF and may exacerbate periods of symptomatic tachycardia.

B	Reduce the dose of beta blocker and review in 6 weeks

This risks further symptoms related to paroxysmal AF; discharging without review for a period of 6 weeks is therefore not advised.

C	Stop the beta blocker and review in 6 weeks

Stopping the beta blocker will almost certainly result in further presentation with episodes of paroxysmal AF, and may only have limited impact on the episodes of bradycardia.

D	Reduce the dose of atenolol and arrange for a 72h Holter monitor

All the information required to decide on further management, (episodes of bradycardia and paroxysmal AF) is provided on the rhythm strips. As such, a Holter

Digoxin won't reduce the risk of paroxysmal AF and may exacerbate periods of symptomatic tachycardia.

B Reduce the dose of beta blocker and review in 6 weeks

This risks further symptoms related to paroxysmal AF; discharging without review for a period of 6 weeks is therefore not advised.

C Stop the beta blocker and review in 6 weeks

Stopping the beta blocker will almost certainly result in further presentation with episodes of paroxysmal AF, and may only have limited impact on the episodes of bradycardia.

D Reduce the dose of atenolol and arrange for a 72h Holter monitor

All the information required to decide on further management, (episodes of bradycardia and paroxysmal AF) is provided on the rhythm strips. As such, a Holter monitor is not required to decide on next steps.

Rate this question:

A 19-year-old man who was adopted soon after birth presents to the cardiology clinic for a consultation. He had attempted to trace his family and was informed by his blood relatives that his father died suddenly of a 'heart problem'. On examination he looks well but has a harsh systolic murmur which increases with the Valsalva manoeuvre and decreases with squatting. Echocardiography reveals ventricular hypertrophy, particularly of the septum, with increased ejection fraction. Outflow gradient measured by echocardiography is 35 mmHg.

What is the treatment of choice in this patient if he was to develop symptoms of dyspnoea?

A Cardiac myomectomy

B Digoxin

C Beta-blockade

D Diuretic therapy

E Nitrate therapy

Submit

A 19-year-old man who was adopted soon after birth presents to the cardiology clinic for a consultation. He had attempted to trace his family and was informed by his blood relatives that his father died suddenly of a 'heart problem'. On examination he looks well but has a harsh systolic murmur which increases with the Valsalva manoeuvre and decreases with squatting. Echocardiography reveals ventricular hypertrophy, particularly of the septum, with increased ejection fraction. Outflow gradient measured by echocardiography is 35 mmHg.

What is the treatment of choice in this patient if he was to develop symptoms of dyspnoea?

Your answer was correct

A Cardiac myomectomy

B Digoxin

C Beta-blockade

D Diuretic therapy

E Nitrate therapy

Explanation

C Beta-blockade

This patient has hypertrophic obstructive cardiomyopathy (HOCM). The disease exists in two major forms: a familial

Explanation

C Beta-blockade

This patient has hypertrophic obstructive cardiomyopathy (HOCM). The disease exists in two major forms: a familial one that presents in young patients and has been mapped to chromosome 14q, and a sporadic form usually found in the elderly. In HOCM there is marked hypertrophy of the myocardium with a disproportionate increase in the size of the septum. Sufferers are prone to sudden death related to cardiac arrhythmias. Symptoms of cardiac failure respond initially to medical therapy with beta blockade, and this is therefore the initial intervention of choice.

A Cardiac myomectomy

Myomectomy is reserved for patients where the outflow gradient is greater than 50 mmHg or there are significant symptoms despite beta blocker therapy. Surgery is usually avoided for as long as possible. Ventricular arrhythmias are managed with an implantable cardioverter defibrillator.

B Digoxin

Digoxin has no effect on outcome in HOCM and is now largely reserved for elderly patients with AF not suitable for other interventions, and for those elderly patients with symptomatic heart failure despite other interventions.

D Diuretic therapy

Diuretic therapy does not improve outcomes in HOCM and should be used cautiously because of its effect on left ventricular volume.

E Nitrate therapy

gradient is greater than 50 mmHg or there are significant symptoms despite beta blocker therapy. Surgery is usually avoided for as long as possible. Ventricular arrhythmias are managed with an implantable cardioverter defibrillator.

B Digoxin

Digoxin has no effect on outcome in HOCM and is now largely reserved for elderly patients with AF not suitable for other interventions, and for those elderly patients with symptomatic heart failure despite other interventions.

D Diuretic therapy

Diuretic therapy does not improve outcomes in HOCM and should be used cautiously because of its effect on left ventricular volume.

E Nitrate therapy

Nitrate therapy can significantly reduce ventricular filling pressure and exacerbate the risk of syncope in HOCM.

Rate this question:

© Pastest 2019

A 61-year-old patient has called 999 with a history of central crushing chest pain radiating down his left arm. He has a history of hypertension treated with atenolol and smokes 20 cigarettes per day. On examination by the paramedic crew his BP was 100/60 mmHg, with a pulse of 38/min; initial ECG is suggestive of complete heart block with ST elevation in II, III (maximally) and aVF, and ST depression in aVL. On arrival he continues to have further chest pain and his BP is now 85/60 mmHg. You notice that his JVP is elevated. His chest is clear and there is no evidence of peripheral oedema.

Investigations:

Hb	13.1 g/dl
WCC	8.2 x10^9/l
PLT	199 x10^9/l
Na^+	138 mmol/l
K^+	4.9 mmol/l
Creatinine	156 µmol/l

Which coronary artery is most likely to be affected?

A	Left anterior descending
B	Circumflex
C	Right coronary artery
D	Left main stem
E	Diagonal

C Right coronary artery

The presentation with initial complete heart block followed by hypotension with a raised JVP is highly suggestive of right ventricular infarction. Management includes optimising right ventricular filling pressure, and closely monitoring pressures with a pulmonary artery catheter where appropriate. Once filling is optimised, if hypotension persists, addition of inotropes may be required. He should be considered for urgent primary PCI to open the culprit artery.

A Left anterior descending

Occlusion of the left anterior descending would be expected to cause an anterior STEMI. This would be associated with ST elevation in the precordial leads (particularly V_2-V_4), and reciprocal ST depression in the inferior leads. The more extensive the area of ischaemic myocardium (i.e. the more proximal the occlusion), the more leads will demonstrate ST elevation.

B Circumflex

In patients with a right dominant circulation (the majority of patients), the right coronary artery supplies the posterior descending artery. In this case, the circumflex artery supplies the posterolateral wall of the left ventricle, and ST changes would be those of posterior infarction (i.e. ST depression in V_1-V_3 with tall, broad R waves). If the patient has a left dominant circulation, the circumflex also supplies the posterior descending artery, and inferior ST changes will also be seen (i.e. ST elevation in II, III and aVF).

D Left main stem

Left main stem occlusion is associated with diffuse ST

A 27-year-old woman who has recently arrived to the UK from India is referred to the Cardiology Department because of intermittent palpitations associated with dizziness. She describes the palpitations as fast and irregular, with sudden onset and termination. She remembers a prolonged illness as a child but is unsure as to the nature of this. Additionally she reports that she suffers from asthma.

On examination, she appears comfortable but underweight. Her pulse is 80 beats/min and regular, the jugular venous pressure is not raised and there is no peripheral oedema. There is a rumbling diastolic murmur over the apex on auscultation of the heart and the chest is clear.

An echocardiogram performed confirms the presence of rheumatic mitral stenosis. The patient is referred for a cardiothoracic opinion.

Two weeks later, she attends the Emergency Department feeling extremely unwell. She has suffered from fast palpitations for 20 minutes before calling the ambulance. On arrival, she is found to be in atrial fibrillation with a rate of 145 beats/min, a blood pressure of 110/70 mmHg and oxygen saturations of 95% on air. She is placed in the resuscitation area for closer monitoring.

Which of the following would be the best pharmacological intervention?

A	Intravenous (iv) esmolol
B	Oral digoxin
C	iv amiodarone
D	iv flecainide
E	DC Cardioversion

12:23

An echocardiogram performed confirms the presence of rheumatic mitral stenosis. The patient is referred for a cardiothoracic opinion.

Two weeks later, she attends the Emergency Department feeling extremely unwell. She has suffered from fast palpitations for 20 minutes before calling the ambulance. On arrival, she is found to be in atrial fibrillation with a rate of 145 beats/min, a blood pressure of 110/70 mmHg and oxygen saturations of 95% on air. She is placed in the resuscitation area for closer monitoring.

Which of the following would be the best pharmacological intervention?

Your answer was correct

A Intravenous (iv) esmolol

B Oral digoxin

C iv amiodarone

D iv flecainide

E DC Cardioversion

Explanation

C iv amiodarone

Amiodarone is a class III antiarrhythmic agent. It is the most suitable option to attempt re-attaining sinus rhythm in this patient. In the Emergency situation, it can be given through a peripheral line to avoid the need to wait for central line insertion.

Rana Alnasser's screen

12:23

C iv amiodarone

Amiodarone is a class III antiarrhythmic agent. It is the most suitable option to attempt re-attaining sinus rhythm in this patient. In the Emergency situation, it can be given through a peripheral line to avoid the need to wait for central line insertion.

A Intravenous (iv) esmolol

IV β-blockade would be appropriate in most patients, and here it would provide rapid rate control and would likely improve cardiac output. It would also be appropriate despite the low blood pressure (which is likely secondary to rate-related reduced cardiac output). However, the patient reports a history of asthma, which is a relative contraindication to the use of a β-blocker in this setting.

B Oral digoxin

Oral digoxin has a slow onset of action and will likely take several hours to have a significant effect in this patient.

D iv flecainide

This patient has a history of rheumatic heart disease with mitral stenosis and requires either rapid rate or rhythm control. Patients with mitral stenosis do poorly in atrial fibrillation. Unfortunately, concern exists about the use of flecainide in patients with 'structural heart disease', , which means it carries a label contra-indication for patients with haemodynamically significant valvular heart disease. This concern came about following the results of the CAST trial which examined the use of flecainide in the acute post-MI period.

The Cardiac Arrhythmia Suppression Trial Investigators: Preliminary report: Effect of encainide and flecainide on

Rana Alnasser's screen

patient reports a history of asthma, which is a relative contraindication to the use of a β-blocker in this setting.

B Oral digoxin

Oral digoxin has a slow onset of action and will likely take several hours to have a significant effect in this patient.

D iv flecainide

This patient has a history of rheumatic heart disease with mitral stenosis and requires either rapid rate or rhythm control. Patients with mitral stenosis do poorly in atrial fibrillation. Unfortunately, concern exists about the use of flecainide in patients with 'structural heart disease', , which means it carries a label contra-indication for patients with haemodynamically significant valvular heart disease. This concern came about following the results of the CAST trial which examined the use of flecainide in the acute post-MI period.

The Cardiac Arrhythmia Suppression Trial Investigators: Preliminary report: Effect of encainide and flecainide on mortality in a randomized trial of arrhythmia suppression after myocardial infarction. *N Engl J Med* 1989;321(6):406-412.

E DC Cardioversion

This patient requires rapid rate or rhythm control to improve cardiac output. DC cardioversion may well be required if the patient deteriorates further. However, currently she is stable with no features of myocardial ischaemia, heart failure, syncope or hypoperfusion. As such, alternative treatment options should be considered initially.

Rate this question:

A 78-year-old woman with a history of ischaemic heart disease and left ventricular failure is admitted with urinary sepsis. According to her daughter, she has been unwell for some days and is now drowsy and confused.

On examination, she looks dry, she is pyrexial 38.2 °C, and is agitated when you press over her lower abdomen. Her blood pressure (BP) is 95/50 mmHg and her pulse is 98/min.

Investigations:

Hb	13.9 g/dl
WCC	13.1×10^9/l
PLT	94×10^9/l
Na^+	139 mmol/l
K^+	5.6 mmol/l
Creatinine	225 µmol/l
Urine	White cells ++, protein +, red cells +

You arrange admission to the ITU for monitoring of fluid balance.

Which of the following cardiac catheterisation results would fit with this clinical picture?

A	Pulmonary artery systolic pressure = 44 mmHg
B	Left ventricular systolic pressure = 95 mmHg
C	Right atrial pressure = 15 mmHg
D	Pulmonary artery wedge pressure = 0 mmHg
E	Right ventricular pressure = 23 mmHg

Explanation

B Left ventricular systolic pressure = 95 mmHg

The clinical picture is one suggestive of a gram negative sepsis secondary to a urinary tract infection. She requires fluid resuscitation and prompt antibiotic therapy. Given he septic state, she is likely to have a reduced circulating volume. A left ventricular systolic pressure of 95 mmHg is low; however, this would be in keeping with profound sepsis.

A Pulmonary artery systolic pressure = 44 mmHg

This value is significantly higher than the normal range (12 16 mmHg). This would be suggestive of profound pulmonary hypertension; there is no suggestion of this diagnosis from the clinical picture.

C Right atrial pressure = 15 mmHg

This value is significantly higher than the normal range (2- mmHg). Right atrial pressure is a marker of fluid status. It would be expected that the right atrial pressure would be low in someone with profound sepsis.

D Pulmonary artery wedge pressure = 0 mmHg

Pulmonary wedge pressure is considered to be a surrogat for left atrial pressure (normal range 8-10 mmHg). A pressure of 0 mmHg would suggest that there was no pressure in the left atrium. Although the pressure is likely to be reduced in the left atrium due to the fluid underload a pressure of 0 mmHg is not sustainable with an active circulation.

E Right ventricular pressure = 23 mmHg

12:30
On Pastest 594-042-7551 Question 23 of 123 Leave

A Pulmonary artery systolic pressure = 44 mmHg

This value is significantly higher than the normal range (12-16 mmHg). This would be suggestive of profound pulmonary hypertension; there is no suggestion of this diagnosis from the clinical picture.

C Right atrial pressure = 15 mmHg

This value is significantly higher than the normal range (2 mmHg). Right atrial pressure is a marker of fluid status. It would be expected that the right atrial pressure would be low in someone with profound sepsis.

D Pulmonary artery wedge pressure = 0 mmHg

Pulmonary wedge pressure is considered to be a surrogat for left atrial pressure (normal range 8-10 mmHg). A pressure of 0 mmHg would suggest that there was no pressure in the left atrium. Although the pressure is likely to be reduced in the left atrium due to the fluid underload a pressure of 0 mmHg is not sustainable with an active circulation.

E Right ventricular pressure = 23 mmHg

The pressure quoted is within the normal range (15-30 mmHg) which would not be expected in this situation. Th poor venous return in this clinical situation should result i lower right-sided cardiac pressures.

Rate this question:

Next Question

Audio Video Share Participants More

Touc... 00:36 12:31
Off Pastest 594-042-7551 Question 24 of 192 Leave

A 74-year-old woman is brought by ambulance to hospita after feeling faint while praying in church. Her friend from the church says that she had a heart attack a few years earlier, and has complained of palpitations on a few occasions since but has been relatively well, although she has fainted on two previous occasions recently. Medications include ramipril 10mg daily, aspirin 75mg and simvastatin 40mg. On examination she has a pulse of 170 beats per minute with a blood pressure of 110/75 mmHg. There are no signs of left ventricular failure.

Her ECG is shown below:

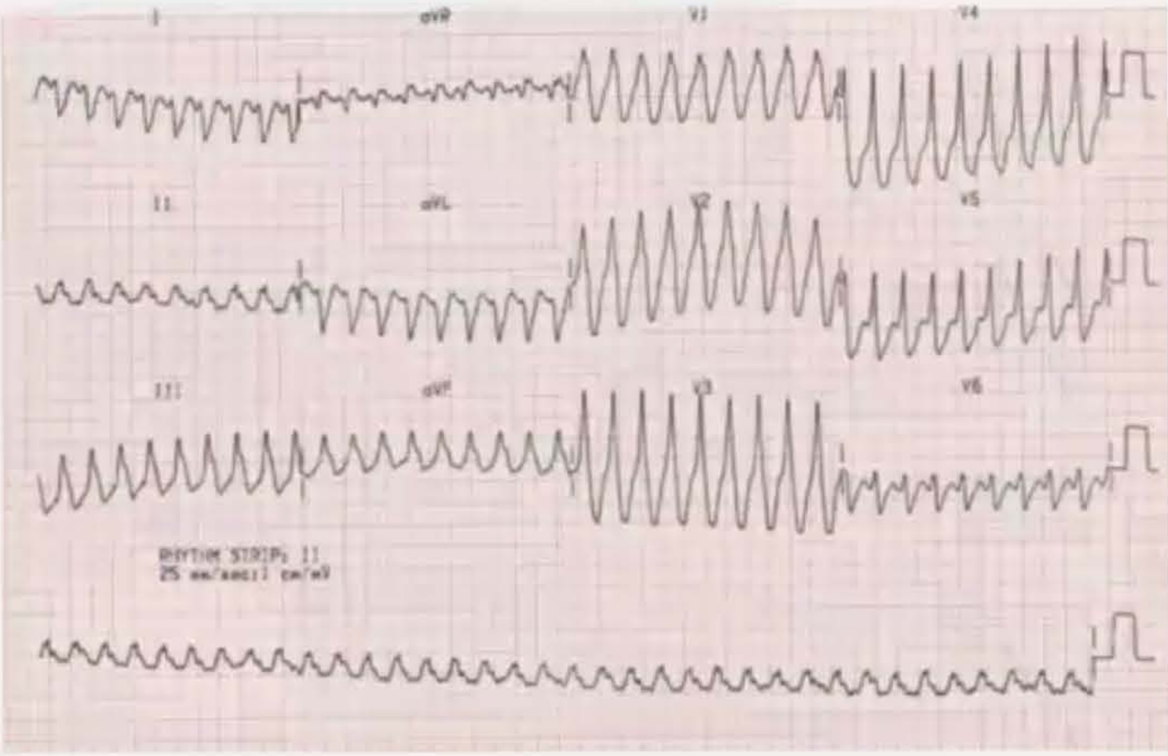

Which of the following is the most likely diagnosis?

A	Ventricular tachycardia
B	SVT with right bundle branch block
C	Sinus tachycardia
D	Atrial fibrillation with right bundle branch block

Audio Video Share Participants More

the church says that she had a heart attack a few years earlier, and has complained of palpitations on a few occasions since but has been relatively well, although she has fainted on two previous occasions recently. Medications include ramipril 10mg daily, aspirin 75mg and simvastatin 40mg. On examination she has a pulse of 170 beats per minute with a blood pressure of 110/75 mmHg. There are no signs of left ventricular failure.

Her ECG is shown below:

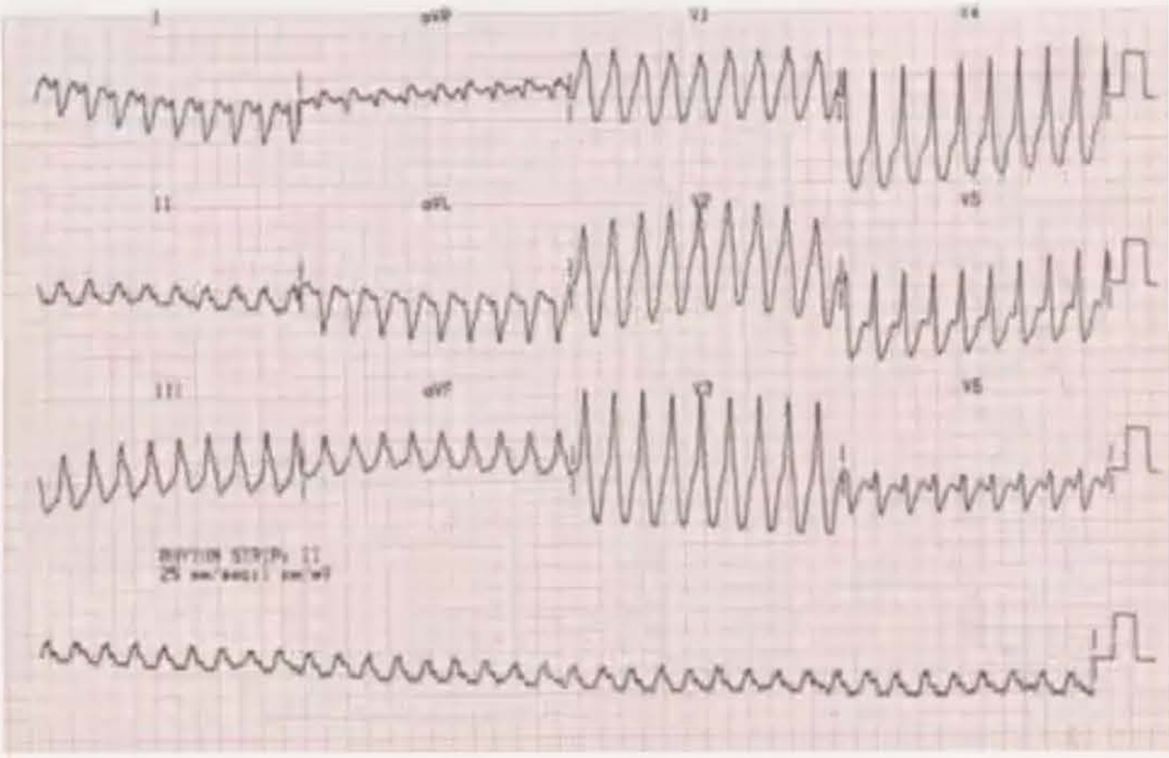

Which of the following is the most likely diagnosis?

A	Ventricular tachycardia
B	SVT with right bundle branch block
C	Sinus tachycardia
D	Atrial fibrillation with right bundle branch block
E	SVT with left bundle branch block

12:35
On
594-042-7551
Leave

B SVT with right bundle branch block

The ECG shows a RBBB pattern and with the regular rhythm and absence of p-waves, SVT is the likely cause of the patient's tachycardia. Flecanide should not be used in this situation with a history of previous ischaemic heart disease, and verapamil can lead to a significant reduction in cardiac output, as such these are best avoided. The use of adenosine to cardiovert the patient would be appropriate in the setting of appropriate resuscitation facilities. It will also help uncover the underlying rhythm should there be any doubt. If the patient is compromised, synchronised DC cardioversion would be the most appropriate treatment option.

A Ventricular tachycardia

With the past history of MI, this could represent VT secondary to scar tissue. However, the absence of negative/positive concordance (deflecting in the same direction) in the chest leads and lack of haemodynamic compromise (normal BP, no evidence of HF), makes VT less likely.

C Sinus tachycardia

There are no visible P waves therefore it is unlikely to be sinus tachycardia.

D Atrial fibrillation with right bundle branch block

The rhythm of the ECG is regular, making it unlikely to be AF.

E SVT with left bundle branch block

Positive deflection in V1 and negative deflection in V6 is

Audio Video Share Participants More

An 18-year-old woman is brought into the accident and emergency department with an abrupt onset 30 min previously of severe chest pain. She describes the pain as 'tearing' and says it radiates into her jaw. There is no past history of cardiovascular disease. The past history is significant for primary amenorrhoea. Blood pressure is 170/110 mmHg in the right arm and 145/90 mmHg in the left, pulse rate is 120/min regularly regular, and she is afebrile. On examination the patient appears in distress and you note a diastolic murmur, muffled heart sounds and a raised JVP. You also notice that the patient is of short stature and has a broad neck. An electrocardiogram (ECG) is performed and reveals sinus tachycardia and widespread ST depression. A portable chest X-ray is performed and reveals a widened mediastinum. You suspect aortic dissection.

What is the likely underlying diagnosis?

A Turner's syndrome

B Pseudoxanthoma elasticum

C Noonan syndrome

D Marfan syndrome

E Osteogenesis imperfecta

32354

Submit

with widely spaced nipples, and aortic dissection in adulthood. Aortic dissection characteristically presents with a very abrupt onset of chest pain which differentiates it from the other differentials. The mediastinum is widened on the chest X-ray in many cases of aortic dissection. Around 2/3rds of dissections in Turner's arise in the ascending aorta. Epidemiological data suggests that the incidence of aortic dissection is many times higher for young women with Turner's versus age matched controls. The annual incidence is 15/100,000 years for those<20 years, and is 73-78/100,000 years for those 20-40 years of age. This is against an incidence of 6/100,000 years for those without Turner's syndrome.

B Pseudoxanthoma elasticum

PXE is a genetic condition that can cause early onset atherosclerosis. It typically causes cutaneous and ophthalmic changes which are not described in the case. It is caused by an autosomal recessive gene mutation in ABCC6 gene on chromosome 16.

C Noonan syndrome

Noonan syndrome is the male version of Turner's syndrome with similar characteristics. It is associated with ASDs, VSDs and pulmonary stenosis.

D Marfan syndrome

Marfan's syndrome is a connective tissue disease. Patients typically are tall and thin with long arms and legs. It is very commonly associated with aortopathy and can present with aortic dissection.

E Osteogenesis imperfecta

A Turner's syndrome

This patient fits the description for Turner's syndrome – Amenorrhoea, short stature and broad neck. The presenting complain of chest pain is highly suggestive of aortic dissection and is supported by the clinical findings of blood pressure difference, diastolic murmur (AR), muffled heart sounds (effusion) and widened mediastinum.

Turner's syndrome is a chromosomal disorder resulting from the 45X karyotype. It is characterised by short stature, ovarian failure with primary or secondary amenorrhoea, webbed neck, cubitus valgus, a broad chest with widely spaced nipples, and aortic dissection in adulthood. Aortic dissection characteristically presents with a very abrupt onset of chest pain which differentiates it from the other differentials. The mediastinum is widened on the chest X-ray in many cases of aortic dissection. Around 2/3rds of dissections in Turner's arise in the ascending aorta. Epidemiological data suggests that the incidence of aortic dissection is many times higher for young women with Turner's versus age matched controls. The annual incidence is 15/100,000 years for those<20 years, and is 73-78/100,000 years for those 20-40 years of age. This is against an incidence of 6/100,000 years for those without Turner's syndrome.

B Pseudoxanthoma elasticum

PXE is a genetic condition that can cause early onset atherosclerosis. It typically causes cutaneous and ophthalmic changes which are not described in the case. It is caused by an autosomal recessive gene mutation in ABCC6 gene on chromosome 16.

C Noonan syndrome

A 38-year-old male has been found to have elevated blood pressure (BP) on several occasions over the last three months. His systolic BP has been around 155 mmHg and diastolic 95 mmHg. He has 5-pack-year history of smoking and consumes 3-4 units of alcohol per day. He has no personal or family history of coronary artery disease, stroke or diabetes. His weight is 93 kg and height 162 cm, and the rest of physical examination is unremarkable. His electrocardiogram (ECG) and chest X-ray are normal.

Investigations:

Cholesterol	5.2 mmol/l
High-density lipoprotein	1 mmol/l
Triglycerides	2.9 mmol/l
Sodium	140 mmol/l
Potassium	4.1 mmol/l
Bicarbonate	26 mmol/l
Chloride	104 mmol/l
Creatinine	93 mmol/l

You have advised him about lifestyle modification.

Which of the following lifestyle modifications will produce the most reduction in BP?

A Weight reduction to 83 kg

B Diet rich in fruits and vegetables and low in fat

C Moderation of alcohol consumption

D Reduce dietary sodium to less than 6 g/day

personal or family history of coronary artery disease, stroke or diabetes. His weight is 93 kg and height 162 cm, and the rest of physical examination is unremarkable. His electrocardiogram (ECG) and chest X-ray are normal.

Investigations:

Cholesterol	5.2 mmol/l
High-density lipoprotein	1 mmol/l
Triglycerides	2.9 mmol/l
Sodium	140 mmol/l
Potassium	4.1 mmol/l
Bicarbonate	26 mmol/l
Chloride	104 mmol/l
Creatinine	93 mmol/l

You have advised him about lifestyle modification.

Which of the following lifestyle modifications will produce the most reduction in BP?

A Weight reduction to 83 kg

B Diet rich in fruits and vegetables and low in fat

C Moderation of alcohol consumption

D Reduce dietary sodium to less than 6 g/day

E Regular exercise without significant weight reduction

12:44
On MyPastest https://mypastest.pastest.com 594-042-7551 Leave

A Weight reduction to 83 kg

This patient has mild hypertension (systolic BP 140–159 mmHg, diastolic BP 90–99 mmHg) and has no evidence of target organ damage. The British Hypertensive Society does not recommend starting antihypertensive therapy in such patients, but lifestyle modifications should be encouraged. Of all the lifestyle modifications described, weight reduction produces the greatest reduction in BP. A 10 kg weight loss is expected to decrease BP by 15–20 mmHg; the effect of other lifestyle modifications on hypertension, as mentioned in the other options, is less than this.

B Diet rich in fruits and vegetables and low in fat

This will only reduce the blood pressure by 8–14 mm Hg.

C Moderation of alcohol consumption

This is defined as less than 14 units a week for both men and women. It will only reduce the blood pressure by 2.5–4.0 mmHg.

D Reduce dietary sodium to less than 6 g/day

This measure will only reduce the blood pressure by 2–8 mmHg.

E Regular exercise without significant weight reduction

This measure will only reduce the blood pressure by 4–9

Audio Video Share Participants More

mmHg; diastolic BP 90–99 mmHg) and has no evidence of target organ damage. The British Hypertensive Society does not recommend starting antihypertensive therapy in such patients, but lifestyle modifications should be encouraged. Of all the lifestyle modifications described, weight reduction produces the greatest reduction in BP. A 10 kg weight loss is expected to decrease BP by 15–20 mmHg; the effect of other lifestyle modifications on hypertension, as mentioned in the other options, is less than this.

B	Diet rich in fruits and vegetables and low in fat

This will only reduce the blood pressure by 8–14 mm Hg.

C	Moderation of alcohol consumption

This is defined as less than 14 units a week for both men and women. It will only reduce the blood pressure by 2.5–4.0 mmHg.

D	Reduce dietary sodium to less than 6 g/day

This measure will only reduce the blood pressure by 2–8 mmHg.

E	Regular exercise without significant weight reduction

This measure will only reduce the blood pressure by 4–9 mmHg.

Rate this question:

Next Question

You are the SHO in the Cardiology Clinic and wish to start Mr D, who has recently been diagnosed with hypertension, on an agent in addition to his ACE inhibitor. He is a type 2 diabetic who is currently diet-controlled. His BP is 155/90 mmHg.

Which of the following is the most appropriate next agent?

A Diltiazem

B Valsartan

C Atenolol

D Amlodipine

E Bendroflumethiazide

Submit

© Pastest 2019

D Amlodipine

Recommendations from the NICE hypertension guidelines recommend the addition of a CCB as step 2 agent, if hypertension is inadequately controlled on ACEi monotherapy. Beta-blockers and thiazides are not recommended as first- or second-line agents due to data around their adverse event profile with respect to the impact they have on blood glucose control. As such, amlodipine is the next logical choice as diltiazem is cardioselective and may precipitate bradycardia.

A Diltiazem

This is a cardioselective, negatively inotropic, calcium channel blocker and is not recommended as it may precipitate bradycardia.

B Valsartan

Valsartan is an angiotensin receptor blocker. It can be used in combination with ACE inhibition in the treatment of heart failure. In combination with ACE inhibition, valsartan can cause hyperkalaemia and it is therefore not the optimal second-line agent here.

C Atenolol

Beta-blockers are not recommended as first- or second-line agents in diabetics due to data around their adverse impact on blood glucose control.

E Bendroflumethiazide

Thiazide diuretics are not recommended as first- or second-line agents in diabetics due to their adverse impact on blood glucose control.

A 68-year-old male presents with history of retrosternal chest pain that started suddenly 6 h ago, radiated to the left arm and lasted for 30 min. About 20 min ago the pain started again. He was diagnosed with hypercholesterolaemia 2 years earlier, and is taking atorvastatin 40 mg/day. On physical examination, his pulse rate is 52/min, blood pressure is 95/55 mmHg and respiratory rate is 22/min. There is no jugular venous distension, heart sounds are normal and his chest is clear to auscultation. Electrocardiogram (ECG) reveals 1.5 mm ST segment depression in lateral leads. The patient is administered chewable aspirin 300 mg, sublingual nitroglycerine, morphine and fondaparinux. Hs-troponin is significantly elevated.

Which additional medication should be administered to this patient?

A Atenolol

B Clopidogrel

C Streptokinase

D Abciximab

E Dopamine

Submit

A 68-year-old male presents with history of retrosternal chest pain that started suddenly 6 h ago, radiated to the left arm and lasted for 30 min. About 20 min ago the pain started again. He was diagnosed with hypercholesterolaemia 2 years earlier, and is taking atorvastatin 40 mg/day. On physical examination, his pulse rate is 52/min, blood pressure is 95/55 mmHg and respiratory rate is 22/min. There is no jugular venous distension, heart sounds are normal and his chest is clear to auscultation. Electrocardiogram (ECG) reveals 1.5 mm ST segment depression in lateral leads. The patient is administered chewable aspirin 300 mg, sublingual nitroglycerine, morphine and fondaparinux. Hs-troponin is significantly elevated.

Which additional medication should be administered to this patient?

Your answer was incorrect

A Atenolol

B Clopidogrel

C Streptokinase

D Abciximab

E Dopamine

Explanation

B Clopidogrel

B Clopidogrel

This patient has non-ST segment elevation myocardial infarction (NSTEMI). Pharmacotherapy for NSTEMI includes antiplatelet therapy in the form of aspirin and clopidogrel, fondaparinux and other agents such as beta-blockers, GTN and angiotensin-converting enzyme inhibitors. However, beta-blockade, nitrates and ACE inhibitors are contraindicated if there is significant hypotension.

D Abciximab

Abciximab is a IIbIIIa platelet inhibitor, and is usually considered in patients with a STEMI where PCI is planned.

A Atenolol

Although introducing atenolol is associated with positive CV outcomes post MI, in this situation with hypotension and relative bradycardia it may lead to significant cardiovascular instability.

C Streptokinase

Thrombolysis isn't indicated in the treatment of NSTEMI; in STEMI, PCI is the preferred intervention.

E Dopamine

Dobutamine is an inotrope. Inotropes are used with caution in the acute MI setting because of the risk that they may actually worsen myocardial ischaemia with only a limited effect on blood pressure.

Rate this question:

A 45-year-old lorry driver presents to the Emergency Department with central crushing chest pain. His initial electrocardiogram (ECG) shows ST elevations in leads V_2–V_5. The patient is undergoes primary percutaneous coronary intervention with one stent to his left anterior descending coronary artery. Following an uneventful 5-day period he is discharged home on aspirin 75 mg, ticagrelor 90 mg bd, bisoprolol 5 mg, ramipril 2.5 mg and atorvastatin 80 mg. He would like to know when he can go back to work. There is no residual chest pain.

Which of the following statements is correct?

A	He has to stop driving, inform the Driver and Vehicle Licensing Agency (DVLA) and return for an exercise tolerance test in 6 weeks on the current regime
B	He has to stop driving, inform the DVLA and return for an exercise tolerance test in 6 weeks after he has stopped his bisoprolol for 48 h
C	He has to stop driving, inform the DVLA and return for an exercise tolerance test in 6 weeks after he has stopped all his medications for 48 h
D	He has to stop driving, inform the DVLA and return for a modified exercise tolerance test in 6 weeks after he has stopped all his medications for 48 h
E	He can return to driving in one month provided an ECG shows preserved left ventricular function

B He has to stop driving, inform the DVLA and return for an exercise tolerance test in 6 weeks after he has stopped his bisoprolol for 48 h

For vocational (Group 2) drivers, the DVLA guidelines state that the patient has to complete stage 3 of a Bruce protocol exercise tolerance test. There should be no residual chest pain or significant ECG changes. The only anti-anginal medication this patient is on is bisoprolol, and his symptoms are stable; if it is stopped before the test, this increases the chances of achieving the target heart rate Bruce stage 3. Before speaking to the patient, the DVLA guidelines on the subject can be found on the DVLA website if in doubt (see below).

A He has to stop driving, inform the Driver and Vehicle Licensing Agency (DVLA) and return for an exercise tolerance test in 6 weeks on the current regime

The beta-blocker is stopped to ensure a satisfactory response of heart rate to exercise.

C He has to stop driving, inform the DVLA and return for an exercise tolerance test in 6 weeks after he has stopped all his medications for 48 h

Early cessation of anti-platelets is associated with a high risk of stent thrombosis.

D He has to stop driving, inform the DVLA and return for a modified exercise tolerance test in 6 weeks after he has stopped all his medications for 48 h

A standard Bruce test must be completed.

A 67-year-old man presents with exertional breathlessness and intermittent palpitations.

On examination, his pulse is found to be irregularly irregular at a rate of 120 bpm. The apex is displaced to the anterior axillary line. Auscultation of his heart reveals a systolic click associated with a late systolic murmur. There are mild bibasal crackles on auscultation of his chest.

His electrocardiogram (ECG) confirms atrial fibrillation with left ventricular hypertrophy.

An echocardiogram confirms the presence of mitral valve prolapse with severe regurgitation and left ventricular impairment with an ejection fraction of 50%.

Which of the following is the management of choice for reducing his chances of long-term complications?

A	Digoxin plus aspirin
B	Digoxin plus formal anticoagulation with warfarin
C	Anticoagulation with warfarin plus bisoprolol for rate control
D	Amiodarone for rate control plus annual echocardiographic follow-up
E	Trans-oesophageal echocardiogram (TOE) with a view to surgical repair/replacement of the mitral valve followed by long-term oral anticoagulation

6929

Submit

view to surgical repair/replacement of the mitral valve followed by long-term oral anticoagulation

This patient has evidence of cardiac decompensation (breathlessness with bi-basal crackles and a displaced apex beat) in the setting of MVP with associated severe mitral regurgitation. Patients under age 75 with mitral valve prolapse (MVP) and who are in atrial fibrillation, or those who have echocardiographic evidence of left ventricular impairment, should be referred for surgical assessment as early as possible. A TOE can demonstrate whether the valve is amenable to repair or needs replacement. This is often performed intra-operatively. Progressive mitral regurgitation is the most serious complication, occurring in about 15% of patients over a 15-year period. Acute hemiplegia, transient ischaemic attacks, cerebellar infarcts, amaurosis fugax and retinal arterioral occlusions all occur more frequently in MVP patients, suggesting that cerebral emboli are actually quite common in this condition.

A Digoxin plus aspirin

Patients with atrial fibrillation and a CHADS2VASC score of 1 (not due to one female sex) should be considered for formal anticoagulation with warfarin or a novel oral anticoagulant.

B Digoxin plus formal anticoagulation with warfarin

If patients are anything other than sedentary then digoxin, as a lone antiarrhythmic, is not particularly effective at controlling a fast-ventricular response in patients with atria fibrillation.

C Anticoagulation with warfarin plus bisoprolol for rate control

Although the patient should be anticoagulated and commenced on a beta blocker, such as bisoprolol, medical

A 53-year-old salesman who was previously fit and well developed prolonged and convincing chest pain playing squash. He is seen in A&E about 6 hours later. Investigation showed T-wave inversion in the inferior leads, creatine kinase (CK) approximately 500 U/l, troponin T level is 0.16 (elevated).

Which of the following represents the most likely diagnosis?

A	Non-cardiac chest pain
B	Unstable angina
C	Stable angina
D	STEMI
E	NSTEMI

6558

Submit

Previous Q... Skip Questi...

© Pastest 2019

A 53-year-old salesman who was previously fit and well developed prolonged and convincing chest pain playing squash. He is seen in A&E about 6 hours later. Investigation showed T-wave inversion in the inferior leads, creatine kinase (CK) approximately 500 U/l, troponin T level is 0.16 (elevated).

Which of the following represents the most likely diagnosis?

Your answer was correct

A	Non-cardiac chest pain
B	Unstable angina
C	Stable angina
D	STEMI
E	NSTEMI

Explanation

E	NSTEMI

Given the inferior ECG changes and the raised troponin at 6 hours, the likely diagnosis is NSTEMI. Management include dual-antiplatelet therapy, appropriate secondary prevention, bed rest, analgesia and continuous ECG monitoring. He would be a candidate for inpatient angiography as his is at a high risk of future cardiovascular events (the GRACE score may be calculated to support this

Given the inferior ECG changes and the raised troponin at 6 hours, the likely diagnosis is NSTEMI. Management include dual-antiplatelet therapy, appropriate secondary prevention, bed rest, analgesia and continuous ECG monitoring. He would be a candidate for inpatient angiography as his is at a high risk of future cardiovascular events (the GRACE score may be calculated to support this decision).

A Non-cardiac chest pain

Given the significant ECG changes and troponin rise, the diagnosis is NSTEMI. Were the investigations to be negative and the pain atypical for cardiac pain, then non-cardiac chest pain may be suspected.

B Unstable angina

The diagnosis of unstable angina relies upon a clinical history of ischaemic pain but without a rise in cardiac biomarkers. Here the troponin is significantly elevated indicating a NSTEMI cause in conjunction with the ECG changes.

C Stable angina

Typical angina chest pain is short-lived, relieved by rest or GTN usually within 5 minutes. The pain usually involves a build-up or crescendo, with troponin levels negative. This patient may have experienced exertional chest pain typical of angina prior to his presentation of NSTEMI in the scenario.

D STEMI

Diagnosis is made with typical acute chest pain and

A 54-year-old man presents to the Emergency Department 2 weeks after discharge following percutaneous intervention for acute MI. He received an LAD stent and was treated post-procedure with aspirin and clopidogrel in combination. On this occasion he has a history of 20 min central crushing chest pain, sweating and pre-syncope. On examination his blood pressure is 95/60 mmHg, with pulse 95/min and regular. He has bilateral crackles consistent with left ventricular failure on auscultation of the chest. ECG reveals ST elevation in leads V_1-V_5 consistent with an acute infarct.

Which of the following is the most appropriate intervention?

A	Clopidogrel, aspirin and fondaparinux
B	Diamorphine, IV nitrate and aspirin
C	Low-molecular weight (LMW) heparin, abciximab, and aspirin
D	Percutaneous intervention (PCI)
E	Thrombolysis

37192

Submit

A 54-year-old man presents to the Emergency Department 2 weeks after discharge following percutaneous intervention for acute MI. He received an LAD stent and was treated post-procedure with aspirin and clopidogrel in combination. On this occasion he has a history of 20 min central crushing chest pain, sweating and pre-syncope. On examination his blood pressure is 95/60 mmHg, with pulse 95/min and regular. He has bilateral crackles consistent with left ventricular failure on auscultation of the chest. ECG reveals ST elevation in leads V_1-V_5 consistent with an acute infarct.

Which of the following is the most appropriate intervention?

Your answer was incorrect

A	Clopidogrel, aspirin and fondaparinux
B	Diamorphine, IV nitrate and aspirin
C	Low-molecular weight (LMW) heparin, abciximab, and aspirin
D	Percutaneous intervention (PCI)
E	Thrombolysis

Explanation

D	Percutaneous intervention (PCI)

This patient has recently had stenting for an acute MI and [illegible] cardiac chest pain associated

Rana Alnasser's screen

D Percutaneous intervention (PCI)

This patient has recently had stenting for an acute MI and represents with significant cardiac chest pain associated with haemodynamic compromise. This is highly suggestive of acute in-stent thrombosis. Use of dual anti-platelet therapy has fortunately made this event rare. Better outcomes occur in patients who undergo acute PCI. PCI allows for thrombus aspiration, balloon angioplasty and placement of an additional stent as necessary.

E Thrombolysis

Thrombolysis has reduced benefit in acute myocardial infarction compared with PCI. However, it should be attempted if it likely that PCI is unavailable or will be significantly delayed. In the case of stent thrombosis, thrombolysis is also thought to have less benefit than PCI: it allows for less control and does not provide the direct visualisation of the coronary anatomy available with angiography. Furthermore, given that this patient is likely already on dual anti-platelet therapy, there is an increased risk of bleeding with thrombolysis that should be considered.

A Clopidogrel, aspirin and fondaparinux

This bundle would be appropriate for the treatment of an acute coronary syndrome event. However, this patient is likely already on dual anti-platelet therapy given their recent stent, and the addition of fondaparinux is not the most appropriate management for stent thrombosis.

B Diamorphine, IV nitrate and aspirin

This forms part of the bundle for the acute treatment of a [illegible] ongoing pain. Diamorphine and

Rana Alnasser's screen

B Diamorphine, IV nitrate and aspirin

This forms part of the bundle for the acute treatment of a myocardial infarction with ongoing pain. Diamorphine and IV nitrate both lead to vasodilatation, thus lowering afterload. Additionally, diamorphine acts on opioid receptors to relieve pain. However, neither of these interventions will have a significant prognostic benefit for stent thrombosis. This patient is likely already on aspirin following their recent stent placement.

C Low-molecular weight (LMW) heparin, abciximab, and aspirin

Abciximab is a glycoprotein IIb/IIIa receptor antagonist. It is primarily recommended as an adjunct during PCI and would not be appropriate as management here. Additionally, the patient is likely already on aspirin. Furthermore, LMW heparin is likely to be insufficient therapy for the stent thrombosis this patient has presented with.

Rate this question:

Next Question

Previous Q... Tag Questi... Feedback End Session

Blog About Pastest Contact Us Help

© Pastest 2019

A 28-year-old woman is referred to the cardiology clinic with exertional breathlessness, which has become progressively worse over the past year. There is no history of wheezing and she has had no benefit from a trial of salbutamol inhalers. On close questioning she describes intermittent episodes of chest pain on exertion. She has become very concerned as she almost fainted on a couple of occasions in the last month.

On examination she has a blood pressure of 135/85 mmHg with a heart rate of 90 beats/min. Her BMI is 22kg/m^2. The jugular venous pressure is raised, with giant v-waves and there is a left parasternal heave.
The electrocardiogram (ECG) shows sinus rhythm with right axis deviation.

Which of the following is the most likely diagnosis?

A	Chronic pulmonary emboli
B	Idiopathic pulmonary artery hypertension (IPAH)
C	Ischaemic heart disease
D	Loeffler syndrome
E	Hypertrophic cardiomyopathy (HCM)

6913

Submit

A 28-year-old woman is referred to the cardiology clinic with exertional breathlessness, which has become progressively worse over the past year. There is no history of wheezing and she has had no benefit from a trial of salbutamol inhalers. On close questioning she describes intermittent episodes of chest pain on exertion. She has become very concerned as she almost fainted on a couple of occasions in the last month.

On examination she has a blood pressure of 135/85 mmHg with a heart rate of 90 beats/min. Her BMI is 22kg/m^2. The jugular venous pressure is raised, with giant v-waves and there is a left parasternal heave.
The electrocardiogram (ECG) shows sinus rhythm with right axis deviation.

Which of the following is the most likely diagnosis?

Your answer was correct

A Chronic pulmonary emboli

B Idiopathic pulmonary artery hypertension (IPAH)

C Ischaemic heart disease

D Loeffler syndrome

E Hypertrophic cardiomyopathy (HCM)

Explanation

B Idiopathic pulmonary artery hypertension (IPAH)

B Idiopathic pulmonary artery hypertension (IPAH)

PPH is a rare condition characterised by elevated pulmonary artery pressure and without a clear cause. The above case describes a typical presentation for IPAH. IPAH was previously known as (and is often still called) primarily pulmonary hypertension (PPH). Syncope is seen in approximately 13% of patients. The ECG findings point towards right ventricular hypertrophy, which is an end result of this condition. Treatment is typically with calcium channel blockers and anticoagulation; nebulised prostacyclin can also be considered

A Chronic pulmonary emboli

Chronic emboli can lead to chronic pulmonary hypertension, which may present with similar features to those described above. However, no risk factors for venous thromboembolism are described. Additionally, there is no description of any DVT symptoms that would support this diagnosis

C Ischaemic heart disease

Intermittent chest pain on exertion may raise the suspicion of myocardial ischaemia. However, the patient is young and no significant risk factors for coronary artery disease have been described, making this diagnosis unlikely.

D Loeffler syndrome

Loffler syndrome is an eponymous term for acute onset pulmonary eosinophilia. Typically this condition occurs secondary to an external trigger (the syndrome was originally described in association with parasitic infection by *Ascaris lumbricoides*). There is no evidence to support an external trigger in this case. Wheeze is often a central

hypertension, which may present with similar features to those described above. However, no risk factors for venous thromboembolism are described. Additionally, there is no description of any DVT symptoms that would support this diagnosis

C Ischaemic heart disease

Intermittent chest pain on exertion may raise the suspicion of myocardial ischaemia. However, the patient is young and no significant risk factors for coronary artery disease have been described, making this diagnosis unlikely.

D Loeffler syndrome

Loffler syndrome is an eponymous term for acute onset pulmonary eosinophilia. Typically this condition occurs secondary to an external trigger (the syndrome was originally described in association with parasitic infection by *Ascaris lumbricoides*). There is no evidence to support an external trigger in this case. Wheeze is often a central feature.

E Hypertrophic cardiomyopathy (HCM)

This lady is presenting with significant breathlessness. Patients with HCM can present this way secondary to heart failure. However, her ECG shows no features to suggest significant left ventricular hypertrophy, which would be expected if HCM was the underlying diagnosis.

A 75-year-old male presents to the emergency department with a history of sudden onset of chest pain one hour ago. The pain is sharp, severe, radiates to the back and is associated with sweating. He is known to have had hypertension for the past 8 years and is taking indapamide 1.5 mg/day. Physical examination reveals blood pressure of 145/75 mmHg, heart rate of 92/min and respiratory rate of 22/min. Heart sounds are normal and lung fields are clear to auscultation.

Investigations show:

Sodium	135 mmol/l
Potassium	4.5 mmol/l
Urea	8 mmol/l
Creatinine	70 µmol/l
Haemoglobin	14 g/dL
White cell count	10×10^9/L
Chest X-ray	A widened mediastinum
Electrocardiogram (ECG)	sinus tachycardia and left ventricular hypertrophy by voltage criteria.
An urgent magnetic resonance angiography	Dissection of the aorta distal to the left subclavian artery

Which of the following is the most appropriate next step in management of this patient?

A Begin intravenous labetolol

B Begin intravenous hydralazine

C Begin intravenous labetolol and sodium

Investigations show:

Sodium	135 mmol/l
Potassium	4.5 mmol/l
Urea	8 mmol/l
Creatinine	70 µmol/l
Haemoglobin	14 g/dL
White cell count	10 x 10^9/L
Chest X-ray	A widened mediastinum
Electrocardiogram (ECG)	sinus tachycardia and left ventricular hypertrophy by voltage criteria.
An urgent magnetic resonance angiography	Dissection of the aorta distal to the left subclavian artery

Which of the following is the most appropriate next step in management of this patient?

A Begin intravenous labetolol

B Begin intravenous hydralazine

C Begin intravenous labetolol and sodium nitroprusside

D Begin intravenous sodium nitroprusside

E Urgent referral for surgery

White cell count	10 x 10^9/L
Chest X-ray	A widened mediastinum
Electrocardiogram (ECG)	sinus tachycardia and left ventricular hypertrophy by voltage criteria.
An urgent magnetic resonance angiography	Dissection of the aorta distal to the left subclavian artery

Which of the following is the most appropriate next step in management of this patient?

Your answer was correct

A Begin intravenous labetolol

B Begin intravenous hydralazine

C Begin intravenous labetolol and sodium nitroprusside

D Begin intravenous sodium nitroprusside

E Urgent referral for surgery

Explanation

A Begin intravenous labetolol

Aortic dissection is classified as type A if it involves the ascending aorta regardless of the site of primary tear, and type B if it does not. This patient has type B aortic dissection. Patients with type A aortic dissection should

Explanation

A	Begin intravenous labetolol

Aortic dissection is classified as type A if it involves the ascending aorta regardless of the site of primary tear, and type B if it does not. This patient has type B aortic dissection. Patients with type A aortic dissection should have emergency surgery because of the high risk of mortality and complication such as aortic regurgitation, myocardial infarction and cardiac tamponade. Most patients with type B dissection should be treated medically unless they have complications such as persistent leak, rupture or compromised blood flow to renal, mesenteric or limb circulation. Beta-blockers are the mainstay of medical therapy, as they reduce the rate of left ventricular ejection and shear on the aortic wall. The aim is to reduce blood pressure to 100–120 mmHg and the pulse to near 60 bpm.

B	Begin intravenous hydralazine

Hydralazine should not be used alone as it may increase rate of left ventricular ejection.

C	Begin intravenous labetolol and sodium nitroprusside

Beta-blockers should be tried first to control blood pressure, only if this fails then it warrants adding sodium nitroprusside, however, it is not required to have the two agents from the onset.

D	Begin intravenous sodium nitroprusside

Sodium nitroprusside can be added if blood pressure is not controlled with beta-blockers but should not be used alone as it may increase rate of left ventricular ejection.

C Begin intravenous labetolol and sodium nitroprusside

Beta-blockers should be tried first to control blood pressure, only if this fails then it warrants adding sodium nitroprusside, however, it is not required to have the two agents from the onset.

D Begin intravenous sodium nitroprusside

Sodium nitroprusside can be added if blood pressure is not controlled with beta-blockers but should not be used alone as it may increase rate of left ventricular ejection.

E Urgent referral for surgery

This patient has a type B aortic dissection. Most patients with type B dissection should be treated medically unless they have complications such as persistent leak, rupture or compromised blood flow to renal, mesenteric or limb circulation. Only in the latter cases is urgent surgery warranted.

Rate this question:

Next Question

Previous Q... Tag Questi... Feedback End Session

Blog About Pastest Contact Us Help

© Pastest 2019

1:14
On MyPastest 594-042-7551 Leave
https://mypastest.pastest.com

A 56-year-old woman, with a history of right coronary artery stent placement three years earlier for an inferior myocardial infarction, presents to the Emergency Department with palpitations lasting for an hour, and syncope related to the fast heart rate. She had one previous episode of palpitations the previous month, which reverted spontaneously after 30 min. Medication includes bisoprolol 2.5 mg OD, ramipril 10 mg OD, atorvastatin 20 mg ON and aspirin 75 mg OD. On examination her blood pressure is 80/60 mmHg, pulse 140/min and irregular and there are bilateral basal crackles on auscultation of the chest.

Investigations:

Hb	129 g/l
WCC	7.4×10^9/l
PLT	208×10^9/l
Na^+	137 mmol/l
K^+	4.5 mmol/l
Creatinine	105 micromol/l
Glucose	5.4 mmol/l
ECG	Atrial fibrillation with evidence of lateral ischaemia

Which of the following is the most appropriate intervention?

A Amiodarone

B DC cardioversion

Audio Video Share Participants More

syncope related to the fast heart rate. She had one previous episode of palpitations the previous month, which reverted spontaneously after 30 min. Medication includes bisoprolol 2.5 mg OD, ramipril 10 mg OD, atorvastatin 20 mg ON and aspirin 75 mg OD. On examination her blood pressure is 80/60 mmHg, pulse 140/min and irregular and there are bilateral basal crackles on auscultation of the chest.

Investigations:

Hb	129 g/l
WCC	7.4×10^9/l
PLT	208×10^9/l
Na^+	137 mmol/l
K^+	4.5 mmol/l
Creatinine	105 micromol/l
Glucose	5.4 mmol/l
ECG	Atrial fibrillation with evidence of lateral ischaemia

Which of the following is the most appropriate intervention?

A Amiodarone

B DC cardioversion

C Digoxin

D Esmolol

E Flecainide

Explanation

B DC cardioversion

The clinical history and examination findings reveal a patient in atrial fibrillation (AF) with clear signs suggestive of haemodynamic compromise secondary to the arrhythmia. Of note, the patient has a significant hypotension, clinical features of heart failure on examination, syncope and signs of cardiac ischaemia on the ECG. Any one of these four features would necessitate the use of urgent DC cardioversion to correct the arrhythmia. This will usually require sedation or general anaesthesia and airway management. The on-call anaesthetist is likely to be the first port of call when getting help in this situation.

A Amiodarone

Amiodarone is a class III antiarrhythmic and is primarily indicated in refractory AF or broad-complex tachy-arrhythmias without haemodynamic compromise. In this case, Amiodarone is not the best treatment option. The patient has haemodynamic compromise with a narrow complex tachycardia and requires urgent DC cardioversion.

C Digoxin

Digoxin acts by reducing conduction through the AV node and will be unlikely to lead to cardioversion. Additionally, the onset of action for digoxin is significantly longer than a number of the other options listed here, which makes it less appropriate in this emergent clinical situation.

D Esmolol

Beta-blockade has a central role in the management of

the onset of action for digoxin is significantly longer than a number of the other options listed here, which makes it less appropriate in this emergent clinical situation.

D Esmolol

Beta-blockade has a central role in the management of irregular narrow-complex tachy-arrhythmias (e.g. AF) when they are not leading to haemodynamic compromise. If this patient were stable, this would likely be the correct management option. However, given the clinical instability, urgent rhythm correction is indicated with DC cardioversion.

E Flecainide

Flecainide is a class I antiarrhythmic which is often successful in leading to pharmacological cardioversion in AF. However, this patient has a history of ischaemic heart disease, which is a contra-indication to the use of class I anti-arrhythics due to the increased risk of pro-arrhythmic effects.

Rate this question:

Next Question

Previous Q... Tag Questi... Feedback End Session

Blog About Pastest Contact Us Help

© Pastest 2019

An 82-year-old woman presented to the Emergency Department with very severe chest pain that she had experienced continuously for the last 2 h. The chest pain was central and radiated to the neck and the left arm. There was a history of nausea and she vomited twice.

On examination, she was distressed, her blood pressure was 150/90 mmHg and pulse 102/min. First and second heart sounds were heard and there was a pansystolic murmur radiating to the axilla. Her chest was clinically clear.

An electrocardiogram (ECG) showed ST elevation in leads V1–V4, and chest X-ray appeared normal.

She is referred for PCI and you next review her on the Coronary Care Ward a few days later.

Which of the following medications has been shown to have the greatest impact on future risk of ischaemic cardiovascular events in this population?

A Beta-blockers

B Long-acting nitrate

C Thiazide diuretic

D Dihydropyridine calcium channel blocker

E Dipyridamole MR

Submit

Explanation

A Beta-blockers

The first international Study of Infarct Survival (ISIS-1) showed that atenolol reduced mortality by 15% during the first week after an ST elevation myocardial infarction (STEMI). The benefits of atenolol were seen for up to 1 year.

B Long-acting nitrate

Although long-acting nitrates improve symptoms in patients with angina, they haven't been shown to have a significant impact on ischaemic cardiovascular events.

C Thiazide diuretic

Although blood pressure lowering irrespective of therapy has been shown to benefit cardiovascular outcomes, a greater benefit on outcomes is thought to be seen with use of either ACE inhibitor or ARBs (see the ANBP2 study).

D Dihydropyridine calcium channel blocker

Dihydropyridine calcium channel blockers do benefit outcomes via blood pressure lowering, although greater positive effects on outcomes are thought to come from either ACE inhibitors, ARBs, beta blockers or I(f) channel inhibitors.

E Dipyridamole MR

Dipyridamole MR has been shown to have positive effects on secondary stroke risk when used in conjunction with aspirin (in the ESPS2 study).

significant impact on ischaemic cardiovascular events.

C Thiazide diuretic

Although blood pressure lowering irrespective of therapy has been shown to benefit cardiovascular outcomes, a greater benefit on outcomes is thought to be seen with use of either ACE inhibitor or ARBs (see the ANBP2 study).

D Dihydropyridine calcium channel blocker

Dihydropyridine calcium channel blockers do benefit outcomes via blood pressure lowering, although greater positive effects on outcomes are thought to come from either ACE inhibitors, ARBs, beta blockers or I(f) channel inhibitors.

E Dipyridamole MR

Dipyridamole MR has been shown to have positive effects on secondary stroke risk when used in conjunction with aspirin (in the ESPS2 study).

Rate this question:

Next Question

Previous Q... Tag Questi... Feedback End Session

Blog About Pastest Contact Us Help

© Pastest 2019

A 68-year-old man with a history of ankylosing spondylitis is referred to the cardiology department following the discovery of a diastolic murmur by the general practitioner (GP). He does not describe any chest pain or breathlessness but he has experienced some palpitations over the last six months.

His blood pressure is 175/95 mmHg with a heart rate of 100 bpm at rest. Clinical examination reveals a collapsing pulse, cardiac apex displaced to the anterior axillary line and a diastolic murmur. The chest is clear on auscultation and there is no peripheral oedema.

Electrocardiogram (ECG) shows sinus rhythm with ventricular ectopics and left ventricular hypertrophy.

Chest X-ray shows cardiomegaly with clear lung fields.

An echocardiogram confirms the presence of aortic regurgitation with a dilated left ventricle (diastolic diameter > 70 mm) and an ejection fraction of 50%.

A 24-h ECG shows sinus rhythm with frequent ventricular ectopics that correspond to the patient's experienced palpitations.

Which of the following is the long-term management of choice in this case?

A	Ramipril
B	Bisoprolol
C	Repeat echo in six months
D	Repeat echo in one year
E	Referral for valve replacement

His blood pressure is 175/95 mmHg with a heart rate of 100 bpm at rest. Clinical examination reveals a collapsing pulse, cardiac apex displaced to the anterior axillary line and a diastolic murmur. The chest is clear on auscultation and there is no peripheral oedema.

Electrocardiogram (ECG) shows sinus rhythm with ventricular ectopics and left ventricular hypertrophy.

Chest X-ray shows cardiomegaly with clear lung fields.

An echocardiogram confirms the presence of aortic regurgitation with a dilated left ventricle (diastolic diameter > 70 mm) and an ejection fraction of 50%.

A 24-h ECG shows sinus rhythm with frequent ventricular ectopics that correspond to the patient's experienced palpitations.

Which of the following is the long-term management of choice in this case?

Your answer was correct

A	Ramipril
B	Bisoprolol
C	Repeat echo in six months
D	Repeat echo in one year
E	Referral for valve replacement

Explanation

E	Referral for valve replacement

The ESC has produced 2017 guidelines on the management

E Referral for valve replacement

Explanation

E Referral for valve replacement

The ESC has produced 2017 guidelines on the management of valvular disease. In regard to chronic aortic regurgitation, they state: 'Surgery should be considered in asymptomatic patients with resting ejection fraction < 50% with severe LV dilatation: LVEDD > 70 mm or LVESD > 50 mm (or LVESD > 25 mm/m^2 BSA in patients with small body size).' Surgery should be considered in all symptomatic patients, regardless of EF and LV dimensions, and in asymptomatic patients with aortic regurgitation and EF < 50%.

In terms of follow-up, the ESC recommends that all asymptomatic patients with severe aortic regurgitation and normal LV function should be seen for follow-up at least every year. In patients with a first diagnosis, or if LV diameter and/or ejection fraction show significant changes or come close to thresholds for surgery, follow-up should be continued at 3–6-month intervals. In inconclusive cases, BNP may be helpful, as its elevation during follow-up has been related to deterioration in LV function. Patients with mild to moderate aortic regurgitation can be reviewed on a yearly basis and echocardiography performed every two years.

A Ramipril

While ramipril represents an important part of the therapy of aortic regurgitation, this patient meets the threshold for intervention and should be referred for consideration of valve replacement.

This patient meets the threshold for intervention and should be referred for consideration of valve replacement. Medical therapy can provide symptomatic improvement in individuals with chronic severe aortic regurgitation in whom surgery is not feasible. In patients who undergo surgery but continue to suffer from heart failure or hypertension, angiotensin-converting enzyme (ACE) inhibitors, angiotensin receptor blockers (ARBs) and beta-blockers are useful. In patients with Marfan syndrome, beta-blockers and/or losartan may slow aortic root dilatation and reduce the risk of aortic complications and should be considered before and after surgery. By analogy, while there are no studies that provide evidence, it is common clinical practice to advise beta-blocker or losartan therapy in patients with bicuspid aortic valve if the aortic root and/or ascending aorta is dilated.

C Repeat echo in six months

This patient already meets the threshold for intervention and should be referred for consideration of valve replacement.

D Repeat echo in one year

This patient already meets the threshold for intervention and should be referred for consideration of valve replacement.

6908

Rate this question:

A 26-year-old female comes to the cardiology clinic having been referred by her general practitioner (GP). She has suffered from progressive shortness of breath for 8 months. She is really worried now because even minimal exertion is making her breathless. She has no palpitations, cough or chest pains. Her past medical history is unremarkable and she takes no medication. She has been seeing her GP over the last 2-3 months but he could not detect any abnormally. Her full blood count (FBC), urea and electrolytes, liver function tests (LFTs) and chest X-ray (CXR) were all reported as normal.
On examination, her blood pressure is 125/60 mmHg, pulse is 86/min and regular. Her jugular venous pressure is raised to 5 cm, there is a parasternal heave and apex beat is in the 5th intercostals space at the mid-clavicular line. She has an increased pulmonary component of second heart sound and tricuspid regurgitation. FBC, LFTs and blood biochemistry are within the normal range.

CXR shows enlarged central pulmonary arteries and clear lung fields.
Electrocardiogram (ECG) shows right axis deviation, tall R waves in V1–V2 and right ventricular strain pattern.

Echocardiogram demonstrates tricuspid regurgitation, right ventricular enlargement, a reduction in left ventricular cavity size and abnormal septal configuration consistent with right ventricular pressure overload.

There is a positive response to acute vasodilator testing.

Which one of the following medications is appropriate first-line therapy in the treatment of this condition?

A Calcium channel blockers

B Beta-blockers

C Hydralazine

D Prostacyclin

is 86/min and regular. Her jugular venous pressure is raised to 5 cm, there is a parasternal heave and apex beat is in the 5th intercostals space at the mid-clavicular line. She has an increased pulmonary component of second heart sound and tricuspid regurgitation. FBC, LFTs and blood biochemistry are within the normal range.

CXR shows enlarged central pulmonary arteries and clear lung fields.
Electrocardiogram (ECG) shows right axis deviation, tall R waves in V1–V2 and right ventricular strain pattern.

Echocardiogram demonstrates tricuspid regurgitation, right ventricular enlargement, a reduction in left ventricular cavity size and abnormal septal configuration consistent with right ventricular pressure overload.

There is a positive response to acute vasodilator testing.

Which one of the following medications is appropriate first-line therapy in the treatment of this condition?

A	Calcium channel blockers
B	Beta-blockers
C	Hydralazine
D	Prostacyclin
E	Angiotensin-converting enzyme (ACE) inhibitors

32513

Submit

5th intercostals space at the mid-clavicular line. She has an increased pulmonary component of second heart sound and tricuspid regurgitation. FBC, LFTs and blood biochemistry are within the normal range.

CXR shows enlarged central pulmonary arteries and clear lung fields.
Electrocardiogram (ECG) shows right axis deviation, tall R waves in V1–V2 and right ventricular strain pattern.

Echocardiogram demonstrates tricuspid regurgitation, right ventricular enlargement, a reduction in left ventricular cavity size and abnormal septal configuration consistent with right ventricular pressure overload.

There is a positive response to acute vasodilator testing.

Which one of the following medications is appropriate first-line therapy in the treatment of this condition?

A	Calcium channel blockers
B	Beta-blockers
C	Hydralazine
D	Prostacyclin
E	Angiotensin-converting enzyme (ACE) inhibitors

Explanation

A	Calcium channel blockers

The above young lady presents with the classical signs and symptoms of primary pulmonary hypertension (PPH). Obesity, portal hypertension, anorexigens, HIV and systemic hypertension have all been implicated in the development of PPH. Whilst only 10-15% of patients appear

Rana Alnasser's screen

A Calcium channel blockers

The above young lady presents with the classical signs and symptoms of primary pulmonary hypertension (PPH). Obesity, portal hypertension, anorexigens, HIV and systemic hypertension have all been implicated in the development of PPH. Whilst only 10-15% of patients appear to have a pulmonary vascular tree responsive to calcium antagonism, these agents still constitute the initial therapy of choice according to guidelines, but only in those patients who show a response to vasodilator testing. Options for later-stage disease include endothelin receptor antagonists (which may be associated with peripheral oedema and hepatotoxicity); PDE-5 inhibitors such as sildenafil; and prostacyclin, which has been shown when given in infusion to impact on both quality of life and survival time.

B Beta-blockers

Beta blockade has no impact on outcomes in primary pulmonary hypertension, and it should therefore be avoided here.

C Hydralazine

Hydralazine is an option for treating patients with left ventricular dysfunction where ACE inhibitors are neither tolerated nor contraindicated.

D Prostacyclin

Prostacyclin is an option for later-stage primary pulmonary hypertension and can be used in combination with endothelin receptor antagonists and PDE-5 inhibitors.

Rana Alnasser's screen

B Beta-blockers

Beta blockade has no impact on outcomes in primary pulmonary hypertension, and it should therefore be avoided here.

C Hydralazine

Hydralazine is an option for treating patients with left ventricular dysfunction where ACE inhibitors are neither tolerated nor contraindicated.

D Prostacyclin

Prostacyclin is an option for later-stage primary pulmonary hypertension and can be used in combination with endothelin receptor antagonists and PDE-5 inhibitors.

E Angiotensin-converting enzyme (ACE) inhibitors

ACE inhibitors have a primary role in the treatment of left ventricular dysfunction.

Rate this question:

Next Question

Previous Q... Tag Questi... Feedback End Session

Blog About Pastest Contact Us Help

© Pastest 2019

A 45-year-old smoker presents to the Accident and Emergency Department following a prolonged episode of chest discomfort lasting 3 h. His initial electrocardiogram (ECG) shows segment (ST) elevation in the chest wall leads. Thrombolysis therapy with tissue plasminogen activator is given on the advice of the cardiology team. The patient is admitted onto a coronary-care bed and is discharged after an uneventful 5-day period. He re-presents after one month complaining of palpitations and dizziness. The electrocardiogram (ECG) shows a broad complex tachycardia.

Investigations:

Hb	14.2 g/dl
WCC	7.8×10^9/l
PLT	310×10^9/l
Na^+	140 mmol/l
K^+	3.7 mmol/l
Urea	6.0 mmol/l
Creatinine	95 µmol/l
Ca^{++}	2.21 mmol/l
Mg^{++}	0.88 mmol/l

A central line is inserted and the patient is loaded with amiodarone. His electrocardiogram (ECG) reverts to sinus rhythm with anterior Q waves. An echocardiogram shows antero-septal hypokinesis with moderate left ventricle (LV) impairment.

Which one of the following is the definitive intervention?

A Amiodarone 200 mg tds

B Amiodarone 200 mg od

Hb	14.2 g/dl
WCC	7.8×10^9/l
PLT	310×10^9/l
Na^+	140 mmol/l
K^+	3.7 mmol/l
Urea	6.0 mmol/l
Creatinine	95 µmol/l
Ca^{++}	2.21 mmol/l
Mg^{++}	0.88 mmol/l

A central line is inserted and the patient is loaded with amiodarone. His electrocardiogram (ECG) reverts to sinus rhythm with anterior Q waves. An echocardiogram shows antero-septal hypokinesis with moderate left ventricle (LV) impairment.

Which one of the following is the definitive intervention?

A Amiodarone 200 mg tds

B Amiodarone 200 mg od

C Sotalol 80 mg bd

D Automated implantable cardiac defibrillator

E Mexiletine

Submit

D Automated implantable cardiac defibrillator

Automated implantable cardiac defibrillator, is correct. The development of ventricular tachycardia/fibrillation (VT/VF) on the first day following an acute myocardial infarction (MI) is thought to be of no prognostic significance if dealt with promptly. However, the late development of VT/VF in the context of a full-thickness myocardial scar, as evidenced by the Q waves on the ECG, carries a very poor prognosis.

Given that there is no evidence of any reversible cause (i.e. electrolyte abnormality) to VF/VT, it is very likely to be scar tissue-related ventricular arrhythmia, especially with the presence of Q waves on ECG indicating a full-thickness infarct. Pharmacological therapy with amiodarone to terminate or prevent recurrence in the acute setting is effective, but in terms of secondary prevention and long-term outcomes, ICD is superior to amiodarone (MADIT-2 trial). Therefore, ICD is indicated in this patient.

A Amiodarone 200 mg tds

Amiodarone is a class III antiarrhythmic drug which works by slowing the conduction rate and prolonging the refectory period of the SA and AV nodes. Pharmacological therapy with amiodarone to terminate or prevent recurrence in the acute setting is effective, but in terms of secondary prevention and long-term outcomes, ICD is superior to amiodarone. Therefore, ICD is indicated in this patient.

B Amiodarone 200 mg od

This is the maintenance dose of amiodarone normally used for patients who have been loaded with amiodarone. It is therefore the wrong dose of amiodarone to use in the current setting. However, we should consider that ICD is the appropriate therapy in this case.

A 46-year-old lady is diagnosed with a large left breast carcinoma. She is seen by the multidisciplinary oncology team who advocate a mastectomy with adjuvant radiotherapy and chemotherapy. A preoperative echocardiogram is performed and is reported as showing a good left ventricle with no significant valvular disease. The patient has a successful operation. The tumour is reported as HER2-positive, and the patient is started on a chemotherapy regime. Two months later she complains of a gradual decrease in her exercise tolerance. On examination there is mild bipedal oedema. Auscultation reveals inspiratory crackles at the bases of the lungs with reduced air entry on the side of the mastectomy. A chest X-ray shows a small unilateral pleural effusion.

Which of the following is the most appropriate next step?

A	Therapeutic drainage of the effusion
B	Conservative management with radiographic follow-up
C	Repeat echocardiogram
D	CT chest
E	Full-body PET

32344

Submit

A 46-year-old lady is diagnosed with a large left breast carcinoma. She is seen by the multidisciplinary oncology team who advocate a mastectomy with adjuvant radiotherapy and chemotherapy. A preoperative echocardiogram is performed and is reported as showing a good left ventricle with no significant valvular disease. The patient has a successful operation. The tumour is reported as HER2-positive, and the patient is started on a chemotherapy regime. Two months later she complains of a gradual decrease in her exercise tolerance. On examination there is mild bipedal oedema. Auscultation reveals inspiratory crackles at the bases of the lungs with reduced air entry on the side of the mastectomy. A chest X-ray shows a small unilateral pleural effusion.

Which of the following is the most appropriate next step?

Your answer was correct

A	Therapeutic drainage of the effusion
B	Conservative management with radiographic follow-up
C	Repeat echocardiogram
D	CT chest
E	Full-body PET

Explanation

C Repeat echocardiogram

C Repeat echocardiogram

The development of symptoms and signs of cardiac failure in an oncology patient should raise the possibility of cardiomyopathy secondary to cardiotoxic chemotherapy. A baseline echocardiogram should ideally be performed prior to embarking on any course of chemotherapy, and repeat echocardiograms are indicated if the patient develops symptoms during or after the course of chemotherapy. Herceptin in particular is recognised as being associated with cardiomyopathy. Animal studies have suggested that agonism of the Erb-B2 (HER2) receptor is protective against the development of dilated cardiomyopathy; as such, antagonism may increase the risk of developing the condition. Additionally, there can be negative synergy between trastuzumab and other chemotherapeutic agents used to treat breast cancer, including anthracyclines such as doxorubicin, putting patients at increased risk of cardiotoxicity.

A Therapeutic drainage of the effusion

We are told that the effusion is small and unilateral. It is less likely to be responsible for this patient's symptoms than cardiac toxicity from her chemotherapy regime.

B Conservative management with radiographic follow-up

We are told that the effusion is small and unilateral. It is less likely to be responsible for this patient's symptoms than cardiac toxicity from her chemotherapy regime. It would seem prudent to actively investigate and treat this.

D CT chest

his would prove a less diagnostically useful investigation in the first instance than an echocardiogram, particularly

B Conservative management with radiographic follow-up

We are told that the effusion is small and unilateral. It is less likely to be responsible for this patient's symptoms than cardiac toxicity from her chemotherapy regime. It would seem prudent to actively investigate and treat this.

D CT chest

his would prove a less diagnostically useful investigation in the first instance than an echocardiogram, particularly given that there is a baseline echo with which it can be compared.

E Full-body PET

This would prove a less diagnostically useful investigation in the first instance than an echocardiogram, particularly given that there is a baseline echo with which it can be compared.

Rate this question:

© Pastest 2019

A 67-year-old lady was admitted to the Emergency Department with central chest pains that had started 3 h earlier. The pain was crushing in nature, radiating to both arms and associated with nausea and vomiting. She has a past medical history of angina, hypertension and type II diabetes. She is on the following medications: glyceryl trinitrate (GTN) spray prn, amlodipine 10 mg od, atorvastatin 40 mg nocte, metformin 500 mg tds and aspirin 75 mg od.

On examination, she was sweaty with a blood pressure of 155/95 mmHg, pulse of 98/min and regular. Her respiratory rate was 24/min and her chest was clinically clear. Her jugular venous pulse was just visible, first and second heart sounds were heard with no added murmurs. The electrocardiogram (ECG) showed ST elevation of 3 mm in V_1–V_4, with reciprocal ST depression in the inferior leads.

Investigations:

Hb	13.8 g/dl
WCC	14.1×10^9/l
PLT	240×10^9 /l
Na^+	14.1×10^9 /l
K^+	3.8 mmol/l
Creatinine	121 µmol/l
MCV	88.6 fll
Urea	7.1 mmol/l

A bolus infusion of tenecteplase was given, together with diamorphine and metoclopramide. Over the next 30 min, she suddenly started becoming progressively hypotensive with a blood pressure of 72/53 mmHg, pulse of 124/min sinus rhythm. Auscultation of her chest revealed a pan-systolic murmur loudest at the lower left sternal edge associated with an audible third heart sound.

Hb	13.8 g/dl
WCC	14.1×10^9/l
PLT	240×10^9 /l
Na^+	14.1×10^9 /l
K^+	3.8 mmol/l
Creatinine	121 μmol/l
MCV	88.6 fll
Urea	7.1 mmol/l

A bolus infusion of tenecteplase was given, together with diamorphine and metoclopramide. Over the next 30 min, she suddenly started becoming progressively hypotensive with a blood pressure of 72/53 mmHg, pulse of 124/min sinus rhythm. Auscultation of her chest revealed a pan-systolic murmur loudest at the lower left sternal edge associated with an audible third heart sound.

What is the most likely diagnosis?

A Acute mitral regurgitation

B Ruptured ventricular free wall

C Ruptured ventricular septum

D Pulmonary embolism

E Pericardial tamponade

Submit

Creatinine	121 µmol/l
MCV	88.6 fll
Urea	7.1 mmol/l

A bolus infusion of tenecteplase was given, together with diamorphine and metoclopramide. Over the next 30 min, she suddenly started becoming progressively hypotensive with a blood pressure of 72/53 mmHg, pulse of 124/min sinus rhythm. Auscultation of her chest revealed a pan-systolic murmur loudest at the lower left sternal edge associated with an audible third heart sound.

What is the most likely diagnosis?

Your answer was correct

A Acute mitral regurgitation

B Ruptured ventricular free wall

C Ruptured ventricular septum

D Pulmonary embolism

E Pericardial tamponade

Explanation

C Ruptured ventricular septum

The most likely diagnosis is ruptured ventricular septum. This rare complication (according to autopsy studies, occurring in 1-3% of cases of MI as opposed to around 10% incidence for ventricular free wall rupture) occurs most

C Ruptured ventricular septum

The most likely diagnosis is ruptured ventricular septum. This rare complication (according to autopsy studies, occurring in 1-3% of cases of MI as opposed to around 10% incidence for ventricular free wall rupture) occurs most commonly after anterior myocardial infarction. The clinical presentation ranges from asymptomatic murmur to cardiogenic shock. Post-infarction ventricular septal defects complicate approximately 1-3% of cases of acute MI, and account for about 5% of early deaths after MI. The average time from infarction to rupture has been reported to be between 2 and 4 days, but it may be as short as a few hours or as long as 2 weeks. An echocardiogram would confirm the diagnosis, and Swan-Ganz catheterisation would help determine the degree of biventricular failure. Mortality is very high, in the order of 80%, and the outlook in this patient is poor given her age, female sex and medical history of diabetes and hypertension. Although right-sided failure is more common in patients with post-infarction ventricular septal rupture, left-sided failure and refractory pulmonary oedema are more prominent in patients with ruptured papillary muscle. Papillary muscle rupture is rarer, with a reported incidence of <1%.

A Acute mitral regurgitation

Whilst mitral regurgitation would also result in a pan-systolic murmur and hypotension, the time to onset is arguably far too short here. Median onset of MR post-myocardial is 7-10 days, although it can be seen earlier with acute papillary muscle rupture.

B Ruptured ventricular free wall

Rupture of the ventricular free wall will result in sudden death of the patient, and this may be the first manifestation of coronary artery disease in a small percentage of patients

Whilst mitral regurgitation would also result in a pan-systolic murmur and hypotension, the time to onset is arguably far too short here. Median onset of MR post-myocardial is 7-10 days, although it can be seen earlier with acute papillary muscle rupture.

B Ruptured ventricular free wall

Rupture of the ventricular free wall will result in sudden death of the patient, and this may be the first manifestation of coronary artery disease in a small percentage of patients with acute myocardial infarction.

D Pulmonary embolism

In pulmonary embolism the signs would include tachycardia, haemoptysis and shortness of breath, and there may be signs of the cause of the pulmonary embolism such as a swollen calf, suggesting a deep vein thrombosis.

E Pericardial tamponade

With cardiac tamponade, the clinical features will include a low arterial blood pressure, distended neck veins and distant heart sounds. There is also a narrow pulse pressure.

Rate this question:

Next Question

Previous Q... Tag Questi... Feedback End Session

A 42-year-old man presents with an episode of chest pain following a vigorous game of squash. On admission to the Emergency Department he admits to a previous episode after jogging a few weeks earlier. He smokes five cigarettes per day and drinks 25 units of alcohol per week. His father died suddenly at the age of 42, and his brother died at the age of 21. On examination there is a systolic murmur, loudest at the left sternal border, and a fourth heart sound. ECG reveals left ventricular hypertrophy. Echocardiography reveals a thickness ratio (septum: left ventricular wall) of 1.5:1.

What diagnosis fits best with this clinical picture?

A Alcoholic cardiomyopathy

B Aortic stenosis

C Hypertrophic obstructive cardiomyopathy

D Coronary artery disease

E Restrictive cardiomyopathy

Submit

Explanation

C Hypertrophic obstructive cardiomyopathy

Familial HOCM occurs as an autosomal dominant condition with variable penetrance. Symptoms may include dyspnoea, syncope, angina or palpitations. Unfortunately the condition is also associated with increased risk of lethal arrhythmias and sudden death. Chest X-ray examination may reveal normal or increased heart size. Electrocardiogram (ECG) shows left ventricular hypertrophy and there are often Q waves in anterolateral and inferior leads. Echocardiography reveals increased septal versus left ventricular wall diameter (diameter ratio of >1.3:1). Surgical resection of myocardial tissue is an option where the outflow gradient is increased. Amiodarone is useful for arrhythmia prophylaxis; an implantable cardioverter/defibrillator may be an option in patients with recurrent ventricular tachycardia.

A Alcoholic cardiomyopathy

Alcohol leads to a dilated cardiomyopathy, but the thickness suggested by the echo and family history of early death makes hypertrophic cardiomyopathy the most likely diagnosis here.

B Aortic stenosis

While exertional angina and an ejection systolic murmur are associated with aortic stenosis, the thickness suggested by the echo and family history of early death makes hypertrophic cardiomyopathy the most likely diagnosis here.

D Coronary artery disease

Rana Alnasser's screen

the echo and family history of

Touch to r... 1:39
Off
594-042-7551
Leave

A 55-year-old lorry driver presents to hospital with central chest pain. He describes this as a feeling of pressure on his chest that is building up in intensity. On arrival in the Emergency Department he looks sweaty and clammy and he vomits once in the resuscitation area. A 12-lead ECG shows ST elevation in the anterior leads, confirming an anterior myocardial infarction. He is transferred for urgent PCI and then moved to the coronary care unit.

Which of the following rhythms on an ECG taken 2 h post-PCI would be associated with the worst prognosis?

A	Multiple ventricular ectopics
B	Accelerated idioventricular rhythm
C	Third-degree atrioventricular block
D	Mobitz type 1 AV block (Wenckeback phenomenon)
E	Sinus rhythm with rate 30 bpm

Submit

Audio Video Share Participants More
Blog About Pastest Contact Us Team

Explanation

C Third-degree atrioventricular block

Complete heart block in the context of an anterior myocardial infarction signifies an extensive area of infarction and carries a high risk of in-hospital death. It is an indication for temporary pacing, and permanent pacing is almost invariably required. The CARISMA trial monitored patients with acute anterior myocardial infarction and reduced ejection fraction, and found that high-degree AV block was the strongest predictor of mortality. Note this is not the same study as the CHARISMA trial, which examined the effect of clopidogrel and aspirin in combination on cardiovascular events.

A Multiple ventricular ectopics

These can be related to reperfusion and are common in the context of acute MI. The CAST trial demonstrated evidence of harm in attempting to suppress ventricular ectopics with class 1 anti-arrhythmics following MI.

B Accelerated idioventricular rhythm

This is a common rhythm abnormality following MI, occurring in 15-20% of patients. Observation is key, and no treatment is usually needed.

D Mobitz type 1 AV block (Wenckeback phenomenon)

This is a relatively common rhythm abnormality following MI, occurring in up to 10% of patients, particularly in cases of inferior MI. It is usually benign, requiring only close observation to ensure that it does not progress to a higher-degree block.

reduced ejection fraction, and found that high-degree AV block was the strongest predictor of mortality. Note this is not the same study as the CHARISMA trial, which examined the effect of clopidogrel and aspirin in combination on cardiovascular events.

A Multiple ventricular ectopics

These can be related to reperfusion and are common in the context of acute MI. The CAST trial demonstrated evidence of harm in attempting to suppress ventricular ectopics with class 1 anti-arrhythmics following MI.

B Accelerated idioventricular rhythm

This is a common rhythm abnormality following MI, occurring in 15-20% of patients. Observation is key, and no treatment is usually needed.

D Mobitz type 1 AV block (Wenckeback phenomenon)

This is a relatively common rhythm abnormality following MI, occurring in up to 10% of patients, particularly in cases of inferior MI. It is usually benign, requiring only close observation to ensure that it does not progress to a higher-degree block.

E Sinus rhythm with rate 30 bpm

Sinus bradycardia is relatively common following MI, and may be due to drugs, ischaemia or a vagal response. Atropine can be used for symptomatic patients, with insertion of a temporary pacing line if this proves ineffective.

Rate this question:

A 53-year-old man has been referred to the Medical Clinic by his GP. In his letter, the GP says he is unsure whether the patient is really hypertensive because his blood pressure at his surgery is usually just borderline (ranges between 145 and 155/80 and 95 mmHg). He has a past medical history of benign prostatic hypertrophy but no history of any cardiovascular disorders.

On examination, his blood pressure is 130/85 mmHg and pulse 70 bpm and regular, his BMI is 34.

What would be the most appropriate step in the management of this patient?

A	Start him on an α-adrenergic blocker
B	Start him on a β-blocker
C	Reassure and discharge from follow-up
D	24 h ambulatory BP monitoring
E	Arrange for ongoing BP monitoring through the GP, with advice to start medication should it remain elevated

2519

Submit

Explanation

D	24 h ambulatory BP monitoring

In such patients where the diagnosis is unclear, an ambulatory 24 h BP monitor may be helpful. This is advocated by ESC guidelines on hypertension, which state that grade 1 hypertension (140–159/90–99) in the healthcare practitioner's office, where there is suspicion of white coat hypertension, can be considered for ambulatory or home BP monitoring. These 'out-of-office' monitoring methodologies are complementary to measurements taken in the healthcare practitioner's office.

A	Start him on an α-adrenergic blocker

Further investigation would be appropriate prior to starting medication in this case. However, were the patient to require anti-hypertensive medication, current NICE guidelines recommend an ACE inhibitor or ARB as first-line therapy in patients under 55 years old.

B	Start him on a β-blocker

Further investigation would be appropriate prior to starting medication in this case. However, were the patient to require anti-hypertensive medication, current NICE guidelines recommend an ACE inhibitor or ARB as first-line therapy in patients under 55 years old.

C	Reassure and discharge from follow-up

Given that this patient has had a number of clinic blood pressures suggestive of low-grade hypertension, it would seem prudent (and indeed is recommended by current ESC guidance) to perform out-of-office monitoring for confirmation.

Further investigation would be appropriate prior to starting medication in this case. However, were the patient to require anti-hypertensive medication, current NICE guidelines recommend an ACE inhibitor or ARB as first-line therapy in patients under 55 years old.

C	Reassure and discharge from follow-up

Given that this patient has had a number of clinic blood pressures suggestive of low-grade hypertension, it would seem prudent (and indeed is recommended by current ESC guidance) to perform out-of-office monitoring for confirmation.

E	Arrange for ongoing BP monitoring through the GP, with advice to start medication should it remain elevated

Given that this patient has had a number of clinic blood pressures suggestive of low-grade hypertension, it would seem prudent (and indeed is recommended by current ESC guidance) to perform out-of-office monitoring for confirmation.

Rate this question:

Next Question

Previous Q... Tag Questi... Feedback End Session

Blog About Pastest Contact Us Help

© Pastest 2019

Rana Alnasser's screen

1:45
On
594-042-7551
Leave

A 48-year-old man is referred to the cardiology clinic with a 6-month history of palpitations.
He describes palpitations every other day, lasting for up to a minute at a time. The palpitations are not associated with shortness of breath, chest pain or dizziness/loss of consciousness, and there is no obvious precipitating factor. They are not impacting on his quality of life, but he has attended for review following encouragement from his family. His past medical history is unremarkable and he is not on any medication.

On examination, he is comfortable with a blood pressure of 132/72 mmHg and pulse rate of 66/min. Cardiovascular, respiratory, abdominal and central nervous systems are all normal.

Investigations:

ECG	sinus rhythm
Chest X-ray	Normal
FBC, U/Es, LFTs, TFTs, lipid profile and Echo	All within normal range
24-hour tape	Sinus rhythm throughout; one episode of premature ventricular ectopics (PVEs) comprising 5 PVEs within 1 min

What is the most appropriate management option?

A Angiography

B Start bisoprolol

C Start verapamil

D Start amiodarone

Audio Video Share Participants More

A 48-year-old man is referred to the cardiology clinic with a 6-month history of palpitations.
He describes palpitations every other day, lasting for up to a minute at a time. The palpitations are not associated with shortness of breath, chest pain or dizziness/loss of consciousness, and there is no obvious precipitating factor. They are not impacting on his quality of life, but he has attended for review following encouragement from his family. His past medical history is unremarkable and he is not on any medication.

On examination, he is comfortable with a blood pressure of 132/72 mmHg and pulse rate of 66/min. Cardiovascular, respiratory, abdominal and central nervous systems are all normal.

Investigations:

ECG	sinus rhythm
Chest X-ray	Normal
FBC, U/Es, LFTs, TFTs, lipid profile and Echo	All within normal range
24-hour tape	Sinus rhythm throughout; one episode of premature ventricular ectopics (PVEs) comprising 5 PVEs within 1 min

What is the most appropriate management option?

Your answer was correct

A Angiography

B Start bisoprolol

C Start verapamil

Diff
Pee
A
B
C
D
E
0 10
Se
Respons
Respons
Respons
Respons
Exte
Frequent
escardio.o

Explanation

E Reassure

With normal echo and 24 h tape, it is unlikely that there is anything sinister going on in this man. PVEs may be considered significant if they fall within any of the following categories:

- Occurring frequently (10 or more beats/hour, or 6 or more beats/min)
- PVE in bigeminal rhythm
- PVE in short runs of ventricular tachycardia
- PVE exhibiting R-on-T phenomenon
- PVE associated with serious organic heart disease such as in the context of MI, and left ventricular decompensation
- PVE associated with significant symptomatology such as syncope.

The symptoms in this young man are not troublesome and he will only need reassurance. Should the PVEs become symptomatically significant, or increase in frequency, a trial of suppression with beta-blocker therapy or rate-limiting calcium channel blocker could be considered.

A Angiography

He does not describe any anginal features, and there is no suggestion from his history, investigations or examination of coronary artery disease.

B Start bisoprolol

Beta-blockers can be used for rate control of arrythmias

of suppression with beta-blocker therapy or rate-limiting calcium channel blocker could be considered.

A Angiography

He does not describe any anginal features, and there is no suggestion from his history, investigations or examination of coronary artery disease.

B Start bisoprolol

Beta-blockers can be used for rate control of arrythmias such as atrial fibrillation, but there is no indication of such an arrhythmia in this case, making beta-blockers an inappropriate choice.

C Start verapamil

Rate-limiting calcium channel blockers such as verapamil can be used to slow ventricular rate in cases of supraventricular tachycardia (though they are not first-line agents for this indication). However, in this case there is no evidence of such an arrhythmia, making calcium channel blockers an inappropriate choice.

D Start amiodarone

Amiodarone would be appropriate to gain control of arrhythmias such as paroxysmal supraventricular, nodal and ventricular tachycardias, atrial fibrillation/flutter, VF and arrhythmia associated with WPW. There is no suggestion of arrhythmia here, making amiodarone an unsuitable choice.

Rate this question:

Next Question

1:50

A 38-year-old man is referred to the Cardiology Clinic by a company doctor for an abnormal heart murmur detected during a routine medical check-up. He had to undergo a medical check-up before starting a new job with the company. He is asymptomatic. His past medical history is unremarkable and he is not on any medication.

On examination, the blood pressure is 135/65 mmHg, with pulse 74/min and regular. His apex beat is in the 6th intercostals space in the anterior axillary line and his jugular venous pulse is not raised. First and second heart sounds are heard and there is a pan-systolic murmur of grade 3/6 radiating to the axilla.

His chest is clinically clear. The following results are obtained:

ECG	sinus rhythm with evidence of left ventricular hypertrophy
Chest X-ray	slight cardiomegaly
Echo	diastolic left ventricular dimension of 6.6 cm with an ejection fraction of 35%. The left atrial dimension is 5.5 cm and there is moderate mitral regurgitation
FBC, U/Es, LFTs, TFTs, urinalysis and lipid profile	All within normal range

How would you manage this young man?

A	Review in 6 months
B	Furosemide

Rana Alnasser's screen

venous pulse is not raised. First and second heart sounds are heard and there is a pan-systolic murmur of grade 3/6 radiating to the axilla.

His chest is clinically clear. The following results are obtained:

ECG	sinus rhythm with evidence of left ventricular hypertrophy
Chest X-ray	slight cardiomegaly
Echo	diastolic left ventricular dimension of 6.6 cm with an ejection fraction of 35%. The left atrial dimension is 5.5 cm and there is moderate mitral regurgitation
FBC, U/Es, LFTs, TFTs, urinalysis and lipid profile	All within normal range

How would you manage this young man?

A	Review in 6 months
B	Furosemide
C	Digoxin
D	Amlodipine
E	Ramipril

70924

Explanation

E Ramipril

There is evidence that ACE inhibitors reduce adverse events in patients with left ventricular dysfunction with no overt heart failure. The Studies of Left Ventricular Dysfunction (SOLVED) study investigated left ventricular dysfunction with and without overt congestive heart failure. In the prevention arm, enalapril reduced the combined incidence of death and development of overt congestive heart failure, and was statistically significant.

A Review in 6 months

Given that the ejection fraction is significantly reduced at 35%, and there is functional MR, non-intervention is inappropriate here.

B Furosemide

Diuretics alone do not impact on outcomes in left ventricular dysfunction, and are unlikely to be of symptomatic benefit bearing in mind there is no overt cardiac failure.

C Digoxin

Digoxin does not carry outcome benefit in heart failure and may indeed increase mortality; it should not therefore be used here.

D Amlodipine

Although dihydropyridine calcium channel blockers reduce BP, they won't impact on the prognosis of heart failure in

Given that the ejection fraction is significantly reduced at 35%, and there is functional MR, non-intervention is inappropriate here.

B Furosemide

Diuretics alone do not impact on outcomes in left ventricular dysfunction, and are unlikely to be of symptomatic benefit bearing in mind there is no overt cardiac failure.

C Digoxin

Digoxin does not carry outcome benefit in heart failure and may indeed increase mortality; it should not therefore be used here.

D Amlodipine

Although dihydropyridine calcium channel blockers reduce BP, they won't impact on the prognosis of heart failure in this situation.

Rate this question:

Next Question

© Pastest 2019

You review a 54-year-old woman who is tired and lethargic. She has undergone multiple dental extractions during the past few months. There is a past history of Sydenham's chorea, but nil else of note.

On examination, you notice subungual splinter haemorrhages and an ejection systolic murmur. A trans thoracic echocardiogram (TTE) is performed, the results of which do not confirm the presence of vegitations.

Which of the following is the most appropriate next investigation?

A	A transoesophageal echocardiogram (TOE)
B	Labelled white cell scan
C	At least three sets of blood cultures from different sites
D	Erythrocyte sedimentation rate (ESR)
E	Plasma viscosity

71652

Submit

You review a 54-year-old woman who is tired and lethargic. She has undergone multiple dental extractions during the past few months. There is a past history of Sydenham's chorea, but nil else of note.

On examination, you notice subungual splinter haemorrhages and an ejection systolic murmur. A trans thoracic echocardiogram (TTE) is performed, the results of which do not confirm the presence of vegitations.

Which of the following is the most appropriate next investigation?

Your answer was correct

A	A transoesophageal echocardiogram (TOE)
B	Labelled white cell scan
C	At least three sets of blood cultures from different sites
D	Erythrocyte sedimentation rate (ESR)
E	Plasma viscosity

Explanation

C At least three sets of blood cultures from different sites

According to Duke's criteria for diagnosis of infective endocarditis, the 2 major criteria would be a positive blood culture of typical organism and presence of vegetation on

Explanation

C	At least three sets of blood cultures from different sites

According to Duke's criteria for diagnosis of infective endocarditis, the 2 major criteria would be a positive blood culture of typical organism and presence of vegetation on echocardiogram. In this patient, the index of suspicion is high (dental work, previous history of valvular heart disease, peripheral signs and murmur). Therefore, the initial investigation would be to obtain the blood cultures before starting antibiotic therapy.

Three sets of blood cultures from different sites are positive in 75% of cases of bacterial endocarditis, the suspected diagnosis here. The past history of Sydenham's chorea, (a condition associated with rheumatic fever) is suggestive of a pre-existing valve lesion (Duke's minor), the recent dental work providing a vector for infection. Clinical examination finding of splinters (Duke's minor) and murmur also increases the index of suspicion.

Streptococcus viridans is the usual infecting agent from dental work and is in total responsible for around 60% of cases of subacute bacterial endocarditis. Staphylococcus aureus is the most commoncause of endocarditis in prosthetic valve disease, acute infective endocarditis, and endocarditis related to IV drug abuse. Benzylpenicillin and gentamicin is the treatment of choice, this being a circumstance when the gentamicin is usually given in divided doses rather than the usual practice of once daily dosing. The antibiotics are normally given for a prolonged period (4-6 weeks) depending on response. Some patients require surgical intervention on their valves due to complications from IE (aortic root abscess, septic emboli, large vegetations causing significant valvular dysfunction).

A	A transoesophageal echocardiogram (TOE)

100% 1:58

complications from IE (aortic root abscess, septic emboli, large vegetations causing significant valvular dysfunction).

A A transoesophageal echocardiogram (TOE)

The use of TOE should be reserved for cases where the transthoracic echocardiogram was inconclusive. However, three sets of blood cultures is a much less invasive way of confirming a major criteria and hence diagnosis in this case.. If blood cultures were negative, then you would consider TOE.

B Labelled white cell scan

A labelled white cell scan would be indicated if both TTE and TOE were inconclusive for infective endocarditis to find the source of sepsis. It would not be indicated as a first line investigation for suspected infective endocarditis.

D Erythrocyte sedimentation rate (ESR)

ESR will be raised in the presence of any inflammatory process. Although it might aid in the diagnosis, it is too non-specific to help and therefore would not be the best initial investigation although one might still perform it as part of the initial workup.

E Plasma viscosity

Like ESR, PV is raised in inflammatory processes. The low specificity makes it a less useful test.

77652

Rate this question:

100% 1:58

You are called to see a 59-year-old man on the coronary care unit who has suffered an upper GI haemorrhage of 250 ml of fresh blood. He is recovering on the cardiology ward following PCI and stenting for inferior myocardial infarction some 3 days earlier. He is still under treatment with fondaparinux, clopidogrel and aspirin. On examination his BP is 100/70 mmHg, and there is a postural drop of 15 mmHg on moving from lying to sitting. Heart sounds are normal and his chest is clear. He has epigastric pain on palpation and admits to taking over-the-counter indigestion medications for many months before admission. PR reveals melaena.

Investigations:

Hb	7.9 g/dl
WCC	11.1 $\times 10^9$/l
PLT	189 $\times 10^9$/l
Na^+	137 mmol/l
K^+	4.3 mmol/l
Creatinine	112 micromol/l
Urea	14.2 mmol/l

You start IV fluids and arrange a blood transfusion.

Which of the following is the most appropriate next step?

A Stop aspirin

B Stop clopidogrel

C Stop aspirin and clopidogrel

D Stop fondaparinux

ward following PCI and stenting for inferior myocardial infarction some 3 days earlier. He is still under treatment with fondaparinux, clopidogrel and aspirin. On examination his BP is 100/70 mmHg, and there is a postural drop of 15 mmHg on moving from lying to sitting. Heart sounds are normal and his chest is clear. He has epigastric pain on palpation and admits to taking over-the-counter indigestion medications for many months before admission. PR reveals melaena.

Investigations:

Hb	7.9 g/dl
WCC	11.1 x10^9/l
PLT	189 x10^9/l
Na^+	137 mmol/l
K^+	4.3 mmol/l
Creatinine	112 micromol/l
Urea	14.2 mmol/l

You start IV fluids and arrange a blood transfusion.

Which of the following is the most appropriate next step?

A	Stop aspirin
B	Stop clopidogrel
C	Stop aspirin and clopidogrel
D	Stop fondaparinux
E	Stop aspirin, clopidogrel and fondaparinux

indigestion medications for many months before admission. PR reveals melaena.

Investigations:

Hb	7.9 g/dl
WCC	11.1 x10^9/l
PLT	189 x10^9/l
Na^+	137 mmol/l
K^+	4.3 mmol/l
Creatinine	112 micromol/l
Urea	14.2 mmol/l

You start IV fluids and arrange a blood transfusion.

Which of the following is the most appropriate next step?

Your answer was correct

A Stop aspirin

B Stop clopidogrel

C Stop aspirin and clopidogrel

D Stop fondaparinux

E Stop aspirin, clopidogrel and fondaparinux

Explanation

D Stop fondaparinux

D Stop fondaparinux

This patient has developed a significant upper gastrointestinal haemorrhage on the background of a recent angioplasty. The patient is on three medications, each of which will increase the risk of bleeding. Both clopidogrel and aspirin are important to reduce the risk of stent thrombosis and should be continued if possible. As a result, fondaparinux is the most appropriate medication to be stopped initially.

A Stop aspirin

This patient has had recent angioplasty. Dual anti-platelet therapy (DAPT) is required to reduce the risk of acute stent thrombosis. The risk of stent thrombosis is highest in the acute period and, if possible, DAPT should not be stopped in this patient.

B Stop clopidogrel

Clopidogrel or another anti-platelet agent in combination with aspirin is the standard of care for patients following the implantation of a cardiac stent. If stopped in the acute setting, the risk of stent thrombosis will increase.

C Stop aspirin and clopidogrel

As above, both these agents are required to reduce the risk of stent thrombosis. They should not be stopped unless the bleeding remains uncontrolled following further management and cessation of fondaparinux has not improved the situation.

E Stop aspirin, clopidogrel and fondaparinux

Stopping all three of these agents would significantly risk

B Stop clopidogrel

Clopidogrel or another anti-platelet agent in combination with aspirin is the standard of care for patients following the implantation of a cardiac stent. If stopped in the acute setting, the risk of stent thrombosis will increase.

C Stop aspirin and clopidogrel

As above, both these agents are required to reduce the risk of stent thrombosis. They should not be stopped unless the bleeding remains uncontrolled following further management and cessation of fondaparinux has not improved the situation.

E Stop aspirin, clopidogrel and fondaparinux

Stopping all three of these agents would significantly risk stent thrombosis in this patient. Fondaparinux is the least important of these three in the post-myocardial infarction period, and should be stopped while both aspirin and clopidogrel are continued initially.

Rate this question:

© Pastest 2019

You are the on-call cardiology senior house officer (SHO) at a tertiary centre. You are asked to see a 72-year-old man, known to have mild aortic stenosis, admitted to the Surgical High Dependency Unit after having had a total left knee replacement under general anaesthetic. The procedure went well and as planned but unfortunately, in recovery an hour ago, the patient's heart rate was noted to jump to 165/min. The ward FY1 has then bleeped you seeking advice.

When you arrive the patient's observations show: RR 25/min, sats 98% on air, BP 75/40, HR 165/min and temperature 36.5°C. The FY1 has given 1L of Hartmann's solution over the last 1 hour with no change in the patient's blood pressure. His electrocardiogram (ECG) shows atrial fibrillation with left ventricular hypertrophy meeting voltage criteria and global ischaemic changes.

The patient is alert and appears anxious and complains of vague discomfort in the chest that began roughly half an hour ago. Capillary blood glucose measurement was normal.

Which of the following is the most appropriate next option for the management of this patient?

A	Rapid bolus of 6 mg IV adenosine
B	Single oral dose of 5 mg bisoprolol
C	Commence rapid loading of digoxin
D	Commence 300 mg loading dose of IV amiodarone
E	Arrange for synchronised DC cardioversion

25/min, sats 98% on air, BP 75/40, HR 165/min and temperature 36.5°C. The FY1 has given 1L of Hartmann's solution over the last 1 hour with no change in the patient's blood pressure. His electrocardiogram (ECG) shows atrial fibrillation with left ventricular hypertrophy meeting voltage criteria and global ischaemic changes.

The patient is alert and appears anxious and complains of vague discomfort in the chest that began roughly half an hour ago. Capillary blood glucose measurement was normal.

Which of the following is the most appropriate next option for the management of this patient?

Your answer was correct

A	Rapid bolus of 6 mg IV adenosine
B	Single oral dose of 5 mg bisoprolol
C	Commence rapid loading of digoxin
D	Commence 300 mg loading dose of IV amiodarone
E	Arrange for synchronised DC cardioversion

Explanation

E Arrange for synchronised DC cardioversion

This patient has developed a tachycardia with features of compromise, as evidenced by his low blood pressure (shock), ischaemic changes on ECG and new onset of chest pain. Other features of compromise include syncope/ loss of consciousness and signs of acute heart failure

100% 2:03

E Arrange for synchronised DC cardioversion

This patient has developed a tachycardia with features of compromise, as evidenced by his low blood pressure (shock), ischaemic changes on ECG and new onset of chest pain. Other features of compromise include syncope/ loss of consciousness and signs of acute heart failure.

In an unstable patient, the appropriate next step is DC cardioversion to restore a stable sinus rhythm. This should reverse the hypotension and rate-related ECG changes/chest pain. This should of course be done with the airway support of our anaesthetic colleagues if possible. The main risk of attempting cardioversion of any form is the risk of thromboembolic stroke. It is generally accepted that the first 24 h from the onset of atrial fibrillation is the 'safe window' for attempting cardioversion. In this case we have a clear time of onset.

A Rapid bolus of 6 mg IV adenosine

The patient is compromised and needs immediate cardioversion to a stable rhythm. Furthermore, adenosine has no role in the management of atrial fibrillation. It might be considered as a treatment while setting up for DC cardioversion in patients with supraventricular tachycardias like AVRT or AVNRT.

B Single oral dose of 5 mg bisoprolol

While this might have been an option if the patient was stable, this is a dangerous option in this case as it will likely drop his blood pressure further.

C Commence rapid loading of digoxin

Sclerosis

- Sclerosis – ↑ Density of bone.
- Can be focal or diffuse
- Etiologies include:
  - Osteoblastic metastasis
  - Primary bone tumor
  - Various benign tumor-like bone lesions
  - Paget's disease
  - Chronic osteomyelitis

A 70 year-old man with known type 2 diabetes is referred to the cardiology clinic by his GP with a three-month history of intermittent palpitations. He describes these as fast and irregular and of sudden onset and termination. He has felt quite light-headed on a couple of occasions during these palpitations but denies any chest pain or shortness of breath. The GP mentions in the referral letter that he has a borderline high blood pressure and was recently started on ramipril. There is no other past medical history of note. Examination reveals a blood pressure (BP) of 145/95 mmHg but is otherwise unremarkable. A routine electrocardiogram (ECG) shows sinus rhythm with left ventricular hypertrophy.

Investigations

Hb	13.1 g/dl
WCC	5.6 x 10^9/l
PLT	253 x 10^9/l
Na^+	136 mmol/l
K^+	4.8 mmol/l
urea	5.0 mmol/l
creatinine	99 µmol/l
TSH	3 mU/l

A 24 h ambulatory ECG test reveals episodes of paroxysmal atrial fibrillation. An echocardiogram shows concentric hypertrophy with mild to moderate impairment of left ventricular systolic function, normal atria and no significant valvular pathology.

Which one of the following would be the anti-arrhythmic treatment of choice?

A Flecainide

Rana Alnasser's screen

creatinine	99 μmol/l
TSH	3 mU/l

A 24 h ambulatory ECG test reveals episodes of paroxysmal atrial fibrillation. An echocardiogram shows concentric hypertrophy with mild to moderate impairment of left ventricular systolic function, normal atria and no significant valvular pathology.

Which one of the following would be the anti-arrhythmic treatment of choice?

A Flecainide

B Bisoprolol

C Digoxin

D Amiodarone

E Verapamil

Submit

Previous Q... Skip Questi...

© Pastest 2019

Rana Alnasser's screen

TSH	3 mU/l

A 24 h ambulatory ECG test reveals episodes of paroxysmal atrial fibrillation. An echocardiogram shows concentric hypertrophy with mild to moderate impairment of left ventricular systolic function, normal atria and no significant valvular pathology.

Which one of the following would be the anti-arrhythmic treatment of choice?

Your answer was correct

A Flecainide

B Bisoprolol

C Digoxin

D Amiodarone

E Verapamil

Explanation

B Bisoprolol

This is the first-line treatment for patients with paroxysmal atrial fibrillation. It can limit the episodes of paroxysmal AF, aid rate control during the episodes and is beneficial for this gentleman's left ventricular systolic impairment and hypertension. With regard to anticoagulation, the risk of stroke from atrial fibrillation is calculated using the CHA2DS2-VASc score. A score of 0 is considered 'low' risk and may not require anticoagulation; a score of 1 is 'low-moderate' risk and anticoagulation should be considered; a

Rana Alnasser's screen

B Bisoprolol

This is the first-line treatment for patients with paroxysmal atrial fibrillation. It can limit the episodes of paroxysmal AF, aid rate control during the episodes and is beneficial for this gentleman's left ventricular systolic impairment and hypertension. With regard to anticoagulation, the risk of stroke from atrial fibrillation is calculated using the CHA2DS2-VASc score. A score of 0 is considered 'low' risk and may not require anticoagulation; a score of 1 is 'low-moderate' risk and anticoagulation should be considered; a score of 2 or greater is 'moderate-high' risk and the patient should be anticoagulated assuming no contraindications.

A Flecainide

Flecainide is contraindicated in patients with structural heart abnormalities or at risk of ischaemic heart disease.

C Digoxin

Digoxin does not reduce the risk of onset of atrial fibrillation and therefore does not have a role in paroxysmal AF.

D Amiodarone

While effective, this should be reserved for refractory cases due to its extensive side effect profile.

E Verapamil

Bisoprolol is the first-line option and also has the added virtue of evidence-based benefit in patients with left ventricular systolic dysfunction. However, this might be an option for acute rate control in a patient without signs of heart failure in whom a beta blocker is contraindicated - for

Rana Alnasser's screen

Flecainide is contraindicated in patients with structural heart abnormalities or at risk of ischaemic heart disease.

C Digoxin

Digoxin does not reduce the risk of onset of atrial fibrillation and therefore does not have a role in paroxysmal AF.

D Amiodarone

While effective, this should be reserved for refractory cases due to its extensive side effect profile.

E Verapamil

Bisoprolol is the first-line option and also has the added virtue of evidence-based benefit in patients with left ventricular systolic dysfunction. However, this might be an option for acute rate control in a patient without signs of heart failure in whom a beta blocker is contraindicated - for example a patient with asthma.

Rate this question:

© Pastest 2019

8:45

A 35-year-old woman presents to the Emergency Department with a 2-day history of dyspnoea on minimal exertion, paroxysmal nocturnal dyspnoea and a non-productive cough. She is 36 weeks' pregnant with twins, the pregnancy having been thus far uncomplicated. She has had two previous uncomplicated pregnancies which resulted in normal vaginal deliveries. There is no history of headache, visual disturbance, abdominal pain or peripheral oedema. There is no history of cardiovascular disease. There is no history of alcohol or illicit drug ingestion. She is a non-smoker.

On examination, the patient is tachypnoeic with a respiratory rate of 28/min and she has a tachycardia of 130/min. Her pulse is regularly regular. She has an elevated jugular venous pulse, a loud P2 and coarse crackles at both lung bases. Blood pressure is 100/60 mmHg. There is no hyper-reflexia or clonus. She is afebrile.

A chest X-ray performed with abdominal shielding reveals cardiomegaly and bilateral pulmonary oedema. Transthoracic echocardiography reveals left systolic dysfunction with an ejection fraction of 30%. Urinalysis is normal. Full blood count, urea and electrolytes, troponin and liver function tests are all within normal limits. The ECG reveals sinus tachycardia. There are no ischaemic changes.

What is the most likely diagnosis?

A	Pre-eclampsia
B	Eclampsia
C	Hypertensive cardiomyopathy
D	Non-cardiogenic pulmonary oedema of pregnancy
E	Peripartum cardiomyopathy

Rana Alnasser's screen

A 35-year-old woman presents to the Emergency Department with a 2-day history of dyspnoea on minimal exertion, paroxysmal nocturnal dyspnoea and a non-productive cough. She is 36 weeks' pregnant with twins, the pregnancy having been thus far uncomplicated. She has had two previous uncomplicated pregnancies which resulted in normal vaginal deliveries. There is no history of headache, visual disturbance, abdominal pain or peripheral oedema. There is no history of cardiovascular disease. There is no history of alcohol or illicit drug ingestion. She is a non-smoker.

On examination, the patient is tachypnoeic with a respiratory rate of 28/min and she has a tachycardia of 130/min. Her pulse is regularly regular. She has an elevated jugular venous pulse, a loud P2 and coarse crackles at both lung bases. Blood pressure is 100/60 mmHg. There is no hyper-reflexia or clonus. She is afebrile.

A chest X-ray performed with abdominal shielding reveals cardiomegaly and bilateral pulmonary oedema. Transthoracic echocardiography reveals left systolic dysfunction with an ejection fraction of 30%. Urinalysis is normal. Full blood count, urea and electrolytes, troponin and liver function tests are all within normal limits. The ECG reveals sinus tachycardia. There are no ischaemic changes.

What is the most likely diagnosis?

Your answer was correct

A	Pre-eclampsia
B	Eclampsia
C	Hypertensive cardiomyopathy
D	Non-cardiogenic pulmonary oedema of pregnancy

E Peripartum cardiomyopathy

Peripartum cardiomyopathy is a dilated cardiomyopathy of uncertain aetiology occurring in the last month of pregnancy or within 5 months after delivery. Symptoms are the same as those of cardiac failure in non-pregnant patients. In order to make the diagnosis there must be (1) absence of any other cause for the cardiac failure, (2) absence of heart disease before the last month of pregnancy and (3) documented systolic dysfunction.

A Pre-eclampsia

Pre-eclampsia is an important differential and must be excluded. A history of visual disturbance, headache, abdominal pain and peripheral oedema along with hyper-reflexia, clonus, right-upper-quadrant tenderness, renal impairment and proteinuria all suggest pre-eclampsia.

B Eclampsia

Ecalmpsia presents with precipitously high blood pressure, decreased consciousness and seizures.

C Hypertensive cardiomyopathy

Hypertensive cardiomyopathy is unusual in the context of pregnancy, and the blood pressure of 100/60 effectively rules this out.

D Non-cardiogenic pulmonary oedema of pregnancy

The reduced ejection fraction of 30% suggests this patient has cardiac failure rather than non-cardiogenic pulmonary oedema.

A 69-year-old man presented to the Emergency Department of a District General Hospital with central chest pain. The hospital does not have an on-site acute angiography service. The pains started when he was walking uphill from the park to his house. The pains were very severe and radiated to his neck, jaw and left arm. The severe pains lasted for about an hour and this was 5 h ago. He had never experienced such severe pains before and thought he was going to die. He still has some dull chest pains but not very severe. He felt nauseated but did not vomit. In the past, he has occasionally had some chest tightness, which came on with strenuous exertion, and he had managed very well by avoiding activities that brought the pain on. He is not on any medication.

On examination, he is alert, distressed, his blood pressure is 110/84 mmHg and pulse 76/min regular. First and second heart sounds are heard and there are no murmurs. His chest is clinically clear.

Investigations:

Hb	16.1 g/dl
WCC	13.2×10^9/l
PLT	256×10^9/l
Na^+	136 mmol/l
K^+	4.2 mmol/l
Creatinine	176 µmol/l
MCV	82 fl
Urea	7.4 mmol/l
Troponin T	Awaited
ECG	Normal sinus rhythm, inferior ST depression
CXR	Unremarkable

Rana Alnasser's screen

WCC	13.2 × 10⁹/l
PLT	256 × 10^9/l
Na^+	136 mmol/l
K^+	4.2 mmol/l
Creatinine	176 µmol/l
MCV	82 fl
Urea	7.4 mmol/l
Troponin T	Awaited
ECG	Normal sinus rhythm, inferior ST depression
CXR	Unremarkable
O_2 saturation	96% on air

You give him diamorphine, fondaparinux and aspirin.

Which one of the following additional medications would you immediately start this patient on?

A TPA

B Tirofiban

C Atorvastatin

D Bisoprolol

E Clopidogrel

Urea	7.4 mmol/l
Troponin T	Awaited
ECG	Normal sinus rhythm, inferior ST depression
CXR	Unremarkable
O_2 saturation	96% on air

You give him diamorphine, fondaparinux and aspirin.

Which one of the following additional medications would you immediately start this patient on?

Your answer was correct

A TPA

B Tirofiban

C Atorvastatin

D Bisoprolol

E Clopidogrel

Explanation

E Clopidogrel

This gentleman has chest pain which is suspicious for ischaemic cardiac pain, but his ECG only shows inferior ST depression. The nature of his pain and ECG changes mean

E Clopidogrel

This gentleman has chest pain which is suspicious for ischaemic cardiac pain, but his ECG only shows inferior ST depression. The nature of his pain and ECG changes mean that it is prudent to manage him with fondaparinux, aspirin and clopidogrel until a troponin level is obtained. The upper limit of normal for troponin has recently been lowered, and with the success of angioplasty and aggressive preventative pharmacotherapy, the threshold for intervention in coronary disease has generally been lowered over the past few years. Of course if his cholesterol is elevated, statin therapy is highly likely to be instigated.

A TPA

TPA isn't indicated as there is no evidence yet of a STEMI; in any case, PCS is preferred to thrombolysis for the treatment of STEMI.

B Tirofiban

Tirofiban is a IIbIIIa platelet inhibitor and is indicated for use in NSTEMI, although use of IIbIIIa inhibitors has largely been superseded by high-dose PY12 inhibitors such as clopidogrel in combination with aspirin.

C Atorvastatin

Of course statins are indicated in this patient population, although the most important intervention early in treatment is the move to dual anti-platelet therapy.

D Bisoprolol

A 23-year-old male presents with a history of palpitations of 3 years' duration. He describes them as forceful contractions that he can hear very loudly and at times he feels as if he had skipped beats. These feelings occur more often when he is under stress, and sometimes are associated with a feeling of inability to get enough breath into his lungs. One week ago he had an attack of palpitations while at university, lasting for 10 minutes and associated with shaking, sweating, chest pain, shortness of breath, throat tightness and light-headedness. His father died of a heart attack at the age of 55 years, and two of his uncles have permanent pacemakers implanted for sick sinus syndrome. Physical examination reveals a lean and tall young male with heart rate of 68/min, blood pressure 115/70 mmHg and respiratory rate of 14/min. He has a high arched palate, normal jugular venous pulse, normal heart sounds and clear lung fields.

An ECG tracing is obtained and is shown below.

What is shown on his ECG tracing?

A	Sinus pause
B	Second degree heart block type 1
C	Second degree heart block type 2
D	First degree heart block
E	Sinus arrhythmia

8:56
594-042-7551
Leave

E Sinus arrhythmia

The ECG tracing shows a normal P wave, PR interval, QRS complex and each P wave conducted to the ventricles. There is a gradual decrease in R–R interval and then an increase again. This slight beat-to-beat variation is termed sinus arrhythmia, and the most common cause is respiration. Respiratory sinus arrhythmia is thus heart rate variability in synchrony with respiration, and is normal in children and young adults. The R–R interval decreases with inspiration and increases with expiration. The episode of palpitations in this patient is suggestive of anxiety, and hence he should be reassured. In sinus arrest, sinoatrial exit block or sinus pause, the R–R interval does not have a rhythmic and cyclical variation; rather there is unexpected disappearance of the P wave for a variable interval.

A Sinus pause

In cases of sinus pause, there is a prolonged interval between one sinus beat and the following one. Due to AV nodal automaticity, 'junctional' depolarisation may be seen. There is not the same rhythmic and cyclical variation in R–R interval seen in sinus arrhythmia – rather there is unexpected disappearance of the P wave for a variable interval.

B Second degree heart block type 1

In second degree heart block, there is abnormal prolongation of the PR interval. This either lengthens (type 1) or remains fixed (type 2) prior to a 'dropped' ventricular beat. Here, there is a normal PR interval, and no evidence of a P wave that fails to be followed by a QRS complex.

C Second degree heart block type 2

Audio Video Share Participants More

A 70-year-old man was admitted to the Emergency Department with central chest pains, which had started three hours earlier. The pain was crushing in nature, radiating to both arms and associated with nausea and vomiting. He has a past medical history of angina, hypertension and type II diabetes. He is on the following medications: glyceryl trinitrate (GTN) spray prn, amlodipine 10 mg od, atorvastatin 40 mg nocte, metformin 500 mg tds and aspirin 75 mg od. On examination, he was sweaty with a blood pressure of 155/95 mmHg, pulse of 98/min and regular. His respiratory rate was 24/min and his chest was clinically clear. His jugular venous pulse was just visible; first and second heart sounds were heard with no added murmurs.

Investigations:

Hb	15.8 g/dl
WCC	14.1×10^9/l
PLT	240×10^9 /l
Na^+	141 mmol/l
K^+	3.8 mmol/l
Creatinine	121 μmol/l
MCV	88.6 fl
Urea	7.1 mmol/l
ECG	ST elevation of 3 mm in V_1–V_4, with reciprocal ST depression in the inferior leads

He was given diamorphine and metoclopramide before being taken to the cardiac catheterisation laboratory, where he received urgent coronary angioplasty. Subsequently, he was transferred to the CCU for further care. Two days into his recovery he suddenly developed

Na^+	141 mmol/l
K^+	3.8 mmol/l
Creatinine	121 μmol/l
MCV	88.6 fl
Urea	7.1 mmol/l
ECG	ST elevation of 3 mm in V_1–V_4, with reciprocal ST depression in the inferior leads

He was given diamorphine and metoclopramide before being taken to the cardiac catheterisation laboratory, where he received urgent coronary angioplasty. Subsequently, he was transferred to the CCU for further care. Two days into his recovery he suddenly developed recurrent chest pain. His blood pressure became unrecordable and he went into profound shock with electromechanical dissociation. Resuscitative measures were started but the patient died within a few minutes.

What is the most likely complication?

A Ventricular free wall rupture

B Acute mitral regurgitation

C Extension of the infarct

D Pulmonary embolism

E Ruptured ventricular septum

7487

Submit

A Ventricular free wall rupture

Autopsy studies reveal that ventricular free wall rupture occurs about 10 times more frequently than post-infarction ventricular septal rupture, in about 11% of patients following acute myocardial infarction. Ventricular rupture and cardiogenic shock are now the leading causes of death following acute myocardial infarction, and together account for over two-thirds of early deaths in patients suffering their first acute infarction.

B Acute mitral regurgitation

Coronary ischemia is responsible for 3-25% of mitral regurgitation. The classical presentation is acute heart failure with a murmur of mitral regurgitation, which is a high-pitched systolic murmur beginning with the first heart sound and extending to the second heart sound. There is no murmur in this case.

C Extension of the infarct

For infarct extension there is a progressive increase in the amount of myocardial necrosis in the infarct zone of the original myocardial infarction. After fibrinolytic therapy, re-occlusion with extension of infarct occurs in 5-10% of patients. Patients with infarct extension present with continuous or intermittent chest pain, with protracted elevation in the creatine kinase level and occasionally new electrocardiographic changes.

D Pulmonary embolism

Pulmonary embolism will present with haemoptysis, tachycardia and tachypnoea, with some signs of the source of pulmonary embolism such as swollen calf, consistent with deep vein thrombosis. It is not the clinical

A 19-year-old girl presents to the Emergency Department complaining of palpitations that have started suddenly and have lasted for 20 min. She is now starting to complain of some chest discomfort and dizziness. On arrival she is found to have a heart rate of 180 beats/min and a blood pressure of 95/60 mmHg. The initial electrocardiogram (ECG) confirms the diagnosis of supra-ventricular tachycardia (SVT). This is terminated using 6 mg of adenosine intravenously. The subsequent ECG shows sinus rhythm with a PR interval of 0.08 s and delta waves.

Which of the following is the treatment of choice?

A	Amiodarone
B	Referral for RadioFrequency ablation
C	Flecainide
D	Bisoprolol
E	Mexiletine

6930

Submit

© Pastest 2019

B Referral for RadioFrequency ablation

The presence of an accessory connection between the atria and the ventricles by-passing the atrioventricular node leads to the typical ECG appearance of a short PR interval and a delta-wave on the QRS (pre-excitation ECG). The ECG after the termination of the SVT is characteristic of Wolff–Parkinson–White syndrome (WPW). The prevalence of WPW is around 1/1000, with a male:female ratio of 2:1. The patient is symptomatic when in the SVT (chest discomfort and dizziness in association with palpitations) and should therefore be referred to an electrocardiologist for consideration of an electrophysiological study (EPS) and radiofrequency ablation.

A Amiodarone

Amiodarone is more commonly used in patients with ventricular arrhythmias and atrial fibrillation.

C Flecainide

Although flecainide, a class 1C agent that increases the refractoriness of the accessory pathway and exhibits a useful property known as 'use-dependence', can be used in the treatment of SVT and uncomplicated WPW with structurally normal hearts, the patient is now back in sinus rhythm and definitive treatment treatment consists of modification of the substrate through radiofrequency of ablation.

D Bisoprolol

Bisoprolol prolongs conduction time and increases the refractoriness of the AV node. Although beta-blockers are sometimes used in the treatment of AVNT and AVNRT, they are not considered first-line treatment for WPW and hypotension may preclude their use.

A 25-year-old woman who has recently arrived in the UK presents to her general practitioner (GP) complaining of intermittent episodes of breathlessness associated with palpitations. She describes these as fast and irregular, and of sudden onset and termination. There is no associated chest pain but she has felt dizzy on a couple of occasions. On examination she has a blood pressure of 125/78 mmHg and a heart rate of 86/min. There is a diastolic murmur over the apex of the heart and the lungs are clear. A 12-lead electrocardiogram (ECG) shows sinus rhythm with bifid P waves.

Which of the following agents is the most appropriate in this case?

A Bisoprolol

B Digoxin

C Amiodarone

D Flecainide

E Mexiletine

Submit

Previous Q... Skip Questi...

9:03
594-042-7551
Leave

A 25-year-old woman who has recently arrived in the UK presents to her general practitioner (GP) complaining of intermittent episodes of breathlessness associated with palpitations. She describes these as fast and irregular, and of sudden onset and termination. There is no associated chest pain but she has felt dizzy on a couple of occasions. On examination she has a blood pressure of 125/78 mmHg and a heart rate of 86/min. There is a diastolic murmur over the apex of the heart and the lungs are clear. A 12-lead electrocardiogram (ECG) shows sinus rhythm with bifid P waves.

Which of the following agents is the most appropriate in this case?

Your answer was correct

A Bisoprolol

B Digoxin

C Amiodarone

D Flecainide

E Mexiletine

Explanation

A Bisoprolol

The finding of a diastolic murmur combined with the presence of a bifid P wave (P-mitrale) on the

Audio Video Share Participants More

9:03
594-042-7551
Leave

A Bisoprolol

The finding of a diastolic murmur combined with the presence of a bifid P wave (P-mitrale) on the electrocardiogram (ECG) points towards the diagnosis of mitral stenosis. The episodes of palpitations most likely represent episodes of paroxysmal atrial fibrillation (AF). A beta-blocker can be used as first-line treatment to prevent atrial tachy-arrhythmias, and slow down the heart rate in sinus rhythm, thus increasing diastolic time and augmenting cardiac output. Digoxin is not particularly helpful in paroxysmal AF, and amiodarone should be reserved for resistant cases.

B Digoxin

It is not an agent recommended for paroxysmal AF. There is evidence that it does not prevent paroxysmal attacks, and may even prolong attacks when they occur.

C Amiodarone

This (or dronedarone) would be indicated in cases of beta-blocker failure/resistant cases, assuming the patient meets the NICE criteria for its use.

D Flecainide

NICE guidelines state its use should be reserved for people with no evidence of structural or ischaemic heart disease. In this case bisoprolol is the preferred initial intervention, flecainide could be considered as a second line therapy.

E Mexiletine

It is a class 1b anti-arrhythmic, which is unlicensed in the UK but available on special order for cases of life-

Audio Video Share Participants More

9:04
594-042-7551
Leave

B Digoxin

It is not an agent recommended for paroxysmal AF. There is evidence that it does not prevent paroxysmal attacks, and may even prolong attacks when they occur.

C Amiodarone

This (or dronedarone) would be indicated in cases of beta-blocker failure/resistant cases, assuming the patient meets the NICE criteria for its use.

D Flecainide

NICE guidelines state its use should be reserved for people with no evidence of structural or ischaemic heart disease. In this case bisoprolol is the preferred initial intervention, flecainide could be considered as a second line therapy.

E Mexiletine

It is a class 1b anti-arrhythmic, which is unlicensed in the UK but available on special order for cases of life-threatening ventricular arrhythmia.

32348
Rate this question:

Audio Video Share Participants More

9:05

A 73-year-old man presents to his general practitioner (GP) with shortness of breath on exertion. This has been getting progressively worse over the last 6 months. He has found that he has to prop himself up with three pillows to go to sleep and there have been a couple of occasions when he woke up in the middle of the night with shortness of breath. He denies any history of chest pain or palpitations. There is no past medical history and he is on no medications. On examination his blood pressure is 168/105 mmHg and his heart rate is 85/min. There is a pansystolic murmur on auscultation of his heart and bi-basal crackles on auscultation of his chest. There is bipedal oedema around his ankles.

Which of the following findings, if present, would be associated with the worst prognosis in this case?

A	Cardiomegaly on chest X-ray
B	Mitral regurgitation on echo
C	Ejection fraction of 50% on echo
D	Left ventricular hypertrophy on ECG
E	Serum sodium of 129 mmol/l

Submit

Previous Q... Skip Questi...

Rana Alnasser's screen

Explanation

E	Serum sodium of 129 mmol/l

This patient presents with symptoms and signs of congestive cardiac failure. Given the history, the most likely cause for this is left ventricular failure secondary to hypertension. Non-iatrogenic hyponatraemia in the context of congestive cardiac failure carries a poor prognosis as it is secondary to significant fluid overload. It was thought that specific vasopressin antagonists may offer a significant prognostic advantage in patients with heart failure and marked hyponatraemia, but the data so far have proved very disappointing.

A	Cardiomegaly on chest X-ray

This patient is markedly hypertensive on presentation, and it could be surmised that this is long-standing and uncontrolled. In this context, cardiomegaly is not an unexpected finding.

B	Mitral regurgitation on echo

This is the most common form of valvular heart disease in developed countries, and while it would be important to quantify and monitor, it is not the most prognostically adverse feature here.

C	Ejection fraction of 50% on echo

This is at the lower end of the normal range, and would not represent the most prognostically adverse finding here.

D	Left ventricular hypertrophy on ECG

This patient is markedly hypertensive on presentation, and

cause for this is left ventricular failure secondary to hypertension. Non-iatrogenic hyponatraemia in the context of congestive cardiac failure carries a poor prognosis as it is secondary to significant fluid overload. It was thought that specific vasopressin antagonists may offer a significant prognostic advantage in patients with heart failure and marked hyponatraemia, but the data so far have proved very disappointing.

A Cardiomegaly on chest X-ray

This patient is markedly hypertensive on presentation, and it could be surmised that this is long-standing and uncontrolled. In this context, cardiomegaly is not an unexpected finding.

B Mitral regurgitation on echo

This is the most common form of valvular heart disease in developed countries, and while it would be important to quantify and monitor, it is not the most prognostically adverse feature here.

C Ejection fraction of 50% on echo

This is at the lower end of the normal range, and would not represent the most prognostically adverse finding here.

D Left ventricular hypertrophy on ECG

This patient is markedly hypertensive on presentation, and it could be surmised that this is long-standing and uncontrolled. In this context, LVH is not an unexpected finding.

Rate this question:

A 33-year-old woman presents with a history of progressive dyspnoea of two weeks' duration, sometimes associated with palpitations. A 24 h tape carried out by her general practitioner (GP) has recorded episodes of paroxysmal atrial fibrillation. She has also noticed increased swelling of her feet and abdomen and decreased effort tolerance. She denies any chest pain, fever, rhinorrhoea, sore throat or rash. She is pregnant in her 36th week of gestation and has no past medical history of note, does not take alcohol or any other drugs.

Examination of the cardiovascular system during prenatal visits has been normal. Electrocardiogram (ECG) and chest X-ray performed a year ago during a pre-employment check-up were normal. Physical examination reveals pulse rate of 98 bpm, respiratory rate 22/min, blood pressure 110/60 mmHg, jugular venous distension, a summation gallop and bilateral inspiratory crackles up to one-third of the chest posteriorly.

ECG shows sinus tachycardia and echocardiography reveals diffuse left ventricular (LV) hypokinesia with an ejection fraction of 25%. The patient is started on digoxin 0.125 mg per day, furosemide 60 mg twice daily and hydralazine 25 mg twice daily.

Which of the following medications is most important to add to the above regimen?

A	Heparin
B	Carvedilol
C	Enalapril
D	Nitroglycerine
E	Methylprednisolone

9:12

MyPastest
https://mypastest.pastest.com

Pastest+

A 33-year-old woman presents with a history of progressive dyspnoea of two weeks' duration, sometimes associated with palpitations. A 24 h tape carried out by her general practitioner (GP) has recorded episodes of paroxysmal atrial fibrillation. She has also noticed increased swelling of her feet and abdomen and decreased effort tolerance. She denies any chest pain, fever, rhinorrhoea, sore throat or rash. She is pregnant in her 36th week of gestation and has no past medical history of note, does not take alcohol or any other drugs.

Examination of the cardiovascular system during prenatal visits has been normal. Electrocardiogram (ECG) and chest X-ray performed a year ago during a pre-employment check-up were normal. Physical examination reveals pulse rate of 98 bpm, respiratory rate 22/min, blood pressure 110/60 mmHg, jugular venous distension, a summation gallop and bilateral inspiratory crackles up to one-third of the chest posteriorly.

ECG shows sinus tachycardia and echocardiography reveals diffuse left ventricular (LV) hypokinesia with an ejection fraction of 25%. The patient is started on digoxin 0.125 mg per day, furosemide 60 mg twice daily and hydralazine 25 mg twice daily.

Which of the following medications is most important to add to the above regimen?

Your answer was incorrect

A Heparin

B Carvedilol

A Heparin

This patient has presented with heart failure in 36th week of pregnancy. She had no prior evidence of heart disease or any identifiable cause of heart failure. This satisfies the clinical criteria for diagnosis of peripartum cardiomyopathy (PPCM). Therapy of PPCM involves sodium restriction, diuretics to optimise the volume status, digoxin and afterload-reducing agents.

Patients with PPCM are at risk of thromboembolism due to both hypercoagulable state of pregnancy and stasis of blood in the left ventricle. In this case, particularly the episodes of paroxysmal atrial fibrillation drive us towards anticoagulation, with heparin preferred to minimise risk of embolic stroke.

C Enalapril

Management of PPCM includes sodium restriction, diuretics to optimise the volume status, digoxin and afterload-reducing agents. Angiotensin-converting enzyme inhibitors are contraindicated during pregnancy, particularly first trimester, therefore hydralazine is preferred.

B Carvedilol

For patients presenting with PPCM, defined as left ventricular systolic dysfunction 1 month prior to delivery or 5 months postpartum, volume status should first be managed with diuretics after liaison with obstetricians. Beta-blockers should be added once the patient's volume status is optimised.

D Nitroglycerine

Nitrates are generally not recommended during pregnancy. A combination of diuretics and supportive measures, together with thromboprophylaxis due to the high risk of

9:14
594-042-7551
Leave

A 27-year-old female in the 12th week of pregnancy is referred for evaluation of progressively worsening exercise intolerance, fatigue and dyspnoea. On physical examination she has a respiratory rate of 20/min, blood pressure 120/90 mmHg and pulse rate of 91/min. She has jugular venous distension, left parasternal heave, loud pulmonary component of the second heart sound, a pan-systolic murmur at the left sternal border and pedal oedema up to the knees.

Investigations:

White cell count	8 × 109/l
Haemoglobin	16.7 g/dl
Platelets	150 × 10^9/l
Electrocardiogram (ECG)	Right atrial and right ventricular hypertrophy
Lung perfusion scintigraphy	No perfusion defects
Pulmonary function test	Mild restrictive defect and moderate decrease in diffusion capacity of carbon monoxide
Echocardiography:	Severe pulmonary hypertension with right ventricular systolic pressure of 80 mmHg and tricuspid regurgitation

Intravenous injection of microbubbles does not show any intracardiac shunting.

Which of the following is most appropriate management step in this patient?

A Heparin, bosentan and Caesarean section at 32 weeks of pregnancy

Audio Video Share Participants More

Platelets	$150 \times 10^9/l$
Electrocardiogram (ECG)	Right atrial and right ventricular hypertrophy
Lung perfusion scintigraphy	No perfusion defects
Pulmonary function test	Mild restrictive defect and moderate decrease in diffusion capacity of carbon monoxide
Echocardiography:	Severe pulmonary hypertension with right ventricular systolic pressure of 80 mmHg and tricuspid regurgitation

Intravenous injection of microbubbles does not show any intracardiac shunting.

Which of the following is most appropriate management step in this patient?

A	Heparin, bosentan and Caesarean section at 32 weeks of pregnancy
B	Heparin, furosemide and Caesarean section at 32 weeks of pregnancy
C	Warfarin, bosentan and induction of labour at 32 weeks of pregnancy
D	Warfarin, furosemide and Caesarean section at 32 weeks of pregnancy
E	Point out the risks to her own health of continuing with the pregnancy

Explanation

E Point out the risks to her own health of continuing with the pregnancy

This patient has primary pulmonary hypertension (PPH). Severe pulmonary hypertension in pregnancy has a high mortality, approaching 50%, and therefore this patient should be advised about this risk versus considering a termination. Patients who opt against termination of pregnancy should be closely followed up and managed with anticoagulation, oxygen and pulmonary vasodilator therapy such as prostacyclin. The patient should be advised regarding contraception in future, but oral contraceptive pills should not be used for possible increased risk of thrombo-embolism.

A Heparin, bosentan and Caesarean section at 32 weeks of pregnancy

Bosentan is teratogenic and should not be used in pregnancy.

B Heparin, furosemide and Caesarean section at 32 weeks of pregnancy

The use of frusemide during pregnancy should be avoided because placental perfusion can be reduced, and therefore there is a need for fetal growth monitoring if frusemide is used. It is contraindicated in breast feeding as it passes into the breast milk and may inhibit lactation.

C Warfarin, bosentan and induction of labour at 32 weeks of pregnancy

Bosentan is teratogenic and should not be used in pregnancy.

9:18
594-042-7551
Leave

weeks of pregnancy

The use of frusemide during pregnancy should be avoided because placental perfusion can be reduced, and therefore there is a need for fetal growth monitoring if frusemide is used. It is contraindicated in breast feeding as it passes into the breast milk and may inhibit lactation.

C Warfarin, bosentan and induction of labour at 32 weeks of pregnancy

Bosentan is teratogenic and should not be used in pregnancy.

D Warfarin, furosemide and Caesarean section at 32 weeks of pregnancy

The use of frusemide during pregnancy should be avoided because placental perfusion can be reduced, and therefore there is a need for fetal growth monitoring if frusemide is used. It is contraindicated in breast feeding as it passes into the breast milk and may inhibit lactation.

Rate this question:

© Pastest 2019

Audio Video Share Participants More

9:18
594-042-7551
Leave

A 43-year-old man presents to the Emergency Department with a 1 h history of central crushing chest pain radiating to his left arm. This has started suddenly and has been building up in intensity. He has been feeling very nauseous and sweaty and is starting to get short of breath. There is no past medical history. He smokes 30/day and drinks about 25 units per week.

On examination he is in pain, his blood pressure is 165/95 mmHg, heart rate 120/min regular, saturations of 95% on room air. His heart sounds are normal and there are bi-basal crackles on auscultation of his chest.
A 12-lead electrocardiogram (ECG) shows ST elevation of 4 mm in leads V2–V5.

A portable chest X-ray shows evidence of left ventricular failure.

Which one of the following measures would offer the greatest prognostic benefit in this patient in the immediate period on admission to hospital?

A	Abciximab
B	Thrombolysis with tPA
C	Immediate primary angioplasty
D	Atenolol 25 mg
E	Ramipril 2.5mg

Submit

Audio Video Share Participants More

9:19
594-042-7551
Leave

Explanation

C Immediate primary angioplasty

The patient has an acute anterior myocardial infarction (MI) leading to acute left ventricular failure (LVF). Aspirin 300 mg and clopidogrel 300 mg stat and immediate primary angioplasty, if the option is available, are the measures that offer the greatest prognostic benefit in the early hours.

A Abciximab

Abciximab, a 2b3a platelet inhibitor, may be useful in the management of acute MI where patients are undergoing PCI. It is not recommended in advance of PCI because given early it isn't associated with improved outcomes versus a delayed approach, and may lead to further bleeding if given early.

B Thrombolysis with tPA

If in a setting where primary angioplasty is not an option, thrombolytic therapy should be instigated as early as possible, although in all but the remotest parts of the UK, PCI is feasible.

D Atenolol 25 mg

Atenolol reduces myocardial oxygen demand and is of prognostic value in acute MI, although given early it may lead to haemodynamic instability.

E Ramipril 2.5mg

Like atenolol, ACE inhibitors do infer prognostic benefit post MI, although they are usually instituted during the first 24 h after admission rather than immediately following.

Audio Video Share Participants More

9:19
594-042-7551
Leave

A 24-year-old man, previously fit and well, is admitted under the care of the orthopaedic team following a road traffic accident. He was riding his motorbike when he was hit by a car, where he sustained a comminuted open fracture of his left tibia and fibula. He undergoes an open reduction and fixation operation and is returned to the ward.

A week later he is found to be pyrexial at 38.9°C and tachycardic at 130 beats/min. His blood pressure is 100/60 mmHg. There are splinter haemorrhages on two of his fingernails. There is a systolic murmur on auscultation of his chest. His chest is clear on auscultation.

A bedside urine dipstick is positive for blood, protein and leucocytes. Serum creatinine is 125 micromol/l.

Given the likely cause of his fever, which of the following is the most appropriate early treatment in this case?

A IV benzylpenicillin and gentamicin

B IV cefuroxime and metronidazole

C IV vancomycin

D IV flucloxacillin

E IV clarithromycin

Submit

Previous Q...
Skip Questi...
Audio
Video
Share
Participants
More

9:21
594-042-7551
Leave

D IV flucloxacillin

This patient has clinical features consistent with a diagnosis of infective endocarditis. After at least three sets of blood cultures have been taken from three different sites, blind treatment should be instigated pending results. The treatment is targeted at the most likely suspected organism. In this case the most likely pathogen is *Staphylococcus* because of his extensive trauma, and initial treatment should involve flucloxacillin. Studies suggest that gentamicin adds little to efficacy and worsens the potential AE profile of therapy, and thus it isn't recommended here.

C IV vancomycin

Vancomycin is usually reserved for endocarditis related to MRSA rather than the likely diagnosis here, which is methicillin-sensitive staphylococcal endocarditis.

A IV benzylpenicillin and gentamicin

Amoxicillin, not benzylpenicillin, is the initial empirical therapy for native valve endocarditis where there is little evidence to support staphylococcal infection.

B IV cefuroxime and metronidazole

Cefuroxime and metronidazole is a usual intervention for infection related to surgery, not for subacute bacterial endocarditis.

E IV clarithromycin

IV clarithromycin is considered an option for treating staphylococcal endocarditis in patients with penicillin allergy.

Audio Video Share Participants More

Your registrar has asked you do some blood gases on a patient who presented with chest pain and is on the coronary care unit. There is a previous history of deep vein thrombosis 5 years ago. The patient is a 65-year-old lady who just presented with severe chest pain that started 6 h earlier. The chest pain was central, radiated to the neck and lasted for about 45 min. The chest pains have resolved some 2 h earlier, although she is syncopal. Her admission electrocardiogram (ECG) revealed sinus rhythm with T wave inversion in the anterior chest leads.

While trying to draw some blood, the patient suddenly becomes restless and starts complaining of shortness of breath. The ECG monitor shows a heart rate of 188/min and her blood pressure (BP) is 105/60 mmHg. You immediately start the patient on high-flow oxygen using a mask and request a 12-lead ECG. This ECG reveals a narrow complex tachycardia.

What would you immediately do for this patient?

A	DC cardioversion
B	Give the patient a bolus dose of intravenous (IV) lidocaine 100 mg
C	Start the patient on amiodarone infusion of 300 mg in 1 h
D	Give the patient a bolus dose of IV adenosine 6 mg
E	Start patient on oral beta-blockade

Rana Alnasser's screen

9:26

lasted for about 45 min. The chest pains have resolved some 2 h earlier, although she is syncopal. Her admission electrocardiogram (ECG) revealed sinus rhythm with T wave inversion in the anterior chest leads.

While trying to draw some blood, the patient suddenly becomes restless and starts complaining of shortness of breath. The ECG monitor shows a heart rate of 188/min and her blood pressure (BP) is 105/60 mmHg. You immediately start the patient on high-flow oxygen using a mask and request a 12-lead ECG. This ECG reveals a narrow complex tachycardia.

What would you immediately do for this patient?

Your answer was correct

A	DC cardioversion
B	Give the patient a bolus dose of intravenous (IV) lidocaine 100 mg
C	Start the patient on amiodarone infusion of 300 mg in 1 h
D	Give the patient a bolus dose of IV adenosine 6 mg
E	Start patient on oral beta-blockade

Explanation

D	Give the patient a bolus dose of IV adenosine 6 mg

This lady is likely to be suffering an acute coronary syndrome episode. Giving her a fast intravenous (IV) dose

Rana Alnasser's screen

D Give the patient a bolus dose of IV adenosine 6 mg

This lady is likely to be suffering an acute coronary syndrome episode. Giving her a fast intravenous (IV) dose of adenosine 6 mg and repeating it if there is no response is the most appropriate immediate action. The patient's response to adenosine would depend on the underlying arrhythmia. In rare cases adenosine has been reported to cause destabilisation of VT and lead to further deterioration of blood pressure and heart rate, but on the balance of probabilities adenosine would still be the best course of action here. The response to giving adenosine in the following situations is tabulated here.

Sinus tachycardia	Transient atrioventricular (AV) block
Atrial fibrillation	Transient AV block
Atrial flutter	Transient AV block
Atrioventricular nodal re-entrant tachycardia (AVNRT)	May terminate
Atrioventricular re-entrant tachycardia (AVRT)	May terminate
Ventricular tachycardia	Likely to have no effect

A DC cardioversion

Her blood pressure (BP) is 105/60 mmHg and so she is not haemodynamically compromised; therefore, giving DC cardioversion is not required and adenosine should be tried first.

Rana Alnasser's screen

Atrioventricular nodal re-entrant tachycardia (AVNRT)	May terminate
Atrioventricular re-entrant tachycardia (AVRT)	May terminate
Ventricular tachycardia	Likely to have no effect

A DC cardioversion

Her blood pressure (BP) is 105/60 mmHg and so she is not haemodynamically compromised; therefore, giving DC cardioversion is not required and adenosine should be tried first.

B Give the patient a bolus dose of intravenous (IV) lidocaine 100 mg

Her blood pressure (BP) is 105/60 mmHg and so she is not haemodynamically compromised; giving lidocaine is incorrect.

C Start the patient on amiodarone infusion of 300 mg in 1 h

Amiodarone would be more appropriate for ventricular tachycardia.

E Start patient on oral beta-blockade

Oral beta-blockers are slow to act and could worsen any heart failure in the acute setting.

7552

Rate this question:

Rana Alnasser's screen

A 35-year-old woman, who recently arrived in this country from Africa, presents with shortness of breath on exertion, and fatigue. On examination she is neither cyanosed nor clubbed, and is apyrexial. There is a right precordial heave, a wide split second heart sound and a pulmonary flow murmur. Her lung fields are clear. A chest X-ray shows cardiomegaly with prominent pulmonary arteries. Her ECG shows sinus rhythm and partial RBBB. Routine full blood count, liver function testing and urea and electrolytes are unremarkable. Transo-esophageal echocardiography is arranged.

Which of the following investigations would be most useful in deciding the next management step?

A	V/Q scan
B	Right heart catheterization
C	Arterial blood gas
D	Pulmonary function testing
E	High-resolution CT thorax

32328

Submit

Explanation

B Right heart catheterization

Patients arriving from developing countries may have undiagnosed pathology, including conditions not commonly encountered in the United Kingdom. Her rather non-specific symptoms are compatible with cardiac or pulmonary disease. The physical signs are in keeping with right-sided cardiac volume overload or pulmonary hypertension. However, in pulmonary hypertension due to pulmonary disease or multiple pulmonary emboli, the pulmonary arteries are characteristically normal or pruned. The presence of a wide (often fixed) split second sound, right bundle branch block and prominent pulmonary vasculature are suggestive of an atrial septal defect. The absence of a temperature or murmurs makes tricuspid endocarditis a less likely diagnosis.

Transthoracic echocardiography may confirm an enlarged right ventricle, but the atrial septum is often difficult to visualise and for this reason trans-oesophageal echocardiography is usually more helpful. Right heart catheterisation will allow quantification of the degree of shunting and an assessment of whether the defect is suitable for closure. In this case, however, the clinical evidence of marked pulmonary hypertension suggests that it may be too late for this patient.

A V/Q scan

This would be used to examine for the presence of pulmonary emboli, which would be a less likely diagnosis here. Additionally, in the absence of contra-indications suc as pregnancy or allergy to contrast media, a CTPA would be the preferred diagnostic test for PE.

C Arterial blood gas

A 76-year-old man with a long-standing history of hypertension is referred to the Cardiology Department wit a 6-month history of worsening shortness of breath on exertion and peripheral oedema. He is now unable to walk more than 20 yards without getting breathless. He finds it very uncomfortable to lie flat at night and over the last month there were a couple of nights when he woke up trying to catch his breath. He is currently on furosemide 40 mg bd and ramipril 5 mg od.

On arrival in the clinic his blood pressure is 145/90 mmHg and heart rate is 85 beats/min, and regular. His heart sounds are normal on auscultation and there are bi-basal crackles on auscultation of his chest. His jugular venous pulse is seen at 4 cm and there is pitting oedema bilaterall to mid calves.
His electrocardiogram (ECG) shows sinus rhythm with left ventricular hypertrophy.

His chest X-ray confirms an enlarged cardiac shadow with evidence of left ventricular failure. Previous echocardiogram from 2 months ago reveals an EF of 32%.

Investigations:

Hb	10.2 g/dl
WCC	6.3×10^9/l
PLT	198×10^9/l
Na^+	132 mmol/l
K^+	3.5 mmol/l
Creatinine	101 μmol/l
Urea	6.0 mmol/l

Which of the following measures is the most appropriate next step in this case?

A Increase furosemide

PLT	198×10^9/l
Na^+	132 mmol/l
K^+	3.5 mmol/l
Creatinine	101 μmol/l
Urea	6.0 mmol/l

Which of the following measures is the most appropriate next step in this case?

A Increase furosemide

B Add bisoprolol

C Add digoxin

D Add metolazone

E Add spironolactone

Submit

Previous Q... Skip Questi...

© Pastest 2019

to mid calves.

His electrocardiogram (ECG) shows sinus rhythm with left ventricular hypertrophy.

His chest X-ray confirms an enlarged cardiac shadow with evidence of left ventricular failure. Previous echocardiogram from 2 months ago reveals an EF of 32%.

Investigations:

Hb	10.2 g/dl
WCC	6.3×10^9/l
PLT	198×10^9/l
Na^+	132 mmol/l
K^+	3.5 mmol/l
Creatinine	101 µmol/l
Urea	6.0 mmol/l

Which of the following measures is the most appropriate next step in this case?

Your answer was correct

A Increase furosemide

B Add bisoprolol

C Add digoxin

D Add metolazone

E Add spironolactone

Explanation

E Add spironolactone

This patient has New York Heart Association III congestive cardiac failure and a poor prognostic outcome. Spironolactone combines a diuretic effect with prognostic benefit for major adverse cardiovascular events (MACE) outcomes and heart failure, as seen in the RALEs study (see weblink below). In this case it will help raise the patient's potassium and, with peripheral oedema and an elevated JVP, it is the intervention of choice.

A Increase furosemide

Increasing furosemide is less favoured versus spironolactone, because it doesn't confer a prognostic benefit and may actually lower potassium into the hypokalaemic range in this setting.

B Add bisoprolol

Bisoprolol is associated with symptomatic and prognostic benefit in NYHA III heart failure, although it should be initiated when the patient is in stable fluid balance rather than the situation seen here.

C Add digoxin

Digoxin is a last resort in patients with no evidence of atrial fibrillation; in patients with heart failure there is a hint from meta-analysis that it may actually increase mortality.

D Add metolazone

Metolazone can be used in patients with severe fluid overload who have 'maxed-out' on loop diuretic. It may, however, be associated with significant electrolyte abnormalities including hypokalaemia and hyponatraemia

A 73-year-old woman attends A&E having felt dizzy and falling while at the supermarket. This is her first such episode, describing it as acute in onset with rapid resolution; there was no associated chest pain. She has a past history of myocardial infarction some 20 years ago, and hypertension. Current medication includes atorvastatin 10 mg, ramipril 10 mg and aspirin 75 mg. On examination her BP is 105/72 mmHg, with pulse 56/min and regular. She has no heart murmurs and is not in cardiac failure.

Investigations:

Hb	11.9 g/dl
WCC	4.3 $\times 10^9$/l
PLT	212 $\times 10^9$/l
Na^+	139 mmol/l
K^+	5.0 mmol/l
Creatinine	171 µmol/l
ECG	Bifascicular block, sinus bradycardia
24hr ECG	Episodes of 4 s pause, single short run of NSVT, paroxysms of atrial fibrillation

Which of the following is the most appropriate next management step for this patient?

A Implantable cardioverter/defibrillator

B Permanent pacemaker

C Load with digoxin

D Load with amiodarone

Rana Alnasser's screen

10 mg, ramipril 10 mg and aspirin 75 mg. On examination her BP is 105/72 mmHg, with pulse 56/min and regular. She has no heart murmurs and is not in cardiac failure.

Investigations:

Hb	11.9 g/dl
WCC	4.3 x10^9/l
PLT	212 x10^9/l
Na^+	139 mmol/l
K^+	5.0 mmol/l
Creatinine	171 µmol/l
ECG	Bifascicular block, sinus bradycardia
24hr ECG	Episodes of 4 s pause, single short run of NSVT, paroxysms of atrial fibrillation

Which of the following is the most appropriate next management step for this patient?

A Implantable cardioverter/defibrillator

B Permanent pacemaker

C Load with digoxin

D Load with amiodarone

E Sotalol

Submit

B Permanent pacemaker

Bifascicular block and history of pauses on 24 h tape indicate the need for permanent pacemaker insertion. Current ESC guidelines on pacing state: 'Pacing is indicated in patients affected by sinus node disease who have the documentation of symptomatic bradycardia due to sinus arrest or sinus- atrial block' as a class I recommendation.

The VT may be related to the pauses (ventricular escape occurs, and ischaemia in a susceptible patient may lead to a run of VT), and should be reassessed after pacemaker insertion has occurred.

A Implantable cardioverter/defibrillator

Implantable cardioverter/defibrillator would not address her pauses or bifascicular block, and is therefore not the most appropriate management option here.

C Load with digoxin

While loading with digoxin would be an appropriate choice for control of atrial fibrillation, in this case it would have the potential to worsen her pauses and is therefore not the most suitable choice.

D Load with amiodarone

While loading with amiodarone would be an appropriate option for control of atrial fibrillation or ventricular tachycardia, in this case it would have the potential to worsen her pauses and is therefore not the most suitable choice.

E Sotalol

Implantable cardioverter/defibrillator would not address her pauses or bifascicular block, and is therefore not the most appropriate management option here.

C Load with digoxin

While loading with digoxin would be an appropriate choice for control of atrial fibrillation, in this case it would have the potential to worsen her pauses and is therefore not the most suitable choice.

D Load with amiodarone

While loading with amiodarone would be an appropriate option for control of atrial fibrillation or ventricular tachycardia, in this case it would have the potential to worsen her pauses and is therefore not the most suitable choice.

E Sotalol

While beta blockers may be an appropriate option for atrial fibrillation, sotalol would not represent a first-choice agent; in any case, here it would have the potential to worsen her pauses and is therefore not the most suitable choice.

A 27-year-old woman who is 24 weeks into her first pregnancy is referred by her general practitioner (GP) to the cardiology department complaining of palpitations. There is no past medical history of note and she is on no medications. On examination her BP is 115/82 mmHg, pulse is 70/min and regular, there is a systolic murmur and a fixed splitting of the second heart sound. Her 12-lead electrocardiogram (ECG) shows left-axis deviation with a right bundle branch block. An echocardiogram is performed which shows an ostium primum atrial septal defect.

What is the risk, if any, to the pregnancy?

A	No significant increase in risk compared to the general population
B	Small risk to the mother, up to 20% risk of CHD to the foetus
C	Significant risk of maternal mortality, up to 40%
D	No significant increase in risk to the mother, up to 40% risk of CHD to the foetus
E	10% risk of maternal mortality, no increased risk to the foetus

32339

Submit

A 27-year-old woman who is 24 weeks into her first pregnancy is referred by her general practitioner (GP) to the cardiology department complaining of palpitations. There is no past medical history of note and she is on no medications. On examination her BP is 115/82 mmHg, pulse is 70/min and regular, there is a systolic murmur and a fixed splitting of the second heart sound. Her 12-lead electrocardiogram (ECG) shows left-axis deviation with a right bundle branch block. An echocardiogram is performed which shows an ostium primum atrial septal defect.

What is the risk, if any, to the pregnancy?

Your answer was correct

A	No significant increase in risk compared to the general population
B	Small risk to the mother, up to 20% risk of CHD to the foetus
C	Significant risk of maternal mortality, up to 40%
D	No significant increase in risk to the mother, up to 40% risk of CHD to the foetus
E	10% risk of maternal mortality, no increased risk to the foetus

Explanation

A No significant increase in risk compared to the

A No significant increase in risk compared to the general population

Atrial septal defects are usually well tolerated, as pulmonary hypertension is not usually present at childbearing age. However, the defect should be closed prior to subsequent pregnancies. In the presence of Eisenmenger syndrome the maternal mortality is approximately 40% and pregnancy is contraindicated, with older maternal age increasing the risk of pulmonary hypertension and Eisenmenger. Systolic flow murmurs are common in pregnancy; in the absence of structural heart disease they do not hold any prognostic significance.

B Small risk to the mother, up to 20% risk of CHD to the foetus

Pregnancy is tolerated well by most women with ASD. Most cases of ASD are sporadic, and the risk to the foetus would not be expected to be as high as 20%.

C Significant risk of maternal mortality, up to 40%

ASD is well tolerated in pregnancy by most women. Such a high maternal mortality (30–50% in older series and 17–33% in more recent studies) is seen in women with severe PAH, and in Eisenmenger syndrome.

D No significant increase in risk to the mother, up to 40% risk of CHD to the foetus

Most cases of ASD are sporadic, and the risk to the foetus would not be expected to be as high as 40%.

A 52-year-old woman who has received chemotherapy and radiotherapy for previous Hodgkin's lymphoma 20 years ago presents to the clinic complaining of shortness of breath, feeling faint and gradually increasing ankle swelling

On examination, she looks short of breath, her systolic blood pressure (BP) is 100 mmHg, but there is a decrease of 20 mmHg on inspiration.

Investigations:

ECG – Low voltage sinus tachycardia.

Cardiac catheterisation:

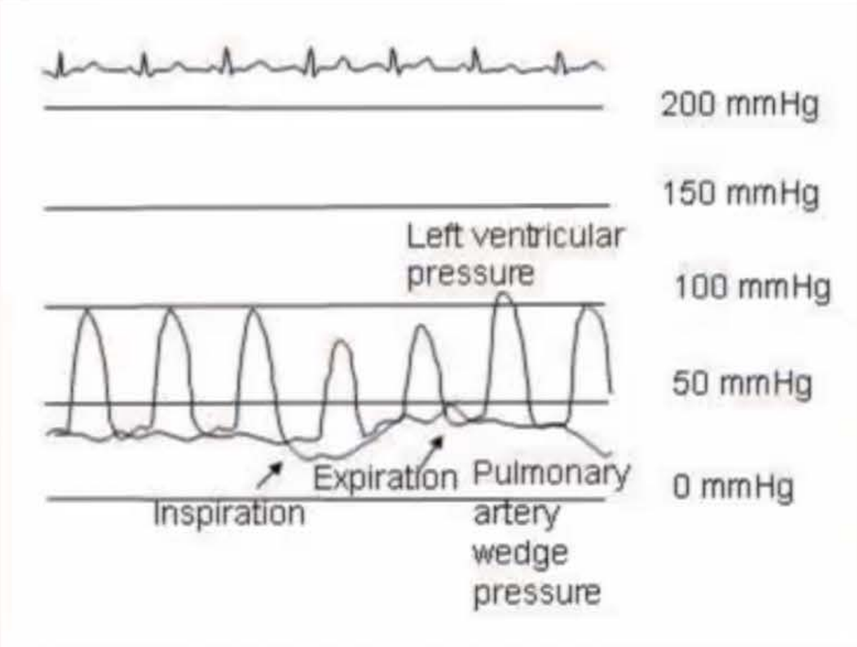

Which of the following is the most likely diagnosis?

A	Primary cardiac lymphoma
B	Myocarditis
C	Dilated cardiomyopathy
D	Pericardial effusion
E	Hypertrophic obstructive cardiomyopathy (HOCM)

D Pericardial effusion

This patient has pulsus paradoxus, a clinical sign in which there is a fall in systolic blood pressure > 10 mmHg on inspiration. This sign is indicative of a number of clinical conditions including pericardial effusion, and constrictive pericarditis. The small amplitude QRS complexes reported in the ECG makes a pericardial effusion significantly more likely. The history of lymphoma with radiotherapy hints to an underlying cause of inflammatory pericarditis leading to the effusion. This is a recognised late complication of midline radiotherapy.

A Primary cardiac lymphoma

Primary cardiac lymphomas are rare and make up only 0.5% of all lymphomas. Secondary cardiac involvement from lymphoma is more common and can result in pericardial tamponade. However, secondary cardiac involvement is more common in non-Hodgkin's lymphoma.

Reference:

McDonnell et al. Involvement of the heart by malignant lymphoma: a clinicopathologic study. Cancer. 1982;49:944-51.

B Myocarditis

The primary aetiology for myocarditis in western Europe is viral infection (eg adenovirus, coxsackie virus), although worldwide Chagas' disease is the most common cause. Anthracycline chemotherapy is a recognised cause; however, these agents are more commonly applied to the treatment of non-Hodgkin's lymphoma. Myocarditis is unlikely in this situation as it primarily presents with chest pain (which is not reported here). Additionally, unless a pericardial effusion develops, it should not result in pulsus paradoxus.

Rana Alnasser's screen

A 65-year-old female, with known chronic obstructive pulmonary disease, presents with a history of progressive shortness of breath of one week's duration. She frequently gets up at night coughing and short of breath. She has been expectorating whitish sputum over the last two days. On examination she has temperature of 37.1°C, blood pressure of 135/85 mmHg, pulse rate of 110/min and respiratory rate of 26/min. She has raised jugular venous pressure and normal heart sounds. Examination of lung fields reveals fine inspiratory crackles at both bases.

Investigations:

Sodium	135 mmol/l
Potassium	4.5 mmol/l
Urea	8 mmol/l
Creatinine	120 µmol/l
Echocardiogram (3 months ago)	Dilated cardiomyopathy with ejection fraction of 32%
Chest X-ray	Borderline cardiomegaly and increased interstitial markings

Which of the following investigations will help clarify whether heart failure or COPD is contributing more to her symptoms at present?

A Ventilation–perfusion scan

B Spiral computed tomography of the chest

C Sputum Gram stain and culture

D Transthoracic echocardiography

shortness of breath of one week's duration. She frequently gets up at night coughing and short of breath. She has been expectorating whitish sputum over the last two days. On examination she has temperature of 37.1°C, blood pressure of 135/85 mmHg, pulse rate of 110/min and respiratory rate of 26/min. She has raised jugular venous pressure and normal heart sounds. Examination of lung fields reveals fine inspiratory crackles at both bases.

Investigations:

Sodium	135 mmol/l
Potassium	4.5 mmol/l
Urea	8 mmol/l
Creatinine	120 µmol/l
Echocardiogram (3 months ago)	Dilated cardiomyopathy with ejection fraction of 32%
Chest X-ray	Borderline cardiomegaly and increased interstitial markings

Which of the following investigations will help clarify whether heart failure or COPD is contributing more to her symptoms at present?

A	Ventilation-perfusion scan
B	Spiral computed tomography of the chest
C	Sputum Gram stain and culture
D	Transthoracic echocardiography
E	Serial B-type atrial natriuretic peptide (BNP) measurements

Creatinine	120 μmol/l
Echocardiogram (3 months ago)	Dilated cardiomyopathy with ejection fraction of 32%
Chest X-ray	Borderline cardiomegaly and increased interstitial markings

Which of the following investigations will help clarify whether heart failure or COPD is contributing more to her symptoms at present?

Your answer was correct

A Ventilation-perfusion scan

B Spiral computed tomography of the chest

C Sputum Gram stain and culture

D Transthoracic echocardiography

E Serial B-type atrial natriuretic peptide (BNP) measurements

Explanation

E Serial B-type atrial natriuretic peptide (BNP) measurements

This patient's dyspnoea might be either secondary to heart failure or exacerbation of her chronic pulmonary obstructive disease. The measurement of BNP in this case is helpful to establish the cause of dyspnoea. Plasma BNP [illegible] to be elevated in patients with

Rana Alnasser's screen

E Serial B-type atrial natriuretic peptide (BNP) measurements

This patient's dyspnoea might be either secondary to heart failure or exacerbation of her chronic pulmonary obstructive disease. The measurement of BNP in this case is helpful to establish the cause of dyspnoea. Plasma BNP levels have been reported to be elevated in patients with pulmonary disease and whose symptoms were secondary to heart failure, and vice versa. Values of less than 100 pg/ml make heart failure unlikely, while values of more than 400 pg/ml are strongly suggestive of heart failure as the cause of dyspnoea. Her BNP is of course likely to be above the upper limit of normal when she is relatively well, but the level of elevation may be useful in elucidating the cause of her symptom exacerbation.

A Ventilation–perfusion scan

Spiral computed tomography may be useful to identify pulmonary embolism, but the clinical picture is not suggestive of pulmonary embolism in this scenario. Typical findings we would expect include haemoptysis and pleuritic chest pain.

B Spiral computed tomography of the chest

. The clinical picture is not suggestive of pneumonia. Typical findings we would expect include a fever, raised white cell count, crepitations in one lung lobe and productive cough.

C Sputum Gram stain and culture

The clinical picture is not suggestive of pneumonia. Typical findings we would expect include a fever, raised white cell count, crepitations in one lung lobe and productive cough.

Rana Alnasser's screen

productive cough.

C Sputum Gram stain and culture

The clinical picture is not suggestive of pneumonia. Typical findings we would expect include a fever, raised white cell count, crepitations in one lung lobe and productive cough.

D Transthoracic echocardiography

In this case, an echocardiogram three months apart may not show differences that would be clear to differentiate between worsening heart failure and COPD. Worsening heart failure clinically is more than just tracking ejection fraction measurements and the echocardiographer's subjective view of contractility. Another indication for an echocardiogram would be to look for right heart strain; however, the clinical picture is not suggestive of pulmonary embolism. Typical findings we would expect include haemoptysis and pleuritic chest pain. There may be signs of risk factors, such as swollen calves, to suggest deep vein thrombosis.

Rate this question:

Previous Q... Tag Questi... Feedback End Session

Blog About Pastest Contact Us Help

© Pastest 2019

Rana Alnasser's screen

A 69-year-old man is admitted to the Emergency Department with sudden onset of palpitations. The palpitations started 3 h ago and are associated with shortness of breath, light-headedness and chest discomfort. He has had two similar episodes of palpitations in the last 2 months that have lasted only a few seconds. He had never sought any medical advice on these previous palpitations. His past medical history is unremarkable and he is not on any medication. On examination, he is dyspnoeic with a blood pressure of 102/55 mmHg, pulse rate of >>120/min and a respiratory rate of 28/min. His oxygen saturation on air is 90%, and his chest is clinically clear. His jugular venous pressure is not raised. First and second heart sounds are heard but you cannot appreciate whether there is any murmur. Initial attempts at carotid sinus massage have failed and he is becoming increasingly distressed.

Investigations:

ECG	Heart rate of 188/min with a narrow QRS complex
XR	Normal

How would you best determine the underlying cardiac rhythm?

A	Ask patient to do a Valsalva manoeuvre
B	Give rapid intravenous adenosine
C	Give 100% oxygen
D	Give intravenous β-blocker
E	Give intravenous calcium channel blocker

B Give rapid intravenous adenosine

To determine the underlying rhythm, adenosine 6 mg in a large peripheral vein should slow the heart rate sufficiently to unveil the underlying rhythm. If the patient does not respond to 6 mg adenosine, the dose could be increased to 12 mg. Adenosine will have the following effects on the narrow complex: atrial fibrillation or atrial flutter (transient atrioventricular block), atrioventricular nodal re-entrant tachycardial or atrioventricular re-entrant tachycardia (may terminate), atrial tachycardia - transient AV block.

A Ask patient to do a Valsalva manoeuvre

As the patient is dyspnoeic and hypoxic, it would not be appropriate to carry out a Valsalva manoeuvre because of the practical difficulty due to poor patient compliance.

C Give 100% oxygen

Although oxygen should be administered to correct hypoxia, it will not correct the underlying rhythm.

D Give intravenous β-blocker

It is important to establish the underlying rhythm with adenosine. Giving a β-blocker will not help in diagnosing the exact rhythm.

E Give intravenous calcium channel blocker

It is important to establish the underlying rhythm with adenosine. Giving a calcium channel blocker will not help in diagnosing the exact rhythm.

Rate this question:

A 64-year-old woman who has been diagnosed with a first deep vein thrombosis is about to be discharged from the ward. She has been started on warfarin. She has a past history of hypertension, COPD, osteoarthritis and type 2 diabetes, and is very concerned about possible changes to her medication and lifestyle.

Which one of the following pieces of information would give to this patient?

A	She can continue to take regular paracetamol
B	She must avoid leafy green vegetables
C	She must avoid any alcohol consumption
D	She needs to take warfarin for up to a year
E	She should always take her warfarin with a meal

32308

Submit

© Pastest 2019

Rana Alnasser's screen

A 64-year-old woman who has been diagnosed with a first deep vein thrombosis is about to be discharged from the ward. She has been started on warfarin. She has a past history of hypertension, COPD, osteoarthritis and type 2 diabetes, and is very concerned about possible changes to her medication and lifestyle.

Which one of the following pieces of information would give to this patient?

Your answer was incorrect

A	She can continue to take regular paracetamol
B	She must avoid leafy green vegetables
C	She must avoid any alcohol consumption
D	She needs to take warfarin for up to a year
E	She should always take her warfarin with a meal

Explanation

A	She can continue to take regular paracetamol

Although interactions between paracetamol and warfarin have been reported, regular paracetamol is unlikely to impact on her INR and would be considered much safer than the use of NSAIDs.

C	She must avoid any alcohol consumption

Explanation

A She can continue to take regular paracetamol

Although interactions between paracetamol and warfarin have been reported, regular paracetamol is unlikely to impact on her INR and would be considered much safer than the use of NSAIDs.

C She must avoid any alcohol consumption

It's important to avoid binge drinking. Regular small amounts of alcohol would be considered low risk in this situation.

B She must avoid leafy green vegetables

Enjoyment of a normal, healthy, balanced diet is not thought to significantly impact on INR.

D She needs to take warfarin for up to a year

Anticoagulation for a period of 3 months for DVT is recommended, although for recurrent DVT lifetime therapy may be considered.

E She should always take her warfarin with a meal

There is no requirement to take warfarin with food, although aiming to take warfarin at the same time each day is advised.

13505

Rate this question:

Next Question

A 72-year-old man attends the GP around 1 week after right hemicolectomy for colonic carcinoma, feeling generally unwell. He has been suffering from sweats, particularly at night, and is feeling increasingly lethargic. On examination he has pyrexia (37.8°C) and a pan-systolic murmur.

Investigations:

Hb	10.3 g/dl
WCC	12.1×10^9/l
PLT	145×10^9/l
Na^+	139 mmol/l
K^+	4.5 mmol/l
Creatinine	180 µmol/l
ESR	77 mm/hr
Trans-oesophageal ECHO	Mitral valve vegetations

Which of the following is the most likely responsible organism?

A *Bacteroides fragilis*

B *Staphylococcus aureus*

C *Staphylococcus epidermidis*

D *Streptococcus viridans*

E *Pseudomonas*

A *Bacteroides fragilis*

Endocarditis is a rare complication of colonic resection, which occurs due to mobilisation of gut bacteria and their entry into the bloodstream. Passage of bacteria to the heart occurs via venous drainage, so valve lesions tend to be right-sided. Vegetations may also occur on the left side of the heart, as seen here, and in this case mitral valve lesions have led to mitral regurgitation.

In the context of endocarditis following bowel resection, *Bacteroides* is the most likely organism of those listed, though *S. bovis* is also seen. The incidence of postoperative endocarditis is very low because of the use of peri-operative broad-spectrum antibiotics (usually a cephalosporin in combination with metronidazole). Management in this case is metronidazole.

B *Staphylococcus aureus*

This species is overall the most common cause of infective endocarditis, and around one third of *Staph. aureus* bacteraemia cases result in endocarditis, the majority of cases occur in structurally normal valves. The main risk factors are intravascular lines, IV drug abuse, alcoholism, cancer and chronic diseases such as diabetes or long-term steroid use. Is therefore more often associated with healthcare-acquired disease.

C *Staphylococcus epidermidis*

This tends to present as subacute disease. Although it can cause native valve disease, it is most associated with early prosthetic valve endocarditis.

D *Streptococcus viridans*

This organism is present in the mouth and is the reason

factors are intravascular lines, IV drug abuse, alcoholism, cancer and chronic diseases such as diabetes or long-term steroid use. Is therefore more often associated with healthcare-acquired disease.

C *Staphylococcus epidermidis*

This tends to present as subacute disease. Although it can cause native valve disease, it is most associated with early prosthetic valve endocarditis.

D *Streptococcus viridans*

This organism is present in the mouth and is the reason that the presence of valvular heart disease may be relevant in dental procedures. It is more commonly associated with community-acquired infection. It commonly presents as subacute disease.

E *Pseudomonas*

This is a bacterium that may contaminate recreational drugs, and it is therefore associated with IV drug abuse. It has a high morbidity and mortality and high rate of relapse.

Rate this question:

Next Question

Previous Q... Tag Questi... Feedback End Session

Blog About Pastest Contact Us Help

You are a general medical senior house officer. A 45-year old African-Caribbean woman has been referred to you by her general practitioner (GP) after attending a well-woman clinic. Her GP is worried she may be hypertensive. Two blood pressure readings taken from her right and left arm are, respectively, 160/95 and 170/90 mmHg. The patient is well and asymptomatic. Apparently you understand that one of her relatives had trouble with a thyroid cancer at a relatively young age, but there is no other significant medical history. Her electrocardiogram (ECG) is shown below. Her full blood count and renal function are within the normal ranges.

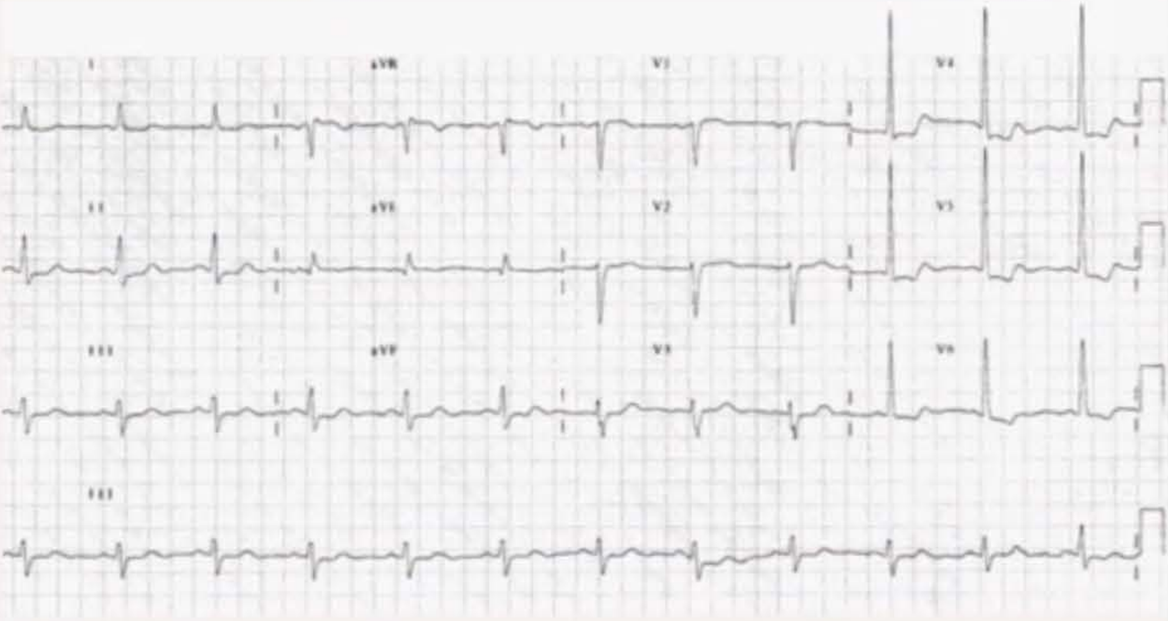

What is the optimal initial management for her hypertension?

A	Ramipril
B	Indapamide
C	Amlodipine
D	Bisoprolol
E	Doxazosin

Current NICE guidelines recommend using a calcium-channel blocker (CCB) to people aged over 55 years or to patients of African or Caribbean family origin of any age. The preference of CCB over an ACE inhibitor in this group of patients is as explained below.

As this woman has hypertension with evidence of end-organ damage, as indicated by left ventricular hypertrophy with lateral strain, medical therapy should be started. Concurrent premorbid risk factors should be assessed and treated, including hypercholesterolaemia and diabetes if identified. If possible the type of thyroid cancer suffered by her relative should be identified, as a medullary carcinoma is suggestive of MEN-2 and may lower the threshold for screening your patient for a phaeochromocytoma.

If a CCB is not suitable, for example because of oedema or intolerance, or if there is evidence of heart failure or a high risk of heart failure, offer a thiazide-like diuretic.

A Ramipril

Patients with hypertension aged under 55 years (except patients of African-Caribbean ethnicity) should be offered treatment with an angiotensin-converting enzyme (ACE) inhibitor or a low-cost angiotensin-II receptor blocker (ARB). If an ACE inhibitor is prescribed and is not tolerated (for example, because of cough), a low-cost ARB should be offered. ACE inhibitors are less effective in patients of African-Caribbean ethnicity due their generally lower circulating blood levels of ACE.

B Indapamide

Diuretics can be added as additional therapy for better control of hypertension. If diuretic treatment is to be initiated or changed, offer a thiazide-like diuretic, such as chlortalidone (12.5–25.0 mg once daily) or indapamide (1.5 mg modified-release once daily or 2.5 mg once daily) in

A 57-year-old man is referred to the cardiology clinic by his general practitioner for an abnormality on his electrocardiogram (ECG). He had gone to see his GP for a general medical check-up. His past medical history is unremarkable and he is not on any medication. He plays squash up to 4 times per week. His physical examination is essentially normal, with a BP of 121/82mmHg and pulse of 56 BPM.

The following results are obtained:

ECG	sinus rhythm with second-degree heart block (Mobitz type I)
chest X-ray (CXR)	Normal
full blood count (FBC)	U/E, liver function tests (LFTs) and lipid profile are within normal range.

How would you manage this gentleman?

A	Refer him for a pacemaker assessment
B	Arrange an outpatient 24hr tape
C	Suggest he buys an ECG recording device for his smartphone
D	Advise him that he shouldn't drive because of risk of blackouts
E	Discharge him from the clinic

Submit

ECG	sinus rhythm with second-degree heart block (Mobitz type I)
chest X-ray (CXR)	Normal
full blood count (FBC)	U/E, liver function tests (LFTs) and lipid profile are within normal range.

How would you manage this gentleman?

Your answer was correct

A Refer him for a pacemaker assessment

B Arrange an outpatient 24hr tape

C Suggest he buys an ECG recording device for his smartphone

D Advise him that he shouldn't drive because of risk of blackouts

E Discharge him from the clinic

Explanation

E Discharge him from the clinic

This asymptomatic man who has second-degree (Mobitz type I) heart block should be discharged from the clinic. Second-degree atrioventricular block Mobitz type I (Wenckebach phenomenon) is characterised by progressive PR interval prolongation until a P wave fails to conduct. The PR interval before the blocked P wave is much longer than the PR interval after the blocked P wave.

E Discharge him from the clinic

This asymptomatic man who has second-degree (Mobitz type I) heart block should be discharged from the clinic. Second-degree atrioventricular block Mobitz type I (Wenckebach phenomenon) is characterised by progressive PR interval prolongation until a P wave fails to conduct. The PR interval before the blocked P wave is much longer than the PR interval after the blocked P wave. The risk of progression to complete heart block with Mobitz type I in an asymptomatic man is very low, unlike in Mobitz type II where pacemaker insertion should be considered. The risk factors for cardiovascular disease are very low in this man and he can be safely discharged from the clinic.

A Refer him for a pacemaker assessment

Pacemaker assessment would be considered in Mobitz type II, where risk of progression to complete heart block is considered significant.

B Arrange an outpatient 24hr tape

This isn't indicated bearing in mind there are no symptoms of either tachycardic or bradycardic episodes, as such it isn't an appropriate use of resources and may increase anxiety.

C Suggest he buys an ECG recording device for his smartphone

This is a waste of money given that he is reporting symptoms of rhythm disturbance.

D Advise him that he shouldn't drive because of risk of blackouts

A 26-year-old man was admitted to the Emergency Department with acute cardiac failure. Previously fit and well, his past medical history is unremarkable. He presented with a three-day history of central chest pain, fever and shortness of breath. Initially he had generalised muscle pains; he then developed chest pain and a cough productive of yellowish sputum. The chest pain radiated to his back and the shortness of breath was progressive. When he presented, he could not complete a sentence in one breath because of breathlessness.

On examination, he was dyspnoeic, febrile and sweaty with a pulse rate of >100/min, respiratory rate of 32/min and a blood pressure was 81/43 mmHg. His jugular venous pressure was slightly raised at 4 cm. First, second and a third heart sounds were heard producing a gallop rhythm. Respiratory examination revealed widespread crackles and scattered rhonchi bilaterally.

Investigations:

Hb	15.8 g/dl
WCC	18×10^9/l (lymphocytosis)
PLT	210×10^9/l
Na+	136 mmol/l
K+	4.1 mmol/l
Creatinine	131 µmol/l
Bicarbonate	23.4 mmol/l
MCV	88.6 fl
Urea	9.7 mmol/l
Mg^{2+}	0.81 mmol/l
Troponin T	12.4 units (normal is <<0.01)
ECG	Sinus rhythm with a right bundle branch block at a rate of 123/min

ECG	Sinus rhythm with a right bundle branch block at a rate of 123/min
CXR	Enlarged globular heart with evidence of pulmonary oedema
Echocardiogram	A small pericardial effusion with a normal left ventricular size but very poor global left ventricular function; the ejection fraction was 25%
Pulmonary capillary wedge pressure (PCWP)	21 mmHg

Blood gases on 100% oxygen:

pH	7.5
$p(O_2)$	15.10 kPa
$p(CO_2)$	3.43 kPa

He is given diamorphine, pain relief, and catheterised.

Which of the following interventions would you immediately commence in addition in this patient?

A Intravenous gelofusin

B Inotropic support

C DC cardioversion

D Thrombolysis

E Potassium and magnesium replacement

10:13
594-042-7551 Leave

Explanation

B Inotropic support

This patient, with a likely diagnosis of acute viral myocarditis, is in cardiogenic shock. In this case with a PCWP >15 mmHg, inotropic support is the most appropriate next step. If PCWP <15 mmHg, then cautious intravenous (IV) fluids (colloids) should be given in 100–200 ml. A small amount of dimorphine is beneficial as it vasodilates and reduces anxiety. Early cardiology consultation is advised. Left ventricular assist devices are also recognised to improve outcomes in this situation.

A Intravenous gelofusin

This patient's PCWP is already above 15 mmhg, and hence further fluid loading is not appropriate.

C DC cardioversion

This patient is tachycardic due to her cardiac failure rather than to a rhythm disturbance requiring cardioversion.

D Thrombolysis

Although this patient is in hypotensive cardiac failure, there is no indication that this is ischaemic in origin and hence thrombolysis isn't required.

E Potassium and magnesium replacement

Both magnesium and potassium are within the normal range, and hence replacement is not required in this situation.

Rate this question:
Audio Video Share Participants More

A 45-year-old lady attends the Emergency Department complaining of palpitations. She describes these as fast and regular, of sudden onset and termination. They have been present for a number of years, but she feels they have become more frequent following a chest infection a week ago for which she is on antibiotics from her GP. She has a past medical history of bipolar affective disorder, for which she is on treatment. On examination in the Emergency Department her BP is 142/72 mmHg, with pulse 70/min and regular. Her chest is clear. Electrolytes reveal that her potassium is in the normal range (3.9 mmol/l).

A resting 12-lead ECG shows a QTc interval of 0.55 s. A 72 h Holter monitor is arranged, which demonstrates a number of short runs of SVT corresponding to the patient's symptoms.

Which of the following agents is most appropriate in this case?

A	Sotalol
B	Bisoprolol
C	Flecainide
D	Amiodarone
E	Disopyramide

32337

Submit

A 45-year-old lady attends the Emergency Department complaining of palpitations. She describes these as fast and regular, of sudden onset and termination. They have been present for a number of years, but she feels they have become more frequent following a chest infection a week ago for which she is on antibiotics from her GP. She has a past medical history of bipolar affective disorder, for which she is on treatment. On examination in the Emergency Department her BP is 142/72 mmHg, with pulse 70/min and regular. Her chest is clear. Electrolytes reveal that her potassium is in the normal range (3.9 mmol/l).

A resting 12-lead ECG shows a QTc interval of 0.55 s. A 72 h Holter monitor is arranged, which demonstrates a number of short runs of SVT corresponding to the patient's symptoms.

Which of the following agents is most appropriate in this case?

Your answer was incorrect

A	Sotalol
B	Bisoprolol
C	Flecainide
D	Amiodarone
E	Disopyramide

Explanation

B Bisoprolol

Explanation

B Bisoprolol

A beta-blocker such as bisoprolol can be used for suppression of arrhythmias in this case, as it does not have an effect on the QT interval. In contrast, other agents such as amiodarone are known to prolong the QT interval; this actually increases the risk of torsades de pointes ventricular tachycardia and, as such, should be avoided. With an ECG showing long QT, she should be given advice to avoid other agents that are known to prolong QT, such as macrolide antibiotics. Additionally, care should be taken to keep both her potassium and magnesium within the normal range if possible.

C Flecainide

Flecainide can cause prolongation of the QT, and would not represent a suitable choice in this case.

A Sotalol

Sotalol can be used for prophylaxis of paroxysmal atrial tachycardia or fibrillation, paroxysmal AV re-entrant tachycardias (both nodal and involving accessory pathways) and paroxysmal supraventricular tachycardia after cardiac surgery. However, it may prolong the QT interval and can cause life-threatening ventricular arrhythmias. In this case, with a prolonged QT interval on admission ECG, sotalol does not represent an appropriate option.

D Amiodarone

An 83-year-old man is seen in the Cardiology Department for pre-syncopal episodes. He describes a couple of events when he felt that he was going to faint and had to sit down. There were no precipitating factors on either of these episodes. There was no associated chest pain or palpitations. In his everyday life he has very good exercise tolerance with no symptoms of chest pain on exertion, shortness of breath on exertion, orthopnoea or paroxysmal nocturnal dyspnoea.

There is a past medical history of hypertension for which he is prescribed bendroflumethiazide 2.5 mg od. There is no history of ischaemic heart disease or valvular heart disease.

On examination he is comfortable, with a blood pressure of 138/86 mmHg and a heart rate of 76 beats/min, which is irregular. His heart sounds are normal and his chest is clear.

An electrocardiogram (ECG) performed shows sinus rhythm with occasional ventricular ectopics. The patient has 24 h ECG monitoring as an outpatient.

Which one of the following findings would be an indication for permanent pacemaker implantation?

A	Frequent ventricular ectopics
B	Sinus pauses of >3.0 s
C	Intermittent Wenckebach phenomenon
D	Paroxysmal atrial fibrillation
E	Non-sustained VT

32277

Submit

these episodes. There was no associated chest pain or palpitations. In his everyday life he has very good exercise tolerance with no symptoms of chest pain on exertion, shortness of breath on exertion, orthopnoea or paroxysmal nocturnal dyspnoea.

There is a past medical history of hypertension for which he is prescribed bendroflumethiazide 2.5 mg od. There is no history of ischaemic heart disease or valvular heart disease.

On examination he is comfortable, with a blood pressure of 138/86 mmHg and a heart rate of 76 beats/min, which is irregular. His heart sounds are normal and his chest is clear.

An electrocardiogram (ECG) performed shows sinus rhythm with occasional ventricular ectopics. The patient has 24 h ECG monitoring as an outpatient.

Which one of the following findings would be an indication for permanent pacemaker implantation?

Your answer was correct

A Frequent ventricular ectopics

B Sinus pauses of >3.0 s

C Intermittent Wenckebach phenomenon

D Paroxysmal atrial fibrillation

E Non-sustained VT

Explanation

B Sinus pauses of >3.0 s

Indications for permanent pacemaker implantation include

Rana Alnasser's screen

B Sinus pauses of >3.0 s

Indications for permanent pacemaker implantation include third-degree heart block, symptomatic second-degree block, asymptomatic type II second-degree block and pauses of more than 3.0 s.

A Frequent ventricular ectopics

Single ventricular ectopics are an indication for neither a permanent pacemaker nor an implantable defibrillator. They are most likely to be a normal phenomenon.

C Intermittent Wenckebach phenomenon

Mobitz type 1 heart block associated with the Wenckebach phenomenon is not associated with progression to complete heart block.

D Paroxysmal atrial fibrillation

PAF is an indication for bisoprolol under current Nice guidance, rather than a pacemaker.

E Non-sustained VT

Ventricular tachycardia (VT) may be an indication for non-sustained VT in the context of a previous myocardial infarction (MI), particularly in the setting of a reduced ejection fraction. The MADIT trial showed a 54% reduction of death in patients following MI with left ventricular ejection fraction (LVEF) < 35% and sustained VT on monitoring or inducible on electrophysiological studies. The AVID trial showed a 31% death reduction in patients with resuscitated VT or ventricular fibrillation (VF). Current indications for automatic implantable cardioverter-

A 65-year-old man with a history of cigarette smoking (40 pack-years) and type II diabetes presents with pain in both calves and feet. He reports calf pain on walking to the pub over the past few months, but says that the pain became much worse a few weeks ago and is now also present at rest. He also has suffered with pins and needles in his feet for two to three years. He takes a PDE-5 inhibitor for erectile dysfunction.

On examination, his distal foot pulses are not easily palpable. Capillary return is poor in both feet and there is an absence of hair. His arches have dropped and his feet show evidence of bony deformity. There is an ulcer on his right great toe with evidence of surrounding infection and oedema. His BP is measured at 155/85 mmHg, with a pulse of 75/min, AF.

Investigations:

Hb	12.1 g/dl
WCC	6.2×10^9/l
PLT	201×10^9/l
Na^+	140 mmol/l
K^+	4.9 mmol/l
Creatinine	192 μmol/l
HbA_1c	77.05 mmol/mol (9.2%)
ABPI	0.4 – both legs

Which of the following is the most likely cause of his calf pain?

A Peripheral neuropathic pain

B Chronic arterial insufficiency

palpable. Capillary return is poor in both feet and there is an absence of hair. His arches have dropped and his feet show evidence of bony deformity. There is an ulcer on his right great toe with evidence of surrounding infection and oedema. His BP is measured at 155/85 mmHg, with a pulse of 75/min, AF.

Investigations:

Hb	12.1 g/dl
WCC	6.2×10^9/l
PLT	201×10^9/l
Na^+	140 mmol/l
K^+	4.9 mmol/l
Creatinine	192 µmol/l
HbA_1c	77.05 mmol/mol (9.2%)
ABPI	0.4 – both legs

Which of the following is the most likely cause of his calf pain?

A Peripheral neuropathic pain

B Chronic arterial insufficiency

C Mixed arterial disease and neuropathy

D Peripheral arterial emboli

E Osteomyelitis

B Chronic arterial insufficiency

The patient has suffered calf claudication for many months, which has progressed to pain at rest. The ABPI has fallen into the critical zone (<0.5) - he therefore requires arterial ultrasound and an arteriogram. There may be lesions that are amenable to angioplasty at the time of angiography, otherwise he may require referral for bypass surgery.

It is also noted that his creatinine is elevated at 192 μmol/l, which puts him at significantly increased risk of contrast nephropathy. It would be important to ensure the patient is adequately hydrated before the procedure to reduce this risk.

C Mixed arterial disease and neuropathy

Although an accurate diagnosis for the overall condition of this patient, it is the chronic arterial insufficiency that accounts for the presentation of claudication progressing to chronic pain.

A Peripheral neuropathic pain

Although there is evidence of peripheral neuropathy with paraesthesia in the feet, ulcers and fallen arches, this is unlikely to be the cause of the pattern of pain described here.

D Peripheral arterial emboli

These would present as an acute ischaemic limb with the classical signs thereof: pain, pallor, pulseless, paraesthesia and paralysis. Diagnosis would be confirmed with Doppler ultrasound or angiography of the affected limb.

E Osteomyelitis

Although there is evidence of peripheral neuropathy with paraesthesia in the feet, ulcers and fallen arches, this is unlikely to be the cause of the pattern of pain described here.

D Peripheral arterial emboli

These would present as an acute ischaemic limb with the classical signs thereof: pain, pallor, pulseless, paraesthesia and paralysis. Diagnosis would be confirmed with Doppler ultrasound or angiography of the affected limb.

E Osteomyelitis

This patient is at high risk of osteomyelitis due to impaired sensation, impaired healing and the presence of infection around the ulcer. The normal white cell count (WCC) reduces the likelihood of this diagnosis, although in chronic infection inflammatory markers may not be elevated. An MRI scan of the foot would be needed to diagnose osteomyelitis of this patient's toe.

Rate this question:

© Pastest 2019

A 71-year-old man returns to the ward for rehabilitation after discharge from the ITU where he was treated for 6 days following a cardiac arrest in the community, thought to be related to right lower lobe pneumonia. Although he appears alert and can converse with nursing staff, they have noticed some lack of short-term memory and intention myoclonus when he attempts to carry out basic tasks on the ward. On examination his blood pressure is 132/82 mmHg, with pulse 75/min and regular. Heart sounds are normal; however, there is still evidence of decreased breath sounds at the right base. He is orientated in time, place and person, and can converse about recent events he has seen on the news. Although power appears normal bilaterally, you confirm intention myoclonus.

Which of the following is the most likely diagnosis?

A	Lance-Adams syndrome
B	Myoclonic status epilepticus
C	Pontine stroke
D	Post-ITU delirium
E	Propofol withdrawal syndrome

Submit

after discharge from the ITU where he was treated for 6 days following a cardiac arrest in the community, thought to be related to right lower lobe pneumonia. Although he appears alert and can converse with nursing staff, they have noticed some lack of short-term memory and intention myoclonus when he attempts to carry out basic tasks on the ward. On examination his blood pressure is 132/82 mmHg, with pulse 75/min and regular. Heart sounds are normal; however, there is still evidence of decreased breath sounds at the right base. He is orientated in time, place and person, and can converse about recent events he has seen on the news. Although power appears normal bilaterally, you confirm intention myoclonus.

Which of the following is the most likely diagnosis?

Your answer was correct

A	Lance-Adams syndrome
B	Myoclonic status epilepticus
C	Pontine stroke
D	Post-ITU delirium
E	Propofol withdrawal syndrome

Explanation

A Lance-Adams syndrome

Lance-Adams syndrome is a rare condition that can occur following a period of cerebral hypoxia. Onset occurs within days to weeks of cardiac arrest. It is characterised by intention myoclonus, as seen with this patient. Although no

10:26

A Lance-Adams syndrome

Lance-Adams syndrome is a rare condition that can occur following a period of cerebral hypoxia. Onset occurs within days to weeks of cardiac arrest. It is characterised by intention myoclonus, as seen with this patient. Although no trials on effective treatment have been conducted, levetiracetam, clonazepam and valproate have been recommended as first-line treatments.

B Myoclonic status epilepticus

Similar to Lance-Adams syndrome, this is a complication of cerebral hypoxia. Unlike the case presented here, however, onset is within 48 h of the hypoxic insult. It has a poor prognosis and is difficult to control. Furthermore, it leads to generalised multifocal clonus and significant cognitive impairment.

C Pontine stroke

Pontine stroke results from pontine infarction following interruption of the vertebra-basilar circulation. The exact clinical presentation depends on the specific area of the pons affected. Typical features include decreased consciousness, nausea and vomiting.

D Post-ITU delirium

This condition is common in patients who are admitted to the ITU due to a number of risk factors including sedating medications, immobilisation and critical illness. This patient remains oriented to time, place and person. Despite some short-term memory deficit reported, the patient does not appear to have significant cognitive impairment. As such, this points away from the diagnosis of delirium.

Rana Alnasser's screen

to generalised multifocal clonus and significant cognitive impairment.

C Pontine stroke

Pontine stroke results from pontine infarction following interruption of the vertebra-basilar circulation. The exact clinical presentation depends on the specific area of the pons affected. Typical features include decreased consciousness, nausea and vomiting.

D Post-ITU delirium

This condition is common in patients who are admitted to the ITU due to a number of risk factors including sedating medications, immobilisation and critical illness. This patient remains oriented to time, place and person. Despite some short-term memory deficit reported, the patient does not appear to have significant cognitive impairment. As such, this points away from the diagnosis of delirium.

E Propofol withdrawal syndrome

This condition is recognised as occurring in some individuals following exposure to propofol. However, it typically presents with generalised seizure activity, which is not reported here.

Rate this question:

A 16-year-old congenitally deaf girl is brought into the Accident and Emergency department following an episode of collapse which occurred while playing tennis. She had fallen to the ground unconscious and spontaneously recovered consciousness a couple of minutes later. The previous week she had begun a course of clarithromycin for a chest infection. When you see her, her vital signs are stable and examination of the cardiovascular and respiratory systems is unremarkable. An ECG is performed which reveals sinus rhythm with a rate of 70/min, a PR interval of 0.15 s, a QRS interval of 0.11 s and a corrected QT interval of 0.48 s.

What of the following syndromes is the most likely diagnosis?

A Romano-Ward

B Jervell-Lange-Nielsen

C Wolff-Parkinson-White

D Lown-Ganong-Levine

E Brugada

7248

Submit

A 16-year-old congenitally deaf girl is brought into the Accident and Emergency department following an episode of collapse which occurred while playing tennis. She had fallen to the ground unconscious and spontaneously recovered consciousness a couple of minutes later. The previous week she had begun a course of clarithromycin for a chest infection. When you see her, her vital signs are stable and examination of the cardiovascular and respiratory systems is unremarkable. An ECG is performed which reveals sinus rhythm with a rate of 70/min, a PR interval of 0.15 s, a QRS interval of 0.11 s and a corrected QT interval of 0.48 s.

What of the following syndromes is the most likely diagnosis?

Your answer was correct

A Romano-Ward

B Jervell-Lange-Nielsen

C Wolff-Parkinson-White

D Lown-Ganong-Levine

E Brugada

Explanation

B Jervell-Lange-Nielsen

The normal range for the duration of the corrected QT

Explanation

B Jervell-Lange-Nielsen

The normal range for the duration of the corrected QT interval (QT_c) is 0.35–0.43 s. Long-QT syndrome is a congenital disorder characterised by a prolonged QT interval; when it is associated with congenital deafness it is termed Jervell–Lange–Nielsen syndrome. Long-QT syndrome carries a risk of ventricular tachy-arrhythmias which may present with syncope, cardiac arrest or sudden death. The risk of tachy-arrhythmias is increased by hypomagnesaemia, hypokalaemia and drugs which prolong the QT interval, of which clarithromycin is one. Beta-blockers are the drugs of choice for patients with long-QT syndrome.

A Romano–Ward

This is associated with long QT but there is no associated deafness in this condition.

C Wolff–Parkinson–White

This is a pre-excitation syndrome associated with short PR interval, broad QRS complex, and the presence of a delta wave.

D Lown–Ganong–Levine

This is a pre-excitation syndrome associated with very short PR, normal QRS, and no delta wave (in contrast to WPW syndrome).

E Brugada

This is associated with ST elevation in leads V1-V3, and a

A 54-year-old Indian immigrant presents to the emergency department with rapidly progressive dyspnoea of 3 h duration. He is a known hypertensive, on atenolol 50 mg per day, and hyperlipidaemic, on simvastatin 20 mg per day and has type 2 diabetes for which he takes metformin and glicazide. The patient states that he had a similar episode in India 4 months ago. On examination he appears breathless and is using the accessory muscles of respiration. His blood pressure is 185/110 mmHg, heart rate 114/min and respiratory rate 28/min. He has raised jugular venous pressure (JVP), summation gallop and inspiratory crackles all over the chest.

Investigations:

Electrocardiogram (ECG)	Sinus tachycardia with left ventricular hypertrophy and strain pattern, antero-lateral ST segment depression
Chest X-ray	Bilateral pulmonary venous congestion
pH	7.38
$p(CO_2)$	4.5 kPa
$p(O_2)$	10 kPa
O_2 saturation	93%
White cell count	14×10^9/l
Haemoglobin	12 g/dl
Platelets	188×10^9/l
Na^+	138 mmol/l
K^+	4.5 mmol/l
Creatinine	112 micromol/l

What is the most likely cause of this patient's symptoms?

Electrocardiogram (ECG)	Sinus tachycardia with left ventricular hypertrophy and strain pattern, antero-lateral ST segment depression
Chest X-ray	Bilateral pulmonary venous congestion
pH	7.38
$p(CO_2)$	4.5 kPa
$p(O_2)$	10 kPa
O_2 saturation	93%
White cell count	14×10^9/l
Haemoglobin	12 g/dl
Platelets	188×10^9/l
Na^+	138 mmol/l
K^+	4.5 mmol/l
Creatinine	112 micromol/l

What is the most likely cause of this patient's symptoms?

A Acute aortic regurgitation

B Bilateral renal artery stenosis

C Myocardial ischaemia

D Community-acquired pneumonia

E Pulmonary embolism

C Myocardial ischaemia

This patient has presented with rapidly worsening dyspnoea and clinical findings namely, tachycardia, raised jugular venous pressure (JVP), gallop rhythm and inspiratory crackles, which suggest acute pulmonary oedema. Rapidly developing pulmonary congestion, as in this patient, is also termed flash pulmonary oedema. The most common cause of flash pulmonary oedema is myocardial ischaemia. He has three risk factors for coronary artery disease - hypertension, high cholesterol and diabetes - and therefore he should be evaluated for it.

B Bilateral renal artery stenosis

Bilateral renal artery stenosis can also present with a similar clinical picture but is a less common cause of flash pulmonary oedema. We would expect difficult-to-treat hypertension and different-sized kidneys on abdominal ultrasound in bilateral renal artery stenosis.

A Acute aortic regurgitation

Aortic regurgitation can cause acute heart failure with flash pulmonary oedema, but is rare. There is no history to suggest the presence of aortic regurgitation. The echocardiographic findings do not include a regurgitant aortic valve.

D Community-acquired pneumonia

Clinical findings are not in favour of community-acquired pneumonia. Typical findings we would expect include a fever, raised white cell count, crepitations in one lung lobe and JVP would not be raised.

E Pulmonary embolism

Bilateral renal artery stenosis can also present with a similar clinical picture but is a less common cause of flash pulmonary oedema. We would expect difficult-to-treat hypertension and different-sized kidneys on abdominal ultrasound in bilateral renal artery stenosis.

A Acute aortic regurgitation

Aortic regurgitation can cause acute heart failure with flash pulmonary oedema, but is rare. There is no history to suggest the presence of aortic regurgitation. The echocardiographic findings do not include a regurgitant aortic valve.

D Community-acquired pneumonia

Clinical findings are not in favour of community-acquired pneumonia. Typical findings we would expect include a fever, raised white cell count, crepitations in one lung lobe and JVP would not be raised.

E Pulmonary embolism

Clinical findings are not in favour of pulmonary embolism. Typical findings we would expect include haemoptysis and pleuritic chest pain. There may be signs of risk factors such as swollen calves to suggest deep vein thrombosis.

A 75-year-old lady presents to the Emergency Department complaining of chest pain. Her initial electrocardiogram (ECG) shows ST elevation in leads II, III and aVF. She underwent primary coronary intervention with stenting. One hour later the ECG shows a bradycardia of 50 beats/min with Mobitz type I atrioventricular block and isoelectric ST segments. The patient is asymptomatic with a blood pressure of 105/62 mmHg.

What is the most appropriate course of action?

A	Continuous monitoring
B	Rescue angioplasty
C	IV atropine
D	Temporary transvenous pacing
E	Transcutaneous pacing

6909

Submit

© Pastest 2019

A 75-year-old lady presents to the Emergency Department complaining of chest pain. Her initial electrocardiogram (ECG) shows ST elevation in leads II, III and aVF. She underwent primary coronary intervention with stenting. One hour later the ECG shows a bradycardia of 50 beats/min with Mobitz type I atrioventricular block and isoelectric ST segments. The patient is asymptomatic with a blood pressure of 105/62 mmHg.

What is the most appropriate course of action?

Your answer was correct

A	Continuous monitoring
B	Rescue angioplasty
C	IV atropine
D	Temporary transvenous pacing
E	Transcutaneous pacing

A
B
C
D
E
0

Resp
Resp
Resp
Resp

Explanation

A	Continuous monitoring

This would be appropriate given the self-limiting nature of Mobitz I atrioventricular block and the lack of adverse features. It's likely post-inferior infarct that the rhythm abnormality will gradually resolve. AV nodal block is seen after approximately 3% of myocardial infarctions treated with PCI.

Explanation

A Continuous monitoring

This would be appropriate given the self-limiting nature of Mobitz I atrioventricular block and the lack of adverse features. It's likely post-inferior infarct that the rhythm abnormality will gradually resolve. AV nodal block is seen after approximately 3% of myocardial infarctions treated with PCI.

B Rescue angioplasty

There is no feature to suggest significant ongoing ischaemia. The absence of chest pain and Mobitz I AV block suggests that the risk of progression is low.

C IV atropine

There are no adverse features that require the immediate administration of atropine. In the event that there was significant bradycardia and hypotension, atropine may have a role whilst transvenous pacing could be instigated.

D Temporary transvenous pacing

Mobitz type I atrioventricular block is usually self-limiting and rarely requires intervention. Transvenous pacing would be required in the event of symptomatic hypotension and bradycardia that doesn't resolve with atropine.

E Transcutaneous pacing

There are no adverse features that require immediate transcutaneous pacing. This would be considered for life-threatening bradycardia that doesn't respond to medical intervention, and there isn't immediate access to transvenous pacing capability.

9:37

A 45-year-old male known to have idiopathic dilated cardiomyopathy and ejection fraction of 30% is evaluated in the clinic. He is on digoxin 0.125 mg OD, furosemide 40 mg BD and enalapril 10 mg BD. He is able to walk 200 m on the flat although he reports significant shortness of breath. He weighs 78 kg, pulse is 70 beats/min, jugular venous pulse (JVP) is 1 cm above the sternal notch, BP is 123/82. Both heart sounds are normal with no murmur, chest is clear on auscultation and there is a trace of pedal oedema. He is started on bisoprolol 5 mg per day. The patient comes to the clinic 4 weeks later and still reports tiredness and shortness of breath on minimal exercise. His BP is 127/82, with pulse 67 beats/min and regular.

What is the most appropriate next step in this patient's management

A	Increase the digoxin dose to 0.25 mg OD
B	Change enalapril to sacubitril/valsartan
C	Increase the furosemide dose to 120 mg per day
D	Add bendroflumethiazide 2.5 mg
E	Add ivabradine 5 mg BD

7424

Submit

Rana Alnasser's screen

A 45-year-old male known to have idiopathic dilated cardiomyopathy and ejection fraction of 30% is evaluated in the clinic. He is on digoxin 0.125 mg OD, furosemide 40 mg BD and enalapril 10 mg BD. He is able to walk 200 m on the flat although he reports significant shortness of breath. He weighs 78 kg, pulse is 70 beats/min, jugular venous pulse (JVP) is 1 cm above the sternal notch, BP is 123/82. Both heart sounds are normal with no murmur, chest is clear on auscultation and there is a trace of pedal oedema. He is started on bisoprolol 5 mg per day. The patient comes to the clinic 4 weeks later and still reports tiredness and shortness of breath on minimal exercise. His BP is 127/82, with pulse 67 beats/min and regular.

What is the most appropriate next step in this patient's management

Your answer was correct

A Increase the digoxin dose to 0.25 mg OD

B Change enalapril to sacubitril/valsartan

C Increase the furosemide dose to 120 mg per day

D Add bendroflumethiazide 2.5 mg

E Add ivabradine 5 mg BD

Explanation

B Change enalapril to sacubitril/valsartan

In patients with symptoms of heart failure not controlled on ACE inhibitors alone, switching to the combination of ARB and neprilysin inhibitor can further improve symptoms and quality of life. In the PARADIGM-HF trial, the combination of sacubitril and valsartan reduced cardiovascular death and heart failure hospitalisations by 20%.

A Increase the digoxin dose to 0.25 mg OD

Increasing the digoxin is not appropriate; although modest doses may reduce symptoms of heart failure, digoxin itself has no positive impact on cardiovascular outcomes and may increase mortality in certain patient groups.

C Increase the furosemide dose to 120 mg per day

There is no indication of a worsening of fluid overload, and increasing the loop diuretic won't have a positive impact on outcomes.

D Add bendroflumethiazide 2.5 mg

Although adding a thiazide diuretic may have a positive impact on fluid overload, it isn't indicated here given that fluid status is stable and furosemide dose has not been maximised.

E Add ivabradine 5 mg BD

Ivabradine is only indicated where pulse rate is greater than 75 beats per minute.

7424

Rate this question:

9:40
On
594-042-7551
Leave

Pastest+

A 24-year-old woman has been referred to clinic with a 1-year history of exertional breathlessness. She undergoes echocardiography, which reveals a congenitally bicuspid aortic valve with a peak gradient of 55 mmHg. She wishes to start a family.

What would be the most appropriate treatment for her valve problem?

A	Advise avoidance of pregnancy
B	Refer for valvuloplasty
C	Refer for metal valve replacement
D	Refer for bio-prosthetic valve replacement
E	Pregnancy under cardiologist supervision and subsequent valve replacement

6515

Submit

Previous Q...
Skip Questi...

© Pastest 2019
Audio Video Share Participants More

D Refer for bio-prosthetic valve replacement

Pregnancy will greatly increase the required cardiac output and lead to a rapid worsening of symptoms. Congenital aortic stenosis is the major cause in patients under the age of 30 years and presenting with symptomatic aortic stenosis. Valvotomy is reserved for patients unsuitable for surgery; This leaves a porcine valve replacement before pregnancy as the best option. Untreated aortic stenosis has an average 5-year survival rate of only 40%.

A Advise avoidance of pregnancy

This patient has severe symptomatic aortic stenosis, and wishes to start a family. She should be offered intervention on her valve prior to pregnancy.

B Refer for valvuloplasty

NICE guidance states that 'in adults, the procedure should only be used to treat patients who are unsuitable for surgery, as the efficacy is usually shortlived.'

C Refer for metal valve replacement

Metal valve replacements require warfarinisation and, as such, would be unsuitable in this patient because warfarin is teratogenic in early pregnancy and not advised in late pregnancy due to the risk of haemorrhage. The risks of anticoagulation and thromboembolism make this an unsuitable choice.

E Pregnancy under cardiologist supervision and subsequent valve replacement

This patient has severe symptomatic aortic stenosis. Pregnancy in this context is associated with 10% maternal

B Refer for valvuloplasty

NICE guidance states that 'in adults, the procedure should only be used to treat patients who are unsuitable for surgery, as the efficacy is usually shortlived.'

C Refer for metal valve replacement

Metal valve replacements require warfarinisation and, as such, would be unsuitable in this patient because warfarin is teratogenic in early pregnancy and not advised in late pregnancy due to the risk of haemorrhage. The risks of anticoagulation and thromboembolism make this an unsuitable choice.

E Pregnancy under cardiologist supervision and subsequent valve replacement

This patient has severe symptomatic aortic stenosis. Pregnancy in this context is associated with 10% maternal morbidity. She should undergo intervention on her valve prior to pregnancy.

Rate this question:

© Pastest 2019

A 21-year-old man presents to the emergency department having collapsed with palpitations while dancing in a night club. He has a past history of cardiac surgery to fix a hole in the heart as a child and to fix an abnormal valve. On examination in the department his BP is 135/72 mmHg, pulse is 75/min and regular. He is not in cardiac failure. ECG reveals sinus rhythm with a short PR interval; in addition there is right bundle branch block and a delta wave.

Which of the following is the most likely diagnosis?

A	Ebstein's anomaly
B	Lown-Ganong-Levine syndrome
C	Uncomplicated SVT
D	Amphetamine toxicity
E	Thyrotoxicosis

32358

Submit

Previous Q... Skip Questi...

© Pastest 2019

A 21-year-old man presents to the emergency department having collapsed with palpitations while dancing in a night club. He has a past history of cardiac surgery to fix a hole in the heart as a child and to fix an abnormal valve. On examination in the department his BP is 135/72 mmHg, pulse is 75/min and regular. He is not in cardiac failure. ECG reveals sinus rhythm with a short PR interval; in addition there is right bundle branch block and a delta wave.

Which of the following is the most likely diagnosis?

Your answer was correct

A Ebstein's anomaly

B Lown–Ganong–Levine syndrome

C Uncomplicated SVT

D Amphetamine toxicity

E Thyrotoxicosis

Explanation

A Ebstein's anomaly

The presence of delta waves and short PR interval is indicative of WPW. When correlated with his past surgical history (repair of atrial septal defect and tricuspid valve abnormalities as a child), Ebstein's anomaly is the most likely diagnosis.

Cardiac problems associated with Ebstein's generally result

A Ebstein's anomaly

The presence of delta waves and short PR interval is indicative of WPW. When correlated with his past surgical history (repair of atrial septal defect and tricuspid valve abnormalities as a child), Ebstein's anomaly is the most likely diagnosis.

Cardiac problems associated with Ebstein's generally result from abnormal formation of the tricuspid valve, atrialisation of the right ventricle and associated defects such as ASD. The condition is rare, probably accounting for around 0.5% of cases of congenital heart disease. Ebstein's may be associated with Wolff–Parkinson–White syndrome as seen here.

Digoxin and verapamil are not recommended treatments for arrhythmias associated with WPW as they may precipitate increased conduction through the accessory pathway and worsening of tachycardia. DC cardioversion is normally the treatment of choice in the acute management of tachyarrhythmia. However, for long-term management, given the patient's age, radiofrequency ablation of the accessory pathway is preferable.

B Lown–Ganong–Levine syndrome

LGL syndrome is like WPW in the sense that it is a pre-excitation syndrome. However, the ECG changes present is only short PR interval without delta waves or abnormal QRS complex.

C Uncomplicated SVT

The presence of an abnormal resting ECG i.e. short PR interval, delta waves and RBBB makes it very unlikely that it was an uncomplicated SVT.

D Amphetamine toxicity

A 48-year-old van driver presents with central chest pain. Past history of note includes type 1 diabetes, hypertension and smoking with a 30 pack-year history. The pain is pleuritic, retrosternal and relieved on sitting forward. On examination, his blood pressure is 148/90 mmHg and pulse is 85/min and regular. There is generalised saddle-shaped ST elevation on ECG.

Which of the following is the most appropriate treatment in this case?

A	Ibuprofen
B	Indometacin
C	Streptokinase
D	Tissue plasminogen activator
E	Paracetamol

9285

Submit

© Pastest 2019

A 48-year-old van driver presents with central chest pain. Past history of note includes type 1 diabetes, hypertension and smoking with a 30 pack-year history. The pain is pleuritic, retrosternal and relieved on sitting forward. On examination, his blood pressure is 148/90 mmHg and pulse is 85/min and regular. There is generalised saddle-shaped ST elevation on ECG.

Which of the following is the most appropriate treatment in this case?

Your answer was correct

A Ibuprofen

B Indometacin

C Streptokinase

D Tissue plasminogen activator

E Paracetamol

Explanation

A Ibuprofen

Although the patient has multiple risk factors for coronary artery disease, the description of chest pain and ECG appearance is highly suggestive of acute pericarditis. The most common viral cause is Coxsackie B virus; other causes include adenovirus, echovirus and influenza viruses. Acute viral pericarditis may occasionally be associated with

Explanation

A Ibuprofen

Although the patient has multiple risk factors for coronary artery disease, the description of chest pain and ECG appearance is highly suggestive of acute pericarditis. The most common viral cause is Coxsackie B virus; other causes include adenovirus, echovirus and influenza viruses. Acute viral pericarditis may occasionally be associated with accumulation of a pericardial effusion.

ESC guidelines have defined the diagnosis of acute pericarditis as 2 out of 4 of the following: (1) pericarditic chest pain; (2) pericardial rub; (3) new widespread ST-elevation or PR depression; and (4) pericardial effusion (new or worsening).

Ibuprofen is a NSAID which is considered first-line therapy for pericarditis. Aspirin or colchicine is the other alternative. Treatment duration should be guided by symptoms and blood tests (CRP), but normally it is for 1-2 weeks' duration. If patients are unable to take NSAIDs, colchicine is the alternative. Corticosteroids should only be used as second line due to the risk of drug dependence. Patients should be told to reduce physical activity for a minimum of 3 months from initial onset.

B Indometacin

Indometacin is also a NSAID. The recommended NSAID according to ESC guidelines is either ibuprofen or aspirin. However, ESC do recommend the use of indometacin in the context of recurrent pericarditis.

C Streptokinase

In the presence of generalised saddle-shaped ST elevation, this is most likely to be pericarditis. Therefore, the use of thrombolysis with streptokinase is not warranted.

A 70-year-old man is reviewed in the clinic some 6 weeks after admission with an acute ischaemic stroke. He has made an almost complete recovery, although he is left with poor coordination affecting his right hand. Previous TIAs before the permanent event are noted. Medication includes ramipril 10 mg daily, atorvastatin 10 mg daily and aspirin 75 mg daily, which he was taking before the event. On examination his BP is 145/82 mmHg.

Investigations:

Hb	12.1 g/dl
WCC	5.0 $\times 10^9$/l
PLT	231 $\times 10^9$/l
Na^+	140 mmol/l
K^+	5.0 mmol/l
Creatinine	131 µmol/l
ESR	11 mm/hr
Carotid USS	<70% stenosis bilaterally
ECHO	Good LV function, no dilatation
ECG	Old inferior infarct, sinus rhythm

Which of the following is the intervention that is most appropriate to reduce his future risk of stroke?

A Increase aspirin to 300mg

B Switch aspirin to clopidogrel

C Add dipyridamole to his aspirin therapy

D Add warfarin

B Switch aspirin to clopidogrel

While clopidogrel is first line as secondary prevention, NICE recommend that aspirin 75 mg daily may be used if both clopidogrel and modified-release dipyridamole are contraindicated or cannot be tolerated. There is no place in the NICE guidance for aspirin 300 mg.

A Increase aspirin to 300mg

While clopidogrel is first line as secondary prevention, NICE recommend that aspirin 75 mg daily may be used if both clopidogrel and modified-release dipyridamole are contraindicated or cannot be tolerated. There is no place in the NICE guidance for aspirin 300 mg.

C Add dipyridamole to his aspirin therapy

While NICE guidance states that aspirin 75 mg daily with modified-release dipyridamole 200 mg twice daily may be used if clopidogrel cannot be tolerated, we are not given any indication here that clopidogrel is an unsuitable choice.

D Add warfarin

This patient is in sinus rhythm, with no suggestion of an arrhythmia that would warrant anticoagulation.

E Refer for carotid endarterectomy

NICE recommends that patients with stable neurological symptoms from acute non-disabling stroke or TIA and who have symptomatic carotid stenosis <70%, according to the ECST criteria, should not undergo surgery.

Rate this question:

A 54-year-old man presents to the Emergency Department complaining of a severe headache lasting 12 h. He gives a history of frequent headaches over the last year. There is no history of fevers, neck stiffness or nausea, but he does complain of some vague visual disturbances. There is no history of sick contacts. He has no past medical history of note. He is a smoker of 15 cigarettes a day and he drinks about 30 units of alcohol a week.

On examination, he is found to be hypertensive, with a blood pressure (BP) of 195/105 mmHg and a heart rate of 96 beats/min. Auscultation of his heart reveals normal heart sounds and the chest is clear. Abdominal palpation reveals no palpable masses or organomegaly. A bruit is heard over the left renal artery. There are flame-shaped haemorrhages and cotton-wool spots seen on fundoscopy.

His electrocardiogram (ECG) shows sinus rhythm with left ventricular hypertrophy. A urine dipstick is positive for blood and protein.

Which of the following would be the most appropriate management?

A	Admission to hospital for blood pressure intervention and monitoring
B	Oral ramipril 5 mg, followed by 2 h of observation then discharge
C	Sublingual nifedipine 10 mg and discharge when the blood pressure settles
D	Simple analgesia for the headache, oral nifedipine 10 mg and discharge home with general practitioner (GP) review
E	CT head to rule out a subarachnoid haemorrhage and, if excluded, simple analgesia for the

His electrocardiogram (ECG) shows sinus rhythm with left ventricular hypertrophy. A urine dipstick is positive for blood and protein.

Which of the following would be the most appropriate management?

A	Admission to hospital for blood pressure intervention and monitoring
B	Oral ramipril 5 mg, followed by 2 h of observation then discharge
C	Sublingual nifedipine 10 mg and discharge when the blood pressure settles
D	Simple analgesia for the headache, oral nifedipine 10 mg and discharge home with general practitioner (GP) review
E	CT head to rule out a subarachnoid haemorrhage and, if excluded, simple analgesia for the headache

6923

Submit

A Admission to hospital for blood pressure intervention and monitoring

This patient has significant hypertension and features of resulting acute end organ damage. In particular the findings on fundoscopy and the urine dipstick are particularly concerning. These features require the patient to undergo acute management and he should be stabilised prior to discharge. Acute lowering of the blood pressure should be balanced against the risk of stroke if the blood pressure is lowered too quickly. Mean arterial BP should be reduced by no more than 25% during the first few hours of intervention. A number of agents can be considered, and intravenous (iv) labetalol is suggested as a first-line agent.

B Oral ramipril 5 mg, followed by 2 h of observation then discharge

This strategy may be appropriate if the patient was asymptomatic and had no features of end organ damage. However, in this case, the patient must be stabilised prior to discharge. Ramipril would be the first line medication if this was chronic hypertension. However, in the acute setting it is insufficient and unlikely to have a sufficiently rapid effect. Additionally, the presence of a renal bruit may suggest underlying renal artery stenosis, which would be a contraindication for ACE inhibition.

C Sublingual nifedipine 10 mg and discharge when the blood pressure settles

Sublingual nifedipine can rapidly lower blood pressure. There is concern over its use in this setting, however, as a significant acute drop in blood pressure may precipitate cerebral ischaemia. As such, short-acting nifedipine should be avoided in the acute setting.

D Simple analgesia for the headache, oral nifedipine

D Simple analgesia for the headache, oral nifedipine 10 mg and discharge home with general practitioner (GP) review

Amlodipine would be recommended as a first-line agent for chronic hypertension if this patient was > 55 years old or of Afro-Caribbean descent. However, it is not sufficient in this setting where there is significant hypertension with features of end organ damage. GP review is also insufficient as this patient requires close monitoring to ensure end organ effects are not continuing.

E CT head to rule out a subarachnoid haemorrhage and, if excluded, simple analgesia for the headache

A presentation with an acute, severe headache should prompt consideration of a subarachnoid haemorrhage. However, the presence of significant hypertension with eye signs makes this the more likely cause of the headache. Additionally, a CT scan is insufficient to rule out a subarachnoid haemorrhage outside of the first six hours.

Rate this question:

© Pastest 2019

A 29-year-old man presents with a one-day history of fever and severe central pleuritic chest pain. He is normally fit and well with no history of drug or alcohol abuse. He was born in the United Kingdom and has no travel history. He reports a similar episode of pleuritic chest pain some 6 months earlier, which his GP diagnosed as pericarditis. On examination, his temperature is 38.5°C. His heart rate is 100 beats per minute and BP 108/70 mmHg. The chest radiograph is within normal limits. The 12-lead ECG showed sinus tachycardia and widespread ST elevation in limb and precordial leads.

What is the most appropriate first-line treatment?

A Aspirin

B Aspirin and colchicine

C Prednisolone

D Alteplase

E Dalteparin

Submit

and severe central pleuritic chest pain. He is normally fit and well with no history of drug or alcohol abuse. He was born in the United Kingdom and has no travel history. He reports a similar episode of pleuritic chest pain some 6 months earlier, which his GP diagnosed as pericarditis. On examination, his temperature is 38.5°C. His heart rate is 100 beats per minute and BP 108/70 mmHg. The chest radiograph is within normal limits. The 12-lead ECG showed sinus tachycardia and widespread ST elevation in limb and precordial leads.

What is the most appropriate first-line treatment?

Your answer was correct

A Aspirin

B Aspirin and colchicine

C Prednisolone

D Alteplase

E Dalteparin

Explanation

B Aspirin and colchicine

Non-steroidal anti-inflammatory drugs and colchicine are recommended first-line therapy for acute pericarditis. The ICAP study has suggested that colchine reduces the risk of recurrent pericarditis from 37.5 to 16.7%, making it the first-choice option her.

A Aspirin

B Aspirin and colchicine

Non-steroidal anti-inflammatory drugs and colchicine are recommended first-line therapy for acute pericarditis. The ICAP study has suggested that colchine reduces the risk of recurrent pericarditis from 37.5 to 16.7%, making it the first-choice option her.

A Aspirin

Colchicine is recommended as an adjunct to non-steroidal anti-inflammatory drugs for the treatment of acute pericarditis, particularly where it is recurrent. High-dose aspirin would have been an option if this was a first episode of pericarditis.

C Prednisolone

Corticosteroids are not recommended as first-line therapy for acute pericarditis. Corticosteroids are usually considered an option for patients who aren't able to tolerate colchicine and don't respond to NSAIDs or aspirin alone.

D Alteplase

This treatment is not indicated for acute pericarditis. It is not associated with improved outcomes and may increase the risk of pericardial haemorrhage.

E Dalteparin

There is no clear indication for anticoagulant use, except for venous thromboembolism prophylaxis. Assuming this young patient is able to move around the bed, they would be considered at low risk of venous thromboembolism.

A 60-year-old man with heart failure comes to the clinic. Current medication includes furosemide 80 mg OD, spironolactone 50 mg OD, bisoprolol 5 mg OD and ramipril 10 mg OD. He has had increased shortness of breath over the past 3 months and is now housebound, only able to live downstairs and move from room to room. On examination his BP is 100/70 mmHg, with a pulse of 55/min. He has late inspiratory crackles in both lung fields on auscultation, and bilateral swollen ankles. A transthoracic echocardiogram shows a left ventricular ejection of 30%.

Investigations:

Hb	11.4 g/dl
WCC	5.0 $\times 10^9$/l
PLT	130 $\times 10^9$/l
Na^+	139 mmol/l
K^+	4.9 mmol/l
Creatinine	155 µmol/l
ECG	Sinus rhythm, with QRS 160 ms
CXR	Evidence of bilateral pulmonary oedema, cardiomegaly
Ejection fraction	30%

Which of the following is the most appropriate intervention to improve mortality?

A Implantation of an implantable cardioverter defibrillator (ICD)

B Implantation of a single chamber pacemaker

bilateral swollen ankles. A transthoracic echocardiogram shows a left ventricular ejection of 30%.

Investigations:

Hb	11.4 g/dl
WCC	5.0 x10^9/l
PLT	130 x10^9/l
Na^+	139 mmol/l
K^+	4.9 mmol/l
Creatinine	155 µmol/l
ECG	Sinus rhythm, with QRS 160 ms
CXR	Evidence of bilateral pulmonary oedema, cardiomegaly
Ejection fraction	30%

Which of the following is the most appropriate intervention to improve mortality?

A Implantation of an implantable cardioverter defibrillator (ICD)

B Implantation of a single chamber pacemaker

C Initiate low-dose digoxin

D Implantation of a cardiac re-synchronisation therapy (CRT) device

E Increase furosemide dose

Na^+	139 mmol/l
K^+	4.9 mmol/l
Creatinine	155 µmol/l
ECG	Sinus rhythm, with QRS 160 ms
CXR	Evidence of bilateral pulmonary oedema, cardiomegaly
Ejection fraction	30%

Which of the following is the most appropriate intervention to improve mortality?

Your answer was incorrect

A Implantation of an implantable cardioverter defibrillator (ICD)

B Implantation of a single chamber pacemaker

C Initiate low-dose digoxin

D Implantation of a cardiac re-synchronisation therapy (CRT) device

E Increase furosemide dose

Explanation

D Implantation of a cardiac re-synchronisation therapy (CRT) device

This patient has developed significant heart failure and

D Implantation of a cardiac re-synchronisation therapy (CRT) device

This patient has developed significant heart failure and appears to be on maximum medical therapy at present. His mild bradycardia limits his ability to tolerate up-titration of his beta-blockade. The presence of a broad LBBB picture on his ECG suggests that ventricular contraction is likely to be uncoordinated. In such patients, implantation of a cardiac re-synchronisation (CRT) device will improve mortality and has been shown to improve symptoms (judged by NYHA class). See Table 1 for full recommendations.

Table 1: Options for implantation of ICD or CRT devices in patients with heart failure and left ventricular dysfunction with a left ventricular ejection fraction of ≤35%. NYHA – New York Heart Association Class of heart failure symptoms. CRT-D – cardiac resynchronisation therapy device with defibrillator capability. CRT-P – cardiac resynchronisation therapy device with pacemaker capability only. ICD – implantable cardioverter defibrillator. *Suggested by presence of positive family history of long-QT syndrome hypertrophic cardiomyopathy, Brugada syndrome or arrhythmogenic right ventricular cardiomyopathy. Adapted from National Institute for Health and Care Excellence TA314 – Implantable cardioverter defibrillators and cardiac resynchronisation therapy for arrhythmias and heart failure.

	NYHA Class			
QRS duration	I	II	III	IV
<120 ms	ICD if high risk of sudden cardiac death*			ICD and CRT not clinically indicated
120-149 ms (no LBBB)	ICD			

*Suggested by presence of positive family history of long-QT syndrome hypertrophic cardiomyopathy, Brugada syndrome or arrhythmogenic right ventricular cardiomyopathy. Adapted from National Institute for Health and Care Excellence TA314 – Implantable cardioverter defibrillators and cardiac resynchronisation therapy for arrhythmias and heart failure.

	NYHA Class			
QRS duration	I	II	III	IV
<120 ms	ICD if high risk of sudden cardiac death*			ICD and CRT not clinically indicated
120-149 ms (no LBBB)	ICD			CRT-P
120-149 ms (LBBB)	ICD	CRT-D	CRT-P or CRT-D	
≥150 ms (±LBBB)	CRT-D			

Cleland JGF et al. The effect of cardiac resynchronization on morbidity and mortality in heart failure. *N Engl J Med.* 2005;352:1539-49.

National Institute for Health and Care Excellence TA314 – Implantable cardioverter defibrillators and cardiac resynchronisation therapy for arrhythmias and heart failure. June 2014

A Implantation of an implantable cardioverter defibrillator (ICD)

Patients with significant heart failure are at risk of developing clinically significant ventricular arrhythmias and associated sudden cardiac death. However, ICD therapy

ATPase pump can inhibit AV-node depolarisation, which would worsen this patient's mild bradycardia.

E	Increase furosemide dose

Furosemide and other loop-diuretics have not been shown to have any significant benefit in mortality for patients with heart failure. This contrasts with potassium-sparing diuretics (such as spironolactone), which do have a mortality benefit when added to beta-blockers and ACE inhibitors in the management of chronic heart failure. Furthermore, in the case of this patient, the low systolic blood pressure would mean that the addition of significant further doses of furosemide may well be poorly tolerated.

References:

Peakcock WF, et al. Impact of intravenous loop diuretics on outcomes of patients hospitalized with acute decompensated heart failure: insights from the ADHERE registry. *Cardiology*. 2009;113:12-19.

Pitt B, et al. The effect of spironolactone on morbidity and mortality in patients with severe heart failure. *N Engl J Med*. 1999;341:709-11.

Rate this question:

© Pastest 2019

A 79-year-old man presents to Accident and Emergency following an episode of syncope. He describes feeling acutely dyspnoeic and dizzy while rushing home from the supermarket, followed by a collapse; he is uncertain how long he was unconscious for.

On examination, his chest is clear, heart sounds are pure and blood pressure is 128/86.

His electrocardiogram (ECG) is shown below:

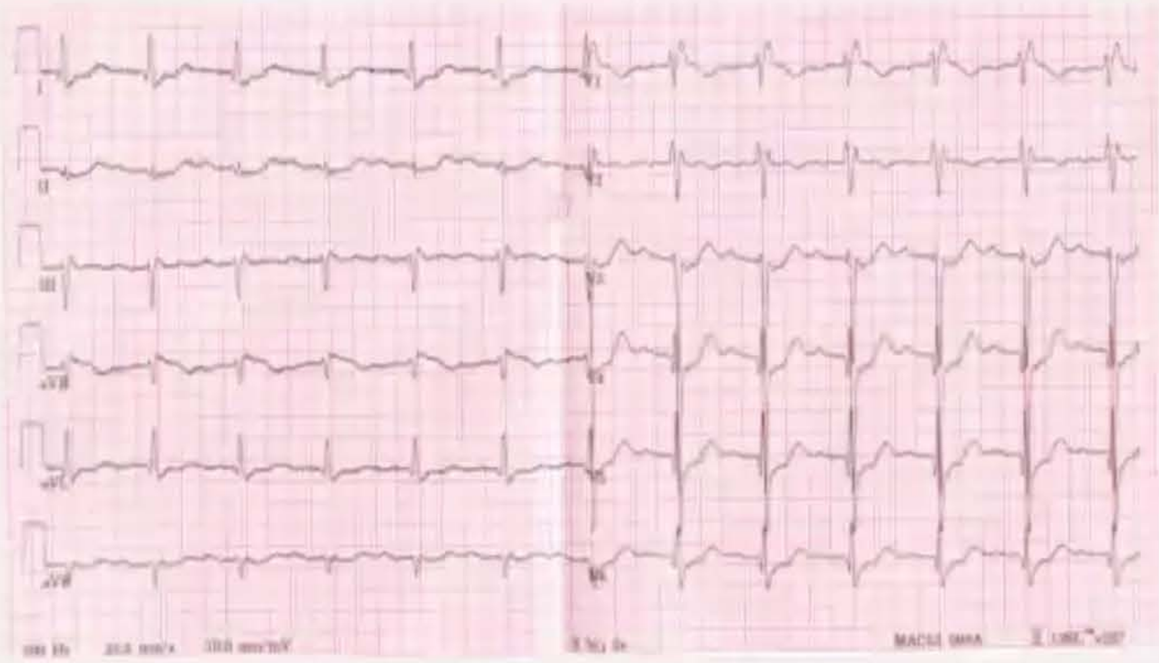

What cardiac conduction abnormality is demonstrated?

A Right bundle branch block

B First degree heart block

C Second degree heart block

D Bifascicular block

E Trifascicular block

E Trifascicular block

The ECG shows sinus rhythm. The PR interval is grossly prolonged, there is an RSR complex in V_1 compatible with a right bundle branch block, and a QRS axis compatible with a left anterior hemi-block (note positive WRS in lead I and equivocal - or more commonly negative - QRS in lead II). The combination of RBBB, LAHB (or LPHB) and long PR interval is termed 'trifascicular' block.

Bifascicular block (which is RBBB and either LAHB or LPHB) and trifascicular block refer to conduction disturbances below the atrioventricular (AV) node in which two or more of the fascicles of the left bundle branch and the right bundle branch are involved. Incomplete trifascicular block has the potential to degenerate to complete heart block.

Current ESC guidelines on pacing recommend that an ICD/CRT-D should be considered in patients with unexplained syncope and BBB, with an EF of < 35%. If the EF is > 35%, they should be considered for further investigation with carotid sinus massage and electrophysiological studies, and if these are negative then for consideration of an implantable loop recorder.

D Bifascicular block

Bifascicular block is the combination of RBBB and either LAHB or LPHB. In this case, PR prolongation is also seen, giving the diagnosis of trifascicular block.

A Right bundle branch block

While the ECG does show an RSR pattern in V1, there are also features of first degree heart block and left anterior hemiblock, making trifascicular block the most appropriate diagnosis.

10:14
On
594-042-7551
Leave

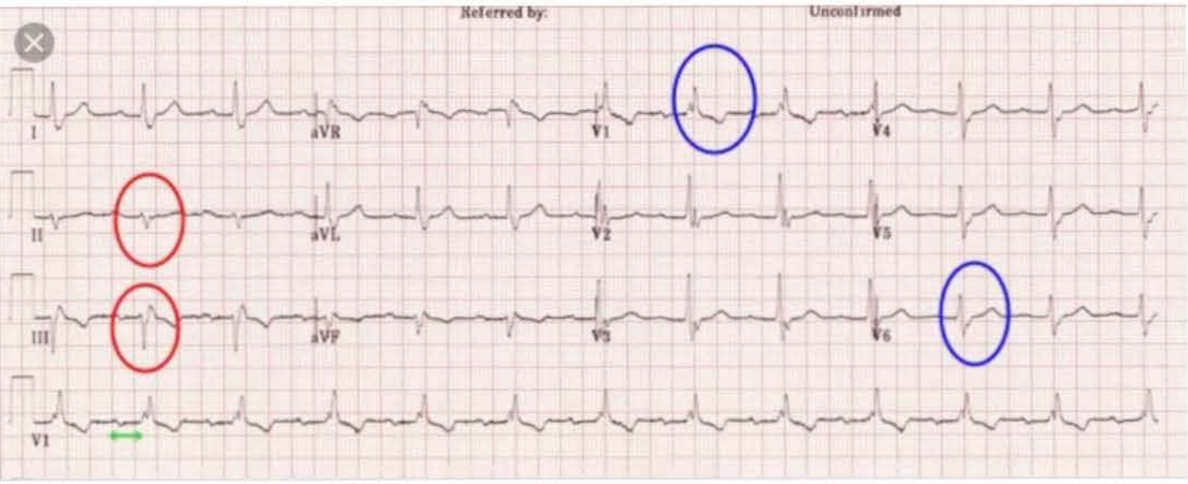

Health Tutor

Trifascicular Block - Health Tutor

Trifascicular Block - ECG

Images may be subject to copyright. Learn more

RELATED IMAGES

Second Degree Heart Block Type I EKG Answ...
practicalclinicalskills.com

1. grads AV-blok: EKG
absalon.ku.dk

Bifascicular Block - Health Tutor
health-tutor.com

Trifascicular block | Blog
mellidion.jp

Index of /wp-content/uploads/2016/02/
resusitasyon.com

Edward Gerstenfeld on Twitter: "Just to clari...
twitter.com

List of Synonyms and Antonyms of the Word...
canacopegdl.com

Severe first degree heart block – ECG quest
ecgquest.net

Discover
Updates
Search
Recent
Annotation
Stop Share

Audio
Video
Share
Participants
More

10:17
On
594-042-7551
Leave

62% 08:17

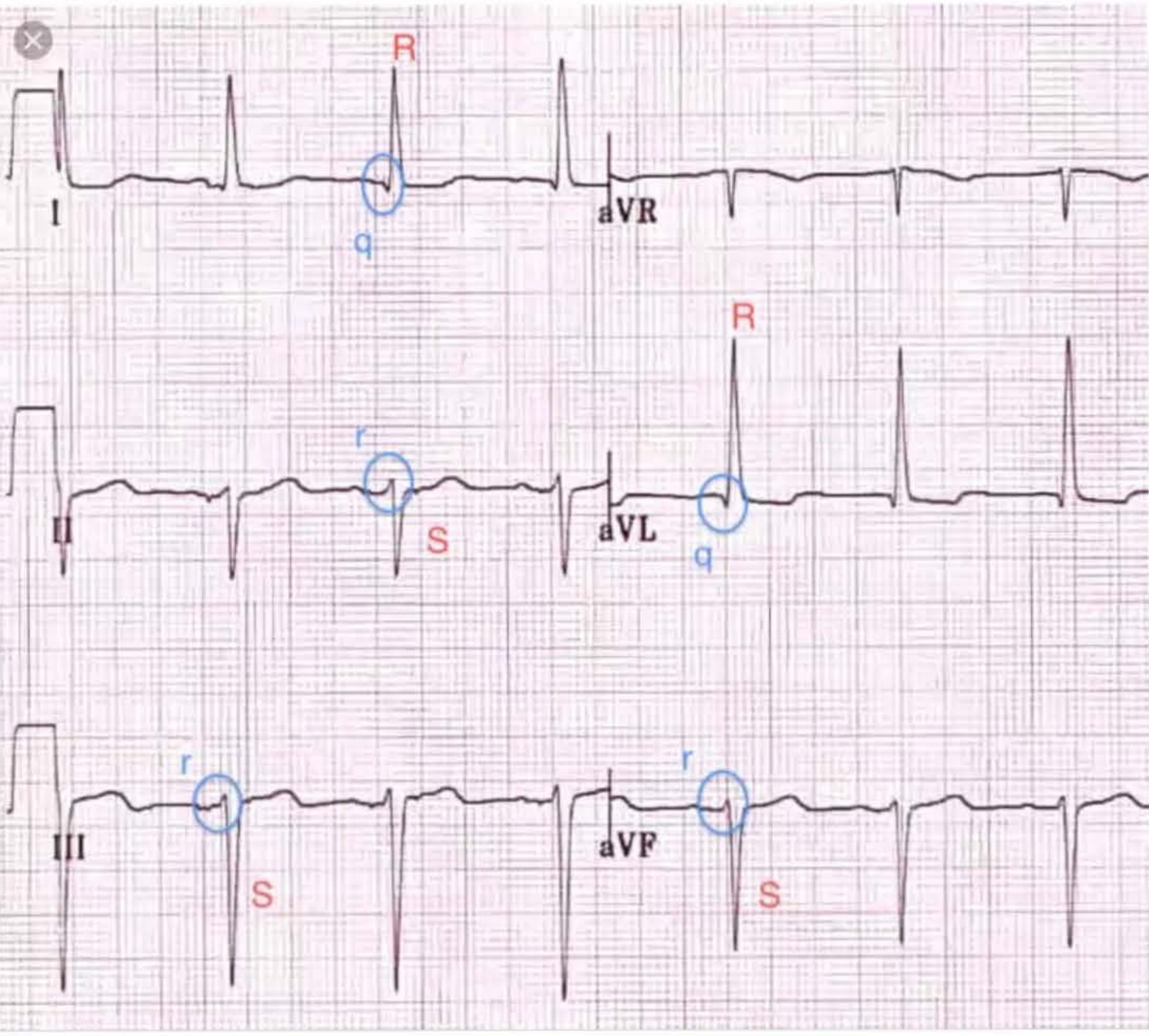

www.mellidion.jp

Trifascicular block | Blog

Images may be subject to copyright. Learn more

RELATED IMAGES

Discover
Updates
Search
Recent

Audio
Video
Share
Participants
More

While the ECG does show an RSR pattern in V1, there are also features of first degree heart block and left anterior hemiblock, making trifascicular block the most appropriate diagnosis.

B	First degree heart block

While the PR interval is prolonged, in keeping with first degree heart block, there are also features of RBBB and LAHB, making trifascicular block the most appropriate diagnosis. In addition, first degree heart block is usually a benign ECG finding in the absence of an underlying cause such as MI, and would be unlikely to lead to syncope.

C	Second degree heart block

Second degree heart block is associated with a prolonged PR interval that either progressively lengthens (Mobitz I/Wenckeback or remains constant (type II), prior to a dropped ventricular beat. There are no dropped beats seen here, and the ECG presented demonstrates trifascicular block.

Rate this question:

© Pastest 2019

A 45-year-old Bulgarian man is admitted via the Emergency Department. He has had a recent history of chronic cough, haemoptysis and weight loss. For the past few days he has suffered increasing shortness of breath, lethargy and exercise intolerance. On examination he looks unwell, he is thin and emaciated, his pulse is 105/min and his blood pressure is 100/60 mmHg. Jugular venous pressure (JVP) is markedly elevated and heart sounds are quiet and muffled; the palpable pulse pressure appears to decrease on inspiration. The electrocardiogram reveals small complexes, and the heart shadow looks globular on X-ray.

Which of following stems represents the best initial management of this case?

A	Intravenous furosemide
B	Sodium nitroprusside
C	Pericardial drainage
D	Bronchoscopy
E	Antibiotic therapy

Submit

A 45-year-old Bulgarian man is admitted via the Emergency Department. He has had a recent history of chronic cough, haemoptysis and weight loss. For the past few days he has suffered increasing shortness of breath, lethargy and exercise intolerance. On examination he looks unwell, he is thin and emaciated, his pulse is 105/min and his blood pressure is 100/60 mmHg. Jugular venous pressure (JVP) is markedly elevated and heart sounds are quiet and muffled; the palpable pulse pressure appears to decrease on inspiration. The electrocardiogram reveals small complexes, and the heart shadow looks globular on X-ray.

Which of following stems represents the best initial management of this case?

Your answer was incorrect

A Intravenous furosemide

B Sodium nitroprusside

C Pericardial drainage

D Bronchoscopy

E Antibiotic therapy

Explanation

C Pericardial drainage

This man is of Eastern European extraction and has

C Pericardial drainage

This man is of Eastern European extraction and has symptoms of possible tuberculous infection. Tuberculosis is a cause of exudative pericardial effusion, and it is likely that this has accumulated to produce symptoms of impending cardiac tamponade. Over the longer term, patients with tuberculous pericarditis are at risk of cardiac constriction. It is important to consider early use of corticosteroids in conjunction with anti-tuberculous therapy in these patients, as there is some evidence that steroids may reduce the risk of constrictive pericarditis. Advice of a cardiac surgeon is recommended, as pericardectomy may be required in some patients with recurrent pericardial effusions. In this instance drainage is both therapeutic and diagnostic - it allows relief of symptoms and the potential for culture and sensitivity of the fluid.

E Antibiotic therapy

Although antibiotics form the mainstay of treatment for TB, in the current clinical scenario the patient has features of a large pericardial effusion and impending tamponade, which needs to be relieved to prevent further clinical deterioration.

A Intravenous furosemide

Although pericardial effusions secondary to fluid overload and congestive cardiac failure may be partially responsive to intravenous diuretics, this is not the case for reactive or infective effusions.

B Sodium nitroprusside

Anti-hypertensives are not used in the management of pericardial effusions or tamponade. Its use in this instance

deterioration.

A Intravenous furosemide

Although pericardial effusions secondary to fluid overload and congestive cardiac failure may be partially responsive to intravenous diuretics, this is not the case for reactive or infective effusions.

B Sodium nitroprusside

Anti-hypertensives are not used in the management of pericardial effusions or tamponade. Its use in this instance would be inappropriate and may worsen the clinical picture.

D Bronchoscopy

Although bronchoscopy, bronchoalveolar washings or transbronchial needle aspiration may be used in the diagnostic work-up for TB, it is not a diagnostic or therapeutic treatment for pericardial effusion.

Rate this question:

Next Question

Previous Q... Tag Questi... Feedback End Session

Blog About Pastest Contact Us Help

© Pastest 2019

A 68-year-old year lady comes to the cardiology clinic for follow up. She suffered an inferior STEMI some 6 weeks ago and was stented. Current medication is 80 mg atorvastatin, 75 mg aspirin and 2.5 mg bisoprolol.

She read an article on the Internet that vitamin E was good for people who have had a previous heart attack and would like your opinion on it.

How would you advise this patient regarding vitamin E?

A	She should start taking 400 U/day of vitamin E
B	She should start taking 400 U of vitamin E weekly
C	There is no evidence that it is beneficial
D	It reduces the incidence of strokes
E	It is only beneficial post MI in patient with diabetes

Submit

Previous Q... Skip Questi...

© Pastest 2019

A 68-year-old year lady comes to the cardiology clinic for follow up. She suffered an inferior STEMI some 6 weeks ago and was stented. Current medication is 80 mg atorvastatin, 75 mg aspirin and 2.5 mg bisoprolol.

She read an article on the Internet that vitamin E was good for people who have had a previous heart attack and would like your opinion on it.

How would you advise this patient regarding vitamin E?

Your answer was correct

A	She should start taking 400 U/day of vitamin E
B	She should start taking 400 U of vitamin E weekly
C	There is no evidence that it is beneficial
D	It reduces the incidence of strokes
E	It is only beneficial post MI in patient with diabetes

Explanation

C There is no evidence that it is beneficial

The Heart Outcomes Prevention Evaluation (HOPE) study was a large randomised trial of ramipril and vitamin E in patients at high risk of cardiovascular events. This study showed no significant differences in the numbers of myocardial infarction, stroke or cardiovascular death between the vitamin E group and the placebo group. The

C There is no evidence that it is beneficial

The Heart Outcomes Prevention Evaluation (HOPE) study was a large randomised trial of ramipril and vitamin E in patients at high risk of cardiovascular events. This study showed no significant differences in the numbers of myocardial infarction, stroke or cardiovascular death between the vitamin E group and the placebo group. The HOPE-TOO was an extension of the same study and still showed no significant differences between the vitamin E group and the placebo group.

A She should start taking 400 U/day of vitamin E

A study has suggested that consumption of more than 60U/day may increase the risk of haemorrhagic stroke. As such 400 U/day, given the lack of impact on ischaemic events, has no role as a therapy.

B She should start taking 400 U of vitamin E weekly

This is a dose of less than 60U/day, thought to be the threshold for pharmaceutical supplementation. It's therefore unlikely to have a positive or negative benefit.

D It reduces the incidence of strokes

Vitamin E has no impact on risk of ischaemic stroke, although it may increase the risk of haemorrhagic stroke.

E It is only beneficial post MI in patient with diabetes

Large CV outcome studies in patients with diabetes have shown no positive impact of vitamin E in preventing ischaemic events.

A 65-year-old hypertensive male presents to the Emergency Department with a history of left praecordial pain of three hours' duration associated with profuse sweating. Electrocardiogram (ECG) reveals anterior myocardial infarction. He is given chewable aspirin, recombinant tissue plasminogen activator, intravenous (IV) heparin infusion and IV esmolol. He improves over the next few hours. ST segment elevation decreases by more than 50% and no arrhythmias are documented.

The next day, he again complains of chest pain which increases on reclining and radiating to the edge of the left trapezius. A pericardial friction rub is heard.

Some investigations were done and revealed:

Sodium	135 mmol/l
Potassium	4.5 mmol/l
Urea	8 mmol/l
Creatinine	70 µmol/l
Haemoglobin	14 g/dL
White cell count	10×10^9/L
Electrocardiogram (ECG)	No significant new changes
Echocardiogram	Anterior hypokinesia, ejection fraction of 35% and no evidence of pericardial effusion

What is the next best step in management of this patient?

A Discontinue IV heparin and increase aspirin to 650 mg every 4 h

Sodium	135 mmol/l
Potassium	4.5 mmol/l
Urea	8 mmol/l
Creatinine	70 μmol/l
Haemoglobin	14 g/dL
White cell count	10×10^9/L
Electrocardiogram (ECG)	No significant new changes
Echocardiogram	Anterior hypokinesia, ejection fraction of 35% and no evidence of pericardial effusion

What is the next best step in management of this patient?

A Discontinue IV heparin and increase aspirin to 650 mg every 4 h

B Discontinue IV heparin and start ibuprofen

C Discontinue IV heparin and start prednisolone

D Start regular paracetamol

E Increase aspirin to 650 mg every 4 h

Submit

D Start regular paracetamol

Early infarct-associated pericarditis usually occurs with large transmural infarctions and is characterised by pleuritic chest pain. Radiation to the trapezius ridge is a feature that is rarely seen with ischaemic pain and is a useful clue to diagnosis. Characteristic electrocardiogram (ECG) changes may not be seen because of changes of myocardial infarction (MI). Patients can usually be managed with simple analgesics such as paracetamol. High doses of aspirin are marked as potentially harmful in recent guidelines on the management of post-infarct pericarditis, particularly in the first seven to ten days after infarction.

E Increase aspirin to 650 mg every 4 h

The dosage of aspirin 650mg every 4 hours is too high. It is important to give other analgesia such as paracetamol to control the pain.

A Discontinue IV heparin and increase aspirin to 650 mg every 4 h

Anticoagulation can be continued if there is no pericardial effusion, as in such cases the risk of haemorrhagic pericarditis is low. However in the presence of significant effusion or if the effusion is increasing, heparin should be discontinued.

B Discontinue IV heparin and start ibuprofen

Anticoagulation can be continued if there is no pericardial effusion, as in such cases the risk of haemorrhagic pericarditis is low. However in the presence of significant effusion or if the effusion is increasing, heparin should be discontinued.

A 65-year-old hypertensive male presents to the Emergency Department with a history of left praecordial pain of three hours' duration associated with profuse sweating. Electrocardiogram (ECG) reveals anterior myocardial infarction. He is given chewable aspirin, recombinant tissue plasminogen activator, intravenous (IV) heparin infusion and IV esmolol. He improves over the next few hours. ST segment elevation decreases by more than 50% and no arrhythmias are documented.

The next day, he again complains of chest pain which increases on reclining and radiating to the edge of the left trapezius. A pericardial friction rub is heard.

Some investigations were done and revealed:

Sodium	135 mmol/l
Potassium	4.5 mmol/l
Urea	8 mmol/l
Creatinine	70 µmol/l
Haemoglobin	14 g/dL
White cell count	10×10^9/L
Electrocardiogram (ECG)	No significant new changes
Echocardiogram	Anterior hypokinesia, ejection fraction of 35% and no evidence of pericardial effusion

What is the next best step in management of this patient?

Your answer was incorrect

A Discontinue IV heparin and increase aspirin to 650

particularly in the first seven to ten days after infarction.

E Increase aspirin to 650 mg every 4 h

The dosage of aspirin 650mg every 4 hours is too high. It is important to give other analgesia such as paracetamol to control the pain.

A Discontinue IV heparin and increase aspirin to 650 mg every 4 h

Anticoagulation can be continued if there is no pericardial effusion, as in such cases the risk of haemorrhagic pericarditis is low. However in the presence of significant effusion or if the effusion is increasing, heparin should be discontinued.

B Discontinue IV heparin and start ibuprofen

Anticoagulation can be continued if there is no pericardial effusion, as in such cases the risk of haemorrhagic pericarditis is low. However in the presence of significant effusion or if the effusion is increasing, heparin should be discontinued.

C Discontinue IV heparin and start prednisolone

Anticoagulation can be continued if there is no pericardial effusion, as in such cases the risk of haemorrhagic pericarditis is low. However in the presence of significant effusion or if the effusion is increasing, heparin should be discontinued. There is no evidence that prednisolone has added benefit in pericarditis.

7471

Rate this question:

Next Question

A 25-year-old man presents with excruciating central chest pain radiating to his back. This began suddenly a few hours earlier while he was playing in a game of basketball with friends. Previous medical history of note includes lens dislocation and problems with lax, dislocatable joints, including his shoulders and patellae. On examination in the Emergency room the blood pressure in his left arm is significantly lower than the right, and he is complaining of some strange feelings and loss of power in his right arm and leg. BP is 150/90 mmHg in the right arm and 110/70 mmHg in the left arm.

A slice from his thoracic CT scan is shown below:

Which of the following is the most likely diagnosis?

A Abdominal aortic aneurysm

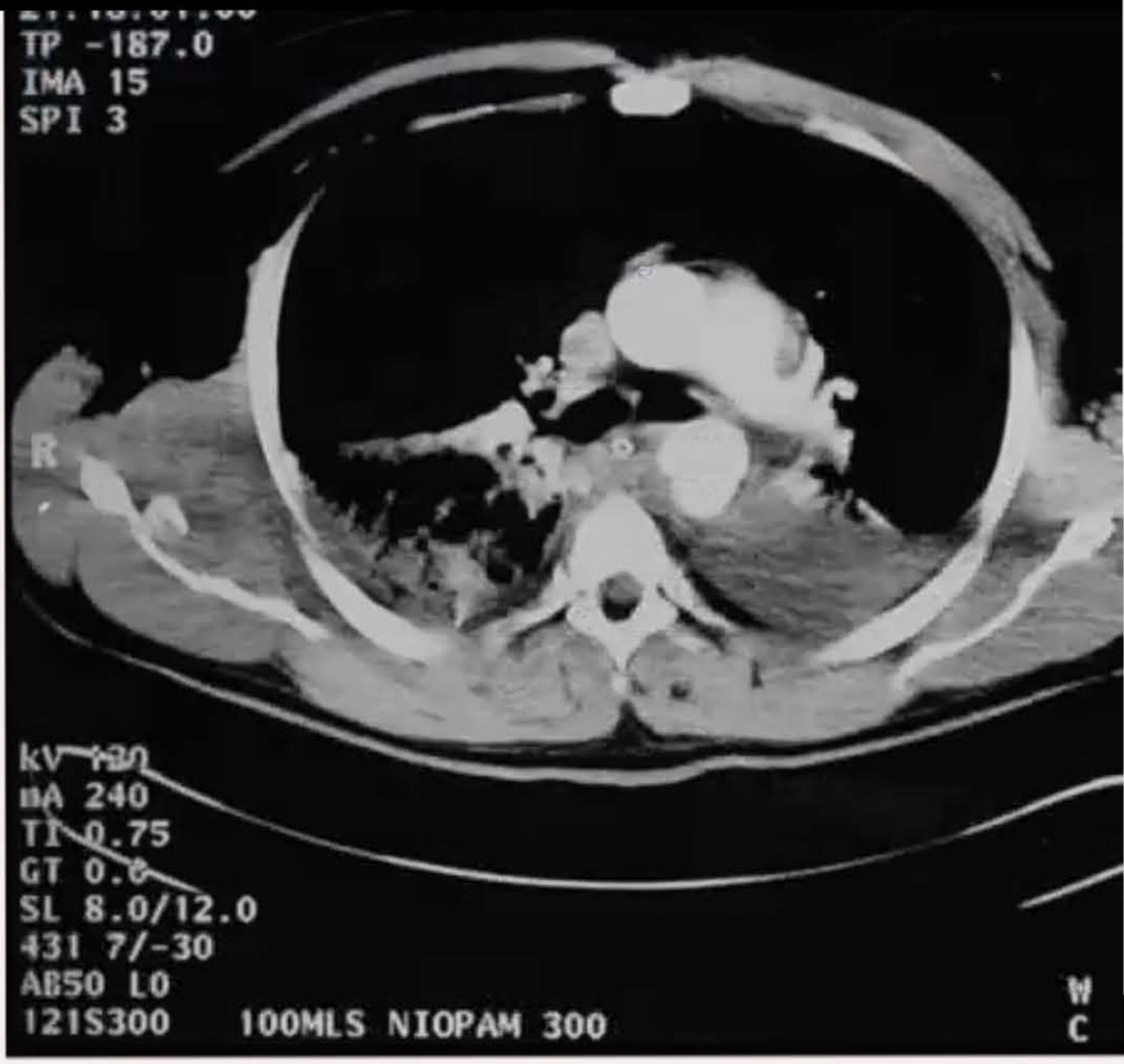

Which of the following is the most likely diagnosis?

A	Abdominal aortic aneurysm
B	Dissecting thoracic aortic aneurysm
C	Left pleural effusion
D	Pneumonia
E	Ruptured oesophagus

Submit

Rana Alnasser's screen

10:32

B Dissecting thoracic aortic aneurysm

The history is highly indicative of Marfan's syndrome and with the sudden onset chest pain, this makes it very likely to be dissection. This is further confirmed on the CT scan slice shown. Given his age, if he didn't have a condition increasing the risk of dissecting thoracic aneurysm, like Marfan's, presentation at this age would be highly unusual. In patients with Marfan's, routine screening for aortopathy is recommended. ESC guidelines have suggested intervention for dilated aortic root of >50mm or >45 in presence of other risk factors.

Blood pressure control is vitally important in achieving a good prognosis for patients with dissecting aneurysm, and IV labetalol would be the agent of choice to control blood pressure in this case. It is an effective negative inotropic agent, which reduces cardiac contractility. Sodium nitroprusside is a useful additional adjunct, but would be avoided in this case as there are concerns about cerebral perfusion. Where beta blockade is unsuitable, then calcium channel antagonists, particularly non-dihydropridines such as diltiazem would be a logical alternative.

A Abdominal aortic aneurysm

The CT scan is showing the thoracic cavity, therefore it would not be possible to diagnose AAA on this slice.

C Left pleural effusion

On the CT slice, there is evidence of a left sided pleural effusion. However, this will not explain the presentation of this patient. Aortic dissection, which is also present in the slice would fit the diagnosis better.

D Pneumonia

Rana Alnasser's screen

10:36
On
594-042-7551
Leave

A 70-year-old woman comes to your clinic for follow-up. She is a known patient with stable heart failure (NYHA II) due to ischaemic cardiomyopathy. She has chronic atrial fibrillation (AF) and has been anticoagulated with warfarin.

Other medications include: digoxin 125 µg od, furosemide 40 mg od, ramipril 2.5 mg od and bisoprolol 2.5 mg. Her resting pulse is 61 with a blood pressure of 132/82 mmHg.

Today, her international normalised ratio (INR) was 2.7. She would like to know whether there would be any benefits if she was cardioverted to normal sinus rhythm.

How would you advise this woman?

A	Rate control is better than rhythm control with respect to stroke
B	She should be referred for electrical cardioversion
C	She should be switched to amiodarone in an attempt to cardiovert her
D	Rhythm control has no survival benefit over a rate control strategy
E	She would benefit from ivabradine

Submit

Audio
Video
Share
Participants
More

Explanation

D	Rhythm control has no survival benefit over a rate control strategy

Current evidence suggests that rhythm control has no benefit over a rate control strategy, and indeed there was a trend to decreased mortality and decreased cardiovascular events in patients treated with a rate control intervention.

A	Rate control is better than rhythm control with respect to stroke

Any difference between rate control and rhythm control on outcomes did not reach statistical significance.

B	She should be referred for electrical cardioversion

In this situation, with dilated cardiomyopathy, electrical cardioversion is unlikely to be successful and would not impact on outcomes.

C	She should be switched to amiodarone in an attempt to cardiovert her

Amiodarone is highly unlikely to help her attain sinus rhythm, and carries significant risk with respect to long-term side effects including photosensitivity and thyroid dysfunction.

E	She would benefit from ivabradine

Patients who benefit most are those with persistent resting tachycardia who are suffering from either heart failure or angina.

Rate this question:

A 58-year-old man presents with central crushing chest pain radiating to his left arm. He has a long history of smoking and takes ramipril, aspirin and simvastatin for hypertension and dyslipidaemia. A few minutes after admission he deteriorates, with loss of consciousness. On examination his BP is 80/50 mmHg and the ECG monitor shows he is in VT. You arrange to cardiovert him. Post-cardioversion his BP recovers to 125/72 mmHg, and he receives aspirin and heparin.

Investigations:

Hb	12.9 g/dl
WCC	6.1 x10^9/l
PLT	310 x10^9/l
Na^+	139 mmol/l
K^+	5.2 mmol/l
Creatinine	120 µmol/l
Troponin	5.1 (<0.05)
ECG	Inferior ST elevation, pulse 75/min

Which one of the following represents the most appropriate management step?

A IV streptokinase

B IV alteplase

C PCI

D IV bretylium

E IV magnesium

shows he is in VT. You arrange to cardiovert him. Post-cardioversion his BP recovers to 125/72 mmHg, and he receives aspirin and heparin.

Investigations:

Hb	12.9 g/dl
WCC	6.1 x10⁹/l
PLT	310 x10⁹/l
Na^+	139 mmol/l
K^+	5.2 mmol/l
Creatinine	120 µmol/l
Troponin	5.1 (<0.05)
ECG	Inferior ST elevation, pulse 75/min

Which one of the following represents the most appropriate management step?

Your answer was correct

A IV streptokinase

B IV alteplase

C PCI

D IV bretylium

E IV magnesium

Explanation

10:39

MyPastest
https://mypastest.pastest.com

Pastest+

C PCI

This man has suffered an acute inferior myocardial infarction and a period of ventricular tachycardia. As such, referral for urgent PCI to relieve ischaemia is the management of choice. Given the results of recent studies, PCI is almost always preferable to thrombolysis where available.

A IV streptokinase

Current guidelines are clear that primary PCI is the recommended reperfusion therapy over fibrinolysis if performed by an experienced team within 120 min of first medical contact. Nice guidelines state that fibrinolysis should be offered as primary treatment 'to people with acute STEMI presenting within 12 hours of onset of symptoms if primary PCI cannot be delivered within 120 minutes of the time when fibrinolysis could have been given'.

B IV alteplase

Current guidelines are clear that primary PCI is the recommended reperfusion therapy over fibrinolysis if performed by an experienced team within 120 min of first medical contact. Nice guidelines state that fibrinolysis should be offered as primary treatment 'to people with acute STEMI presenting within 12 hours of onset of symptoms if primary PCI cannot be delivered within 120 minutes of the time when fibrinolysis could have been given'.

D IV bretylium

recommended reperfusion therapy over fibrinolysis if performed by an experienced team within 120 min of first medical contact. Nice guidelines state that fibrinolysis should be offered as primary treatment 'to people with acute STEMI presenting within 12 hours of onset of symptoms if primary PCI cannot be delivered within 120 minutes of the time when fibrinolysis could have been given'.

D IV bretylium

Cardioversion is the management of choice for sustained VT and VF. Sustained monomorphic VT that is recurrent or refractory to direct current cardioversion should be considered to be treated with IV amiodarone in the first instance, and may be considered for treatment with IV lidocaine or sotalol (do not use IV sotalol or other beta-blockers in the context of a low ejection fraction).

E IV magnesium

Hypomagnesaemia may worsen the propensity to develop VT; as such, if there is reasonable suspicion of hypomagnesaemia such as a history of diarrhoea, IV magnesium replacement may be considered. However, we are not given such a history here and, as such, while it may prove advantageous, provision of IV magnesium should not delay access to definitive management, in this case PCI.

Rate this question:

Next Question

Previous Q... Tag Questi... Feedback End Session

A 68-year-old woman presents to the Emergency Department after a collapse in the local supermarket. Apparently she had attended a few months earlier with a similar episode. She had suffered an inferior myocardial infarction seven years ago but was otherwise relatively well. Other past history of note includes the development of paroxysmal atrial fibrillation three years earlier. Medication includes ramipril 10 mg OD, aspirin 75 mg OD, indapamide 1.5 mg OD, bisoprolol 2.5 mg OD and atorvastatin 10 mg ON. She also takes ranitidine for indigestion. On examination in the Emergency Department she looks relatively well, her pulse is 62/min and regular with a BP of 115/72 mmHg.

Investigations:

Hb	12.1 g/dl
WCC	5.6 $\times 10^9$/l
PLT	156 $\times 10^9$/l
Na^+	140 mmol/l
K^+	5.0 mmol/l
Creatinine	120 µmol/l

ECG shows second-degree heart block.

A 24 h tape while on the ward shows two episodes of complete heart block, both occurring at night, the longest episode lasting 8 s.

Which of the following is the most appropriate intervention?

A Stop bisoprolol and discharge

B Single chamber pacemaker

C Dual chamber pacemaker

Hb	12.1 g/dl
WCC	5.6 x10^9/l
PLT	156 x10^9/l
Na^+	140 mmol/l
K^+	5.0 mmol/l
Creatinine	120 µmol/l

ECG shows second-degree heart block.

A 24 h tape while on the ward shows two episodes of complete heart block, both occurring at night, the longest episode lasting 8 s.

Which of the following is the most appropriate intervention?

A Stop bisoprolol and discharge

B Single chamber pacemaker

C Dual chamber pacemaker

D Stop bisoprolol and observe as an inpatient

E Stop ranitidine and discharge

Submit

Hb	12.1 g/dl
WCC	5.6 x10⁹/l
PLT	156 x10⁹/l
Na^+	140 mmol/l
K^+	5.0 mmol/l
Creatinine	120 µmol/l

ECG shows second-degree heart block.

A 24 h tape while on the ward shows two episodes of complete heart block, both occurring at night, the longest episode lasting 8 s.

Which of the following is the most appropriate intervention?

Your answer was correct

A Stop bisoprolol and discharge

B Single chamber pacemaker

C Dual chamber pacemaker

D Stop bisoprolol and observe as an inpatient

E Stop ranitidine and discharge

Explanation

C Dual chamber pacemaker

This patient presents with two episodes of collapse

10:41

MyPastest
https://mypastest.pastest.com

Pastest+

C Dual chamber pacemaker

This patient presents with two episodes of collapse associated with second-degree heart block with periods of complete heart block. Although cessation of her beta-blocker may have some benefit to her symptoms it is unlikely to completely resolve her clinical situation. As such, implantation of a pacemaker is required. Given that her atrial fibrillation is paroxysmal, she is likely to benefit from a dual-chamber pacemaker.

A Stop bisoprolol and discharge

The use of bisoprolol in this patient may have exacerbated her underlying cardiac rhythm. However, stopping this therapy is unlikely to resolve her rhythm abnormalities or symptoms completely. Additionally, bisoprolol has a positive mortality benefit following this patient's myocardial infarction and should be continued if possible. Given repeated episodes of collapse and positive findings on her 24 h tape, this option would be insufficient.

B Single chamber pacemaker

This patient does require implantation of a pacemaker given her symptoms and ECG findings. However, a dual-chamber pacemaker allows for both atrial and ventricular pacing. In patients that have organised atrial activity this is beneficial. If her atrial fibrillation was long-standing, persistent or permanent in nature, then a single-change device could be considered.

D Stop bisoprolol and observe as an inpatient

As with Option A, stopping the low dose of bisoprolol is

10:42

MyPastest
https://mypastest.pastest.com

Pastest+

on her 24 h tape, this option would be insufficient.

B	Single chamber pacemaker

This patient does require implantation of a pacemaker given her symptoms and ECG findings. However, a dual-chamber pacemaker allows for both atrial and ventricular pacing. In patients that have organised atrial activity this is beneficial. If her atrial fibrillation was long-standing, persistent or permanent in nature, then a single-change device could be considered.

D	Stop bisoprolol and observe as an inpatient

As with Option A, stopping the low dose of bisoprolol is unlikely to completely resolve her symptoms or ECG findings. Although observing this patient rather than discharging immediately may be of some benefit, these should be considered for a dual-chamber pacemaker in the first instance.

E	Stop ranitidine and discharge

Ranitidine has been shown to induce bradycardia in some patients, and case reports of syncope induced by ranitidine have been published. However, given the history of an inferior myocardial infarction (which is most likely to damage the AV node), it is unlikely that the use of ranitidine is primarily responsible for the recurrent collapses in this lady.

References:

Camarri E, et al. Ranitidine induced bradycardia. *Lancet*. 1982;320:160.

Radhamanohar M. Syncope caused by ranitidine-induced

10:42

A 45-year-old smoker presents to the rapid access clinic with a 3-month history of chest pains on exertion. These have been increasing in frequency over the last 3 weeks. He has no past medical history and is on no medications. On arrival he has a blood pressure of 156/97 mmHg and a heart rate of 89/min. Examination reveals no abnormality. The resting electrocardiogram (ECG) shows normal sinus rhythm with no evidence of left ventricular hypertrophy.

Investigations:

Hb	13.6 g/dl
WCC	4.6×10^9/l
PLT	208×10^9/l
Na^+	138 mmol/l
K^+	4.9 mmol/l
Creatinine	83 µmol/l
Urea	5.1 mmol/l
Cholesterol	6.4 mmol/l
Glucose	4.8 mmol/l

Which one of the following is the most important intervention to perform next?

A Antihypertensive therapy with an ACE inhibitor

B Trial of GTN spray

C Initiation of statin therapy

D ETT

E CT coronary angiography

Rana Alnasser's screen

E CT coronary angiography

This patient has symptoms suggestive of ischaemic heart disease. In the context of risk factors for ischaemic heart disease (hypertension, hypercholesterolaemia, smoking), the clinical diagnosis should be confirmed in the first instance with CT coronary angiography and later with non-invasice functional imaging.. Any concomitant risk factors, such as hypertension or dyslipidaemia, should also be aggressively managed and he should be strongly encouraged to stop smoking.

A Antihypertensive therapy with an ACE inhibitor

While it is important to aggressively manage risk factors in this patient, and he should certainly be started on antihypertensive therapy, it would not aid in diagnosing the aetiology of his symptoms, and does not represent the *most* important next step.

B Trial of GTN spray

While it would prove prudent to provide a GTN spray for symptom control, doing so would not aid in the diagnosis of the underlying cause of the patient's symptoms and would not represent the *most* appropriate next step in his care.

C Initiation of statin therapy

While it is important to aggressively manage risk factors in this patient, and he would likely benefit from being started on started on statin therapy, it is not the *most* important next step.

D ETT

While it is important to aggressively manage risk factors in this patient, and he should certainly be started on antihypertensive therapy, it would not aid in diagnosing the aetiology of his symptoms, and does not represent the *most* important next step.

B Trial of GTN spray

While it would prove prudent to provide a GTN spray for symptom control, doing so would not aid in the diagnosis of the underlying cause of the patient's symptoms and would not represent the *most* appropriate next step in his care.

C Initiation of statin therapy

While it is important to aggressively manage risk factors in this patient, and he would likely benefit from being started on started on statin therapy, it is not the *most* important next step.

D ETT

According to current NICE guidance, exercise ECG is recommended as the initial test for establishing a diagnosis of stable coronary artery disease in patients with symptoms of angina and intermediate pre-test probability of coronary artery disease (15–65%), free of anti-ischaemic drugs, unless they cannot exercise or display ECG changes which make the ECG non-evaluable. However CT angiography is recommended as the initial test for diagnosing stable coronary artery disease if the pre test probability is between 66–85% or if LVEF is < 50% in patients without typical angina. The guidance is clear that stress imaging is recommended as the initial test option if local expertise and availability permit.

A 67-year-old gentleman is referred to the cardiology clinic by his General Practitioner for an abnormal heart sound. He had gone to see his GP for a general medical check-up. His past medical history is unremarkable and he is not on any medication.

On examination, he is comfortable at rest with a blood pressure of 145/65 mmHg, pulse of 66/min and regular. He has no pedal oedema and his jugular venous pressure is not raised. He has an early diastolic murmur best heard at the left sternal edge in expiration with the patient leaning forward. His chest is clinically clear.

The following results are obtained:

chest X-ray	normal
electrocardiogram (ECG)	sinus rhythm
Echocardiogram	LV enlargement seen. There is a mild to moderate aortic regurgitation
full blood count (FBC)	U&E, liver function tests (LFTs) and lipid profile are within normal range

How are you going to manage this man?

A Start him on a bisoprolol

B Start him on ramipril

C Start him on amlodipine

D Discharge him from the clinic

E Start him on aspirin

B Start him on ramipril

This asymptomatic man with aortic regurgitation should be started on an ACE inhibitor. The Studies Of Left Ventricular Dysfunction (SOLVD) trial did show that enalapril did improve the prognosis in asymptomatic left ventricular dysfunction. ACEI slowed the development of left ventricular dysfunction. This same trial also showed symptomatic improvement and prognosis in patients with symptomatic heart failure.

A Start him on a bisoprolol

As initial therapy, beta blockade was thought to prolong diastole and potentially worsen AR. This hasn't been borne out in clinical data, however, and larger trials are required. This places beta blockade as a second-line option for management of AR.

C Start him on amlodipine

Although amlodipine is effective as an anti-hypertensive, it may actually unmask symptoms of cardiac failure in AR because of tachycardia and peripheral vasodilatation.

D Discharge him from the clinic

This patient has established AR with signs of left ventricular failure, if he is discharged without medical intervention there is a risk of accelerating the worsening of her symptoms.

E Start him on aspirin

This patient has not had a previous ischaemic cardiovascular event, and it is possible that his AR is merely degenerative, hence aspirin is unlikely to significantly improve his outcome.

A 48-year-old African-Caribbean man underwent ambulatory blood pressure monitoring. His daytime average blood pressure was recorded as 155/96 mmHg. He is asymptomatic, his chest is clear, abdomen is soft and non-tender, and his BMI is 24. Ophthalmoscopy is entirely normal, and routine bloods including urea and creatinine are unremarkable.

Which of the following pharmacological treatments would be the most appropriate to initiate for him?

A Amlodipine

B None indicated

C Losartan

D Atenolol

E Doxazosin

6579

Submit

Previous Q... Skip Questi...

© Pastest 2019

10:48

A 48-year-old African-Caribbean man underwent ambulatory blood pressure monitoring. His daytime average blood pressure was recorded as 155/96 mmHg. He is asymptomatic, his chest is clear, abdomen is soft and non-tender, and his BMI is 24. Ophthalmoscopy is entirely normal, and routine bloods including urea and creatinine are unremarkable.

Which of the following pharmacological treatments would be the most appropriate to initiate for him?

Your answer was correct

A	Amlodipine
B	None indicated
C	Losartan
D	Atenolol
E	Doxazosin

Explanation

A Amlodipine

The current NICE clinical guideline for hypertension (CG127, see below) recommends calcium channel blockers as first-line antihypertensive treatment for patients at any age of African-Caribbean family origin.

B None indicated

10:48

MyPastest
https://mypastest.pastest.com

A Amlodipine

The current NICE clinical guideline for hypertension (CG127, see below) recommends calcium channel blockers as first-line antihypertensive treatment for patients at any age of African-Caribbean family origin.

B None indicated

The current NICE clinical guideline for hypertension (CG127) recommends initiating antihypertensive drug treatment for patients of any age with stage 2 hypertension. The stages of hypertension are:

Stage 1: Clinic BP is ≥140/90 mmHg and confirmed by subsequent ABPM daytime average ≥135/85 mmHg.

Stage 2: Clinic BP is ≥160/100 mmHg and confirmed by subsequent ABPM daytime average ≥150/95 mmHg.

Severe: Clinic systolic BP is ≥180 mmHg or clinic diastolic BP ≥110 mmHg.

C Losartan

The current NICE clinical guideline for hypertension (CG127) recommends that first-line antihypertensive treatment for patients at any age, and of African-Caribbean family origin, is calcium channel blockers. Angiotensin receptor blockers are first-line antihypertensive treatment for patients age <55 years from a non-African-Caribbean family background.

D Atenolol

The current NICE clinical guideline for hypertension (CG127) recommends that first-line antihypertensive treatment for patients at any age, and of African-Caribbean

receptor blockers are first-line antihypertensive treatment for patients age <55 years from a non-African-Caribbean family background.

D Atenolol

The current NICE clinical guideline for hypertension (CG127) recommends that first-line antihypertensive treatment for patients at any age, and of African-Caribbean family origin is calcium channel blockers. Beta-blockers are not preferred first-line antihypertensive treatments, because meta-analysis suggests they are associated with increased risk of impaired glucose tolerance.

E Doxazosin

The current NICE clinical guideline for hypertension (CG127) recommends that first-line antihypertensive treatment for patients at any age, and of African-Caribbean family origin is calcium channel blockers. Alpha-blockers such as doxazosin are reserved for patients with resistant hypertension. They may increase the risk of cardiac failure in some patients.

Rate this question:

Next Question

© Pastest 2019

An 82-year-old woman is being reviewed in the Neurology Clinic. She has some residual weakness in her left hand from an ischaemic stroke she sustained 3 months earlier. At the time, she refused admission to the hospital, having discharged herself after a head computed tomography (CT) scan. There are no symptoms of breathlessness, orthopnoea or paroxysmal nocturnal dyspnoea, and she has good exercise tolerance.

Her past medical history includes porcine aortic valve replacement 4 years earlier, hypertension and congestive heart failure.

Her medications include aspirin, started by her general practitioner after a transient ischaemic attack (TIA) affecting her right side 3 years ago, a beta-blocker, an angiotensin-converting enzyme (ACE) inhibitor and a statin.

Her resting electrocardiogram (ECG) shows sinus rhythm, and 72-h Holter monitoring shows no evidence of paroxysmal atrial fibrillation (AF).

What would be the most appropriate next step in her management?

A	Commence warfarin
B	Start dipyridamole
C	Change aspirin to clopidogrel
D	Increase the dose of aspirin to 300 mg once daily
E	CT head

(CT) scan. There are no symptoms of breathlessness, orthopnoea or paroxysmal nocturnal dyspnoea, and she has good exercise tolerance.

Her past medical history includes porcine aortic valve replacement 4 years earlier, hypertension and congestive heart failure.

Her medications include aspirin, started by her general practitioner after a transient ischaemic attack (TIA) affecting her right side 3 years ago, a beta-blocker, an angiotensin-converting enzyme (ACE) inhibitor and a statin.

Her resting electrocardiogram (ECG) shows sinus rhythm, and 72-h Holter monitoring shows no evidence of paroxysmal atrial fibrillation (AF).

What would be the most appropriate next step in her management?

Your answer was incorrect

A Commence warfarin

B Start dipyridamole

C Change aspirin to clopidogrel

D Increase the dose of aspirin to 300 mg once daily

E CT head

Explanation

C Change aspirin to clopidogrel

Guidance for antiplatelet therapy post-stroke or TIA has

C Change aspirin to clopidogrel

Guidance for antiplatelet therapy post-stroke or TIA has recently been simplified. The National Institute for Health and Care Excellence (NICE) guidelines state that, irrespective of whether the event is a stroke or TIA, clopidogrel is the optimal antiplatelet therapy. Clopidogrel is licensed for use in ischaemic stroke and is used off-licence in TIA.

Given this patient appears relatively fit, she should also be considered for further TIA investigation, including carotid Doppler to assess for carotid stenosis.

A Commence warfarin

This patient is in sinus rhythm, both clinically and on Holter monitoring, without symptoms of AF. This makes AF unlikely to have contributed to her stroke, and warfarin is not indicated. Patients with AF and paroxysmal AF should be assessed with the CHA2DS2-VASc and HASBLED scoring systems to assess the benefits and risks of anticoagulation, respectively. Porcine valves do not need anticoagulation.

B Start dipyridamole

Modified-release dipyridamole 200 mg twice daily may be used if both clopidogrel and aspirin are contraindicated or cannot be tolerated, but it is not a first-line agent in the absence of contraindications to these agents.

D Increase the dose of aspirin to 300 mg once daily

Clopidogrel 75 mg is the first-line agent recommended by NICE in secondary prevention of stroke and TIA. Aspirin 75 mg daily, with modified-release dipyridamole 200 mg twice daily, may be used if clopidogrel cannot be tolerated, but

absence of contraindications to these agents.

D Increase the dose of aspirin to 300 mg once daily

Clopidogrel 75 mg is the first-line agent recommended by NICE in secondary prevention of stroke and TIA. Aspirin 75 mg daily, with modified-release dipyridamole 200 mg twice daily, may be used if clopidogrel cannot be tolerated, but higher doses of aspirin do not feature in the guidelines. High-dose aspirin is indicated in acute stroke when bleeding has been excluded.

E CT head

We are told the patient underwent a CT head scan 3 months ago, and no new symptomatology has been described since that time. A repeat CT head scan would be unlikely to provide additional information and does not represent the most appropriate management option in this case. The role of CT in acute stroke is more to exclude a bleed, rather than to confirm a stroke. If there were doubt in the original diagnosis, then magnetic resonance imaging would have been a far more appropriate investigation.

Rate this question:

Previous Q... Tag Questi... Feedback End Session

Blog About Pastest Contact Us Help

© Pastest 2019

A 30-year-old lady who is 16 weeks' pregnant presents to her general practitioner (GP) complaining of palpitations. A resting electrocardiogram (ECG) is reported as partial right bundle branch block (RBBB) with right axis deviation. Clinical examination reveals a heaving precordium with fixed splitting of the first and second heart sounds and no added murmurs.

What is the most likely diagnosis?

A	Mitral valve prolapse
B	Primary pulmonary hypertension
C	Ostium secundum atrial septal defect (ASD)
D	Patent foramen ovale
E	Ostium primum atrial septal defect (ASD)

Submit

Previous Q... Skip Questi...

© Pastest 2019

A 30-year-old lady who is 16 weeks' pregnant presents to her general practitioner (GP) complaining of palpitations. A resting electrocardiogram (ECG) is reported as partial right bundle branch block (RBBB) with right axis deviation. Clinical examination reveals a heaving precordium with fixed splitting of the first and second heart sounds and no added murmurs.

What is the most likely diagnosis?

Your answer was incorrect

A	Mitral valve prolapse
B	Primary pulmonary hypertension
C	Ostium secundum atrial septal defect (ASD)
D	Patent foramen ovale
E	Ostium primum atrial septal defect (ASD)

Explanation

C Ostium secundum atrial septal defect (ASD)

The clinical and ECG findings are most consistent with this diagnosis. Atrial septal defects (ASDs) make up 30% of congenital heart disease detected in the adult population. The female:male ratio is 2:1, of which 75% are ostium secundum ASDs. These can present during pregnancy with either breathlessness or palpitations. The clinical findings depend on the degree of left-to-right shunt and its effects

C Ostium secundum atrial septal defect (ASD)

The clinical and ECG findings are most consistent with this diagnosis. Atrial septal defects (ASDs) make up 30% of congenital heart disease detected in the adult population. The female:male ratio is 2:1, of which 75% are ostium secundum ASDs. These can present during pregnancy with either breathlessness or palpitations. The clinical findings depend on the degree of left-to-right shunt and its effects on the right heart. In addition, ostium primum ASDs are associated with mitral valve abnormalities, and mitral regurgitation may be audible. The combination of right bundle branch block (RBBB) and right axis deviation on the electrocardiogram (ECG) makes an ostium secundum ASD more likely.

E Ostium primum atrial septal defect (ASD)

Ostium primum ASDs are associated with mitral valve abnormalities, and mitral regurgitation may be audible. The most common ECG findings are left axis deviation with RBBB.

A Mitral valve prolapse

The clinical signs described are not consistent with this diagnosis. Mitral valve prolapse is associated with dynamic mid-to-late systolic click, often followed by a late systolic mitral regurgitant murmur; it is not associated with RBBB.

B Primary pulmonary hypertension

The clinical signs described are not consistent with this diagnosis. Primary pulmonary hypertension is associated with episodes of exertional syncope and atrial fibrillation, and murmurs consistent with pulmonary or tricuspid regurgitation.

10:54
On
594-042-7551
Leave

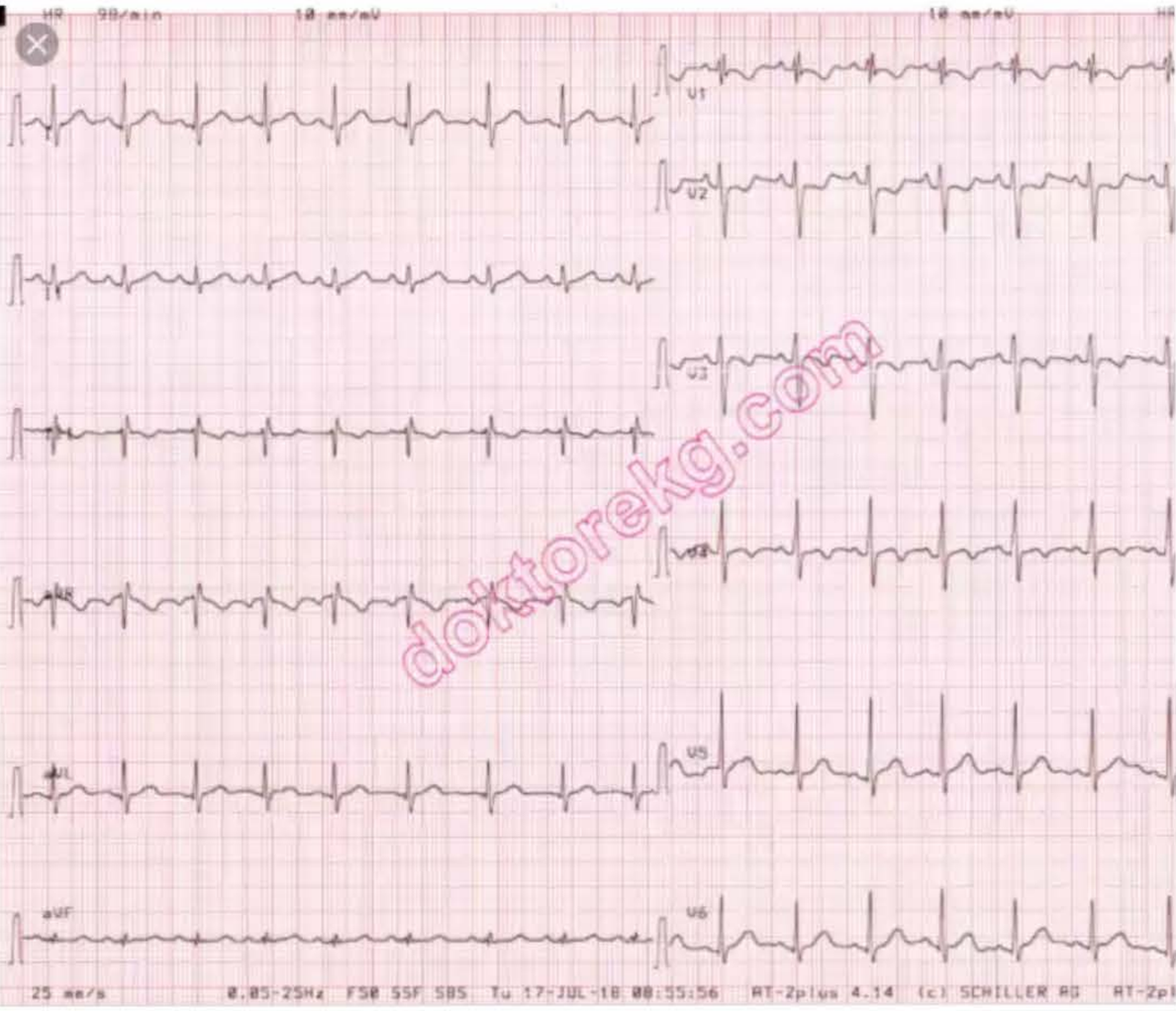

mete alpaslan

atrial septal defect (asd) - atriyal septal defekt - ekg - ecg ...

ECG 11. The ECG above is from a 6 years-old boy with a large (21 mm) ostium secundum type atrial septal defe

Images may be subject to copyright. Learn more

RELATED IMAGES

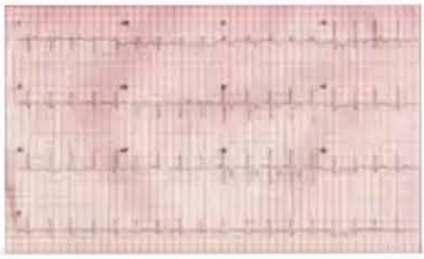

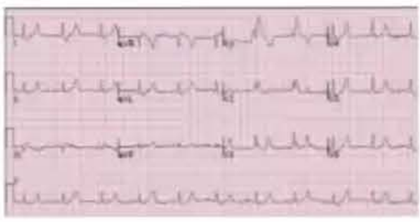

Dr. Smith's ECG Blog: Is This a Simple Right ...

Discover
Updates
Search
Recent
More

Audio
Video
Share
Participants
More

A Mitral valve prolapse

The clinical signs described are not consistent with this diagnosis. Mitral valve prolapse is associated with dynamic mid-to-late systolic click, often followed by a late systolic mitral regurgitant murmur; it is not associated with RBBB.

B Primary pulmonary hypertension

The clinical signs described are not consistent with this diagnosis. Primary pulmonary hypertension is associated with episodes of exertional syncope and atrial fibrillation, and murmurs consistent with pulmonary or tricuspid regurgitation.

D Patent foramen ovale

Approximately 25% of the population have a patent foramen ovale, but it is usually benign and does not cause any symptoms. Case reports suggest that the incidence of migraine is increased in patients with PFO.

Rate this question:

Next Question

© Pastest 2019

A 75-year-old male presents to the emergency department with history of sudden onset of chest pain that started 2 h ago. The pain is sharp, severe, radiates to the back and is associated with sweating. He is known to have had hypertension for past 8 years and is taking indapamide 1.5 mg/day. Physical examination reveals blood pressure of 95/75 mmHg, heart rate of 108/min and respiratory rate of 27/min. The pulse is low volume with collapsing character, the neck veins are distended, apex beat is difficult to appreciate and heart sounds are distant.

Investigations show:

Sodium	135 mmol/l
Potassium	4.5 mmol/l
Urea	8 mmol/l
Creatinine	70 µmol/l
Haemoglobin	14 g/dL
White cell count	10×10^9/L
Chest X-ray	Large cardiac silhouette and widened mediastinum
Electrocardiogram (ECG)	Sinus tachycardia and low voltage
An urgent transoesophageal echocardiography	Dissection of the ascending aorta and a moderate to large amount of blood in pericardium

What is the next best step in the management of this patient?

A Intravenous sodium nitroprusside

B Immediate surgery

Potassium	4.5 mmol/l
Urea	8 mmol/l
Creatinine	70 µmol/l
Haemoglobin	14 g/dL
White cell count	10 x 10^9/L
Chest X-ray	Large cardiac silhouette and widened mediastinum
Electrocardiogram (ECG)	Sinus tachycardia and low voltage
An urgent transoesophageal echocardiography	Dissection of the ascending aorta and a moderate to large amount of blood in pericardium

What is the next best step in the management of this patient?

A Intravenous sodium nitroprusside

B Immediate surgery

C Intravenous beta-blockers

D Intravenous hydralazine

E Pericardiocentesis

Submit

Rana Alnasser's screen

10:58
On 594-042-7551 Leave

B Immediate surgery

Aortic dissection is classified as type A if it involves the ascending aorta regardless of the site of primary tear and type B if it does not. This patient has acute type A aortic dissection complicated by haemopericardium and cardiac tamponade. Pericardiocentesis in these patients can increase the intra-aortic pressure and reopen the closed communication between false lumen and pericardium. This can lead to recurrent cardiac tamponade that may be lethal. Therefore, if these patients are relatively stable, they should have immediate surgical repair and surgical evacuation of haemopericardium.

A Intravenous sodium nitroprusside

Because this patient has type A aortic dissection with complication of haemopericardium and cardiac tamponade, treating medically would be inappropriate.

C Intravenous beta-blockers

Because this patient has type A aortic dissection with complication of haemopericardium and cardiac tamponade, treating medically would be inappropriate.

D Intravenous hydralazine

Because this patient has type A aortic dissection with complication of haemopericardium and cardiac tamponade, treating medically would be inappropriate.

E Pericardiocentesis

Only if patients with pericardial effusion from aortic dissection have marked hypotension or electromechanical dissociation, then pericardiocentesis should be performed.

Audio Video Share Participants More

10:59

A 65-year-old woman is brought to the Emergency Department after suffering a collapse in church around 1 h earlier. She is conscious but complains of central chest pain. There is a past history of hypertension for which she takes ramipril 10 mg daily, and a previous myocardial infarction some 2 years earlier. On examination her blood pressure is 90/60 mmHg, her pulse is 150–200 beats per minute. She has bi-basal crackles on auscultation of the chest.

Investigations:

K^+	5.4 mmol/l
Na^+	139 mmol/l
Creatinine	150 micromol/l
Urea	8.1 mmol/l
Hb	12.1 g/dl

His ECG is shown below.

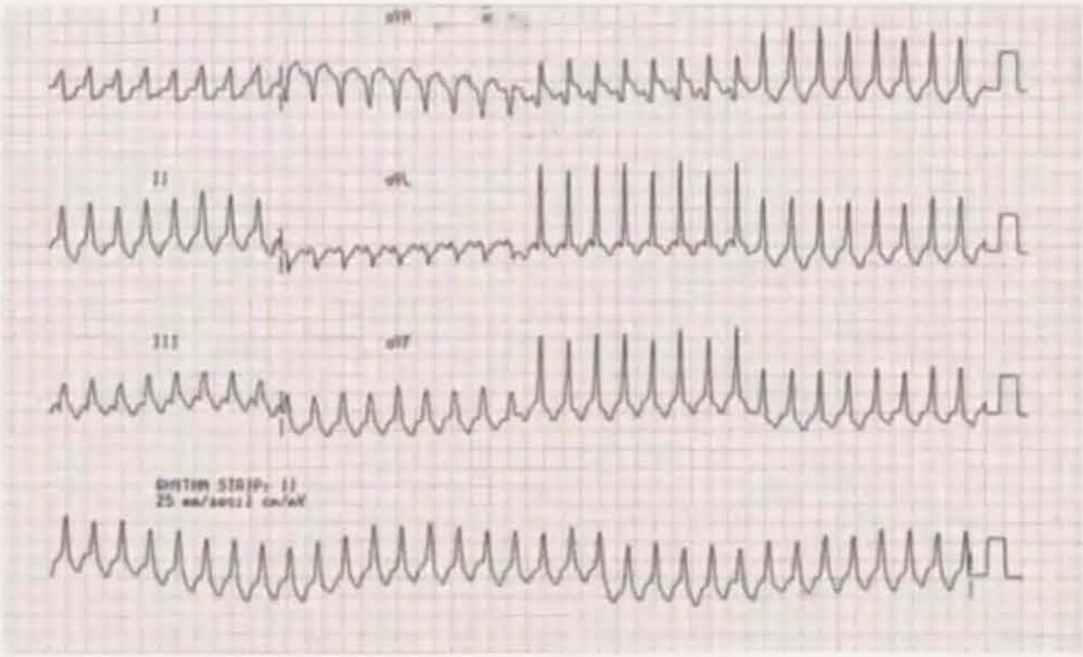

Which of the following is the most appropriate management option?

A. Load with IV amiodarone

Rana Alnasser's screen

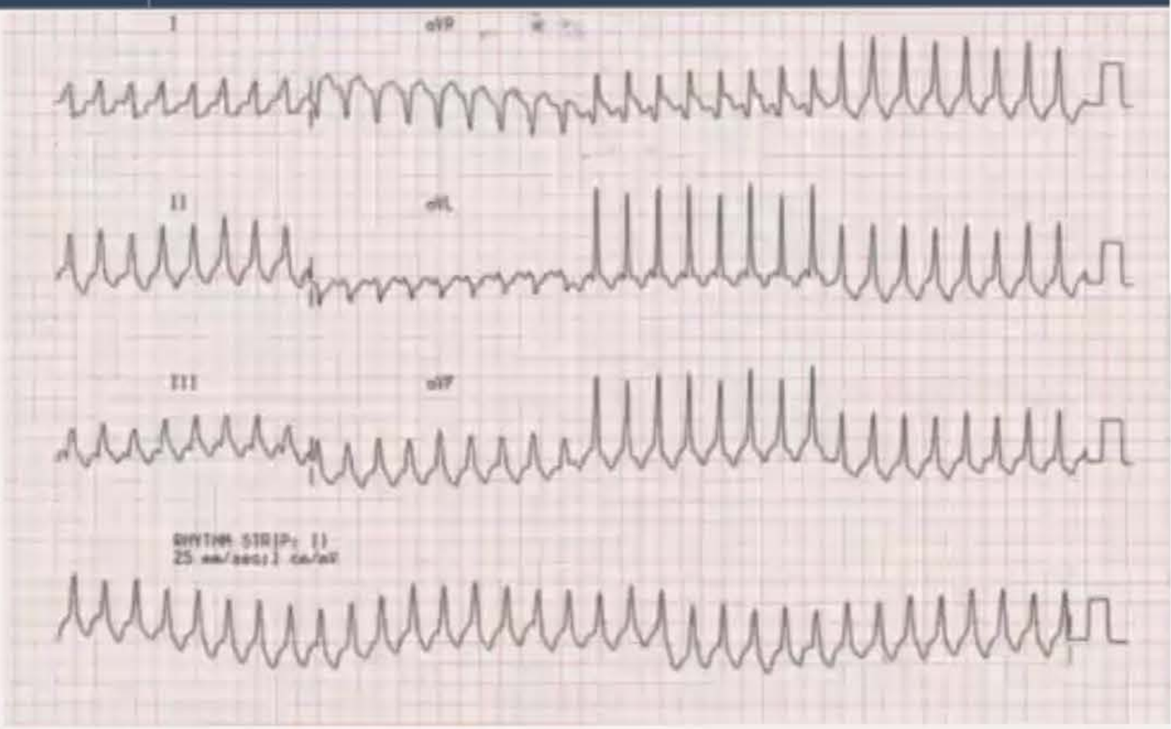

Which of the following is the most appropriate management option?

A Load with IV amiodarone

B Load with IV flecainide

C IV adenosine bolus

D DC synchronised cardioversion

E Carotid sinus massage

Submit

Previous Q... Skip Questi...

Rana Alnasser's screen

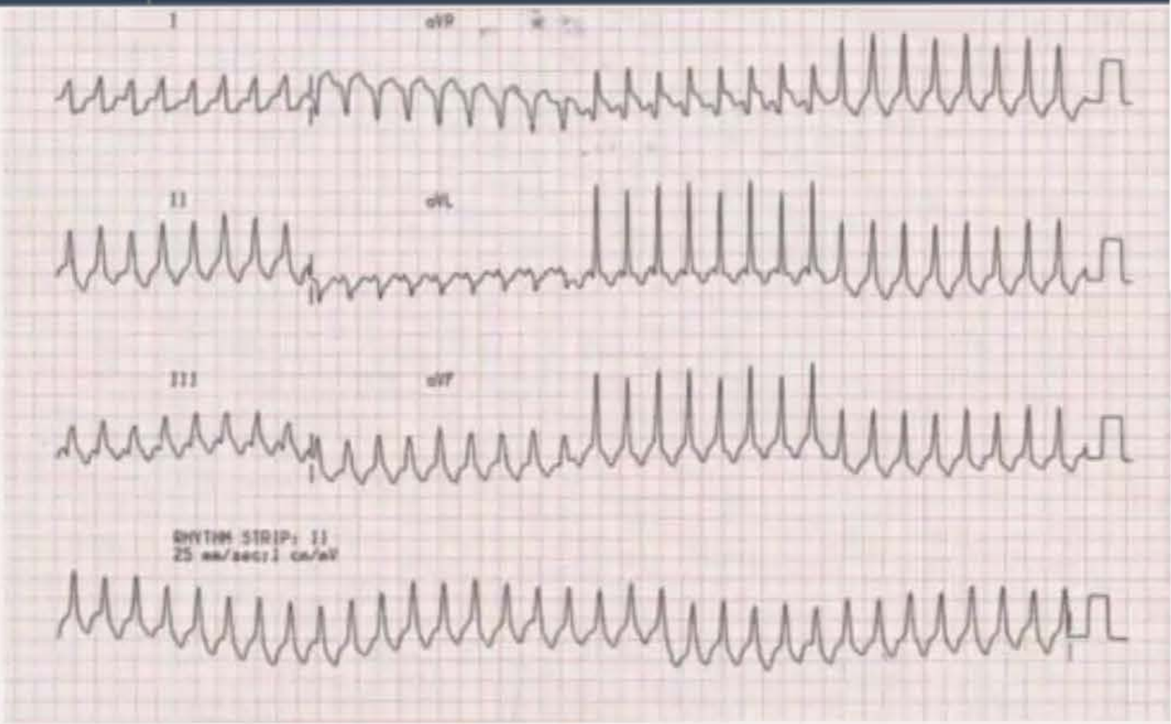

Which of the following is the most appropriate management option?

Your answer was correct

A	Load with IV amiodarone
B	Load with IV flecainide
C	IV adenosine bolus
D	DC synchronised cardioversion
E	Carotid sinus massage

Explanation

D DC synchronised cardioversion

This woman has chest pain and a significant fall in her blood pressure. Resuscitation Council guidelines for the management of tachyarrhythmias state that in the presenc

Rana Alnasser's screen

D DC synchronised cardioversion

This woman has chest pain and a significant fall in her blood pressure. Resuscitation Council guidelines for the management of tachy-arrythmias state that in the presenc of adverse features – shock, syncope, myocardial ischaemia, heart failure – treatment is with synchronised DC shock (up to 3 attempts) followed by amiodarone and further attempt at DC cardioversion if this is unsuccessful.

A Load with IV amiodarone

While it may produce cardioversion, amiodarone ideally should be given through a large central vein and can take time to effect a benefit. As this patient is haemodynamically unstable, urgent DC cardioversion represents the management of choice.

B Load with IV flecainide

Flecainide is contraindicated in patients with a history of structural heart disease or coronary artery disease; the results of the CAST trial showed increased mortality in patients treated with encainide or flecainide following recent MI.

C IV adenosine bolus

While IV adenosine may slow her ventricular rate temporarily, and reveal the underlying rhythm, it would be unlikely to achieve cardioversion. She is haemodynamically unstable and requires urgent DC cardioversion.

E Carotid sinus massage

While carotid sinus massage may slow her ventricular rate temporarily, and reveal the underlying rhythm, it would be unlikely to achieve cardioversion. She is haemodynamically

A 55-year-old man had an infero-lateral myocardial infarction a year ago. Since then, he had been fine and was discharged from your care until a month ago, when he started suffering from chest pains again.

The chest pains continued to worsen despite increasing his anti-angina medication, and he underwent coronary angioplasty with stenting of his right coronary artery. He has come to see you in the Cardiology Clinic for review of his symptoms and therapy.

Which one of the following medications should he be taking to provide a proven mortality benefit?

A	Amlodipine
B	Flecainide
C	Nitrates
D	Clopidogrel
E	Nicorandil

Submit

A 55-year-old man had an infero-lateral myocardial infarction a year ago. Since then, he had been fine and was discharged from your care until a month ago, when he started suffering from chest pains again.

The chest pains continued to worsen despite increasing his anti-angina medication, and he underwent coronary angioplasty with stenting of his right coronary artery. He has come to see you in the Cardiology Clinic for review of his symptoms and therapy.

Which one of the following medications should he be taking to provide a proven mortality benefit?

Your answer was correct

A	Amlodipine
B	Flecainide
C	Nitrates
D	Clopidogrel
E	Nicorandil

Explanation

D	Clopidogrel

The Second International Study of Infarct Survival (ISIS-2) showed that aspirin and streptokinase, or both, improved survival outcomes in patients with myocardial infarction. The First International Study of Infarct Survival (ISIS-1)

Rana Alnasser's screen

D Clopidogrel

The Second International Study of Infarct Survival (ISIS-2) showed that aspirin and streptokinase, or both, improved survival outcomes in patients with myocardial infarction. The First International Study of Infarct Survival (ISIS-1) revealed an improved survival in a randomised trial of intravenous atenolol among 16,027 cases of suspected acute myocardial infarction. The CAPRIE trial was a randomised, blinded trial of clopidogrel versus aspirin in patients at risk of ischaemic events; it demonstrated an 8.7% relative risk reduction with respect to ischaemic events versus aspirin. The Scandinavian Simvastatin Survival Study (4S) was a randomised trial of cholesterol lowering in 4444 patients with coronary artery disease. Among other drugs that do not improve prognosis include magnesium and anti-arrhythmics such as propafenone and flecainide.

A Amlodipine

While verapamil has been shown to provide mortality benefit in the chronic phase following STEMI (and is recommended for those with contraindication to beta-blocker therapy), routine use of dihydropyridines has failed to show benefit and they should therefore only be prescribed for clear additional indications, such as hypertension or residual angina.

B Flecainide

Flecainide has not been proven to provide a mortality benefit in the context of ischaemic heart disease.

C Nitrates

The ISIS-4 trial demonstrated no mortality benefit from nitrates in the setting of STEMI.

A 28-year-old male presents with two days' history of high grade fever. He has no other symptoms. He has had insulin dependent diabetes mellitus for the last 10 years which is well controlled on twice daily intermediate-acting insulin. Physical examination reveals a sick-looking young male with a temperature of 39.5°C, blood pressure 150/70 mmHg, pulse rate 98/min and respiratory rate of 22/min. Examination of the skin, chest, abdomen, cardiovascular and central nervous system is non-contributory.

Investigations:

Hb	13.1 g/dl
WCC	14×10^9/l
PLT	452×10^9/l
Na+	132 mmol/l (135-145)
K+	4.1 mmol/l (3.5-5.0)
Creatinine	100 µmol/l (18-106)
Chloride	92 mmol/l (97–110 mmol/l)
Bicarbonate	26 mmol/l (22–28mmol/l)
Urine dipstick	Normal
Urine dipstick	Normal
ECG	Normal
CXR	Normal
Blood culture	Preliminary report shows Gram-positive cocci in clusters in both aerobic and anaerobic bottles

Which of the following is the investigation most likely to confirm the diagnosis in this patient?

K+	4.1 mmol/l (3.5-5.0)
Creatinine	100 µmol/l (18-106)
Chloride	92 mmol/l (97–110 mmol/l)
Bicarbonate	26 mmol/l (22–28mmol/l)
Urine dipstick	Normal
Urine dipstick	Normal
ECG	Normal
CXR	Normal
Blood culture	Preliminary report shows Gram-positive cocci in clusters in both aerobic and anaerobic bottles

Which of the following is the investigation most likely to confirm the diagnosis in this patient?

A Upper GI endoscopy

B Lumbar puncture

C Abdominal ultrasound scan

D CT abdomen

E Trans-oesophageal echocardiogram (TOE)

Submit

dipstick	Normal
ECG	Normal
CXR	Normal
Blood culture	Preliminary report shows Gram-positive cocci in clusters in both aerobic and anaerobic bottles

Which of the following is the investigation most likely to confirm the diagnosis in this patient?

Your answer was correct

A Upper GI endoscopy

B Lumbar puncture

C Abdominal ultrasound scan

D CT abdomen

E Trans-oesophageal echocardiogram (TOE)

Explanation

E Trans-oesophageal echocardiogram (TOE)

This patient has community-acquired staphylococcal bacteraemia. Up to 20% of these patients may have infective endocarditis without any clinical stigmata of infective endocarditis. TOE is more sensitive than transthoracic (TTE), is widely available and is the investigation of choice versus TTE in those patients who are able to tolerate the procedure. The antimicrobial therapy of choice is IV flucloxacillin coupled with IV

E Trans-oesophageal echocardiogram (TOE)

This patient has community-acquired staphylococcal bacteraemia. Up to 20% of these patients may have infective endocarditis without any clinical stigmata of infective endocarditis. TOE is more sensitive than transthoracic (TTE), is widely available and is the investigation of choice versus TTE in those patients who are able to tolerate the procedure. The antimicrobial therapy of choice is IV flucloxacillin coupled with IV gentamicin, unless the isolate is found to be methicillin resistant.

A Upper GI endoscopy

Streptococcus gallolyticus is a cause of endocarditis in patients with underlying colon cancer or infection of the biliary tree. If either of these is suspected then ERCP or colonoscopy is a potentially more appropriate investigation. In the absence of any GI symptoms it wouldn't be suspected as the underlying cause of his presentation.

B Lumbar puncture

The lack of headache or symptoms of meningism counts against CNS infection as the cause of this patient's symptoms.

C Abdominal ultrasound scan

Abdominal ultrasound scan is a relatively insensitive method to confirm a source for any infection, given there are no symptoms of biliary tract or urinary infection.

D CT abdomen

infective endocarditis. TOE is more sensitive than transthoracic (TTE), is widely available and is the investigation of choice versus TTE in those patients who are able to tolerate the procedure. The antimicrobial therapy of choice is IV flucloxacillin coupled with IV gentamicin, unless the isolate is found to be methicillin resistant.

A Upper GI endoscopy

Streptococcus gallolyticus is a cause of endocarditis in patients with underlying colon cancer or infection of the biliary tree. If either of these is suspected then ERCP or colonoscopy is a potentially more appropriate investigation. In the absence of any GI symptoms it wouldn't be suspected as the underlying cause of his presentation.

B Lumbar puncture

The lack of headache or symptoms of meningism counts against CNS infection as the cause of this patient's symptoms.

C Abdominal ultrasound scan

Abdominal ultrasound scan is a relatively insensitive method to confirm a source for any infection, given there are no symptoms of biliary tract or urinary infection.

D CT abdomen

CT abdomen is most useful in identifying an intra-abdominal abscess, active diverticular disease or other conditions such as ischaemic bowel as causes of this patient's acute presentation, none of which are suspected here.

A 19-year-old man presents to the Emergency Department of a small district general hospital in the early hours of the morning, complaining of severe epigastric and retrosternal pain. He gives a history of a pyrexial illness over the preceding few days, which he thought was 'the flu'. He has not been able to sleep as he finds lying down extremely uncomfortable.

On examination he is pyrexial at 38°C, with a blood pressure of 135/85 mmHg and a heart rate of 90 beats/min Saturations are 100% on room air. There is a friction rub heard over the precordium and the chest is clear on auscultation.

Investigations:

Hb	13.1 g/dl
WCC	11.6×10^9/l
PLT	253×10^9/l
Na^+	138 mmol/l
K^+	4.7 mmol/l
Creatinine	79 µmol/l
Urea	4.0 mmol/l
ESR	60 mm/h
CK	250 U/l (25–195 U/l)

His electrocardiogram (ECG) shows widespread ST elevation.

Which of the following would be the most appropriate next step in this patient's care?

A	Ibuprofen 800 mg
B	Thrombolytic therapy with tissue plasminogen activator

WCC	11.6×10^9/l
PLT	253×10^9/l
Na^+	138 mmol/l
K^+	4.7 mmol/l
Creatinine	79 µmol/l
Urea	4.0 mmol/l
ESR	60 mm/h
CK	250 U/l (25–195 U/l)

His electrocardiogram (ECG) shows widespread ST elevation.

Which of the following would be the most appropriate next step in this patient's care?

A	Ibuprofen 800 mg
B	Thrombolytic therapy with tissue plasminogen activator
C	Blood cultures and intravenous blind antibiotic treatment pending results
D	Urgent referral to the on-call cardiologist for echocardiogram
E	Urgent computerised tomography (CT) pulmonary angiogram

Submit

Explanation

A	Ibuprofen 800 mg

The clinical features presented here are suggestive of pericarditis, which often occurs with an antecedent viral illness. The pain is reported as positional, and auscultation reveals a pericardial rub (often described as the sound of walking on fresh snow). Ibuprofen is the first-line therapy for pericarditis and acts to reduce the pericardial inflammation.

B	Thrombolytic therapy with tissue plasminogen activator

The widespread ECG changes may initially raise a concern of ischaemic heart disease. However, the young age and the fact that the ST-segment changes are not limited to a specific coronary artery territory point away from this diagnosis.

C	Blood cultures and intravenous blind antibiotic treatment pending results

The clinical picture of fever with a raised white cell count should always raise the suspicion of developing sepsis in this patient. However, the remainder of the clinical picture does not support profound sepsis and highlights pericarditis as a likely diagnosis. The majority of pericarditis in the UK is caused by a viral infection and, as such, antibiotics will not alter the disease progression.

D	Urgent referral to the on-call cardiologist for echocardiogram

This patient does not have significant features of myocarditis (which can develop in conjunction with

A 35-year-old African-Caribbean male presents to his general practitioner (GP) with a history of palpitations. These occur randomly at rest but there have been episode of fast palpitations on exertion associated with dizzy spells He has had one episode of collapse after a game of squash On examination there is a prominent apical impulse. A systolic murmur is heard over the left sternal edge on auscultation of the heart and the chest is clear. An echo reveals septal hypertrophy with a left ventricular outflow gradient of 55 mmHg, consistent with hypertrophic obstructive cardiomyopathy. A 72 h Holter monitor reveals episodes of non-sustained ventricular tachycardia.

Which of the following is most appropriate for managing his rhythm disturbance?

A	Metoprolol
B	Verapamil
C	Digoxin
D	Amiodarone
E	Implantable cardioverter defibrillator

32549

Submit

A 35-year-old African-Caribbean male presents to his general practitioner (GP) with a history of palpitations. These occur randomly at rest but there have been episode of fast palpitations on exertion associated with dizzy spells He has had one episode of collapse after a game of squash On examination there is a prominent apical impulse. A systolic murmur is heard over the left sternal edge on auscultation of the heart and the chest is clear. An echo reveals septal hypertrophy with a left ventricular outflow gradient of 55 mmHg, consistent with hypertrophic obstructive cardiomyopathy. A 72 h Holter monitor reveals episodes of non-sustained ventricular tachycardia.

Which of the following is most appropriate for managing his rhythm disturbance?

Your answer was correct

A	Metoprolol
B	Verapamil
C	Digoxin
D	Amiodarone
E	Implantable cardioverter defibrillator

Explanation

E	Implantable cardioverter defibrillator

This man has already suffered one episode of syncope, and has documented non-sustained VT on his 72 h Holter monitor. In the context of HOCM, he is at significant risk of sudden cardiac death related to VT, with an odds ratio of

E Implantable cardioverter defibrillator

This man has already suffered one episode of syncope, and has documented non-sustained VT on his 72 h Holter monitor. In the context of HOCM, he is at significant risk of sudden cardiac death related to VT, with an odds ratio of 4.35, and as such an implantable cardioverter defibrillator is the management of choice. Small studies in those with HOCM and VT show that ICDs have a positive impact on reducing the risk of sudden death.

A Metoprolol

There are no randomised, controlled data to support the use of anti-arrhythmics for the prevention of SCD in HCM. Beta-blockers and/or amiodarone are recommended in patients with an ICD and who continue to have symptomatic ventricular arrhythmias or recurrent shocks despite optimal treatment and device reprogramming.

B Verapamil

There are no randomised, controlled data to support the use of anti-arrhythmics for the prevention of SCD in HCM. It is recommended (class IC) for controlling ventricular rate in patients with permanent or paroxysmal AF (beta-blockers or diltiazem represent alternative options for this indication).

C Digoxin

There are no randomised, controlled data to support the use of anti-arrhythmics for the prevention of SCD in HCM. ESC guidelines state that digoxin should be avoided in patients with LVOTO, such as in this case ('By convention, LVOTO is defined as a peak instantaneous Doppler LV outflow tract gradient of ≥30 mm Hg, but the threshold for invasive treatment is usually considered to be ≥50 mm Hg'

in patients with permanent or paroxysmal AF (beta-blockers or diltiazem represent alternative options for this indication).

C Digoxin

There are no randomised, controlled data to support the use of anti-arrhythmics for the prevention of SCD in HCM. ESC guidelines state that digoxin should be avoided in patients with LVOTO, such as in this case ('By convention, LVOTO is defined as a peak instantaneous Doppler LV outflow tract gradient of ≥30 mm Hg, but the threshold for invasive treatment is usually considered to be ≥50 mm Hg') because of its positive inotropic effects. Low-dose digoxin may be considered for patients without LVOTO who are in NYHA functional class II–IV and have an EF <50% and permanent atrial fibrillation to control heart rate response, but it is not recommended in those with a preserved LV.

D Amiodarone

If the patient were to refuse an ICD, amiodarone would be the most appropriate anti-arrhythmic choice, but it is a less suitable management option than ICD implantation. Amiodarone was associated with a lower incidence of SCD in one small observational study of patients with NSVT on Holter monitoring while in others it increased the threshold for VF, but observational data suggest that amiodarone often fails to prevent SCD.

Rate this question:

A 78-year-old man has just driven his wife to the hospital for a blood test when he suddenly collapses to the ground There was no chest pain.

On questioning, he gives a history of previous collapses in the last 5 years with no predisposing factors. He gives a history of diet-controlled type 2 diabetes, and takes no regular medication.

An electrocardiogram (ECG) performed in Accident and Emergency shows RBBB, with left posterior fascicular block. The PR interval is 205 ms. You are asked to see him.

What is the most appropriate management plan?

A	Monitor overnight and discharge in the morning if he has no further episodes
B	Monitor overnight and then arrange elective permanent pacemaker insertion
C	If his blood sugar is normal, reassure and discharge home
D	Treat as NSTEMI
E	Refer to neurology for inpatient review

Submit

A 78-year-old man has just driven his wife to the hospital for a blood test when he suddenly collapses to the ground There was no chest pain.

On questioning, he gives a history of previous collapses in the last 5 years with no predisposing factors. He gives a history of diet-controlled type 2 diabetes, and takes no regular medication.

An electrocardiogram (ECG) performed in Accident and Emergency shows RBBB, with left posterior fascicular block. The PR interval is 205 ms. You are asked to see him.

What is the most appropriate management plan?

Your answer was correct

A	Monitor overnight and discharge in the morning if he has no further episodes
B	Monitor overnight and then arrange elective permanent pacemaker insertion
C	If his blood sugar is normal, reassure and discharge home
D	Treat as NSTEMI
E	Refer to neurology for inpatient review

Explanation

B	Monitor overnight and then arrange elective permanent pacemaker insertion

Given that his ECG is suggestive of possible episodes of complete heart block because of the RBBB and left

B Monitor overnight and then arrange elective permanent pacemaker insertion

Given that his ECG is suggestive of possible episodes of complete heart block because of the RBBB and left posterior fascicular block, and prolonged PR interval, it is likely that his episode of collapse represents a period of complete heart block. He could therefore be listed for permanent pacemaker and told not to drive until the procedure is done.

A Monitor overnight and discharge in the morning if he has no further episodes

This patient's symptoms and ECG are suggestive of episodic complete heart block. Discharge from follow-up without intervention would be inappropriate.

C If his blood sugar is normal, reassure and discharge home

His symptoms and ECG changes are suggestive of a cardiac aetiology, not hypoglycaemic episodes.

D Treat as NSTEMI

We are not given a history of cardiac chest pain, or dynamic ECG changes suggestive of cardiac ischaemia. Complete heart block is a more likely explanation for this patient's presentation than ACS.

E Refer to neurology for inpatient review

This patient's symptoms and ECG are suggestive of a cardiac, rather than neurological, pathology.

A 69-year-old man presented to the Emergency Department with central chest pain. The pains started when he was walking uphill from the park to his house. The pains were very severe and radiated to his neck, jaw and left arm. The severe pains lasted for about an hour and this was 12 h ago. He had never experienced such severe pains before and thought he was going to die. He still has some residual dull chest ache. He felt nauseated but did not vomit. In the past, he occasionally had some chest tightness that came on with strenuous exertion and he had managed very well by avoiding activities that brought the pain on. He is not on any medication.

On examination, he is alert, distressed, his blood pressure is 106/60 mmHg and pulse 51/min regular. First and second heart sounds are heard and there are no murmurs. His chest is clinically clear.

Investigations:

Hb	16.1 g/dl
WCC	13.2×10^9/l
PLT	256×10^9/l
Na+	136 mmol/l
K+	4.2 mmol/l
Creatinine	132 µmol/l
MCV	82 fl
Urea	7.4 mmol/l
Hs-troponin	2× upper limit of normal
ECG	Normal sinus rhythm with ST depression of 1 mm in leads II, III and aVF
CXR	Unremarkable
O_2	95% on air

Na+	136 mmol/l
K+	4.2 mmol/l
Creatinine	132 µmol/l
MCV	82 fl
Urea	7.4 mmol/l
Hs-troponin	2× upper limit of normal
ECG	Normal sinus rhythm with ST depression of 1 mm in leads II, III and aVF
CXR	Unremarkable
O_2 saturation	95% on air

Which of the following is the most appropriate treatment?

A	Beta blockade and early outpatient angiography
B	Clopidogrel, aspirin, low molecular weight heparin and inpatient stress-test
C	Clopidogrel, aspirin, low molecular weight heparin and Inpatient angiography
D	Beta blockade and oral nitrate
E	Aspirin, low-molecular weight heparin and tirofiban

troponin	2× upper limit of normal
ECG	Normal sinus rhythm with ST depression of 1 mm in leads II, III and aVF
CXR	Unremarkable
O_2 saturation	95% on air

Which of the following is the most appropriate treatment?

Your answer was correct

A Beta blockade and early outpatient angiography

B Clopidogrel, aspirin, low molecular weight heparin and inpatient stress-test

C Clopidogrel, aspirin, low molecular weight heparin and Inpatient angiography

D Beta blockade and oral nitrate

E Aspirin, low-molecular weight heparin and tirofiban

Explanation

C Clopidogrel, aspirin, low molecular weight heparin and Inpatient angiography

This gentleman is high risk; his symptoms, ECG changes and investigations are consistent with an NSTEMI. In this case he may well be considered for inpatient angiography.

C Clopidogrel, aspirin, low molecular weight heparin and Inpatient angiography

This gentleman is high risk; his symptoms, ECG changes and investigations are consistent with an NSTEMI. In this case he may well be considered for inpatient angiography. High-dose clopidogrel and aspirin are now the treatments of choice in conjunction with fondaparinux.

A Beta blockade and early outpatient angiography

This patient is at very high risk of a STEMI, and thus beta blockade alone and outpatient angiography is inappropriate.

B Clopidogrel, aspirin, low molecular weight heparin and inpatient stress-test

Stress testing is discouraged according to NICE guidance, as it may either precipitate ischaemia or generate a false-negative result.

D Beta blockade and oral nitrate

Although beta blockade will have positive effects on reducing myocardial oxygen demand, the risk of STEMI in the short term will remain significant.

E Aspirin, low-molecular weight heparin and tirofiban

The use of IIbIIIa inhibitors has been largely superseded by high-dose clopidogrel and aspirin in conjunction with fondaparinux.

Rate this question:

A 47-year-old woman is referred for an opinion with atrial fibrillation. She has suffered increasing tiredness over the past few months, consulted her GP and was noted to be in AF. On examination she has a small-volume pulse, distended jugular veins, left parasternal lift, a tapping apex impulse and there is a loud first heart sound and a mitral early- to mid-diastolic murmur. There also appears to be a mid-diastolic tricuspid murmur.

What diagnosis fits with this clinical picture?

A	Mitral stenosis
B	Atrial septal defect
C	Tricuspid regurgitation
D	Lutembacher syndrome
E	Eisenmenger's syndrome

Submit

Previous Q... Skip Questi...

© Pastest 2019

11:18

A 47-year-old woman is referred for an opinion with atrial fibrillation. She has suffered increasing tiredness over the past few months, consulted her GP and was noted to be in AF. On examination she has a small-volume pulse, distended jugular veins, left parasternal lift, a tapping apex impulse and there is a loud first heart sound and a mitral early- to mid-diastolic murmur. There also appears to be a mid-diastolic tricuspid murmur.

What diagnosis fits with this clinical picture?

Your answer was incorrect

A	Mitral stenosis
B	Atrial septal defect
C	Tricuspid regurgitation
D	Lutembacher syndrome
E	Eisenmenger's syndrome

Explanation

D	Lutembacher syndrome

This was first described in 1916 by Lutembacher, and is a syndrome characterised by both mitral stenosis and atrial septal defect (ASD). Both conditions may be congenital

D Lutembacher syndrome

This was first described in 1916 by Lutembacher, and is a syndrome characterised by both mitral stenosis and atrial septal defect (ASD). Both conditions may be congenital and occur concurrently, or the mitral stenosis may occur as a result of rheumatic fever or some other cause. The incidence of Lutembacher syndrome is higher in women due to the greater incidence of congenital ASD. Cardiac signs are mixed due to the two concurrent lesions. Presentation is typically in later life, with fatigue or atrial fibrillation. Ideally, surgery should be performed as early as possible due to the risks of Eisenmenger syndrome in untreated patients.

A Mitral stenosis

The mid-diastolic tricuspid murmur fits with increased tricuspid valve flow, consistent with a shunt because of an ASD, and hence isolated mitral stenosis is ruled out here.

B Atrial septal defect

An isolated ASD is ruled out because of the presence of the mitral murmur here.

C Tricuspid regurgitation

The presence of the mitral murmur makes Lutembacher syndrome with increased tricuspid flow a much more likely diagnosis than isolated tricuspid regurgitation.

E Eisenmenger's syndrome

Eisenmenger syndrome leads to cyanotic heart disease because of reversal of a long-standing left-to-right shunt to a right-to-left cardiac shunt.

11:19
On 594-042-7551 Leave

A 50-year-old man with a history of hypertension presents to the Emergency Department with central chest pain which came on while he was playing squash and lasted for approximately 35 minutes. He had one previous episode 3 months earlier while using a cross trainer at the gym, he did not seek medical advice. His only current medication is atenolol 50mg PO daily.

His ECG is shown below;

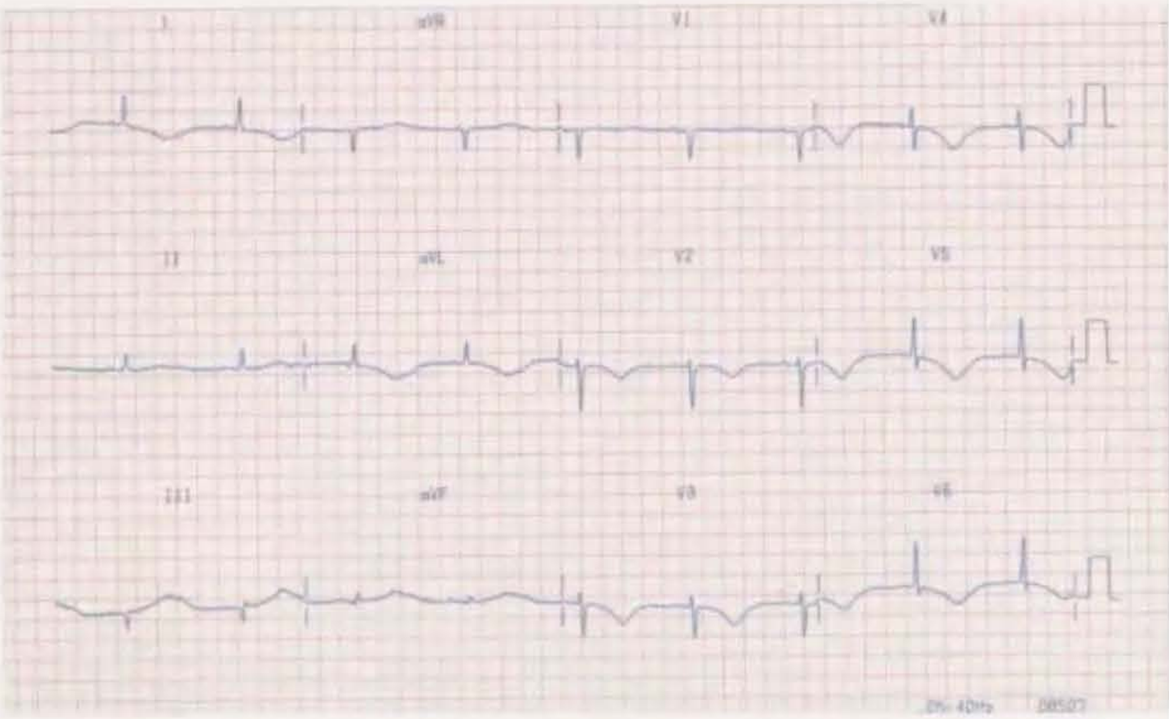

He is admitted and managed with subcutaneous fondaparinux, aspirin and ticragrelor. BP on admission is 90/70 mmHg, pulse is 65/min and regular. Creatinine is 132 micromol/l. There is no further chest pain and his T-wave inversion appears to be partially resolved, but a 12 h troponin is raised at 3.5 µg/l.

Which of the following represents the optimal management in this case?

A Inpatient limited exercise test

B Plan routine angiography within 3 months

Audio Video Share Participants More

11:21

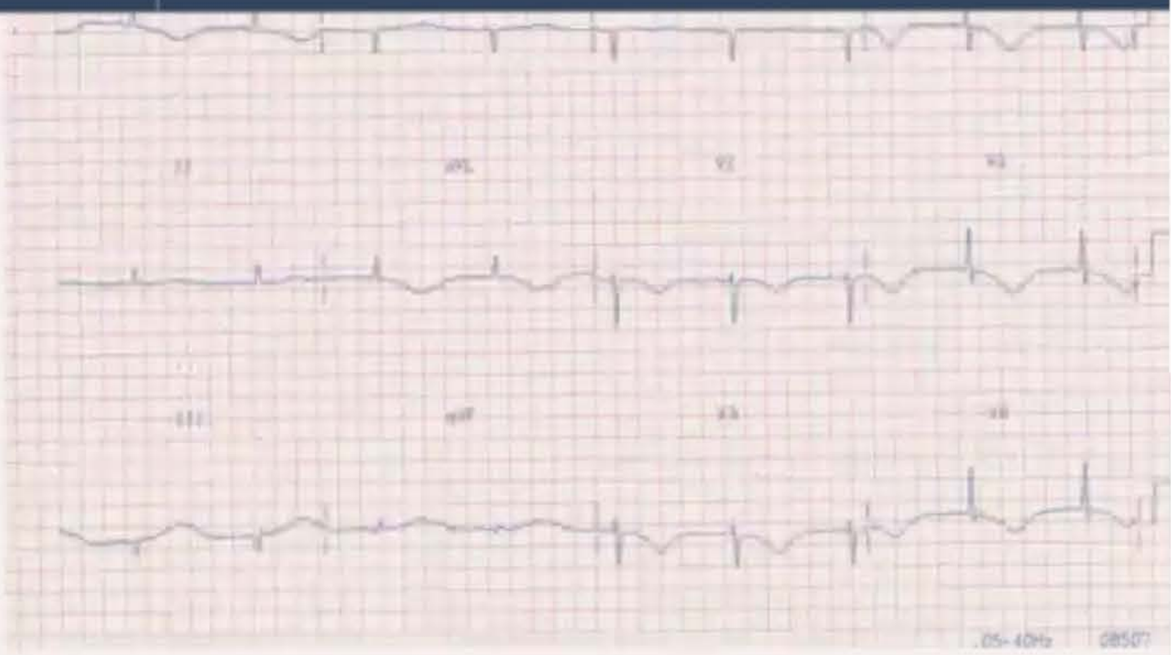

He is admitted and managed with subcutaneous fondaparinux, aspirin and ticragrelor. BP on admission i 90/70 mmHg, pulse is 65/min and regular. Creatinine is micromol/l. There is no further chest pain and his T-wav inversion appears to be partially resolved, but a 12 h troponin is raised at 3.5 µg/l.

Which of the following represents the optimal management in this case?

A	Inpatient limited exercise test
B	Plan routine angiography within 3 months
C	Plan for urgent angiography
D	Treat with streptokinase
E	Treat with TPA

Submit

4G 11:22

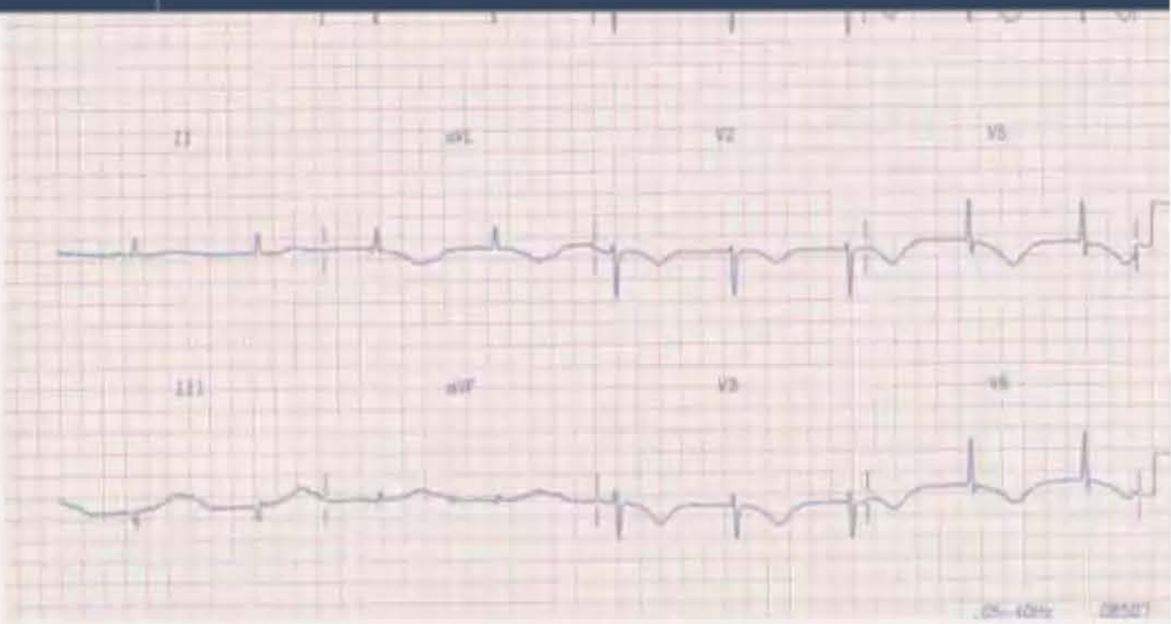

He is admitted and managed with subcutaneous fondaparinux, aspirin and ticragrelor. BP on admission i 90/70 mmHg, pulse is 65/min and regular. Creatinine is micromol/l. There is no further chest pain and his T-wav inversion appears to be partially resolved, but a 12 h troponin is raised at 3.5 µg/l.

Which of the following represents the optimal management in this case?

Your answer was correct

A	Inpatient limited exercise test
B	Plan routine angiography within 3 months
C	Plan for urgent angiography
D	Treat with streptokinase
E	Treat with TPA

Explanation

C Plan for urgent angiography

11:22
On
594-042-7551
Leave

C Plan for urgent angiography

The T wave inversion seen on ECG, raised troponin and cardiac chest pain put this patient into the NSTEMI category. As such he is at intermediate to high risk of a further NSTEMI or STEMI with a GRACE score of 6%. Whilst he has had no further chest pain, urgent angiography with angioplasty +/- stenting where appropriate would significantly reduce the risk of further events. He should of course also be aggressively managed to statin and blood pressure control targets and started on aspirin and ticagrelor.

A Inpatient limited exercise test

In the presence of chest pain, ECG changes and raised troponin, this patient should be treated as an NSTEMI. Therefore, no further confirmatory investigation is needed.

B Plan routine angiography within 3 months

NICE guidelines have suggested performing inpatient angiography +/- PCI within 96 hours of admission on intermediate to high risk inpatients. The risk is calculated using GRACE scoring.

D Treat with streptokinase

Thrombolysis is no longer indicated except in the context of STEMI where PCI is not available within 90minutes of first medical contact.

E Treat with TPA

Thrombolysis is no longer indicated except in the context of STEMI where PCI is not available within 90minutes of first medical contact.

Audio Video Share Participants More

In the presence of chest pain, ECG changes and raised troponin, this patient should be treated as an NSTEMI. Therefore, no further confirmatory investigation is needed.

B Plan routine angiography within 3 months

NICE guidelines have suggested performing inpatient angiography +/- PCI within 96 hours of admission on intermediate to high risk inpatients. The risk is calculated using GRACE scoring.

D Treat with streptokinase

Thrombolysis is no longer indicated except in the context of STEMI where PCI is not available within 90minutes of first medical contact.

E Treat with TPA

Thrombolysis is no longer indicated except in the context of STEMI where PCI is not available within 90minutes of first medical contact.

Rate this question:

© Pastest 2019

A 73-year-old female is brought into the Emergency Department by an ambulance because of a sudden onset of palpitations and shakes. This is the second time she has had such an experience. The first incidence only lasted about one minute, a month ago. She did not seek medical attention because she thought it was just one of those things that come with old age. The current episode has been going on for about an hour. She also has some shortness of breath but no dizziness. The ambulance crew noted that her blood pressure (BP) was very high, 230/110 mmHg. Her past medical history and family history are unremarkable.

On examination, she is dyspnoeic, sweating and shaking. Her blood pressure is 237/115 mmHg and her pulse is >150/min. Her chest is clear.

Investigations:

Electrocardiogram (ECG) monitor	Heart rate 188/min
12-lead electrocardiogram	Narrow complex tachycardia

You start the patient on high-flow oxygen (15 l) and you give her a fast intravenous dose of adenosine 6 mg. She experiences some chest tightness and the ECG monitor shows the heart rate slowing down. After a few minutes she calms down, the heart rate is 90/min, regular and the BP is 140/80mmHg.

What type of supraventricular tachycardia is this likely to be?

A Atrial flutter

B Atrial fibrillation

C Multifocal atrial tachycardia

Her blood pressure is 237/115 mmHg and her pulse is >150/min. Her chest is clear.

Investigations:

Electrocardiogram (ECG) monitor	Heart rate 188/min
12-lead electrocardiogram	Narrow complex tachycardia

You start the patient on high-flow oxygen (15 l) and you give her a fast intravenous dose of adenosine 6 mg. She experiences some chest tightness and the ECG monitor shows the heart rate slowing down. After a few minutes she calms down, the heart rate is 90/min, regular and the BP is 140/80mmHg.

What type of supraventricular tachycardia is this likely to be?

A Atrial flutter

B Atrial fibrillation

C Multifocal atrial tachycardia

D Sinus tachycardia

E Atrioventricular re-entrant tachycardia (AVRT)

Submit

12-lead electrocardiogram	Narrow complex tachycardia

You start the patient on high-flow oxygen (15 l) and you give her a fast intravenous dose of adenosine 6 mg. She experiences some chest tightness and the ECG monitor shows the heart rate slowing down. After a few minutes she calms down, the heart rate is 90/min, regular and the BP is 140/80mmHg.

What type of supraventricular tachycardia is this likely to be?

Your answer was correct

A Atrial flutter

B Atrial fibrillation

C Multifocal atrial tachycardia

D Sinus tachycardia

E Atrioventricular re-entrant tachycardia (AVRT)

Explanation

E Atrioventricular re-entrant tachycardia (AVRT)

AVRT and atrioventricular nodal re-entrant tachycardia (AVNRT) may be terminated with adenosine. Other manoeuvres that may unmask underlying rhythms include valsalva manoeuvres and carotid sinus massage.

A Atrial flutter

E Atrioventricular re-entrant tachycardia (AVRT)

AVRT and atrioventricular nodal re-entrant tachycardia (AVNRT) may be terminated with adenosine. Other manoeuvres that may unmask underlying rhythms include valsalva manoeuvres and carotid sinus massage.

A Atrial flutter

Transient atrioventricular (AV) block will unmask atrial flutter but is unlikely to terminate it.

B Atrial fibrillation

Transient atrioventricular (AV) block will unmask atrial fibrillation but is unlikely to terminate it.

C Multifocal atrial tachycardia

Transient atrioventricular (AV) block will unmask multifocal atrial tachycardia but is unlikely to terminate it.

D Sinus tachycardia

Sinus tachycardia is unlikely to be treated with adenosine; there may be just transient AV block.

Rate this question:

Next Question

11:27

A 38-year-old carpenter had been feeling unwell for 1 week with rhinorrhoea, dry cough, generalised myalgia and low-grade fever.

For the past 8 h, he has experienced substernal chest pain that is sharp and increases with respiration, and is slightly relieved when he leans forward. There is no radiation, sweating, palpitations or shortness of breath. He has no past medical history of note.

Physical examination reveals a well-built young male, not in any distress. His pulse rate if 68/min, blood pressure 144/84 mmHg and respiratory rate 14/min. There is a pericardial friction rub best heard at the left sternal edge. The rest of the examination is unremarkable.

Investigations:

Hb	16 g/dl
WCC	7.8×10^9/l
PLT	550×10^9/l
ESR	32 mm/1st hour

The electrocardiogram (ECG) is shown below.

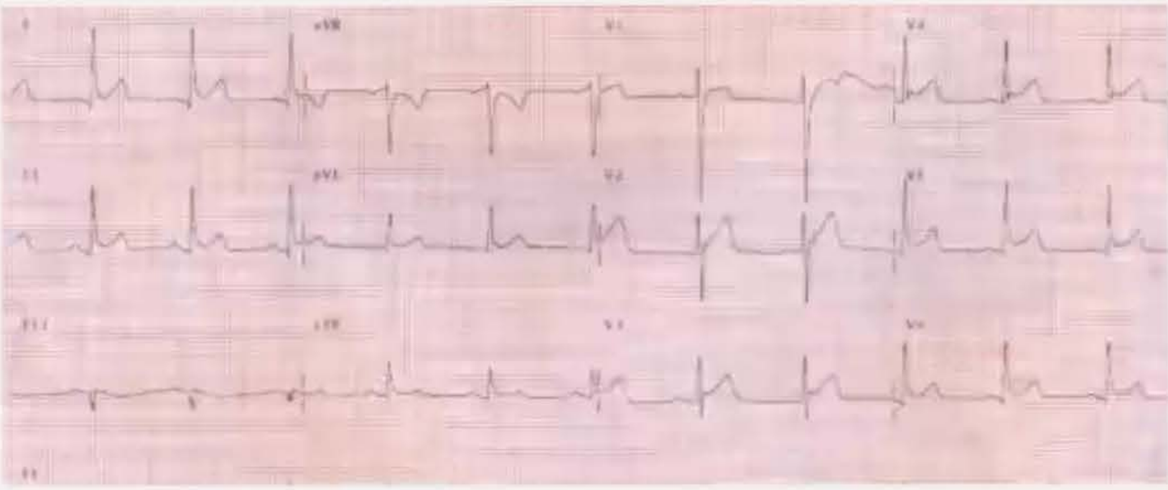

Which one of the following electrocardiographic features is most helpful in establishing the diagnosis of acute pericarditis?

A T wave inversion in aVR

Rana Alnasser's screen

11:29
On
594-042-7551
Leave

ne electrocardiogram (ECG) is shown below.

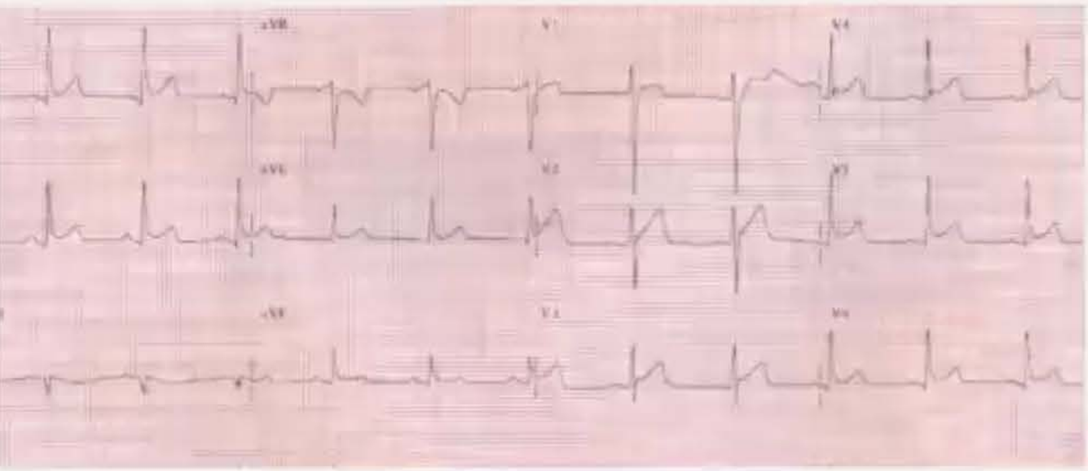

hich one of the following electrocardiographic features most helpful in establishing the diagnosis of acute ericarditis?

A T wave inversion in aVR

B Normal QRS axis

C PR segment depression in lead II and elevation in aVR

D Early transition of R waves in chest leads

E RS pattern in lead V1

Submit

Audio
Video
Share
Participants
More

11:30
On 594-042-7551 Leave

Explanation

C PR segment depression in lead II and elevation in aVR

The clinical features and electrocardiogram (ECG) in this patient are consistent with a diagnosis of acute pericarditis. The electrocardiographic differential diagnosis of acute pericarditis is myocardial infarction and early repolarisation abnormality. It can be differentiated from myocardial infarction by concavity of ST segment elevation and localisation of ST segment elevation to infarct-related artery and, given his age and prodromal symptoms, pericarditis is the more likely cause. However, these two ECG features do not differentiate acute pericarditis and early repolarisation abnormality. The two most helpful differentiating features are PR segment depression, which is usually best seen in lead II and V6, and PR segment elevation in aVR. This results from injury current that is directed towards aVR. An ST/T ratio greater 0.25 or a T-wave amplitude of less than or equal to 3 mm also has high positive and negative predictive value in diagnosis of acute pericarditis.

A T wave inversion in aVR

The T wave is normally inverted in aVR in adults, and hence it isn't a useful differentiator towards pericarditis.

B Normal QRS axis

Although constrictive pericarditis is associated with right axis deviation, a normal QRS axis doesn't rule pericarditis in or out.

D Early transition of R waves in chest leads

Early transition of R waves may be seen in some normal

Audio Video Share Participants More

11:35

A 32-year-old electrician presents with history of cramping pain in his right calf of three months' duration. Pain usually starts after walking a couple of blocks and forces him to stop. After stopping for few minutes, the pain is relieved. He is a lifelong non-smoker and has no family history of cardiovascular disease. He consumes three to four units of alcohol every week. Physical examination reveals an obese young male with absent right pedal pulse. He also has palmar and tuberous xanthomas. His ankle-brachial index is 0.6 on the right and 0.9 on the left.

The results of laboratory investigations are:

Electrocardiogram (ECG)	Normal
Chest X-ray	Normal
White cell count	8×10^9/l
Haemoglobin	11.9 g/dl with normal mean corpuscular volume and mean corpuscular haemoglobin
Platelets	188×10^9/l
Serum cholesterol	8.2 mmol/l
Triglycerides	4.1 mmol/l
High-density lipoprotein (HDL)	1 mmol/l
Thyroid-stimulating hormone	28 mU/l
Total thyroxine	50 nmol/l (58–155nmol/l)

What is the most likely cause of his lipid abnormality?

A Familial combined hyperlipidaemia

Rana Alnasser's screen

(ECG)	
Chest X-ray	Normal
White cell count	8×10^9/l
Haemoglobin	11.9 g/dl with normal mean corpuscular volume and mean corpuscular haemoglobin
Platelets	188×10^9/l
Serum cholesterol	8.2 mmol/l
Triglycerides	4.1 mmol/l
High-density lipoprotein (HDL)	1 mmol/l
Thyroid-stimulating hormone	28 mU/l
Total thyroxine	50 nmol/l (58–155nmol/l)

What is the most likely cause of his lipid abnormality?

A Familial combined hyperlipidaemia

B Hyperchylomicronaemia

C Hypothyroidism

D Dysbetalipoproteinaemia

E Obesity

Submit

D Dysbetalipoproteinaemia

Palmar xanthomas are pathognomonic of dysbetalipoproteinaemia (type III hyperlipoproteinaemia). It is caused by mutation in apoprotein E, and transmitted as an autosomal recessive trait and usually requires a secondary exacerbating metabolic factor for expression of the phenotype. Therefore, secondary causes of hyperlipidaemia such as hypothyroidism, obesity, diabetes mellitus, renal insufficiency, high-calorie, high-fat diet or alcohol are often encountered at diagnosis, as in this patient who has hypothyroidism and obesity. Patients are predisposed to peripheral vascular disease and coronary artery disease. Lipid profile in these patients reveals elevated cholesterol and triglycerides while high-density lipoprotein (HDL) is normal and low-density lipoprotein(LDL) low. Definitive diagnosis can be made by lipoprotein electrophoresis or genotyping of apoprotein E. Treatment involves management of secondary causes, which in this case are hypothyroidism and obesity. Drug therapy can be employed if treatment of secondary causes yields unsatisfactory results.

A Familial combined hyperlipidaemia

There is no palmar xanthomas in Familial combined hyperlipidaemia. This type of lipid disorder runs in families and is typified by high cholesterol levels, increased LDL and triglyceride concentrations, often accompanied by a decreased HDL. On lipoprotein electrophoresis there is hyperlipoproteinemia type IIB. It affects around one in 200 persons. Individuals who have coronary artery disease before age 60years have this disorder.

B Hyperchylomicronaemia

There is no palmar xanthomas in hyperchylomicronaemia. There is lipoprotein lipase deficiency, apolipoprotein(apo)

hyperlipidaemia. This type of lipid disorder runs in families and is typified by high cholesterol levels, increased LDL and triglyceride concentrations, often accompanied by a decreased HDL. On lipoprotein electrophoresis there is hyperlipoproteinemia type IIB. It affects around one in 200 persons. Individuals who have coronary artery disease before age 60years have this disorder.

B Hyperchylomicronaemia

There is no palmar xanthomas in hyperchylomicronaemia. There is lipoprotein lipase deficiency, apolipoprotein(apo) CII deficiency or LPL inhibition. This syndrome is characterized by hyperchylomicronaemia, attacks of epigastric pain, recurrent pancreatitis and the presence of eruptive xanthomas, may ultimately lead to necrotizing pancreatitis or pancreatic insufficiency. The treatment involves lifelong adherence to a low-fat diet to prevent hyperchylomicronaemia and its sequelae.

C Hypothyroidism

There is no palmar xanthomas in hypothyroidism. Hypothyroid patients have increased levels of total cholesterol and LDL. Hypothyroidism is a common cause of secondary dyslipidaemia.

E Obesity

There is no palmar xanthomas in obesity. Body mass index is positively correlated with triglyceride levels and negatively correlated with HDL cholesterol.

7472

Rate this question:

Next Question

Rana Alnasser's screen

1 Hyperchylomicronemia	2 F.H	3 Remnant (Dysbetalipoproteinemia)	4 Hypertriglyceridemia
Chylomicrons (**TG**)	LDL (**cholesterol**)	Mixed (**cholesterol + TGL**)	VLDL (**TG**)
Autosomal recessive	Autosomal dominant		Autosomal dominant
▪ **Lipoprotein lipase deficiency** ▪ **APO-C II deficiency**	**LDL receptors (ApoB100)**→ ↓hepatic uptake of LDL	APO-E2 homozygosity → ↓hepatic uptake of IDL	Hepatic overproduction of VLDL
▪ **Pancreatitis** ▪ HSM ▪ Eruptive (pruritic) xanthomas No ↑ASCVD risk	▪ **Accelerated atherosclerosis** ▪ Tendon (Achilles) xanthomas ▪ Xanselasma ▪ Corneal arcus	▪ **Yellow palmar crease**	▪ **Pancreatitis** ▪ CRVO ▪ Lipemia retinalis No ↑ASCVD risk
Diet control	Statins	fibrates	Fibrates / statin

11:43
On ...
594-042-7551
Leave

A 71-year-old man is admitted to the Emergency Department after a collapse. This is his third episode of syncope in the past 3 months. An ECG from the previous episode reveals Mobitz type 2 heart block. He has a history of inferior myocardial infarction and hypertension, managed with ramipril, bisoprolol 2.5mg and indapamide.

On examination his BP is 125/60 mmHg and pulse 40/min and regular. He is not in cardiac failure. An ECG is taken which reveals complete heart block with broad QRS complexes.

Which of the following is the most appropriate next step?

A	Administer 500mcg of atropine IV
B	Discharge and list for a permanent pacemaker as an outpatient
C	Stop bisoprolol and review in 4 weeks as an outpatient
D	Admit for permanent pacing
E	Give a bolus of 500 mcg adrenaline IV

Submit

Audio
Video
Share
Participants
More

A 71-year-old man is admitted to the Emergency Department after a collapse. This is his third episode of syncope in the past 3 months. An ECG from the previous episode reveals Mobitz type 2 heart block. He has a history of inferior myocardial infarction and hypertension, managed with ramipril, bisoprolol 2.5mg and indapamide.

On examination his BP is 125/60 mmHg and pulse 40/min and regular. He is not in cardiac failure. An ECG is taken which reveals complete heart block with broad QRS complexes.

Which of the following is the most appropriate next step?

Your answer was incorrect

A	Administer 500mcg of atropine IV
B	Discharge and list for a permanent pacemaker as an outpatient
C	Stop bisoprolol and review in 4 weeks as an outpatient
D	Admit for permanent pacing
E	Give a bolus of 500 mcg adrenaline IV

Explanation

A Administer 500mcg of atropine IV

This patient has had three collapses and is now in complete

A Administer 500mcg of atropine IV

This patient has had three collapses and is now in complete heart block with broad QRS complexes. Management of this situation is made simple by following the Resuscitation Council guidelines for bradycardia (see weblink below).

This patient has had three collapses and is now in complete heart block. In the presence of heart failure, shock, syncope or myocardial infarction, the immediate first step management options of this patient include one of the following:

- Atropine 500 mcg IV, up to a maximum dose of 3 mg if repetition is needed.
- Temporary pacing
- Alternative drugs such as isoprenaline or adrenaline.

These measures should also be considered in patients who are at risk of asystole - such as those with recent asystole, Mobitz type 2 AV block, complete heart block with broad QRS complexes, or episodes of ventricular pause lasting more than 3 seconds.

D Admit for permanent pacing

Admitting for permanent pacing as an inpatient will be required, but this is not the most important next step in the patient's management.

B Discharge and list for a permanent pacemaker as an outpatient

Discharging the patient home and listing for outpatient pacemaker insertion, represents a significant mortality risk given the three collapses over the course of 12 weeks. This would not be the appropriate management of this patient.

A 27-year-old professional football player is admitted with a fracture of his right tibia, which he sustained during the course of a match. He is put on traction in the ward and he is scheduled for theatre two days later. On the eve of the procedure he is seen by the house officer because of an episode of chest pain. Clinical examination is unremarkable. His electrocardiogram (ECG) and chest X-ray are reported as normal, and the patient is prescribed some analgesia. The following morning the patient is taken to theatre as planned. While in the anaesthetic room he is noted to have a respiratory rate of 25/min and oxygen saturations of 90% on room air. His heart rate is 100 beats/min regular and his blood pressure is 90/65 mmHg. His heart sounds are normal and there are coarse crackles on auscultation of his chest bilaterally. His jugular venous pressure is raised to 5 cm. There is no peripheral oedema.

His ECG shows right axis deviation with prominent R waves on leads V1–V2.

Which one of the following measures would be the appropriate next step in this patient's management?

A	IV furosemide
B	IV GTN infusion
C	IV fluids
D	Subcutaneous low-molecular weight heparin
E	IV thrombolysis

11:56
On ...
594-042-7551
Leave

A 27-year-old professional football player is admitted with a fracture of his right tibia, which he sustained during the course of a match. He is put on traction in the ward and he is scheduled for theatre two days later. On the eve of the procedure he is seen by the house officer because of an episode of chest pain. Clinical examination is unremarkable. His electrocardiogram (ECG) and chest X-ray are reported as normal, and the patient is prescribed some analgesia. The following morning the patient is taken to theatre as planned. While in the anaesthetic room he is noted to have a respiratory rate of 25/min and oxygen saturations of 90% on room air. His heart rate is 100 beats/min regular and his blood pressure is 90/65 mmHg. His heart sounds are normal and there are coarse crackles on auscultation of his chest bilaterally. His jugular venous pressure is raised to 5 cm. There is no peripheral oedema.

His ECG shows right axis deviation with prominent R waves on leads V1–V2.

Which one of the following measures would be the appropriate next step in this patient's management?

Your answer was incorrect

A IV furosemide

B IV GTN infusion

C IV fluids

D Subcutaneous low-molecular weight heparin

Audio Video Share Participants More

C IV fluids

This patient has symptoms and signs suggestive of acute pulmonary oedema. This is extremely unlikely to be cardiac in origin in a young athlete. In this case the most likely diagnosis is acute respiratory distress syndrome (ARDS) secondary to a fat embolus. Initial resuscitation should involve high-flow oxygen and IV fluids to maintain high right ventricular filling pressures. Steroid therapy is normally introduced later in ARDS; however if used at this stage, this could worsen pulmonary oedema and evidence is equivocal as to benefit. Mechanical ventilation with PEEP may be required.

E IV thrombolysis

Although thrombolysis is of benefit in massive pulmonary embolism, it is not of use here as the symptoms are related to ARDS, not to an embolus.

A IV furosemide

IV furosemide is not recommended in the acute situation because of the importance of maintaining circulatory pressure.

B IV GTN infusion

Like furosemide, GTN infusion may significantly reduce blood pressure with a consequent negative impact on outcomes.

D Subcutaneous low-molecular weight heparin

There is no evidence that heparin is of benefit in the management of fat embolism.

Rana Alnasser's screen

A 68-year-old male with ischaemic cardiomyopathy presents with worsening effort tolerance of 3 months' duration. He becomes short of breath even after mild exertion. Five years ago he had an anterior myocardial infarction. Coronary angiography at that time showed three-vessel disease, and he underwent coronary artery bypass grafting. His last echocardiography two months ago showed an ejection fraction of 20%. His current medications are: aspirin 75 mg, digoxin 125 mcg, furosemide 60 mg twice daily, lisinopril 10 mg/day, metoprolol 50 mg twice daily, simvastatin 20 mg/day and lansoprazole 30 mg daily. Physical examination reveals a blood pressure of 105/65 mmHg, pulse 68/min, mild jugular venous distension, fine bibasal crepitations and mild pedal oedema.

Investigations:

White blood cells	8.0×10^9/l
Haemoglobin	13.1 g/dl
Sodium	132 mmol/l (135–145 mmol/l)
Potassium	5.3 mmol/l (3.5–5 mmol/l)
Chloride	92 mmol/l (97–110 mmol/l)
Bicarbonate	26 mmol/l (22–28 mmol/l)
Creatinine	110 µmol/l (18–106 µmol/l)
Electrocardiogram (ECG)	QRS > 120ms. Left bundle branch block (LBBB)

Which of the following interventions would be most likely to improve the patient's symptoms?

A Hydralazine and isosorbide dinitrate

B Biventricular pacing

metoprolol 50 mg twice daily, simvastatin 20 mg/day and lansoprazole 30 mg daily. Physical examination reveals a blood pressure of 105/65 mmHg, pulse 68/min, mild jugular venous distension, fine bibasal crepitations and mild pedal oedema.

Investigations:

White blood cells	8.0×10^9/l
Haemoglobin	13.1 g/dl
Sodium	132 mmol/l (135–145 mmol/l)
Potassium	5.3 mmol/l (3.5–5 mmol/l)
Chloride	92 mmol/l (97–110 mmol/l)
Bicarbonate	26 mmol/l (22–28 mmol/l)
Creatinine	110 µmol/l (18–106 µmol/l)
Electrocardiogram (ECG)	QRS > 120ms. Left bundle branch block (LBBB)

Which of the following interventions would be most likely to improve the patient's symptoms?

A Hydralazine and isosorbide dinitrate

B Biventricular pacing

C Increase digoxin to 250 mcg/day

D Spironolactone

E Warfarin

12:00
On
594-042-7551
Leave

B Biventricular pacing

Bundle branch blocks or intraventricular conduction delay (IVCD cause ventricular dys-synchrony and reduce the cardiac contractile function. This leads to worsening of heart failure symptoms. Such patients have poorer exercise tolerance and worse prognosis compared to patients with normal sinus rhythm. Cardiac resynchronisation therapy by biventricular pacing improves left ventricular contractile function in patients with left bundle branch block (LBBB or IVCD, and thus improves symptoms. National Institute for Health and Care Excellence (NICE) guidelines recommend that cardiac resynchronisation therapy should be considered in patients with left ventricular ejection fraction less than 35%, drug-refractory symptoms and QRS duration >120 ms.

A Hydralazine and isosorbide dinitrate

Hydralazine and nitrates in combination are recommended in patients who do not tolerate angiotensin-converting enzyme inhibitors.

C Increase digoxin to 250 mcg/day

Increasing serum digoxin in this patient, who has slightly raised serum creatinine, can lead to digoxin toxicity and is unlikely to improve symptoms.

D Spironolactone

Spironolactone has been shown to decrease hospitalisation and improve survival in patients with severe heart failure; however, this patient's serum potassium level is slightly higher than normal and adding spironolactone in such cases can further increase the serum potassium to

Audio Video Share Participants More

12:01
On
594-042-7551
Leave

A 73-year-old female who is known to suffer from peptic ulcer disease presents to the Emergency Department complaining of a 6 h history of epigastric pain. She initially felt this was a bout of severe indigestion but called an ambulance after she started becoming short of breath. On arrival in the department her blood pressure is 100/60 mmHg, heart rate 120/min and she appears clammy and sweaty. Her heart sounds are normal and there are some basal crackles on auscultation of her chest. A 12-lead electrocardiogram (ECG) shows ST elevation of 1 mm in leads I and aVL, with ST depression of 2 mm and a dominant R wave in leads V1–V3. She undergoes urgent primary PCI and makes a good initial recovery. One week later she re-attends complaining of severe retrosternal chest pain that is worse on inspiration. On examination she is found to have a low-grade pyrexia. There is a rub on auscultation of her chest. A 12-lead ECG shows dominant R waves in leads V1-V3. A chest X-ray shows cardiomegaly with a small left-sided pleural effusion.

Which of the following is the most likely diagnosis?

A	Posterior myocardial infarction
B	Viral infection
C	Dressler syndrome
D	Bacterial lower respiratory tract infection
E	Pulmonary embolism

Audio
Video
Share
Participants
More

A 73-year-old female who is known to suffer from peptic ulcer disease presents to the Emergency Department complaining of a 6 h history of epigastric pain. She initially felt this was a bout of severe indigestion but called an ambulance after she started becoming short of breath. On arrival in the department her blood pressure is 100/60 mmHg, heart rate 120/min and she appears clammy and sweaty. Her heart sounds are normal and there are some basal crackles on auscultation of her chest. A 12-lead electrocardiogram (ECG) shows ST elevation of 1 mm in leads I and aVL, with ST depression of 2 mm and a dominant R wave in leads V1–V3. She undergoes urgent primary PCI and makes a good initial recovery. One week later she re-attends complaining of severe retrosternal chest pain that is worse on inspiration. On examination she is found to have a low-grade pyrexia. There is a rub on auscultation of her chest. A 12-lead ECG shows dominant R waves in leads V1-V3. A chest X-ray shows cardiomegaly with a small left-sided pleural effusion.

Which of the following is the most likely diagnosis?

Your answer was correct

A Posterior myocardial infarction

B Viral infection

C Dressler syndrome

D Bacterial lower respiratory tract infection

E Pulmonary embolism

Explanation

C Dressler syndrome

Dressler syndrome usually occurs 1–6 weeks after a myocardial infarction and is characterised by fever, pleuritis and pericarditis. It is thought to be an autoimmune reaction to myocardial antigens released after the infarction. Management is with aspirin, and corticosteroids are used in resistant cases, particularly those where pericardiocentesis has been required for drainage of pericardial effusion; in rare cases up to 1500 ml of fluid is recognised to accumulate in the pericardial sac. Other post-MI syndromes include papillary muscle rupture, with a median time to onset of 13 h, which leads to acute mitral regurgitation, and ventricular septal defect, occurring with an incidence of 0.2% post-infarct, leading to catastrophic heart failure.

A Posterior myocardial infarction

The pleuritic nature of her chest pain, in the context of a recent MI, and the absence of dynamic ST changes on her ECG, make this a less likely diagnosis than Dressler syndrome.

B Viral infection

We are given a history of only a mild pyrexia, and in the context of a recent MI this would be a less likely diagnosis than Dressler syndrome. It is important to remember, however, that viral infections (particularly Coxsackie) can cause pericarditis.

D Bacterial lower respiratory tract infection

We are not given a significant history of respiratory symptoms such as productive cough, and the CXR was not overtly suspicious for LRTI (though in some cases of LRTI,

12:04
On
594-042-7551
Leave

The pleuritic nature of her chest pain, in the context of a recent MI, and the absence of dynamic ST changes on her ECG, make this a less likely diagnosis than Dressler syndrome.

B Viral infection

We are given a history of only a mild pyrexia, and in the context of a recent MI this would be a less likely diagnosis than Dressler syndrome. It is important to remember, however, that viral infections (particularly Coxsackie) can cause pericarditis.

D Bacterial lower respiratory tract infection

We are not given a significant history of respiratory symptoms such as productive cough, and the CXR was not overtly suspicious for LRTI (though in some cases of LRTI, parapneumonic effusions can be seen). Particularly in the context of recent MI, this makes LRTI a less likely diagnosis than Dressler syndrome.

E Pulmonary embolism

The presence of a rub, and a pleural effusion, in the context of a recent MI, make this a less likely diagnosis than Dressler syndrome.

Rate this question:

Next Question

Audio Video Share Participants More

12:04

A 75-year-old man is brought to the Emergency Department in a collapsed state. He had collapsed in a department store while doing some shopping with his wife. An ambulance was called and he was brought to the Emergency Department. He had received three direct current (DC) shocks on his way to the hospital in the ambulance.

On a quick look through his notes, he has a past medical history of psychotic depression for which he is on quetiapine and amitriptyline. He was admitted last week for the treatment of a lower respiratory tract infection and was commenced on clarithromycin. His admission ECG at the time showed sinus rhythm 84/min, normal axis and a QTc of 460 ms.

On examination now he 'does not feel right', with a blood pressure of 102/60 mmHg, HR >120/min and oxygen saturation of 93% on 35% oxygen. His electrocardiogram (ECG) reveals polymorphic VT.

Arterial blood gas analysis reveals that he is hypokalaemic.

Which of the following interventions would you immediately consider in this patient?

A	Amiodarone infusion
B	Magnesium sulphate and potassium infusion
C	IV sotalol
D	IV flecainide
E	Repeat DC cardioversion

Rana Alnasser's screen

history of psychotic depression for which he is on quetiapine and amitriptyline. He was admitted last week for the treatment of a lower respiratory tract infection and was commenced on clarithromycin. His admission ECG at the time showed sinus rhythm 84/min, normal axis and a QTc of 460 ms.

On examination now he 'does not feel right', with a blood pressure of 102/60 mmHg, HR >120/min and oxygen saturation of 93% on 35% oxygen. His electrocardiogram (ECG) reveals polymorphic VT.

Arterial blood gas analysis reveals that he is hypokalaemic.

Which of the following interventions would you immediately consider in this patient?

Your answer was correct

A	Amiodarone infusion
B	Magnesium sulphate and potassium infusion
C	IV sotalol
D	IV flecainide
E	Repeat DC cardioversion

Explanation

B	Magnesium sulphate and potassium infusion

This is the first-line treatment for torsades de pointes. Polymorphic VT is a form of ventricular tachycardia with wide QRS complexes of multiple morphologies seen on ECG. There are changing R-R intervals as well as axis of the

B Magnesium sulphate and potassium infusion

This is the first-line treatment for torsades de pointes. Polymorphic VT is a form of ventricular tachycardia with wide QRS complexes of multiple morphologies seen on ECG. There are changing R-R intervals as well as axis of the QRS complexes. The key distinction to be made here is the difference between a diagnosis of torsades de pointes versus other forms of polymorphic VT. Not all polymorphic VT is torsades. The key is in the history. Torsades de pointes is a polymorphic VT in the context of a prolonged QT interval. First-line treatment would entail IV magnesium and correction of any electrolyte abnormalities. Other forms of polymorphic VT secondary to scar tissue after myocardial infarction would NOT respond to the same treatment and would likely require electrical or chemical cardioversion. Other therapies include overdrive pacing and isoproterenol infusion.

In this case the patient has a history of prolonged QTc with predisposing drugs, and was recently given an antibiotic known to further prolong the QT interval. This has likely precipitated his presentation with torsades de pointes. It is important to avoid drugs that further prolong the QTc.

A Amiodarone infusion

This is not an option for the treatment of torsades de pointes and can potentially worsen the situation via its QT-prolongation effects.

C IV sotalol

Sotalol prolongs the QT interval and has no role in the treatment of torsades.

D IV flecainide

Dr. Smith's ECG Blog

Smith's ECG Blog: Polymorphic Ventricular Tachycardia

nd it is "Polymorphic" VT because there are multiple morphologies to the complex Polymorphic VT is either torsade ...

es may be subject to copyright. Learn more

ATED IMAGES

ith's ECG Blog: Very Wide and Very Fas...
ed-ecg.blogspot.com

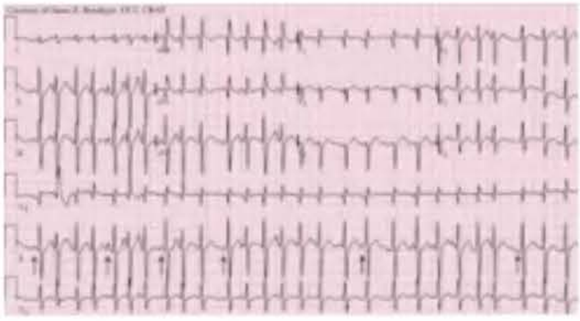

Multifocal atrial tachycardia - Wikiwand
wikiwand.com

Torsa
wikiwa

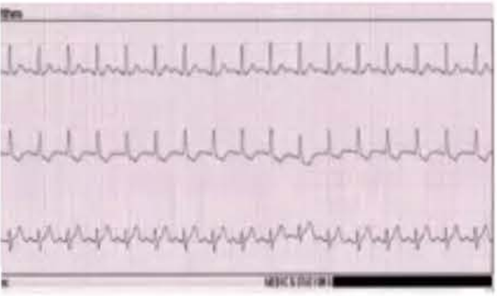

tachycardia - Wikipedia
pedia.org

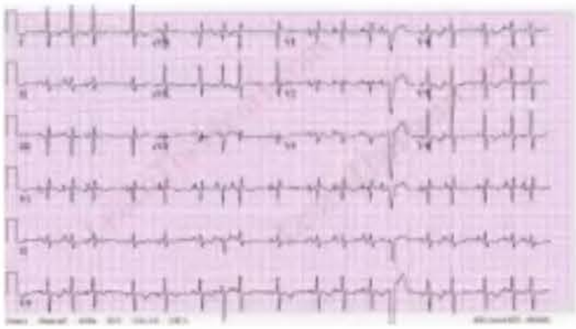

Atrial Arrhythmias ECG Quiz 5 | LearntheHea...



Heart

12:08
On
594-042-7551
Leave

A 74-year-old male presents to his general practitioner (GP) with symptoms of breathlessness on climbing up stairs over the last 6 months. There is no history of chest pain or palpitations. He is known to suffer from hypertension for which he is on amlodipine 5 mg once daily. He is a smoker with a 40-pack year history and is obese with a BMI of 32. Blood pressure in the surgery is 155/85 mmHg, pulse is 80/min and regular. The GP can hear a quiet systolic murmur. His resting electrocardiogram (ECG) shows evidence of left ventricular hypertrophy. The GP refers the patient to the cardiology open-access echocardiography service.

Which of the following echo findings would most strongly point towards a non-cardiac cause of his breathlessness?

A	Left ventricular hypertrophy
B	Right ventricular impairment
C	Moderate aortic stenosis
D	Hypokinetic anterior wall of the left ventricle
E	Moderate mitral regurgitation

Submit

Previous Q...
Skip Questi...
Audio
Video
Share
Participants
More

A 74-year-old male presents to his general practitioner (GP) with symptoms of breathlessness on climbing up stairs over the last 6 months. There is no history of chest pain or palpitations. He is known to suffer from hypertension for which he is on amlodipine 5 mg once daily. He is a smoker with a 40-pack year history and is obese with a BMI of 32. Blood pressure in the surgery is 155/85 mmHg, pulse is 80/min and regular. The GP can hear a quiet systolic murmur. His resting electrocardiogram (ECG) shows evidence of left ventricular hypertrophy. The GP refers the patient to the cardiology open-access echocardiography service.

Which of the following echo findings would most strongly point towards a non-cardiac cause of his breathlessness?

Your answer was correct

A Left ventricular hypertrophy

B Right ventricular impairment

C Moderate aortic stenosis

D Hypokinetic anterior wall of the left ventricle

E Moderate mitral regurgitation

Explanation

B Right ventricular impairment

Rana Alnasser's screen

The story is suggestive of early onset heart failure. The

B Right ventricular impairment

The story is suggestive of early onset heart failure. The picture of right ventricular dysfunction should raise the possibility of an underlying respiratory pathology. In someone with a heavy smoking history, this is most likely to be chronic obstructive airways disease leading to chronic hypoxia and pulmonary hypertension; however, chronic thromboembolic disease is another possibility. If right ventricular impairment is demonstrated, given his BMI, CT pulmonary angiography (CTPA) or V/Q scan could be considered.

A Left ventricular hypertrophy

Given his raised BP despite anti-hypertensive medication, this would suggest the possibility of uncontrolled hypertension as a potential cause of early-onset heart failure, explaining his breathlessness.

C Moderate aortic stenosis

This would point towards valvular disease as a cause of his breathlessness.

D Hypokinetic anterior wall of the left ventricle

This would suggest possible previous MI/IHD as a possible cardiac cause of his breathlessness.

E Moderate mitral regurgitation

This would point towards valvular disease as a cause of his breathlessness.

32336

Rana Alnasser's screen

Rate this question:

You are a gastroenterology senior house officer (SHO). A cardiology SHO has called you, asking for some advice. A 70-year-old man has been admitted with signs of heart failure. An echocardiogram reported severe calcific aortic stenosis, with a gradient of 110 mmHg across the valve and a valve area of 0.6 cm^2. Routine blood tests have shown this man to have microcytic hypochromic anaemia, with a haemoglobin level of 8.7 g/dl.

Over the past 5 years, the patient has undergone several gastric endoscopies and colonoscopies in search of an underlying cause of his anaemia, the last only a year ago. However, on each occasion, nothing was found. The patient is taking lansoprazole and iron tablets.

Which of the following is the most appropriate course of action with respect to long-term management of his clinical condition?

A	Replace the aortic valve
B	Serial blood transfusions
C	Continue with serial endoscopies until a source of bleeding is identified
D	Add ranitidine to the patient's pharmacological treatment
E	Refer to a haematologist for bone marrow examination

You are a gastroenterology senior house officer (SHO). A cardiology SHO has called you, asking for some advice. A 70-year-old man has been admitted with signs of heart failure. An echocardiogram reported severe calcific aortic stenosis, with a gradient of 110 mmHg across the valve and a valve area of 0.6 cm^2. Routine blood tests have shown this man to have microcytic hypochromic anaemia, with a haemoglobin level of 8.7 g/dl.

Over the past 5 years, the patient has undergone several gastric endoscopies and colonoscopies in search of an underlying cause of his anaemia, the last only a year ago. However, on each occasion, nothing was found. The patient is taking lansoprazole and iron tablets.

Which of the following is the most appropriate course of action with respect to long-term management of his clinical condition?

Your answer was correct

A Replace the aortic valve

B Serial blood transfusions

C Continue with serial endoscopies until a source of bleeding is identified

D Add ranitidine to the patient's pharmacological treatment

E Refer to a haematologist for bone marrow examination

Explanation

A Replace the aortic valve

A Replace the aortic valve

This is Heyde syndrome, a well-known association between microcytic anaemia and calcific aortic stenosis.

Heyde syndrome occurs due to the depletion of von Willebrand factor (vWF) in blood that flows through the narrowed valvular stenosis, with subsequent gastrointestinal bleeding from angiodysplastic lesions.

Treatment is to replace the aortic valve.

B Serial blood transfusions

Blood transfusions would help to acutely restore haemoglobin levels but would not deal with the underlying Heyde syndrome. Repeated transfusions are known to carry a risk of alloimmune reactions and iron overload.

C Continue with serial endoscopies until a source of bleeding is identified

The investigation of choice after valve replacement is mesenteric angiography, as the bleeding vessels are poorly visualised on colonoscopy. This would look for the presence of angiodysplasia, which may be associated with aortic stenosis.

D Add ranitidine to the patient's pharmacological treatment

Given the fact that no gastric ulcers have been identified and that the patient has a clearly identified source of bleeding, adding ranitidine would not be of any benefit.

E Refer to a haematologist for bone marrow examination

The investigation of choice after valve replacement is mesenteric angiography, as the bleeding vessels are poorly visualised on colonoscopy. This would look for the presence of angiodysplasia, which may be associated with aortic stenosis.

D	Add ranitidine to the patient's pharmacological treatment

Given the fact that no gastric ulcers have been identified and that the patient has a clearly identified source of bleeding, adding ranitidine would not be of any benefit.

E	Refer to a haematologist for bone marrow examination

The patient is suffering from microcytic anaemia, a sequela of chronic bleeding. Even more, he is found to have a well-recognised cause of bleeding from the gut (Heyde syndrome) and no signs of bone marrow failure. Bone marrow examination is likely going to yield normal findings and would not be of diagnostic help.

Rate this question:

Next Question

Previous Q... Tag Questi... Feedback End Session

Blog About Pastest Contact Us Help

© Pastest 2019

You are called by an obstetrician for evaluation of a 39-year-old Thai female in her 39th week of gestation. She is planned to undergo Caesarean section because of fetal distress due to placental abruption.

On examination, she appears an averagely built lady with body mass index of 27, heart rate of 95 bpm, blood pressure (BP) 132/78 mmHg and respiratory rate of 18/min. She has no jugular venous distension; her apex beat is in fifth intercostals space, midclavicular line, has a mid-systolic click and a late systolic murmur at apex radiating towards axilla. The rest of her physical examination is unremarkable except for gravid uterus.

She has no past medical history of note except for a history of skin wheals and pruritis following ingestion of amoxicillin. The symptoms resolved after treatment with chlorpheniramine maleate

Which of the following is the best regimen for endocarditis prophylaxis in this patient?

A	Ampicillin 2 g IV 30 min before operation
B	Vancomycin 1 g IV 60 min before operation
C	Clindamycin 600 mg IV 30 min before operation
D	Erythromycin 500 mg IV 30 min before procedure
E	No prophylaxis required

Submit

You are called by an obstetrician for evaluation of a 39-year-old Thai female in her 39th week of gestation. She is planned to undergo Caesarean section because of fetal distress due to placental abruption.

On examination, she appears an averagely built lady with body mass index of 27, heart rate of 95 bpm, blood pressure (BP) 132/78 mmHg and respiratory rate of 18/min. She has no jugular venous distension; her apex beat is in fifth intercostals space, midclavicular line, has a mid-systolic click and a late systolic murmur at apex radiating towards axilla. The rest of her physical examination is unremarkable except for gravid uterus.

She has no past medical history of note except for a history of skin wheals and pruritis following ingestion of amoxicillin. The symptoms resolved after treatment with chlorpheniramine maleate

Which of the following is the best regimen for endocarditis prophylaxis in this patient?

Your answer was correct

A	Ampicillin 2 g IV 30 min before operation
B	Vancomycin 1 g IV 60 min before operation
C	Clindamycin 600 mg IV 30 min before operation
D	Erythromycin 500 mg IV 30 min before procedure
E	No prophylaxis required

Explanation

E	No prophylaxis required

E No prophylaxis required

The evidence in favour of antibiotic prophylaxis is limited, with no randomised trial. NICE guidelines (CG64: Prophylaxis against infective endocarditis) no longer recommend antibiotic prophylaxis for dental or respiratory procedures. They are only indicated for gastrointestinal and genitourinary procedures where there is a suspicion of pre-existing infection. In this case while a cardiac murmur is detected, there are no signs or symptoms from the clinical history suggestive of infective endocarditis.

A Ampicillin 2 g IV 30 min before operation

NICE guidelines generally no longer recommend routine prophylaxis for valve lesions due to lack of evidence of benefit. In a patient with a potential penicillin allergy, ampicillin is not an appropriate choice of antibiotic.

B Vancomycin 1 g IV 60 min before operation

The role for prophylactic antibiotics no longer features in NICE guideline recommendations. They are only recommended for gastrointestinal and genitourinary procedures where there is a suspicion of pre-existing infection. High-risk patients for infective endocarditis are identified by NICE guidelines (CG64: Prophylaxis against infective endocarditis), they include previous infective endocarditis, prosthetic valves, acquired valvular heart disease with stenosis or regurgitation, and structural congenital heart disease including surgically corrected or palliated structural conditions.

C Clindamycin 600 mg IV 30 min before operation

Antibiotic prophylaxis is no longer recommended for valve lesions in accordance with NICE guidelines (2008). ESC

A 64-year-old man with a long history of IHD and cardiac failure is reviewed in the cardiology clinic. He unfortunately still has symptoms of shortness of breath on exercise and is dyspnoeic at night, despite being managed with ramipril 10 mg daily, carvedilol 12.5 mg BD, digoxin 125 mcg daily, spironolactone 25 mg daily and furosemide 80 mg daily. On examination his BP is 104/60 mmHg, with a pulse of 50 bpm, and his chest is clear.

Investigations:

Hb	13.2 g/dl
WCC	4.8 $\times 10^9$/l
PLT	304 $\times 10^9$/l
Na^+	139 mmol/l
K^+	4.9 mmol/l
Creatinine	175 µmol/l
ECG	Sinus rhythm, QRS widening (155ms)
Ejection fraction	28%
PaO_2	9 kPa

Which of the following is the most appropriate management for him based on the available information?

A Offer morphine to relieve his shortness of breath

B Start home oxygen therapy

C Increase his furosemide to 160mg daily

D Add metolazone to his regime

E Consider cardiac resynchronisation therapy

Hb	13.2 g/dl
WCC	4.8 x10^9/l
PLT	304 x10^9/l
Na^+	139 mmol/l
K^+	4.9 mmol/l
Creatinine	175 µmol/l
ECG	Sinus rhythm, QRS widening (155ms)
Ejection fraction	28%
PaO_2	9 kPa

Which of the following is the most appropriate management for him based on the available information?

Your answer was correct

A Offer morphine to relieve his shortness of breath

B Start home oxygen therapy

C Increase his furosemide to 160mg daily

D Add metolazone to his regime

E Consider cardiac resynchronisation therapy

Explanation

E Consider cardiac resynchronisation therapy

E Consider cardiac resynchronisation therapy

According to current guidelines, this patient fits the drug therapy, ECG and echocardiographic criteria for cardiac resynchronisation therapy. This is usually with permanent dual-chamber pacing, although certain patients at high risk of ventricular arrhythmias and cardiac arrest may receive an implantable cardioverter defibrillator instead.

A Offer morphine to relieve his shortness of breath

While morphine can be considered as an adjunctive/palliative therapy for patients with heart failure, it is not the most appropriate option in this case as the patient meets the criteria for CRT implantation.

B Start home oxygen therapy

We are told his PaO_2 is 9, which is above the current threshold for consideration of instituting home oxygen therapy.

C Increase his furosemide to 160mg daily

We are not given evidence of fluid overload, and it is worth noting that this gentleman's creatinine is raised at 175. SIGN are clear that the diuretic dose chosen or reached should eliminate ankle or pulmonary oedema without dehydrating the patient and placing them at risk of renal dysfunction or hypotension.

D Add metolazone to his regime

We are not given evidence of fluid overload, and this gentleman is already taking two diuretic agents. ESC guidance states that a mineralocorticoid antagonist (MRA),

A 23-year-old female presents to the Emergency Department with collapse. She was playing tennis when she suddenly felt faint but didn't lose consciousness. This is her second episode of pre-syncope, the other occurred when she went swimming as part of a charity event. Extensive investigations were carried out on the first occasion but none revealed anything diagnostic. The investigations included: electrocardiogram (ECG), 24 h ECG monitor, echocardiography, chest X-ray (CXR), routine full blood count (FBC) and biochemistry, which were all normal. There is no past medical history of any serious illness apart from syncope. She is not on any medication.
On examination she is alert, her blood pressure is 120/65 mmHg and pulse 70/min and regular. Cardiovascular, respiratory, nervous and abdominal examinations are all normal.

Investigations:

Urea and electrolytes	Normal
Full blood count	Normal
Chest X-ray	Normal
Electrocardiogram (ECG)	QT prolongation: QTc 0.49 s

How would you manage this young lady?

A Electrophysiological studies

B Insert a cardioverter-defibrillator

C Start her on a beta-blocker

D Start her on amiodarone

E Start her on a calcium channel blocker

A 23-year-old female presents to the Emergency Department with collapse. She was playing tennis when she suddenly felt faint but didn't lose consciousness. This is her second episode of pre-syncope, the other occurred when she went swimming as part of a charity event. Extensive investigations were carried out on the first occasion but none revealed anything diagnostic. The investigations included: electrocardiogram (ECG), 24 h ECG monitor, echocardiography, chest X-ray (CXR), routine full blood count (FBC) and biochemistry, which were all normal. There is no past medical history of any serious illness apart from syncope. She is not on any medication.
On examination she is alert, her blood pressure is 120/65 mmHg and pulse 70/min and regular. Cardiovascular, respiratory, nervous and abdominal examinations are all normal.

Investigations:

Urea and electrolytes	Normal
Full blood count	Normal
Chest X-ray	Normal
Electrocardiogram (ECG)	QT prolongation: QTc 0.49 s

How would you manage this young lady?

Your answer was incorrect

A Electrophysiological studies

B Insert a cardioverter-defibrillator

C Start her on a beta-blocker

Long-QT syndrome (LQTS) is a congenital disorder characterised by a prolongation of the QT interval on electrocardiogram (ECG) and a propensity to ventricular tachyarrhythmias, which may lead to syncope, cardiac arrest or sudden death. LQTS is caused by mutations of cardiac ion channel genes, and two forms have been recognised: Romano–Ward syndrome and Jervell and Lang–Nielsen. Beta-blockers are the drugs of choice for patients with LQTS. The protective effect of beta-blockers is related to their adrenergic blockade diminishing the risk of cardiac arrhythmias.

A Electrophysiological studies

Electrophysiological studies are minimally invasive procedures that test the electrical conduction system of the heart to assess its electrical activity and conduction pathways. It is not needed in this scenario, as we know that QT is prolonged and it has a certain set of potential differentials.

B Insert a cardioverter-defibrillator

Implantation of cardioverter-defibrillators appears to be the most effective therapy for high-risk patients, and left cervicothoracic stellectomy is another antiadrenergic therapeutic measure used in high-risk patients with LQTS. High risk in this context is usually described by a history of collapse. Given this woman's age, it may be preferable to have a trial of beta-blockade before committing to an implantable cardioverter-defibrillator.

D Start her on amiodarone

Amiodarone will prolong the QT interval, so it would not be

A Electrophysiological studies

Electrophysiological studies are minimally invasive procedures that test the electrical conduction system of the heart to assess its electrical activity and conduction pathways. It is not needed in this scenario, as we know that QT is prolonged and it has a certain set of potential differentials.

B Insert a cardioverter-defibrillator

Implantation of cardioverter-defibrillators appears to be the most effective therapy for high-risk patients, and left cervicothoracic stellectomy is another antiadrenergic therapeutic measure used in high-risk patients with LQTS. High risk in this context is usually described by a history of collapse. Given this woman's age, it may be preferable to have a trial of beta-blockade before committing to an implantable cardioverter-defibrillator.

D Start her on amiodarone

Amiodarone will prolong the QT interval, so it would not be given in this case.

E Start her on a calcium channel blocker

Calcium channel blockers are not useful in this case of prolonged QT interval; in fact, some calcium channel blockers are responsible for prolongation of QT interval.

Rate this question:

pressure is 115/75 mmHg and respiratory rate is 22/min. There is no jugular venous distension, heart sounds are normal and the chest is clear to auscultation. The patient is administered chewable aspirin 300 mg, sublingual nitroglycerine, morphine and unfractionated heparin infusion.

Investigations show:

Sodium	135 mmol/l
Potassium	4.5 mmol/l
Urea	8 mmol/l
Creatinine	70 µmol/l
Haemoglobin	14 g/dL
White cell count	11 x 10^9/L
Electrocardiogram (ECG)	1.5 mm ST segment depression in lateral leads

If this patient has sustained a non-ST elevation myocardial infarction, which of the following cardiac markers would you expect to be raised at this time?

A Creatine kinase

B Lactate dehydrogenase

C Troponin I

D Myoglobin

E Troponin T

D Myoglobin

Myoglobin is the earliest to be elevated among all the cardiac markers listed in event of myocardial infarction (MI). Elevated levels can be detected as early as 1 h of MI (range 1–4), peaks in 6–7 h and returns to normal in 24 h. Myoglobin however is much less specific than the troponins and can be elevated in skeletal muscle injury and renal impairment.

A Creatine kinase

Creatine kinase begins to rise 3–12 h after MI and peak concentrations are reached in 18–24 h.

B Lactate dehydrogenase

Lactate dehydrogenase begins to rise in 6–12 h.

C Troponin I

Troponins begin to rise 3–12 h after MI. Troponin I is the most specific of all cardiac markers listed. Troponins remain elevated up to 10 days after the MI, and therefore can be helpful in establishing the diagnosis in patients who present after several days.

E Troponin T

Troponins begin to rise 3–12 h after MI. Troponins remain elevated up to 10 days after the MI, and therefore can be helpful in establishing the diagnosis in patients who present after several days.

Rate this question:

A general practitioner (GP) calls you up. He is asking for advice regarding a 52-year-old white man who came to his surgery, complaining of chest pain, which was subsequently diagnosed as musculoskeletal in origin because of tenderness in the upper chest wall and a recent history of moving heavy boxes at home.

During his initial assessment, the patient's blood pressure was 170/100 mmHg, and on subsequent visits, it has remained at around this level. Ambulatory blood pressure measurement has confirmed moderate hypertension.

He is an ex-smoker of 4 years. There is a strong family history of ischaemic heart disease and hypertension. He says that there is no evidence of left ventricular hypertrophy on his electrocardiogram (ECG), and his urine dipstick did not show proteinuria.

The GP wants advice regarding treating his blood pressure.

What is your advice to the GP?

A	You suggest reassurance and a 'do-nothing approach'
B	You suggest a low-salt diet and regular exercise
C	You suggest treatment with an angiotensin-converting enzyme (ACE) inhibitor
D	You suggest treatment with a calcium channel inhibitor
E	You suggest treatment with an angiotensin II receptor blocker (ARB)

During his initial assessment, the patient's blood pressure was 170/100 mmHg, and on subsequent visits, it has remained at around this level. Ambulatory blood pressure measurement has confirmed moderate hypertension.

He is an ex-smoker of 4 years. There is a strong family history of ischaemic heart disease and hypertension. He says that there is no evidence of left ventricular hypertrophy on his electrocardiogram (ECG), and his urine dipstick did not show proteinuria.

The GP wants advice regarding treating his blood pressure.

What is your advice to the GP?

Your answer was correct

A	You suggest reassurance and a 'do-nothing approach'
B	You suggest a low-salt diet and regular exercise
C	You suggest treatment with an angiotensin-converting enzyme (ACE) inhibitor
D	You suggest treatment with a calcium channel inhibitor
E	You suggest treatment with an angiotensin II receptor blocker (ARB)

Explanation

C	You suggest treatment with an angiotensin-converting enzyme (ACE) inhibitor

The National Institute for Health and Care Excellence

C You suggest treatment with an angiotensin-converting enzyme (ACE) inhibitor

The National Institute for Health and Care Excellence (NICE) guidelines give separate guidance for adults over and under the age of 55 years. A meta-analysis of all currently available evidence indicates that first-line therapy for those aged < 55 years should be an ACE inhibitor.

ACE inhibitors have been shown to be effective not only against hypertension, but also in the prevention of diabetic nephropathy, congestive heart failure and the prophylaxis of cardiovascular events.

A You suggest reassurance and a 'do-nothing approach'

This man has moderate hypertension, confirmed over several readings. Even though there is no evidence of end-organ damage (and without knowing his total cholesterol to high-density lipoprotein (HDL) ratio) he falls into the cardiovascular disease risk group of 10–20% over the next 10 years on the Framingham charts, which warrants pharmacological interventions.

B You suggest a low-salt diet and regular exercise

Given the above risk of cardiovascular disease, the patient warrants treatment with pharmacological interventions, and not just lifestyle modification.

D You suggest treatment with a calcium channel inhibitor

NICE guidelines recommend that in patients over 55 years of age, initial therapy should be with a calcium channel inhibitor or a thiazide-like diuretic if the calcium channel inhibitor is unsuitable.

B You suggest a low-salt diet and regular exercise

Given the above risk of cardiovascular disease, the patient warrants treatment with pharmacological interventions, and not just lifestyle modification.

D You suggest treatment with a calcium channel inhibitor

NICE guidelines recommend that in patients over 55 years of age, initial therapy should be with a calcium channel inhibitor or a thiazide-like diuretic if the calcium channel inhibitor is unsuitable.

E You suggest treatment with an angiotensin II receptor blocker (ARB)

Treatment with an ARB is advocated by NICE guidelines for patients in whom treatment with an ACE inhibitor is not tolerated.

Data from meta-analyses have shown no difference in total mortality or cardiovascular outcomes for ARBs, as compared with ACE inhibitors. However, unlike ACE inhibitors, ARBs have not been directly studied in placebo-controlled trials for hypertension. Thus, the use of ARBs has weaker evidence regarding mortality and morbidity outcomes, compared with ACE inhibitors.

A 54-year-old man is referred by his GP for routine cardioversion after a new diagnosis of atrial fibrillation. He has not required rate control. At presentation his heart rate is 75/min, AF, BP 142/82 mmHg. There are no signs of cardiac failure or respiratory tract infection.

Investigations:

Hb	12.9 g/dl
WCC	7.2×10^9/l
PLT	288×10^9/l
Na^+	141 mmol/l
K^+	4.2 mmol/l
Creatinine	130 µmol/l
TSH	3.1 U/l (<0.5-4.5)
Echocardiogram	Normal left atrial size, no significant valvular disease

Which of the following is the most appropriate plan with respect to his anti-coagulation, given the planned admission for cardioversion in 1 month?

A Aspirin and clopidogrel 6 weeks pre- and until 1 month after the procedure

B Low-molecular weight heparin for 72 h pre- and then 48 h post- the procedure

C Low-molecular weight heparin while being warfarinised, then continue warfarin for 6 months after the procedure

D Low-molecular weight heparin while being warfarinised, then continue warfarin for 1 year

PLT	288 × 10⁹/l
Na^+	141 mmol/l
K^+	4.2 mmol/l
Creatinine	130 μmol/l
TSH	3.1 U/l (<0.5-4.5)
Echocardiogram	Normal left atrial size, no significant valvular disease

Which of the following is the most appropriate plan with respect to his anti-coagulation, given the planned admission for cardioversion in 1 month?

A Aspirin and clopidogrel 6 weeks pre- and until 1 month after the procedure

B Low-molecular weight heparin for 72 h pre- and then 48 h post- the procedure

C Low-molecular weight heparin while being warfarinised, then continue warfarin for 6 months after the procedure

D Low-molecular weight heparin while being warfarinised, then continue warfarin for 1 year after the procedure

E Low-molecular weight heparin while being warfarinised, then review need for continued anti-coagulation at 1-month follow-up

Submit

E Low-molecular weight heparin while being warfarinised, then review need for continued anti-coagulation at 1-month follow-up

Evidence suggests that 1/3 of patients who are successfully cardioverted to sinus rhythm revert to atrial fibrillation during the first month after cardioversion. This puts them at significant risk of thromboembolic events. This patient is in a high potential success group because of his normal echocardiogram, with normal left atrial size and lack of significant valvular disease, and absence of other cardiac risk factors.

Warfarin takes several days to reach therapeutic levels, so he will need initial treatment with LMWH until this is achieved. He can then be maintained on warfarin until review at 1 month, when his anti-coagulation can be reassessed. If he is still in sinus rhythm and has no further symptoms of palpitations, anticoagulation can be discontinued.

A Aspirin and clopidogrel 6 weeks pre- and until 1 month after the procedure

Dual antiplatelet therapy (aspirin and clopidogrel) is not indicated for management of AF. It is used as secondary prevention in CVD following MI, CVE and angina.

B Low-molecular weight heparin for 72 h pre- and then 48 h post- the procedure

The short duration of treatment with this option, just 72 h pre- and 48 h post-procedure, would not be adequate given the high risk of developing a clot pending cardioversion. It would also make cardioversion in one month's time unsafe, as clots may have formed in the left atrium during the period of AF, which can dislodge at cardioversion causing CVE.

A 55 year old Indian male known to have ankylosing spondylitis is referred by his general practitioner for evaluation of a murmur. The patient has no history of chest pain, orthopnoea, paroxysmal nocturnal dyspnoea, pedal oedema or abdominal swelling. He is a lifelong non-smoker, has no family history of premature coronary artery disease and his lipid profile is normal. Apart from ankylosing spondylitis, he has no other past medical history of note. He takes no medications apart from occasional diclofenac for his back pain. Examination of the cardiovascular system reveals blood pressure 140/50 mmHg, bounding pulses at a rate of 88 beats/min, no jugular venous distension, apex beat at the 6th intercostal space that is diffuse and hyperdynamic, and a diastolic murmur at the left sternal edge. The lung fields are clear on auscultation and there is no pedal oedema.
An echocardiogram reveals severe aortic regurgitation (AR) and an ejection fraction (EF) of 45%.

What is the most appropriate management for this patient?

A	Start nifedipine and repeat echocardiography after 6 months
B	Start enalapril and repeat echocardiography after 6 months
C	Start enalapril and repeat echocardiography after 3 months
D	Start bisoprolol and repeat echocardiography after 3 months
E	Aortic valve replacement

pain, orthopnoea, paroxysmal nocturnal dyspnoea, pedal oedema or abdominal swelling. He is a lifelong non-smoker, has no family history of premature coronary artery disease and his lipid profile is normal. Apart from ankylosing spondylitis, he has no other past medical history of note. He takes no medications apart from occasional diclofenac for his back pain. Examination of the cardiovascular system reveals blood pressure 140/50 mmHg, bounding pulses at a rate of 88 beats/min, no jugular venous distension, apex beat at the 6th intercostal space that is diffuse and hyperdynamic, and a diastolic murmur at the left sternal edge. The lung fields are clear on auscultation and there is no pedal oedema.

An echocardiogram reveals severe aortic regurgitation (AR) and an ejection fraction (EF) of 45%.

What is the most appropriate management for this patient?

Your answer was correct

A	Start nifedipine and repeat echocardiography after 6 months
B	Start enalapril and repeat echocardiography after 6 months
C	Start enalapril and repeat echocardiography after 3 months
D	Start bisoprolol and repeat echocardiography after 3 months
E	Aortic valve replacement

Explanation

Although enalapril will have a positive impact on LV function and potentially reduce further valve deterioration, the patient has already reached the point where valve replacement is the only potential intervention.

C	Start enalapril and repeat echocardiography after 3 months

By this stage of valve deterioration, reducing pre-load with enalapril has little impact and delaying 3 months only prolongs the patient's symptoms whilst awaiting definitive intervention.

D	Start bisoprolol and repeat echocardiography after 3 months

Conventional teaching suggests that because beta blockade is not appropriate in the treatment of AR, this is best avoided here. Retrospective data do, however, suggest a mortality benefit associated with beta blockade, such that the contra-indication for beta blockade in AR may be challenged in the future.

© Pastest 2019

A 74-year-old lady is referred by her general practitioner (GP) to the Emergency Department for worsening shortness of breath over the past 3-4 weeks. She is a known patient with dilated cardiomyopathy who has been stabilised on medication. She is on furosemide 80 mg od, bisoprolol 5 mg od, ramipril 10 mg od, aspirin 75 mg od and atorvastatin 80 mg nocte.

On examination she is dyspnoeic, with blood pressure 120/60 mmHg and pulse 92/min, regular. She has grossly swollen oedematous legs and her jugular venous pressure is raised. On auscultation, first and second heart sounds ar heard and there is a grade III pan-systolic murmur radiatin to the axilla. Auscultation of her chest reveals bi-basal crackles.

Investigations:

Hb	12.1 g/dl
MCV	86 fl
WCC	8×10^9/l
PLT	288×10^9/l
Na^+	141 mmol/l
K^+	3.0 mmol/l
Urea	8.1 mmol/l
Creatinine	131 µmol/l
CXR	Enlarged heart and bilateral small pleural effusions
ECG	Left bundle branch block (LBBB)

What would be the most appropriate next step in the long-term management of her condition?

A Increase the dose of furosemide

Rana Alnasser's screen

Hb	12.1 g/dl
MCV	86 fl
WCC	8×10^9/l
PLT	288×10^9/l
Na^+	141 mmol/l
K^+	3.0 mmol/l
Urea	8.1 mmol/l
Creatinine	131 µmol/l
CXR	Enlarged heart and bilateral small pleural effusions
ECG	Left bundle branch block (LBBB)

What would be the most appropriate next step in the long-term management of her condition?

A Increase the dose of furosemide

B Start her on digoxin

C Start her on spironolactone

D Start her on dobutamine

E Urgent echocardiography

Submit

Heart failure has a uniformly poor prognosis. More money is spent on it than any other illness. Spironolactone would be a good choice in this case, because it would raise the potassium and help remove the excess fluids on board. The Randomized Aldactone Evaluation Study (RALES) showed that spironolactone in a small dose of 25 mg reduced mortality by 30% when added to conventional therapy.

A Increase the dose of furosemide

Furosemide would offload fluid, but it would reduce the potassium further and therefore it is not a good choice in this case as the potassium is already low.

B Start her on digoxin

Digoxin would not be a good choice in this case because the patient is in sinus rhythm and has mild hypokalaemia. Results of the Digitalis Investigation Group (DIG) trial showed no difference in survival between the treatment arm and placebo.

D Start her on dobutamine

This patient's blood pressure is adequate and fluid removal is important, and therefore dobutamine would not be the best choice.

E Urgent echocardiography

Urgent echocardiography would not help symptoms and is likely to show heart failure with fluid overload, as suggested by the cardiomegaly and bilateral pleural effusion on the chest X-ray. She is already known to have dilated cardiomyopathy.

A 21-year-old model attends his GP complaining of feeling unwell. His symptoms began within the previous 2–3 weeks and include tiredness and fatigue, fever, loss of appetite and weight loss, and general aches and pains over his body. He had delayed coming to see his GP since he thought it was a flu-like illness but his symptoms have been getting worse. He is otherwise medically fit and is not on any medication. He denies being a smoker and does not drink but does not give a forthright answer to a question about recreational drug use. The GP examines the patient thoroughly and notes a temperature of 38°C, tachycardia and the presence of a previously unrecorded cardiac murmur. A diagnosis of endocarditis is suspected and the GP immediately sets about obtaining the first set of blood cultures.

Which one of the following clinical features/investigations would most add credence to the suspected diagnosis?

A	Recent dental extraction
B	Normal ESR
C	Microscopic haematuria
D	Subconjunctival haemorrhages
E	Palmar erythema

Submit

C Microscopic haematuria

Most patients with endocarditis have evidence of vasculitis strongly associated with microscopic haematuria. Other vasculitic features include splinter haemorrhages, Osler's nodes (finger/toe pulp infarcts) and Janeway lesions (palmar/plantar macules). Patients may also be clubbed.

D Subconjunctival haemorrhages

Subconjunctival haemorrhages may occur for a number of reasons, including severe coughing, head injury and uncontrolled hypertension.

A Recent dental extraction

Dental extraction is common, and the vast majority of procedures are carried out with no sequelae. Risk of infection after dental extraction is increased in patients with a history of valvular disease.

B Normal ESR

Marked elevation in ESR is the norm for patients with bacterial endocarditis.

E Palmar erythema

Palmar erythema is associated with liver failure rather than with bacterial endocarditis.

32314

Rate this question:

A 59-year-old heavy goods vehicle driver was admitted to hospital with chest pain. An electrocardiogram (ECG) showed T-wave inversion in leads II, III and aVF. His pain settled within one hour and repeat electrocardiogram (ECG) was normal. A troponin T level after 12 hours was <0.05 μg/l (0–0.05). He underwent coronary angiography and had a stent to his right coronary artery. At angiography, the other coronary arteries were mildly stenosed. He was sent home 5 days post-admission.

What advice should have been given to him regarding driving?

A	Do not drive for one month
B	Do not drive the heavy goods vehicle until assessed by the DVLA. Car driving is permitted after one week if pain free
C	Inform the DVLA and do not drive until assessed further
D	He will never be able to drive heavy goods vehicle again but car driving permitted in one month if pain free
E	No restriction on driving

8535

Submit

B Do not drive the heavy goods vehicle until assessed by the DVLA. Car driving is permitted after one week if pain free

Car driving is permitted after one week if pain free, is correct. This is the correct response according to the DVLA guidelines. Car driving is allowed in 1 week if there is no urgent planned revascularisation and LVEF is >40% before discharge. If not treated by angioplasty, the patient must wait 1 month.

For Class 2 vehicles, driving may be permitted, by the DVLA, after six weeks, providing the exercise test requirements are met. For further information refer to DVLA website given below.

D He will never be able to drive heavy goods vehicle again but car driving permitted in one month if pain free

A Class 2 licence is at the discretion of DVLA (until after at least 6 weeks) and car driving should be 1 week after the event.

A Do not drive for one month

This is for patients with a Class 1 driving license who have not had successful coronary intervention.

C Inform the DVLA and do not drive until assessed further

This is for a Class 2 licence. The patient should still be able to drive Class 1 vehicles.

E No restriction on driving

D He will never be able to drive heavy goods vehicle again but car driving permitted in one month if pain free

A Class 2 licence is at the discretion of DVLA (until after at least 6 weeks) and car driving should be 1 week after the event.

A Do not drive for one month

This is for patients with a Class 1 driving license who have not had successful coronary intervention.

C Inform the DVLA and do not drive until assessed further

This is for a Class 2 licence. The patient should still be able to drive Class 1 vehicles.

E No restriction on driving

Car driving is allowed in a week if there is no urgent planned revascularisation and LVEF is >40% before discharge. For a Class 2 licence, the patient should be in contact with DVLA and not drive until relicensing after at least 6 weeks.

Rate this question:

A 72-year-old retired policeman comes to the Cardiology Clinic for follow-up for his heart failure. He had been hospitalised for the fourth time in 4 months for congestion Shortness of breath interrupts sleeping and any physical activity he tries to engage in. He has chronic coronary artery disease and had a quadruple by-pass 3 years ago. H is taking 120 mg furosemide, 125 mcg digoxin, 25 mg spironolactone, 10 mg ramipril and 10mg bisoprolol and fo his heart failure, and is being followed up on an advanced heart failure programme.

Investigations:

Na^+	125 mmol/l
K^+	5.5 mmol/l
eGFR	30 ml/min
CXR	Bilateral interstitial shadowing, cardiomegaly
Echocardiogram	Left ventricular ejection fraction 22% (normal 55–75%)

He expresses a willingness to try anything to feel better. Which of the following options would be the most likely beneficial treatment?

A	Increase spironolactone
B	Increase digoxin
C	No treatment would be useful because he is already on maximal medication
D	Left ventricular assist device
E	Stop rampril

D Left ventricular assist device

The Randomised Evaluation of Mechanical Assistance Therapy as an alternative in Congestive Heart failure (REMATCH) trial demonstrated 52% overall survival at 1 year in 68 non-transplantation candidates randomised to a left ventricular assist device. Subsequent 1-year survival in registries also centres around 50%. Outcomes are improving with device modifications and with strong emphasis on preventing infection. Therefore, of the options available, a left ventricular assist device is the most appropriate option.

A Increase spironolactone

A landmark study, 'RALES Trial', reported that the use of spironolactone in addition to standard medical therapy for patients with heart failure resulted in a reduction in mortality and hospitalization rate. Aldosterone antagonism with spironolactone is therefore considered for all patients with left ventricular ejection fraction of less than 35% and NYHA Class III-IV. However, a subsequent study showed that since this increased prescription of spironolactone there has been a rise in morbidity associated with hyperkalaemia. In this patient with renal impairment, because the potassium is already slightly elevated at 5.5 mmol/l, further increase in spironolactone may not confer additional benefit with larger increase in potassium, and therefore this is not the correct answer.

B Increase digoxin

Evidence from clinical trials supports the use of digoxin in heart failure with left ventricular systolic dysfunction, especially in patients with advanced symptoms. However, there is no evidence that digoxin improves survival. Digoxin is excreted by the kidneys; because there is renal impairment in this patient, increasing digoxin further may

1:28
On
594-042-7551
Leave

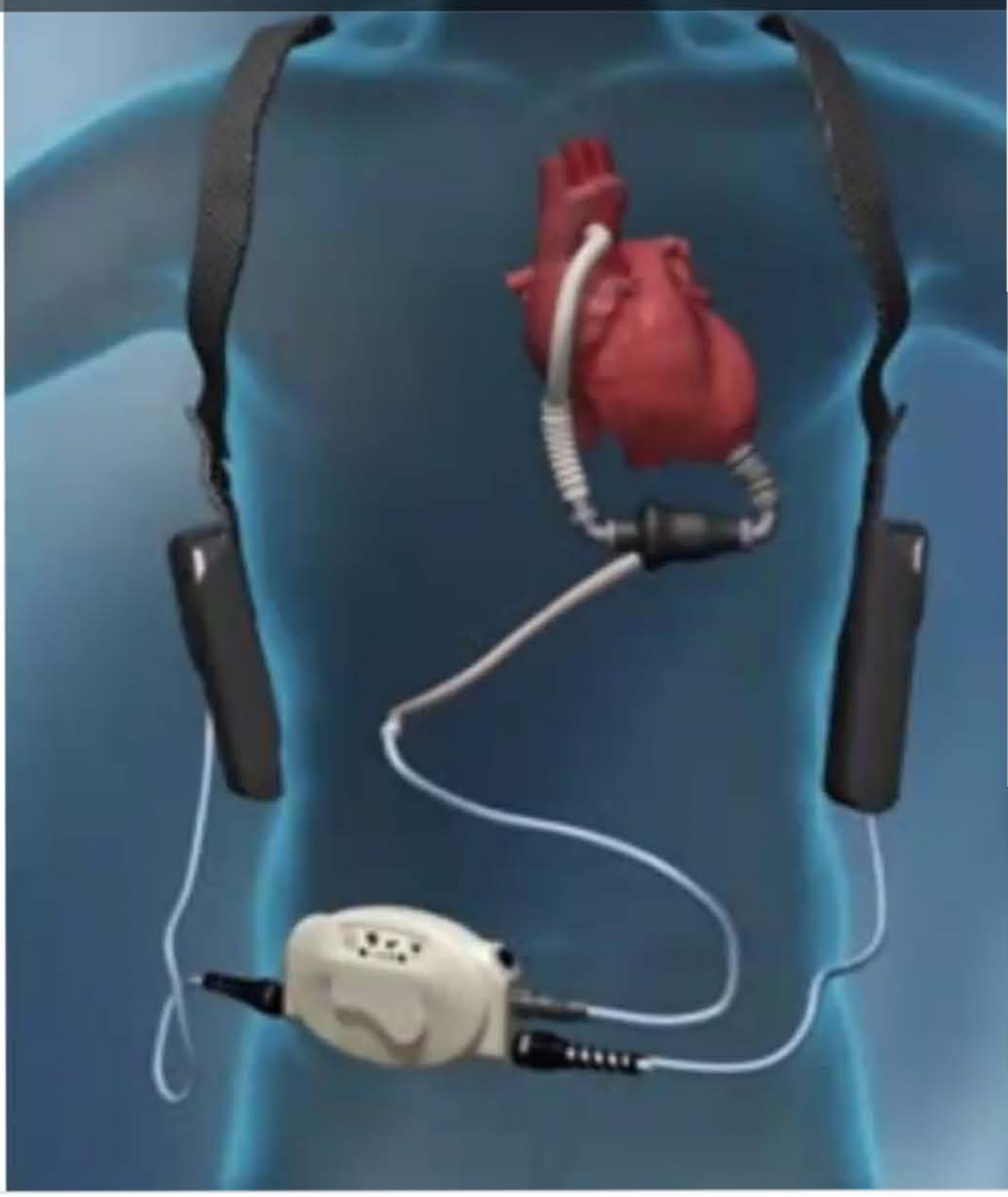

urgery

sist Device Options | Columbia University Department of

Device Options

bject to copyright. Learn more

s



Audio
Video
Share
Participants
More

1:29

MyPastest
https://mypastest.pastest.com

A 58-year-old man is brought into the Accident and Emergency Department of your University Hospital with a history of central crushing chest pain associated with weakness and diaphoresis.

He has no history of ischaemic heart disease but had a left carotid endarterectomy 10 months ago after an ischaemic stroke, from which he has almost fully recovered. He smokes 20 cigarettes/day. The patient was administered oxygen, aspirin and sublingual nitroglycerine (GTN) spray in the ambulance but has persistent pain. On examination, he has a pulse rate of 120/min, blood pressure is 140/90 mmHg.

Examination of the chest does not reveal any abnormality. His O_2 saturation is measured at 93%. A 12-lead electrocardiogram (ECG) reveals sinus tachycardia and ST-segment elevation suggestive of ischaemia in leads 1, aVL, V5 and V6. There is no history of haemorrhagic stroke, active internal bleeding, suspected aortic dissection, active peptic ulcer disease, major surgery within the past 3 weeks or recent trauma.

It is now 1 h since the onset of symptoms. You plan to take him to the Cardiac Catheter Lab for angioplasty. He has been treated with heparin and morphine and given aspirin by the paramedic crew.

Which one of the following treatments is likely to have the greatest impact on prognosis whilst awaiting transfer to the catheter lab?

A	Reperfusion therapy with a thrombolytic agent
B	Intravenous beta-blocker

Rana Alnasser's screen

He has no history of ischaemic heart disease but had a left carotid endarterectomy 10 months ago after an ischaemic stroke, from which he has almost fully recovered. He smokes 20 cigarettes/day. The patient was administered oxygen, aspirin and sublingual nitroglycerine (GTN) spray in the ambulance but has persistent pain. On examination, he has a pulse rate of 120/min, blood pressure is 140/90 mmHg.

Examination of the chest does not reveal any abnormality. His O_2 saturation is measured at 93%. A 12-lead electrocardiogram (ECG) reveals sinus tachycardia and ST-segment elevation suggestive of ischaemia in leads 1, aVL, V5 and V6. There is no history of haemorrhagic stroke, active internal bleeding, suspected aortic dissection, active peptic ulcer disease, major surgery within the past 3 weeks or recent trauma.

It is now 1 h since the onset of symptoms. You plan to take him to the Cardiac Catheter Lab for angioplasty. He has been treated with heparin and morphine and given aspirin by the paramedic crew.

Which one of the following treatments is likely to have the greatest impact on prognosis whilst awaiting transfer to the catheter lab?

A	Reperfusion therapy with a thrombolytic agent
B	Intravenous beta-blocker
C	ACE inhibitor
D	Ticagrelor
E	IV GTN

active internal bleeding, suspected aortic dissection, active peptic ulcer disease, major surgery within the past 3 weeks or recent trauma.

It is now 1 h since the onset of symptoms. You plan to take him to the Cardiac Catheter Lab for angioplasty. He has been treated with heparin and morphine and given aspirin by the paramedic crew.

Which one of the following treatments is likely to have the greatest impact on prognosis whilst awaiting transfer to the catheter lab?

Your answer was correct

A	Reperfusion therapy with a thrombolytic agent
B	Intravenous beta-blocker
C	ACE inhibitor
D	Ticagrelor
E	IV GTN

Explanation

D	Ticagrelor

Ticagrelor studies have demonstrated that in dual anti-platelet therapy for patients with STEMI it is associated with reduced risk of further MI or stent thrombosis compared to clopidogrel as the alternative. The PLATO study trialed a dose of 90 mg ticagrelor.

D Ticagrelor

Ticagrelor studies have demonstrated that in dual anti-platelet therapy for patients with STEMI it is associated with reduced risk of further MI or stent thrombosis compared to clopidogrel as the alternative. The PLATO study trialed a dose of 90 mg ticagrelor.

A Reperfusion therapy with a thrombolytic agent

It's clear from modern clinical practice that stenting is preferred to thrombolysis, and hence thrombolysis before PCI is not appropriate.

B Intravenous beta-blocker

Blood pressure may be unstable in the context of acute ischaemia; IV beta blockade is therefore not an interventio of choice in this situation.

C ACE inhibitor

For similar reasons to avoiding IV beta-blockers, ACE inhibitors are avoided in the acute period after an infarct.

E IV GTN

Although GTN may relieve ischaemia and lead to periphera vasodilatation, resulting in symptom relief, it has less of an impact on prognosis than dual anti-platelet therapy.

Rate this question:

Next Question

A 65-year-old man, known to have rheumatoid arthritis, presents with a 2-month history of breathlessness and orthopnoea. He initially presented to his general practitioner (GP), who diagnosed a chest infection and prescribed a course of antibiotic treatment that had helped his breathlessness; however, his symptoms soon returned.

He comes to see you today in clinic. He gives no history of rheumatic fever, tuberculosis or chest pain. His only medication is co-dydramol for pain relief.

On examination, you find classical arthritic small joint changes and distended neck veins. He is breathless at rest and has normal heart sounds, with ascites and ankle oedema. There are bibasal lung crepitations posteriorly.

You arrange admission for this man. His blood tests are normal; an electrocardiogram (ECG) shows sinus rhythm. A transthoracic echocardiogram reports global biventricular failure, with gross biatrial dilatation. There is a high-intensity echo signal around the heart.

He is treated for heart failure with intravenous (IV) furosemide and fluid restriction, and he has a good response.

What further investigation is most likely to determine the underlying diagnosis?

A	Left heart catheterisation and myocardial biopsy
B	Left and right heart catheterisation with pressure studies
C	Transoesophageal echocardiography (TOE)
D	Mantoux testing
E	Surgical pericardial biopsy

E Surgical pericardial biopsy

Treatment for this patient consists of treating both the heart failure and the underlying cause of the constrictive pericarditis (portrayed by the echocardiogram finding of a high-intensity signal around the heart), hence the need for pericardial biopsy and examination of the tissue.

A Left heart catheterisation and myocardial biopsy

This is a case of constrictive pericarditis. This is suggested by calcification of the pericardium on lateral chest X-rays, and typical echo findings. Neither left heart catheterisation nor myocardial biopsy are going to add useful information to the diagnosis.

B Left and right heart catheterisation with pressure studies

Right and left heart catheterisation will demonstrate equal left and right ventricular and right atrial pressures, confirming constrictive pericarditis. However, pressure studies will not help identify the underlying cause of the constrictive pericarditis.

C Transoesophageal echocardiography (TOE)

The advantage of TOE over transthoracic echocardiography (TTE) is clearer images, especially of structures that are difficult to view through the chest wall such as the aorta, pulmonary artery, valves of the heart and atria. TOE, in particular, has a much higher sensitivity for locating a blood clot inside the left atrium. TOE would not be of help in determining the underlying pathology of the pericardial disease.

D Mantoux testing

constrictive pericarditis.

C Transoesophageal echocardiography (TOE)

The advantage of TOE over transthoracic echocardiography (TTE) is clearer images, especially of structures that are difficult to view through the chest wall such as the aorta, pulmonary artery, valves of the heart and atria. TOE, in particular, has a much higher sensitivity for locating a blood clot inside the left atrium. TOE would not be of help in determining the underlying pathology of the pericardial disease.

D Mantoux testing

Constrictive pericarditis is suggested by calcification of the pericardium on lateral chest X-rays, and typical echo findings.

The Mantoux test is used for the screening and diagnosis of tuberculosis (TB). Even though TB is a well-recognised cause of constrictive pericarditis, an isolated positive Mantoux test would not be enough to reach that diagnosis

Rate this question:

Next Question

Previous Q... Tag Questi... Feedback End Session

Blog About Pastest Contact Us Help

© Pastest 2019

A 78-year-old man presents to the cardiology clinic for review. For the past 2 years he has suffered dull, aching chest pains and reduced exercise tolerance, having to cut the length of his dog walk from 3 to 2 miles, missing out a steep hill at the end. There is no chest pain at rest. When he gets pain on exercise it settles when he rests for 3-4 minutes. He is an ex- smoker, having given up 20 years ago and has a history of hypertension for which he takes ramipril and indapamide. His GP has also prescribed aspirin 75 mg OD and atorvastatin 10 mg ON. Apparently he tried a GTN spray but this gave him a headache. Examination reveals a blood pressure of 142/85 mmHg, with pulse 80/min and regular. His chest is clear and there is no peripheral oedema. He has a BMI of 24kg/m^2.

Investigations:

Hb	13.1 g/dl
WCC	8.0 x10^9/l
PLT	178 x10^9/l
Na^+	137 mmol/l
K^+	5.0 mmol/l
Creatinine	112 micromol/l
Total cholesterol	4.1 mmol/l
CXR	Unremarkable

Which of the following is the most appropriate intervention to manage his chest pain?

A Bisoprolol

B Diltiazem

C Isosorbide mononitrate – sustained release

peripheral oedema. He has a BMI of 24kg/m^2.

Investigations:

Hb	13.1 g/dl
WCC	8.0 x10^9/l
PLT	178 x10^9/l
Na^+	137 mmol/l
K^+	5.0 mmol/l
Creatinine	112 micromol/l
Total cholesterol	4.1 mmol/l
CXR	Unremarkable

Which of the following is the most appropriate intervention to manage his chest pain?

A Bisoprolol

B Diltiazem

C Isosorbide mononitrate – sustained release

D Ivabradine

E Nicorandil

40248

Submit

Explanation

A Bisoprolol

This patient presents with features strongly suggestive of angina. NICE guidance on chest pain of recent onset suggests that such patients (with typical angina symptoms) should undergo CT coronary angiography. However, in the meantime treatment should be initiated. NICE guidance for stable angina supports the use of β-blockade for symptomatic and prognostic benefit.

B Diltiazem

Calcium channel blockers are second-line agents in the treatment of stable angina and should be considered in patients intolerant to β-blockade.

C Isosorbide mononitrate – sustained release

sosorbide mononitrate is a long-acting nitrate and is a treatment option considered if both β-blockers and calciur channel blockers are contraindicated or not tolerated. This option could also be considered as a third agent if symptoms are not controlled using both β-blockade and a calcium channel blocker combined.

D Ivabradine

Ivabradine acts by blocking the I_f current primarily located in the sino-atrial node. This leads to a reduced heart rate and lowers myocardial oxygen demand. Much like long-acting nitrates, ivabradine can be considered if both β-blockers and calcium channel blockers are contra-indicated, not tolerated or insufficient to manage the patient symptoms. Of note, ivabradine is only effective in patients in sinus rhythm and should not be initiated in patients in atrial fibrillation.

sosorbide mononitrate is a long-acting nitrate and is a treatment option considered if both β-blockers and calciur channel blockers are contraindicated or not tolerated. This option could also be considered as a third agent if symptoms are not controlled using both β-blockade and a calcium channel blocker combined.

D Ivabradine

Ivabradine acts by blocking the I_f current primarily located in the sino-atrial node. This leads to a reduced heart rate and lowers myocardial oxygen demand. Much like long-acting nitrates, ivabradine can be considered if both β-blockers and calcium channel blockers are contra-indicated, not tolerated or insufficient to manage the patient symptoms. Of note, ivabradine is only effective in patients in sinus rhythm and should not be initiated in patients in atrial fibrillation.

E Nicorandil

Nicorandil acts as a vasodilator and can be considered for the treatment of angina. It has the same indications as long-acting nitrates and should be considered if β-blockad and/or calcium channel blockade is contraindicated, not tolerated or ineffective.

Rate this question:

A 70-year-old known diabetic is referred to the Rapid Access Clinic by his general practitioner (GP) because of a 3-month history of intermittent palpitations. He describes these as fast and irregular and of sudden onset and termination. He has felt quite light-headed on a couple of occasions during these palpitations, but denies any chest pain or shortness of breath. The general practitioner (GP) mentions in the referral letter that he has a borderline high blood pressure and was recently started on ramipril. Examination reveals a blood pressure of 145/95 mmHg but is otherwise unremarkable.
A routine electrocardiogram (ECG) shows sinus rhythm with left ventricular hypertrophy.

Investigations:

Hb	13.1 g/dl
WCC	5.6×10^9/l
PLT	253×10^9/l
Na^+	136 mmol/l
K^+	4.8 mmol/l
Urea	5.0 mmol/l
Creatinine	99 μmol/l
TSH	3 mU/l

A 24 h ECG reveals episodes of paroxysmal atrial fibrillation (PAF). An echocardiogram shows concentric hypertrophy with mild impairment of left ventricular function, dilated left atrium and no significant valvular pathology.

Which one of the following would be the intervention of choice?

Examination reveals a blood pressure of 145/95 mmHg but is otherwise unremarkable.

A routine electrocardiogram (ECG) shows sinus rhythm with left ventricular hypertrophy.

Investigations:

Hb	13.1 g/dl
WCC	5.6×10^9/l
PLT	253×10^9/l
Na^+	136 mmol/l
K^+	4.8 mmol/l
Urea	5.0 mmol/l
Creatinine	99 µmol/l
TSH	3 mU/l

A 24 h ECG reveals episodes of paroxysmal atrial fibrillation (PAF). An echocardiogram shows concentric hypertrophy with mild impairment of left ventricular function, dilated left atrium and no significant valvular pathology.

Which one of the following would be the intervention of choice?

A Flecainide

B Bisoprolol

C Digoxin

D Amiodarone

E Verapamil

A 70-year-old known diabetic is referred to the Rapid Access Clinic by his general practitioner (GP) because of a 3-month history of intermittent palpitations. He describes these as fast and irregular and of sudden onset and termination. He has felt quite light-headed on a couple of occasions during these palpitations, but denies any chest pain or shortness of breath. The general practitioner (GP) mentions in the referral letter that he has a borderline high blood pressure and was recently started on ramipril. Examination reveals a blood pressure of 145/95 mmHg but is otherwise unremarkable.
A routine electrocardiogram (ECG) shows sinus rhythm with left ventricular hypertrophy.

Investigations:

Hb	13.1 g/dl
WCC	5.6×10^9/l
PLT	253×10^9/l
Na^+	136 mmol/l
K^+	4.8 mmol/l
Urea	5.0 mmol/l
Creatinine	99 µmol/l
TSH	3 mU/l

A 24 h ECG reveals episodes of paroxysmal atrial fibrillation (PAF). An echocardiogram shows concentric hypertrophy with mild impairment of left ventricular function, dilated left atrium and no significant valvular pathology.

Which one of the following would be the intervention of choice?

Your answer was correct

B Bisoprolol

A beta-blocker can limit the episodes of PAF and achieve rate control during the episodes, as well as being beneficia for blood pressure control and left ventricular impairment, and is the treatment of choice if there are no contraindications. It is recommended by NICE guidance.

A Flecainide

Flecainide is contraindicated in patients with structural abnormalities and at high risk of ischaemic heart disease, and is therefore not an option. It is usually considered only in younger patients with no evidence of IHD and acute-onset AF.

C Digoxin

Digoxin does not maintain sinus rhythm in paroxysmal atrial fibrillation, and doesn't confer prognostic benefit in IHD. As such, it doesn't have a role here.

D Amiodarone

Amiodarone isn't indicated here for long-term use because of its adverse event profile, including photosensitisation, lung fibrosis and thyroid function test abnormalities.

E Verapamil

Verapamil is a second-choice option for rate control of AF if other options such as bisoprolol are unsuitable or contraindicated.

A 42-year-old adopted man presents with symptoms of angina and intermittent claudication. On examination he is obese and has evidence of tendon xanthomas. Lipid profiling reveals a low-density lipoprotein cholesterol level of 8.2 mmol/l, with normal triglyceride levels.

Which of the following is the first step in his lipid management?

A	Fenofibrate
B	Atorvastatin
C	Ezetimibe
D	Evolocumab
E	Nicotinic acid

Submit

Previous Q...

Skip Questi...

© Pastest 2019

B Atorvastatin

This patient has markedly raised low-density lipoprotein cholesterol (LDL-c) levels and almost certainly has heterozygous familial hypercholesterolaemia (FH). Prognosis in these patients depends on reducing LDL-c to as near normal levels as possible, and treating other risk factors such as smoking and hypertension as aggressively as possible. The dose of atorvastatin should be titrated to the maximum tolerated or 80 mg/day, whichever is greate

A Fenofibrate

Fibrates are the intervention of choice for familial hypertriglyceridaemia, rather than hypercholesterolaemia.

C Ezetimibe

Ezetimibe can further reduce LDL cholesterol on top of statins alone and is therefore the default oral add-in therapy for patients not at target cholesterol.

D Evolocumab

Evolocumab is a PCSK9 inhibitor that can significantly reduce LDL cholesterol and achieve target levels in patients unable to attain them on statins alone. It is given as a 2-weekly or monthly injectable therapy, and is usually second or third line in the management of FH.

E Nicotinic acid

Nicotinic acid is most useful in reducing elevated triglycerides, not LDL cholesterol.

Rate this question:

A 26-year-old man comes to the cardiology clinic for review. He is concerned as his father died suddenly some 6 weeks earlier at the age of 52, and was found on post mortem to have evidence of hypertrophic obstructive cardiomyopathy, (HOCM). On examination, his BP is 145/85 mmHg, pulse is 78/min and regular. The apex beat is displaced laterally and there is an ejection systolic murmur

Which of the following ECG findings would most support diagnosis of HOCM?

A	Anterior Q waves
B	Inferior T wave inversion
C	P mitrale
D	P pulmonale
E	Right bundle branch block

Submit

Previous Q... Skip Questi...

© Pastest 2019

Explanation

E Right bundle branch block

The presence of RBBB is correlated with anterior, anteroseptal and mid-septal myocardial fibrosis in HOCM. ECG changes seen in HOCM include right or left axis deviation, bundle branch block, PR prolongation, and non specific T wave abnormalities, although these are more commonly seen in anterior leads.

A Anterior Q waves

Anterior Q waves is indicative of previous full thickness infarct of the anterior wall. In HOCM, the presence of Q waves is more typically in inferolateral leads.

B Inferior T wave inversion

Inferior T wave inversion is more in keeping with ischemia along the inferior wall of the LV.

C P mitrale

P mitrale is associated with left atrial enlargement.

D P pulmonale

P pulmonale is associated with pulmonary disease as the name suggests.

Rate this question:

Next Question

A 73-year-old woman comes for review in cardiology clinic with her husband. He is very worried because she passed out after getting out of her chair to go to the toilet. He reports that she went pale and then collapsed, hitting her head on the floor. She had around 20-30 seconds of twitching and was incontinent of urine. She has a history of hypertension for which she takes ramipril 5 mg daily. Her BP in the clinic is 155/90 mmHg; otherwise cardiovascular examination is unremarkable. Neurological examination is entirely normal.

Investigations:

Hb	13.1 g/dl
WCC	5.4×10^9/l
PLT	201×10^9/l
Na^+	140 mmol/l
K^+	4.4 mmol/l
Creatinine	130 μmol/l
Resting ECG	Old inferior infarct, otherwise normal
CXR	Slight cardiomegaly but nil else of note

Which of the following investigations is most likely to reveal the underlying cause of her collapse?

A 72 h ECG monitoring

B Tilt table test

C CT head

D 24 h BP recording

E ECG

B Tilt table test

The history here is typical of orthostatic hypotension. The twitching and incontinence witnessed by her husband are most likely related to the syncopal event, rather than a primary neurological problem. The tilt table allows for very accurate measurement of pulse and blood pressure moving from a supine to a standing position. Tilt table testing will reveal bradycardic or hypotensive carotid body syndrome, which can then be managed with appropriate intervention.

A 72 h ECG monitoring

This is used to investigate cardiac arrhythmias, which may present with syncope similar to that described above. It does not provide any information about blood pressure, which is key to identifying the cause of this lady's postural symptoms.

C CT head

It would be tempting to perform a CT scan of this lady's head given the history of head injury and preceding loss of consciousness, with some features suggestive of seizure activity. In this case it would not play any diagnostic role.

D 24 h BP recording

This is usually used in the diagnosis of hypertension, where recordings in the GP surgery or clinic are variable and unreliable. It may well identify this lady's postural drop, but would not be the most efficient way to do this.

E EEG

This is used to diagnose epilepsy. The clinical scenario described here does not suggest that this lady is having

A 28-year-old IV heroin abuser is admitted to the Emergency Department. He has been suffering from fevers for the past few days and is feeling very unwell. There is a history of a flu-like illness which resolved about a week ago. On further questioning he admits to problems finding an injecting site and has recently taken to using groin vessels. On examination he looked emaciated, with a BMI calculated at 16. Cardiovascular examination reveals a murmur consistent with pulmonary regurgitation. Respiratory examination suggested pockets of infection consistent with pneumonia.

Investigations:

Hb	10.1 g/dl
MCV	97 fl
WCC	11.2 $\times 10^9$/l (Neut 8.2 $\times 10^9$/l)
Na^+	135 mmol/l
K^+	5.4 mmol/l
Creatinine	185 µmol/l
Urea	10.1 mmol/l
ESR	87 mm/1st hr
CXR	Multiple areas of patchy consolidation consistent with pneumonia with abscess formation

Which of the following is the most likely diagnosis in this case?

A *Klebsiella* pneumonia

B *Streptococcus pneumoniae* pneumonia

C *Streptococcus bovis* endocarditis

calculated at 16. Cardiovascular examination reveals a murmur consistent with pulmonary regurgitation. Respiratory examination suggested pockets of infection consistent with pneumonia.

Investigations:

Hb	10.1 g/dl
MCV	97 fl
WCC	11.2 $\times 10^9$/l (Neut 8.2 $\times 10^9$/l)
Na^+	135 mmol/l
K^+	5.4 mmol/l
Creatinine	185 µmol/l
Urea	10.1 mmol/l
ESR	87 mm/1st hr
CXR	Multiple areas of patchy consolidation consistent with pneumonia with abscess formation

Which of the following is the most likely diagnosis in this case?

A *Klebsiella* pneumonia

B *Streptococcus pneumoniae* pneumonia

C *Streptococcus bovis* endocarditis

D *Staphylococcus aureus* endocarditis

E *Pseudomonas* endocarditis

D *Staphylococcus aureus* endocarditis

The most likely diagnosis is *S. aureus* endocarditis. This man is an IV drug abuser, with evidence of poor injection technique and right-sided valvular disease. Often right-sided endocarditis leads to septic emboli distributed via the pulmonary vasculature, and the chest X-ray findings would be consistent with this. In contrast, left-sided endocarditis is more commonly associated with embolic phenomena involving the periphery, such as the toes or even with emboli affecting the renal or cerebral vasculature. Diagnosis is based on the collection of multiple blood cultures (at least three), and imaging of affected valves via echocardiography. Choice of antibiotics depends upon local policy, but a regime suitably targeted against *S. aureus* would be appropriate in this case.

A *Klebsiella* pneumonia

This condition is most commonly seen in those with underlying conditions such as alcoholism, diabetes or COPD. It is associated with sputum production, which features haemoptysis more commonly than other bacterial pneumonias. CXR changes are most commonly seen in the upper lobes.

B *Streptococcus pneumoniae* pneumonia

The presence of abscesses makes this a less likely diagnosis, and it does not explain the patient's murmur.

C *Streptococcus bovis* endocarditis

This organism is most commonly isolated in patients with colon cancer.

1:52

A 76-year-old man with a history of chronic asthma managed with high-dose seretide comes to the A&E complaining of palpitations. He has felt very faint, with shortness of breath for the past 30 min. Two further episodes occur during his time in the Emergency Department, documented as fast atrial fibrillation. By the time you examine him his BP is 135/80 mmHg, with pulse 80/min regular. ECG at that time reveals sinus rhythm with evidence of lateral ST depression.

Which of the following is the most appropriate treatment for him to control his ventricular rate?

A Bisoprolol

B Amiodarone

C Ivabradine

D Verapamil

E Adenosine

Submit

Previous Q... Skip Questi...

Rana Alnasser's screen

A 76-year-old man with a history of chronic asthma managed with high-dose seretide comes to the A&E complaining of palpitations. He has felt very faint, with shortness of breath for the past 30 min. Two further episodes occur during his time in the Emergency Department, documented as fast atrial fibrillation. By the time you examine him his BP is 135/80 mmHg, with pulse 80/min regular. ECG at that time reveals sinus rhythm with evidence of lateral ST depression.

Which of the following is the most appropriate treatment for him to control his ventricular rate?

Your answer was incorrect

A	Bisoprolol
B	Amiodarone
C	Ivabradine
D	Verapamil
E	Adenosine

Explanation

D Verapamil

Verapamil is a non-dihydropridine calcium antagonist which is an appropriate choice to obtain long-term ventricular rate control.

D Verapamil

Verapamil is a non-dihydropridine calcium antagonist which is an appropriate choice to obtain long-term ventricular rate control.

A Bisoprolol

Beta blockers should be used with caution in patients with asthma, and this is therefore not the most appropriate option for this patient.

B Amiodarone

Amiodarone, while a highly effective anti-arrhythmic agent, is limited by long-term systemic side effects, and current guidelines recommend use of other anti-arrhythmic agents as first line before the introduction of amiodarone.

C Ivabradine

This is a 'funny channel' blocker used in the management of angina and heart failure. It has been used off-licence in treatment of atrial fibrillation but is not recommended under current guidelines (which in fact state that use of ivabradine has been associated with increased rates of atrial fibrillation).

E Adenosine

Adenosine is a short-acting agent which serves to cause a transient AV block. It can be useful in terminating transient tachy-arrhythmias, and in the diagnosis of the underlying rhythm in cases of SVT of uncertain aetiology. It would not be the most appropriate choice as prophylactic agent here.

Rate this question:

You asked to evaluate a pregnant female in the obstetrics department who has been complaining of severe shortness of breath for the last 5 h. She was admitted one day earlier, in her 30th week of gestation for premature labour. She was started on intravenous terbutaline and had been doing well. About 6 h ago she started complaining of shortness of breath that has been progressively worsening. She denies any chest pain, palpitations or lower limb pain and swelling. She has no past medical history of note and her prenatal examination had been normal.

Physical examination reveals a dyspnoeic lady with respiratory rate of 25/minute, blood pressure 115/90 mmHg, and pulse 122/minute. She has jugular venous distension and bilateral diffuse inspiratory crackles.

Investigations reveal:

White cell count	11×10^9/l
Hemoglobin	12 g/dl
Platelet	660×10^9/l
Electrocardiogram (ECG)	Sinus tachycardia
Chest X-ray	Bilateral alveolar type infiltrates and normal cardiothoracic ratio

Which of the following is most likely diagnosis?

A Mitral stenosis

B Myocarditis

C Peripartum cardiomyopathy

D Pulmonary embolism

in her 30th week of gestation for premature labour. She was started on intravenous terbutaline and had been doing well. About 6 h ago she started complaining of shortness of breath that has been progressively worsening. She denies any chest pain, palpitations or lower limb pain and swelling. She has no past medical history of note and her prenatal examination had been normal.

Physical examination reveals a dyspnoeic lady with respiratory rate of 25/minute, blood pressure 115/90 mmHg, and pulse 122/minute. She has jugular venous distension and bilateral diffuse inspiratory crackles.

Investigations reveal:

White cell count	11×10^9/l
Hemoglobin	12 g/dl
Platelet	660×10^9/l
Electrocardiogram (ECG)	Sinus tachycardia
Chest X-ray	Bilateral alveolar type infiltrates and normal cardiothoracic ratio

Which of the following is most likely diagnosis?

A Mitral stenosis

B Myocarditis

C Peripartum cardiomyopathy

D Pulmonary embolism

E Tocolysis-associated pulmonary oedema

E Tocolysis-associated pulmonary oedema

Tocolytics are medications administered for the suppression of premature contractions. Acute pulmonary oedema can occur with administration of β_2 agonists for tocolysis in up to 5–15% of cases. It usually occurs after 24 h of administration of these agents. The chest X-ray reveals pulmonary infiltrates and normal heart size. Concomitant use of corticosteroids that are often administered for lung maturation have also been implicated as risk factor for development of tocolysis-associated pulmonary oedema. Treatment involves stopping the tocolytics, oxygen and careful volume control.

A Mitral stenosis

As the patient's examination was normal prior to this event, mitral stenosis is less likely. A mitral stenosis murmur will present with an loud first heart sound which may be palpable because of the increased force in closing the mitral valve. An opening snap that is a high pitched sound heard after second heart sound may be heard. There is a mid-diastolic rumbling murmur with presystolic accentuation heard after the opening snap.

B Myocarditis

Myocarditis cause systolic dysfunction and will be expected to show cardiomegaly on chest X-ray. Other symptoms of myocarditis will include fever, sweats, chills and shortness of breath. In viral myocarditis there is typically a 1-2 week history of preceeding flulike symptoms of fevers, arthralgia and malaise with pharyngitis, tonsillitis or upper respiratory tract symptoms.

C Peripartum cardiomyopathy

Peripartum cardiomyopathy cause systolic dysfunction and

Myocarditis cause systolic dysfunction and will be expected to show cardiomegaly on chest X-ray. Other symptoms of myocarditis will include fever, sweats, chills and shortness of breath. In viral myocarditis there is typically a 1-2 week history of preceeding flulike symptoms of fevers, arthralgia and malaise with pharyngitis, tonsillitis or upper respiratory tract symptoms.

C Peripartum cardiomyopathy

Peripartum cardiomyopathy cause systolic dysfunction and will be expected to show cardiomegaly on chest X-ray. Peripartum cardiomyopathy typically presents in the last month of pregnancy and up-to 6 months postpartum.

D Pulmonary embolism

Pulmonary embolism is unlikely to cause bilateral chest infiltrates. Symptoms of pulmonary embolism include haemoptysis, pleuritic chest pain, tachycardia and tachypnoea.

Rate this question:

Next Question

Previous Q... Tag Questi... Feedback End Session

Blog About Pastest Contact Us Help

© Pastest 2019

A 74-year-old hypertensive man is referred by his general practitioner (GP) to the cardiology department with a diastolic murmur that was picked up incidentally during one of his regular reviews. He denies any symptoms of angina, shortness of breath or palpitations. He is on bendrofluazide and ramipril for his hypertension, but no other medications. There is no past medical history of note. On examination he is comfortable at rest with a blood pressure of 155/65 mmHg and a heart rate of 85 beats/min. He has a heaving precordium on palpation and there is a diastolic murmur at the left sternal edge which is present for half of diastole.
His electrocardiogram (ECG) shows sinus rhythm with left ventricular hypertrophy (LVH).

An echocardiogram shows a dimensionally normal left ventricle with good function. There is moderate aortic regurgitation and no other significant valve pathology.

Which one of the following should form part of this patient's management?

A	Coronary angiography
B	Annual echocardiographic follow-up
C	Beta-blocker therapy
D	Antibiotic prophylaxis advice
E	Outpatient 24 h ECG

Submit

2:04

A 74-year-old hypertensive man is referred by his general practitioner (GP) to the cardiology department with a diastolic murmur that was picked up incidentally during one of his regular reviews. He denies any symptoms of angina, shortness of breath or palpitations. He is on bendrofluazide and ramipril for his hypertension, but no other medications. There is no past medical history of note. On examination he is comfortable at rest with a blood pressure of 155/65 mmHg and a heart rate of 85 beats/min. He has a heaving precordium on palpation and there is a diastolic murmur at the left sternal edge which is present for half of diastole.
His electrocardiogram (ECG) shows sinus rhythm with left ventricular hypertrophy (LVH).

An echocardiogram shows a dimensionally normal left ventricle with good function. There is moderate aortic regurgitation and no other significant valve pathology.

Which one of the following should form part of this patient's management?

Your answer was correct

A	Coronary angiography
B	Annual echocardiographic follow-up
C	Beta-blocker therapy
D	Antibiotic prophylaxis advice
E	Outpatient 24 h ECG

Explanation

B Annual echocardiographic follow-up

Rana Alnasser's screen

2:04
https://mypastest.pastest.com

Explanation

B Annual echocardiographic follow-up

This patient has asymptomatic moderate aortic regurgitation (AR) with no signs of left ventricular failure, and therefore does not have any indications for surgery at this time. Patients with AR require regular echocardiographic follow-up to assess the state of the left ventricle, as symptoms develop quite late in the course of the disease. Elective valve replacement is indicated in patients who develop limiting symptoms, and in asymptomatic patients with evidence of progressive LV dilatation on echocardiography. Emergency valve replacement should be considered in patients with severe acute AR usually due to endocarditis.

A Coronary angiography

In the context of valvular disease, coronary angiography is indicated for the detection of associated coronary artery disease when surgery is planned. It may not be indicated before surgery in young patients with no atherosclerotic risk factors, or in rare circumstances when the risk of doing coronary angiography outweighs benefit. This patient has asymptomatic moderate aortic regurgitation (AR) with no signs of left ventricular failure, and therefore surgery is not indicated at this time. Coronary angiography would, therefore, not be appropriate.

C Beta-blocker therapy

This patient has asymptomatic moderate aortic regurgitation (AR) with no signs of left ventricular failure. Beta-blockade may significantly impact cardiac function, and so angiotensin-converting enzyme (ACE) inhibitors are

Rana Alnasser's screen

prevent left ventricular (LV) dilatation in the longer term.

D	Antibiotic prophylaxis advice

Patients with acquired valvular heart disease are at increased risk of developing infective endocarditis (IE) and, previously, these patients were given antibiotic prophylaxis before dental and certain non-dental procedures, such procedures involving the upper and lower gastrointestinal tract. However, antibiotic prophylaxis is no longer recommended by NICE, and therefore advice on antibiotic prophylaxis would not be appropriate. However, advice on good oral hygiene and the symptoms that may indicate infective endocarditis would be.

E	Outpatient 24 h ECG

This patient has asymptomatic moderate aortic regurgitation (AR) with no signs of left ventricular failure. An outpatient 24 h ECG is not indicated in this patient. However, an ECG would have been carried out, initially, alongside a clinical examination of the patient.

Rate this question:

Next Question

Previous Q... Tag Questi... Feedback End Session

Blog About Pastest Contact Us Help

© Pastest 2019

A 23-year-old woman is admitted to the Emergency Department for the second time in a month with a syncopal episode. She admits to tiredness, which has increased over the past few months, and says that she has never been keen on physical activity, even at school, because of muscle cramps and easy fatigue. Apparently, one other relative has similar symptoms.

Examination reveals a blood pressure (BP) of 100/60 mmHg, with pulse 85/min and regular. There is a postural drop of 10 mmHg on standing. Her BMI is 22.

Investigations:

Hb	13.0 g/dl
WCC	5.6×10^9/l
PLT	222×10^9/l
Na^+	137 mmol/l
K^+	2.9 mmol/l
Creatinine	90 micromol/l
Bicarbonate	33 mmol/l
Glucose	4.3 mmol/l

Which of the following is the most likely diagnosis?

A Bartter syndrome

B Classical congenital adrenal hyperplasia

C Conn syndrome

D Cushing syndrome

E Gitelman syndrome

mmHg, with pulse 85/min and regular. There is a postural drop of 10 mmHg on standing. Her BMI is 22.

Investigations:

Hb	13.0 g/dl
WCC	5.6×10^9/l
PLT	222×10^9/l
Na^+	137 mmol/l
K^+	2.9 mmol/l
Creatinine	90 micromol/l
Bicarbonate	33 mmol/l
Glucose	4.3 mmol/l

Which of the following is the most likely diagnosis?

Your answer was correct

A Bartter syndrome

B Classical congenital adrenal hyperplasia

C Conn syndrome

D Cushing syndrome

E Gitelman syndrome

Explanation

E Gitelman syndrome

Gitelman syndrome is a genetic disorder inherited in an autosomal-recessive manner. It presents with hypokalaemia, hypomagnesaemia and a metabolic alkalosis. The mutation causing this condition results in a loss of function of the Na-Cl symporter in the distal convoluted tubule of the kidney. This history provides clues to the genetic nature of the diagnosis by highlighting other relatives with the same symptoms.

A Bartter syndrome

This is a condition characterised by hypokalaemia, metabolic alkalosis and hypotension, as seen here. However, typically Bartter syndrome presents in childhood making the diagnosis less likely here.

B Classical congenital adrenal hyperplasia

This is an autosomal recessive genetic disorder in which the production of mineralocorticoids is impaired. This leads to hyperkalaemia as well as significant dehydration from salt-wasting. Further virilisation is a key presenting feature, resulting from increased production of excessive sex steroids. These symptoms typically present in childhood.

C Conn syndrome

This is the eponymous name for primary hyperaldosteronism, in which excess aldosterone is released from the adrenal gland. This leads to hypokalaemia. Unlike this clinical scenario, Conn syndrome presents with hypertension.

D Cushing syndrome

This results from excess corticosteroids and can lead to hypokalaemia. However, typically patients develop obesity

You are a CT2 at a district general hospital. You are on call as the middle grade cover because the registrar has gone home sick. You are called to the resuscitation department to see a 71-year-old man who collapsed at home. His wife called the ambulance, but on arrival of the ambulance crew the patient was alert; she has not travelled to the hospital with her husband. The paramedics report the initial rhythm strip showed sinus rhythm. The patient denies any chest pain and does not remember any prodromal symptoms preceding the collapse. There is no past medical history of note.

On examination his blood pressure is 150/85 mmHg, heart rate 75/min regular, temperature 36.6°C, oxygen saturations 99% on 10 l/min. His Glasgow Coma Score is 15/15; there are no tongue abrasions or evidence of urinary incontinence. The cardiovascular, respiratory and neurological examination is unremarkable.

He has been having recurrent episodes of arrhythmia in the department, and a rhythm strip is shown below.

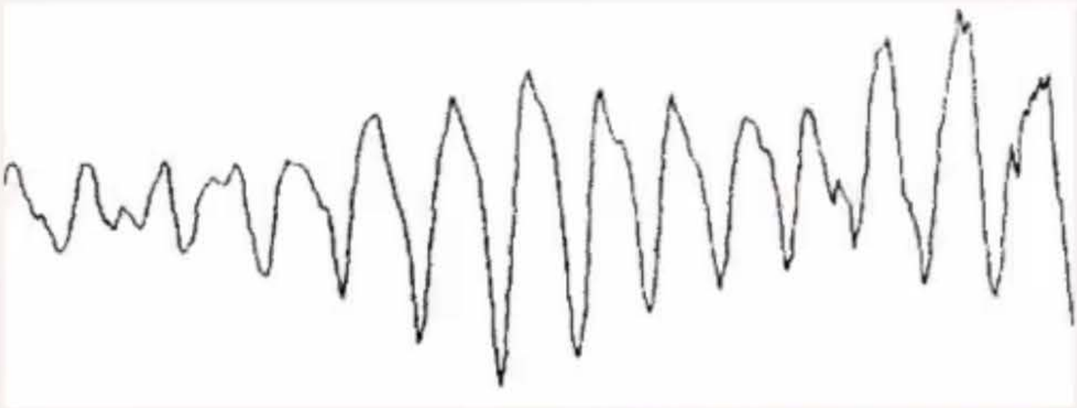

What is the most appropriate treatment for his rhythm disturbance?

A	IV potassium replacement
B	IV magnesium infusion
C	IV amiodarone 300mg followed by maintenance infusion

with her husband. The paramedics report the initial rhythm strip showed sinus rhythm. The patient denies any chest pain and does not remember any prodromal symptoms preceding the collapse. There is no past medical history of note.

On examination his blood pressure is 150/85 mmHg, heart rate 75/min regular, temperature 36.6°C, oxygen saturations 99% on 10 l/min. His Glasgow Coma Score is 15/15; there are no tongue abrasions or evidence of urinary incontinence. The cardiovascular, respiratory and neurological examination is unremarkable.

He has been having recurrent episodes of arrhythmia in the department, and a rhythm strip is shown below.

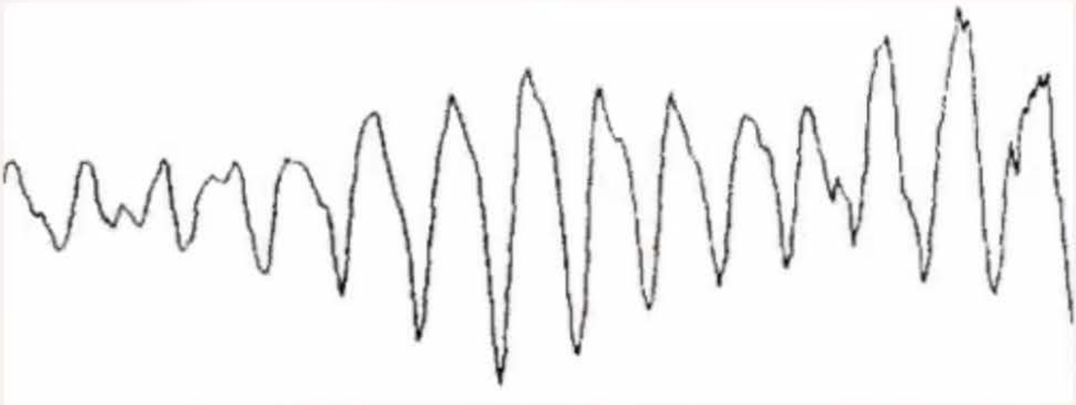

What is the most appropriate treatment for his rhythm disturbance?

A	IV potassium replacement
B	IV magnesium infusion
C	IV amiodarone 300mg followed by maintenance infusion
D	IV adenosine bolus
E	IV flecainide infusion

B IV magnesium infusion

This ECG demonstrates torsades de pointes. A prolonged episode that results in cardiovascular instability should be treated with DC cardioversion. Pharmacotherapy for polymorphic ventricular tachycardia is magnesium, which decreases calcium influx, reducing the amplitude of the VT and helping terminate runs of torsades. It is effective even when serum magnesium is normal. Overdrive pacing or isoprenaline (to reduce the QT interval once the torsades has been corrected) can also be used to prevent relapse. Common drugs that prolong the QT interval and can potentially cause torsades – e.g. erythromycin, carbamazepine, ketoconazole and tricyclic antidepressants – should be avoided. Amiodarone, quinidine and flecainide are recognised as worsening the arrhythmia, and adenosine is ineffective in terminating it. A collateral drug history is important as he may well have been exposed to agents that lead to long QT syndrome or those that cause hypomagnesaemia.

A IV potassium replacement

Potassium levels should be measured, and replaced if low, but routine potassium replacement does not represent the most appropriate management of TdP.

C IV amiodarone 300mg followed by maintenance infusion

Amiodarone can cause QT prolongation and is therefore an inappropriate choice in the treatment of TdP. Resuscitation Council guidelines regarding the management of TdP state: 'Do not give amiodarone for definite torsade de pointes'.

D IV adenosine bolus

Adenosine depresses AV node and sinus node activity. If

2:08

An 80-year-old, known hypertensive is admitted to hospital with congestive heart failure. Physical examination reveals a blood pressure of 175/95 mmHg, a raised JVP, peripheral oedema and bilateral pulmonary crepitations.

A chest X-ray shows pulmonary oedema and slight cardiomegaly. Echocardiography results reveal a normal left ventricular cavity, left atrial enlargement and a left ventricular ejection fraction of 65%. The left ventricular Doppler filling pattern is abnormal and a diagnosis of diastolic heart failure is made.

What is the most appropriate step in the initial management of this patient?

A	Start diuretics
B	Perform cardiac catheterisation
C	Start digoxin
D	Give IV fluids
E	Insert a central venous line

Submit

Previous Q... Skip Questi...

Rana Alnasser's screen

A chest X-ray shows pulmonary oedema and slight cardiomegaly. Echocardiography results reveal a normal left ventricular cavity, left atrial enlargement and a left ventricular ejection fraction of 65%. The left ventricular Doppler filling pattern is abnormal and a diagnosis of diastolic heart failure is made.

What is the most appropriate step in the initial management of this patient?

Your answer was correct

A	Start diuretics
B	Perform cardiac catheterisation
C	Start digoxin
D	Give IV fluids
E	Insert a central venous line

Explanation

A	Start diuretics

Cross-section and population-based studies indicate that at least one-third of all patients with congestive heart failure (CHF) have a normal or near-normal ejection fraction. The mortality rate among patients with diastolic heart failure (5–8%) is lower than in those with systolic heart failure (10–15%). There are few published data concerning the incidence of heart failure among patients with diastolic dysfunction as demonstrated by Doppler echocardiography. Echocardiography plays a critical

2:09
https://mypastest.pastest.com

Cross-section and population-based studies indicate that at least one-third of all patients with congestive heart failure (CHF) have a normal or near-normal ejection fraction. The mortality rate among patients with diastolic heart failure (5–8%) is lower than in those with systolic heart failure (10–15%). There are few published data concerning the incidence of heart failure among patients with diastolic dysfunction as demonstrated by Doppler echocardiography. Echocardiography plays a critical diagnostic role in patients with heart failure, in part because the physical examination, ECG and chest X-ray do not provide information that distinguishes diastolic from systolic heart failure.

Major objectives in management are: to reverse the consequences of diastolic dysfunction and to eliminate or reduce the factors responsible for the diastolic dysfunction. Initial treatment is aimed at reducing pulmonary venous pressure and congestion, and such treatment usually requires therapy with diuretics. Certain angiotensin receptor blockers like losartan, and telmisartan, irbesartan and candesartan, possess additional properties that are independent of ACE inhibition. These include anti-platelet, hypo-uricaemic, anti-diabetic and atrial anti-fibrillatory effects, which may have a particularly beneficial role in this clinical setting. A growing body of evidence shows that angiotensin receptor blockers are an important contribution to the pharmaceutical management of patients with heart failure. Candesartan has a moderate impact in preventing admissions for CHF among patients who have heart failure and a left ventricular ejection fraction (LVEF) higher than 40% (as shown in the CHARM study.

Reference: Erhardt, L.R. A review of the current evidence for the use of angiotensin-receptor blockers in chronic heart failure. *Int J Clin Pract* 2005 May;59(5):571–8.

B Perform cardiac catheterisation

C Start digoxin

The DIG trial found that 'In ambulatory patients with chronic mild to moderate diastolic heart failure and normal sinus rhythm receiving angiotensin-converting enzyme inhibitor and diuretics, digoxin had no effect on natural history end points such as mortality and all-cause or cardiovascular hospitalizations.'

D Give IV fluids

This patient is congested both clinically and on echocardiography, and the key is to reduce this congestion with diuretics. Thus the provision of additional fluid is inappropriate here.

E Insert a central venous line

Diuretics should represent the initial stage of this patient's management, and can be provided either orally or via a peripheral IV cannula. A central venous catheter would represent an unnecessary risk of complications in this context.

Rate this question:

© Pastest 2019

A 55-year-old female is admitted to hospital for the second time in two months with exacerbation of dyspnoea and peripheral oedema. She is known to have dilated cardiomyopathy, and echocardiography performed on previous admission revealed an ejection fraction of 25% and moderate mitral and tricuspid regurgitation. Her heart failure regimen includes furosemide 60 mg twice daily, digoxin 0.25 mg/day, enalapril 15 mg twice daily, carvedilol 12.5 mg twice daily and spironolactone 50 mg/day. She has type 2 diabetes mellitus maintained on pioglitazone 15 mg twice daily. However, she had poor glycaemic control and was started on insulin lente 15 units twice daily and insulin lispro 5 units twice daily. Physical examination reveals blood pressure of 105/75 mmHg, pulse rate of 90/min and respiratory rate of 25/min. She has jugular venous distension, bilateral inspiratory crackles halfway up the lung fields and pitting oedema up to the knees. She improves on intravenous diuretics over the next three days.

Investigations:

Sodium	135 mmol/l
Potassium	4.5 mmol/l
Urea	8 mmol/l
Creatinine	120 µmol/l
Glucose (random)	13 mmol/l
Electrocardiogram (ECG)	Sinus tachycardia and poor R-wave progression in chest leads

What change in her regular medications should be made to decrease recurrent exacerbations of heart failure?

A	Add hydrochlorothiazide
B	Decrease the dose of carvedilol to 6.25 mg twice daily

type 2 diabetes mellitus maintained on pioglitazone 15 mg twice daily. However, she had poor glycaemic control and was started on insulin lente 15 units twice daily and insulin lispro 5 units twice daily. Physical examination reveals blood pressure of 105/75 mmHg, pulse rate of 90/min and respiratory rate of 25/min. She has jugular venous distension, bilateral inspiratory crackles halfway up the lung fields and pitting oedema up to the knees. She improves on intravenous diuretics over the next three days.

Investigations:

Sodium	135 mmol/l
Potassium	4.5 mmol/l
Urea	8 mmol/l
Creatinine	120 µmol/l
Glucose (random)	13 mmol/l
Electrocardiogram (ECG)	Sinus tachycardia and poor R-wave progression in chest leads

What change in her regular medications should be made to decrease recurrent exacerbations of heart failure?

A	Add hydrochlorothiazide
B	Decrease the dose of carvedilol to 6.25 mg twice daily
C	Discontinue pioglitazone
D	Stop carvedilol
E	Start warfarin 5 mg per day

C Discontinue pioglitazone

Thiozolidinediones can cause fluid retention and precipitate heart failure. Therefore, pioglitazone should be avoided in patients with symptomatic heart failure, especially those with New York Heart Association Class III and IV. Metformin should also be avoided in heart failure patients who require drug therapy because of increased risk of lactic acidosis.

Other drugs that should be avoided in heart failure include non-steroidal anti-inflammatory agents, cilostazol and sildenafil.

A Add hydrochlorothiazide

Hydrochlorothiazide may be added if oedema is resistant to loop diuretics, but in this case the heart failure exacerbation has responded well so that it is not required.

B Decrease the dose of carvedilol to 6.25 mg twice daily

There is no need to reduce the dose of carvedilol, as it improves morbidity and mortality in heart failure. It can cause fluid retention when initiated, but this should be managed by increasing the dose of diuretics.

D Stop carvedilol

There is no need to discontinue carvedilol, as it improves morbidity and mortality in heart failure. It can cause fluid retention when initiated, but this should be managed by increasing the dose of diuretics.

E Start warfarin 5 mg per day

exacerbation has responded well so that it is not required.

B	Decrease the dose of carvedilol to 6.25 mg twice daily

There is no need to reduce the dose of carvedilol, as it improves morbidity and mortality in heart failure. It can cause fluid retention when initiated, but this should be managed by increasing the dose of diuretics.

D	Stop carvedilol

There is no need to discontinue carvedilol, as it improves morbidity and mortality in heart failure. It can cause fluid retention when initiated, but this should be managed by increasing the dose of diuretics.

E	Start warfarin 5 mg per day

In some patients, warfarin may be advocated in severe cardiomyopathy to prevent pulmonary embolism. However, it will not prevent recurrent heart failure episodes.

Rate this question:

Next Question

Previous Q... Tag Questi... Feedback End Session

© Pastest 2019

A 45-year-old woman presents with breathlessness and palpitations. On examination there is a left parasternal heave. She has no murmurs and her chest is clear. The resting ECG shows atrial fibrillation with right axis deviation. An echocardiogram confirms dilated right heart chambers.

The following data are collected during a left and right heart catheterisation study:

Sample site	Oxygen saturations (%)
Inferior vena cava	62
Superior vena cava	58
Right atrium	78
Right ventricle	79
Pulmonary artery	80
Arterial saturation	98

Which of the following is the most likely diagnosis?

A Atrial septal defect

B Ventricular septal defect

C Patient ductus arteriosus

D Ebstein's anomaly

E Pulmonary stenosis

2:17

A Atrial septal defect

The findings of a parasternal heave on examination in combination with the right axis deviation are consistent with right ventricular volume overload. The cardiac catheterisation data show a step-up in oxygen saturations at the level of the right atrium. This signifies the presence of a left-to-right shunt at the level of the atrium, making an atrial septal defect the most likely diagnosis. The patient should be cardioverted to sinus rhythm prior to any intervention, to close the atrial septal defect. A transoesophageal echocardiogram can give sufficient anatomical data as to the size and site of the defect. It is well worth patients undergoing electrophysiological studies prior to any closure procedure. These are far easier to perform while the defect is present, as they provide an easy route into the left atrium. Any abnormal pathways predisposing to atrial flutter/fibrillation should be considered for radiofrequency ablation, which can be curative.

B Ventricular septal defect

The cardiac catheterisation data show a step-up in saturations at the level of the right atrium, making an ASD a more likely diagnosis than a VSD (in which case such a step-up would not be seen until the level of the right ventricle).

C Patient ductus arteriosus

PDA is often associated with a conspicuous apex beat due to left venticular hypertrophy, and a continuous murmur classically described as 'machinery like'.

D Ebstein's anomaly

This is a rare congenital condition which is characterised by

Rana Alnasser's screen

B Ventricular septal defect

The cardiac catheterisation data show a step-up in saturations at the level of the right atrium, making an ASD a more likely diagnosis than a VSD (in which case such a step-up would not be seen until the level of the right ventricle).

C Patient ductus arteriosus

PDA is often associated with a conspicuous apex beat due to left venticular hypertrophy, and a continuous murmur classically described as 'machinery like'.

D Ebstein's anomaly

This is a rare congenital condition which is characterised by 'atrialisation' of the right ventricle due to apical displacement of the tricuspid valve. The first heart sound is widely split due to delayed closure of the tricuspid valve. S2 is usually normal, but may be widely split when P2 is delayed due to right bundle-branch block. A pansystolic tricuspid regurgitation murmur is also common. Patients may present with cyanosis and clubbing.

E Pulmonary stenosis

For stenosis to be sufficiently severe that a patient would present with symptoms, this would typically be associated with a loud pulmonary ejection murmur - loudest at the pulmonary area - with radiation to the left shoulder.

Rate this question:

Next Question

A 58-year-old man with a history of type 2 diabetes mellitus and hypertension comes to the Emergency Department complaining of central crushing chest pain radiating to his left arm. He takes a number of medications including ramipril, simvastatin, aspirin, metformin and gliclazide. Examination reveals a blood pressure of 155/90 mmHg and a regular pulse (88/min). There are bilateral crackles on auscultation of the chest consistent with heart failure.

Investigations:

Hb	13.1 g/dl
WCC	8.9 x10^9/l
PLT	210 x10^9/l
Na^+	137 mmol/l
K^+	4.5 mmol/l
Creatinine	132 micromol/l
HbA1c	56 mmol/mol (7.3%)
ECG	anterolateral ST depression
CXR	Cardiomegaly, evidence of LVF

His pain eases from 8/10 to 3/10 with two doses of sublingual GTN and one dose of IV morphine. He is given fondaparinux, aspirin and clopidogrel.

Which of the following is the most appropriate immediate intervention?

A IV beta-blockade

B IV GTN

C IV Morphine

failure.

Investigations:

Hb	13.1 g/dl
WCC	8.9 x10⁹/l
PLT	210 x10⁹/l
Na^+	137 mmol/l
K^+	4.5 mmol/l
Creatinine	132 micromol/l
HbA1c	56 mmol/mol (7.3%)
ECG	anterolateral ST depression
CXR	Cardiomegaly, evidence of LVF

His pain eases from 8/10 to 3/10 with two doses of sublingual GTN and one dose of IV morphine. He is given fondaparinux, aspirin and clopidogrel.

Which of the following is the most appropriate immediate intervention?

A IV beta-blockade

B IV GTN

C IV Morphine

D Proceed to percutaneous intervention (PCI)

E Thrombolysis

39054

Explanation

B IV GTN

This patient has presented with features highly suggestive of a non-ST-elevation myocardial infarction. He remains hypertensive and has ongoing pain despite the use of sublingual GTN. Ongoing pain is suggestive of continuing myocardial ischaemia/infarction. Although PCI is likely to be required, this will take time to organise. GTN acts as a vasodilator through the production of NO. Vasodilatation reduces cardiac afterload, which has the effect of improving heart failure symptoms and reducing the cardiac oxygen demand.

D Proceed to percutaneous intervention (PCI)

PCI is likely to be the most appropriate definitive intervention. However, this patient is currently unstable. IV GTN is a quick intervention that may reduce heart failure features and ongoing myocardial ischaemia.

A IV beta-blockade

β-Blockade will have negative chronotropic and inotropic effects, reducing cardiac oxygen demand. However, this patient has signs of acute heart failure (bilateral crackles of respiratory auscultation). The use of β -blockade in acute heart failure can lead to further decompensation and should not be initiated in this setting.

C IV Morphine

IV morphine would have a dual effect if given to a patient in this setting. Morphine acts as a vasodilator and will reduce cardiac afterload. Furthermore, it will act as an analgesic to reduce the ongoing chest pain. The reduction

A 58-year-old man with a history of type 2 diabetes mellitus and hypertension comes to the Emergency Department complaining of central crushing chest pain radiating to his left arm. He takes a number of medications including ramipril, simvastatin, aspirin, metformin and gliclazide. Examination reveals a blood pressure of 155/90 mmHg and a regular pulse (88/min). There are bilateral crackles on auscultation of the chest consistent with heart failure.

Investigations:

Hb	13.1 g/dl
WCC	8.9 x10^9/l
PLT	210 x10^9/l
Na^+	137 mmol/l
K^+	4.5 mmol/l
Creatinine	132 micromol/l
HbA1c	56 mmol/mol (7.3%)
ECG	anterolateral ST depression
CXR	Cardiomegaly, evidence of LVF

His pain eases from 8/10 to 3/10 with two doses of sublingual GTN and one dose of IV morphine. He is given fondaparinux, aspirin and clopidogrel.

Which of the following is the most appropriate immediate intervention?

Your answer was incorrect

A IV beta-blockade

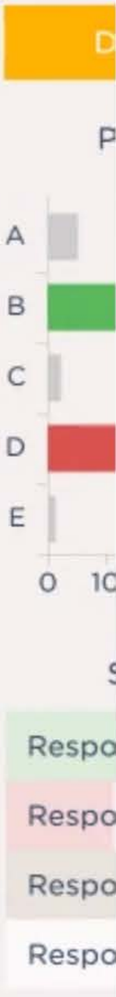

You are a general medical senior house officer in a district general hospital. You are asked to see a 20-year-old man in the Emergency Department who is breathless. He gives a history of recent air travel to South America within the last 10 days. He denies any past medical history but says that he has a chronic smokers' cough. The patient is not taking any regular medications.
On examination, he is a thin man with tachypnoea at rest. His baseline observations are blood pressure 120/80 mmHg, heart rate 100 beats/min, oxygen saturations 89% on room air and temperature 38.5°C. He is noted to have bi-basal crepitations and ill-defined heart sounds on auscultation. Routine bloods reveal an elevated white blood cell count and CRP.

An electrocardiogram (ECG) done on admission is shown below.

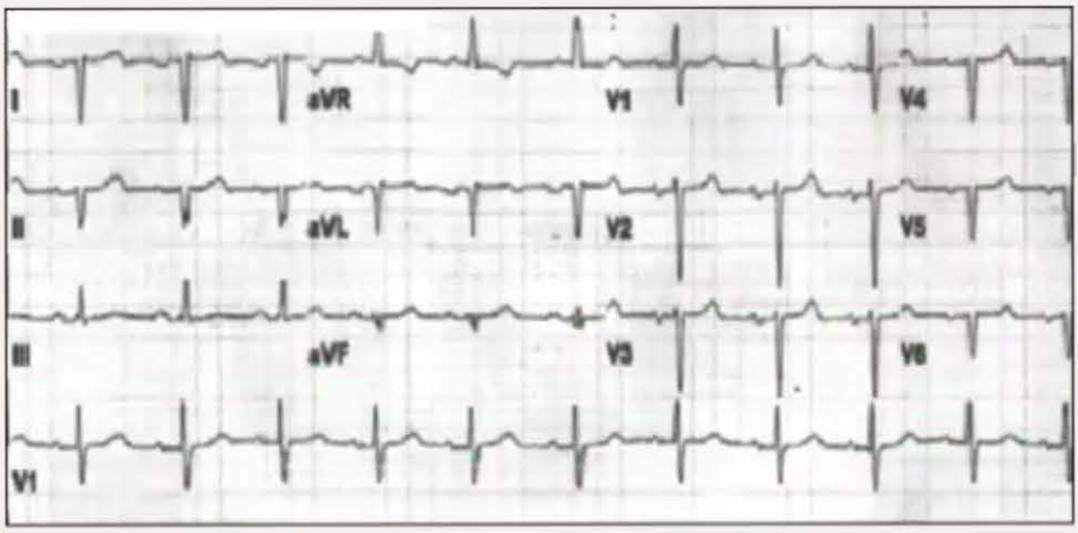

What is the next step in management?

A	Echocardiogram to rule out an atrial septal defect (ASD)
B	Organise a VQ scan and commence low-molecular weight heparin

on room air and temperature 38.5°C. He is noted to have bi-basal crepitations and ill-defined heart sounds on auscultation. Routine bloods reveal an elevated white blood cell count and CRP.

An electrocardiogram (ECG) done on admission is shown below.

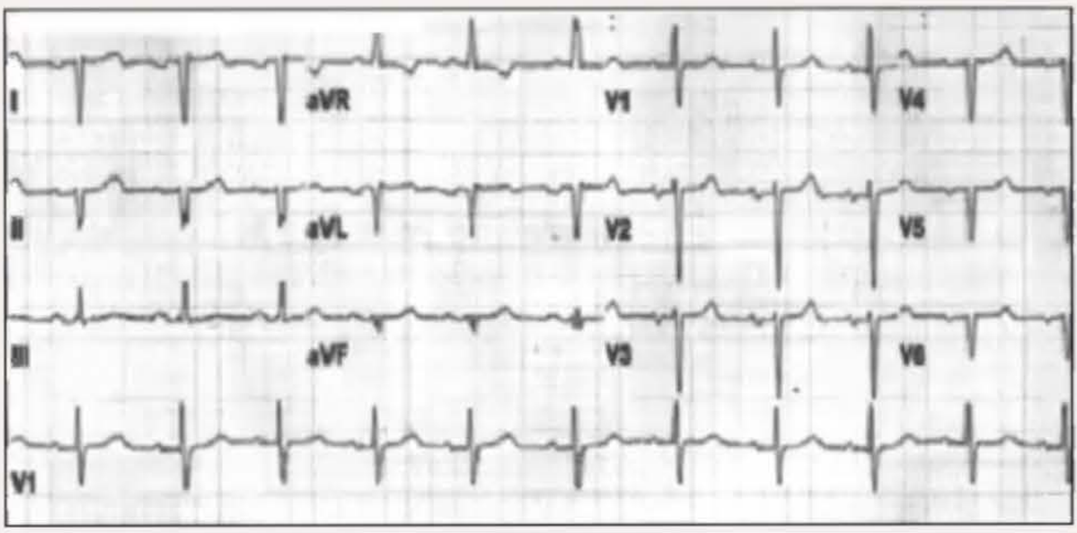

What is the next step in management?

A	Echocardiogram to rule out an atrial septal defect (ASD)
B	Organise a VQ scan and commence low-molecular weight heparin
C	Measure alpha-1 antitrypsin level and arrange a thoracic CT
D	Organise a chest X-ray and commence antibiotic therapy
E	Perform delta F508 genetic screening

D Organise a chest X-ray and commence antibiotic therapy

Although the story is of a young man having travelled to South America, the faint heart sounds, 'chronic smokers' cough and abnormal ECG all point towards dextrocardia, bronchiectasis and therefore Kartagener syndrome.

The clinical features are consistent with an acute lower respiratory tract infection.

The ECG with leads in the usual precordial position reveals inverted P-waves in lead I with a negative major QRS deflection. Upright P-waves with a positive QRS deflection are seen in lead aVR with mirror image findings in lead aVL, and an abnormal precordial progression of R wave from lead V1 to V6.

A Echocardiogram to rule out an atrial septal defect (ASD)

The most pressing problem here is the likely acute lower respiratory tract infection, with antibiotic therapy the key intervention. An ASD is less likely versus dextrocardia, for which the ECG findings are very consistent.

B Organise a VQ scan and commence low-molecular weight heparin

The pyrexia and abnormal chest findings on auscultation make respiratory tract infection more likely as the underlying cause of his symptoms versus a pulmonary embolism.

C Measure alpha-1 antitrypsin level and arrange a thoracic CT

Alpha-1 antitrypsin deficiency is associated with

A 72-year-old man comes to the clinic for review. He has severe biventricular failure and is taking ramipril 10 mg, furosemide 160 mg, spironolactone 25 mg, digoxin 62.5 mcg and bisoprolol 10 mg. On examination he looks a little dry, his BP is 110/72 mmHg lying and 95/65 mmHg on standing. There is no peripheral oedema and no crackles on auscultation of the chest.

Investigations:

Hb	12.1 g/dl
WCC	5.0×10^9/l
PLT	208×10^9/l
Na^+	140 mmol/l
K^+	5.6 mmol/l
Creatinine	210 µmol/l (165 at last clinic appointment)
Urea	13.1 mmol/l

Which of the following agents should be reduced in dose or discontinued?

A Ramipril

B Furosemide and spironolactone

C Spironolactone

D Digoxin

E Bisoprolol

Rana Alnasser's screen

9:08

MyPastest
https://mypastest.pastest.com

B Furosemide and spironolactone

This patient's renal function has deteriorated since his last clinic appointment, with rising urea and creatinine suggesting pre-kidney disease. Given there are no clinical signs of heart failure, the most sensible first modification to this patient's medications would be to reduce the dose of furosemide and withhold spironolactone until the potassium falls. After reducing the dose it is important to monitor U&Es regularly. His potassium is elevated at 5.6 mmol, but this might be expected to fall as the pre-kidney disease resolves.

A Ramipril

This is an ACE inhibitor known to improve mortality in heart failure. It can be implicated in the development of kidney disease, and U&E should be monitored throughout its use. In this case however, with only mildly elevated potassium it's prudent to stop the diuretics first.

C Spironolactone

Reducing spironolactone alone is unlikely to resolve the pre-kidney disease, and potassium may therefore remain elevated. It's important therefore to withhold both diuretics.

D Digoxin

Digoxin levels may increase in the presence of kidney disease, and therefore it would be important to monitor for signs of toxicity, or indeed digoxin levels. With mild kidney disease, the dose is unlikely to require changing and [illegible] the development of kidney

Rana Alnasser's screen

disease resolves.

A Ramipril

This is an ACE inhibitor known to improve mortality in heart failure. It can be implicated in the development of kidney disease, and U&E should be monitored throughout its use. In this case however, with only mildly elevated potassium it's prudent to stop the diuretics first.

C Spironolactone

Reducing spironolactone alone is unlikely to resolve the pre-kidney disease, and potassium may therefore remain elevated. It's important therefore to withhold both diuretics.

D Digoxin

Digoxin levels may increase in the presence of kidney disease, and therefore it would be important to monitor for signs of toxicity, or indeed digoxin levels. With mild kidney disease, the dose is unlikely to require changing and digoxin is not implicated in the development of kidney disease. It is used in heart failure because it improves symptoms and prevents hospital admissions.

E Bisoprolol

This provides control of heart rate and prevents arrhythmias in heart failure. It also conveys some survival benefit and improves symptoms. Dose should be reduced when eGFR <20 ml/min.

21277

Rate this question:

Next Question

You accompany a patient for an exercise test. This was the patient's 7th day post-myocardial infarction. He had an inferolateral myocardial infarction and he was having an exercise test for the purpose of risk stratification. At rest, his blood pressure (BP) was 130/75 mmHg. He was able to manage 8 min on the treadmill using the Bruce protocol. He could have gone on for some more minutes but was limited by shortness of breath and not chest pain. At maximum exercise, his BP was 160/72 mmHg.

Investigations:

Urea and electrolytes	Normal
Full blood count	Normal
Chest X-ray	Normal
Resting Electrocardiogram (ECG)	Q waves in leads II, III, aVF

How would you best describe this BP response to exercise?

A	Both systolic and diastolic responses were abnormal
B	The diastolic response was normal but not the systolic
C	The systolic response was excessive
D	The systolic response was normal but not the diastolic
E	Both systolic and diastolic responses were normal

9:12
594-042-7551
Leave

E Both systolic and diastolic responses were normal

With exercise, systolic pressure progressively increases until maximum exercise. Diastolic BP remains the same and may decrease slightly with progressive exercise. With heart disease, abnormalities in BP response to exercise are common. A fall in blood pressure, failure to rise or excessive rise (systolic >250 mmHg) in blood pressure is an indication to terminate the exercise test.

A Both systolic and diastolic responses were abnormal

With exercise, systolic pressure progressively increases until maximum exercise. Diastolic BP remains the same and may decrease slightly with progressive exercise. This is the case in this scenario, and therefore responses are normal.

B The diastolic response was normal but not the systolic

With exercise, systolic pressure progressively increases until maximum exercise – it is a normal response in this case.

C The systolic response was excessive

Providing systolic rises to <250 mmhg with exercise, then this is not excessive.

D The systolic response was normal but not the diastolic

Diastolic BP remains the same and may decrease slightly with progressive exercise, as in this case, so it is a normal diastolic response.

Audio Video Share Participants More

9:13
594-042-7551
Leave

A 28-year-old woman presents to the Emergency Department with sudden onset of palpitations whilst doing the cleaning at home.

She has no past medical history of note and her only medication is the combined oral contraceptive pill. She drinks six cups of coffee per day.

On examination, her BP is 122/70 mmHg, with pulse 140 bpm and regular. Her chest is clear.

Investigations:

Hb	13.1 g/dl
WCC	6.2×10^9/l
PLT	221×10^9/l
Na^+	138 mmol/l
K^+	4.5 mmol/l
Creatinine	85 µmol/l

ECG is shown below:

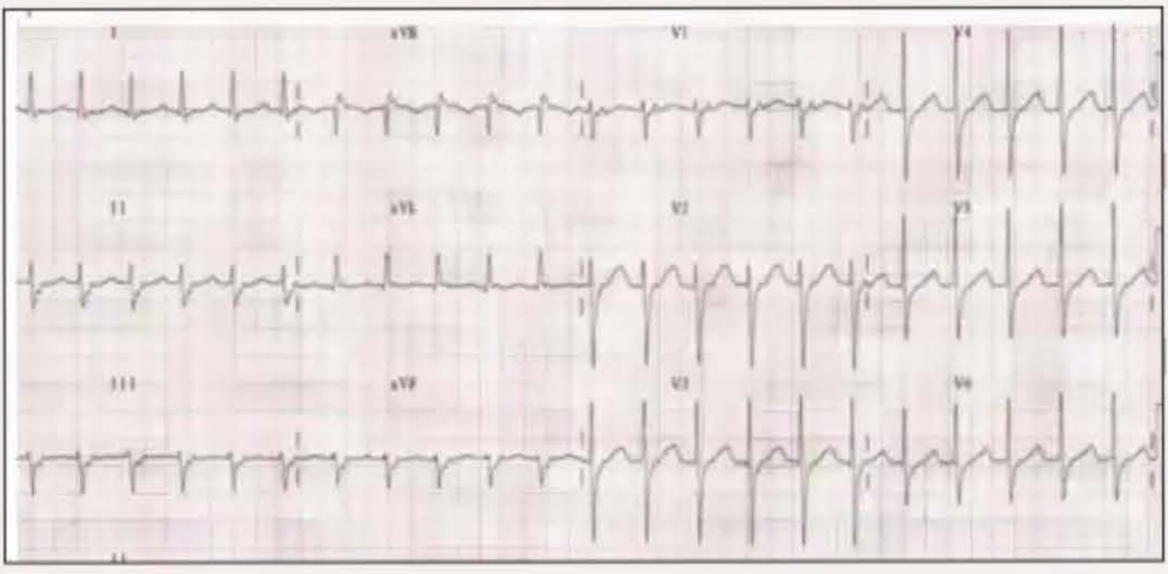

Which of the following is the most appropriate initial intervention?

Audio
Video
Share
Participants
More

Na^+	138 mmol/l
K^+	4.5 mmol/l
Creatinine	85 µmol/l

ECG is shown below:

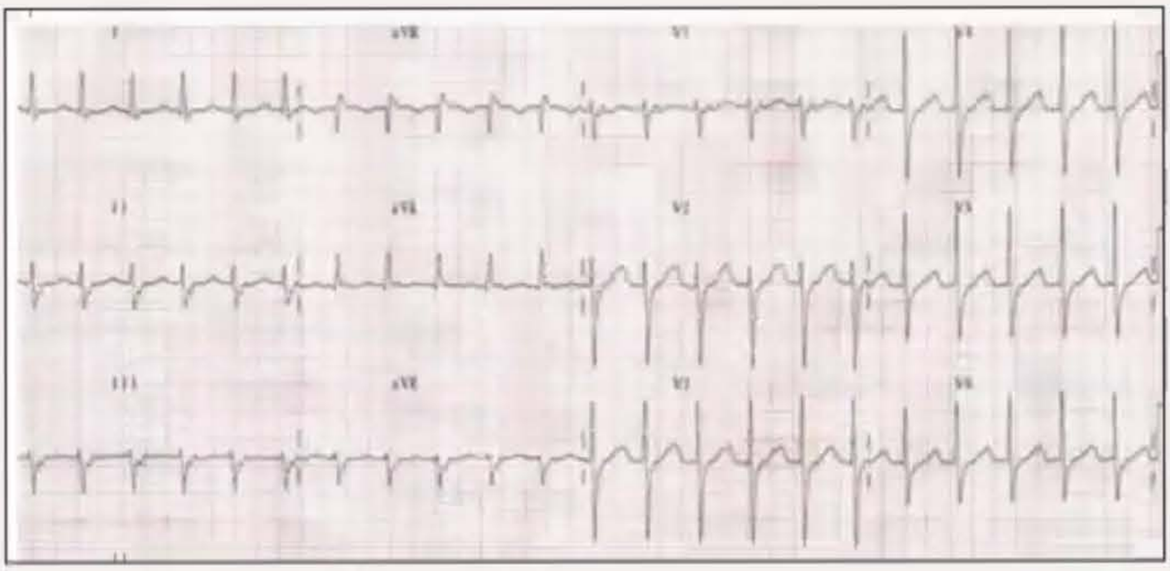

Which of the following is the most appropriate initial intervention?

A Adenosine

B Amiodarone

C Carotid sinus massage

D Direct current (DC) cardioversion

E Esmolol

Submit

Rana Alnasser's screen

Explanation

C Carotid sinus massage

The ECG shows a regular narrow-complex tachycardia. There is no clear atrial activity visible, in part due to the ventricular rate. Given the patient's age and clinical background, atrioventricular re-entrant tachycardia (AVRT) or AV nodal re-entrant tachycardia (AVNRT) is the most likely diagnosis. The first-line treatment for such arrhythmias, when the patient is haemodynamically stable, is vagal stimulation. This stimulation reduces the rate of depolarisation of the AV node, a central component for both arrhythmias. If sufficient vagal stimulation is achieved, this will temporarily break the re-entrant circuit and terminate the arrhythmia. Techniques for vagal stimulation include carotid sinus massage, Valsalva manoeuvre and triggering of the diving reflex by place the patient's face in cold water (note this final technique has a more profound effect on heart rate in the paediatric population). Carotid sinus massage should be used with caution in older patients, as there is a risk of causing a stroke by breaking off plaque for an atherosclerotic carotid artery.

A Adenosine

Adenosine has a central role in the treatment of arrhythmias involving the AV node (i.e. AVRT and AVNRT). Adenosine is an agonist for adenosine receptors (A_1) in the AV node, stimulation of these receptors leading to hyperpolarisation of the AV node. If sufficiently hyperpolarised, this breaks the re-entrant circuit and terminates the arrhythmia. Adenosine should be used as a second-line treatment after vagal manoeuvres in most patients. Caution should be used in patients with airway disease (e.g. asthma or COPD).

Rana Alnasser's screen

where a patient has a shockable rhythm, and potentially in patients with atrial fibrillation not controlled by initial treatments.

D	Direct current (DC) cardioversion

DC cardioversion in AVRT and AVNRT is primarily reserved for patients with haemodynamic compromise, chest pain, developing heart failure and syncope. This patient does not demonstrate any of these significant features and, as such, DC cardioversion would not be appropriate as an initial intervention.

E	Esmolol

Esmolol is a selective β_1 antagonist. β-Blockade is a primary treatment for patients with atrial fibrillation or atrial flutter. Although atrial flutter will often present as a narrow-complex regular tachycardia, it is unlikely in this case (due to patient age, ventricular rate and clinical scenario). If, when vagal manoeuvres or adenosine are used, flutter waves are revealed, then β-blockade could be considered.

Rate this question:

Next Question

Previous Q... Tag Questi... Feedback End Session

Blog About Pastest Contact Us Help

© Pastest 2019

A 65-year-old Jamaican lady is referred to the cardiology department by her GP with a history of progressive breathlessness. She has also noticed that her ankles have been swelling up recently. A trial of furosemide 40 mg once daily by her general practitioner (GP) has not produced any noticeable results.
On examination in the clinic she is found to have a blood pressure of 138/95 mmHg with a heart rate of 85 beats/min. Her jugular venous pressure is elevated and there is a third heart sound on auscultation. There is pedal oedema bilaterally. Her chest X-ray shows bilateral hilar lymphadenopathy with a normal-sized heart.
An echocardiogram is performed that shows biatrial enlargement with normal-sized ventricles and preserved left ventricular systolic function.

Which of the following investigations would be most appropriate next step in establishing the diagnosis?

A	Computerised tomography (CT) of the chest
B	Serum angiotensin-converting enzyme (ACE)
C	Rectal biopsy
D	Liver biopsy
E	Immunoglobulin electrophoresis

32283

Submit

A 65-year-old Jamaican lady is referred to the cardiology department by her GP with a history of progressive breathlessness. She has also noticed that her ankles have been swelling up recently. A trial of furosemide 40 mg once daily by her general practitioner (GP) has not produced any noticeable results.
On examination in the clinic she is found to have a blood pressure of 138/95 mmHg with a heart rate of 85 beats/min. Her jugular venous pressure is elevated and there is a third heart sound on auscultation. There is pedal oedema bilaterally. Her chest X-ray shows bilateral hilar lymphadenopathy with a normal-sized heart.
An echocardiogram is performed that shows biatrial enlargement with normal-sized ventricles and preserved left ventricular systolic function.

Which of the following investigations would be most appropriate next step in establishing the diagnosis?

Your answer was correct

A	Computerised tomography (CT) of the chest
B	Serum angiotensin-converting enzyme (ACE)
C	Rectal biopsy
D	Liver biopsy
E	Immunoglobulin electrophoresis

Explanation

Explanation

A	Computerised tomography (CT) of the chest

This patient presents with symptoms of heart failure with preserved systolic function of the heart. This raises the possibility of restrictive cardiomyopathy leading to diastolic dysfunction. Causes of restrictive cardiomyopathy include infiltrative disease, such as amyloidosis, haemochromatosis and sarcoidosis, and post-radiation therapy fibrosis.

In the presence of hilar lympadenopathy in a Jamaican lady, sarcoidosis is a possible underlying cause. The true incidence of cardiac involvement in sarcoidosis is unknown. Infiltrating granulomas may occur in the heart of up to 50% of patients with systemic sarcoidosis, but clinical manifestations of cardiac involvement are thought to occur in 5%. Cardiac involvement in sarcoidosis is not always associated with widespread disease but when present it indicates a poor prognosis.

A liver biopsy may be undertaken if the diagnosis of haemochromatosis is suspected. Given that in this case, sarcoidosis is a more likely diagnosis, a CT of the chest is the preferred next diagnostic step.

B	Serum angiotensin-converting enzyme (ACE)

This patient presents with symptoms of heart failure with preserved systolic function of the heart. This raises the possibility of restrictive cardiomyopathy leading to diastolic dysfunction. Causes of restrictive cardiomyopathy include infiltrative disease, such as amyloidosis, haemochromatosis and sarcoidosis, and post radiation therapy fibrosis. The ACE level is elevated in 75% of untreated patients with sarcoidosis However, serum ACE has limited utility as a diagnostic test, due to poor sensitivity (false negative results) and insufficient specificity (almost a 10% rate of false positive results).

D Liver biopsy

This patient presents with symptoms of heart failure with preserved systolic function of the heart. This raises the possibility of restrictive cardiomyopathy leading to diastolic dysfunction. Secondary causes of restrictive cardiomyopathy include infiltrative disease, such as amyloidosis, haemochromatosis and sarcoidosis, and post-radiation therapy fibrosis. A liver biopsy may be undertaken if the diagnosis of haemochromatosis is suspected. Given that in this case, sarcoidosis is a more likely diagnosis. A CT of the chest is the preferred next diagnostic step.

E Immunoglobulin electrophoresis

This patient presents with symptoms of heart failure with preserved systolic function of the heart. This raises the possibility of restrictive cardiomyopathy leading to diastolic dysfunction. Secondary causes of restrictive cardiomyopathy include infiltrative disease, such as amyloidosis, haemochromatosis and sarcoidosis, and post-radiation therapy fibrosis.

Rate this question:

Next Question

Previous Q... Tag Questi... Feedback End Session

Blog About Pastest Contact Us Help

© Pastest 2019

A 25-year-old woman is referred to the cardiology department with a history of palpitations. She describes these as of sudden onset and termination associated with a feeling of light-headedness. They have occurred on a couple of occasions while she was running on the treadmill in the gym and she felt she had to stop. She smokes 10 cigarettes a day and denies any heavy alcohol use. There is no past medical history and she is on no regular medication.

On examination there is a systolic murmur at the left lower sternal edge and a prominent apical impulse.

The electrocardiogram (ECG) shows deep T wave inversions in leads V_3–V_5.

Which test is the first line investigation to reveal the underlying diagnosis?

A	Echocardiogram
B	24-h ECG
C	Exercise ECG
D	MIBI scan
E	Thyroid function tests

6927

Submit

A 25-year-old woman is referred to the cardiology department with a history of palpitations. She describes these as of sudden onset and termination associated with a feeling of light-headedness. They have occurred on a couple of occasions while she was running on the treadmill in the gym and she felt she had to stop. She smokes 10 cigarettes a day and denies any heavy alcohol use. There is no past medical history and she is on no regular medication.

On examination there is a systolic murmur at the left lower sternal edge and a prominent apical impulse.

The electrocardiogram (ECG) shows deep T wave inversions in leads V_3–V_5.

Which test is the first line investigation to reveal the underlying diagnosis?

Your answer was correct

A Echocardiogram

B 24-h ECG

C Exercise ECG

D MIBI scan

E Thyroid function tests

Explanation

A Echocardiogram

Explanation

A Echocardiogram

The history of palpitations precipitated by exercise and associated with pre-syncope is very sinister. The presence of a systolic murmur and T-wave inversions in the anterior leads makes hypertrophic obstructive cardiomyopathy (HOCM) the most likely diagnosis in this age group. The echocardiogram is key to the diagnosis and monitoring of HOCM. Given the clinical presentation, and echocardiogram should be performed urgently to look for evidence of septal hypertrophy and left ventricular outflow obstruction.

B 24-h ECG

Although this may be performed as part of the diagnostic work-up to risk stratify the patient and look for non-sustained VT (NSVT), the echocardiogram represents a first-line diagnostic test in patients with suspected HOCM.

C Exercise ECG

Although an exercise treadmill test may be performed, it is not a first-line test. An abnormal blood pressure response to exercise is an important, though non-specific, risk factor for sudden death.

D MIBI scan

MIBI scanning is more commonly performed to look for significant ischaemia in patients with suspected coronary artery disease.

E Thyroid function tests

This patient presents with exercise-induced palpitations

European Society of Cardiology

Focus on echocardiography in hypertrophic cardiomyopathy - fourth ...

Discover Updates Search More

9:26

594-042-7551

Leave

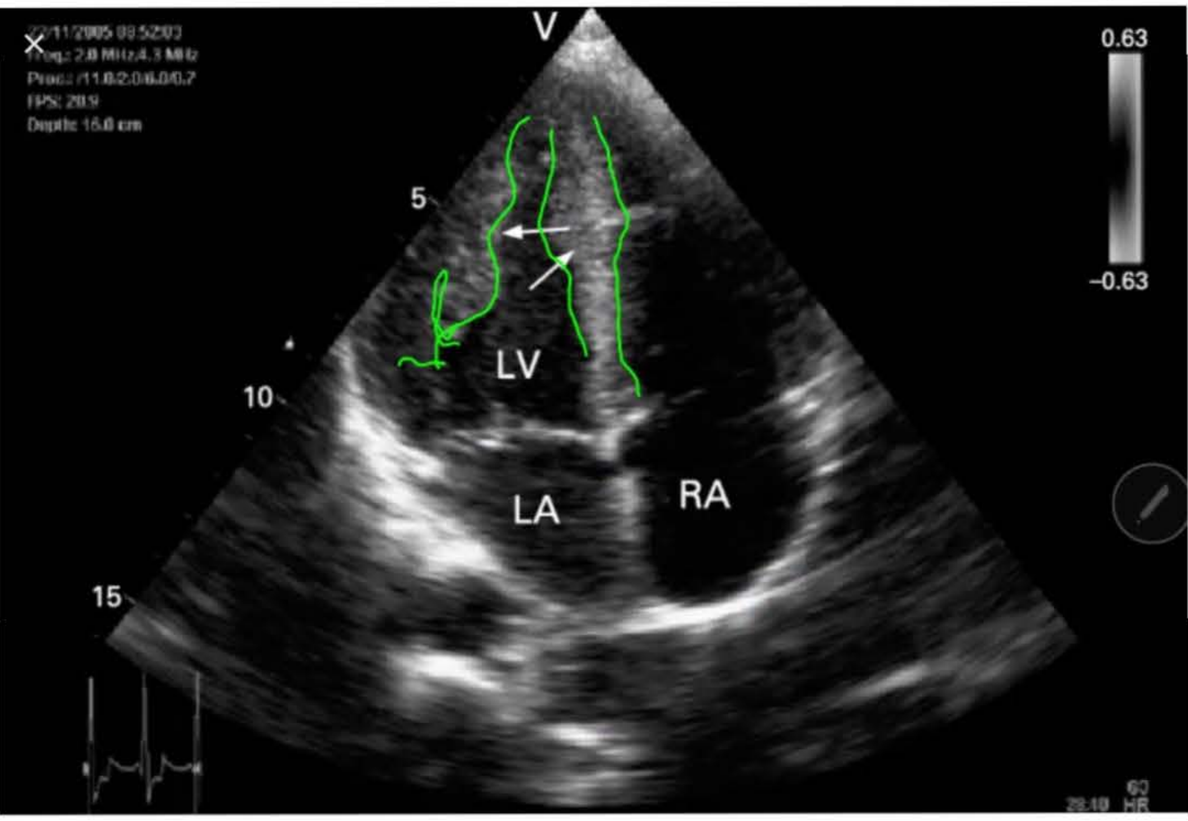

www.researchgate.net

Echocardiography showing apical left ventricular hypertrophy. LA, left... | Download Scientific Diagram

Download scientific diagram | Echocardiography showing apical left ventricular hypertrophy. LA, left atrium; RA, right atrium; LV, left ventricle; RV, right ventricle; arrows, myocardial hypertroph...

Images may be subject to copyright. Learn more

RELATED IMAGES

Stop Annotation | Spotlight | Pen | Highlighter | Line | Rectangle | Oval | Undo | Redo | Clear | Color | Stop Share

Discover | Updates | Search | Recent | More

Audio | Video | Share | Participants | More

9:33

A 75-year-old man is referred for total hip replacement. He has a history of hypertension and angina and suffered a myocardial infarction some 8 years earlier. Current medication includes atenolol 50 mg daily, ramipril 10 mg daily, aspirin 75 mg daily, atorvastatin 20 mg daily and isosorbide dinitrate 60 mg. Blood pressure at the preoperative assessment was 160/80 mmHg, but he maintains that his readings with the general practitioner have been normal. He last had an exercise test some 3 years earlier and managed 8 min with no significant ECG changes.

Which of the following investigations in addition to standard physical assessment would be most appropriate for the preoperative assessment of this patient?

A	Repeat exercise ECG test
B	Stress echocardiogram
C	Nuclear myocardial perfusion scan
D	Lung function testing
E	Cardiac MRI

Submit

Previous Q... Skip Questi...

Rana Alnasser's screen

A 75-year-old man is referred for total hip replacement. He has a history of hypertension and angina and suffered a myocardial infarction some 8 years earlier. Current medication includes atenolol 50 mg daily, ramipril 10 mg daily, aspirin 75 mg daily, atorvastatin 20 mg daily and isosorbide dinitrate 60 mg. Blood pressure at the preoperative assessment was 160/80 mmHg, but he maintains that his readings with the general practitioner have been normal. He last had an exercise test some 3 years earlier and managed 8 min with no significant ECG changes.

Which of the following investigations in addition to standard physical assessment would be most appropriate for the preoperative assessment of this patient?

Your answer was correct

A	Repeat exercise ECG test
B	Stress echocardiogram
C	Nuclear myocardial perfusion scan
D	Lung function testing
E	Cardiac MRI

Explanation

B Stress echocardiogram

This is a common referral for cardiology clinics. It is important to have a good basic assessment of this patient's

9:35

MyPastest
https://mypastest.pastest.com

Pastest+

B Stress echocardiogram

This is a common referral for cardiology clinics. It is important to have a good basic assessment of this patient's cardiac function to help shed light on his perioperative risk. This will all have an effect on potential haemodynamic changes during the surgery, as well as for any potential complications during the post-op period.

This option is will give us a wealth of information including the LV function, any existing regional wall-motion abnormalities and any significant valvular disease.

A Repeat exercise ECG test

Given this patient's hip is failing and needs to be replaced it's highly unlikely that he will be able to comply with an exercise test..

C Nuclear myocardial perfusion scan

Nuclear myocardial perfusion scan is used as an investigation for coronary artery disease in some centres, either to diagnose the presence of atherosclerosis (which we already know is present in this patient) or assess coronary flow reserve.

D Lung function testing

This patient has no history of lung disease, as such it's very unlikely lung function testing will be of value here.

E Cardiac MRI

Cardiac MRI is commonly used in the assessment of new

This will all have an effect on potential haemodynamic changes during the surgery, as well as for any potential complications during the post-op period.

This option is will give us a wealth of information including the LV function, any existing regional wall-motion abnormalities and any significant valvular disease.

A Repeat exercise ECG test

Given this patient's hip is failing and needs to be replaced it's highly unlikely that he will be able to comply with an exercise test..

C Nuclear myocardial perfusion scan

Nuclear myocardial perfusion scan is used as an investigation for coronary artery disease in some centres, either to diagnose the presence of atherosclerosis (which we already know is present in this patient) or assess coronary flow reserve.

D Lung function testing

This patient has no history of lung disease, as such it's very unlikely lung function testing will be of value here.

E Cardiac MRI

Cardiac MRI is commonly used in the assessment of new cardiac disease for which the aetiology is not immediately clear (for example young patients with new severe heart failure), or for objective assessment of myocardial status and disease.

12326

Rate this question:

A 70-year-old woman is admitted to the Emergency Department with central crushing chest pain, nausea, sweating and syncope. She has had two inferior myocardial infarctions in the past 3 years. She has type 2 diabetes, for which she takes metformin. Recent echocardiography revealed an ejection fraction of 30%.

On examination, BP is 124/80 mmHg and pulse 85/min. There are bi-basal crackles on auscultation of the chest. A dull chest pain persists.

Investigations:

Hb	12.9 g/dl
WCC	10.2 $\times 10^9$/l
PLT	243 $\times 10^9$/l
Na^+	138 mmol/l
K^+	4.3 mmol/l
Creatinine	131 micromol/l
6hr troponin	3.9
ECG	ST depression in V1-V4

She is given aspirin 300 mg and clopidogrel 300 mg. Her pain gradually settles.

Which of the following is the most appropriate next step (according to current NICE guidelines)?

A Unfractionated heparin

B Enoxaparin

C Fraxiparin

D Fondaparinux

revealed an ejection fraction of 30%.

On examination, BP is 124/80 mmHg and pulse 85/min. There are bi-basal crackles on auscultation of the chest. A dull chest pain persists.

Investigations:

Hb	12.9 g/dl
WCC	10.2 x10^9/l
PLT	243 x10^9/l
Na^+	138 mmol/l
K^+	4.3 mmol/l
Creatinine	131 micromol/l
6hr troponin	3.9
ECG	ST depression in V1-V4

She is given aspirin 300 mg and clopidogrel 300 mg. Her pain gradually settles.

Which of the following is the most appropriate next step (according to current NICE guidelines)?

A Unfractionated heparin

B Enoxaparin

C Fraxiparin

D Fondaparinux

E Bivalirudin

Rana Alnasser's screen

A Unfractionated heparin

This patient has ongoing chest pain. Given her cardiac history, she is at significant risk of further infarct. Cardiac risk is calculated using risk-scoring systems such as GRACE. Using that score, this patient's 6-month risk of death is around 10%, deemed 'highest risk' according to NICE guidance (see weblink below). This has significant implications for her ongoing management and means that she is likely to have angiography within the next 24 h. In this situation, NICE recommends unfractionated heparin over fondaparinux. A glycoprotein inhibitor such as tirofiban or abciximab is also indicated in high-risk patients such as this.

E Bivalirudin

Bivalirudin, is an alternative to unfractionated heparin with a glycoprotein inhibitor where angiography is considered within 24 h. It is also used in patients who suffer from heparin-induced thrombocytopenia.

B Enoxaparin

Enoxaparin, was formerly used for acute coronary syndrome (ACS), and still is in some trusts, though is no longer part of NICE guidance.

C Fraxiparin

Fraxiparin is a low-molecular weight heparin similar to enoxaparin.

D Fondaparinux

Fondaparinux, is the antithrombin agent of choice if

9:43

bivalirudin

ALL NEWS IMAGES SHOPPING VIDEOS BOOKS MAPS FL

Bivalirudin
Drug

Bivalirudin is a direct thrombin inhibitor. Chemically, it is a synthetic congener of t
hirudin. Bivalirudin is a DTI that overcomes many limitations seen with indirect thr
heparin. Bivalirudin is a short, synthetic peptide. Wikipedia

Molar mass: 2,180.29 g/mol

Formula: $C_{98}H_{138}N_{24}O_{33}$

People also search for: Argatroban, Fondaparinux, Eptifibatide, Tirofiban, Dabigatr
Abciximab, Lepirudin, Ticagrelor, Clopidogrel, Hirudin, Prasugrel, Rivaroxaban, mo

More about Bivalirudin

BIVALIRUDIN | Drug | BNF content published by NICE
https://bnf.nice.org.uk › drug › bivalirudin

Indications, dose, contra-indications, side-effects, interactions, cautions, warnings
for BIVALIRUDIN.

Bivalirudin - Wikipedia
https://en.wikipedia.org › wiki › Bivaliru...

Bivalirudin is a direct thrombin inhibitor (DTI). Chemically, it is a synthetic congene
hirudin Bivalirudin is a DTI that overcomes many limitations seen with indirect thr

Trade names: Angiomax

Routes of administration: Intravenous injection/infusion only

Pregnancy category: US: B (No risk in non-human studies)

ATC code: B01AE06 (WHO)

Indications | Basic chemical and ... | Dosing and administration | Safety i

Discover Updates Search Rec

she is likely to have angiography within the next 24 h. In this situation, NICE recommends unfractionated heparin over fondaparinux. A glycoprotein inhibitor such as tirofiban or abciximab is also indicated in high-risk patients such as this.

E Bivalirudin

Bivalirudin, is an alternative to unfractionated heparin with a glycoprotein inhibitor where angiography is considered within 24 h. It is also used in patients who suffer from heparin-induced thrombocytopenia.

B Enoxaparin

Enoxaparin, was formerly used for acute coronary syndrome (ACS), and still is in some trusts, though is no longer part of NICE guidance.

C Fraxiparin

Fraxiparin is a low-molecular weight heparin similar to enoxaparin.

D Fondaparinux

Fondaparinux, is the antithrombin agent of choice if angiography is not being expedited.

Rate this question:

Next Question

Previous Q... Tag Questi... Feedback End Session

9:47

A 50-year-old man comes to the cardiology clinic for follow-up. He has been annually followed up in the clinic for 10 years for his aortic stenosis. He informs you that his exercise tolerance has decreased. He experiences some chest discomfort and dizziness on strenuous exertion. On examination, he is comfortable with a blood pressure of 125/85 mmHg and pulse of 76/min and regular. His jugular venous pulse is not raised and his chest is clinically clear. First and second heart sounds are heard and there is an ejection systolic murmur grade 3/6 in the aortic distribution.

On echocardiogram, a gradient of 60 mmHg is found across the aortic valve.

You explain to the patient that he will need a valve replacement. He would like to know the pros and cons of the different heart valves.

Which one of the following statements is true of prosthetic heart valves?

A	A tissue valve would be most suitable for this patient
B	Both tissue and metallic valves need anticoagulation for life
C	Tissue valves last as long as metallic valves
D	A metallic valve would be most suitable for this patient
E	Tissue valves last for 5 years on average

Rana Alnasser's screen

125/85 mmHg and pulse of 76/min and regular. His jugular venous pulse is not raised and his chest is clinically clear. First and second heart sounds are heard and there is an ejection systolic murmur grade 3/6 in the aortic distribution.

On echocardiogram, a gradient of 60 mmHg is found across the aortic valve.

You explain to the patient that he will need a valve replacement. He would like to know the pros and cons of the different heart valves.

Which one of the following statements is true of prosthetic heart valves?

Your answer was correct

A	A tissue valve would be most suitable for this patient
B	Both tissue and metallic valves need anticoagulation for life
C	Tissue valves last as long as metallic valves
D	A metallic valve would be most suitable for this patient
E	Tissue valves last for 5 years on average

Explanation

D	A metallic valve would be most suitable for this patient

A metallic valve would be most suitable for this patient

D A metallic valve would be most suitable for this patient

A metallic valve would be most suitable for this patient because he is young. The negative side of metallic valves is that he will need anticoagulation for life. Data from a review published in 2012 also support the view that haemodynamic performance of mechanical valves and anti-coagulation may drive better outcomes versus tissue valves.

A A tissue valve would be most suitable for this patient

Tissue valves do not require anticoagulation but on average they only last for about 10 years. Therefore, since the patient is young, a metal valve is more appropriate.

B Both tissue and metallic valves need anticoagulation for life

Metallic heart valves require anticoagulation for life to prevent thromboembolism, while tissue valves do not require anticoagulation. The latter type does not increase the risk of thromboembolism.

C Tissue valves last as long as metallic valves

Tissue valves on average last for about 10 years, so metallic valves last longer. Mechanical heart valves are more resistant than tissue valves to the constant demands placed on them, such as opening and closing with every heartbeat. The materials used in mechanical valves stand up well to wear and tear as opposed to tissue valves.

E Tissue valves last for 5 years on average

the patient is young, a metal valve is more appropriate.

B	Both tissue and metallic valves need anticoagulation for life

Metallic heart valves require anticoagulation for life to prevent thromboembolism, while tissue valves do not require anticoagulation. The latter type does not increase the risk of thromboembolism.

C	Tissue valves last as long as metallic valves

Tissue valves on average last for about 10 years, so metallic valves last longer. Mechanical heart valves are more resistant than tissue valves to the constant demands placed on them, such as opening and closing with every heartbeat. The materials used in mechanical valves stand up well to wear and tear as opposed to tissue valves.

E	Tissue valves last for 5 years on average

Tissue heart valves on average last for about 10 years. Fortunately, there is adequate time to prepare for valve replacement. It is important to remember that any valve replacement surgery carries a significant risk of death, so a patient's life expectancy is a major criterion in considering whether to insert a tissue valve.

7497

Rate this question:

A 19-year-old football player has been referred to A&E following a pre-season medical. He had spent the morning training, and was subsequently undergoing a series of tests including an ECG. When the ECG was taken, it showed ST segment elevation in the anterior chest leads and he was quickly referred to the Emergency Department.
On arrival at the Emergency Department, he was comfortable but anxious at rest. He had no chest pain during or after exercise, no shortness of breath and no dizziness/loss of consciousness. His past medical history was unremarkable and he was not on any medication. His physical examination was entirely normal.

Investigations:

Chest X-ray	Normal
ECG	Sinus rhythm, with 2 mm concave ST elevation in V_2–V_5. J point notching is seen, with peaked T waves

What is the most likely diagnosis?

A	Wolff–Parkinson–White syndrome
B	Early repolarisation
C	Acute myocardial infarction
D	Pericarditis
E	Pulmonary embolism

On arrival at the Emergency Department, he was comfortable but anxious at rest. He had no chest pain during or after exercise, no shortness of breath and no dizziness/loss of consciousness. His past medical history was unremarkable and he was not on any medication. His physical examination was entirely normal.

Investigations:

Chest X-ray	Normal
ECG	Sinus rhythm, with 2 mm concave ST elevation in V_2–V_5. J point notching is seen, with peaked T waves

What is the most likely diagnosis?

Your answer was correct

A Wolff–Parkinson–White syndrome

B Early repolarisation

C Acute myocardial infarction

D Pericarditis

E Pulmonary embolism

Explanation

B Early repolarisation

There exists a benign but often alarming electrocardiographic entity that presents with ST segment elevation. It is known as the early repolarisation variant and

B Early repolarisation

There exists a benign but often alarming electrocardiographic entity that presents with ST segment elevation. It is known as the early repolarisation variant and expresses as an early uptake of the ST segment before the descending limb of the R wave has reached the baseline. Features of early repolarization variant are:

- Classically the ST segment elevation during early exercise returns to normal as heart rate increases further
- It is common in black males
- Clinical evaluation is entirely normal
- ST elevation is usually seen in the precordial leads.

A Wolff–Parkinson–White syndrome

Wolff–Parkinson–White syndrome is associated with an accessory conduction pathway between the atrium and ventricle. ECG features include a short PR interval, a delta wave (slurred upstroke of the QRS complex) and a broad QRS complex. The morphology of the delta wave is suggestive of the location of the accessory pathway.

C Acute myocardial infarction

The history given is not typical for acute myocardial infarction, in that there is no chest pain or associated autonomic features. The patient also has no risk factors for ACS. The ECG features seen are more in keeping with benign early repolarisation than acute MI, and there is no evidence of reciprocal ECG changes to support this diagnosis.

D Pericarditis

9:56

Early repolarization pattern on ECG (early repolarization syndrome) – ECG learn...
https://ecgwaves.com

Stop Annotation Spotlight Pen Highlighter Line Rectangle Oval Undo Redo Clear Color Stop Share

from sudden cardiac arrest at the a

9:56
594-042-7551
Leave
66% 19:56

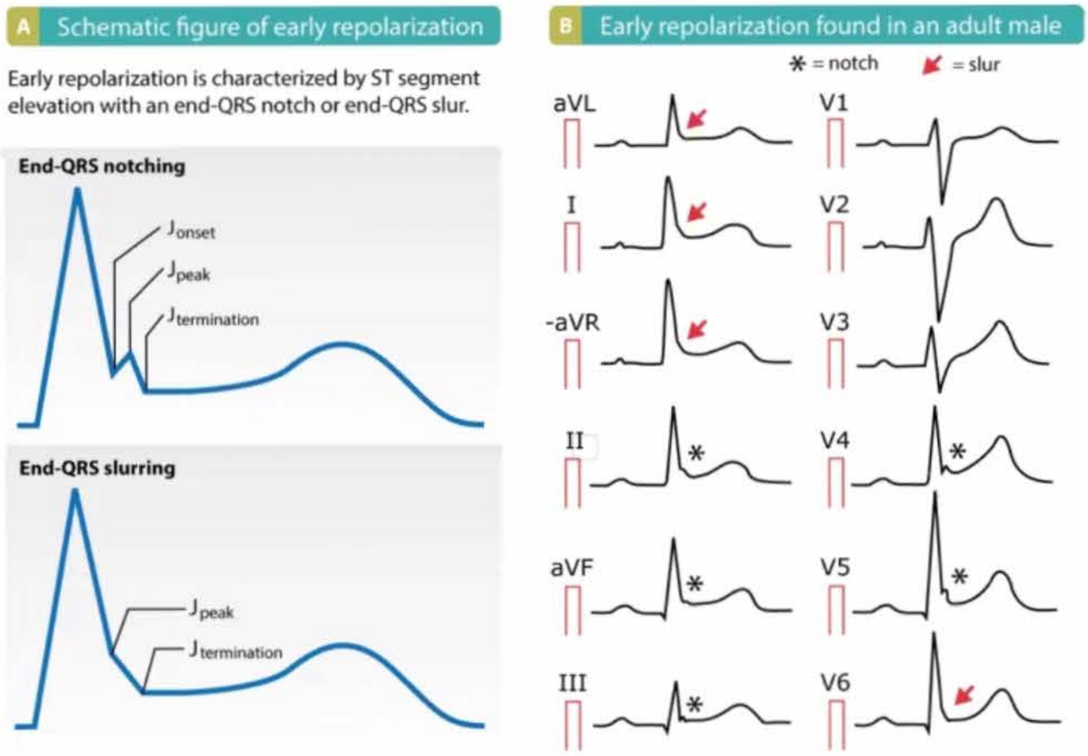

Figure 1. Early repolarization pattern on ECG. Note the end-QRS notches and slurs, as well as the ST segment elevations.

The end-QRS notch is located above the baseline and the end-QRS slur starts before the baseline is reached. As seen in Figure 1, the terms J_{onset}, J_{peak}, $J_{termination}$ are used to desbribe the notch/slurring. However, these terms lack clinical significance. In case of ST segment elevation, the magnitude of the ST segment elevation is always measured

ECG criteria for early repolarization

According to MacFarlane et al:

Audio
Video
Share
Participants
More

9:56

D Pericarditis

There is no history of chest pain given by the patient, nor prodromal features such as viral illness. The changes here are localised to the precordial leads, where changes in pericarditis are often more generalised in nature. Additionally, the presence of J-point notching and prominent T waves is more suggestive of benign early repolarisation than pericarditis.

E Pulmonary embolism

The most common ECG change seen in cases of acute pulmonary embolus is sinus tachycardia. There may also be the presence of a large S wave inlLead 1, with a Q wave and T wave inversion in lead 3 ('$S_1Q_3T_3$'), indicative of right heart strain. There are also no symptoms such as dyspnoea or acute chest pain, or risk factors such as immobility to support this diagnosis.

Rate this question:

Next Question

Previous Q... Tag Questi... End Session

© Pastest 2019

Rana Alnasser's screen

9:56

A 68-year-old lady has had more than three readings of blood pressure (BP) 175/65 mmHg during the past month. She is obese with a body mass index of 34. On further questioning she admits to shortness of breath on minimal exercise, and occasionally she wakes in the night very short of breath and has to open the windows. She does not report suffering from any excessive sleepiness in the daytime, and is able to maintain her job as a busy PA.

Which of the following would be the most appropriate initial therapy in this patient?

A	Ramipril
B	Atenolol
C	Bendrofluazide
D	Doxazosin
E	Bisoprolol

6554

Submit

Rana Alnasser's screen

9:59

MyPastest
https://mypastest.pastest.com

Pastest+

A 68-year-old lady has had more than three readings of blood pressure (BP) 175/65 mmHg during the past month. She is obese with a body mass index of 34. On further questioning she admits to shortness of breath on minimal exercise, and occasionally she wakes in the night very short of breath and has to open the windows. She does not report suffering from any excessive sleepiness in the daytime, and is able to maintain her job as a busy PA.

Which of the following would be the most appropriate initial therapy in this patient?

Your answer was correct

A Ramipril

B Atenolol

C Bendrofluazide

D Doxazosin

E Bisoprolol

Explanation

A Ramipril

While NICE guidelines recommend calcium channel blockers in the over 55 age group, her obesity and heart

A Ramipril

While NICE guidelines recommend calcium channel blockers in the over 55 age group, her obesity and heart failure would drive you towards ramipril. Her shortness of breath may be indicative of left ventricular dysfunction, therefore ramipril would be the best choice. Meta-analyses have suggested that ARBs or ACEIs are associated with the lowest incidence of diabetes.

NICE guidelines recommend clinic blood pressure and subsequent ambulatory blood pressure monitoring for diagnosis of hypertension. Screening for complications, ie target organ damage, is required, including ECG to exclude left ventricular hypertrophy or previous cardiovascular events, urine dip for protein, renal function and hypertensive retinal changes.

In addition to lifestyle modification, medication can be initiated in this case of grade 2 hypertension.

B Atenolol

Beta-blockers are not recommended for initial treatment of uncomplicated hypertension owing to conflicting evidence on their benefit. The majority of evidence for β-blockers in hypertensive management is based upon atenolol.

C Bendrofluazide

Given this patient has signs suggestive left ventricular impairment, an ACE inhibitor would be preferred over a thiazide diuretic such as bendroflumethiazide. Thiazide-like diuretics are now a more favourable alternative to the traditional thiazides, with them being particularly effective for antihypertensive treatment when used in combination therapy. Side effects include hyperuricaemia, hyperglycaemia, hyponatraemia and hypokalaemia.

In addition to lifestyle modification, medication can be initiated in this case of grade 2 hypertension.

B Atenolol

Beta-blockers are not recommended for initial treatment of uncomplicated hypertension owing to conflicting evidence on their benefit. The majority of evidence for β-blockers in hypertensive management is based upon atenolol.

C Bendrofluazide

Given this patient has signs suggestive left ventricular impairment, an ACE inhibitor would be preferred over a thiazide diuretic such as bendroflumethiazide. Thiazide-like diuretics are now a more favourable alternative to the traditional thiazides, with them being particularly effective for antihypertensive treatment when used in combination therapy. Side effects include hyperuricaemia, hyperglycaemia, hyponatraemia and hypokalaemia.

D Doxazosin

Alpha-blockers are not recommended because in the ALLHAT trial, treatment with doxazocin resulted in worse outcomes leading to early termination in the treatment arm.

E Bisoprolol

Atenolol is the β-blocker upon which the majority of evidence for antihypertensive treatment is based. The ASCOT study reported that the use of β-blockers and thiazides increased the risk of new-onset type 2 diabetes, therefore they would not be the preferred option this scenario.

A 23-year-old man is admitted as an emergency from a nightclub. He presents with new-onset atrial fibrillation (AF) with a ventricular rate of 130 bpm. His systolic blood pressure is only 95 mmHg and he is electrically cardioverted. His sinus rhythm electrocardiogram (ECG) shows a PR interval of 100 milliseconds and a slurred onset of the QRS complex (delta wave).

What is the long-term treatment of choice in this patient?

A	Digoxin
B	Amiodarone
C	Sotalol
D	Radiofrequency ablation of the accessory pathway
E	Cardioversion for symptomatic arrhythmias in the future

8561

Submit

Previous Q... Skip Questi...

© Pastest 2019

A 23-year-old man is admitted as an emergency from a nightclub. He presents with new-onset atrial fibrillation (AF) with a ventricular rate of 130 bpm. His systolic blood pressure is only 95 mmHg and he is electrically cardioverted. His sinus rhythm electrocardiogram (ECG) shows a PR interval of 100 milliseconds and a slurred onset of the QRS complex (delta wave).

What is the long-term treatment of choice in this patient?

Your answer was correct

A	Digoxin
B	Amiodarone
C	Sotalol
D	Radiofrequency ablation of the accessory pathway
E	Cardioversion for symptomatic arrhythmias in the future

Explanation

D	Radiofrequency ablation of the accessory pathway

This patient has Wolff–Parkinson–White syndrome associated with an accessory conduction pathway leading to earlier than normal ventricular depolarisation, predisposing the patient to tachyarrhythmias. The majority of patients present with reciprocating tachycardias at 150–250 bpm. 15% present with AF and around 5% with atrial

D Radiofrequency ablation of the accessory pathway

This patient has Wolff–Parkinson–White syndrome associated with an accessory conduction pathway leading to earlier than normal ventricular depolarisation, predisposing the patient to tachyarrhythmias. The majority of patients present with reciprocating tachycardias at 150–250 bpm, 15% present with AF and around 5% with atrial flutter. In a patient of this age, referral to a cardiovascular electrophysiologist for consideration of radiofrequency ablation would be the treatment of choice.

A Digoxin

AV nodal blocking agents should be avoided with pre-excited AF; digoxin can enhance antegrade conduction through the accessory pathway resulting in a rapid ventricular rate and subsequent ventricular fibrillation.

B Amiodarone

Stable patients with atrioventricular re-entrant tachycardia (AVRT) may respond to amiodarone to control the rate of the re-entrant tachycardia; however long-term treatment of choice is radiofrequency ablation of the accessory pathway.

C Sotalol

Beta-blockers do not usually affect the accessory pathway conduction but can often reduce the rate of re-entrant tachycardia.

E Cardioversion for symptomatic arrhythmias in the future

A 19-year-old college student presents with history of three episodes of transient loss of consciousness over the past 2 months. All three episodes happened while the patient was standing and were preceded by a feeling of nausea, warmth and light-headedness. He regains consciousness shortly after the collapse but he continues to feel nauseated and fatigued for about 15 min. There is no past medical history of note. His father had died of myocardial infarction at age of 60 years. His physical examination is unremarkable and there is no orthostatic hypotension.

Investigations reveal:

Sodium	135 mmol/l
Potassium	4.5 mmol/l
Urea	8 mmol/l
Creatinine	70 µmol/l
Haemoglobin	14 g/dL
White cell count	10×10^9/L
Electrocardiogram (ECG)	normal
Chest X-ray	normal
Echocardiogram	normal

What is the best investigation in evaluation of this patient?

A 24-hour electrocardiogram (ECG) monitoring

B Computed tomography (CT) of the head

C Electroencephalogram (EEG)

D Exercise electrocardiography

standing and were preceded by a feeling of nausea, warmth and light-headedness. He regains consciousness shortly after the collapse but he continues to feel nauseated and fatigued for about 15 min. There is no past medical history of note. His father had died of myocardial infarction at age of 60 years. His physical examination is unremarkable and there is no orthostatic hypotension.

Investigations reveal:

Sodium	135 mmol/l
Potassium	4.5 mmol/l
Urea	8 mmol/l
Creatinine	70 µmol/l
Haemoglobin	14 g/dL
White cell count	10×10^9/L
Electrocardiogram (ECG)	normal
Chest X-ray	normal
Echocardiogram	normal

What is the best investigation in evaluation of this patient?

A 24-hour electrocardiogram (ECG) monitoring

B Computed tomography (CT) of the head

C Electroencephalogram (EEG)

D Exercise electrocardiography

E Tilt table test

E Tilt table test

The history in this case suggests vasovagal syncope. Th patients with vasovagal syncope are usually young and healthy, episodes occur while standing and there is a prodrome of nausea, warmth, pallor or sweating. The syncope lasts briefly, but nausea, warmth and sweating may persist for some time. Patients may also report fati on recovery. If structural heart disease is excluded and syncope is reproduced on tilt table testing along with fa blood pressure and heart rate, then this is diagnostic of vasovagal syncope.

A 24-hour electrocardiogram (ECG) monitoring

Syncope associated with arrhythmias is usually sudden, without prodromal symptoms and has rapid recovery. T patient has normal electrocardiogram (ECG) and echocardiography therefore 24-hour electrocardiogram unlikely to contribute anything. It is unlikely to be an arrhythmia.

B Computed tomography (CT) of the head

Symptoms are not suggestive of seizures or structural brain disease. We may expect added symptoms of post ictal confusion or incontinence during loss of consciousness episodes if there was indication of seizu

C Electroencephalogram (EEG)

Symptoms are not suggestive of seizures or structural brain disease. We may expect added symptoms of post ictal confusion or incontinence during loss of

10:04
594-042-7551
Leave

A 54-year-old man, who has received tissue plasminogen activator (TPA) for an anterior myocardial infarction (MI), develops sudden dyspnoea and left ventricular failure five days later.

On examination systolic murmur is heard loudest at the left sternal edge. Echocardiography with colour flow Doppler reveals a left to right shunt.

What is the diagnosis?

A	Ventricular septal defect (VSD)
B	Mitral regurgitation
C	Atrial septal defect
D	Aortic regurgitation
E	Aortic dissection

6557

Submit

Blog About Pastest Contact Us Help
© Pastest 2019
Audio Video Share Participants More

A Ventricular septal defect (VSD)

VSD is classically seen 5–10 days after MI. Patients present with rapid deterioration, pulmonary oedema and hypotension. There is a harsh pansystolic murmur loudest at the left sternal edge. Diagnosis is usually made with the aid of colour flow Doppler. Inotropes are used to manage severe hypotension; cautious vasodilator therapy may be employed if the systolic blood pressure is above 100 mmHg. If patients remain unstable, intra-aortic balloon pump may be considered. Surgical or specialist cardiological opinion should be requested with reference to formal surgical closure or catheter placement of an umbrella device.

B Mitral regurgitation

Mitral regurgitation can occur due to papilllary muscle damage as a complication of an MI. The murmur is typically pansystolic and best heard at the cardiac apex, with radiation to the axillae.

C Atrial septal defect

Atrial septal defects can present as a chronic left to right shunt which results in right ventricular volume overload. It is not commonly associated with acute myocardial infarction, therefore the patient's presentation and heart sounds are consistent with an acute ventricular septal defect (VSD) secondary to ischaemia.

D Aortic regurgitation

Aortic regurgitation is not a typical complication of an acute MI. An aortic regurgitation murmur may be described as an early diastolic murmur, loudest at the right sternal edge, second intercostal space and accentuated by leaning

shunt which results in right ventricular volume overload. It is not commonly associated with acute myocardial infarction, therefore the patient's presentation and heart sounds are consistent with an acute ventricular septal defect (VSD) secondary to ischaemia.

D Aortic regurgitation

Aortic regurgitation is not a typical complication of an acute MI. An aortic regurgitation murmur may be described as an early diastolic murmur, loudest at the right sternal edge, second intercostal space and accentuated by leaning the patient forward in held expiration.

E Aortic dissection

Aortic dissections present classically as acute central chest pain radiating to the back, described as a sharp, tearing or ripping pain. Patients exhibit acute cardiac decompensation and shock. An aortic regurgitation murmur may be detected depending upon the type of dissection.

Rate this question:

Next Question

Previous Q... Tag Questi... Feedback End Session

Blog About Pastest Contact Us Help

© Pastest 2019

A 30-year-old man is found to be hypertensive with a blood pressure of 165/95 mmHg during a routine work medical. He is referred to Cardiology for further investigation and undergoes an echocardiogram that shows a hypertrophic left ventricle, with a bicuspid aortic valve that is seen to open well and with no significant pressure gradient across the valve.

Which of the following investigations is most likely to provide the underlying diagnosis?

A	24 h urinary cortisol
B	Urinary catecholamines
C	Renal ultrasound with Doppler
D	MRI thorax
E	Plasma renin

Submit

© Pastest 2019

A 30-year-old man is found to be hypertensive with a blood pressure of 165/95 mmHg during a routine work medical. He is referred to Cardiology for further investigation and undergoes an echocardiogram that shows a hypertrophic left ventricle, with a bicuspid aortic valve that is seen to open well and with no significant pressure gradient across the valve.

Which of the following investigations is most likely to provide the underlying diagnosis?

Your answer was correct

A 24 h urinary cortisol

B Urinary catecholamines

C Renal ultrasound with Doppler

D MRI thorax

E Plasma renin

Explanation

D MRI thorax

The finding of hypertension in a young patient with no risk factors or previous medical history should prompt consideration of secondary hypertension. One such cause is aortic coarctation, which can be associated with a bicuspid aortic valve, and is the likely underlying cause in this case. A computerised tomography (CT) aortogram or

Explanation

D MRI thorax

The finding of hypertension in a young patient with no risk factors or previous medical history should prompt consideration of secondary hypertension. One such cause is aortic coarctation, which can be associated with a bicuspid aortic valve, and is the likely underlying cause in this case. A computerised tomography (CT) aortogram or an MRI of the chest can define the exact site of the lesion. The prognosis of the condition is better the earlier a repair procedure is undertaken. There is 75% mortality by the age of 50 years if uncorrected.

A 24 h urinary cortisol

This would be used in the investigation of Cushing syndrome.

B Urinary catecholamines

This would be used in the investigation of a phaeochromocytoma.

C Renal ultrasound with Doppler

This would be appropriate if secondary hypertension were suspected secondary to renal or reno-vascular disease. The most likely diagnosis of aortic coarctation makes thoracic MRI a more appropriate investigation.

E Plasma renin

This would be appropriate in the investigation of low-renin hypertension, or renal artery hypertension.

10:09

A 41-year-old bond trader is brought to the Emergency Department by ambulance with crushing central chest pain, nausea, vomiting and collapse. He smokes 20 cigarettes per day and uses daily cocaine.

On examination, his blood pressure (BP) is 180/72 mmHg, his pulse is 95/min and he looks very unwell. He has bilateral crackles at both lung bases.

Investigations:

Hb	13.1 g/dl
WCC	6.7×10^9/l
PLT	167×10^9/l
Na^+	139 mmol/l
K^+	4.5 mmol/l
Creatinine	100 µmol/l
Troponin	3.0 µg/l
ECG	Anterior ST elevation consistent with acute MI
Coronary artery angiography	Left main stem, flow decreased by 85%, but no focal lesion identified

Which of the following is the most appropriate immediate management with respect to his chest pain?

A Aspirin

B Low-molecular weight (LMW) heparin

C Angioplasty

Rana Alnasser's screen

Hb	13.1 g/dl
WCC	6.7×10^9/l
PLT	167×10^9/l
Na^+	139 mmol/l
K^+	4.5 mmol/l
Creatinine	100 µmol/l
Troponin	3.0 µg/l
ECG	Anterior ST elevation consistent with acute MI
Coronary artery angiography	Left main stem, flow decreased by 85%, but no focal lesion identified

Which of the following is the most appropriate immediate management with respect to his chest pain?

A Aspirin

B Low-molecular weight (LMW) heparin

C Angioplasty

D Atenolol

E GTN

Submit

Hb	13.1 g/dl
WCC	6.7×10^9/l
PLT	167×10^9/l
Na^+	139 mmol/l
K^+	4.5 mmol/l
Creatinine	100 µmol/l
Troponin	3.0 µg/l
ECG	Anterior ST elevation consistent with acute MI
Coronary artery angiography	Left main stem, flow decreased by 85%, but no focal lesion identified

Which of the following is the most appropriate immediate management with respect to his chest pain?

Your answer was correct

A Aspirin

B Low-molecular weight (LMW) heparin

C Angioplasty

D Atenolol

E GTN

Explanation

E GTN

This case suggests a STEMI in an otherwise young and healthy patient. The use of cocaine can lead to the development of coronary vasospasm. This is suggested by the coronary angiogram which does not show a focal lesion. Intravenous (iv) GTN is the most appropriate initial management for the treatment of coronary vasospasm.

A Aspirin

Aspirin has a role in the acute treatment of acute coronary syndrome where platelet aggregation following plaque rupture plays a major pathological role. However, antiplatelet agents have no role in the treatment of coronary vasospasm, the underlying condition in this case.

B Low-molecular weight (LMW) heparin

LMWH, primarily fondaparinux, is part of the treatment bundle for acute coronary syndrome. However, there is no evidence of acute occlusion on the angiogram. LMWH is unnecessary in coronary vasospasm.

C Angioplasty

No focal lesion was seen on angiography, as such there is no location amenable to stenting. This is a case of coronary vasospasm for which stenting is not appropriate.

D Atenolol

Beta-blockade is an important element in the treatment bundle for acute coronary syndrome. In that setting it reduces the risk of post-infarct arrhythmias. However, in the case of coronary vasospasm, beta-blockade may worsen vasoconstriction and should be avoided.

development of coronary vasospasm. This is suggested by the coronary angiogram which does not show a focal lesion. Intravenous (iv) GTN is the most appropriate initial management for the treatment of coronary vasospasm.

A Aspirin

Aspirin has a role in the acute treatment of acute coronary syndrome where platelet aggregation following plaque rupture plays a major pathological role. However, antiplatelet agents have no role in the treatment of coronary vasospasm, the underlying condition in this case.

B Low-molecular weight (LMW) heparin

LMWH, primarily fondaparinux, is part of the treatment bundle for acute coronary syndrome. However, there is no evidence of acute occlusion on the angiogram. LMWH is unnecessary in coronary vasospasm.

C Angioplasty

No focal lesion was seen on angiography, as such there is no location amenable to stenting. This is a case of coronary vasospasm for which stenting is not appropriate.

D Atenolol

Beta-blockade is an important element in the treatment bundle for acute coronary syndrome. In that setting it reduces the risk of post-infarct arrhythmias. However, in the case of coronary vasospasm, beta-blockade may worsen vasoconstriction and should be avoided.

Rate this question:

You see a 20-year-old man in clinic who has been referred for investigation of mild heart failure, for which his general practitioner prescribed furosemide 40 mg twice daily. This resulted in some improvement in symptoms. On examination the patient appears well. He has a sinus tachycardia of 110 beats/min and blood pressure is 120/85 mmHg. Chest examination reveals mild, coarse crepitations at both lung bases. You also note that he has hypertrophied calves, but examination of his lower limbs reveals weakness of both proximal muscles and plantar flexion. Reflexes are normal. The patient has had a trans-thoracic echocardiogram which showed a dilated left ventricle with global hypokinesia and an ejection fraction of <50%.

Investigations:

Hb	12.6 g/dl (13–18)
WCC	8×10^9/l ($4–11 \times 10^9$)
Urea	6 mmol/l (2.5–7.5)
Creatinine	90 mmol/l (60–110)
Potassium	3.8 mmol/l (3.5–4.9)
Sodium	140 mmol/l (137–144)
Chloride	100 mmol/l (95–107)
Creatinine kinase	2100 U/l (24–195)

What is the most likely diagnosis?

A Viral myocarditis

B Fascio-scapulo-humeral muscular dystrophy

C Becker's muscular dystrophy

Rana Alnasser's screen

10:13
594-042-7551
Leave

flexion. Reflexes are normal. The patient has had a trans-thoracic echocardiogram which showed a dilated left ventricle with global hypokinesia and an ejection fraction of <50%.

Investigations:

Hb	12.6 g/dl (13–18)
WCC	8×10^9/l ($4–11 \times 10^9$)
Urea	6 mmol/l (2.5–7.5)
Creatinine	90 mmol/l (60–110)
Potassium	3.8 mmol/l (3.5–4.9)
Sodium	140 mmol/l (137–144)
Chloride	100 mmol/l (95–107)
Creatinine kinase	2100 U/l (24–195)

What is the most likely diagnosis?

A Viral myocarditis

B Fascio-scapulo-humeral muscular dystrophy

C Becker's muscular dystrophy

D Duchenne's muscular dystrophy

E Myotonic dystrophy

Submit
Audio Video Share Participants More

thoracic echocardiogram which showed a dilated left ventricle with global hypokinesia and an ejection fraction of <50%.

Investigations:

Hb	12.6 g/dl (13–18)
WCC	8×10^9/l ($4–11 \times 10^9$)
Urea	6 mmol/l (2.5–7.5)
Creatinine	90 mmol/l (60–110)
Potassium	3.8 mmol/l (3.5–4.9)
Sodium	140 mmol/l (137–144)
Chloride	100 mmol/l (95–107)
Creatinine kinase	2100 U/l (24–195)

What is the most likely diagnosis?

Your answer was correct

A Viral myocarditis

B Fascio-scapulo-humeral muscular dystrophy

C Becker's muscular dystrophy

D Duchenne's muscular dystrophy

E Myotonic dystrophy

Explanation

Rana Alnasser's screen

C Becker's muscular dystrophy

Becker's muscular dystrophy is an X-linked genetic disorder resulting from a mutation in the dystrophin gene. The clinical picture is similar to that of Duchenne's muscular dystrophy but it is much milder. Patients usually present between the ages of 5 and 15 years, though presentation may not be until the fourth or fifth decade. Patients may present with heart failure secondary to dilated cardiomyopathy rather than the classic proximal muscle weakness. Inheritance is X-linked recessive.

A Viral myocarditis

Viral myocarditis presents with a rapid deterioration in ejection fraction leading to marked cardiac failure; patients can often identify a precipitating illness.

B Fascio-scapulo-humeral muscular dystrophy

FMD very rarely affects cardiac or respiratory muscles compared to other forms of muscular dystrophy. It is more likely to be associated with high-tone deafness and defects of night vision.

D Duchenne's muscular dystrophy

DMD presents at a much earlier age and with more severe proximal muscle weakness than that seen here.

E Myotonic dystrophy

Myotonic dystrophy presents as progressive muscle weakness with increased tone and cardiac conduction defects rather than the frank cardiac failure seen here.

Rana Alnasser's screen

10:15
594-042-7551 Leave

A 67-year-old lady was admitted to the Emergency Department with central chest pains that had started 3 h earlier. The pain was crushing in nature, radiating to both arms and associated with nausea and vomiting. She has a past medical history of angina, hypertension and type II diabetes. She is on the following medications: glyceryl trinitrate (GTN) spray prn, amlodipine 10 mg od, atorvastatin 40 mg nocte, metformin 500 mg tds and aspirin 75 mg od.

On examination, she was sweaty with a blood pressure of 155/95 mmHg, pulse of 98/min and regular. Her respiratory rate was 24/min and her chest was clinically clear. Her jugular venous pulse was just visible, and first and second heart sounds were heard with no added murmurs.

Investigations:

Electrocardiogram (ECG)	ST elevation of 3 mm in V1–V4, with reciprocal ST depression in the inferior leads
Haemoglobin	13.8 g/dl
MCV	88.6 fl
PLT	240×10^9 /l
WCC	14.1×10^9 /l
Na^+	141 mmol/l
K^+	3.8 mmol/l
Urea	7.1 mmol/l
Creatinine	121 μmol/l

A bolus infusion of tenecteplase was given, together with diamorphine and metoclopramide. She is transferred to the coronary care unit.

You are asked to see her on day 4 post-infarct because the nurses are very concerned as she has become

Audio Video Share Participants More

Na^+	141 mmol/l
K^+	3.8 mmol/l
Urea	7.1 mmol/l
Creatinine	121 μmol/l

A bolus infusion of tenecteplase was given, together with diamorphine and metoclopramide. She is transferred to the coronary care unit.

You are asked to see her on day 4 post-infarct because the nurses are very concerned as she has become progressively more short of breath with hypotension, BP of 72/53 mmHg and pulse of 124/min sinus rhythm. Auscultation of her chest revealed a pan-systolic murmur, loudest at the lower left sternal edge and associated with an audible third heart sound.

An urgent echocardiogram at the time showed hyper-dynamic left ventricular function, muscular ventricular septal defect, dilated right ventricle and moderate tricuspid regurgitation.

You arrange review with respect to intra-aortic balloon pump insertion.

What is the most important additional intervention for this lady?

A Afterload reduction

B Immediate surgery

C Dobutamine

D Diuretics

E Dopamine

Rana Alnasser's screen

10:17
594-042-7551
Leave

A Afterload reduction

B Immediate surgery

C Dobutamine

D Diuretics

E Dopamine

Explanation

B Immediate surgery

Immediate surgery is recommended whatever the clinical status of the patient. The most important determinant of early outcome following post-infarction ventricular septal rupture is the development of heart failure. The associated cardiogenic shock leads to end-organ malperfusion, which may be irreversible. Clearly, performing surgery so close to both the infarct and thrombolysis carries a very high operative mortality, but you are left with little choice in this situation.

A Afterload reduction

Medical management is usually futile in post-infarction ventricular septal rupture, but afterload reduction may be tried. Afterload reduction increases effective left ventricular stroke volume by reducing left-to-right shunting. Intravenous afterload-reducing pharmacotherapy, such as sodium nitroprusside, has the advantage of being rapidly titrated or emergently discontinued compared with oral agents.

Audio Video Share Participants More

10:17
594-042-7551 Leave

tried. Afterload reduction increases effective left ventricular stroke volume by reducing left-to-right shunting. Intravenous afterload-reducing pharmacotherapy, such as sodium nitroprusside, has the advantage of being rapidly titrated or emergently discontinued compared with oral agents.

C Dobutamine

Dobutamine helps improve cardiac contractility in cardiogenic shock. However, dopamine would be a preferred agent in hypotension. In post-infarction ventricular septal rupture, immediate surgery is the only intervention that may potentially improve outcome.

D Diuretics

Diuretics may reduce pre-load on the heart, which may help in cardiac failure from other causes, but in this situation it would be ineffective because immediate surgery is the only intervention that may potentially improve outcome.

E Dopamine

Dopamine, an endogenous catecholamine, has been suggested to improve renal function in patients with congestive heart failure. However, there is insufficient evidence supporting its use and it is now not regularly used for this purpose. Certainly, it would not have a role in improving outcome in post-infarction ventricular septal rupture.

7486
Rate this question:
Next Question
Audio Video Share Participants More

A 73-year-old male presents to the Emergency Department complaining of central chest and back pain. This has started suddenly 2 hours ago and is getting progressively worse. He has a past medical history of hypertension, for which he is on bendroflumathiazide and perindopril. He denies any history of angina in the past.

On examination his blood pressure is 90/30 mmHg and his heart rate is 120 beats/min. There is an early diastolic murmur on auscultation of his heart and reduced air entry in the bases of his lungs bilaterally. He appears not to be moving the left side of his body.

An electrocardiogram (ECG) performed in the resuscitation area shows ST elevation in leads II, III and aVF.

A chest X-ray shows an enlarged heart with a small, left-sided pleural effusion.

Which of the following would be the most appropriate next step in the management?

A	Initiation of thrombolytic therapy with streptokinase
B	Fluid resuscitation and admission to the coronary care unit
C	Urgent computerised tomography of the chest with contrast
D	Bedside echocardiogram and urgent cardiothoracic review
E	Urgent cardiology referral for primary revascularisation

Rana Alnasser's screen

D Bedside echocardiogram and urgent cardiothoracic review

This patient presents with features suggestive of aortic dissection. In particular, the history of chest pain radiating to the back is concerning. The presence of an early diastolic murmur suggests aortic valve regurgitation. The ECG changes are in the inferior territory and indicate occlusion of the right coronary artery. These two features combined suggest that the dissection has tracked back to the heart itself. The enlarged heart on chest X-ray may suggest a haemopericardium, and the patient should be assessed for cardiac tamponade given his low blood pressure. This patient is highly unstable and requires urgent cardiothoracic involvement if he is to survive. Although a CT would be the gold standard investigation, he is too unstable to be moved. An echocardiogram is likely to visualise some aspect of the dissection in this instance due to the cardiac involvement. Additionally, it will be able to assess cardiac function and assess for the presence of cardiac tamponade.

E Urgent cardiology referral for primary revascularisation

The ST-segment elevation seen on the ECG, combined with chest pain, would be concerning and may suggest an acute right coronary artery occlusion. However, the nature of the chest pain and other clinical features presented should raise the suspicion of aortic dissection. This must be ruled out first before proceeding to coronary angiography.

A Initiation of thrombolytic therapy with streptokinase

The ECG findings here associated with chest pain may suggest a diagnosis of myocardial infarction. However, the nature of the chest pain should raise the concern of aortic

blood-thinning agents, as these could kill the patient.

B	Fluid resuscitation and admission to the coronary care unit

This patient likely does require careful fluid resuscitation as he appears to be developing haemodynamic compromise. However, this does not address the reason for the patient's deterioration. Further investigation is required to confirm the likely cause (in this case a possible type A aortic dissection).

C	Urgent computerised tomography of the chest with contrast

This patient likely has a type A aortic dissection. A CT scan of the chest with contrast is the gold standard investigation. However, because this patient has a systolic blood pressure of 90 mmHg and an elevated heart rate, he is probably too unstable to be moved to radiology at this time. The presence of an early diastolic murmur on auscultation suggests the presence of aortic regurgitation secondary to the dissection. If the dissection has involved the aortic valve then it is likely that some aspect of it will be visualised on ECG, which will not require the patient to be moved.

Rate this question:

Next Question

Previous Q... Tag Questi... Feedback End Session

Rana Alnasser's screen

Blog About Pastest Contact Us Help

10:22

A 32-year-old man is admitted from King's Cross station after a cardiac arrest. One of the station staff used an automatic defibrillator and shocked him from ventricular fibrillation into sinus rhythm. He denies chest pain prior to the event, has an unremarkable past medical history and documented normal glucose, blood pressure and cholesterol at his GP surgery. He is a non-smoker. On examination in casualty he is GCS (Glasgow Coma Scale) 13, blood pressure is 120/80 mmHg and he is now in sinus rhythm. The electrocardiogram reveals right bundle-branch block and ST elevation in the right precordial leads.

Which one of the following would be the most appropriate treatment option in this case?

A	Amiodarone
B	Verapamil
C	Implantable cardioverter defibrillator
D	Long-term anticoagulation
E	Atenolol

Submit

Previous Q... Skip Questi...

Rana Alnasser's screen

10:24

A 32-year-old man is admitted from King's Cross station after a cardiac arrest. One of the station staff used an automatic defibrillator and shocked him from ventricular fibrillation into sinus rhythm. He denies chest pain prior to the event, has an unremarkable past medical history and documented normal glucose, blood pressure and cholesterol at his GP surgery. He is a non-smoker. On examination in casualty he is GCS (Glasgow Coma Scale) 13, blood pressure is 120/80 mmHg and he is now in sinus rhythm. The electrocardiogram reveals right bundle-branch block and ST elevation in the right precordial leads.

Which one of the following would be the most appropriate treatment option in this case?

Your answer was correct

A Amiodarone

B Verapamil

C Implantable cardioverter defibrillator

D Long-term anticoagulation

E Atenolol

Explanation

C Implantable cardioverter defibrillator

Right bundle-branch block and ST elevation in the right precordial leads associated with ventricular fibrillation and sudden death is characteristic of Brugada syndrome.

Rana Alnasser's screen

ted to history of previous

C Implantable cardioverter defibrillator

Right bundle-branch block and ST elevation in the right precordial leads associated with ventricular fibrillation and sudden death is characteristic of Brugada syndrome. Prognosis of patients is related to history of previous syncope and inducibility of arrhythmias during ventricular stimulation. An implantable defibrillator is the treatment of choice in these patients, although a subset of patients may also be considered for therapy with quinidine, particularly those who present with 'VF storm', with multiple firings of their defibrillator in one day.

A Amiodarone

Amiodarone is not effective in the management of arrhythmia associated with Brugada syndrome. It may be of value in patients with VT related to ischaemic cardiomyopathy with decreased LV function.

B Verapamil

Verapamil is not of value in the management of Brugada syndrome; it is usually a treatment option for patients with paroxysmal SVT.

D Long-term anticoagulation

This patient's collapse isn't due to a thromboembolic phenomenon. Anticoagulation is therefore not of value here.

E Atenolol

Beta blockade is considered for patients with long-QT syndrome to reduce the risk of ventricular tachycardia.

10:27
594-042-7551
Leave

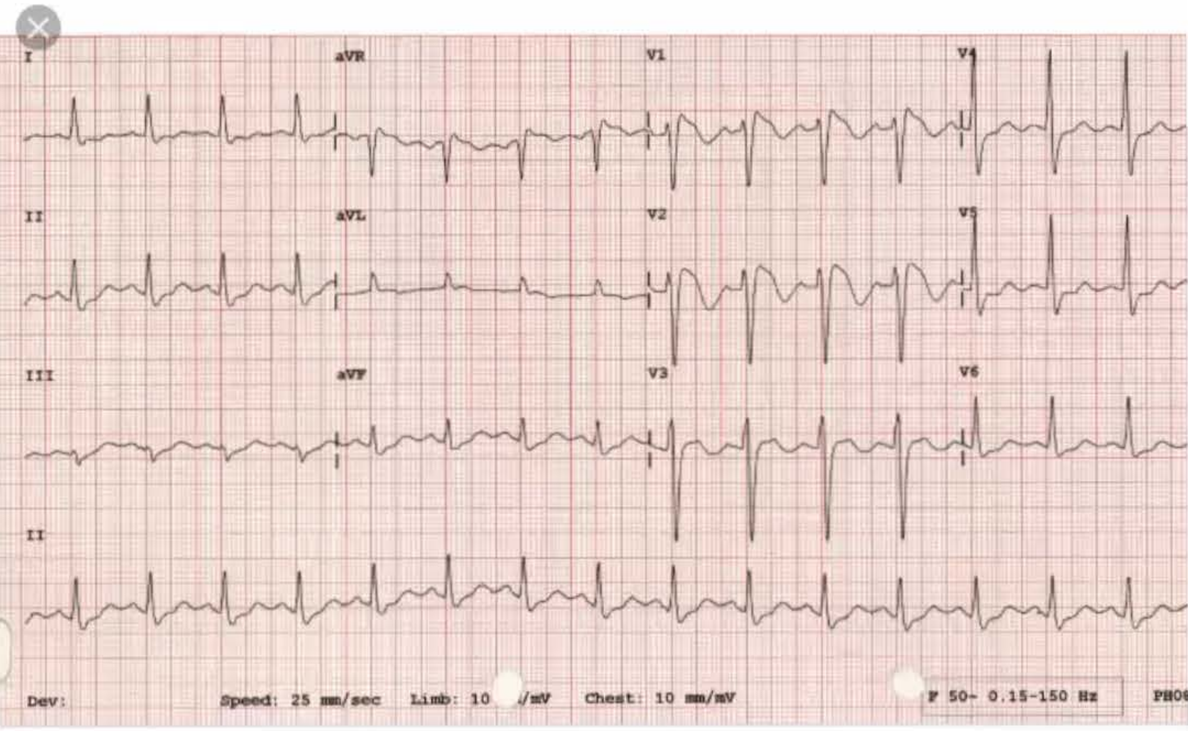

Life in the Fast Lane

Brugada Syndrome

Brugada type 1

Images may be subject to copyright. Learn more

RELATED IMAGES

Posterior STEMI - REBEL EM - Emergency M...
rebelem.com

Dr. Smith's ECG Blog: Young man with synco...
hqmeded-ecg.blogspot.com

Right bundle branch block – Par
ems12lead.com

Brugada Syndrome – The Student Physiologi...

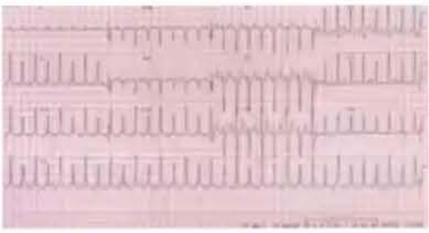

SVT – ECG quest
ecgquest.net

EKG showing sinus rhythm with
researchgate.net

Discover
Updates
Search
Recent
Mo

Audio
Video
Share
Participants
More

10:29
594-042-7551
Leave

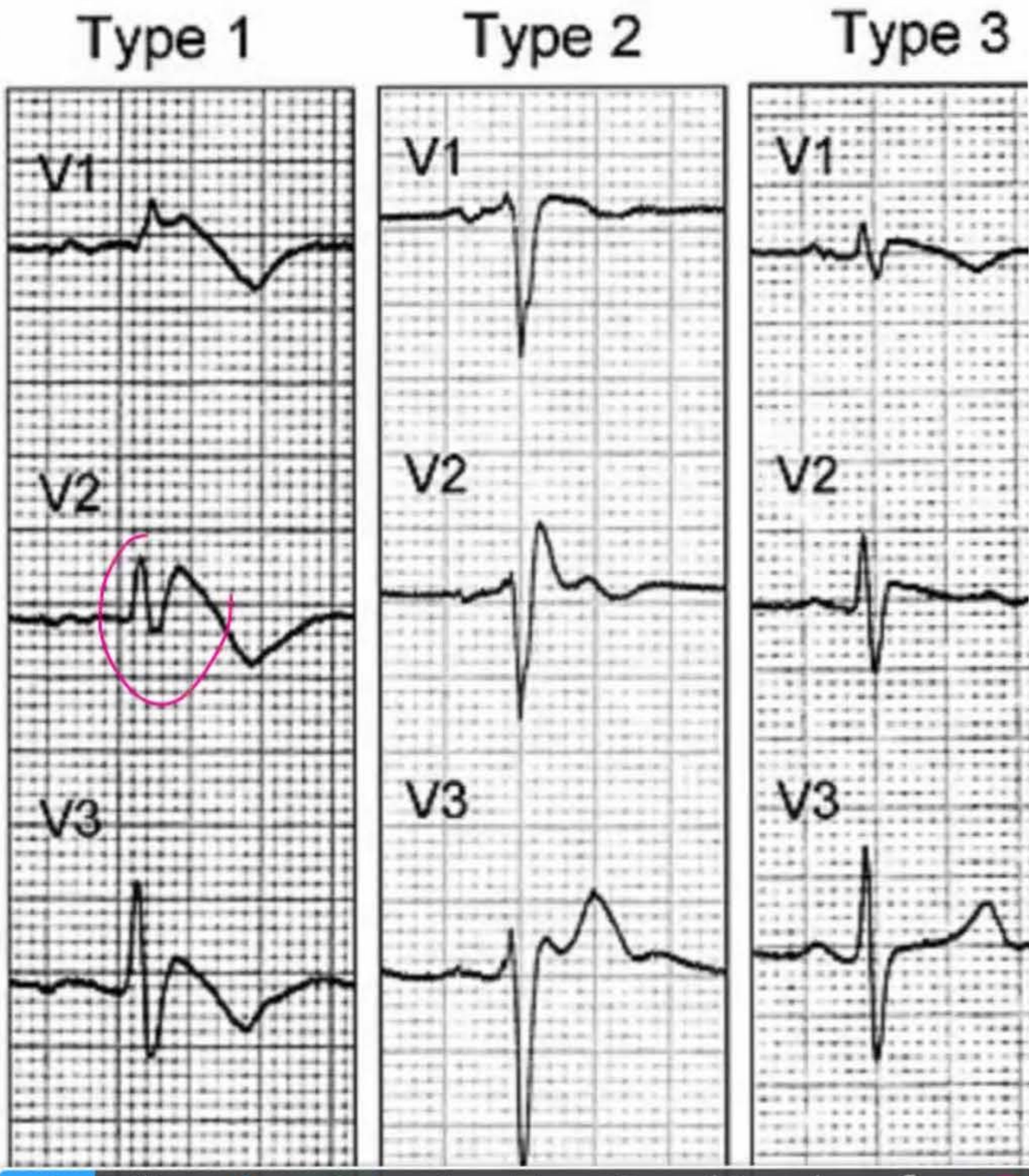

Stop Annotation
Spotlight
Pen
Highlighter
Line
Rectangle
Oval
Undo
Redo
Clear
Color
Wikipedia

Brugada syndrome - Wikipedia

ECG pattern in Brugada syndrome. According to a recent consensus document, Type 1 ST segment elevatio
spontaneously present or induced with the ...

Images may be subject to copyright. Learn more
Discover
Updates
Search
Recent
Mo
Audio
Video
Share
Participants
More

10:29

You are working as an expedition doctor on a climbing trip to the Andes. A 38-year-old man is brought down rapidly from the mountain to base camp.

On arrival at the medical tent, he is on 40% oxygen and saturations are still only 90%.

On examination, there is evidence of bilateral crepitations, consistent with pulmonary oedema.

Which of the following agents represents the next most appropriate intervention for this man?

A	Intravenous (IV) furosemide
B	IV Hydrocortisone
C	Nifedipine
D	Acetazolamide
E	High-concentration oxygen

6559

Submit

Previous Q... Skip Questi...

© Pastest 2019

Rana Alnasser's screen

You are working as an expedition doctor on a climbing trip to the Andes. A 38-year-old man is brought down rapidly from the mountain to base camp.

On arrival at the medical tent, he is on 40% oxygen and saturations are still only 90%.

On examination, there is evidence of bilateral crepitations, consistent with pulmonary oedema.

Which of the following agents represents the next most appropriate intervention for this man?

Your answer was incorrect

A	Intravenous (IV) furosemide
B	IV Hydrocortisone
C	Nifedipine
D	Acetazolamide
E	High-concentration oxygen

Explanation

E	High-concentration oxygen

This man has high-altitude pulmonary oedema, a type of high-altitude illness. This is caused by accumulation of white and red blood cells in the lungs due to a breakdown of the pulmonary blood–gas barrier due to hypobaric hypoxia. This results in accumulation of extravascular fluid in the alveolar spaces – pulmonary oedema.

E High-concentration oxygen

This man has high-altitude pulmonary oedema, a type of high-altitude illness. This is caused by accumulation of white and red blood cells in the lungs due to a breakdown of the pulmonary blood-gas barrier due to hypobaric hypoxia. This results in accumulation of extravascular fluid in the alveolar spaces – pulmonary oedema.

Nifedipine reduces pulmonary hypertension and is the treatment of choice for pulmonary oedema in cases where high-concentration oxygen is not available. In this case, however, it is, so oxygen would be initiated first, particularly in view of persistent hypoxia on 40% oxygen.

D Acetazolamide

Acetazolamide may be of some value in prophylaxis in preventing acute mountain sickness, but the best prevention is slow acclimatisation.

A Intravenous (IV) furosemide

Given the pathophysiology of high-altitude pulmonary oedema caused by exposure to a low partial pressure of oxygen at high altitude, IV furosemide is not the correct choice.

B IV Hydrocortisone

In acute mountain sickness, patients may also present with high-altitude cerebral oedema, the treatment for which is dexamethasone.

10:35

MyPastest
https://mypastest.pastest.com

Pastest+

Acetazolamide may be of some value in prophylaxis in preventing acute mountain sickness, but the best prevention is slow acclimatisation.

A Intravenous (IV) furosemide

Given the pathophysiology of high-altitude pulmonary oedema caused by exposure to a low partial pressure of oxygen at high altitude, IV furosemide is not the correct choice.

B IV Hydrocortisone

In acute mountain sickness, patients may also present with high-altitude cerebral oedema, the treatment for which is dexamethasone.

C Nifedipine

If high-flow oxygen is not available, then nifedipine can be used as second line. It reduces pulmonary hypertension and therefore is an appropriate choice for pulmonary oedema in the context of acute mountain sickness.

Rate this question:

Previous Q... Tag Questi... Feedback End Session

You are called to see a 58-year old man who has had a ventricular fibrillation (VF) arrest. He reverts to sinus rhythm following the third electrical shock with a maintained BP of 110/70 mmHg. He is a smoker who has significant peripheral vascular disease and stable angina and has undergone a femoral-popliteal bypass graft on the previous day.

A post-arrest electrocardiogram (ECG) is available as shown:

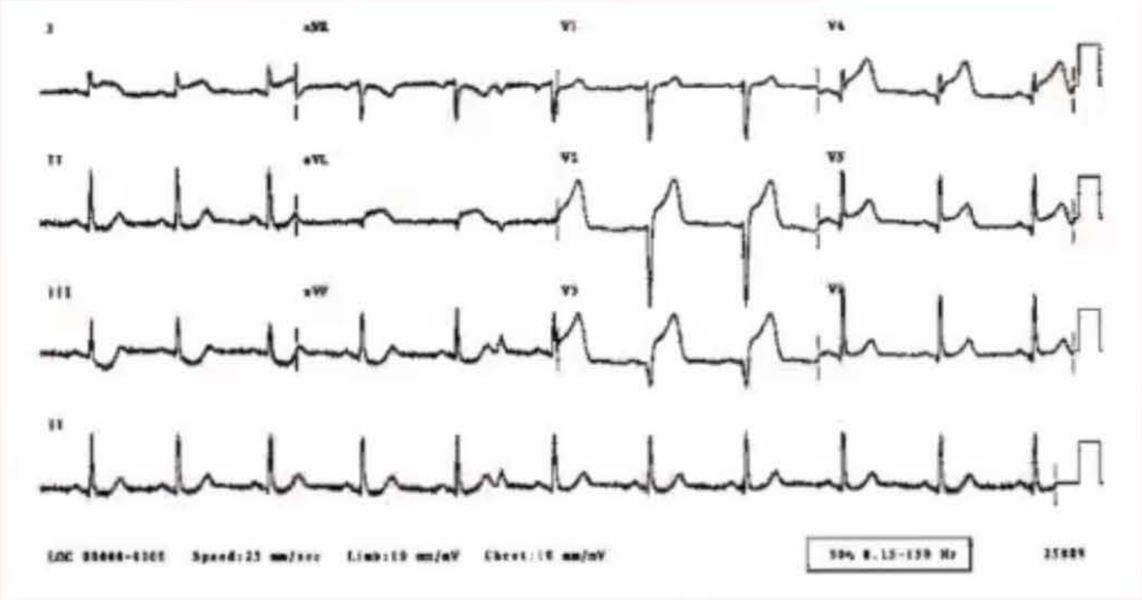

Occlusion of which of the following coronary arteries is most likely to be responsible for his presentation?

A	Right coronary artery
B	Left main stem
C	Left anterior descending and circumflex arteries
D	Posterior descending artery
E	Left circumflex artery

10:37
594-042-7551
Leave

rhythm following the third electrical shock with a maintained BP of 110/70 mmHg. He is a smoker who has significant peripheral vascular disease and stable angina and has undergone a femoral-popliteal bypass graft on the previous day.

A post-arrest electrocardiogram (ECG) is available as shown:

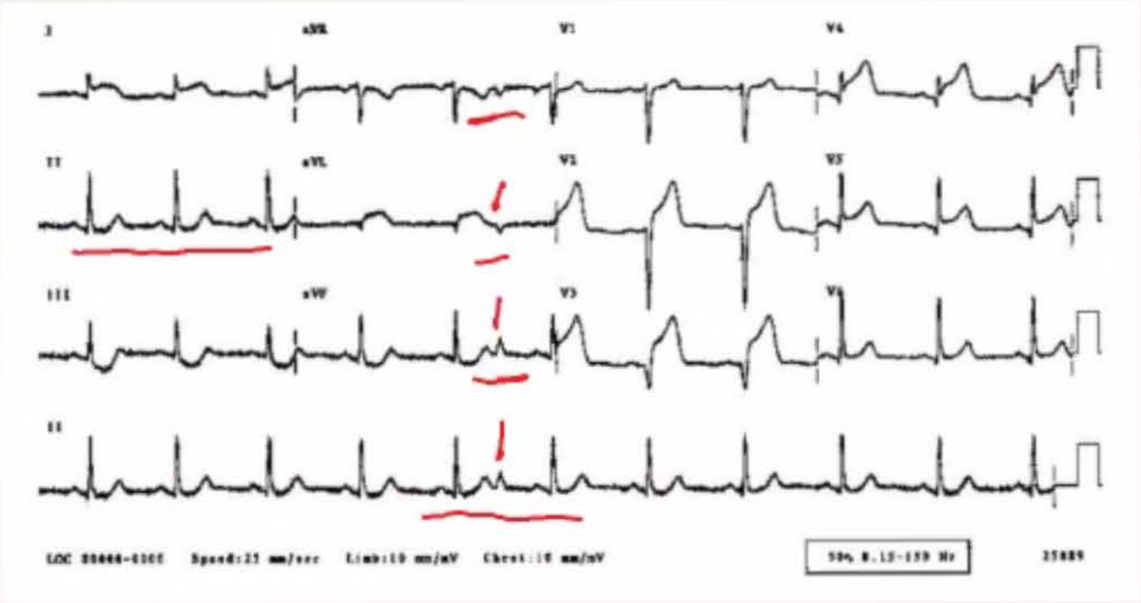

Occlusion of which of the following coronary arteries is most likely to be responsible for his presentation?

A Right coronary artery

B Left main stem

C Left anterior descending and circumflex arteries

D Posterior descending artery

E Left circumflex artery

Stop Annotation
Spotlight
Pen
Highlighter
Line
Rectangle
Oval
Undo
32359
Audio
Video
Share
Participants
More

10:38
594-042-7551
Leave

C Left anterior descending and circumflex arteries

The ECG shows anterolateral STEMI with reciprocal inferior changes. This is likely due to the occlusion of both LAD and circumflex artery.

This man had a cardiac arrest, and was found to be in ventricular fibrillation, following an anterolateral myocardial infarction. It is not uncommon for patients undergoing vascular surgery to have an acute coronary event, as a significant number will have co-existent coronary artery disease. Due to the recent surgery, thrombolysis is contraindicated and PCI is likely to be associated with a better outcome anyway, he should therefore progress as soon as possible to the angiography suite. The fact that he has angina, suggests the disease is distal to the left mainstem, and the ECG changes fit best with the distribution of the LAD and circumflex arteries. Patients with left main stem disease often get little warning of their impending infarct.

A Right coronary artery

Occlusion of the RCA typically causes inferior changes on the ECG. Although the ECG has inferior ST depression, it is likely to be reciprocal change of the anterolateral ST elevation in this case.

B Left main stem

LMS occlusion may present with sudden cardiac arrest, and this is often seen in the absence of other signs of cardiovascular disease. ECG findings include ST elevation in aVR with diffuse ST depression in other leads.

D Posterior descending artery

The posterior descending artery is a branch of the RCA (in

Audio Video Share Participants More

has angina, suggests the disease is distal to the left mainstem, and the ECG changes fit best with the distribution of the LAD and circumflex arteries. Patients with left main stem disease often get little warning of their impending infarct.

A Right coronary artery

Occlusion of the RCA typically causes inferior changes on the ECG. Although the ECG has inferior ST depression, it is likely to be reciprocal change of the anterolateral ST elevation in this case.

B Left main stem

LMS occlusion may present with sudden cardiac arrest, and this is often seen in the absence of other signs of cardiovascular disease. ECG findings include ST elevation in aVR with diffuse ST depression in other leads.

D Posterior descending artery

The posterior descending artery is a branch of the RCA (in a right dominant system). It supplies the posterior part of the heart and occlusion causes a posterior STEMI where performing an ECG with posteriorly placed leads will show ST elevation in V7-V9.

E Left circumflex artery

Occlusion of the left circumflex artery normally causes lateral ST changes +/- posterior changes (in left dominant system).

Rate this question:

Rana Alnasser's screen

10:43

594-042-7551

Leave

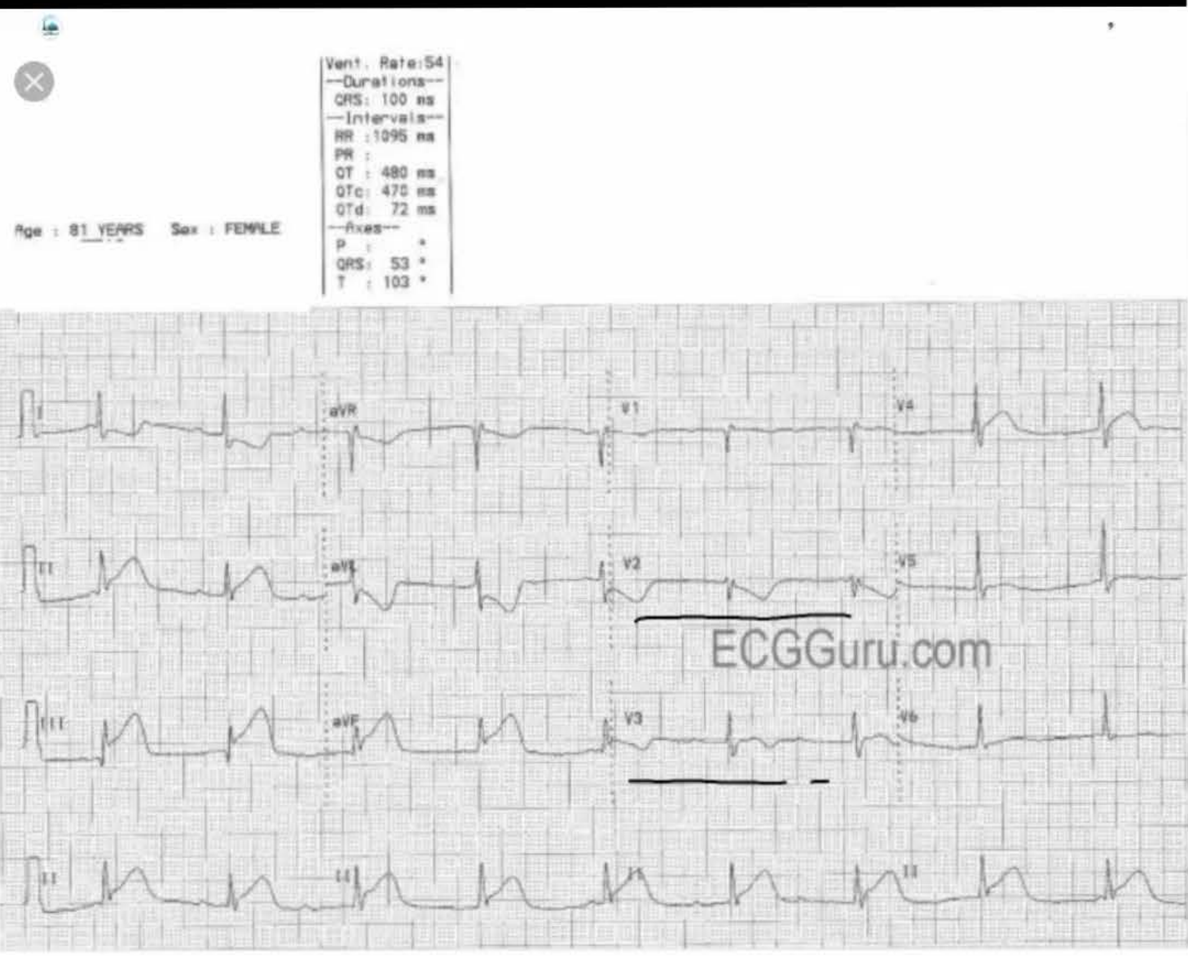

ECG Guru

Stop Annotation | Spotlight | Pen | Highlighter | Line | Rectangle | Oval | Undo | Redo | Clear | Color | Stop Share

Images may be subject to copyright. Learn more

RELATED IMAGES

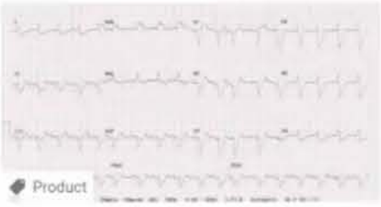

Product

LMCA Occlusion – ECG quest

ecgquest.net

Discover | Updates | Search | Recent | More

Audio | Video | Share | Participants | More

10:44

A 56-year-old male presents to the outpatient clinic for evaluation prior to his coronary angiography that is scheduled for the next day. The patient has had diabetes mellitus for 8 years and is currently taking metformin 500 mg three times per day and gliclazide 40 mg BD. He had suffered from recent onset of chest discomfort on exertion, and on a treadmill test was found to be positive for stress-induced ischaemia. He is currently taking clopidogrel 75 mg per day, atenolol 50 mg per day, indapamide 2.5 mg and fosinopril 10 mg per day. Physical examination reveals a pulse rate of 62 beats/min, blood pressure of 105/65 mmHg and jugular venous distension up to 2 cm above the sternomanubrial angle. The heart sounds are normal and chest is clear on auscultation. ECG reveals T-wave inversion in leads I and aVL.

Which of the following medications should be stopped for 24 h prior to his coronary angiography?

A Metformin

B Indapamide

C Clopidogrel

D Atenolol

E Gliclazide

Submit

Audio Video Share Participants More

A 56-year-old male presents to the outpatient clinic for evaluation prior to his coronary angiography that is scheduled for the next day. The patient has had diabetes mellitus for 8 years and is currently taking metformin 500 mg three times per day and gliclazide 40 mg BD. He had suffered from recent onset of chest discomfort on exertion, and on a treadmill test was found to be positive for stress-induced ischaemia. He is currently taking clopidogrel 75 mg per day, atenolol 50 mg per day, indapamide 2.5 mg and fosinopril 10 mg per day. Physical examination reveals a pulse rate of 62 beats/min, blood pressure of 105/65 mmHg and jugular venous distension up to 2 cm above the sternomanubrial angle. The heart sounds are normal and chest is clear on auscultation. ECG reveals T-wave inversion in leads I and aVL.

Which of the following medications should be stopped for 24 h prior to his coronary angiography?

Your answer was correct

A Metformin

B Indapamide

C Clopidogrel

D Atenolol

E Gliclazide

Explanation

A Metformin

A Metformin

About 5% of patients undergoing cardiac catheterisation experience contrast-induced renal dysfunction. Patients with diabetes and prior renal dysfunction are at increased risk. Renal impairment increases the risk of accumulation of metformin and lactic acidosis. Therefore, metformin should be stopped prior to coronary angiography and reinstated 48 h after the procedure if renal function is found to be normal. Although recent data on acute angioplasty have not supported any risk associated with metformin therapy and angioplasty, the guidelines recommending cessation of therapy for elective angioplasty persist.

B Indapamide

Although diuretics need not necessarily be discontinued, adequate hydration is essential before angiography.

C Clopidogrel

Aspirin and clopidogrel are important adjuncts to any percutaneous coronary intervention that might be done during coronary angiography.

D Atenolol

Myocardial oxygen demand may increase at the time of elective angiography, and atenolol can reduce the risk of peri-procedural ischaemia.

E Gliclazide

Although continuing the gliclazide may increase the risk of hypoglycaemia, as long as the patient is eating it need not be discontinued.

A 72-year-old man with temporal headaches, hip and shoulder girdle pain presents to the Emergency Department with sudden loss of vision in his right eye. He also reports pain in his jaw on eating. He has a past history of hypertension for which he takes ramipril 10 mg daily. On examination he appears to have no vision in his right eye and he has 6/12 vision in his left eye. There is tenderness to palpation over both temples.

Investigations:

Hb	11.5 g/dl
WCC	10.3 $\times 10^9$/l
PLT	321 $\times 10^9$/l
Na^+	139 mmol/l
K^+	4.9 mmol/l
Creatinine	100 µmol/l
ESR	79 mm/h
ECG	Slow AF, ventricular rate 65/min

Which of the following is the most likely cause of his loss of vision?

A Right carotid artery stenosis

B Right inflammatory optic neuritis

C Thromboembolic disease

D Vasculitis

E Mastoiditis

10:47
594-042-7551
Leave

Hb	11.5 g/dl
WCC	10.3 x10⁹/l
PLT	321 x10⁹/l
Na^+	139 mmol/l
K^+	4.9 mmol/l
Creatinine	100 µmol/l
ESR	79 mm/h
ECG	Slow AF, ventricular rate 65/min

Which of the following is the most likely cause of his loss of vision?

Your answer was correct

A Right carotid artery stenosis

B Right inflammatory optic neuritis

C Thromboembolic disease

D Vasculitis

E Mastoiditis

Explanation

D Vasculitis

This man has temporal arteritis, as evidenced by his clinical history, examination and raised ESR. Management of temporal arteritis involves the use of high-dose steroids

Audio Video Share Participants More

10:48

D Vasculitis

This man has temporal arteritis, as evidenced by his clinical history, examination and raised ESR. Management of temporal arteritis involves the use of high-dose steroids and, if successful, symptoms usually improve significantly within a few days of starting therapy. In patients who fail to respond to treatment, another diagnosis should be suspected. The jaw pain on eating seen here most likely represents claudication due to maxillary artery involvement.

A Right carotid artery stenosis

The symptoms fit more with temporal arteritis here, although ipsilateral visual field disturbance is seen, other symptoms such as contralateral weakness or sensory disturbance.

B Right inflammatory optic neuritis

Right inflammatory optic neuritis is more usually associated with ocular pain, with either a pale optic disc in patients with established disease or the potential for the optic disc to be oedematous in patients with acute disease.

C Thromboembolic disease

Given the marked temporal artery tenderness consistent with temporal arteritis, AF as a cause of the symptoms here is less likely to be responsible.

E Mastoiditis

Although mastoiditis may result in jaw tenderness on eating, it wouldn't result in the temporal artery tenderness or visual field loss seen here.

Audio Video Share Participants More

A 45-year-old woman presents with history of severe retrosternal chest pain of one day's duration. The pain radiates to the back and left shoulder and increases with inspiration, coughing and changes in body posture.

On examination, her blood pressure is 105/8 5 mmHg, heart rate 110/min, respiratory rate 22/min and temperature 38.1 °C. Heart sounds are normal and a friction rub is heard during expiration.

ECG reveals ST segment elevation in both limb and chest leads and ST segment depression in aVR. She has a WCC of 14,000/ml with left shift and erythrocyte sedimentation rate of 55 mm in the first hour. Chest X-ray is unremarkable. She responds well over the next few days to ibuprofen 800 mg four times per day and is discharged home.

She presents five months later with low-grade fever and chest pain. She describes similar symptoms three months after the initial episode that responded to ibuprofen which she self-administered. She is started on ibuprofen again and work-up for autoimmune screening is requested, which turns out to be negative. However, despite seven days' therapy with ibuprofen, she experiences bouts of chest pain.

What is the next step recommended in the management of this patient?

A	Pericardial biopsy
B	Prednisolone
C	Pericardectomy
D	Colchicine
E	Cyclosporin

10:53
594-042-7551
Leave

D Colchicine

Between 15 and 30% of patients with apparently idiopathic acute pericarditis may have recurrent attacks, and this is considered to be an autoimmune phenomenon. Colchicine is useful both in acute episode and to prevent recurrence of pericarditis.

A Pericardial biopsy

Pericardial biopsy in patients with recurrent pericarditis without effusion is unlikely to be revealing and is not needed.

B Prednisolone

Prednisolone can be considered in patients who fail to respond to non-steroidal anti-inflammatory drug and colchicine therapy. It is reserved for patients who fail to respond to initial intervention because of the adverse effects of steroid therapy including weight gain, loss of bone mineral density and dysglycaemia.

C Pericardectomy

Pericardectomy is only indicated for recurrent pericarditis once medical interventions have failed.

E Cyclosporin

Cyclosporine is used in the treatment of recurrent pericarditis post-transplant, but colchicine is preferred as a first-line agent in the non-transplant setting.

Audio Video Share Participants More
Rate this question

A 67-year-old Afro-Caribbean man with a history of hypertension comes to the clinic for review. He didn't tolerate a calcium channel blocker due to ankle swelling, so has been commenced on indapamide as the first intervention for his hypertension.

After three months of treatment, his BP is still elevated at 155/95 mmHg. His BMI is 33. His creatinine is 105 micromol/l.

Which of the following is the most appropriate next intervention?

A	Amlodipine
B	Valsartan
C	Bendroflumethiazide
D	Atenolol
E	Chlorthalidone

Submit

A 67-year-old Afro-Caribbean man with a history of hypertension comes to the clinic for review. He didn't tolerate a calcium channel blocker due to ankle swelling, so has been commenced on indapamide as the first intervention for his hypertension.

After three months of treatment, his BP is still elevated at 155/95 mmHg. His BMI is 33. His creatinine is 105 micromol/l.

Which of the following is the most appropriate next intervention?

Your answer was incorrect

A	Amlodipine
B	Valsartan
C	Bendroflumethiazide
D	Atenolol
E	Chlorthalidone

Explanation

B	Valsartan

Treatment of hypertension is indicated in patients under the age of 80 with stage 1 hypertension (>140/90) and one of the following: target organ damage, established cardiovascular disease, renal disease, diabetes or a 10-year cardiovascular risk equivalent to 20% of greater

Valsartan

Treatment of hypertension is indicated in patients under the age of 80 with stage 1 hypertension (>140/90) and one of the following: target organ damage, established cardiovascular disease, renal disease, diabetes or a 10-year cardiovascular risk equivalent to 20% of greater.

The choice of initial drug treatment is different in the under-55s and the over-55s or black people of African or Caribbean origin. An angiotensin-converting enzyme (ACE) inhibitor or angiotensin II receptor blocker (ARB) is first-line treatment in the first group, whereas a calcium-channel blocker is recommended in the latter. For the next step of treatment, angiotensin receptor blockers are preferred to ACE inhibitors in patients of Afro-Caribbean origin – for this reason valsartan is the preferred option in this case.

A Amlodipine

Amlodipine is contraindicated as the patient previously developed ankle swelling on a calcium antagonist.

C Bendroflumethiazide

Thiazide diuretics such as bendroflumethiazide are included in step three of the guidelines for management of hypertension, and should be added on top of an ACE inhibitor or ARB and calcium-channel blocker.

D Atenolol

Atenolol, is not recommended as a first- or second-line anti-hypertensive agent, particularly in the obese population because of its association with impaired glucose tolerance.

A 48-year-old man is admitted to the Coronary Care Unit post-PCI, having had acute onset retrosternal chest pain some two hours earlier. He is initially stable, with a pulse of 67 sinus rhythm and BP of 125/70 mmHg. Six hours after arrival, the nurse in charge calls you because his ECG monitor shows frequent premature ventricular contractions (PVCs). The patient is comfortably lying in the bed, and is asymptomatic: blood pressure (BP) 105/65 mmHg, pulse 69 beats/min, jugular venous pulse (JVP) is 2 cm above the sternal notch and the chest is clear to auscultation. As you examine him, you notice frequent PVCs and a run of ventricular tachycardia (VT) lasting 5 s. The nurse tells you that he had a similar run of VT few minutes ago.

Which of the following steps is most appropriate at this stage?

A IV lignocaine

B IV Amiodarone

C IV Procainamide

D Observation

E Check potassium and magnesium levels

Submit

A 48-year-old man is admitted to the Coronary Care Unit post-PCI, having had acute onset retrosternal chest pain some two hours earlier. He is initially stable, with a pulse of 67 sinus rhythm and BP of 125/70 mmHg. Six hours after arrival, the nurse in charge calls you because his ECG monitor shows frequent premature ventricular contractions (PVCs). The patient is comfortably lying in the bed, and is asymptomatic: blood pressure (BP) 105/65 mmHg, pulse 69 beats/min, jugular venous pulse (JVP) is 2 cm above the sternal notch and the chest is clear to auscultation. As you examine him, you notice frequent PVCs and a run of ventricular tachycardia (VT) lasting 5 s. The nurse tells you that he had a similar run of VT few minutes ago.

Which of the following steps is most appropriate at this stage?

Your answer was incorrect

A	IV lignocaine
B	IV Amiodarone
C	IV Procainamide
D	Observation
E	Check potassium and magnesium levels

Explanation

E	Check potassium and magnesium levels

Premature ventricular contractions (PVCs) and non-

E Check potassium and magnesium levels

Premature ventricular contractions (PVCs) and non-sustained ventricular tachycardia (NSVT) are common in the early post-myocardial infarction (MI) period. NSVT is defined as three or more consecutive beats at a rate >100 beats/min that last less than 30 s. If these do not cause any haemodynamic compromise, treatment is not needed.

Hypokalaemia increases the incidence of NSVT as well as VT and ventricular fibrillation (VF), and hence it is prudent to check serum potassium (K^+) levels early. During the GISSI-2 trial it was observed that a serum K^+ level of <3.6 mmol/l was associated with a twofold increased risk of VF. Therefore serum K^+ should be maintained >4 mmol/l by oral or intravenous (IV) supplementation in patients with acute MI.

Concomitant magnesium (Mg^{2+}) deficiency is present in many patients with hypokalaemia and also makes correction of hypokalaemia difficult. Hence serum Mg^{2+} levels should also be checked and maintained >1 mmol/l.

D Observation

Hypokalaemia and hypomagnesaemia are both associated with significant risk of VF, and hence leaving levels unchecked is not an option.

A IV lignocaine

Anti-arrhythmic therapy might be considered if NSVT causes haemodynamic compromise or becomes sustained VT. Lignocaine can be significantly negatively inotropic, and hence it isn't a first-choice option here.

B IV Amiodarone

Therefore serum K^+ should be maintained >4 mmol/l by oral or intravenous (IV) supplementation in patients with acute MI.

Concomitant magnesium (Mg^{2+}) deficiency is present in many patients with hypokalaemia and also makes correction of hypokalaemia difficult. Hence serum Mg^{2+} levels should also be checked and maintained >1 mmol/l.

D Observation

Hypokalaemia and hypomagnesaemia are both associated with significant risk of VF, and hence leaving levels unchecked is not an option.

A IV lignocaine

Anti-arrhythmic therapy might be considered if NSVT causes haemodynamic compromise or becomes sustained VT. Lignocaine can be significantly negatively inotropic, and hence it isn't a first-choice option here.

B IV Amiodarone

IV amiodarone is a first-choice antiarrhythmic, although the first step in this case is to check potassium and magnesium levels and correct them as needed.

C IV Procainamide

It was thought that there was little practical difference between amiodarone and procainamide for the treatment of VT, although recent RCT evidence supports a superior efficacy profile for procainamide in the event that an anti-arrhythmic is required.

A 63-year-old woman with congestive cardiac failure comes to the clinic for review. She has had two previous myocardial infarctions. Regular medications include ramipril 10 mg, furosemide 80 mg, bisoprolol 10 mg, digoxin 125 bmcg and spironolactone 25 mg. On examination, BP is 142/82 mmHg, pulse is 80/min regular and she has bibasal crackles consistent with left ventricular failure and bilateral pitting oedema of the ankles.

Investigations:

Hb	11.9 g/dl
WCC	5.4×10^9/l
PLT	210×10^9/l
Na^+	140 mmol/l
K^+	4.9 mmol/l
Creatinine	135 µmol/l

Which of the following is the most appropriate management for her?

A Reduce bisoprolol

B Increase spironolactone

C Increase furosemide

D Increase digoxin

E Increase bisoprolol

C Increase furosemide

This patient is relatively hypertensive, with evidence of decompensated heart failure and fluid overload. The most appropriate initial management is to increase in her diuretic therapy and relieve the symptoms of fluid overload - pulmonary and peripheral oedema.

A Reduce bisoprolol

This is unlikely to be of any benefit as her symptoms are not related to beta-blockade. Bisoprolol is used as an adjunct in heart failure, with doses starting at 1.25 mg per day, titrated up to 10 mg per day over several weeks.

B Increase spironolactone

Spironolactone is associated with an increased risk of hyperkalaemia. While spironolactone in combination with an ACE inhibitor or ARB has been shown to improve mortality in heart failure, this effect is not dose dependent - studies suggest that increasing the dose of spironolactone above the minimum does not improve outcome.

D Increase digoxin

This may be considered over the longer term, but there is no indication to do so in this situation. It would not change her current symptoms, which are related to fluid overload. Digoxin improves symptoms although it has no impact on mortality in heart failure. The recommended dose for this indication is 125-250 micrograms per day.

E Increase bisoprolol

- studies suggest that increasing the dose of spironolactone above the minimum does not improve outcome.

D	Increase digoxin

This may be considered over the longer term, but there is no indication to do so in this situation. It would not change her current symptoms, which are related to fluid overload. Digoxin improves symptoms although it has no impact on mortality in heart failure. The recommended dose for this indication is 125-250 micrograms per day.

E	Increase bisoprolol

This is not advised as the patient is already on the maximum dose recommended in heart failure.

It is worth noting the elevated creatinine. Many of the drugs used in heart failure cause kidney disease or need dose adjustment in the presence thereof. If making any alterations to this lady's medications, renal function should be monitored regularly.

Rate this question:

© Pastest 2019

Rana Alnasser's screen

An 18-year-old woman presents to the Emergency Department for review. She has been unwell for the past few days with fevers, lethargy and joint pains, and has an erythematous rash over her trunk which started on her back. A severe episode of tonsillitis/pharyngitis began a short period before these new symptoms.

On examination, she has a BP of 115/82 mmHg, with pulse 85/min and regular. There is a mitral murmur but otherwise auscultation of the chest is normal. You note joint pains predominantly affecting her knees and elbows, subcutaneous nodules over each elbow and an erythematous rash over the trunk.

Investigations:

Hb	13.0 g/dl
WCC	10.4×10^9/l
PLT	181×10^9/l
Na^+	137 mmol/l
K^+	4.3 mmol/l
Creatinine	101 µmol/l
ESR	75 mm/1st hour
CRP	132 mg/l
Urine	Blood+, protein+
Throat swab	Streptococcus Group A

Which of the following is the most important intervention?

A Antibiotic therapy

B Aspirin

Rana Alnasser's screen

auscultation of the chest is normal. You note joint pains predominantly affecting her knees and elbows, subcutaneous nodules over each elbow and an erythematous rash over the trunk.

Investigations:

Hb	13.0 g/dl
WCC	10.4×10^9/l
PLT	181×10^9/l
Na^+	137 mmol/l
K^+	4.3 mmol/l
Creatinine	101 µmol/l
ESR	75 mm/1st hour
CRP	132 mg/l
Urine	Blood+, protein+
Throat swab	Streptococcus Group A

Which of the following is the most important intervention?

A Antibiotic therapy

B Aspirin

C Ibuprofen

D Prednisolone

E Bed rest

WCC	10.4×10^9/l
PLT	181×10^9/l
Na^+	137 mmol/l
K^+	4.3 mmol/l
Creatinine	101 µmol/l
ESR	75 mm/1st hour
CRP	132 mg/l
Urine	Blood+, protein+
Throat swab	Streptococcus Group A

Which of the following is the most important intervention?

Your answer was correct

A Antibiotic therapy

B Aspirin

C Ibuprofen

D Prednisolone

E Bed rest

Explanation

A Antibiotic therapy

This patient presents with a likely diagnosis of rheumatic

A Antibiotic therapy

This patient presents with a likely diagnosis of rheumatic fever. The major and minor manifestations of this condition are presented in the table below. Rheumatic fever is an inflammatory disease that develops following a streptococcal throat infection. Diagnosis is based on evidence of a streptococcal throat infection with two major or one major and two minor criteria. Streptococcal throat infections should be treated with penicillin, in part to avoid the risk of rheumatic fever and the late manifestation of rheumatic heart disease.

Major criteria	Minor criteria
Migrating polyarthritis	Fever
Carditis	Raised ESR or CRP
Erythema marginatum	Arthralgia
Sydenham's chorea	ECG showing heart block
Subcutaneous nodules	Previous rheumatic fever

B Aspirin

Aspirin is considered to be an effective agent for the treatment of inflammation in the case of rheumatic fever. There is limited evidence to support the use of aspirin or corticosteroids over one another. However, although useful for treating inflammation, antibiotics are the key treatment in this condition.

C Ibuprofen

NSAIDS can form a part of the treatment bundle for rheumatic fever, but aspirin would be preferred over ibuprofen. The management of the inflammatory elements

C Ibuprofen

NSAIDS can form a part of the treatment bundle for rheumatic fever, but aspirin would be preferred over ibuprofen. The management of the inflammatory elements for rheumatic fever are secondary to effective antibiotic therapy.

D Prednisolone

Steroids and NSAIDs have limited evidence to suggest one over the other in the treatment of the inflammatory component of rheumatic fever, and either can be considered. Steroids are preferred in cases with cardiac involvement. Although an important element of the treatment of this patient, it is secondary to the use of antibiotics.

E Bed rest

Rheumatic fever must be treated to reduce the incidence of long-term sequelae. Bed rest alone is not an appropriate treatment option.

Rate this question:

Next Question

Previous Q... Tag Questi... Feedback End Session

Blog About Pastest Contact Us Help

© Pastest 2019

A 45-year-old rugby player is admitted to the Emergency Department with palpitations. He is on tour with his team. They had spent the evening celebrating victory in a local bar and he has consumed 8–10 pints of strong lager. He awoke at 3 am with fast, irregular palpitations, and immediately called for an ambulance. He has no past medical history of note, takes no medications and runs 20–25 km per week. He is not fasted. On examination, his BP is 110/70 mmHg with pulse 125/min and irregular. There are no murmurs and no signs of cardiac failure.

Investigations:

Hb	13.9 g/dl
WCC	8.0 $\times 10^9$/l
PLT	203 $\times 10^9$/l
Na^+	138 mmol/l
K^+	3.9 mmol/l
Creatinine	103 micromol/l
ECG	Fast atrial fibrillation, ventricular rate 122/min
CXR	Normal heart size, no signs of cardiac failure
Echocardiogram	Structurally normal heart

He is given low-molecular weight heparin

Which of the following is the most appropriate next step?

A IV flecainide

B Oral amiodarone

C IV amiodarone

Investigations:

Hb	13.9 g/dl
WCC	8.0 x10^9/l
PLT	203 x10^9/l
Na^+	138 mmol/l
K^+	3.9 mmol/l
Creatinine	103 micromol/l
ECG	Fast atrial fibrillation, ventricular rate 122/min
CXR	Normal heart size, no signs of cardiac failure
Echocardiogram	Structurally normal heart

He is given low-molecular weight heparin

Which of the following is the most appropriate next step?

A IV flecainide

B Oral amiodarone

C IV amiodarone

D Oral diltiazem

E Oral bisoprolol

34968

Submit

Investigations:

Hb	13.9 g/dl
WCC	8.0 x10⁹/l
PLT	203 x10⁹/l
Na^+	138 mmol/l
K^+	3.9 mmol/l
Creatinine	103 micromol/l
ECG	Fast atrial fibrillation, ventricular rate 122/min
CXR	Normal heart size, no signs of cardiac failure
Echocardiogram	Structurally normal heart

He is given low-molecular weight heparin

Which of the following is the most appropriate next step?

Your answer was correct

A IV flecainide

B Oral amiodarone

C IV amiodarone

D Oral diltiazem

E Oral bisoprolol

Explanation

A IV flecainide

This man has no evidence of structural heart disease, and this episode of paroxysmal AF is likely to be related to alcohol excess. As such, chemical cardioversion with IV flecainide is appropriate.

For patients with acute onset (<48 h) atrial fibrillation (AF) without haemodynamic instability, rate or rhythm control can be considered. The options for pharmacological cardioversion are flecainide or amiodarone for people with no evidence of structural heart disease, or amiodarone in the presence of structural heart disease.

B Oral amiodarone

This does cardiovert paroxysmal AF, although it is less effective compared to flecainide in the acute situation.

C IV amiodarone

IV amiodarone, would therefore be appropriate had he not had a structurally normal heart on the echocardiogram.

D Oral diltiazem

Diltiazem is a calcium channel blocker. No drugs of this class should be used to attempt pharmacological cardioversion, though they can be used as monotherapy for rate control.

E Oral bisoprolol

Oral bisoprolol is a reasonable choice for prophylaxis if further episodes of paroxysmal AF (PAF) occur.

Rate this question:

A 50-year-old male presents to the emergency department with central crushing chest pain, which was subsequently confirmed as a myocardial infarction. He developed atrial fibrillation 2 days post-myocardial infarction (MI) and was digitalised, although he was not fully anticoagulated at this point. Six days post-MI he banged into a bed and the wall while walking to the toilet, and appeared blind although he denied this, attempting to describe objects around his bed space. Pupillary reflexes were normal.

Which of the following best describes the lesion that has occurred?

A	Bilateral occipital lobe infarcts
B	Bilateral retinal artery thrombosis
C	Bilateral retinal vein thrombosis
D	Retinal detachment
E	Branch retinal vein occlusion

Submit

© Pastest 2019

A 50-year-old male presents to the emergency department with central crushing chest pain, which was subsequently confirmed as a myocardial infarction. He developed atrial fibrillation 2 days post-myocardial infarction (MI) and was digitalised, although he was not fully anticoagulated at this point. Six days post-MI he banged into a bed and the wall while walking to the toilet, and appeared blind although he denied this, attempting to describe objects around his bed space. Pupillary reflexes were normal.

Which of the following best describes the lesion that has occurred?

Your answer was correct

A	Bilateral occipital lobe infarcts
B	Bilateral retinal artery thrombosis
C	Bilateral retinal vein thrombosis
D	Retinal detachment
E	Branch retinal vein occlusion

Explanation

A	Bilateral occipital lobe infarcts

This patient has cortical blindness, lacking insight into the fact that he is unable to see. Denial of visual loss has been described previously as the Anton-Babinski syndrome, and indeed visual hallucinations are often also reported. The cause in this case is likely to be extensive occipital lobe infarcts as a result of emboli from his atrial fibrillation.

Explanation

A Bilateral occipital lobe infarcts

This patient has cortical blindness, lacking insight into the fact that he is unable to see. Denial of visual loss has been described previously as the Anton-Babinski syndrome, and indeed visual hallucinations are often also reported. The cause in this case is likely to be extensive occipital lobe infarcts as a result of emboli from his atrial fibrillation. Neuroimaging should be urgently performed to confirm the diagnosis. The pupillary response in this case is preserved. Unfortunately, the window for immediate treatment with thrombolysis is lost, and full heparinisation at this point increases the risk of haemorrhagic conversion.

Although he is at high risk of falls given his blindness, anticoagulation with NOACs or warfarin should still be considered to prevent further embolic events as his risk is high (CHADS2Vasc = 3 without knowing if he has CCF, hypertension or diabetes). NICE guidelines has recommended that anticoagulation should not be withheld for risk of falls.

B Bilateral retinal artery thrombosis

AF can cause arterial thrombosis if not anticoagulated. However, as the patient was unaware that he is blind, this is in keeping with cortical blindness. In retinal artery thrombosis, the patient would be aware that he is blind. It normally affects only one eye and is described as sudden and painless. 'Cherry red spot' with pale retina will be seen on fundoscopy.

C Bilateral retinal vein thrombosis

In the presence of AF, arterial thrombosis is much more likely than venous thrombosis. Vein thrombosis typically

C Bilateral retinal vein thrombosis

In the presence of AF, arterial thrombosis is much more likely than venous thrombosis. Vein thrombosis typically causes gradual visual blurring and loss. On fundoscopy, you will see retinal haemorrhages and oedema with dilated veins.

D Retinal detachment

With no risk factor for retinal detachment described and bilateral involvement, it is very unlikely to be retinal detachment. Retinal detachment normally presents with acute symptoms of flashes of light and floaters. Typical risk factors include glaucoma and diabetic retinopathy.

E Branch retinal vein occlusion

In the presence of AF, arterial thrombosis is much more likely than venous thrombosis. Given that only a branch of the vein is affected, patients typically present with reduced peripheral vision or an enlarged blind spot.

© Pastest 2019

TECHNICAL DEXTROCARDIA

- R wave positive in lead avR
- Extreme axis eviation
- Reverse polarity in all normal deflection in lead I and avL
- **DIFFERENTIAL IS DEXTROCARDIA**
- In dextrocardia precordial R wave progression is reversed
- In technical dextrocardia it is normal.

An 82-year-old male is seen in the cardiology clinic with a history of dizzy spells on exertion. There is no history of associated chest pain or palpitations. He describes a couple of episodes when he felt as if he was going to pass out. He has a previous history of hypertension, for which he is treated by his general practitioner (GP) with bendrofluazide. On arrival his blood pressure is measured at 146/86 mmHg and his heart rate is 65 beats/min. Clinic examination reveals a soft systolic murmur over the aortic area, with no radiation. His resting electrocardiogram (ECG) shows sinus rhythm with a PR interval of 0.24 ms. Routine blood tests including thyroid function tests are normal. A 24 h tape is arranged.

Which of the following results would be an indication for permanent pacemaker?

A	PR interval 260 ms
B	Paroxysmal AF with pauses of 2 s
C	Episodes of asymptomatic Wenckebach rhythm
D	Episodes of sinus pauses lasting 2.5 s
E	Episodes of asymptomatic type 2 second-degree block

Submit

E Episodes of asymptomatic type 2 second-degree block

Indications for permanent pacemaker implantation includ third-degree block, symptomatic Wenckebach phenomenon, asymptomatic type II second-degree block and pauses of >3.0 s. Asymptomatic Mobitz type II secon degree block is an indication because it is likely to progre to complete heart block and/or lead to episodes of syncope. Operative complications include lead displacement, haematomas, infection and, rarely, erosion the pacemaker box through the skin. Occasionally patient may present with failure of the impulse to capture and symptomatic bradycardia. Often reprogramming alone m be adequate to prevent further problems.

A PR interval 260 ms

In the absence of haemodynamic compromise, 1st-degree heart block does not require specific intervention.

B Paroxysmal AF with pauses of 2 s

Pauses lasting 3 s or longer represent an indication for pacing.

C Episodes of asymptomatic Wenckebach rhythm

Symptomatic Wenckeback would be an indication for pacemaker insertion.

D Episodes of sinus pauses lasting 2.5 s

Pauses lasting 3 s or longer represent an indication for pacing.

1:18

A 69-year-old man is admitted to the Emergency Department with sudden onset of palpitations. The palpitations started 3 h ago, and are associated with shortness of breath, light-headedness and chest discomfort. He has had two similar episodes of palpitations in the last 2 months that have lasted only a few seconds. He had never sought any medical advice on these previous palpitations. His past medical history is unremarkable and he is not on any medication.
On examination, he is dyspnoeic with a blood pressure of 112/55 mmHg, pulse rate of >>120/min regular and a respiratory rate of 28/min. His oxygen saturation on air is 90%, and his chest is clinically clear. His jugular venous pressure is not raised. First and second heart sounds are heard but you cannot appreciate whether there is any murmur.

An electrocardiogram (ECG) shows a heart rate of 188/mim with a narrow QRS complex; chest X-ray is normal.

The patient is placed on a monitor and given rapid IV 6 mg of adenosine, but the heart rate only slows down to 176/min. The patient is then given 12 mg of adenosine and the heart rate slows to 110/min to reveal the underlying atrial fibrillation. He is also given oxygen and low-molecular weight heparin.

ECG shows a heart rate of 110/min and atrial fibrillation.

Which of the following interventions would you immediately start for this patient?

A	DC cardioversion
B	Loading dose of IV 0.75–1 mg digoxin in 50 ml saline over 1–2 h
C	Glycoprotein IIb/IIIa inhibitor

Rana Alnasser's screen

respiratory rate of 28/min. His oxygen saturation on air is 90%, and his chest is clinically clear. His jugular venous pressure is not raised. First and second heart sounds are heard but you cannot appreciate whether there is any murmur.

An electrocardiogram (ECG) shows a heart rate of 188/mim with a narrow QRS complex; chest X-ray is normal.

The patient is placed on a monitor and given rapid IV 6 mg of adenosine, but the heart rate only slows down to 176/min. The patient is then given 12 mg of adenosine and the heart rate slows to 110/min to reveal the underlying atrial fibrillation. He is also given oxygen and low-molecular weight heparin.

ECG shows a heart rate of 110/min and atrial fibrillation.

Which of the following interventions would you immediately start for this patient?

A	DC cardioversion
B	Loading dose of IV 0.75–1 mg digoxin in 50 ml saline over 1–2 h
C	Glycoprotein IIb/IIIa inhibitor
D	IV amiodarone
E	Angiotensin-converting enzyme (ACE) inhibitor

Submit

Explanation

D IV amiodarone

This patient has atrial fibrillation, which given the history is probably of relatively acute onset. The immediate need would be to try and manage chemical cardioversion, in which case IV amiodarone is an obvious choice. Digoxin would not encourage reversion to sinus rhythm so would not be the first choice here. The likely outcome is the patient reverting back to sinus rhythm within hours. If the patient does not revert back to sinus rhythm, formal anticoagulation would need to be instituted. He would also need to be investigated for the cause of the atrial fibrillation. Electrical cardioversion may be an option acutely if he becomes significantly compromised with respect to his BP, or considered at a later date as an elective procedure post oral anticoagulation.

A DC cardioversion

This patient has a well-maintained blood pressure; chemical cardioversion is therefore the preferred option.

B Loading dose of IV 0.75–1 mg digoxin in 50 ml saline over 1–2 h

In this situation with a relatively short duration of AF, it is reasonable to try and attain sinus rhythm with amiodarone.

C Glycoprotein IIb/IIIa inhibitor

Platelet inhibition isn't the most important next step, control of the patient's atrial fibrillation is. In the event there is a strong suspicion of ACS, then the first-line interventions are high-dose aspirin, clopidogrel and fondaparinux.

A 65-year-old lady comes to the cardiology clinic for follow up of her chest pain. She attended clinic 6 weeks ago and an exercise test was requested, (against current NICE guidelines). The following is the summary of her exercise test: 'she started having chest pains in the second stage of the Bruce protocol. There was ST depression of 2.5 mm in V1 to V4. This is a positive exercise test'.

What is the next step in the management of this lady?

A	Bypass surgery
B	Angiogram +/- angioplasty
C	Technetium scan
D	Dobutamine stress echocardiography
E	Cardiac MRI

9490

Submit

Previous Q... Skip Questi...

© Pastest 2019

1:25

MyPastest
https://mypastest.pastest.com

A 65-year-old lady comes to the cardiology clinic for follow up of her chest pain. She attended clinic 6 weeks ago and an exercise test was requested, (against current NICE guidelines). The following is the summary of her exercise test: 'she started having chest pains in the second stage of the Bruce protocol. There was ST depression of 2.5 mm in V1 to V4. This is a positive exercise test'.

What is the next step in the management of this lady?

Your answer was correct

A	Bypass surgery
B	Angiogram +/- angioplasty
C	Technetium scan
D	Dobutamine stress echocardiography
E	Cardiac MRI

Explanation

B	Angiogram +/- angioplasty

This lady has early onset of angina and ischaemic ECG changes that are associated with an adverse prognosis and more severe coronary artery disease in the context of an ETT. ETTs are not recommended by NICE because of the

B Angiogram +/- angioplasty

This lady has early onset of angina and ischaemic ECG changes that are associated with an adverse prognosis and more severe coronary artery disease in the context of an ETT. ETTs are not recommended by NICE because of the possibility of missing a diagnosis of significant coronary artery stenosis, and inherent risks of the test in patients with severe disease, although the positive test this time prompts an angiogram to determine the extent of her coronary atherosclerosis.

A Bypass surgery

Bypass surgery may be required, although further evaluation with angiography is required first.

C Technetium scan

Technetium scanning is of value in detecting an area of myocardial ischaemia, although an angiogram would still be required to determine the most appropriate intervention with respect to treatment.

D Dobutamine stress echocardiography

Dobutamine stress echocardiography is useful to identify abnormal ventricular wall motion, but again would not identify the best mode of intervention.

E Cardiac MRI

Cardiac MRI may be useful where there is a delay or the patient cannot undergo invasive angiography, although the advantage of the invasive procedure is that progression to stenting can be an option.

A 48-year-old male presents with general malaise and ankle swelling. On close questioning he describes a decrease in his exercise tolerance over the last few months because of increasing breathlessness. He also describes a cough that is productive of clear sputum. There is no history of chest pains. He has no past medical history of note. He works as a financial consultant in a city firm. He smokes 10 cigarettes a day and drinks 40 units of alcohol per week.

On examination he is comfortable at rest, with a blood pressure of 155/98 mmHg and a heart rate of 90 beats/min regular. His jugular venous pressure (JVP) is raised and there is bipedal oedema. There is a pan-systolic murmur on auscultation of his heart and bi-basal crackles on auscultation of his chest.
His chest X-ray shows an enlarged heart with evidence of fluid overload.

His electrocardiogram (ECG) shows borderline left bundle branch block.

Investigations:

Hb	16.1 g/dl
WCC	6.6×10^9/l
PLT	273×10^9/l
Na^+	137 mmol/l
K^+	4.8 mmol/l
Creatinine	89 µmol/l
MCV	98 fl
Urea	6.0 mmol/l
TSH	3 mU/l
Albumin	36 g/l

Rana Alnasser's screen

PLT	273×10^9/l
Na^+	137 mmol/l
K^+	4.8 mmol/l
Creatinine	89 µmol/l
MCV	98 fl
Urea	6.0 mmol/l
TSH	3 mU/l
Albumin	36 g/l
ALT	30 IU/l
AST	65 IU/l
GGT	100 IU/l

An echocardiogram shows a dilated left ventricle, with moderate global impairment of function and an ejection fraction of 40%. There is mild to moderate mitral regurgitation which is deemed to be functional.

Which of the following would be of most value impacting on his long term prognosis?

A Viral serology

B Beta-blocker therapy

C Angiotensin converting enzyme inhibitor therapy

D Alcohol cessation

E Diuretic therapy

TSH	3 mU/l
Albumin	36 g/l
ALT	30 IU/l
AST	65 IU/l
GGT	100 IU/l

An echocardiogram shows a dilated left ventricle, with moderate global impairment of function and an ejection fraction of 40%. There is mild to moderate mitral regurgitation which is deemed to be functional.

Which of the following would be of most value impacting on his long term prognosis?

Your answer was correct

A Viral serology

B Beta-blocker therapy

C Angiotensin converting enzyme inhibitor therapy

D Alcohol cessation

E Diuretic therapy

Explanation

D Alcohol cessation

This patient has symptoms and signs of heart failure and the most likely cause in this case is one of dilated cardiomyopathy secondary to alcohol abuse. Abstinence

Explanation

D Alcohol cessation

This patient has symptoms and signs of heart failure and the most likely cause in this case is one of dilated cardiomyopathy secondary to alcohol abuse. Abstinence from alcohol is paramount in arresting the progress of the condition, and if he doesn't stop drinking, despite receiving medication for heart failure, he will continue to experience significant symptoms.

A Viral serology

This patient has symptoms and signs of heart failure and the most likely cause in this case is dilated cardiomyopathy secondary to alcohol abuse. Viral serology has a very low diagnostic yield and would not affect the advice to discontinue with alcohol consumption.

B Beta-blocker therapy

This patient has symptoms and signs of heart failure and the most likely cause in this case is dilated cardiomyopathy secondary to alcohol abuse. Beta-blockers reduce mortality and morbidity in symptomatic heart failure and should be started alongside an angiotensin-converting enzyme (ACE) inhibitor. However, given the aetiology, if he doesn't stop drinking he will continue to experience significant symptoms, and therefore this is not the most appropriate answer.

C Angiotensin converting enzyme inhibitor therapy

This patient has symptoms and signs of heart failure. The most likely cause in this case is one of dilated cardiomyopathy secondary to alcohol abuse. Angiotensin-converting enzyme (ACE) inhibitors reduce mortality and morbidity in heart failure and are therefore recommended

C Angiotensin converting enzyme inhibitor therapy

This patient has symptoms and signs of heart failure. The most likely cause in this case is one of dilated cardiomyopathy secondary to alcohol abuse. Angiotensin-converting enzyme (ACE) inhibitors reduce mortality and morbidity in heart failure and are therefore recommended in patients, unless contraindicated or not tolerated. However, given the aetiology, if he doesn't stop drinking he will continue to experience significant symptoms, and therefore this is not the most appropriate answer.

E Diuretic therapy

This patient has symptoms and signs of heart failure and the most likely cause in this case is one of dilated cardiomyopathy secondary to alcohol abuse. Diuretics are recommended to reduce the signs and symptoms of congestion, but their effect on mortality and morbidity have not been studied in RCTs. This is, therefore, not the most appropriate answer. If he doesn't stop drinking, despite receiving medication, he will continue to experience significant symptoms.

Rate this question:

Next Question

Previous Q... Tag Questi... Feedback End Session

Blog About Pastest Contact Us Help

© Pastest 2019

You are crash-called to a 67-year-old man who is recovering on the surgical ward after a cholecystectomy. He has a history of ischaemic heart disease and type 2 diabetes mellitus. On examination his BP is 70/50 mmHg, with pulse 240/min and regular. He is attached to the defibrillator, and it is showing what looks like ventricular tachycardia (VT).

Which of the following is the most important intervention?

A	IV amiodarone
B	IV lignocaine
C	DC cardioversion
D	IV adrenaline
E	IV magnesium

26025

Submit

Previous Q... Skip Questi...

© Pastest 2019

1:29
594-042-7551 Leave

C DC cardioversion

This man has unstable VT and is at imminent risk of developing pulseless VT or ventricular fibrillation (VF). Following the Resuscitation Council adult tachyarrhythmia guidelines (see 1st weblink below), the immediate treatment is DC cardioversion and therefore option C is correct. Anaesthetics should be involved so that sedation can be used.

A IV amiodarone

IV amiodarone, is used second line after DC cardioversion or for stable VT.

B IV lignocaine

IV lignocaine, can also be used for VT, but is not part of the guidelines and should be used only with specialist involvement – ITU or Cardiology.

D IV adrenaline

IV adrenaline, is part of the adult advanced life support (ALS) algorithm (see 2nd weblink below), but is not indicated in this situation where the patient has not yet descended to cardiac arrest.

E IV magnesium

IV magnesium, is used for broad-complex tachycardias including polymorphic VT (torsades de pointes), again with expert advice. It will also be worth considering why the patient has developed this arrhythmia and become so unwell. Given that the patient has undergone abdominal surgery, he may be potassium and magnesium depleted, but these can be replaced soon after the cardioversion. It

Audio Video Share Participants More

A 76-year-old woman with known rheumatoid arthritis presents with a 3-month history of breathlessness. There is no past medical history of ischaemic heart disease or hypertension and she denies any history of chest pains. She had been on celecoxib for her arthritis up until a year ago when she was switched to ibuprofen. She has also been on methotrexate for the last 15 years.

On examination, she is found to have a blood pressure of 100/70 mmHg, with a heart rate of 125 bpm and irregular. Her jugular venous pressure (JVP) is raised at 5 cm H_2O, and there is bipedal oedema to the mid calf. Her heart sounds are normal, and her chest is clear on auscultation.

An electrocardiogram (ECG) shows atrial fibrillation, with normal complexes. A chest X-ray reveals a small left-sided pleural effusion, but a normal-sized heart.

An echocardiogram shows left ventricular hypertrophy, with a speckled myocardium. There is bi-atrial enlargement, with no significant valvular pathology.

Which of the following medications is used with particular caution in this case?

A	Digoxin
B	Bisoprolol
C	Atenolol
D	Metoprolol
E	Carvedilol

A Digoxin

This patient has features consistent with restrictive cardiomyopathy. The history of rheumatoid arthritis and the echocardiographic finding of bi-atrial dilatation, ventricular hypertrophy and a speckled appearance to the myocardium make amyloidosis the most likely underlying cause. Digoxin is used with caution in amyloid patients, as digoxin binds irreversibly to amyloid fibrils.

B Bisoprolol

This beta-blocker is a good first-line choice for achieving ventricular rate control in atrial fibrillation.

C Atenolol

This beta-blocker is not contraindicated in amyloidosis and is an option for rate control in patients with good left ventricular function.

D Metoprolol

This is a short-acting beta-blocker that can be used for rate control in atrial fibrillation.

E Carvedilol

Again, this beta-blocker can be used to control the ventricular rate in atrial fibrillation but is more frequently used in heart failure.

6935

Rate this question:

1:32
594-042-7551
Leave

A 40-year-old woman presents to the Accident and Emergency Department with palpitations and light-headedness. The symptoms began suddenly 3 h ago while she was playing golf. She is otherwise well and has no significant past history. On examination she appears well, with a normal respiratory rate. Her blood pressure is 120/75 mmHg. She is afebrile. Her electrocardiogram (ECG) reveals a regular narrow complex tachycardia with a rate of 170/min. There are no flutter waves, but retrograde p-waves are visible in the inferior leads.

What is the most appropriate initial management?

A	DC cardioversion
B	Amiodarone
C	Adenosine
D	Vagal manoeuvres
E	Anticoagulation, (followed by DC cardioversion in 4 weeks)

7245

Submit

Audio
Video
Share
Participants
More

1:33
594-042-7551
Leave

Pastest

Vagal manoeuvres

most likely diagnosis is paroxysmal SVT, where vagal
oeuvres are the optimal first-line treatment where
od pressure is stable. These slow conduction in the AV
e, potentially interrupting any re-entrant circuit. The
ence of flutter waves excludes atrial flutter. Retrograde
aves in the inferior leads are typical of supraventricular
ycardia. Most of the patients who present with
oxysmal SVT have an AV nodal re-entrant arrhythmia.
se arrhythmias depend on AV nodal conduction and
efore can be terminated by transiently blocking AV
al conduction.

DC cardioversion

his situation, DC cardioversion is only really required for
ents resistant to vagal manoeuvres or adenosine, or
re there is significant haemodynamic compromise.

Amiodarone

odarone is the preferred intervention for atrial
llation where there is a past history of structural or
aemic heart disease.

Adenosine

nosine blocks AV nodal conduction and is the preferred
rvention in patients who fail to cardiovert with vagal
ulation, where there is no past history of asthma.

Anticoagulation, (followed by DC cardioversion in
4 weeks)

coagulation is preferred for patients with more
onged tachycardia due to AF where risk of embolism is

Audio Video Share Participants More

T	203 x109/l
+	138 mmol/l
	4.3 mmol/l
eatinine	103 micromol/l

ch of the following is the most appropriate way to age him?

- Aspirin, clopidogrel and fondaparinux and supportive care
- Urgent troponin
- GTN and bisoprolol
- Thrombolysis
- Primary PCI

37189

Submit

evious Q... Skip Questi...

Rana Alnasser's screen

1:34
594-042-7551
Leave

A 62-year-old man with no previous cardiac history presents to the Emergency Department with central chest pain of 30 min duration and associated diaphoresis. He smokes five cigars per day and has a BMI of 32. He has no past medical history of note and takes no regular medications.

On examination his BP is 100/60 mmHg, with pulse 85/min and regular. He has no clinical features of cardiac failure.

His ECG is shown below; one taken for an insurance medical 6 months earlier showed no QRS widening.

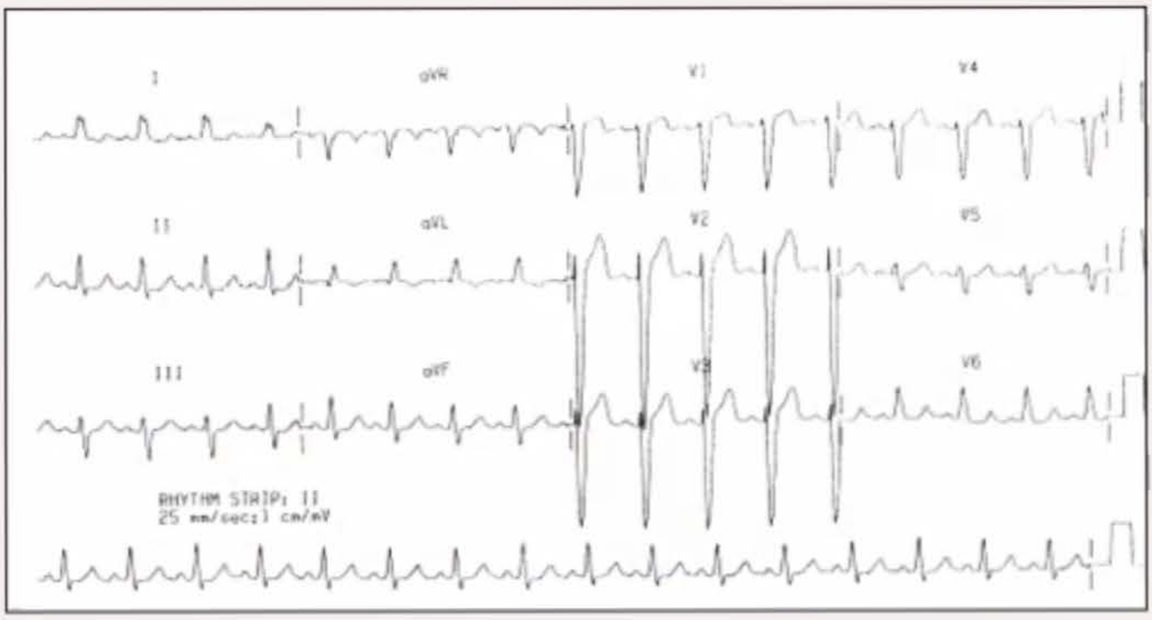

Investigations;

Hb	13.1 g/dl
WCC	7.8 x10⁹/l
PLT	203 x109/l
Na^+	138 mmol/l
K^+	4.3 mmol/l
Creatinine	103 micromol/l

Which of the following is the most appropriate way to manage him?

Audio
Video
Share
Participants
More

Investigations;

Hb	13.1 g/dl
WCC	7.8 x10⁹/l
PLT	203 x109/l
Na^+	138 mmol/l
K^+	4.3 mmol/l
Creatinine	103 micromol/l

Which of the following is the most appropriate way to manage him?

A	Aspirin, clopidogrel and fondaparinux and supportive care
B	Urgent troponin
C	GTN and bisoprolol
D	Thrombolysis
E	Primary PCI

E Primary PCI

The ECG is consistent with new-onset left bundle branch block. Together with the history of severe central chest pain, this should raise strong suspicion of an acute coronary syndrome. As such, the most appropriate next step is urgent PCI. Managing for unstable angina with medical therapy, or waiting for the 6 h troponin, risks further loss of myocardium.

Thrombolysis is proven to be inferior to angioplasty. It is therefore first line only if angioplasty is unavailable within recommended timescales, or unsuitable for any reason.

A Aspirin, clopidogrel and fondaparinux and supportive care

While aspirin, clopidogrel and fondaparinux are key components of ACS therapy, and will comprise ongoing treatment, the main priority here is revascularisation and primary PCI should be performed.

B Urgent troponin

Troponin is a useful test in the context of diagnostic uncertainty, but here the ECG and history are strongly suggestive of an ongoing acute coronary syndrome and primary PCI should be performed without delay.

C GTN and bisoprolol

While GTN should be offered for symptomatic relief and bisoprolol should be provided as part of post-ACS medical therapy, these do not represent the most appropriate immediate management of this patient, who should undergo primary PCI as a matter of priority.

medical therapy, or waiting for the 6 h troponin, risks further loss of myocardium.

Thrombolysis is proven to be inferior to angioplasty. It is therefore first line only if angioplasty is unavailable within recommended timescales, or unsuitable for any reason.

A Aspirin, clopidogrel and fondaparinux and supportive care

While aspirin, clopidogrel and fondaparinux are key components of ACS therapy, and will comprise ongoing treatment, the main priority here is revascularisation and primary PCI should be performed.

B Urgent troponin

Troponin is a useful test in the context of diagnostic uncertainty, but here the ECG and history are strongly suggestive of an ongoing acute coronary syndrome and primary PCI should be performed without delay.

C GTN and bisoprolol

While GTN should be offered for symptomatic relief and bisoprolol should be provided as part of post-ACS medical therapy, these do not represent the most appropriate immediate management of this patient, who should undergo primary PCI as a matter of priority.

D Thrombolysis

Current ESC guidelines on the management of STEMI recommend that PCI should be first line if it is available within 120 min of the diagnosis of STEMI. Otherwise, thrombolysis could be considered.

Rate this question:

1:41

A 38-year-old man presents to A+E with acutely worsening dyspnoea on the background of progressive shortness of breath over the past 2 weeks. His only past medical history of note includes recurrent shoulder dislocation.

On examination, he is 1.93 m in height and 51 kg in weight. On examination his blood pressure is 110/55 mmHg (equal in both arms), pulse 110/min, he is peripherally shut down and has pulmonary oedema. There are ejection systolic and short early diastolic murmurs heard best over the left 3rd interspace.

What diagnosis fits best with this clinical picture?

A	Acute aortic regurgitation
B	Acute mitral regurgitation
C	Aortic stenosis
D	Acute LV failure
E	Aortic dissection

Submit

Previous Q...

Rana Alnasser's screen

A 38-year-old man presents to A+E with acutely worsening dyspnoea on the background of progressive shortness of breath over the past 2 weeks. His only past medical history of note includes recurrent shoulder dislocation.

On examination, he is 1.93 m in height and 51 kg in weight. On examination his blood pressure is 110/55 mmHg (equal in both arms), pulse 110/min, he is peripherally shut down and has pulmonary oedema. There are ejection systolic and short early diastolic murmurs heard best over the left 3rd interspace.

What diagnosis fits best with this clinical picture?

Your answer was incorrect

A	Acute aortic regurgitation
B	Acute mitral regurgitation
C	Aortic stenosis
D	Acute LV failure
E	Aortic dissection

Explanation

A	Acute aortic regurgitation

The presentation here, with no previous past medical history of note, suggests acute aortic regurgitation, with his phenotype pointing to Marfan as the likely underlying cause. Definitive treatment is aortic valve replacement.

A Acute aortic regurgitation

The presentation here, with no previous past medical history of note, suggests acute aortic regurgitation, with his phenotype pointing to Marfan as the likely underlying cause. Definitive treatment is aortic valve replacement, with condition at presentation being the major determinant of mortality. Pre-surgery patients should be managed with opiates, if in significant pain or LVF, loop diuretic therapy and nitrates if blood pressure allows. Inotropic support with agents such as dobutamine may also be necessary.

B Acute mitral regurgitation

While Marfan syndrome can be associated with mitral regurgitation, this is associated with a pan-systolic murmur best heard at the apex with radiation to the axilla.

C Aortic stenosis

While Marfan syndrome is associated with increased incidence of aortic stenosis, aortic regurgitation is the most likely diagnosis in this case. Aortic stenosis is associated with angina, dyspnoea and syncope, and with a slow rising pulse, heaving apex beat and an ejection systolic murmur which radiates to the carotids.

D Acute LV failure

While valvular heart disease can lead to left ventricular failure, the timescale in this case, the examination findings and the phenotypical findings are in keeping with Marfan syndrome, make aortic regurgitation the likely underlying cause.

E Aortic dissection

with agents such as dobutamine may also be necessary.

B Acute mitral regurgitation

While Marfan syndrome can be associated with mitral regurgitation, this is associated with a pan-systolic murmur best heard at the apex with radiation to the axilla.

C Aortic stenosis

While Marfan syndrome is associated with increased incidence of aortic stenosis, aortic regurgitation is the most likely diagnosis in this case. Aortic stenosis is associated with angina, dyspnoea and syncope, and with a slow rising pulse, heaving apex beat and an ejection systolic murmur which radiates to the carotids.

D Acute LV failure

While valvular heart disease can lead to left ventricular failure, the timescale in this case, the examination findings and the phenotypical findings are in keeping with Marfan syndrome, make aortic regurgitation the likely underlying cause.

E Aortic dissection

This is associated with acute 'tearing' chest/back pain, which may radiate to the neck. There may be symptoms of ischaemia if other arteries become involved, such as angina, limb ischaemia, neurological symptoms and pulse deficit between left and right limbs.

7026

Rate this question:

End Session

A 68-year-old male is admitted to hospital with acute onset of substernal chest pain; an electrocardiogram (ECG) reveals acute inferior myocardial infarction. He undergoes primary angioplasty and stenting to the right coronary artery and makes an uneventful recovery. He is discharged home on aspirin 75 mg/day, atenolol 50 mg/day, pravastatin 20 mg/day, enalapril 10 mg twice daily and clopidogrel 75 mg/day. He presents two weeks later again with substernal chest pain. The pain is sharp, radiates to the left trapezius ridge and left lower chest and increases with respiration. On physical examination his pulse rate is 75/min, blood pressure 110/60 mmHg, respiratory rate 22/min and temperature 38.5°C. There is no jugular venous distension, heart sounds are normal and a friction rub is heard at the left anterior and posterior chest. Chest X-ray reveals cardiomegaly, small left pleural effusion and few infiltrates at the left lower zone.

Further investigations:

Hb	13.8 g/dl
WCC	15×10^9/l
PLT	187×10^9/l
ESR	55 mm/1st h
Troponin	<0.05
Urea & other electrolytes	Normal

Which one of the following is the most appropriate way to treat this patient?

A	IV antibiotics
B	Aspirin 650 mg QDS
C	Prednisolone 60 mg/day

B Aspirin 650 mg QDS

This patient's clinical presentation is suggestive of Dressler syndrome, which usually occurs 1-8 weeks after myocardial infarction. Patients present with malaise, fever, pericardial pain, elevated ESR and sometimes may also have pleuritis and pneumonitis. It has been postulated that the syndrome results from release of cardiac antigens which then stimulate antibody production. The immune complexes are then deposited in the pericardium, pleura and lung. There may be accompanying pleural and pericardial effusion and therefore echocardiography should be done.

E Indometacin 100 mg BD

Other NSAIDs such as indomethacin may be utilised in the event that aspirin isn't tolerated.

A IV antibiotics

This patient has inflammatory rather than infective pericarditis, and thus antibiotics have no role in its management.

C Prednisolone 60 mg/day

Corticosteroids are not recommended in the treatment of Dressler syndrome because of the risk that they may delay myocardial healing.

D S/c low-molecular weight (LMW) heparin

The friction rub on auscultation is more consistent with pericarditis versus a pulmonary embolus, and thus LMW

A 26-year-old known asthmatic presents to the Emergency Department complaining of a fluttering in his chest. This started suddenly following the use of his salbutamol inhaler. He says that he usually feels his heart racing after using salbutamol but that this usually settles after a couple of minutes. On this occasion, the palpitations have lasted for 20 min and he is starting to feel uncomfortable.

On arrival his heart rate is 190 beats/min and his blood pressure is 125/75 mmHg. Auscultation of his heart reveals no murmurs and his chest is clear.

His ECG shows a narrow complex, regular tachycardia without any obvious P waves.
Vagal manoeuvres are unsuccessful.

A venous blood sample is taken and run through the blood gas machine:

pH	7.39
Na^+	137 mmol/l
K^+	4.2 mmol/l

Which of the following would be the management of choice?

A	IV verapamil
B	IV digoxin
C	IV adenosine
D	DC cardioversion
E	IV sotalol

A 26-year-old known asthmatic presents to the Emergency Department complaining of a fluttering in his chest. This started suddenly following the use of his salbutamol inhaler. He says that he usually feels his heart racing after using salbutamol but that this usually settles after a couple of minutes. On this occasion, the palpitations have lasted for 20 min and he is starting to feel uncomfortable.

On arrival his heart rate is 190 beats/min and his blood pressure is 125/75 mmHg. Auscultation of his heart reveals no murmurs and his chest is clear.

His ECG shows a narrow complex, regular tachycardia without any obvious P waves.
Vagal manoeuvres are unsuccessful.

A venous blood sample is taken and run through the blood gas machine:

pH	7.39
Na^+	137 mmol/l
K^+	4.2 mmol/l

Which of the following would be the management of choice?

Your answer was correct

A IV verapamil

B IV digoxin

C IV adenosine

A IV verapamil

This patient has a supraventricular tachycardia. Adenosine is contraindicated in asthmatic patients as is beta-blockade. Resuscitation council (RSC) guidelines recommend the following management for patients with narrow-complex regular tachycardia: trial vagal manoeuvres first, followed adenosine 6 mg, followed by a further 12 mg bolus if this is unsuccessful, and a final 12 mg bolus if required. In patients in whom adenosine is contraindicated, such as this patient, or in whom adenosine fails to terminate the rhythm without demonstrating atrial flutter, verapamil 2.5–5 mg IV should be used. This should be done in a closely monitored environment. A rhythm strip should be recorded continuously during the administration of any drug when dealing with SVTs to capture the termination of the arrhythmia. A post-termination ECG should be examined closely for evidence of pre-excitation.

B IV digoxin

This can be considered for rate control of arrhythmias such as atrial fibrillation, but in the context of narrow-complex regular tachycardia, adenosine or verapamil is the recommended agent.

C IV adenosine

While an appropriate choice for the termination of a regular narrow-complex tachycardia, it is contra-indicated in this case due to this patient's history of asthma.

A 38-year-old woman who is 30 weeks pregnant is admitted with central crushing chest pain, sweating and vomiting of 3 h duration. She smoked 20 cigarettes per da prior to her pregnancy and has continued to smoke 10 cigarettes per day since becoming pregnant. Her father suffered a myocardial infarction at the age of 48.

On examination, she has a blood pressure (BP) of 100/50 mmHg, looks pale and sweaty. Her pulse is 60/min regula and she is not in cardiac failure. During the examination, she suffers a VF arrest which responds to one DC shock.

Investigations:

Hb	11.0 g/dl
WCC	5.9×10^9/l
PLT	179×10^9/l
Na^+	139 mmol/l
K^+	4.2 mmol/l
Creatinine	95 µmol/l
ECG	Anterior ST elevation consistent with STEMI

Which of the following is the most appropriate management for her?

A	Angioplasty
B	Low molecular weight (LMW) heparin
C	Recombinant tissue plasminogen activator (rTPA)
D	Intravenous (iv) amiodarone
E	Tirofiban

A Angioplasty

This patient has features which suggest the presence of an acute myocardial infarction. This is supported by her smoking history, significant family history, the nature of the pain, and ECG findings. There is limited data on the management of acute myocardial infarction; although pregnancy is associated with a 3 to 4-fold increases in the risk of pregnancy, the baseline risk remains rare. It is felt that the treatment of acute myocardial infarction should follow the usual standard of care (ie angioplasty).

Reference:

Roth A, Elkayam U. Acute myocardial infarction associated with pregnancy. J Am Coll Cardiol. 2008;52:171-180.

B Low molecular weight (LMW) heparin

This treatment would be appropriate if the likely diagnosis was a pulmonary embolism (PE). Although common in pregnancy, the clinical picture does not fit this diagnosis. The patient's baseline heart rate is 60 bpm. It would be expected that the patient would be tachycardic if the PE was large enough to result in a cardiac arrest. Further, the ECG demonstrates features of a STEMI and does not indicate right ventricular strain

C Recombinant tissue plasminogen activator (rTPA)

While rTPA can be appropriate for the treatment of an acute STEMI, this is primarily limited to situations in which angioplasty is not immediately available. The placental transfer of rTPA is limited, and unlikely to affect the foetus However, despite some evidence of favourable outcomes when thrombolysis has been used for the treatment of PEs there have been reports of maternal haemorrhage, preterm delivery, foetal loss, and spontaneous abortion.

Reference:

B Low molecular weight (LMW) heparin

This treatment would be appropriate if the likely diagnosis was a pulmonary embolism (PE). Although common in pregnancy, the clinical picture does not fit this diagnosis. The patient's baseline heart rate is 60 bpm. It would be expected that the patient would be tachycardic if the PE was large enough to result in a cardiac arrest. Further, the ECG demonstrates features of a STEMI and does not indicate right ventricular strain

C Recombinant tissue plasminogen activator (rTPA)

While rTPA can be appropriate for the treatment of an acute STEMI, this is primarily limited to situations in which angioplasty is not immediately available. The placental transfer of rTPA is limited, and unlikely to affect the foetus However, despite some evidence of favourable outcomes when thrombolysis has been used for the treatment of PEs there have been reports of maternal haemorrhage, preterm delivery, foetal loss, and spontaneous abortion.

Reference:

Lecander I, Nilsson M, Astedt B. Depression of plasminogen activator activity during pregnancy by the placental inhibitor PAI 2. Fibrinolysis 1988;2:165-7.

Roth A, Elkayam U. Acute myocardial infarction associated with pregnancy. J Am Coll Cardiol. 2008;52:171-180.

D Intravenous (iv) amiodarone

Amiodarone is a class III antiarrhythmic agent and may have some role in the secondary prevention of further VF arrests if an underlying cause is uncertain. However, the cause of this arrest is likely secondary to an acute myocardial infarction. Treatment of this cause should be the priority.

A 55-year-old woman presents with a history of tiredness and decreased effort tolerance of 3 months' duration. She has a 5-year history of hypertension controlled with slow-release indapamide 1.5 mg a day. She is a lifelong non-smoker and has no family history of premature coronary artery disease. Her lipid profile checked 6 months earlier was normal. She has no other past medical history of note.

Physical examination reveals an irregular pulse at a rate of 95 bpm, a blood pressure of 135/80 mmHg, no jugular venous distension, an apex beat in the fifth intercostal space and normal heart sounds, without any murmur.

Investigations:

Haemoglobin (Hb)	140 g/dl
Potassium (K^+)	4.4 mmol/L
Sodium (Na^+)	138 mmol/l
Creatinine	85 µmol/l
Thyroid-stimulating hormone (TSH)	1.3 iu/l (0.4–5)
Free thyroxine (T4)	13 pmol/l (10–22)
Electrocardiogram (ECG)	Atrial fibrillation with ventricular rate of 108/min
Echocardiography	Left ventricular (LV) ejection fraction 58%, left atrial diameter 4.6 cm, concentric LV hypertrophy and trivial mitral regurgitation

She is started on low molecular weight heparin.

Which of the following treatments would you institute next?

Sodium (Na^+)	138 mmol/l
Creatinine	85 µmol/l
Thyroid-stimulating hormone (TSH)	1.3 iu/l (0.4–5)
Free thyroxine (T4)	13 pmol/l (10–22)
Electrocardiogram (ECG)	Atrial fibrillation with ventricular rate of 108/min
Echocardiography	Left ventricular (LV) ejection fractio 58%, left atrial diameter 4.6 cm, concentric LV hypertrophy and trivial mitral regurgitation

She is started on low molecular weight heparin.

Which of the following treatments would you institute next?

A	Aspirin
B	Aspirin and dipyramidole
C	Dipyridamole modified-release (MR)
D	Clopidogrel
E	Non-vitamin K oral anticoagulant (NOAC)

6069

Submit

E Non-vitamin K oral anticoagulant (NOAC)

The National Institute for Health and Care Excellence (NICE) guidelines (CG180: Management of atrial fibrillation) advocate rhythm control should be initiated in this patient. The duration of AF is uncertain; therefore, the first step should be adequate anticoagulation with a NOAC, eg rivaroxaban, apixaban, or dabigatran. NICE has now advocated that patients can be started immediately on a NOAC for non-valvular AF, as opposed to using warfarin. NOACs have advantages over warfarin, in terms of simpler monitoring and management, as well as fewer interactions. Anticoagulation should be continued for at least 3 weeks before direct current cardioversion. Anticoagulation may be continued thereafter, given her increased left atrial size and mitral regurgitation.

A Aspirin

Aspirin has no role in anticoagulation of patients in AF. In this clinical case, her CHA_2DS_2-VAS_c score for AF is 2, hence conveying an annual risk of stroke of 2.2%. Therefore, anticoagulation with warfarin or a non-vitamin K oral anticoagulant (NOAC), eg rivaroxaban, apixaban or dabigatran, is recommended.

B Aspirin and dipyramidole

A patient's bleeding risk must be considered before commencing anticoagulation of AF; the HASBLED score can be used to assess this. Studies showed aspirin with the addition of another antiplatelet was worse than warfarin alone in stroke prevention, with an increased risk of bleeding, compared with warfarin.

C Dipyridamole modified-release (MR)

Dipyridamole MR has no role in the reduction of stroke in

door she found her mother sprawled on the couch. She also found the gas heater switched on but there was no flame. She then quickly called the ambulance. On examination, the patient is drowsy with a Glasgow Coma Scale of 12/15, blood pressure of 154/90, pulse of 98/min and a respiratory rate of 28/min. The patient has already been started on high flow oxygen via a non-rebreather mask.

What single initial investigation would be most helpful in determining the prognosis for this patient?

A	Toxicology screen
B	Carboxyhaemoglobin (COHb)
C	12-lead electrocardiogram
D	Full blood count (FBC), U and E, creatine phosphokinase (CPK) and cardiac enzymes
E	Oxygen saturation with pulse oximeter

7515

Submit

A 42-year-old homeless man is admitted with confusion, fever and shortness of breath. He is well known to the Emergency Department and has presented on a number of occasions with alcohol intoxication. On examination he is pyrexial at 38.6°C. He has a cough productive of purulent and blood-stained sputum. Auscultation of the chest reveals findings consistent with left-sided consolidation, and chest X-ray confirms consolidation and evidence of cavitation with abscess formation.

Which of the following is the most likely diagnosis?

Your answer was correct

A *Chlamydia psittaci*

B *Haemophilus influenzae*

C *Klebsiella pneumoniae*

D *Staphylococcus aureus*

C *Klebsiella pneumoniae*

This patient has pneumonia with evidence of lung abscess formation. Given his history of alcoholism and the fact there is evidence of cavitation on chest X-ray, *Klebsiella* is a likely cause. Third-generation cephalosporins or quinolones provide coverage for community-acquired infection but macrolides do not. Mortality is particularly high in patients with a history of alcoholism, potentially as a result of poor nutrition and defective immunity associated with chronic excess alcohol consumption.

A *Chlamydia psittaci*

C. psittaci is associated with atypical pneumonia as a result of exposure to infected birds. Symptoms may initially mimic typhoid fever with fever, joint pains, gastrointestinal (GI) disturbance, headache and lymphopaenia. A cough and evidence of respiratory tract infection develop later.

B *Haemophilus influenzae*

H. influenzae infection is associated primarily with exacerbations of chronic obstructive pulmonary disease (COPD) rather than the cavitating pneumonia seen here.

D *Staphylococcus aureus*

S. aureus is also associated with cavitation and abscess formation, but occurs more commonly after an episode of influenza.

E *Streptococcus pneumoniae*

S. pneumoniae is a common cause of community-acquired pneumonia, although it is not usually cavitating.

32429

Rate this question:

A 56-year-old lady comes into the Emergency Department with palpitations and shortness of breath. She is known to have mild chronic obstructive pulmonary disease (COPD) and is on the following inhalers: salbutamol, ipratropium bromide and beclomethasone; according to her notes, she does have a mild degree of reversibility. On examination, the patient is dyspnoeic with blood pressure 154/88 mmHg and pulse rate of >100/min (AF). She underwent echocardiography 6 months ago, which showed normal ventricular function and no structural abnormality.

Her admission arterial blood gases (ABG) are:

pH	7.32
$p_a(O_2)$	8.1 kPa
$p_a(CO_2)$	6.2 kPa
Bicarbonate	28 mmol/l

You start the patient on 28% oxygen, nebulisers (salbutamol 5 mg and

nebulisers (salbutamol 5 mg and ipratropium 0.5 mg) and repeat the blood gases after 30 min:

pH	7.36
$p_a(O_2)$	9.6 kPa
$p_a(CO_2)$	5.8 kPa
Bicarbonate	29 mmol/l

You reassure her that she is improving on the current medication, but she tells you that she is still having palpitations. You do a 12-lead electrocardiogram (ECG), which reveals multi-focal atrial tachycardia (MAT) with a rate of 118/min. Her BP has fallen to 110/70 mmHg.

How would you control this arrhythmia?

Your answer was correct

A DC – cardioversion

B Start metoprolol

Your answer was correct

A	DC – cardioversion
B	Start metoprolol
C	Start verapamil
D	Increase inspired oxygen to 40%
E	Observation only

Explanation

C	Start verapamil

MAT commonly occurs in critically ill patients with obstructive airways disease who may be hypoxic and hypercapnic. It is characterised by at least three different P-wave morphologies with varying PP and PR

C Start verapamil

MAT commonly occurs in critically ill patients with obstructive airways disease who may be hypoxic and hypercapnic. It is characterised by at least three different P-wave morphologies with varying PP and PR intervals. Aim to improve both $p_a(O_2)$ and $p_a(CO_2)$.

Whilst AF control may not be required as her pulmonary status improves, it is likely that in the acute phase, especially with repeated salbutamol nebulisers, that she will suffer from worsening symptoms of tachycardia. As such, verapamil would be an appropriate option. It can be given in small boluses of 5 mg intravenously and then as an oral dose of 40–120 mg TDS. It is a moot point whether she will require long-term AF control. If following the acute episode she remains in sinus rhythm, a 72 h ECG monitor may be appropriate prior to committing her to new medication.

A DC cardioversion

A DC – cardioversion

DC cardioversion would be an inappropriate option in this patient. It should be done in an emergency situation if the patient becomes haemodynamically unstable or develops myocardial infarction as a result of the arrhythmia. If this happens and the patient is conscious, then sedation can be given. It is important that the shock delivered is synchronised to avoid shocking on a T wave, which could lead to asystole.

B Start metoprolol

Metoprolol could make her COPD worse as it is a beta-antagonist. It could induce worsening bronchospasm and is therefore contraindicated for this patient. However, modern evidence has demonstrated that metoprolol is cardioselective and is unlikely to cause significant problems for most patients with COPD.

metoprolol is cardioselective and is unlikely to cause significant problems for most patients with COPD.

D	Increase inspired oxygen to 40%

This would be inappropriate as it would not deal immediately with the underlying problem of the arrhythmia, which is important as the patient's blood pressure has become lower. Also, the hypoxia is already improving, and increasing oxygen may worsen the patient's hypercapnia.

E	Observation only

This arrhythmia has become significant in that it has caused a drop in blood pressure in a very unstable patient. Therefore it would be inappropriate to simply observe.

7504

Rate this question:

A 67-year-old man presents with increasing shortness of breath, cough at night and pleuritic chest pain. He has a past history of myocardial infarction and left ventricular failure and a 40 pack-year smoking history. Medication includes ramipril, furosemide and amlodipine. Last year he was prescribed amiodarone for paroxysmal ventricular tachycardia and he has taken the medication since then. On examination his blood pressure is 142/85 mmHg, pulse is 85/min and there are scattered crackles on auscultation with evidence of a left-sided pleural effusion. Chest X-ray (CXR) reveals evidence of lung infiltration with bilateral focal opacities and confirms a small left-sided pleural effusion.

Which of the following diagnoses fits best with this clinical picture?

A	Left ventricular failure
B	Amiodarone toxicity

of a left-sided pleural effusion. Chest X-ray (CXR) reveals evidence of lung infiltration with bilateral focal opacities and confirms a small left-sided pleural effusion.

Which of the following diagnoses fits best with this clinical picture?

A	Left ventricular failure
B	Amiodarone toxicity
C	Angiotensin-converting enzyme (ACE) inhibitor-induced lung fibrosis
D	Idiopathic pulmonary fibrosis
E	Chronic obstructive pulmonary disease (COPD)

32428

Submit

B Amiodarone toxicity

Amiodarone toxicity occurs in approximately 5% of patients. This can vary from acute respiratory distress to a picture of cough, pleuritic chest pain, pulmonary infiltrates and small pleural effusions, to interstitial pneumonitis and eventually progressive pulmonary fibrosis. Due to its long half-life, amiodarone toxicity takes some weeks to resolve; as such, corticosteroids are added when therapy is discontinued as this may lead to more rapid resolution of symptoms. Of course cardiology input is vital before amiodarone is discontinued – as in this case when paroxysmal VT is the indication for therapy, an implantable cardioverter defibrillator is the next logical step (and has been proven in trials to have a superior outcome).

E Chronic obstructive pulmonary disease (COPD)

COPD is not associated with the pulmonary fibrotic changes seen on

pulmonary fibrotic changes seen on CXR here, although smoking-related lung disease may be a contributor to his shortness of breath.

A	Left ventricular failure

Left ventricular failure is associated with infiltrates on the CXR consistent with fluid overload, but not with the focal opacities seen here. Upper lobe diversion is also expected on CXR examination where there is significant LVF.

C	Angiotensin-converting enzyme (ACE) inhibitor-induced lung fibrosis

ACE inhibitors are associated with a dry cough and bronchospasm, but are not associated with pulmonary fibrosis.

D	Idiopathic pulmonary fibrosis

Idiopathic pulmonary fibrosis is diagnosed once other causes of

Left ventricular failure is associated with infiltrates on the CXR consistent with fluid overload, but not with the focal opacities seen here. Upper lobe diversion is also expected on CXR examination where there is significant LVF.

C	Angiotensin-converting enzyme (ACE) inhibitor-induced lung fibrosis

ACE inhibitors are associated with a dry cough and bronchospasm, but are not associated with pulmonary fibrosis.

D	Idiopathic pulmonary fibrosis

Idiopathic pulmonary fibrosis is diagnosed once other causes of pulmonary fibrosis have been excluded. In this case, given the amiodarone use, this is a more likely cause of the lung changes.

32428

Rate this question:

A 70-year-old lady is referred to the Medical Clinic by her general practitioner (GP) following shortness of breath. She has been seeing her GP over the last couple of months for increasing shortness of breath on exercise. Her GP had done some investigations but still could not explain her shortness of breath on exercise. She has had a dry cough which has been on and off for the last 4 months. On examination, her blood pressure is 135/80 mmHg, pulse 70 bpm and regular. Her jugular venous pulse is not raised and her heart sounds are normal. Her breathing is noisy but her chest is clinically clear on auscultation.

Which investigation is likely to be most helpful in determining where any obstruction lies?

A	Chest X-ray
B	Bronchoscopy

pressure is 135/80 mmHg, pulse 70 bpm and regular. Her jugular venous pulse is not raised and her heart sounds are normal. Her breathing is noisy but her chest is clinically clear on auscultation.

Which investigation is likely to be most helpful in determining where any obstruction lies?

A	Chest X-ray
B	Bronchoscopy
C	Flow volume loop
D	Polysomnography
E	Arterial blood gases

7506

Submit

C Flow volume loop

This patient likely has a partial upper airway obstruction. The causes in this age group would include: a tumour, a multinodular goitre or an aneurysm. A flow loop volume would show characteristic patterns with intrathoracic/extrathoracic obstruction.

A Chest X-ray

This patient has signs suggestive of partial upper airway obstruction. A chest X-ray would not help determining where the upper airway obstruction lies. A significant multinodular goitre may, however, be an incidental finding on chest X-ray.

B Bronchoscopy

Though bronchoscopy is important in the diagnosis and management of central airway obstruction, its role in

B Bronchoscopy

Though bronchoscopy is important in the diagnosis and management of central airway obstruction, its role in the diagnosis of upper airway obstruction is limited.

D Polysomnography

This test would not help determine the location of the upper airway obstruction. Polysomnography is used in the diagnosis of sleep disorders.

E Arterial blood gases

In the context of the history given, there is no indication for an arterial blood gas.

7506

Rate this question:

Next Question

A 70-year-old female smoker presents with a 3-day history of loss of sensation of both her lower legs. She also reports a 1-stone (6.53 kg) weight loss and unresolving cough over the last month. Her chest X-ray shows a large hilar mass, not seen on a chest X-ray from 2 months ago. She has no other past medical history and is not on any medication. On examination she has loss of light touch and pain sensation in a stocking distribution, reduced air entry in her right chest, palpable supraclavicular lymph node and a large craggy liver edge.

Investigations:

WCC	6.2×10^9/l ($4–11 \times 10^9$/l)
Hb	11.6 g/dl (11.5–16.0 g/dl)
PLT	347×10^9/l ($150–400 \times 10^9$/l)

Which of the following is the most likely diagnosis?

A	Small-cell carcinoma

Investigations:

WCC	6.2×10^9/l ($4–11 \times 10^9$/l)
Hb	11.6 g/dl (11.5–16.0 g/dl)
PLT	347×10^9/l ($150–400 \times 10^9$/l)

Which of the following is the most likely diagnosis?

A Small-cell carcinoma

B Non-Hodgkin's lymphoma

C Adenocarcinoma

D Sarcoid

E Squamous cell carcinoma

A Small-cell carcinoma

Given the rapid progression and spread of her pathology and the probable paraneoplastic peripheral neuropathy, this is the most likely diagnosis. Small cell carcinoma accounts for 20% of all lung cancers (National Cancer Intelligence Network, 2012), and it is the morphological subtype of lung cancer most closely associated with smoking. Small cell carcinoma often presents with unilateral hilar enlargement, a perihilar or a mediastinal mass. Less commonly, it may present with a central lesion, often cavitating, and given its rapid growth, with satellite lesions elsewhere in the thorax, characteristically with extensive, bulky mediastinal lymphadenopathy.

B Non-Hodgkin's lymphoma

The rapid spread of disease in this patient would be associated with an abnormal full blood count in non-

Hodgkin's lymphoma.

C	Adenocarcinoma

Though the most common type of non-small-cell lung cancer, it is usually slow growing. It typically presents as a peripheral mass lesion, or less commonly as an area of segemental ground-glass attenuation.

D	Sarcoid

The history of smoking and rapid progression of pathology are suggestive of a malignant process. Sarcoid could cause the neurology seen, but would cause a smooth, enlarged granulomatous liver and widespread generalised lymphadenopathy rather than the craggy liver edge and isolated palpable supraclavicular lymph node noted.

E	Squamous cell carcinoma

ground-glass attenuation.

D	Sarcoid

The history of smoking and rapid progression of pathology are suggestive of a malignant process. Sarcoid could cause the neurology seen, but would cause a smooth, enlarged granulomatous liver and widespread generalised lymphadenopathy rather than the craggy liver edge and isolated palpable supraclavicular lymph node noted.

E	Squamous cell carcinoma

Like adenocarcinoma, squamous cell carcinoma is much slower growing. It typically presents as a central lesion on chest X-ray, with or without lung collapse due to intraluminal obstruction.

7175

Rate this question:

A 23-year-old African-Caribbean patient develops painful red nodules on both her shins over 2 days and has noticed painful knees, ankles and wrists. She also complains of mild sweats and weight loss over the past 2 months. Chest X-ray shows bilateral hilar lymphadenopathy (BHL) but clear lung fields.

Given the likely clinical diagnosis, what is the most likely outcome for her?

A	Complete remission after a course of steroids
B	Spontaneous resolution with no long-term sequelae
C	Spontaneous resolution followed by further relapses
D	Peripheral lung infiltrates and shortness of breath
E	Increasing weight loss and

A 23-year-old African-Caribbean patient develops painful red nodules on both her shins over 2 days and has noticed painful knees, ankles and wrists. She also complains of mild sweats and weight loss over the past 2 months. Chest X-ray shows bilateral hilar lymphadenopathy (BHL) but clear lung fields.

Given the likely clinical diagnosis, what is the most likely outcome for her?

A	Complete remission after a course of steroids
B	Spontaneous resolution with no long-term sequelae
C	Spontaneous resolution followed by further relapses
D	Peripheral lung infiltrates and shortness of breath

B Spontaneous resolution with no long-term sequelae

This patient has acute sarcoidosis with erythema nodosum, polyarthralgia and mild constitutional symptoms. Around 90% patients have BHL at presentation. In 10–20% of cases, symptoms progress to shortness of breath, dry cough and chest pain. The majority of patients (80%) either stabilise or regress, so in the first instance treatment is not indicated. Non-pulmonary manifestations include neuropathy, Bell's palsy, hepatosplenomegaly, uveitis, conjunctivitis, lupus pernio, subcutaneous nodules, cardiomyopathy, arrhythmias, hypercalcaemia and renal stones. Treatment of acute sarcoidosis is usually supportive, including non-steroidal anti-inflammatory drugs (NSAIDs) for polyarthralgia, because most recover spontaneously.

A Complete remission after a course of steroids

A Complete remission after a course of steroids

Sarcoidosis usually resolves spontaneously and steroids at first presentation would not be indicated. Steroids should be commenced if: symptoms worsen or cause limitation to daily activities, pulmonary function deteriorates, CXR signs worsen (e.g. development of cavitation or fibrosis) or if other organ system involvement develops.

C Spontaneous resolution followed by further relapses

Most patients recover spontaneously, and in 90% this is within 2 years. Less than 10% develop relapses after this point. Relapses and chronic disease are more likely if spontaneous remission does not occur within the first 2 years.

D Peripheral lung infiltrates and shortness of breath

are more likely if spontaneous remission does not occur within the first 2 years.

D	Peripheral lung infiltrates and shortness of breath

The extent of infiltrates on CXR is used in staging of the disease and is a guide to prognosis, with the likelihood of relapse increasing as the extent of infiltrate worsens. This option is incorrect because it is uncommon.

E	Increasing weight loss and neurological impairment

Neurological involvement does occur with sarcoidosis, but this is rare, occurring in 5-15% of patients. Neurological involvement tends to be present at presentation and often in disease with other significant extra-pulmonary features. This option is incorrect because it is an uncommon outcome.

A 45-year-old farmer comes to the Respiratory Clinic for review. He has been diagnosed by the GP as having asthma, for which he is treated with high-dose fluticasone/salmeterol and salbutamol ,without significant improvement in his symptoms. Examination reveals a BP of 122/72 mmHg, with pulse 70/min and regular. There is scattered wheeze and coarse crackles on auscultation of the chest. Respiratory function tests show an obstructive picture. A thoracic HRCT shows bilateral centrally dilatated thickened airways with 'signet rings'.

Which of the following tests would be most useful to confirm the suspected diagnosis?

A	IgE
B	IgG
C	ANCA
D	ANA

improvement in his symptoms. Examination reveals a BP of 122/72 mmHg, with pulse 70/min and regular. There is scattered wheeze and coarse crackles on auscultation of the chest. Respiratory function tests show an obstructive picture. A thoracic HRCT shows bilateral centrally dilatated thickened airways with 'signet rings'.

Which of the following tests would be most useful to confirm the suspected diagnosis?

A	IgE
B	IgG
C	ANCA
D	ANA
E	C3 and C4

A 45 year old farmer comes to the Respiratory Clinic for review. He has been diagnosed by the GP as having asthma, for which he is treated with high-dose fluticasone/salmeterol and salbutamol ,without significant improvement in his symptoms. Examination reveals a BP of 122/72 mmHg, with pulse 70/min and regular. There is scattered wheeze and coarse crackles on auscultation of the chest. Respiratory function tests show an obstructive picture. A thoracic HRCT shows bilateral centrally dilatated thickened airways with 'signet rings'.

Which of the following tests would be most useful to confirm the suspected diagnosis?

Your answer was incorrect

A IgE

B IgG

C ANCA

A IgE

The HRCT changes described are classical of proximal bronchiectasis. The diagnosis is therefore allergic bronchopulmonary aspergillosis (ABPA). The total IgE will be raised in ABPA, especially during a flare-up, and therefore represents the preferred investigation.

C ANCA

ANCA is most likely to be elevated in vasculitis. Eosinophilic vasculitis (Churg–Strauss) is associated with more features than just worsening of asthma, including skin lesions and mononeuritis, which aren't seen in this scenario.

B IgG

IgG can be low in bronchiectasis secondary to hypogammaglobulinaemia, although presentation for the first time at an

A IgE

The HRCT changes described are classical of proximal bronchiectasis. The diagnosis is therefore allergic bronchopulmonary aspergillosis (ABPA). The total IgE will be raised in ABPA, especially during a flare-up, and therefore represents the preferred investigation.

C ANCA

ANCA is most likely to be elevated in vasculitis. Eosinophilic vasculitis (Churg–Strauss) is associated with more features than just worsening of asthma, including skin lesions and mononeuritis, which aren't seen in this scenario.

B IgG

IgG can be low in bronchiectasis secondary to hypogammaglobulinaemia, although presentation for the first time at an

hypogammaglobulinaemia, although presentation for the first time at an earlier age would be expected because of recurrent respiratory tract infection.

D	ANA

ANA is raised in connective tissue disease such as SLE, although there are no other features to suggest connective tissue disease as the underlying diagnosis.

E	C3 and C4

Complement factors are consumed most when there is active tissue inflammation, such as with SLE. The absence of other features such as glomerulonephritis counts against C3 and C4 as being useful here.

2329

Rate this question:

Next Question

A 64-year-old female presents to the Emergency Department with severe shortness of breath, fever, and a cough productive of rusty-coloured sputum. She has no past medical history. On auscultation of her chest, crackles are heard at the right base. Her blood pressure is 110/70 mmHg, she is tachycardic with a pulse rate of 101 beats per minute, her respiratory rate is 28 breaths per minute and she is pyrexial at 38.2°C.

Investigations:

Hb	121 g/l (115–165)
WCC	12.9×10^9/l (4.0–11.0)
PLT	204×10^9/l (150–400)
Na^+	140 mmol/l (133–146)
K^+	4.5 mmol/l (3.5–5.3)
Urea	9.0 mmol/l (2.5–7.8)
Creatinine	110 micromol/l (50 –120)
P_aO_2	8.2 kPa (11–13)
P_aCO_2	6.1 kPa (4.7–6.0)

P_aO_2	8.2 kPa (11–13)
P_aCO_2	6.1 kPa (4.7–6.0)
EGG	Sinus tachycardia – 101 beats/min

Which of the following features in the clinical picture would contribute to an increased CURB-65 score in his case?

A	pO_2 8.2 kPa
B	pCO_2 5.9 kPa
C	WCC 12.9 × 10^9/l
D	Urea 9.0 mmol/l
E	Respiratory rate 28/min

21468

Submit

D Urea 9.0 mmol/l

The CURB-65 score is a simple additive score ranging from 0–5, based on the presence of confusion, urea, respiratory rate, blood pressure and age, which can be used to stratify patients with community-acquired pneumonia into different management groups.

Each of the following features score 1 point:
Confusion (<8/10 score on abbreviated mental teste (AMT))
Urea >7 mmol/l
Respiratory rate >30 breaths/min
Blood pressure – systolic <90 mmHg and/or diastolic <60 mmHg
Age > 65.

Patients with scores of 0 and 1 are at low risk of mortality (<2%) and might be suitable for management as hospital outpatients or by their general practitioner. Patients with a score of 2 are at intermediate risk of mortality (9%) and should be considered for hospital-supervised treatment. Patients

with a score of >2 are at high risk of mortality (>19%). They should be treated in hospital. Initial care in an intensive care or high-dependency unit may be appropriate in those with the highest scores

A	pO_2 8.2 kPa

Hypoxaemia does not feature in the CURB-65 score. However, patients with hypoxaemia do have a worse prognosis.

B	pCO_2 5.9 kPa

Hypercapnia does not feature in the CURB-65 score. However, the presence of co-existing lung disease is a bad prognostic factor.

C	WCC $12.9 \times 10^9/l$

White cell count does not feature in the CURB-65 score. However, a white cell count above $12 \times 10^9/l$ is a feature of the systemic inflammatory response

A 16-year-old boy presents with a persistent cough productive of brown/green sputum. He occasionally produces a small amount of blood. His mother said he had always suffered from chest infections, requiring numerous courses of antibiotics. He also complained of offensive-smelling stools which were difficult to flush. On examination he looked small for his age. Auscultation of his chest revealed bi-basal coarse crackles.

Investigations:

Hb	11.2 g/dl
WBC	10.7 $\times 10^9$/l
PLT	511 $\times 10^9$/l
MCV	91 fl
Na^+	139 mmol/l
K^+	3.9 mmol/l
Urea	5.3 mmol/l
Creatinine	99 micromol/l
Bilirubin	18 micromol/l

Creatinine	99 micromol/l
Bilirubin	18 micromol/l
AST	34 U/l
ALP	93 U/l
Albumin	39 g/l
Total Protein	50 g/l

His CXR is shown below:

What is the diagnosis?

A	Cystic fibrosis
B	Kartagener's syndrome
C	Young's syndrome

What is the diagnosis?

A	Cystic fibrosis
B	Kartagener's syndrome
C	Young's syndrome
D	X-linked hypogammaglobulinaemia
E	Eosinophilic granulomatosis with polyangiitis (Churg-Strauss)

6:41

Albumin	39 g/l
Total Protein	50 g/l

is CXR is shown below:

What is the diagnosis?

K^+	3.9 mmol/l
Urea	5.3 mmol/l
Creatinine	99 micromol/l
Bilirubin	18 micromol/l
AST	34 U/l
ALP	93 U/l
Albumin	39 g/l
Total Protein	50 g/l

His CXR is shown below:

What is the diagnosis?

Your answer was correct

D X-linked hypogammaglobulinaemia

This patient has X-linked hypogammaglobulinaemia. The main clue is the low total protein with a normal albumin, demonstrating low levels of globulins.

Patients usually present in childhood with recurrent infections, which result in bronchiectasis if untreated, and malabsorption, in a similar way to patients with cystic fibrosis. All immunoglobulin classes and B cells and plasma cells are reduced.

The defect is in the differentiation of pre-B cells into B cells. T cells are normal. The gene defect is on the long arm of the X chromosome, making it an X-linked condition.

Treatment is with IV immunoglobulin therapy which, if started early, can prevent progression of disease.

The chest X-ray shows bronchiectasis – parallel thickened bronchial walls with a 'tram track' appearance.

Although the patient has symptoms compatible with CF, bronchiectasis visible on his CXR and the low total protein makes X-linked hypogammaglobulinaemia more likely.

B	Kartagener's syndrome

There is no dextrocardia seen on the CXR. Kartagener syndrome is associated with bronchiectasis, sinusitis and dextrocardia.

C	Young's syndrome

Young syndrome is not associated with malabsorption: it is the triad of bronchiectasis, rhinosinusitis and reduced fertility.

E	Eosinophilic granulomatosis with polyangiitis (Churg-Strauss)

An asthma/rhinitis prodrome to this condition is classical, followed by an eosinophilia and systemic vasculitis.

A 31-year-old asthmatic woman was seen in the Respiratory Outpatient Clinic. She said she had been generally well although she had not been sleeping well at night due to coughing. She had also noticed that when playing tennis she was getting wheezy and requiring her salbutamol inhaler more frequently – at least 4 times a week. She was taking budesonide 200 micrograms two puffs twice a day. She had no significant past medical history. She smoked 10 cigarettes/day and had done so for 2 years. Auscultation of her chest revealed a mild expiratory wheeze. Examination was otherwise remarkable.

Auscultation of her chest revealed a mild expiratory wheeze. Examination was otherwise remarkable.

Investigations:

PEF	80% predicted
FEV1	85% predicted
FVC	90% predicted

She is treated successfully and goes home.

Her symptoms improve and she goes back to playing regular tennis without a problem. Three months later she was feeling so much better she decided not to renew her prescription for her inhalers.

Two weeks following this she developed a chest infection and became acutely short of breath. On examination she is unable to speak full sentences. Respiratory rate is 30/min, pulse 115/min, BP 100/60 mmHg.

Auscultation of her chest reveals an expiratory wheeze throughout.

PEFR	150 l/min
ABGs on air:	
pH	7.47
pCO_2	4.06 kPa
pO_2	12 kPa
Bicarbonate	21.5 mmol/l

best initial management for this patient?

A	High-flow oxygen, oral/intravenous steroid, and salbutamol
B	60% oxygen, oral/intravenous steroid, salbutamol and ipratropium bromide nebulisers and leukotriene receptor antagonist
C	60% oxygen, oral/intravenous steroid, salbutamol and intravenous magnesium
D	High-flow oxygen, salbutamol and ipratropium bromide nebulisers and intravenous magnesium
E	High-flow oxygen, intravenous/oral steroids, ipratropium bromide nebuliser and intravenous

B	60% oxygen, oral/intravenous steroid, salbutamol and ipratropium bromide nebulisers and leukotriene receptor antagonist
C	60% oxygen, oral/intravenous steroid, salbutamol and intravenous magnesium
D	High-flow oxygen, salbutamol and ipratropium bromide nebulisers and intravenous magnesium
E	High-flow oxygen, intravenous/oral steroids, ipratropium bromide nebuliser and intravenous aminophylline

WhatsApp • 3 messages from 2 chats • Just now
Mrcp2: Dr.Ahmed 1 or 3
Asmaa Abd Elazeem (2 messages): بس مش ملاحقه...

A High-flow oxygen, oral/intravenous steroid, and salbutamol

After stopping her inhalers she is no longer on any medication to control her asthma. She presents to the Emergency Department with symptoms and signs of a severe asthma exacerbation – inability to complete a sentence in one breath, respiratory rate >25/min, tachycardia >110 bpm and PEFR <50%. The correct management is high-flow oxygen as patients with pure asthma do not retain carbon dioxide; salbutamol driven by oxygen; steroid therapy – prednisolone 40 mg orally if the patient is able to take oral medication, or 100 mg intravenous hydrocortisone. Ipratropium may also be used. Intravenous magnesium should be given in life-threatening asthma or if there is no response to initial therapy. Intravenous aminophylline can also be used.

A High-flow oxygen, oral/intravenous steroid, and salbutamol

After stopping her inhalers she is no longer on any medication to control her asthma. She presents to the Emergency Department with symptoms and signs of a severe asthma exacerbation – inability to complete a sentence in one breath, respiratory rate >25/min, tachycardia >110 bpm and PEFR <50%. The correct management is high-flow oxygen as patients with pure asthma do not retain carbon dioxide; salbutamol driven by oxygen; steroid therapy – prednisolone 40 mg orally if the patient is able to take oral medication, or 100 mg intravenous hydrocortisone. Ipratropium may also be used. Intravenous magnesium should be given in life-threatening asthma or if there is no response to initial therapy. Intravenous aminophylline can also be used.

steroid, salbutamol and intravenous magnesium

Intravenous magnesium is reserved for patients with a PEFR <50% predicted and who have not had a good response to inhaled bronchodilator therapies.

B	60% oxygen, oral/intravenous steroid, salbutamol and ipratropium bromide nebulisers and leukotriene receptor antagonist

Leukotriene receptor antagonists are used in the management of asthma, but are not appropriate as an acute treatment for an exacerbation.

D	High-flow oxygen, salbutamol and ipratropium bromide nebulisers and intravenous magnesium

Intravenous magnesium is reserved for patients with a PEFR <50% predicted

A woman presents to clinic in her eighth week of pregnancy. She is concerned about her husband's family history of cystic fibrosis (CF), as her husband's brother has cystic fibrosis and her husband has been confirmed as a carrier. The patient does not wish to know about her risk of developing CF and is reluctant to be tested herself, but is concerned about the health of her child. There is a 1:20 prevalence of CF carriage in the area where she lived as a child and husband and wife are not consanguineous.

What is the chance of her child having cystic fibrosis?

A	1/4
B	1/40
C	1/80
D	1/160

and her husband has been confirmed as a carrier. The patient does not wish to know about her risk of developing CF and is reluctant to be tested herself, but is concerned about the health of her child. There is a 1:20 prevalence of CF carriage in the area where she lived as a child and husband and wife are not consanguineous.

What is the chance of her child having cystic fibrosis?

A	1/4
B	1/40
C	1/80
D	1/160
E	1/320

9835

Submit

C 1/80

CF is an autosomal recessive disease, so two abnormal alleles are required for the disease to be manifest. As a carrier (with one abnormal gene) the husband has a 1:2 chance of passing the abnormal gene to his offspring. If one assumes that the woman is of the same genetic stock as those in the area of her birth, she has a 1:20 chance of being a carrier, so the chance of the child receiving an abnormal allele from both parents is 1/2 (male risk) × 1/20 (female carrier risk) × 1/2 (female risk of passing a gene on) = 1/80.

B 1/40

1 in 40 would be the risk of offspring suffering from a recessive condition if one partner was a homozygote for the abnormal gene, and the carrier frequency was 1 in 20.

A 1/4

one partner was a homozygote for the abnormal gene, and the carrier frequency was 1 in 20.

A	1/4

1 in 4 is the risk of a child being affected by CF if both of the parents are confirmed to be carriers for the disease.

D	1/160

This would be the correct answer if the carrier frequency was 1 in 40, not 1 in 20 as it is.

E	1/320

This would be the correct answer if the carrier frequency was 1 in 80.

9835

Rate this question:

Next Question

A 54-year-old woman has a left adenocarcinoma of the bronchus confirmed on transbronchial biopsy. She tells you that she has lost weight over the past few months and has a nagging cough, particularly in the mornings, but actually has still been able to hold down her job, riding her bike the short distance to work and caring for her teenage children.

Investigations:

Hb	13.5 g/dl
WCC	5.6 $\times 10^9$/l
PLT	190 $\times 10^9$/l
Na^+	139 mmol/l
K^+	4.5 mmol/l
Creatinine	120 μmol/l

Which of the following is likely to be most informative with respect to determining her suitability for surgery?

Hb	13.5 g/dl
WCC	5.6 x10^9/l
PLT	190 x10^9/l
Na^+	139 mmol/l
K^+	4.5 mmol/l
Creatinine	120 µmol/l

Which of the following is likely to be most informative with respect to determining her suitability for surgery?

A Pulmonary function testing

B CT thorax

C PET/CT combined scan

D Serum calcium

E CT Head

C PET/CT combined scan

PET/CT combined scanning offers the best imaging modality to determine lymph node involvement in bronchial carcinoma. In this case, with a good functional status at the point of diagnosis, it's lymph node involvement which is likely to be the biggest determinant of the success or failure of surgical intervention.

A Pulmonary function testing

Of course, FEV_1 and FVC do have an impact on suitability for surgery, but given that we are told she cycles to work and aren't given information on her smoking status, it is likely that her lung function is adequate to undergo pneumonectomy.

B CT thorax

CT thorax is informative with respect to tumour staging, but won't deliver

CT thorax is informative with respect to tumour staging, but won't deliver adequate information with respect to lymph node involvement.

D	Serum calcium

A number of reasons for hypercalcaemia quite unconnected with bronchial carcinoma may be apparent – hence raised calcium *per se* would not represent a contraindication to surgery. PTHrp is also much less likely to be elevated in patients with an underlying adenocarcinoma versus other bronchial carcinomas.

E	CT Head

We are given no indication of cerebral metastases, meaning that CT head is of limited value here.

21214

Rate this question:

Next Question

This 66-year-old man presented with several months history of dyspnoea and chest pain which has not responded to inhalers or to medication for angina. He is a retired boilermaker, who smoked 40 cigarettes per day until 4 years ago. On examination his BP is 152/92, with pulse 80 and regular. There is wheeze on auscultation of the chest, and pitting oedema of both ankles.

His chest radiograph is shown below.

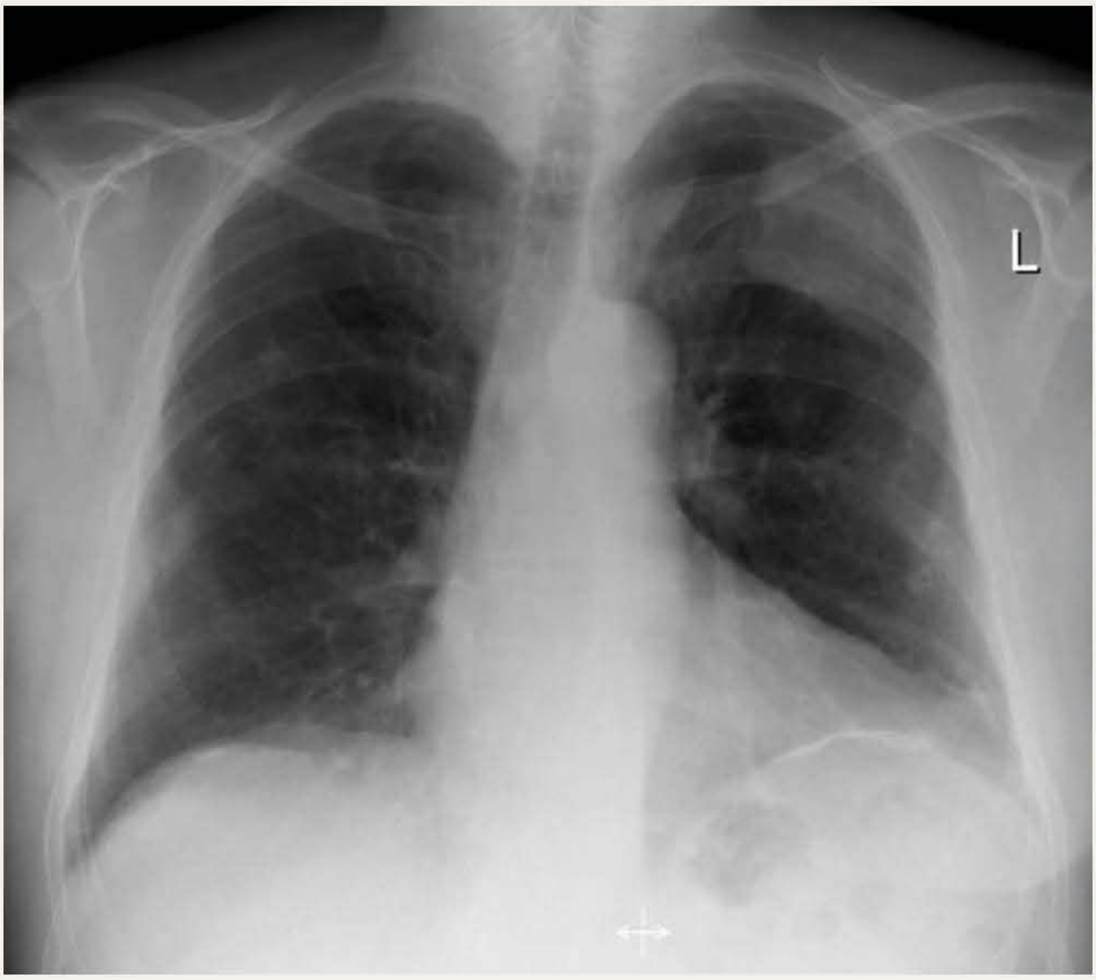

What is the most likely cause for the main abnormalities shown?

What is the most likely cause for the main abnormalities shown?

A	Cigarette smoking
B	Tuberculosis
C	Asbestos exposure
D	Silica exposure
E	Previous trauma

A 64-year-old man was referred to the clinic with insomnia. He complained of falling asleep during the day and having an early morning headache. He had a past history of a cholecystectomy and gout. He took no other regular medication. Examination was unremarkable.

Weight	115 kg
Height	175 cm
Hb	16.1 g/dl
WCC	6.4 $\times 10^9$/l
PLT	94 $\times 10^9$/l
MCV	101 fl
TSH	1.2 mU/l
Glucose	8.2 mmol/l

What would the optimal management of this patient be over the long term?

A Refer for non-invasive

WCC	6.4 x10⁹/l
PLT	94 x10⁹/l
MCV	101 fl
TSH	1.2 mU/l
Glucose	8.2 mmol/l

What would the optimal management of this patient be over the long term?

A	Refer for non-invasive ventilation
B	Diuretics
C	Advise to lose weight
D	Refer to ENT surgeons
E	Doxapram

7:45
tps://mypastest.pastest.com
10

A 64-year-old man was referred to the clinic with insomnia. He complained of falling asleep during the day and having an early morning headache. He had a past history of a cholecystectomy and gout. He took no other regular medication. Examination was unremarkable.

Weight	115 kg
Height	175 cm
Hb	16.1 g/dl
WCC	6.4 $\times 10^9$/l
PLT	94 $\times 10^9$/l
MCV	101 fl
TSH	1.2 mU/l
Glucose	8.2 mmol/l

C Advise to lose weight

This patient has obstructive sleep apnoea (OSA) – insomnia, daytime somnolence, morning headache and obesity. Other symptoms include poor concentration during the day and partners may describe snoring followed by apnoeic episodes.

Diagnosis is made using the Epworth score – which is a measure of daytime somnolence – and sleep studies, which would show apnoeic/hypopnoeic episodes associated with desaturations, increase in heart rate and arousal from sleep. Treatment will depend on severity of symptoms and desaturations. In most cases, weight loss is advisable.

In mild OSA syndrome, a mandibular advancement device may control symptoms in mild to severe OSA syndrome, such as nocturnal non-invasive ventilation (NIV) using continuous positive airway pressure (CPAP). Early morning headaches can be caused by a transient

(CPAP). Early morning headaches can be caused by a transient hypercapnia.This normally corrects to normal when the patient is awake. If a patient has hypercapnia in waking hours (and not just on an early morning blood gas) then overlap syndrome with obesity hypoventilation syndrome should be considered, although severe OSA may cause persistent hypercapnia in some cases. Patients with persistent hypercapnia should be considered for bi-level positive airway pressure (BiPAP).

It is important to exclude underlying causes – this patient has a history of gout which, together with the raised MCV and low platelets, suggests alcohol consumption, which can precipitate the problem. Hypothyroidism, acromegaly and sedating drugs also need to be excluded. Retrognathia can cause OSA and large tonsils may obstruct the airway.

A Refer for non-invasive ventilation

Although NIV is optimal for relief of symptoms, over the long term, given significant risk of type 2 diabetes and diseases associated with insulin resistance, weight loss is preferred long term.

B Diuretics

Diuretics would be an appropriate treatment for pulmonary oedema.

D Refer to ENT surgeons

Surgery is used as a last resort as a treatment for OSA and is often unsuccessful.

E Doxapram

Doxopram is a respiratory stimulant with a vast array of side effects previously used to treat acute type 2 respiratory failure. It has been superceded by non-invasive ventilation now.

A 73-year-old man is sent to the Emergency Department by ambulance after a GP home visit. The GP found him to be extremely short of breath, with a cough productive of rust-coloured sputum. He has herpetic lesions at the corner of his mouth.

On examination, he has right-sided crackles and bronchial breathing consistent with pneumonia. His blood pressure is 105/65 mmHg and respiratory rate 33. His abbreviated mental test (AMT) is 10.

Investigations:

Hb	119 g/l
WCC	13.9×10^9/l
PLT	203×10^9/l
Na+	137 mmol/l
K+	4.8 mmol/l
Creatinine	87 μmol/l
Urea	9.2 mmol/l

You use the British Thoracic Society

Urea	9.2 mmol/l

You use the British Thoracic Society Community Acquired Pneumonia Severity Score (CURB-65) criteria to assess the severity of infection with respect to the need for HDU/ITU.

Which of the following features is associated with a poor prognosis as identified by CURB criteria?

A	AMT score of 10
B	Urea 9.2 mmol/l
C	Systolic BP of 105 mmHg
D	Diastolic BP of 65 mmHg
E	Creatinine of 87 micromol/l

32432

Submit

B Urea 9.2 mmol/l

Urea is one of the variables assessed in the CURB criteria, where a level of >7 mmol/l is associated with a poor prognostic outcome. Other criteria not listed as part of the options here include age >65 and respiratory rate of 30/min or greater. A score of 3, as in this case, is associated with a risk of mortality of 17% from community-acquired pneumonia. For 5 this rises to a risk of mortality of 57%.

A AMT score of 10

Confusion with an AMT of 8 or less is associated with a poor prognosis in community-acquired pneumonia.

C Systolic BP of 105 mmHg

BP criteria used to assess severity in CURB criteria are systolic blood pressure 90 mmHg or less or a diastolic BP of 60 mmHg or less.

associated with a poor prognosis in community-acquired pneumonia.

C	Systolic BP of 105 mmHg

BP criteria used to assess severity in CURB criteria are systolic blood pressure 90 mmHg or less or a diastolic BP of 60 mmHg or less.

D	Diastolic BP of 65 mmHg

The diastolic BP criterion that stratifies poor prognosis in pneumonia is 60 mmHg.

E	Creatinine of 87 micromol/l

Creatinine is not a criterion used to assess prognosis under the CURB criteria.

32432

Rate this question:

Next Question

You are called to a cardiac arrest on the coronary care unit. A 74-year-old man with a 40-pack year smoking history and COPD on high-dose salmeterol/fluticasone combination inhaler has arrested two days after admission with an inferior myocardial infarction.

Arterial blood gasses on admission:

pH	7.39
pO_2	8.5 mmol/l
pCO_2	5.8 mmol/l
HCO_3^-	31 mmol/l

Arterial blood gasses on 35% O_2 post-cardiac arrest:

pH	7.29
pO_2	7.5 kPa
pCO_2	6.9 kPa

He responds appropriately to commands and is cooperative post his cardiac arrest. A portable chest X-ray

pCO_2	6.9 kPa

He responds appropriately to commands and is cooperative post his cardiac arrest. A portable chest X-ray shows no sign of resuscitation injury.

Which of the following is the most appropriate course of action with respect to his ventilatory support?

A	Continue 35% O_2 therapy
B	Reduce his inspired oxygen to 28%
C	Increase his inspired oxygen to 60%
D	Consider him for non-invasive positive pressure ventilation (NIPPV)
E	Move to intubation and ventilation

Arterial blood gasses on admission:

pH	7.39
pO_2	8.5 mmol/l
pCO_2	5.8 mmol/l
HCO_3^-	31 mmol/l

Arterial blood gasses on 35% O_2 post-cardiac arrest:

pH	7.29
pO_2	7.5 kPa
pCO_2	6.9 kPa

He responds appropriately to commands and is cooperative post his cardiac arrest. A portable chest X-ray shows no sign of resuscitation injury.

Which of the following is the most appropriate course of action with respect to his ventilatory support?

Your answer was correct

D Consider him for non-invasive positive pressure ventilation (NIPPV)

On admission his arterial blood gasses revealed a compensated respiratory acidosis with some degree of CO_2 retention. Post cardiac arrest he has decompensated with relative hypoxia and CO_2 retention. At this point the concern is that the acidosis may promote further respiratory weakness, driving CO_2 retention and worsening the pH further. NIPPV should reverse the respiratory acidosis and may have a positive impact on any pulmonary oedema associated with the MI.

A Continue 35% O_2 therapy

Continuing his 35% O_2 may further exacerbate CO_2 retention and lead to respiratory arrest, because of increasing drowsiness and lethargy.

B Reduce his inspired oxygen to 28%

28%

This risks worsening any hypoxia, which could exacerbate myocardial ischaemia leading to chest pain and/or rhythm disturbance.

C	Increase his inspired oxygen to 60%

This, like continuing 35% O_2, risks worsening respiratory acidosis without significantly increasing PaO_2 because of consequent respiratory muscle weakness and steadily decreasing consciousness.

E	Move to intubation and ventilation

This should be carefully considered based on pre-morbid status, and ideally would be a step only after NIPPV had not succeeded in maintaining oxygenation and reversing respiratory acidosis.

A 42-year-old publican is admitted with increasing shortness of breath which is relieved by lying flat. He has been seen on one previous occasion with a haematemesis, and admits to drinking 6–8 pints of strong lager per day. He also smokes 20 cigarettes per day. On examination he looks unwell; he has signs of chronic liver disease including clubbing, spider naevi, scratch marks, swollen ankles and ascites. He is tender in the right upper quadrant. Respiratory examination is suggestive of bilateral pleural effusions. His BP is 95/60 mmHg, and pulse is 100/min.

Investigations:

Hb	10.0 g/dl
WCC	5.6 $\times 10^9$/l
PLT	78 $\times 10^9$/l
Na^+	138 mmol/l
K^+	3.8 mmol/l
Creatinine	90 μmol/l

Creatinine	90 μmol/l
ALT	140 U/l
Bilirubin	110 μmol/l
Albumin	22 g/l
pO_2	7.9 kPa
pCO_2	3.9 kPa

Which of the following is the most likely diagnosis?

A Pulmonary embolus

B Cardiac failure

C Hepatopulmonary syndrome

D Chronic obstructive pulmonary disease (COPD)

E Pulmonary fibrosis

C Hepatopulmonary syndrome

Given the history of significant liver disease, a link between this and his chest pathology, hepatopulmonary syndrome is more likely than a pulmonary embolus. Equally, there are no signs suggestive of either COPD or pulmonary fibrosis. Hepatopulmonary syndrome is due to arteriovenous shunting and is potentially progressive and life-threatening. It is associated with gross dilatation of pulmonary pre-capillary and capillary vessels; hypoxia may be exacerbated by sitting upright because of preferential perfusion of lung bases (with poor ventilation of these areas in the upright position). Lung bases are better ventilated when the patient lies flat. Hypoxia may be further worsened by the presence of significant pleural effusions. Nitric oxide is thought to play a role in the condition, largely as a result of studies in rodent models, although this is yet to be confirmed in human studies. The syndrome may be corrected by liver transplantation, and is adequate

syndrome may be corrected by liver transplantation, and is adequate reason for expedited referral. Platypnoea is related to this abnormal pulmonary vasodilation, which leads to inappropriate shunting. Bubbles can be seen appearing late in the left atrium when agitated saline is injected, and the atrium is observed on echocardiography.

A Pulmonary embolus

Although hypoxia and shortness of breath could be associated with pulmonary embolism, it's less likely given decreased hepatic synthetic function and likely abnormal clotting, coupled with obvious decompensated cirrhosis, meaning hepatopulmonary syndrome is a much more obvious cause.

B Cardiac failure

Significant left ventricular failure is more likely to be associated with type 2 respiratory failure rather than the low

B	Cardiac failure

Significant left ventricular failure is more likely to be associated with type 2 respiratory failure rather than the low CO_2 seen here.

D	Chronic obstructive pulmonary disease (COPD)

Bilateral pleural effusions would not fit with a diagnosis of COPD, and chronic COPD would usually be associated with an elevated bicarbonate because of metabolic compensation, not seen here.

E	Pulmonary fibrosis

Pulmonary fibrosis is associated with crackles on auscultation, and not with the pleural effusions seen here. Shortness of breath would also not be improved by lying flat.

20999

Rate this question:

This 66-year-old man presented with several months history of dyspnoea and chest pain which has not responded to inhalers or to medication for angina. He is a retired boilermaker, who smoked 40 cigarettes per day until 4 years ago. On examination his BP is 152/92, with pulse 80 and regular. There is wheeze on auscultation of the chest, and pitting oedema of both ankles.

His chest radiograph is shown below.

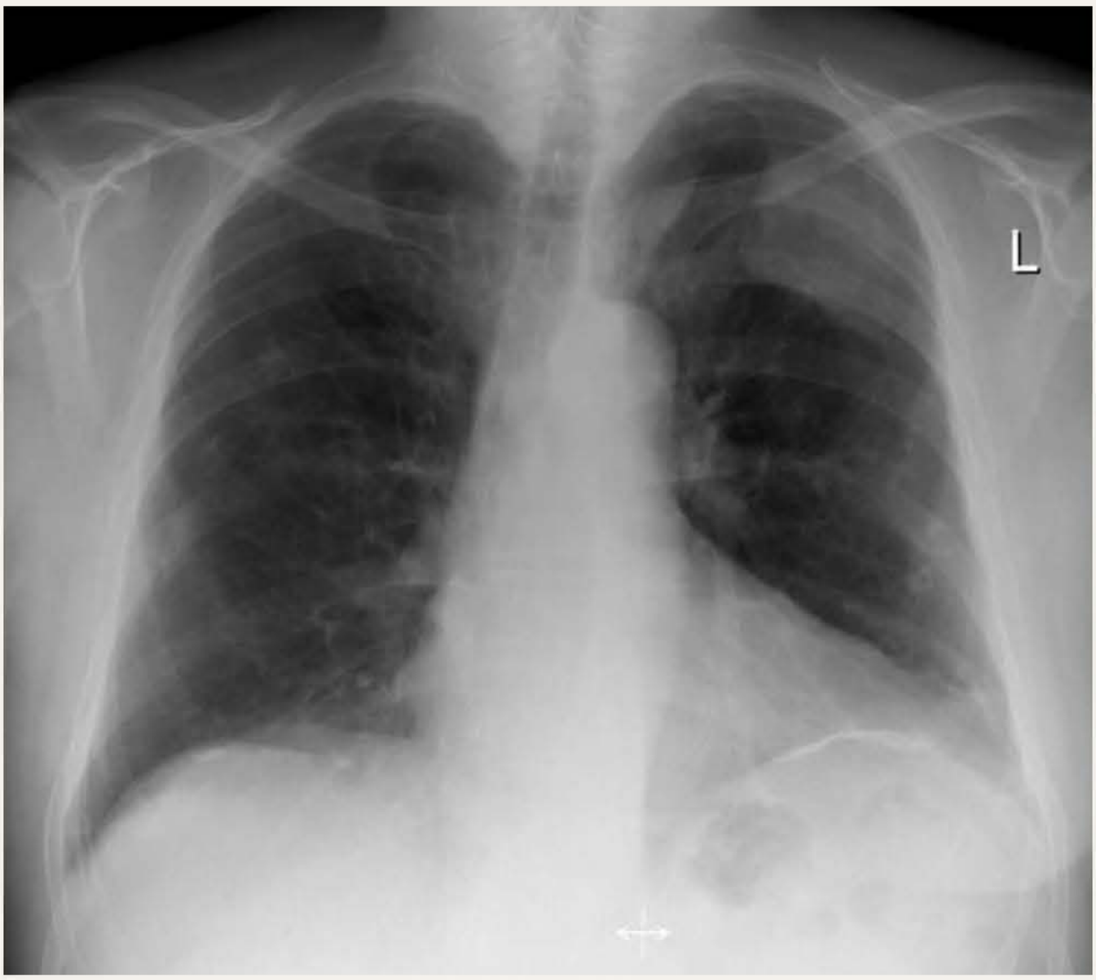

What is the most likely cause for the main abnormalities shown?

What is the most likely cause for the main abnormalities shown?

A	Cigarette smoking
B	Tuberculosis
C	Asbestos exposure
D	Silica exposure
E	Previous trauma

9151

Submit

C Asbestos exposure

The chest radiograph shows a mesothelioma at the left apex which is invading the underlying rib. There are also calcified pleural plaques on the surface of both hemi-diaphragms. These appearances are consistent with asbestos exposure. Extensive occupational history is essential to establish any entitlement to compensation, as mesothelioma can develop up to 40 years after the initial exposure (often presenting with a unilateral pleural effusion). It is rarely suitable for surgical resection and is not responsive to chemotherapy. Palliative radiotherapy may be indicated. The prognosis is extremely poor, with an average survival of 1–2 years from diagnosis.

A Cigarette smoking

Cigarette smoking could not account for the mesothelioma seen in the left upper zone on CXR, nor the calcified

8:10
tps://mypastest.pastest.com
10

the chest, and pitting
ankles.

graph is shown below.

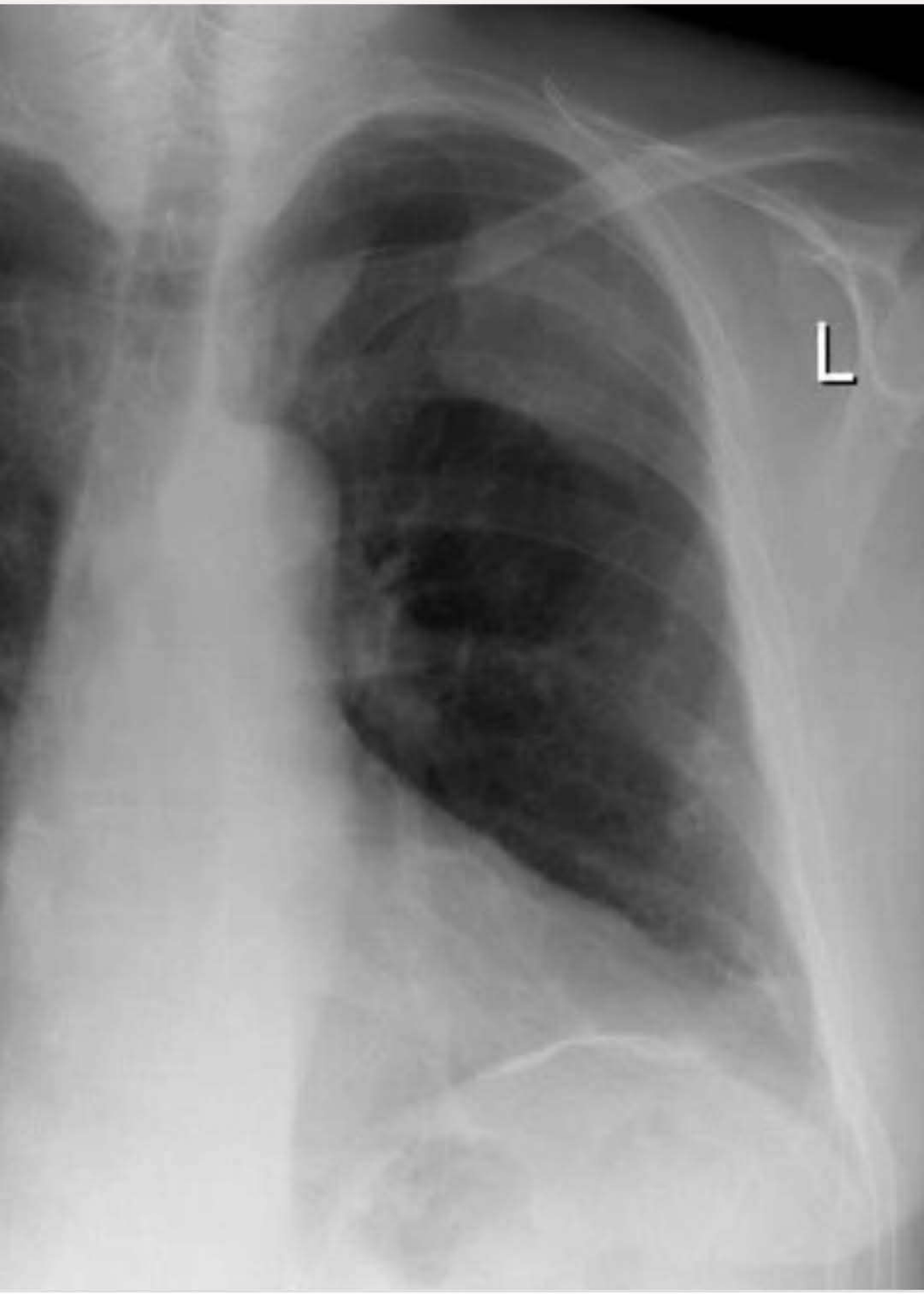

An 18-year-old patient of short stature presents with fevers, thick nasal mucus and frontal headache. He is found to have bilateral crackles and clubbing of his fingers. He also gives a past history of chronic diarrhoea and has long-term problems with maintaining his weight.

Which of the following results is most closely related to the underlying diagnosis?

A	Hypercalcaemia
B	Eosinophilia
C	A high number of macrophages on bronchoalveolar lavage
D	A forced expiratory volume in 1 second (FEV_1) that improves > 12% following administration of salbutamol
E	Inadequate pancreatic exocrine function

An 18-year-old patient of short stature presents with fevers, thick nasal mucus and frontal headache. He is found to have bilateral crackles and clubbing of his fingers. He also gives a past history of chronic diarrhoea and has long-term problems with maintaining his weight.

Which of the following results is most closely related to the underlying diagnosis?

Your answer was correct

A	Hypercalcaemia
B	Eosinophilia
C	A high number of macrophages on bronchoalveolar lavage
D	A forced expiratory volume in 1 second (FEV_1) that improves > 12% following administration of salbutamol

E Inadequate pancreatic exocrine function

Cystic fibrosis gene mutation leads to defective chloride secretion and increased sodium absorption across the airway epithelium, which can result in bronchiectasis and deficient pancreatic exocrine function.

A Hypercalcaemia

The constellation of clinical signs is in keeping with a diagnosis of cystic fibrosis. A raised calcium level could be associated with a number of conditions (such as sarcoidosis, hyperparathyroidism, Paget's disease and bone metastases), none of which would be consistent with the above findings.

B Eosinophilia

Multiple conditions may lead to a state of eosinophilia. Common causes include allergic conditions such as hay

include allergic conditions such as hay fever and asthma, as well as hypersensitivity due to medications. Eosinophilia may also be indicative of allergic bronchopulmonary aspergillosis (ABPA), which would, however, not lead to clubbing.

C	A high number of macrophages on bronchoalveolar lavage

A high number of macrophages are often seen in smokers' lungs and are considered to be a non-specific finding.

D	A forced expiratory volume in 1 second (FEV_1) that improves > 12% following administration of salbutamol

A forced expiratory volume in 1 second (FEV_1) that improves > 12% following administration of salbutamol (Option D) is incorrect.

On spirometry, reversible FEV_1 values

8:15
tps://mypastest.pastest.com
10

A 69-year-old man was taken to the Emergency Department with a reduced GCS score; no history was available from Accident & Emergency for the patient. The ambulance crew said that the call was put out by his wife as he had become increasingly short of breath. When they arrived he looked breathless and cyanosed. He denied any chest pain at that time.

On examination, he had a GCS score of 13, respiratory rate 10/min, BP 130/70 mmHg, pulse 120/min, temperature 36.9 °C, SaO_2 94% on 15 l oxygen. Auscultation of the chest revealed an expiratory wheeze throughout.

Heart sounds were normal and abdominal examination unremarkable. There was no obvious focal neurological abnormality and both plantars showed a flexor response.

Investigations:

Hb	17.3 g/dl

Investigations:

Hb	17.3 g/dl
WCC	8.2×10^9/l
PLT	400×10^9/l
MCV	84 fl
CRP	21 mg/l
ECG	Sinus tachycardia
CXR	Hyperinflated lung fields with low, flattened diaphragm; no evidence of a pneumothorax
Renal function & liver tests	Unremarkable

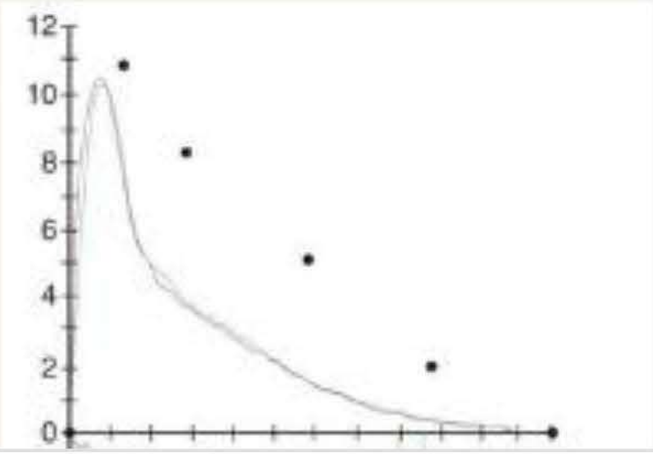

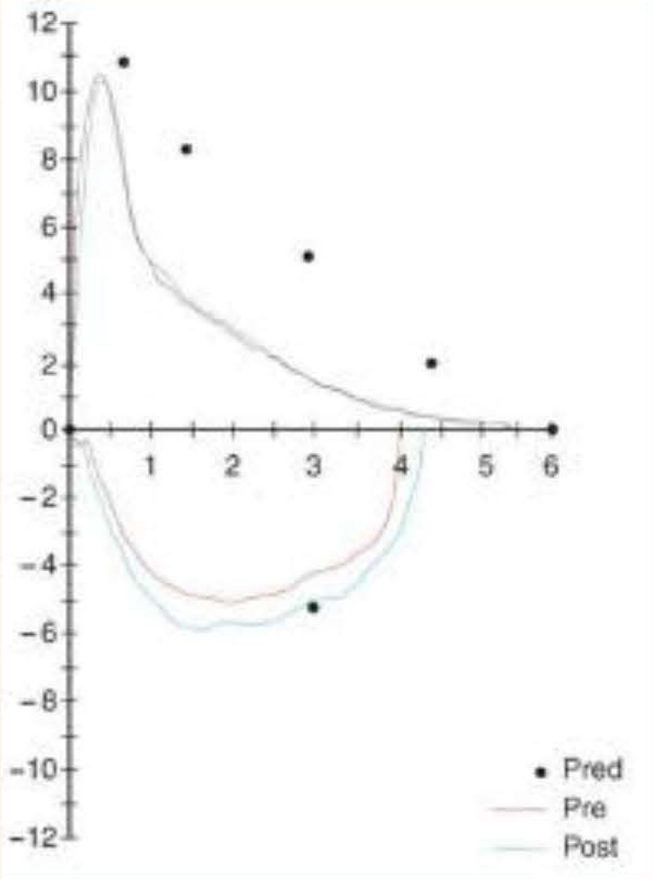

ABGs on high-flow oxygen on this admission:	
pH	7.29
PCO_2	10.91 kPa
PO_2	12.39 kPa
Bicarbonate	40.6 mmol/l
Base excess	10.4

What is the most appropriate next

PO_2	12.39 kPa
Bicarbonate	40.6 mmol/l
Base excess	10.4

What is the most appropriate next step in the management of this patient?

A	Intubation and invasive ventilation
B	Start non-invasive ventilation
C	Hydrocortisone 100 mg IV
D	Salbutamol 2.5 mg via nebuliser
E	Reduce inspired oxygen concentration to 28% and repeat ABG

E Reduce inspired oxygen concentration to 28% and repeat ABG

This patient has an acute on chronic respiratory acidosis. The high bicarbonate and base excess shows that there is an underlying chronic respiratory acidosis with renal compensation. The acidosis and high CO_2 indicate an acute respiratory acidosis. If this was acute without a chronic element then, for a PCO_2 of 10.91 one would expect the pH to be lower.

This question is about oxygen therapy in COPD. The diagnosis of COPD is suggested from the CXR and flow-volume curve, which shows the classic shape for COPD. In some patients with COPD, CO2 retention is more prevalent. Two reasons are now thought to underlie this, 1) there is greater v/q mismatch in COPD, and secondly, the Haldane effect, a shift in the CO2 dissociation curve occurs.

The immediate management on arrival

The immediate management on arrival in the Emergency Department is to reduce the inspired oxygen concentration and repeat the arterial blood gases. If by doing this the patient becomes hypoxic or remains acidotic, they should then be referred for non-invasive ventilation.

National Collaborating Centre for Chronic Conditions. 2004. Chronic obstructive pulmonary disease. National clinical guideline on management of chronic obstructive pulmonary disease in adults in primary and secondary care.Thorax, 59 (suppl 1), 1-232

A	Intubation and invasive ventilation

An anaesthetic opinion would be warranted for consideration of intubation if he did not respond to controlled oxygen ± a trial of NIV, but it does not represent the optimal next step for this patient.

B	Start non-invasive ventilation

Non-invasive ventilation (NIV) would be appropriate if controlled oxygen therapy and medical therapies did not result in clinical improvement including resolution of acidosis, but does not represent the optimal next step for this patient.

C	Hydrocortisone 100 mg IV

While NICE recommend corticosteroids (prednisolone orally for a maximum of 7-14 days) for patients without contraindications who present to hospital with an exacerbation of COPD, in this case the patient has become obtunded due to excessive oxygen therapy. Corticosteroids may play a role in his medical management, but the optimal next step is to provide controlled oxygen therapy.

D	Salbutamol 2.5 mg via nebuliser

Radiopaedia

Chronic obstructive pulmonary disease | Radiology Case ...

1 article features images from this case. Chronic obstructive pulmonary disease

Images may be subject to copyright. Learn More

RELATED IMAGES SEE MORE



A 42-year-old man presented with massive haemoptysis.

He smokes 20 cigarettes per day and admits to a chronic cough with night sweats and gradual weight loss over the past 6–9 months.

He has not consulted medical services as he is currently homeless.

His chest X-ray is shown below:

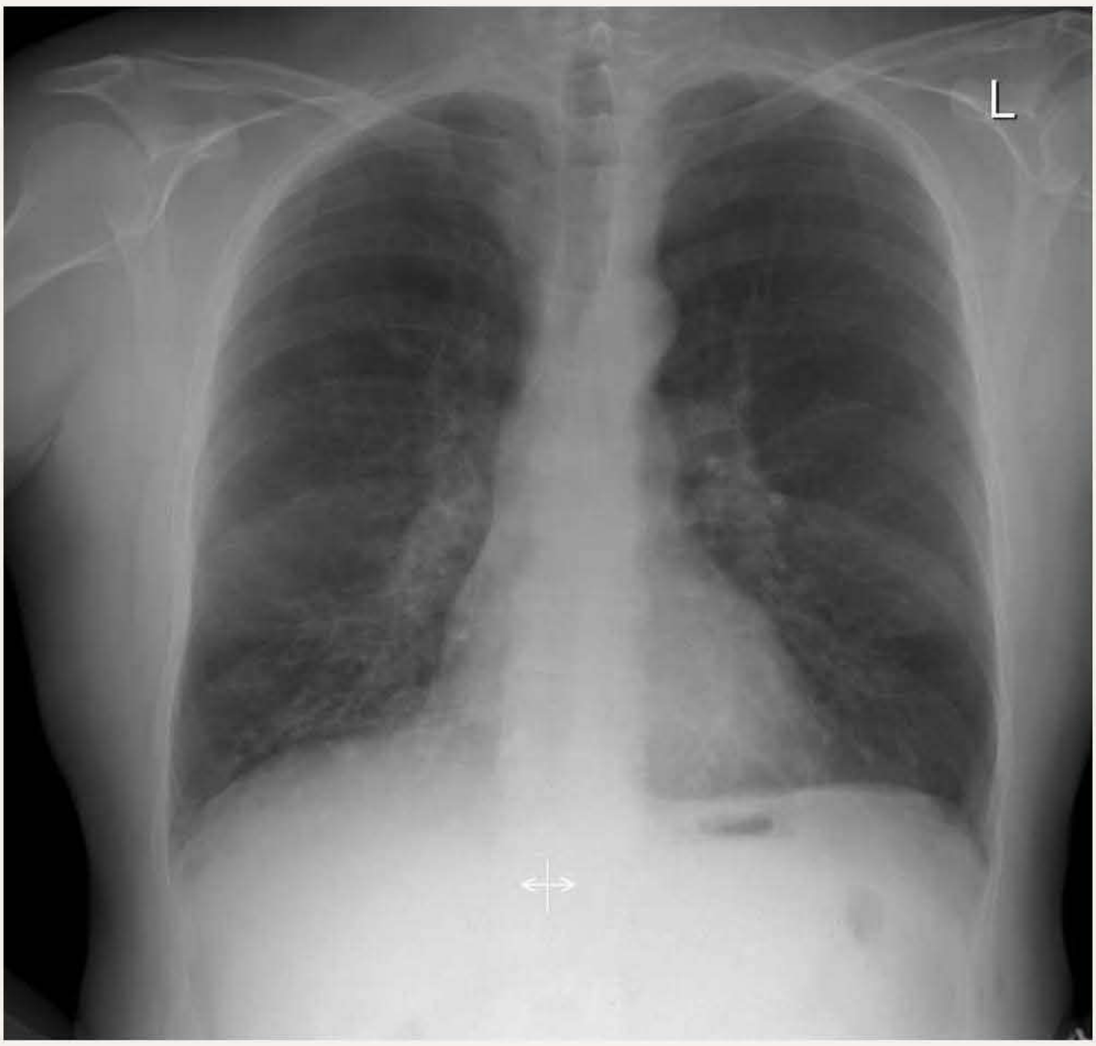

What is the underlying cause for the haemoptysis?

What is the underlying cause for the haemoptysis?

A	Granulomatosis with polyangitis
B	Pulmonary tuberculosis
C	Aspergilloma
D	Bronchiectasis
E	Anti-GBM disease

9149

Submit

currently homeless.

t X-ray is shown below:

the underlying cause for t
tysis?

D Bronchiectasis

The chest X-ray shows the typical appearance of bronchiectasis, with dilated, thickened, oedematous bronchial walls (tramline and ring shadows: see expanded radiograph below). Sometimes multiple, fluid-filled cysts are also seen. Surgery for partial lung resection is usually avoided in bronchiectasis, but might be considered where there is massive haemoptysis and localised infection. Other causes of massive haemoptysis include bronchial carcinoma, TB and cavitating lung lesions (e.g. aspergilloma).

B Pulmonary tuberculosis

In tuberculosis, evidence of upper zone fibrosis with potential calcification and hilar lymphadenopathy would be expected.

A Granulomatosis with polyangitis

expected.

A	Granulomatosis with polyangitis

This is associated with patchy interstitial shadowing rather than the features of bronchiectasis seen here.

C	Aspergilloma

Aspergillomas are ball-shaped lesions which occur within an old cavity, usually from previous tuberculosis infection.

E	Anti-GBM disease

Like granulomatosis with polyangitis, this is associated with pulmonary haemorrhage and consequent patchy interstitial shadowing on CXR.

9149

Rate this question:

Next Question

8:53
tps://mypastest.pastest.com
10

s the underlying cause for th
ptysis?

nswer was incorrect

8:58
https://www.google.com/sea
10

RING SHADOWS

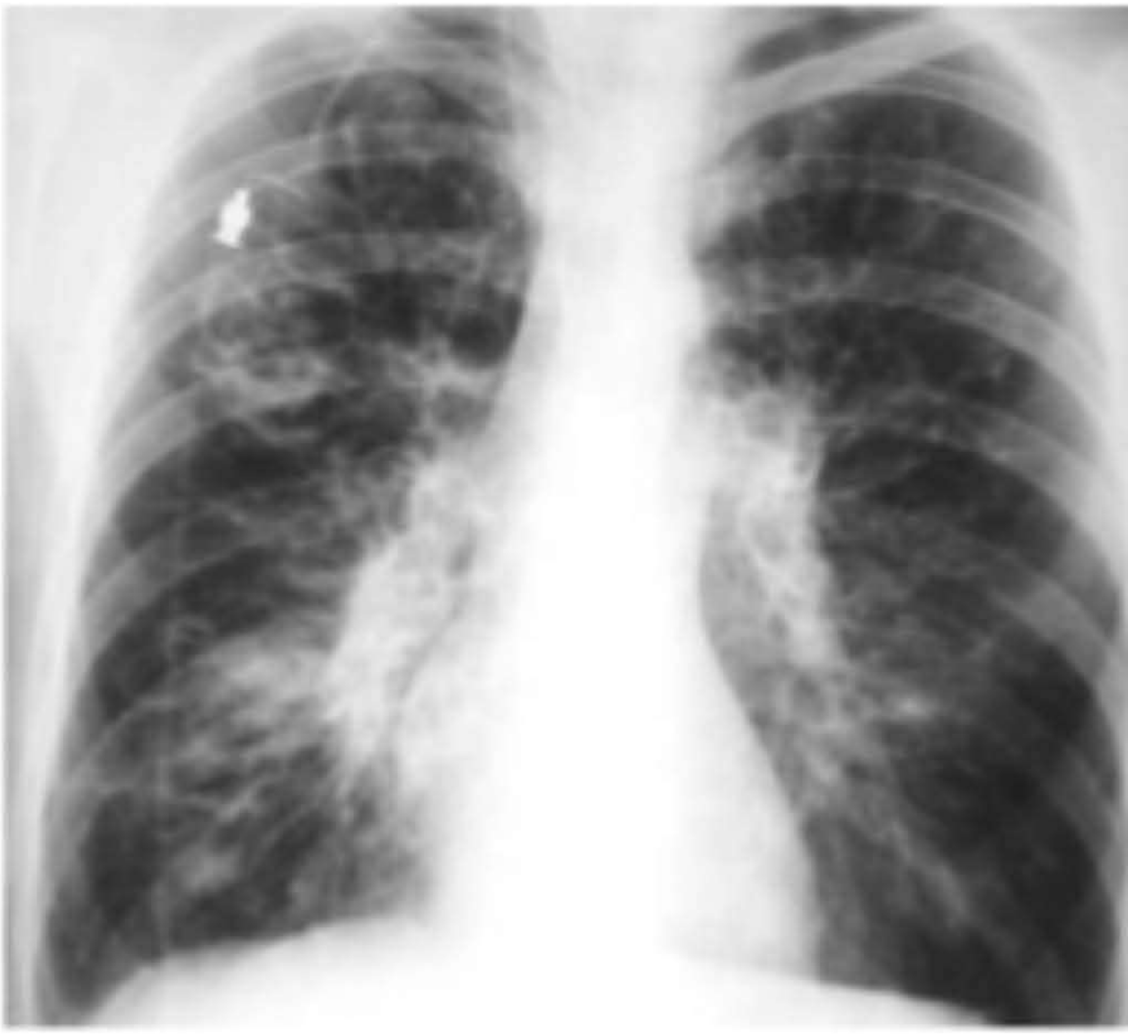

Product
Radiographic signs in bronchi...
slideshare.net
Radiographic signs
• Silhouette sign: opacity near the heart so you can not detect the heart boarder easily.
• Notes from the radiographs: opacity frontal and
RADIOLOGY - CXR Bronchiect...
slideplayer.com
Radiological features of

A 39-year-old Irish accountant was referred to the clinic with a 4-month history of progressive breathlessness. He noticed this mainly on climbing the stairs. Over the last few months, he had been using some eye drops from the local pharmacy for dry eyes. He was also complaining of fatigue, night sweats and polyuria. He was a non-smoker and drank 20 units of alcohol a week.

On examination, he had conjunctival injection, but examination of his eyes was otherwise unremarkable. He had no rash or joint swelling. On auscultation of his chest, he had fine inspiratory crackles. Heart sounds were normal. He had no organomegaly on palpation of the abdomen. Urinalysis was unremarkable.

Investigations:

Hb	10.1 g/dl
WCC	6.4×10^9/l
PLT	201×10^9/l
Na^+	141 mmol/l

Na^+	141 mmol/l
K^+	3.9 mmol/l
Creatinine	100 micromol/l
MCV	84 fl
ESR	45 mm/1st h
Urea	7.2 mmol/l
Bilirubin	23 µmol/l
AST	51 U/l
ALP	191 U/l
Albumin	45 g/l
TB test	-
Pulmonary function tests:	
FEV_1	75% predicted
FVC	70% predicted
	80%

His chest X-ray is shown below:

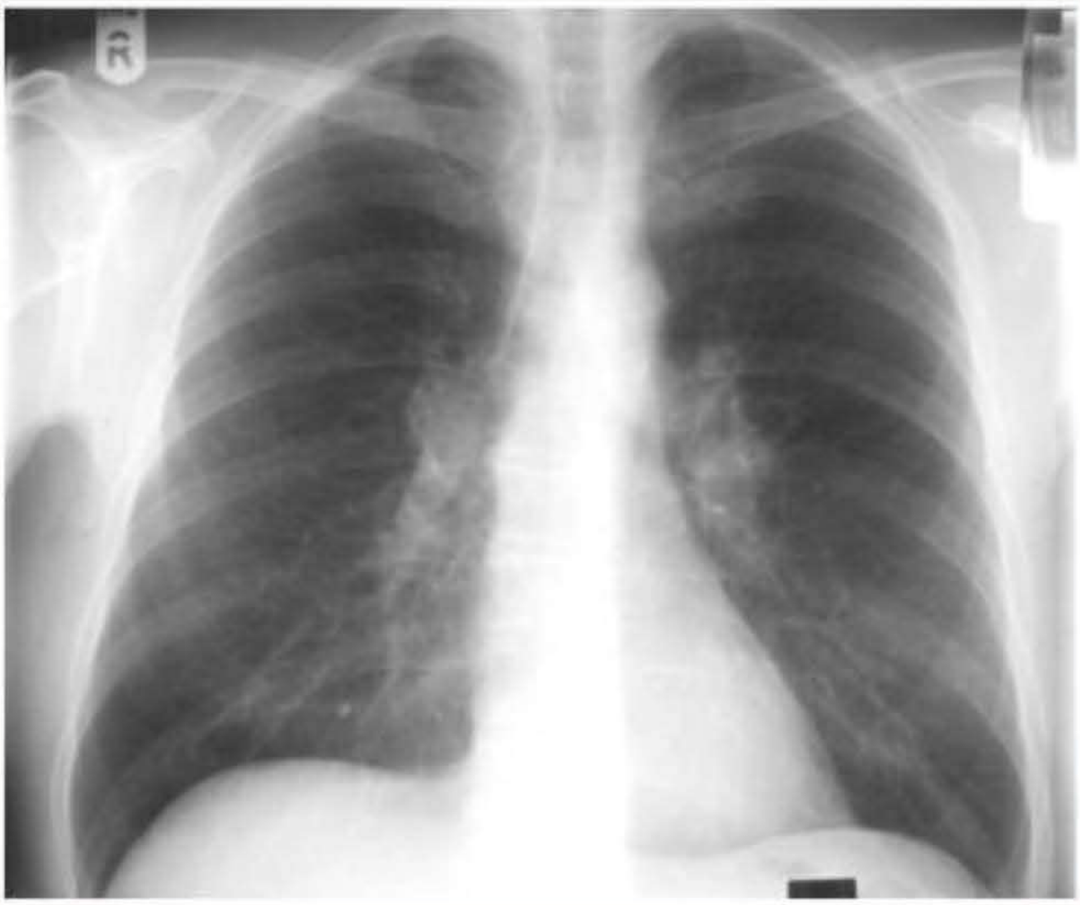

What is the most likely diagnosis?

A	Tuberculosis
B	Berylliosis
C	Small cell lung carcinoma
D	Sarcoidosis
E	Langerhans cell histiocytosis

D Sarcoidosis

The most likely diagnosis is sarcoidosis. This is a relatively young patient with breathlessness, dry eyes, fatigue, night sweats and polyuria. He has a normocytic anaemia, a raised ESR and slightly deranged liver function tests.

Sarcoid is a multi-system granulomatous disorder of unknown aetiology, with a number of different presentations. It usually presents in those under 40, and is more common in women and persons of West Indian and African descent. Presentation may be with erythema nodosum, bilateral hilar lymphadenopathy on chest radiography with fever or arthralgia (Löfgren syndrome), or more insidiously with symptoms such as dyspnoea, dry cough, fever, malaise and weight loss. The main differential diagnoses are TB and lymphoma.

The diagnosis is suggested from a chest X-ray and high-resolution CT. High-resolution CT characteristically shows features such as hilar and

mediastinal lymphadenopathy, peribronchovascular nodules, ground-glass shadowing, parenchymal bands, cysts and fibrosis.

Pulmonary involvement can be classified according to the radiographic stage of the disease as below:

Stage 0: Clear chest radiograph
Stage 1: Bihilar adenopathy
Stage 2: Bihilar adenopathy and interstitial infiltrates
Stage 3: Diffuse interstitial disease
Stage 4: Advanced fibrosis.

Transbronchial biopsy is the investigation with the highest yield, as positive results are seen in 90% of patients with pulmonary sarcoidosis. Endobronchial biopsies are also useful but less sensitive. Histology typically shows non-caseating granulomas composed of macrophages, lymphocytes and epithelioid histiocytes, which fuse to form multinucleate giant cells.

Serum ACE is not specific, as raised levels are also seen in pulmonary TB

asbestosis, silicosis and lymphoma. It is elevated in about 75% of patients with untreated sarcoid. The value of using serum ACE to monitor disease activity remains unclear.

24 h urinary calcium excretion is often raised.

The lung function tests depend on severity of the disease. The tuberculin test is negative in 80% of patients with sarcoidosis, but clinicians must be mindful that anergy can also be seen in HIV-positive patients or patients who have overwhelming TB.

Treatment is rarely required in stage 0 or 1 disease. Corticosteroids should be given to patients with stage 2 or higher disease with deterioration in lung function, or patients with ocular sarcoid, hypercalcaemia, severe or persistent erythema nodosum, or myocardial and neurological manifestations of sarcoidosis. Prednisolone dose is 0.5 mg/kg for the first four weeks of treatment and is then down-titrated to the lowest maintenance dose that controls the

maintenance dose that controls the disease. Treatment withdrawal should be considered after 6–24 months. Steroid-sparing agents such as methotrexate or azathioprine may be used for relapsing disease.

Common clinical characteristics of sarcoidosis include:

- Skin:
  Erythema nodosum – caution, not always on the shins
  Lupus pernio – red crusty lesions, often around the nose
  Annular lesions
- Polyuria:
  Secondary to hypercalciuria/hypercalcaemia (can also cause renal calculi and nephrocalcinosis)
  Secondary to central diabetes insipidus
- Cardiac:
  Ventricular arrhythmias
  Conduction defects
  Cardiomyopathy

Congestive cardiac failure

- Neurological:
  Involvement of CNS occurs in 2%
  Cranial diabetes insipidus
- Ocular:
  Anterior uveitis
  Conjunctivitis
  Retinal lesions
  Keratoconjunctivitis sicca and lacrimal gland enlargement
  Optic neuritis
- Metabolic:
  Hypercalcaemia and hypercalciuria
- Bone and joints:
  Arthralgia
  Bone cysts
- Others:
  Hepatosplenomegaly
  Löfgren syndrome (acute sarcodosis) – triad of bihilar lymphadenopathy, arthritis and erythema nodosum.

B Berylliosis

There is no history suggestive of beryllium exposure, and bilateral hilar lymphadenopathy is not a feature of berylliosis.

A Tuberculosis

We are not given a history of contact with TB, nor a history of fevers. Inflammatory markers are normal, and tuberculin test is negative (with no history to suggest immunosuppression).

C Small cell lung carcinoma

The patient is young and is a non-smoker, making SCLC a less likely diagnosis. The chest radiograph does not show any lung lesion suggestive of a lung malignancy; it shows bilateral lymphadenopathy and diffuse interstitial infiltrates.

A 90-year-old man was referred to the clinic with a history of progressive shortness of breath and dry cough. Eighteen months ago he was able to complete a full round of golf. He has now stopped playing as he is breathless after walking 200 m. He had been a heavy smoker all his life. He has no known asbestos exposure. On examination he is breathless at rest. He has a photosensitive rash on his face and neck. He is clubbed. His pulse is irregularly irregular. Auscultation of his chest reveals fine inspiratory crackles bi-basally.

Investigations:

Hb	12.1 g/dl
WCC	9.2×10^9/l
Neutrophils	6.1×10^9/l
PLT	203×10^9/l
TSH	7.1 mU/l

Blood gases on 30% oxygen:

pH	7.46
PCO_2	4.68 kPa
PO_2	8.8 kPa
Bicarbonate	25.4 mmol/l

His CXR is shown below:

Spirometry:

FEV_1	1.1 L (predicted 2.0 – 2.4 L)
FVC	2.0 L (predicted 3.2 – 3.8 L)
KCO	74% predicted



Spirometry:

FEV_1	1.1 L (predicted 2.0 – 2.4 L)
FVC	2.0 L (predicted 3.2 – 3.8 L)
KCO	74% predicted

What is the likely cause of his breathlessness?

A	Bronchial alveolar carcinoma
B	Interstitial lung disease
C	COPD
D	Lymphangioleiomyomatosis
E	Pulmonary oedema

9:11
:tps://mypastest.pastest.com

pirometry:

FEV_1	1.1 L (predicted 2.0 –
FVC	2.0 L (predicted 3.2 –
KCO	74% predicted

A 90-year-old man was referred to the clinic with a history of progressive shortness of breath and dry cough. Eighteen months ago he was able to complete a full round of golf. He has now stopped playing as he is breathless after walking 200 m. He had been a heavy smoker all his life. He has no known asbestos exposure. On examination he is breathless at rest. He has a photosensitive rash on his face and neck. He is clubbed. His pulse is irregularly irregular. Auscultation of his chest reveals fine inspiratory crackles bi-basally.

Investigations:

Hb	12.1 g/dl
WCC	9.2×10^9/l
Neutrophils	6.1×10^9/l
PLT	203×10^9/l
TSH	7.1 mU/l

Blood gases on 30% oxygen:

B Interstitial lung disease

This man has interstitial lung disease – gradual onset of shortness breath and dry cough. He is clubbed and has fine inspiratory crackles. Lung function tests show a mixed restrictive / obstructive picture and he has type I respiratory failure. Chest radiograph shows small lung fields and reticular nodular shadowing.

The patient has a photosensitive rash on his face, atrial fibrillation and abnormal thyroid function, suggesting that he is on amiodarone. Interstitial lung disease is an important side effect of long-term amiodarone administration. Pulmonary fibrosis is a known side effect of several other drugs, including beta blockers, nirofurantoin and methotrexate.

Diagnosis is made by a combination of clinical findings, lung function tests, CXR, BAL and high-resolution CT. It is confirmed with a VATS or an open lung biopsy in patients fit to undergo the procedure.

If there was no obvious cause for the interstitial lung disease and radiology and biopsy histology were consistent with usual interstitial pneumonia, then idiopathic pulmonary fibrosis would be the most likely diagnosis.

Interstitial lung disease is an important side effect of long-term amiodarone administration.

Other side effects of amiodarone include:

- Hyper- and hypothyroidism
- Peripheral sensory neuropathy
- Hepatitis
- Photosensitivity
- Ataxia
- Corneal microdeposits (reversible)
- Metallic taste
- Arrhythmias (torsade de pointes).

Drugs causing interstitial lung disease:

- Antibiotics – nitrofurantoin
- Cardiovascular – amiodarone, beta-blockers
- Chemotherapeutic – bleomycin, busulfan, cyclophosphamide, carmustine, lomustine, methotrexate, melphalan, mitomycin C, nitrosureas, sulfasalazine, 5-fluorouracil (5FU)
- Drugs used to treat rheumatoid arthritis – sulfasalazine, penicillamine, cyclophosphamide, methotrexate, gold
- Drugs used to treat migraine – ergotamine, ergots, methysergide
- Others:
  bromocriptine
  radiation
  dothiepin
  pesticides
  high-flow oxygen.

Causes of lower interstitial lung disease:

- Drugs
- Connective tissue disease
- Asbestosis
- Idiopathic pulmonary fibrosis.

E	Pulmonary oedema

This is a reasonable differential diagnosis based on the history, but the chest radiograph shows interstitial lung disease, not pulmonary oedema.

A	Bronchial alveolar carcinoma

The duration of symptoms is too long for bronchoalveolar cell carcinoma, and this is usually associated with a productive cough with frothy sputum. The chest radiograph shows interstitial lung disease.

C	COPD

9:18
:tps://mypastest.pastest.com

You are seeing a patient on the surgical wards as a medical referral. He has had a lymph node dissected from his neck for possible recurrent head and neck cancer. On his postoperative chest X-ray, he has a moderate pleural effusion, which on aspiration drains white, milky fluid.

What is the likely diagnosis of the cause of the effusion?

A	Empyema
B	Mesothelioma
C	Chylous effusion
D	Reactive effusion
E	Malignant effusion

surgical wards as a medical referral. He has had a lymph node dissected from his neck for possible recurrent head and neck cancer. On his postoperative chest X-ray, he has a moderate pleural effusion, which on aspiration drains white, milky fluid.

What is the likely diagnosis of the cause of the effusion?

Your answer was correct

A	Empyema
B	Mesothelioma
C	Chylous effusion
D	Reactive effusion
E	Malignant effusion

Explanation

C Chylous effusion

A chylous effusion is suggested by the white milky fluid aspirated on thoracocentesis. Cardiothoracic and head or neck surgery, including excision of cervical lymph nodes, can result in damage to the thoracic duct resulting in a chylothorax. To confirm the diagnosis, test for pleural fluid triglycerides and cholesterol levels.

A Empyema

Aspiration of frankly purulent fluid would indicate an empyema.

B Mesothelioma

Though mesothelioma can present with a pleural effusion alone, the history in this case is not suggestive of this diagnosis.

D Reactive effusion

Though mesothelioma can present with a pleural effusion alone, the history in this case is not suggestive of this diagnosis.

D Reactive effusion

You would not aspirate white, milky fluid in a reactive effusion. The fluid may be cloudy or even slightly clear. Reactive effusions are principally lymphocytic infiltrates secondary to the movement of interstitial fluid. The underlying aetiology is varied, and includes congestive heart failure and collagen vascular disease.

E Malignant effusion

Malignant effusions can present as either serous or serosanginous fluid.

7179

Rate this question:

Next Question

A man with a history of COPD who is on home oxygen therapy is admitted to hospital with central chest pain. He suffers a cardiac arrest in the Emergency Department and is resuscitated for 23 min before return of spontaneous circulation. During resuscitation he was intubated, and he is now able to achieve adequate minute ventilation with minimal pressure support. His BP is 96/50 mmHg, HR 80, RR16, SpO_2 98% with an F_iO_2 of 0.6. Arterial blood gases are taken 3 min after ROSC.

Which of the following results are most likely to be shown on arterial blood gas analysis?

A	pH 7.45 P_aO_2 7.9 kPa P_aCO_2 3.1 HCO_3^- 31 mmol/l
B	pH 7.30 P_aO_2 7.9 kPa P_aCO_2 4.2 HCO_3^- 12 mmol/l
C	pH 7.15 P_aO_2 12.2 kPa P_aCO_2 4.3 HCO_3^- 17 mmol/l

pressure support. His BP is 90/60 mmHg, HR 80, RR16, SpO_2 98% with an F_iO_2 of 0.6. Arterial blood gases are taken 3 min after ROSC.

Which of the following results are most likely to be shown on arterial blood gas analysis?

A	pH 7.45 P_aO_2 7.9 kPa P_aCO_2 3.1 HCO_3^- 31 mmol/l
B	pH 7.30 P_aO_2 7.9 kPa P_aCO_2 4.2 HCO_3^- 12 mmol/l
C	pH 7.15 P_aO_2 12.2 kPa P_aCO_2 4.3 HCO_3^- 17 mmol/l
D	pH 7.55 P_aO_2 12.2 kPa P_aCO_2 4.3 HCO_3^- 31 mmol/l
E	pH 7.10 P_aO_2 7.9 kPa P_aCO_2 4.3 HCO_3^- 12 mmol/l

C | pH 7.15 P_aO_2 12.2 kPa P_aCO_2 4.3 HCO_3^- 17 mmol/l

This man has COPD requiring home oxygen. As such, he is likely to have chronic CO_2 retention and will consequently have significant renal compensation and an elevated serum bicarbonate. Given that he has suffered a significant period of cardiac arrest, it is also likely that he will have significant tissue hypoxia, leading to a build-up of products of metabolism such as lactate. This leads to the decreased pH. In patients who have suffered a cardiac arrest there is usually a significant metabolic acidosis with a low bicarbonate level. However, due to pre-existing renal compensation, the bicarbonate in this patient will not be as low as if there was no previous renal compensation. In the absence of previous renal compensation, a bicarbonate of the levels seen in B) or E), would be expected. The pressure support on the ventilator allows him to achieve adequate gas exchange.

A pH 7.45 P_aO_2 7.9 kPa P_aCO_2 3.1 HCO_3^- 31 mmol/l

In post-arrest patients we expect to see a metabolic acidosis.

B pH 7.30 P_aO_2 7.9 kPa P_aCO_2 4.2 HCO_3^- 12 mmol/l

The degree of acidaemia in this patient is likely to be worse, but the bicarbonate is likely to be higher due to previous renal compensation.

D pH 7.55 P_aO_2 12.2 kPa P_aCO_2 4.3 HCO_3^- 31 mmol/l

A metabolic alkalosis is not realistic in this scenario.

E pH 7.10 P_aO_2 7.9 kPa P_aCO_2 4.3 HCO_3^- 12 mmol/l

The bicarbonate is likely to be higher due to previous renal compensation.

A 19-year-old man presents to the Emergency Department with a 3-day history of minor right-sided chest discomfort and lethargy. He smokes 20 cigarettes a day. A chest X-ray is obtained which shows a right-sided pneumothorax that is <1 cm from the chest wall. He is not distressed and he is not in significant pain. His oxygen saturation is 98% on air, his BP is 124/82 mmHg and his pulse is 81/min and regular.

How should he be managed?

A	Pleural aspiration
B	Small-bore chest drain insertion
C	Oxygen therapy
D	Outpatient clinic review
E	Large-bore chest drain insertion

D Outpatient clinic review

In a patient under the age of 50 without evidence of pre-existing lung disease, this is a primary pneumothorax. As the pneumothorax is <1 cm from the chest wall, it is reasonable to consider discharging the patient for review in the outpatient clinic.

A Pleural aspiration

Primary pneumothoracies which are >2 cm from the chest wall, or are associated with breathlessness, should be aspirated. Secondary pneumothoarcies which are 1–2 cm from the chest wall should be aspirated.

B Small-bore chest drain insertion

In primary or secondary pnemothoracies where aspiration was initially indicated but has failed, and in

In primary or secondary pnemothoracies where aspiration was initially indicated but has failed, and in secondary pneumothoracies >2 cm from the chest wall, insertion of an 8–14 F chest drain is indicated.

C	Oxygen therapy

Admission for high-flow oxygen therapy is indicated in secondary pneumothoracies <1 cm from the chest wall, or where aspiration has reduced the pneumothorax to this size. Care needs to be taken where there is oxygen sensitivity.

E	Large-bore chest drain insertion

Large-bore chest drains are usually greater than 20 F. Such drains are indicated in haemothoracies and complex empyema.

21545

Rate this question:

9:34
tps://mypastest.pastest.com
10

A 31-year-old lady presented to the Respiratory Outpatients Department with a 3-year history of increasing shortness of breath and cough. She had required numerous courses of antibiotics in the last few years. She was a smoker of 5/day for about 5 years. Respiratory examination revealed a hyperinflated chest and a mild wheeze throughout.

Lung function tests:

FEV_1	50% predicted
FVC	80% predicted
TLCO	68% predicted
KCO	71% predicted
RV:TLC	Increased

Which investigation would be most useful in making a diagnosis?

A Histamine challenge test

FEV_1	50% predicted
FVC	80% predicted
TLCO	68% predicted
KCO	71% predicted
RV:TLC	Increased

Which investigation would be most useful in making a diagnosis?

A	Histamine challenge test
B	Sweat test
C	Alpha-1 anti trypsin deficiency genotyping
D	Reversibility testing
E	High-resolution CT

70193

Submit

C Alpha-1 anti trypsin deficiency genotyping

Alpha-1-antitrypsin deficiency is a rare autosomal recessive disease associated with the development of premature pan-lobular emphysema, most severe in the basal areas of the lungs. Emphysema is thought to result from an imbalance in the lung between neutrophil elastase (which destroys elastin) and the elastase inhibitor α1-antitrypsin (which protects against proteolytic degradation by elastin). The decline in lung function is accelerated in smokers.

Patients usually present with progressive increasing shortness of breath and weight loss. Cor pulmonale and polycythaemia occur later in the course of the disease. A chest X-ray usually shows bilateral bi-basal emphysema. Lung function tests show an obstructive picture and the RV:TLC ratio is raised, indicating gas trapping. Transfer factor will be reduced. There are a number of different phenotypes depending on the serum level of α1-

depending on the serum level of α1-antitrypsin:
Pi – protease inhibitor
M – normal allele
S, X and null are disease alleles

Phenotype	α1-Antitrypsin level	Disease
PiMM	Normal	
PiMS	80%	
PiMZ	60%	
PiSS	60%	
PiSZ	40%	Liver cirrhosis/prem emphysema
Pi Null Null	Nil	Premature emphysema

Treatment is similar to that of asthma. Alpha1-antitrypsin replacement can be given weekly or monthly and is recommended for those with very low serum levels and abnormal lung function. Lung transplantation should

function. Lung transplantation should be considered in advanced disease. Patients should be encouraged to stop smoking.

B Sweat test

This would be used to confirm a diagnosis of cystic fibrosis, where levels of sodium and chloride are measured in sweat, production of which is stimulated by pads soaked in pilocarpine.

A Histamine challenge test

This would be used to confirm a diagnosis of asthma. Histamine challenge is rarely performed because of technical difficulties in performing it, including the risk of provoking severe bronchoconstriction.

D Reversibility testing

This would be used to confirm a diagnosis of asthma, rather than the

This would be used to confirm a diagnosis of asthma. Histamine challenge is rarely performed because of technical difficulties in performing it, including the risk of provoking severe bronchoconstriction.

D	Reversibility testing

This would be used to confirm a diagnosis of asthma, rather than the picture consistent with alpha-1-antitrypsin deficiency seen here.

E	High-resolution CT

This would be helpful in confirming basal predominant pan-lobular emphysema, making the diagnosis likely, but α1-antitrypsin levels would be more helpful in making definitive diagnosis.

70193

Rate this question:

Next Question

A 54-year-old stonemason was referred to the clinic with a 3-year history of progressive breathlessness. He is an ex-smoker (40 pack-years) having stopped 14 years ago.

On examination at that time, he looked well, was not clubbed and there was no lymphadenopathy. His chest was hyper-expanded and he had basal inspiratory crackles.

His spirometry revealed:

FEV_1	38% predicted
FVC	70% predicted
KCO	55% predicted

His chest X-ray from the original referral is shown below:

referral is shown below.

Three years later, he presents to the Emergency Department with increasing shortness of breath, cough and wheeze. Over the last year, he has had recurrent chest infections and now has a cough productive of green sputum.

On examination, respiratory rate 30/min, temperature 36.2 °C, blood pressure (BP) 160/100 mmHg, pulse 130/min, SpO_2 57% on air.

He is breathing through pursed lips. Auscultation of his chest reveals expiratory wheeze and crackles

Three years later, he presents to the Emergency Department with increasing shortness of breath, cough and wheeze. Over the last year, he has had recurrent chest infections and now has a cough productive of green sputum.

On examination, respiratory rate 30/min, temperature 36.2 °C, blood pressure (BP) 160/100 mmHg, pulse 130/min, SpO_2 57% on air.

He is breathing through pursed lips. Auscultation of his chest reveals expiratory wheeze and crackles throughout.

Blood gases on 28% oxygen:

pH	7.22
PO_2	7.9 kPa
PCO_2	8.0 kPa
Bicarbonate	20 mmol/l
Base excess	-3

What do the blood gases show?

PO_2	7.9 kPa
PCO_2	8.0 kPa
Bicarbonate	20 mmol/l
Base excess	-3

What do the blood gases show?

A Metabolic acidosis

B Respiratory acidosis

C Respiratory acidosis with metabolic compensation

D Mixed respiratory and metabolic acidosis

E Metabolic acidosis with respiratory compensation

70920

9:42
tps://mypastest.pastest.com
10

eferral is shown below:

Three years later, he presents
Emergency Department with
ncreasing shortness of breat
nd wheeze. Over the last yea
had recurrent chest infection

D Mixed respiratory and metabolic acidosis

This patient's blood gases show a picture of mixed respiratory and metabolic acidosis.

It is important when assessing blood gas results to do so in a systematic manner to make sure the correct diagnosis is reached.

Initially, looking at the pH in this case, it can be seen that there is an acidosis. pH normally ranges between 7.35 and 7.45, with values lower than 7.35 representing acidosis and values greater than 7.45 representing alkalosis.

When it has been established that an alkalosis or acidosis exists, look next at the CO_2 and bicarbonate to establish the cause, and the presence of compensation (if any).

pCO_2 is normally 4.5–6.0 kPa. As CO_2 is acidic, values greater >6.0 signify acidosis (respiratory acidosis) while values lower <4.5 signify alkalosis

acidosis (respiratory acidosis) while values lower <4.5 signify alkalosis (respiratory alkalosis).

Bicarbonate normally ranges between 22 and 28 mEq/l. As bicarbonate is basic, values lower than 22 signify acidosis (metabolic acidosis) while values greater than 28 signify alkalosis (metabolic alkalosis).

In this case, it can be seen that CO_2 is elevated *and* bicarbonate is reduced, indicating a mixed respiratory and metabolic cause of this patient's acidosis.

Compensation can be seen when there are abnormalities of either CO_2 or bicarbonate in the 'opposite' direction to the change in pH. For example, in the case of metabolic acidosis (with low pH and low bicarbonate) there may be respiratory compensation in which the patient hyperventilates to 'blow off' CO_2 and, as such, a reduced CO_2 is seen (which in isolation would normally signify a respiratory alkalosis).

A 71-year-old man with a 40 pack-year smoking history presents for review after a third hospital admission in the past year with a COPD exacerbation. He is managed at home with a salbutamol nebuliser; he has a carer and a disabled badge to help him with getting around. Other medication of note includes salmeterol BD. He has previously gained some benefit from courses of oral steroids.

Investigations:

Hb	14.5 g/dl
WCC	5.2×10^9/l
PLT	201×10^9/l
Na^+	139 mmol/l
K^+	4.9 mmol/l
Bicarbonate	29 mmol/l
Creatinine	104 μmol/l
FEV_1	40% predicted

Which of the following is the most appropriate therapy to reduce

Bicarbonate	29 mmol/l
Creatinine	104 μmol/l
FEV_1	40% predicted

Which of the following is the most appropriate therapy to reduce exacerbations?

A Ipratropium

B Montelukast

C Salmeterol

D Low-dose beclomethasone

E Salmeterol and high-dose fluticasone in combination

20606

Submit

E Salmeterol and high-dose fluticasone in combination

This patient has severe COPD, and evidence from the TORCH study suggests that high-dose fluticasone in combination with salmeterol is associated with reduced exacerbations of COPD. This is, however, at the expense of increased incidence of pneumonia.

A Ipratropium

Ipratropium is useful for short-term relief of symptoms, although it does not impact on outcomes in COPD. There is little evidence to support its use outside an exacerbation of COPD. In contrast, long-acting muscarinic antagonists such as tiotropium are shown to reduce the risk of exacerbations.

B Montelukast

Montelukast is a leukotriene antagonist

shown to reduce the risk of exacerbations.

B Montelukast

Montelukast is a leukotriene antagonist used for the treatment of asthma and does not have a role in the treatment of COPD.

C Salmeterol

Salmeterol use in the absence of inhaled corticosteroid is not advised. It is thought to increase the risk of atrial arrhythmia.

D Low-dose beclomethasone

Low-dose beclomethasone is not effective in reducing the risk of COPD exacerbations.

20606

Rate this question:

Next Question

A 72-year-old woman is brought to the Emergency Department by ambulance after her daughter found her unresponsive. The daughter, who lives next door, frequently visits her mother.

Today, her mother did not respond to the doorbell and when she opened the door she found her mother sprawled on the couch. She also found the gas stove switched on, but there was no flame. She then quickly called the ambulance.

On examination, the patient is drowsy with a Glasgow Coma Scale of 12/15, blood pressure of 154/90 mmHg, pulse of 98/min and a respiratory rate of 28/min. Oxygen saturation is 99%. The patient has already been started on high-flow oxygen via a non-rebreather mask.

Investigations:

$p_a(O_2)$	9.8 kPa
$p_a(CO_2)$	4.8 kPa
Bicarbonate	15 mmol/l

Carboxyhaemoglobin (COHb)	45%

Which of the following is the most important for management of such patients?

A	The acidosis should be treated with bicarbonate infusion
B	The $p_a(CO_2)$ has prognostic implications
C	Oxygen saturation by pulse oximeter can be used to monitor tissue oxygen saturation
D	The level of COHb increases the risk of fits
E	This patient is at high risk of sudden death

D The level of COHb increases the risk of fits

E This patient is at high risk of sudden death

Explanation

COHb levels have prognostic implications in carbon monoxide poisoning, the diagnosis here:

<30% cause only headache and dizziness, 40-60% produces syncope, tachypnea, tachycardia and fits, >60% cause increasing risk of cardiorespiratory failure and death.

Monitoring oxygen saturation with a pulse oximeter is unhelpful since it will not distinguish HbO_2 and COHb. Fits should be controlled by intravenous diazepam (5–10 mg). The metabolic acidosis corrects itself when the hypoxia is treated and does not require treatment with intravenous bicarbonate.

A 30-year-old man from London, with no significant past medical history, went on holiday to Peru to climb the Inca Trail. He is a non-smoker. After climbing above 3500 m he developed a headache, associated with nausea and vomiting. He also felt tired and complained of insomnia. His respiratory rate was 22/min and his pulse was 90/min. The remainder of physical examination was unremarkable.

Investigations reveal:

Urea	10 mmol/l
Creatinine	70 μmol/l
Na^+	135 mmol/l
K^+	4.3 mmol/l

That night it was noticed that he was disorientated and walking with a broad-based gait, and by the following morning he was drowsy and incoherent.

What is the most likely cause?

Creatinine	70 μmol/l
Na^+	135 mmol/l
K^+	4.3 mmol/l

That night it was noticed that he was disorientated and walking with a broad-based gait, and by the following morning he was drowsy and incoherent.

What is the most likely cause?

A	Cerebellar infarction
B	Cerebral haemorrhage
C	High-altitude pulmonary oedema
D	Meningococcal septicaemia
E	High-altitude cerebral oedema

Na^+	135 mmol/l
K^+	4.3 mmol/l

That night it was noticed that he was disorientated and walking with a broad-based gait, and by the following morning he was drowsy and incoherent.

What is the most likely cause?

Your answer was correct

A	Cerebellar infarction
B	Cerebral haemorrhage
C	High-altitude pulmonary oedema
D	Meningococcal septicaemia
E	High-altitude cerebral oedema

E High-altitude cerebral oedema

There are three types of altitude illness: acute mountain sickness (AMS), high-altitude cerebral oedema (HACE) and high-altitude pulmonary oedema (HAPE). This man has acute mountain sickness with some evidence of cerebral oedema. The exact cause is unknown, but it is thought to be secondary to cerebral oedema and raised intracranial pressure. It is more common in people who live at low altitude.

Symptoms and signs of AMS are non-specific; however, diagnosis can be made using the criteria named in 'The Lake Louise Score', namely, the setting of recent gain in altitude, the presence of headache and at least one of the following symptoms:

- Gastrointestinal – anorexia, nausea and vomiting
- Fatigue and weakness
- Dizziness or light-headedness

- Fatigue and weakness
- Dizziness or light-headedness
- Difficulty sleeping.

He does not improve and progresses to develop ataxia and drowsiness. This is the development of high-altitude cerebral oedema, which can be considered as end-stage AMS.

Treatment is immediate descent, oxygen and intravenous dexamethasone.

Acetazolamide may be used for prevention and treatment of AMS. This is a carbonic anhydrase inhibitor which causes intracellular acidosis. It has a diuretic effect which can be useful in AMS/HACE and HAPE. It is also beneficial as it shifts the oxygen-dissociation curve to the right and therefore at lower partial pressures, more oxygen is released to the tissues.

A	Cerebellar infarction

There is no history of unsteady gait

There is no history of unsteady gait and, given that the patient is at altitude, mountain sickness is more likely. Cerebellar infarction presents with non-specific symptoms such as dizziness, nausea and vomiting, unsteady gait and headache.

B	Cerebral haemorrhage

There are other more likely diagnoses here. He has no neurological symptoms other than headache. Cerebral haemorrhage will present with neurological symptoms and signs depending on where the haemorrhage is located. For example, a cerebellar infarct will present with unsteady gait.

C	High-altitude pulmonary oedema

There is nothing in the history to suggest pulmonary oedema. There is no history of breathlessness.

D	Meningococcal septicaemia

10:00
:tps://mypastest.pastest.com

A 21-year-old man with a history of cystic fibrosis comes to the Respiratory Clinic for review. He had been admitted with a significant exacerbation some 2 months earlier, and has been finding it difficult to maintain his weight since then. On examination his BP is 132/82 mmHg, with pulse 75/min and regular. You can hear coarse crackles and wheeze throughout both lung fields on auscultation. On examining his blood results, you note that he has a fasting plasma glucose of 8.5 mmol/l and his HbA1c is 53 mmol/mol.

Which of the following is the most appropriate way to manage his blood sugar?

A	Empagliflozin
B	Gliclazide
C	High-carbohydrate diet and

with pulse 75/min and regular. You can hear coarse crackles and wheeze throughout both lung fields on auscultation. On examining his blood results, you note that he has a fasting plasma glucose of 8.5 mmol/l and his HbA1c is 53 mmol/mol.

Which of the following is the most appropriate way to manage his blood sugar?

A	Empagliflozin
B	Gliclazide
C	High-carbohydrate diet and basal-bolus insulin
D	Low-carbohydrate diet
E	Metformin

C High-carbohydrate diet and basal-bolus insulin

In this situation, where patients with cystic fibrosis find it difficult to maintain their weight because of exocrine pancreatic insufficiency and frequent infections, a diagnosis of diabetes only compounds their difficulties. Treatment involves maintaining carbohydrate intake and using enough insulin to maintain glucose control.

A Empagliflozin

SGLT-2 inhibitors are not an appropriate option for control of blood glucose in this situation; they in essence remove carbohydrate by promoting urinary excretion of glucose, which leads to a calorie deficit, exactly what patients with cystic fibrosis don't need.

B Gliclazide

B Gliclazide

Although gliclazide may stimulate residual insulin production to attain some improvement in glucose control, this is likely to be short term and inadequate compared to a basal-bolus insulin regime.

D Low-carbohydrate diet

A low-carbohydrate diet here is not appropriate because it will potentially drive further weight loss without achieving adequate glucose control.

E Metformin

Insulin resistance is not the primary problem in diabetes associated with cystic fibrosis; as such, metformin is ineffective in reducing blood sugar here.

7624

Rate this question:

A 19-year-old man presents with a 10-day history of headaches and malaise, with the more recent development of a dry cough and breathlessness.

On examination, he was pyrexial, and he had a rash which looked like this:

Investigations:

Hb	9.4 g/dl
WCC	10×10^9/l
Neutrophils	9.2×10^9/l
PLT	200×10^9/l
Reticulocytes	5.1%
Na^+	129 mmol/l
K^+	5.0 mmol/l

Urea	4.4 mmol/l
Creatinine	90 micromol/l
Bilirubin	30 micromol/l
AST	44 U/l
ALT	30 U/l
ALP	121 U/l
Albumin	35 g/l
LDH	495 U/l
Creatinine	90 μmol/l

His chest X-ray is shown below:

What is the most likely diagnosis?

A	Epstein–Barr virus (EBV)
B	*Legionella* pneumonia
C	Streptococcal pneumonia
D	Tuberculosis
E	*Mycoplasma* pneumonia

70075

Submit

E *Mycoplasma* pneumonia

Mycoplasma usually affects young individuals and occurs in epidemics every 3–4 years. Chest symptoms are usually preceded by non-specific symptoms such as malaise and headaches.

The CXR usually shows only one lobe to be involved; however, about 20% show bilateral pneumonia. There is often a discrepancy between X-ray appearances and the clinical condition of the patient.

Diagnosis is by *Mycoplasma* serology – cold agglutinins occur in 50%. The image shows erythema multiforme, which further supports the diagnosis. The blood results suggest a haemolytic anaemia with a reticulocytosis, hyperbilirubinaemia and elevated LDH; autoimmune haemolytic anaemia (AIHA), when caused by cold agglutinins, is associated with *Mycoplasma* and can be diagnosed with a direct Coomb's test.

Extra-pulmonary complications of

Extra-pulmonary complications of *Mycoplasma* include:

- Cardiovascular – myocarditis and pericarditis
- Dermatological – erythema multiforme (as shown here), erythema nodosum, Stevens–Johnson syndrome and non-specific rashes
- Gastrointestinal – hepatitis, pancreatitis, nausea, vomiting, anorexia and transient abdominal pain
- Neurological – meningoencephalitis, meningitis, ascending paralysis, transient myelitis, cranial nerve palsies, peripheral neuropathy, bullous myringitis
- Haematological – cold autoimmune haemolytic anaemia, thrombocytopenia, disseminated intravascular

coagulation

- Renal – glomerulonephritis
- Others – arthralgia, arthritis, bullous myringitis.

Treatment: macrolides.

Causes of erythema multiforme:

- Infections – herpes simplex virus (most common cause), orf, HBV, HIV, EBV, mumps (paramyxovirus), *Mycoplasma*, psittacosis, *Rickettsiae*, *Streptococcus*, typhoid, diphtheria
- Drug reactions – barbiturates, penicillin, sulphonamides, phenytoin
- Connective tissue disease – SLE
- Vasculitis – polyarteritis nodosa, granulomatosis with polyangiitits

Others – underlying malignancy, sarcoidosis, rheumatoid arthritis, ulcerative colitis

A Epstein–Barr virus (EBV)

EBV causes infectious mononucleosis but is not associated with pneumonia. The disease is characterised by malaise and *upper* respiratory tract symptoms.

B *Legionella* pneumonia

Whilst dry cough, malaise, hyponatraemia and pneumonia are compatible with a diagnosis of *Legionella* pneumonia, the presence of erythema multiforme and headache, with normal LFTs, in a teenage patient is more consistent with *Mycoplasma* pneumonia.

C Streptococcal pneumonia

This patient presents with features of an atypical pneumonia. *Streptococcus pneumoniae* is the commonest cause of community-acquired pneumonia and would be associated with a sudden onset of symptoms, including fever and productive cough.

A 70-year-old lady presents in acute respiratory distress. She gives a history of some chest pain earlier that morning, which was worse on coughing. She is an ex-smoker of 30 pack-years (20/day for 30 years).

On examination she looks unwell. Respiratory rate is 30/min, pulse 120/min, BP 80/50 mmHg and O_2 saturation is 80% on air. Heart sounds are normal and her chest is clear.

ABG on air:

pH	7.44
PO_2	7.0 kPa
PCO_2	3.25 kPa
Base excess	-2.6
Bicarbonate	19.5 mmol/l

You manage to get an urgent CT within the hour, shown below.

within the hour, shown below.

What is the most likely diagnosis?

A	Congestive cardiac failure
B	Myocardial infarction
C	Pneumonia
D	Pulmonary embolism
E	Pneumothorax

A 70-year-old lady presents in acute respiratory distress. She gives a history of some chest pain earlier that morning, which was worse on coughing. She is an ex-smoker of 30 pack-years (20/day for 30 years).

On examination she looks unwell. Respiratory rate is 30/min, pulse 120/min, BP 80/50 mmHg and O_2 saturation is 80% on air. Heart sounds are normal and her chest is clear.

ABG on air:

pH	7.44
PO_2	7.0 kPa
PCO_2	3.25 kPa
Base excess	-2.6
Bicarbonate	19.5 mmol/l

You manage to get an urgent CT within the hour, shown below.

D Pulmonary embolism

This lady has had a massive pulmonary embolus, as shown on the CTPA. She presents with shortness of breath and tachypnoea, and her arterial blood gases show she has type I respiratory failure; note the low CO_2 – common in PE.

The CT shows large filling defects in the left and right main pulmonary arteries.

PE should be managed according to British Thoracic Society guidelines on the treatment of massive PE. The guidelines state that if a PE is sufficiently severe to cause circulatory collapse, thrombolysis should be given as early as possible. The current guidelines recommend alteplase as the thrombolytic agent of choice, as it can be given to the hypotensive patient, as in this example.

A Congestive cardiac failure

The patient's symptoms are not in

A Congestive cardiac failure

The patient's symptoms are not in keeping with cardiac failure, and her clear chest on examination makes this a less likely option. The CTPA is also clearly demonstrative of PE as the cause of her symptoms.

B Myocardial infarction

We are not given a history of cardiac chest pain, and the CTPA is clearly demonstrative of PE as the cause of her symptoms.

C Pneumonia

The patient would be expected to demonstrate symptoms such as productive cough, fever, etc. if the diagnosis were pneumonia. Her clear chest on examination also makes this a less likely option. The CTPA is also clearly demonstrative of PE as the cause of her symptoms.

We are not given a history of cardiac chest pain, and the CTPA is clearly demonstrative of PE as the cause of her symptoms.

C	Pneumonia

The patient would be expected to demonstrate symptoms such as productive cough, fever, etc. if the diagnosis were pneumonia. Her clear chest on examination also makes this a less likely option. The CTPA is also clearly demonstrative of PE as the cause of her symptoms.

E	Pneumothorax

Clear chest on examination, and a CTPA demonstrative of PE, make pneumothorax a less likely option. Pneumothorax would be demonstrated by CT if present.

70080

Rate this question:

A 39-year-old lady from Zimbabwe presents to the Emergency Department with a 5-day history of increasing shortness of breath and dry cough. She has a 1-day history of sudden onset of sharp chest pain which is worse on coughing, movement and deep inspiration. She describes having had night sweats and a poor appetite for 2 months. Her weight has decreased by about 5 kg. She has a past medical history of genital herpes and depression. She is married and has two children who live in Zimbabwe. She moved to England 2 years ago and has not travelled since. She is a smoker of 20/day and drinks little alcohol.

On examination she looked unwell. Observations: temperature 38.3°C, BP 108/72 mmHg, pulse 120/min, regular, respiratory rate 30/min. Auscultation of her chest revealed inspiratory crackles bi-basally.

Investigations:

Hb	10.2 g/dl

Hb	10.2 g/dl
WCC	9.4 $x10^9$/l
Neutrophils	8.6 $x10^9$/l
PLT	439 $x10^9$/l
MCV	79 fl
CRP	73 mg/l
Na^+	141 mmol/l
K^+	4.2 mmol/l
Urea	5.0 mmol/l
Creatinine	75 micromol/l
Glucose	5.7 mmol/l
Blood gases on 80% oxygen:	
pH	7.46
PCO_2	3.44 kPa
PO_2	10.77 kPa
Bicarbonate	17.6 mmol/l

Bicarbonate	17.6 mmol/l
Base excess	-3.5

Her CXR is shown:

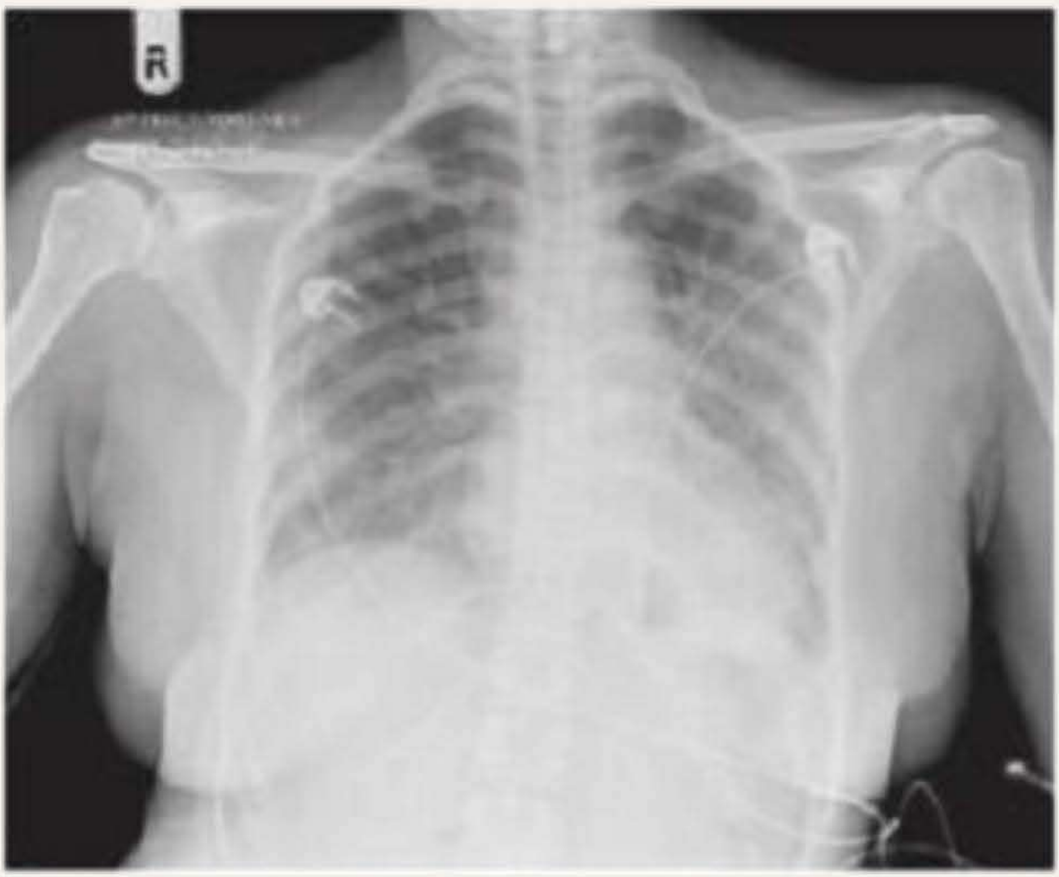

Which investigation would be most helpful in establishing a diagnosis?

A	Bronchoscopy and transbronchial biopsy
B	CT pulmonary angiogram
C	Lung function tests and

Which investigation would be most helpful in establishing a diagnosis?

A	Bronchoscopy and transbronchial biopsy
B	CT pulmonary angiogram
C	Lung function tests and transfer factor
D	Indirect immunofluorescence of bronchoalveolar lavage fluid
E	Blood cultures

D Indirect immunofluorescence of bronchoalveolar lavage fluid

Diagnosis is now usually made by PCR of sputum or BAL fluid. Other diagnostic methods include staining induced sputum or BAL with indirect immunofluorescence with monoclonal antibodies.

For the purpose of the exam, people who have lived abroad (especially Africa and South America), businessmen who work abroad, homosexuals and intravenous drug users, are more likely to have HIV.

This lady has HIV – the history of living in Zimbabwe and the low lymphocyte count are the clues. *Pneumocystis jirovecii* is the most common opportunistic infection to cause pneumonia in AIDS – especially when the CD4 count is <200/mm^3. It accounts for about 50% of cases of pneumonia in AIDS and 40% of all AIDS-defining illnesses.

Patients usually present with a fever,

Patients usually present with a fever, dry cough and breathlessness. They are usually hypoxic and desaturate on exercise.

In *P. jirovecii* pneumonia (PJP) the chest X-ray usually shows bilateral interstitial shadowing and cysts in the mid and lower zones. However, the CXR may be normal. Pneumothorax (because the cysts rupture) may be present in up to 10%.

Treatment is with high-flow oxygen and high-dose co-trimoxazole. Prednisolone should be added in severe cases (PO_2 <9.5 kPa).

A	Bronchoscopy and transbronchial biopsy

Transbronchial biopsy would cause undue risk of pneumothorax in a patient already at risk of pneumothorax due to *Pneumocystis* pneumonia. Also, it is likely that this patient will end up invasively ventilated, further adding to risk of pneumothorax.

A 30-year-old woman presents with sudden-onset shortness of breath and chest pain. She had a similar episode earlier in the year. At that time she had a chest X-ray taken and a needle inserted into her lung, which relieved the problem. Last year she had shortness of breath associated with 'fluid on her lung', which was drained off, and she was told to follow a low-fat diet. She has no other past medical history and is not on any medications.

What is the most likely diagnosis?

A	Histiocytosis
B	Tuberous sclerosis
C	Neurofibromatosis type 1
D	Recurrent *Pneumocystis jirovecii* infection
E	Lymphangioleiomyomatosis

A 30-year-old woman presents with sudden-onset shortness of breath and chest pain. She had a similar episode earlier in the year. At that time she had a chest X-ray taken and a needle inserted into her lung, which relieved the problem. Last year she had shortness of breath associated with 'fluid on her lung', which was drained off, and she was told to follow a low-fat diet. She has no other past medical history and is not on any medications.

What is the most likely diagnosis?

Your answer was correct

A	Histiocytosis
B	Tuberous sclerosis
C	Neurofibromatosis type 1
D	Recurrent *Pneumocystis jirovecii* infection

E Lymphangioleiomyomatosis

Lymphangioleiomyomatosis is a rare idiopathic disease, affecting women of reproductive years. It is characterised by infiltration of immature muscle cells into the bronchiolar and alveolar walls. This results in destruction of the airways, cyst formation and progressive decline in lung function. Typical radiological findings are of interstitial lung disease, recurrent pneumothoraces and chylous effusions. Treatment is lung transplantation. Patients are asked to avoid taking the oral contraceptive pill, pregnancy and long-haul flights. Conservative management includes progesterone supplements, but the response is variable. Management of pneumothorax and chylous effusions is standard. If this occurs in men then tuberous sclerosis should be considered.

A Histiocytosis

A Histiocytosis

Histiocytosis, or Langerhans cell histiocytosis, is a sign or multi-system condition characterised by infiltrating granulomas with Langerhans cells. In the lungs this can cause pneumothoraces and pulmonary hypertension, with cysts and honeycombing on imaging. Diagnosis is by biopsy and treatment is with local excision and steroids. The presence of pleural effusions makes this unlikely in this patient, as does the absence of any guiding radiological features.

B Tuberous sclerosis

Tuberous sclerosis is an autosomal dominant disorder with hamartoma formation in the heart, kidneys, eyes, brain and skin. Patients can have adenoma sebaceum, angiofibromas and ash leaf hypomelanic macules, as well as shagreen patches. It is associated with Von Hippel–Lindau. The absence of any such skin features makes this an unlikely underlying

makes this an unlikely underlying cause.

C	Neurofibromatosis type 1

Neurofibromatosis type 1 is an autosomal dominant condition. Patients have café-au-lait spots, freckling and neurofibromas. Some can develop problems resulting from neurofibromas, particularly ophthalmic and neurological complications. The absence of any neurofibromas makes this an unlikely diagnosis.

D	Recurrent *Pneumocystis jirovecii* infection

Pneumocystis jirovecii is an opportunistic, AIDS-defining infection associated with severe immunosuppression in HIV. It is very unlikely to cause infection without HIV and immunocompromise, but in such patients it can cause pneumothorax as a complication.

A 71-year-old man presents to his GP along with his wife. He has severe problems with sleeping at night, with episodes where he snores, stops breathing, is restless and often disturbs his wife from sleep. During the day his family complain that he often falls asleep watching the television, after his dinner or even whilst talking to his wife. He is a smoker of 20 cigarettes per day, has hypertension and suffered a TIA 3 years earlier. Medication includes ramipril 10 mg, simvastatin 40 mg and aspirin 75 mg. On examination his BMI is 32, his BP is 150/90 mmHg and he has signs of right heart failure.

Investigations:

Hb	14.0 g/dl
WCC	5.8 $\times 10^9$/l
PLT	220 $\times 10^9$/l
Na^+	138 mmol/l
K^+	4.5 mmol/l
Creatinine	140 μmol/l

PLT	220 x10^9/l
Na^+	138 mmol/l
K^+	4.5 mmol/l
Creatinine	140 µmol/l

Which of the following is the most likely diagnosis?

A Central sleep apnoea

B Nocturnal epilepsy

C Obstructive sleep apnoea

D Multiple TIAs

E Narcolepsy

18628

Submit

A 71-year-old man presents to his GP along with his wife. He has severe problems with sleeping at night, with episodes where he snores, stops breathing, is restless and often disturbs his wife from sleep. During the day his family complain that he often falls asleep watching the television, after his dinner or even whilst talking to his wife. He is a smoker of 20 cigarettes per day, has hypertension and suffered a TIA 3 years earlier. Medication includes ramipril 10 mg, simvastatin 40 mg and aspirin 75 mg. On examination his BMI is 32, his BP is 150/90 mmHg and he has signs of right heart failure.

Investigations:

Hb	14.0 g/dl
WCC	5.8 $\times 10^9$/l
PLT	220 $\times 10^9$/l
Na^+	138 mmol/l
K^+	4.5 mmol/l

C Obstructive sleep apnoea

This patient is obese, with hypertension and right heart failure. He has significant symptoms of nocturnal airway obstruction and daytime sleepiness, and this constellation of symptoms and signs fits with a diagnosis of obstructive sleep apnoea. Management of the condition involves aggressive weight reduction and the use of nocturnal CPAP to relieve nocturnal airway obstruction. Clearly this gentleman should also receive very strong advice to stop smoking and should be advised not to drive.

A Central sleep apnoea

Central sleep apnoea is usually seen in patients with significant neurological impairment, and the fact this patient is a smoker and obese is a much stronger pointer to obstructive sleep apnoea.

B Nocturnal epilepsy

B Nocturnal epilepsy

Nocturnal epilepsy is more likely to be associated with tonic–clonic movements, automatisms or sleep-walking, rather than the clinical picture seen here.

D Multiple TIAs

There are no focal features to suggest TIAs; the recurrent snoring and cessation of breathing is much more suggestive of obstructive sleep apnoea.

E Narcolepsy

Narcolepsy is associated with excessive daytime sleepiness, cataplexy, hypnagogic hallucinations and sleep paralysis. The snoring and periods of apnoea are not consistent with a diagnosis of narcolepsy.

18628

Rate this question:

A 44-year-old man presented with a rash on his legs and feeling generally unwell with malaise, weight loss and fevers. He also had recently noticed some loss of sensation over the top of his right foot, with the foot dragging when he walked. He had been diagnosed with asthma by his general practitioner many years ago and used a salbutamol inhaler as required. He also had a constant watery nasal discharge, but no epistaxis. He was a non-smoker. On examination he had a low-grade pyrexia and scattered wheeze in his chest. Heart sounds were normal. His abdomen was soft and non-tender, with no masses. He had a purpuric rash on his lower limbs and several tender subcutaneous nodules on his forearms. He had a right foot drop but no other neurological abnormalities.

Investigations:

Hb	10.6 g/dl
WCC	$10.9 \times 10^9/l$
PLT	$390 \times 10^9/l$

WCC	10.9×10^9/l
PLT	390×10^9/l
Neutrophils	6.2×10^9/l
Eosinophils	2.2×10^9/l
Monocytes	1.6×10^9/l
Basophils	0.1×10^9/l
MCV	94 fl
ESR	82 mm/h
Na^+	120 mmol/l
K^+	4.2 mmol/l
ALP	80 IU/l
ALT	30 IU/l
Urea	5.2 mmol/l
GGT	42 IU/l
Bilirubin	14 μmol/l
Creatinine	110 μmol/l
Antinuclear antibody	-

Anti-neutrophil cytoplasmic antibody (pANCA)	+
Urinalysis	Normal
CXR	Patchy shadowing at hilar regions, small pleural effusion

What is the most likely diagnosis?

A	Systemic lupus erythematosus
B	Polyarteritis nodosa
C	Eosinophilic granulomatosis with polyangitis
D	Anti-GBM disease
E	Granulomatosis with polyangitis

C Eosinophilic granulomatosis with polyangitis

This man presents with the classic triad of asthma, eosinophilia and systemic vasculitis. There is usually a prodromal period for many years consisting of allergic rhinitis and late-onset asthma, which can be difficult to control.

The chest X-ray may show nodules, transient hilar lymphadenopathy and pulmonary infiltrates. There may also be pleural or pericardial effusions. Mononeuritis multiplex can occur. Anti-neutrophil cytoplasmic antibody (ANCA) is positive in approximately 40% of cases. Renal involvement is rare. Treatment is with high-dose corticosteroids, azathioprine or cyclophosphamide.

A Systemic lupus erythematosus

Although SLE is associated with an erythematous rash on sun-exposed

Although SLE is associated with an erythematous rash on sun-exposed areas, the eosinophilia, negative ANA and positive pANCA would be unusual for a diagnosis of lupus.

B	Polyarteritis nodosa

pANCA is classically not positive in patients with PAN. In addition, the symptoms of significant asthma poorly responsive to conventional therapies, and eosinophilia, are inconsistent with a diagnosis of PAN.

D	Anti-GBM disease

This presents with rapidly progressive pulmonary and kidney disease, accompanied by haemoptysis and kidney disease due to glomerulonephritis. Eosinophilia isn't a feature, nor is mononeuritis multiplex.

E	Granulomatosis with polyangitis

A 47-year-old hotel cleaner presents with a fever of 39°C, malaise and myalgia followed by the development of a dry and non-productive cough. Other non-specific symptoms include headache, anorexia, nausea and non-specific abdominal pain. Positive findings on general examination include tachycardia, tachypnoea and bibasal crackles on auscultation of the chest. The CXR shows early bibasal consolidation. Blood investigations show hyponatraemia and deranged LFTs, and urine testing shows the presence of protein and blood.

Which of the following is the most appropriate initial antibiotic regimen?

A	Benzylpenicillin and gentamicin
B	Erythromycin
C	Levofloxacin
D	Oxytetracycline

specific abdominal pain. Positive findings on general examination include tachycardia, tachypnoea and bibasal crackles on auscultation of the chest. The CXR shows early bibasal consolidation. Blood investigations show hyponatraemia and deranged LFTs, and urine testing shows the presence of protein and blood.

Which of the following is the most appropriate initial antibiotic regimen?

A	Benzylpenicillin and gentamicin
B	Erythromycin
C	Levofloxacin
D	Oxytetracycline
E	Rifampicin

C Levofloxacin

The picture here, with marked fever, hyponatraemia, GI disturbance and blood and proteinuria, fits well with a diagnosis of Legionnaires' disease. Although trials have shown no significant difference in mortality, they do suggest that treatment with a quinolone versus a macrolide results in more rapid fever resolution and improvement in general well-being.

A Benzylpenicillin and gentamicin

This was the standard empirical intervention for bacterial endocarditis, although gentamicin now appears not to impact significantly on prognosis versus benzylpenicillin alone.

B Erythromycin

Macrolide antibiotics are slightly less efficient at relieving symptoms versus

B Erythromycin

Macrolide antibiotics are slightly less efficient at relieving symptoms versus modern quinolones, and dosing of erythromycin, coupled with GI side effects, means that other macrolides such as clarithromycin are preferred.

D Oxytetracycline

Oxytetracycline is an alternative, rather than a first- or second-line option, for the treatment of Legionnaires' disease.

E Rifampicin

Rifampicin is used in combination with a quinolone or a macrolide for treatment of severe *Legionella* infection.

A 39-year-old woman from Zimbabwe presents to the Emergency Department with a 5-day history of increasing shortness of breath and dry cough. She has a 1-day history of sudden onset of sharp chest pain which is worse on coughing, movement and deep inspiration. She describes having had night sweats and a poor appetite for two months. Her weight has decreased by about 5 kg. She has a past medical history of genital herpes and depression. She is married and has two children who live in Zimbabwe. She moved to England 2 years ago and has not travelled since. She is a smoker of 20/day and drinks little alcohol.

On examination, she looked unwell. Observations: temperature 38.3 °C, blood pressure (BP) 108/72 mmHg, pulse 120/min, regular, respiratory rate 30/min. Auscultation of her chest revealed inspiratory crackles bi-basally.

Investigations:

Hb	10.2 g/dl

WCC	3.4×10^9/l
PLT	439×10^9/l
Na+	141 mmol/l
K+	4.2 mmol/l
Creatinine	75 µmol/l
MCV	79 fl
CRP	73 mg/l
Urea	5.0 mmol/l
Glucose	5.7 mmol/l

Blood gases on 80% oxygen:

pH	7.46
PCO_2	3.44 kPa
PO_2	10.77 kPa
Bicarbonate	17.6 mmol/l
Base excess	−3.5

Her chest X-ray is shown below:

Her chest X-ray is shown below:

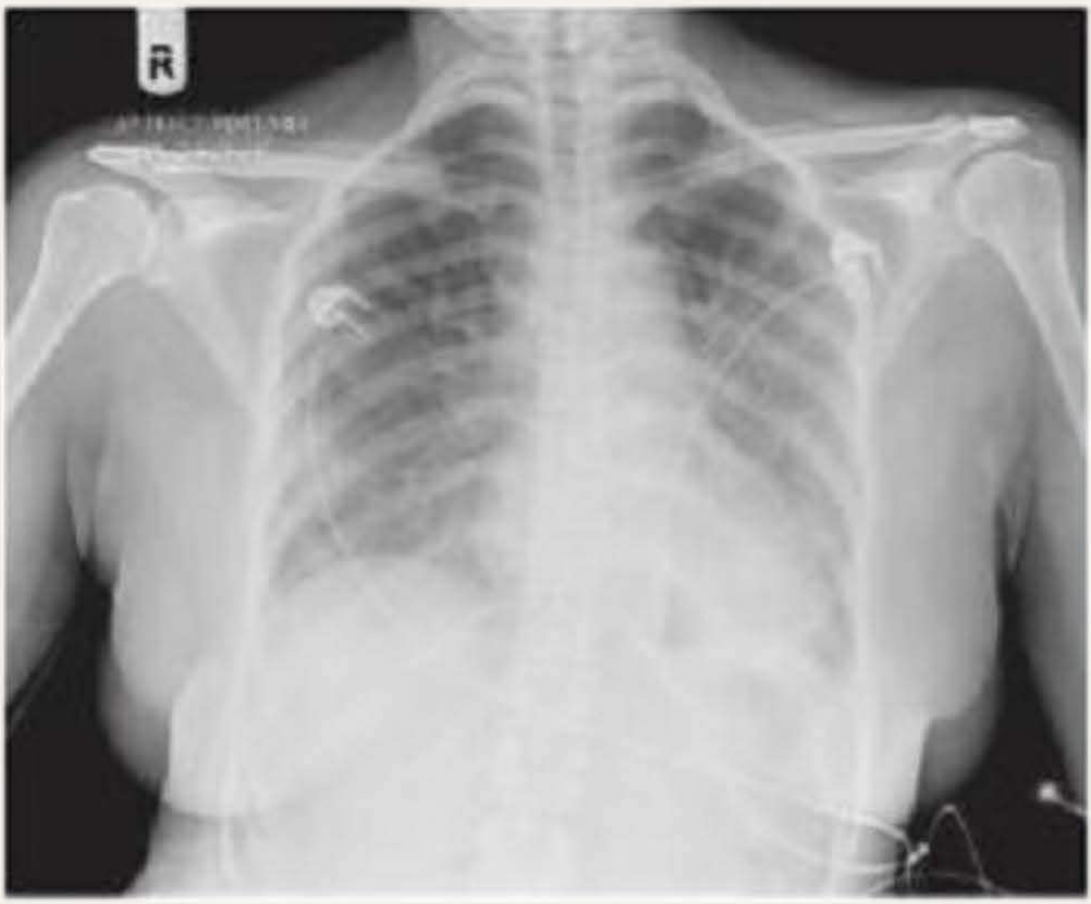

What treatment should be started?

A	Intravenous co-amoxiclav and clarithromycin
B	Anticoagulation with warfarin
C	Prednisolone
D	Intravenous ganciclovir
E	Intravenous high-dose co-

What treatment should be started?

A	Intravenous co-amoxiclav and clarithromycin
B	Anticoagulation with warfarin
C	Prednisolone
D	Intravenous ganciclovir
E	Intravenous high-dose co-trimoxazole ± steroids

E Intravenous high-dose co-trimoxazole ± steroids

For the purpose of the exam, people who have lived abroad (especially Africa and South America), businessmen who work abroad, homosexuals and intravenous drug users, are more likely to have HIV.

This lady has HIV – the history of living in Zimbabwe and the low white cell count are the clues. *Pneumocystis jirovecii* is the most common opportunistic infection to cause pneumonia in AIDS – especially when the CD4 count is <200/mm^3. It accounts for about 50% of cases of pneumonia in AIDS and 40% of all AIDS-defining illnesses.

Patients usually present with a fever, dry cough and breathlessness. They are usually hypoxic and desaturate on exercise.

In *P. jirovecii* pneumonia (PJP) the chest X-ray usually shows bilateral interstitial shadowing and cysts in the mid and lower zones. However, the

chest X-ray usually shows bilateral interstitial shadowing and cysts in the mid and lower zones. However, the CXR may be normal. Pneumothorax (because the cysts rupture) may be present in up to 10%.

Diagnosis is now usually made by PCR of sputum or BAL fluid. Other diagnostic methods include staining induced sputum or BAL with indirect immunofluorescence with monoclonal antibodies.

Treatment is with high-flow oxygen and high-dose co-trimoxazole. Prednisolone should be added in severe cases (PO_2 <9.5 kPa).

A	Intravenous co-amoxiclav and clarithromycin

This is appropriate treatment for community-acquired pneumonia.

B	Anticoagulation with warfarin

This is appropriate treatment for PE.

A 25-year-old man presents with left-sided pleuritic chest pain that come on suddenly 3 days previously. Initially he thought it was secondary to his workout in the gym. However, since it did not improve and he noticed that he was slightly more breathless than usual, he went to the Emergency Department. He has no significant past medical history. He is a smoker of 20/day. On examination he looked well. He was a tall, thin man and was not short of breath at rest. Examination was unremarkable except for a clicking sound which was synchronous with the heart sounds. CXR was unremarkable.

What is the diagnosis?

A	Mitral valve prolapse
B	Pericarditis
C	Primary pneumothorax
D	Pleurisy

did not improve and he noticed that he was slightly more breathless than usual, he went to the Emergency Department. He has no significant past medical history. He is a smoker of 20/day. On examination he looked well. He was a tall, thin man and was not short of breath at rest. Examination was unremarkable except for a clicking sound which was synchronous with the heart sounds. CXR was unremarkable.

What is the diagnosis?

A	Mitral valve prolapse
B	Pericarditis
C	Primary pneumothorax
D	Pleurisy
E	Secondary pneumothorax

9:37
tps://mypastest.pastest.com

A 25-year-old man presents with left-sided pleuritic chest pain that come on suddenly 3 days previously. Initially he thought it was secondary to his workout in the gym. However, since it did not improve and he noticed that he was slightly more breathless than usual, he went to the Emergency Department. He has no significant past medical history. He is a smoker of 20/day. On examination he looked well. He was a tall, thin man and was not short of breath at rest. Examination was unremarkable except for a clicking sound which was synchronous with the heart sounds. CXR was unremarkable.

What is the diagnosis?

Your answer was incorrect

A Mitral valve prolapse

C Primary pneumothorax

A click synchronous with the heart sounds is a recognised sign of a small left apical pneumothorax. He is a tall, thin man and a smoker, which are both risk factors for developing a pneumothorax. There is a strong association between pneumothoraces and smoking. The most recent British Thoracic Society (BTS) guidelines suggest that if the postero-anterior (PA) chest X-ray is normal and a small pneumothorax is suspected, a lateral decubitus chest X-ray provides added information in up to 14% of cases (see weblink below). Expiratory films add little and are not recommended.

The treatment of a primary pneumothorax in a non-smoker, <50 years old, with no evidence of underlying lung disease, with a rim of air of <2 cm and no breathlessness is to discharge and follow up as an outpatient. Although this patient is a smoker there is nothing to suggest underlying lung disease, and it is likely that his apical pneumothorax is too

that his apical pneumothorax is too small to safely aspirate. Patients should be given analgesia if required and clear instructions to return if their symptoms get any worse.

A Mitral valve prolapse

This is associated with a mid- to late systolic click. It occurs when there is an abnormally thickened mitral valve leaflet that displaces into the left atrium during systole.

B Pericarditis

The patient has pleuritic, not pericarditic, chest pain. Pericarditis typically causes symptoms that include sudden onset of sharp chest pain. The pain may be felt in the shoulders, neck or back. It is typically relieved by sitting up and worse when lying down or deep inspiration. Other symptoms include fever, weakness, palpitations or dyspnoea.

sitting up and worse when lying down or deep inspiration. Other symptoms include fever, weakness, palpitations or dyspnoea.

D	Pleurisy

Onset was sudden and not associated with infective symptoms. Pleurisy results in a sharp chest pain on breathing. Other symptoms include breathlessness, cough, fever and weight loss.

E	Secondary pneumothorax

There is no history of underlying lung disease. Secondary pneumothorax is defined as pneumothorax that occurs in the presence of underlying lung disease. This is in contrast to primary pneumothorax, where there is no lung disease.

70118

Rate this question:

Next Question

You are asked to review a 64-year-old man with a history of chronic obstructive pulmonary disease (COPD), prior to planned surgery for a large inguinal hernia. You take a history and examine him. He is worked up with investigations before proceeding to the operation.

Which of the following is most associated with increased risk of peri-operative complications?

A	Nature of the surgery (hernia repair)
B	CO_2 level of 6.2 kPa on air-breathing arterial blood gas sample
C	FEV_1 (forced expiratory volume in 1 s) of 1.4 l
D	History of treated hypertension
E	Ability to walk 1.2 miles on the

B CO_2 level of 6.2 kPa on air-breathing arterial blood gas sample

A raised CO_2 on air would have most impact on increased peri-operative risk in this case. Whilst epidural anaesthesia may offer a reduction in peri-operative risk, atelectasis due to continued abdominal pain is still associated with increased incidence of postoperative lower respiratory tract infection. Postoperative pain relief and aggressive physiotherapy support are therefore essential components of treatment.

C FEV_1 (forced expiratory volume in 1 s) of 1.4 l

FEV_1 <0.8 l is particularly associated with operative risk. Obesity, because of splinting of the diaphragm, may also drive postoperative respiratory failure.

A Nature of the surgery (hernia repair)

repair)

Although abdominal surgery is associated with increased risk of postoperative respiratory failure, hernia repair is a relatively minor procedure and adequate analgesia should minimise the risk of perioperative complications.

D	History of treated hypertension

Controlled blood pressure should not be associated with significant operative risk. Recent ischaemic cardiovascular events on the other hand do significantly impact on outcome.

E	Ability to walk 1.2 miles on the flat

Ability to walk 1.2 miles implies a functional status associated with low risk of operative complications.

A 70-year-old woman who underwent right hemicolectomy opted to receive a designated blood transfusion from her daughter, who is the same blood group. Whilst on the ward undergoing the first unit of blood she began to complain of extreme shortness of breath. Her blood pressure was markedly reduced, at 90/50 mmHg. On examination there were inspiratory crackles consistent with heart failure throughout both lung fields. Dipstick of her urine was negative for haematuria.

Which of the following is the most likely cause of this transfusion reaction?

A	ABO incompatibility
B	Rhesus incompatibility
C	Granulocyte antibodies in the donor blood

breath. Her blood pressure was markedly reduced, at 90/50 mmHg. On examination there were inspiratory crackles consistent with heart failure throughout both lung fields. Dipstick of her urine was negative for haematuria.

Which of the following is the most likely cause of this transfusion reaction?

A	ABO incompatibility
B	Rhesus incompatibility
C	Granulocyte antibodies in the donor blood
D	Granulocyte antibodies in the recipient blood
E	Cytokines in the donor blood

C Granulocyte antibodies in the donor blood

Transfusion-related lung injury or TRALI is thought to be related to anti-HLA or anti-granulocyte antibodies in the donor blood. Despite the fact that the donor and recipient are matched, the possibility of anti-granulocyte antibodies cannot be excluded. It is postulated that TRALI is seen more often in multiparous women who donate blood, because of the generation of antibodies to HLA antigens through multiple exposures to fetal blood. Lung symptoms are often difficult to distinguish from ARDS, and management of TRALI is consistent with the management of ARDS itself.

A ABO incompatibility

ABO incompatibility is associated with an acute deterioration characterised by hypotension, tachycardia

haemolysis and symptoms similar to anaphylaxis, although the reaction isn't mediated by IgE. It carries a mortality of up to 10%.

B	Rhesus incompatibility

Rhesus incompatibility presents with a similar picture to ABO incompatibility, but symptoms are generally less severe.

D	Granulocyte antibodies in the recipient blood

It is antibodies in the donor blood against neutrophils in the recipient that may have undergone priming due to an acute respiratory illness, which drive the presentation here.

E	Cytokines in the donor blood

Cytokines in donor blood are associated with febrile transfusion reactions. There are normally no other sequelae apart from an increase in

A 58-year-old man was referred to the neurology clinic by his general practitioner with a 4-month history of progressive weakness. He described difficulty walking, with heavy, stiff legs. He had particular trouble in going upstairs and rising from a chair. He also occasionally had episodes of double vision. Apart from controlled hypertension, he had no significant past medical history. He smoked 20 cigarettes per day and drank 16 units of alcohol per week. On systems enquiry, he also admitted to weight loss of one stone, a persistent cough and a dry mouth. He reluctantly admitted that he had been having some sexual difficulties with his wife recently.

On examination, he looked reasonably well. There was no finger clubbing or lymphadenopathy. Cardiorespiratory examination revealed coarse crackles consistent with COPD, and abdominal examination was unremarkable. On neurological examination, his tone and sensation were normal, with no muscle wasting. He had predominantly

wasting. He had predominantly proximal muscle weakness and his tendon reflexes were universally absent. Apart from mild bilateral ptosis, his cranial nerves were intact. Interestingly, his power and reflexes seemed to improve after a brief period of repetitive exercise of the affected muscle.

Investigations:

Hb	14.0 g/dl
WCC	5.0×10^9/l
Platelets	300×10^9/l
Urea	5.2 mmol/l
MCV	82 fl
Na^+	130 mmol/l
K^+	3.6 mmol/l
Bilirubin	10 μmol/l
ALT	32 IU/l μmol/l
Creatinine	120 μmol/l
ALP	80 IU/l

ALT	32 IU/l µmol/l
Creatinine	120 µmol/l
ALP	80 IU/l
GGT	42 IU/l

Which of the following investigations would be the most useful in making a diagnosis?

A	Tensilon (edrophonium) test
B	Serum acetylcholine receptor antibodies
C	Muscle biopsy
D	Anti-calcium channel antibodies
E	Serum creatine kinase

D Anti-calcium channel antibodies

This man has Lambert–Eaton myasthenic syndrome (LEMS), which is associated with an underlying small cell carcinoma of the bronchus. This is a rare paraneoplastic phenomenon which can precede radiological evidence of the tumour by up to 5 years. LEMS is a presynaptic disorder of the neuromuscular junction which is caused by antibodies to the voltage-gated calcium channels of the nerve terminal, leading to failure of acetylcholine release. The clinical features are proximal muscle weakness and depressed tendon reflexes, which can return after a few minutes of muscular contraction. Autonomic symptoms are common. The diagnosis is made electrophysiologically, and auto-antibodies are found in 90% of cases. Treatment is with 3,4-diaminopyridine, prednisolone and occasionally plasma exchange.

In this patient with a significant smoking history, evidence of COPD and proximal muscle weakness, the most likely diagnosis is Lambert-Eaton myasthenic syndrome (LEMS), which is associated with an underlying small cell carcinoma of the bronchus. A tensilon test would be diagnostic for myasthenia gravis, an autoimmune muscle condition which is associated with fatigueability, i.e. power and function deteriorate with repeated testing.

B	Serum acetylcholine receptor antibodies

In this patient with a significant smoking history, evidence of COPD and proximal muscle weakness, the most likely diagnosis is Lambert-Eaton myasthenic syndrome (LEMS), which is associated with an underlying small cell carcinoma of the bronchus. ACh receptor antibodies would be part of the diagnostic testing for myasthenia gravis, an autoimmune muscle

C Muscle biopsy

In this patient with a significant smoking history, evidence of COPD and proximal muscle weakness, the most likely diagnosis is Lambert-Eaton myasthenic syndrome (LEMS), which is associated with an underlying small cell carcinoma of the bronchus. A muscle biopsy would be useful in diagnosing an inflammatory or necrotising myopathy, but these diagnoses are less likely, given that testing improves with repetition in this patient, and one would expect power to decline with repeated testing in a myopathy.

E Serum creatine kinase

In this patient with a significant smoking history, evidence of COPD and proximal muscle weakness, the most likely diagnosis is Lambert-Eaton myasthenic syndrome (LEMS), which is associated with an underlying small

A 62-year-old man who has a history of COPD, for which he takes fluticasone and salmeterol (combined) and salbutamol, comes to the Emergency Department with sudden-onset shortness of breath and right-sided pleuritic chest pain. He takes a number of medications for hypertension and ischaemic heart disease, but has recently enrolled on a pulmonary rehabilitation programme and is walking up to 2 miles per day. On examination his BP is 155/90 mmHg with pulse 92/min and regular. He has diminished breath sounds over the right-hand side on auscultation. Oxygen saturation is reduced at 90%. CXR reveals a right-sided pneumothorax with a 1.5 cm rim of air.

Which of the following is the most appropriate intervention?

A	Admit for high-flow oxygen
B	Air aspiration

disease, but has recently enrolled on a pulmonary rehabilitation programme and is walking up to 2 miles per day. On examination his BP is 155/90 mmHg with pulse 92/min and regular. He has diminished breath sounds over the right-hand side on auscultation. Oxygen saturation is reduced at 90%. CXR reveals a right-sided pneumothorax with a 1.5 cm rim of air.

Which of the following is the most appropriate intervention?

A	Admit for high-flow oxygen
B	Air aspiration
C	Discharge and review in 24 h
D	Discharge and review in 2 weeks
E	Insert size 8–14 Fr chest drain

A 62-year-old man who has a history of COPD, for which he takes fluticasone and salmeterol (combined) and salbutamol, comes to the Emergency Department with sudden-onset shortness of breath and right-sided pleuritic chest pain. He takes a number of medications for hypertension and ischaemic heart disease, but has recently enrolled on a pulmonary rehabilitation programme and is walking up to 2 miles per day. On examination his BP is 155/90 mmHg with pulse 92/min and regular. He has diminished breath sounds over the right-hand side on auscultation. Oxygen saturation is reduced at 90%. CXR reveals a right-sided pneumothorax with a 1.5 cm rim of air.

Which of the following is the most appropriate intervention?

Your answer was correct

A	Admit for high-flow oxygen
B	Air aspiration

E Insert size 8–14 Fr chest drain

Although the rim is <2 cm, in the presence of significant symptoms (i.e. shortness of breath) a chest drain is preferred to air aspiration and is therefore the correct course of action.

A Admit for high-flow oxygen

This is the correct course of action after successful air aspiration for secondary pneumothorax, where patients are usually brought into hospital for a period of 24 h.

B Air aspiration

This is the recommended intervention for a secondary pneumothorax of size 1–2 cm that isn't associated with symptoms.

C Discharge and review in 24 h

Discharge and review in 2–4 weeks is

patients are usually brought into hospital for a period of 24 h.

B Air aspiration

This is the recommended intervention for a secondary pneumothorax of size 1–2 cm that isn't associated with symptoms.

C Discharge and review in 24 h

Discharge and review in 2–4 weeks is recommended after successful air aspiration of a primary pneumothorax.

D Discharge and review in 2 weeks

This is the correct course of action after successful air aspiration of a primary pneumothorax.

40118

Rate this question:

Next Question

A 70-year-old man with type 2 diabetes was admitted from a care home with a cough, fever and chest pain. He has been managed with IV co-amoxiclav for four days but is not improving. Other medication of note includes ramipril, atorvastatin, aspirin and mixed insulin BD.

On examination he is pyrexial at 38.5 °C, with BP 100/60 mmHg and pulse 95/min. Auscultation of the chest reveals coarse crackles at the right base consistent with continuing pneumonia.

Investigations:

Hb	12.1 g/dl
WCC	13.4 $\times 10^9$/l
PLT	231 $\times 10^9$/l
Na^+	139 mmol/l
K^+	4.9 mmol/l
Creatinine	145 µmol/l
Glucose	12.1 mmol/l
	MRSA sensitive to fusidic

Creatinine	145 µmol/l
Glucose	12.1 mmol/l
Sputum culture	MRSA sensitive to fusidic acid, gentamycin, vancomycin and rifampicin, resistant to co-amoxiclav

Which of the following is the most appropriate treatment?

A	Continue co-amoxiclav
B	Add oral fusidic acid
C	Switch to oral rifampicin
D	Switch to IV vancomycin
E	Add IV gentamycin

Sputum culture	MRSA sensitive to fusidic acid, gentamycin, vancomycin and rifampicin, resistant to co-amoxiclav

Which of the following is the most appropriate treatment?

Your answer was correct

A Continue co-amoxiclav

B Add oral fusidic acid

C Switch to oral rifampicin

D Switch to IV vancomycin

E Add IV gentamycin

Explanation

D Switch to IV vancomycin

D Switch to IV vancomycin

This man has nosocomial pneumonia, most likely acquired from his care home. The usual dose for vancomycin is 1 g BD 12-hourly, or 15 mg/kg. Vancomycin is effective as a single agent. It is only effective IV for this indication, due to poor absorption from the GI tract. It is implicated in nephrotoxicity and this patient already has a degree of renal impairment. Along with commencing vancomycin and careful monitoring during its use, other changes should be made to his medications and measures to prevent further decline in his renal function should be taken.

A Continue co-amoxiclav

The patient has failed to improve on this agent and the sputum culture has proven resistance to it. Persisting with this would be detrimental to the patient and increase the risk of antibiotic resistance.

B Add oral fusidic acid

Widespread use of topical fusidic acid has encouraged the development of *S. aureus* resistance and therefore the use of fusidic acid alone as an anti-staphylococcal agent is not recommended.

C Switch to oral rifampicin

Oral rifampicin is an option for MRSA, but it is associated with rapid development of resistance when used as a single agent.

E Add IV gentamycin

Although the sputum culture has shown that the MRSA in this case is sensitive to gentamicin, this patient already has a degree of kidney disease and therefore gentamicin is contraindicated. There would also be no sense in continuing the co-amoxiclav.

A 71-year-old patient undergoes radical surgery for an oesophageal adenocarcinoma with oesophagectomy, gastrectomy and splenectomy. Initially he makes a good recovery but you are asked to review him a few days later because he is increasingly short of breath. On examination BP is 142/72 mmHg and pulse 79/min and regular. There is reduced expansion of the left side of the chest and dullness to percussion over the left lung fields.

Investigations:

Hb	10.9 g/dl
WCC	7.9 x109/l
PLT	172 x109/l
Na^+	139 mmol/l
K^+	4.2 mmol/l
Creatinine	105 µmol/l
CXR	Large left sided pleural effusion
Diagnostic	milky coloured effusion

CXR	Large left sided pleural effusion
Diagnostic tap	milky coloured effusion, protein content 48g/l

Which of the following investigations on the pleural fluid is most likely to contribute to confirming the underlying diagnosis?

A	Triglycerides
B	LDH
C	Culture and sensitivity
D	pH
E	Glucose

23330

Submit

adenocarcinoma with oesophagectomy, gastrectomy and splenectomy. Initially he makes a good recovery but you are asked to review him a few days later because he is increasingly short of breath. On examination BP is 142/72 mmHg and pulse 79/min and regular. There is reduced expansion of the left side of the chest and dullness to percussion over the left lung fields.

Investigations:

Hb	10.9 g/dl
WCC	7.9 x109/l
PLT	172 x109/l
Na^+	139 mmol/l
K^+	4.2 mmol/l
Creatinine	105 µmol/l
CXR	Large left sided pleural effusion
Diagnostic tap	milky coloured effusion, protein content 48g/l

A Triglycerides

A triglyceride level greater than 1.2 mmol/l indicates a 99% chance that the fluid in the pleural space is chyle. This is likely to be a complication of surgery, with intra-operative damage to the duct or one of its tributaries. This can cause up to 4 l of fluid per day to leak into the pleural space, leading to the classic symptoms of a large pleural effusion. Initial management is conservative as the thoracic duct leak reduces spontaneously over a few days. If the effusion persists, imaging is needed, with referral for surgical ligation as indicated.

D pH

Testing the acidity of pleural fluid is used as a guide to treatment in para-pneumonic and malignant pleural effusions: a pH of <7.2 in the former indicates the need to drain, and <7.3 in the latter is associated with worse outcome. Neither is relevant in this

B LDH

LDH is used to distinguish an exudate from a transudate, and is therefore utilised to elucidate the cause of pleural effusion when heart failure versus inflammation or infection needs to be delineated. It is often done as part of the routine tests on pleural fluid, but will not be the most useful in confirming the underlying diagnosis.

C Culture and sensitivity

This would identify the organism in an infective pleural effusion but would not aid the diagnosis here.

E Glucose

Glucose levels are of value in para-pneumonic effusions and identify causes such as tuberculosis or malignancy.

23330

Rate this question:

A 73-year-old man with severe COPD managed with high-dose combination steroid and long-acting beta-agonist (LABA) inhaler is admitted to the Emergency Room. He has suffered increasing shortness of breath and a worsening cough over the past few days and is now completely unable to get his breath.

On examination he is pyrexial (38.2 °C) and there are chest signs consistent with both right-sided consolidation and pulmonary oedema. He looks tired and his respiratory rate has fallen to 13/min.

Investigations:

Hb	13.1 g/dl
WCC	10.1×10^9/l
PLT	295×10^9/l
Na^+	134 mmol/l
K^+	4.0 mmol/l
Creatinine	128 μmol/l
CRP	52 mg/l

Creatinine	128 µmol/l
CRP	52 mg/l
Chest X-ray	Right sided consolidation, with evidence of pulmonary oedema

Blood gases on 40% O_2:

pH	7.28
pO_2	9.3 kPa
pCO_2	6.7 kPa

Which of the following is the most appropriate way to manage his O_2 replacement?

A	Continue 40% O_2 by mask
B	Decrease inspired pO_2 to 28% by mask
C	Continuous positive airway

pH	7.28
pO_2	9.3 kPa
pCO_2	6.7 kPa

Which of the following is the most appropriate way to manage his O_2 replacement?

A	Continue 40% O_2 by mask
B	Decrease inspired pO_2 to 28% by mask
C	Continuous positive airway pressure (CPAP)
D	BiPAP
E	Increase inspired O_2 to 60% by mask

18669

Submit

D BiPAP

This patient has evidence of both LVF and right-sided pneumonia, a long history of COPD and is beginning to tire. The acidosis seen here can drive worsening respiratory muscle weakness, and risks increasing CO_2 retention further. BiPAP can reverse acidosis and significantly reduces progression to intubation and ventilation.

C Continuous positive airway pressure (CPAP)

BiPAP reduces the work of breathing during inspiration more than CPAP, and hence confers a potential advantage in COPD versus CPAP alone.

A Continue 40% O_2 by mask

Acidosis and CO_2 retention is potentially progressive, and continuing the status quo here with respect to O_2 replacement is considered inadequate.

A	Continue 40% O_2 by mask

Acidosis and CO_2 retention is potentially progressive, and continuing the status quo here with respect to O_2 replacement is considered inadequate.

B	Decrease inspired pO_2 to 28% by mask

This will drive hypoxia in addition to CO_2 retention, putting the patient at risk of cardiac rhythm disturbance and worsening pulmonary oedema.

E	Increase inspired O_2 to 60% by mask

Once acidosis is established, respiratory muscle weakness is progressive; increasing inspired O_2 won't reverse this and will at best lead to a minor, short-term incremental improvement in oxygenation.

18669

Rate this question:

A 27-year-old woman presents with right-sided pleuritic chest pain. She says the pain came on suddenly while lifting her son into his push-chair some 30 h earlier. Her only medication of note is the oral contraceptive pill, and she is usually fit and well. The symptoms have largely resolved and she has not taken paracetamol for some 6 h.

On examination, BP is 120/70 mmHg, pulse 80/min and regular, breath sounds seem normal and O_2 saturation on air is 97%.

Investigations:

Hb	12.9 g/dl
WCC	8.2 x10^9/l
PLT	192 x10^9/l
Na^+	138 mmol/l
K^+	4.3 mmol/l
Creatinine	110 µmol/l
CXR	Small right pneumothorax – rim less

K^+	4.3 mmol/l
Creatinine	110 µmol/l
CXR	Small right pneumothorax – rim less than 1cm

Which of the following is the most appropriate next course of action?

A	Send home with a plan for early review
B	Admit for observation and oxygen therapy
C	Admit for air aspiration
D	Admit for formal chest drain insertion
E	Admit for thoracoscopy

A Send home with a plan for early review

This woman has a pneumothorax which is more than 1 day old, and the chest X-ray indicates that the size is small. Given that her symptoms are improving, it would be most appropriate to discharge her with a plan to review in the respiratory clinic, or to return if her pain significantly worsens. Air aspiration might be considered for a larger pneumothorax, whereas formal chest drain insertion would be indicated if the pneumothorax was larger and there was a previous history of chest disease.

B Admit for observation and oxygen therapy

The patient's oxygen saturations are 97% on air, so there is no indication for supplemental oxygen. As this is a spontaneous pneumothorax in an otherwise well patient

In the case of a primary spontaneous pneumothorax, air aspiration is only indicated if the pneumothorax is >2 cm and/or the patient is breathless. If this fails to resolve the symptoms or the pneumothorax does not decrease in size, then formal chest drain insertion would be needed.

D	Admit for formal chest drain insertion

Formal chest drain insertion is only indicated in symptomatic/>2 cm primary spontaneous pneumothorax where aspiration has failed. It is first line if there is underlying lung disease and the patient is breathless or the pneumothorax is >2 cm in size.

E	Admit for thoracoscopy

Thoracoscopy is usually performed to investigate pleural disease or in preparation for pleurodesis. This patient has had a spontaneous pneumothorax and there is no current

A 69-year-old smoker presents for review. He has a 60-pack year history and has recently begun losing weight. In addition he has a chronic cough and is thirsty all the time. Past history of note includes two left carotid territory TIAs in the past year. Blood testing reveals mild hypercalcaemia, a left upper lobe lung mass is seen on chest X-ray and trans-bronchial biopsy confirms this to be a squamous cell carcinoma of the bronchus.

Investigations:

CT scan	Left upper lobe mass, with maximal dimension of 5.2cm. No evidence of lymph node, pleural or rib involvement
Spirometry	FEV_1 pre surgery less than 40% predicted
Carotid ultrasound	Left carotid 90% stenosis
Corrected calcium	2.7 mmol/l

Which of the following represents the

Carotid ultrasound	Left carotid 90% stenosis
Corrected calcium	2.7 mmol/l

Which of the following represents the most appropriate management in this case?

A	Refer for left pneumonectomy
B	Refer for left upper lobectomy
C	Refer for radiotherapy
D	Refer for chemotherapy
E	Refer for combined chemo- and radiotherapy

18548

Submit

TIAs in the past year. Blood testing reveals mild hypercalcaemia, a left upper lobe lung mass is seen on chest X-ray and trans-bronchial biopsy confirms this to be a squamous cell carcinoma of the bronchus.

Investigations:

CT scan	Left upper lobe mass, with maximal dimension of 5.2cm. No evidence of lymph node, pleural or rib involvement
Spirometry	FEV_1 pre surgery less than 40% predicted
Carotid ultrasound	Left carotid 90% stenosis
Corrected calcium	2.7 mmol/l

Which of the following represents the most appropriate management in this case?

Your answer was incorrect

E Refer for combined chemo- and radiotherapy

Unfortunately, this patient makes a very poor operative candidate due to his spirometry and carotid stenosis, which means he is at risk of not having sufficient residual lung function postoperatively, and of suffering a perioperative stroke. As such, radical radio- and chemotherapy is the intervention of choice.

A Refer for left pneumonectomy

Pneumonectomy is likely not survivable for this patient, given that his FEV_1 pre-surgery is less than 40% predicted.

B Refer for left upper lobectomy

Although left upper lobectomy may preserve sufficient lung function in this patient, his carotid atherosclerosis puts

Although left upper lobectomy may preserve sufficient lung function in this patient, his carotid atherosclerosis puts him at high risk of a perioperative stroke.

C	Refer for radiotherapy

Radiotherapy alone risks denying this patient access to chemotherapy for squamous cell carcinoma, which may significantly impact on his 2-year survival.

D	Refer for chemotherapy

Chemotherapy alone risks denying this patient access to the benefits of aggressive radiotherapy – for example, continuous hyperfractionated radiotherapy (CHART).

18548

Rate this question:

Next Question

A 54-year-old stonemason was referred to the clinic with a 3-year history of progressive breathlessness. He is an ex-smoker (40 pack-years) having stopped 14 years ago.

On examination at that time, he looked well, was not clubbed and there was no lymphadenopathy. His chest was hyper-expanded and he had basal inspiratory crackles.

His spirometry revealed:

FEV_1	38% predicted
FVC	70% predicted
KCO	55% predicted

His chest X-ray from the original referral is shown below:

Three years later he presents to the Emergency Department with increasing shortness of breath, cough and wheeze. Over the last year he has had recurrent chest infections and now has a cough productive of green sputum.

On examination: respiratory rate 30/min, temperature 36.2 °C, BP 160/100 mmHg, pulse 130/min, SpO_2 57% on air.

He is breathing through pursed lips. Auscultation of his chest reveals expiratory wheeze and crackles

throughout.

Blood gases on 28% oxygen:

pH	7.22
PO_2	7.9 kPa
PCO_2	8.0 kPa
Bicarbonate	20 mmol/l
Base excess	-3

Despite controlled oxygen, antibiotics, nebulisers and hydrocortisone, he fails to improve and is moved to ICU where he is started on non-invasive ventilation (inspiratory positive airway pressure, IPAP, 12 cm H_2O; and expiratory positive airway pressure, EPAP, 5 cm H_2O).

Initially, he does very well but he suddenly desaturates, although his BP remains stable.

On examination, the left side of his chest has reduced expansion, is hyper-resonant on percussion with diminished breath sounds. The trachea is not deviated

suddenly desaturates, although his BP remains stable.

On examination, the left side of his chest has reduced expansion, is hyper-resonant on percussion with diminished breath sounds. The trachea is not deviated.

What is the most appropriate step in his management?

A	Aspirate the left side of the chest with a large bore cannula to a maximum of 2 litres
B	Permanently stop non-invasive ventilation (NIV)
C	Insert a left-sided chest drain
D	Increase IPAP
E	Reduce EPAP

C Insert a left-sided chest drain

Silicosis is a fibrotic lung disease associated with inhalation of silica (silicon dioxide), which is highly fibrogenic. It is usually seen in quarrying and mining tunneling occupations and in sandblasters, ceramic workers, pottery workers and in stonemasons if the dust generated contains quartz.

Acute silicosis may present as an acute illness within 12 months of exposure to very heavy exposure and is characterised by dry cough and breathlessness. Patients deteriorate rapidly over one to two years and there is no effective treatment to slow the progression. Chronic silicosis runs a more chronic course as in this patient and is associated with a gradual worsening of breathlessness associated with restrictive lung function and a reduced transfer factor. Chronic silicosis is associated with silicotic nodule formation 3-5 mm in diameter which predominantly affect

the upper lobes.These nodules may coalesce and cause progressive massive fibrosis. Diagnosis is made on history of exposure and chest X-ray changes. The chest X-ray may show hilar eggshell calcification (pathognomonic of silicosis), as in the chest X-ray shown, with or without upper zone pulmonary nodules and fibrosis.

This man also has an element of chronic obstructive pulmonary disease (COPD) – mixed obstructive and restrictive spirometry (FEV1 more markedly reduced than FVC) and a history of smoking. He has presented with an exacerbation, made worse by the underlying silicosis, with a mixed respiratory and metabolic acidosis. He is commenced on a trial of non-invasive ventilation (NIV) and initially does well. He later desaturates as he develops a pneumothorax. The treatment of choice in any ventilated patient with a pneumothorax is insertion of a chest drain. If the patient had a tension pneumothorax, a chest drain should be inserted after initial

A Aspirate the left side of the chest with a large bore cannula to a maximum of 2 litres

He has no clinical evidence to suggest tension pneumothorax. He is on non invasive ventilation therefore a chest drain is required.

B Permanently stop non-invasive ventilation (NIV)

The priority is definitive treatment for his pneumothorax. It may only be necessary to discontinue the NIV for a short period.

D Increase IPAP

Increasing his IPAP will increase positive airway pressure and accelerate progression of his pneumothorax.

E Reduce EPAP

You are asked to comment on some arterial blood gas results. You understand the sample was taken from a 64-year-old patient attending one of the outpatient clinics.

Investigations:

pH	7.38
pCO_2	6.5 kPa
pO_2	8.0 kPa
HCO_3^-	38 mmol/l

Which of the following is the most likely underlying diagnosis?

A	Diuretic therapy
B	Bartter syndrome
C	Chronic COPD
D	Acute exacerbation of COPD
E	Conn syndrome

a 64-year-old patient attending one of the outpatient clinics.

Investigations:

pH	7.38
pCO_2	6.5 kPa
pO_2	8.0 kPa
HCO_3^-	38 mmol/l

Which of the following is the most likely underlying diagnosis?

A	Diuretic therapy
B	Bartter syndrome
C	Chronic COPD
D	Acute exacerbation of COPD
E	Conn syndrome

C Chronic COPD

This picture is consistent with chronic COPD, as exhibited by CO_2 retention in the presence of a pH within the normal range. What has occurred over time is renal compensation with conservation of bicarbonate, leading to the elevated HCO_3^- level of 38 mmol/l which is seen here.

A Diuretic therapy

Although diuretic therapy does result in a metabolic alkalosis, the raised bicarbonate seen here is as a result of compensation for chronic respiratory acidosis.

B Bartter syndrome

Bartter syndrome is associated with metabolic alkalosis and normal blood pressure. It often presents in infancy as a result of salt wasting. The elevated bicarbonate is inconsistent with Bartter as the underlying diagnosis.

as the underlying diagnosis.

D	Acute exacerbation of COPD

An acute exacerbation is likely to be associated with respiratory acidosis due to further CO_2 retention, and it's unlikely the patient would be attending the outpatient's clinic.

E	Conn syndrome

Conn syndrome is associated with metabolic alkalosis and hypertension, but not with the CO_2 retention seen here.

During an acute exacerbation a vicious circle occurs, with inadequate gas exchange leading to progressive hypoxia and CO_2 retention, resulting in worsening acidosis.

18627

Rate this question:

Next Question

An acutely unwell 62-year-old man is brought to the Emergency Department by his wife. They had returned from holiday to Spain three days ago. Apart from some mild flu-like symptoms, he had been otherwise well on returning to the United Kingdom. Over the last 24 hours, he had developed a severe headache, violent shivers and muscle pains. He also had some abdominal pain, with several episodes of diarrhoea. He had no significant past medical history and was on no medication. He had consumed some seafood on holiday, but his wife had eaten the same dish and had no symptoms.

On examination, he was confused and agitated, with a fever of 40 °C. His respiratory rate was 32 bpm, pulse 110 bpm and blood pressure 100/62 mmHg. His heart sounds were normal, and he had right basal crepitations on chest auscultation. His abdomen was soft and non-specifically tender, with scanty bowel sounds. There was no focal neurology.

Investigations:

WhatsApp • 9 messages from 3 chats • Just now
Mrcp2: Nassma Mrcp Chronic
+966 53 053 9397 (5 messages): بليز🙏🏻
Medo2 (3 messages): يم يم 😋😋

White cell count (WCC)	12.0×10^9/l
Platelets (PLT)	380×10^9/l
Sodium (Na^+)	122 mmol/l
Potassium (K^+)	3.2 mmol/l
Creatinine	170 μmol/l
Neutrophils	10.2×10^9/l
Lymphocytes	0.5×10^9/l
Monocytes	0.8×10^9/l
Eosinophils	0.4×10^9/l
Basophils	0.1×10^9/l
Gamma glutamyltransferase (GGT)	65 iu/l
Total Ca^{2+}	2.06 mmol/l
Bilirubin	16 μmol/l
Alanine aminotransferase	92 iu/l

Haemoglobin (Hb)	13.6 g/dl
White cell count (WCC)	12.0×10^9/l
Platelets (PLT)	380×10^9/l
Sodium (Na^+)	122 mmol/l
Potassium (K^+)	3.2 mmol/l
Creatinine	170 μmol/l
Neutrophils	10.2×10^9/l
Lymphocytes	0.5×10^9/l
Monocytes	0.8×10^9/l
Eosinophils	0.4×10^9/l
Basophils	0.1×10^9/l
Gamma glutamyltransferase (GGT)	65 iu/l
Total Ca^{2+}	2.06 mmol/l
Bilirubin	16 μmol/l
Alanine aminotransferase	92 iu/l

Alanine aminotransferase (ALT)	92 iu/l
Albumin	30 g/l
Alkaline phosphatase (ALP)	98 iu/l
Urea	7.6 mmol/l
Electrocardiogram (ECG)	Sinus tachycardia
Urinalysis	Blood+++, protein+
Chest X-ray	Shown below

By Antonella GrottolaComments to Author , Fabio Forghieri, Marisa Meacci, Anna Fabio, Lorena Pozzi, Patrizia Marchegiano, Mauro Codeluppi, Monica Morselli, Leonardo Potenza, Ambra Paolini, Valeria Coluccio, Mario Luppi, Fabio Rumpianesi, and Monica Pecorari [Public domain], via Wikimedia Commons

What is the most likely causative organism?

A	*Legionella pneumophila*
B	*Mycoplasma pneumoniae*
C	*Coxiella burnetii* (Q fever)
D	*Salmonella typhi*
E	*Chlamydia pneumoniae*

A *Legionella pneumophila*

This man has the typical features of legionnaires' disease. *Legionella* infection is said to be the cause of between 1 and 5% of adult pneumonias. The organism is a small coccobacillus, which is not seen on Gram staining and can only be cultured on special media. Infection is spread by the aerosol route and is usually acquired from contaminated air-conditioning or shower systems in institutions such as hotels and hospitals. Investigations may show hyponatraemia, normal or slightly elevated WCC with lymphopenia, hypoalbuminaemia and raised liver enzymes. Chest X-ray may show either unilobar or multilobar involvement and/or a pleural effusion. Haematuria and kidney disease can occur. Diagnosis is made by either a fourfold increase in antibody titre or a highly specific urine antigen test. Macrolides or quinolones with rifampicin are used in combination for patients with severe infection. Mortality is 15–30%

infection. Mortality is 15–30%, particularly in the elderly.

B	*Mycoplasma pneumoniae*

Mycoplasma is associated with a dry cough and pleuritic chest pain, and in some patients, it may be associated with haemolysis. It is less likely than *Legionella* to be associated with gastrointestinal disturbance and is treated with macrolides as the first-line intervention.

C	*Coxiella burnetii* (Q fever)

Coxiella burnetii is a cause of Q fever, with abrupt onset of fever, malaise, profuse sweating, severe headaches, muscle and joint pains, loss of appetite, dry cough, pleuritic chest pain and confusion.

D	*Salmonella typhi*

Typhoid fever presents with marked pyrexia and abdominal pain, with

A 55-year-old man presents to the Emergency Admission with dry cough and shortness of breath, which he has had for the past 4 days. He has recently returned from a winter holiday to an all-inclusive hotel in Spain. He also complains of some abdominal discomfort, nausea, vomiting, diarrhoea and a headache. He was previously well before he developed these symptoms and is not on any medication. On examination, he is unwell with a blood pressure of 123/67 mmHg, pulse of 92/min and a respiratory rate of 22/min. On auscultation of his chest, he has bi-basal crackles. His cardiovascular examination is unremarkable.

Investigations:

Hb	14.3 g/dl
WCC	16.1×10^9/l
PLT	278×10^9/l
Na^+	129 mmol/l
K^+	3.5 mmol/l

Na^+	129 mmol/l
K^+	3.5 mmol/l
Creatinine	112 μmol/l
Urea	8.1 mmol/l
CRP	69

What initial investigation is most likely to be helpful in elucidating the diagnosis?

A	Urinary immunoglobulin titres
B	Sputum microscopy and culture
C	Stool microscopy and culture
D	Bronchoalveolar lavage
E	Urinary antigen testing

E Urinary antigen testing

The most likely diagnosis is *Legionella pneumophila*. This usually infects middle-aged men, more severely in smokers, is twice as common in men and has an incubation period of 2–10 days. It causes moderate leucocytosis (neutrophilia, lymphopenia), hyponatraemia, deranged LFTs, proteinuria, haematuria and myoglobinuria. Diagnosis: urinary antigen testing, rise in specific IgM and IgG titres in the urine, blood and sputum or by direct immunofluorescent staining of the organism via bronchial washings. Treatment should be with a quinolone ideally, e.g. ciprofloxacin. Macrolides were used historically but quinolones have shown to have greater intracellular activity, greater lung penetration and reduced toxicity and are therefore preferred.

A Urinary immunoglobulin titres

This is not a commonly used

A Urinary immunoglobulin titres

This is not a commonly used investigation in infection.

B Sputum microscopy and culture

Patients with pneumonia should have a sputum MCS sample sent. *Legionella*, as this patient has, can be diagnosed from growth by a sputum sample, but that takes time and is therefore not as helpful as urinary antigen testing, which is much faster.

C Stool microscopy and culture

Despite the patient having diarrhoea, abdominal pain and a travel history, there are also respiratory signs and symptoms. This makes a respiratory pathogen far more likely than a gastrointestinal one, and so a stool sample is unlikely to provide any useful information.

A 56-year-old man is referred to the outpatients department with a 2-year history of increasing breathlessness and deteriorating exercise tolerance. He has a non-productive cough and always feels tired, so much so that he has needed to ask his wife to help him look after his pigeons, which he has been racing for many years. Over the last year he has lost about 1 stone in weight. He has a past medical history of asthma as a child. In his social history, he has had no history of recent foreign travel, except to France. He has always worked in a bank and is an ex-smoker who drinks minimal amounts of alcohol.

On examination, he is not clubbed. On auscultation of his chest, he has fine inspiratory crackles.

ABGs on air reveal:

pH	7.36
PO_2	7.4 kPa
PCO_2	4.7 kPa

Lung function tests:

Lung function tests:

FEV_1	70% predicted
FVC	64% predicted
KCO	53% predicted
TLCO	55% predicted

His chest X-ray is shown below:

What is the most likely diagnosis?

A	Bronchopulmonary aspergillosis

What is the most likely diagnosis?

A	Bronchopulmonary aspergillosis
B	Extrinsic allergic alveolitis
C	Idiopathic pulmonary fibrosis
D	Psittacosis
E	Sarcoidosis

70114

Submit

B Extrinsic allergic alveolitis

The patient has interstitial lung disease, demonstrated by the slowly progressive shortness of breath, type I hypoxia and restrictive lung function tests with reduced TLCO and KCO. In the chest radiograph there is reticular nodular shadowing. The diagnosis is extrinsic allergic alveolitis secondary to pigeons – bird fancier's lung. This is caused by inhaled avian serum proteins (usually IgA) present in the pigeon's feathers and excreta. It is a hypersensitivity pneumonitis caused by a specific immunological response to inhaled organic dusts. EAA may present either as an acute or a chronic disease. Acute disease develops several hours after exposure to high concentrations of the allergen. Breathlessness and flu-like symptoms occur sometimes with headaches, fever and myalgia. Symptoms usually resolve within 48 h. The patient has chronic disease, as it has progressed to interstitial lung disease with fibrosis.

The diagnosis of extrinsic allergic

The diagnosis of extrinsic allergic alveolitis is made by:

- Identifying a potential source of antigen
- Characteristic clinical features: this patient has chronic EAA and presents with similar features to pulmonary fibrosis – clubbing tends to occur later (idiopathic pulmonary fibrosis would typically be associated with clubbing)
- Characteristic radiology (usually upper lobe fibrosis)
- Lung function tests – showing a restrictive defect with reduced carbon monoxide gas transfer
- Demonstrating precipitating antibodies (precipitins) in the patient's serum
- Resolution or improvement of symptoms following avoidance of exposure to the cause

- Histology of lung tissue biopsy showing a mononuclear cell infiltrate with the formation of non-caseating granulomas
- Fluid obtained from bronchoalveloar lavage has a high lymphocyte count (typically >40%).

Treatment is avoidance of the antigen. Corticosteroids may improve recovery in acute attacks but do not seem to provide long-term benefit. They are not usually helpful once fibrosis has occurred.

Other causes of EAA include:

- Farmer's lung, due to *Micropolyspora faeni* and *Thermactinomyces* in mouldy hay, straw and grain
- Bagassosis due to *Thermactinomyces sacchari* in sugar cane processing
- Malt worker's lung due to

- Malt worker's lung due to *Aspergillus clavatus*
- Mushroom worker's lung due to thermophilic actinomycetes
- Ventilation and water-related contamination, e.g. due to thermophilic actinomycetes contaminating air-conditioning systems
- Veterinary workers and animal handlers
- Workers in milling and construction, e.g. wood dust pneumonitis due to *Alternaria* spp.

Causes of upper-zone fibrosis:

- Progressive massive fibrosis/coal worker's pneumoconiosis
- Ankylosing spondylitis
- Sarcoid/silicosis
- Tuberculosis
- Extrinsic allergic alveolitis

- Radiation (depending on site).

A	Bronchopulmonary aspergillosis

The chest radiograph shows diffuse infiltrates. CXR findings in ABPA are more likely to include proximal bronchiectasis, lobar collapse or discrete pulmonary infiltates.

C	Idiopathic pulmonary fibrosis

There is a clear precipitant to interstitial lung disease here.

D	Psittacosis

Psittacosis is an infection caused by *Chlamydia psittacosis*. It usually presents with a sudden onset of fever, dry cough and headache following a recent exposure to birds. Psittacosis is typically linked to parrots. The duration of symptoms is too long for psittacosis, and the chest X-ray

A 66-year-old woman is admitted for an elective hernia repair by the general surgeons with the procedure done under general anaesthetic. Of note in her past medical history is hypertension, for which she takes bendrofluazide 2.5 mg od. She is an ex-smoker of four years (40 pack years history).

Seven days after the operation, the patient's condition deteriorates and the surgeons ask for your advice. When directly questioned, she denies any cough, but feels mild breathlessness and fatigue. Her appetite is also depressed.

On examination, her temperature is 38 °C, blood pressure (BP) 135/90 mmHg, pulse 140 beats per minute, oxygen saturation 91% on air. Examination of the chest demonstrates coarse crepitations at the left lower zone with a dull percussion note. Abdominal examination is unremarkable. The operation scar looks clean, with no signs of infection. Chest X-ray reveals an ill-defined mass in the left lower zone in an area of consolidation. The

saturation 91% on air. Examination of the chest demonstrates coarse crepitations at the left lower zone with a dull percussion note. Abdominal examination is unremarkable. The operation scar looks clean, with no signs of infection. Chest X-ray reveals an ill-defined mass in the left lower zone in an area of consolidation. The opacity contains an air–fluid level.

What is the most likely diagnosis?

A	Aspiration pneumonia
B	Left lower lobe collapse
C	Pulmonary embolus
D	Lung abscess
E	Transudate pleural effusion

6357

Submit

a dull percussion note. Abdominal examination is unremarkable. The operation scar looks clean, with no signs of infection. Chest X-ray reveals an ill-defined mass in the left lower zone in an area of consolidation. The opacity contains an air–fluid level.

What is the most likely diagnosis?

Your answer was correct

A	Aspiration pneumonia
B	Left lower lobe collapse
C	Pulmonary embolus
D	Lung abscess
E	Transudate pleural effusion

Explanation

D	Lung abscess

D Lung abscess

All of the above options could account for deterioration postoperatively, but the clinical findings together with the CXR findings suggest lung abscess to be the most likely complication following the general anaesthetic. An air–fluid level is characteristic of a lung abscess. A contrast-enhanced computerised tomography (CT) scan would show the abscess more clearly.

A Aspiration pneumonia

Although aspiration pneumonia may cause the pyrexia and shortness of breath seen here, it's much more likely to be associated with right-sided consolidation.

B Left lower lobe collapse

The air–fluid level directs us more towards an abscess rather than pure collapse as the underlying cause of

B Left lower lobe collapse

The air-fluid level directs us more towards an abscess rather than pure collapse as the underlying cause of symptoms here.

C Pulmonary embolus

At least early on, significant CXR changes in PE would be unexpected. The air-fluid level also suggests an abscess rather than consolidation associated with lung infarction.

E Transudate pleural effusion

Transudate pleural effusions are more likely to appear as bilateral uncomplicated effusions rather than the picture seen here.

6357

Rate this question:

Next Question

10:54
tps://mypastest.pastest.com

A 45 year old woman is referred by the GP to the respiratory care clinic with shortness of breath of unknown origin. Spirometry results: KCO 60%, FEV_1/FVC 90%.

Which of the following is most likely to be the underlying cause of these pulmonary function test results?

A	Sarcoidosis
B	Severe kyphoscoliosis
C	Muscular dystrophy
D	Pneumonectomy
E	Bronchiectasis

A 45 year old woman is referred by the GP to the respiratory care clinic with shortness of breath of unknown origin. Spirometry results: KCO 60%, FEV_1/FVC 90%.

Which of the following is most likely to be the underlying cause of these pulmonary function test results?

Your answer was incorrect

A	Sarcoidosis
B	Severe kyphoscoliosis
C	Muscular dystrophy
D	Pneumonectomy
E	Bronchiectasis

Explanation

A	Sarcoidosis

A Sarcoidosis

A FEV_1/FVC of 90% indicates a restrictive cause. All the above diseases are evidenced by a restrictive pattern, except bronchiectasis which can result in an obstructive pattern. Only sarcoidosis would reduce the transfer coefficient as there is damage to the alveolar cells themselves. Other conditions where a reduction in KCO is reduced include those such is idiopathic pulmonary fibrosis, where there is also loss of alveolar function.

B Severe kyphoscoliosis

Abnormalities of the thoracic cage lead to a reduction in available lung volume for gas exchange but don't impact on the transfer coefficient.

C Muscular dystrophy

Similar to kyphoscoliosis, muscular dystrophy can lead to a restrictive lung

volume for gas exchange but don't impact on the transfer coefficient.

C	Muscular dystrophy

Similar to kyphoscoliosis, muscular dystrophy can lead to a restrictive lung pattern but doesn't impact on gas transfer.

D	Pneumonectomy

Pneumonectomy is most likely to have been performed for chronic bronchiectasis or lung cancer, both of which would be unusual in a 45-year-old woman and wouldn't be expected to impact on transfer factor in the remaining lung.

E	Bronchiectasis

Bronchiectasis produces an obstructive lung pattern on pulmonary function testing.

A 64-year-old man was referred to the clinic with insomnia. He complained of falling asleep during the day and having an early morning headache. He had a past history of a cholecystectomy and gout. He took no other regular medication. Examination was unremarkable. His weight and height were 120 kg and 175 cm, respectively.

Investigations:

Weight	120 kg
Height	175 cm
Hb	16.1 g/dl
WCC	6.4 $\times 10^9$/l
PLT	94 $\times 10^9$/l
MCV	101 fl
TSH	1.2 mU/l

What underlying cause should be suspected in this patient?

A Acromegaly

Height	175 cm
Hb	16.1 g/dl
WCC	6.4 $x10^9$/l
PLT	94 $x10^9$/l
MCV	101 fl
TSH	1.2 mU/l

What underlying cause should be suspected in this patient?

A Acromegaly

B Alcohol excess

C Hypothyroidism

D Cushing's disease

E Enlarged tonsils

A 64-year-old man was referred to the clinic with insomnia. He complained of falling asleep during the day and having an early morning headache. He had a past history of a cholecystectomy and gout. He took no other regular medication. Examination was unremarkable. His weight and height were 120 kg and 175 cm, respectively.

Investigations:

Weight	120 kg
Height	175 cm
Hb	16.1 g/dl
WCC	6.4 x10^9/l
PLT	94 x10^9/l
MCV	101 fl
TSH	1.2 mU/l

What underlying cause should be suspected in this patient?

B Alcohol excess

This patient has obstructive sleep apnoea (OSA) – insomnia, daytime somnolence, morning headache and obesity. Other symptoms include poor concentration during the day and partners may describe snoring followed by apnoeic episodes.

Diagnosis is made using the Epworth score – which is a measure of daytime somnolence – and sleep studies, which would show apnoeic/hypopnoeic episodes associated with desaturations, increase in heart rate and arousal from sleep. Treatment will depend on severity of symptoms and desaturations. In most cases, weight loss is advisable.

In mild OSA syndrome, a mandibular advancement device may control symptoms in mild to severe OSA syndrome nocturnal non-invasive ventilation (NIV) using continuous positive airway pressure (CPAP). Early morning headaches can be caused by a transient hypercapnia.This normal

morning headaches can be caused by a transient hypercapnia.This normal corrects to normal when the patient is awake.If a patient has hypercapnia in waking hours (and not just on an early morning blood gas) then overlap syndrome with obesity hypoventilation syndrome should be considered, although severe OSA may cause persistent hypercapnia in some case. Patients with persistent hypercapnia should be considered for bilevel positive airway pressure (eg BiPAP).

It is important to exclude underlying causes – this patient has a history of gout which, together with the raised MCV and low platelets, suggests alcohol consumption, which can precipitate the problem. Hypothyroidism, acromegaly and sedating drugs also need to be excluded. Retrognathia can cause OSA and large tonsils may obstruct the airway.

A	Acromegaly

Acromegaly is associated with OSA

A Acromegaly

Acromegaly is associated with OSA but there are no features in the history to suggest this over the more likely diagnosis of alcohol excess.

C Hypothyroidism

The patient's TSH is not raised, making this an unlikely diagnosis.

D Cushing's disease

Cushing's disease may be associated with OSA, but there are no features in the history or blood tests to suggest this as the more likely diagnosis versus alcohol excess.

E Enlarged tonsils

Enlarged tonsils may be associated with OSA, but the history and blood tests are more strongly suggestive of alcohol excess.

A 45-year-old woman is referred to the Respiratory Clinic for review. She has a history of SLE which is currently treated with hydroxychloroquine, but she continues to have multiple joint pains and a photosensitive rash. Over the past few weeks she has suffered from increasingly severe left-sided pleuritic chest pain and a dull chest ache. On examination her BP is 155/85 mmHg, with pulse 75/min and regular. There are decreased breath sounds at the left base on auscultation.

Investigations:

Hb	12.1 g/dl
WCC	10.5 $\times 10^9$/l
PLT	155 $\times 10^9$/l
Na^+	137 mmol/l
K^+	4.4 mmol/l
Creatinine	133 micromol/l
ESR	72 mm/1st hour
CXR	small left sided pleural effusion

K^+	4.4 mmol/l
Creatinine	133 micromol/l
ESR	72 mm/1st hour
CXR	small left sided pleural effusion

Which of the following is the most likely underlying cause of her chest symptoms?

A	Alveolar haemorrhage
B	Bronchiolitis obliterans
C	Chronic interstitial pneumonitis
D	Multiple pulmonary emboli
E	Pleuritis

E Pleuritis

Pleuritis is the most common manifestation of SLE-related lung disease; up to 60% of patients with SLE may report pleuritic chest pain, with or without concomitant pleural effusion. Pleural biopsies are rarely performed, although when they are, usually to exclude alternative diagnoses, non-specific inflammation is seen.

A Alveolar haemorrhage

Alveolar haemorrhage may be seen in SLE, although more rarely than pleuritis, and it is associated with interstitial shadowing rather than the pleural effusion seen here.

B Bronchiolitis obliterans

Bronchiolitis obliterans isn't classically associated with a pleural effusion – it is associated with hyperinflation, attenuation of vascular markings and

Bronchiolitis obliterans isn't classically associated with a pleural effusion – it is associated with hyperinflation, attenuation of vascular markings and reticulonodular shadowing in some cases.

C	Chronic interstitial pneumonitis

Chronic interstitial pneumonitis (CIP) is associated with more widespread inflammatory infiltrates and may be seen in up to 15% of individuals with SLE.

D	Multiple pulmonary emboli

Although pulmonary embolism is a possible differential, multiple pulmonary emboli would be unlikely to affect one segment of the lung only.

36027

Rate this question:

Next Question

A 55-year-old man presents to the Emergency Department with a dry cough and shortness of breath, which he has had for the past four days. He also complains of some abdominal discomfort, nausea, vomiting, diarrhoea and a headache. He was previously well before he developed these symptoms and is not on any medication, having recently returned from a convention in Spain.

On examination, he is unwell with a blood pressure of 123/67 mmHg, pulse of 92/min and a respiratory rate of 22/min. On auscultation of his chest, he has bi-basal crackles. He is pyrexial, 38.9 ºC. His cardiovascular examination is unremarkable.

Investigations:

Hb	14.3 g/dl
WCC	16.1×10^9/l
PLT	278×10^9 /l
Na^+	129 mmol/l
K^+	3.5 mmol/l

K^+	3.5 mmol/l
Creatinine	112 µmol/l
MCV	89 fl
Urea	10.0 mmol/l
CRP	169 mg/l
Urinalysis	protein ++, blood ++, glucose –

What is the likely diagnosis?

A	Streptococcal pneumoniae
B	Mycoplasma pneumoniae
C	Chlamydia pneumoniae
D	Legionella pneumophila
E	Viral pneumonia

D	Legionella pneumophila

Legionella pneumophilia usually infects middle-aged or older men, is more severe in smokers and has an incubation period of 2–10 days. Male to female ratio is 2:1. It causes moderate leucocytosis (neutrophilia, lymphopenia), hyponatraemia, deranged LFTs, proteinuria, haematuria and myoglobinuria. Infection may be acquired from infected water-based air-conditioning systems, hence the link to a convention in Spain. Both fluoroquinolones and clarithromycin have activity against the bacterium. Rifampicin may be used as combination therapy in severe disease.

A	Streptococcal pneumoniae

Streptococcal pneumonia is less likely to be associated with hyponatraemia or GI upset. The attendance at a convention is also a stronger pointer towards Legionnaire's.

B	Mycoplasma pneumoniae

Mycoplasma pneumonia tends to follow a more subacute course, with pleuritic chest pain and a dry cough both prominent features. Often appearance on chest X-ray is of a more severe pneumonia than first appears to be the case clinically.

C	Chlamydia pneumoniae

Chlamydial pneumonia, like mycoplasma, follows a more subacute course, and may be seen in patients who keep or are in close proximity to birds.

E	Viral pneumonia

Viral pneumonitis is more likely to be associated with generalised crackles on auscultation of the chest due to more widespread infiltration, and a lesser rise in CRP would be expected.

7508

A 64-year-old woman is referred with worsening COPD. She has a 10 pack-year smoking history. Her exercise tolerance has been steadily decreasing due to dyspnoea, and she is only able to walk a short distance on the flat now. FEV1 is now only 38% of predicted. She has tried PRN salbutamol but this has not helped.

Which of the following represents the most appropriate next step for this patient?

A	Switch salbutamol to PRN ipratropium
B	Start BD inhaled beclomethasone
C	Start oral prednisolone 5 mg OD
D	Start oral theophylline
E	Start regular high-dose inhaled fluticasone and

to walk a short distance on the flat now. FEV1 is now only 38% of predicted. She has tried PRN salbutamol but this has not helped.

Which of the following represents the most appropriate next step for this patient?

A	Switch salbutamol to PRN ipratropium
B	Start BD inhaled beclomethasone
C	Start oral prednisolone 5 mg OD
D	Start oral theophylline
E	Start regular high-dose inhaled fluticasone and inhaled long-acting β-agonist

E Start regular high-dose inhaled fluticasone and inhaled long-acting β-agonist

This patient has severe COPD. Recent studies have demonstrated that high-dose combination therapy with fluticasone and long-acting β-agonist may slow deterioration in FEV1. Low-dose fluticasone, beclomethasone, ipratropium and ventolin have no impact on the deterioration of lung function. The TORCH study (2007) showed a reduction in exacerbations with respect to dual LABA and inhaled steroid therapy. It did, however, show that the risk of pneumonia was increased in the treated group. Current NICE guidance states that for patients with FEV_1 <50%, either LABA with an inhaled corticosteroid (ICS) in a combination inhaler or LAMA should be offered.

A Switch salbutamol to PRN ipratropium

long-acting muscarinic antagonist should be offered in preference to four-times-daily short-acting muscarinic antagonists to people with stable COPD who remain breathless or have exacerbations despite using short-acting bronchodilators as required. Ipratropium is a short-acting muscarinic antagonist and is therefore not a suitable option here.

B	Start BD inhaled beclomethasone

NICE guidelines state that if FEV_1 is <50% predicted then give either LABA with an inhaled corticosteroid (ICS) in a combination inhaler, or LAMA. Corticosteroid monotherapy for COPD is not recommended.

C	Start oral prednisolone 5 mg OD

Prednisolone would be appropriate if the patient had presented acutely with an exacerbation of COPD (though a

C	Start oral prednisolone 5 mg OD

Prednisolone would be appropriate if the patient had presented acutely with an exacerbation of COPD (though a higher dose would be required), but NICE guidelines state that 'Maintenance use of oral corticosteroid therapy in COPD is not normally recommended'.

D	Start oral theophylline

NICE guidance states that 'Theophylline should only be used after a trial of short-acting bronchodilators and long-acting bronchodilators' and therefore does not represent the most appropriate next step for this patient.

6609

Rate this question:

Next Question

A 62-year-old man attends for a chest X-ray as part of a medical prior to emigrating to Australia. Unfortunately the chest X-ray reveals a number of rounded opacities predominantly in the left lung field, all less than 3 cm in diameter. He has had 5 kg of unintentional weight loss over the past year but no other history of note.

Which of the following features would be the strongest pointer to malignancy when the chest X-ray is reviewed?

A	Spiculated margin to one of the nodules, with distortion of neighbouring vessels
B	Smaller lesion size
C	A rounded appearance to the nodules
D	No enhancement with contrast on future CT thorax

diameter. He has had 5 kg of unintentional weight loss over the past year but no other history of note.

Which of the following features would be the strongest pointer to malignancy when the chest X-ray is reviewed?

A	Spiculated margin to one of the nodules, with distortion of neighbouring vessels
B	Smaller lesion size
C	A rounded appearance to the nodules
D	No enhancement with contrast on future CT thorax
E	Age 62 at presentation

32434

Submit

A Spiculated margin to one of the nodules, with distortion of neighbouring vessels

A spiculated margin to one of the nodules, particularly when there is distortion of neighbouring vessels, raises the possibility of malignancy. Associated ground-glass shadowing, or the presence of cavitation or pseudo-cavitation within the lesion, increases the chances of malignant disease. CT thorax to further characterise the lesions is indicated.

B Smaller lesion size

Lesions larger than 3 cm are more likely to be associated with underlying malignancy.

C A rounded appearance to the nodules

Rounded appearance to the nodules, implying organised growth, is less likely to be associated with an

malignancy.

C	A rounded appearance to the nodules

Rounded appearance to the nodules, implying organised growth, is less likely to be associated with an underlying malignancy.

D	No enhancement with contrast on future CT thorax

Enhancement of nodules with contrast on CT thorax increases the likelihood that they are malignant in origin.

E	Age 62 at presentation

Older age at presentation and history of smoking are associated with increased likelihood of malignancy.

32434

Rate this question:

Next Question

A 25-year-old man presents with left-sided pleuritic chest pain. It had come on suddenly 3 days previously. Initially he thought it was secondary to his workout in the gym. However, since it did not improve and he noticed that he was slightly more breathless than usual, he went to the Emergency Department. He has no significant past medical history. He is a smoker of 20/day. On examination he looked well. He was a tall, thin man and was not short of breath at rest. Examination was unremarkable except for a clicking sound which was synchronous with the heart sounds. CXR was unremarkable.

How would you best manage this patient?

A	Analgesia and discharge with follow-up in the clinic
B	Aspiration of chest
C	Chest drain insertion

medical history. He is a smoker of 20/day. On examination he looked well. He was a tall, thin man and was not short of breath at rest. Examination was unremarkable except for a clicking sound which was synchronous with the heart sounds. CXR was unremarkable.

How would you best manage this patient?

A	Analgesia and discharge with follow-up in the clinic
B	Aspiration of chest
C	Chest drain insertion
D	Non-steroidal anti-inflammatory drugs and admit patient
E	Refer to Cardiology Department

A Analgesia and discharge with follow-up in the clinic

A synchronous click with the heart sounds is a recognised sign of a small left apical pneumothorax. He is a tall thin man and a smoker, which are both risk factors for developing a pneumothorax. There is a strong association between pneumothoraces and smoking. The most recent British Thoracic Society (BTS) guidelines[1], suggest that if the postero-anterior (PA) chest X-ray is normal and a small pneumothorax is suspected, a lateral decubitus chest X-ray provides added information in up to 14% of cases. Expiratory films add little and are not recommended. The treatment of a primary pneumothorax in a non smoker with no evidence of underlying lung disease <50yrs old with a rim of air of <2 cm and no breathlessness is to discharge and follow up as an outpatient. Although this patient is a smoker there is nothing to suggest underlying lung disease and it is likely that his apical pneumothorax is too small to safely aspirate. Patients should

that his apical pneumothorax is too small to safely aspirate. Patients should be given analgesia if required and clear instructions to return if their symptoms get any worse.

[1]https://www.brit-thoracic.org.uk/document-library/clinical-information/pleural-disease/pleural-disease-guidelines-2010/appendix-3-spontaneous-pneumothorax-poster-pleural-disease-guideline/

B	Aspiration of chest

There is no clinical indication to admit this patient, although he should be followed up as an outpatient.

C	Chest drain insertion

There is no indication to aspirate a small pneumothorax in a young patient with no lung disease who is not breathless when reviewed.

D	Non-steroidal anti-

A 41-year-old man is referred to the hospital with a 1-week history of fever, malaise, increasing confusion, cough and breathlessness. The cough was initially dry but has become productive of yellow sputum in the last few days. He saw the GP 4 days ago, who prescribed amoxicillin with no benefit. His wife reports that he has also been suffering from abdominal pain and vomiting. He is a smoker of 20/day and works in a large law firm.

On examination he looks unwell and dehydrated. Temperature 39°C, BP 100/50 mmHg, pulse 120/min, respiratory rate 30/min, SpO_2 89% on air and Glasgow Coma Scale score 12. Auscultation of his chest reveals crackles in the left lower zone. His abdomen is generally tender on palpation. Examination is otherwise unremarkable. Urinalysis shows blood +++.

Investigations:

Hb	11.1 g/dl
WCC	10.6 x10^9/l

WCC	10.6 $x10^9$/l
Neutrophils	9.2 $x10^9$/l
PLT	151 $x10^9$/l
Na^+	127 mmol/l
K^+	3.4 mmol/l
Urea	9.0 mmol/l
Creatinine	120 micromol/l
Bilirubin	28 micromol/l
AST	220 U/l
ALT	190 U/l
ALP	140 U/l
Albumin	28 g/l
CRP	110 mg/l
Arterial blood gases (ABG) on air:	

Arterial blood gases (ABG) on air:	
pH	7.39
PCO_2	4.66 kPa
PO_2	7.3 kPa
Bicarbonate	21.4 mmol/l

Which organism is most likely to be responsible?

A	*Streptococcus pneumoniae*
B	*Legionella pneumophila*
C	*Mycoplasma pneumoniae*
D	*Coxiella burnetti*
E	*Chlamydia psittaci*

70073

B *Legionella pneumophila*

Legionella pneumophila is an aerobic, waterborne, Gram-negative, non-motile bacillus and has three epidemiological patterns:

- Outbreaks due to contaminated water-cooling systems, air-conditioning or showers. May be an occupational history or recent hotel holiday. Usually occurs in previously fit individuals. This man worked in a law firm and it is presumed this contains an air-conditioning system.
- Sporadic cases. Rare at extremes of age. Usually age 40–70. More common in men than in women. At-risk groups: smokers, chronic illness – especially chest disease, diabetes mellitus – and alcoholics.
- Outbreaks occurring in immunosuppressed individuals,

immunosuppressed individuals, e.g. those on corticosteroids.

pneumophila can cause two distinct disease entities:

- Legionnaires' disease, which is characterised by pneumonia.
- Pontiac fever, which is a milder, self-limiting illness consisting of fever and myalgia but no pneumonia.

2–15% of community-acquired pneumonias requiring hospitalisation globally are secondary to *L. pneumophila*. Mortality is 10% in treated patients who are not immunocompromised, rising to nearly 50% in nosocomial infections.

The incubation period of *L. pneumophila* is 2–10 days and it typically presents with flu-like symptoms – fevers, malaise, myalgia and headaches; the patient later develops a cough (often non-

develops a cough (often non-productive), breathlessness and confusion; 50% develop gastrointestinal symptoms (usually diarrhoea and vomiting). Patients may also experience pleuritic chest pain and episodes of haemoptysis.

Investigations may show: hyponatraemia (due to SIADH), lymphopenia, haematuria, proteinuria and hypoxia. Abnormal liver biochemistry (especially aminotransferases) and renal function occur in 50% of patients.

Diagnosis: the quickest way is to test for *Legionella* antigen in urine, and direct immunofluorescent staining of the organism in sputum, pleural fluid or bronchial washings. *L. pneumophila* is a fastidious organism. Gram stain does not usually reveal an organism and culture on standard media is often negative.

Chest X-ray usually shows lobar and then multilobar shadowing. Small pleural effusions may occur.

Treatment is with a macrolide. The

other clue in this question is the lack of response to beta-lactam antibiotics.

A	*Streptococcus pneumoniae*

Whilst *Streptococcus pneumoniae* is the commonest cause of community-acquired pneumonia (accounting for 50–70% of cases), this gentleman has features of an atypical pneumonia: initial dry cough, lack of response to beta-lactam antibiotics and gastrointestinal disturbance, in addition to hyponatraemia and deranged liver function. Herpetic cold sores are associated with pneumococcal pneumonia and may be specifically mentioned in an exam question relating to pneumococcal pneumonia.

C	*Mycoplasma pneumoniae*

Pneumonia caused by *Mycoplasma pneumoniae* typically affects young adults but usually has a longer prodrome of 2 weeks or more. White

agglutinins may be present in 50% of patients. Extra-pulmonary manifestations include pericarditis, myocarditis, rashes such as erythema multiforme and erythema nodosum, neurological pathology such as cranial or peripheral nerve palsies, and meningoencephalitis. Thrombocytopenia and haemolytic anaemia may occur, which are not suggested by the blood results given for this question.

D	*Coxiella burnetti*

Coxiella burnetii infection is associated with Q fever. In acute Q fever, 60% of patients are asymptomatic. The incubation period varies from 2 to 6 weeks, and there are three main clinical presentations:

- A self-limiting, flu-like illness with abrupt onset of fever, headache, myalgia and arthralgia. This presentation does not fit with the case described.

- Pneumonia (predominant in North America), usually of mild severity and often an incidental finding on CXR. If patients have symptoms, typically there will be a dry cough, breathlessness and pleuritic chest pain. Again this presentation does not fit with the case described.
- Hepatitis (predominant in Europe), usually with mild elevation of LFTs. Nausea and vomiting can occur but diarrhoea is rare. Whilst some elements of the case described fit with this, there are many other symptoms and results in the case which do not, making *L. pneumophila* more likely.

E	*Chlamydia psittaci*

Pneumonia due to *Chlamydia psittaci* is termed psittacosis. It is an infection

the case described fit with this, there are many other symptoms and results in the case which do not, making *L. pneumophila* more likely.

E	*Chlamydia psittaci*

Pneumonia due to *Chlamydia psittaci* is termed psittacosis. It is an infection acquired from avian reservoirs, and is classically associated with parrots. Incubation period is 5–14 days. Common symptoms include fever, chills and malaise, cough (usually dry), sore throat, mild pharyngitis, epistaxis and severe headache. Whilst some of these symptoms are described in this case, the lack of mention of avian contact, along with several features more in keeping with *L. pneumophila*, make this option unlikely.

70073

Rate this question:

The medical registrar on the grand round shows a chest X-ray of a man who has industrial lung disease.

The X-ray is shown below.

Of the known industrial lung dust diseases, exposure to which pathogen is most likely to give these findings?

A	Asbestos
B	Coal dust
C	Silica

Of the known industrial lung dust diseases, exposure to which pathogen is most likely to give these findings?

A	Asbestos
B	Coal dust
C	Silica
D	Beryllium
E	Iron dust

7623

Submit

B Coal dust

Coal dust exposure causes the occupational disease coal worker's pneumoconiosis (CWP). This can be classified into two subsets of disease.

Simple CWP generally leads to multiple small, round opacities, typically 1–10 mm in diameter, mostly in the upper lobes.

Complicated CWP shows much larger opacities in the upper lobes with associated fibrosis, particularly when there is coexisting smoking.

The X-ray in this case shows complicated CWP. Cases of CWP can be mistaken for malignancy, and further investigation following initial X-ray is always required.

C Silica

Silica exposure is associated with diffuse small nodules scattered throughout the lung fields and with eggshell calcification of hilar lymph

eggshell calcification of hilar lymph nodes.

A Asbestos

Asbestos exposure is associated with pleural plaques and fibrosis, which is more marked in the lower zones.

D Beryllium

Beryllium exposure presents with acute pneumonitis that may continue to a granulomatous reaction (compare to sarcoidosis) with lymphadenopathy.

E Iron dust

Iron dust exposure presents with small nodules which appear more dense than those associated with coal dust exposure, although there is less associated fibrosis.

7623

Rate this question:

6:25
https://www.google.com/sea
13

Radiopaedia

Coal workers' pneumoconiosis | Radiology Reference Article ...

Coal workers' pneumoconiosis | Radiology Reference Article | Radiopaedia.org

Images may be subject to copyright. Learn More

RELATED IMAGES SEE MORE

www.expressmedicals.co....

silicosis | Express Medicals | Express Medicals

Images may be subject to copyright. Learn More

RELATED IMAGES

SEE MORE

Asbestosis Imaging: Practice...
emedicine.medscape.com

emedicine.medscape.com

X Ray Computed Tomography Reveals The Response Of Root

4 ★★★★☆ (112)

New kind of 'X ray/CT vision'.Heterotopic ossification in the.General pediatric in training Examination.

RELATED IMAGES SEE MORE

Pulmonary fibrosis | Radiolog

Medscape eMedicine

Imaging in Silicosis and Coal Worker Pneumoconiosis: Overvi...

Radiography

Images may be subject to copyright. Learn More

RELATED IMAGES SEE MORE

6:26

Medscape eMedicine

Imaging in Silicosis and Coal Worker Pneumoconiosis: Overvi...

Silicosis with progressive massive fibrosis. Image

Images may be subject to copyright. Learn More

RELATED IMAGES SEE MORE

A 69-year-old gentleman was taken to the Emergency Department with a reduced GCS score; no history was available from relatives for the patient in A&E. The ambulance crew said that the call was put out by his wife as he had become increasingly short of breath. When they arrived he looked breathless and cyanosed. He denied any chest pain at that time.

On examination he had a GCS score of 10 (M5, V2, E3), respiratory rate 10/min, BP 130/70 mmHg, pulse 120/min, temperature 36.9°C, SaO_2 94% on 15 l oxygen. Auscultation of the chest revealed an expiratory wheeze throughout.

Heart sounds were normal and abdominal examination unremarkable. There was no obvious focal neurological abnormality and both plantars showed a flexor response.

Investigations:

Hb	17.3 g/dl
WCC	8.2 $\times 10^9$/l

WCC	8.2 x10⁹/l
PLT	400 x10⁹/l
MCV	84 fl
CRP	21 mg/l
ECG	Sinus tachycardia
CXR	Hyperinflated lung fields with low, flattened diaphragm; no evidence of a pneumothorax

In his notes you find a flow-volume curve from 1 year ago shown below.

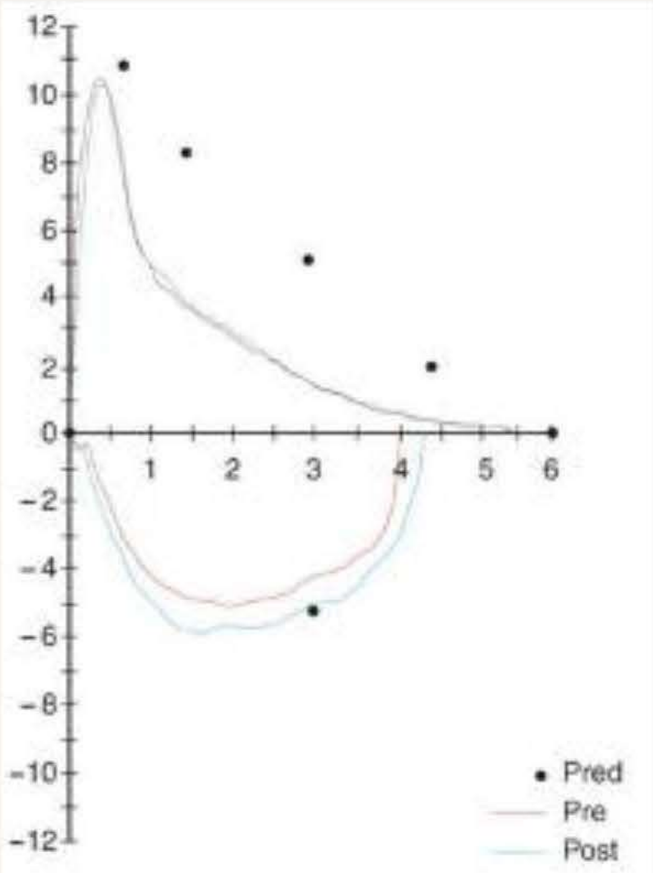

ABGs on high-flow oxygen on this admission:

ABGs on high-flow oxygen on this admission:	
pH	7.29
PCO_2	10.91 kPa
PO_2	12.39 kPa
Bicarbonate	40.6 mmol/l
Base excess	10.4

What does the arterial blood gas analysis show?

A	Mixed respiratory and metabolic acidosis
B	Acute respiratory acidosis
C	Metabolic acidosis
D	Acute on chronic respiratory

PCO_2	10.91 kPa
PO_2	12.39 kPa
Bicarbonate	40.6 mmol/l
Base excess	10.4

What does the arterial blood gas analysis show?

A	Mixed respiratory and metabolic acidosis
B	Acute respiratory acidosis
C	Metabolic acidosis
D	Acute on chronic respiratory acidosis
E	Metabolic alkalosis

D Acute on chronic respiratory acidosis

This patient has an acute on chronic respiratory acidosis. The high bicarbonate and base excess show that there is an underlying chronic respiratory acidosis with renal compensation. The acidosis and high CO_2 indicate an acute respiratory acidosis. If this was acute without a chronic element then, for a PCO_2 of 10.91 one would expect the pH to be lower.

The diagnosis of COPD is suggested from the CXR and flow-volume curve, which shows the classic shape for COPD. In some patients with COPD, respiratory drive depends on their degree of hypoxia, rather than the usual dependence on hypercapnia. Although it is important to prevent life-threatening hypoxia, uncontrolled oxygen therapy should be used with caution. This patient has a suppressed respiratory drive and carbon dioxide narcosis secondary to high-flow oxygen. He was able to tell the

narcosis secondary to high-flow oxygen. He was able to tell the ambulance crew that he had no chest pain at home; he was then given high-flow oxygen and his GCS dropped. Note on arrival at the Emergency Department that he scored 2/5 for verbal response and therefore would not be able to give any information. The immediate management is therefore to reduce the inspired oxygen concentration and repeat the arterial blood gases. If by doing this the patient becomes hypoxic or remains acidotic, they should then be referred for non-invasive ventilation.

A	Mixed respiratory and metabolic acidosis

The ABG would be expected to show low bicarbonate and base excess if a metabolic component to the acidosis were present.

B	Acute respiratory acidosis

In acute respiratory acidosis, one

An HIV-positive patient attends A+E with a history of a dry cough, shortness of breath and a fever. On investigation, his CD4 count is 50 cells/mm^3 and his oxygen levels drop after exercise. On further questioning, he admits that he has not been taking his medications recently.

Investigations:

Hb	14.5 g/dl
CD4	50/mm^3
PLT	210 × 10^9/l
pO2 on room air	9.5 kpa

Which of the following is the first-line treatment for this patient?

A	Prednisolone
B	Co-trimoxazole
C	Aciclovir

Hb	14.5 g/dl
CD4	50/mm^3
PLT	210 × 10^9/l
pO2 on room air	9.5 kpa

Which of the following is the first-line treatment for this patient?

A	Prednisolone
B	Co-trimoxazole
C	Aciclovir
D	Rifampicin, Isoniazid, Ethambutol and Pyrizinamide quadruple therapy
E	Ganciclovir

B Co-trimoxazole

Clinically he is infected with *Pneumocystis jirovecii*, which often presents with a dry cough in HIV-positive patients and other immunosuppressed patients, particularly after organ transplantation and prolonged use of immunosuppressants, and when the CD4 count is very low as here. On examination there is often tachycardia and tachypnoea, and there may be signs of cyanosis; however, the chest may even reveal no abnormality on examination in some patients. The chest X-ray may reveal bilateral hilar infiltrates or even cysts, but the pleura is rarely involved. If there is significant infiltration then crackles will be found on auscultation. Diagnosis is from pulmonary secretions or lung biopsy, looking for organisms using immunofluorescence or methenamine silver staining. The first-line treatment is with co-trimoxazole, but prednisolone can be added if the oxygen level is < 9.3 kPa

A	Prednisolone

The first-line treatment is with co-trimoxazole but prednisolone can be added as adjuvant therapy.

C	Aciclovir

This is used to treat herpes virus infections. Herpes simplex infection is associated with oral and genital mucous membrane ulceration. It can be associated with headache and neurological symptomatology in the case of simplex encephalitis/meningitis.

D	Rifampicin, Isoniazid, Ethambutol and Pyrizinamide quadruple therapy

This is the treatment for tuberculosis. It is associated with cough, fever, weight loss and night sweats, which are often described as 'drenching' in severity.

A 67-year-old man suffers a cardiac arrest on the ward shortly after coming back from the operating theatre. The arterial blood gas results taken 5 min after the cardiac arrest call are shown below.

Investigations:

pH	6.73
pCO_2	7.2 kPa
pO_2	6.2 kPa
Bicarbonate	14 mmol/l
Anion gap	24
Lactate	14 mmol/l

Which of the following best describes his acid-base disturbance?

A	Metabolic alkalosis
B	Compensated metabolic acidosis

Bicarbonate	14 mmol/l
Anion gap	24
Lactate	14 mmol/l

Which of the following best describes his acid-base disturbance?

A	Metabolic alkalosis
B	Compensated metabolic acidosis
C	Mixed metabolic and respiratory acidosis
D	Compensated respiratory acidosis
E	Compensated respiratory alkalosis

71077

Submit

C Mixed metabolic and respiratory acidosis

This patient has suffered a significant postoperative event, with raised lactate and low bicarbonate consistent with tissue hypoxia, and elevated CO_2 and decreased O_2 consistent with disordered gas exchange, for example due to postoperative pulmonary oedema.

A Metabolic alkalosis

The bicarbonate and pH are both low, ruling out a metabolic alkalosis.

B Compensated metabolic acidosis

Compensation implies increased respiratory effort to blow off CO_2. In this case the CO_2 is clearly elevated, meaning this is not compensated.

D Compensated respiratory

Compensation implies increased respiratory effort to blow off CO_2. In this case the CO_2 is clearly elevated, meaning this is not compensated.

D	Compensated respiratory acidosis

Compensated respiratory acidosis is seen in patients with COPD, where there is elevated bicarbonate. The fact that bicarbonate is low confirms that metabolic compensation has not occurred.

E	Compensated respiratory alkalosis

Respiratory alkalosis is seen in patients with aspirin overdose; however the elevated pCO_2 and low pH rule out respiratory alkalosis here.

71077

Rate this question:

Next Question

A 52-year-old farmer presented with a 5-month history of progressively worsening exertional dyspnoea and a persistent dry cough. He also described 6 kg weight loss and general malaise over this time period. He had no significant past medical history or family history. He was an ex-smoker who stopped 10 years ago and drank 10–12 units of alcohol per week.

On examination, he was dyspnoeic on minimal exertion, but not at rest. He was not cyanosed and there was no finger clubbing. He had a low-grade pyrexia of 37.4 °C. His heart sounds were normal, jugular venous pressure was not raised and there was no peripheral oedema. He had bilateral fine apical crepitations on chest auscultation. Abdominal and neurological examinations were unremarkable.

Investigations:

Hb	11.2 g/dl
WCC	12.4×10^9/l

WCC	12.4 × 10⁹/l
PLT	420 × 10^9/l
Na^+	140 mmol/l
K^+	3.6 mmol/l
Creatinine	110 μmol/l
Ca^{2+}	2.42 mmol/l
Bilirubin	14 μmol/l
Urea	6.1 mmol/l
ALT	32 IU/l
ALP	92 IU/l
GGT	44 IU/l
MCV	92 fl
ESR	60 mm/h
Pulmonary function tests	Restrictive defect, reduced gas transfer

A high-resolution computed tomography (CT) scan of the thorax is shown below:

What is the most likely diagnosis?

A	Sarcoidosis
B	Allergic bronchopulmonary aspergillosis
C	Idiopathic pulmonary fibrosis
D	Extrinsic allergic alveolitis
E	Pulmonary tuberculosis

A 52-year-old farmer presented with a 5-month history of progressively worsening exertional dyspnoea and a persistent dry cough. He also described 6 kg weight loss and general malaise over this time period. He had no significant past medical history or family history. He was an ex-smoker who stopped 10 years ago and drank 10–12 units of alcohol per week.

On examination, he was dyspnoeic on minimal exertion, but not at rest. He was not cyanosed and there was no finger clubbing. He had a low-grade pyrexia of 37.4 °C. His heart sounds were normal, jugular venous pressure was not raised and there was no peripheral oedema. He had bilateral fine apical crepitations on chest auscultation. Abdominal and neurological examinations were unremarkable.

Investigations:

Hb	11.2 g/dl
WCC	12.4 × 10^9/l

Pulmonary function tests	Restrictive defect, reduced gas transfer

A high-resolution computed tomography (CT) scan of the thorax is shown below:

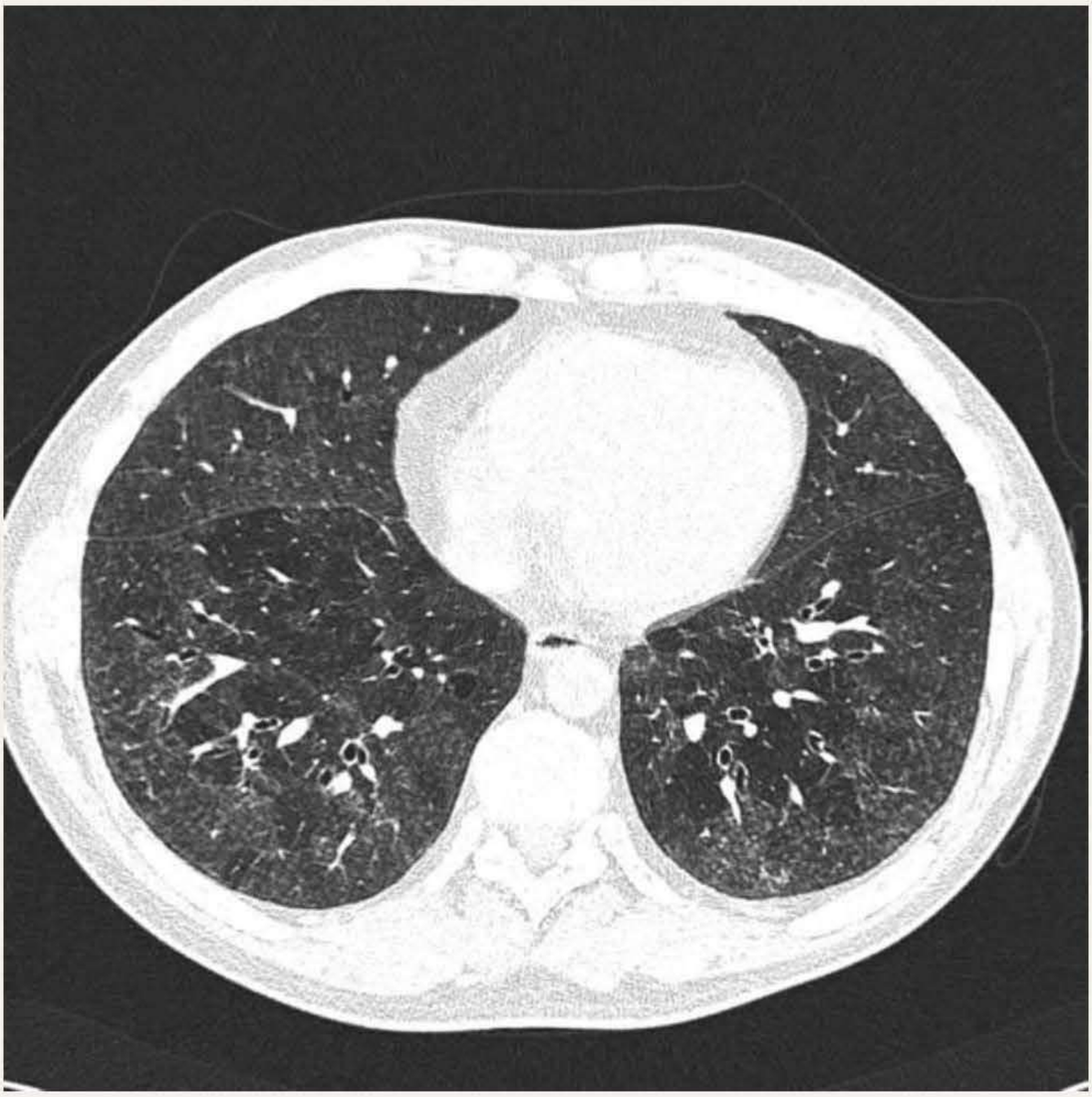

What is the most likely diagnosis?

Your answer was incorrect

A Sarcoidosis

D Extrinsic allergic alveolitis

This man has chronic extrinsic allergic alveolitis (EAA). This is caused by inhaled allergens provoking a hypersensitivity reaction in the lungs and resulting in diffuse inflammation involving the small airways and alveoli. In the chronic form, lymphocytic and giant cell infiltration can eventually lead to pulmonary fibrosis. Typical allergens include microbial spores, especially *Micropolyspora faeni* in mouldy hay, which causes farmer's lung, and avian proteins causing bird fancier's lung. The diagnosis can be made by a combination of imaging, respiratory function tests, serum precipitins and bronchoalveolar lavage. The computed tomography (CT) scan shows multiple small, ill-defined nodules throughout both lungs, with areas of ground-glass opacity in the basal segments. Treatment consists of avoidance of the causative allergen and long-term corticosteroid therapy. In some patients progression to end-stage fibrosis and respiratory failure

cannot be prevented.

C	Idiopathic pulmonary fibrosis

Idiopathic pulmonary fibrosis in this case is a diagnosis of exclusion. The occupation as a farmer means that disease related to exposure to inhaled allergens should be excluded first.

A	Sarcoidosis

Sarcoidosis is associated with progressive pulmonary fibrosis if there is marked disease activity which is left untreated, but other features associated with active sarcoid, such as erythema nodosum and elevated serum calcium, appear absent here.

B	Allergic bronchopulmonary aspergillosis

ABPA is associated with exaggerated asthma symptoms that do not respond to inhaled therapies, rather than the restrictive lung picture seen here.

6:44
https://www.google.com/sea
13

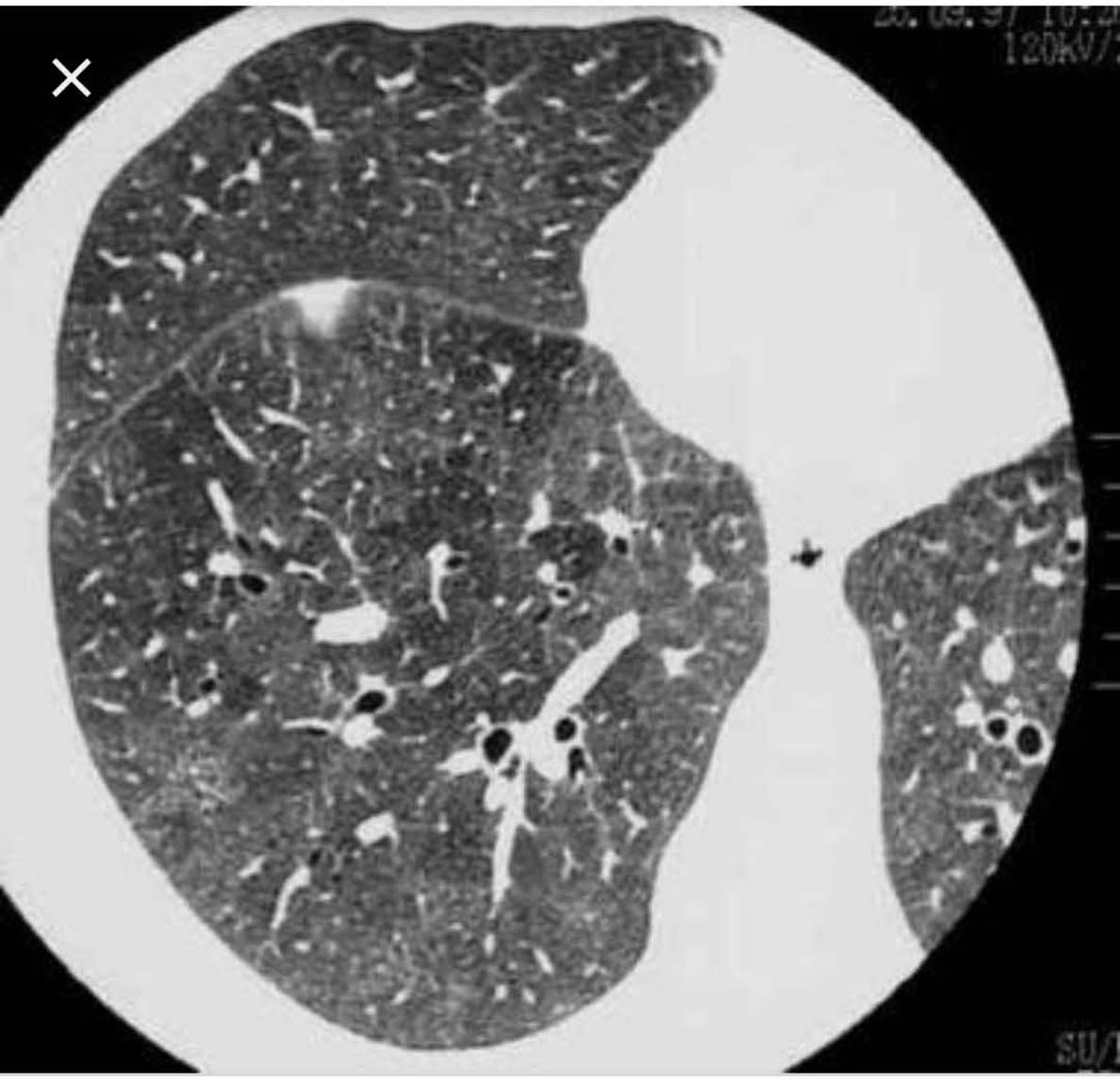

eMedicine (Medscape)

Extrinsic Allergic Alveolitis Imaging: Overview, Radiography...

Magnified high-resolution CT (HRCT) scan.

Images may be subject to copyright. Learn More

RELATED IMAGES SEE MORE

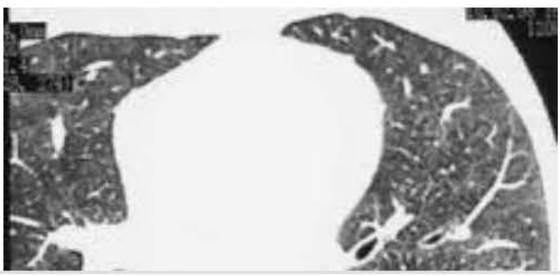

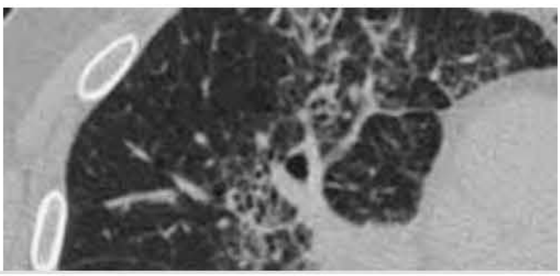

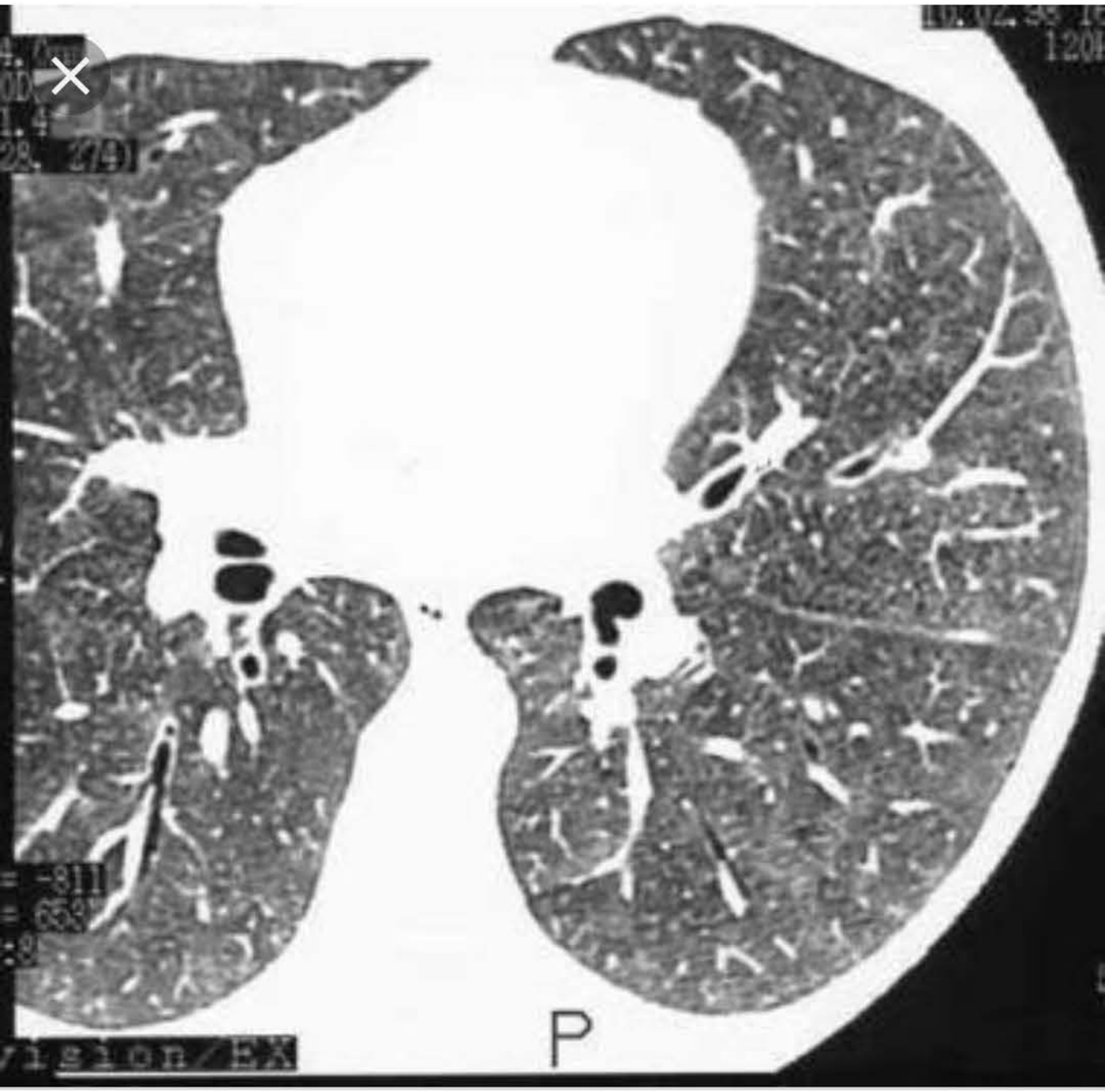

eMedicine (Medscape)

Extrinsic Allergic Alveolitis Imaging: Overview, Radiography...

High-resolution CT (HRCT) scan in a man with a cli

Images may be subject to copyright. Learn More

RELATED IMAGES SEE MORE

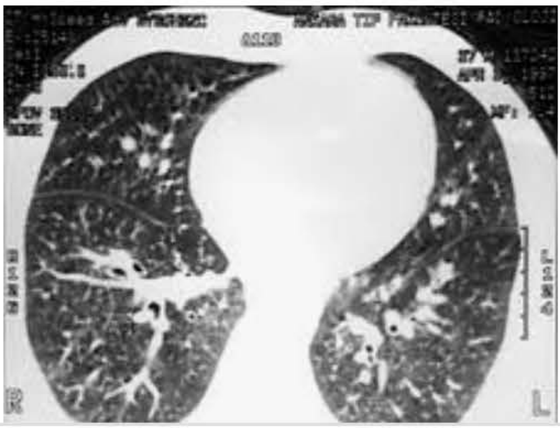

6:46
https://www.google.com/sea
13

European Respiratory Revi...

Imaging: how to recognise idiopathic pulmonary fibrosis | ...

Download figure ...

Images may be subject to copyright. Learn More

RELATED IMAGES SEE MORE

Thin-section CT of a current s...
researchgate.net

Figure 5 from Idiopathic Pulm...

6:46
https://www.google.com/sea
13

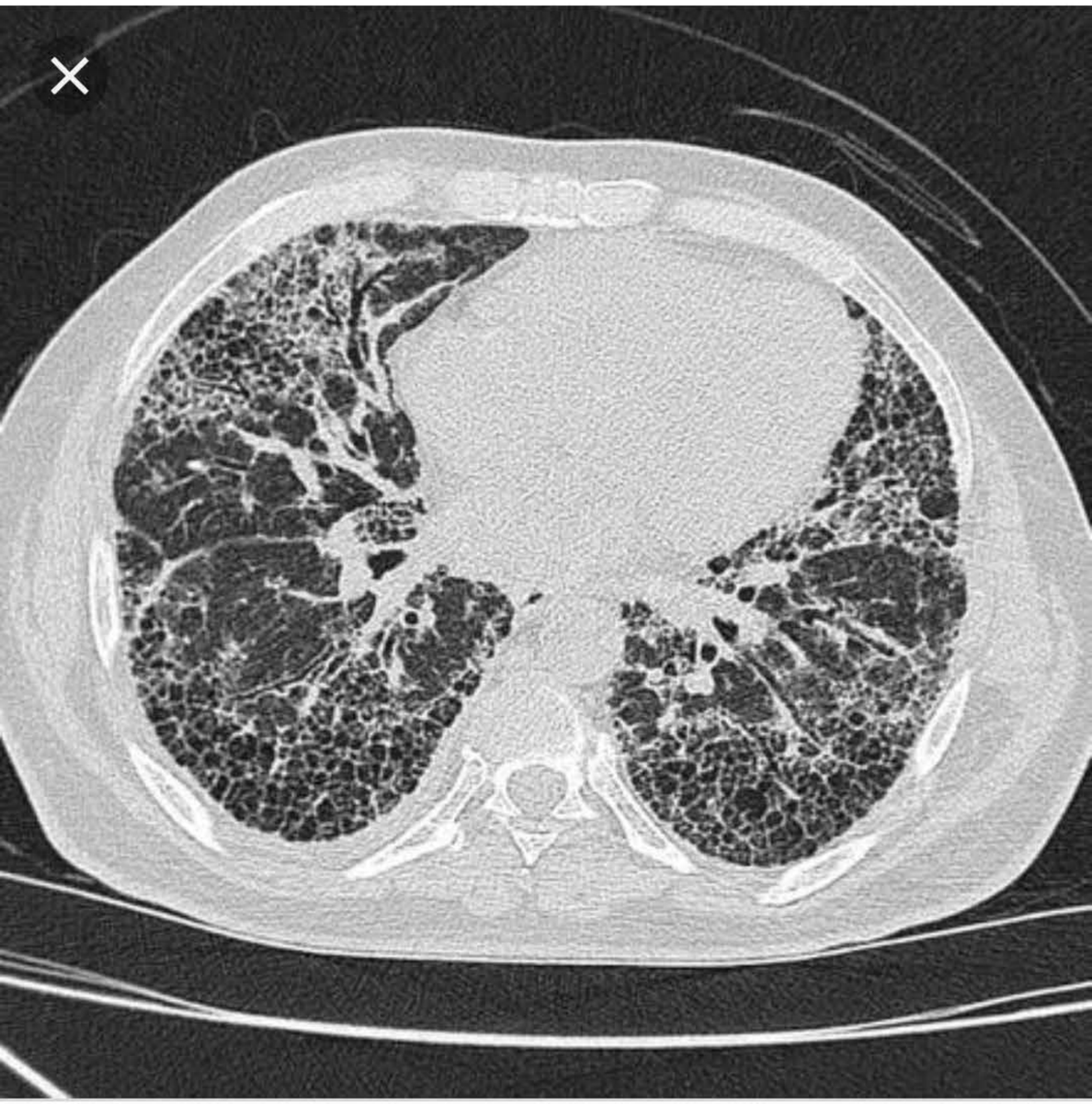

Radiopaedia

Idiopathic pulmonary fibrosis | Radiology Reference Article ...

Idiopathic pulmonary fibrosis | Radiology Reference Article | Radiopaedia.org

Images may be subject to copyright. Learn More

RELATED IMAGES SEE MORE

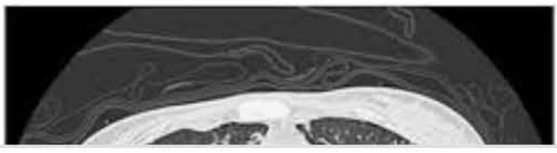

6:46

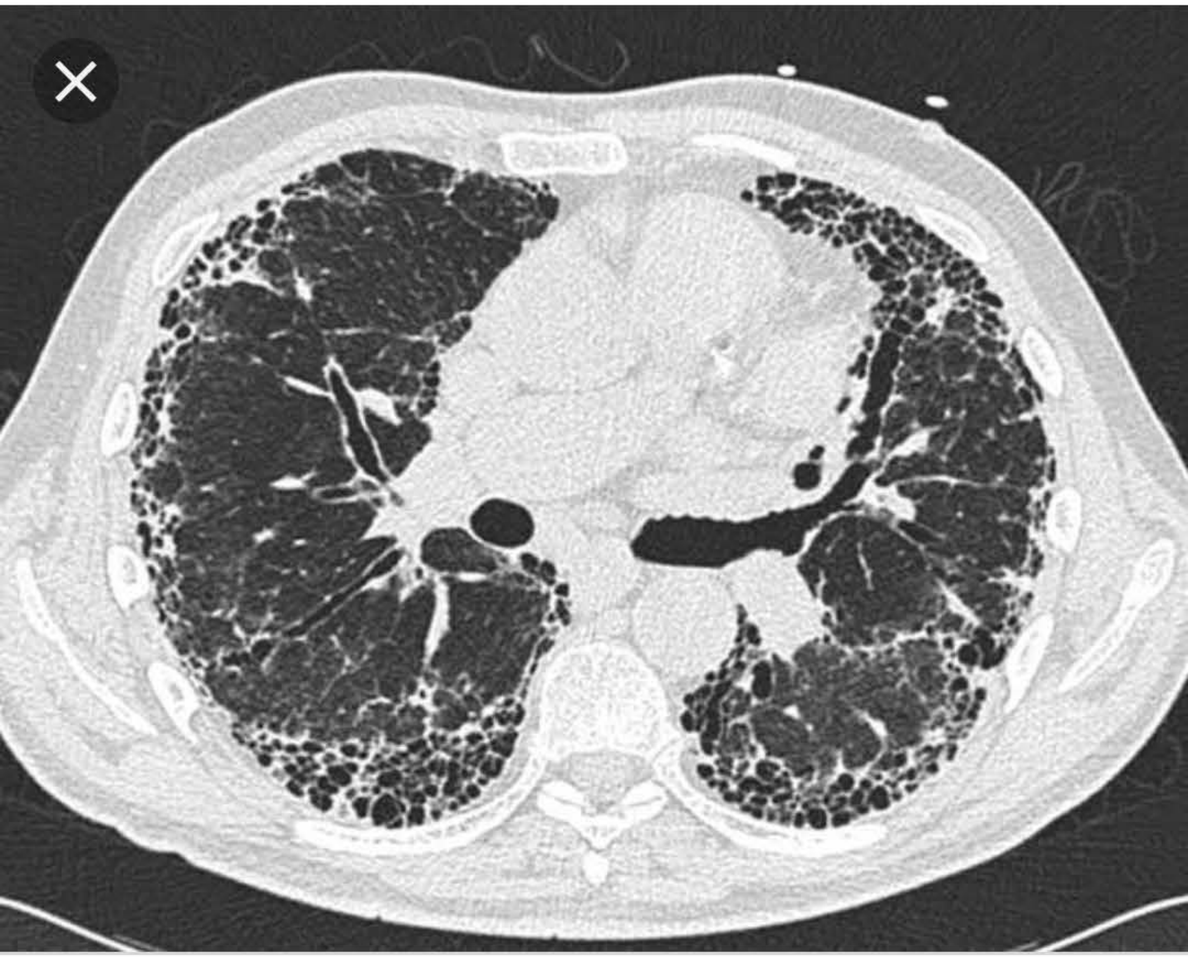

Pinterest

Idiopathic Pulmonary Fibrosis X-Ray | Idiopathic Pulmonary ...

Idiopathic Pulmonary Fibrosis X-Ray | Idiopathic Pulmonary Fibrosis Scan Photo Notice reticular pattern especially along pleura.

Images may be subject to copyright. Learn More

RELATED IMAGES SEE MORE

patientMpowerpatientMpowe...
info.patientmpower.com

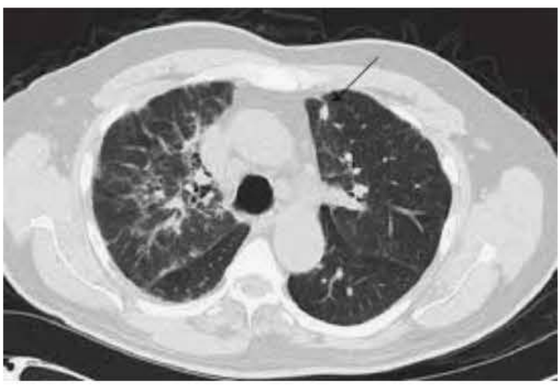

Computed tomography scan ...
researchgate.net

A 76-year-old woman presents to the Respiratory Clinic with symptoms of stridor and shortness of breath. She smokes 5 cigarettes per day and has done for 50 years. She has also noticed in increase in swelling around the front of her neck over the past few weeks. On examination her BP is 138/80 mmHg, pulse is 75/min and regular. You notice a hard mass extending from the left lobe of the thyroid and regional lymphadenopathy. Auscultation of the chest reveals significant transmitted upper airway sounds. Abdomen is soft and non tender.

Her flow volume loop is shown below:

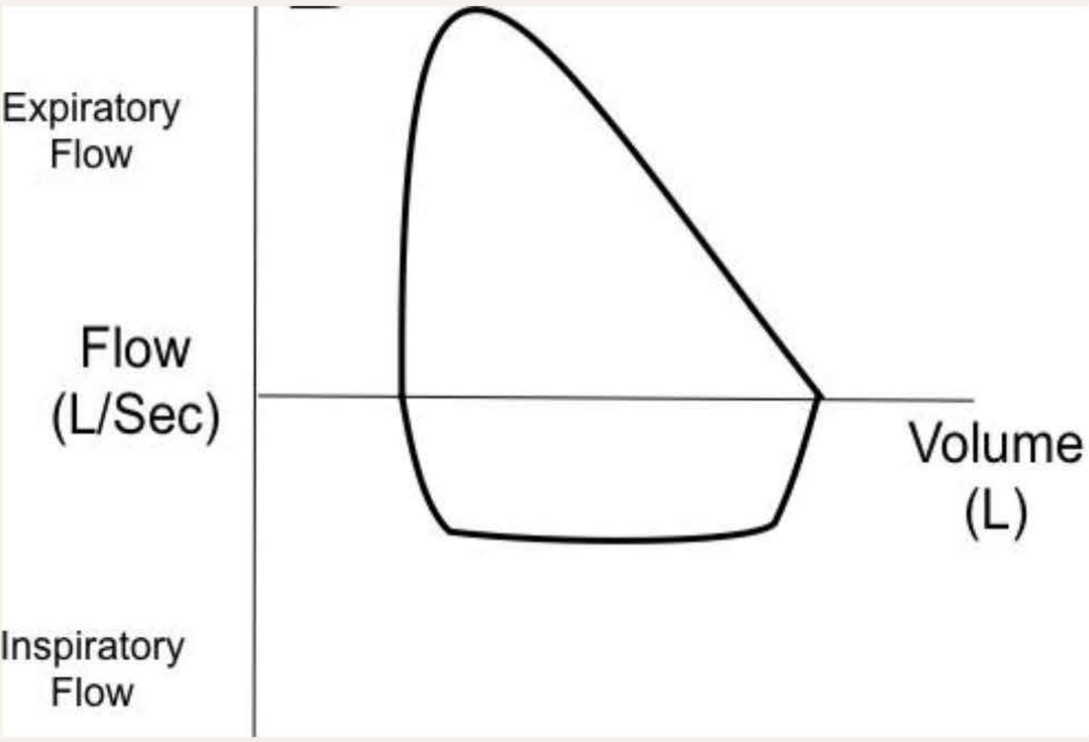

Which one of the following is the most

Which one of the following is the most likely cause of her shortness of breath?

A	Asthma
B	Emphysema
C	Left ventricular failure
D	Non-Hodgkin's lymphoma
E	Thyroid carcinoma

70415

Submit

6:51

Copy Share Select all Web search

E Thyroid carcinoma

The features here with a rapidly enlarging anterior neck mass, are very suggestive of a diagnosis of anaplastic thyroid carcinoma. Tumoural extension has led to extra-thoracic obstruction and the restriction of inspiratory flow seen here on the flow volume loop.

A Asthma

Obstructive lung disease results in a concave shape to the expiratory portion of the flow volume loop.

B Emphysema

Emphysema shows a similar concavity with respect to the expiratory portion of the loop, residual volume is elevated, and total lung capacity is also increased.

C Left ventricular failure

A 21-year-old woman with a history of well-controlled asthma on salmeterol/fluticasone combination inhaler goes out to an Indonesian restaurant with friends. While eating her main course she suddenly develops a wheeze, feels very light-headed and looks flushed in the face. A taxi is called, which brings her to the Emergency Room. On examination she looks unwell with a BP of 95/55 mmHg, a pulse of 100/min and severe wheeze on auscultation of the chest. She has significant facial flushing and a hives-like rash over her neck. She is given back-to-back salbutamol nebulisers, IV normal saline and IV hydrocortisone.

Which of the following additional therapies is appropriate for her?

A	IV adrenaline
B	IV aminophylline
C	IV magnesium

looks flushed in the face. A taxi is called, which brings her to the Emergency Room. On examination she looks unwell with a BP of 95/55 mmHg, a pulse of 100/min and severe wheeze on auscultation of the chest. She has significant facial flushing and a hives-like rash over her neck. She is given back-to-back salbutamol nebulisers, IV normal saline and IV hydrocortisone.

Which of the following additional therapies is appropriate for her?

A	IV adrenaline
B	IV aminophylline
C	IV magnesium
D	SC adrenalin
E	IM adrenaline

E IM adrenaline

This woman has presented with severe anaphylaxis, possibly due to something contained in her Indonesian meal. Immediate therapy centres on volume expansion with normal saline, IV corticosteroids to manage inflammation, IM adrenaline to assist blood pressure and relieve bronchoconstriction, and back-to-back salbutamol nebulisers. Common causes of anaphylaxis, particularly where a trip out for an oriental meal is involved, include allergies to shellfish proteins. Many referral centres have a batch of antigens that can be tested against, either via patch or RAST testing. Of course, she may require long-term anti-histamines or even an adrenaline auto-injector pen, but some attempt at least should be made to identify the precipitating antigen first. Desensitisation therapy may be particularly effective where bee or wasp stings precipitate the anaphylactic attack.

IV adrenalin has a greater propensity to lead to arrhythmia, and as such would not necessarily be the first choice ahead of the IM option.

B IV aminophylline

Aminophylline has limited added efficacy versus salbutamol alone with respect to bronchodilatation, and increases the risk of arrhythmia.

C IV magnesium

Although IV magnesium has a role in the treatment of acute asthma, it doesn't have a positive effect on blood pressure compared with IM adrenalin.

D SC adrenalin

SC adrenalin leads to local vasoconstriction, which can drive unpredictable absorption and potentially reduced systemic effects. As such, this is not advised.

A 39-year-old woman from Zimbabwe presents to the Emergency Department with a 5-day history of increasing shortness of breath and dry cough. She has a 1-day history of sudden onset of sharp chest pain which is worse on coughing, movement and deep inspiration. She describes having had night sweats and a poor appetite for 2 months. Her weight has decreased by about 5 kg. She has a past medical history of genital herpes and depression. She is married and has two children who live in Zimbabwe. She moved to England 2 years ago and has not travelled since. She is a smoker of 20/day and drinks little alcohol.

On examination, she looked unwell. Observations: temperature 38.3 °C, BP 108/72 mmHg, pulse 120/min, regular, respiratory rate 30/min. Auscultation of her chest revealed inspiratory crackles bi-basally.

Investigations:

Her chest X-ray is shown:

Hb	10.2 g/dl
WCC	6.4×10^9/l
Lymphocytes	1.0×10^9/l
PLT	439×10^9/l
Na^+	141 mmol/l
K^+	4.2 mmol/l
Creatinine	75 µmol/l
MCV	79 fl
CRP	73 mg/l
Urea	5.0 mmol/l
Glucose	5.7 mmol/l

Blood gases on 80% oxygen:

pH	7.46
PCO_2	3.44 kPa
PO_2	10.77 kPa
Bicarbonate	17.6 mmol/l
Base excess	−3.5

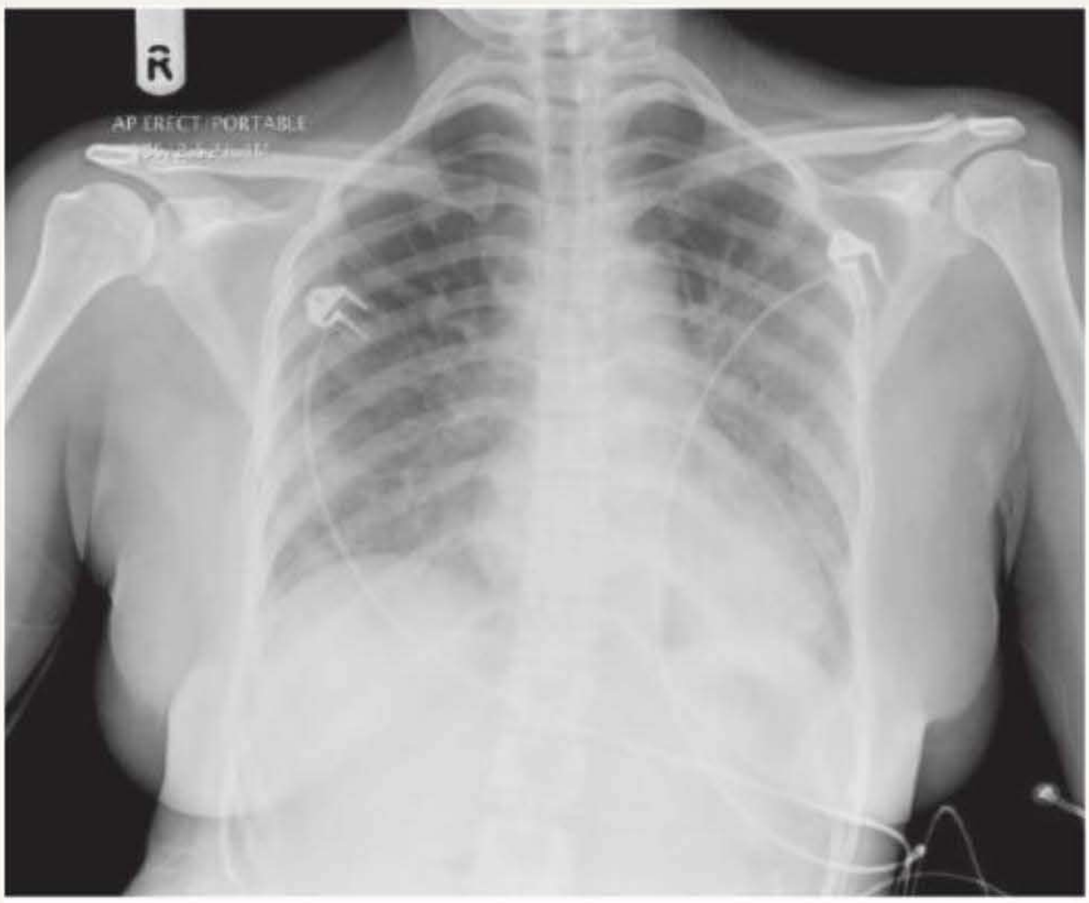

What is the most likely underlying cause?

A	Lymphoma
B	HIV
C	Bronchiectasis
D	Sarcoid
E	Common variable immune deficiency

B HIV

For the purpose of the exam, people who have lived abroad (especially Africa and South America), businessmen who work abroad, homosexuals and intravenous drug users, are more likely to have HIV.

This lady has HIV – the history of living in Zimbabwe and the low lymphocyte count are the clues. *Pneumocystis jirovecii* is the most common opportunistic infection to cause pneumonia in AIDS – especially when the CD4 count is <200/mm^3. It accounts for about 50% of cases of pneumonia in AIDS and 40% of all AIDS-defining illnesses.

Patients usually present with a fever, dry cough and breathlessness. They are usually hypoxic and desaturate on exercise.

In *P. jirovecii* pneumonia (PJP) the chest X-ray usually shows bilateral interstitial shadowing and cysts in the mid and lower zones. However, the CXR may be normal. Pneumothorax

interstitial shadowing and cysts in the mid and lower zones. However, the CXR may be normal. Pneumothorax (because the cysts rupture) may be present in up to 10%.

Diagnosis is now usually made by PCR of sputum or BAL fluid. Other diagnostic methods include staining induced sputum or BAL with indirect immunofluorescence with monoclonal antibodies.

Treatment is with high-flow oxygen and high-dose co-trimoxazole. Prednisolone should be added in severe cases (PO_2 <9.5 kPa).

A	Lymphoma

Given the patient is from sub-Saharan Africa and is presenting with a history suggestive of disseminated lung infection HIV is more a likely cause than lymphoma for the night sweats and weight loss.

C	Bronchiectasis

A 24-year-old man with a known history of cystic fibrosis (CF) presents as a self-admission to the ward. He has increased volume of purulent sputum, more shortness of breath and left-sided chest ache. On reviewing his history, you note that he is under consideration for the transplant list and has been colonised with *Pseudomonas* for some years. On examination he is pyrexial, with a temperature of 38.2°C, and appears very unwell with FEV_1 (forced expiratory volume in 1 s) having fallen to <75% of the previous recorded value. He is hypotensive and tachycardic, with a respiratory rate of 32/min. Gram-negative rod-shaped bacilli are isolated from his sputum.

Which of the following micro-organisms would fit best with this pattern of deterioration?

A	*Haemophilus influenzae*
B	*Staphylococcus aureus*

examination he is pyrexial, with a temperature of 38.2°C, and appears very unwell with FEV_1 (forced expiratory volume in 1 s) having fallen to <75% of the previous recorded value. He is hypotensive and tachycardic, with a respiratory rate of 32/min. Gram-negative rod-shaped bacilli are isolated from his sputum.

Which of the following micro-organisms would fit best with this pattern of deterioration?

A	*Haemophilus influenzae*
B	*Staphylococcus aureus*
C	*Streptococcus pneumoniae*
D	*Burkholderia cepacia*
E	*Stenotrophomonas multiphilia*

value. He is hypotensive and tachycardic, with a respiratory rate of 32/min. Gram-negative rod-shaped bacilli are isolated from his sputum.

Which of the following micro-organisms would fit best with this pattern of deterioration?

Your answer was incorrect

A	*Haemophilus influenzae*
B	*Staphylococcus aureus*
C	*Streptococcus pneumoniae*
D	*Burkholderia cepacia*
E	*Stenotrophomonas multiphilia*

Explanation

D	*Burkholderia cepacia*

D *Burkholderia cepacia*

Cepacia syndrome is associated with a severe worsening of respiratory symptoms in a small number of patients with cystic fibrosis. Thankfully the majority of patients colonised with *B. cepacia* do not, however, suffer a deterioration in their underlying condition. Cepacia is known to demonstrate resistance to multiple antibiotics including colomycin and aminoglycosides, and hence intravenous regimes involving two or more antibiotics such as ceftazidime and an aminoglycoside should be employed. Other possible combinations include ceftazidime and chloramphenicol or chloramphenicol and minocycline. Approximately 2.5–3.0% of cystic fibrosis individuals are thought to be colonised with *B. cepacia*, and measures are usually taken to limit colonisation where possible.

A *Haemophilus influenzae*

H. influenzae colonisation is frequently seen in patients with CF, where they are visible as Gram-negative cocci in sputum samples. Colonisation may be associated with acute exacerbations of cystic fibrosis.

B	*Staphylococcus aureus*

S. aureus is most likely to be associated with lower respiratory tract infection post-influenza. There is no apparent preceding episode of influenza reported here.

C	*Streptococcus pneumoniae*

S. pneumoniae is a Gram-positive coccus that does cause community-acquired pneumonia. However, the picture here with rapid deterioration and rod-shaped bacilli on sputum sampling is more consistent with *B. cepacia* syndrome.

E	*Stenotrophomonas multiphilia*

B *Staphylococcus aureus*

S. aureus is most likely to be associated with lower respiratory tract infection post-influenza. There is no apparent preceding episode of influenza reported here.

C *Streptococcus pneumoniae*

S. pneumoniae is a Gram-positive coccus that does cause community-acquired pneumonia. However, the picture here with rapid deterioration and rod-shaped bacilli on sputum sampling is more consistent with *B. cepacia* syndrome.

E *Stenotrophomonas multiphilia*

S. multiphilia colonises equipment used in mechanical ventilation and urinary catheters, and is a rare cause of opportunistic infection in these settings.

A 40-year-old nurse is admitted to the Medical Unit with a 2-day history of wheeze and exacerbation of asthma during peak pollen season. She has had this diagnosis for four years, since moving from her home in West Africa to the UK. She also has a history of hay fever since moving to the UK, and her daughter has developed asthma too. She has no other past medical history and is a non-smoker.

Investigations:

Hb	13.5 g/dl
WCC	10×10^9/l
Eosinophils	1.5×10^9/l
PLT	350×10^9/l

Her lung fields on the chest X-ray show minor patchy shadowing.

Which additional test would you opt to do to best exclude causes, other than asthma, of her wheeze and current exacerbation?

PLT	$350 \times 10^9/l$

Her lung fields on the chest X-ray show minor patchy shadowing.

Which additional test would you opt to do to best exclude causes, other than asthma, of her wheeze and current exacerbation?

A	Antinuclear antibody (ANA)
B	IgE
C	*Aspergillus*-specific IgE radioallergosorbant (RAST) level
D	Peak flow reading
E	Stool culture for ova, cysts and parasites

C	*Aspergillus*-specific IgE radioallergosorbant (RAST) level

Allergic bronchopulmonary aspergillosis (ABPA) should always be excluded in people with asthma who have a raised eosinophil count. ABPA is a hypersensitivity reaction to *Aspergillus* in people with asthma. This can be done by sputum culture or testing for atopy to the fungi with RAST, skin-prick tests or IgE specific to the fungi. *Aspergillus* precipitins testing looks for the presence of the antibody in the serum; if the result is highly positive, the patient may have invasive aspergillosis.

A	Antinuclear antibody (ANA)

Although eosinophil count can also be raised in Churg–Strauss syndrome, a small-to-medium-vessel vasculitis that presents usually in adults with asthma-like symptoms, this results in a positive pANCA, not ANA.

B	IgE

A high eosinophil count may be due to her atopy and the high pollen count, so her total IgE would also be raised.

D	Peak flow reading

Peak flow readings will likely be low in respiratory diseases like asthma, ABPA and Churg–Strauss, and therefore not good at excluding causes of wheeze and exacerbation.

E	Stool culture for ova, cysts and parasites

Stool culture may be positive in a parasitic cause of eosinophilia pneumonia, but this is unlikely given the very minor chest X-ray changes.

32448

Rate this question:

Next Question

A 67-year-old obese man with known mild chronic obstructive pulmonary disease (COPD) presents via ambulance. He is drowsy, and his wife is unable to rouse him. He usually has a good level of functioning, is able to walk to the local pub, uses a salbutamol inhaler only and continues to smoke five cigarettes per day.

You arrange a chest X-ray and blood gases:

pH	7.2
$p_a(CO_2)$	8.7 kPa
$p_a(O_2)$	6.3 kPa
$HCO3^-$	24.7 mmol/l

Which of the following best describes the blood gas results?

A	Mixed metabolic and respiratory acidosis
B	Metabolic acidosis

You arrange a chest X-ray and blood gases:

pH	7.2
$p_a(CO_2)$	8.7 kPa
$p_a(O_2)$	6.3 kPa
$HCO3^-$	24.7 mmol/l

Which of the following best describes the blood gas results?

A	Mixed metabolic and respiratory acidosis
B	Metabolic acidosis
C	Fully compensated respiratory acidosis
D	Respiratory acidosis
E	Metabolic alkalosis

D Respiratory acidosis

This is a respiratory acidosis, characterised by raised $p_a(CO_2)$, decreased pH and serum bicarbonate in the normal range. Exacerbation of COPD is a common cause, although the fact that the bicarbonate is in the normal range suggests that his deterioration has been too rapid to allow renal compensation. Pneumonia or abnormalities of the thoracic cage, such as those related to spina bifida, may also be responsible. In compliant patients, non-invasive positive pressure ventilation (NIPPV) may be an option. Alternatives include doxapram, a central respiratory stimulant. These would be combined with appropriate antimicrobial therapy. Unfortunately, many patients with COPD are unsuitable for formal intubation and ventilation.

A Mixed metabolic and respiratory acidosis

$HCO3^-$ is a base in nature. This means that an acidosis is metabolic if HCO3- is lower than the normal range. This is not the case as it is increased rather than lowered, indicating a compensatory mechanism for respiratory acidosis.

B	Metabolic acidosis

Metabolic acidosis can occur with an increased or normal anion gap. In an increased anion gap there is increased production or reduced excretion of organic acids, which causes $HCO3^-$ to fall. In a normal anion gap there is loss of bicarbonate or ingestion of H^+ ions, such as in diarrhoea and renal tubular acidosis. In this patient, the $HCO3^-$ is raised in acidosis, meaning that it is being produced in greater amounts as a compensatory mechanism.

C	Fully compensated respiratory acidosis

The acidosis is not fully compensated

Metabolic acidosis can occur with an increased or normal anion gap. In an increased anion gap there is increased production or reduced excretion of organic acids, which causes $HCO3^-$ to fall. In a normal anion gap there is loss of bicarbonate or ingestion of H^+ ions, such as in diarrhoea and renal tubular acidosis. In this patient, the $HCO3^-$ is raised in acidosis, meaning that it is being produced in greater amounts as a compensatory mechanism.

C	Fully compensated respiratory acidosis

The acidosis is not fully compensated as the pH is <7.35, and so the patient is still acidotic.

E	Metabolic alkalosis

Metabolic alkalosis can occur with vomiting, potassium depletion and ingestion of a base. It is seen with a pH < 7.45 and a high $HCO3^-$. This patient has a low pH.

A 67-year-old man presents with bilateral motor and sensory weakness of his lower limbs associated with urinary incontinence and constipation. Over the past few months he has suffered chronic back pain. Past history involves asthma, smoking of 30 pack years and chronic depression. Medication history includes amitriptyline and salbutamol. On examination he was unable to move off the trolley, his BP is 142/82 mmHg, with pulse 80/min and regular. There is a palpable bladder, a sensory level at T10 and bilateral lower limb power weakness.

Investigations:

Hb	12.6 g/dl
WCC	5.0×10^9/l
PLT	160×10^9/l
Ca^{2+}	2.9 mmol/l
ALT	145 U/l
ALP	352 U/l
GGT	50 U/l

ALP	352 U/l
GGT	50 U/l
Bilirubin	25 µmol/l
Albumin	30 g/l
MCV	80 fl

Which of the following is the investigation of choice in this case?

A	Magnetic resonance imaging (MRI) scan of the spine
B	Computed tomography (CT) scan of the spine
C	Plain X-ray of the spine
D	Bone scan of the spine
E	Skeletal survey

A Magnetic resonance imaging (MRI) scan of the spine

Symptoms and signs are consistent with spinal cord compression, and MRI scanning is useful to demonstrate the level of compression. It also provides valuable information as to the nature of the lesion leading to compression, and hence potential therapeutic options.

B Computed tomography (CT) scan of the spine

This is less reliable than MRI but can be used if the latter is unavailable.

C Plain X-ray of the spine

Although it will show evidence of metastases (smoking, raised calcium and ALP with possible bronchial carcinoma as primary), it will not show the degree of spinal cord compression.

Although it will show evidence of metastases (smoking, raised calcium and ALP with possible bronchial carcinoma as primary), it will not show the degree of spinal cord compression.

D	Bone scan of the spine

Like plain X-ray, it will show metastases but not spinal cord compression.

E	Skeletal survey

This will not show spinal cord involvement, which is the investigation required to determine level of compression in keeping with the symptoms and signs that gentleman presents with. Skeletal survey is useful in conditions such as multiple myeloma, metastatic bone disease or Paget's disease.

32443

Rate this question:

ambulance. On examination, the patient is drowsy with a Glasgow Coma Scale of 12/15, blood pressure of 154/90, pulse of 98/min and a respiratory rate of 28/min. The patient has already been started on high flow oxygen via a non-rebreather mask.

What single initial investigation would be most helpful in determining the prognosis for this patient?

A	Toxicology screen
B	Carboxyhaemoglobin (COHb)
C	12-lead electrocardiogram
D	Full blood count (FBC), U and E, creatine phosphokinase (CPK) and cardiac enzymes
E	Oxygen saturation with pulse oximeter

B Carboxyhaemoglobin (COHb)

COHb levels have prognostic implications in carbon monoxide poisoning, the diagnosis here:

<30% causes only headaches and dizziness, 40–60% produces syncope, tachypnoea, tachycardia and fits, >60% causes increasing risk of cardiorespiratory failure and death.

Apply a tight-fitting non-rebreather mask and give 100% oxygen. If the patient is comatose, she should be intubated and ventilated with 100% oxygen. Hyperbaric oxygen will shorten the wash-out of COHb.

A Toxicology screen

A toxicology screen would be useful in a drowsy patient, to look for barbiturates or benzodiazepines as a cause of sedation, but it is very unlikely in a 72-year-old woman who collapsed at home. Had empty blister packets been found, benzodiazepine overdose

Patients who have collapsed should have an ECG, and in general it is useful in establishing an ECG baseline. This patient is unlikely to have a diagnosis revealed by an ECG as there is no evidence of chest pain, suggesting a large ischaemic event, abnormal heart rate suggesting arrhythmia, or cardiopulmonary compromise.

D	Full blood count (FBC), U and E, creatine phosphokinase (CPK) and cardiac enzymes

Whilst these investigations may be helpful, they are unlikely to lead to a diagnosis for this patient.

E	Oxygen saturation with pulse oximeter

Pulse oximetry cannot distinguish between haemoglobin bound to oxygen and that bound to carbon monoxide. Therefore it would give a falsely reassuring oxygenation reading.

You review a 48-year-old man in the Respiratory Clinic. He is diagnosed with tuberculosis and you want to start quadruple anti-tuberculous therapy. He is very concerned about the potential side effects of therapy. Previous history of note includes abnormal liver function tests and a history of alcohol abuse; most recently he has been diagnosed with type 2 diabetes. Recent ALT was 65 U/l, creatinine 102 μmol/l and a liver biopsy has shown early hepatic fibrosis.

Which of the following is important to bear in mind when managing his anti-tuberculous therapy?

A	Ethambutol should not be given
B	Isoniazid should not be given
C	Pyrazinamide should not be given
D	Pyridoxine should not be

side effects of therapy. Previous history of note includes abnormal liver function tests and a history of alcohol abuse; most recently he has been diagnosed with type 2 diabetes. Recent ALT was 65 U/l, creatinine 102 μmol/l and a liver biopsy has shown early hepatic fibrosis.

Which of the following is important to bear in mind when managing his anti-tuberculous therapy?

A	Ethambutol should not be given
B	Isoniazid should not be given
C	Pyrazinamide should not be given
D	Pyridoxine should not be given
E	Rifampicin should not be given

quadruple anti-tuberculous therapy. He is very concerned about the potential side effects of therapy. Previous history of note includes abnormal liver function tests and a history of alcohol abuse; most recently he has been diagnosed with type 2 diabetes. Recent ALT was 65 U/l, creatinine 102 µmol/l and a liver biopsy has shown early hepatic fibrosis.

Which of the following is important to bear in mind when managing his anti-tuberculous therapy?

Your answer was incorrect

A	Ethambutol should not be given
B	Isoniazid should not be given
C	Pyrazinamide should not be given
D	Pyridoxine should not be given

C Pyrazinamide should not be given

Drug-induced hepatitis associated with anti-tuberculous therapy can be fatal; for this reason pyrazinamide should not be used in patients with known chronic liver disease, even if it is thought to be stable. Baseline and regular monitoring of liver function should be undertaken in patients on anti-tuberculous therapy, and where there is a history of chronic liver disease it is advised that this is weekly for the first two weeks and then two-weekly thereafter.

B Isoniazid should not be given

In stable liver disease it is acceptable to give up to two drugs which may have hepatotoxicity, usually isoniazid and rifampicin only.

A Ethambutol should not be given

given

Ethambutol can accumulate in patients with chronic kidney disease, leading to optic neuropathy, and therefore should be given at a lower dose. The creatinine of 102 μmol/l seen here means that dose adjustment is not required.

D	Pyridoxine should not be given

Pyridoxine should be given in addition to isoniazid in those with renal impairment, to prevent peripheral neuropathy.

E	Rifampicin should not be given

Rifampicin should only be avoided where there is decompensated liver disease and in those patients taking sulphonylureas where it may reduce the effectiveness of these agents.

A 62-year-old male smoker of 30 cigarettes per day presents with symptoms of cough and dyspnoea, accompanied by vague, non-specific chest pain. There is general malaise and joint pain, which has been relieved by using diclofenac as required (prn), and his cough has not been improved by a salbutamol inhaler prn.

His chest X-ray is shown below.

By James Heilman, MD [CC BY-SA 4.0 (https://creativecommons.org/licenses/by-sa/4.0)], from Wikimedia Commons

There is a non-specific increase in

By James Heilman, MD [CC BY-SA 4.0 (https://creativecommons.org/licenses/by-sa/4.0)], from Wikimedia Commons

There is a non-specific increase in immunoglobulins and raised serum angiotensin-converting enzyme (ACE) level.

Which of the following diagnoses fits best with this clinical picture?

A	Bronchial carcinoma
B	Sarcoidosis
C	Multiple myeloma
D	Lymphoma
E	Tuberculosis

B Sarcoidosis

In this case, there is evidence of bilateral hilar lymphadenopathy on chest X-ray. More than 90% of patients with sarcoidosis have abnormal chest X-ray findings. Both immunoglobulins and serum ACE levels can be raised in active sarcoidosis. Renal function, liver function tests and serum calcium levels should also be assessed at initial appointment. High-resolution computed tomography (CT) scanning may demonstrate micronodules in a subpleural and bronchoalveolar distribution, fissural nodularity and bronchial distortion. Irregular linear opacities and ground-glass shadowing may also be seen. Air trapping due to endobronchial granulomas and 'honeycombing' may also be seen. Kveim tests are no longer performed due to perceived danger of infection. If the CT scan is diagnostic, then mediastinoscopy, bronchoscopy or biopsies can often be avoided.

A Bronchial carcinoma

Bronchial carcinoma is more usually associated with a unilateral mass seen on chest X-ray, with lymph node spread to the ipsilateral side.

C Multiple myeloma

Multiple myeloma is associated with the appearance of a paraprotein band on immunoglobulin testing, rather than the non-specific increases seen here.

D Lymphoma

Lymphoma is associated with hilar lymphadenopathy, although the dry cough and elevated serum ACE level are more consistent with a diagnosis of sarcoidosis.

E Tuberculosis

Tuberculosis is less likely, given the hilar lymphadenopathy is bilateral and no risk factors for tuberculosis are proffered in the clinical scenario.

A 56-year-old man presented to his GP with a 4-week history of feeling generally unwell. He described nasal congestion, with pain under his left eye, flu-like symptoms and lethargy. His GP made a diagnosis of sinusitis and gave him a course of antibiotics. He did not improve and developed breathlessness, cough and chest pain. He had previously been fit and his only past medical history was of an inguinal hernia repair 10 years previously. He worked in a shop. He smoked 10 cigarettes a day and drank about 10 units of alcohol a week. He was taking no regular medication.

On examination he looked unwell and pale. Observations: respiratory rate 34/min, BP 140/85 mmHg, pulse 120 bpm, temperature 36.6 °C. He had crusting of his nasal septum. His JVP was not elevated, and heart sounds were normal. Auscultation of his chest revealed fine crackles bilaterally. His abdominal and neurological examinations were unremarkable.

Urinalysis:

Protein	++
Blood	++
Nitrites	-
Leucocytes	-
Bilirubin	-

Haematology:

Hb	8.1 g/dl
WBC	6.3×10^9/l
MCV	81 fl
Platelets	510×10^9/l
ESR	114 mm/1st hour
CRP	45 mg/l
Na^+	142 mmol/l
K^+	5.9 mmol/l
Urea	21 mmol/l
Creatinine	341 micromol/l
Bilirubin	18 micromol/l

AST	31 U/l
ALP	191 U/l
Albumin	34 g/l

Spirometry:

FEV1	72% predicted
FVC	77% predicted
KCO	122% predicted

His CXR is shown below:

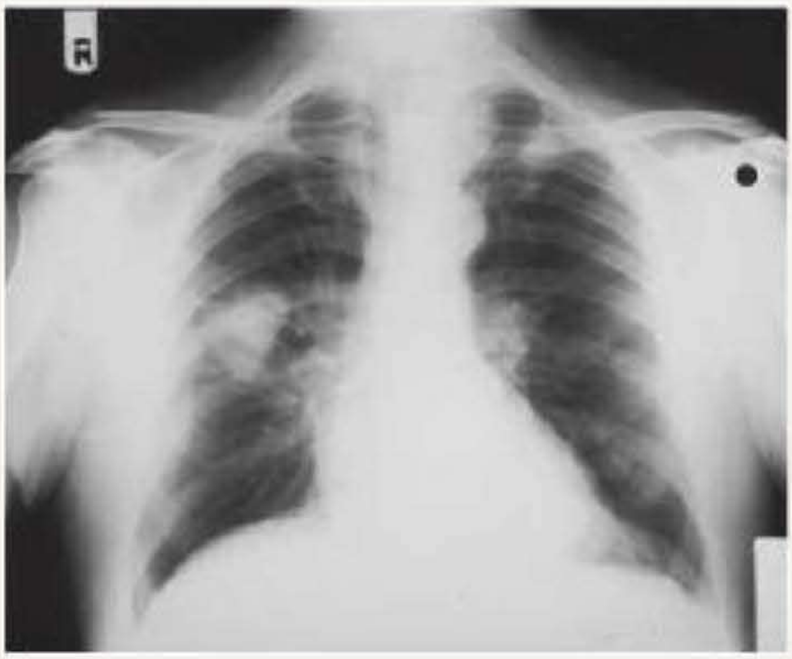

Which investigation would help make a diagnosis?

A	c-ANCA (anti-proteinase 3)

Which investigation would help make a diagnosis?

A	c-ANCA (anti-proteinase 3)
B	Anti-GBM antibodies
C	p-ANCA (anti-myeloperoxidase)
D	*Legionella* antigen
E	Echocardiogram

A c-ANCA (anti-proteinase 3)

This is a question about pulmonary–renal syndromes (for a list see below). The raised KCO and the CXR should make one think of pulmonary haemorrhage. This should narrow the diagnosis down to a vasculitis, Goodpasture's syndrome and SLE.

This patient has granulomatosis with polyangiitis (previously known as Wegener's granulomatosis). The clinical diagnosis is made by the triad of upper respiratory tract (nasal polyps and sinusitis), lower respiratory tract and renal involvement. It is a small-vessel vasculitis associated with granulomas.

The diagnosis of granulomatosis with polyangiitisis is suggested by a positive c-ANCA with the presence of an antibody to proteinase-3. The chest radiograph usually shows single or multiple nodules, fixed infiltrates or cavities. Pleural effusions and pulmonary infiltrates may also been seen. Diagnosis is usually confirmed with a biopsy. If untreated the median

with a biopsy. If untreated the median survival is just five months. Treatment is with intravenous cyclophosphamide and prednisolone, which reduces mortality to approximately 10%. Plasmapheresis would be first-line treatment if the disease was primarily renal.

Causes of pulmonary–renal syndromes:

- Systemic diseases:
  Granulomatosis with polyangiitis
  Microscopic polyangiitis
  Goodpasture syndrome
  Systemic lupus erythematosus
  Polyarteritis nodosa
  Henoch–Schönlein purpura
  Churg–Strauss syndrome (renal involvement less common)
- Primary pulmonary disease:
  Legionella pneumonia and interstitial nephritis
  Bacterial pneumonia with renal compromise secondary to sepsis
- Others:
  Pulmonary oedema with acute

Systemic lupus erythematosus
Polyarteritis nodosa
Henoch–Schönlein purpura
Churg–Strauss syndrome (renal involvement less common)

- Primary pulmonary disease:
  Legionella pneumonia and interstitial nephritis
  Bacterial pneumonia with renal compromise secondary to sepsis
- Others:
  Pulmonary oedema with acute kidney disease
  Uraemic pneumonitis
  Right-sided bacterial endocarditis – may cause pulmonary embolic lesions and glomerulonephritis
  Iatrogenic glomerulonephritis with ciprofloxacin, e.g. in patients given ciprofloxacin for cystic fibrosis.

8:09

Medscape eMedicine

Granulomatosis with polyangiitis (Wegener Granulomatosis) Tho...

Wegener granulomatosis, thoracic. Thick-walled rig

Images may be subject to copyright. Learn More

RELATED IMAGES SEE MORE

Figure 4 from Wegener's gran...
semanticscholar.org

A chest x-ray on admission s...
researchgate.net

8:09

Radiopaedia

Wegener granulomatosis | Radiology Case | Radiopaedia.o...

Sign up

Images may be subject to copyright. Learn More

RELATED IMAGES

SEE MORE

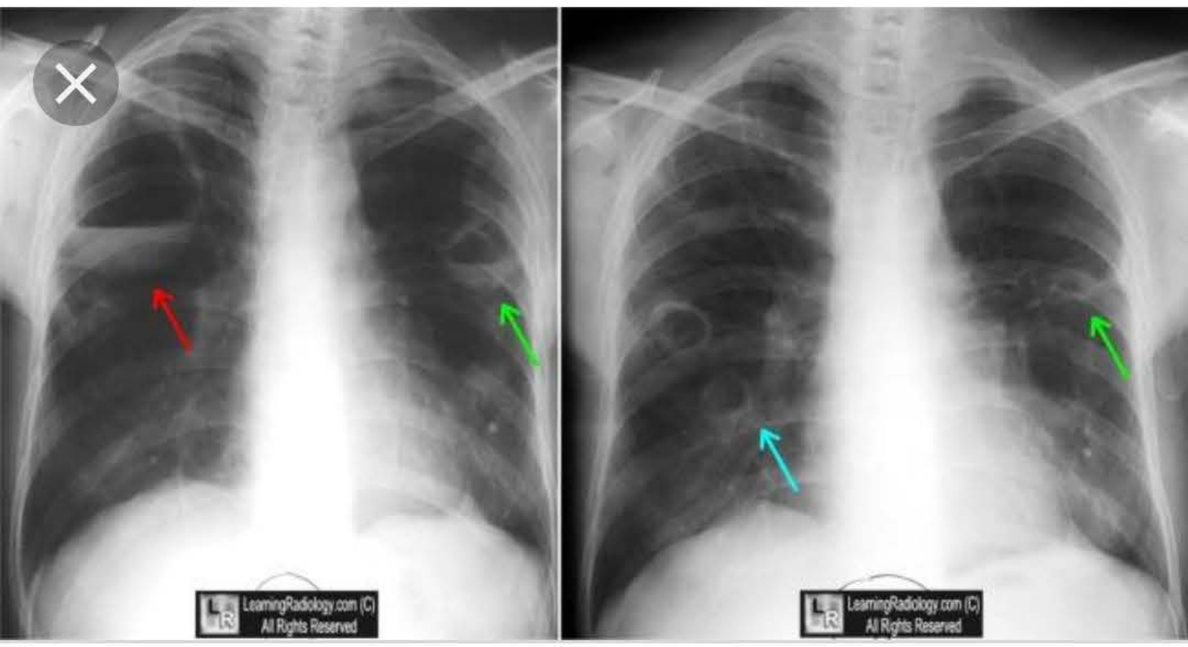

LearningRadiology

LearningRadiology - Granulomatosis, PolyangiitiS, G...

Wegener's Granulomatosis. Four images span approximately two years and show typical waxing and waning of pulmonary masses (white and green arrows), ...

Images may be subject to copyright. Learn More

RELATED IMAGES

SEE MORE

Welcome to LearningRadiology
learningradiology.com

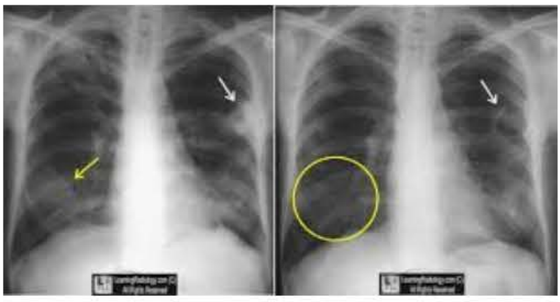

LearningRadiology - Granulo...
learningradiology.com

8:11
https://www.google.com/sea
13

Radiopaedia

Wegener granulomatosis | Radiology Case | Radiopaedia.o...

Loading Stack -

Images may be subject to copyright. Learn More

RELATED IMAGES SEE MORE

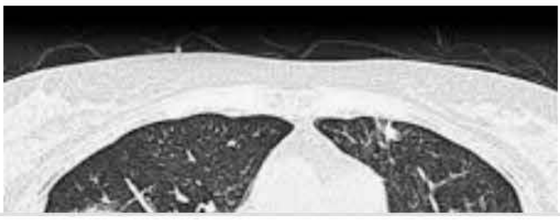

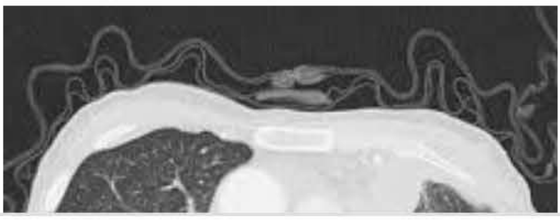

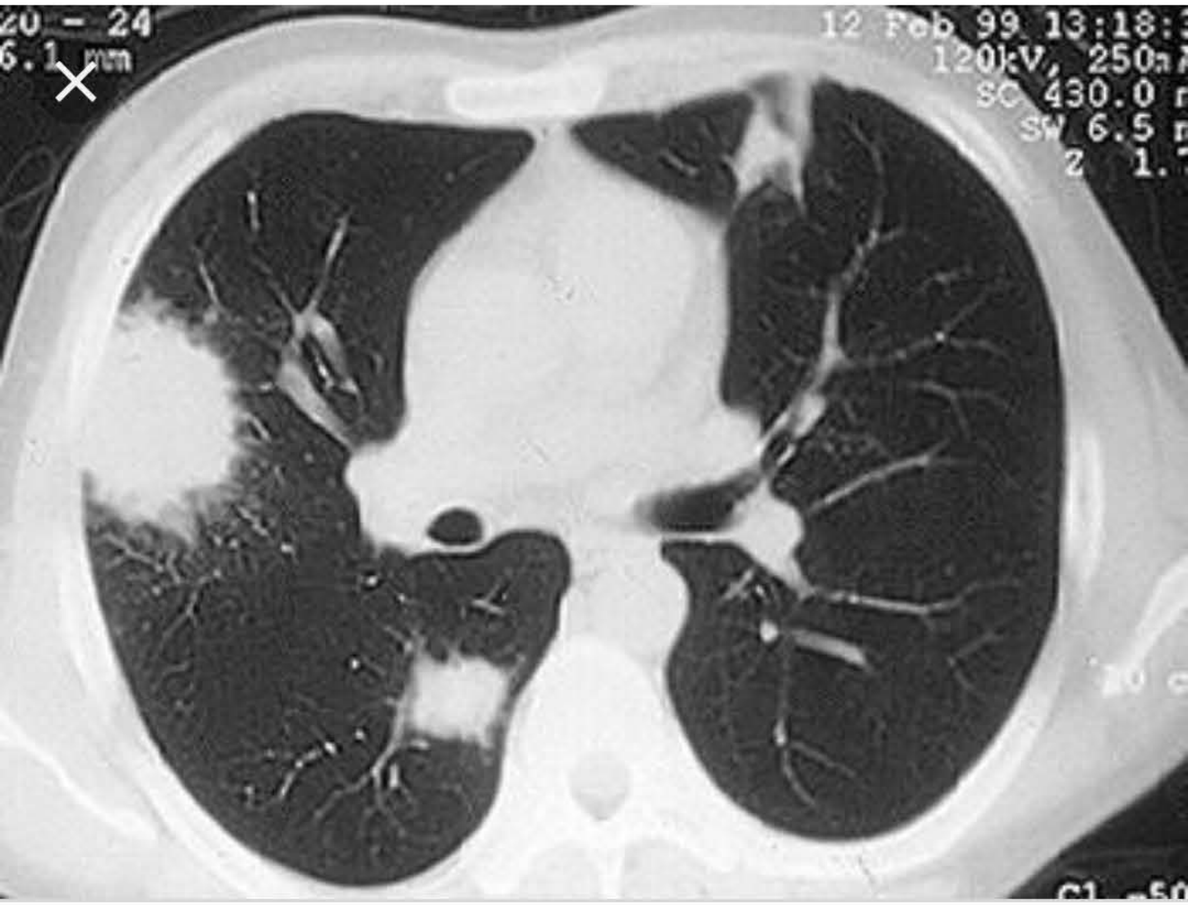

Johns Hopkins Vasculitis ...

Granulomatosis with Polyangiitis (Wegener's) - Johns Hopkins

Granulomatosis with Polyangiitis can affect virtually any site in the body, but it has a predisposition for certain organs. The classic organs involved in ...

Images may be subject to copyright. Learn More

RELATED IMAGES

SEE MORE

Chest CT scan showing diffu...
researchgate.net

Computed tomographic (CT) ...
researchgate.net

8:11
https://www.google.com/sea
13

Radiopaedia

Granulomatosis with polyangiitis | Radiology Reference Article ...

Case 3Case 3

Images may be subject to copyright. Learn More

RELATED IMAGES SEE MORE

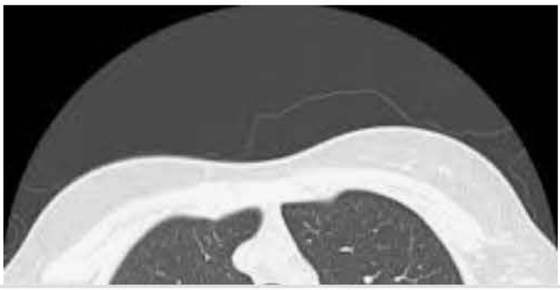

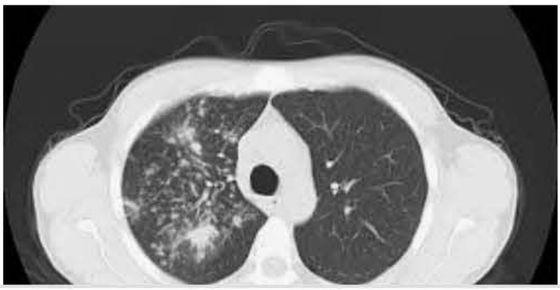

A woman with known rheumatoid arthritis presents with breathlessness, which has increased over the past 10 days, accompanied by night sweats and a dry cough. Currently, she takes prednisolone 3 mg and methotrexate 10 mg once per week, ranitidine and folic acid.

Her chest X-ray is shown below.

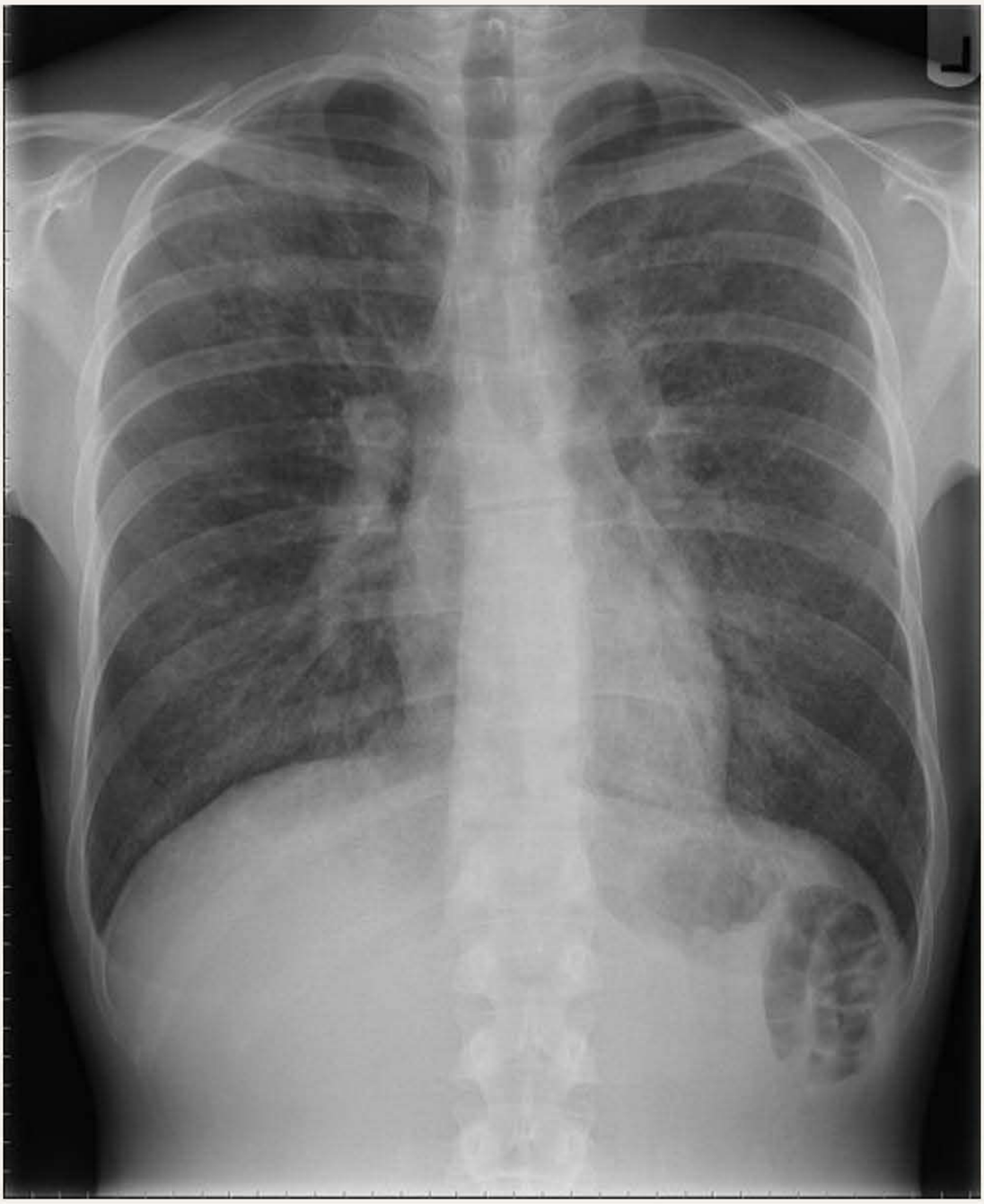

By -- Samir धर्म 06:38, 14 January 2007

or CC-BY-SA-3.0 (http://creativecommons.org/licenses/by-sa/3.0/)], via Wikimedia Commons

Oxygen saturations are 97% on air but fall to 90% on exercise. Other bloods are unremarkable, apart from her lymphocyte count, which is slightly below the lower limit of the normal range.

What is the best investigation to elicit the likely diagnosis?

A	Bronchoscopy and lavage
B	Lung function tests
C	Arterial blood gases
D	Ventilation/perfusion (V/Q) scan
E	Echocardiogram

A Bronchoscopy and lavage

The presence of exercise-induced oxygen desaturation in an immunocompromised or immunosuppressed person should always raise the possibility of *Pneumocystis jiroveci* pneumonia (PCP). In this case, however, the possibility of methotrexate-induced pneumonitis should also be considered. Both conditions can be associated with dyspnoea, exercise-induced desaturation and fever. Radiographic features vary considerably, with diffuse, bilateral interstitial or alveolar infiltrates also possible in both conditions. In this case, the X-ray shows diffuse bilateral interstitial changes.

Laboratory findings in PCP are generally unhelpful. Diagnosis can be made by staining spontaneous or induced sputum samples. In patients with human immunodeficiency virus (HIV), bronchoalveolar lavage diagnostic yield approaches 95% and

diagnostic yield approaches 95% and this can be raised to nearer 100% with the use of transbronchial biopsy.

B	Lung function tests

This patient may have underlying methotrexate-related pneumonitis where a restrictive picture is seen on lung function tests, but it is important to exclude PCP first.

C	Arterial blood gases

Arterial blood gases may reveal hypoxia but will not rule significant infection in or out. As such, they are not the preferred investigation here.

D	Ventilation/perfusion (V/Q) scan

A V/Q scan may reveal ventilatory defects consistent with infection but will not confirm the nature of the pathogen.

A 60-year old man presents with dull, right-sided chest ache, progressive shortness of breath and weight loss. He smokes 30 cigarettes per day and is a retired plumber with known asbestos exposure. On examination, BP is 125/72 mmHg with pulse 80/min and regular. There is reduced chest expansion on the right, with dullness to percussion and reduced air entry in the same area. Chest X-ray confirms the presence of a right-sided pleural effusion.

Which of the following is the optimal way to confirm the diagnosis?

A	Blind pleural biopsy
B	CT thorax
C	Pleural fluid aspiration
D	Thoracoscopy and biopsy
E	Ultrasound guided biopsy

A 60-year old man presents with dull, right-sided chest ache, progressive shortness of breath and weight loss. He smokes 30 cigarettes per day and is a retired plumber with known asbestos exposure. On examination, BP is 125/72 mmHg with pulse 80/min and regular. There is reduced chest expansion on the right, with dullness to percussion and reduced air entry in the same area. Chest X-ray confirms the presence of a right-sided pleural effusion.

Which of the following is the optimal way to confirm the diagnosis?

Your answer was incorrect

A	Blind pleural biopsy
B	CT thorax
C	Pleural fluid aspiration

D Thoracoscopy and biopsy

This patient most likely has mesothelioma, which can be difficult to diagnose. Biopsy is essential, but this needs to be done under imaging guidance to reduce the risk of tract spread, which is seeding of the tumour cells along the route of the biopsy needle. Thoracoscopy with biopsy under direct vision is the investigation of choice to confirm the diagnosis, and therefore this option is correct.

Mesothelial cells line the body cavities of the pleura, peritoneum, testis and pericardium. Malignancies involving these cells can be diffuse or localised. Most but not all pleural mesothelioma is associated with asbestos exposure. The most potent one is crocidolite (blue) followed by amosite (brown). There are three main histological types: mixed, sarcomatous and epithelial. The tumour arises from the visceral or parietal pleura and expands to encase the lung and spread to the oesophagus, superior vena cava and

oesophagus, superior vena cava and other nearby structures. The latent period from exposure is usually over 30 years. The higher the exposure dose the higher the risk. Some patients present up to 60 years after asbestos exposure. Where exposure is very high, presentation may occur as little as 10 years. Median survival after diagnosis is 11 months.

E	Ultrasound guided biopsy

USS guidance is now recommended for all intrathoracic biopsies and fluid sampling. The superiority of thoracoscopy and biopsy under direct vision makes this option incorrect.

A	Blind pleural biopsy

Although pleural biopsy is necessary for the diagnosis of mesothelioma, this method is relatively inaccurate at identifying the correct location for biopsy, and there is high risk of tract spread. CT-guided biopsy is better

spread. CT-guided biopsy is better than blind biopsy with an Abraham's needle, since it increases the chance of biopsy of an affected area; however, it still carries the same risk of tract spread.

B	CT thorax

CT is often used in the early stages of diagnosis of mesothelioma. On CT, mesothelioma appears as a nodular mass that spreads along pleural fissures. CT is a less sensitive test and would require subsequent biopsy to confirm the diagnosis.

C	Pleural fluid aspiration

More than 90% of patients present with pleural effusion and although pleural fluid aspiration may be necessary, it is not frequently diagnostic. Pleural fluid tends to have low leukocyte levels, low LDH and elevated protein.

Wikipedia

Mesothelioma - Wikipedia

CXR demonstrating a mesothelioma

Images may be subject to copyright. Learn More

RELATED IMAGES

SEE MORE

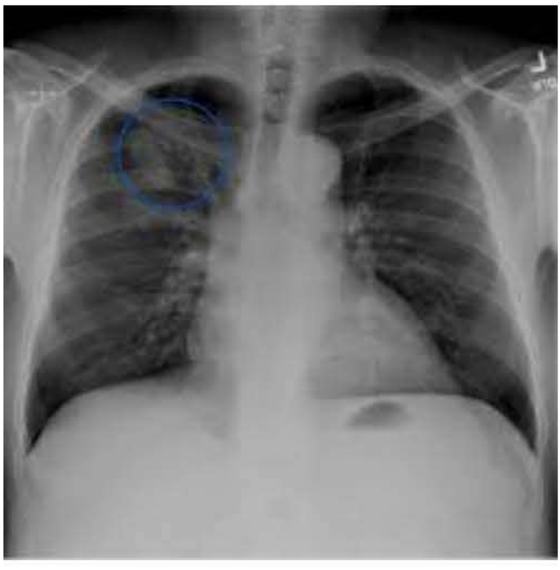

X-ray of chest PA view. The a...

8:22

Medscape eMedicine

Malignant Mesothelioma Imaging: Overview, Radiography...

This 57-year-old man presented with shortness of b

Images may be subject to copyright. Learn More

RELATED IMAGES SEE MORE

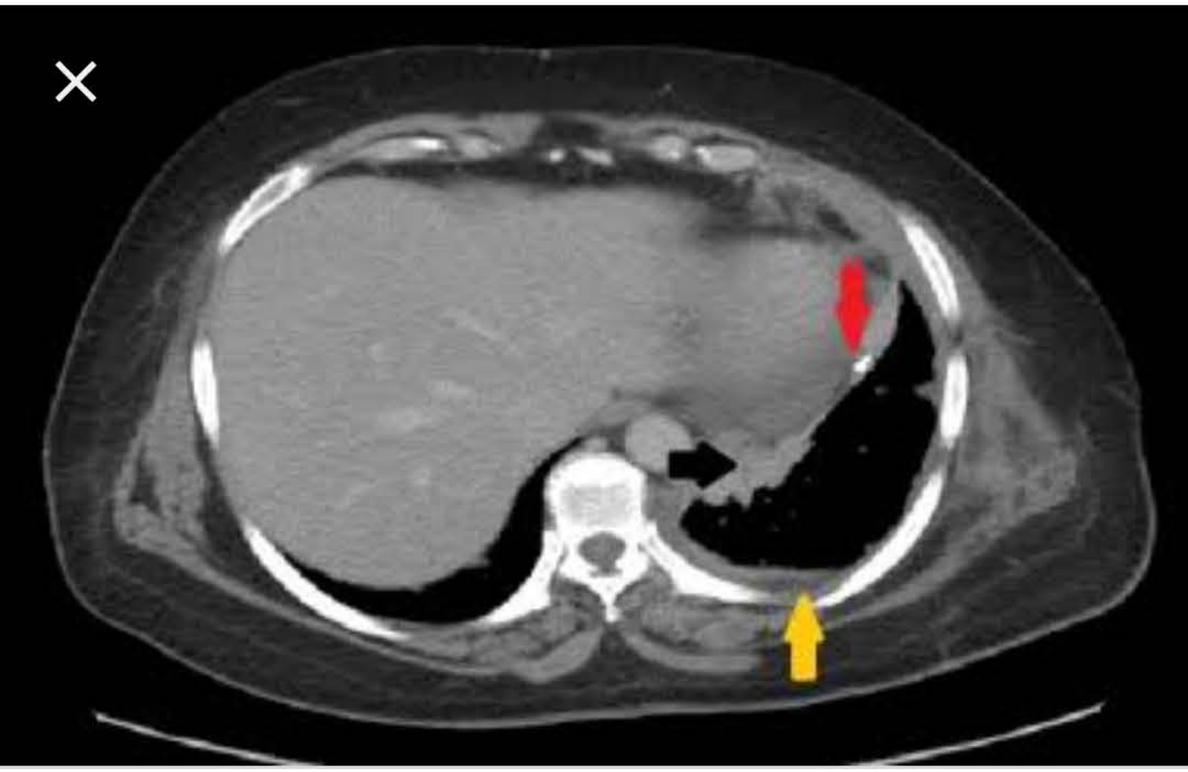

Medscape eMedicine

Malignant Mesothelioma Imaging: Overview, Radiography...

Axial slice from staging CT scan of a 67-year-old

Images may be subject to copyright. Learn More

RELATED IMAGES

SEE MORE

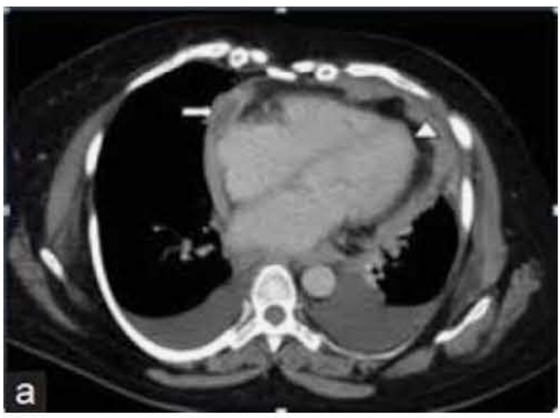

Journal of Clinical Imaging S...
clinicalimagingscience.org

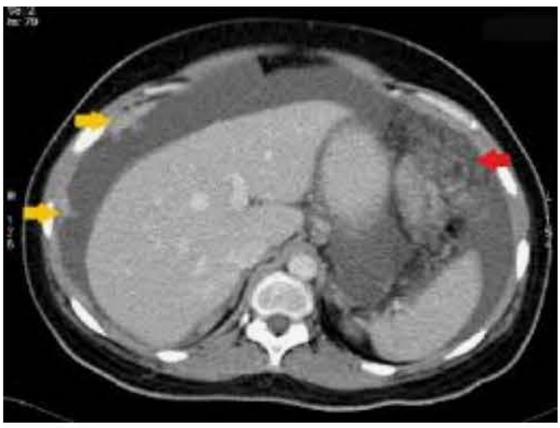

img.medscapestatic.com/pi/...
emedicine.medscape.com

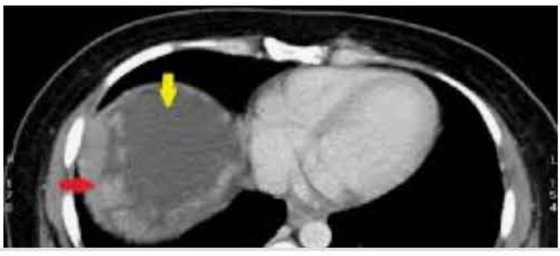

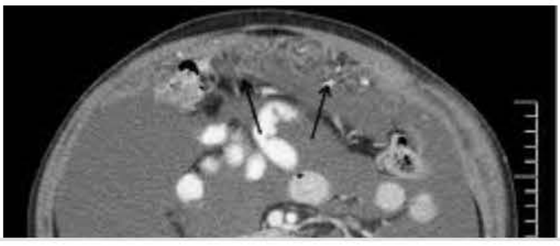

8:25

radiopaedia.org

Mesothelioma | Radiology Reference Article | Radiopaedia...

Images may be subject to copyright. Learn More

RELATED IMAGES SEE MORE

CT Scanning Not Reliable for

8:25

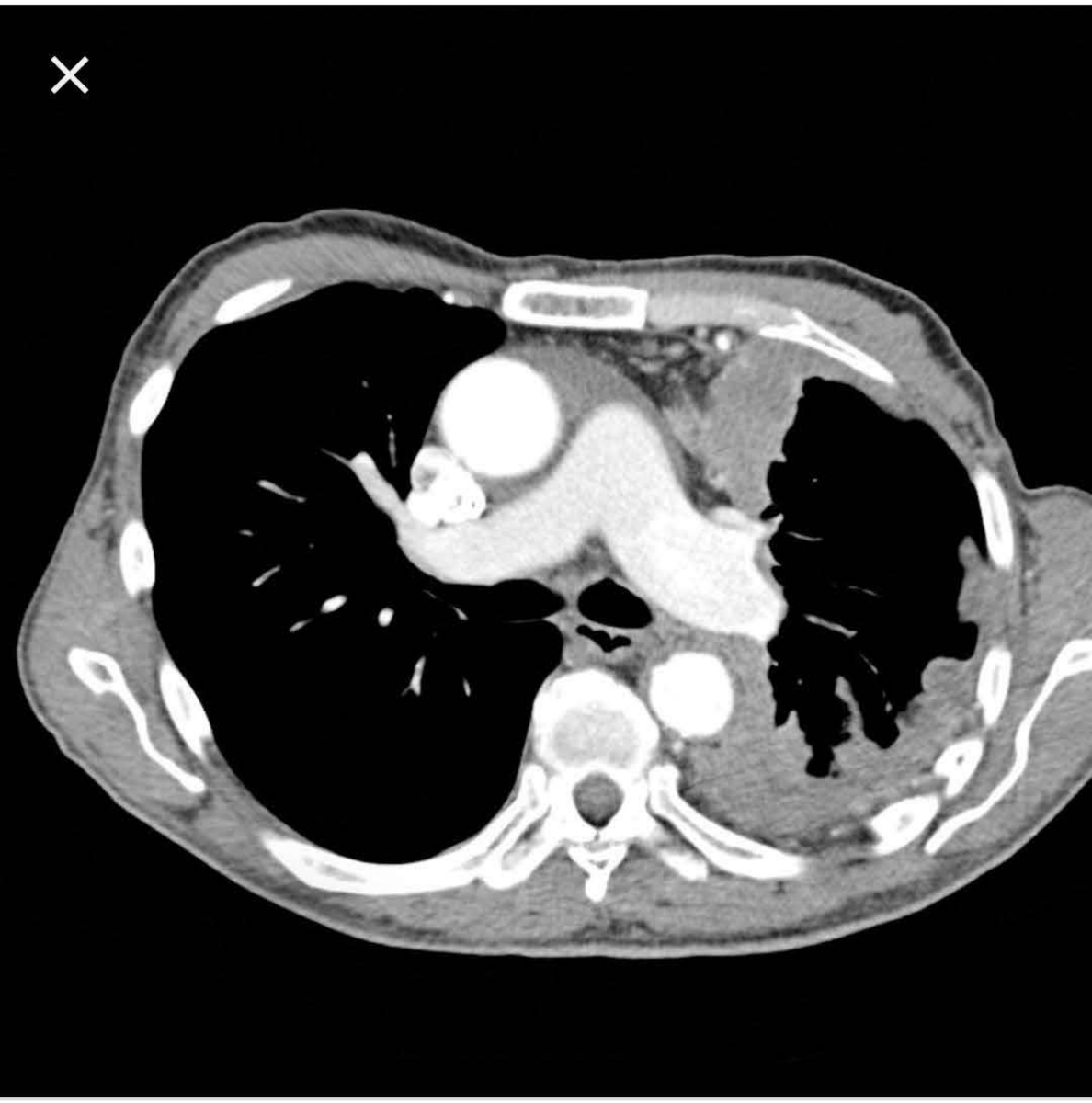

radiopaedia.org

Mesothelioma | Image | Radiopaedia.org

Images may be subject to copyright. Learn More

RELATED IMAGES SEE MORE

You review a 67-year-old man with severe chronic obstructive pulmonary disease (COPD) who stopped smoking 3 years ago. He has a history of myocardial infarction 4 years ago and chronic peripheral vascular disease. His medications include ramipril, indapamide, salbutamol and ipratropium.

Which of the following clinical features would best support prescription of long-term oxygen therapy (LTOT)?

A	$Pa(O_2)$ of 8.2 kPa
B	Pitting oedema of the lower limbs
C	$Pa(CO_2)$ of 5.1 kPa
D	FEV_1 (forced expiratory volume in 1 s) of 1.7 l
E	History of angina

B Pitting oedema of the lower limbs

According the British Thoracic Society guidelines on long-term oxygen therapy (LTOT) in regard to patients with stable chronic obstructive pulmonary disease (COPD) (see weblink below), a resting $Pa(O_2) \leq 7.3$ kPa should be assessed for LTOT, which offers survival benefit when used for at least 15 h per day and improves pulmonary haemodynamics. LTOT should be offered to those patients with stable COPD and a resting $Pa(O_2) \leq 8$ kPa with evidence of peripheral oedema, polycythaemia (haematocrit ≥55%) or pulmonary hypertension. Swollen ankles indicate the possibility of right heart failure, which may be occurring as a result of pulmonary hypertension which is in keeping with the guidelines above.

Two measures are required to make the decision on therapy, and samples should be taken at least 3 weeks apart whilst the patient is stable and free of

should be taken at least 6 weeks apart whilst the patient is stable and free of an exacerbation. This leads to a reduction in secondary polycythaemia, reduced sympathetic outflow and consequent salt and water retention, a reduction in cardiac arrhythmias, and improved sleep quality due to reduced hypoxia-induced sleep arousals.

D	FEV_1 (forced expiratory volume in 1 s) of 1.7 l

Spirometry findings do warrant criteria for oxygen therapy and do not indicate hypoxia.

A	$Pa(O_2)$ of 8.2 kPa

$Pa(O_2)$ >8kPa should not lead to a prescription of LTOT.

C	$Pa(CO_2)$ of 5.1 kPa

Although LTOT should be ordered for patients with resting hypercapnia (if they fulfil all other criteria for LTOT),

for oxygen therapy and do not indicate hypoxia.

A	$Pa(O_2)$ of 8.2 kPa

$Pa(O_2)$ >8kPa should not lead to a prescription of LTOT.

C	$Pa(CO_2)$ of 5.1 kPa

Although LTOT should be ordered for patients with resting hypercapnia (if they fulfil all other criteria for LTOT), this gentleman does not have resting hypercapnia.

E	History of angina

Although it can be used in chronic heart failure, history of angina is not an appropriate use of LTOT. Anti-anginal medication or a coronary angiogram would be required if patient has recurrent episodes of angina.

32441

Rate this question:

A known asthmatic is admitted to A&E with wheeze and shortness of breath, although she is not yet showing signs of fatigue. She is given continued nebulised salbutamol, IV steroids and high-flow oxygen. You are asked by the nursing sister in charge whether giving IV magnesium is appropriate.

According to the BTS guidelines, which of the following would count against the need for IV magnesium at this stage?

A	Patient is 18 years old
B	Magnesium is at the lower end of the normal range
C	Tachycardia with a heart rate of 120 beats/min
D	Patient is treated with oral theophylline
E	PEFR 240 vs 140 on admission (normal 500)

E PEFR 240 vs 140 on admission (normal 500)

The British Thoracic Society (BTS) guidelines say that 50% magnesium sulphate at 1.2–2 g (4–8 mmol) over 20 min can be given IV to a patient with severe asthma not responding to inhaled bronchodilator or who has severe life-threatening asthma. In this case the PEFR is improving, without signs of fatigue, and it is therefore appropriate to continue with current management.

D Patient is treated with oral theophylline

The need for oral theophylline implies a poor response to beta-agonist therapy, and therefore a possible greater need for acute intervention with magnesium.

A Patient is 18 years old

Age is irrelevant when considering the

A Patient is 18 years old

Age is irrelevant when considering the need for magnesium infusion, and there is little difference in response as age increases.

B Magnesium is at the lower end of the normal range

Magnesium concentration is irrelevant as supra-therapeutic levels are given to achieve a pharmacological response with reduced acetylcholine release and improved smooth muscle relaxation

C Tachycardia with a heart rate of 120 beats/min

Heart rate >110/min is an indicator of severe asthma and more likely to drive the use of magnesium.

2332

Rate this question:

8:35
tps://mypastest.pastest.com
13

A 24-year-old asthmatic on PRN salbutamol inhaler and budesonide 200 µg inhaler twice per day is not well controlled and needs his treatment stepping up.

Which of the following would be recommended according to current (2017) NICE guidelines?

A	Add oral cromoglicate
B	Increase budesonide to 800 µg BD
C	Add oral theophylline (modified release)
D	Add montelukast
E	Add tiotropium

D	Add montelukast

Montelukast is a leukotriene receptor antagonist. The 2017 NICE guidelines say:

If asthma is uncontrolled in adults (aged 17 and over) on a low dose of ICS as maintenance therapy, offer a leukotriene receptor antagonist (LTRA) in addition to the ICS and review the response to treatment in 4–8 weeks.

A	Add oral cromoglicate

Cromoglicate is only effective for asthma prophylaxis by inhalation 3–4 times a day and is generally only considered after patients have failed to gain control on multiple agents, including inhaled corticosteroids, long-acting beta-agonist and monteleukast.

B	Increase budesonide to 800 µg BD

The standard dose of budesonide is 100–400 µg, the high dose is 0.8–2mg

A 45-year-old patient presents to his GP with dyspnoea and cough over the past week. He has also noticed recurrent nose bleeds and crusting around his nose over the past month. He is a non-smoker, has no past medical history and is not on any medications.

Spirometry is performed:

Forced expiratory volume in 1 second (FEV_1)	80% predicted
Forced vital capacity (FVC)	65% predicted
Total lung capacity (TLC)	70% predicted
Lung CO transfer factor (T_{LCO})	120% predicted factor
CO transfer coefficient (K_{CO})	120% predicted coefficient

Urine dip: protein ++, blood +

Urine dip: protein ++, blood +

Blood tests show:

Hb	11.2 g/dl
WCC	11.2×10^9/l
PLT	540×10^9/l
MCV	90 fl
eGFR	41

Which is the most likely diagnosis?

A	Pulmonary haemorrhage
B	Pneumonectomy
C	Left-to-right shunt
D	Sarcoidosis
E	Neuromuscular defect

A Pulmonary haemorrhage

The spirometry shows a restrictive picture (FEV_1/FVC >80%). This suggests that there is a restrictive cause of the shortness of breath, such as haemorrhage, sarcoidosis, pneumonectomy or reduced work of the respiratory muscles due to a neuromuscular defect. Pulmonary haemorrhage would be a cause of increased K_{CO} and hence is the most likely diagnosis when taken with the history of nose bleeds, making a vasculitis such as granulomatosis with polyangitis (Wegener's) the likely underlying diagnosis. GPA is also associated with collapse of the nasal bridge, leading to a 'saddle nose' deformity.

B Pneumonectomy

This would be expected to result in a reduced transfer factor due to loss of significant volume of alveolar membrane, with normal transfer coefficient assuming the residual lung

membrane, with normal transfer coefficient assuming the residual lung is normal.

C	Left-to-right shunt

While this would cause an increased transfer factor, it does not explain the nose bleeds as adequately as a diagnosis of underlying vasculitis. We are also not given any history of murmurs such as ASD, VSD or PDA on examination, nor features of underlying pulmonary hypertension.

D	Sarcoidosis

While this would result in a restrictive pattern of PFTs, we are not given any history of other symptoms such as erythema nodosum, and this does not explain the increased K_{CO} as adequately as pulmonary haemorrhage.

E	Neuromuscular defect

diagnosis of underlying vasculitis. We are also not given any history of murmurs such as ASD, VSD or PDA on examination, nor features of underlying pulmonary hypertension.

D	Sarcoidosis

While this would result in a restrictive pattern of PFTs, we are not given any history of other symptoms such as erythema nodosum, and this does not explain the increased K_{CO} as adequately as pulmonary haemorrhage.

E	Neuromuscular defect

While this would result in a restrictive pattern of PFTs, we are not given any other features to suggest a neurological aetiology such as motor or sensory deficit. It also fails to adequately explain the patient's epistaxis.

7161

Rate this question:

A 41-year-old woman who is known to have brittle asthma was admitted to the Emergency Department with increased shortness of breath and a severe cough over the past few days, productive of yellow/green sputum. She was pyrexial 38.4°C, pulse was 90/min and regular, BP was 85/60 mmHg on admission, but improved with a fluid challenge. You review her on the ward some 36 h later, with her blood culture results. Her BP is now 105/70 mmHg, with pulse 75/min and regular. There are right basal crackles consistent with consolidation. She is still spiking fevers of 39.2°C every few hours.

Investigations:

Hb	129 g/l
WCC	15.2
PLT	203 x 10^9/l
CRP	215 mg/l
Na^+	132 mmol/l
K^+	5.1 mmol/l

CRP	215 mg/l
Na^+	132 mmol/l
K^+	5.1 mmol/l
Creatinine	162 micromol/l
Urea	14.1 mmol/l
Blood cultures	*Pseudomonas*

Which of the following is the most appropriate antibiotic choice?

A IV colistin (polymyxin E)

B IV gentamicin

C IV meropenem

D IV tazocin

E Oral ciprofloxacin

with a fluid challenge. You review her on the ward some 36 h later, with her blood culture results. Her BP is now 105/70 mmHg, with pulse 75/min and regular. There are right basal crackles consistent with consolidation. She is still spiking fevers of 39.2°C every few hours.

Investigations:

Hb	129 g/l
WCC	15.2
PLT	203 x 10^9/l
CRP	215 mg/l
Na^+	132 mmol/l
K^+	5.1 mmol/l
Creatinine	162 micromol/l
Urea	14.1 mmol/l
Blood cultures	*Pseudomonas*

Which of the following is the most appropriate antibiotic choice?

D IV tazocin

The choice here is between oral quinolone and IV therapy for *Pseudomonas*. Given that this patient is still spiking fevers and has an elevated urea, IV therapy with tazocin is most appropriate.

C IV meropenem

Carbapenems are an option for the treatment of *Pseudomonas*, although inducible resistance is a concern. For this reason, tazocin is the preferred option.

A IV colistin (polymyxin E)

Colistin is generally reserved for serious pseudomonal infections that are resistant to therapy with other agents.

B IV gentamicin

this reason, tazocin is the preferred option.

A	IV colistin (polymyxin E)

Colistin is generally reserved for serious pseudomonal infections that are resistant to therapy with other agents.

B	IV gentamicin

Gentamicin monotherapy is not recommended for the treatment of respiratory tract infections.

E	Oral ciprofloxacin

Although oral ciprofloxacin is an option for pseudomonal infection, the severity of this patient's pneumonia drives us more towards IV tazocin as the preferred therapy.

70490

Rate this question:

A 54-year-old man presented with increasing shortness of breath and orthopnoea. He had noticed these symptoms over the last few years but only went to his GP after he had had a severe episode of breathlessness when he went wading in the sea on holiday. On further enquiry, he had also become aware of morning headaches and an increasing tendency to fall asleep during the day.

On examination he looked well. Auscultation of his chest revealed reduced breath sounds and percussion note bi-basally.

Investigations:

Hb	17.7 g/dl
WCC	12.3 × 10^9/l
PLT	289 × 10^9/l
PCV	0.51
Residual volume Erect (%	105

Residual volume Erect (% predicted)	105
Total lung capacity Erect (% predicted)	80
Vital capacity Erect (% predicted)/Supine (% predicted)	75/50
TLCO Erect (% predicted)	70
KCO Erect (% predicted)	95

What is the most likely diagnosis?

A	Obstructive sleep apnoea
B	Nocturnal asthma
C	Bilateral diaphragmatic weakness
D	Left ventricular failure
E	Multiple sclerosis

PLT	289 × 10^9/l
PCV	0.51
Residual volume Erect (% predicted)	105
Total lung capacity Erect (% predicted)	80
Vital capacity Erect (% predicted)/Supine (% predicted)	75/50
TLCO Erect (% predicted)	70
KCO Erect (% predicted)	95

What is the most likely diagnosis?

Your answer was correct

A Obstructive sleep apnoea

B Nocturnal asthma

C Bilateral diaphragmatic

C Bilateral diaphragmatic weakness

In bilateral diaphragmatic weakness, patients commonly present with breathlessness on exertion and when lying flat. It can be associated with sleep apnoea, resulting in daytime somnolence and headaches. The symptoms are due to the paradoxical movement of the diaphragm during inspiration.

In the supine position, expansion of the ribs results in movement of abdominal contents into the chest, aided by gravity. Symptoms can be worse when standing up to the waist in water, as this counteracts the effects of gravity and prevents outward movement of the abdomen during inspiration and therefore produces a similar situation to being in the supine position.

A chest X-ray may show relatively small lung fields and basal linear shadowing due to sub-segmental collapse. A SNIF test (diaphragmatic screening on ultrasound) will show

screening on ultrasound) will show paradoxical movement of the diaphragm, particularly on sniffing. Blood gases may show a type II respiratory failure, particularly at night. Lung function tests classically show a low vital capacity, which falls further in the supine position. All lung volumes except the residual volume are reduced. The gas transfer tends to mildly impaired with a normal KCO. Treatment is with non-invasive ventilation.

A Obstructive sleep apnoea

The 15% change in vital capacity when supine alongside breathlessness when submerged in water and orthopnoea make diaphragmatic weakness more likely.

B Nocturnal asthma

The patient has no symptoms to suggest that asthma is the diagnosis. There is no wheeze or cough. The

breathlessness is progressive and there are several other features in this history to suggest diaphragmatic weakness.

D	Left ventricular failure

Orthopnoea and dull percussion notes bilaterally (due to pleural effusions) in isolation could be in keeping with LVF, but there is more going on here. The patient has a change in sitting and supine VC, there is a normal transfer factor when corrected for lung volumes and haemoglobin is high (you would expect a lower Hb in LVF due to fluid overload and haemodilution).

E	Multiple sclerosis

Patients with MS can experience diaphragmatic weakness, but there are no other clinical features to suggest an underlying diagnosis of MS.

70150

Rate this question:

A 27-year-old pregnant lady is referred to the Emergency Admission for sudden development of shortness of breath. She was well until 2 days ago when she developed shortness of breath. She has some slight left-sided chest pains, but no cough or haemoptysis. She is 28 weeks' pregnant and has had no problems with the pregnancy. There is no history of long flights or swelling of her legs. On examination, she appears anxious with a blood pressure of 110/60 mmHg, pulse rate of 92/min and a respiratory rate of 26/min. Her oxygen saturation on air is 98%. Her abdomen is distended and fetal movements are seen. Her chest is clinically clear. Her cardiovascular and lower limb examinations are unremarkable.

Investigations:

Hb	11.3 g/dl
WCC	10.1×10^9/l
PLT	278×10^9/l
Na+	139 mmol/l

PLT	$278 \times 10^9/l$
Na+	139 mmol/l
K+	3.5 mmol/l
Creatinine	112 μmol/l
MCV	89 fl
Urea	6.1 mmol/l
CRP	6.0 mg/l
D-dimers	0.62 mg/l (<0.25)
pH	7.48
pa(O_2) on air	13.7 kpa
pa(CO_2) on air	3.9 kPa
CXR	No focal abnormality
V/Q scan	Low probability of pulmonary embolism (PE)

What would be the most appropriate step in her immediate management?

air	13.7 kpa
pa(CO_2) on air	3.9 kPa
CXR	No focal abnormality
V/Q scan	Low probability of pulmonary embolism (PE)

What would be the most appropriate step in her immediate management?

A	Commence low-molecular weight heparin
B	Commence warfarin
C	Arrange for her discharge
D	Commence low-dose aspirin
E	Thrombolysis

C Arrange for her discharge

A low-probability V/Q scan has a low clinical suspicion of pulmonary emboli (PE) and should prompt a search for another cause for the patient's symptoms. The slightly elevated pH, with O_2 towards the upper end of the normal range, accompanied by low CO_2 are more suggestive of mild hyperventilation and anxiety. Taking these facts into account, it is safe to facilitate discharge.

E Thrombolysis

Both thoracotomy with embolectomy and thrombolysis can be considered for pregnant women with massive pulmonary embolism, although that isn't the diagnosis here.

A Commence low-molecular weight heparin

There is no indication here for

A Commence low-molecular weight heparin

There is no indication here for anticoagulation given the V/Q scan result.

B Commence warfarin

There is no indication for anticoagulation taking into account the V/Q result, and warfarin is not advised in early or in very late pregnancy.

D Commence low-dose aspirin

There is no indication for anti-platelet therapy, and even if there were evidence of thromboembolic disease, aspirin is not an effective intervention.

7511

Rate this question:

Next Question

A 27-year-old pregnant lady is referred to the Emergency Admission for sudden development of shortness of breath. She was well until 2 days ago when she developed shortness of breath. She has some slight left-sided chest pains, but no cough or haemoptysis. She is 28 weeks' pregnant and has had no problems with the pregnancy. There is no history of long flights or swelling of her legs. On examination, she appears anxious with a blood pressure of 110/60 mmHg, pulse rate of 92/min and a respiratory rate of 26/min. Her oxygen saturation on air is 98%. Her abdomen is distended and fetal movements are seen. Her chest is clinically clear. Her cardiovascular and lower limb examinations are unremarkable.

Investigations:

Hb	11.3 g/dl
WCC	10.1×10^9/l
PLT	278×10^9/l
Na+	139 mmol/l

A 60-year-old man with known emphysema presented to the Emergency Department with sudden onset of severe left-sided pleuritic chest pain and shortness of breath. He is a smoker of 20/day. On examination he looks unwell. He is pale and sweaty. BP 140/85 mmHg, pulse 120/min, respiratory rate 30/min, SaO_2 88% on air. He has reduced expansion and reduced breath sounds on the left side. Heart sounds were normal and abdominal examination unremarkable.

ABGs on air:

pH	7.41
PO_2	7.5 kPa
PCO_2	6.5 kPa

His CXR is shown below;

He is given 28% oxygen and analgesia and his saturations improve.

What would your immediate management of this patient be?

A	Chest aspiration
B	Insertion of an intercostal chest drain
C	Arrange an urgent CT scan of the chest
D	Refer to the thoracic surgeons
E	Insertion of an intercostal tube and apply suction

9:36
tps://mypastest.pastest.com 13

PO_2	7.5 kPa
PCO_2	6.5 kPa

His CXR is shown below;

He is given 28% oxygen and an
and his saturations improve.

What would your immediate management of this patient be

B Insertion of an intercostal chest drain

This man has a secondary pneumothorax as he has underlying lung disease. The management is different for primary (no underlying pulmonary disease) and secondary (underlying pulmonary disease) pneumothoraces. Current guidelines[1] suggest that an intercostal drain should be inserted if the patient is breathless, over 50 years old with a significant smoking history and there is a rim of air of > 2 cm from the chest wall on a standard size chest X-ray. This patient fits all the above criteria. Suction should not be applied immediately and it is recommended that it should not be routinely employed. It maybe considered after 48 hours whilst awaiting surgical review if the lung is not fully re-expanded or if there is a persistent air leak. Suction should be low-pressure (-10 to -20 cmH_2O), high-volume.
If this patient had a persistent air leak, despite suction, they should be

If this patient had a persistent air leak, despite suction, they should be referred to the thoracic surgeons. The exact timing of referral remains contentious but it is suggested that in cases of persistent air leak or failure of the lung to re-expand, an early (3-5 days) thoracic surgical opinion should be sought.

For secondary pneumothoraces, an early thoracic surgical referral is recommended.

[1]http:www.brit-thoracic.org.uk https://www.brit-thoracic.org.uk/document-library/clinical-information/pleural-disease/pleural-disease-guidelines-2010/pleural-disease-guideline-quick-reference-guide/

A Chest aspiration

Chest aspiration should only be considered for a secondary pneumothorax <2cm if the patient is clinically stable.

C Arrange an urgent CT scan of

the chest

A CT is not required here, the diagnosis of pneumothorax is clearly visible on CXR.

D	Refer to the thoracic surgeons

It would be appropriate to try and resolve pneumothorax with an intercostal drain before assessing whether a surgical referral is required.

E	Insertion of an intercostal tube and apply suction

Suction should be applied with caution due to risk of re-expansion pulmonary oedema. It should only be applied after consideration and specialist advice and monitoring.

70121

Rate this question:

A 30-year-old man, who is fit and well, is admitted with sudden-onset shortness of breath associated with sharp chest pain made worse with coughing. The symptoms began suddenly while the patient was working on his computer.

He is not on any regular medications. His blood pressure (BP) is 145/70 mmHg, and his pulse is 70 bpm and regular. After clinical examination of the patient, a chest X-ray is requested, which confirms the presence of a pneumothorax.

Which of the following signs is most likely to have been elicited during the clinical examination?

A	Deviation of the trachea
B	Bilateral reduced expansion
C	Saturation of 90% on air
D	Dull percussion note

He is not on any regular medications. His blood pressure (BP) is 145/70 mmHg, and his pulse is 70 bpm and regular. After clinical examination of the patient, a chest X-ray is requested, which confirms the presence of a pneumothorax.

Which of the following signs is most likely to have been elicited during the clinical examination?

A	Deviation of the trachea
B	Bilateral reduced expansion
C	Saturation of 90% on air
D	Dull percussion note
E	Unilateral decreased breath sounds

71456

Submit

E Unilateral decreased breath sounds

This is another classical finding that occurs due to failure of the affected lung to expand appropriately.

A Deviation of the trachea

A pneumothorax occurs due to the entry of air in the intrapleural space and the subsequent partial or total collapse of the lung. Pneumothoraces are often spontaneous and are more likely to occur in young, thin men. A secondary pneumothorax is more likely to occur in the presence of an underlying lung disease. Patients may be asymptomatic or they may present with sudden onset of shortness of breath and pleuritic chest pain. The classical signs of a pneumothorax on clinical examination of the chest include: reduced expansion on the affected side, hyperresonant percussion note and diminished breath sounds.

A deviated trachea (away from the affected side) is seen in cases of a tension pneumothorax and is usually accompanied by a combination of respiratory distress, tachycardia, tachypnoea and hypotension.

B	Bilateral reduced expansion

Unilateral reduced expansion is a very common finding in a pneumothorax. Due to the entry of air, the associated lung collapses and cannot inflate, leading to reduced chest expansion on the affected side.

C	Saturation of 90% on air

The patient described has unremarkable BP and heart rate measurements. Given that and the fact that spontaneous pneumothoraces are often small, normal saturation levels would be an expected finding.

D	Dull percussion note

An 18-year-old woman comes to the Emergency Room complaining of extreme lethargy. A couple of weeks earlier she had suffered from a nasty bout of gastroenteritis after a takeaway meal. She complains of abnormal sensation and numbness in her fingers, and weakness of her lower legs. She is generally hypotonic and has difficulty standing. On examination there is a postural drop in BP of 20 mmHg to 105/70 mmHg, and she has a resting tachycardia of 90 BPM. No deep tendon reflexes can be elicited in her lower limbs. Only medication of note includes the oral contraceptive pill.

Investigations:

Hb	12.1 g/dl
WCC	6.9 $\times 10^9$/l
PLT	230 $\times 10^9$/l
Na^+	141 mmol/l
K^+	4.8 mmol/l
Creatinine	140 μmol/l

K^+	4.8 mmol/l
Creatinine	140 μmol/l
Glucose	7.2 mmol/l
TSH	1.8 U/l

Given the likely diagnosis, which of the following is the most important way to monitor the progress of her condition?

A Lumbar puncture

B Anti-GQ1b antibodies

C FVC

D FEV_1

E Creatine kinase levels

21025

Submit

C FVC

This woman has a history consistent with Guillain–Barré syndrome (GBS), which is known to occur after an episode of bacterial gastroenteritis. Typical symptoms seen here include paraesthesia in the fingers, with progressive lower limb weakness. Autonomic signs such as tachycardia and postural hypotension also occur. FVC is the most helpful investigation in assessing prognosis. Respiratory failure, including supervening bacterial pneumonia, is the most important cause of morbidity/mortality associated with the condition.

A Lumbar puncture

Although an elevation in CSF protein may be seen, this may be normal in the early stages of the condition and therefore doesn't rule out the diagnosis.

B Anti-GQ1b antibodies

therefore doesn't rule out the diagnosis.

B	Anti-GQ1b antibodies

Anti-GQ1b antibodies are found in the Miller Fisher variant of GBS, which is associated with ophthalmoplegia; they are not predictive of outcomes in the condition.

D	FEV_1

FEV_1 is a marker of airways obstruction, and is much more useful in the monitoring of asthma and COPD.

E	Creatine kinase levels

CK is a marker of disease activity in dermatomyositis, and is not useful in monitoring of Guillain–Barré syndrome.

21025

Rate this question:

Next Question

A 64-year-old man was referred to the clinic with insomnia. He complained of falling asleep during the day and having an early morning headache. He had a past history of a cholecystectomy and gout. He took no other regular medication. Examination was unremarkable. His weight and height were 120 kg and 175 cm, respectively

Investigations:

Hb	16.1 g/dl
WCC	6.4×10^9/l
PLT	94×10^9/l
MCV	101 fl
TSH	1.2 mU/l

Which of the following investigations would most aid diagnosis?

A	ABG
B	Sleep studies

WCC	$6.4 \times 10^9/l$
PLT	$94 \times 10^9/l$
MCV	101 fl
TSH	1.2 mU/l

Which of the following investigations would most aid diagnosis?

A ABG

B Sleep studies

C CXR

D CT thorax

E Body plethysmography

70139

Submit

B Sleep studies

This patient has obstructive sleep apnoea (OSA), suggested by insomnia, daytime somnolence, morning headache and obesity. Other symptoms include poor concentration during the day, and partners may describe snoring followed by apnoeic episodes.

Diagnosis is made using the Epworth score, which is a measure of daytime somnolence, and sleep studies, which would show apnoeic/hypopnoeic episodes associated with desaturations, increase in heart rate and arousal from sleep. Treatment will depend on severity of symptoms and desaturations. In most cases weight loss is advisable.

In mild OSA syndrome a mandibular advancement device may control symptoms. In moderate to severe OSA syndrome, nocturnal non-invasive ventilation (NIV) using continuous positive airway pressure (CPAP) can be considered. Early-morning

be considered. Early-morning headaches can be caused by a transient hypercapnia, which corrects to normal when the patient is awake. If a patient has hypercapnia in waking hours (and not just on an early morning blood gas) then overlap syndrome with obesity hypoventilation syndrome should be considered, although severe OSA may cause persistent hypercapnia in some cases. Patients with persistent hypercapnia should be considered for bi-level positive airway pressure (BiPAP).

It is important to exclude underlying causes; this patient has a history of gout which, together with the raised MCV and low platelets, suggests alcohol consumption, which can precipitate the problem. Hypothyroidism, acromegaly and sedating drugs also need to be excluded. Retrognathia can cause OSA, and large tonsils may obstruct the airway.

A ABG

Arterial blood gases would be helpful in assessing for hypercapnoea, but are not diagnostic of OSA.

C CXR

Radiology is usually normal in obstructive sleep apnoea.There are no respiratory symptoms to suggest an intrathoracic pathology that would require a CXR.

D CT thorax

Radiology is usually normal in obstructive sleep apnoea.There are no respiratory symptoms to suggest an intrathoracic pathology that would require a CT.

E Body plethysmography

Body plethysmography may reveal restrictive lung function with a normal gas transfer but this is not a diagnostic test for OSA

An HIV-positive patient is admitted acutely unwell with shortness of breath initially only on exertion, but now present even at rest. He has been prescribed HAART and pentamidine nebulisers (co-trimoxazole being unsuitable for him). However, recently he says that he has not had time to come to the clinic for treatment. His chest X-ray shows bilateral air-space shadowing and his arterial blood gas on air shows pO_2 7.9 kPa and pCO_2 5.0 kPa. His CD4 count is 164.

What is the most appropriate initial treatment option?

A	Clindamycin and primaquine
B	Further nebulised pentamidine
C	Intravenous Pentamidine with prednisolone
D	Intravenous cefotaxime and oral clarithromycin

unsuitable for him). However, recently he says that he has not had time to come to the clinic for treatment. His chest X-ray shows bilateral air-space shadowing and his arterial blood gas on air shows pO_2 7.9 kPa and pCO_2 5.0 kPa. His CD4 count is 164.

What is the most appropriate initial treatment option?

A	Clindamycin and primaquine
B	Further nebulised pentamidine
C	Intravenous Pentamidine with prednisolone
D	Intravenous cefotaxime and oral clarithromycin
E	IV hydrocortisone

acutely unwell with shortness of breath initially only on exertion, but now present even at rest. He has been prescribed HAART and pentamidine nebulisers (co-trimoxazole being unsuitable for him). However, recently he says that he has not had time to come to the clinic for treatment. His chest X-ray shows bilateral air-space shadowing and his arterial blood gas on air shows pO_2 7.9 kPa and pCO_2 5.0 kPa. His CD4 count is 164.

What is the most appropriate initial treatment option?

Your answer was correct

A	Clindamycin and primaquine
B	Further nebulised pentamidine
C	Intravenous Pentamidine with prednisolone
D	Intravenous cefotaxime and

C Intravenous Pentamidine with prednisolone

The patient has an intolerance to co-trimoxazole and has a CD4 count less than 200, so needs pentamidine nebulisers as PCP prophylaxis. If he has not been having these, he is at risk of pneumocystis pneumonia (PCP), which must be treated even before definitive histology can be obtained. The ideal treatment for him is as for severe PCP with respect to antimicrobial therapy, as his pO_2 is below 9.3 kPa. He needs intravenous treatment, of which Pentamidine is second choice after septrin, with oral or intravenous steroids as his pO_2 is below the 9.3 kPa threshold.

A Clindamycin and primaquine

This combination is recommended for moderate Pneumocystis, (the diagnosis here). Given significant hypoxia, IV pentamidine is indicated.

C	Further nebulised pentamidine

This is an appropriate prophylactic treatment, but is not the best management choice for this patient's acute presentation.

D	Intravenous cefotaxime and oral clarithromycin

This antibiotic combination therapy would be suitable if a bacterial aetiology were suspected for his presentation, and may well be appropriate as additional therapy until microbiological confirmation of the organism can be obtained, but the more likely diagnosis of PCP would make this inappropriate as sole therapy.

E	IV hydrocortisone

While corticosteroids are an important adjuvant therapy, they are inadequate as monotherapy in the treatment of PCP.

A 22-year-old woman with cystic fibrosis attends the chest clinic with her partner. They want to start a family before her health deteriorates. She has had several admissions to hospital over the past few years, but currently she feels relatively well. She works at a local estate agent. During a recent admission to hospital with an exacerbation of her cystic fibrosis, a sputum culture revealed a heavy growth of *Pseudomonas*, sensitive to ceftazidime.

Investigations:

Hb	124 g/l (115–165)
WCC	11.2×10^9/l (4.0–11.0)
PLT	197×10^9/l (150–400)
Na^+	139 mmol/l (133–146)
K^+	4.5 mmol/l (3.5–5.3)
Creatinine	110 μmol/l (55–120)
FEV_1	72% of that predicted

Which of the following is the correct

FEV_1	72% of that predicted

Which of the following is the correct advice when it comes to getting pregnant?

A	She should be advised to never get pregnant
B	After treating the acute infection she still has a very high risk of dying/premature delivery of her child
C	After treating the acute infection she has a good chance of a successful pregnancy
D	She is unlikely to conceive due to thickening of the cervical mucus
E	The fact her periods started late indicates subfertility

C After treating the acute infection she has a good chance of a successful pregnancy

Evidence is difficult to evaluate with respect to cystic fibrosis and successful pregnancy. Around 98% of men with CF will be infertile, but the effect of CF on fertility in women is not so clear-cut. The first successful pregnancy in a woman with cystic fibrosis occurred in 1960, and since then increasing number of children have been born to mothers with CF.

D She is unlikely to conceive due to thickening of the cervical mucus

Despite the fact that cervical mucus is thicker, this does not appear to impact significantly on ability to become pregnant. CFTR is found in large quantities on the cervix, which means that cervical mucus remains thick throughout the menstrual cycle.

A	She should be advised to never get pregnant

Pregnancy can be well tolerated in those with mild disease, but in patients whose lung function is poor there is increased likelihood of infant prematurity and death. There may also be loss of maternal lung function with accelerated decline following pregnancy.

B	After treating the acute infection she still has a very high risk of dying/premature delivery of her child

Observational studies suggest that patients with an FEV1 <60% predicted have a much worse outcome both with respect to their own health status and the viability of the pregnancy, and that chronic *Pseudomonas* infection and multiple exacerbations do much worse.

E	The fact her periods started late indicates subfertility

pregnancy.

B	After treating the acute infection she still has a very high risk of dying/premature delivery of her child

Observational studies suggest that patients with an FEV1 <60% predicted have a much worse outcome both with respect to their own health status and the viability of the pregnancy, and that chronic *Pseudomonas* infection and multiple exacerbations do much worse.

E	The fact her periods started late indicates subfertility

Even though menstruation tends to begin later in CF, this does not appear to impact significantly on ability to get pregnant.

21536

Rate this question:

Next Question

A 35-year-old African female presents with a 6-months history of night sweats, shortness of breath on exertion and dry cough. She also gives a history of weight loss and arthralgia over the same period of time. She had been intermittently unwell for 1 year before the development of these symptoms. She recalls a painful rash on her shins 3 months ago, which resolved spontaneously. She gives no history of eye problems, polyuria or polydipsia. She denies chest pain or tightness. She denies any past medical problems and is not on any medications. On examination she appears well at rest. There is no joint swelling or redness. Cardiovascular, respiratory and abdominal examinations are normal. A high resolution CT of the thorax has revealed bilateral hilar lymphadenopathy with evidence of early fibrosis.

Which investigation is most likely to help confirm the diagnosis?

A	Serum angiotensin-converting enzyme (ACE) concentration

examination she appears well at rest. There is no joint swelling or redness. Cardiovascular, respiratory and abdominal examinations are normal. A high resolution CT of the thorax has revealed bilateral hilar lymphadenopathy with evidence of early fibrosis.

Which investigation is most likely to help confirm the diagnosis?

A	Serum angiotensin-converting enzyme (ACE) concentration
B	Pulmonary function tests
C	Quantiferon gamma
D	Bronchoalveolar lavage
E	Transbronchial lung biopsy

32403

Submit

A 35-year-old African female presents with a 6-months history of night sweats, shortness of breath on exertion and dry cough. She also gives a history of weight loss and arthralgia over the same period of time. She had been intermittently unwell for 1 year before the development of these symptoms. She recalls a painful rash on her shins 3 months ago, which resolved spontaneously. She gives no history of eye problems, polyuria or polydipsia. She denies chest pain or tightness. She denies any past medical problems and is not on any medications. On examination she appears well at rest. There is no joint swelling or redness. Cardiovascular, respiratory and abdominal examinations are normal. A high resolution CT of the thorax has revealed bilateral hilar lymphadenopathy with evidence of early fibrosis.

Which investigation is most likely to help confirm the diagnosis?

Your answer was incorrect

E Transbronchial lung biopsy

In this patient of African ethnicity with a description of probable erythema nodosum and a dry cough, the most likely diagnosis is sarcoidosis. Sarcoidosis is a multi-system granulomatous disorder of unknown aetiology and is characterised pathologically by the presence of non-caseating granulomas in involved organs. As with the diagnosis of tuberculosis, a tissue diagnosis is the only completely specific way that a confirmed diagnosis can be made, as all the other diagnostic tests are non-specific to sarcoidosis.

D Bronchoalveolar lavage

In this patient of African ethnicity with a description of probable erythema nodosum and a dry cough, the most likely diagnosis is sarcoidosis. Bronchoalveolar lavage (BAL) can be used as an adjunctive measure to support the diagnosis of sarcoidosis.

support the diagnosis of sarcoidosis. Bronchoalveolar lavage shows lymphocytosis in most patients with active sarcoidosis, but is rarely indicated because patients with hypersensitivity pneumonitis show similar lymphocytosis.

A	Serum angiotensin-converting enzyme (ACE) concentration

In this patient of African ethinicity with a description of probable erythema nodosum and a dry cough, the most likely diagnosis is sarcoidosis. Serum angiotensin-converting enzyme (ACE) activity is elevated in 60% of patients, presumably reflecting macrophage activity. It can also be elevated in patients with histoplasmosis, acute miliary tuberculosis (TB), Gaucher's hepatitis or lymphoma, and is non-specific. Liver disease slows the metabolic excretion of serum ACE and results in increased ACE activity.

B	Pulmonary function tests

In this patient of African ethnicity with a description of probable erythema nodosum and a dry cough, the most likely diagnosis is sarcoidosis. However, pulmonary function tests are non-specific in making this diagnosis. Pulmonary function tests show restriction, decreased compliance and impaired diffusing capacity. However, serial pulmonary function tests are important for assessing disease progression and guiding treatment.

C	Quantiferon gamma

This is an African patient with a dry cough and what sounds like erythema nodosum. Whilst tuberculosis would be in the differential diagnosis, given that she is having night sweats and is systemically unwell, a quantiferon gamma would not confirm or refute a diagnosis of active tuberculosis, as it cannot differentiate between active or latent disease.

32403

Rate this question:

A 28-year-old man who is currently prescribed highly active anti-retroviral therapy (HAART) comes to the clinic for review. He is extremely worried as he has been working in a homeless shelter with a man who has recently been identified as having active pulmonary tuberculosis. He is currently feeling well.

On examination, his BP is 122/72 mmHg, pulse is 80/min and regular and he is apyrexial. His chest is clear. His BMI is 25 and has been stable over the past six months at least. His CD4 count is 420, and an interferon gamma screen for TB is positive.

Which of the following is the most appropriate next step?

A	Quadruple anti-tuberculous therapy with rifampicin, pyrazinamide, ethambutol and isoniazid for six months
B	Dual anti-tuberculous therapy with rifampicin and pyrazinamide for two months

screen for TB is positive.

Which of the following is the most appropriate next step?

A	Quadruple anti-tuberculous therapy with rifampicin, pyrazinamide, ethambutol and isoniazid for six months
B	Dual anti-tuberculous therapy with rifampicin and pyrazinamide for two months
C	Dual anti-tuberculous therapy with rifampicin and isoniazid for three months
D	Monotherapy with isoniazid for six to nine months
E	Monotherapy with isoniazid for one year

D Monotherapy with isoniazid for six to nine months

Monotherapy with isoniazid for six months can be associated with poor compliance but is the regime of choice as per the WHO guidelines on treatment of latent TB in patients with HIV on HAART. This man will hopefully engage with treatment as he seems to have a stable lifestyle. This will give his the best chance of both treating the latent TB and avoiding dangerous drug interactions if a rifampicin containing regime was used.

A Quadruple anti-tuberculous therapy with rifampicin, pyrazinamide, ethambutol and isoniazid for six months

Quadruple anti-tuberculous therapy is the intervention for patients suffering from active TB.

B Dual anti-tuberculous therapy with rifampicin and

B Dual anti-tuberculous therapy with rifampicin and pyrazinamide for two months

In an attempt to improve adherence, a 2-month rifampicin and pyrazinamide regime was considered but this is not widely used because of reported cases of hepatotoxicity.

C Dual anti-tuberculous therapy with rifampicin and isoniazid for three months

This patient fits the criteria for a diagnosis of latent TB and, in this situation, against a background of HIV, anti-tuberculous chemotherapy is considered. A commonly used option is rifampicin and isoniazid for a 3-month period, but this has high incidence of harmful drug interactions with HAART and this patient likely does not have a chaotic lifestyle as he works, so would hopefully engage with monotherapy treatment.

E Monotherapy with isoniazid

This patient fits the criteria for a diagnosis of latent TB and, in this situation, against a background of HIV, anti-tuberculous chemotherapy is considered. A commonly used option is rifampicin and isoniazid for a 3-month period, but this has high incidence of harmful drug interactions with HAART and this patient likely does not have a chaotic lifestyle as he works, so would hopefully engage with monotherapy treatment.

E	Monotherapy with isoniazid for one year

One year of monotherapy with isoniazid is not a commonly recognised regime. The 2015 WHO guidelines on treatment of latent TB discuss monotherapy for up to 36 months in high incidence areas, in lower incidence areas the usual course is six to nine months.

71624

Rate this question:

A 19-year-old student is brought to the Emergency Department by his housemates. He has suffered a chronic cough for the past week and using increasing amounts of his blue inhaler. Ordinarily he is maintained on fluticasone/salmeterol combination inhaler, 250 μg/50 mg BD, and montelukast, 10 mg daily. His housemates don't think he has registered with the student health service and are worried that he may not have filled his prescription.

Clinical features on admission to Emergency are respiratory rate 30/min, PEFR 240 l/min and predicted 590 l/min, and O_2 saturation 90%.

You commence oxygen therapy, give a bolus of IV hydrocortisone and give him a nebuliser containing salbutamol 5 mg and ipratropium 500 μg. The nurses repeat the salbutamol nebuliser three times.

Clinical features later in the evening (on oxygen):

Respiratory rate	15/min

(on oxygen).

Respiratory rate	15/min
PEFR	230 L/min
pH	7.35
pO_2	7.7 kPa
pCO^2	5.8 kPa

What is the most appropriate next step for this gentleman?

A	IV salbutamol therapy
B	IV aminophylline therapy
C	IV magnesium therapy
D	Review by the ITU outreach team
E	Continuous nebulised salbutamol

Emergency are respiratory rate 30/min, PEFR 240 l/min and predicted 590 l/min, and O_2 saturation 90%.

You commence oxygen therapy, give a bolus of IV hydrocortisone and give him a nebuliser containing salbutamol 5 mg and ipratropium 500 µg. The nurses repeat the salbutamol nebuliser three times.

Clinical features later in the evening (on oxygen):

Respiratory rate	15/min
PEFR	230 L/min
pH	7.35
pO_2	7.7 kPa
pCO^2	5.8 kPa

What is the most appropriate next step for this gentleman?

Your answer was incorrect

A	IV salbutamol therapy

D Review by the ITU outreach team

The most appropriate next step in this case would be review by an ITU physician. Despite therapy his peak flow has deteriorated, he is making less respiratory effort and there is evidence of hypoxia with hypercapnia on arterial blood gas testing. He is at risk of respiratory arrest and should be assessed for ventilatory support.

C IV magnesium therapy

IV magnesium is recommended in the management of acute severe asthma, although it may well not reverse the current deterioration in this patient's symptoms. Hence planning for ITU admission is an essential next step.

A IV salbutamol therapy

IV salbutamol gives only limited advantage versus continuous nebuliser therapy, and increases the risk of atrial

A	IV salbutamol therapy

IV salbutamol gives only limited advantage versus continuous nebuliser therapy, and increases the risk of atrial arrhythmia.

B	IV aminophylline therapy

IV aminophylline is no longer considered a first-line therapy for acute asthma because of the limited additional beta agonist efficacy versus continuous nebulisers, against a risk of significant arrhythmia.

E	Continuous nebulised salbutamol

Although continuous nebulised salbutamol is appropriate here, review by the ITU outreach team is crucial with respect to outcomes.

18552

Rate this question:

A 27-year-old pregnant lady is referred to the Emergency Admission for sudden development of shortness of breath. She was well until 2 days ago when she developed shortness of breath. She has some slight left-sided chest pains but no cough or haemoptysis. She is 28 weeks' pregnant and has had no problems with the pregnancy. There is no history of long flights or swelling of her legs. On examination, she appears anxious with a blood pressure of 110/60 mmHg, pulse rate of 92/min and a respiratory rate of 26/min. Her oxygen saturation on air is 98%. Her abdomen is distended and fetal movements are seen. Her chest is clinically clear. Her cardiovascular and lower limb examinations are unremarkable.

Investigations:

Hb	11.3 g/dl
WCC	$10.1 \times 10^9/l$
PLT	$278 \times 10^9/l$
Na^+	139 mmol/l

PLT	278 x 10^9/l
Na^+	139 mmol/l
K^+	3.5 mmol/l
Creatinine	112 µmol/l
MCV	89 fl
Urea	6.1 mmol/l
CRP	6 mg/l (<10)
D-dimers	0.62 mg/l (normal is < 0.25 mg/l)

Which of the following investigations would be the most useful next step?

A	Bilateral lower limb Doppler scan
B	Ventilation/perfusion (V/Q) scan
C	Chest X-ray

MCV	89 fl
Urea	6.1 mmol/l
CRP	6 mg/l (<10)
D-dimers	0.62 mg/l (normal is < 0.25 mg/l)

Which of the following investigations would be the most useful next step?

A	Bilateral lower limb Doppler scan
B	Ventilation/perfusion (V/Q) scan
C	Chest X-ray
D	Pulmonary angiography
E	Echocardiogram

C Chest X-ray

This patient has symptoms of a potential pulmonary embolus, and green top guidance from the RCOG recommends a CXR as an initial step in investigation. Although D-dimers are elevated here, they are unreliable when measured in pregnancy and guidance doesn't support their use.

A Bilateral lower limb Doppler scan

Given that the lower limbs appear normal on examination, bilateral lower limb Doppler scan in this case is unlikely to prove useful in ruling a pulmonary embolus in or out.

B Ventilation/perfusion (V/Q) scan

According to the RCOG guidelines V/Q or CTPA can be considered once the CXR has been performed, although where the CXR has proven to be

CXR has been performed, although where the CXR has proven to be abnormal, CTPA is preferred to V/Q.

D	Pulmonary angiography

CTPA is the preferred investigation post CXR in the event that the chest X-ray is found to be abnormal. The choice between CTPA and V/Q is a balance between risk of radiation exposure to the pregnant woman's breast tissue (much higher for CTPA) and radiation exposure to the fetus (which is higher for V/Q scanning).

E	Echocardiogram

Echo is most useful as a bedside investigation when there is a high suspicion of PE and the patient is unstable. It may reveal evidence of right ventricular strain.

7510

Rate this question:

A 20-year-old man has recently started work in the bakery section of his local supermarket. He complains of increasing shortness of breath, cough and wheeze during the course of the working week. These symptoms resolve somewhat at weekends and improved markedly during a week's holiday in Spain. Examination in the clinic on a Monday morning reveals no evidence of wheeze; peak flow is 520 (540 predicted).

Which of the following initial actions is most appropriate in this case?

A	Trial of salbutamol
B	2-hourly peak flow recordings during the week, comparing work to rest periods
C	Chest X-ray
D	Bronchial provocation testing
E	Patch testing

increasing shortness of breath, cough and wheeze during the course of the working week. These symptoms resolve somewhat at weekends and improved markedly during a week's holiday in Spain. Examination in the clinic on a Monday morning reveals no evidence of wheeze; peak flow is 520 (540 predicted).

Which of the following initial actions is most appropriate in this case?

A	Trial of salbutamol
B	2-hourly peak flow recordings during the week, comparing work to rest periods
C	Chest X-ray
D	Bronchial provocation testing
E	Patch testing

B 2-hourly peak flow recordings during the week, comparing work to rest periods

It is important to establish the relationship of deterioration in peak flow to work periods as there is a suspicion of occupational asthma here. Occupational asthma in bakers may occur due to flour dust or to other allergens used in making breads and cakes. Review of the worker's work pattern, allowing for removal of exposure to the potential allergen, is optimal therapy, of course with the cooperation of the employer.

A Trial of salbutamol

A trial of salbutamol is inappropriate given the likely history of occupational triggers for this patient's asthma. Removal of exposure to any potential allergen is much more important than starting asthma therapy.

C Chest X-ray

Removal of exposure to any potential allergen is much more important than starting asthma therapy.

C Chest X-ray

A chest x-ray is not useful when evaluating potential bronchoconstriction related to asthma.

D Bronchial provocation testing

Bronchial provocation testing should only be undertaken in specialised centres, with appropriate anaesthetist support, and only when there is doubt as to the underlying trigger.

E Patch testing

Patch testing is rarely useful in evaluating occupational asthma.

32435

Rate this question:

Next Question

10:36
tps://mypastest.pastest.com
13

A 64-year-old man with a history of COPD managed with high-dose fluticasone and salmeterol (combined) comes to the Emergency Department for review. He has attended the clinic for routine follow up, where he was found on CXR to have a 1.5 cm pneumothorax. On aspiration this reduces to 0.75 cm. There is no significant shortness of breath.

Which of the following is the most appropriate next step?

A	Discharge with follow-up in 24 h
B	Admit for formal chest drain
C	Admit overnight for oxygen supplementation
D	Repeat aspiration

COPD managed with high dose fluticasone and salmeterol (combined) comes to the Emergency Department for review. He has attended the clinic for routine follow up, where he was found on CXR to have a 1.5 cm pneumothorax. On aspiration this reduces to 0.75 cm. There is no significant shortness of breath.

Which of the following is the most appropriate next step?

A	Discharge with follow-up in 24 h
B	Admit for formal chest drain
C	Admit overnight for oxygen supplementation
D	Repeat aspiration
E	Discharge with follow-up in 2 weeks

A 64-year-old man with a history of COPD managed with high-dose fluticasone and salmeterol (combined) comes to the Emergency Department for review. He has attended the clinic for routine follow up, where he was found on CXR to have a 1.5 cm pneumothorax. On aspiration this reduces to 0.75 cm. There is no significant shortness of breath.

Which of the following is the most appropriate next step?

Your answer was incorrect

A	Discharge with follow-up in 24 h
B	Admit for formal chest drain
C	Admit overnight for oxygen supplementation
D	Repeat aspiration

C Admit overnight for oxygen supplementation

This man has a history of COPD, and therefore this case follows the secondary pneumothorax line of the BTS algorithm with respect to management. Because, after aspiration the pneumothorax has reduced in size to <1 cm, observation overnight with oxygen supplementation is the management of choice.

E Discharge with follow-up in 2 weeks

This is the correct course of action when a primary pneumothorax has been successfully aspirated.

A Discharge with follow-up in 24 h

Discharge of patients with pneumothorax applies if primary pneumothorax has occurred and has been successfully aspirated; however

A Discharge with follow-up in 24 h

Discharge of patients with pneumothorax applies if primary pneumothorax has occurred and has been successfully aspirated; however, review within 2–4 weeks is advised.

B Admit for formal chest drain

Admission and insertion of a chest drain is only required if air aspiration of the pneumothorax has proved unsuccessful.

D Repeat aspiration

Repeat aspiration is not required. In the event that air aspiration is unsuccessful, insertion of an 8–14 Fr chest drain is the next step.

36568

Rate this question:

Next Question

A 39-year-old man presented to his GP with a 3-month history of fever, rhinitis and weight loss. Two weeks ago he had an exacerbation of asthma and was treated with a course of erythromycin. He also complained of weakness in his hands and legs. He has a past medical history of angina. He is an ex-smoker and stopped 5 years ago.

On examination he has a rash on his shins, shown below.

Auscultation of his chest reveals a mild expiratory wheeze. Examination was otherwise unremarkable. Urinalysis was normal.

normal.

Investigations:

Hb	12.1 g/dl
MCV	84 fl
WCC	9.4×10^9/l
Neutrophils	5.3×10^9/l
Lymphocytes	1.8×10^9/l
Monocytes	0.3×10^9/l
Basophils	0.08×10^9/l
Eosinophils	1.9 × 10(9)/l
PLT	411×10^9/l
ESR	82 mm/1st hour
Na^+	138 mmol/l
K^+	4.2 mmol/l
Urea	4.1 mmol/l
Creatinine	111 micromol/l

What is the diagnosis?

ESR	82 mm/1st hour
Na^+	138 mmol/l
K^+	4.2 mmol/l
Urea	4.1 mmol/l
Creatinine	111 micromol/l

What is the diagnosis?

A	Microscopic polyangiitis
B	Granulomatosis with polyangiitis
C	Eosinophilic pneumonia secondary to erythromycin
D	Churg Strauss syndrome
E	Allergic bronchopulmonary aspergillosis

D Churg Strauss syndrome

The patient has systemic symptoms, asthma, eosinophils >1.5 × 10^9/l and evidence of vasculitis in two or more non-lung organs (Lanham's criteria):

- Cutaneous vasculitis (see picture)
- Mononeuritis multiplex
- A cardiac history.

The American Criteria of Rheumatology require four out of six of the following to be present for a diagnosis of Churg–Strauss syndrome:

- The presence of asthma
- Eosinophils >10% in the peripheral blood
- Evidence of a neuropathy in a vasculitic pattern, e.g. mononeuritis multiplex
- Transient pulmonary infiltrates
- A history of sinus disease

- Evidence of intravascular eosinophils on biopsy.

Renal involvement in Churg–Strauss syndrome is very rare.

A	Microscopic polyangiitis

Microscopic polyangiitis is associated with renal disease. The absence of any evidence of glomerulonephritis counts against this as the underlying diagnosis.

B	Granulomatosis with polyangiitis

Granulomatosis with polyangiitis is associated with glomerulonephritis, which has not been demonstrated here.

C	Eosinophilic pneumonia secondary to erythromycin

The symptoms preceded erythromycin

Granulomatosis with polyangiitis is associated with glomerulonephritis, which has not been demonstrated here.

C	Eosinophilic pneumonia secondary to erythromycin

The symptoms preceded erythromycin administration, making eosinophilic pneumonia unlikely.

E	Allergic bronchopulmonary aspergillosis

Allergic bronchopulmonary aspergillosis usually occurs in asthmatics, but would not produce the signs and symptoms of vasculitis as in this patient, including the obvious skin lesions.

70091

Rate this question:

Next Question

A 38-year-old man with known alpha-1-antitrypsin deficiency presents to the hospital with a spontaneous right-sided pneumothorax. A chest drain is inserted and initially appears to work correctly, but is then noted to be swinging and bubbling. However, after three days, the fluid level stops swinging and the nurses notice he has begun to develop surgical emphysema. He complains of renewed, severe, right-sided pain.

On examination, he has diminished breath sounds on the right and a resonant percussion note. You notice that the drain has been clamped. On further questioning, it transpires that nursing staff had seen that the drain had stopped swinging.

Which of the following is the most appropriate next step?

A	Formal PA chest film
B	AP erect chest film

begun to develop surgical emphysema. He complains of renewed, severe, right-sided pain.

On examination, he has diminished breath sounds on the right and a resonant percussion note. You notice that the drain has been clamped. On further questioning, it transpires that nursing staff had seen that the drain had stopped swinging.

Which of the following is the most appropriate next step?

A	Formal PA chest film
B	AP erect chest film
C	Lateral chest X-ray
D	Unclamp the drain
E	Pull the chest drain back by 1 cm

D Unclamp the drain

There is evidence to suggest that this patient is unstable, with renewed pain and surgical emphysema. It is possible that he has an air leak into the tissues around the insertion site. Transferring him to the radiology department may put him at significant risk. The optimal course of action is to unclamp the drain immediately and arrange for an urgent portable chest X-ray. Further management will be guided by the clinical and radiological findings after unclamping the drain and obtaining imaging.

C Lateral chest X-ray

As before, this would necessitate an intra-hospital transfer with an unstable patient and will not add anything additional that a portable chest X-ray can provide after the drain has been unclamped.

A Formal PA chest film

The patient in the scenario is unstable, and transferring the patient to the radiology department may put them at risk. After the drain has been unclamped, a portable chest X-ray will provide the required information in a safer and more timely manner.

B	AP erect chest film

Whilst a portable chest X-ray is required, the immediate management is to unclamp the drain as this may allow the pneumothorax to drain and prevent the situation from deteriorating further.

E	Pull the chest drain back by 1 cm

The safest thing to do is to unclamp the drain and obtain an urgent X-ray to assess position and clinical status. Depending on findings, the drain may need to be pulled back after reviewing the imaging, but it is not the initial step.

An 18-year-old male attends his GP complaining of fever and a productive cough present for 2 weeks. He initially thought it was flu but the symptoms have been getting worse and not better. He is concerned since he is the main breadwinner at home for his elderly parents, who have just returned from a trip to India. On further questioning he admits to having lost his appetite recently, and at night-time suffers from terrible sweating, drenching the bed sheets. On the basis of the history and his clinical examination, the GP suspects a diagnosis of tuberculosis. An urgent referral is made to the local Chest Clinic to confirm the diagnosis, and tests confirm that the diagnosis is correct. The patient is commenced on standard treatment for pulmonary tuberculosis. He returns to the GP several weeks later, stating that he has noticed deterioration in his eyesight since his diagnosis.

Which of the following is most likely to be responsible for this side effect?

referral is made to the local Chest Clinic to confirm the diagnosis, and tests confirm that the diagnosis is correct. The patient is commenced on standard treatment for pulmonary tuberculosis. He returns to the GP several weeks later, stating that he has noticed deterioration in his eyesight since his diagnosis.

Which of the following is most likely to be responsible for this side effect?

A	Ethambutol
B	Rifampicin
C	Isoniazid
D	Pyrizinamide
E	Streptomycin

6806

Submit

A Ethambutol

The standard medical treatment of pulmonary tuberculosis consists of an initial phase of 2 months on rifampicin, isoniazid, pyrazinamide and ethambutol. This is followed by a further 4-month continuation phase on isoniazid and rifampicin only. There are some combination preparations that may also be used, but this depends on their availability. Prior to treatment, it is imperative to stress the importance of compliance. Also, both liver and renal function should be assessed prior to commencing therapy. Visual acuity, colour vision and visual fields should also be tested, preferably by an ophthalmologist, both before and during treatment with ethambutol since ocular toxicity may occur.

B Rifampicin

This is associated with orange discoloration of secretions such as tears and urine. GI symptoms and

discoloration of secretions such as tears and urine, GI symptoms and alteration of hepatic function.

C Isoniazid

This is associated with peripheral neuropathy in high doses, GI upset, agranulocytosis and haemolytic anaemia.

D Pyrizinamide

This is associated with GI upset and hepatotoxicity.

E Streptomycin

This is associated with vestibular and renal toxicity.

6806

Rate this question:

Next Question

You admit a 73-year-old man to the Emergency Department. He has had influenza over the past few days and has a worsening cough productive of purulent, blood-stained sputum. Observations: BP 122/72 mmHg, pulse 90/min and regular, respiratory rate 28/min. There are signs of right lower lobe pneumonia. A routine blood screen including arterial blood gas is performed.

Which one of the following features on admission is likely to be associated with a poorer prognosis when symptoms, signs and investigations are reviewed?

A	Age
B	Respiratory rate 28/min
C	Serum urea 6 mmol/l
D	Albumin 37 g/l
E	ALT slightly outside the

has a worsening cough productive of purulent, blood-stained sputum. Observations: BP 122/72 mmHg, pulse 90/min and regular, respiratory rate 28/min. There are signs of right lower lobe pneumonia. A routine blood screen including arterial blood gas is performed.

Which one of the following features on admission is likely to be associated with a poorer prognosis when symptoms, signs and investigations are reviewed?

A	Age
B	Respiratory rate 28/min
C	Serum urea 6 mmol/l
D	Albumin 37 g/l
E	ALT slightly outside the normal range

A Age

Age >65 years is associated with a poorer prognosis in acute pneumonia. Other features not present here and which are associated with poorer prognosis include:

- confusion;
- urea >7 mmol/l;
- respiratory rate >30/min;
- blood pressure <90 systolic or <60 diastolic.

These features plus age make up the CURB-65 criteria. Where all five features are present, mortality from pneumonia is >50%, whereas 0-1 features carries a mortality rate of <3%.

B Respiratory rate 28/min

The normal respiratory rate is 12-20 breaths per minute. It is likely to be elevated in the context of pneumonia, due both to the lung pathology and

A 50-year-old housewife is being followed up in the chest clinic for her asthma. Over the past 2 years she has had intermittent low-grade fevers, weight loss, cough and shortness of breath. On examination she has end-expiratory wheeze with occasional crackles that do not resolve on coughing. She does not have any clubbing. She is a non-smoker. Her past medical history includes asthma and atrial fibrillation. Her drug history includes salbutamol inhaler, high-dose steroid inhaler and amiodarone. Her chest X-ray shows peripheral infiltrates on the outer two-thirds of the peripheries. Her sputum microbiology is negative but she has a raised number of eosinophils. Her blood tests show a raised serum eosinophil count, IgG and ESR.

Which of the following is the most likely diagnosis?

A	Amiodarone-induced fibrosis
B	Chronic eosinophilic

steroid inhaler and amiodarone. Her chest X-ray shows peripheral infiltrates on the outer two-thirds of the peripheries. Her sputum microbiology is negative but she has a raised number of eosinophils. Her blood tests show a raised serum eosinophil count, IgG and ESR.

Which of the following is the most likely diagnosis?

A	Amiodarone-induced fibrosis
B	Chronic eosinophilic pneumonia (CEP)
C	Allergic bronchopulmonary aspergillosis (ABPA)
D	Treatment-resistant asthma
E	Acute eosinophilic pneumonia (AEP)

A 50-year-old housewife is being followed up in the chest clinic for her asthma. Over the past 2 years she has had intermittent low-grade fevers, weight loss, cough and shortness of breath. On examination she has end-expiratory wheeze with occasional crackles that do not resolve on coughing. She does not have any clubbing. She is a non-smoker. Her past medical history includes asthma and atrial fibrillation. Her drug history includes salbutamol inhaler, high-dose steroid inhaler and amiodarone. Her chest X-ray shows peripheral infiltrates on the outer two-thirds of the peripheries. Her sputum microbiology is negative but she has a raised number of eosinophils. Her blood tests show a raised serum eosinophil count, IgG and ESR.

Which of the following is the most likely diagnosis?

Your answer was correct

A Amiodarone-induced fibrosis

B Chronic eosinophilic pneumonia (CEP)

Eosinophilic pneumonia is a rare respiratory pathology characterised by pulmonary infiltrates and pulmonary eosinophilia. It can be idiopathic or secondary to parasites, drugs or systemic diseases such as vasculitis. The peripheral eosinophil count is not always raised. The serum IgG is raised in two-thirds and the ESR is elevated. Sputum and bronchoalveolar lavage often show an eosinophilia.

This presents over months to years. CEP usually occurs in those aged in their 50s, with a female:male ratio of 2:1. It can be irreversible. About 60% of patients with CEP have asthma and 90% are non-smokers. Patients present with constitutional symptoms, cough, wheeze and fever. Chest X-ray in CEP shows dense, bilateral peripheral infiltrates often 'opposite to pulmonary oedema' with a distribution in the outer two-thirds of the lung. Treatment is with steroids.

A	Amiodarone-induced fibrosis

In this condition, changes are usually seen in the bases. The treatment is to stop the drug, and steroids may help.

C	Allergic bronchopulmonary aspergillosis (ABPA)

There would be an elevated total serum IgE rather than IgG and IgG precipitins to *Aspergillus fumigatus*.

D	Treatment-resistant asthma

Asthma does not present with intermittent low-grade fevers, and CXR would be normal rather than show pulmonary infiltrates.

E	Acute eosinophilic pneumonia (AEP)

This presents over a few days. Patients with AEP are acutely unwell with temperature, tachycardia and

C	Allergic bronchopulmonary aspergillosis (ABPA)

There would be an elevated total serum IgE rather than IgG and IgG precipitins to *Aspergillus fumigatus*.

D	Treatment-resistant asthma

Asthma does not present with intermittent low-grade fevers, and CXR would be normal rather than show pulmonary infiltrates.

E	Acute eosinophilic pneumonia (AEP)

This presents over a few days. Patients with AEP are acutely unwell with temperature, tachycardia and tachypnoea. AEP chest X-ray may show bilateral diffuse infiltrates associated with an effusion.

32445

Rate this question:

Next Question

11:01
https://www.google.com/sea
13

Radiopaedia

Chronic eosinophilic pneumonia | Radiology Case | Radiopaedia.o...

Chronic eosinophilic pneumonia

Images may be subject to copyright. Learn More

RELATED IMAGES SEE MORE

11:02

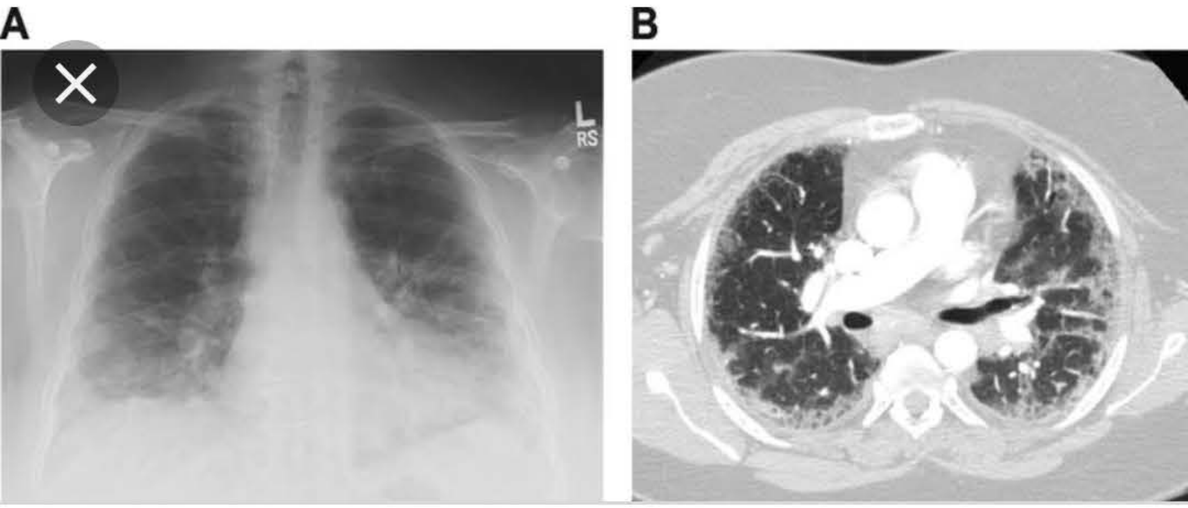

ResearchGate

Representative chest X-ray (A) and CT scan (B) of chronic ...

Representative chest X-ray (A) and CT scan (B) of chronic

Images may be subject to copyright. Learn More

RELATED IMAGES SEE MORE

The Radiology Assistant : Lun...
radiologyassistant.nl

Pulmonary toxicity from cardi...
pneumon.org

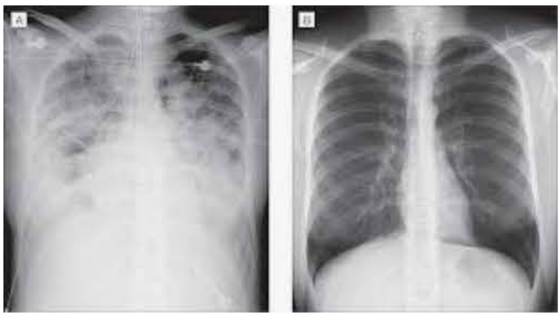

Acute Eosinophilic Pneumoni...
jamanetwork.com

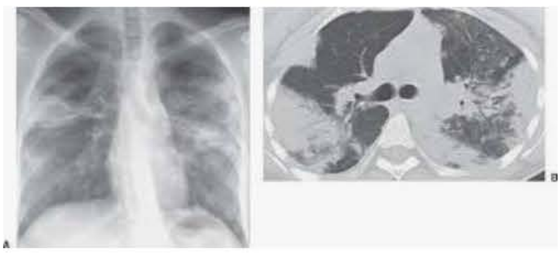

Bronchial Pneumonia Lungs -...
thegolfclub.info

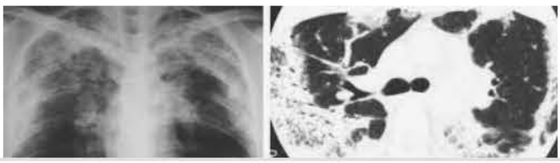

11:02

Respiratory Care

Chronic Eosinophilic Pneumonia in a Breast Cancer Patient Post ...

Download figure ...

Images may be subject to copyright. Learn More

RELATED IMAGES SEE MORE

American Thoracic Society - ...

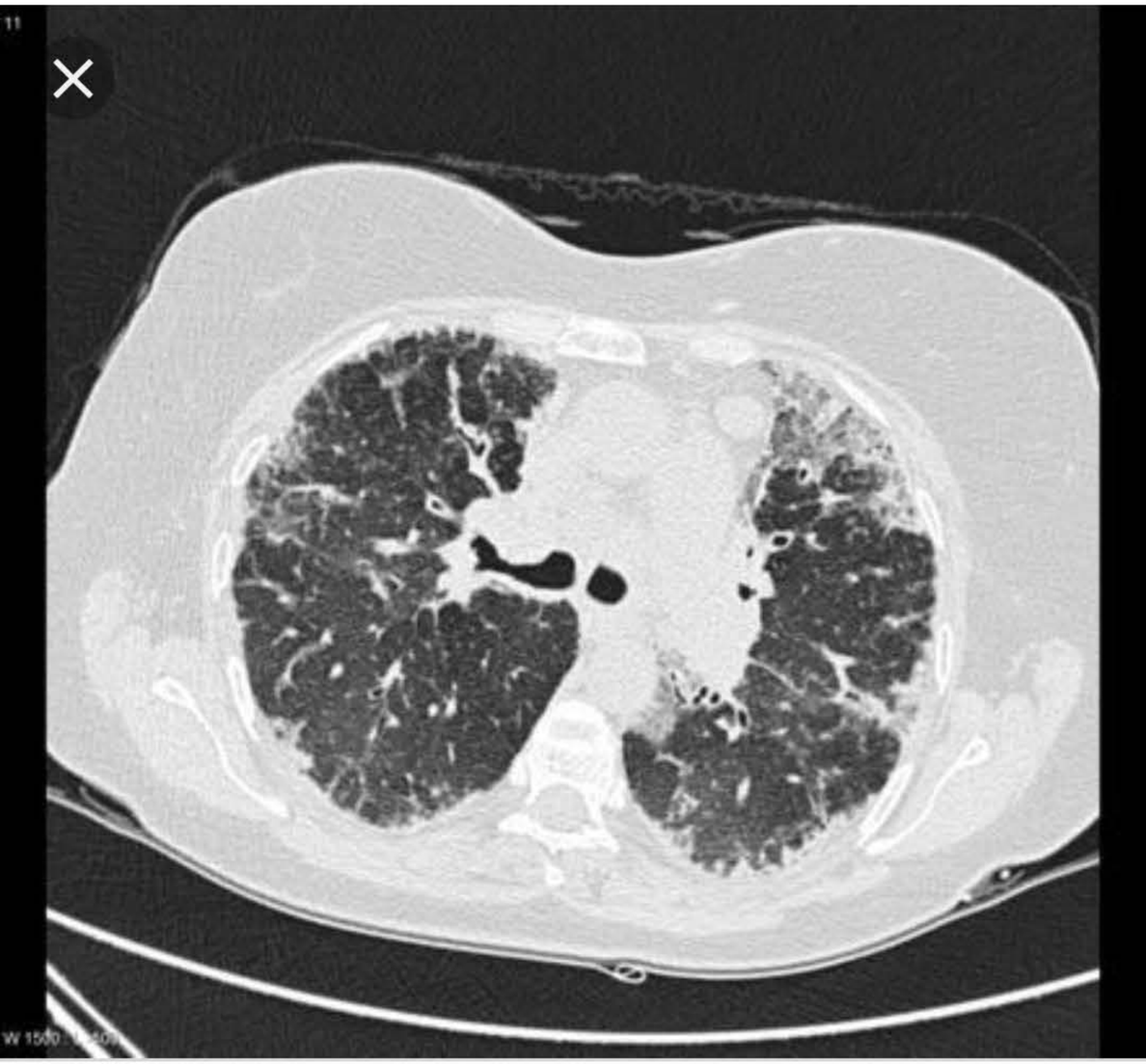

Radiopaedia

Chronic eosinophilic pneumonia | Radiology Reference Article ...

Chronic eosinophilic pneumonia | Radiology Reference Article | Radiopaedia.org

Images may be subject to copyright. Learn More

RELATED IMAGES SEE MORE

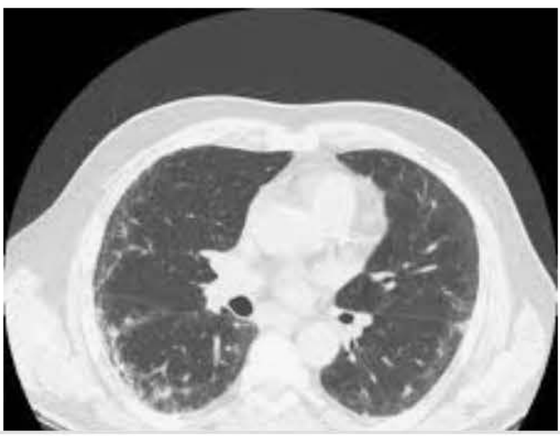

11:03

radiopaedia.org

Acute eosinophilic pneumonia | Radiology Case | Radiopaedia.o...

Images may be subject to copyright. Learn More

RELATED IMAGES

SEE MORE

11:03

rc.rcjournal.com

Eosinophilic Pneumonia Associated With Azacitidine in ...

Eosinophilic pneumonia is characterized by cough, lung infiltrates on imaging, and by the presence of eosinophils in the alveoli and pulmonary interstitium. Azacitidine, a pyramidine nucleoside...

Images may be subject to copyright. Learn More

RELATED IMAGES SEE MORE

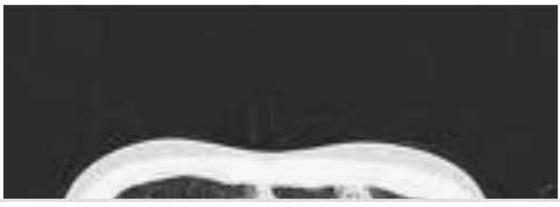

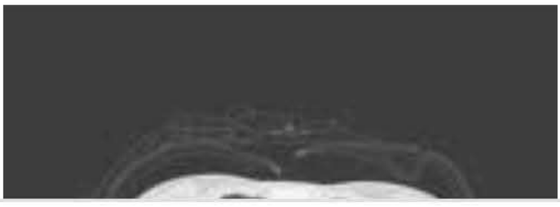

A 30-year-old man from London, with no significant past medical history, went on holiday to Peru to climb the Inca Trail. He is a non-smoker. After climbing above 3500 m he developed a headache, associated with nausea and vomiting. He also felt tired and complained of insomnia. His respiratory rate was 22/min and his pulse was 90/min. The rest of the physical examination was unremarkable. No investigations are available as the nearest hospital is over 100 km away. That night it was noticed that he was disorientated and walking with a broad-based gait, and by the following morning he was drowsy and incoherent.

How would you treat this man?

A	Immediate transfer down the mountain
B	Acetazolamide and continue ascent
C	Aspirin

that he was disorientated and walking with a broad-based gait, and by the following morning he was drowsy and incoherent.

How would you treat this man?

A	Immediate transfer down the mountain
B	Acetazolamide and continue ascent
C	Aspirin
D	Dexamethasone and continue ascent
E	Immediate antibiotics

70109

Submit

A Immediate transfer down the mountain

There are three types of altitude illness: acute mountain sickness (AMS), high-altitude cerebral oedema (HACE) and high-altitude pulmonary oedema (HAPE). This man has acute mountain sickness with some evidence of cerebral oedema. The exact cause is unknown, but it is thought to be secondary to cerebral oedema and raised intracranial pressure. It is more common in people who live at low altitude.

Symptoms and signs of AMS are non-specific; however, diagnosis can be made using the criteria named in 'The Lake Louise Score', namely, the setting of recent gain in altitude, the presence of headache and at least one of the following symptoms:

- Gastrointestinal – anorexia, nausea and vomiting
- Fatigue and weakness

nausea and vomiting

- Fatigue and weakness
- Dizziness or light-headedness
- Difficulty sleeping.

If he does not improve and progresses to develop ataxia and drowsiness, this is the development of high-altitude cerebral oedema, which can be considered as end-stage AMS. This is the presentation of this case.

D	Dexamethasone and continue ascent

This patient has full house symptoms of altitude sickness and is at high risk of further deterioration. Further ascent even with acetazolamide would be dangerous.

B	Acetazolamide and continue ascent

Acetazolamide may be used for the prevention and treatment of AMS. This

54-year-old stonemason was referred to the clinic with a 3-year history of progressive breathlessness. He is an ex-smoker (40 pack-years), having stopped 14 years ago.

On examination he looked well, was not clubbed and there was no lymphadenopathy. His chest was hyper-expanded and he had basal inspiratory crackles.

His spirometry revealed:

FEV_1	58% predicted (1.71 litres)
FVC	70% predicted (2.4 litres)
KCO	55% predicted

His CXR is shown below:

What is the most underlying diagnosis?

A	Silicosis
B	Asbestosis
C	Byssinosis
D	Berylliosis
E	Simple pneumoconiosis

70077

11:09
tps://mypastest.pastest.com
13

54-year-old stonemason was referred to the clinic with a 3-year history of progressive breathlessness. He is an ex-smoker (40 pack-years), having stopped 14 years ago.

On examination he looked well, was not clubbed and there was no lymphadenopathy. His chest was hyper-expanded and he had basal inspiratory crackles.

His spirometry revealed:

FEV_1	58% predicted (1.71 litres)
FVC	70% predicted (2.4 litres)
KCO	55% predicted

His CXR is shown below:

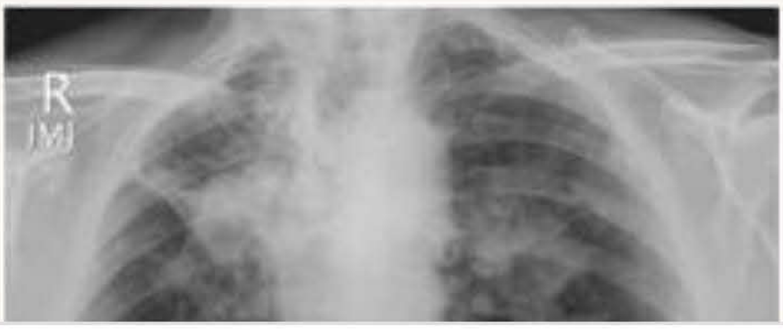

A Silicosis

Silicosis is a fibrotic lung disease associated with inhalation of silica (silicon dioxide), which is highly fibrogenic. It is usually seen in quarrying and mining occupations and in sandblasters, ceramic workers, pottery workers and in stonemasons if the dust generated contains quartz.

Acute silicosis may present within 12 months if exposure has been heavy, and is characterised by dry cough and breathlessness. Patients deteriorate rapidly over 1–2 years and there is no effective treatment to slow the progression.

Chronic silicosis runs a more chronic course, as in this patient, and is associated with a gradual worsening of breathlessness, with restrictive lung function and a reduced transfer factor.

Chronic silicosis is associated with silicotic nodule formation (3–5 mm in diameter), predominantly affecting the upper lobes. These nodules may

silicotic nodule formation (3–5 mm in diameter), predominantly affecting the upper lobes. These nodules may coalesce and cause progressive massive fibrosis. Diagnosis is made on history of exposure and XR changes. The CXR may show hilar eggshell calcification (pathognomonic of silicosis), as in the CXR shown, with or without upper zone pulmonary nodules and fibrosis.

B Asbestosis

There is no mention of potential exposure to asbestos, and the chest radiograph shows no pleural or diaphragmatic calcification to suggest previous asbestos exposure.

C Byssinosis

Byssinosis is associated with exposure to cotton dust, flax and hemp.

D Berylliosis

A 39-year old Irish accountant was referred to the clinic with a 4-month history of progressive breathlessness. He noticed this mainly on climbing the stairs. Over the last few months he had been using some eye drops from the local pharmacy for dry eyes. He was also complaining of fatigue, night sweats and polyuria. He was a non-smoker and drank 20 units of alcohol per week.

On examination he had conjunctival injection, but examination of his eyes was otherwise unremarkable. He had no rash or joint swelling. On auscultation of his chest he had fine inspiratory crackles. Heart sounds were normal. He had no organomegaly on palpation of the abdomen. Urinalysis was unremarkable.

Investigations:

Hb	10.1 g/dl
WCC	6.4×10^9/l
PLT	201×10^9/l
Na+	141 mmol/l

PLT	201×10^9/l
Na+	141 mmol/l
K+	3.9 mmol/l
Creatinine	100 µmol/l
MCV	84 fl
ESR	45 mm/1st h
Urea	7.2 mmol/l
Bilirubin	23 µmol/l
AST	51 U/l
ALP	91 U/l
Albumin	45 g/l
Tuberculin test	-
FEV1	75% predicted
FVC	70% predicted
TLCO	80% predicted

His CXR is shown below.

Which of the following is most likely to give you a definitive diagnosis?

A	Serum angiotensin-converting enzyme
B	Sputum for microbiology
C	Bronchoscopy and transbronchial biopsies
D	Bronchoscopy and endobronchial biopsies
E	Kveim test

C Bronchoscopy and transbronchial biopsies

The most likely diagnosis is sarcoidosis. This is a relatively young patient with breathlessness, dry eyes, fatigue, night sweats and polyuria. He has a normocytic anaemia, a raised ESR and slightly deranged liver function tests.

Sarcoid is a multi-system granulomatous disorder of unknown aetiology with a number of different presentations. It usually presents in the under-forties, and is more common in women and persons of West Indian and African descent. Presentation may be with erythema nodosum, bilateral hilar lymphadenopathy on chest radiography with fever or arthralgia (Löfgren syndrome) or, more insidiously, with symptoms such as dyspnoea, dry cough, fever, malaise and weight loss. The main differential diagnoses are TB and lymphoma.

The diagnosis is suggested from a chest X-ray and high-resolution CT.

The diagnosis is suggested from a chest X-ray and high-resolution CT. High-resolution CT characteristically shows features such as hilar and mediastinal lymphadenopathy, peribronchovascular nodules, ground-glass shadowing, parenchymal bands, cysts and fibrosis. Pulmonary involvement can be classified according to the radiographic stage of the disease:

Stage 0: Clear chest radiograph
Stage 1: Bi-hilar adenopathy
Stage 2: Bi-hilar adenopathy and interstitial infiltrates
Stage 3: Diffuse interstitial disease
Stage 4: Advanced fibrosis.

Transbronchial biopsy is the investigation with the highest yield, as positive results are seen in 90% of patients with pulmonary sarcoidosis. Endobronchial biopsies are also useful, but less sensitive. Histology typically shows non-caseating granulomas composed of macrophages, lymphocytes and epithelioid histiocytes, which fuse to form multinucleate giant cells.

The lung function tests depend on severity of the disease. The tuberculin test is negative in 80% of patients with sarcoidosis, but clinicians must be mindful that anergy can also be seen in HIV-positive patients or patients who have overwhelming TB.

Treatment is rarely required in stage 0 or 1 disease. Corticosteroids should be given to patients with stage 2 or higher disease with deterioration in lung function or in patients with ocular sarcoid, hypercalcaemia, severe or persistent erythema nodosum, myocardial and neurological manifestations of sarcoidosis. Prednisolone dose is 0.5 mg/kg for first 4 weeks of treatment and is then down-titrated to the lowest maintenance dose that controls the disease. Treatment withdrawal should be considered after 6–24 months. Steroid-sparing agents such as methotrexate or azathioprine may be used for relapsing disease.

Common clinical characteristics of sarcoidosis include:

- Skin:
  Erythema nodosum – caution, not always on the shins
  Lupus pernio – red crusty lesions, often around the nose
  Annular lesion
- Polyuria:
  Secondary to hypercalciuria/hypercalcaemia (can also cause renal calculi and nephrocalcinosis)
  Secondary to central diabetes insipidus
- Cardiac:
  Ventricular arrhythmias
  Conduction defects
  Cardiomyopathy
  Congestive cardiac failure
- Neurological:
  Involvement of CNS occurs in 2%
  Cranial diabetes insipidus
- Ocular:
  Anterior uveitis
  Conjunctivitis

Conjunctivitis
Retinal lesions
Keratoconjunctivitis sicca and lacrimal gland enlargement
Optic neuritis

- Metabolic:
  Hypercalcaemia and hypercalciuria
- Bone and joints:
  Arthralgia
  Bone cysts

Others:
Hepatosplenomegaly
Löfgren syndrome (acute sarcodosis) – triad of bi-hilar lymphadenopathy, arthritis and erythema nodosum.

A	Serum angiotensin-converting enzyme

Serum ACE is not a specific test for sarcoidosis. Raised ACE levels are also seen in pulmonary TB, asbestosis, silicosis and lymphoma. It is elevated in about 75% of patients with untreated

about 75% of patients with untreated sarcoid. The value of using serum ACE to monitor disease activity remains unclear – currently inflammatory markers are thought to be more useful.

B	Sputum for microbiology

This is not a history of infection. Sputum culture will be negative. Culture may be useful in the event that TB is suspected, although there is no history of potential TB exposure.

D	Bronchoscopy and endobronchial biopsies

Endobronchial biopsies may give a diagnosis of sarcoidosis, but transbronchial biopsies in addition to endobronchial biopsies will give a higher yield.

E	Kveim test

The Kveim test is now obsolete because of potential infection risk. It

A 62-year-old woman presents to the Emergency Admission with a cough, which she has had for the past three days. She was previously well until she got this cough, which is productive of purulent sputum. She also has right-sided chest pains, fever and some shortness of breath.

On examination, she is confused, febrile with a blood pressure of 89/60 mmHg, pulse rate of 102/min and a respiratory rate of 31/min. Her oxygen saturation is 89%. She has right-sided upper lobe bronchial sounds on auscultation. Her abdominal examination is unremarkable.

Investigations:

Hb	12.3 g/dl
WCC	15.1×10^9/l
PLT	178×10^9/l
Na^+	133 mmol/l
K^+	3.2 mmol/l
Creatinine	112 μmol/l

Creatinine	112 μmol/l
MCV	89 fl
Urea	8.1 mmol/l
CRP	59
CXR	Right upper lobe consolidation

What would be the most appropriate next step in her immediate management?

A	Start oral antibiotics
B	Intravenous fluids
C	High-flow oxygen mask for delivery of 60–80% F_iO_2
D	Hypertonic saline solution
E	Potassium supplements

febrile with a blood pressure of 89/60 mmHg, pulse rate of 102/min and a respiratory rate of 31/min. Her oxygen saturation is 89%. She has right-sided upper lobe bronchial sounds on auscultation. Her abdominal examination is unremarkable.

Investigations:

Hb	12.3 g/dl
WCC	15.1×10^9/l
PLT	178×10^9/l
Na^+	133 mmol/l
K^+	3.2 mmol/l
Creatinine	112 µmol/l
MCV	89 fl
Urea	8.1 mmol/l
CRP	59
CXR	Right upper lobe consolidation

What would be the most appropriate

C High-flow oxygen mask for delivery of 60–80% F_iO_2

This woman has severe pneumonia, which has a mortality of about 10% in patients admitted to hospital. Features of severity include: confusion, urea > 7.0 mmol/l, respiratory rate ≥ 30/min, blood pressure (BP) < 90 systolic. A score of > 2 indicates severe pneumonia. She would of course, as rapidly as possible, need intravenous antibiotics, fluids, oxygen and analgesia. In this situation the most marked abnormality is the O_2 saturation of 89%, and this should therefore be addressed first.

A Start oral antibiotics

This would be inappropriate as the patient is septic secondary to a chest infection and needs intravenous (iv) antibiotics. Sepsis is defined as meeting two or more of SIRS criteria with a suspected source of infection. SIRS criteria include temperature

outside of 36–38°C, heart rate > 90, respiratory rate > 20 or $PaCO_2$ < 32 mmHg and WBC outside of 4–12/mm^3. This patient has at least three of these criteria.

B	Intravenous fluids

Whilst iv fluids should be given very urgently, it is of greater importance to ensure that the patient has good oxygenation.

D	Hypertonic saline solution

This is inappropriate. There is only mild hyponatraemia, which does not need to be correct urgently, and standard crystalloid fluids could be used for resuscitation. Hypertonic saline can be used in patients with chronic hyponatraemia with symptoms and sodium < 120 mmol/l.

E	Potassium supplements

Potassium supplements should be

SIRS criteria include temperature outside of 36–38°C, heart rate > 90, respiratory rate > 20 or $PaCO_2$ < 32 mmHg and WBC outside of 4–12/mm^3. This patient has at least three of these criteria.

B	Intravenous fluids

Whilst iv fluids should be given very urgently, it is of greater importance to ensure that the patient has good oxygenation.

D	Hypertonic saline solution

This is inappropriate. There is only mild hyponatraemia, which does not need to be correct urgently, and standard crystalloid fluids could be used for resuscitation. Hypertonic saline can be used in patients with chronic hyponatraemia with symptoms and sodium < 120 mmol/l.

E	Potassium supplements

Whilst IV fluids should be given very urgently, it is of greater importance to ensure that the patient has good oxygenation.

D	Hypertonic saline solution

This is inappropriate. There is only mild hyponatraemia, which does not need to be correct urgently, and standard crystalloid fluids could be used for resuscitation. Hypertonic saline can be used in patients with chronic hyponatraemia with symptoms and sodium < 120 mmol/l.

E	Potassium supplements

Potassium supplements should be given either as part of fluid management or with oral supplementation, but are of no immediate urgency for this patient.

7507

Rate this question:

Next Question

A 42-year-old man, who is known to be HIV positive, presents with a cough productive of rusty-coloured sputum. He has been feeling unwell for around a week or so. On examination he is pyrexial (38.2°C) with a BP of 135/70 mmHg. His pulse is 95/min and regular. Auscultation of the chest reveals an area of bronchial breathing over the right lower lung field.

Investigations:

Hb	12.4 g/dl
WCC	13.1 x10^9/l (Neutrophilia)
PLT	195 x10^9/l
Na^+	139 mmol/l
K^+	4.9 mmol/l
Cr	100 µmol/l
CXR	R. lower lobe consolidation

Which of the following types of pneumonia is the most likely diagnosis?

WCC	13.1 x10⁹/l (Neutrophilia)
PLT	195 x10^9/l
Na^+	139 mmol/l
K^+	4.9 mmol/l
Cr	100 µmol/l
CXR	R. lower lobe consolidation

Which of the following types of pneumonia is the most likely diagnosis?

A	*Pneumocystis*
B	*Staphylococcus aureus*
C	*Mycoplasma*
D	*Streptococcus pneumoniae*
E	*Klebsiella*

be HIV positive, presents with a cough productive of rusty-coloured sputum. He has been feeling unwell for around a week or so. On examination he is pyrexial (38.2°C) with a BP of 135/70 mmHg. His pulse is 95/min and regular. Auscultation of the chest reveals an area of bronchial breathing over the right lower lung field.

Investigations:

Hb	12.4 g/dl
WCC	13.1 x10^9/l (Neutrophilia)
PLT	195 x10^9/l
Na^+	139 mmol/l
K^+	4.9 mmol/l
Cr	100 µmol/l
CXR	R. lower lobe consolidation

Which of the following types of pneumonia is the most likely diagnosis?

Your answer was incorrect

D *Streptococcus pneumoniae*

This man has community-acquired pneumonia which is most likely to be *S. pneumoniae*. The estimated attack rate is higher in HIV-infected patients (5.9/1000 vs 0.31/1000 in non-HIV infected patients). Resistance patterns are similar in HIV and non-HIV infected patients, and invasive disease is rare and tends to occur in patients with a low CD4 count. The pattern of lobar pneumonia and neutrophilia fits best with a *S. pneumoniae* episode rather than another cause for the respiratory tract infection.

A *Pneumocystis*

Pneumocystis pneumonia is associated with diffuse patchy consolidation, and the hallmark of the condition is desaturation on exercise (usually measured with a hand-held pulse oximeter).

B *Staphylococcus aureus*

B *Staphylococcus aureus*

Staphylococcus aureus pneumonia, even in the context of underlying HIV infection, normally follows an episode of influenza.

C *Mycoplasma*

Mycoplasma pneumonia often follows a slightly more subacute course than streptococcal pneumonia, with a dry cough, chest pain and wheeze, that can be present for a few days before patients engage with medical services.

E *Klebsiella*

Klebsiella pneumonia is associated with lobar infection with cavitation and is seen most commonly in patients with a history of alcoholism.

20635

Rate this question:

A 90-year-old man was referred to the clinic with a history of progressive shortness of breath and dry cough. Eighteen months ago, he was able to complete a full round of golf. He has now stopped playing as he is breathless after walking 200 m. He had been a heavy smoker all his life. He has no known asbestos exposure.

On examination, he is breathless at rest. He has a photosensitive rash on his face and neck. He is not clubbed. His pulse is irregularly irregular. Auscultation of his chest reveals fine inspiratory crackles bi-basally.

Investigations:

Hb	12.1 g/dl
WCC	9.2×10^9/l
Neutrophils	6.1×10^9/l
PLT	203×10^9/l
TSH	7.1 mU/l

Blood gases on 30% oxygen:

Blood gases on 30% oxygen:

pH	7.48
pCO_2	4.68 kPa
pO_2	8.8 kPa
Bicarbonate	25.4 mmol/l

His CXR is shown below:

Spirometry:

FEV_1	1.7 l (predicted 2.0 – 2.4 l)
FVC	2.0 l (predicted 3.2 – 3.8 l)



Spirometry:

FEV_1	1.7 l (predicted 2.0 – 2.4 l)
FVC	2.0 l (predicted 3.2 – 3.8 l)
KCO	74% predicted

What is the likely cause of the suspected diagnosis?

A	Rheumatoid arthritis
B	Amiodarone
C	Pesticides
D	Sarcoidosis
E	Smoking

B Amiodarone

This man has interstitial lung disease – gradual onset of shortness breath and dry cough. He is not clubbed (but this could well be a feature) and has fine inspiratory crackles. Lung function tests are restrictive and he has type I respiratory failure. The chest radiograph shows small lung fields and reticular nodular shadowing.

Next you have to look for a cause. He has a photosensitive rash on his face, atrial fibrillation and abnormal thyroid function, suggesting that he is on amiodarone. Interstitial lung disease is an important side effect of long-term amiodarone administration.

Other side effects of amiodarone include:

- Hyper- and hypothyroidism
- Peripheral sensory neuropathy
- Hepatitis
- Photosensitivity
- Ataxia

- Ataxia
- Corneal micro-deposits (reversible)
- Metallic taste
- Arrhythmias (torsade de pointes): a number of drugs cause pulmonary fibrosis – see below.

Diagnosis is made by a combination of clinical findings, lung function tests, CXR, BAL and high-resolution CT. It is confirmed with a VATS or an open lung biopsy in patients fit to undergo the procedure.

If there was no obvious cause for the interstitial lung disease and radiology and biopsy histology were consistent with usual interstitial pneumonia, then idiopathic pulmonary fibrosis would be the most likely diagnosis.

Drugs causing interstitial lung disease:

- Antibiotics – nitrofurantoin
- Cardiovascular – amiodarone, beta-blockers

beta-blockers

- Chemotherapeutic – bleomycin, busulfan, cyclophosphamide, carmustine, lomustine, methotrexate, melphalan, mitomycin C, nitrosureas, sulfasalazine, 5-fluorouracil (5FU)
- Drugs used to treat rheumatoid arthritis – sulfasalazine, penicillamine, cyclophosphamide, methotrexate, gold
- Drugs used to treat migraine – ergotamine, ergots, methysergide
- Others:
  bromocriptine
  radiation
  dothiepin
  pesticides
  high-flow oxygen.

Causes of lower interstitial lung disease:

Causes of lower interstitial lung disease:

- Drugs
- Connective tissue disease
- Asbestosis
- Idiopathic pulmonary fibrosis.

A	Rheumatoid arthritis

There is nothing in the history to suggest RA. Rheumatoid arthritis resulting in interstitial lung disease can cause shortness of breath, chronic dry cough, fatigue and weakness. There may be lung nodules.

C	Pesticides

It is more likely that the ILD has been caused by amiodarone, given the patient's sun-exposed rash.

D	Sarcoidosis

This is not sarcoidosis, the

D	Sarcoidosis

This is not sarcoidosis, the presentation of which would be very unusual at this age. When sarcoidosis affects the lungs there is a collection of inflammatory cells forming lumps known as granulomas. This may present with wheezing, cough, shortness of breath or chest pain. Lofgren syndrome is where there is fever, lymphadenopathy, arthritis and erythema nodosum.

E	Smoking

Amiodarone is more likely to cause ILD than smoking. Smoking is associated with desquamative interstitial pneumonia, but the history and age of the patient are against this.

70117

Rate this question:

Next Question

A 62-year-old man presents with progressively increasingly dyspnoea over several months and a dry cough. He also had some malaise and arthralgia, but no other systemic symptoms. He is an ex-smoker who stopped 5 years ago. Apart from a small myocardial infarction 2 years ago and controlled hypertension, he has no other significant past medical history. He is a retired carpenter who used to work in a pine warehouse. He has no family history of respiratory disease, although he thinks his mother had hepatitis.

On examination he was dyspnoeic at rest with a respiratory rate of 24/min. He was centrally cyanosed and had finger clubbing. His heart sounds were normal. He had bi-basal fine end-inspiratory crepitations on chest auscultation. His jugular venous pressure was raised and he had early pitting ankle oedema. His GP has previously tried oral steroids with no significant response.

Investigations:

Hb	17.0 g/dl
WCC	6.0×10^9/l
PLT	200×10^9/l
Na^+	136 mmol/l
K^+	4.0 mmol/l
Creatinine	110 μmol/l
ESR	40 mm/h
GGT	44 IU/l
ALT	36 IU/l
ALP	90 IU/l
Bilirubin	14 μmol/l
Urea	5.2 mmol/l
Anti-nuclear antibody	+
Rheumatoid factor	Weakly +

High-resolution computed tomography (CT) of the chest is shown below.

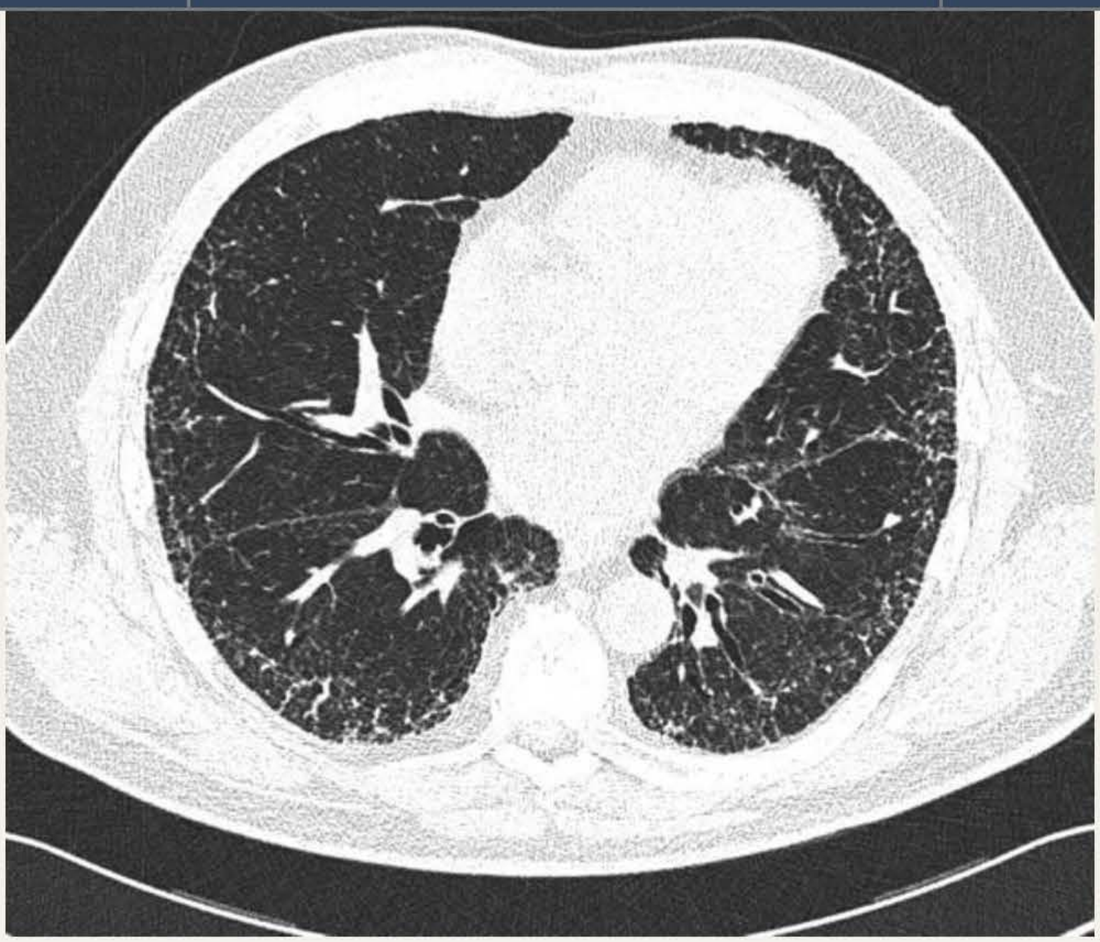

What is the most likely diagnosis?

A	Congestive cardiac failure
B	Idiopathic pulmonary fibrosis
C	Extrinsic allergic alveolitis
D	Rheumatoid lung fibrosis
E	Systemic lupus erythematosis

B Idiopathic pulmonary fibrosis

Idiopathic pulmonary fibrosis is a disorder of unknown aetiology causing diffuse pulmonary fibrosis. It has an incidence of 6–10/100,000 per year and is most common in middle-aged male smokers. There is some association with exposure to metal or wood dusts. Respiratory function tests show a restrictive defect with reduced transfer factor. Rheumatoid factor and antinuclear antibody are positive in 30–50% of cases. The diagnosis can usually be made by a combination of clinical features, respiratory function tests and high-resolution computed tomography, which shows honeycombing and reticular opacities. Histological confirmation by transbronchial biopsy is occasionally required. Treatment is with steroids, azathioprine or cyclophosphamide, although many patients are steroid unresponsive. Median survival is 5 years. Lung transplantation is occasionally indicated.

D Rheumatoid lung fibrosis

Rheumatoid arthritis has many extra-articular features and can affect the lungs. It can cause fibrosing alveolitis, obliterative bronchiolitis and pleural effusions. The absence of any rheumatological features, the age and sex of presentation, all makes any rheumatoid lung disease.

A Congestive cardiac failure

Heart failure is when cardiac output is inadequate for the requirements of the body. Heart failure can be precipitated by previous ischaemia or hypertension, of which this patient has both, but would also cause peripheral oedema, orthopnoea and paroxysmal nocturnal dyspnoea. The absence of these features makes it less likely, despite the elevated JVP. Also the CT demonstrates no evidence of pulmonary oedema or cardiomegaly, making it very unlikely.

C	Extrinsic allergic alveolitis

In extrinsic allergic alveolitis (EAA), sensitized individuals inhale allergens provoking a hypersensitivity reaction. In the acute phase alveoli become inflamed, but over time granulomata form and obliterative bronchiolitis occurs. Allergens are varied and can be associated with exposure to birds, or industrial exposure in farming or working with mushrooms, mail or sugar. Patients develop a dry cough with dyspnoea and fever, and over time develop weight loss and exertional dyspnoea. Treatment is with prednisolone. The absence of any history indicating a relevant exposure makes this diagnosis unlikely.

E	Systemic lupus erythematosis

Systemic lupus erythematosis can cause serositis in the lungs presenting as pleuritis. This causes pleuritic pain and dyspneoa, but would not cause a dry cough like this patient has. Also the absence of a rash and

A 62-year-old woman with a history of 30 pack-years of smoking presents with a cough and haemoptysis. She has been feeling increasingly lethargic over the past few months. On examination there is no lymphadenopathy and she looks thin. Auscultation of the chest reveals wheeze and occasional coarse crackles consistent with a COPD picture.

Investigations:

Hb	11.5 g/dl
WCC	8.1 $\times 10^9$/l
PLT	224 $\times 10^9$/l
Na^+	134 mmol/l
K^+	5.0 mmol/l
Creatinine	100 μmol/l
CXR	Right upper lobe tumour
FEV_1	2.0 l
Staging	3.5 cm lesion with ipsilateral hilar lymphadenopathy; PET

Staging CT	3.5 cm lesion with ipsilateral hilar lymphadenopathy; PET uptake consistent with ipsilateral lymph node involvement only

Which of the following represents the likely appropriate management?

A	Palliative chemotherapy
B	Palliative radiotherapy
C	Radical radiotherapy
D	Pneumonectomy
E	Radical chemoradiotherapy

21215

Submit

PLT	224 x10⁹/l
Na^+	134 mmol/l
K^+	5.0 mmol/l
Creatinine	100 µmol/l
CXR	Right upper lobe tumour
FEV_1	2.0 l
Staging CT	3.5 cm lesion with ipsilateral hilar lymphadenopathy; PET uptake consistent with ipsilateral lymph node involvement only

Which of the following represents the likely appropriate management?

Your answer was correct

A	Palliative chemotherapy
B	Palliative radiotherapy
C	Radical radiotherapy

D Pneumonectomy

The N1 staging seen here, with ipsilateral hilar lymphadenopathy, is not a contraindication to surgery, with the PET scanning reassuring with respect to the possibility of metastases. This woman's lung function also suggests that she would be a potential surgical candidate. Guidelines suggest that FEV_1 >2.0 l is the cut-off for pneumonectomy. N2 lymph nodes (ipsilateral mediastinal or sub-carinal involvement), particularly when they are bulky, do contraindicate surgery.

A Palliative chemotherapy

Palliative chemotherapy for non-small cell lung cancer is thought to at best extend life by around 2 months. Given this patient's young age, more aggressive intervention is warranted.

B Palliative radiotherapy

Palliative radiotherapy is considered for stage III and IV non-small cell lung cancer where surgical resection isn't an option.

C	Radical radiotherapy

Radical radiotherapy is considered for patients with potentially curable lung cancer who are not fit to undergo surgical resection, for example on grounds of poor lung function or severe cardiovascular disease.

E	Radical chemoradiotherapy

Here, with a curable lesion, surgery is the most appropriate intervention. With regards to immunotherapy in lung cancer, PD-1 and PDL-1 inhibitors, which help T cells to recognise cancer cells, are gaining ground in the treatment of the condition.

If she did have more advanced lymph node involvement and was not a surgical candidate, then combined chemo- and radiotherapy would be the

A 60-year-old man with known emphysema presented to the Emergency Department with sudden onset of severe left-sided pleuritic chest pain and shortness of breath. He is a smoker of 20/day. On examination he looks unwell. He is pale and sweaty. BP 140/85 mmHg, pulse 120/min, respiratory rate 30/min, SaO_2 88% on air. He has reduced expansion and reduced breath sounds on the left side. Heart sounds were normal and abdominal examination unremarkable.

ABGs on air:

pH	7.41
PO_2	7.5 kPa
PCO_2	6.5 kPa

His CXR is shown below;

He is given 28% oxygen and analgesia and his saturations improve.

The patient is reviewed 4 days later, following chest drain insertion at the time of diagnosis. There is a persistent air leak despite suction (pressure -20 cm H_2O).

What would you do next?

A	Insert another chest drain
B	Increase suction pressure to -30 cm H_2O
C	Refer to thoracic surgeons
D	Arrange a CT scan of the chest
E	Wait another 4 days

6:31
tps://mypastest.pastest.com 13

O_2	7.5 kPa
CO_2	6.5 kPa

s CXR is shown below;

is given 28% oxygen and ar
d his saturations improve.

e patient is reviewed 4 days

He is given 28% oxygen and analgesia and his saturations improve.

The patient is reviewed 4 days later, following chest drain insertion at the time of diagnosis. There is a persistent air leak despite suction (pressure -20 cm H_2O).

What would you do next?

Your answer was correct

A	Insert another chest drain
B	Increase suction pressure to -30 cm H_2O
C	Refer to thoracic surgeons
D	Arrange a CT scan of the chest

C Refer to thoracic surgeons

The answer is Refer to thoracic surgeons -

This man has a secondary pneumothorax as he has underlying lung disease. The management is different for primary (no underlying pulmonary disease) and secondary (underlying pulmonary disease) pneumothoraces. Current guidelines[1] suggest that an intercostal drain should be inserted if the patient is breathless, over 50 years old with a significant smoking history and there is a rim of air of > 2 cm from the chest wall on a standard size chest X-ray. This patient fits all the above criteria. Suction should not be applied immediately and it is recommended that it should not be routinely employed. It maybe considered after 48 hours whilst awaiting surgical review if the lung is not fully re-expanded or if there is a persistent air leak. Suction should be low-pressure (-10 to -20 cmH_2O), high-volume.

leak. Suction should be low pressure (-10 to -20 cmH_2O), high-volume. Because this patient has a persistent air leak at 4 days, despite suction, they should be referred to the thoracic surgeons. The exact timing of referral remains contentious but it is suggested that in cases of persistent air leak or failure of the lung to re-expand, an early (3-5 days) thoracic surgical opinion should be sought. For secondary pneumothoraces, an early thoracic surgical referral is recommended.

A	Insert another chest drain

Insert another chest drain is incorrect. The placement of a further intercostal drain is not recommended in a patient with a persistent air leak. A surgical review is warranted here.

B	Increase suction pressure to -30 cm H_2O

Increase suction pressure to -30 cm H_2O is incorrect. Suction pressure

Increase suction pressure to -30 cm H_2O is incorrect. Suction pressure should not be increased over -20cm H_2O.

D	Arrange a CT scan of the chest

Arrange a CT scan of the chest is incorrect. A CT scan may be helpful to look for bullae which may have triggered the pneumothorax and is usually required prior to surgical intervention. Apical bullectomies are often performed at the time of surgical pleurectomy to help minimise risk of recurrence. However the most appropriate next step in this case prior to CT is referring to the surgical team.

E	Wait another 4 days

Wait another 4 days is incorrect. Guidelines suggest involvement of thoracic surgeons should be earlier.

A 54 year old male with a history of alcohol excess presents to A+E with cough, dyspnoea and drenching night sweats. Following investigation, the diagnosis of TB is confirmed, and he is commenced on directly observed quadruple anti-TB combination treatment. Prior to beginning treatment, he attends the clinic for discussion of the therapy and potential side effects to be aware of.

Which of the following listed options is a possible side effect of anti-tuberculous therapy?

A	Hepatic obstruction
B	Haematuria
C	Vitamin A deficiency
D	Cortical visual loss
E	Peripheral neuropathy

E Peripheral neuropathy

Isoniazid can cause a peripheral neuropathy, particularly if used in patients with malnourishment, HIV or alcoholism, or other patients at risk of peripheral neuropathy.

Among of the main side effects to be aware of with anti-TB therapy are: peripheral neuropathy with isoniazid; orange-red staining of secretions with rifampicin; and optic neuritis with ethambutol. Rifampicin, isoniazid and pyrazinamide are all associated with GI upset and hepatitis.

A Hepatic obstruction

Anti-TB therapy is more commonly associated with drug-related hepatitis than obstruction.

B Haematuria

Rifampicin is known to cause orange-red discoloration of secretions such as

Rifampicin is known to cause orange-red discoloration of secretions such as urine, sweat and tears, but is not associated with haematuria.

C Vitamin A deficiency

Rifampicin and isoniazid can cause a relative vitamin D deficiency, probably already present in the patient but unmasked by the anti-TB therapy, but anti-TB therapy is not associated with vitamin A deficiency.

D Cortical visual loss

Rifampicin causes an orange discolouration of the urine. Ethambutol tends to cause colour blindness, restriction of visual fields and loss of visual acuity because of optic neuropathy, but not cortical blindness.

7172

Rate this question:

A 32-year-old African-Caribbean nurse is referred to the Chest Clinic with several months of progressive dyspnoea and a dry cough. She is now short of breath on minimal exertion. She was previously fit and well, has no relevant family history and is on no medications. She is a non-smoker.

On closer questioning, she also described fatigue and weight loss and a painful eye with blurred vision for the last few weeks.

On examination, she was comfortable at rest with mild pyrexia of 37.4 °C. Her heart sounds were normal and she had fine crackles at both mid-zones in her chest. Her abdomen was non-tender with no palpable masses. She had no focal neurological signs. She had an inflamed, watery right eye with reduced visual acuity.

On inspection of her skin, she had several raised erythematous lesions on her shins that were tender to palpation.

Investigations:

Investigations:

Hb	9.8 g/dl
WCC	7.6×10^9/l
Platelets	360×10^9/l
GGT	32 IU/l
MCV	92 fl
ESR	80 mm/hr
Na^+	138 mmol/l
K+	4.2 mmol/l
Ca^{2+}	2.78 mmol/l
Albumin	36 g/l
Bilirubin	14 µmol/l
Urea	4.2 mmol/l
Creatinine	82 µmol/l
ALT	38 IU/l
ALP	60 IU/l
	Mottling at both mid-zones with some line

CXR	Mottling at both mid-zones with some line shadows. Enlarged hilar bilaterally.

Pulmonary function tests:

Forced expiratory volume (FEV_1)	78% of predicted
Forced vital capacity (FVC)	70% of predicted
Transfer co-efficient (Kco)	78% of predicted

Which of the following is the most appropriate initial therapy for this patient?

A	Anti-tuberculous chemotherapy
B	Ciclosporin
C	Cyclophosphamide

volume (FEV_1)	predicted
Forced vital capacity (FVC)	70% of predicted
Transfer co-efficient (Kco)	78% of predicted

Which of the following is the most appropriate initial therapy for this patient?

A	Anti-tuberculous chemotherapy
B	Ciclosporin
C	Cyclophosphamide
D	Methotrexate
E	Prednisolone

E Prednisolone

Steroid are indicated in this case of sarcodosis as a first line treatment, as the patient has hypercalcaemia. Without hypercalcaemia, the management would simply be supportive. Local corticosteroids may be appropriate for her eye disease.

A Anti-tuberculous chemotherapy

This woman has pulmonary sarcoidosis with anterior uveitis and erythema nodosum, with evidence of bilateral hilar lymphadenopathy on her chest x-ray. Therefore, this option is incorrect as this is the treatment for TB.

B Ciclosporin

Ciclosporin could be considered further down the line as a steroid-sparing agent if the patient was unable to wean off prednisolone.

Ciclosporin could be considered further down the line as a steroid-sparing agent if the patient was unable to wean off prednisolone.

C Cyclophosphamide

Cyclophosphamide could be considered further down the line if the patient is particularly resistant to high-dose steroids.

D Methotrexate

Methotrexate could be considered at a later stage as a steroid-sparing agent if the patient fails to wean off prednisolone.

32406

Rate this question:

Next Question

Previous Question Tag Question

A 32-year-old homosexual man, who has been human immunodeficiency virus (HIV)-positive for 5 years and started highly active antiretroviral therapy several months ago, presented with several days of malaise, rigors, a cough productive of blood-streaked green sputum and pleuritic chest pain. His latest CD4 count was $320 \times 10^6/l$ several weeks ago.

On examination, he was unwell, with pyrexia of 39 °C, pulse of 110 bpm, blood pressure of 100/70 mmHg and oxygen saturation of 91% on air. On auscultation of his chest, he had bronchial breathing and coarse crepitations at the left lower zone.

His chest X-ray is shown below.

What is the most likely diagnosis?

A	*Pneumocystis jiroveci* pneumonia (PCP)
B	Streptococcal pneumonia
C	Staphylococcal pneumonia
D	*Mycobacterium avium intacellulare* infection
E	Lymphoid interstitial pneumonitis

A 32-year-old homosexual man, who has been human immunodeficiency virus (HIV)-positive for 5 years and started highly active antiretroviral therapy several months ago, presented with several days of malaise, rigors, a cough productive of blood-streaked green sputum and pleuritic chest pain. His latest CD4 count was 320 × 10^6/l several weeks ago.

On examination, he was unwell, with pyrexia of 39 °C, pulse of 110 bpm, blood pressure of 100/70 mmHg and oxygen saturation of 91% on air. On auscultation of his chest, he had bronchial breathing and coarse crepitations at the left lower zone.

His chest X-ray is shown below.

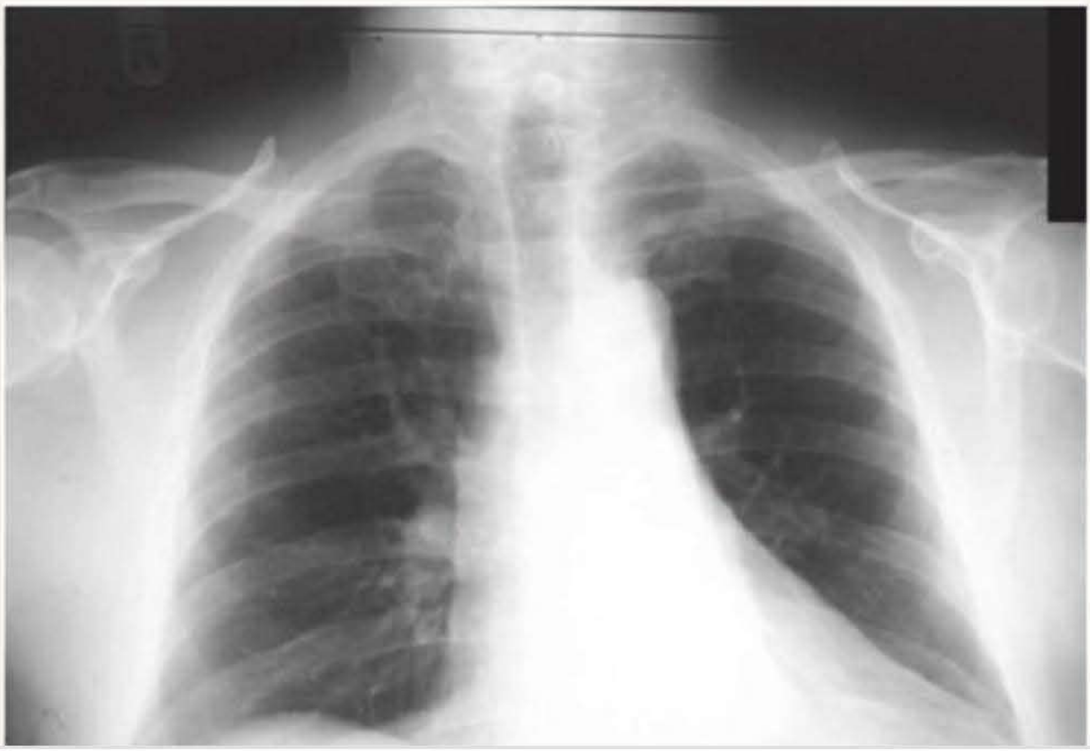

B Streptococcal pneumonia

This man has community-acquired pneumonia, 60–75% of which are caused by *Streptococcus pneumoniae*. Disseminated bacterial sepsis is common in HIV patients and may be seen in the early stages of infection, before a significant decline in the CD4 count. The chest X-ray shows the classical 'sail sign', which indicates left lower lobe collapse. In this case, this has been caused by community-acquired pneumonia.

A *Pneumocystis jiroveci* pneumonia (PCP)

P. jiroveci (previously *carinii*) pneumonia and *Mycobacterium avium intracellulare* infection are acquired immune deficiency syndrome (AIDS)-defining conditions and require a CD4 count of < 200 × 10^9/l to develop. PCP also usually develops as a dry cough, with desaturation on exercise and patchy interstitial shadowing on chest

Staphylococcal pneumonia tends to occur post-influenza infection or in intravenous drug users, and causes cavitation and multiple lung abscesses. There is no indication of previous influenza as a driver for infection here.

D	*Mycobacterium avium intacellulare* infection

Atypical mycobacterial infection, like PCP, occurs in patients with a significant fall in their CD4 count and is an AIDS-defining condition.

E	Lymphoid interstitial pneumonitis

Lymphoid interstitial pneumonitis is due to infiltration of the alveolar tissue by lymphocytes and plasma cells and presents with dry cough, dyspnoea and reticulo-nodular shadowing on chest X-ray. It is uncommon in adults but well described in paediatric HIV infection.

A 49-year-old male head teacher presents with a progressive shortness of breath on exertion for the last six months. He has also suffered from joint pains over the last few months, and an erythematous rash affecting sun-exposed areas during the summer months. He has previously been fit and has had no medical consultations for 25 years. He does not smoke. On examination his BP is 155/82 mmHg, pulse is 82/min and regular, BMI 22 and there are occasional crackles on auscultation of his chest. Full blood count and renal function are within normal limits, but autoantibodies are positive for anti-nuclear antibodies. Lung function test results are as follows:

	Actual	Predicted
FEV_1 (L/min)	1.4	2.0 - 2.8
VC (L)	1.6	2.4 - 3.4
FEV_1/VC	88%	
TLCO (ml/min/mmHg)	2.8	3.5 - 7.3

VC (L)	1.6	2.4 - 3.4
FEV_1/VC	88%	
TLCO (ml/min/mmHg)	2.8	3.5 - 7.3
KCO	0.9	1.2 - 1.8

Which of the following is the most likely cause of his abnormal lung function?

A	Asthma
B	Systemic lupus erythematosus (SLE)
C	Pulmonary haemorrhage
D	Idiopathic pulmonary fibrosis (IPF)
E	Inherited thrombophilia with multiple pulmonary emboli

6:49

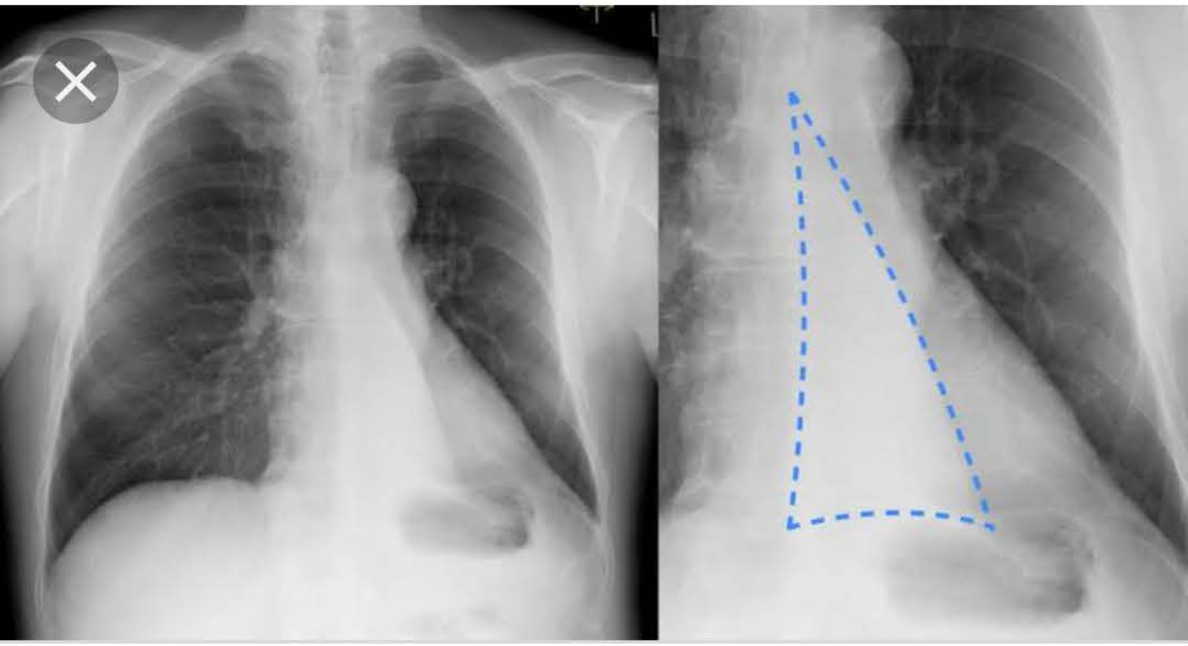

Diagnostic and Interventio...

Left lower lobe collapse - CXR - Radiology at St. Vincent's ...

Left lower lobe collapse – CXR

Images may be subject to copyright. Learn More

RELATED IMAGES

SEE MORE

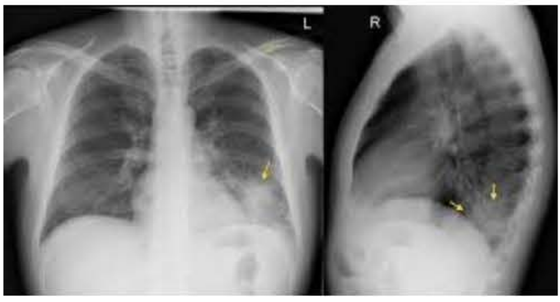

Left lower lobe pneumonia - l...
svuhradiology.ie

Thorax Radiologic Anatomy
meddean.luc.edu

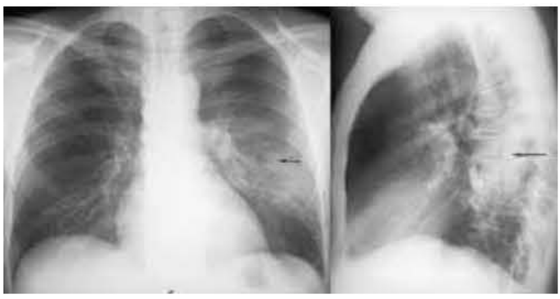

Pneumonia - Net Health Book
nethealthbook.com

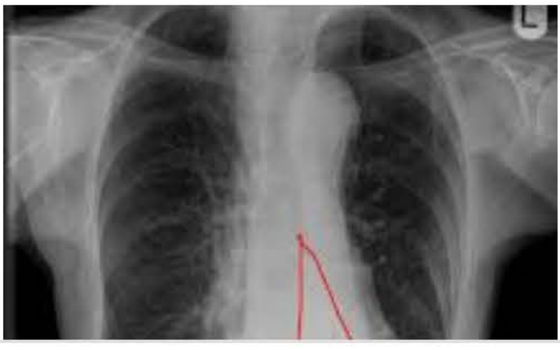

6:49
https://www.google.com/sea
13

Diagnostic and Interventio...

Left lower lobe collapse - Radiology at St. Vincent's Unive...

Left lower lobe collapse

Images may be subject to copyright. Learn More

RELATED IMAGES SEE MORE

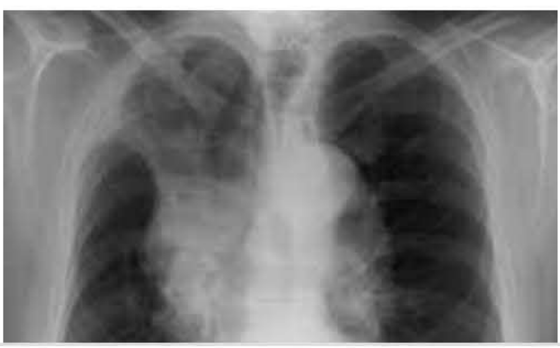

B Systemic lupus erythematosus (SLE)

The results show reduced lung volumes with normal FEV_1/VC ratio and impaired gas transfer. The diagnosis is interstitial lung disease, of which the most common in this age group are idiopathic fibrosing alveolitis, and fibrosing alveolitis secondary to connective tissue disease, sarcoidosis and pneumoconiosis. Spirometry shows reduced lung volumes with FEV_1/FVC ratio >75%. Gas transfer is also impaired (low KCO). The history of polyarthritis, photosensitive rash and positive anti-nuclear antibodies fits best with a diagnosis of SLE.

A Asthma

Asthma is associated with an obstructive lung defect rather than the restrictive picture seen here.

C Pulmonary haemorrhage

A more acute deterioration would be expected in patients with pulmonary haemorrhage, and elevation in low carbon monoxide transfer factor (TLCO) due to intra-alveolar haemoglobin would be expected.

D	Idiopathic pulmonary fibrosis (IPF)

IPF is inconsistent with the other features of connective tissue disease seen here.

E	Inherited thrombophilia with multiple pulmonary emboli

Multiple thromboemboli may result in reduced gas transfer, but they wouldn't result in the restrictive picture on pulmonary function testing seen here. In addition, given the features of SLE seen here, if pulmonary emboli were detected, anti-cardiolipin antibodies would be a more likely cause.

A 62-year-old retired office worker presents to the clinic with progressively increased shortness of breath on exercise and a chronic non-productive cough.

On examination, he looks tired and a little thin; his body mass index (BMI) is 21. His blood pressure (BP) is 142/88 mmHg, with pulse 78/min and regular. There are bi-basal end-expiratory crackles on auscultation. He is clubbed and there is bilateral peripheral ankle oedema.

Investigations:

Hb	14.8 g/dl
WCC	7.9×10^9/l
PLT	201×10^9/l
Na^+	141 mmol/l
K^+	4.0 mmol/l
Creatinine	141 μmol/l
Autoimmune profile	No specific abnormalities

Autoimmune profile	No specific abnormalities
PaO_2	7.9 kPa
$PaCO_2$	3.9 kPa
CXR	Interstitial shadowing at both lung bases
CTR	Suggests lung fibrosis

Which of the following is the most appropriate initial treatment?

A	N-acetylcysteine
B	High-dose prednisolone
C	Low-dose prednisolone
D	Cyclophosphamide
E	Long-term oxygen replacement therapy

Investigations:

Hb	14.8 g/dl
WCC	7.9×10^9/l
PLT	201×10^9/l
Na^+	141 mmol/l
K^+	4.0 mmol/l
Creatinine	141 μmol/l
Autoimmune profile	No specific abnormalities
PaO_2	7.9 kPa
$PaCO_2$	3.9 kPa
CXR	Interstitial shadowing at both lung bases
CTR	Suggests lung fibrosis

Which of the following is the most appropriate initial treatment?

Your answer was incorrect

E Long-term oxygen replacement therapy

This man has strong evidence to support a diagnosis of idiopathic pulmonary fibrosis. There is nothing, in either his occupational history or the blood results, to suggest a diagnosis of connective tissue disease or occupational lung disease.

Unfortunately, trials of corticosteroids, potential disease-modifying agents such as cyclophosphamide or methotrexate and novel therapies such as N-acetylcysteine have been uniformly disappointing, although these agents are often trialled as a small proportion of patients may respond.

He is significantly hypoxic, and thus home oxygen therapy may offer both symptom relief and affect prognosis with respect to secondary pulmonary hypertension and right heart failure. Pirfenidone and nintedanibare currently available agents which are proven to delay progression of the

B High-dose prednisolone

Prednisolone is specifically advised against in idiopathic pulmonary fibrosis. However, if extrinsic allergic alveolitis (EAA) was suspected then it could be trialled. EAA would be suggested be eosinophilia in blood tests and honeycombing on CT scanning. In the absence of these features and of any known environmental exposure, this would not be helpful.

A N-acetylcysteine

N-acetylcysteine can be used under limited circumstances for idiopathic pulmonary fibrosis, but NICE advises that its benefits are uncertain.

C Low-dose prednisolone

Prednisolone is specifically advised against in idiopathic pulmonary fibrosis.

environmental exposure, this would not be helpful.

A	N-acetylcysteine

N-acetylcysteine can be used under limited circumstances for idiopathic pulmonary fibrosis, but NICE advises that its benefits are uncertain.

C	Low-dose prednisolone

Prednisolone is specifically advised against in idiopathic pulmonary fibrosis.

D	Cyclophosphamide

Cyclophosphamide is specifically advised against in idiopathic pulmonary fibrosis. Had the diagnosis of a rheumatoid lung condition been suspected, then this could have been considered.

21246

Rate this question:

7:03
tps://mypastest.pastest.com 13

A 57-year-old male patient with a 40 pack-year smoking history attends his GP with incessant daytime sleepiness, making it difficult for him to even attend work. His initial examination reveals a height of 180 cm, weight of 120 kg and neck circumference of 44 cm. He is referred for sleep studies, which show hypnoea/apnoea episodes consistent with the diagnosis of moderate to severe obstructive sleep apnoea (OSA).

Which of the following is the most appropriate treatment option?

A	Overnight continuous positive airways pressure (CPAP)
B	Amitriptyline
C	Long-term oxygen therapy
D	Nocturnal lorazepam

making it difficult for him to even attend work. His initial examination reveals a height of 180 cm, weight of 120 kg and neck circumference of 44 cm. He is referred for sleep studies, which show hypnoea/apnoea episodes consistent with the diagnosis of moderate to severe obstructive sleep apnoea (OSA).

Which of the following is the most appropriate treatment option?

A	Overnight continuous positive airways pressure (CPAP)
B	Amitriptyline
C	Long-term oxygen therapy
D	Nocturnal lorazepam
E	Intra-oral device to prevent snoring

A Overnight continuous positive airways pressure (CPAP)

The treatment of choice has been shown in studies to be effective in reducing OSA symptoms, and is first line in moderate–severe disease requiring intervention, but does not prevent the cardiovascular mortality associated with OSA. Hypnotics worsen OSA, as do alcohol, smoking and obesity, and so patients should alter their lifestyle appropriately, with weight loss and alcohol and smoking cessation as first-line treatment. Long-term oxygen therapy has not been shown to have any long-term benefit in OSA patients. Modafinil has been shown in some small studies to have beneficial effects in use with CPAP, but not as an alternative. Intra-oral devices may be useful for mild OSA, but not in daytime sleepiness.

B Amitriptyline

This is an inappropriate treatment

B	Amitriptyline

This is an inappropriate treatment option, as hypnotics can worsen OSA.

C	Long-term oxygen therapy

This can be used as an adjunct to CPAP therapy or in cases where patients are unable to adhere to CPAP, but should not be offered first line in preference to CPAP.

D	Nocturnal lorazepam

This is an inappropriate treatment option, as hypnotics can worsen OSA.

E	Intra-oral device to prevent snoring

This may be useful for patients with mild OSA, but this patient has presented with daytime sleepiness and studies consistent with moderate–severe disease.

A 36-year-old devout Hindu woman who follows a vegan diet is referred to the Gastroenterology Outpatient Clinic by her general practitioner (GP). She complains of a 6-month history of lethargy and increasing breathlessness on exertion. Her blood pressure is 112/82, pulse is 70, BMI is 23. Neurological examination is normal.

Investigations:

Hb	8.6 g/dl
MCV	112 fl
WBC	3.8 × 10/l
Plt	110 × 10/l
ESR	8 mm/h
Biochemical profile	normal
Serum gastrin	42 pmol/l (< 55)

What is the most likely diagnosis?

A Pernicious anaemia

MCV	112 fl
WBC	3.8 × 10/l
Plt	110 × 10/l
ESR	8 mm/h
Biochemical profile	normal
Serum gastrin	42 pmol/l (< 55)

What is the most likely diagnosis?

A Pernicious anaemia

B Dietary deficiency of B12

C Aplastic anaemia

D Myxoedema

E Myelodysplasia

B Dietary deficiency of B12

The most likely cause of a macrocytic anaemia with a mild reduction in white cell count and platelets in this patient is dietary deficiency. A Hindu diet is usually vegetarian. Vitamin B_{12} is only found in foods of animal origin, e.g. meat, fish and eggs. First-line investigations should confirm vitamin B_{12} deficiency before undertaking further, more invasive investigations.

A Pernicious anaemia

Pernicious anaemia is associated with elevated serum gastrin and decreased intrinsic factor. As such, the normal serum gastrin effectively excludes the diagnosis.

C Aplastic anaemia

There are no precipitating risk factors for aplastic anaemia, and in a strict vegetarian, B_{12} deficiency is the likely cause of macrocytic anaemia seen

An 18-year-old man is admitted after celebrating his birthday with friends at a night club. He drank a large volume of vodka and beer and then proceeded to vomit copiously. After vomiting and retching for the third time, the vomit was seen to contain bright red blood.

Endoscopy the following morning was normal.

Which of the following is the next most appropriate management step?

A	Angiography of the coeliac axis
B	Repeat endoscopy in 1 month
C	Start intravenous proton pump inhibitor therapy
D	Start oral proton pump inhibitor therapy
E	Discharge the patient and reassure them

An 18-year-old man is admitted after celebrating his birthday with friends at a night club. He drank a large volume of vodka and beer and then proceeded to vomit copiously. After vomiting and retching for the third time, the vomit was seen to contain bright red blood.

Endoscopy the following morning was normal.

Which of the following is the next most appropriate management step?

A	Angiography of the coeliac axis
B	Repeat endoscopy in 1 month
C	Start intravenous proton pump inhibitor therapy
D	Start oral proton pump inhibitor therapy
E	Discharge the patient and reassure them

E Discharge the patient and reassure them

The history of retching followed by bright red blood in the vomitus and the normal findings on endoscopy suggest a diagnosis of Mallory–Weiss tear. The patient is haemodynamically stable and requires no specific intervention, except reassurance and advice on safe consumption of alcohol.

A Angiography of the coeliac axis

This would be a possible investigation for mesenteric ischaemia. Mesenteric ischaemia is small bowel injury due to hypoxia following a thrombosis or embolus. It is associated with AF and causes sudden and severe pain with PR bleeding. This does not fit, as the patient has vomited blood rather than passed it PR, and he lacks any relevant risk factors.

B Repeat endoscopy in 1 month

12:06

tps://mypastest.pastest.com 7

A 50-year-old woman is referred to the outpatient gastroenterology clinic with an 11-month history of abdominal cramps and diarrhoea. She opens her bowels three or four times a day and the stools are loose and foul-smelling. She denies any rectal bleeding but admitted to losing some weight, particularly over the last six months. Her appetite has remained unchanged.

In her past medical history, she underwent a total abdominal hysterectomy for carcinoma of the cervix together with external radiation 1 year earlier. Recent follow-up by her gynaecologist confirmed no recurrence of the malignancy. She was a non-smoker and drank alcohol occasionally.

On examination, she is emaciated and afebrile. On abdominal examination there is a healed midline scar and mild tenderness in the right iliac fossa with no other abnormalities. Rectal examination is normal.

Investigations:

Investigations:

Hb	10.0 g/dl
WCC	8.0×10^9/l
PLT	199×10^9/l
MCV	106 fl
ESR	22
Serum B_{12}	95 pmol/l (160-170)
Serum folate	20 µg/l (2-11)
Urea and electrolytes	Within normal limits
CXR	Normal
AXR	Normal

Which of the following is the most likely diagnosis?

A Crohn's disease

B Jejunal diverticulae

Serum folate	20 µg/l (2-11)
Urea and electrolytes	Within normal limits
CXR	Normal
AXR	Normal

Which of the following is the most likely diagnosis?

A Crohn's disease

B Jejunal diverticulae

C Small bowel lymphoma

D Pernicious anaemia

E Radiation enteritis

6356

Submit

E Radiation enteritis

This lady has a malabsorption syndrome with selective B_{12} malabsorption, due either to terminal ileal disease (Crohn's disease, terminal ileal resection, ileal tuberculosis (TB)), pernicious anaemia or excess B_{12} utilisation in the gut (secondary to diverticulae, fistulae, radiation enteritis and small bowel involvement in systemic sclerosis).

Radiation enteritis is secondary to the abdominal radiotherapy, which leads to fibrotic strictures and adhesions. These strictures predispose to bacterial overgrowth and this in turn leads to steatorrhoea due to deconjugation of bile salts. Vitamin B_{12} is selectively metabolised by the bacteria and the folate is left.

A Crohn's disease

Although this diagnosis is a possibility, her age is not typical for Crohn's

Although this diagnosis is a possibility, her age is not typical for Crohn's (there is a bimodal presentation with peaks between 15-30 years and between 60-80 years), and it would not explain the high folate seen in this case.

B Jejunal diverticulae

The age of the patient and the duration of symptoms are not explained by the diverticulae.

C Small bowel lymphoma

Small bowel lymphoma will not lead to a selective B_{12} deficiency.

D Pernicious anaemia

Symptoms of malabsorption are absent in pernicious anaemia.

6356

Rate this question:

A 50-year-old Asian male, presents with a 3-week history of jaundice and pruritus. He has a 1-year history of diarrhoea which had been diagnosed as irritable bowel syndrome by his general practitioner. There is no history of foreign travel and he denies any illicit drug use or recent blood transfusion. On examination he appears jaundiced and has scratch marks on his trunk, but the liver is not enlarged and there is no evidence of ascites.

A liver biopsy is performed and the histology shows typical onion skin-type periductal concentric fibrosis.

What is the most likely diagnosis?

A	Primary biliary cholangitis
B	Haemochromatosis
C	Autoimmune hepatitis
D	Primary sclerosing cholangitis (PSC)

of foreign travel and he denies any illicit drug use or recent blood transfusion. On examination he appears jaundiced and has scratch marks on his trunk, but the liver is not enlarged and there is no evidence of ascites.

A liver biopsy is performed and the histology shows typical onion skin-type periductal concentric fibrosis.

What is the most likely diagnosis?

A	Primary biliary cholangitis
B	Haemochromatosis
C	Autoimmune hepatitis
D	Primary sclerosing cholangitis (PSC)
E	Alcoholic liver disease

A liver biopsy is performed and the histology shows typical onion skin-type periductal concentric fibrosis.

What is the most likely diagnosis?

Your answer was correct

A	Primary biliary cholangitis
B	Haemochromatosis
C	Autoimmune hepatitis
D	Primary sclerosing cholangitis (PSC)
E	Alcoholic liver disease

Explanation

D	Primary sclerosing cholangitis (PSC)

D Primary sclerosing cholangitis (PSC)

Periductal concentric fibrosis ('onion skin') is a classic histopathologic finding of PSC on liver biopsy. The long history of diarrhoea should make you consider a diagnosis of inflammatory bowel disease (IBD), a condition strongly associated with PSC. In fact approximately 60-80% of patients with PSC have concomitant IBD.

A Primary biliary cholangitis

This typically shows a dense lymphocytic infiltrate in the portal tracts with granulomatous destruction and loss of medium-sized interlobular bile ducts, focal and variable within the liver.

B Haemochromatosis

When a liver biopsy is performed in this setting, Perls' Prussian blue stain would be performed to evaluate the

A 35-year-old man presents to the clinic complaining of diarrhoea, passing up to eight stools per day.

On further questioning, he admits that they are very smelly and difficult to flush away and that he has suffered loss of appetite and feelings of abdominal bloating for some months.

On examination, there is evidence of ankle oedema.

Testing reveals:

Potassium	3.6 mmol/l
Sodium	140 mmol/l
Albumin	26 g/l
Prothrombin time	20.3 s
Faecal elastase-1	500 mcg/g (NR = > 200)

Which of the following would be the initial investigation of choice in this man?

Sodium	140 mmol/l
Albumin	26 g/l
Prothrombin time	20.3 s
Faecal elastase-1	500 mcg/g (NR = > 200)

Which of the following would be the initial investigation of choice in this man?

A	Colonoscopy
B	Barium follow through
C	Abdominal CT
D	Upper gastrointestinal endoscopy with small bowel biopsy
E	Anti-TTG antibodies

E Anti-TTG antibodies

There is strong evidence in the history and blood results to suggest a syndrome of small bowel malabsorption. Before proceeding to upper GI endoscopy it's sensible to include assay of anti-tissue transglutamase antibody to rule out the possibility of coeliac disease. If anti-TTG antibodies are negative, then proceeding to upper GI endoscopy with small bowel biopsy would be the next logical step. Other causes of small bowel malabsorption in this patient could include infective cause such as Whipple's disease or tropical sprue.

A Colonoscopy

The symptoms suggest a small bowel malabsorption syndrome, as such a colonoscopy is much less likely to be useful here.

B Barium follow through

A 26-year-old woman presents with a 3-day history of progressively worsening abdominal distension, severe epigastric pain, nausea and vomiting. She was previously fit and well with no significant past medical history and the only medication she took was the oral contraceptive pill. There was no relevant family history. She smoked 10 cigarettes per day and drank approximately 12 units of alcohol per week.

On examination, she was unwell, drowsy and deeply jaundiced. She was apyrexial. Her heart sounds were normal, her chest was clear to auscultation and she had peripheral oedema. Her abdomen was distended with shifting dullness and tender hepatomegaly. There were no focal neurological signs.

Investigations:

Hb	13.0 g/dl
WCC	13.0×10^9/l
PLT	200×10^9/l

12:19
tps://mypastest.pastest.com

Hb	13.0 g/dl
WCC	13.0×10^9/l
PLT	200×10^9/l
Na^+	132 mmol/l
K^+	4.8 mmol/l
Creatinine	120 μmol/l
MCV	82 fl
Urea	7.2 mmol/l
Bilirubin	120 μmol/l
ALP	410 IU/l
AST	900 IU/l
GGT	850 IU/l
Albumin	24 g/l
PT	30 s

Ascitic fluid analysis:

Ascitic fluid analysis:

Protein	35 g/l
Neutrophils	80 cells/mm^3
Gram stain	No organisms seen
Amylase	100 IU/l

Which investigation should be performed next?

A	Serum alpha-fetoprotein
B	Colour flow Doppler ultrasound of the hepatic vasculature
C	Liver biopsy
D	Anti-mitochondrial antibodies
E	Serum caeruloplasmin

B Colour flow Doppler ultrasound of the hepatic vasculature

The diagnosis is Budd–Chiari syndrome. Doppler ultrasound will show obliteration of the hepatic veins and abnormalities of the direction of blood flow in the remainder of the hepatic vasculature. Budd-Chiari syndrome is defined as the obstruction of venous outflow from the liver caused by hepatic vein occlusion. The most common cause is thrombosis, usually in association with a hypercoagulable state, in conditions such as primary polycythaemia, thombophilias and leukaemia. There is also an association with the oral contraceptive pill. Other causes include malignancy (especially hepatocellular, renal and adrenal), radiotherapy, trauma and congenital venous webs. The cause is unknown in one-third of cases. It can present either acutely or chronically. In the acute from, there is abdominal pain, nausea and vomiting, ascites, tender hepatomegaly and

chronically. In the acute from, there is abdominal pain, nausea and vomiting, ascites, tender hepatomegaly and sometimes fulminant hepatic failure. The chronic form presents more insidiously, with signs of cirrhosis and portal hypertension. Ascitic fluid analysis will show a high protein content. An enlarged caudate lobe may be seen on ultrasound/computed tomography (CT)/magnetic resonance imaging (MRI) scan of the liver. Liver biopsy usually shows centrilobular congestion with fibrosis. Management includes treating the underlying cause, portocaval shunts and TIPSS (transjugular intrahepatic portosystemic stent shunt). Treatment with streptokinase and subsequent anticoagulation may be attempted if the thrombus is known to be of recent onset. Liver transplantation is the only option in the acute presentation, which has a very poor prognosis, with two-thirds of patients dead within 1 year.

A	Serum alpha-fetoprotein

A 21-year-old man is referred to the Neurology Clinic for investigation of a persistent tremor in his right hand. It had become more pronounced over the last few months and is now causing difficulties with tasks such as writing and fastening buttons. He also noticed that recently he was having difficulty in articulating his words properly.

On closer questioning, he admitted to profound fatigue and mild abdominal discomfort. There was no significant past medical history and he was on no regular medications. He was a non-smoker, drank 16 units of alcohol per week and denied illicit drug use. There was no relevant family history.

On examination, he had palmar erythema and multiple spider naevi on his chest. Cardiorespiratory examination was unremarkable. He had mild distension of his abdomen with palpable hepatosplenomegaly. On neurological examination he had an obvious resting tremor of his right hand with some cogwheel rigidity, and was mildly dysarthric with slow

hand with some cogwheel rigidity, and was mildly dysarthric with slow, monotonous speech. There were no other focal neurological signs.

Investigations:

Hb	15 g/dl
WCC	9.0×10^9/l
PLT	200×10^9/l
Na^+	142 mmol/l
K^+	4.2 mmol/l
Creatinine	130 μmol/l
MCV	98 fl
Urea	4.8 mmol/l
Ca^{2+}	2.30 mmol/l
Bilirubin	26 μmol/l
ALP	280 IU/l
GGT	120 IU/l
AST	320 IU/l
Glucose (random)	7.2 mmol/l

GGT	120 IU/l
AST	320 IU/l
Glucose (random)	7.2 mmol/l
Albumin	32 g/l
PT	18 s
INR	1.2

What is the most straightforward hospital test to support the diagnosis?

A	Slit lamp examination of the eyes
B	Serum caeruloplasmin levels
C	Serum ferritin levels
D	Magnetic resonance imaging (MRI) brain scan
E	Transferrin saturation measurement

A Slit lamp examination of the eyes

The combination of parkinsonism and chronic liver disease in a young person is highly suggestive of Wilson's disease, also known as hepatolenticular degeneration. This is a rare, autosomal recessive disorder of copper metabolism. There is failure of copper excretion in bile, resulting in its accumulation in the body and deposition in certain areas, particularly the brain, basal ganglia, eyes and liver. It usually presents between the ages of 5 and 30 years. In children it tends to present with hepatic disease, whereas in adults neurological symptoms predominate. These include parkinsonism, tremor, choreoathetosis, dysarthria, fits and dementia. Kayser–Fleischer rings on the cornea are the most specific sign of Wilson's disease, although they may be absent in up to 50% of cases. These are due to copper deposition in Descemet's membrane and appear as a green–brown discoloration at the corneo-scleral

junction - only usually visible on slit lamp examination.

B	Serum caeruloplasmin levels

Serum caeruloplasmin is usually low in Wilson's disease, but is sometimes normal if there is ongoing hepatitis and can also be reduced by advanced liver failure from any cause, so it is a non-specific test.

C	Serum ferritin levels

Serum ferritin is an acute-phase protein and is elevated in a range of causes of liver disease.

D	Magnetic resonance imaging (MRI) brain scan

Although MRI brain may show some evidence of degeneration, it wouldn't reveal the underlying cause.

E	Transferrin saturation

A 62-year-old Pakistani man with rheumatoid arthritis presents with a 2-month history of diarrhoea, upper abdominal pain and weight loss. He reports two episodes of dark red blood per rectum. He has a 7-year history of rheumatoid arthritis, which was refractory to high doses of non-steroidal anti-inflammatory drugs.

Over the last 2 years, his symptoms of joint pain have progressed and he has been switched to methotrexate. He also has a past history of anal cancer and received chemoradiation in Pakistan. His last hospital admission was for pneumonia. He is a non-smoker and consumes fewer than two units of alcohol per week.

On examination, he looks unwell with a temperature of 37.8 °C. Examination of the oral cavity reveals buccal ulcers. Cardiovascular and respiratory examinations are unremarkable. The abdomen is soft and non-tender with normal bowel sounds. A colonoscopy is performed. Histological analysis of rectal biopsy shows round intranuclear

examinations are unremarkable. The abdomen is soft and non-tender with normal bowel sounds. A colonoscopy is performed. Histological analysis of rectal biopsy shows round intranuclear inclusion bodies within some of the epithelial cells.

What is the most likely diagnosis?

A	Metastatic colonic malignancy
B	Cytomegalovirus-associated colitis
C	Pseudomembranous colitis
D	Lymphocytic colitis
E	*Cryptosporidium* diarrhoea

8489

Submit

been switched to methotrexate. He also has a past history of anal cancer and received chemoradiation in Pakistan. His last hospital admission was for pneumonia. He is a non-smoker and consumes fewer than two units of alcohol per week.

On examination, he looks unwell with a temperature of 37.8 °C. Examination of the oral cavity reveals buccal ulcers. Cardiovascular and respiratory examinations are unremarkable. The abdomen is soft and non-tender with normal bowel sounds. A colonoscopy is performed. Histological analysis of rectal biopsy shows round intranuclear inclusion bodies within some of the epithelial cells.

What is the most likely diagnosis?

Your answer was incorrect

A	Metastatic colonic malignancy
B	Cytomegalovirus-associated colitis

B Cytomegalovirus-associated colitis

Gastrointestinal cytomegalovirus (CMV) infection commonly presents with colitis. There is a well-established link between CMV infection and inflammatory bowel disease. Histologically, the demonstration of round intranuclear or intracytoplasmic inclusion bodies within epithelial cells of the intestinal mucosa is pathognomonic. Generally the case reports in immunocompetent patients with gastrointestinal CMV infection suggest a good clinical outcome; infection is often self-limiting and thus requires no treatment. However, it is more commonly associated with immunosuppression and in this case the patient is on methotrexate therapy, which makes him prone towards opportunistic infection. The recommended treatment for symptomatic CMV in the immunocompromised is intravenous ganciclovir, followed by oral maintenance therapy.

Like collagenous colitis, lymphocytic colitis is a recently recognised cause of chronic diarrhoea and it is diagnosed on the histological appearance of an increased number of intra-epithelial lymphocytes with epithelial surface damage. There is only partial success in treatment with sulphasalazine or prednisolone.

A	Metastatic colonic malignancy

Whilst this patient has a history of anal cancer, there is little evidence to suggest progression to metastatic cancer. This may have been a greater consideration of further evidence of generalised deterioration such as weight loss or fatigue, or if focal signs such as evidence of lymph node development, liver decompensation or features suggestive of an intracranial space-occupying lesion. Also, the histology is inconsistent.

C	Pseudomembranous colitis

space-occupying lesion. Also, the histology is inconsistent.

C	Pseudomembranous colitis

Pseudomembranous colitis is a complication of *C. difficile* infection. The infection forms pseudomembranes on histology. It is associated with acute diarrhoea and abdominal pain following recent antibiotic use. The absence of antibiotics makes this less likely.

E	*Cryptosporidium* diarrhoea

Cryptosporidium is a protozoan which can cause chronic diarrhoea, but this is primarily associated with HIV infection.

8489

Rate this question:

At a routine company medical, it transpires that a solderer, who is otherwise fit and well and has no significant past medical history, has an alcohol intake of 4 pints of beer a day and has been doing so for about 2 years. He is not on any medications and is a non-smoker. His BMI is 31.

The conscientious doctor decides to do some routine laboratory tests and some of the results are shown below:

Hb	12.5 g/dl
WCC	7×10^9/l
Plt	220×10^9/l
MCV	105 fl
GGT	40 U/l
AST	155 U/l
ALT	130 U/l
ALP	80 U/l

Based on these results, what is the most likely diagnosis in this patient?

Plt	220 × 10^9/l
MCV	105 fl
GGT	40 U/l
AST	155 U/l
ALT	130 U/l
ALP	80 U/l

Based on these results, what is the most likely diagnosis in this patient?

A	Hepatic steatosis
B	Isocyanate exposure
C	Cirrhosis
D	Previous hepatitis A infection
E	Gilbert syndrome

A 65-year-old man presents with unexplained iron deficiency anaemia in association with 3 kg weight loss. There is no history of change in bowel habit. He has a history of hypertension for which he takes ramipril, but is on no regular medication apart from this.

On examination, his BP is 142/82 mmHg. His BMI is 19, abdominal examination and PR is unremarkable.

Investigations:

Hb	9.9 g/dl
MCV	78 fl
WCC	5.4×10^9/l
PLT	180×10^9/l
ESR	49 mm/h
Na^+	140 mmol/l
K^+	4.4 mmol/l
Creatinine	100 μmol/l
Flexible sigmoidoscopy	mild diverticular disease

ESR	49 mm/h
Na^+	140 mmol/l
K^+	4.4 mmol/l
Creatinine	100 µmol/l
Flexible sigmoidoscopy	mild diverticular disease
Upper GI endoscopy	unremarkable

Which of the following is the most likely cause of his blood loss?

A Meckel's diverticulum

B Diverticulosis

C Angiodysplasia

D Right sided colonic carcinoma

E Crohn's disease

ESR	49 mm/h
Na^+	140 mmol/l
K^+	4.4 mmol/l
Creatinine	100 µmol/l
Flexible sigmoidoscopy	mild diverticular disease
Upper GI endoscopy	unremarkable

Which of the following is the most likely cause of his blood loss?

A Meckel's diverticulum

B Diverticulosis

C Angiodysplasia

D Right sided colonic carcinoma

E Crohn's disease

D Right sided colonic carcinoma

The BSG guidelines on iron deficiency anaemia (IDA) recommend that all males, in the absence of a history of overt blood loss and negative coeliac serology should undergo upper GI endoscopy and colonoscopy (if upper GI endoscopy is negative). If colonoscopy is not tolerated or appropriate then CT colonography (or rarely flexible sigmoidoscopy and barium enema) are considered sufficient. This reflects the fact that right sided colorectal cancers are common and flexible sigmoidoscopy alone is not sufficient to rule out a colonic malignancy.

For more information see: BSG guidelines on the management of iron deficiency anaemia. 2005 and NICE guideline CG131 – colorectal cancer: diagnosis and management. 2011 (updated 2014).

B Diverticulosis

Only mild diverticular disease was seen on endoscopy, this is unlikely to account for the severity of anaemia seen here or the significant weight loss.

A	Meckel's diverticulum

Meckel's diverticulum is an embryonic remnant present in 2% of the population. It resides in the ileum and can cause complications such as intussusception, infection and most commonly bleeding. However, significant weight loss is rare and bleeding tends to be more obvious.

C	Angiodysplasia

Angiodysplasia are a common cause of bleeding in the GI tract, particularly in patients over 60 and are known to be associated with aortic stenosis (Heyde's syndrome). They account for 30-40% occult GI bleeding and most frequently occur in the caecum and right colon. However, they do not cause weight loss.

Angiodysplasia are a common cause of bleeding in the GI tract, particularly in patients over 60 and are known to be associated with aortic stenosis (Heyde's syndrome). They account for 30-40% occult GI bleeding and most frequently occur in the caecum and right colon. However, they do not cause weight loss.

For more information see: Regula J, Wronska E, Pachlewski J. Vascular lesions of the gastrointestinal tract. *Best Pract Res Clin Gastroenterol*. 2008. 22(2):313-28.

E	Crohn's disease

One would expect the patient to present with a change in bowel habit, PR bleeding or post prandial abdominal pain (the latter indicating small bowel disease) to suggest Crohn's disease, making this less likely.

21504

Rate this question:

A 26-year-old man is referred for investigation of profuse, watery diarrhoea that had been going on for the past 6 weeks. He had lost one stone in weight over this time, even though his appetite remained good. He had not seen any blood or mucus in the stool and had no abdominal pain, distension or vomiting. Apart from lethargy, he had no other symptoms.

He had no significant past medical history and took no regular medication. He did not smoke, and drank 10 units of alcohol per week. There was no relevant family history.

He had recently spent a year in Australia, travelling out and back through South East Asia, but had returned home over 6 months ago. His general practitioner had tried him on several anti-diarrhoeal agents that had not worked, and multiple stool cultures had come back negative.

On examination, he was thin, but not wasted. There was no lymphadenopathy, jaundice or clubbing. His abdomen was soft and

wasted. There was no lymphadenopathy, jaundice or clubbing. His abdomen was soft and non-tender with no masses, and normal bowel sounds. Digital rectal examination was normal.

Investigations:

Hb	10.0 g/dl
WCC	3.4×10^9/l
PLT	260×10^9/l
Na^+	137 mmol/l
K^+	4.3 mmol/l
Creatinine	100 μmol/l
MCV	102 fl
Urea	5.2 mmol/l
CRP	8.0 mg/l
Ca^{2+}	1.9 mmol/l
Bilirubin	14 μmol/l
ALP	60 IU/l
GGT	48 IU/l

CRP	8.0 mg/l
Ca^{2+}	1.9 mmol/l
Bilirubin	14 µmol/l
ALP	60 IU/l
GGT	48 IU/l
AST	22 IU/l
Albumin	30 g/l
Serum anti-endomysial antibodies	-
Colonoscopy	No abnormality seen, good views to terminal ileum
Small bowel barium follow-through	Normal
Abdominal ultrasound scan	Normal

What would be the next most useful

follow-through	Normal
Abdominal ultrasound scan	Normal

What would be the next most useful investigation to establish the cause of the diarrhoea?

A	Serum gastrin level
B	HIV test
C	Hydrogen breath test
D	Radio-isotope-labelled white cell scan
E	24 h urinary 5-hydroxyindoleacetic acid (5-HIAA)

B HIV test

This patient has diarrhoea of small bowel origin, with evidence of malabsorption (macrocytic anaemia, low calcium and albumin). Inflammatory bowel disease and coeliac disease have been excluded by the investigations performed so far. An HIV test should be performed after appropriate consent and counselling. Diarrhoea is a common problem in HIV infection and has many causes, mainly infective. Pathogens include *Cryptosporidium parvum*, *Giardia lamblia*, *Entamoeba histolytica*, *Mycobacterium avium intracellulare*, *Isospora bella* and cytomegalovirus (CMV), as well as those that can cause diarrhoea in immunocompetent patients. Intestinal lymphomas can also cause similar symptoms. As this patient has had multiple negative stool cultures, the diarrhoea could be due to HIV enteropathy which is caused by partial villous atrophy.

A	Serum gastrin level

Serum gastrin level is most useful in evaluating potential Zollinger-Ellison syndrome, which results in multiple gastric ulcers.

C	Hydrogen breath test

Hydrogen breath testing is useful in the evaluation of bacterial overgrowth syndrome, which leads to symptoms of both diarrhoea and abdominal bloating.

D	Radio-isotope-labelled white cell scan

Radio isotope-labelled white cell scans are most useful in evaluating abscesses related to inflammatory bowel disease.

E	24 h urinary 5-hydroxyindoleacetic acid (5-HIAA)

A 27-year-old Zimbabwean woman presents to the Emergency Department following two episodes of haematemesis. She gives a 4-week history of increasing heartburn and dysphagia for both solids and liquids. She has been treated by her general practitioner (GP) with anti-reflux medication, with only partial relief of her symptoms. She has lost 2 kg in weight over the last 6 weeks.

On examination, there is cervical lymphadenopathy and mild epigastric tenderness on palpation. Abdominal examination is otherwise unremarkable. She is admitted for investigation and undergoes a gastroscopy that reveals widespread shallow ulceration of the oesophagus with adherent white patches.

What is the most likely cause for this patient's dysphagia?

A	Barrett's oesophagus
B	Cytomegalovirus

1:25
tps://mypastest.pastest.com

examination is otherwise unremarkable. She is admitted for investigation and undergoes a gastroscopy that reveals widespread shallow ulceration of the oesophagus with adherent white patches.

What is the most likely cause for this patient's dysphagia?

A	Barrett's oesophagus
B	Cytomegalovirus
C	Candida oesophagitis
D	Gastro-oesophageal reflux
E	Oesophageal carcinoma

9510

Submit

1:27
tps://mypastest.pastest.com

examination is otherwise unremarkable. She is admitted for investigation and undergoes a gastroscopy that reveals widespread shallow ulceration of the oesophagus with adherent white patches.

What is the most likely cause for this patient's dysphagia?

Your answer was correct

A	Barrett's oesophagus
B	Cytomegalovirus
C	Candida oesophagitis
D	Gastro-oesophageal reflux
E	Oesophageal carcinoma

Explanation

WhatsApp • Just now
Mrcp2 (2 messages)
Ahmed Kambel C 🤔
REPLY MARK AS READ

This patient has developed candida oesophagitis as a complication of HIV infection. The appearance of the oesophagus at endoscopy is typical of candida infection. Approximately 90% of patients with HIV/AIDS will develop oral/oesophageal candidiasis.

A	Barrett's oesophagus

Barrett's is associated with prolonged, severe reflux disease. It is associated with increased risk of oesophageal malignancy.

B	Cytomegalovirus

Infection with cytomegalovirus classically causes giant ulcers, although the symptom picture is similar to that seen here.

D	Gastro-oesophageal reflux

C Candida oesophagitis

This patient has developed candida oesophagitis as a complication of HIV infection. The appearance of the oesophagus at endoscopy is typical of candida infection. Approximately 90% of patients with HIV/AIDS will develop oral/oesophageal candidiasis.

A Barrett's oesophagus

Barrett's is associated with prolonged, severe reflux disease. It is associated with increased risk of oesophageal malignancy.

B Cytomegalovirus

Infection with cytomegalovirus classically causes giant ulcers, although the symptom picture is similar to that seen here.

D Gastro-oesophageal reflux

ulceration/erythema, rather than the multiple adherent white patches seen here.

E	Oesophageal carcinoma

Squamous cell carcinoma (SCC) and adenocarcinoma account for >95% of oesophageal malignant tumours. Barium studies may suggest the presence of oesophageal cancer, but the diagnosis is established with endoscopic biopsy. Early oesophageal cancers appear endoscopically as superficial plaques, nodules or ulcerations. Advanced lesions appear as strictures, ulcerated masses, circumferential masses or large ulcerations. The adherent white patches are not typical of oesophageal carcinoma.

9510

Rate this question:

A 59-year-old woman, who is awaiting a surgical outpatient appointment for a history of right upper quadrant pain and nausea after fatty meals, presents to the Emergency Department with severe epigastric pain radiating to her back, nausea, vomiting and fever.

On examination, she looks unwell. She has a temperature of 38.2 °C, a blood pressure (BP) of 100/65 mmHg and a pulse of 105/min. On her abdominal examination, there is severe epigastric tenderness.

Investigations:

Hb	13.1 g/dl
WCC	12.4×10^9/l
PLT	301×10^9/l
Na^+	139 mmol/l
K^+	4.0 mmol/l
Creatinine	100 μmol/l
Albumin	28 g/l
Amylase	789 U/l

Albumin	28 g/l
Amylase	789 U/l
Ca^{2+}	2.08 mmol/l

Which of the following is the most important first step in her management?

A	Supportive care with oxygen, analgesia, intravenous (iv) fluids
B	Surgery for partial pancreatectomy
C	Endoscopic retrograde cholangiopancreatography (ERCP)
D	Magnetic resonance cholangiopancreatography (MRCP)
E	Abdominal ultrasound scan

to the Emergency Department with severe epigastric pain radiating to her back, nausea, vomiting and fever.

On examination, she looks unwell. She has a temperature of 38.2 °C, a blood pressure (BP) of 100/65 mmHg and a pulse of 105/min. On her abdominal examination, there is severe epigastric tenderness.

Investigations:

Hb	13.1 g/dl
WCC	12.4×10^9/l
PLT	301×10^9/l
Na^+	139 mmol/l
K^+	4.0 mmol/l
Creatinine	100 μmol/l
Albumin	28 g/l
Amylase	789 U/l
Ca^{2+}	2.08 mmol/l

Which of the following is the most

A	Supportive care with oxygen, analgesia, intravenous (iv) fluids

This patient clearly has acute pancreatitis, which may well have been precipitated by gallstone disease. At present, she has features of shock and is in pain, and so supportive care with oxygen, IV fluid replacement and analgesia is crucial.

A score of 3 or greater indicates severe acute pancreatitis. Depending on the severity of pancreatitis, patients may require management on an Intensive Care Unit (ICU) rather than on a general surgical ward.

B	Surgery for partial pancreatectomy

Surgical treatment for pancreatitis may be indicated at a later point if complications develop, but the mainstay of treatment in the acute phase would be supportive therapy.

B	Surgery for partial pancreatectomy

Surgical treatment for pancreatitis may be indicated at a later point if complications develop, but the mainstay of treatment in the acute phase would be supportive therapy.

C	Endoscopic retrograde cholangiopancreatography (ERCP)

ERCP may be a crucial step with sphincterotomy and stone extraction, but this would ordinarily only be considered when the patient is more stable and after appropriate abdominal imaging has been performed.

D	Magnetic resonance cholangiopancreatography (MRCP)

In this instance the diagnosis of acute pancreatitis is clear given the typical

stable and after appropriate abdominal imaging has been performed.

D	Magnetic resonance cholangiopancreatography (MRCP)

In this instance the diagnosis of acute pancreatitis is clear given the typical history and raised serum amylase result. The first step therefore is to initiate supportive treatments, not MRCP.

E	Abdominal ultrasound scan

Again the diagnosis of acute pancreatitis has already been made based on the history and examination findings, so the priority would be to initiate supportive treatments rather than to perform abdominal imaging.

20599

Rate this question:

Next Question

A young adult man is admitted to hospital after a seizure. He admits to drinking at least a bottle of vodka per day. He says he stopped drinking one day ago as he ran out of money.

He previously had seizures after stopping drinking alcohol. He says he would like to stop forever and is admitted for a detoxification regime and intravenous (iv) thiamine.

Which of the following results would you most expect to find in his serum immunology screen?

A	Markedly raised IgA
B	Low IgA
C	Markedly raised IgM
D	Markedly raised IgE
E	Low IgM

A Markedly raised IgA

Alcoholic hepatitis causes a markedly raised IgA, and it can also cause a mildly elevated IgG and IgM. Raised IgA can also be present in both chronic active hepatitis and IgA nephropathy.

AST is often more than twice the ALT in alcoholic liver disease. If the alanine aminotransferase (ALT) is >300 U/l, you may suspect an alternative cause for the deranged liver function results such as paracetamol overdose, an infective cause of the hepatitis, ischaemic hepatitis or autoimmune hepatitis. Hyperbilirubinaemia is often seen in alcoholic liver disease and can be up to 500 μmol/l. This usually reflects the severity of the disease. There will also usually be an elevated GGT and ALP.

C Markedly raised IgM

A raised IgM may be seen in primary biliary cirrhosis, Waldenström's

A raised IgM may be seen in primary biliary cirrhosis, Waldenström's macroglobulinaemia and as an acute response to infection.

B Low IgA

Deficiency of IgA is associated with autoimmune disorders, chronic diarrhoea and respiratory infections.

D Markedly raised IgE

A markedly raised IgE would raise suspicion of non-liver-related diseases such as atopic dermatitis, psoriasis, asthma, allergic bronchopulmonary aspergillosis (ABPA) and parasitic infection.

E Low IgM

Selective IgM deficiency is a rare congenital immunodeficiency, with approximately 300 cases described, it is associated with severe bacterial

A 38-year-old man is sent to the clinic for review. He is obese with a BMI of 33. His general practitioner (GP) has noticed that he has an elevated ALT of 102 U/l (5–35); a similar rise in AST is also seen. He admits to drinking 4 pints of beer at weekends, although he avoids alcohol during the week because of his job as a taxi driver.

His fasting blood glucose is measured at 6.0 mmol/l, and his HDL cholesterol is 0.7 mmol/l. Hepatic ultrasound reveals a hyperechogenic liver image. Liver biopsy reveals steatosis and evidence of inflammatory infiltrates.

Which of the following is the most likely diagnosis in this case?

A	Alcoholic steatohepatitis
B	Non-alcoholic steatohepatitis
C	Autoimmune hepatitis
D	Haemochromatosis

102 U/l (5–35); a similar rise in AST is also seen. He admits to drinking 4 pints of beer at weekends, although he avoids alcohol during the week because of his job as a taxi driver.

His fasting blood glucose is measured at 6.0 mmol/l, and his HDL cholesterol is 0.7 mmol/l. Hepatic ultrasound reveals a hyperechogenic liver image. Liver biopsy reveals steatosis and evidence of inflammatory infiltrates.

Which of the following is the most likely diagnosis in this case?

A	Alcoholic steatohepatitis
B	Non-alcoholic steatohepatitis
C	Autoimmune hepatitis
D	Haemochromatosis
E	Viral hepatitis

B Non-alcoholic steatohepatitis

NASH is characterised by the accumulation of liver fat and associated inflammation. Over time it is thought to progress in some patients to areas of fibrosis and eventually end-stage liver disease. It is strongly associated with insulin resistance and dysglycaemia. A rise in aminotransferases is seen, with similar rises in both ALT and AST being indicative of NASH, rather than alcoholic fatty liver disease. Aggressive weight loss is the mainstay of therapy, although pioglitazone and vitamin E are also used off-licence for treating the condition.

A Alcoholic steatohepatitis

Alcoholic steatohepatitis is unlikely given relatively modest alcohol consumption, and the fact there is not a significant elevation in the AST:ALT ratio.

A 68-year-old man complains of lethargy and progressive shortness of breath on exertion. He has a long history of intermittent heartburn and has occasionally passed some dark red blood mixed with his stools.

Other past medical history includes hypertension and diet-controlled type 2 diabetes mellitus. He has not lost any weight recently, is an ex-smoker and drinks only occasional alcohol.

Physical examination confirms hypertension, blood pressure 150/90 mmHg, but is otherwise unremarkable.

Investigations:

Haemoglobin (Hb)	84 g/l
Mean corpuscular volume (MCV)	70 fl
White cell count (WCC)	9.5×10^9/l
Neutrophils	5.4×10^9/l
Platelets	258×10^9/l

Renal and hepatic function are normal.

Gastroscopy and barium enema are normal.

Mesenteric angiography showed an abnormal vascular blush in the ascending colon.

What is the most likely cause of his anaemia?

A	Colonic carcinoma
B	Angiodysplasia
C	Colonic varices
D	Meckel's diverticulum
E	Ulcerative colitis

3G 1:43
tps://mypastest.pastest.com 7

Gastroscopy and barium enema are normal.

Mesenteric angiography showed an abnormal vascular blush in the ascending colon.

What is the most likely cause of his anaemia?

Your answer was correct

A	Colonic carcinoma
B	Angiodysplasia
C	Colonic varices
D	Meckel's diverticulum
E	Ulcerative colitis

Explanation

B Angiodysplasia

This patient has a microcytic anaemia and a history of gastrointestinal bleeding. The findings on mesenteric angiography, combined with a normal barium enema, suggest a diagnosis of angiodysplasia. Angiodysplasia may be found throughout the gastrointestinal tract, although it most commonly occurs in the caecum and ascending colon. It is a significant cause of chronic anaemia and can also cause acute haemorrhage. Treatment is either by heat coagulation at endoscopy or by embolisation of the bleeding vessel during angiography.

A Colonic carcinoma

Barium enema would not be normal in colonic carcinoma – we would expect a colonic mass in carcinoma. The mesenteric angiography would be normal.

C Colonic varices

C	Colonic varices

Colonic varices would produce distension of the veins in the colon and would not appear as an abnormal vascular blush on mesenteric angiography.

D	Meckel's diverticulum

Meckel's diverticulum is the most common congenital anomaly of the gastrointestinal tract. It results from incomplete obliteration of the vitelline duct leading to the formation of a true diverticulum of the small intestine. Meckel's diverticulum is a true diverticulum, containing all layers of the small bowel wall. It arises from the anti-mesenteric surface of the middle-to-distal ileum. The diverticulum represents a persistent remnant of the omphalo-mesenteric duct, which connects the midgut to the yolk sac in the foetus. Meckel's diverticulum is uncommon and often clinically silent, particularly in adults. Asymptomatic Meckel's diverticulum may be

A 28-year-old teacher presents to clinic with bloating, abdominal pain and weight loss. He tells you that he also has diarrhoea, which is very difficult to flush away and tends to float on the toilet pan.

On examination, his BP is 115/72 mmHg and he looks pale. His BMI is 21, and his abdomen is soft and non-tender.

Results of blood tests show an iron deficiency anaemia and an elevated ALP; his albumin is low at 30 g/l.

What would be the most useful blood test to perform next?

A	Helicobacter pylori serology
B	Serum iron levels
C	Tissue transglutaminase antibody
D	Haptoglobins and reticulocyte count

also has diarrhoea, which is very difficult to flush away and tends to float on the toilet pan.

On examination, his BP is 115/72 mmHg and he looks pale. His BMI is 21, and his abdomen is soft and non-tender.

Results of blood tests show an iron deficiency anaemia and an elevated ALP; his albumin is low at 30 g/l.

What would be the most useful blood test to perform next?

A	Helicobacter pylori serology
B	Serum iron levels
C	Tissue transglutaminase antibody
D	Haptoglobins and reticulocyte count
E	Serum gastrin

C Tissue transglutaminase antibody

The symptoms and the iron deficiency anaemia are suggestive of coeliac disease. Coeliac disease can be associated with deranged liver function tests. Serological tests for coeliac disease include IgA antibodies to tissue transglutaminase (TTG) (preferred and most widely available), anti-endomysial and gliadin antigen. negatives can occur in patients with selective IgA deficiency, and hence many clinicians will also check immunoglobulin levels in those patients at high risk of coeliac disease in whom initial serology is negative. The 'gold standard' remains a duodenal or jejunal biopsy.

A Helicobacter pylori serology

H. pylori serology is used in the investigation of dyspepsia and peptic ulcer disease. The clinical picture of steatorrhoea, weight loss and low

At a routine company medical, it transpires that a solderer, who is otherwise fit and well and has no significant past medical history, has an alcohol intake of 4 pints of beer a day and has been doing so for about 2 years. He is not on any medications and is a non-smoker. His BMI is 31.

The conscientious doctor decides to do some routine laboratory tests and some of the results are shown below:

Hb	12.5 g/dl
WCC	7×10^9/l
Plt	220×10^9/l
MCV	105 fl
GGT	40 U/l
AST	155 U/l
ALT	130 U/l
ALP	80 U/l

Based on these results, what is the most likely diagnosis in this patient?

Plt	$220 \times 10^9/l$
MCV	105 fl
GGT	40 U/l
AST	155 U/l
ALT	130 U/l
ALP	80 U/l

Based on these results, what is the most likely diagnosis in this patient?

A	Hepatic steatosis
B	Isocyanate exposure
C	Cirrhosis
D	Previous hepatitis A infection
E	Gilbert syndrome

alcohol intake of 4 pints of beer a day and has been doing so for about 2 years. He is not on any medications and is a non-smoker. His BMI is 31.

The conscientious doctor decides to do some routine laboratory tests and some of the results are shown below:

Hb	12.5 g/dl
WCC	7×10^9/l
Plt	220×10^9/l
MCV	105 fl
GGT	40 U/l
AST	155 U/l
ALT	130 U/l
ALP	80 U/l

Based on these results, what is the most likely diagnosis in this patient?

Your answer was correct

A Hepatic steatosis

A Hepatic steatosis

Fatty liver occurs after the ingestion of moderate to large amounts of alcohol or in association with obesity or other conditions of insulin resistance such as type 2 diabetes. Commonly, no abnormalities are noted on clinical examination but hepatomegaly may occur with severe fatty infiltration. Although this is a reversible condition, it may progress to cirrhosis if the level of alcohol intake continues and weight loss isn't achieved.

B Isocyanate exposure

Isocyanates are hepatotoxins which lead to cirrhosis; they are usually associated with exposure to plastics, rather than exposure to solder material.

C Cirrhosis

In cirrhosis other signs of chronic liver disease, including spider naevi, ascites

rather than exposure to solder material.

C	Cirrhosis

In cirrhosis other signs of chronic liver disease, including spider naevi, ascites and signs of portal hypertension, would be expected.

D	Previous hepatitis A infection

Chronic liver disease does not occur in association with hepatitis A infection.

E	Gilbert syndrome

Gilbert syndrome is associated with unconjugated hyperbilirubinaemia rather than the elevated transaminases seen here, and patients suffer episodes of jaundice during an intercurrent illness.

6812

Rate this question:

A 21-year-old student presents to Clinic with recurrent episodes of melaena requiring admission and blood transfusions.

He has been investigated by upper endoscopy and colonoscopy, both investigations proving negative. Between episodes of melaena he is asymptomatic.

Which of the following investigations would you organise from the Clinic?

A	Barium swallow
B	Mesenteric angiogram
C	Wireless capsule endoscopy
D	Barium enema
E	Octreotide scan

A 21-year-old student presents to Clinic with recurrent episodes of melaena requiring admission and blood transfusions.

He has been investigated by upper endoscopy and colonoscopy, both investigations proving negative. Between episodes of melaena he is asymptomatic.

Which of the following investigations would you organise from the Clinic?

Your answer was correct

A Barium swallow

B Mesenteric angiogram

C Wireless capsule endoscopy

D Barium enema

C Wireless capsule endoscopy

Meckel's diverticulum should always be considered in a young adult presenting with intermittent malaena, despite normal OGD and colonoscopic findings.

Wireless capsule endoscopy is increasingly used for the work-up of gastrointestinal bleeding of uncertain origin, and case reports have demonstrated its ability to identify Meckel's diverticulum. The use of capsule endoscopy in diagnosis will undoubtedly grow, but not all centres yet have easy access to this service and it is not offered as an option for the above case.

Alternatively, In the stable outpatient setting, a Meckel's scan can be useful in investigating the presence of gastrointestinal diverticula containing ectopic gastric mucosa.

A Barium swallow

The patient's blood loss is severe and occurs intermittently. A mesenteric angiogram is most effective during active blood loss (usually >1 ml/min) and, as such, is not an appropriate investigation for use in the stable outpatient setting.

D	Barium enema

A repeat colonoscopy may be indicated, as proximal colonic lesions may be missed for a variety of reasons. However, a barium enema does not have a role in the investigation of suspected small bowel bleeding in a patient with a normal colonoscopy.

E	Octreotide scan

The patient's symptoms of intermittent, significant, gastrointestinal bleeding are not the typical presentation of a neuroendocrine tumour, and therefore an octreotide scan is not warranted.

A 46-year-old man is seen in neurology outpatients after being referred with disinhibited behaviour of 2 months' duration. His family tells you that he passes urine in public and the police have brought him home on two occasions recently. He has been losing weight for the last year and was previously 110 kg, now weighing 92 kg. He has diarrhoea and his family tell you it smells bad and is difficult to flush. The patient complains of pain in his right knee, left ankle and lower back.

On examination, he looks pale and has angular cheilitis. He has a distended abdomen with some shifting dullness but no palpable organomegaly. His palmo-mental reflex is positive. The right knee and left ankle are both swollen with minimal tenderness and a good range of movement.

Investigations:

Sodium	134 mmol/l
Potassium	4.1 mmol/l
Urea	4.8 mmol/l

A 17-year-old girl is sent to you for assessment, as she is profoundly depressed. She has features of anhedonia and anorexia over the last 6 months. Before this, she had always been an excellent student and has many friends.

She has no known medical problems, but her mother has a history of schizophrenia. She does not smoke or drink, and both she and her parents deny that she has used drugs.

On examination, she is well-dressed but does not keep eye contact. She tells you that she is hearing second-person auditory hallucinations and has done so for 3 months. She has an expressionless face and when writing a sentence she has small, cramped handwriting. Her gait is slow and there is some increased tone in her right arm.

Investigations:

Albumin	36 g/l
sALT	201 U/l

is some increased tone in her right arm.

Investigations:

Albumin	36 g/l
sALT	201 U/l
ALP	121 U/l
Bilirubin	28 μmol/l

What is the most likely diagnosis?

A Abuse of clozapine

B Chronic abuse of LSD

C Ganser syndrome

D Othello syndrome

E Wilson's disease

but does not keep eye contact. She tells you that she is hearing second-person auditory hallucinations and has done so for 3 months. She has an expressionless face and when writing a sentence she has small, cramped handwriting. Her gait is slow and there is some increased tone in her right arm.

Investigations:

Albumin	36 g/l
sALT	201 U/l
ALP	121 U/l
Bilirubin	28 μmol/l

What is the most likely diagnosis?

Your answer was correct

A	Abuse of clozapine
B	Chronic abuse of LSD
C	Ganser syndrome

E Wilson's disease

Wilson's disease is an inherited disorder of hepatic copper disposition caused by mutations in the gene *ATP7B* on chromosome 13. The average prevalence is 30/million. It can present as either psychiatric (depression/neurotic behaviour), neurological (extrapyramidal signs) or with liver disease (asymptomatic hepatomegaly, elevated transaminase).

Biochemical findings include low serum ceruloplasmin and copper and elevated 24 h urinary excretion of copper. There is an increased copper concentration in the liver parenchyma. Kayser–Fleischer rings need to be looked for with a slit lamp and are present in 60% of cases. The mainstay of treatment is chelation therapy, with penicillamine. Second-line treatment involves trientine, and occasionally zinc. With effective and early treatment, most patients are well and live normally.

A Abuse of clozapine

The atypical antipsychotics carry a lower risk of extrapyramidal symptoms than typical antipsychotics. The more common signs and symptoms such as lethargy and sedation (histamine blockade), miosis, tachycardia, orthostatic hypotension (alpha-adrenergic blockade) and confusion (muscarinic blockade). Clozapine abuse is not the best explanation for this patient's presentation with extrapyramidal signs and deranged liver function tests.

B Chronic abuse of LSD

Lysergic acid use can cause a wide variety of neuropsychiatric symptoms, including visual illusions and distortion of time perception. Chronic use can lead to persistent psychosis, but is unlikely to account for the neurological signs and raised ALT.

C Ganser syndrome

signs and raised ALT.

C	Ganser syndrome

Ganser syndrome is a dissociative disorder characterised by absurd or approximate answers to questions (paralogias), clouding of consciousness, somatic conversion symptoms, hallucinations and amnesia. The syndrome is associated with a history of head injury, Munchausen syndrome, solitary confinement or extreme stress. This diagnosis would not explain the extrapyramidal signs and abnormal liver function tests.

D	Othello syndrome

Othello syndrome is a term used to describe morbid jealousy, which may involve delusions, obsessions and overvalued ideas. It would not explain this patient's neurological signs or deranged liver function tests.

6869

Rate this question:

As the medical registrar, you are asked for an opinion by the surgical house officer on a 72-year-old woman who is 24 h post-abdominal aneurysm repair. All the other members of the surgical team are occupied in theatre at the present time.

The patient is complaining of severe constant abdominal pain, mainly localised to the right iliac fossa, but on examination no abdominal signs are elicited. Apart from hypertension, she has no other significant past medical history. The patient is tachycardic and has a blood pressure of 95/61 mmHg.

Urgent bloods, including ABG, are requested as well as an abdominal X-ray. Fluid replacement is commenced. The abdominal X-ray is reported by the duty registrar as showing a gasless abdomen.

Investigations:

Hb	18.0 g/dl
WCC	14 g/dl
Platelets	420 x 10^9/l

WCC	14 g/dl
Platelets	420 × 10^9/l
Amylase	270 U/l
pH	7.31
$p_a(CO_2)$	3.5 kPa
$p_a(O_2)$	14.0 kPa
Standard bicarbonate	12mmol/l (normal range 22–28 mmol/l)

The patient undergoes a single contrast barium assessment the next day. The provisional report suggests that there is thumbprinting of the bowel wall.

On the basis of these results, what is the most likely diagnosis?

A Acute pancreatitis

B Acute ischaemic colitis

C Ulcerative colitis

Standard bicarbonate	12mmol/l (normal range 22–28 mmol/l)

The patient undergoes a single contrast barium assessment the next day. The provisional report suggests that there is thumbprinting of the bowel wall.

On the basis of these results, what is the most likely diagnosis?

A	Acute pancreatitis
B	Acute ischaemic colitis
C	Ulcerative colitis
D	Crohn's disease
E	Acute bowel obstruction

6811

Submit

Standard bicarbonate	12mmol/l (normal range 22–28 mmol/l)

The patient undergoes a single contrast barium assessment the next day. The provisional report suggests that there is thumbprinting of the bowel wall.

On the basis of these results, what is the most likely diagnosis?

Your answer was correct

A Acute pancreatitis

B Acute ischaemic colitis

C Ulcerative colitis

D Crohn's disease

E Acute bowel obstruction

Explanation

B Acute ischaemic colitis

Ischaemic colitis is a disease that results from an insufficient blood supply to a segment of or the entire colon. It tends to be a problem encountered in old age due to atheroma in the mesenteric vessels – it is rarely seen in patients below the age of 60 – but other causes include embolic disease (such as atrial fibrillation), blunt abdominal trauma, disseminated intravascular coagulation, aortic aneurysm and shock, both hypovolaemic and endotoxic. Typically, with sudden thromboembolism, patients experience the sudden onset of abdominal pain, sometimes associated with bloody diarrhoea. If the ischaemia is severe enough to cause bowel necrosis and perforation, the patient may present with an acute abdomen. An abdominal X-ray may be normal – a gasless abdomen is a non-specific radiological finding and can be seen in other inflammatory conditions of the colon. Barium enema results tend to be

Barium enema results tend to be abnormal in 90% of patients – thumbprinting being indicative of mucosal oedema – but CT is the single best test after plain radiography since other causes of abdominal pain can be excluded and the diagnosis of intestinal ischemia can be established.

A	Acute pancreatitis

Acute pancreatitis is effectively ruled out by the amylase of 270. A much greater rise in amylase to at least greater than 800 would be expected in acute pancreatitis.

C	Ulcerative colitis

Ulcerative colitis is unlikely to present for the first time at the age of 72, and the coincident abdominal aortic aneurysm makes ischaemic colitis the much more likely cause of symptoms here.

D	Crohn's disease

A 22-year-old lady is seen in the clinic. She has a history of nose bleeds and has also recently undergone investigation for anaemia. She reports that her father died suddenly of a brain haemorrhage in his 40s. She does not take any regular medications.

On examination, the lesions illustrated below are noted.

What is the most likely diagnosis?

A	Systemic lupus erythematosus
B	Peutz-Jeghers syndrome

What is the most likely diagnosis?

A	Systemic lupus erythematosus
B	Peutz-Jeghers syndrome
C	Hereditary haemorrhagic telangiectasia (HHT)
D	Ataxia-telangiectasia
E	CREST syndrome (Calcinosis, Raynaud's syndrome, Esophageal dysmotility, Sclerodactyly and Telangiectasia

2:10
tps://mypastest.pastest.com

A 22-year-old lady is seen in the clinic. She has a history of nose bleeds and has also recently undergone investigation for anaemia. She reports that her father died suddenly of a brain haemorrhage in his 40s. She does not take any regular medications.

On examination, the lesions illustrated below are noted.

What is the most likely diagnosis?

Your answer was correct

C Hereditary haemorrhagic telangiectasia (HHT)

HHT (also known as Osler–Weber–Rendu disease) is an autosomal dominant disorder manifested by telangiectases of the skin and mucous membranes associated with bleeding tendency. Larger lesions may affect the nasopharynx, central nervous system, lung, liver and spleen, as well as the urinary and gastrointestinal tracts. Arteriovenous malformations (AVMs) may be present, and are a source of significant morbidity and mortality. This was probably the cause of her father's brain haemorrhage.

A Systemic lupus erythematosus

This is typically not associated with nose bleeds and there is very little in the clinical vignette to suggest this diagnosis.

B Peutz-Jeghers syndrome

B	Peutz-Jeghers syndrome

This is associated with pigmented oral lesions rather than telangiectasia.

D	Ataxia-telangiectasia

There is no history of ataxia in this patient.

E	CREST syndrome (Calcinosis, Raynaud's syndrome, Esophageal dysmotility, Sclerodactyly and Telangiectasia

This is not associated with nose bleeds and there are no other clues in the clinical history to suggest this diagnosis. CREST is the limited cutaneous form of scleroderma.

6343

Rate this question:

Next Question

A 19-year-old woman presents to her general practitioner (GP) with an itchy rash over both elbows and an 8-week history of loose bowel motions. She feels lethargic and has lost approximately 2 kg in weight over the last few months. She has previously been fit and well and takes no regular medication.

On examination, she looks pale and has a rash over both elbows, but there are no other significant findings.

Investigations:

Haemoglobin (Hb)	96 g/l
Mean corpuscular volume (MCV)	80 fl
White cell count (WCC)	6.4×10^9/l
Platelets	200×10^9/l
Erythrocyte sedimentation rate	26 mm/h
Na^+	140 mmol/l
K^+	4.0 mmol/l

Urea	5.4 mmol/l
Albumin	32 g/l
Bilirubin	12 µmol/l
Alkaline transferase (ALT)	20 U/l
Alkaline phosphatase (ALP)	145U/l (30–150)
Corrected calcium	2.2 mmol/l

What is the likely diagnosis?

A Tropical sprue

B Small bowel lymphoma

C Coeliac disease

D Whipple's disease

E Pseudomembranous colitis

C Coeliac disease

Coeliac disease is a common and underdiagnosed condition that may present at any age. It is a hypersensitivity to gluten found in wheat, rye, oats and barley. The gliadin fraction of the protein provokes an inflammatory response, causing sub-total or total villous atrophy of the small bowel resulting in malabsorption. It classically presents with a history of diarrhoea, weight loss, lethargy and anaemia (folate-, B_{12}- or iron-deficient). It is associated with dermatitis herpetiformis, a pruritic and blistering polymorphic skin rash. Treatment is by maintaining a strict diet avoiding foods containing wheat, rye, oats or barley.

A Tropical sprue

Tropical sprue is a small bowel condition characterised by malabsorption with inflammation and villous flattening. It occurs in tropical climates, but the causative agent is not

A 35-year-old man is being investigated for recurrent gastric and duodenal ulceration diagnosed at endoscopy. He has suffered from bouts of abdominal pain and intermittent diarrhoea, although his weight is stable. On examination, his abdomen is soft and there is no organomegaly.

Investigations:

Hb	13.0 g/dl (13.0-18.0)
WCC	6.5×10^9/l (4.0-11.0)
PLT	310×10^9/l (150-400
MCV	92 fl (80-96)
Urea and electrolytes	Normal
ALT	45 U/l (5-35)
ALP	128 U/l
GGT	38 U/l (< 50)
Bilirubin	17 μmol/l

Bilirubin	17 μmol/l
Basal acid secretion	20 mEq/h (1–5)
Fasting gastrin	200 pg/ml (< 100)
Basal gastrin	200 pg/ml
Post-secretin gastrin	500 pg/ml

Which of the following are responsible for the elevated gastrin levels?

A	Omeprazole therapy
B	Pernicious anaemia
C	Gastrinoma
D	*H. pylori* infection
E	Carcinoma of the stomach

C Gastrinoma

All of the above conditions are associated with hypergastrinaemia. Gastrinoma is the correct answer and can confidently be diagnosed in patients with gastrin levels >1000 pg/ml and basal acid output >15 mEq/l. The secretin test can be used to differentiate low-output gastrinomas from other causes of hypergastrinaemia – this will only be positive (rise in gastrin of >200 pg/ml 10 min after secretin injection) in the presence of a gastrinoma.

A Omeprazole therapy

Proton pump inhibitor (PPI) therapy with omeprazole is associated with hypergastrinaemia but low acid secretion, so is therefore an incorrect option.

B Pernicious anaemia

Loss of normal gastric mucosa, such as

would be low, so this option is incorrect.

D	*H. pylori* infection

This has been associated with high basal acid secretion and hypergastrinaemia. G-cell hyperplasia is an increase in the number of gastrin-producing cells in the normal gastric mucosa and is associated with *H. pylori*, and is thought to account for the raised gastrin levels seen in *H. pylori* infection.

E	Carcinoma of the stomach

This condition, in which normal gastric mucosa is replaced with cancerous cells, will lead to an increase in gastrin levels, but again one would not expect to see high levels of acid secretion, and secretin usually inhibits gastrin production. Therefore this option is incorrect.

6438

Rate this question:

A 69-year-old man undergoes a colonoscopy for investigation of long-standing diarrhoea. A polyp is found on the right side of the colon and removed by snare polypectomy.

Six hours later, on the Recovery Ward, he becomes drowsy and is now experiencing both severe abdominal pain and vomiting.

Which of the following is the most appropriate management plan?

A	Administer flumazenil as he may be experiencing side effects from the sedation given
B	Arrange an urgent water-soluble contrast enema to identify the perforation site
C	Keep nil by mouth, and arrange an urgent erect chest X-ray

experiencing both severe abdominal pain and vomiting.

Which of the following is the most appropriate management plan?

A	Administer flumazenil as he may be experiencing side effects from the sedation given
B	Arrange an urgent water-soluble contrast enema to identify the perforation site
C	Keep nil by mouth, and arrange an urgent erect chest X-ray
D	Schedule a repeat colonoscopy to identify the site of perforation
E	Reassurance and discharge with analgesia

C Keep nil by mouth, and arrange an urgent erect chest X-ray

A colonic perforation must be excluded given that he has recently had a polyp removed, and the colorectal surgeons should be involved at an early stage. An urgent chest X-ray is of course to look for air under the diaphragm, consistent with a perforated abdominal viscus.

D Schedule a repeat colonoscopy to identify the site of perforation

This may exacerbate the problem if there is a perforation present.

A Administer flumazenil as he may be experiencing side effects from the sedation given

This would not explain the severe

A Administer flumazenil as he may be experiencing side effects from the sedation given

This would not explain the severe abdominal pain experienced by the patient.

B Arrange an urgent water-soluble contrast enema to identify the perforation site

A water soluble contract enema would not be appropriate in a patient who you suspect may have had a perforation post-procedure, and this would exacerbate the problem.

E Reassurance and discharge with analgesia

This patient is clearly in some discomfort so it would be unsafe to send him home until the cause of his symptoms is identified and treated.

A 34-year-old woman is found to have the following blood results on routine preoperative blood tests.

She has no past medical history of note, but remembers a short episode of jaundice after a bout of flu around 12 years ago.

Bilirubin	36 µmol/l
Alkaline phosphatase	108 U/l
Alanine aminotransferase (ALT)	20 U/l
Urine dipstick	Normal

What is the most likely diagnosis?

A Budd–Chiari syndrome

B Gilbert's syndrome

C Dubin–Johnson syndrome

D Primary biliary cirrhosis

note, but remembers a short episode of jaundice after a bout of flu around 12 years ago.

Bilirubin	36 μmol/l
Alkaline phosphatase	108 U/l
Alanine aminotransferase (ALT)	20 U/l
Urine dipstick	Normal

What is the most likely diagnosis?

A	Budd–Chiari syndrome
B	Gilbert's syndrome
C	Dubin–Johnson syndrome
D	Primary biliary cirrhosis
E	Sclerosing cholangitis

B Gilbert's syndrome

This patient has asymptomatic jaundice, diagnosed incidentally. Gilbert syndrome is a common cause of unconjugated hyperbilirubinaemia and is often diagnosed incidentally. The prognosis is excellent. It is characterised by a mildly elevated bilirubin. The diagnosis can be confirmed by either an increase in bilirubin provoked by fasting or by a slow rise in bilirubin following administration of intravenous nicotinic acid.

A Budd–Chiari syndrome

Budd-Chiari syndrome is defined as hepatic venous outflow tract obstruction, independent of the level or mechanism of obstruction, provided the obstruction is not due to cardiac disease, pericardial disease or sinusoidal obstruction syndrome (veno-occlusive disease). Studies suggest that in non-Asian countries,

suggest that in non-Asian countries, Budd–Chiari syndrome is more common in women and usually presents in the third or fourth decade of life (although it may occur in children or older adults). Symptoms in patients with Budd–Chiari syndrome may include fever, abdominal pain, abdominal distension (from ascites), lower extremity oedema, jaundice, gastrointestinal bleeding (from varices or portal hypertensive gastropathy) and/or hepatic encephalopathy. Patients presenting with acute liver failure, acute hepatitis or chronic liver disease, particularly if the patient has known risk factors for Budd–Chiari syndrome such as myeloproliferative disease and malignancy. It is not diagnosed incidentally as in this case.

C	Dubin–Johnson syndrome

The lack of bilirubin excretion in the urine indicates that the patient has an unconjugated hyperbilirubinaemia, thereby excluding a diagnosis of Dubin–Johnson syndrome. Dubin–

thereby excluding a diagnosis of Dubin–Johnson syndrome. Dubin–Johnson syndrome is a familial hyperbilirubinaemia characterised by a raised water-soluble, conjugated bilirubin that is excreted in the urine.

D	Primary biliary cirrhosis

Primary biliary cholangitis (PBC, previously referred to as primary biliary cirrhosis) is characterised by an ongoing immunologic attack on the intralobular bile ducts that eventually leads to cirrhosis and liver failure. There would be abnormalities in liver function tests, unlike in this case.

E	Sclerosing cholangitis

Primary sclerosing cholangitis is a chronic, progressive disorder of unknown aetiology that is characterised by inflammation, fibrosis and stricturing of medium and large ducts in the intrahepatic and/or extrahepatic biliary tree. Patients with

9:07
tps://mypastest.pastest.com

ducts in the intrahepatic and/or extrahepatic biliary tree. Patients with primary sclerosing cholangitis may be asymptomatic and diagnosed as part of the evaluation of abnormal laboratory tests, or they may have symptoms such as fatigue and pruritus. Physical examination may reveal jaundice, hepatomegaly, splenomegaly and excoriations, though it is often normal. Liver biochemical tests usually demonstrate a cholestatic pattern, with elevation of the serum alkaline phosphatase predominating in most patients. Radiographic findings include abnormal-appearing bile ducts with wall thickening, dilations and strictures.

9509

Rate this question:

Next Question

Previous Question Tag Question

A 35-year-old Israeli student was admitted to hospital on a number of occasions with abdominal pain associated with arthralgia and fever.

Previous medical history included appendicectomy and cholecystitis. Pain was often associated with constipation that became diarrhoea when the pain resolved.

Clinical examination revealed a pyrexia of 38.5 °C, with generalised rebound tenderness in the abdomen and diminished bowel sounds. Bilateral swollen knees were noted and clear fluid was aspirated from each joint. Computed tomography (CT) examination was unremarkable.

Investigations:

Hb	13.5 g/dl
WCC	10.0×10^9/l
PLT	300×10^9/l
Bilirubin	10 μmol/l (1–22)
AST	16 u/l (1–31)

AST	16 u/l (1–31)
ALT	21 u/l (5–35)
Albumin	40 g/l (37–49)
CRP	72 mg/l
ESR	50 mm/h
Synovial fluid	No organisms
Urinalysis	Protein+++
Urinary porphyrins	Normal

What is the most likely diagnosis?

A Familial Mediterranean fever

B Crohn's disease

C Acute intermittent porphyria

D Adult Still's disease

E Irritable bowel syndrome

A Familial Mediterranean fever

Familial Mediterranean fever is an autosomal recessive disorder characterised by sporadic paroxysmal attacks of fever and serosal inflammation. Patients are recurrently admitted to hospital and undergo extensive investigation and often abdominal surgery, but no specific pathology is found. Constipation accompanying the fever is common and diarrhoea may follow its resolution. Synovitis has been reported in up to 75% of patients. Erythrocyte sedimentation rate and C-reactive protein are elevated, and serosal (peritoneal or pleural) or synovial fluid may show large numbers of neoutrophils with no organisms. Amyloidosis manifesting as proteinuria can occur, particularly in Sephardic (Middle Eastern and North African) Jews. Therefore, Option A is the best answer here. A specific genetic test is now available to aid diagnosis, and the treatment of choice is colchicine.

intestinal manifestations such as arthritis. However, this patient has a fever and, in the context of Crohn's disease, you would be concerned about an abscess or another complication of Crohn's such as a perforation, which would usually be apparent on a CT scan.

C	Acute intermittent porphyria

Normal urinary porphyrins effectively rule out acute intermittent porphyria.

D	Adult Still's disease

This condition is usually associated with a classic salmon-coloured rash and a raised ferritin. Splenomegaly can also be present.

E	Irritable bowel syndrome

This is a diagnosis of exclusion and is not associated with elevated inflammatory markers, fevers or joint swelling, so is therefore incorrect.

A 29-year-old woman comes to the clinic. She is 30 weeks pregnant and has a previous history of Crohn's disease but this was quiescent prior to becoming pregnant and she discontinued her treatment 18 months ago. She was previously managed with sulphasalazine. She now complains of severe diarrhoea and abdominal pain.

Abdominal examination is consistent with a 30-week pregnancy and it is difficult to assess specific tenderness, which may be related to active Crohn's.

Investigations:

Hb	10.9 g/dl
WCC	11.1×10^9/l
PLT	190×10^9/l
ESR	47 mm/h
Na^+	139 mmol/l
K^+	4.8 mmol/l
Creatinine	100 μmol/l

ESR	47 mm/h
Na^+	139 mmol/l
K^+	4.8 mmol/l
Creatinine	100 μmol/l

Which of the following would be the most appropriate initial treatment for her?

A Sulphasalazine

B Methotrexate

C Metronidazole

D Infliximab

E Prednisolone

21163

Submit

Explanation

E	Prednisolone

Prednisolone is the preferred treatment of a relapse during pregnancy (in the absence of infective complications, such as abscesses). Corticosteroids are rapidly metabolised by the fetus leading to low fetal blood concentrations and a low risk of fetal complications.

In terms of maintenance therapy during pregnancy then recent metanalyses have shown that thiopurines, such as azathioprine or 6MP, are not associated with an increased risk of adverse pregnancy outcomes when compared with IBD patients on no treatment. As such, patients should remain on thiopurines during pregnancy; better maternal and fetal outcomes are strongly associated with good disease control during pregnancy.

A	Sulphasalazine

A Sulphasalazine

This lady has an acute flare of Crohn's and needs induction of remission. Sulphasalazine has not been shown to be efficacious in inducing remission in an acute flare and despite the fact she was previously taking this, its role as a maintenance therapy in Crohn's is no longer recommended.

B Methotrexate

It is absolutely contraindicated in pregnancy due to its teratogenicity, particularly in the first trimester. For patients trying to conceive there is an approximate 6-week wash-out period.

C Metronidazole

There is no role for induction of an acute flare and although metronidazole can be safely used in pregnancy its use in acute Crohn's tends to be limited to patients with infective complications such as

You are asked to review a 26-year-old woman who suffers from severe Crohn's disease. She has numerous previous admissions to the hospital and two previous ileal resections.

On this occasion, there is a history of abdominal pain and diarrhoea with intermittent fevers. CRP is raised at 75 U/l. She is currently managed on azathioprine therapy and a maintenance dose of 10 mg prednisolone per day. Her BMI is 16.

Which of the following would you advise her with respect to dietary control of her Crohn's?

A	Short-term use of TPN may be helpful
B	Elemental diet is definitely of benefit
C	Low-fat, medium-chain triglyceride diet is of no benefit

intermittent fevers. CRP is raised at 75 U/l. She is currently managed on azathioprine therapy and a maintenance dose of 10 mg prednisolone per day. Her BMI is 16.

Which of the following would you advise her with respect to dietary control of her Crohn's?

A	Short-term use of TPN may be helpful
B	Elemental diet is definitely of benefit
C	Low-fat, medium-chain triglyceride diet is of no benefit
D	Dairy-free diet definitely won't impact on her diarrhoea
E	Wheat-free diet is likely to impact on her diarrhoea

A	Short-term use of TPN may be helpful

This patient is severely debilitated by her Crohn's disease, and short-term TPN to supplement normal eating, allowing recovery of calorie intake and improving her weight and nutritional status may be indicated.

B	Elemental diet is definitely of benefit

Elemental diet has mixed benefit according to randomised controlled trials, some showing improved recovery and decreased steroid use, others showing little significant benefit.

C	Low-fat, medium-chain triglyceride diet is of no benefit

This may allow improved calorie delivery and reduce associated diarrhoea

C Low-fat, medium-chain triglyceride diet is of no benefit

This may allow improved calorie delivery and reduce associated diarrhoea.

D Dairy-free diet definitely won't impact on her diarrhoea

There is a significant portion of Crohn's patients who are lactose intolerant, and hence a dairy free diet may reduce the frequency of her diarrhoea.

E Wheat-free diet is likely to impact on her diarrhoea

A wheat-free diet is of greatest utility in patients with coeliac disease who are gluten intolerant.

18535

Rate this question:

9:21
tps://mypastest.pastest.com

This barium swallow is from a 56-year-old man who presented with intermittent dysphagia.

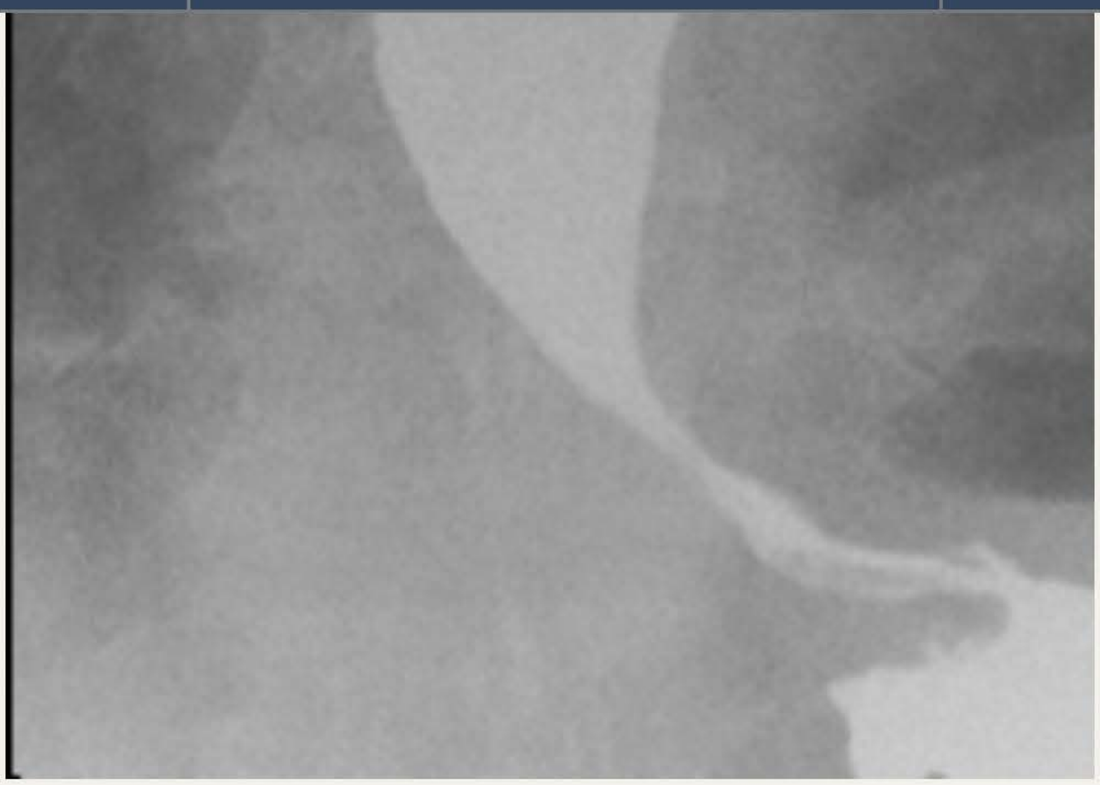

What is the diagnosis?

A	Benign oesophageal stricture
B	Diffuse oesophageal spasm
C	Oesophageal carcinoma
D	Achalasia
E	Barrett's oesophagus

D Achalasia

The barium swallow shows the typical appearance of achalasia, with a dilated atonic oesophagus tapering to a narrowed distal end and tight lower oesophageal sphincter. Achalasia has an incidence of 1 per 100,000 per year and is defined as reduced or absent peristalsis and failure of the lower oesophageal sphincter (LOS) to relax when swallowing. It is due to the degeneration of ganglionic cells in the nerve plexi of the oesophageal wall. It can present at any age with intermittent dysphagia to both solids and liquids, regurgitation, severe retrosternal chest pain and aspiration pneumonia. A chest X-ray may show an air–fluid level behind the heart. Upper gastrointestinal endoscopy should always be performed in suspected achalasia to exclude a tumour, which can present similarly. However, all these investigations may be normal and the definitive diagnostic test is oesophageal manometry, which will confirm a high oesophageal resting

test is oesophageal manometry, which will confirm a high oesophageal resting tone, weak or absent peristalsis and a non-relaxing lower oesophageal sphincter. Treatment options include endoscopic pneumatic dilation of the LOS (successful in 80% of cases), intra-sphincteric botulinum toxin injection and surgical division of the LOS (Heller's cardiomyotomy). There is an increased risk of carcinoma of the oesophagus in patients with achalasia.

A	Benign oesophageal stricture

Benign oesophageal strictures are caused by inflammation, leading to scar tissue formation which can be secondary to reflux disease, corrosives, surgery or radiotherapy. Treatment is possible with endoscopic balloon dilatation.

B	Diffuse oesophageal spasm

Diffuse oesophageal spasm causes intermittent dysphagia and chest pain.

C	Oesophageal carcinoma

Oesophageal cancer is associated with being male, smoking history, oesophageal reflux, Barrett's oesophagus and achalasia. Oesophageal malignancy should be suspected when the patient has described dysphagia as affecting solids before liquids, rather than both at the same time; as being associated with odynophagia; and as being constant and progressive. Management is via an MDT approach; this can involve surgery, chemotherapy and radiotherapy, but prognosis is generally poor.

E	Barrett's oesophagus

Barrett's oesophagus is metaplasia secondary to acid reflux, resulting in a change from mucosa with columnar epithelium. Diagnosis is histological on biopsy during OGD, and management depends on histological risk towards dysplasia. Resection or eradicative

A 46-year-old man is seen in neurology outpatients after being referred with disinhibited behaviour of 2 months' duration. His family tells you that he passes urine in public and the police have brought him home on two occasions recently. He has been losing weight for the last year and was previously 110 kg, now weighing 92 kg. He has diarrhoea and his family tell you it smells bad and is difficult to flush. The patient complains of pain in his right knee, left ankle and lower back.

On examination, he looks pale and has angular cheilitis. He has a distended abdomen with some shifting dullness but no palpable organomegaly. His palmo-mental reflex is positive. The right knee and left ankle are both swollen with minimal tenderness and a good range of movement.

Investigations:

Sodium	134 mmol/l
Potassium	4.1 mmol/l
Urea	4.8 mmol/l

Sodium	134 mmol/l
Potassium	4.1 mmol/l
Urea	4.8 mmol/l
Creatinine	45 μmol/l
Calcium (corrected)	1.74 mmol/l
Albumin	27 g/l
WCC	6.5×10^9/l
Hb	9.2 g/dl
MCV	78.2 fl
Platelets	512×10^9/l
INR	1.4
CT brain	Normal

Oesophago-gastro-duodenoscopy (OGD) is performed and duodenal biopsy demonstrates expanded villi containing macrophages staining positive with periodic acid–Schiff stain.

What is the most likely diagnosis?

INR	1.4
CT brain	Normal

Oesophago-gastro-duodenoscopy (OGD) is performed and duodenal biopsy demonstrates expanded villi containing macrophages staining positive with periodic acid–Schiff stain.

What is the most likely diagnosis?

A	Hartnup disease
B	Coeliac disease
C	HIV enteropathy and dementia
D	Tropical sprue
E	Whipple's disease

6864

Submit

INR	1.4
CT brain	Normal

Oesophago-gastro-duodenoscopy (OGD) is performed and duodenal biopsy demonstrates expanded villi containing macrophages staining positive with periodic acid–Schiff stain.

What is the most likely diagnosis?

Your answer was correct

A Hartnup disease

B Coeliac disease

C HIV enteropathy and dementia

D Tropical sprue

E Whipple's disease

Explanation

E Whipple's disease

Whipple disease is a systemic disease caused by *Tropheryma whippeli*, a Gram-positive, non-acid-fast rod. It is usually found in white, middle-aged males, most commonly in Europe. The classic presentation, believed to be caused by organism infiltration of the body tissue, is that of a wasting illness characterised by four cardinal features: migratory arthralgia of the large joints, arthritis, intermittent diarrhoea and colicky abdominal pain. The disease can affect the central nervous system (CNS) and produce frontal signs (such as in our patient), meningoencephalitis or dementia.

The organism is taken up by the macrophages, and diagnosis is established by identifying 'foamy' macrophages that stain positive with periodic acid-Schiff (PAS) stain on jejunal biopsy. PCR testing is also used for confirmation. Other infections, such as with endemic fungi (e.g. *Histoplasma* spp.), *Rhodococcus* and HIV-infected mycobacterial disease.

as with endemic fungi (e.g. *Histoplasma* spp.), *Rhodococcus* and HIV-infected mycobacterial disease, can be histologically similar to Whipple's disease, but many can be ruled in or out by additional testing (i.e. staining for organisms, culture, antigen testing). Antibiotics are the mainstay of treatment - usually co-trimoxazole or tetracycline is given for 1 year. Clinical failure is suggested by a positive PCR in the relevant specimen from patients who fail to respond clinically to adequate therapy or have recurrence of symptoms after initial improvement. One third of patients relapse.

A	Hartnup disease

Hartnup disease is an autosomal recessive disorder caused by impaired amino acid transport in the apical brush border membrane of the small intestine and the proximal tubule of the kidney. If symptomatic, it usually presents in childhood with pellagra-like skin eruptions, cerebellar ataxia and gross aminoaciduria

immunosuppressed) and Whipple's disease are similar. Neurocognitive disorders can be seen in advanced or untreated HIV infection. However, there is no history of cough, which would be the usual first presentation of MAI infection. And while *M. avium*-positive duodenal biopsies are also PAS positive, contrary to Whipple's disease, they also stain positive with Ziehl-Neelson. Whipple's disease is more likely to explain the overall clinical picture.

D	Tropical sprue

The gastrointestinal symptoms of tropical sprue and Whipple's disease are indistinguishable. However, the cognitive changes as seen in this case would be more difficult to attribute to tropical sprue. Furthermore, histology of the duodenum would reveal flattened villi and inflammatory cell infiltrates, but no PAS-positive macrophages.

A 32-year-old woman presents to the Emergency Department with a sudden onset of severe central abdominal pain and profuse vomiting. She had also passed several loose stools, but these had not been associated with any blood or mucus. She had no other symptoms.

On examination, she was pyrexial and tachycardic with generalised abdominal tenderness. She had eaten in a Chinese buffet restaurant 3 h prior to the onset of symptoms, and remembers that she mainly ate from the rice dishes.

Apart from a raised white count with neutrophilia, her full blood count and serum biochemistry were normal.

What is the most likely causative organism?

A	*Campylobacter jejuni*
B	*Escherichia coli* 0157:H7

On examination, she was pyrexial and tachycardic with generalised abdominal tenderness. She had eaten in a Chinese buffet restaurant 3 h prior to the onset of symptoms, and remembers that she mainly ate from the rice dishes.

Apart from a raised white count with neutrophilia, her full blood count and serum biochemistry were normal.

What is the most likely causative organism?

A	*Campylobacter jejuni*
B	*Escherichia coli* 0157:H7
C	*Bacillus cereus*
D	*Staphylococcus aureus*
E	*Listeria monocytogenes*

C *Bacillus cereus*

The short onset of food poisoning in this patient fits with symptoms related to enterotoxin production, and given the history of consumption of fried rice, a diagnosis of *Bacillus cereus* food poisoning fits best. This is a Gram-positive bacillus which produces an enterotoxin that is classically found in reheated fried rice. Ingestion of the preformed toxin causes fairly rapid (1–4 h) onset of acute abdominal pain with profuse vomiting and sometimes diarrhoea. There is usually recovery within 24–48 h. There is no specific therapy, and treatment is purely supportive.

A *Campylobacter jejuni*

Campylobacter symptoms are slower in onset, occurring up to 48 h after consumption of contaminated food, and are associated with fever, cramping stomach pains, vomiting and diarrhoea, which may be bloody.

A 58-year-old woman presents with a 4-day history of shortness of breath and cough. There is a long past medical history of indigestion, worse when she lies flat on the bed, with occasional acid regurgitation. She may even wake at night occasionally with acid in her mouth and paroxysms of coughing.

On examination, her body mass index (BMI) is 31, she is pyrexial with a temperature of 39 °C, there is an area of bronchial breathing over the right lung and a suggestion of increased shadowing on the chest X-ray at the right base.

Which of the following is the most likely underlying cause for this clinical picture?

A	Bronchiectasis
B	Exacerbation of asthma
C	Oesophageal carcinoma

(BMI) is 31, she is pyrexial with a temperature of 39 °C, there is an area of bronchial breathing over the right lung and a suggestion of increased shadowing on the chest X-ray at the right base.

Which of the following is the most likely underlying cause for this clinical picture?

A	Bronchiectasis
B	Exacerbation of asthma
C	Oesophageal carcinoma
D	Benign oesophageal stricture
E	Gastro-oesophageal reflux disease (GORD)

13482

Submit

E Gastro-oesophageal reflux disease (GORD)

This woman has a long history of indigestion, particularly worse when lying flat, and acid regurgitation, complicated by a chronic nocturnal cough. It is likely that an episode of regurgitation has led to right-sided lower respiratory tract infection. She is obese, which may well contribute to her symptoms. Other predisposing factors which increase the likelihood of GORD include smoking; hiatus hernia; medications which relax the lower oesophageal sphincter such as calcium channel blockers and beta-blockers; pregnancy; and foods such as chocolate and peppermint. Weight reduction would be the mainstay of management in this case, with the addition of proton pump inhibitors.

A Bronchiectasis

Bronchiectasis is associated with longer-term shortness of breath and

A Bronchiectasis

Bronchiectasis is associated with longer-term shortness of breath and recurrent episodes of lower respiratory tract infection.

B Exacerbation of asthma

Given the long history of water brash and associated coughing, reflux is the more likely primary cause of her symptoms, and the CXR changes, rather than asthma alone.

C Oesophageal carcinoma

The long history of indigestion without progression to dysphagia and lack of weight loss doesn't fit with a diagnosis of oesophageal carcinoma.

D Benign oesophageal stricture

Benign oesophageal stricture leads to regurgitation of food, often a mix of

tract infection.

B Exacerbation of asthma

Given the long history of water brash and associated coughing, reflux is the more likely primary cause of her symptoms, and the CXR changes, rather than asthma alone.

C Oesophageal carcinoma

The long history of indigestion without progression to dysphagia and lack of weight loss doesn't fit with a diagnosis of oesophageal carcinoma.

D Benign oesophageal stricture

Benign oesophageal stricture leads to regurgitation of food, often a mix of both solid and liquid meals, rather than the progressive dysphagia seen with oesophageal Ca.

13482

Rate this question:

An 18-year-old woman is seen to take a large quantity of paracetamol tablets following an argument with her boyfriend. At 72 h later, she presents to the Emergency Department with jaundice and vomiting.

On examination, her BP is 105/72, pulse is 85 and regular. She is tender in the epigastrium and tells you she is passing only small amounts of dark urine.

Which of the following would be the best indicator of her overall prognosis?

A	Prothrombin time
B	Liver transaminases
C	Serum paracetamol levels
D	Bilirubin
E	Urea

A Prothrombin time

Paracetamol can cause liver failure even at relatively low doses (>7 g). The transplant criteria published by King's College Hospital are based on prognostic factors from a large retrospective cohort of patients. In these criteria, coagulopathy (prolonged prothrombin time/increased international normalised ration (INR)) is an important prognostic indicator along with encephalopathy, development of kidney disease and acidosis not corrected by fluid resuscitation.

Maximal liver damage will occur approximately 72 h after ingestion when prothrombin time will be maximally prolonged – it will then either return to normal (recovery with no sequelae) or remain prolonged (acute liver failure – recovery unlikely).

B Liver transaminases

Transaminases are released by

B Liver transaminases

Transaminases are released by damaged hepatocytes and are always raised in significant paracetamol poisoning, reaching levels of >10 000 IU/l. Transaminase levels are, however, not good indications of whether progression to acute liver failure will occur.

C Serum paracetamol levels

Although raised serum paracetamol levels at >48 h would suggest a large or staggered overdose, both more at risk of progressing to acute liver failure, the value has no prognostic role.

D Bilirubin

Although serum bilirubin is included in some prognostic indices in paracetamol poisoning, it is nowhere near as reliable as prothrombin time.

Transaminases, γ-glutamyl

risk of progressing to acute liver failure, the value has no prognostic role.

D	Bilirubin

Although serum bilirubin is included in some prognostic indices in paracetamol poisoning, it is nowhere near as reliable as prothrombin time. Transaminases, γ-glutamyl transpeptidase (GGt), albumin and alkaline phosphatase are of no benefit.

E	Urea

Creatinine, not urea is used as an indicator of impending acute kidney disease in paracetamol overdose. Measurement of urea is confounded as a measure of renal failure because of it's absorption as part of a 'blood meal'.

9830

Rate this question:

A 40-year-old man is admitted to the Emergency Department having taken a paracetamol overdose. On questioning he describes having taken 50 tablets of 500 mg of paracetamol over 30 min, with the intention of ending his own life. He did this 6 h ago and has been brought into hospital after being found by his girlfriend. She reports that she found him conscious and he agreed to go to hospital. During the journey to hospital he started developing abdominal pain, which has been progressively become worse since then. He has also vomited once. On examination he looks unhappy and downcast, and his RUQ is mildly tender. He is not jaundiced, and he has a GCS of 15/15.

Which of the following investigations is the best indicator of the severity of liver failure?

A	Blood glucose
B	Creatinine

found by his girlfriend. She reports that she found him conscious and he agreed to go to hospital. During the journey to hospital he started developing abdominal pain, which has been progressively become worse since then. He has also vomited once. On examination he looks unhappy and downcast, and his RUQ is mildly tender. He is not jaundiced, and he has a GCS of 15/15.

Which of the following investigations is the best indicator of the severity of liver failure?

A	Blood glucose
B	Creatinine
C	Alkaline phosphatase
D	Prothrombin time
E	Alanine aminotransferase

D Prothrombin time

Paracetamol overdose is one of the most common methods of self-poisoning in the UK. Paracetamol is metabolised by glucuronidation in the liver. The toxicity of this analgesic arises from its saturable metabolism. Excess oxidation product, NAPQI (*N*-acetyl-benzoquinoneimine) is produced, overwhelming the liver's capacity to detoxify it by conjugation with glutathione. Serum paracetamol levels should be measured at least 4 h after ingestion. Initial symptoms of overdose are nausea and vomiting, with hepatic and/or kidney disease presenting at 24–36 h. Liver damage peaks at 3–4 days after ingestion. The prothrombin time (PT) is the most sensitive indicator of liver damage. A poor prognosis is indicated by a PT >100 s, serum creatinine >300 μmol/l and arterial pH <7.3.

A Blood glucose

In acute liver failure, gluconeogenesis fails. This can lead to hypoglycaemia, which is important to correct if found. However, this is an intermittent problem and a poor marker of liver failure as it fluctuates easily following ingestion of food and IV treatment with glucose. Hypoglycaemia can also occur in sepsis, which is a common presentation in acute liver failure.

B Creatinine

Kidney disease is common in liver failure but can occur due to several causes, including acute renal injury and dehydration.

C Alkaline phosphatase

ALP is present especially in the liver, bile ducts, kidneys and bone. ALP is released in the liver and in diseases of elevated bone turnover. It can be very high in liver failure, especially if there is a biliary cause. However, it is not a

9:39
tps://mypastest.pastest.com

ALP is present especially in the liver, bile ducts, kidneys and bone. ALP is released in the liver and in diseases of elevated bone turnover. It can be very high in liver failure, especially if there is a biliary cause. However, it is not a marker of synthetic liver function and therefore not useful in direct assessment of liver failure.

E	Alanine aminotransferase

AST is present especially in hepatocytes and is released on cell injury. It can be very high in liver failure, especially if there is a hepatic cause. However, it is not a marker of synthetic liver function and therefore not useful in direct assessment of liver failure.

9516

Rate this question:

Next Question

A 45-year-old man presents with a 6-month history of progressive intermittent dysphagia to both solids and liquids, and a persistent productive cough. He is a long-term smoker but otherwise is fit and well; he reports no significant weight loss.

Clinical examination is unremarkable and an upper gastrointestinal endoscopy report from another hospital is normal.

Investigations:

Bilirubin	19 μmol/l (1–22)
AST	22 u/l (1–31)
ALT	31 u/l (5–35)
Albumin	42 g/l (37–49)
Haemoglobin (Hb)	148 g/l
White cell count (WCC)	9×10^9/l
Platelets	258×10^9/l

Lower oesophageal sphincter resting pressure	60mmHg (17–36)
Residual lower oesophageal sphincter relaxing pressure	12mmHg (<8)

Peristalsis:

Proximal amplitude	80 mmHg (33–91)
Proximal duration	3 s (2.0–3.6)
Distal amplitude	0 mmHg (64–154)
Distal duration	Absent (2.9–5.1)

What is the most likely diagnosis?

A	Scleroderma
B	Nutcracker oesophagus
C	Diffuse oesophageal spasm

Peristalsis:

Proximal amplitude	80 mmHg (33–91)
Proximal duration	3 s (2.0–3.6)
Distal amplitude	0 mmHg (64–154)
Distal duration	Absent (2.9–5.1)

What is the most likely diagnosis?

A Scleroderma

B Nutcracker oesophagus

C Diffuse oesophageal spasm

D Carcinoma of the oesophagus

E Achalasia

Lower oesophageal sphincter resting pressure	60mmHg (17–36)
Residual lower oesophageal sphincter relaxing pressure	12mmHg (<8)

Peristalsis:

Proximal amplitude	80 mmHg (33–91)
Proximal duration	3 s (2.0–3.6)
Distal amplitude	0 mmHg (64–154)
Distal duration	Absent (2.9–5.1)

What is the most likely diagnosis?

Your answer was correct

A	Scleroderma
B	Nutcracker oesophagus

E Achalasia

Achalasia describes a failure of relaxation of the lower oesophageal sphincter, and affects an estimated 10 in 10,000 people. Endoscopy is often normal but can show lower oesophageal dilatation and failure of the lower oesophageal sphincter (LOS) to relax. The hallmark feature of manometry is absence of peristalsis in the distal oesophagus, accompanied by failure of the LOS to relax during swallowing (i.e. a high residual relaxing pressure). These features may be accompanied by a high resting LOS pressure, but this is not necessary for a diagnosis. Achalasia often causes intermittent symptoms, with residual food and liquid in the distal oesophagus causing halitosis and recurrent chest sepsis due to nocturnal aspiration.

A Scleroderma

Scleroderma is an autoimmune

A Scleroderma

Scleroderma is an autoimmune connective tissue disorder which causes fibrosis of organs. It can cause fibrosis of the oesophagus leading to dysphagia, but is unlikely without other features such as calcinosis, Raynaud's, sclerodactyly and telangiectasis. Scleroderma can also lead to reduced or occasionally absent distal peristalsis, but this is accompanied by low resting LOS pressures.

B Nutcracker oesophagus

Nutcracker oesophagus is an oesophageal dysmotility disorder characterised by dysphagia of both liquids and solids, with chest pain. In nutcracker oesophagus, there is oesophageal pressure exceeding 180 mmHg, which this patient does not have.

C Diffuse oesophageal spasm

have.

C Diffuse oesophageal spasm

Diffuse oesophageal spasm causes intermittent dysphagia and chest pain. A barium swallow can differentiate from achalasia by demonstrating abnormal oesophageal contractions such as a corkscrew pattern. In this patient there is interruption of peristalsis, which does not fit.

D Carcinoma of the oesophagus

Oesophageal cancer is associated with male gender, smoking history, oesophageal reflux, Barrett's oesophagus and achalasia. Management is via an MDT approach. The presence of intermittent rather than progressive dysphagia makes this unlikely, as does the abnormal manometry.

6437

Rate this question:

A 77-year-old woman is seen with a 3-h history of cramping abdominal pain, bloody diarrhoea and abdominal distension. The blood is dark and looks mixed with the stool. She has previously been relatively well.

She has a history of atrial fibrillation, for which she takes warfarin. She also has hypertension and is on a diuretic. She stopped smoking 2 years ago and she occasionally drinks a sherry at night.

On examination, she is in pain and has a mild fever, temperature 37.6 °C Her pulse is 100/min and irregular and blood pressure is 124/76 mmHg. Her abdomen is distended, with generalised tenderness on palpation. Abdominal X-ray (AXR) shows mild, diffuse bowel dilatation.

Investigations:

WCC	17.2×10^9/l
Hb	10.1 g/dl
MCV	84.3 fl

WCC	$17.2 \times 10^9/l$
Hb	10.1 g/dl
MCV	84.3 fl
Platelets	$531 \times 10^9/l$
INR	1.8

A barium enema is requested, which demonstrates thickening of the bowel wall with some evidence of thumb printing.

What is the most likely diagnosis?

A	Acute duodenal ulcer
B	Diverticulitis
C	Mesenteric venous thrombosis
D	Ischaemic colitis
E	Crohn's colitis

D Ischaemic colitis

Ischaemic colitis occurs secondary to a sudden drop in the colonic blood supply, but in most patients, no specific cause of the decrease can be identified. Presentation can range from acute abdominal cramping and distension to mild pain with rectal bleeding and diarrhoea. The predominant predisposing factors are atherosclerosis, shock and congestive heart failure. The condition is associated with aorto-iliac surgery (3–6% with such operations). High clinical suspicion is needed, and in our patient the finding of AF increases the risk of an embolus to the gut vasculature.

Abdominal X-ray, barium enema and computed tomography (CT) show evidence of bowel wall thickening and thumbprinting. Sigmoidoscopy frequently reveals oedematous, friable mucosa, erythema and interspersed pale areas. Bluish haemorrhagic nodules may be seen representing submucosal bleeding. The majority have transient, non-gangrenous

pale areas. Bluish haemorrhagic nodules may be seen representing submucosal bleeding. The majority have transient, non-gangrenous ischaemia which responds favourably and rapidly to simple conservative measures, with spontaneous recovery within 24-48 h. Conservative management includes close monitoring, appropriate intravenous rehydration and broad-spectrum antibiotics that cover enteric flora, and aggressive measures to correct processes that may have precipitated the ischaemic insult. Colonic strictures following recovery are common.

A minority of patients require exploratory laparotomy without the benefit of an established preoperative diagnosis. Due to the paucity of vessels/anastomoses supplying the splenic flexure/descending colon and sigmoid colon, these areas are most often affected. Gangrenous ischaemic colitis requires prompt resuscitation, followed by resection of the affected bowel and stoma formation.

A 30-year-old man with a history of manic depression is referred from the Psychiatric Department. He is found to have abnormal liver function tests.

On examination, he is very irritable, dysarthric and ataxic.

Investigations:

Na^+	133 mmol/l
K^+	4.5 mmol/l
Urea	14.0 mmol/l
Creatinine	220 μmol/l
Bilirubin	45 μmol/l
ALT	135 U/l (5–35)
ALP	160 U/l (30–150)
GGT	89
Albumin	33 g/l

Given the likeliest diagnosis, what therapy is he likely to require?

A Desferrioxamine

Urea	14.0 mmol/l
Creatinine	220 μmol/l
Bilirubin	45 μmol/l
ALT	135 U/l (5–35)
ALP	160 U/l (30–150)
GGT	89
Albumin	33 g/l

Given the likeliest diagnosis, what therapy is he likely to require?

A Desferrioxamine

B Trientine

C Venesection

D Genetic analysis

E N-acetylcystiene

B Trientine

A young man with basal ganglia signs and deranged liver function tests is likely to have Wilson's disease, also referred to as hepatolenticular degeneration. It is an autosomal recessive disorder of copper metabolism resulting in its accumulation in liver, kidneys, cornea and brain. Those affected become symptomatic in childhood and early adulthood. Chronic hepatitis may lead to cirrhosis and its complications. Neurological or psychiatric disease is the presenting feature in about 40% of cases. Many of these patients have Kayser–Fleischer rings, a physical sign pathognomonic of Wilson's disease. It is associated with renal tubular acidosis type II. Although serum copper and caeruloplasmin can be low, specificity is poor. The 24 h urinary copper excretion is rarely less than 100 μg and comparison can be made following penicillamine challenge. A liver biopsy can be diagnostic. Treatments include trientine and

liver biopsy can be diagnostic. Treatments include trientine and penicillamine, both of which act as copper or chelating agents. A genetic test has been difficult to develop due to a number of mutations in the gene.

A Desferrioxamine

Deferrioxamine is a medication which binds iron and aluminium. It is specifically used in iron overdose and haemachromatosis. The presence of dysarthria and ataxia make Wilson's disease more likely over haemachromatosis, as Wilson's is associated with hepatolenticular degeneration. Arthralgia, diabetes and bronze discoloration would make haemachromatosis more likely.

C Venesection

Venesection is a long-term treatment option for haemachromatosis, as excess iron is removed by serially bleeding the patient until iron stores

C Venesection

Venesection is a long-term treatment option for haemachromatosis, as excess iron is removed by serially bleeding the patient until iron stores are depleted.

D Genetic analysis

Whilst genetic analysis can be of use in diagnosing haemachromatosis and Wilson's disease, it would not help this patient in the first instance and would waste valuable time.

E N-acetylcystiene

This would be the correct treatment option for acute paracetamol overdose. Whilst liver failure in the context of depression can often be due to paracetamol overdose, it would not explain the neurological features.

7398

Rate this question:

A 46-year-old man is admitted to hospital following a first episode of syncope. It was witnessed by his wife, who said he suddenly went very pale and collapsed to the floor with loss of consciousness for a few seconds, and was immediately oriented on coming round.

The patient described progressively worsening exertional dyspnoea and fatigue over the last few months. He had some pains in the small joints of his hands for the last few years, but more recently these had become more severe and had spread to involve other joints. He also reluctantly admitted to difficulties maintaining an erection recently, but put this down to being stressed at work. He was a solicitor, had never smoked, and drank approximately 16 units of alcohol per week. He had no significant past medical history or family history and took no medications.

On examination, he was dyspnoeic on minimal exertion. His pulse was irregularly irregular and his blood pressure was 110/60 mmHg. He had a

irregularly irregular and his blood pressure was 110/60 mmHg. He had a raised jugular venous pressure, displaced apex beat, gallop rhythm and peripheral oedema. There were bilateral chest crepitations to the mid-zones. His abdomen was soft and not distended, with smooth, non-tender hepatomegaly but no palpable spleen. Neurological examination was normal. It was also noted that he had an absence of body hair, testicular atrophy and greyish skin pigmentation in his axillae and groins.

Investigations:

Hb	14 g/dl
WCC	8.0×10^9/l
PLT	250×10^9/l
Na^+	136 mmol/l
K^+	3.8 mmol/l
Creatinine	120 μmol/l
Urea	5.2 mmol/l
Ca^{2+}	2.20 mmol/l

Ca^{2+}	2.20 mmol/l
Bilirubin	14 µmol/l
ALP	90 u/l
AST	32 U/l
GGT	48 U/l
Albumin	38 g/l
Cholesterol	5.2 mmol/l
Glucose (random)	15.2 mmol/l
ECG	Atrial fibrillation, widespread T-wave inversion
CXR	Cardiomegaly, pulmonary oedema
Urinalysis	Glucose +++
Echocardiogram	Globally dilated and hypokinetic heart, no valvular lesions

Urinalysis	Glucose +++
Echocardiogram	Globally dilated and hypokinetic heart, no valvular lesions

Which further investigation would be the most useful in confirming the diagnosis?

A	Genetic analysis
B	Coronary angiography
C	Magnetic resonance imaging (MRI) of the pituitary fossa
D	Thyroid function tests
E	24 h ECG recording

A Genetic analysis

The combination of pituitary dysfunction, arthralgia, diabetes mellitus, hepatomegaly (and cirrhosis) with normal liver function tests and cardiomyopathy points strongly towards a diagnosis of hereditary haemochromatosis (also known as 'bronze diabetes'). This is an autosomal recessive disorder that is relatively common in Caucasians with approximately 1 in 300 people affected (homozygotes) and 10% of people carriers (heterozygotes). A genetic screen for the C282Y and H63D mutations exists. Haemochromatosis usually presents in men over the age of 40 years, and is much less common in women, presumably due to menstrual blood loss. It is due to excessive iron absorption from the small intestine and its subsequent deposition in cells of the liver, heart, pancreas and pituitary gland resulting in tissue damage and organ failure. The clinical features are as above. The abnormal skin pigmentation is due to melanin

gland resulting in tissue damage and organ failure. The clinical features are as above. The abnormal skin pigmentation is due to melanin deposition, and the arthritis due to accumulation of calcium pyrophosphate in joints. If cirrhosis develops, there is an increased risk of hepatocellular carcinoma. The disease has an excellent prognosis if recognised and treated before complications develop. Diagnosis can be made by an elevated serum iron concentration, reduced total iron-binding capacity (TIBC) and increased transferrin saturation, although gene testing for haemochromatosis mutations is now also available and is the preferred way to confirm the diagnosis. Liver biopsy may also be considered to demonstrate the extent of tissue damage and allow measurement of the hepatic iron concentration. Treatment with regular venesection or chelation therapy with desferrioxamine can result in a normal life expectancy.

B Coronary angiography

A 46-year-old Malaysian woman with hepatitis C-related liver cirrhosis is seen in clinic for her 6-monthly follow-up. Surveillance ultrasound shows two small focal lesions in the liver. Her alpha-fetoprotein (AFP) is 78 ng/ml (10–20). It was 30 ng/ml six months ago. Spiral computed tomography scan of the liver and thorax confirms two liver lesions, both measuring 2.5 cm × 2.5 cm and no pulmonary lesions.

What is the most definitive way to manage these two liver lesions?

A	Partial hepatic resection
B	Liver transplantation
C	Percutaneous ethanol injection of the lesions
D	Trans-catheter embolization of the lesions
E	Intravenous interferon

10:04
:tps://mypastest.pastest.com

A 46-year-old Malaysian woman with hepatitis C-related liver cirrhosis is seen in clinic for her 6-monthly follow-up. Surveillance ultrasound shows two small focal lesions in the liver. Her alpha-fetoprotein (AFP) is 78 ng/ml (10–20). It was 30 ng/ml six months ago. Spiral computed tomography scan of the liver and thorax confirms two liver lesions, both measuring 2.5 cm × 2.5 cm and no pulmonary lesions.

What is the most definitive way to manage these two liver lesions?

Your answer was incorrect

A Partial hepatic resection

B Liver transplantation

C Percutaneous ethanol

B Liver transplantation

The only proven potentially curative therapy for hepatocellular carcinoma (HCC) remains surgical, either hepatic resection or liver transplantation. Liver transplantation should be considered in any patient with cirrhosis and a single small HCC (<5 cm) or up to three lesions (<3 cm). Hepatic resection should be considered as a primary therapy in any patient with HCC and non-cirrhotic liver. A rising alpha-fetoprotein indicative of a hepatoma and biopsy is not always necessary to avoid seeding of tumour.

A Partial hepatic resection

This is not advised because of the potential to generate new areas of dysplasia within the remaining abnormal liver.

C Percutaneous ethanol injection of the lesions

C	Percutaneous ethanol injection of the lesions

Percutaneous ethanol injection has been shown to produce necrosis of small HCC and is best suited for peripheral lesions. Given the two lesions here are small, liver transplantation if possible is the preferred intervention.

D	Trans-catheter embolization of the lesions

Chemo-embolisation can produce tumour necrosis and has been shown to affect survival in highly selected patients with good liver reserve, although in this case it would only be considered if liver transplantation was not an option.

E	Intravenous interferon

Systemic therapies including interferon have a poor response rate in the treatment of hepatocellular carcinoma

A 67-year-old Asian man presents with a 5-week history of generalised abdominal pain, nausea, weight loss and fever. He has also been having night sweats for a few weeks. He has no history of diarrhoea or recent travel. His past history includes a pulmonary embolus 15 years ago and an inguinal hernia repair.

On examination, his temperature was 38.6 °C, his pulse is 96/min and blood pressure is 120/60 mmHg. He has right upper quadrant tenderness but no palpable organomegaly.

Investigations:

Bilirubin	9 μmol/l
ALP	91 U/l
ALT	56 U/l
Albumin	33 g/l
INR	1.1
Hb	13.4 g/dl
WCC	4.8×10^9/l

Albumin	33 g/l
INR	1.1
Hb	13.4 g/dl
WCC	4.8×10^9/l
Platelets	96×10^9/l
CRP	254 µg/l
Sodium	134 mmol/l
Potassium	4.7 mmol/l
Urea	13 mmol/l
Creatinine	140 µmol/l
LDH	4213 U/l (10–250)
Blood culture (x3)	Negative

OGD: multiple polyps in stomach and mild duodenitis. Biopsy taken but the sample is lost. CT abdomen: thickened small bowel and peritoneum around the terminal ileum.

LDH	4213 U/l (10–250)
Blood culture (x3)	Negative

OGD: multiple polyps in stomach and mild duodenitis. Biopsy taken but the sample is lost. CT abdomen: thickened small bowel and peritoneum around the terminal ileum.

Colonoscopy: no evidence of stricture.

What is the most likely diagnosis?

A	Burkitt's lymphoma
B	Tuberculosis
C	Crohn's disease
D	Yersinia enterocolitis
E	Gardner syndrome

A 67-year-old Asian man presents with a 5-week history of generalised abdominal pain, nausea, weight loss and fever. He has also been having night sweats for a few weeks. He has no history of diarrhoea or recent travel. His past history includes a pulmonary embolus 15 years ago and an inguinal hernia repair.

On examination, his temperature was 38.6 °C, his pulse is 96/min and blood pressure is 120/60 mmHg. He has right upper quadrant tenderness but no palpable organomegaly.

Investigations:

Bilirubin	9 μmol/l
ALP	91 U/l
ALT	56 U/l
Albumin	33 g/l
INR	1.1
Hb	13.4 g/dl
WCC	4.8×10^9/l

Urea	13 mmol/l
Creatinine	140 µmol/l
LDH	4213 U/l (10–250)
Blood culture (x3)	Negative

OGD: multiple polyps in stomach and mild duodenitis. Biopsy taken but the sample is lost. CT abdomen: thickened small bowel and peritoneum around the terminal ileum.

Colonoscopy: no evidence of stricture.

What is the most likely diagnosis?

Your answer was incorrect

A Burkitt's lymphoma

B Tuberculosis

C Crohn's disease

A Burkitt's lymphoma

Burkitt's lymphoma (BL) comprises about 2% of all lymphomas. Patients with BL present with rapidly growing tumour masses and often have evidence of spontaneous tumor lysis, with very high lactate and uric acid levels. The tumour doubling time is very short (e.g. 25 h), and so can present over a short history, such as in our patient. In the endemic (African) variety, it often starts as tumours of the jaw or other facial bones. In non-endemic form, the lymphoma usually has an abdominal presentation with massive disease in the abdomen, where it forms a large tumour mass involving the distal ileum, stomach, caecum and other organs. It can also spread to the brain and spinal fluid. Ninety per cent of patients are male, and the average age is about 30. Treatment involves short-duration combination chemotherapy ± rituximab. Two-year survival rates are 80-90%.

B Tuberculosis

In an Asian with night sweats, fever and weight loss, tuberculosis should always be considered and could present similarly to our case. However, the short history, multiple lesions and the grossly elevated lactate dehydrogenase (LDH) levels are more consistent with a diagnosis of lymphoma.

C Crohn's disease

Thickening of the terminal ileum also occurs in Crohn's disease; however, the absence of chronic diarrhoea and the finding of very high lactate make Crohn's a less likely diagnosis in this case.

D Yersinia enterocolitis

Yersinia can cause abdominal pain, fever and a diffuse ulcerating ileitis. However, there is usually a history of diarrhoea, which is absent in this case.

A 34-year-old nurse has had recurrent admissions for intermittent upper abdominal pain, especially after eating fatty food, for the last four years. She has been extensively investigated with an upper gastrointestinal endoscopy and an ultrasound scan of the biliary tree, both of which are normal. She underwent a magnetic resonance cholangiopancreatogram (MRCP), which was normal, and is currently awaiting an endoscopic retrograde cholangiopancreatogram (ERCP). She is a teetotaller. She has a history of depression and takes the oral contraceptive pill.

She has normal serum immunoglobulins levels and her liver function tests are as below:

Bilirubin	14 μmol/l
ALT	40 U/l (5-35)
ALP	156 U/l (30–150)
Amylase	100 U/l (60-180)

What is the most likely diagnosis?

immunoglobulins levels and her liver function tests are as below:

Bilirubin	14 μmol/l
ALT	40 U/l (5-35)
ALP	156 U/l (30–150)
Amylase	100 U/l (60-180)

What is the most likely diagnosis?

A	Recurrent pancreatitis
B	Acute acalculous cholecystitis
C	Primary biliary cirrhosis (PBC)
D	Sphincter of Oddi dysmotility
E	Munchausen syndrome

A 34-year-old nurse has had recurrent admissions for intermittent upper abdominal pain, especially after eating fatty food, for the last four years. She has been extensively investigated with an upper gastrointestinal endoscopy and an ultrasound scan of the biliary tree, both of which are normal. She underwent a magnetic resonance cholangiopancreatogram (MRCP), which was normal, and is currently awaiting an endoscopic retrograde cholangiopancreatogram (ERCP). She is a teetotaller. She has a history of depression and takes the oral contraceptive pill.

She has normal serum immunoglobulins levels and her liver function tests are as below:

Bilirubin	14 μmol/l
ALT	40 U/l (5-35)
ALP	156 U/l (30–150)
Amylase	100 U/l (60-180)

D Sphincter of Oddi dysmotility

Sphincter of Oddi dysmotility (SOD) can cause back-up of bile and pancreatic juices, which can result in biliary colic. More prolonged obstruction may result in bile leaking back into the bloodstream, which can cause transient abnormal liver biochemistry. SOD most commonly occurs in young females, especially those who have previously undergone cholecystectomy. At endoscopic retrograde cholangiopancreatogram (ERCP), delayed drainage of contrast is seen and SOD manometry can confirm the diagnosis. There is usually a high resting pressure with marked phasic contractions and often some retrograde peristalsis. Endoscopic sphincterotomy or balloon sphincteroplasty often relieves this condition.

E Munchausen syndrome

Although there is a history of depression, Munchausen should only

Although there is a history of depression, Munchausen should only realistically be considered once other potential organic diagnoses have been ruled out.

A Recurrent pancreatitis

The rather benign presentation without a formal diagnosis of pancreatitis makes this a very unlikely diagnosis. The amylase checked between attacks is not, however, predictive of future episodes of pancreatitis.

B Acute acalculous cholecystitis

This is very unlikely given an unremarkable ultrasound and MRCP. At least some thickening of the gall bladder wall consistent with chronic inflammation would be expected.

C Primary biliary cirrhosis (PBC)

The primary presentation of primary biliary cirrhosis is with progressive

Calculator

Normal Values

A 51-year-old Chinese man presents to you with hepatitis B. He is teetotal.

Investigations:

Hepatitis B surface Antigen	+
Hepatitis B e Antigen	-
HBV DNA level	500,000 copies/ml
Alanine aminotransferase (ALT)	96 U/l (5–35)
Liver biopsy	Moderate hepatitis with bridging fibrosis

Which of the following is the most appropriate management?

A Close monitoring of liver function test

B Repeat biopsy in 2 years

C Start pegylated interferon

D Start pegylated interferon and ribavirin

E Start lamivudine

MRCP Part 1's screen

C Start pegylated interferon

The patient has eAg-negative chronic hepatitis B. The eAg negativity indicates there is not active viral replication, but the raised ALT and high viral tires indicate chronic active infection, which is confirmed on biopsy and therefore necessitates treatment. NICE guidelines now recommend treatment in patients who meet the following criteria:

- Adults >30 years with HBV DNA >2000 IU/ml and abnormal ALT (>30 IU/ml in males and >19 IU/ml in females) on 2 consecutive tests, 3 months apart.
- Adults <30 years with HBV DNA >2000 IU/ml and abnormal ALT (>30 IU/ml in males and >19 IU/ml in females) on 2 consecutive tests, 3 months apart if there is evidence of necro-inflammation or fibrosis on liver biopsy or transient elastography score >6 kPa.
- Adults who have HBV DNA >20,000 IU/ml and abnormal ALT (>30 IU/ml in males and >19 IU/ml in females) on 2 consecutive tests conducted 3 months apart regardless of age or the extent of liver disease.
- Patients without a liver biopsy to adults with a transient elastography score >11 kPa.

NICE recommends first-line treatment with Peginterferon alfa-2a in patients with compensated liver disease for 48 weeks. Entecavir and tenofovir are offered as second-line treatments where PEG-interferon therapy has failed or is not tolerated.

E Start lamivudine

MRCP Part 1's screen

E Start lamivudine

Lamivudine is only indicated as an adjunct in patients who are Hepatitis B e-Antigen positive and compensated liver disease and despite 96 weeks of tenofevir still have detectable Hepatitis B DNA or in patients who are likely to be immunocompromised for 6 months with Hepatitis B DNA < 2000 IU/ml. See NICE guidance for further details.

A Close monitoring of liver function test

The patient has chronic hepatitis B with histological evidence of early cirrhosis, making treatment an imperative to avoid progression to further fibrosis and to reduce hepatocellular carcinoma risk.

B Repeat biopsy in 2 years

Having established that the patient has early cirrhosis, it is clear that he requires treatment. Indications for a further biopsy would be in the case of suspected HCC or a failure to respond to treatment and thus to exclude an alternative diagnosis. Transient elastography (fibroscan) as an assessment of liver stiffness and surrogate marker of cirrhosis has reduced the number of biopsies performed prior to commencing antivirals.

D Start pegylated interferon and ribavirin

This is offered as first-line therapy for patients with hepatitis C. However, NICE has recently

A 40-year-old business executive presents with weight loss of 4 kg over 3 months, and diarrhoea with bulky, pale stools. He has previously been well other than occasional bouts of indigestion that have forced him to stay in bed for a couple of days at a time.

He takes no medication; he smokes the occasional cigar and drinks 3–4 double whiskies per day as well as the occasional bottle of champagne.

Investigations:

Hb	10.0 g/dl (13.0-18.0)
WCC	6.0×10^9/l (4.0-11.0)
PLT	300×10^9/l (150-400
MCV	110 fl (80-96)
Urea and electrolytes	Normal
ALT	40 U/l (5-35)
ALP	120 U/l
GGT	200 U/l (< 50)
Bilirubin	27 µmol/l
B_{12}	120 ng/l (160-760)
PT	14 s (11.5–15.5)

B_{12}	120 ng/l (100-700)
PT	14 s (11.5–15.5)
Serum folate	1.5 µg/l (2.0-11.0)
Faecal elastase	100 µg/g (> 200)

Which is the best investigation to help you make the diagnosis?

A CT abdomen

B Endoscopic retrograde cholangiopancreatography (ERCP)

C Abdominal ultrasound

D Magnetic resonance cholangiopancreatography (MRCP)

E Colonoscopy

71087

A CT abdomen

Chronic pancreatitis has an incidence of 8.2 new cases/100, 000/year, with a prevalence of 26.4 cases/100 000 population in the UK; 10–40% of cases are idiopathic. Alcohol (60–90%) and cystic fibrosis transmembrane conductance regulator (CFTR) mutations are the most frequent causes in adults and children, respectively. Hypertriglyceridaemia, autoimmune pancreatitis (e.g. associated with primary sclerosing cholangitis) and surgery are also related causes. Hereditary pancreatitis (autosomal dominant) and pancreas divisum (congenital pancreatic abnormality of fusion), hyperparathyroidism and uraemia are rare causes. Gallstones (more commonly associated with recurrent acute pancreatitis) may be a contributing cause in ~20–25% of cases.
Faecal elastase is a sensitive marker of pancreatic insufficiency and, given the history of excessive alcohol intake and episodic abdominal pain, a diagnosis of chronic pancreatitis is likely. CT abdomen would be the most sensitive investigation for detecting chronic pancreatitis, with the typical appearance of a granular, calcified pancreas seen on imaging. Therefore, Option A is the best answer. An abdominal CT would also help to rule out more sinister causes for this gentleman's weight loss, such as malignancy.

B Endoscopic retrograde cholangiopancreatography (ERCP)

This is no longer used as a diagnostic test and carries a 5% risk of pancreatitis.

C Abdominal ultrasound

MRCP Part 1's screen

A 25-year-old postman is admitted to hospital with severe central abdominal pain. He admits to several previous episodes. He has never visited a doctor before and takes no prescription medication. He does not drink in the week but often drinks 10–12 double whiskies on a Friday and Saturday night. He does not smoke but takes occasional ecstasy tablets.

On examination he is in pain, sweaty and pale with a pulse rate of 110 beats/min. Abdominal examination reveals peri-umbilical tenderness with guarding but no rebound, and scanty bowel sounds.

Investigations:

Hb	14.0 g/dl
WCC	16.0×10^9/l
PLT	450×10^9/l
Na^+	140mmol/l
K^+	5.0 mmol/l
Creatinine	140 µmol/l
Urea	9.0 mmol/l
Glucose	8.0 mmol/l
CRP	160 mg/l

Arterial blood gases (on air):

pa(O_2)	8.0 kPa
pa(CO_2)	4.5 kPa
pH	7.35

What is the next step in this patient's management?

Your answer was incorrect

A Intravenous antibiotics

B Intravenous fluids

C Total parenteral nutrition (TPN)

D Nasogastric feeding

E Keep nil by mouth

Explanation

B Intravenous fluids

The history and examination findings are classical for acute ethanol-associated pancreatitis. This is confirmed biochemically by a raised amylase, although serum lipase is a better marker if available.

The elevated C-reactive protein, lactate dehydrogenase and blood glucose, along with the relative hypoxia, are all poor prognostic features suggesting a severe attack. Intravenous fluids is the correct answer as aggressive hydration is required in these patients particular in the first 24-48 h of admission. The American College of Gastroenterology guidelines on pancreatitis suggest 250-500 ml/h of isotonic crystalloid solution in all patients, unless cardiovascular and/or renal comorbidites exist

D Nasogastric feeding

Nasogastric feeding may be suitable if the patient is vomiting and not tolerating oral intake, but this would not be the next step.

A Intravenous antibiotics

The guidelines provided by the British Society of Gastroenterology (BSG) suggest that there is no good evidence to support the use of antibiotics in this setting as studies have been contradictory and antibiotics are unlikely to be affect outcome in patients not exhibiting extensive pancreatic necrosis.

MRCP Part 1's screen

extensive pancreatic necrosis.

C Total parenteral nutrition (TPN)

Nutrition should always favour the enteral route where possible, and therefore total parenteral nutrition is incorrect.

E Keep nil by mouth

The BSG guidelines do recommend feeding in acute pancreatitis, so keeping the patient nil by mouth is incorrect; besides, there is no indication that this patient requires any form of surgery as the next step in their management.

6443

Rate this question:

Next Question

Previous Question Tag Question Feedback End Session

A 45-year-old Chinese man is admitted to hospital with abdominal swelling. During his admission, his liver function tests are discovered to be abnormal and he has an abdominal ultrasound scan that shows ascites, a small irregular liver and a large spleen.

A thorough history reveals that his mother had hepatitis B (HB) and died of liver cancer.

Investigations:

Albumin	30 g/l (37–49)
Bilirubin	35 µmol/l (1–22)
HBcAb	+
HBeAg	-
HBSAg	+
HBV DNA	500 000 IU
Liver transaminase (AST)	152 U/l (1–31)
Plasma thromboplastin (PT)	17 s (11.5–15.5)

Calculator

Normal Values

What immediate treatment is indicated for this man's hepatitis B?

A Not treatment indicated

MRCP Part 1's screen

HBSAg	+
HBV DNA	500 000 IU
Liver transaminase (AST)	152 U/l (1–31)
Plasma thromboplastin (PT)	17 s (11.5–15.5)

What immediate treatment is indicated for this man's hepatitis B?

A No treatment is indicated

B Interferon

C Interferon and ribavirin

D Tenofovir

E Liver transplantation

6361

D Tenofovir

This gentleman has chronic hepatitis B, most probably acquired by vertical transmission. The absence of E antigen in the presence of HBV virus in the blood shows that he has a pre-core mutant form of the virus. The irregular, shrunken liver and enlarged spleen suggest the development of cirrhosis.

The appearance of ascites in a patient with cirrhosis indicates decompensation of their liver disease. In this situation active hepatitis B (i.e. any detectable DNA in blood) requires treatment by viral suppression.

Tenofovir is an effective anti-viral agent for suppression of hepatitis B virus, and whilst it is second line to interferon in the NICE guidance for compensated liver disease, in this case with hepatic decompensation, it is a reasonable first choice.

A No treatment is indicated

This patient has active hepatitis B, as evidenced by his elevated viral DNA, and therefore requires direct treatment.

B Interferon

Interferon is indicated for the treatment of chronic hepatitis B in E antigen-positive patients, but is contraindicated in patients with decompensated liver disease. Tenofovir and entecavir are [illegible] interferon treatment.

MRCP Part 1's screen

466-910-629

Interferon is indicated for the treatment of chronic hepatitis B in E antigen-positive patients, but is contraindicated in patients with decompensated liver disease. Tenofovir and entecavir are alternatives to interferon treatment.

C Interferon and ribavirin

Ribavirin is ineffective against HBV and is only used in combination with interferon in the treatment of hepatitis C.

E Liver transplantation

Liver transplantation is effective in end-stage liver disease caused by hepatitis B, but adequate viral suppression is the initial treatment of choice pending assessment of suitability for transplantation.

6361

Rate this question:

A 45-year-old woman with known rheumatoid arthritis complains of generalised pruritis.

On examination, she is mildly jaundiced and has periorbital xanthelasmata. Abdominal palpation reveals hepatomegaly 2 cm below the right costal margin. She has no lymphadenopathy.

Calculator

Normal Values

Investigations:

Haemoglobin (Hb)	112 g/l
Mean corpuscular volume (MCV)	89 fl
White cell count (WCC)	4.6×10^9/l
Platelets	310×10^9/l
Erythrocyte sedimentation rate (ESR)	34 mm/h
Albumin	30 g/l
Bilirubin	30 µmol/l
Alkaline phosphatase (ALP)	260 U/l

Which of the following tests would be most useful?

A. M_2 subtype anti-mitochondrial antibody

MRCP Part 1's screen

406-910-629

Erythrocyte sedimentation rate (ESR)	34 mm/h
Albumin	30 g/l
Bilirubin	30 µmol/l
Alkaline phosphatase (ALP)	260 U/l

Which of the following tests would be most useful?

A	M_2 subtype anti-mitochondrial antibody
B	Anti-smooth muscle antibody
C	Hepatitis serology
D	M_5 subtype anti-mitochondrial antibody
E	Serum electrophoresis

Explanation

A M_2 subtype anti-mitochondrial antibody

Primary biliary cirrhosis is a slowly progressive inflammation and destruction of the intrahepatic ducts leading to eventual cirrhosis. The cause is unknown but it is thought to be an autoimmune disease, and there is a strong association with other autoimmune conditions such as rheumatoid arthritis, Sjögren syndrome and CREST syndrome. Most patients are diagnosed between the ages of 40 and 70 years, and 90% of patients are female.

B Anti-smooth muscle antibody

Autoimmune hepatitis is a chronic hepatitis characterised by immunologic and auto-immunologic features, generally including the presence of circulating auto-antibodies and a high total serum gamma globulin, usually confined to the IgG fraction. The main circulating auto-antibodies, although not specific for the disease, are antinuclear antibodies (ANA) and anti-smooth muscle antibodies (ASMA) in type 1 disease and, in type 2 autoimmune hepatitis, anti-liver-kidney microsome-1 antibodies (ALKM-1) and anti-liver cytosol antibody-1 (ALC-1). In this case, it is primary biliary cirrhosis that we are wanting to diagnose so anti-smooth muscle antibody is not particularly useful.

C Hepatitis serology

Hepatitis serology is negative in primary biliary cirrhosis and there is no association.

MRCP Part 1's screen

Hepatitis serology is negative in primary biliary cirrhosis and there is no association.

D M_5 subtype anti-mitochondrial antibody

Anti-mitochondrial antibodies are found in over 90% of patients, the M_2 subtype being specific. Therefore M_5 is not the most specific for primary biliary cirrhosis.

E Serum electrophoresis

Serum electrophoresis is abnormal in disorders such as multiple myeloma, but not in primary biliary cirrhosis.

9515

Rate this question:

Next Question

Previous Question Tag Question Feedback End Session

MRCP Part 1's screen

CT abdomen	Normal
Urinary porphobilinogen	300 µmol//dl (0–18)
Faecal porphyrins	Normal (co-proporphyrins and protoporphyrins)
Plasma porphyrins	Markedly increased

What is the most likely diagnosis?

A Acute intermittent porphyria

B Variegate porphyria

C Hereditary co-proporphyria

D Porphyria cutanea tarda

E Lead poisoning

71088

Submit

A 22-year-old woman is admitted to hospital with severe abdominal pain, nausea and vomiting. She undergoes emergency laparotomy, which is normal.

On further questioning, she reveals a family history of an aunt who has a light-sensitive rash and a diagnosis of porphyria.

On examination, she is hypertensive, with generalised rebound tenderness. She responds to analgesia and once she is stabilised a porphyrin screen is sent.

Investigations:

Sodium	125 mmol/l
Potassium	4.0 mmol/l
Glucose	5.0 mmol/l
FBC	Normal
CT abdomen	Normal
Urinary porphobilinogen	300 µmol//dl (0–18)
Faecal porphyrins	Normal (co-proporphyrins and protoporphyrins)
Plasma porphyrins	Markedly increased

What is the most likely diagnosis?

Difficulty: Difficult

Peer Responses %

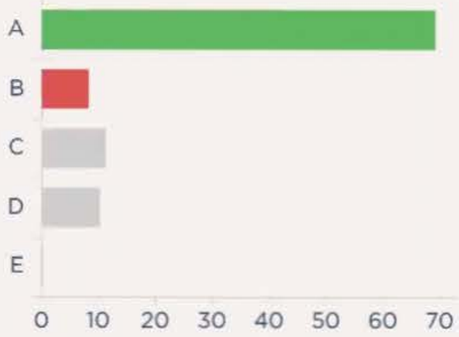

Session Progress

Responses Correct:	4
Responses Incorrect:	7
Responses Total:	11
Responses - % Correct:	36%

MRCP Part 1's screen

A Acute intermittent porphyria

Attacks of acute porphyria are often mistaken for surgical abdomens. Family histories may be misleading, as porphyria may be misdiagnosed or may not be manifest in other family members. Acute intermittent porphyria is correct as it fits the clinical symptoms of gastrointestinal upset with abdominal pain and cramp with nausea and vomiting. Urinary porphyrins are raised in all three acute porphyrias (acute intermittent porphyria, hereditary co-proporpyria and variegate porphyria), so these can often be impossible to distinguish clinically. Faecal porphyrins can be useful to differentiate the conditions, because they are elevated in coproporphyria and variegate porphyria.

B Variegate porphyria

Variegate porphyria is an autosomal dominant disease caused by a mutation of protoporphyrinogen oxide. It is characterised by symptoms of neurovisceral crises similar to those in a patient with AIP, but is also associated with a classic photosensitive skin disorder which this patient did not have.

C Hereditary co-proporphyria

Similarly, hereditary co-proporphyria is also incorrect as it is associated with a blistering skin rash, particularly in sun-exposed areas.

D Porphyria cutanea tarda

MRCP Part 1's screen

A 34-year-old man undergoes colonoscopy for weight loss and episodic diarrhoea. He has no past medical history but is unable to give a family history as he was adopted at birth.

Examination reveals multiple lesions within the oral cavity which have previously been diagnosed as oral papillomas by a dermatologist, and a diffuse swelling in the anterior neck.

At colonoscopy it is noted that he has multiple small polyps scattered throughout the colon, and several of these are removed for routine histological analysis.

Investigations:

Bilirubin	10 µmol/l (1–22)
AST	16 u/l (1–31)
ALT	21 u/l (5–35)
Albumin	40 g/l (37–49)
Haemoglobin (Hb)	11.5 g//dl
White cell count (WCC)	10×10^9/l
Platelets	300×10^9/l
Thyroid-stimulating hormone (TSH)	0.2 mu/l
Free thyroxine	30 pmol/l

MRCP Part 1's screen

Investigations:

Bilirubin	10 µmol/l (1–22)
AST	16 u/l (1–31)
ALT	21 u/l (5–35)
Albumin	40 g/l (37–49)
Haemoglobin (Hb)	11.5 g//dl
White cell count (WCC)	10×10^9/l
Platelets	300×10^9/l
Thyroid-stimulating hormone (TSH)	0.2 mu/l
Free thyroxine	30 pmol/l

Histology of colonic polyp:

Hamartomatous polyp with dilated mucus-filled glands and plasma and lymphocytic infiltration of the lamina propria.

What is the most likely diagnosis in this case?

A	Familial adenomatous polyposis
B	Familial juvenile polyposis

Free thyroxine	30 pmol/l

Histology of colonic polyp:

Hamartomatous polyp with dilated mucus-filled glands and plasma and lymphocytic infiltration of the lamina propria.

What is the most likely diagnosis in this case?

A Familial adenomatous polyposis

B Familial juvenile polyposis

C Peutz–Jeghers syndrome

D Multiple endocrine neoplasia syndrome type 2 B (MEN2B)

E Cowden syndrome

6440

Submit

MRCP Part 1's screen

E Cowden syndrome

The finding of multiple hamartomatous polyps in the gastrointestinal (GI) tract suggests the presence of one of the hamartomatous polyposis syndromes. These include familial juvenile polyposis, Cowden syndrome, Peutz–Jeghers syndrome, neurofibromatosis type one and multiple endocrine neoplasia syndrome type 2, all of which can give rise to hamartomatous polyps in the GI tract. These syndromes are distinct from the more common adenomatous syndromes such as HNPCC (hereditary non-polyposis colon cancer) and familial adenomatous polyposis.

Cowden syndrome is an inherited condition resulting from a defect in the PTEN tumour suppressor gene. Hamartomatous polyps of the GI tract are often the first manifestation, along with characteristic mucocutaneous lesions such as oral mucosal papillomas, palmoplantar keratoses and trichilemmomas (benign tumours of hair follicles). It is important to diagnose the syndrome early because of the high risk of malignancy, particularly of the breast and thyroid. Thyroid dysfunction is common even in the absence of cancer.

A Familial adenomatous polyposis

Familial adenomatosis polyposis (FAP) is associated with hundreds to thousands of colonic adenomas. This can cause rectal bleeding and anaemia, and can progress to malignancy. Serial monitoring with colonoscopy is needed.

B Familial juvenile polyposis

MRCP Part 1's screen

Familial juvenile polyposis also results in multiple polyps in the colon identical to those found

406-910-629

A 34-year-old man undergoes colonoscopy for weight loss and episodic diarrhoea. He has no past medical history but is unable to give a family history as he was adopted at birth.

Examination reveals multiple lesions within the oral cavity which have previously been diagnosed as oral papillomas by a dermatologist, and a diffuse swelling in the anterior neck.

At colonoscopy it is noted that he has multiple small polyps scattered throughout the colon, and several of these are removed for routine histological analysis.

Investigations:

Bilirubin	10 µmol/l (1–22)
AST	16 u/l (1–31)
ALT	21 u/l (5–35)
Albumin	40 g/l (37–49)
Haemoglobin (Hb)	11.5 g//dl
White cell count (WCC)	10×10^9/l
Platelets	300×10^9/l
Thyroid-stimulating hormone (TSH)	0.2 mu/l
Free thyroxine	30 pmol/l

Difficulty: Difficult

Peer Responses %

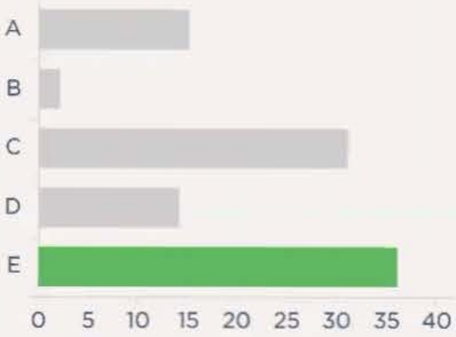

Session Progress

Responses Correct:	5
Responses Incorrect:	7
Responses Total:	12
Responses - % Correct:	42%

Audio Video Share Participants More

E Cowden syndrome

The finding of multiple hamartomatous polyps in the gastrointestinal (GI) tract suggests the presence of one of the hamartomatous polyposis syndromes. These include familial juvenile polyposis, Cowden syndrome, Peutz–Jeghers syndrome, neurofibromatosis type one and multiple endocrine neoplasia syndrome type 2, all of which can give rise to hamartomatous polyps in the GI tract. These syndromes are distinct from the more common adenomatous syndromes such as HNPCC (hereditary non-polyposis colon cancer) and familial adenomatous polyposis.

Cowden syndrome is an inherited condition resulting from a defect in the PTEN tumour suppressor gene. Hamartomatous polyps of the GI tract are often the first manifestation, along with characteristic mucocutaneous lesions such as oral mucosal papillomas, palmoplantar keratoses and trichilemmomas (benign tumours of hair follicles). It is important to diagnose the syndrome early because of the high risk of malignancy, particularly of the breast and thyroid. Thyroid dysfunction is common even in the absence of cancer.

A Familial adenomatous polyposis

Familial adenomatosis polyposis (FAP) is associated with hundreds to thousands of colonic adenomas. This can cause rectal bleeding and anaemia, and can progress to malignancy. Serial monitoring with colonoscopy is needed.

B Familial juvenile polyposis

MRCP Part 1's screen

Familial juvenile polyposis also results in multiple polyps in the colon identical to those found

A Familial adenomatous polyposis

Familial adenomatosis polyposis (FAP) is associated with hundreds to thousands of colonic adenomas. This can cause rectal bleeding and anaemia, and can progress to malignancy. Serial monitoring with colonoscopy is needed.

B Familial juvenile polyposis

Familial juvenile polyposis also results in multiple polyps in the colon identical to those found in Cowden syndrome, but the associated oral lesions are absent.

C Peutz-Jeghers syndrome

Peutz-Jeghers syndrome results in polyps with a classical histological appearance of smooth muscle 'arborisation', and it is unusual to find cases in young adults without the characteristic peristomal hyperpigmentation.

D Multiple endocrine neoplasia syndrome type 2 B (MEN2B)

Intestinal polyps found in MEN2B are readily identified histologically as ganglioneuromas, and are usually asymptomatic. MEN2B is associated with medullary cell thyroid cancer.

6440

Rate this question:

A 21-year-old man comes to the Accident and Emergency Department with right upper quadrant pain, nausea and fever. He has recently returned from his gap year in Argentina, where he worked on a cattle ranch. He has always been fit and well, smokes 20 cigarettes/day and drinks the occasional pint in the evening.

On examination, he looks well but has a temperature of 38.1 ºC. He is tender over the right upper quadrant. Ultrasound shows a unilocular, unechoic, 6 cm cystic lesion with double-line sign in the right lobe of his liver. Serology for *Echinoccus granulosus* returns as positive (1:160), and you diagnose the patient with hydatid liver disease.

What is the best management of this patient?

Calculator

Normal Values

A	Refer for consideration of liver transplant
B	Surgical resection alone
C	Intravenous mebendazole
D	Treat the patient symptomatically for fever
E	Percutaneous aspiration ('PAIR' technique) with adjunctive albendazole

MRCP Part 1's screen

cigarettes/day and drinks the occasional pint in the evening.

On examination, he looks well but has a temperature of 38.1 ºC. He is tender over the right upper quadrant. Ultrasound shows a unilocular, unechoic, 6 cm cystic lesion with double-line sign in the right lobe of his liver. Serology for *Echinoccus granulosus* returns as positive (1:160), and you diagnose the patient with hydatid liver disease.

What is the best management of this patient?

Your answer was incorrect

A	Refer for consideration of liver transplant
B	Surgical resection alone
C	Intravenous mebendazole
D	Treat the patient symptomatically for fever
E	Percutaneous aspiration ('PAIR' technique) with adjunctive albendazole

Peer Responses %

Session Progress

Responses Correct:	5
Responses Incorrect:	8
Responses Total:	13
Responses - % Correct:	38%

Explanation

MRCP Part 1's screen

E Percutaneous aspiration ('PAIR' technique) with adjunctive albendazole

Hydatid liver disease is caused by the tapeworm *Echinococcus granulosis*, and is uncommon in Europe and the United States but common in certain regions such as the Middle East and South America, and in sheep-rearing areas such as Australia. Transmission is via the faeco-oral route from food contaminated with infected dog faeces. The eggs penetrate the intestinal wall and move to the liver through the portal system. The liver acts as a filter and is the most common site of disease (~65% of cases). Most individuals are asymptomatic. Pressure from the cyst may lead to hepatomegaly and right upper quadrant pain. Cysts can also cause obstructive jaundice, cholangitis and pyrexia of unknown origin. Diagnosis is with Echinococcus ELISA, ultrasound, and CT showing characteristic daughter cysts.

Management options include observation, drug therapy with albendazole, percutaneous aspiration via the 'PAIR' (puncture, aspiration, injection, re-aspiration) technique, surgical resection or a combination of approaches. For a single cyst of >5 cm, and with the ultrasonographic features described in this case, the WHO recommendation for treatment is: percutaneous aspiration using the 'PAIR' procedure, with adjunctive albendazole (4-30 days preoperatively, and 30 days postprocedure). For the WHO ultrasound-based classification of cystic echinococcosis and treatment stratified by cyst stage, see: International classification of ultrasound images in cystic echinococcosis for application in clinical and field epidemiological settings (2003). *Acta Trop* 85: 253–261. pmid:12606104.

C Intravenous mebendazole

Mebendazole is commonly used in the treatment of hydatid cysts but this has been

MRCP Part 1's screen

C Intravenous mebendazole

Mebendazole was formerly used in the treatment of hydatid cysts, but this has been surpassed by albendazole, which has demonstrated superior efficacy and is administered orally. Mebendazole is used only in the absence of albendazole.

A Refer for consideration of liver transplant

The finding of a single hydatid cyst is not an indication for referral for liver transplant, and there are medical, percutaneous and surgical therapies available for treatment.

B Surgical resection alone

Surgery is the treatment of choice for management of complicated cysts or cysts with many daughter cysts that are not suitable for percutaneous management. However, surgery is rarely carried out without adjunctive drug therapy as there is a risk of secondary echinococcosis from seeding of proto-scolices in the abdominal cavity in the event of fluid spillage. Albendazole is generally administered beginning one week prior to surgery and is continued for at least four weeks postoperatively.

D Treat the patient symptomatically for fever

Hydatid cysts are staged on the basis of the WHO ultrasound-based cyst classification into active, transitional and 'inactive'. The ultrasonographic appearance of the cyst in this

MRCP Part 1's screen

A 39-year-old businesswoman underwent a routine medical for health insurance purposes. She is normally fit and well and denies any medical problems. She is a non-smoker and consumes about 10–15 glasses of wine per week at work functions. She is on no medications.

On examination, her blood pressure is 122/82 mmHg, pulse is 71/min and regular and BMI is 27. Routine laboratory tests showed some abnormalities of her liver function, with raised aspartate aminotransferase (AST) and alanine aminotransferase (ALT), hypertriglyceridaemia and hypercholesterolaemia. Her fasting glucose is 6.0 mmol/l.

Which of the following is the most important intervention?

A	Alcohol cessation
B	Metformin
C	Pioglitazone

no medications.

On examination, her blood pressure is 122/82 mmHg, pulse is 71/min and regular and BMI is 27. Routine laboratory tests showed some abnormalities of her liver function, with raised aspartate aminotransferase (AST) and alanine aminotransferase (ALT), hypertriglyceridaemia and hypercholesterolaemia. Her fasting glucose is 6.0 mmol/l.

Which of the following is the most important intervention?

A	Alcohol cessation
B	Metformin
C	Pioglitazone
D	Simvastatin
E	Weight loss

A Alcohol cessation

Alcoholic fatty liver (simple steatosis) is an early and reversible consequence of excessive alcohol consumption and, with complete abstinence, the histological changes seen in the liver can return to normal within 2–4 weeks. Lower doses of alcohol are required to develop more severe alcoholic liver disease in women than in men – this condition also develops more quickly in the female sex. Simple steatosis is usually asymptomatic, but a thorough history is required to determine the role of alcohol in the abnormal biochemical profile of the patient. Special emphasis should be placed on determining the amount of alcohol consumed as well as the patient's occupation, since some occupations lend themselves to 'silent' drinking more than others. Liver function tests are deranged with an increase in the aminotransferase levels, but although gamma glutamyl transpeptidase (GGT) may be elevated in relation to alcohol use, it is neither specific nor sensitive.

may be elevated in relation to alcohol use, it is neither specific nor sensitive. Abstinence and an adequate diet are the mainstays of treatment in simple steatosis.

E Weight loss

Weight loss is the intervention of choice for non-alcoholic steatic hepatitis (NASH); in this case, alcohol cessation would have the greatest impact on outcomes.

B Metformin

Metformin has a very limited effect on steatosis, although it can delay any worsening in glucose tolerance. As such, it is not the optimal choice here.

C Pioglitazone

Pioglitazone does reduce hepatic fat in patients with non-alcoholic steatohepatitis, but it has not been shown to affect progression of the

A 27-year-old office worker presents with a 3-year history of epigastric pain, especially 30 min after eating. This is associated with nausea and belching. She also describes constipation with occasional explosive diarrhoea. The stools are normally hard with mucus and she needs to strain with every motion.

Abdominal pain is relieved after defecation but abdominal bloating persists. She wakes up an hour earlier each morning to finish her breakfast in order to prevent vomiting. She has missed work on a few occasions and feels that her weight has fluctuated.

Past medical history includes scarlet fever. She is not on any regular medications except intermittent laxatives over the counter. Abdominal examination is normal. Rectal examination reveals an anal fissure.

Investigation results:

Haemoglobin	13.1 g/dl
White blood count	6.0×10^9/l

White blood count	6.0 × 10^9/l
Platelets	180 × 10^9/l
Mean cell volume	87 fL
International normalised ratio	1.0
ESR	1.1 mm/1st hour
Na^+	136 mmol/l
K^+	3.9 mmol/l
Urea	3.7 mmol/l
Creatinine	70 µmol/l
Albumin	39 g/L
Liver function test	normal
Anti-endomysial antibody	negative
Thyroid function test	normal

Thyroid function test	normal
Gastroscopy	normal
Flexible sigmoidoscopy and biopsy	normal
Abdominal and pelvic ultrasound scan	normal

What is the most likely diagnosis to account for her symptoms?

A	Overlap irritable bowel syndrome and functional dyspepsia
B	Diarrhoea pre-dominant irritable bowel syndrome
C	Sphincter of Oddi dysfunction
D	Malabsorption sydrome and non-ulcer dyspepsia
E	Globus hystericus

A 29-year-old man from Uzbekistan is seen in the Accident and Emergency Department with a 4-day history of abdominal pain, which is now generalised and severe. It had come on gradually over the last few days and he also noticed his abdomen was swelling up.

Of note, in the last few months he had developed some oral ulceration for which his GP had given him some local anaesthetic preparation, which seemed to help, and uveitis for which his GP prescribed some eye drops. His father died suddenly of a myocardial infarction when he was 39. He smokes 20 cigarettes/day and drinks half a bottle of wine every evening. He also hesitantly tells you that he had a lesion on his scrotum.

On examination, he was jaundiced and had a distended abdomen, which was positive for shifting dullness. He had a 10 cm tender liver edge below the right costal margin and a 4 cm spleen below the left costal margin. He also had several sterile pustules on both arms,

which he said was where he had pricked himself on thorns a few days previously. He has a deep ulcer on his scrotum (0.5 x 1.2 cm).

Investigations:

Alanine aminotransferase (ALT)	97 U/l
Alkaline phosphatase (ALP)	154 U/l
γ-glutamyl transferase (GGT)	172 U/l
Bilirubin	41 μmol/l
Albumin	36 g/l
Ascitic fluid	Protein 26 g/l
White blood cells (WBC)	325/μl
Serum ascites albumin gradient	1.1 g/dl
Haemoglobin (Hb)	123 g/l
White blood count (WBC)	10.1×10^9/l

White blood count (WBC)	10.1×10^9/l
Platelets (PLT)	190×10^9/l
Mean cell volume (MCV)	74 fl
Sodium	143 mmol/l
Potassium	3.8 mmol/l
Creatinine	79 μmol/l

What is the most likely diagnosis?

A Sweet syndrome

B Metastatic colon cancer

C Budd–Chiari syndrome

D Tuberculosis

E Syphilis

C Budd–Chiari syndrome

This patient has Budd–Chiari presenting as a new diagnosis of Behçet's disease. The syndrome most often manifests in patients with underlying thrombotic disorders, including myeloproliferative disorders and paroxysmal nocturnal haemoglobinuria, pregnancy, tumours, chronic inflammatory diseases, clotting disorders and infections.

It causes obstruction of intrahepatic veins leading to a congested liver. Hepatocellular injury results from microvascular ischaemia due to congestion causing portal hypertension and liver insufficiency. He has the triad of abdominal pain, ascites and hepatomegaly with a high protein level of his ascitic fluid. To diagnose Budd–Chiari one needs to have a high index of suspicion and perform a liver ultrasound with Doppler of the hepatic veins. Liver biopsy is also required. Treatment includes management of ascites and anticoagulation.

congestion causing portal hypertension and liver insufficiency. He has the triad of abdominal pain, ascites and hepatomegaly with a high protein level of his ascitic fluid. To diagnose Budd–Chiari one needs to have a high index of suspicion and perform a liver ultrasound with Doppler of the hepatic veins. Liver biopsy is also required. Treatment includes management of ascites and anticoagulation.

Behçet's is a clinical diagnosis consisting of four major features – oral and genital ulceration, eye disease (iridocyclitis, chorioretinitis, retinouveitis, definite history of chorioretinitis or retinouveitis) and skin disease (erythaema nodosum, subcutaneous thrombophlebitis, folliculitis [acne-like lesions], pathergy). Various major and minor features make up the diagnosis. Treatment is symptomatic, with steroids the mainstay of treatment, but no single drug has shown huge benefit.

A Sweet syndrome

Sweet syndrome, or acute febrile neutrophilic dermatosis, is an inflammatory disorder characterised by painful erythematous papules or plaques with fever and leucocytosis. It can be idiopathic or secondary to malignancy or drugs. In this syndrome, neutrophilic infiltration of other organs can cause many different manifestations including hepatitis, but it is uncommon for there to be decompensation leading to ascites, and the rash described is not matching this syndrome.

B Metastatic colon cancer

Colorectal cancer can cause altered bowel habit, chronic rectal blood loss and abdominal pain. The acute onset of symptoms in a young patient makes this very unlikely. Had there been a history of familial adenomatous polyposis or known ulcerative colitis, then colorectal malignancy could be a

E	Syphilis

Syphilis is a sexually transmitted infection caused by *Treponema pallidum*. It starts as a painless anogenital ulcer and, if untreated, can lead to to rash of the face, palms and soles. There can also be fever and lymphoadenopathy, and in some cases hepatosplenomegaly, uveitis and meningitis. This can further progress to cardiac and neuropsychiatric symptoms. This is a strong differential for this patient, especially as he has a genital ulcer, but the onset of symptoms is far too rapid. The progression from primary to secondary syphilis would occur over a range of six weeks to six months, making this unlikely.

6874

Rate this question:

A 49-year-old Somalian woman is referred to the Cardiology Clinic with a heart murmur and symptoms of flushing, especially when she drinks alcohol. She has a history of atrial fibrillation and thyroid disease.

An echocardiogram and ultrasound scan are arranged, but she misses her appointments and defaults to follow-up.

Nine months later, she re-presents to the Emergency Department with widespread pigmentation on her face and neck, confusion and diarrhoea.

What is the cause for her new symptoms?

A	Cerebral systemic lupus erythematosus
B	Cerebral tuberculosis
C	Cerebral abscess
D	Amiodarone toxicity

An echocardiogram and ultrasound scan are arranged, but she misses her appointments and defaults to follow-up.

Nine months later, she re-presents to the Emergency Department with widespread pigmentation on her face and neck, confusion and diarrhoea.

What is the cause for her new symptoms?

A	Cerebral systemic lupus erythematosus
B	Cerebral tuberculosis
C	Cerebral abscess
D	Amiodarone toxicity
E	Pellagra

8:31
:tps://mypastest.pastest.com

appointments and defaults to follow-up.

Nine months later, she re-presents to the Emergency Department with widespread pigmentation on her face and neck, confusion and diarrhoea.

What is the cause for her new symptoms?

Your answer was correct

A	Cerebral systemic lupus erythematosus
B	Cerebral tuberculosis
C	Cerebral abscess
D	Amiodarone toxicity
E	Pellagra

E Pellagra

Pellagra is characterised by the '4Ds', which are dementia, diarrhoea, dermatitis and death. The rash is photosensitive and normally affects the face, neck and forearm. It is rare and can be either primary or secondary. Primary causes include niacin or tryptophan (precursor of niacin) deficiency. Secondary causes include carcinoid syndrome, which is what this lady has. Patients with carcinoid get pellagra as the tumour cells convert tryptophan to serotonin, thereby reducing endogenous niacin production. It can also present in patients with anorexia nervosa, chronic alcoholism, gastrointestinal tuberculosis and human immunodeficiency virus. In carcinoid syndrome, patients develop right-sided valvular disease and, if she has attended for her echocardiogram, the possible findings are tricuspid incompetence or pulmonary stenosis.

A Cerebral systemic lupus

A	Cerebral systemic lupus erythematosus

SLE is an idiopathic chronic inflammatory disease which is characterised by the presence of antinuclear antibodies. Presentation is varied as SLE can affect virtually any organ. In some patients the presentation can be neuropsychiatric, causing a broad range of neurological deficits which could explain this patient's confusion. However, the skin involvement in SLE is usually in the form of a butterfly rash or discoid lesions, rather than the type of pigmentation this patient has, which is why this is a less likely diagnosis. In addition, SLE is not a good explanation for diarrhoea.

B	Cerebral tuberculosis

TB is caused by *Mycobacterium tuberculosis*, which can cause infection in almost any organ. In 1% of TB cases the presentation is with tuberculous meningitis. This presents with a

meningitis. This presents with a subacute febrile illness preceded by an insidious headache and malaise, then characterised by meningismus, vomiting and confusion. It can proceed to coma as well. It is of much higher risk in the presence of HIV. Whilst this could be an explanation for her confusion, the absence of meningism and headache makes this a less likely diagnosis, which also could not explain her rash.

C	Cerebral abscess

A cerebral abscess is a focal collection within the brain parenchyma. It can occur either through direct spread from the ears, sinuses or oropharynx, or by haematogenous spread. It presents with headache, changes in mental state and fever. The absence of high fever and headache, and the presence of diarrhoea and rash, makes this a less likely diagnosis.

D	Amiodarone toxicity

occur either through direct spread from the ears, sinuses or oropharynx, or by haematogenous spread. It presents with headache, changes in mental state and fever. The absence of high fever and headache, and the presence of diarrhoea and rash, makes this a less likely diagnosis.

D	Amiodarone toxicity

Amiodarone is an anti-arrhythmic drug which can cause multiple side effects. In the lungs it can cause interstitial pneumonitis, in the thyroid it can cause both hyper- and hypothyroidism, and it also causes AV block, photosensitivity rash and gastrointestinal upset. Whilst it could explain many of the patient's symptoms, including a rash which could be photosensitive in nature, it would not explain the confusion or the previous murmur.

8487

Rate this question:

Next Question

A 27-year-old office worker presents with a 3-year history of epigastric pain, especially 30 min after eating. This is associated with nausea and belching. She also describes constipation with occasional explosive diarrhoea. The stools are normally hard with mucus and she needs to strain with every motion.

Abdominal pain is relieved after defecation but abdominal bloating persists. She wakes up an hour earlier each morning to finish her breakfast in order to prevent vomiting. She has missed work on a few occasions and feels that her weight has fluctuated.

Past medical history includes scarlet fever. She is not on any regular medications except intermittent laxatives over the counter. Abdominal examination is normal. Rectal examination reveals an anal fissure.

Investigation results:

Haemoglobin	13.1 g/dl
White blood count	6.0 ×

White blood count	6.0 × 10^9/l
Platelets	180 × 10^9/l
Mean cell volume	87 fL
International normalised ratio	1.0
ESR	1.1 mm/1st hour
Na^+	136 mmol/l
K^+	3.9 mmol/l
Urea	3.7 mmol/l
Creatinine	70 µmol/l
Albumin	39 g/L
Liver function test	normal
Anti-endomysial antibody	negative
Thyroid function test	normal

Gastroscopy	normal
Flexible sigmoidoscopy and biopsy	normal
Abdominal and pelvic ultrasound scan	normal

What is the most likely diagnosis to account for her symptoms?

A	Overlap irritable bowel syndrome and functional dyspepsia
B	Diarrhoea pre-dominant irritable bowel syndrome
C	Sphincter of Oddi dysfunction
D	Malabsorption sydrome and non-ulcer dyspepsia
E	Globus hystericus

A Overlap irritable bowel syndrome and functional dyspepsia

This lady has signs of irritable bowel syndrome, especially in light of all the normal investigation results. It is the result of complex interactions between psychosocial factors, disordered bowel motility and altered intestinal sensations. This disorder is commonly associated with functional dyspepsia and patients are more likely to get chronic fatigue syndrome and globus hystericus.

Diagnostic criteria have been developed, most notably the 'Rome criteria'. These include symptoms of abdominal pain relieved by defecation that is associated with a change in stool frequency and consistency, abdominal bloating and passing mucus per rectum.

B Diarrhoea pre-dominant irritable bowel syndrome

C	Sphincter of Oddi dysfunction

The classical symptoms of Sphincter of Oddi dysfunction are of recurrent biliary-type epigastric / right upper quadrant pain, which last from 30 minutes to several hours, and is not relieved by bowel movements. It is not typically associated with diarrhoea, or a change in stool consistency. For diagnosis, the patient must have biliary pain, and imaging must reveal the absence of bile duct stones or other structural abnormalities, and elevated liver enzymes or dilated bile duct, but not both.

D	Malabsorption sydrome and non-ulcer dyspepsia

There is no supporting evidence in the history of a malabsorption syndrome: no sustained weight loss, albumin is normal, and coeliac antibodies are negative.

A 34-year-old woman presents with a 4-month history of diarrhoea and intermittent fresh rectal bleeding. She works as a shopkeeper and smokes ten cigarettes per day. Her brother suffers from colitis. Blood tests show microcytic anaemia and a raised C-reactive protein.

Colonoscopy shows inflammation in the recto-sigmoid colon and a normal terminal ileum. Histology suggests indeterminate colitis. She turns up to clinic very keen to know the exact diagnosis.

Which of the following will favour a diagnosis of Crohn's disease?

A	Anti-endomysial antibodies
B	Detection of perinuclear anti-cytoplasmic antibodies (pANCA)
C	Dilated colon on plain abdominal radiography

reactive protein.

Colonoscopy shows inflammation in the recto-sigmoid colon and a normal terminal ileum. Histology suggests indeterminate colitis. She turns up to clinic very keen to know the exact diagnosis.

Which of the following will favour a diagnosis of Crohn's disease?

A	Anti-endomysial antibodies
B	Detection of perinuclear anti-cytoplasmic antibodies (pANCA)
C	Dilated colon on plain abdominal radiography
D	Anti-Saccharomyces cerevisiae antibodies (ASCA)
E	Arthritis

D Anti-Saccharomyces cerevisiae antibodies (ASCA)

The diagnosis of inflammatory bowel disease is based on clinical history, inflammatory markers, colonoscopy and histology results. In around 10% of patients, it is impossible to distinguish ulcerative from Crohn's colitis and this is termed indeterminate colitis. Serological markers have been studied extensively in trials but are not yet in everyday clinical use. Ulcerative colitis is strongly associated with perinuclear anti-cytoplasmic antibodies (pANCA – detected in 60–70% of UC vs 10–15% of CD). The presence of anti-*Saccharomyces cerevisiae* antibodies favours Crohn's disease (ASCA IgG + in 60–70% CD vs 10–15% of UC vs <5% in non-IBD colitis). The two antibodies can be used in combination, and a serological profile of ASCA±pANCA– has an 80% positive predictive value of progression to CD.

Reference: Mitsuyama K, et al. Antibody markers in the diagnosis of inflammatory bowel disease. *World*

Anti-endomysial antibodies are seen in coeliac disease. Although there is an overlap with inflammatory bowel disease and coeliac disease, the positivity of these antibodies would not help clarify the diagnosis.

B	Detection of perinuclear anti-cytoplasmic antibodies (pANCA)

pANCA positivity has been well described in inflammatory bowel disease but is more commonly seen in UC rather than Crohn's. In patients with indeterminate colitis (IC), pANCA and ASCA have been shown in studies to provide a predictive value. ASCA-/pANCA+ serology in indeterminate colitis is 64% predictive for a diagnosis of UC.

C	Dilated colon on plain abdominal radiography

This is a non-specific finding that could represent multiple pathologies:

and ASCA have been shown in studies to provide a predictive value. ASCA-/pANCA+ serology in indeterminate colitis is 64% predictive for a diagnosis of UC.

C	Dilated colon on plain abdominal radiography

This is a non-specific finding that could represent multiple pathologies: obstruction, volvulus, ileus or toxic megacolon.

E	Arthritis

Although arthritis (including asymmetrical polyarthritis, spondylitis, sacroilitis and enthesopathy) is well described as an extra-intestinal manifestation of Crohn's disease, their presence or absence is not a good predictive marker of underlying inflammatory bowel disease.

7402

Rate this question:

10:38
https://mypastest.paste

You are asked by the Emergency Department team to review a 32-year-old man who has received 35% burns in a house fire. You understand that he has suffered a significant degree of inhalation injury and when you review him he is intubated and ventilated. You question his relatives and find out that he likes to drink up to seven pints of beer per night.

On examination, his blood pressure is 110/60 mmHg, his pulse is 85 bpm and regular. He is 105 kg.

Investigations:

Hb	12.1 g/dl
WCC	9.2 × 10^9/l
PLT	178 × 10^9/l
	139

Audio Video Stop Share Participants More

10:38
https://mypastest.paste

PLT	10^9/l
Na^+	139 mmol/l
K^+	4.4 mmol/l
Creatinine	156 µmol/l
Alanine aminotransferase (ALT)	145 U/l
Alkaline phosphatase	320 U/l
Amylase	1200 U/l
Creatine kinase (CK)	430 U/l

Which of the following is the most likely cause of his pancreatitis?

A	Cholecystis

Audio Video Stop Share Participants More

10:38
https://mypastest.paste

Amylase	1200 U/l
Creatine kinase (CK)	430 U/l

Which of the following is the most likely cause of his pancreatitis?

A	Cholecystis
B	Chronic pancreatitis related to alcohol consumption
C	Post-burn pancreatitis
D	Trauma
E	Rhabdomyolysis

21208

Audio Video Stop Share Participants More

10:41
https://mypastest.paste

C Post-burn pancreatitis

The raised amylase, more than three times the upper limit of normal, would point to acute pancreatitis. Based on the history, postburn is the most likely aetiology. It is said to occur in patients who have a high degree of full thickness burn injury, have significant inhalation injury and a high percentage of overall skin damage. Management is supportive, with appropriate fluid resuscitation and management of associated hypoxia and hypocalcaemia.

B Chronic pancreatitis related to alcohol consumption

The patient's amylase is significantly elevated suggesting acute pancreatitis. In chronic pancreatitis the amylase and lipase are frequently normal as there is

Audio Video Stop Share Participants More

10:42
https://mypastest.paste

fibrosis of the pancreas over time rather than in acute pancreatitis where there an inflammatory response results in amylase release. Chronic pancreatitis classically presents with abdominal pain, typically after eating and pancreatic insufficiency (manifest as fat malabsorption/steatorrhoea and diabetes).

A Cholecystis

Cholecystitis is inflammation of the gall bladder caused by obstruction of the cystic duct by gallstones. This patient has acute pancreatitis, which is frequently caused by gallstones obstructing the pancreatic duct. However, there is nothing in the case to suggest a history of gallstones.

D Trauma

Audio Video Stop Share Participants More

10:42
https://mypastest.paste

A 28-year-old woman presents to the gastroenterology clinic complaining of long periods of constipation interspersed with short episodes of diarrhoea. She has not lost any weight over the past year and continues to eat a varied diet.

On examination, her BP is 122/82, pulse is 67 and regular and her BMI is 22.5. Full blood count and viscosity are normal. Flexible sigmoidoscopy is unremarkable.

What is the next most appropriate management step?

A	Colonoscopy
B	Barium enema
C	Wheat-free diet

Audio Video Stop Share Participants More

10:43
https://mypastest.paste

On examination, her BP is 122/82, pulse is 67 and regular and her BMI is 22.5. Full blood count and viscosity are normal. Flexible sigmoidoscopy is unremarkable.

What is the next most appropriate management step?

A	Colonoscopy
B	Barium enema
C	Wheat-free diet
D	Soluble fibre supplementation
E	Lactose-free diet

Audio Video Stop Share Participants More

10:44
https://mypastest.paste

D Soluble fibre supplementation

Normal clinical examination, stable weight and normal routine bloods make a sinister diagnosis unlikely. Irritable bowel syndrome is therefore the most likely cause of her symptoms. Psyllium or ispahula supplementation is of value in patients like this who have predominant constipation symptoms.

A Colonoscopy

Given the normal findings so far, there is little value in progressing to colonoscopy in this patient. Committing her to further investigation will only serve to increase anxiety.

B Barium enema

Audio Video Stop Share Participants More

10:44
https://mypastest.paste

Like colonoscopy, progressing to barium enema would be considered over-investigation in this situation.

C Wheat-free diet

There is no evidence this patient has coeliac disease. Some patients with bloating benefit from reducing intake of wheat, although greater benefit is usually found from lactose exclusion.

E Lactose-free diet

A lactose-free diet is effective in reducing bloating associated with irritable bowel disease, but has limited impact on constipation.

6638

Rate this question:

Audio Video Stop Share Participants More

10:45
https://mypastest.paste

A 60-year-old woman with systemic sclerosis complains of diarrhoea, abdominal bloating, lethargy and weight loss.

On examination, she is pale. Respiratory and cardiovascular examinations are normal. The abdomen is distended, but soft and non-tender. Bowel sounds are present. She has bilateral pitting ankle oedema. There is proximal weakness of her arm and leg muscle. The tone, reflexes and sensation are normal. Blood pressure is 122/82, pulse is 75 and regular.

Investigations:

Hb	8.0 g/dl
WCC	11.2×10^9/l
PLT	400×10^9/l
Na^+	136 mmol/l
K^+	4.4 mmol/l

Audio Video Stop Share Participants More

10:45
https://mypastest.paste

investigations:

Hb	8.0 g/dl
WCC	11.2×10^9/l
PLT	400×10^9/l
Na^+	136 mmol/l
K^+	4.4 mmol/l
Creatinine	60 μmol/l
MCV	106 fl
Urea	2.5 mmol/l
Albumin	34 g/l
Serum B_{12}	123 ng/l (160–900)
Folate	22 μg/l (2–11)

A barium meal is reported as showing multiple rounded jejunal diverticulae.

What other test may best help to confirm the underlying cause of her

Audio Video Stop Share Participants More

10:46
https://mypastest.paste

Folate	22 µg/l (2–11)

A barium meal is reported as showing multiple rounded jejunal diverticulae.

What other test may best help to confirm the underlying cause of her presentation?

A	Hydrogen breath test
B	Urea breath test
C	Schilling's test
D	Thyroid function test
E	Faecal calprotectin

8490

Audio Video Stop Share Participants More

10:47
https://mypastest.paste

A Hydrogen breath test

Bacterial overgrowth is common in patients with jejunal diverticulae, which in this case has led to malabsorption of vitamin D and calcium and muscle weakness. The bacteria can also lead to B_{12} deficiency, although folate levels are not normally depleted. Bacterial overgrowth can be confirmed by the hydrogen breath test after giving lactose or glucose. Small-bowel diverticula develop secondary to intestinal dysmotility and connective tissue disorders – for example, Marfan syndrome and systemic sclerosis. Patients are usually asymptomatic, but on bacterial colonisation they develop malabsorption. Treatment is empirical, and options include metronidazole and tetracycline. If this fails, jejunal aspiration is recommended to identify the organism.

Audio Video Stop Share Participants More

10:47
https://mypastest.paste

The urea breath test is used to confirm a diagnosis of *H. pylori*, which is associated with peptic ulceration, rather than the symptoms of malabsorption seen here.

C	Schilling's test

Schilling's test is used to diagnose pernicious anaemia, but the jejunal diverticulae seen here drive us more towards bacterial overgrowth and malabsorption as the cause of the abnormal metabolic picture seen here, rather than pernicious anaemia.

D	Thyroid function test

Stable weight, pulse and blood pressure, coupled with normal reflexes, count against thyroid dysfunction as the underlying cause of this patient's

Audio Video Stop Share Participants More

10:47
https://mypastest.paste

A 64-year-old woman is admitted to hospital with recurrent vomiting. She has been diabetic since the age of 14 years. She usually vomits several times in the evening and the vomitus often contains undigested residues of her morning meal. Apart from her insulin she also takes a statin and an angiotensin-converting enzyme (ACE) inhibitor.

Examination is unremarkable other than hypertension. She was given a 2-week course of erythromycin by her general practitioner (GP) for a chest infection, which she finished a week ago.

During her hospitalisation, she has an upper gastrointestinal endoscopy, oesophageal manometry and a barium swallow, all of which are reported as normal.

Investigations:

Audio Video Stop Share Participants More

10:48
https://mypastest.paste

Hb A_{1c} (HbA_{1c})	79 mmol/mol (9.4%)
Urea	9.0 mmol/l
Glucose	8.0 mmol/l
Na^+	134 mmol/l
K^+	4.8 mmol/l
Creatinine	155 µmol/l

What is the most likely cause of the vomiting?

A	Side effect of erythromycin therapy
B	Uraemia
C	Gastroparesis
D	Addison's disease

Audio Video Stop Share Participants More

10:49
https://mypastest.paste

A 64-year-old woman is admitted to hospital with recurrent vomiting. She has been diabetic since the age of 14 years. She usually vomits several times in the evening and the vomitus often contains undigested residues of her morning meal. Apart from her insulin she also takes a statin and an angiotensin-converting enzyme (ACE) inhibitor.

Examination is unremarkable other than hypertension. She was given a 2-week course of erythromycin by her general practitioner (GP) for a chest infection, which she finished a week ago.

During her hospitalisation, she has an upper gastrointestinal endoscopy, oesophageal manometry and a barium swallow, all of which are reported as normal.

Investigations:

Audio Video Stop Share Participants More

10:49
https://mypastest.paste

During her hospitalisation, she has an upper gastrointestinal endoscopy, oesophageal manometry and a barium swallow, all of which are reported as normal.

Investigations:

Hb A_{1c} (HbA_{1c})	79 mmol/mol (9.4%)
Urea	9.0 mmol/l
Glucose	8.0 mmol/l
Na^+	134 mmol/l
K^+	4.8 mmol/l
Creatinine	155 µmol/l

What is the most likely cause of the vomiting?

A Side effect of erythromycin therapy

Audio Video Stop Share Participants More

10:50
https://mypastest.paste

K^+	4.8 mmol/l
Creatinine	155 µmol/l

What is the most likely cause of the vomiting?

A Side effect of erythromycin therapy

B Uraemia

C Gastroparesis

D Addison's disease

E Bulimia nervosa

6445

Submit

Audio Video Stop Share Participants More

10:51
https://mypastest.paste

C Gastroparesis

The history of vomiting temporally removed from eating and with the vomitus containing recognisable food from hours before is the hallmark of a gastric-emptying disorder. The exclusion of gastric outflow obstruction (by normal endoscopy and barium studies) would lead towards a diagnosis of functional delayed gastric emptying, and in the context of long-standing diabetes, gastroparesis is correct as it is by far the most likely diagnosis. It is now recognised that some degree of delayed gastric emptying occurs in over 50% of diabetics, and the incidence seems to be related to the degree of glycaemic control. The aetiology is complex and may not be due to simple autonomic neuropathy as was thought in the past. Diagnosis depends on excluding other pathology and the demonstration of a

Audio Video Stop Share Participants More

10:52
https://mypastest.paste

pathology and the demonstration of a significant delay of gastric emptying by scintigraphy. While many drugs list nausea and vomiting as side effects, these are usually mild and transitory.

A Side effect of erythromycin therapy

Although this medication is known for its gastrointestinal (GI) side effects, it usually causes an increase in GI motility.

B Uraemia

Although it can cause intractable vomiting, this usually occurs in the context of end-stage renal disease with much higher levels of uraemia.

D Addison's disease

Audio Video Stop Share Participants More

10:52
https://mypastest.paste

Although it can cause intractable vomiting, this usually occurs in the context of end-stage renal disease with much higher levels of uraemia.

D	Addison's disease

Vomiting is a symptom in about 50% of people with Addison's disease, but this option is incorrect as the high glucose and hypertension make this diagnosis unlikely.

E	Bulimia nervosa

Bulimia nervosa, while probably underdiagnosed in older people, is still rare in this age group and the vomiting is typically surreptitious and soon after eating.

6445

Rate this question:

Audio Video Stop Share Participants More

10:53
https://mypastest.paste

A 45-year-old man is seen in clinic with pain in his wrists and knees. He has recently found it difficult walking because of pain mainly in his right knee. He also tells you that he has been feeling more tired recently, is feeling thirsty all the time and has abdominal pain which is mainly in the RUQ and worst in the evenings.

He smokes 20 cigarettes/day, drinks half a bottle of wine with his evening meal and has recently returned from a safari in Mozambique. He took precautions by only drinking boiled water and took anti-malarial medication.

He looks tanned but tired. His wrist joints and knees are tender and his right knee is swollen. His examination is otherwise unremarkable. You aspirate his right knee and the report is of crystals, which exhibit positive birefringence.

Audio Video Stop Share Participants More

10:54
https://mypastest.paste

Investigations:

Na^+	134 mmol/l
K^+	5.1 mmol/l
Urea	6.5 mmol/l
Creatinine	95 μmol/l
TSH	0.68m U/l (0.4–5)
Free thyroxine (fT4)	8.5 pmol/l (10–22)
Glucose	13.1 mmol/l
ALT	216 U/l
ALP	123 U/l
Bilirubin	16 μmol/l
Transferrin saturation	55%

Of the options given, which is most

Audio Video Stop Share Participants More

10:54
https://mypastest.paste

Bilirubin	16 μmol/l
Transferrin saturation	55%

Of the options given, which is most useful in making the diagnosis in this patient?

A	Magnetic resonance imaging (MRI) pituitary
B	Liver biopsy
C	Alpha-fetoprotein
D	Rheumatoid factor
E	Genetic screening

33017

Audio Video Stop Share Participants More

10:55
https://mypastest.paste

E Genetic screening

This patient has hereditary haemochromatosis (HHC), which usually presents in the fourth or fifth decade. It manifests earlier in men because women have regular iron loss through their periods. The C282Y mutation of the haemochromatosis, HFE gene on chromosome 6p is homozygous in 1/300 of the UK population, but iron overload manifests in only a few. Blood loss, iron intake and alcohol have a role to play. Iron is deposited in the anterior pituitary (loss of libido, tiredness), skin (pigmentation), heart (cardiac failure/dysrhythmia), joints (mainly metacarpal (MCP)/wrist/knee – with chondrocalcinosis and pseudo-gout), maturity-onset diabetes mellitus and liver failure.
Cirrhosis develops and the patient may present with hepatocellular carcinoma,

Audio Video Stop Share Participants More

10:56
https://mypastest.paste

maturity-onset diabetes mellitus and liver failure.
Cirrhosis develops and the patient may present with hepatocellular carcinoma, which is often metastatic before symptoms develop. Genetic testing is widely available and liver biopsy is helpful. Serum ferritin is pathologically elevated in these patients; however, it can be acutely elevated in acute inflammatory states.
HHC should be diagnosed before organ damage, as the prognosis is poor once the patient has cirrhosis. Treatment is regular phlebotomy. Cardiac and liver damage may improve with treatment, but joint pain and diabetes often remain. Screening first-degree relatives is crucial.

A	Magnetic resonance imaging (MRI) pituitary

Whilst there may be deposition in the

Audio Video Stop Share Participants More

10:56
https://mypastest.paste

B Liver biopsy

A liver biopsy in haemachromatosis would demonstrate iron load and be able to assess disease severity. However, genetic testing can be sufficient and non-invasive in HHC and establish the specific mutation which has caused the disease, and is therefore a better option.

C Alpha-fetoprotein

AFP is associated with hepatocellular carcinoma, metastatic cancer in the liver and some germ cell tumours. It is a useful test to monitor for liver cancer in patients with established cirrhosis of the liver, but would not help in diagnosing haemachromatosis.

D Rheumatoid factor

Audio Video Stop Share Participants More

10:57
https://mypastest.paste

A 21-year-old woman presents to your clinic with worsening diarrhoea and intermittent rectal bleeding. She was diagnosed with left-sided ulcerative colitis 2 years ago. She currently takes mesalazine tablets. She has had three episodes of exacerbation of her colitis in the past year, and was put on steroids for each occasion. She now opens her bowels 15 times a day and has lost 5 kg in weight. She smokes 10 cigarettes per day.

On examination, she is thin and has a tender, reddish purple rash on both shins. The rest of the physical examination is normal.

Investigations:

Hb	9.4 g/dl
WBC	12.2×10^9/l
PLT	420×10^9/l
MCV	72 fl

Audio Video Stop Share Participants More

10:58
https://mypastest.paste

Na^+	134 mmol/l
K^+	3.2 mmol/l
Urea	7.0 mmol/l
Creatinine	100 µmol/l
Albumin	35 g/l
C-reactive protein	37 mg/l
Liver function tests	Normal

Flexible sigmoidoscopy shows the appearance below.

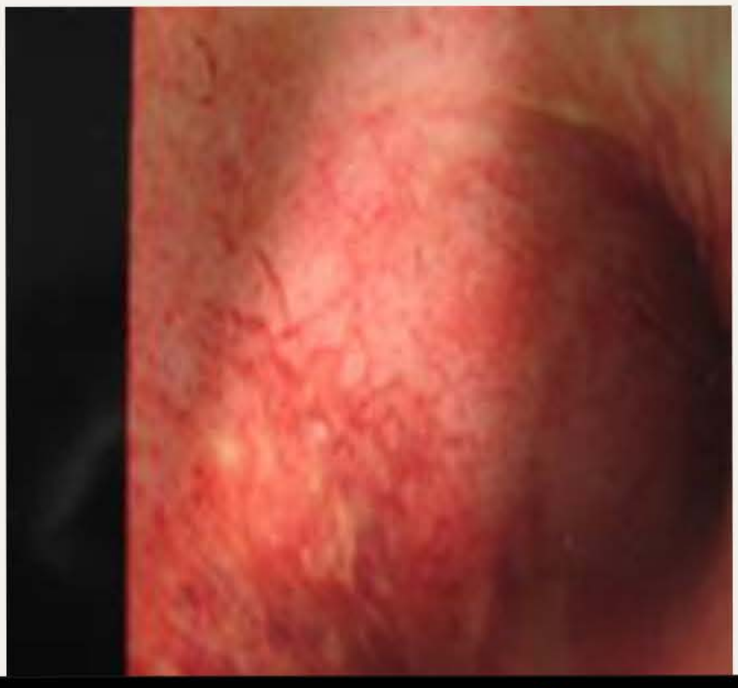

Audio Video Stop Share Participants More

10:58
https://mypastest.paste



Colonic biopsies show acute active inflammation and samples are sent for stool culture.

What is most important disease management step?

A	Treat acute flare of colitis with systemic corticosteroids
B	Carry out urgent colonoscopy and multiple biopsies
C	Surgical referral
D	Advise her to stop smoking
E	Refer to a dermatologist for a skin biopsy of rash

Audio Video Stop Share Participants More

10:59
https://mypastest.paste

A Treat acute flare of colitis with systemic corticosteroids

The drug treatment for ulcerative colitis comprises local or systemic steroids to induce remission, and generally a 5-amino-salicylic acid (5-ASA) compound to help maintain remission. However, there is a subgroup of patients who suffer repeated relapses despite maintenance treatment – like the patient above, who requires frequent courses of steroids. In these circumstances, 'steroid-sparing' drugs like azathioprine or 6-mercaptopurine should be considered. It is important to get on top of the flare with steroids, as immunomodulators take 2–3 months before they exert an effect. Anti-TNFs may be of value where patients have failed a traditional second-line agent such as azathioprine.

Audio Video Stop Share Participants More

11:00
https://mypastest.paste

A 35-year-old man is admitted to hospital after collapsing at home. He gives a 3-month history of watery diarrhoea with occasional nocturnal incontinence, for which he is being investigated in the Outpatient Department. He has no history of foreign travel, and other family members are well. He takes no regular medication and is a non-smoker.

On examination, he is thin and clinically dehydrated.

Investigations:

Urea	20.0 mmol/l
Creatinine	100 μmol/l
Sodium	140 mmol/l
Potassium	2.0 mmol/l
Glucose	5.0

Audio Video Stop Share Participants More

11:00
https://mypastest.paste

Potassium	2.0 mmol/l
Glucose	5.0 mmol/l
CT abdomen	Normal
OGD	Normal
Colonoscopy	Normal
Gastric pH	6.5
Plasma chromogranin A	60 u/l (< 20)
Urinary 5-hydroxyindoleacetic acid (5-HIAA)	60 µmol/24 h (< 70)

What is the likely diagnosis?

A	Addison's disease
B	Vasoactive intestinal peptide (VIP)

Audio Video Stop Share Participants More

11:01
https://mypastest.paste

Gastric pH	6.5
Plasma chromogranin A	60 u/l (< 20)
Urinary 5-hydroxyindoleacetic acid (5-HIAA)	60 µmol/24 h (< 70)

What is the likely diagnosis?

A	Addison's disease
B	Vasoactive intestinal peptide (VIP)
C	Gastrinoma
D	Carcinoid tumour
E	Insulinoma

Audio Video Stop Share Participants More

11:02
https://mypastest.paste

B Vasoactive intestinal peptide (VIP)

Gut neuroendocrine tumours are a rare but important cause of diarrhoea. Serum chromogranin A is elevated in the majority of neuroendocrine tumours, with the exception of insulinomas. Hypokalaemia, dehydration, watery diarrhoea and achlorhydria are hallmarks of vasoactive intestinal peptide (VIP)omas, which is the correct diagnosis here.

A Addison's disease

This would lead to hyponatraemia with hyperkalaemia, not hypokalaemia which is seen in this case.

C Gastrinoma

Audio Video Stop Share Participants More

11:03
https://mypastest.paste

This would lead to hyponatraemia with hyperkalaemia, not hypokalaemia which is seen in this case.

C Gastrinoma

In the absence of medication such as proton pump inhibitors, a high gastric pH suggests achlorhydria and excludes a diagnosis of gastrinoma - a tumour in the pancreas or duodenum that secretes gastrin leading to hypersecretion of acid.

D Carcinoid tumour

A normal urinary 5-hydroxyindoleacetic acid (5-HIAA) would be unusual with carcinoid tumours.

E Insulinoma

Audio Video Stop Share Participants More

11:04
https://mypastest.paste

A 79-year-old man presents with right upper quadrant pain, rigors, a temperature of 39 °C and deranged liver function tests.

An abdominal ultrasound reports no gallstones in the common bile duct, but there are dilated intra- and extrahepatic bile ducts.

What is the most likely diagnosis?

A	Cholecystitis
B	Cholangitis
C	Tumour at the ampulla of Vater
D	Pancreatic tumour
E	Cholangiocarcinoma at the level of the porta hepatis

Audio Video Stop Share Participants More

11:07
https://mypastest.paste

B Cholangitis

The clinical picture is suggestive of ascending cholangitis. He has evidence of extrahepatic obstruction on ultrasound scanning (USS), and there is still a chance that gallstones are present in the common bile duct, despite these not having been visualised on US scanning; the sensitivity for detection of choledocholithiasis with ultrasound is 75% in the presence of dilated ducts, and 50% for non-dilated ducts. The distal common bile duct is often obscured by air-containing bowel loops.

MRCP is superior to CT for diagnosing and locating gallstones, with a sensitivity of around 93%. ERCP and sphincterotomy may be required in the acute setting if sepsis does not resolve with antibiotics. It may also prevent

Audio Video Stop Share Participants More

11:08
https://mypastest.paste

future recurrence, particularly if the risk of laparoscopic cholecystectomy is high.

C	Tumour at the ampulla of Vater

A tumour at the ampulla of Vater could cause distal biliary obstruction, and ascending cholangitis, but is likely to present more insidiously with obstructive jaundice, weight loss and dull abdominal pain. Cholangitis is an infrequent manifestation, and hence it is not the most likely explanation here.

A	Cholecystitis

The ultrasound did not report evidence of cholecystitis, and the sensitivity of ultrasound for the diagnosis of cholecystitis is good (around 90%). Furthermore, this diagnosis is unlikely

Audio Video Stop Share Participants More

11:09
https://mypastest.paste

ultrasound for the diagnosis of cholecystitis is good (around 90%). Furthermore, this diagnosis is unlikely to explain extrahepatic duct dilatation.

D	Pancreatic tumour

A tumour in the head of the pancreas could cause distal biliary obstruction, and subsequent ascending cholangitis, but is likely to present more insidiously with obstructive jaundice, weight loss and dull abdominal pain. Cholangitis is an infrequent manifestation, and hence it is not the most likely explanation here.

E	Cholangiocarcinoma at the level of the porta hepatis

A cholangiocarcinoma at the porta hepatis would not explain the extrahepatic duct dilatation.

Audio Video Stop Share Participants More

11:10
https://mypastest.paste

A 17-year-old Turkish girl presented to the Emergency Department with a 4-h history of severe abdominal pain. the onset was rapid and without preceding symptoms. She described no change in her bowel habit or urinary symptoms. She had an appendectomy 6 months previously and an exploratory laparotomy 2 months ago for similar episodes. At neither operation was any abnormality found other than a small amount of peritoneal fluid.

On examination she is pyrexial at 39.2 °C and tachycardic at 105 bpm. Her abdomen is diffusely tender with guarding in the right upper quadrant. Bowel sounds are reduced. A painful erythematous rash was noted on the lower limbs.

Investigations;

Urinalysis	blood +
Hb	13.6 g/dl

Audio Video Stop Share Participants More

11:10
https://mypastest.paste

lower limbs.

Investigations;

Urinalysis	blood +
Hb	13.6 g/dl
MCV	85 fl
WCC	14.8×10^9/l
PLT	387×10^9/l
CRP	55 mg/l
β-HCG	< 5 U/l
Erect chest X-ray	normal

Which of the following is the most likely diagnosis?

A	Ectopic pregnancy
B	Familial Mediterranean fever

Audio Video Stop Share Participants More

11:11
https://mypastest.paste

CRP	55 mg/l
β-HCG	< 5 U/l
Erect chest X-ray	normal

Which of the following is the most likely diagnosis?

A	Ectopic pregnancy
B	Familial Mediterranean fever
C	Acute intermittent porphyria
D	Renal colic
E	Abdominal angina

70159

Audio Video Stop Share Participants More

11:12
https://mypastest.paste

B Familial Mediterranean fever

Familial Mediterranean fever (FMF) presents typically (although not exclusively) in Turkish, Armenian, Arabic, Mediterranean and/ or Jewish people. It is an autosomal recessive disorder, with the site of the mutation being on chromosome 16. Approximately half of affected people have no family history of the condition. It typically presents at a young age, with only 5-10% presenting after the age of 20 years.

FMF is characterised by recurrent episodes of fever with severe abdominal pain and signs of peritonitis, and so affected people often have a history of previous surgery, particular appendectomy. Other commonly-described symptoms include pleuritis, pericarditis, synovitis and an erysipeloid rash on the lower limbs.

Audio Video Stop Share Participants More

11:12
https://mypastest.paste

FMF is characterised by recurrent episodes of fever with severe abdominal pain and signs of peritonitis, and so affected people often have a history of previous surgery, particular appendectomy. Other commonly-described symptoms include pleuritis, pericarditis, synovitis and an erysipeloid rash on the lower limbs. Attacks normally occur without warning, and typically last for 24-72 hours. Blood tests are consistent with an acute-phase response.

FMF attacks can normally be prevented with Colchicine. Colchicine also prevents the development of amyloidosis, a recognised complication of the chronic inflammation that may occur if the condition is untreated.

The diagnosis is principally made on clinical criteria (including response to Colchicine), although genetic testing is becoming more widely-available. However, a proportion of people with

Audio Video Stop Share Participants More

11:12
https://mypastest.paste

clinical criteria (including response to Colchicine), although genetic testing is becoming more widely-available. However, a proportion of people with classical clinical features of FMF are found to have only one mutation or none at all, implying that there are more gene mutations causing the condition than are currently recognised.

A	Ectopic pregnancy

Ectopic pregnancy is ruled out by the negative pregnancy test.

C	Acute intermittent porphyria

Acute intermittent porphyria may present with acute severe abdominal pain but tends not to present with fever.

Audio Video Stop Share Participants More

11:13
https://mypastest.paste

A 52-year-old truck driver has been referred by his general practitioner (GP) to the rapid access upper gastrointestinal (GI) clinic with a 10-day history of intermittent epigastric pain and nausea.

He has been prescribed a proton pump inhibitor (PPI) which he started taking 4 days ago with some relief. He has taken regular co-codamol for years for chronic back pain but otherwise has no previous medical history. His weight is stable and clinical examination is unremarkable.

Investigations:

Hb	14.7 g/dl
WCC	3.6×10^9/l
PLT	212×10^9/l
MCV	86 fl

Audio Video Stop Share Participants More

11:13
https://mypastest.paste

Which is the most appropriate next step in management according to available evidence?

A	Urgent upper gastrointestinal (GI) endoscopy
B	*pylori* eradication therapy
C	Continue proton pump inhibitor
D	Refer for routine upper GI endscopy and give symptomatic antacids in first instance
E	Add metoclopramide 10 mg tds and review in 2 weeks

Audio Video Stop Share Participants More

11:14
https://mypastest.paste

C	Continue proton pump inhibitor

This gentleman is <55 years old without 'alarm' features – weight loss, persistent vomiting, dysphagia – and does not take non-steroidal anti-inflammatory drugs (NSAIDs). He is not anaemic and has no epigastric mass on examination. As he has gained some relief from the PPI it's therefore appropriate to continue the medication.

A	Urgent upper gastrointestinal (GI) endoscopy

Alarm features that prompt urgent referral for endoscopy include weight loss, persistent vomiting, dysphagia, anaemia and the presence of an epigastric mass on physical examination.

Audio Video Stop Share Participants More

11:15
https://mypastest.paste

A 78-year-old man is referred to the gastroenterology clinic for investigation of abdominal pain and weight loss, which had been going on for several months. He described the pain as peri-umbilical, severe and colicky in nature and it usually came on 30–60 min after eating. He also had intermittent diarrhoea and several episodes of altered blood mixed with the stool. There was no associated vomiting. His past medical history included angina, a myocardial infarction and several transient ischaemic attacks. He smoked 10 cigarettes per day and did not drink alcohol.

On examination he was thin and hypertensive, with a regular pulse. A left carotid bruit was audible. His heart sounds were normal and chest was clear. His abdomen was soft and non-tender with no masses, and normal bowel sounds. Rectal examination was

Audio Video Stop Share Participants More

11:16
https://mypastest.paste

sounds were normal and chest was clear. His abdomen was soft and non-tender with no masses, and normal bowel sounds. Rectal examination was normal. He had a mild normocytic anaemia, but other than that, his full blood count and serum biochemistry were normal. His inflammatory markers were not raised.

What is the investigation most likely to establish the diagnosis?

A	Colonoscopy
B	Mesenteric angiography
C	Small bowel barium follow through
D	CT abdomen

Audio Video Stop Share Participants More

11:17
https://mypastest.paste

B Mesenteric angiography

This man gives a classic history of chronic small bowel ischaemia, also known as 'intestinal angina'. This is an uncommon condition that usually occurs in elderly smokers with evidence of vascular disease elsewhere. It is due to atheromatous occlusion of the coeliac axis and superior and inferior mesenteric arteries. It presents with post-prandial colicky abdominal pain, diarrhoea, rectal bleeding and weight loss. The weight loss can be due to a combination of fear of eating (because of the pain) and malabsorption. An abdominal bruit may be audible, but is a non-specific sign. Diagnosis can be difficult and is usually made by angiography, where a meandering mesenteric artery with areas of stenosis may be seen. This is in contrast for angiography for acute

Audio Video Stop Share Participants More

11:18
https://mypastest.paste

bleeding, where a blush of contrast consistent where the area of acute bleeding may be seen. Vascular reconstruction is sometimes possible. If undiagnosed, it may progress to acute intestinal ischaemia which has a mortality rate of approximately 80%.

A	Colonoscopy

The pattern of pain suggests small bowel ischaemia rather than a primary colonic lesion as the cause of this patient's symptoms. A marked change in bowel habit or bloody diarrhoea with mucus would be more suggestive of a colonic lesion.

C	Small bowel barium follow through

Small bowel follow-through is most useful in evaluating structural small

Audio Video Stop Share Participants More

11:18
https://mypastest.paste

A 72-year-old woman presents with a long history of dysphagia for both liquids and solids. Food occasionally gets stuck, but this is relieved by drinking large volumes of fluid.

Chest X-ray reveals a dilated lower oesophagus with a fluid level behind the heart. Barium swallow shows gradual narrowing of the distal end of the oesophagus, 'swan-necking'.

Endoscopy reveals food residue in the distal oesophagus. Routine bloods are entirely unremarkable.

Her blood pressure is 132/82 mmHg, with pulse 62/min and regular.

Which of the following would represent the most appropriate initial medical treatment in this patient?

A	Atenolol

Audio Video Stop Share Participants More

11:19
https://mypastest.paste

entirely unremarkable.

Her blood pressure is 132/82 mmHg, with pulse 62/min and regular.

Which of the following would represent the most appropriate initial medical treatment in this patient?

A	Atenolol
B	Nifedipine
C	Diltiazem
D	Ramipril
E	Propanolol

33071

Submit

Audio Video Stop Share Participants More

11:19
https://mypastest.paste

B Nifedipine

This patient has achalasia, a condition which can present at any age, of unknown aetiology, and which results in failure of relaxation of the lower oesophageal sphincter and oesophageal dilatation. Medical treatments include calcium channel antagonists such as nifedipine or nitrate donors such as isosorbide dinitrate. Botox is a potential option where patients fail to respond to systemic medical therapy. Case series (both treated and untreated) suggest that there is around a 7% increase in cases of oesophageal squamous cell carcinoma over 25 years in patients with achalasia. Therapeutic endoscopy with balloon dilatation and botulinum toxin injection are both effective treatments for achalasia, and are increasingly used in elderly patients. Where patients fail to respond to

Audio Video Stop Share Participants More

11:20
https://mypastest.paste

carcinoma over 25 years in patients with achalasia. Therapeutic endoscopy with balloon dilatation and botulinum toxin injection are both effective treatments for achalasia, and are increasingly used in elderly patients. Where patients fail to respond to medical therapy or therapeutic endoscopy, cardiomyotomy may be considered.

A Atenolol

Beta-blockers to not lead to dilation of the lower oesophageal sphincter and therefore don't have a role in the management of achalasia.

C Diltiazem

Although diltiazem is a calcium channel antagonist and therefore may have a role in dilatation of the lower

Audio Video Stop Share Participants More

11:20
https://mypastest.paste

A 63-year-old man with a 15-year history of recurrent peptic ulceration presents with a further relapse.

The results of investigations reveal:

Fasting serum gastrin	480 pmol/l (normal <55 pmol/l)
Serum gastrin following injection of secretin (2 U/kg)	720 pmol/l

What diagnosis would you consider in his case?

A	Chronic pancreatitis
B	Zollinger–Ellison syndrome
C	Gastric lymphoma

Audio Video Stop Share Participants More

11:21
https://mypastest.paste

Fasting serum gastrin	(normal <55 pmol/l)
Serum gastrin following injection of secretin (2 U/kg)	720 pmol/l

What diagnosis would you consider in his case?

A Chronic pancreatitis

B Zollinger–Ellison syndrome

C Gastric lymphoma

D Gastro-intestinal carcinoid

E Gastric cancer

33041

Audio Video Stop Share Participants More

11:22
https://mypastest.paste

B Zollinger–Ellison syndrome

Zollinger–Ellison syndrome is a rare condition in which a gastrin-secreting adenoma results in severe and recurrent gastric and duodenal ulceration. The condition may be diagnosed by detecting a raised serum gastrin level, or if there is doubt as to the diagnosis with only a mild elevation in gastrin, the secretin test leads to a marked elevation in gastrin levels. The level of gastrin seen here is markedly elevated. Treatment is with high-dose proton pump inhibitors and, if possible, surgical resection of the adenoma. Approximately 50% of adenomas are malignant with a 5-year survival rate of 80% for a single tumour. Other causes of an elevated serum gastrin level include atrophic gastritis and proton pump inhibitor therapy.

Audio Video Stop Share Participants More

A 28-year-old woman is admitted to hospital with acute, severe abdominal pain and vomiting. She had been for a night out with her friends and had consumed approximately 8 units of alcohol. Her friends said that she had been acting strangely all night and seemed disoriented. The patient was unable to give an adequate history, but her friends stated that she had been previously fit and well and that she was not on any regular medication, although she had been admitted to hospital on one previous occasion. Having read her computerised file, you understand that she was admitted overnight with agitation and abdominal pain and was found to be hyponatraemic. Her friends were adamant that she had not taken any illicit drugs and were unsure about her family history.

On examination, she was unwell, restless and agitated. She was disoriented in time, place and person and was expressing some paranoid ideas. Her temperature was 37.8 °C

signs. Her pupils were equal and reactive to light, but fundoscopy was not possible due to her agitation. She had no visible rashes.

Investigations:

Hb	13.8 g/dl
WCC	14.0×10^9/l
PLT	350×10^9/l
Na^+	132 mmol/l
K^+	3.6 mmol/l
Creatinine	100 μmol/l
MCV	96 fl
Urea	10.2 mmol/l
Ca^{2+}	2.32 mmol/l
CRP	42 mg/l
Bilirubin	26 μmol/l
AST	62 IU/l

ECG	Sinus tachycardia
Urinalysis	Protein+
Erect chest X-ray	Normal
Abdominal X-ray	Normal

What is the most likely diagnosis?

A Wilson's disease

B Acute pancreatitis

C Ruptured ectopic pregnancy

D Acute intermittent porphyria

E Sepsis from urinary tract infection

6747

The porphyrias are a rare group of inherited disorders that are due to various enzyme abnormalities in the biosynthetic pathway of haem, resulting in overproduction of intermediate compounds called porphyrins. They can be classified as either acute or chronic. Acute intermittent porphyria (AIP) is caused by the toxic accumulation of porphobilinogen and d-aminolaevulinic acid, and tends to present with acute neurovisceral crises as in the above case. It is an autosomal dominant condition that usually presents in early adult life and is more common in women. Acute abdominal pain and vomiting are the commonest presenting features (90%), often associated with acute neuropsychiatric symptoms, ranging from anxiety and depression to fits and frank psychosis. Other features include fever, hypertension, polyneuropathies and tachycardia. Skin lesions are not seen in AIP. Blood tests may show a leucocytosis, raised urea and abnormal liver function tests. Acute

more common in women. Acute abdominal pain and vomiting are the commonest presenting features (90%), often associated with acute neuropsychiatric symptoms, ranging from anxiety and depression to fits and frank psychosis. Other features include fever, hypertension, polyneuropathies and tachycardia. Skin lesions are not seen in AIP. Blood tests may show a leucocytosis, raised urea and abnormal liver function tests. Acute attacks may be precipitated by alcohol and a variety of drugs, including the oral contraceptive pill. The diagnosis can be made by a relevant family history and raised urinary porphobilinogen excretion. Management is largely supportive, but may involve a high carbohydrate intake and intravenous haem arginate. With respect to considering acute pancreatitis as a differential, the amylase whilst elevated is not as high as would be expected and other measures such as calcium are also in the normal range.

differential, the amylase whilst elevated is not as high as would be expected and other measures such as calcium are also in the normal range.

A Wilson's disease

Although Wilson's disease does present with abnormal transaminases, a presentation with neuropsychiatric features including depression, anxiety and movement disorders is more usual than the acute severe abdominal pain and vomiting seen here.

B Acute pancreatitis

Although the amylase is moderately elevated at 420, a greater elevation in amylase and more marked epigastric tenderness would be expected in pancreatitis.

C Ruptured ectopic pregnancy

A 19-year-old man presents with multiple episodes of unexplained abdominal pain. He also has documented positive faecal occult bloods.

On examination, there is peri-oral pigmentation with a number of macular lesions which cross the vermillion border. His BP is normal at 110/70 mmHg, pulse is 68/min and his BMI is 23. His abdomen is soft but mildly tender on palpation.

He is admitted acutely a few days later after an upper gastrointestinal (GI) haemorrhage. Upper GI endoscopy reveals a number of hamartomatous polyps.

Which of the following diagnoses fits best with this clinical picture?

A	Plummer–Vinson syndrome
B	Peutz–Jegher's syndrome

68/min and his BMI is 23. His abdomen is soft but mildly tender on palpation.

He is admitted acutely a few days later after an upper gastrointestinal (GI) haemorrhage. Upper GI endoscopy reveals a number of hamartomatous polyps.

Which of the following diagnoses fits best with this clinical picture?

A	Plummer–Vinson syndrome
B	Peutz–Jegher's syndrome
C	Gardener's syndrome
D	Familial adenomatous polyposis
E	Cowden disease

33054

Ahmed's screen

This is an autosomal dominant disorder characterised by the presence of multiple hamartomatous polyps throughout the gastrointestinal tract, and mucocutaneous melanocytic macules. The condition has equal sex distribution and has been documented in most races. The cause is thought to be a mutation of the serine threonine kinase 11 gene. There is significant risk of eventual malignant transformation. Almost half of all Peutz-Jegher's syndrome patients develop and die from cancer by the age of 57 years. The mean age at first diagnosis of cancer is 43 years. The cumulative risks of cancer development are highest for the stomach, colon, pancreas and breast. Regular surveillance examinations, endoscopies and ultrasound imaging (yearly) are recommended.

A Plummer–Vinson syndrome

A 72-year-old man presents with a 4-day history of vomiting, headache, jaundice, fever and generalised upper abdominal tenderness on examination. There are quiet bowel sounds and he has not passed a motion for the past four days.

His blood pressure is 90/60 mmHg, pulse is 110/min, regular. His past medical history includes a laparoscopic cholecystectomy 10 years ago and he takes regular aspirin and amlodipine for hypertension.

Blood tests show:

Hb	13.1 g/dl
MCV	84 fl
WCC	16.4×10^9/l
Platelets	314×10^9/l
Sodium	144 mmol/l

12:07
820-068-1014
End

amlodipine for hypertension.

Blood tests show:

Hb	13.1 g/dl
MCV	84 fl
WCC	16.4 × 10^9/l
Platelets	314 × 10^9/l
Sodium	144 mmol/l
Potassium	4.9 mmol/l
Creatinine	172 µmol/l
Bilirubin	217 µmol/l
ALT	340 U/l
ALP	565 U/l

Assuming that you have already taken blood cultures, checked an arterial blood gas and started antibiotics, which is the next most appropriate investigation?

Audio
Video
Share
Participants
More

12:07
820-068-1014
End

Assuming that you have already taken blood cultures, checked an arterial blood gas and started antibiotics, which is the next most appropriate investigation?

A	Erect chest X-ray
B	Abdominal ultrasound scan (USS)
C	Urgent CT of the abdomen
D	Endoscopic retrograde cholangiopancreatography (ERCP)
E	Magnetic resonance cholangiopancreatography (MRCP)

33038

Audio
Video
Share
Participants
More

12:09
820-068-1014
End

cholangiopancreatography (MRCP)

Explanation

A Erect chest X-ray

The story is highly suggestive of ascending cholangitis. In the acute setting the most important first steps in management are to exclude bowel perforation (erect chest) and to evaluate the degree of metabolic compromise due to sepsis/shock (arterial blood gas, ABG) to determine the need for high-dependency care.

E Magnetic resonance cholangiopancreatography (MRCP)

MRCP may be useful in evaluating architecture of the biliary tree, but is less important than ruling out a perforation first.

Audio Video Share Participants More

MRCP may be useful in evaluating architecture of the biliary tree, but is less important than ruling out a perforation first.

B	Abdominal ultrasound scan (USS)

Abdominal USS comes later, and is specifically instituted to rule out dilatation of the biliary tree.

C	Urgent CT of the abdomen

CT may be useful in this situation, but the benefit risk favours other investigations such as MRCP because of haemodynamic instability related to sepsis.

D	Endoscopic retrograde cholangiopancreatography (ERCP)

Given that ERCP is invasive and gives only

12:11
820-068-1014
End

A 66-year-old man is under investigation for recurrent fevers and arthralgia. He has had episodes of fevers over the last 4 years associated with seronegative non-destructive arthropathies. Episodes have been characterised by elevated C-reactive protein (CRP) and have responded to antibiotics. Blood cultures have been persistently negative.

On this admission, the patient complains of persistent diarrhoea and weight loss over the last 6 months, as well as myalgia. His wife has noticed that he has become more forgetful of late.

On examination, he is pale and thin, and auscultation reveals a systolic murmur in the aortic area. Central nervous system (CNS) examination shows signs of mild ataxia.

Investigations:

Hb	11.5 g/dl
WCC	[illegible]

Audio
Video
Share
Participants
More

12:12
820-068-1014
End

examination shows signs of mild ataxia.

Investigations:

Hb	11.5 g/dl
WCC	10.0×10^9/l
PLT	300×10^9/l
Bilirubin	10 µmol/l (1–22)
AST	16 U/l (1-31)
ALT	21 U/l (5-35)
Albumin	29 g/l (37-49)
CRP	82
ESR	76 mm/h

What is the most likely diagnosis?

A Histoplasmosis

Audio Video Share Participants More

12:13
820-068-1014
End

AST	16 U/l (1-31)
ALT	21 U/l (5-35)
Albumin	29 g/l (37-49)
CRP	82
ESR	76 mm/h

What is the most likely diagnosis?

A	Histoplasmosis
B	Whipple's disease
C	Giardiasis
D	H. pylori infection
E	Sickle cell crisis

Audio
Video
Share
Participants
More

12:14
820-068-1014
End

Whipple's disease is a rare but potentially fatal condition caused by an abnormal host immune response to the intracellular organism *Tropheryma whippeli*. Symptoms include seronegative arthropathy (>70%), weight loss (>90%) and diarrhoea (>70%). Cardiac complications including pericarditis and valvular heart disease occur in up to 30% of patients, and central nervous system (CNS) manifestations (including ocular disturbances, higher-function abnormalities and cerebellar symptoms) occur in 15%. Biochemical abnormalities include a systemic inflammatory response with anaemia and hypoalbuminaemia secondary to malabsorption.

The histological hallmarks of the disease are (1) lipid deposition in the lamina propria of intestinal villi and (2) the presence of lipid-containing macrophages with sickle-like inclusion bodies that stain with diastase-resistant Periodic acid Schiff reagent (PAS). Polymerase chain reaction (PCR)-based

Audio
Video
Share
Participants
More

containing macrophages with sickle-like inclusion bodies that stain with diastase-resistant Periodic acid Schiff reagent (PAS). Polymerase chain reaction (PCR)-based detection from affected tissues and body fluids is now possible. Treatment is with protracted courses of antibiotics.

A Histoplasmosis

Although macrophage infiltration of the small bowel is associated with histoplasmosis, the clinical features seen in this case are not usually seen with histoplasmosis - a large encapsulated organism that predominantly affects the respiratory system.

C Giardiasis

This is a parasitic infection that is spread by contaminated food and water. Infection presents with gastrointestinal symptoms,

12:16

A 32-year-old woman presents to Outpatients after noticing the whites of her eyes changing colour. She is 36 weeks' pregnant with her first child. She feels well in herself and has no relevant past medical history other than a transient episode of jaundice in her late teens, and takes no medication. There is no history of recent travel.

Clinical examination reveals icteric sclerae and excoriations on the upper arms.

Investigations:

Bilirubin	150 µmol/l (1–22)
Alanine aminotransferase (ALT)	150 u/l (5–35)
Alkaline phosphatase (ALP)	600 u/l (45–105)
[illegible]	40 g/l (37–

Ahmed's screen

investigations:

Bilirubin	150 μmol/l (1–22)
Alanine aminotransferase (ALT)	150 u/l (5–35)
Alkaline phosphatase (ALP)	600 u/l (45–105)
Albumin	40 g/l (37–49)
Urinalysis	Bilirubin +++
Haemoglobin (Hb)	11.0 g/dl
White cell count (WCC)	5.0×10^9/l
Platelets	350×10^9/l
Prothrombin time (PT)	17 s (11.5–15.5)

What is the most likely diagnosis?

A Pre-eclampsia

White cell count (WCC)	$5.0 \times 10^9/l$
Platelets	$350 \times 10^9/l$
Prothrombin time (PT)	17 s (11.5–15.5)

What is the most likely diagnosis?

A	Pre-eclampsia
B	HELLP syndrome (haemolysis, elevated liver enzymes and low platelets)
C	Cholestasis of pregnancy
D	Hepatitis E
E	Acute fatty liver of pregnancy

12:19
820-068-1014
End

C Cholestasis of pregnancy

Cholestasis of pregnancy is by far the most likely diagnosis. This condition is caused by a bile acid transporter defect and usually manifests in the last trimester. It is not associated with significant constitutional symptoms for the mother, although the risk of stillbirth and postpartum haemorrhage is slightly increased. Milder episodes may have occurred earlier in life associated with hormonal contraception, and it recurs in subsequent pregnancies. Prothrombin time may be prolonged in any cholestatic process due to deficiency of vitamin K.

Pre-eclampsia, HELLP syndrome and acute fatty liver of pregnancy form a spectrum of disease known as toxaemias of pregnancy. All are associated with constitutional symptoms and are potentially life-threatening.

Audio Video Share Participants More

12:19
820-068-1014
End

likely diagnosis. This condition is caused by a bile acid transporter defect and usually manifests in the last trimester. It is not associated with significant constitutional symptoms for the mother, although the risk of stillbirth and postpartum haemorrhage is slightly increased. Milder episodes may have occurred earlier in life associated with hormonal contraception, and it recurs in subsequent pregnancies. Prothrombin time may be prolonged in any cholestatic process due to deficiency of vitamin K.
Pre-eclampsia, HELLP syndrome and acute fatty liver of pregnancy form a spectrum of disease known as toxaemias of pregnancy. All are associated with constitutional symptoms and are potentially life-threatening.

A	Pre-eclampsia

Pre-eclampsia is defined as pregnancy-induced hypertension with proteinuria. There

Audio
Video
Share
Participants
More

A 30-year-old woman in her third trimester of pregnancy presents with deranged liver enzymes and right upper quadrant pain.

Her blood pressure (BP) is 165/90 mmHg, and her pulse is 96 bpm. This is her first pregnancy, and she is normally fit. She admits no risk factors for hepatitis.

There is no family history of liver disorders, and she is not on any regular medications.

Investigations:

Haemoglobin (Hb)	61 g/l
White cell count (WCC)	6.7×10^9/l
Platelets (PLT)	47×10^9/l
Sodium (Na^+)	138 mmol/l
Potassium (K^+)	4.4 mmol/l
Creatinine (Cr)	100 µmol/l

Haemoglobin (Hb)	61 g/l
White cell count (WCC)	6.7×10^9/l
Platelets (PLT)	47×10^9/l
Sodium (Na^+)	138 mmol/l
Potassium (K^+)	4.4 mmol/l
Creatinine (Cr)	100 μmol/l
Bilirubin	7 μmol/l
Alanine transaminase (ALT)	682 u/l
Alkaline phosphatase (ALP)	280 u/l
Gamma glutamyl transpeptidase (GGT)	40 u/l (4–35)
Urine dipstick	Blood+, protein+++,

Ahmed's screen

phosphatase (ALP)	
Gamma glutamyl transpeptidase (GGT)	40 u/l (4–35)
Urine dipstick	Blood+, protein+++, leukocytes–, nitrites–

What is the most likely diagnosis?

A	Alcohol-induced liver disease
B	Cholangitis
C	Hereditary haemochromatosis
D	HELLP syndrome
E	Primary biliary cholangitis

12:21
820-068-1014
End

D HELLP syndrome

HELLP is a syndrome characterised by Haemolysis, Elevated Liver enzymes and Low Platelet count. It is thought to represent a form of pre-eclampsia. Thrombocytopenia occurs as a result of microangiopathic haemolytic anaemia. This takes place within the sinusoids, resulting in fibrin deposition, which leads to congestion, hepatic ischaemia and transaminitis. Treatment is with antihypertensive drugs, such as labetalol, to control hypertension, magnesium to prevent convulsion and prompt delivery.

A Alcohol-induced liver disease

The anaemia indicates haemolysis; in conjunction with the elevated (predominantly hepatitic) liver enzymes and low platelets, in the context of hypertension and proteinuria (ie pre-eclampsia), this lends itself to a diagnosis of HELLP syndrome. This

Audio Video Share Participants More

12:22

A 45-year-old man is referred by his general practitioner (GP) for an upper gastrointestinal (GI) endoscopy. He describes a 3-month history of worsening epigastric pain and anorexia. He suffers from chronic back pain following a road traffic accident 5 years ago. He smokes 10 cigarettes per day and drinks 30 units of alcohol per week.

Examination is unremarkable and all his blood tests are normal. You perform a gastroscopy, and there is no blood in the stomach.

The oesophagus and duodenum look normal, but the appearance below is seen in the antral region of the stomach (see below).

Ahmed's screen

12:23
820-068-1014
End

Which of the following is the most appropriate management step?

A	Refer back to the GP for smoking cessation advice
B	Eradicate *pylori* if present
C	Refer for partial gastrectomy
D	Repeat endoscopy in 2 weeks
E	Adrenalin injection to the base of the lesion

Audio
Video
Share
Participants
More

E	Adrenalin injection to the base of the lesion

Explanation

B	Eradicate *pylori* if present

The endoscopic appearance is that of a large gastric ulcer with a white sloughy base. *H. pylori*, aspirin, corticosteroids, non-steroidal anti-inflammatory drugs (NSAIDs) and smoking are aetiological factors for gastric ulcer. Other less common causes include Crohn's disease, tuberculosis and vasculitides. Biopsy for histological analysis is important from the ulcer edge, to exclude malignancy. The association of *H. pylori* with gastric ulceration is weaker (60–70%) than with duodenal ulceration (90%), but eradication therapy may prevent recurrence.

12:24
820-068-1014
End

D	Repeat endoscopy in 2 weeks

There is no indication for repeat endoscopy after only 2 weeks. *H. pylori* eradication should be attempted first, with a follow-up endoscopy at least 4–6 weeks later.

E	Adrenalin injection to the base of the lesion

As the ulcer is covered in slough and there is no active bleeding, injection therapy is not indicated; disturbing the overlying slough may actually increase the risk of further haemorrhage.

33022

Rate this question:

Next Question

Audio
Video
Share
Participants
More

12:24
820-068-1014
End

A 46-year-old female general practitioner (GP) presents with a 2-month history of itching and lethargy, now complicated by jaundice. According to the patient there is no previous history of use of drugs or excess alcohol. Viral screen for causes of hepatitis is negative. A past medical history of hypothyroidism treated with thyroxine is noted.

Investigations:

Bilirubin	286 μmol/l
AST	456 U/l
GT	392 U/l
ALP	242 U/l

Which investigation is most likely to confirm the likely clinical diagnosis?

Audio
Video
Share
Participants
More

12:25
820-068-1014
End

AST	456 U/l
GT	392 U/l
ALP	242 U/l

Which investigation is most likely to confirm the likely clinical diagnosis?

A	CT abdomen
B	Ultrasound abdomen
C	MRI liver
D	Magnetic resonance cholangiopancreatography (MRCP)
E	Liver biopsy

Audio
Video
Share
Participants
More

12:26
820-068-1014
End

Explanation

E	Liver biopsy

This woman, in her fifth decade, presents with jaundice and predominantly a transaminitis. The most likely cause, in the absence of a positive drug history, no history of excess alcohol consumption and no history to suggest infection, would be autoimmune hepatitis. Generally, in these cases imaging is unhelpful and liver biopsy is the correct answer as this would be the investigation of choice. Biopsy usually shows the classical features of interface hepatitis (i.e. piecemeal necrosis, bridging necrosis and fibrosis). About 78–90% of sufferers from autoimmune hepatitis are women; the incidence in Western Europe is 0.69/100,000 per year. There are associations with HLA B8, B14, DR3 and DR4. Her history of autoimmune disease (hypothyroidism) makes autoimmune hepatitis a strong possibility.

Audio
Video
Share
Participants
More

12:27
820-068-1014
End

This will not help you in making a diagnosis of autoimmune hepatitis, and more than often will be normal.

B Ultrasound abdomen

Although this is an essential screening tool in the investigation of abnormal LFTs, the question asks which investigation will most likely confirm the diagnosis, and an ultrasound abdomen in a patient with autoimmune hepatitis is likely to be normal unless the they are cirrhotic.

C MRI liver

It will not aid in the diagnosis and is more useful for investigating specific liver lesions.

D Magnetic resonance cholangiopancreatography (MRCP)

Audio Video Share Participants More

12:28
820-068-1014
End

A 23-year-old woman from Vietnam presents with fever, abdominal pain and weight loss. There is no diarrhoea or rectal bleeding. Her mother has liver cirrhosis secondary to hepatitis C. She has no past medical problems.

On examination, she is pyrexial, there is no lymphadenopathy, her abdomen is soft and there is a 2 cm tender hepatomegaly.

Liver function tests are as below:

Bilirubin	33 μmol/l
ALT	89 U/l (5-35)
ALP	190 U/l (30–150)
GGT	105 U/l
Anti-*Entamoeba histolytica* antibodies	+

Audio
Video
Share
Participants
More

12:29
820-068-1014
End

Ultrasound	4 cm × 3 cm abscess in left lobe of liver

An aspiration is planned.

Which option is considered the most appropriate antibiotic therapy for her liver abscess?

A	10-day course of metronidazole
B	10 day course of ciprofloxacin
C	14 day course of co-amoxiclav
D	2-week course of albendazole
E	2-week course of doxycycline

33029

Audio
Video
Share
Participants
More

12:29
820-068-1014
End

Explanation

A	10-day course of metronidazole

For larger liver abscesses aspiration is the intervention of choice, combined with antibiotic therapy. Liver abscesses due to amoebae mainly occur in endemic tropical countries. Clinical presentation can be indistinguishable from pyogenic abscesses. The collection is commonly single and confined to the right lobe, but multiple left-sided abscesses may also occur. Specific anti-*E. histolytica* antibodies can be found in the sera of over 90% of patients with amoebic liver abscess. Management involves treatment with a 10-day course of metronidazole.

B	10 day course of ciprofloxacin

Ciprofloxacin is a potential intervention for

Audio
Video
Share
Participants
More

12:30
820-068-1014
End

C	14 day course of co-amoxiclav

Although co-amoxiclav is a potential option for Gram-negative liver abscess, quinolones are generally the preferred first choice because of the risk of cholestatic jaundice associated with prolonged use of co-amoxiclav.

D	2-week course of albendazole

Albendazole is effective therapy for echinococcal or hydatid cysts rather than for amoebic liver abscess.

E	2-week course of doxycycline

Doxycycline is a standard intervention for the treatment of *Chlamydia*.

33029

Audio
Video
Share
Participants
More

12:31
820-068-1014
End

A 27-year-old woman presents to the Emergency Department with severe agitation and anxiety and is complaining of abdominal pain. You understand from her notes that this has happened on six occasions over the past four years, on one of which she underwent surgery.

Her blood pressure is elevated at 155/95 mmHg, and her pulse is 92 bpm and regular. Her body mass index (BMI) is 25 kg/m^2. Her abdomen is soft, although there is generalised tenderness. Admission blood testing is normal, apart from mild neutrophilia and a low sodium level at 130 mmol/l.

A picture of her abdomen is shown below.

Audio
Video
Share
Participants
More

12:32
820-068-1014
End

Which of the following diagnoses would you consider most likely for this patient?

A	Acute intermittent porphyria
B	Crohn's disease
C	Irritable bowel syndrome (IBS)
D	Pelvic inflammatory disease
E	Somatoform disorder

71648

Audio
Video
Share
Participants
More

12:34
820-068-1014
End

D	Pelvic inflammatory disease
E	Somatoform disorder

Explanation

A	Acute intermittent porphyria

In a patient presenting with multiple episodes of abdominal pain, symptoms of agitation with psychiatric disturbance, hyponatraemia and mild neutrophilia, acute intermittent porphyria, although a rare diagnosis, should be considered. Urinary porphobilinogen levels measured during an acute attack is the initial screening test of choice. The patient should avoid drugs which can precipitate an acute attack, including hormonal contraceptives.

B	Crohn's disease

Audio
Video
Share
Participants
More

12:34
820-068-1014
End

A 57-year-old schoolteacher is found to have abnormal liver function tests at a health screening. Other than tiredness and occasional gritty eyes that she attributes to age, she is well. She is postmenopausal and takes hormone replacement therapy (HRT) but no other medication. She smokes 12 cigarettes per day but takes no alcohol.

Examination is unremarkable.

Investigations:

Bilirubin	12 μmol/l (1–22)
ALT	14 U/l (5–35)
ALP	300 U/l (45–105)
AMA	Positive (>

Audio
Video
Share
Participants
More

12:35
820-068-1014
End

	22)
ALT	14 U/l (5–35)
ALP	300 U/l (45–105)
AMA	Positive (> 1:160)
Anti-dsDNA	Weakly positive
High-density lipoprotein (HDL) cholesterol	4.0 mmol/l (> 1.55)
Liver–kidney microsomal antibody (anti-LKM)	-
Low-density lipoprotein (LDL) cholesterol	4.0 mmol/l (< 3.36)
Plasma thromboplastin (PT)	12 s (11.5–15.5)
Smooth muscle antibody (SMA)	-

Audio
Video
Share
Participants
More

12:37
820-068-1014
End

Low-density lipoprotein (LDL) cholesterol	4.0 mmol/l (< 3.36)
Plasma thromboplastin (PT)	12 s (11.5–15.5)
Smooth muscle antibody (SMA)	-

Which treatment would you initiate?

A Prednisolone

B Ursodeoxycholic acid

C Cholestyramine

D Azathioprine

E Budesonide

Audio
Video
Share
Participants
More

Explanation

B	Ursodeoxycholic acid

The presence of anti-mitochondrial antibodies (in 90–95% of cases) in conjunction with a raised ALP is strongly suggestive of primary biliary cholangitis (PBC), formerly known as primary biliary cirrhosis. PBC is primarily a disease of middle-aged women and is associated with other autoimmune conditions, notably Sjögren syndrome, scleroderma and systemic lupus erythematosus (SLE). Common serum abnormalities at presentation include raised ALP and serum lipids. Studies have shown that particularly in early disease, ursodeoxycholic acid is well tolerated, improves liver biochemistry and may slow disease progression.

A	Prednisolone

12:39
820-068-1014
End

This is a bile acid sequestrant used to treat pruritis in PBC, but this patient does not have any symptoms of pruritis.

D	Azathioprine

This is used to treat autoimmune hepatitis, but trials have shown no benefit in the context of PBC.

E	Budesonide

Again, steroids have not been shown to improve symptoms or alter disease progression in PBC.

6362

Rate this question:

Next Question

Audio Video Share Participants More

3G 12:40

A 42-year-old woman presents to the clinic with symptoms of indigestion and heart burn that have worsened over the past 18 months. She is most concerned as her uncle died of oesophageal carcinoma. You arrange an upper GI endoscopy on the routine list.

Investigations:

Hb	13.1 g/dl
WCC	5.3×10^9/l
PLT	175×10^9/l
Na^+	140 mmol/l
K^+	4.9 mmol/l
Creatinine	100 μmol/l
Endoscopy	Helicobacter gastritis

She is treated with eradication therapy, which is thought to be successful.

Ahmed's screen

12:43

How would you advise her with respect to the future risk of cancers / re-treatment of her helicobacter?

A	Her future risk of oesophageal carcinoma is likely to be increased
B	She can be reassured that she no longer has a clinically significant increased risk of gastric cancer
C	She is at increased risk of gastric lymphoma
D	She should be re-treated with eradication therapy every 3 years
E	Consumption of 5 units of alcohol per week will significantly increase her risk of stomach cancer

Ahmed's screen

12:43
820-068-1014
End

her risk of stomach cancer

Explanation

B	She can be reassured that she no longer has a clinically significant increased risk of gastric cancer

Eradication of H.pylori can prevent the progression to atrophic gastritis and intestinal metaplasia (a premalignant condition). Even in patients with established intestinal metaplasia, eradication of H.pylori in patients has been shown to prevent the progression to gastric cancer.

For more information see "Management of Helicobacter pylori – the Maastricht IV/Florence consensus report". Gut. 2012.

A	Her future risk of oesophageal carcinoma is likely to be increased

Audio
Video
Share
Participants
1
More

A 21-year-old woman presents with intermittent abdominal discomfort, bloating and weight loss over the last 18 months. She has had two episodes of self-limiting diarrhoea with mucus, each lasting 5 days, but no rectal bleeding. She avoids vegetables and fruits as they make her bloating worse. She describes herself as a 'skinny child' but finds that her weight has fluctuated over the last few years. Apart from asthma, she has no other medical problems.

She works as a cashier and smokes five cigarettes a day. She drinks socially. She has also noticed an itchy, blistering rash on her elbows which she puts down to an insect bite after her weekend visit to the New Forest. This similar rash is now affecting her buttocks.

Her height is 166 cm, weight 44 kg. Cardiovascular, respiratory, abdominal and neurological examinations are normal, as are

12:45
820-068-1014
End

and fruits as they make her bloating worse. She describes herself as a 'skinny child' but finds that her weight has fluctuated over the last few years. Apart from asthma, she has no other medical problems.

She works as a cashier and smokes five cigarettes a day. She drinks socially. She has also noticed an itchy, blistering rash on her elbows which she puts down to an insect bite after her weekend visit to the New Forest. This similar rash is now affecting her buttocks.

Her height is 166 cm, weight 44 kg. Cardiovascular, respiratory, abdominal and neurological examinations are normal, as are rectal examination and rigid sigmoidoscopy.

Hb	9.0 g/dl
WCC	4.2×10^9/l
PLT	105×10^9/l
MCV	70 fl

Audio
Video
Share
Participants
1
More

12:45
820-068-1014
End

MCV	70 fl
Na^+	132 mmol/l
K^+	4.4 mmol/l
Urea	2.5 mmol/l
Creatinine	60 µmol/l
ALP	205 U/l (30–150)
ALT	25 U/l (5-35)
Albumin	32 g/l
B_{12}	200 ng/l (160-900)
Folate	4 µg/l (2-11)
Ferritin	2 µg/l (4-120)

What further investigation is most likely to contribute towards making the diagnosis?

A CRP

Audio Video Share Participants 1 More

12:46
820-068-1014
End

ALT	25 U/l (5-35)
Albumin	32 g/l
B_{12}	200 ng/l (160-900)
Folate	4 µg/l (2-11)
Ferritin	2 µg/l (4-120)

What further investigation is most likely to contribute towards making the diagnosis?

A CRP

B Immunoglobulin levels

C Anti-TTG antibody titre

D Skin scrapings

E Abdominal ultrasound scan

Audio Video Share Participants 1 More

12:47
820-068-1014
End

The most likely diagnosis is coeliac disease, especially with the picture of iron and folate deficiency and a normal B_{12}. She is likely to have hyposplenism and Howell–Jolly bodies may be seen on blood film. There is a history of weight loss and her body mass index is 16, confirming that she is underweight. Ulcerative colitis is less likely with a normal sigmoidoscopy. Crohn's disease is a possibility, but the rash of dermatitis herpetiformis is associated with a gluten-sensitive enteropathy. It is a blistering, subepidermal eruption of the skin seen on extensors and pressure areas, which improve on a gluten-free diet. Vitamin D malabsorption results in osteomalacia (raised alkaline phosphatase) and secondary or tertiary hyperparathyroidism. Serological tests for coeliac disease have become more widely available. Anti-gliadin, anti-endomysial and anti-tissue transglutaminase antibody tests are available, with the last of these having sensitivity and specificity up to 100%.

Audio
Video
Share
Participants
1
More

12:48
820-068-1014
End

may be seen on blood film. There is a history of weight loss and her body mass index is 16, confirming that she is underweight. Ulcerative colitis is less likely with a normal sigmoidoscopy. Crohn's disease is a possibility, but the rash of dermatitis herpetiformis is associated with a gluten-sensitive enteropathy. It is a blistering, subepidermal eruption of the skin seen on extensors and pressure areas, which improve on a gluten-free diet. Vitamin D malabsorption results in osteomalacia (raised alkaline phosphatase) and secondary or tertiary hyperparathyroidism. Serological tests for coeliac disease have become more widely available. Anti-gliadin, anti-endomysial and anti-tissue transglutaminase antibody tests are available, with the last of these having sensitivity and specificity up to 100%. It can be used as a method of monitoring response to gluten-free diets. Small bowel biopsy remains the 'gold standard' and may show total or subtotal villous atrophy with increased intra-epithelial lymphocytes.

Audio
Video
Share
Participants
1
More

A 34-year-old man who has undergone right hemi-colectomy for Crohn's disease 6 months ago comes to the clinic for review. He is generally happy with the result, but is a bit upset that he still has problems with diarrhoea. Medications include budesonide and mesalazine, B_{12} replacement and occasional codeine to help suppress the diarrhoea. He tells you the stools have a high volume and are difficult to flush away.

On examination, his abdomen is soft and non-tender, and he has a scar from his previous surgery.

Investigations:

Hb	11.9 g/dl
WCC	5.5×10^9/l
PLT	192×10^9/l
Na^+	139 mmol/l

Investigations:

Hb	11.9 g/dl
WCC	5.5×10^9/l
PLT	192×10^9/l
Na^+	139 mmol/l
K^+	4.0 mmol/l
Creatinine	95 μmol/l
Albumin	39 g/l
ESR	14 mm/h
^{14}C glycolate test	Abnormal
Upper GI endoscopy & colonoscopy	Unremarkable

Which of the following is the most likely diagnosis?

A Bacterial overgrowth syndrome

ESR	14 mm/h
^{14}C glycolate test	Abnormal
Upper GI endoscopy & colonoscopy	Unremarkable

Which of the following is the most likely diagnosis?

A Bacterial overgrowth syndrome

B Tropical sprue

C Bile acid malabsorption

D Short bowel syndrome

E Terminal ileal Crohn's disease

E Terminal ileal Crohn's disease

Explanation

C Bile acid malabsorption

The ileum plays an important role in the reabsorption of bile salts, and it is likely that a portion was resected during this man's right hemicolectomy. Bile acid malabsorption leads to chronic diarrhoea, as unabsorbed bile salts pass into the colon stimulating water and electrolyte secretion. The ^{14}C glycolate test has existed since the 1970s as a way to estimate bile acid malabsorption, and represents the best test for making the diagnosis. The diarrhoea usually responds well to colestyramine, which works by binding bile salts in the intestinal lumen.

A Bacterial overgrowth syndrome

binding bile salts in the intestinal lumen.

A Bacterial overgrowth syndrome

Given this patient's history of previous right hemicolectomy, dysfunctional bile salt reabsorption because of damage to or partial resection of the terminal ileum is much more likely than bacterial overgrowth as the underlying diagnosi.

B Tropical sprue

Tropical sprue is defined as chronic, progressive malabsorption in a patient in or from the tropics. In this case we are given nothing to suggest a significant travel history.

D Short bowel syndrome

We are told that the patient has undergone a right hemicolectomy for Crohn's disease

12:53

A 38-year-old health worker finds out that he has contracted hepatitis C infection from a needle-stick injury that he sustained 6 weeks ago.

Which of the following management strategies is the most appropriate?

A	He requires a liver biopsy before consideration of treatment
B	He should receive antiviral treatment in the acute setting, which can lead to a sustained antiviral response in more than 80% of cases
C	He should be vaccinated to prevent spread of the virus

Ahmed's screen

consideration of treatment

B He should receive antiviral treatment in the acute setting, which can lead to a sustained antiviral response in more than 80% of cases

C He should be vaccinated to prevent spread of the virus

D An endoscopy should be arranged soon to exclude oesophageal varices

E He requires no treatment as the probability of developing cirrhosis is less than 5%

12:54
820-068-1014
End

D He should receive antiviral treatment in the acute setting, which can lead to a sustained antiviral response in more than 80% of cases

Interferon-based antiviral treatment regimens have been the preferred treatment for acute HCV infection, and if treatment is started within 12 weeks, sustained virological response (SVR) rates of over 80% have been achieved. Patients with asymptomatic acute HCV are thought to be at increased risk for developing chronic infection. In these patients, and I patients at increased risk of transmission, such as surgeons, treatment is usually initiated at the time of diagnosis (rather than wait the 12 weeks from the time of suspected inoculation before starting therapy, to allow time for spontaneous viral clearance to occur). The use of all-oral direct-acting antiviral-based regimens has not been extensively studied in the acute setting.

Audio Video Share Participants 1 More

12:56

A 22-year-old woman presents with a severe headache, peripheral oedema and indigestion. She is 32 weeks' pregnant with her first child.

On examination, her BP is 140/90 mmHg and she looks tired; her ankles are swollen.

Investigations:

Hb	9.0 g/dl
WCC	7.1×10^9/l
PLT	68×10^9/l
Na^+	139 mmol/l
K^+	4.4 mmol/l
Creatinine	185 μmol/l
AST	205 U/l
ALT	150 U/l

Ahmed's screen

Bilirubin	80 µmol/l
INR	1.0
Urine	Protein++

Which of the following is the most likely diagnosis?

A	Acute fatty liver of pregnancy
B	Cholestasis of pregnancy
C	Pre-eclampsia
D	Eclampsia
E	Idiopathic thrombocytopaenic purpura (ITP)

Explanation

C	Pre-eclampsia

The combination of severe headache, peripheral oedema, indigestion and proteinuria is very classical for pre-eclampsia. This patient has associated HELLP syndrome. Micro-angiopathic haemolytic anaemia, which accounts for the blood picture seen here, is typical of the situation. Of paramount importance is control of blood pressure and rapid assessment of the pregnancy by the obstetric team. The only way to resolve pre-eclampsia is delivery of the placenta, and hence the neonate.

A	Acute fatty liver of pregnancy

This is rare, occurring at around week 35 in pregnancy, and is associated with a moderate elevation in transaminases;

abnormal, although the hypertension seen here is not present.

B	Cholestasis of pregnancy

The main symptoms of cholestasis of pregnancy are itching and lethargy, which begin as early as week 25.

D	Eclampsia

Eclampsia is where seizures are seen on top of the picture of pre-eclampsia described here.

E	Idiopathic thrombocytopaenic purpura (ITP)

ITP is not associated with the other features seen here, including hypertension, proteinuria, renal impairment and abnormal liver function tests.

A 59-year-old man presents to the Emergency Department with an acute upper GI bleed. He admits to having had symptoms of indigestion for the past 6 months, he smokes 20 cigarettes per day and drinks 30 units of alcohol per week. Most recently he has been taking ibuprofen for a back injury.

On examination, is blood pressure (BP) is 110/70 mmHg, with a pulse of 90/min; on moving from lying to sitting, his systolic falls to 90 mmHg and his pulse increases to 105/min. He is acutely tender in the epigastrium and vomits up a mix of fresh and altered blood after the consultation.

Investigations:

Hb	8.7 g/dl
WCC	$10.2 \times 10^9/l$
PLT	$152 \times 10^9/l$

12:59
820-068-1014
End

altered blood after the consultation.

Investigations:

Hb	8.7 g/dl
WCC	10.2×10^9/l
PLT	152×10^9/l
Na^+	138 mmol/l
K^+	4.3 mmol/l
Creatinine	110 μmol/l
Urea	18.2 mmol/l
Albumin	38 g/l
ALT	24 U/l
Upper GI endoscopy	Large bleeding DU, injected during the procedure

Which of the following further interventions has been shown to positively impact on prognosis?

Audio
Video
Share
Participants
More

Albumin	38 g/l
ALT	24 U/l
Upper GI endoscopy	Large bleeding DU, injected during the procedure

Which of the following further interventions has been shown to positively impact on prognosis?

A Oral propranolol

B Oral lactulose

C IV omeprazole

D Oral ranitidine

E IV terlipressin

E IV terlipressin

Explanation

C IV omeprazole

IV omeprazole has been proven in a number of meta-analyses to impact positively on mortality when used in addition to optimal endoscopic therapy. The aim of IV PPI therapy is to increase the pH in the stomach to promote coagulation. Oral PPI has also been shown to reduce the length of hospital stay and re-bleeding rates.

A Oral propranolol

Oral propranolol is used as a chronic treatment in patients with proven portal hypertension and varices.

B Oral lactulose

treatment in patients with proven portal hypertension and varices.

B Oral lactulose

Lactulose is used to reduce absorption and production of ammonia from a blood meal in patients with liver failure who have had a significant GI bleed.

D Oral ranitidine

Oral H2 receptor antagonists have not been shown to reduce the risk of ulcer re-bleeding.

E IV terlipressin

Terlipressin is an acute treatment that has a role in the management of variceal bleeding. This patient has risk factors and history suggestive of peptic ulcer disease, and a bleeding duodenal ulcer is found on upper GI

1:01
820-068-1014
End

A 42-year-old Russian immigrant with a background of haemophilia A is admitted after a road traffic accident. He is transfused with four units of blood and given recombinant factor VIII concentrate. He otherwise appears well. He drinks 10 units of alcohol per week and denies and previous intravenous (iv) drug use.

Investigations:

ALT	140 U/l
GGT	88 U/l
ALP	120 U/l
Bilirubin	25 μmol/l

You suspect he has viral hepatitis.

What diagnosis fits best with this clinical picture?

Audio
Video
Share
Participants
1
More

1:02
820-068-1014
End

GGT	88 U/l
ALP	120 U/l
Bilirubin	25 µmol/l

You suspect he has viral hepatitis.

What diagnosis fits best with this clinical picture?

A	Hepatitis A
B	Hepatitis B
C	Hepatitis C
D	Hepatitis D
E	Hepatitis E

Audio
Video
Share
Participants
More

1:04
820-068-1014
End

D	Hepatitis D
E	Hepatitis E

Explanation

C	Hepatitis C

Unfortunately, due to inadequate screening of donated blood and the pooling of multiple samples, significant numbers of haemophilia patients have been infected with hepatitis C virus following blood transfusions, so option C is correct. The picture seen here is most typical of hepatitis C infection, and around 50% of patients are diagnosed on routine liver function testing with an isolated rise in alanine transferase (ALT). Diagnosis is made by confirming the presence of hepatitis C antibodies using ELISA.

B	Hepatitis B

Audio
Video
Share
Participants
More

1:05
820-068-1014
End

A 28-year-old woman presents with intermittent episodes of diarrhoea, constipation, abdominal bloating and flatulence. She has not lost weight over the course of the past year.

Clinical examination is unremarkable. Her BP is 110/70 mmHg, pulse is 65/min and regular, BMI 24 and her abdomen is soft and non-tender. Faecal occult bloods are negative and haematological and biochemical investigations are unremarkable.

Which of the following diagnoses fits best with this clinical picture?

A	Colonic carcinoma
B	Crohn's disease

Audio
Video
Share
Participants
1
More

Clinical examination is unremarkable. Her BP is 110/70 mmHg, pulse is 65/min and regular, BMI 24 and her abdomen is soft and non-tender. Faecal occult bloods are negative and haematological and biochemical investigations are unremarkable.

Which of the following diagnoses fits best with this clinical picture?

A	Colonic carcinoma
B	Crohn's disease
C	Coeliac disease
D	Ulcerative colitis
E	Irritable bowel syndrome

33057

Ahmed's screen

1:06
820-068-1014
End

E Irritable bowel syndrome

Explanation

E Irritable bowel syndrome

In the presence of a normal physical examination and a series of normal investigations, irritable bowel syndrome is the most likely diagnosis here. Many patients with symptoms of irritable bowel syndrome also have lactose intolerance. Hence, a trial of dairy-free diet may bring about significant improvement in symptoms, as unmetabolised lactose contributes to large bowel symptoms of bloating and flatulence because lactose provides a substrate for metabolism by colonic bacteria. Other components of the diet may be excluded on a trial basis to assess the impact on symptoms.

A Colonic carcinoma

Audio Video Share Participants 1 More

A 26-year-old man with human immunodeficiency virus (HIV) infection presents with spiking temperatures over the past two weeks, right upper quadrant pain and abnormal liver function tests. He has a low CD4 count. Ultrasound scan and computed tomography (CT) scan are normal.

Blood tests show:

Hb	12.0 g/dl
White blood count	4.0×10^9/l
Platelets	151×10^9/l
International normalised ratio (INR)	1.0
Bilirubin	20 μmol/l
Alanine aminotransferase (ALT)	37 U/l (5–35)
[illegible]	380 U/l (30–

Gamma GT (GGT)	189
Albumin	35 g/l

What is the best way to establish the underlying diagnosis?

A Blood culture

B Liver biopsy

C Magnetic resonance cholangiopancreatography (MRCP)

D Endoscopic retrograde cholangiopancreatography (ERCP)

E CT abdomen

71349

1:08
820-068-1014
End

D Endoscopic retrograde cholangiopancreatography (ERCP)

Biliary involvement in HIV infection is commonly known as AIDS (acquired immunodeficiency syndrome) cholangiopathy, and is a syndrome of biliary obstruction resulting from infection-related strictures of the biliary tract. There is a spectrum of involvement including acute acalculous cholecystitis, papillary stenosis and sclerosing cholangitis. Cholangiopathy is mostly associated with cryptosporidium parvum, but other pathogens have also been identified, including cytomegalovirus (CMV) and Microsporidium.

The definitive diagnosis of cholangiopathy is made with direct visualisation by endoscopic retrograde cholangiopancreatography (ERCP), which can reveal several patterns of biliary abnormality; the combination of papillary stenosis and sclerosing cholangitis

Audio Video Share Participants 1 More

1:09
820-068-1014
End

mostly associated with cryptosporidium parvum, but other pathogens have also been identified, including cytomegalovirus (CMV) and Microsporidium.

The definitive diagnosis of cholangiopathy is made with direct visualisation by endoscopic retrograde cholangiopancreatography (ERCP), which can reveal several patterns of biliary abnormality; the combination of papillary stenosis and sclerosing cholangitis is the most unique to AIDS cholangiopathy. ERCP also allows both confirmation of the diagnosis and the performance of therapeutic procedures, if indicated. Biliary brushings and biopsy, biliary aspiration, and small bowel biopsy can also be performed to aid in diagnosis, including detection of the etiologic agent using appropriate stains. However, other studies (particularly ultrasound and magnetic resonance cholangiopancreatography [MRCP]) can be helpful in early evaluation, and in selecting patients for ERCP.

Audio
Video
Share
Participants
1
More

1:10
820-068-1014
End

cholangiopancreatography (MRCP)

This is a cost-effective and sensitive initial screening investigation, but ECRP is considered the definitive modality, and carries further diagnostic and therapeutic options.

A Blood culture

This would not particularly contribute to diagnosis - imaging of the biliary tree is required to explore this patient's symptoms pattern of liver enzyme derangement.

B Liver biopsy

Liver biopsy has little value in the diagnosis of AIDS cholangiopathy; diagnosis is informed by imaging of the biliary tree.

E CT abdomen

Audio Video Share Participants More

1:11
820-068-1014
End

A 56-year-old man presents in Accident and Emergency with sudden-onset chest pain. He has had severe gastroenteritis for the last 48 h and reports severe epigastric pain radiating to his back, which he says came on suddenly during a paroxysm of vomiting. His medical history includes ischaemic heart disease.

On examination, his blood pressure is 120/80 mmHg and he has a small left pleural effusion. The electrocardiogram shows T-wave inversion in lead III in association with a sinus tachycardia of 100 bpm.

Which of the following tests would you organise to best confirm your clinical diagnosis?

A	D-dimer
B	Echocardiogram

Audio
Video
Share
Participants
More

1:11
820-068-1014
End

history includes ischaemic heart disease.

On examination, his blood pressure is 120/80 mmHg and he has a small left pleural effusion. The electrocardiogram shows T-wave inversion in lead III in association with a sinus tachycardia of 100 bpm.

Which of the following tests would you organise to best confirm your clinical diagnosis?

A	D-dimer
B	Echocardiogram
C	Troponin levels
D	Serum amylase
E	Gastrograffin swallow

Audio
Video
Share
Participants
More

1:13
820-068-1014
End

E Gastrograffin swallow

Explanation

E Gastrograffin swallow

Severe gastroenteritis is associated with vomiting and diarrhoea. This, in combination with sudden-onset chest pain and a pleural effusion, raises the suspicion of oesophageal perforation. A gastrograffin swallow, using a water-soluble contrast medium, will demonstrate the site of the perforation.

D Serum amylase

Serum amylase is a useful investigation for acute pancreatitis, which causes epigastric pain radiating to the back and which can be associated with vomiting and tachycardia, as well as pleural effusion. However, the absence of causes such as gallstones or alcohol, the sudden onset of pain during

Audio Video Share Participants 1 More

1:14
820-068-1014
End

effusion, raises the suspicion of oesophageal perforation. A gastrograffin swallow, using a water-soluble contrast medium, will demonstrate the site of the perforation.

D	Serum amylase

Serum amylase is a useful investigation for acute pancreatitis, which causes epigastric pain radiating to the back and which can be associated with vomiting and tachycardia, as well as pleural effusion. However, the absence of causes such as gallstones or alcohol, the sudden onset of pain during vomiting and the location of pain make this less likely.

A	D-dimer

The presence of sudden-onset chest pain with T-wave inversion and sinus tachycardia could be suggestive of a diagnosis of pulmonary embolism, which may even be

Audio
Video
Share
Participants
1
More

1:15
820-068-1014
End

suggested by a differential blood pressure in the limbs and absence of other symptoms such as gastroenteritis.

C	Troponin levels

Troponin is a cardiac enzyme, and troponins T and I are measured clinically. Raised troponin can suggest myocardial infarction, pericarditis, myocarditis, PE, sepsis or recent CPR. The sudden onset of chest pain in a male with a previous history of ischaemic heart disease makes a diagnosis of infarction more likely, as do the T-wave changes on the ECG, but the fact that the pain is radiating to the back and started during vomiting makes it less likely.

2289

Rate this question:

Next Question

Audio
Video
Share
Participants
More

1:16
820-068-1014
End

A 44-year-old man presents with a 10-month history of pain in his lower back, hips, ankles and feet. He has tried osteopathy, acupuncture and diclofenac, but had no relief. He has also been feeling increasingly tired and breathless on walking up steep inclines. He had lost 10 kg in the last 6 months despite eating reasonable meals. He had no dysphagia, change in bowel habit or night sweats. He smokes 30 cigarettes/day and drinks two pints of beer 3 times per week. His past history includes hypothyroidism for which he takes thyroxine, and his mother is a tablet-controlled diabetic.

On examination, his clothes fit loosely and he looks pale. He has no clubbing or lymphadenopathy. He had normal cardiac, chest and abdominal examinations.

On joint examination, there was pain when moving each joint but no obvious focus of

Audio
Video
Share
Participants
1
More

1:17
820-068-1014
End

the pain. Chest X-ray is normal, faecal occult blood (FOB) is positive.

Investigations:

Hb	7.1 g/dl
WCC	6.5×10^9/l
PLT	512×10^9/l
Na^+	136 mmol/l
K^+	3.8 mmol/l
Creatinine	71 μmol/l
Urea	4.6 mmol/l
Ca^{2+} (corrected)	1.82 mmol/l
Albumin	26 g/l
MCV	71.2 fl
INR	1.5
PTH	15 pmol/l (0.9–5.4)

Audio
Video
Share
Participants
More

1:18
820-068-1014
End

Ca^{2+} (corrected)	1.82 mmol/l
Albumin	26 g/l
MCV	71.2 fl
INR	1.5
PTH	15 pmol/l (0.9–5.4)

What is the most likely diagnosis?

A	Crohn's disease
B	Metastatic caecal carcinoma
C	Coeliac disease
D	Whipple disease
E	Intestinal lymphangiectasis

6863
Audio
Video
Share
Participants
1
More

1:18
820-068-1014
End

Coeliac disease is common, with a prevalence of 1: 100 and as much as 1: 30 in the west of Ireland. Only one-third of patients present with chronic diarrhoea and steatorrhoea. Malabsorption in this case has caused vitamin D deficiency with secondary hyperparathyroidism, low albumin, impaired clotting, iron deficiency anaemia and weight loss. The vitamin D deficiency has led to osteomalacia, causing the presenting feature of lower back and leg pain. Iron deficiency anaemia is the most common presentation of coeliac disease, and the stool may be positive for faecal occult blood, although this is no more common than in the general population. Having other autoimmune conditions in coeliac patients is common, such as hypo/hyperthyroidism and type 1 diabetes mellitus (7%).

A	Crohn's disease

Crohn's disease is less likely to have an

Audio
Video
Share
Participants
More

B Metastatic caecal carcinoma

Caecal carcinoma can present with anaemia, although it is much less likely to present with osteomalacia than coeliac disease.

D Whipple disease

Whipple's disease is associated with diarrhoea and malabsorption, but it is also associated with small joint polyarthritis and is significantly rarer than coeliac disease.

E Intestinal lymphangiectasis

Intestinal lymphangiectasia is a protein-losing enteropathy and presents in childhood with symptoms of malabsorption and peripheral oedema.

6863

Rate this question:

Ahmed's screen

You are asked to review a 42-year-old man with alcoholic cirrhosis who is an inpatient on the Gastroenterology Ward. His spironolactone has been withdrawn, but the nurses are concerned as his creatinine has risen to 180 μmol/l. He has received albumin infusions.

On examination, his BP is 110/70 mmHg, with pulse 75/min and regular. He has marked ascites consistent with cirrhosis. You suspect hepatorenal syndrome.

Which of the following is the most effective intervention with respect to his renal function?

A	Terlipressin
B	Lactulose

infusions.

On examination, his BP is 110/70 mmHg, with pulse 75/min and regular. He has marked ascites consistent with cirrhosis. You suspect hepatorenal syndrome.

Which of the following is the most effective intervention with respect to his renal function?

A	Terlipressin
B	Lactulose
C	Furosemide
D	Dobutamine
E	Midodrine

A Terlipressin

The class of drugs known as splanchnic vasoconstrictors has been studied regarding treatment of individuals with hepatorenal syndrome. One of the drugs terlipressin, has a positive impact on both blood pressure and glomerular filtration rate (GFR), when used in combination with albumin. Terlipressin is a non-selective V1 vasopressin agonist, with lower incidence of ischemic complications as compared to ornipressin. Also, terlipressin can be given as a bolus. Albumin is useful in expanding the plasma volume and maintenance of cardiac output. Liver transplantation is the ultimate definitive treatment of hepatorenal syndrome. Over the longer term, transjugular intrahepatic portosystemic shunt (TIPS) may be of value, although ultimately liver transplantation is the most effective option. In a study by Sarwar et al. (see below), complete response

non-selective V1 vasopressin agonist, with lower incidence of ischemic complications as compared to ornipressin. Also, terlipressin can be given as a bolus. Albumin is useful in expanding the plasma volume and maintenance of cardiac output. Liver transplantation is the ultimate definitive treatment of hepatorenal syndrome. Over the longer term, transjugular intrahepatic portosystemic shunt (TIPS) may be of value, although ultimately liver transplantation is the most effective option. In a study by Sarwar et al. (see below), complete response to terlipressin–albumin therapy was seen in 58.3% patients, 29.2% achieved partial response with > 25% creatinine reduction, while 12.5% showed no response.

Reference: Sarwar, S., Khan, A.A. (2016). Hepatorenal syndrome: Response to terlipressin and albumin and its determinants. *Pakistan Journal of Medical Sciences* 32(2):274–8.

1:22
820-068-1014
End

Pakistan Journal of Medical Sciences 32(2):274–8.

B Lactulose

Lactulose is used in the management of hepatic encephalopathy. It reduces ammonia production in the intestine. Lactulose is the mainstay of treatment and results in improvement in approximately 70–80% of patients with overt hepatic encephalopathy. It would not be effective in this particular scenario.

C Furosemide

Furosemide, a diuretic, is not indicated as the patient is already on spironolactone and his blood pressure needs to be maintained at an optimal level.

D Dobutamine

Audio
Video
Share
Participants
More

1:22
820-068-1014
End

Midodrine (an alpha-agonist) is used the treatment of postural hypotension and is non-selective in constricting splanchnic vessels, and thus cannot be used in this case. Where terlipressin therapy is not available, initial treatment with a combination of midodrine, octreotide and albumin is suggested. Investigations of midodrine alone or in combination have shown conflicting results for systemic and renal haemodynamics and renal function in patients with cirrhosis-related complications.

36466

Rate this question:

Next Question

Previous Question
Tag Question
Feedback
End Session

Audio
Video
Share
Participants
More

1:23
820-068-1014
End

and now lower limb oedema.

Examination reveals pallor, stomatitis and glossitis. His BMI is only 20 and he admits to having lost 6 kg in weight in 2 months.

Investigations reveal:

Blood count and film	Megaloblastic anaemia
Albumin	24 g/l
D-xylose malabsorption test	Positive
Faecal fat excretion	8.5 g / 24 h (normal value < 7 g / 24 h)
Anti-endomysial antibodies	Negative

Which diagnosis fits best with this clinical picture?

A. Coeliac disease

Audio
Video
Share
Participants
More

Malabsorption test	Positive
Faecal fat excretion	8.5 g / 24 h (normal value < 7 g / 24 h)
Anti-endomysial antibodies	Negative

Which diagnosis fits best with this clinical picture?

A Coeliac disease

B Helicobacter pylori infection

C Tropical sprue

D Giardiasis

E HIV enteropathy

1:24
820-068-1014
End

Explanation

C Tropical sprue

First described by William Hillary in an account of medical observations of Barbados, this disease is most common in the Caribbean and the Far East. It is characterised by a picture of small intestinal malabsorption and the cause is thought to be infectious in origin. Jejunal biopsy reveals mild villous atrophy, increased villous crypts and mononuclear cellular infiltrates, enlarged epithelial cells, and large nuclei caused by folate and/or vitamin B12 deficiency. Tetracyclines or ampicillin are treatments of choice; prolonged therapy for 6 months or more may be required. Folate and B12 deficiencies should also be corrected: folic acid with oral replacement and B12 with intramuscular injection. Complete recovery is possible with appropriate therapy.

Audio Video Share Participants 1 More

1:25
820-068-1014
End

A Coeliac disease

Coeliac disease is the alternative possible diagnosis, although negative anti-endomysial antibodies are possible in coeliac patients with selective IgA deficiency, given the history of travel to Barbados, tropical sprue is more likely.

B Helicobacter pylori infection

Helicobacter pylori infection is a cause of peptic ulcer disease rather than small bowel malabsorption syndromes.

D Giardiasis

Giardiasis can result in a malabsorption type picture, but the symptom picture is similar to intermittent irritable bowel syndrome after an acute diarrhoeal illness, rather than the

Audio Video Share Participants 1 More

E Variceal banding and terlipressin

The combination of banding and terlipressin appears to be most effective in controlling acute variceal bleed, re-bleeding rate and early complications. Sclerotherapy is superior to balloon tamponade alone, terlipressin alone and a combination of terlipressin and balloon tamponade for control of active variceal haemorrhage.

Randomised controlled trials have shown banding to be superior to sclerotherapy in achieving acute haemostasis (86 versus 77% in the largest study) and prevention of early re-bleeding. Complication rates appear to be lower in the banding group. Somatostatin, octreotide or terlipressin is effective in acute management of variceal bleed, but combined therapy with banding (or scleropathy as a second choice if banding is not possible for technical reasons) has been shown to be more effective

A 31-year-old previously fit and healthy woman is knocked over by a cyclist on the pedestrian crossing. She is admitted to hospital and has an abdominal computed tomography (CT) scan. This shows that the spleen and liver are normal except for a cyst in the pancreas. The cyst shows features of a 1 cm serous cystadenoma.

Which of the following is the most appropriate management?

A	Do nothing
B	Annual follow-up
C	Resection of cyst alone
D	Resection of tail of pancreas

Ahmed's screen

pedestrian crossing. She is admitted to hospital and has an abdominal computed tomography (CT) scan. This shows that the spleen and liver are normal except for a cyst in the pancreas. The cyst shows features of a 1 cm serous cystadenoma.

Which of the following is the most appropriate management?

A	Do nothing
B	Annual follow-up
C	Resection of cyst alone
D	Resection of tail of pancreas
E	Resection of whole pancreas

1:36
On 820-068-1014 End

Explanation

A	Do nothing

Serous cystadenomas (SCAs) are benign tumours of the pancreas commonly picked up on imaging. They are rarely >2 cm and usually remain benign, and therefore do not require follow-up. The differential in this case would be a mucinous cystadenoma, which has malignant potential (in about 25% of cases). CT and MRCP can differentiate between the two but occasionally EUS with FNA of serous fluid may be required. High levels of CEA are typically observed in a mucinous cystadenoma (but are normal in a serous cystadenoma). The international consensus guidelines (2012) recommend all mucinous cystadenomas should be resected.

Other cystic lesions of the pancreas that may be noted incidentally include intraductal papillary mucinous neoplasm (IPMN), which

Audio Video Share Participants 1 More

cases). CT and MRCP can differentiate between the two but occasionally EUS with FNA of serous fluid may be required. High levels of CEA are typically observed in a mucinous cystadenoma (but are normal in a serous cystadenoma). The international consensus guidelines (2012) recommend all mucinous cystadenomas should be resected.

Other cystic lesions of the pancreas that may be noted incidentally include intraductal papillary mucinous neoplasm (IPMN), which also has a malignant potential and requires MRCP surveillance; pancreatic pseudocysts (in a patient with a history of pancreatitis); retention cysts (simple cysts, seen in association with Von Hippel–Lindau disease and polycystic kidney disease); and papillary cystic neoplasm (typically seen in young females, in the tail or body of the pancreas).

Reference: Tanaka et al. *Pancreatology* 12 (2012): 183–197.

1:39
On
820-068-1014
End

A 64-year-old man presents to accident and emergency complaining of a 4-day history of upper abdominal pain which radiates to his back, along with nausea and diarrhoea. He has been admitted to hospital twice in the past 8 months with similar symptoms and has lost approximately 5 kg in weight over this time.

His past medical history includes hypertension, gastric ulceration and a partial gastrectomy 12 years ago. His current medication includes atenolol 50 mg once daily and omeprazole 20 mg once daily.

The following blood results were obtained:

WCC	12.6×10^9/l
Hb	124 g/l
MCV	112 fl
PLT	110×10^9/l

Audio
Video
Share
Participants
1
More

1:39
On 820-068-1014 End

MCV	112 fl
PLT	110×10^9/l
Na^+	135 mmol/l
K^+	3.2 mmol/l
Urea	2.4 mmol/l
Creatinine	64 mmol/l
Calcium	2.24 mmol/l
ALT	64 U/l
ALP	250 U/l
Bilirubin	26 μmol/l
Albumin	30 g/l
Random glucose	18 mmol/l

3-day faecal fat excretion 21 g/day = 63 g total (normal < 30 g/3 days)

Which of the following is the most likely cause of his symptoms?

Audio Video Share Participants 1 More

1:40
On 820-068-1014 End

Albumin	30 g/l
Random glucose	18 mmol/l

3-day faecal fat excretion 21 g/day = 63 g total (normal < 30 g/3 days)

Which of the following is the most likely cause of his symptoms?

A	Alcohol abuse
B	Haemochromatosis
C	Sclerosing cholangitis
D	Gastric carcinoma
E	Coeliac disease

33036

Audio Video Share Participants 1 More

1:44
On
820-068-1014
End

A Alcohol abuse

In view of this man's history, the most likely diagnosis is recurrent pancreatitis secondary to alcohol abuse or gallstones. Alcohol is a cause of chronic pancreatitis, whereas gallstones may be associated with recurrent acute pancreatitis. Other causes of chronic pancreatitis include cystic fibrosis, haemochromatosis and sclerosing cholangitis. Chronic pancreatitis is an inflammatory condition which is characterised by irreversible damage to both the exocrine and endocrine pancreas. This patient's faecal fat excretion is high (> 30 g/3 days) indicating pancreatic enzyme insufficiency. This is further supported by an elevated random glucose consistent with a diagnosis of Type II diabetes mellitus. Initial further investigations in this patient should include abdominal ultrasound and, if indicated, endoscopic retrograde cholangiopancreatography. Chronic

Audio
Video
Share
Participants
More

1:45
On
820-068-1014
End

Coeliac disease is a possible differential, but given the duration of symptoms, more pronounced anaemia and associated conditions such as dermatitis herpetiformis would be expected.

B Haemochromatosis

There is an absence of other symptoms of haemochromatosis including increased pigmentation, endocrine dysfunction and costochondritis, and presentation at an age earlier than 64 years would be expected.

C Sclerosing cholangitis

Primary sclerosing cholangitis is strongly associated with inflammatory bowel disease, and usually presents at an earlier age than 64 years.

D Gastric carcinoma

Audio
Video
Share
Participants
1
More

A 32-year-old nurse presents with iron deficiency anaemia. She prefers mainly white meat and fish, but claims that her diet is sufficiently varied. She also reports frequent diarrhoea and weight loss of 6 kg in the past year.

On examination, her body mass index (BMI) is 22, but no other abnormalities are found.

Investigations:

Hb	10.4 g/dl
MCV	80 fl (76–96)
Serum ferritin	14 µg/l (15–300)
Serum folate	1.4 µg/l (2–11)
Albumin	34 g/l (37–49)
IgG	15 g/l (6–13)

1:48
On 820-068-1014 End

IgA	3.8 g/l (0.8–3.0)
IgM	2.6 g/l (0.4–2.5)

An OGD is performed, which shows some mild duodenitis. Small bowel biopsies are taken and are reported as showing subtotal villous atrophy.

What is the most likely diagnosis?

A Coeliac disease

B Crohn's disease

C Small bowel lymphoma

D Whipple's disease

E Small intestinal bacterial overgrowth

Audio Video Share Participants 1 More

1:50
On
820-068-1014
End

A Coeliac disease

Coeliac disease is characterised by diarrhoea and malabsorption precipitated by sensitivity to gliadin, a protein fraction of gluten found in wheat, rye, barley and oats. Peaks of incidence occur in the third and seventh decades, there is a slight female preponderance and incidence is increased in Caucasian populations. Diagnosis is made by testing for tissue transglutaminase antibody (TTG) or small bowel biopsy, which shows the classical appearance of subtotal villous atrophy. Coeliac is also an important cause of iron deficiency anaemia caused by malabsorption of iron, as seen in this patient. Therefore, Option A is correct as it best fits the clinical picture and biopsy findings. Note that this patient has a normocytic anaemia, as she is both iron deficient (microcytic) and folate deficient (macrocytic) giving an overall normocytic picture. Treatment for coeliac is avoidance of gluten-containing foods.

Audio
Video
Share
Participants
1
More

1:51
On 820-068-1014 End

transmural inflammation. This may also be associated with aphthous ulcers in the mouth.

C	Small bowel lymphoma

This is extremely rare, and usually occurs in older individuals and one would expect to see abnormal plasma cells on biopsy such as abnormal T-cell proliferation.

D	Whipple's disease

This is a rare malabsorptive disease caused by the bacterium *Tropheryma whipplei* and occurs in conjunction with neurological, cardiac or rheumatological sequelae. This patient did not elicit any of these symptoms.

E	Small intestinal bacterial overgrowth

This usually gives a high folate as a result of

Audio Video Share Participants 1 More

1:51
On
820-068-1014
End

A 45-year-old banker is referred by his general practitioner with abnormal liver function tests. He had a heart attack 2 years ago and is regularly seen in the Diabetic Clinic for poor glycaemic control. He currently takes metformin, atenolol and atorvastatin. He drinks socially and smokes 10 cigarettes per day. There is no history of blood transfusion or drug abuse.

On examination, he is overweight and there is an enlarged, non-tender liver. Ultrasound scan of the liver is reported as showing a generalised, hyper-echogenic appearance with no focal lesions.

Investigations:

Hb	13 g/dl
WBC	8.0×10^9/l
Platelets	240×10^9/l

Audio
Video
Share
Participants
1
More

Sodium	136 mmol/l
Potassium	3.7 mmol/l
Urea	9.0 mmol/l
Creatinine	90 µmol/l
Albumin	39 g/l
ALT	96 U/l (5–35)
AST	70 U/l (10–40)
ALP	135 U/l (30–150)
Hepatitis and autoimmune serology	Negative
Ferritin	Normal

What is the most likely diagnosis?

Ahmed's screen

ALP	135 U/l (30–150)
Hepatitis and autoimmune serology	Negative
Ferritin	Normal

What is the most likely diagnosis?

A Drug-induced hepatitis

B Non-alcoholic steatohepatitis

C Alcoholic-induced hepatitis

D Chronic active hepatitis

E Amyloidosis

Ahmed's screen

1:54

B Non-alcoholic steatohepatitis

Most patients with non-alcoholic steatohepatitis (NASH) are asymptomatic. The condition is usually discovered incidentally after abnormal liver tests. Diffuse fatty change can be detected on ultrasonography as a hyper-echogenic appearance. It is part of a metabolic syndrome and is commonly associated with obesity, diabetes mellitus, hypercholesterolaemia and drugs. In patients with NASH, the ratio of aspartate aminotransferase (AST) to alanine aminotransferase (ALT) is usually <1, whereas in alcoholic liver disease the ratio is usually >2. Liver biopsy reveals macrovesicular steatosis. Treatment is that of underlying cause, encouraging moderate weight loss, exercise, improved diabetic control, treatment of hyperlipidaemia and avoidance of alcohol. Bariatric surgery is perhaps the best therapeutic modality in the presence of severe obesity.

Ahmed's screen

the history, and viral serology is negative.

E	Amyloidosis

Hepatic amyloidosis occurs in the setting of primary (AL) or secondary (AA) amyloidosis. Hepatomegaly is present in 80% of patients, but one would expect the presentation to include other signs and symptoms of systemic illness such as weight loss, abdominal pain, anorexia, ascites, peripheral oedema and splenomegaly. Alkaline phosphatase (ALP) is frequently raised. Ultrasonographic findings of hepatic amyloidosis include heterogeneous echogenicity. The diagnosis of gastrointestinal amyloid requires a tissue biopsy with positive staining of amyloid by Congo red or the presence of amyloid fibrils on electron microscopy.

7385

Rate this question:

Ahmed's screen

You are asked to review a 65-year-old retired politician in the Coronary Care Unit who was admitted 6 days ago with a non ST elevation myocardial infarction (NSTEMI).

On admission, he was haemodynamically stable and apyrexial. He developed atrial fibrillation 24 h after admission and was commenced on intravenous digoxin.

On questioning, he complains of severe abdominal pain, which is initially dull in nature but has now become sharp and radiates to his back. This pain is precipitated by meals and he finds it worse after food. He has never had similar symptoms previously and denies any chest pain. His drug chart shows that he is currently on aspirin, clopidogrel, digoxin, low molecular weight heparin, atorvastatin, omeprazole and regular salbutamol inhalers.

He was diagnosed with non-insulin-

shows that he is currently on aspirin, clopidogrel, digoxin, low molecular weight heparin, atorvastatin, omeprazole and regular salbutamol inhalers.

He was diagnosed with non-insulin-dependent diabetes 6 years ago, and had an inferior myocardial infarction 2 years after that. There is a strong family history of ischaemic heart disease. He is also hypertensive and has mild chronic obstructive airway disease. He smokes 20 cigarettes per day and drinks a glass of brandy in the evening.

On examination, he looks pale and unwell. He has xanthelasma. His heart rate is 120 beats/min and regular and blood pressure 100/60 mmHg. His temperature is 37.5 °C and saturation is 98% on 2 l oxygen. The jugular venous pressure is not visible and there is a soft systolic murmur at the apex. He has a left carotid bruit. There are sparse bibasal crackles on chest examination. His abdomen is tender in the epigastric and

that. There is a strong family history of ischaemic heart disease. He is also hypertensive and has mild chronic obstructive airway disease. He smokes 20 cigarettes per day and drinks a glass of brandy in the evening.

On examination, he looks pale and unwell. He has xanthelasma. His heart rate is 120 beats/min and regular and blood pressure 100/60 mmHg. His temperature is 37.5 °C and saturation is 98% on 2 l oxygen. The jugular venous pressure is not visible and there is a soft systolic murmur at the apex. He has a left carotid bruit. There are sparse bibasal crackles on chest examination. His abdomen is tender in the epigastric and umbilical area. There is no palpable aortic aneurysm or ascites. Scanty bowel sounds are audible.

Investigations are as below:

Hb	11.0 g/dl

MCV	93 fl
INR	1.3
Na^+	141 mmol/l
K^+	5.3 mmol/l
Urea	14.0 mmol/l
Creatinine	147 μmol/l
Bicarbonate	15 mmol/l
C-reactive protein	34 mg/l (0-1)
Liver function tests	Normal
Amylase	380 IU
Electrocardiogram	Sinus tachycardia and Q waves on inferior leads
Chest and abdominal radiographs	Normal

E CT scan of the abdomen with angiography

CT scan of the abdomen with angiography. The combination of acute abdominal pain 15-30 min post-meal, relative hypotension (note normal hypertensive) and acidosis all point towards acute mesenteric ischaemia. The condition is often associated with modest elevations in amylase. He is diabetic, a long-term smoker and has had a cardiac event in the past. All these favour atherosclerosis, making the diagnosis of intestinal ischaemia more likely in this situation, although other differential diagnosis includes acute or chronic pancreatitis. Carcinoma of the pancreas normally has a more insidious onset. Increased intestinal motility after a meal exacerbates ischaemia, causing pain. Mesenteric ischaemia is essentially a diagnosis of exclusion. In this situation a computed tomography (CT) scan will help exclude necrosis of the pancreas, and mesenteric angiography would help validate

the past. All these favour atherosclerosis, making the diagnosis of intestinal ischaemia more likely in this situation, although other differential diagnosis includes acute or chronic pancreatitis. Carcinoma of the pancreas normally has a more insidious onset. Increased intestinal motility after a meal exacerbates ischaemia, causing pain. Mesenteric ischaemia is essentially a diagnosis of exclusion. In this situation a computed tomography (CT) scan will help exclude necrosis of the pancreas, and mesenteric angiography would help validate the clinical suspicion of mesenteric ischaemia. The patient will probably need a laparotomy, which will be high risk in view of recent coronary event, but mortality is extremely high without surgery. An arterial blood gas will no doubt show a metabolic acidosis, and amylase can be normal in chronic pancreatitis.

A Blood cultures

A 42-year-old publican with a 6-year history of chronic liver disease secondary to alcohol abuse presents with increased abdominal pain, swelling and confusion.

On examination, there is jaundice with spider naevi and finger clubbing. His temperature is 37.2 °C with a blood pressure of 115/75 mmHg. There is gynaecomastia with obvious abdominal distension due to ascites. This was surprising as he had therapeutic drainage of his ascites a few days earlier.

He has been using occasional 'painkillers' for his pain. He thought to be allergic to both penicillin and tramadol.

Investigations:

Hb	14.4 g/dl
WCC	$10.2 \times 10^9/l$
PLT	$124 \times 10^9/l$

Investigations:

Hb	14.4 g/dl
WCC	10.2×10^9/l
PLT	124×10^9/l
Na^+	129 mmol/l
K^+	4.2 mmol/l
Creatinine	100 µmol/l
Glucose	4.9 mmol/l
Bilirubin	95 µmol/l
AST	145 IU/l
ALT	125 IU/l
ALP	440 IU/l
GGT	490 IU/l
Amylase	450 IU/l
Urea	6.8 mmol/l

Amylase	450 IU/l
Urea	6.8 mmol/l

Ascitic tap revealed a neutrophil count of 300 cells per mm^3 in the ascitic fluid.

Which of the following represents the best initial management for this patient?

A	IV ciprofloxacin and vancomycin
B	IV cefotaxime
C	Naloxone
D	Thiamine
E	Ascitic drain

E Ascitic drain

Explanation

A IV ciprofloxacin and vancomycin

The diagnosis is spontaneous bacterial peritonitis (SBP), which is said to occur in 8% of patients with cirrhosis and ascites. Most frequently implicated bacteria are *E. coli*, *Klebsiella* and enterococci. The condition carries a 25% mortality and has a 70% recurrence rate within one year. Patients in whom SBP occurs should be considered for liver transplant. IV ciprofloxacin and vancomycin are an effective dual therapy approach for patients with penicillin allergy.

B IV cefotaxime

Given we aren't aware of the severity of this patient's penicillin allergy, and there is

A 48-year-old man presents with a long history of dysphagia. For the past 12–18 months he has suffered dysphagia to both liquids and solids, and regurgitation of undigested food. He has only lost approximately 2 kg in weight over the past year.

A few months ago, he was prescribed a salbutamol inhaler for nocturnal cough and shortness of breath.

Clinical examination reveals wheeze. His blood pressure is 132/82 mmHg, with pulse 70/min and regular. His BMI is 28. Full blood count, urea and electrolytes, liver function tests and viscosity are normal.

Which of the following would be the initial investigation of choice in this case?

A	Abdominal X-ray
B	Barium swallow
C	Upper gastrointestinal endoscopy

cough and shortness of breath.

Clinical examination reveals wheeze. His blood pressure is 132/82 mmHg, with pulse 70/min and regular. His BMI is 28. Full blood count, urea and electrolytes, liver function tests and viscosity are normal.

Which of the following would be the initial investigation of choice in this case?

A	Abdominal X-ray
B	Barium swallow
C	Upper gastrointestinal endoscopy
D	Manometry
E	Barium follow-through

33066

B Barium swallow

The long history in this case, coupled with the normal blood results and dysphagia to both liquids and solids, is suggestive of a non-sinister cause. Barium swallow would be the investigation of choice to demonstrate any oesophageal dilatation or dysmotility and to exclude other causes. Where the result is inconclusive, manometry or endoscopy may be helpful. Given the long history of symptoms, achalasia is a definite possibility, with a tapering bird's beak appearance being the typical appearance on barium swallow. This disease is thought to result from viral or autoimmune destruction of the oesophageal myenteric plexus. Botulinum toxin is a successful medical therapy for this condition; surgical approaches may be used in those patients who fail to respond to medical treatment.

D Manometry

Manometry is useful in cases where the diagnosis is difficult. It demonstrates high intra-oesophageal resting pressure, high lower oesophageal sphincter pressure and inadequate relaxation of the lower oesophageal sphincter after swallow.

A Abdominal X-ray

Plain abdominal X-ray is insensitive with respect to excluding achalasia or a malignant oesophageal lesion, and is therefore not recommended here.

C Upper gastrointestinal endoscopy

Upper GI endoscopy should follow barium swallow, because if achalasia is suspected, botulinum toxin could be made available for therapy at the same time.

Plain abdominal X-ray is insensitive with respect to excluding achalasia or a malignant oesophageal lesion, and is therefore not recommended here.

C	Upper gastrointestinal endoscopy

Upper GI endoscopy should follow barium swallow, because if achalasia is suspected, botulinum toxin could be made available for therapy at the same time.

E	Barium follow-through

Barium follow-through is useful for diagnosing small bowel pathology rather than an underlying oesophageal lesion.

33066

Rate this question:

Next Question

A 32-year-old bar owner returns from Spain and requires emergency consultation in the clinic. He feels lethargic and has not been able to maintain an adequate erection during intercourse or masturbation during the past few months. This is causing some marital difficulties. He also complains of swelling of his ankles and swelling around the abdomen.

On examination, he appears tanned, there is a paucity of underarm and genital hair and he has evidence of chronic liver disease and testicular atrophy. Past history of note includes arthritis and joint pain. He admits to drinking 12 units/standard drinks of alcohol per week (glass of wine or half pint of beer).

Investigations reveal:

Glucose (fasting)	8.2 mmol/l
ALT	183 U/l
Bilirubin	125 μmol/l

Which of the following represents the

pint of beer).

Investigations reveal:

Glucose (fasting)	8.2 mmol/l
ALT	183 U/l
Bilirubin	125 μmol/l

Which of the following represents the most likely diagnosis in this case?

A Wilson's disease

B Haemochromatosis

C Alcoholic cirrhosis

D Infective hepatitis

E Drug induced hepatitis

33049

Submit

B Haemochromatosis

Symptoms of haemochromatosis usually begin in males aged between 30 and 50 years and include increased skin pigmentation (due to iron deposition and melanin), cirrhosis, diabetes mellitus, arthropathy, impotence in males and heart failure. Previously, liver biopsy with total hepatic iron estimation was considered the gold standard test for haemochromatosis. Now however, genetic screening for the two identified mutations is seen as the next investigation of choice after transferrin saturation estimation. Around 10% of the Northern European population are heterozygous for each mutation, (so called compound heterozygotes), and this may account for accelerated deterioration of liver function in patients with moderate alcohol intake corresponding to 15-30 standard drinks (units) per week.

A Wilson's disease

A 56-year-old man presents with a Glasgow Coma Scale (GCS) of 5/15 after being found on the floor by his neighbour. The only past medical history available is that he has chronic hepatitis C.

Medication found in his bag includes tramadol, diclofenac and furosemide. His temperature is 38.0 °C.

Blood pressure is 100/60 mmHg, with pulse 120/min. Heart sounds are normal. There are coarse crackles at his right lung base. His abdomen is distended, with shifting dullness. His pupils are equal and reactive and the plantar responses are flexor.

He is transferred to the Intensive Care Unit and receives fluid resuscitation and broad-spectrum antibiotics for his chest. All his usual medications are stopped.

Investigations:

Hb	13.0 g/dl

Investigations:

Hb	13.0 g/dl
WCC	13.0×10^9/l
PLT	134×10^9/l
Na^+	137 mmol/l
K^+	3.4 mmol/l
Creatinine	130 μmol/l
MCV	101 fl
INR	1.6
Urea	11.0 mmol/l
Bilirubin	38 μmol/l
ALT	88 U/l (5-35)
ALP	235 U/l (30–150)
Albumin	32 g/l
Urinalysis	No blood or protein
Computed tomography scan of brain	Cerebral atrophy; no intracerebral haemorrhage or lesions

Computed tomography scan of abdomen	Free fluid in pelvis; cirrhotic liver

Three days later, he becomes oliguric. Ultrasound scan shows no evidence of ureteric obstruction. He has become apyrexial.

Repeat renal function tests:

Na^+	128 mmol/l
K^+	3.2 mmol/l
Urea	25.0 mmol/l
Creatinine	300 μmol/l
Urinary Na^+	8.0 mmol/l
Blood culture	-
Ascitic tap	Polymorphic neutrophil count 30 cells/mm^3; no organisms

culture	
Ascitic tap	Polymorphic neutrophil count 30 cells/mm^3; no organisms

What is the most likely diagnosis for his worsening renal function?

A	Septicaemia
B	Drug-induced acute kidney disease
C	Hepatitis B-related membranous glomerulonephritis
D	Acute tubular necrosis
E	Hepatorenal syndrome

8486

Submit

E Hepatorenal syndrome

This is usually a diagnosis of exclusion, after other potential causes of acute kidney disease have been ruled out.

The raised white cell count and initial pyrexia are in keeping with likely chest infection, which has been treated.

Hepatorenal syndrome refers to the development of acute kidney disease in a patient who has advanced liver disease, due to cirrhosis, and who has no identifiable cause of intrinsic renal disease. It usually represents the end stage of a sequence of reductions in renal perfusion induced by increasingly severe hepatic injury. Splanchnic vasodilatation appears to play an important role in the decline in renal function in hepatic disease.

The following definition and diagnostic criteria have been proposed for hepatorenal syndrome:

(a) chronic or acute hepatic disease with advanced hepatic failure and portal hypertension;

hepatorenal syndrome:

(a) chronic or acute hepatic disease with advanced hepatic failure and portal hypertension;

(b) a plasma creatinine concentration >133 μmol/l that progresses over days to weeks;

(c) the absence of any other apparent cause for the renal disease, including shock, active sepsis, current nephrotoxic drugs and the absence of ultrasonographic evidence of obstruction or parenchymal renal disease. It is particularly important to exclude spontaneous bacterial peritonitis, which is complicated with acute kidney disease;

(d) a urine sodium concentration <10 meq/l (off diuretics) and protein excretion <500 mg/day;

(e) lack of improvement in renal function after volume expansion with 1.5 l of isotonic saline.

D Acute tubular necrosis

Acute tubular necrosis is associated with increased renal sodium excretion; urinary sodium here is 8.0 mmol/l, which is in the normal range.

A	Septicaemia

The fact that this patient is now apyrexial makes continued septicaemia very unlikely as the cause of his kidney disease.

B	Drug-induced acute kidney disease

Although both diclofenac and furosemide can exacerbate renal impairment, his chronic liver disease is the much greater contributor to renal dysfunction seen here.

C	Hepatitis B-related membranous glomerulonephritis

Urinalysis is negative for urine sediment containing red cells or casts.

A 29-year-old woman with a history of Crohn's disease presents to the clinic with worsening abdominal pain and diarrhoea. She has undergone multiple surgical procedures over the years for fistulae and abscesses, and now takes 15 mg of prednisolone daily for her Crohn's.

On examination, she looks tired and in pain. Her abdomen has multiple scars from previous surgical procedures and although it is soft, she complains of some tenderness.

Investigations:

Hb	10.0 g/dl
WCC	8.9×10^9/l
PLT	156×10^9/l
Na^+	139 mmol/l
K^+	4.0 mmol/l

	mmol/l
Creatinine	100 µmol/l
MCV	106 fl
ESR	56 mm/h
Thiopurine methyl-transferase (TPMT)	Activity low

Which of the following represents the most appropriate option for her?

A	Laparoscopy with a view to further bowel resection
B	Elemental diet
C	Methotrexate
D	Azathioprine
E	Infliximab

E Infliximab

Anti-TNF therapy is an option for Crohn's disease that is resistant to other interventions, particularly where there is fistulating disease. Patients should of course have TB excluded before therapy is commenced.

A Laparoscopy with a view to further bowel resection

Given Crohn's has a high incidence of recurrence and affects both the large and small bowel, surgery should be avoided if possible.

B Elemental diet

Elemental diet has mixed results in Crohn's disease, with only some studies demonstrating a positive impact on symptoms and disease activity.

C Methotrexate

Crohn's disease, with only some studies demonstrating a positive impact on symptoms and disease activity.

C Methotrexate

Methotrexate is appropriate for patients with steroid-resistant disease who cannot take azathioprine, although infliximab is a better choice for patients like this one who have fistulating disease.

D Azathioprine

Azathioprine is not recommended in patients with low TMPT activity because of the risk of significant bone marrow suppression due to mercaptopurine toxicity.

20546

Rate this question:

A 34-year-old woman with no previous significant medical history presents for review.

Medication history includes the oral contraceptive pill and she smokes 15 cigarettes per day and drinks 15 units per week. She complains of vague upper abdominal pain, worse on the right-hand side.

On examination, there is a palpable non-tender mass in the right hypochondrium. Investigations reveal mild elevations in aspartate aminotransferase (AST) and alanine aminotransferase (ALT); alpha-fetoprotein is within the normal range. Hepatic ultrasound scan reveals a solitary mass in the left lobe of the liver, which is hypoechoic and subcapsular.

Which of the following diagnoses fits best with this clinical picture?

A	Hepatic adenoma
B	Hepatocellular carcinoma

hypochondrium. Investigations reveal mild elevations in aspartate aminotransferase (AST) and alanine aminotransferase (ALT); alpha-fetoprotein is within the normal range. Hepatic ultrasound scan reveals a solitary mass in the left lobe of the liver, which is hypoechoic and subcapsular.

Which of the following diagnoses fits best with this clinical picture?

A	Hepatic adenoma
B	Hepatocellular carcinoma
C	Liver metastasis
D	Hydatid cyst
E	Focal nodular hyperplasia

33051

Submit

review.

Medication history includes the oral contraceptive pill and she smokes 15 cigarettes per day and drinks 15 units per week. She complains of vague upper abdominal pain, worse on the right-hand side.

On examination, there is a palpable non-tender mass in the right hypochondrium. Investigations reveal mild elevations in aspartate aminotransferase (AST) and alanine aminotransferase (ALT); alpha-fetoprotein is within the normal range. Hepatic ultrasound scan reveals a solitary mass in the left lobe of the liver, which is hypoechoic and subcapsular.

Which of the following diagnoses fits best with this clinical picture?

Your answer was correct

A Hepatic adenoma

B Hepatocellular carcinoma

A Hepatic adenoma

This woman has a history of use of the oral contraceptive pill, with an asymptomatic liver mass. It is hypoechoic and subcapsular, appearing uniform in texture. The presence of a normal alpha-fetoprotein makes hepatocellular carcinoma unlikely; therefore, the most likely diagnosis is hepatic adenoma. Stopping the oral contraceptive pill often causes tumour regression, although complete regression is very atypical. Any tumour regression reduces risks associated with elective surgical resection; although mortality associated with resection is very rare, surgery results in significant morbidity in around 13% of patients. In patients who experience some regression after stopping the pill, there is still a risk of malignant transformation, and such patients should be monitored with alpha-fetoprotein measurement if they are unwilling or unable to undergo elective tumour resection.

B Hepatocellular carcinoma

Hepatocellular carcinoma is usually seen against a background of chronic liver disease with cirrhosis, and is associated with rapid worsening of ascites with elevation in alpha-fetoprotein.

C Liver metastasis

Liver metastases are usually characterised by more than one lesion, and the absence of other symptoms of cancer, makes this a much less likely diagnosis.

D Hydatid cyst

Hydatid disease appears as a multi-loculated cyst on ultrasound scan rather than the hypoechoic mass which isn't multi-loculated here.

E Focal nodular hyperplasia

cancer, makes this a much less likely diagnosis.

D	Hydatid cyst

Hydatid disease appears as a multi-loculated cyst on ultrasound scan rather than the hypoechoic mass which isn't multi-loculated here.

E	Focal nodular hyperplasia

The echogenicity of both FNH and its scar is variable, which makes it difficult to detect on ultrasound. Some lesions are well demarcated and easily seen whereas others are isoechoic with surrounding liver. Detectable lesions characteristically will demonstrate a central scar with the displacement of peripheral vasculature on colour doppler examination, rather than the well demarcated hypoechoic lesion seen here.

33051

Rate this question:

A 41-year-old nursing sister presents with right iliac fossa swelling and fullness. She has lost 3 kg in weight during the past 3 weeks and has recently returned from a spell in the tropics working for an aid agency.

A previous episode 23 years previously was diagnosed as colitis, when she was put on appropriate treatment that was discontinued spontaneously a few years ago. Since then she has suffered bouts of diarrhoea, which she has ignored.

Investigations:

Hb	10.0 g/dl
WCC	14×10^9/l
CRP	360 mg/l
PLTS	520×10^9/l

This acute event was treated and her symptoms settled.

Repeat investigations:

Hb	12.4 g/dl

Repeat investigations:

Hb	12.4 g/dl
WCC	11×10^9/l
CRP	30 mg/l
PLTS	380×10^9/l

A small bowel follow-through reveals a stricture of the terminal ileum with evidence of mucosal oedema.

Which of the following diagnoses fits best with this clinical picture?

A Crohn's disease

B Coeliac disease

C Tropical sprue

D Ulcerative colitis

E Whipple's disease

9:32
tps://mypastest.pastest.com

WCC	11 × 10⁹/l
CRP	30 mg/l
PLTS	380 × 10^9/l

A small bowel follow-through reveals a stricture of the terminal ileum with evidence of mucosal oedema.

Which of the following diagnoses fits best with this clinical picture?

Your answer was correct

A Crohn's disease

B Coeliac disease

C Tropical sprue

D Ulcerative colitis

E Whipple's disease

A Crohn's disease

The long history of this patient's bowel disease, the previous episode 23 years ago, the position of the abnormality seen on small bowel follow-through and the inflammatory picture during the acute episode all point towards this diagnosis. The aetiology of Crohn's disease is still a subject for debate – genetic and infectious aetiologies have been postulated but a definitive answer is still awaited. It may involve any part of the gastrointestinal tract and is characterised by transmural inflammation that need not be continuous, producing so called 'skip lesions'. The right iliac fossa swelling seen here may be indicative of abscess formation. The mainstay of medical therapy is the use of corticosteroids and sparing agents such as azathioprine.

B Coeliac disease

Coeliac disease is a common and

B	Coeliac disease

Coeliac disease is a common and underdiagnosed condition, which may present at any age. It is a hypersensitivity to gluten found in wheat, rye and barley. The gliadin fraction of the protein provokes an inflammatory response causing subtotal or total villous atrophy of the small bowel resulting in malabsorption. It classically presents with a history of diarrhoea, weight loss, oral ulceration, lethargy and anaemia (folate, B_{12} or iron-deficient). There is an association with dermatitis herpetiformis, a very pruritic polymorphic skin rash, and an increased risk of developing gastrointestinal malignancy. Treatment is by maintaining a strict diet avoiding foods containing wheat, rye, oats or barley. The small bowel follow-through results do not suggest this diagnosis.

C	Tropical sprue

C	Tropical sprue

Tropical sprue is a chronic diarrhoeal disease, possibly of infectious origin, that involves the small intestine and is characterised by malabsorption of nutrients, especially folic acid and vitamin B_{12}. Signs and symptoms of malabsorption are common, and include glossitis and cheilitis, protuberant abdomen and pedal oedema. Radiologic examinations of the small intestine in tropical sprue reveal non-specific changes of dilation, thickening and oedema of mucosal folds, and retention or secretion of fluid in the lumen which dilutes the barium column during its passage through the small intestine. These changes are non-specific and are also described in coeliac disease, olmesartan-associated enteropathy, scleroderma and hypoalbuminaemia and anasarca of any aetiology. The signs and symptoms with imaging results in this scenario do not fit with this diagnosis.

D	Ulcerative colitis

Ulcerative colitis is characterised by recurring episodes of inflammation limited to the mucosal layer of the colon. It commonly involves the rectum and may extend in a proximal and continuous fashion to involve other parts of the colon. Patients with ulcerative colitis usually present with diarrhoea, which may be associated with blood. Bowel movements are frequent and small in volume as a result of rectal inflammation. Associated symptoms include colicky abdominal pain, urgency, tenesmus and incontinence. Patients with mainly distal disease may have constipation accompanied by frequent discharge of blood and mucus. Double-contrast barium enema may be normal in mild ulcerative colitis. Findings on barium enema may include a diffusely reticulated pattern with superimposed punctate collections of barium in micro-ulcerations. The signs and symptoms with imaging results in this scenario do not fit with this diagnosis.

ulcerative colitis. Findings on barium enema may include a diffusely reticulated pattern with superimposed punctate collections of barium in micro-ulcerations. The signs and symptoms with imaging results in this scenario do not fit with this diagnosis.

E	Whipple's disease

Whipple's disease is caused by infection with *Tropheryma whippelii*. The organism can be identified by PAS staining of a jejunal biopsy. It is an uncommon condition classically affecting men aged 40–60 years. Gastrointestinal symptoms of diarrhoea, malabsorption and steatorrhoea are often preceded by arthropathy. The signs and symptoms with imaging results in this scenario do not fit with this diagnosis.

9296

Rate this question:

Next Question

A 63-year-old man with a history of COPD and severe arthritis presents to the Emergency Department of the university hospital with haematemesis. You get his old notes and find that his lung function is quite poor. He is managed with both salmeterol/fluticasone high-dose inhaler and tiotropium. Medication for his arthritis includes diclofenac.

On examination, he is very unwell, with a pulse of 105/min and BP of 85/50 mmHg. You resuscitate him with fluids and 2 units of blood and arrange an endoscopy; the endoscopist visualises a large bleeding duodenal ulcer, but he is unable to reach it properly to control the bleeding via the scope. The patient has a further large haematemesis.

Investigations:

Hb	8.9 g/dl
WCC	5.4×10^9/l
PLT	130×10^9/l
Na^+	138 mmol/l

Na^+	138 mmol/l
K^+	5.1 mmol/l
Creatinine	189 μmol/l
ECG	Lateral ST depression

Which of the following represents the most appropriate management in this case?

A	Further fluid resuscitation and delayed endoscopy
B	Progression to open surgery
C	Fluid resuscitation and IV pantoprazole
D	Angiography and selective embolization
E	Fluid resuscitation and IV terlipressin

COPD and severe arthritis presents to the Emergency Department of the university hospital with haematemesis. You get his old notes and find that his lung function is quite poor. He is managed with both salmeterol/fluticasone high-dose inhaler and tiotropium. Medication for his arthritis includes diclofenac.

On examination, he is very unwell, with a pulse of 105/min and BP of 85/50 mmHg. You resuscitate him with fluids and 2 units of blood and arrange an endoscopy; the endoscopist visualises a large bleeding duodenal ulcer, but he is unable to reach it properly to control the bleeding via the scope. The patient has a further large haematemesis.

Investigations:

Hb	8.9 g/dl
WCC	5.4×10^9/l
PLT	130×10^9/l
Na^+	138 mmol/l
K^+	5.1 mmol/l

D Angiography and selective embolization

This patient is a very poor surgical candidate, with severe COPD and an ECG which reveals signs of ischaemia, potentially related to hypovolaemia as a result of blood loss. In this situation a number of case series have demonstrated that selective arterial embolisation is an effective way to control bleeding from a duodenal ulcer, and leads to improved survival vs other potential interventions.

E Fluid resuscitation and IV terlipressin

IV terlipressin is of value in controlling bleeding from oesophageal varices, not as a result of peptic ulceration.

A Further fluid resuscitation and delayed endoscopy

This risks further catastrophic bleeding

A Further fluid resuscitation and delayed endoscopy

This risks further catastrophic bleeding from the duodenal ulcer.

B Progression to open surgery

Open surgery is not an option for this patient in his current state; he has an unstable blood pressure and is unlikely to avoid long-term ventilation because of his COPD.

C Fluid resuscitation and IV pantoprazole

Although acute use of PPIs does reduce the risk of re-bleeding in peptic ulcer disease, given the size of the ulcer and continued bleeding on endoscopy it's unlikely to impact here.

18657

Rate this question:

Next Question

A woman who is 30 weeks pregnant presents to her general practitioner (GP) complaining of itching, more intense over her palms and soles of her feet and worse at night.

On examination, she looks tired and has yellow sclerae. Her BP is 105/60 mmHg and she is apyrexial.

Investigations:

Hb	10.9 g/dl
WCC	6.7×10^9/l
PLT	167×10^9/l
Na^+	138 mmol/l
K^+	4.4 mmol/l
Creatinine	80 μmol/l
Bilirubin	11 μmol/l
Alanine aminotransferase (ALT)	670 U/l
Alkaline phosphatase	730 U/l
Gamma-glutamyl	210 U/l (4–

Bilirubin	11 μmol/l
Alanine aminotransferase (ALT)	670 U/l
Alkaline phosphatase	730 U/l
Gamma-glutamyl transferase	210 U/l (4–35 U/l)

Which of the following is the most likely diagnosis?

A HELLP

B Cholestasis of pregnancy

C Acute fatty liver of pregnancy

D Budd Chiari syndrome

E Viral hepatitis

B Cholestasis of pregnancy

Cholestasis of pregnancy is the correct answer as this patient's presentation most resembles the clinical picture. The condition is characterised by pruritus (typically starting on the palms and soles of the feet) with raised fasting and post-prandial serum bile acids. The condition occasionally presents with pale stool and dark urine. It typically presents within the third trimester and resolves up to 6 weeks postpartum. Treatment is for pruritus with ursodeoxycholic acid and rifampicin.

C Acute fatty liver of pregnancy

Pruritus is not a typical feature and the bilirubin would be abnormal. It is a rare and potentially fatal obstetric emergency that occurs in the third trimester. Presentation can be non-specific with nausea and vomiting, abdominal pain or acute liver failure in the most severe cases. Bilirubin and

the most severe cases. Bilirubin and transaminases tend to be significantly raised with a rise in WCC and hypoglycaemia/hyperlactaemia (hallmarks of acute liver failure).

A	HELLP

The platelet count and blood pressure are normal and pruritus is not a typical feature. HELLP syndrome is a hepatic manifestation of pre-eclampsia. This occurs after the 20th week of gestation and tends to occur in the presence of hypertension (> 140/90 mmHg). Thrombocytopenia occurs as a result of a microangiopathic haemolytic anaemia. This takes place within the sinusoids leading to congestion, hepatic ischaemia and a transaminitis.

D	Budd Chiari syndrome

It tends to present with acute abdominal pain and clinical features of portal hypertension. It is characterised by obstruction of the hepatic vein,

D	Budd Chiari syndrome

It tends to present with acute abdominal pain and clinical features of portal hypertension. It is characterised by obstruction of the hepatic vein, sinusoidal congestion and portal hypertension. Pregnancy is a hypercoagulable state and risk of Budd–Chiari is increased although remains rare. Most patients presenting with de novo occlusion tend to have an undiagnosed underlying thrombophilia and should be investigated.

E	Viral hepatitis

Typically one would expect to see an ALT >1000 U/l in viral hepatitis. Most viral hepatitis in pregnancy follows the same course as in the normal population but hepatitis E has an increased mortality in pregnancy and can lead to fulminant hepatic failure. Treatment is supportive.

21184

Rate this question:

A 27-year-old woman, who is 16 weeks pregnant, is referred for an opinion by the obstetricians because of recurrent vomiting. She had started vomiting early in her pregnancy and has not responded to treatment with anti-emetics. She now weighs 5 kg less than when she became pregnant.

Nasogastric and nasojejunal feeding were unsuccessful due to recurrent regurgitation of the tubes. Accordingly, total parenteral nutrition (TPN) was commenced. She also required supplemental intravenous fluids due to recurrent vomiting.

Her blood tests were checked 72 hours after initiating TPN and were as follows:

Sodium	137 mmol/l
Potassium	2.9 mmol/l
Urea	2.4 mmol/l
Creatinine	69 μmol/l
Corrected calcium	2.2 mmol/l
Phosphate	0.3 mmol/l

Creatinine	69 µmol/l
Corrected calcium	2.2 mmol/l
Phosphate	0.2 mmol/l
Magnesium	0.4 mmol/l

What is the most likely explanation for these results?

A	Bloods taken from drip arm
B	Syndrome of inappropriate ADH secretion
C	Inappropriate intravenous fluid replacement
D	Refeeding syndrome
E	Vomiting-related electrolyte loss

recurrent vomiting.

Her blood tests were checked 72 hours after initiating TPN and were as follows:

Sodium	137 mmol/l
Potassium	2.9 mmol/l
Urea	2.4 mmol/l
Creatinine	69 µmol/l
Corrected calcium	2.2 mmol/l
Phosphate	0.2 mmol/l
Magnesium	0.4 mmol/l

What is the most likely explanation for these results?

Your answer was correct

A	Bloods taken from drip arm
B	Syndrome of inappropriate ADH secretion

D Refeeding syndrome

The refeeding syndrome is characterised by very marked shifts in fluid and electrolyte balance occurring during the early stages of reintroducing nutrition to malnourished people. Typical clinical features include deficiencies in all plasma electrolytes (particularly hypophosphataemia, hypokalaemia and hypomagnesaemia), vitamin deficiencies, and the occurrence of peripheral oedema.

The syndrome occurs as reintroduction of glucose/carbohydrate to malnourished people results in a surge in insulin production, which causes a shift of electrolytes into the intracellular space from the gut/serum; in addition, insulin also stimulates anabolic metabolic pathways.

The combination of rapid intracellular uptake of phosphate in combination with utilisation of the little phosphate available in the formation of metabolites that have previously been very depleted (e.g. generation of ATP)

metabolites that have previously been very depleted (e.g. generation of ATP) together rapidly depletes phosphate supplies, and hypophosphataemia quickly results if left unchecked. Similarly, vitamin supplies that are already depleted through malnutrition may become depleted even further as metabolic pathways begin to be activated.

The combination of serum electrolyte deficiencies and anaerobic metabolism that may occur in untreated refeeding syndrome may result in cardiac dysrhythmia and myocardial ischaemia, and sudden cardiac death is therefore the most feared complication.

Prevention of refeeding syndrome is the key to management. A graded re-introduction of calories – together with close monitoring and supplementing of electrolytes – is the mainstay of minimising the effect of the syndrome. Supplementation of vitamins is also paramount, with particular regard given to vitamin B1 supplementation to prevent Wernicke's encephalopathy or Korsakoff's syndrome

prevent Wernicke's encephalopathy or Korsakoff's syndrome.

A	Bloods taken from drip arm

Blood tests taken from the drip arm is possible, but not the most likely explanation within the scenario described.

B	Syndrome of inappropriate ADH secretion

Syndrome of inappropriate ADH secretion could explain certain aspects of her blood tests, but would not explain why she is deficient in all electrolytes.

C	Inappropriate intravenous fluid replacement

Inappropriate intravenous fluid replacement could explain certain aspects of her blood tests, but would not explain why she is deficient in all

C	Inappropriate intravenous fluid replacement

Inappropriate intravenous fluid replacement could explain certain aspects of her blood tests, but would not explain why she is deficient in all electrolytes.

E	Vomiting-related electrolyte loss

Vomiting-related electrolyte loss could explain certain aspects of her blood tests, but would not explain why she is deficient in all electrolytes.

70160

Rate this question:

A 56-year-old man is admitted directly to the high-dependency unit with suspected acute pancreatitis. This is his third attack over the past 3 years and he is recognised to have a history of alcohol abuse.

On examination, his blood pressure (BP) is 100/60 mmHg, his pulse is 100/min and regular, he is pyrexial 37.8 °C and complaining of severe epigastric pain. His amylase is confirmed at 1450 U/l. Other bloods are in progress.

Which of the following features would be consistent with severe pancreatitis?

A	Calcium 2.1 mmol/l
B	Albumin 34 g/l
C	Lactate dehydrogenase (LDH) 620 U/l
D	Amylase 1450 U/l

On examination, his blood pressure (BP) is 100/60 mmHg, his pulse is 100/min and regular, he is pyrexial 37.8 °C and complaining of severe epigastric pain. His amylase is confirmed at 1450 U/l. Other bloods are in progress.

Which of the following features would be consistent with severe pancreatitis?

A	Calcium 2.1 mmol/l
B	Albumin 34 g/l
C	Lactate dehydrogenase (LDH) 620 U/l
D	Amylase 1450 U/l
E	Urea 14 mmol/l

32376

Submit

3G 10:22

PANCREAS

PANCREAS

P	PaO2 <8 kPa
A	Age >55 years old
N	Neutrophilia: WCC >15 × 109/l
C	Calcium <2 mmol/l
R	Renal function: Urea >16 mmol/’
E	Enzymes: LDH >600 IU/l or AST >200 IU/
A	Albumin <32 g/l (serum)
S	Sugar: blood glucose >10 mmol/l

Close

B	Albumin 34 g/l

A serum albumin <32 g/l would be consistent with a severe pancreatitis if seen in conjunction with two other factors in the Glasgow Prognostic Score.

C Lactate dehydrogenase (LDH) 620 U/l

The Glasgow Prognostic Score is closely linked to outcomes and prognosis. Three or more of these factors indicate severe **pancreatitis** and should prompt consideration for referral to a higher dependency setting.

A Calcium 2.1 mmol/l

A calcium level <2 mmol/l would be consistent with a severe pancreatitis if seen in conjunction with two other factors in the Glasgow Prognostic Score.

B Albumin 34 g/l

A serum albumin <32 g/l would be consistent with a severe pancreatitis if seen in conjunction with two other factors in the Glasgow Prognostic Score.

A 62-year-old man presents to the Emergency Room with deep jaundice, drowsiness and confusion. He has been increasingly unwell for the past 3 months, and an ultrasound of his abdomen from 2 weeks earlier demonstrated a mass in the head of the pancreas, a degree of biliary obstruction and probable metastases within the liver substance itself.

On examination, he is drowsy and confused, his temperature is 37.8 °C, his BP is 100/60 mmHg with a pulse of 85/min, there are a number of scratch marks on his skin and he is deeply jaundiced. He is tender in the epigastrium and you can feel a liver edge.

Investigations:

Hb	10.1 g/dl
WCC	8.2×10^9/l
PLT	102×10^9/l
Na^+	137 mmol/l
K^+	4.0 mmol/l

Na	137 mmol/l
K^+	4.0 mmol/l
Creatinine	130 μmol/l
ALT	105 U/l
Bilirubin	280 μmol/l
ALP	485 U/l

Which of the following is the most important intervention here?

A	Oral ciprofloxacin
B	Percutaneous trans-hepatic cholangiography (PTC) tube
C	Choledochojejunostomy
D	Whipple's procedure
E	Endoscopic retrograde cholangiopancreatography (ERCP) with stenting

demonstrated a mass in the head of the pancreas, a degree of biliary obstruction and probable metastases within the liver substance itself.

On examination, he is drowsy and confused, his temperature is 37.8 °C, his BP is 100/60 mmHg with a pulse of 85/min, there are a number of scratch marks on his skin and he is deeply jaundiced. He is tender in the epigastrium and you can feel a liver edge.

Investigations:

Hb	10.1 g/dl
WCC	8.2×10^9/l
PLT	102×10^9/l
Na^+	137 mmol/l
K^+	4.0 mmol/l
Creatinine	130 μmol/l
ALT	105 U/l
Bilirubin	280 μmol/l
ALP	485 U/l

E Endoscopic retrograde cholangiopancreatography (ERCP) with stenting

This patient has hepatic obstruction, as evidenced by his deep jaundice and obstructive picture on liver function testing. ERCP with stenting delivered at the same time is the preferred option here, and is likely to drive an improvement in symptoms for at least a few months.

A Oral ciprofloxacin

Ascending cholangitis is a possibility and would be used in combination with ERCP. They are not likely to be effective used in isolation.

B Percutaneous trans-hepatic cholangiography (PTC) tube

PTC is only indicated in the event that the obstruction cannot be relieved by ERCP alone.

PTC is only indicated in the event that the obstruction cannot be relieved by ERCP alone.

C	Choledochojejunostomy

Choledochojejunostomy is a potential alternative to ERCP, although this patient's advanced disease implies that even this procedure is not an option.

D	Whipple's procedure

Surgical resection will not be curative, carries a high operative risk and should be avoided here.

21019

Rate this question:

Next Question

A 67-year-old man of Irish descent presented to Outpatients with a 10-month history of right iliac fossa abdominal pain and watery diarrhoea up to 15 times a day. He had been a heavy drinker in the past, consuming 40 pints of beer a week, but had cut back to 1 pint a day for several years.

He had recently noticed that his symptoms became worse when drinking alcohol so has now stopped completely. His wife had noticed that that he has lost weight recently but he was unable to quantify this. He has never smoked but his wife has noticed that he has had some attacks of wheeziness.

Examination of his abdomen revealed 3 cm hepatomegaly and an indistinct mass in the right iliac fossa. Urea and electrolytes, liver function tests and full blood count were normal, but a small-bowel barium examination revealed a submucosal mass in the ileum.

What is the likely diagnosis?

that he has had some attacks of wheeziness.

Examination of his abdomen revealed 3 cm hepatomegaly and an indistinct mass in the right iliac fossa. Urea and electrolytes, liver function tests and full blood count were normal, but a small-bowel barium examination revealed a submucosal mass in the ileum.

What is the likely diagnosis?

A	Coeliac disease-related lymphoma
B	Chronic pancreatitis
C	Villous adenoma
D	Carcinoid syndrome
E	Immunoproliferative small intestinal disease

A 67-year-old man of Irish descent presented to Outpatients with a 10-month history of right iliac fossa abdominal pain and watery diarrhoea up to 15 times a day. He had been a heavy drinker in the past, consuming 40 pints of beer a week, but had cut back to 1 pint a day for several years.

He had recently noticed that his symptoms became worse when drinking alcohol so has now stopped completely. His wife had noticed that that he has lost weight recently but he was unable to quantify this. He has never smoked but his wife has noticed that he has had some attacks of wheeziness.

Examination of his abdomen revealed 3 cm hepatomegaly and an indistinct mass in the right iliac fossa. Urea and electrolytes, liver function tests and full blood count were normal, but a small-bowel barium examination revealed a submucosal mass in the ileum.

What is the likely diagnosis?

Your answer was correct

D Carcinoid syndrome

Carcinoid tumours are neuroendocrine tumours that most commonly occur in the GI tract. They secrete many vasoactive molecules (particularly serotonin), which, in the absence of hepatic involvement, are metabolised in the liver. If these tumours metastasise to the liver, the liver's ability to break down the serotonin produced by these tumours may be overwhelmed; it may then enter the systemic circulation, and symptoms will subsequently develop.

It is the phalanx of symptoms produced through serotonin entering the circulation that defines the carcinoid syndrome. Of these symptoms, debilitating diarrhoea – often associated with abdominal pain – is the most common. Flushing (which commonly affects the neck and face) may be associated with wheezing, and telangiectases may result.

Alcohol and food intolerances, and exacerbations of symptoms by stress

Alcohol and food intolerances, and exacerbations of symptoms by stress and some drugs, are not uncommon. The classic cardiac findings are of right-sided heart disease, namely tricuspid incompetence or pulmonary stenosis. Examination often reveals hepatomegaly; imaging of the liver reveals metastatic disease.

Urinary levels of 5-hydroxyindoleacetic acid (5-HIAA) are normally increased. Treatment with somatostatin analogues (such as octreotide) may improve symptoms, and chemotherapy may also be helpful. Men and women are equally affected by carcinoid tumours, and presentation tends to occur between the ages of 50 and 75 years. Carcinoid tumours are mostly commonly found in the ileum and appendix, but can be located in many other sites, both intestinal and extra-intestinal. Approximately only one-third of tumours metastasise and, consequently, many are asymptomatic.

A	Coeliac disease-related lymphoma

lymphoma

Lymphoma is a recognised complication of coeliac disease, but his lack of GI symptoms prior to 10 months earlier makes underlying coeliac disease unlikely (although coeliac disease may be subclinical).

B Chronic pancreatitis

Chronic pancreatitis tends to cause upper abdominal pain and malabsorptive (as opposed to watery) diarrhoea. It is not likely to cause the associated symptoms described in the presentation.

C Villous adenoma

Villous adenomas of the rectum are not likely to cause the associated symptoms described in the presentation.

E Immunoproliferative small intestinal disease

diarrhoea. It is not likely to cause the associated symptoms described in the presentation.

C	Villous adenoma

Villous adenomas of the rectum are not likely to cause the associated symptoms described in the presentation.

E	Immunoproliferative small intestinal disease

IPSID is a proximal small bowel lymphoproliferative condition that tends to present with malabsorption and weight loss. As with coeliac disease, it may progress to lymphoma. It does not describe the full pattern of symptoms described in the scenario.

70169

Rate this question:

Next Question

A 55-year-old man was found on the street by the police. He complains of right upper quadrant pain and anorexia. He works at a building site but has recently lost his job.

On examination, he smells very strongly of alcohol. He has icteric sclera. His temperature is 37.6 °C. There is spider naevi and palmar erythema. Heart sounds and chest examination are unremarkable. Abdominal examination reveals dull flanks and a tender liver edge. There is no focal neurology but a hepatic flap is present.

Investigation results are as below:

Haemoglobin (Hb)	12.1 g/dl
White blood count (WBC)	17.0×10^9/l
Platelets	80×10^9/l
Mean cell volume (MCV)	103 fL
International normalised ratio (INR)	1.6
Na^+	132 mmol/l

ratio (INR)	
Na^+	132 mmol/l
K^+	3.3 mmol/l
Urea	1.7 mmol/l
Creatinine	70 µmol/l
Albumin	35 g/L
Bilirubin	102 µmol/l
Alanine aminotransferase (ALT)	45 U/l (5–35)
Aspartate aminotransferase (AST)	100 U/l (10–40)
Alkaline phosphatase (ALP)	156 U/l (30–150)
Ferritin	987 µg/l
Hepatitis and autoimmune serology	Negative

What is the most likely diagnosis?

A	Hepatoma

aminotransferase (AST)	(10–40)
Alkaline phosphatase (ALP)	156 U/l (30–150)
Ferritin	987 µg/l
Hepatitis and autoimmune serology	Negative

What is the most likely diagnosis?

A Hepatoma

B Alcoholic hepatitis

C Choledocholithiasis

D Viral hepatitis

E Haemochromatosis

7390

Submit

B Alcoholic hepatitis

Alcoholic hepatitis commonly occurs after a prolonged period of alcohol abuse or return to alcohol after period of abstinence. It often presents with malaise, anorexia, mild fever, tender hepatolomegaly, and (if severe) jaundice. Investigations usually reveal mildly increased serum transaminases, macrocytosis, thrombocytopenia, poor hepatic synthetic function, leukocytosis irrespective of infection and increased acute phase reactants. Usually the AST : ALT > 2.

The prognosis depends on its severity. Malnutrition, jaundice, fluid retention and encephalopathy are associated with poor outlook. Histology can help to confirm diagnosis.

The mainstay of treatment is supportive in nature:

- Alcohol abstinence
- Prevention and treatment of alcohol withdrawal
- Fluid management

- Prevention and treatment of alcohol withdrawal
- Fluid management
- Nutritional support
- Infection surveillance
- Prophylaxis against gastric mucosal bleeding

The discriminant function (DF) can be used to identify patients for treatment. Those who have a value > 32 may benefit from corticosteroids. If there is a contraindication to steroids, pentoxifylline is an alternative.

E	Haemochromatosis

There is no suggestion of other organ involvement, and haemochromatosis is less likely to explain the tender hepatomegaly, raised WCC, and mild fever. The raised ferritin in this case is likely due to alcoholic liver disease and not haemochromatosis.

A	Hepatoma

but has recently lost his job.

On examination, he smells very strongly of alcohol. He has icteric sclera. His temperature is 37.6 °C. There is spider naevi and palmar erythema. Heart sounds and chest examination are unremarkable. Abdominal examination reveals dull flanks and a tender liver edge. There is no focal neurology but a hepatic flap is present.

Investigation results are as below:

Haemoglobin (Hb)	12.1 g/dl
White blood count (WBC)	17.0×10^9/l
Platelets	80×10^9/l
Mean cell volume (MCV)	103 fL
International normalised ratio (INR)	1.6
Na^+	132 mmol/l
K^+	3.3 mmol/l
Urea	1.7 mmol/l

ratio (INR)	
Na^+	132 mmol/l
K^+	3.3 mmol/l
Urea	1.7 mmol/l
Creatinine	70 µmol/l
Albumin	35 gIL
Bilirubin	102 µmol/l
Alanine aminotransferase (ALT)	45 U/l (5–35)
Aspartate aminotransferase (AST)	100 U/l (10–40)
Alkaline phosphatase (ALP)	156 U/l (30–150)
Ferritin	987 µg/l
Hepatitis and autoimmune serology	Negative

What is the most likely diagnosis?

Your answer was incorrect

of alcohol, low-grade fever and high WCC, make alcoholic hepatitis a more likely cause.

C	Choledocholithiasis

Acute gallstone impaction in the common bile duct is likely to present with right upper quadrant pain, with possible complicating cholangitis causing a fever. But this would not account for the macrocytosis, signs of chronic liver disease, and decompensation with jaundice, ascites and asterixis.

D	Viral hepatitis

This could be the cause of chronic liver disease, which has now decompensated, but we are told that viral serology is negative.

7390

Rate this question:

A young man with known alcoholic cirrhosis presents saying that he has had black, foul-smelling stool after a week of binge drinking. He has had two such episodes. He has never had melaena before, but on ultrasound one year ago he was found to have mild splenomegaly and has recently had drainage of ascites.

He is refusing an oesophago-gastro-duodenoscopy (OGD) as he had a 'bad experience' before. However, he will undergo other investigations as necessary and will have an OGD if you can determine that he has had an upper gastrointestinal bleed. His haemoglobin is reduced significantly at 6.9 g/dl, and urea is significantly elevated. He is transfused with 4 units of packed cells and serum haemoglobin is re-checked.

Which of the following blood test results might you expect to see?

A	Reduced calcium vs baseline
B	Reduced potassium vs

upper gastrointestinal bleed. His haemoglobin is reduced significantly at 6.9 g/dl, and urea is significantly elevated. He is transfused with 4 units of packed cells and serum haemoglobin is re-checked.

Which of the following blood test results might you expect to see?

A	Reduced calcium vs baseline
B	Reduced potassium vs baseline
C	Elevated magnesium vs baseline
D	Reduced phosphate vs baseline
E	Moderate increase in serum albumin vs baseline

undergo other investigations as necessary and will have an OGD if you can determine that he has had an upper gastrointestinal bleed. His haemoglobin is reduced significantly at 6.9 g/dl, and urea is significantly elevated. He is transfused with 4 units of packed cells and serum haemoglobin is re-checked.

Which of the following blood test results might you expect to see?

Your answer was incorrect

A	Reduced calcium vs baseline
B	Reduced potassium vs baseline
C	Elevated magnesium vs baseline
D	Reduced phosphate vs baseline

A Reduced calcium vs baseline

Packed cells contain citrate as a buffer, which can result in a reduction in ionised calcium unless a citrate-free formulation of packed cells is used.

C Elevated magnesium vs baseline

Hypomagnesaemia is common in alcoholism and levels don't rise in association with blood transfusion.

B Reduced potassium vs baseline

After a blood transfusion, potassium is elevated due to red blood cell haemolysis in the transfusion. In chronic alcoholism *per se*, hypokalaemia is of course relatively more common.

D Reduced phosphate vs baseline

After a blood transfusion, potassium is elevated due to red blood cell haemolysis in the transfusion. In chronic alcoholism *per se*, hypokalaemia is of course relatively more common.

D	Reduced phosphate vs baseline

Hyperphosphatemia is the main consequence of large-volume blood transfusion.

E	Moderate increase in serum albumin vs baseline

Packed cells do not result in a significant change in serum albumin; for this, albumin infusions themselves are required.

33070

Rate this question:

Next Question

10:56
tps://mypastest.pastest.com

thinks she has lost some weight.

Examination of all systems is normal, and her blood test shows mild dehydration.

Her general practitioner (GP) referred her for a barium swallow, which is shown as below:

An endoscopy is arranged.

What further investigation will you consider before proceeding to treatment?

A 31-year-old woman presents with a 9-month history of intermittent dysphagia to solids and liquids which appears to have worsened over the last two months. She is hungry, but finds it difficult to keep the food down. She regurgitates her food and describes frank vomiting recently. She thinks she has lost some weight.

Examination of all systems is normal, and her blood test shows mild dehydration.

Her general practitioner (GP) referred her for a barium swallow, which is shown as below:

C Oesophageal manometry study

The barium swallow shows characteristic sharp narrowing of the lower oesophagus exhibiting a typical 'bird's beak' appearance, with hold-up of barium. This is consistent with achalasia but doesn't totally rule out a carcinoma. It is characterised by aperistalsis of the body of the oesophagus and impaired relaxation of the lower oesophageal sphincter. Manometry is the gold standard investigation, which shows a high resting lower oesophageal sphincter pressure and non-propagated lower oesophageal body contractions.

The aetiology remains unclear. The greatest incidence is between 30–50 years of age. Chest radiography can be non-specific, but may show a mediastinal shadow caused by the dilated oesophagus with an air/fluid level. Barium swallow is the mainstay of radiological diagnosis. Endoscopy is necessary in any patient to exclude a more sinister cause, because rarely a

more sinister cause, because rarely a stenosing adenocarcinoma can present in a manner similar to achalasia (the so-called pseudo-achalasia).

A CT scan of the thorax

Although this may reveal the dilated oesophagus with narrowing of the lower portion, it is less useful versus manometry with respect to confirming the underlying diagnosis.

B CT scan of the abdomen

CT scan of the abdomen is only really of utility here if oesophageal carcinoma is suspected, as a screen for hepatic metastases.

D Endoluminal ultrasound scan

Endoluminal ultrasound scanning has a role in the initial evaluation of oesophageal cancer, with respect to the depth and lateral spread of any lesions identified

hepatic metastases.

D	Endoluminal ultrasound scan

Endoluminal ultrasound scanning has a role in the initial evaluation of oesophageal cancer, with respect to the depth and lateral spread of any lesions identified.

E	Gastric transit study

Gastric transit studies are used in the evaluation of gastroparesis, which is associated with autonomic neuropathy, for example in long-standing diabetes mellitus.

33026

Rate this question:

A 42-year-old man presented to his GP complaining of lethargy, pruritus, right upper quadrant discomfort and dry mouth and eyes. Otherwise he was asymptomatic and had no previous history of note. He drank 24 units of alcohol per week.

On examination, he had two-finger hepatomegaly and his spleen was just palpable. No signs of chronic liver disease were present.

Investigations:

Na^+	132 mmol/l
K^+	4.4 mmol/l
Urea	2.4 mmol/l
Creatinine	70 micromol/l
Albumin	34 g/l
Bilirubin	25 micromol/l
AST	44 U/l
ALT	41 U/l

ALT	41 U/l
ALP	556 U/l
GGT	1021 U/l
Serum LDL cholesterol	3.22 mmol/l
Serum HDL cholesterol	5.56 mmol/l
Serum IgM	6.5 g/l

What is the most likely diagnosis?

A Gallstones

B Pancreatic carcinoma

C Primary sclerosing cholangitis

D Primary biliary cirrhosis

E Haemochromatosis

K^+	4.4 mmol/l
Urea	2.4 mmol/l
Creatinine	70 micromol/l
Albumin	34 g/l
Bilirubin	25 micromol/l
AST	44 U/l
ALT	41 U/l
ALP	556 U/l
GGT	1021 U/l
Serum LDL cholesterol	3.22 mmol/l
Serum HDL cholesterol	5.56 mmol/l
Serum IgM	6.5 g/l

What is the most likely diagnosis?

Your answer was incorrect

D Primary biliary cirrhosis

This man is most likely to have primary biliary cirrhosis (PBC). This is a condition of unclear aetiology that is characterised by the destruction of the small and medium-sized bile ducts. There is a presumed autoimmune component to the pathogenesis of PBC, and other immunologically driven conditions (including Graves' disease and pernicious anaemia) are found at higher rates in those with PBC than in the general population.

PBC particularly affects women (female:male of 9: 1) and onset is usually between the ages of 30 and 60 years. The presenting symptoms are usually non-specific, with fatigue and pruritus being the most common complaints.

Examination may be normal, although xanthelasmata are commonly found in association with PBC. Despite the name of the condition, there is actually a spectrum in the severity of liver disease associated with PBC:

improvements in diagnostics mean that many people are diagnosed and first treated whilst in an early phase of disease without significant liver fibrosis, although cirrhosis and portal hypertension may occur in advanced cases.

Investigation shows marked elevation of ALP and GGT, with lesser increases in the transaminases. Serum immunoglobulins (particularly IgM) are also often elevated. Positive anti-mitochondrial (M2) antibodies have a sensitivity and specificity of over 90%. Biopsy is not essential in making the diagnosis, although may help to confirm the diagnosis and is useful for staging disease.

Ursodeoxycholic acid (UDCA) is the only specific treatment of any benefit in PBC. For reasons that are not clear, not all affected people respond to UDCA. Treatment of the pruritus that occurs in PBC is often difficult. Cholestyramine is the best treatment for pruritus, although it is often poorly tolerated; antihistamines, opiate antagonists and Rifampicin also have a

antagonists and Rifampicin also have a role to play. Liver transplantation may be indicated for severe refractory pruritus, along with decompensated PBC cirrhosis.

C Primary sclerosing cholangitis

The elevated IgM and HDL cholesterol are consistent with PBC, but are not typical features of PSC.

A Gallstones

The history given in the scenario does not fit with gallstones.

B Pancreatic carcinoma

The history given in the scenario does not fit with pancreatic carcinoma.

E Haemochromatosis

Haemochromatosis tends to cause a hepatitic rather than a cholestatic

Creatinine	micromol/l
Albumin	34 g/l
Bilirubin	25 micromol/l
AST	44 U/l
ALT	41 U/l
ALP	556 U/l
GGT	1021 U/l
Serum LDL cholesterol	3.22 mmol/l
Serum HDL cholesterol	5.56 mmol/l
Serum IgM	6.5 g/l

What is the most likely diagnosis?

Your answer was incorrect

A Gallstones

11:08
:tps://mypastest.pastest.com

You are asked to review a 56-year-old man who works in a smoked meats and fish factory. He receives free food from the factory every month. He complains of increasing indigestion and has lost a stone in weight over the past 2 months. He drinks 10 units per week.

On examination, he has a mass in the epigastrium and a hard, palpable liver. Investigations reveal a microcytic anaemia; alanine aminotransferase and alkaline phosphatase are also both raised.

Which of the following is the most likely underlying aetiological factor in his condition?

Your answer was correct

A Smoked foods

B Alcohol consumption

A Smoked foods

This clinical picture is suggestive of gastric cancer. The patient has iron deficiency anaemia and a mass in the epigastrium. Aetiological risk factors include chronic H. pylori infection, tobacco abuse, alcohol consumption, food additives (nitrosamines), smoked foods, occupational exposure to heavy metals, rubber and asbestos. Although in a normal diet smoked foods only cause a very modest effect on risk of stomach cancer, in this case, regular consumption inis associated with elevated risk. Other associations with gastric cancer are gastritis with intestinal metaplasia, hypertrophic gastritis and pernicious anaemia. Unfortunately, few patients present early enough to be suitable for surgery. Whilst chemotherapy has not been proven to prolong survival, it may provide some degree of palliation. With the presence of metastases, gastrectomy is only considered in rare cases to prolong duration and quality of life. Five-year survival of gastric

of life. Five-year survival of gastric carcinoma is 12% overall, although survival for early carcinomas where resection is possible is much higher (>35%). Imatinib (Glivec) is an effective treatment for gastrointestinal stromal tumours (GIST) but is not useful in the management of gastric adenocarcinoma.

B	Alcohol consumption

This patient's alcohol consumption is very modest and unlikely therefore to be a significant contributor to risk of gastric cancer.

C	Genetics

Hereditary gastric cancer syndromes such as hereditary diffuse gastric cancer do exist, but they are very rare, HDGC is autosomal dominant in its inheritance pattern.

D	Chronic H. pylori infection

A 42-year-old pre-menopausal woman presented to her GP with a three-week history of epigastric pain, occasionally retrosternal and worse at night. She had tried over-the-counter antacid preparations but had achieved no relief. Her weight was steady and bowel habit normal. There was no history of gastric malignancy in the family.

Examination was unremarkable except for obesity, and her BMI is 31. Her GP has checked an Hb, which is slightly reduced at 11.4 g/dl, MCV is in the normal range.

Which of the following describes the best management step?

A	Prescribe a proton pump inhibitor (PPI) and review symptoms in one month
B	Arrange upper gastrointestinal (GI) endoscopy

normal range.

Which of the following describes the best management step?

A	Prescribe a proton pump inhibitor (PPI) and review symptoms in one month
B	Arrange upper gastrointestinal (GI) endoscopy
C	Check ferritin and then refer for upper gastrointestinal (GI) endoscopy
D	Start a PPI and perform breath test screening for *pylori*
E	Prescribe a PPI and refer for endoscopy if there is no resolution within 2 weeks

A Prescribe a proton pump inhibitor (PPI) and review symptoms in one month

NICE guidelines state in this age group that dyspepsia, in the absence of alarm symptoms, should be treated with lifestyle advice and PPI if needed. If after one month symptoms are not controlled then testing for *Helicobacter pylori* (breath test or serology) could be carried out. Alternatively *H. pylori* screening could happen at the beginning, but there isn't strong evidence as to which to do first. There needs to be a two-week wash-out period off the PPI for a urea breath test to be reliable.

B Arrange upper gastrointestinal (GI) endoscopy

There are no alarm symptoms such as weight loss, regurgitation of food or anaemia seen here, and the patient is under 55 years, hence going straight

C	Check ferritin and then refer for upper gastrointestinal (GI) endoscopy

We already know that the Hb is only just below the lower limit of normal and that the MCV is normal, and hence significant iron deficiency is unlikely.

D	Start a PPI and perform breath test screening for *pylori*

H. pylori testing should be conducted after a 2-week wash-out period from PPI, as use of acid suppression can make interpretation of the test unreliable.

E	Prescribe a PPI and refer for endoscopy if there is no resolution within 2 weeks

A 2-week trial of therapy is too short to make a decision as to the impact on symptoms.

A 26-year-old woman who is 17 weeks pregnant with her third child comes to the clinic complaining of right upper quadrant pain, worsening nausea and jaundice. Apart from nausea at the beginning of her pregnancy, things have followed a relatively uneventful course and the family has most recently returned from a trip to Tunisia.

On examination, she has jaundiced sclerae and looks tired. Her blood pressure is 110/60 mmHg, she is tender over the right upper quadrant, and she is pyrexial at 37.8 °C.

Investigations:

Hb	11.0 g/dl
WCC	11.2×10^9/l (mild lymphocytosis)
PLT	200 × 109/l
Na^+	140 mmol/l
K^+	4.8 mmol/l
Creatinine	100 μmol/l

Creatinine	100 μmol/l
Alanine aminotransferase (ALT)	1200 U/l
Alkaline phosphatase	420 U/l
Bilirubin	230 μmol/l

Which of the following is the most likely diagnosis?

A Fatty liver of pregnancy

B Cholestasis of pregnancy

C Hepatitis A

D Budd Chiari syndrome

E HELLP syndrome

have followed a relatively uneventful course and the family has most recently returned from a trip to Tunisia.

On examination, she has jaundiced sclerae and looks tired. Her blood pressure is 110/60 mmHg, she is tender over the right upper quadrant, and she is pyrexial at 37.8 °C.

Investigations:

Hb	11.0 g/dl
WCC	11.2 × 10^9/l (mild lymphocytosis)
PLT	200 × 109/l
Na^+	140 mmol/l
K^+	4.8 mmol/l
Creatinine	100 µmol/l
Alanine aminotransferase (ALT)	1200 U/l
Alkaline phosphatase	420 U/l

C Hepatitis A

The fever, leukocytosis, history of recent travel abroad and transaminase >1000 U/l all point towards acute hepatitis A infection. Hepatitis A has a similar course to non-pregnant patients and fulminant hepatic failure is rare. In utero infection has been associated with postnatal complications, so if a pregnant patient is travelling to an endemic area then vaccination is recommended.

A Fatty liver of pregnancy

The patient is only in the 17th week of gestation. Acute fatty liver of pregnancy is a rare and potentially fatal obstetric emergency that occurs in the third trimester. Presentation can be non-specific with nausea and vomiting, abdominal pain or acute liver failure in the most severe cases. Bilirubin and transaminases tend to be significantly raised with a rise in WCC and hypoglycaemia/hyperlactaemia

and hypoglycaemia/hyperlactaemia (hallmarks of acute liver failure).

B	Cholestasis of pregnancy

With this answer, one would expect the patient to have pruritus. Bilirubin is normally not elevated. The condition is characterised by pruritus (typically starting on the palms and soles of the feet) with raised fasting and post-prandial serum bile acids. Total bilirubin is rarely raised. The condition occasionally presents with pale stool and dark urine. It typically presents within the third trimester and resolves up to 6 weeks postpartum. Treatment is for pruritus with ursodeoxycholic acid and rifampicin.

D	Budd Chiari syndrome

This clinical picture could resemble Budd–Chiari, however the travel history and lymphocytosis would

hepatitis A. One might also expect to see clinical features of portal hypertension. Budd–Chiari is characterised by obstruction of the hepatic vein, sinusoidal congestion and portal hypertension. Pregnancy is a hypercoagulable state and the risk of Budd–Chiari is increased although it remains rare. Most patients presenting with de novo occlusion tend to have an undiagnosed underlying thrombophilia and should be investigated.

E	HELLP syndrome

The platelet count and blood pressure are normal and the patient is only in the 17th week gestation. HELLP syndrome is an hepatic manifestation of pre-eclampsia. This occurs after the 20th week of gestation and tends to occur in the presence of hypertension (>140/90 mmHg). Thrombocytopenia occurs as a result of a microangiopathic haemolytic anaemia. This takes place within the sinusoids leading to congestion, hepatic ischaemia and a transaminitis.

A 19-year-old woman presents to the Emergency Department with abdominal pain and vomiting. She has a long history of cramping abdominal pain, as does her younger brother. Her father has had two laparotomies.

Examination and investigation reveals signs of small-bowel obstruction. A picture of her mouth is shown below:

Which of the following is the most likely diagnosis?

A	Hereditary haemorrhagic telangiectasia
B	Juvenile polyposis
C	Familial adenomatous polyposis

picture of her mouth is shown below:

Which of the following is the most likely diagnosis?

A	Hereditary haemorrhagic telangiectasia
B	Juvenile polyposis
C	Familial adenomatous polyposis
D	Peutz-Jeghers syndrome
E	Cronkhite-Canada syndrome

D Peutz-Jeghers syndrome

The history of small bowel obstruction with the classic signs of perioral pigmentation fits with Peutz-Jeghers syndrome. This disorder is inherited in an autosomal dominant fashion, with the defect being in a gene on chromosome 19 which encodes a serine threonine kinase.

The characteristic pigmentation occurs circumorally, on the buccal mucosa, and may also occur on the hands and feet, and/ or around the anus. The pigmented areas may fade with age. Hamartomatous polyps typically develop in the small intestine, although they may occur in the stomach and colon too. Small intestinal intussusception may lead to small bowel obstruction requiring laparotomy. Accordingly, once diagnosed, screening for small intestinal polyps is undertaken; surgery has been the conventional means by which these are removed if present, but developments in enteroscopy mean that this is increasingly another

but developments in enteroscopy mean that this is increasingly another option.

Screening of the small bowel may be via radiological means, and/ or by capsule endoscopy. People with Peutz-Jeghers syndrome are also at increased risk of both other gastrointestinal (GI) tract malignancies, as well as non-GI malignancies (including breast and ovarian cancer).

A	Hereditary haemorrhagic telangiectasia

HHT classically presents initially with epistaxis, occurring first at a mean age of 12 years; by 21 years of age, over 90% of affected people are symptomatic. Telangiectasia (rather than pigmented spots) occurs on the lips, oral mucosa, tongue, face, conjunctivae, ears and fingers. Upper gastrointestinal haemorrhage occurs frequently, causing anaemia which often requires transfusion. Other visceral angiodysplasias may also

occur (including pulmonary AVMs), and vascular abnormalities in the liver may lead to cirrhosis.

B	Juvenile polyposis

Juvenile polyposis may also cause small intestinal polyps, but not perioral pigmentation.

C	Familial adenomatous polyposis

FAP is a familial bowel cancer syndrome, but is also not associated with perioral pigmentation.

E	Cronkhite-Canada syndrome

Cronkhite-Canada syndrome is a very rare disorder characterised by multiple intestinal polyps, alopecia, nail dystrophy and widespread skin pigmentation. It does not appear to have a familial tendency. The syndrome often first presents with diarrhoea.

A 40 year old woman with a history of chronic alcoholism presents to the clinic with increased abdominal swelling. She has noticed increasing abdominal girth over the past 4-6 months.

On examination, there are signs of chronic liver disease, including spider naevi and ascites, and she also has jaundiced sclerae. Her BP is 100/65 mmHg.

Investigations:

Hb	10.5 g/dl
MCV	107 fL
WCC	5.6×10^9/l
PLT	202×10^9/l
Na^+	136 mmol/l
K^+	3.9 mmol/l
Creatinine	85 μmol/l
CA-125	65 U/ml (< 35)

What is the most likely cause for the increased CA-125?

E Cirrhosis

The patient has clinical features of chronic liver disease and the alcohol history makes cirrhosis the most likely option. Cirrhosis with ascites is a well recognised cause of a false positive CA125.

B Ovarian carcinoma

A patient presenting with ascites and a raised CA-125 raises the suspicion of ovarian cancer, however, there is a clear alcohol history and the patient has features of chronic liver disease. Although CA-125 is often used to screen for ovarian cancer there are multiple conditions that also result in an elevated CA-125 (including cirrhosis and ascites, other intra-abdominal cancers, endometriosis, PID, fibroids, pancreatitis and heart failure amongst others).

If ovarian cancer is suspected, NICE recommend using the "Risk of Malignancy Index (RMI)", which

If ovarian cancer is suspected, NICE recommend using the "Risk of Malignancy Index (RMI)", which combines transvaginal US, menopausal status and CA-125 level to assess the risk. All women with a score >250 should be referred for specialist assessment.

In women where there is a family history of ovarian carcinoma, genetic screening for BRCA1/2 is recommended as the preferred method for assessing future ovarian carcinoma risk.

A	Ascites

Patients with cirrhosis and ascites can have an elevated CA-125 but it is not the ascites in isolation that is associated with an elevation of the enzyme.

C	Colonic carcinoma

Colon cancer can produce a falsely

11:33
:tps://mypastest.pastest.com

A 16-year-old boy presents with a 2-day history of colicky abdominal pain, vomiting and diarrhoea. He has been passing blood mixed with diarrhoea. He has no significant past medical history and takes no regular medication.

On examination, he is pyrexial and clinically dehydrated. Cardiorespiratory and abdominal examinations are normal.

What is the most likely diagnosis?

Your answer was incorrect

A	Crohn's disease
B	Pseudomembranous colitis
C	*Salmonella typhi* infection

11:33
tps://mypastest.pastest.com

E *Campylobacter* infection

This patient has acute bloody diarrhoea most likely secondary to a bacterial gastroenteritis. In the UK *Campylobacter* infection is the commonest cause of this, followed by *Salmonella* and *Shigella*. Infection usually arises from eating undercooked frozen food, e.g. at barbeques. The symptoms are usually self-limiting, lasting up to 5 days.

C *Salmonella typhi* infection

Typhoid fever is characterised by severe systemic illness with fever and abdominal pain. The organism classically responsible for the enteric fever syndrome is *Salmonella enterica* serotype Typhi (formerly *S. typhi*). Other *Salmonella* serotypes, particularly *S. enterica* serotypes Paratyphi A, B or C, can cause a similar syndrome; however, it is usually not

particularly *S. enterica* serotypes Paratyphi A, B or C, can cause a similar syndrome; however, it is usually not clinically useful or possible to reliably predict the causative organism based on clinical findings. The term 'enteric fever' is a collective term that refers to both typhoid and paratyphoid fever. Because humans are the only reservoir for *Salmonella enterica* serotype Typhi, a history of travel to settings in which sanitation is poor or contact with a known typhoid case or carrier is useful for identifying people at risk of infection outside of endemic areas, although a specific source or contact is identified in a minority of cases. Transmission from an index case to a contact is rarely documented in resource-rich settings.

A	Crohn's disease

Crohn's disease is an inflammatory condition of unknown aetiology that can affect any portion of the gastrointestinal tract, from the mouth to the perianal area. Its transmural inflammatory nature is coupled with

D Viral gastroenteritis

Most cases of acute infectious gastroenteritis are viral, with norovirus being the most common cause of acute gastroenteritis and the second most common cause of hospitalisation for acute gastroenteritis. The other common pathogens causing viral gastroenteritis are rotavirus, enteric adenovirus and astrovirus. In addition to large outbreaks from consumption of contaminated food and water, noroviruses are efficiently spread person-to-person. Viral gastroenteritis has pronounced peaks in the winter and spring. Characteristics of the history that suggest a viral aetiology of acute gastroenteritis include: an intermediate incubation period (24–60 h), a short infection duration (12–60 h) and a high frequency of vomiting. The bloody diarrhoea goes against viral gastroenteritis in this case.

9518

Rate this question:

operative assessment for hip replacement. She suffers from severe arthritis, hypercholesterolaemia, complex partial epilepsy and hypertension. She was treated for cystitis by her general practitioner (GP) 3 weeks ago. She is teetotal and a non-smoker.

Blood test results are as below:

Bilirubin	25 μmol/l
Alanine aminotransferase (ALT)	174 U/l (5–35)
Aspartate aminotransferase(AST)	180 U/l (10–40)
Alkaline phosphatase (ALP)	160 U/l (30–150)
Hepatitis and autoimmune serology	Negative
Ferritin	89 μg/l
Ultrasound scan	Normal

Which of the drugs listed below would be most likely to account for her

C Simvastatin

The incidental discovery of asymptomatic patients with mild to moderate increases in serum transaminase concentrations represents a common clinical problem. Hydroxymethyl glutaryl co-enzyme A reductase inhibitors (statins), are well recognised to cause deranged liver function tests, classically causing a hepatocellular pattern of derangement, although other biochemical patterns of injury are possible. Over-the-counter medications and herbal remedies may also be associated. If viral, autoimmune and metabolic causes are excluded, patients should be advised to discontinue medications that may be the cause.

A Co-amoxiclav

Amoxycillin-clavulanic acid (co-amoxiclav) can be responsible for a drug-induced liver injury, but this classically causes a cholestatic pattern of derangement in liver function tests

of derangement in liver function tests, although other biochemical patterns of injury are possible. The pattern of liver injury in this case is predominantly hepatocellular, and hence co-amoxiclav is not the best answer.

B Carbamazepine

Carbamazepine can be associated with a drug-induced liver injury, but more classically causes a cholestatic pattern of derangement in liver function tests, although other biochemical patterns of injury are possible. The pattern of liver injury in this case is predominantly hepatocellular, and hence Carbamazepine is not the best answer.

D Bendrofluazide

Although any drug can theoretically result in a drug-induced liver injury, only rare instances of clinically apparent liver injury have been linked to thiazide diuretics.

C Colonoscopy should be performed annually

This patient has had ulcerative colitis (UC) for 10 years and has developed associated primary sclerosing cholangitis (PSC) of the liver. Patients with concomitant UC and PSC are at a higher risk of developing colonic cancer, and it is recommended that they be screened annually with colonoscopy. Those with history of colon cancer in a first-degree relative under 50 years of age should also be subject to annual surveillance.

A Colonoscopy should be performed only when there are symptoms of colitis

Given there is significant risk of colonic dysplasia and subsequent carcinoma, expectant colonoscopy only when there are symptoms runs the risk of missing a lesion that could be advanced at the point of diagnosis.

You are seeing a 25-year-old woman in clinic with a history of ulcerative colitis (UC). She had extensive colitis 10 years ago, which has improved with medical treatment.

Last year, she had been diagnosed with early primary sclerosing cholangitis after an MRCP and liver biopsy. Her last colonoscopy was 6 months ago, which detected no active disease, and random biopsies were normal. She is remaining well and asymptomatic.

Physical examination is unremarkable, with a normal BMI of 23.

When should colonic screening be performed on this patient?

Your answer was correct

A	Colonoscopy should be performed only when there are symptoms of colitis
B	Colonoscopy should be performed in 10 years' time

When should colonic screening be performed on this patient?

Your answer was correct

A	Colonoscopy should be performed only when there are symptoms of colitis
B	Colonoscopy should be performed in 10 years' time
C	Colonoscopy should be performed annually
D	Colonoscopy should be performed in 3 years' time
E	Flexible sigmoidoscopy should be used 2-yearly

Explanation

C	Colonoscopy should be

C Colonoscopy should be performed annually

This patient has had ulcerative colitis (UC) for 10 years and has developed associated primary sclerosing cholangitis (PSC) of the liver. Patients with concomitant UC and PSC are at a higher risk of developing colonic cancer, and it is recommended that they be screened annually with colonoscopy. Those with history of colon cancer in a first-degree relative under 50 years of age should also be subject to annual surveillance.

A Colonoscopy should be performed only when there are symptoms of colitis

Given there is significant risk of colonic dysplasia and subsequent carcinoma, expectant colonoscopy only when there are symptoms runs the risk of missing a lesion that could be advanced at the point of diagnosis.

Even those patients with low-risk disease (those with previous extensive colitis with no active endoscopic/histological inflammation or left-sided colitis or Crohn's colitis of <50% colon) should be surveyed 5-yearly.

D	Colonoscopy should be performed in 3 years' time

Those with intermediate-risk disease, extensive colitis with mild active endoscopic/histological inflammation or post-inflammatory polyps or family history of colorectal cancer in a first-degree relative aged 50+, should be surveyed 3-yearly.

E	Flexible sigmoidoscopy should be used 2-yearly

Flexible sigmoidoscopy is inappropriate because it would fail to detect right-sided colonic lesions.

A 45-year-old theology student from East Africa is admitted to the Emergency Room with upper gastrointestinal haemorrhage. Past history of note includes hepatitis C infection.

On examination, he shows signs of chronic liver disease with lower limb oedema, ascites, spider naevi and scratch marks.

Investigations:

Hb	9.8 g/dl
WCC	6.7×10^9/l (slightly elevated eosinophils)
PLT	130×10^9/l
Na^+	139 mmol/l
K^+	5.4 mmol/l
Creatinine	165 μmol/l
Upper GI endoscopy	Varices
Hepatic USS	Peri-portal fibrosis

USS	
Abdominal CT	Capsules and septa visualised within the liver

Which of the following represents the most likely diagnosis?

A	Cirrhosis due to chronic hepatitis C infection
B	Portal hypertension due to *mansoni* infection
C	Portal hypertension due to *haematobium* and hepatitis C infection
D	Portal hypertension due to *mansoni* and hepatitis C infection
E	Portal hypertension due to *mekongi* and hepatitis C infection

scratch marks.

Investigations:

Hb	9.8 g/dl
WCC	6.7×10^9/l (slightly elevated eosinophils)
PLT	130×10^9/l
Na^+	139 mmol/l
K^+	5.4 mmol/l
Creatinine	165 µmol/l
Upper GI endoscopy	Varices
Hepatic USS	Peri-portal fibrosis
Abdominal CT	Capsules and septa visualised within the liver

Which of the following represents the most likely diagnosis?

D Portal hypertension due to *mansoni* and hepatitis C infection

In the early stages of *Schistosoma mansoni* infection symptoms can include indigestion, flatulence and left hypochondrial pain due to splenic enlargement. Anaemia or cor pulmonale may cause generalised weakness, and shortness of breath. In the later stages, abdominal distention, lower limb oedema, haematemesis and melaena can occur. In the case of *S. mansoni*, peri-portal fibrosis is thought to contribute to portal hypertension, as seen here. Management involves worm clearance with an appropriate therapy such as praziquantel, and treatment of the portal hypertension.

A Cirrhosis due to chronic hepatitis C infection

Although hepatitis C infection could lead to the features of chronic liver disease seen here, there are several

case. The fact that the patient has an eosinophilia and is from an area where schistosomiasis is endemic should make you suspicious for this as a potential contributing factor. Additionally, the abdominal CT features found in this patient would not be explained by hepatitis C infection alone.

B	Portal hypertension due to *mansoni* infection

Schistosoma mansoni rarely leads to chronic liver disease unless there is superimposed hepatitis B or C infection. In this instance we know that the patient already has a diagnosis of hepatitis C infection.

C	Portal hypertension due to *haematobium* and hepatitis C infection

Schistosoma haematobium is found in areas of sub-Saharan Africa and in the Middle East. but causes genitourinary

areas of sub-Saharan Africa and in the Middle East. but causes genitourinary tract disease which is not the clinical picture seen here. Long-term complications of *S. haematobium* infection can lead to fibrosis of the bladder which, in turn, can result in an obstructive uropathy. It also is a risk factor for the development of bladder cancer.

E	Portal hypertension due to *mekongi* and hepatitis C infection

Schistosoma mekongi occurs in the Mekong river basin in South East Asia, so is not going to be the organism involved in this case. It is a cause of intestinal schistosomiasis and the clinical picture is often similar to that described for *S. mansoni*, though neurological features can sometimes be seen if deposition of eggs into the central nervous system occurs.

20547

Rate this question:

D Barium swallow

The regurgitation of undigested food and halitosis is typical of a Zencker's diverticulum. This is an outpouching of the musocsa and submucosa in an area of anatomical weakness at the level of the cricopharynx (Killian's triangle). Coughing minutes to hours after eating is common and occurs during emptying of the diverticulum. Bleeding has been reported due to the effects of undigested medicines within the diverticula. Barium investigations are both useful at outlining the structure of the oesophagus and any accompanying motility disorders (Zencker's diverticulae occur in the context of a hypertensive upper oesophageal sphincter). Surgical intervention is the treatment of choice, although endoscopic therapies are also available.

Siddiq M, Sood S, Strachan D. Pharyngeal pouch (Zenker's diverticulum). *Postgraduate Medical Journal*. 2001;77(910):506-511.

11:55
tps://mypastest.pastest.com

A 58-year-old man presents with dysphagia to solids and liquids and a nocturnal cough. He has had the problem for some time and is rather embarrassed about it as he has a new partner and has even coughed up food on his pillow which he notices first thing in the morning. He says the material is undigested and smells disgusting. He reports occasional acid in his throat, but doesn't think this is the major problem. He smokes 10 cigarettes per day and drinks a glass of Scotch each evening.

On examination, his BMI is 27 and his BP is 142/92 mmHg. Other physical examination is unremarkable.

Investigations:

Hb	12.1 g/dl
WCC	5.9×10^9 /l
PLT	241×10^9 /l
Na^+	141 mmol/l

PLT	241×10^9 /l
Na^+	141 mmol/l
K^+	4.5 mmol/l
Creatinine	129 µmol/l
Plasma Viscosity	1.4 mPa/s (1.5-1.72)

Which of the following is the most appropriate next investigation?

Your answer was correct

A Oesophageal manometry

B CT scan abdomen and thorax

C Upper GI endoscopy

D Barium swallow

E Oesophageal pH

D Barium swallow

The regurgitation of undigested food and halitosis is typical of a Zencker's diverticulum. This is an outpouching of the musocsa and submucosa in an area of anatomical weakness at the level of the cricopharynx (Killian's triangle). Coughing minutes to hours after eating is common and occurs during emptying of the diverticulum. Bleeding has been reported due to the effects of undigested medicines within the diverticula. Barium investigations are both useful at outlining the structure of the oesophagus and any accompanying motility disorders (Zencker's diverticulae occur in the context of a hypertensive upper oesophageal sphincter). Surgical intervention is the treatment of choice, although endoscopic therapies are also available.

Siddiq M, Sood S, Strachan D. Pharyngeal pouch (Zenker's diverticulum). *Postgraduate Medical Journal*. 2001;77(910):506-511.

A 22-year-old dancer attends the Emergency Department as she has been unable to dance because of losing her balance. She has otherwise been well and denies drug or alcohol misuse. She has no family history, other than an aunt who died young with cirrhosis of the liver.

Examination reveals her to be jaundiced, with a slight voluntary tremor of the arms and legs; no other abnormalities were noted.

Investigations:

White cell count (WCC)	6.5×10^9/l
Haemoglobin (Hb)	8.0 g/dl
Platelets	300×10^9/l
Reticulocytes	5%
Bilirubin	100 μmol/l (1–22)
Aspartate transaminase (AST)	1600 u/l (1–31)
Alanine	900 u/l (5

Alanine aminotransferase (ALT)	900 u/l (5–35)
Albumin	29 g/l (37–49)
Prothrombin time (PT)	50 s (11.5–15.5)
Serum free copper	10 µmol/l (0-1.6)

Which of the following should be the next investigation?

A	Blood film
B	Liver biopsy
C	Slit lamp examination
D	Computed tomography (CT) of the head
E	Genetic testing

Reticulocytes	5%
Bilirubin	100 µmol/l (1–22)
Aspartate transaminase (AST)	1600 u/l (1–31)
Alanine aminotransferase (ALT)	900 u/l (5–35)
Albumin	29 g/l (37–49)
Prothrombin time (PT)	50 s (11.5–15.5)
Serum free copper	10 µmol/l (0-1.6)

Which of the following should be the next investigation?

Your answer was correct

A	Blood film

C Slit lamp examination

The haemolysis and high serum free copper in a young person point towards a picture of fulminant Wilson's disease. In this situation there is massive hepatic necrosis releasing the abnormally sequestered copper from the hepatocytes into the circulation, leading to haemolysis. Rapid and fatal liver failure can follow and an urgent diagnosis is required. In this situation the presence of KF rings (copper deposition in Descemet's membrane) is the most rapid diagnostic sign, although rarely it may be absent.

Ataxia and tremor are common neurological manifestations of Wilson's disease, and the diagnosis should be suspected in any young adult with neuropsychiatric symptoms and a family history of liver disease.

A Blood film

A blood film in Wilson's disease may show evidence of oxidant damage by

A 60-year-old man presents with a 9-month history of dysphagia and retrosternal chest pain on eating. There is no difference between solids and liquids. He also gives a history of regurgitating undigested food shortly after a meal. When he experiences discomfort after eating, this is relieved by regurgitation.

He has a BMI of 29 kg/m^2 and has lost no weight over the last few months.

Which investigation is most likely to definitively confirm the diagnosis?

A	Barium swallow
B	CT chest
C	Oesophageal manometry
D	OGD
E	Video fluoroscopy

C Oesophageal manometry

This patient has achalasia – failure of relaxation of the lower oesphageal sphincter. The primary clinical feature is dysphagia to both solids and liquids. Oesphageal manometry is correct as this will confirm the diagnosis, with the combination of absent body peristalsis and absent or impaired post-deglutitive relaxation of the lower oesophageal sphincter being diagnostic.

A Barium swallow

Although this is a useful screening test for dysphagia, it cannot confirm the diagnosis and further testing would be required. It will show a stricturing lesion, a pharyngeal pouch and, in the case of achalasia, it reveals the classic 'bird beak' appearance at the cardia. This is due to failure of the sphincter to relax. The absence of peristalsis is evident.

A 40-year-old woman presents with a history of chronic diarrhoea. She also complains of bone pain.

On examination, she has a number of small blisters on the skin that are extremely itchy. Blood testing reveals low corrected calcium, raised alkaline phosphatase and low albumin levels. She is also found to be anaemic.

Which of the following represents the best treatment option for this patient?

A	Calcium and vitamin D supplementation
B	Intravenous albumin
C	Topical corticosteroids
D	Gluten-free diet
E	Oral 5-aminosalicyclic acid

A 40-year-old woman presents with a history of chronic diarrhoea. She also complains of bone pain.

On examination, she has a number of small blisters on the skin that are extremely itchy. Blood testing reveals low corrected calcium, raised alkaline phosphatase and low albumin levels. She is also found to be anaemic.

Which of the following represents the best treatment option for this patient?

Your answer was correct

A	Calcium and vitamin D supplementation
B	Intravenous albumin
C	Topical corticosteroids
D	Gluten-free diet

D Gluten-free diet

The history of anaemia with associated hypoalbuminaemia, hypocalcaemia and raised alkaline phosphatase all point to a malabsorptive process secondary to coeliac disease and associated osteomalacia from vitamin D deficiency. There are dual peaks of incidence in the 3rd and 7th decades, and the disease is commoner in women. An OGD with duodenal or jejunal biopsy is the gold standard test, and demonstrates sub-total villous atrophy. Treatment is the commencement of a gluten-free diet, so Option D is correct. This will also help treat the skin rash from which the patient is suffering, called dermatitis herpetiformis - a chronic blistering skin rash linked to coeliac disease.

A Calcium and vitamin D supplementation

It would help with the low calcium but would not treat the underlying cause, so is not the best option here and is therefore incorrect.

B Intravenous albumin

This is rarely used as a treatment strategy to correct hypoalbuminaemia and would not be the best treatment in this patient.

C Topical corticosteroids

Topical corticosteroids have no role in the management of this skin condition.

E Oral 5-aminosalicyclic acid

The diarrhoea is caused by malabsorption from coeliac disease. 5-ASAs have no role in the management of coeliac disease and are more commonly used in the treatment of inflammatory bowel disease.

A 51-year-old man with a history of ulcerative colitis comes to the gastroenterology clinic for review.

Over the past 6 months, since his last appointment, he has felt increasingly fatigued and off his food because of problems with nausea. He has also lost 6 kg in weight over the past 3 months and noticed his stools have become increasingly paler, with dark urine and he has problems with generalised itching.

On examination, his BP is 132/72 mmHg, his pulse is 75/min and his BMI is 19. He looks jaundiced. Abdominal examination reveals no palpable masses.

Investigations:

Hb	10.9 g/dl
WCC	8.9×10^9/l
PLT	182×10^9/l
Na^+	138 mmol/l

PLT	182×10^9/l
Na^+	138 mmol/l
K^+	4.4 mmol/l
Creatinine	110 μmol/l
AST	141 U/l
Alk Phos	387 U/l
Bilirubin	188 μmol/l

Which of the following is the most likely diagnosis?

A Carcinoma of the gall bladder

B Pancreatic carcinoma

C Primary biliary cirrhosis

D Cholangiocarcinoma

E Autoimmune hepatitis

D Cholangiocarcinoma

This patient has a history of ulcerative colitis, which raises the possibility of underlying chronic liver disease related to primary sclerosing cholangitis. One outcome of primary sclerosing cholangitis is the development of cholangiocarcinoma, which presents often with only vague right upper quadrant pain, anorexia, jaundice and weight loss. It accounts in total for around 25% of biliary tract cancers. Ultrasound and MRCP are the initial non-invasive investigations of choice to confirm the diagnosis.

A Carcinoma of the gall bladder

This is a rare diagnosis and although a carcinoma of the gall bladder could present with weight loss and obstructive jaundice you may also find a painless palpable gall bladder. It is also not typically associated with ulcerative colitis and therefore is not the most likely diagnosis.

B Pancreatic carcinoma

Although pancreatic carcinoma would present with weight loss and obstructive jaundice, patients may also complain of abdominal pain radiating through to the back and an epigastric mass may be palpable. It is also not typically associated with ulcerative colitis.

C Primary biliary cirrhosis

This is a disease found predominantly in females. It presents with fatigue, itch and jaundice. Patients usually have positive anti-mitochondrial antibodies.

E Autoimmune hepatitis

Autoimmune hepatitis typically presents with fever, jaundice, fatigue and right upper quadrant pain, and is predominantly seen in females and is associated with other autoimmune conditions. Patients usually have positive antinuclear, anti-smooth muscle and anti-liver kidney

A 40-year-old woman presents with a history of abdominal pain and distension for the past 7 days.

On examination, she is found to have jaundice, a smooth, 5 cm hepatomegaly and ascites. There are no stigmata of chronic liver disease and she does not take any regular medication.

Investigations:

Hb	15.0 g/dl
WCC	11.0×10^9/l
PLT	200×10^9/l
Na+	140 mmol/l
K+	4.7 mmol/l
Creatinine	200 μmol/l
Urea	20 mmol/l
APTT	50 s
PT	13 s

What is the most likely diagnosis?

PLT	200 × 10⁹/l
Na+	140 mmol/l
K+	4.7 mmol/l
Creatinine	200 μmol/l
Urea	20 mmol/l
APTT	50 s
PT	13 s

What is the most likely diagnosis?

A	Alcoholic liver disease
B	Right heart failure
C	Glomerulonephritis
D	Budd–Chiari syndrome
E	Metastatic liver disease

APTT	50 s
PT	13 s

What is the most likely diagnosis?

Your answer was correct

A Alcoholic liver disease

B Right heart failure

C Glomerulonephritis

D Budd–Chiari syndrome

E Metastatic liver disease

Explanation

D Budd–Chiari syndrome

The prolonged APTT in the presence of a normal PT is suggestive of lupus

D Budd-Chiari syndrome

The prolonged APTT in the presence of a normal PT is suggestive of lupus anticoagulant, which would be consistent with anti-phospholipid syndrome, well recognised as a cause of Budd–Chiari syndrome. Budd-Chiari syndrome commonly presents with a triad of abdominal pain, hepatomegaly and ascites. It is a rare condition caused by occlusion to the hepatic vein. Treatment is with anticoagulation, surgery or a transjugular intrahepatic portosystemic shunt (TIPS) procedure.

A Alcoholic liver disease

Although this could account for her presentation, there is no mention of excessive alcohol intake in the history and her presentation is far more typical of Budd-Chiari syndrome.

B Right heart failure

Although this might cause an engorged liver and ascites, it would

B Right heart failure

Although this might cause an engorged liver and ascites, it would not explain her clotting abnormalities.

C Glomerulonephritis

This would not explain the hepatomegaly and jaundice.

E Metastatic liver disease

You would not expect to feel a smooth liver in this case, and the ascitic fluid tap is more likely to be exudative in malignancy rather than transudative.

2314

Rate this question:

Next Question

Previous Question Tag Question

12:16
tps://mypastest.pastest.com
10

Ultrasound scan shows multiple hypo-echoic lesions in the liver, and a computed tomography scan (CT) of the abdomen is arranged (see figure below).

What is the most likely diagnosis?

A	Carcinoid tumour and liver metastases
B	Hepatic abscesses
C	Haemangiomas

D Pancreatic carcinoma and liver metastases

The computed tomography scan reveals a large mass of the pancreas with multiple liver metastases. The diagnosis is supported by the history. Abdominal pain, weight loss and jaundice are the three commonest symptoms of this cancer, which is an adenocarcinoma. It has a very poor prognosis, with the overall 5-year survival rate being less than 5%. A total of 80% of cases will have tumour spread to regional lymph nodes or distant organs at the time of presentation. A 4-week holiday to Egypt is highly unlikely to be associated with a risk of schistosomiasis; the pancreatic mass makes hepatic abscesses, haemangiomas and a carcinoid tumour unlikely.

A Carcinoid tumour and liver metastases

Carcinoid tumours are well-differentiated neuroendocrine tumours. Carcinoid tumours can cause carcinoid syndrome, which occurs due to humoral factors released by these tumours. Carcinoid syndrome causes flushing and diarrhoea. Whilst the patient does have flushing, and if there was hepatic spread this could explain abdominal pain, there is no evidence of diarrhoea. That makes this diagnoses less likely. Carcinoid tumours are also very rare.

B	Hepatic abscesses

Liver abscesses mostly occur following peritonitis due to leaking of bowel content with spread to the liver by portal circulation. Alternatively, there can be direct spread from the biliary system or haematogenous seeding from systemic infection. Liver abcesses commonly cause fever and abdominal pain, whilst patients can also have anorexia, vomiting and weight loss. This patient's abdominal pain and tenderness with weight loss could be supported by this diagnosis. However

making this a less likely diagnosis. Also, the CT findings do not support it.

C	Haemangiomas

Hepatic heamangiomas are common benign tumours, but multiple lesions may be present. Patients are mostly asymptomatic with diagnosis usually being incidental, but some patients can have abdominal pain or fullness. The presence of weight loss and massive hepatomegaly is not supported by this diagnosis, making it unlikely.

E	Schistosomiasis

Schistosomiasis is an infection caused by parasitic flukes spread from freshwater snails. Species exist mostly in sub-Saharan Africa, but also in the Middle East, China, and central Africa. Schistosomiasis has multiple clinical manifestations which can be acute or chronic. In the acute phase, there can be swimmer's itch or acute schistosomiasis syndrome, also known as Katayama fever. Chronic infection

12:46
:tps://mypastest.pastest.com

A 36-year-old nurse has a 1-year history of recurrent urinary tract infections, altered bowel habit, brown discoloration of urine and has noticed intermittent air bubbles on passing urine.

Which of the following is the most likely diagnosis?

A	Crohn's disease
B	Ulcerative colitis
C	*Klebsiella* infection
D	Pneumatosis coli
E	Collagenous colitis

A 36-year-old nurse has a 1-year history of recurrent urinary tract infections, altered bowel habit, brown discoloration of urine and has noticed intermittent air bubbles on passing urine.

Which of the following is the most likely diagnosis?

Your answer was incorrect

A	Crohn's disease
B	Ulcerative colitis
C	*Klebsiella* infection
D	Pneumatosis coli
E	Collagenous colitis

Explanation

A Crohn's disease

A Crohn's disease

The combination of recurrent UTI, pneumaturia, faecaluria and underlying gastrointestinal symptoms is suggestive of a colovesical fistula. Causes of gastrointestinal fistula include Crohn's disease, diverticulitis and colorectal tumours.

D Pneumatosis coli

Pneumatosis coli is a clinical sign suggestive of gas within the bowel wall. This finding can result from a number of conditions, including bowel ischaemia and infective enteritis, and has a range of clinical manifestations. However, it is unlikely to explain this patient's urinary symptoms.

B Ulcerative colitis

Ulcerative colitis does not cause fistulating disease, and hence is not considered an underlying cause of colovesical fistula.

Ulcerative colitis does not cause fistulating disease, and hence is not considered an underlying cause of colovesical fistula.

C	*Klebsiella* infection

K. pneumoniae can cause gas-forming 'emphysematous' urinary tract infections, with abdominal imaging revealing air in the renal parenchyma, bladder or surrounding tissue. However, such a cause does not best explain the patient's faecaluria and altered bowel habit

E	Collagenous colitis

Collagenous colitis is a chronic, inflammatory disease of the colon that is characterized by chronic, watery diarrhoea. It typically occurs in middle-aged females, but is not considered a cause of colovesical fistula, which is the clinical presentation described in this case.

A 48-year-old woman presents for review. Over the past few weeks, she has noticed a progressive increase in itching and now notices that her sclerae and skin are yellowed.

There is no history of abdominal pain. Past medical history of note includes obesity and type 2 diabetes, for which she takes metformin.

Investigations:

Bilirubin	230 μmol/l
Alkaline phosphatase	430 U/l
ALT	110 U/l
Gamma GT	245 U/l

Which of the following investigations is the most appropriate next investigation?

A	Abdominal ultrasound scan
B	Abdominal CT

ALT	110 U/l
Gamma GT	245 U/l

Which of the following investigations is the most appropriate next investigation?

A	Abdominal ultrasound scan
B	Abdominal CT
C	Endoscopic retrograde cholangiopancreatography (ERCP)
D	Magnetic resonance cholangiopancreatography (MRCP)
E	Percutaneous cholangiogram

D Magnetic resonance cholangiopancreatography (MRCP)

This lady has painless jaundice with an obstructive blood picture on liver function testing, which puts common bile duct stricture high on the list of possible causes. MRCP is now a particularly effective technique at determining the level and cause of biliary tract obstruction.

A Abdominal ultrasound scan

An abdominal ultrasound would be useful in excluding an extrahepatic cause for cholestasis, but would not lead to the diagnosis. It is far more useful in jaundice secondary to gallstone and to diagnose cholecystitis. The fact that the patient is obese would also limit the amount of information potentially obtained from an USS scan of the abdomen.

B Abdominal CT

B	Abdominal CT

CT scanning is unlikely to demonstrate problems within the common bile duct such as strictures, primary biliary sclerosis or sclerosing cholangitis, but could be used to assess for acute cholecystitis. The absence of evidence of acute infection, such as fever, makes this investigation unlikely to lead to a diagnosis.

C	Endoscopic retrograde cholangiopancreatography (ERCP)

The alternative would be ERCP, but this technique would not be without morbidity in this woman and hence MRCP would be the preferred option. The differentiation between MRCP and ERCP here is with respect to clinical appropriateness, weighing up the possibility of ERCP-related complications versus the advantage of slightly better imaging.

The alternative would be ERCP, but this technique would not be without morbidity in this woman and hence MRCP would be the preferred option. The differentiation between MRCP and ERCP here is with respect to clinical appropriateness, weighing up the possibility of ERCP-related complications versus the advantage of slightly better imaging.

E	Percutaneous cholangiogram

This is a process of inserting a needle into the liver and injecting contrast into the biliary tree. Whilst it would be diagnostic, it is an invasive technique when compared to ERCP, MRCP or CT imaging. It still has its uses when other imaging has failed, and it can be used therapeutically for placement of biliary stents.

18557

Rate this question:

Next Question

A 28-year-old woman in the third trimester of her first pregnancy presents with persistent generalised itching which has been getting progressively worse over the last 2 weeks. She also feels generally unwell with anorexia and malaise, but there are no other specific symptoms.

She has no significant past medical or family history and is on no medications. She is a non-smoker and drank approximately 10 units of alcohol per week prior to her pregnancy, and nothing during the pregnancy itself.

On examination, she looks well. She is normotensive and haemodynamically stable. She has icteric sclerae, but is not deeply jaundiced, and there are no skin rashes visible. Her abdomen is distended, consistent with pregnancy, and non-tender. Cardiorespiratory and neurological examinations are unremarkable. Urine dipstick analysis is normal.

Blood results are below:

Haemoglobin (Hb)	10 g/dl

Haemoglobin (Hb)	10 g/dl
White cell count	9.0×10^9/l
Platelets	400×10^9/l
Mean corpuscular volume (MCV)	96 fl
Na^+	133 mmol/l
K^+	3.5 mmol/l
Urea	3.2 mmol/l
Creatinine	68 µmol/l
Bilirubin	72 µmol/l
Alkaline phosphatase	820 IU/l
Aspartate transaminase (AST)	220 IU/l
Gamma-glutamyl	320 IU/l

Alkaline phosphatase	820 IU/l
Aspartate transaminase (AST)	220 IU/l
Gamma-glutamyl transferase	320 IU/l
Prothrombin time	21 s

What is the most likely diagnosis?

A	Primary biliary cirrhosis (PBC)
B	Acute fatty liver of pregnancy
C	Gilbert's syndrome
D	HELLP (haemolysis, elevated liver enzymes and low platelets) syndrome
E	Intrahepatic cholestasis of pregnancy

E Intrahepatic cholestasis of pregnancy

Intrahepatic cholestasis of pregnancy is a rare disorder of pregnancy, due to inherited susceptibility of liver cells to high oestrogen levels. This condition is characterized by jaundice, malaise and generalized pruritis (can have predilection for palms and soles). Liver function tests will show a cholestatic picture, with high alkaline phosphatase (>4× normal) with more modest elevations in aspartate transaminase (<300 IU/l) and bilirubin (<100 μmol/l). There may be a prolonged prothrombin time. Clinical features and laboratory finding makes this as the best option to select.

A Primary biliary cirrhosis (PBC)

Primary Biliary cirrhosis is a condition of gradual destruction of the intrahepatic bile ducts, leading to fibrosis and cholestasis and ultimately hepatic cirrhosis, usually presented in

alkaline phosphatase and pruritis are also features seen in PBC, however, history of symptoms in third trimester makes this option less likely. Anti-mitochondrial antibodies test is specific to PBC, as these antibodies are present in more than 90 % of cases of PBC and can exclude this disease from other causes of jaundice during pregnancy.

B	Acute fatty liver of pregnancy

Acute fatty liver of pregnancy can cause acute liver failure, which also occurs in third trimester of pregnancy. Alkaline phosphatase is elevated as well as moderate increase in liver transaminase (usually 500-1000 units / ml). Clinical features include; jaundice, flu like symptoms, abdominal pain, encephalopathy and DIC. White blood cells are usually elevated in acute fatty liver of pregnancy, contrary to the findings in this case.

C	Gilbert's syndrome

C	Gilbert's syndrome

Gilbert syndrome is a benign condition of asymptomatic hereditary jaundice, due to reduced activity of glucuronyl transferase. Unconjugated bilirubinaemia (indirect) is seen and patient presents with mild jaundice. Clinical features and laboratory findings are pointing towards intrahepatic cholestasis of pregnancy, not Gilbert syndrome.

D	HELLP (haemolysis, elevated liver enzymes and low platelets) syndrome

HELLP (haemolysis, elevated liver enzymes and low platelets) syndrome is an advanced stage of severe pre-eclampsia. Clinical features include; headache, Change in vision, High Blood pressure. Normal platelet count seen in the case, makes this option less likely, as HELLP syndrome is characterized by low platelet count.

A 74-year-old patient has been thrombolysed for an anterior myocardial infarction. You are asked to see him 3 days later as he has suddenly become unwell.

Past medical history includes hypertension, and omeprazole recently prescribed by his GP for indigestion.

On examination, his blood pressure is 100/50 mmHg, pulse is 100 bpm regular and he looks unwell. He is not in left ventricular failure on clinical findings, and his abdomen is very firm, with exquisite tenderness in the epigastrium. His lower limb pulses are intact.

Investigations:

Hb	95 g/l (125 g/l on admission)
WCC	11.2×10^9/l
PLT	201×10^9/l
Na^+	140 mmol/l
K^+	4.5 mmol/l

Creatinine	145 μmol/l
Amylase	290 U/l
Alanine aminotransferase (ALT)	190 U/l
Bilirubin	45 μmol/l
ECG	Sinus rhythm 100, anterolateral ST depression

Which of the following is the most likely diagnosis?

A	Acute cholecystitis
B	Acute pancreatitis
C	Aortic dissection
D	Ventricular septal defect (VSD)
E	Perforated gastric ulcer

E Perforated gastric ulcer

The history of previous indigestion, and the Hb drop of 3 g/dl is highly suggestive of an acute GI bleed. He is normally hypertensive but his BP has dropped to 100/50 mmHg, indicating significant hypovolaemia. Amylase may be slightly elevated with a perforated abdominal viscus and a level of 290 U/l fits with this.

A Acute cholecystitis

The rise in ALT is non-specific and unlikely to be related to cholecystitis. One might expect to see a rise in alkaline phosphatase or gamma-glutamyl transferase indicating acute biliary obstruction.

B Acute pancreatitis

Although the epigastric pain, tachycardia and hypotension in the context of a raised amylase could indicate pancreatitis and SIRS, the fact

Although the epigastric pain, tachycardia and hypotension in the context of a raised amylase could indicate pancreatitis and SIRS, the fact the haemoglobin has dropped significantly following thrombolysis makes an upper GI bleed much more likely.

C	Aortic dissection

The fact that his lower limb pulses are intact and there are no neurological sequelae makes an aortic dissection unlikely.

D	Ventricular septal defect (VSD)

Patients can rarely develop VSD post-myocardial infarction but this will present with cardiogenic shock. The clinical findings, (absent of a murmur or left ventricular failure), are not indicative of this.

21280

Rate this question:

A 59-year-old woman presents with an episode of diarrhoea, with her bowels opening six times a day. This is associated with rectal bleeding and generalised abdominal cramps.

Investigations:

Hb	10.0 g/dl
WCC	13.0×10^9/l
PLT	440×10^9/l
Na+	140 mmol/l
K+	4.7 mmol/l
Creatinine	80 μmol/l
Urea	6.8 mmol/l
CRP	58

She has a barium enema, which is shown below:

shown below:

Image courtesy of Ian Maddison, London South Bank University

What is the most likely diagnosis?

A	Ulcerative colitis
B	Crohn's disease
C	Coeliac disease
D	Diverticulosis
E	Colorectal cancer

A Ulcerative colitis

The barium enema shows ulcerative colitis as evidenced by mucosal thickening, lack of haustra and thickening affecting the whole of the descending colon, which is continuous. There also appears to be thumbprinting affecting the more proximal colon. Barium enemas are now rarely performed since the advent of colonoscopy and flexible sigmoidoscopy. The blood tests are also consistent with an acute severe colitis, with elevated inflammatory markers, a reactive thrombocythaemia and anaemia.

B Crohn's disease

You would expect to see discontinuous (skip) lesions and a so-called 'cobblestone' appearance, which are barium-filled craters surrounded by a lucent halo, coalescing to form a lattice-work of confluent ulcers.

'cobblestone' appearance, which are barium-filled craters surrounded by a lucent halo, coalescing to form a lattice-work of confluent ulcers.

C Coeliac disease

Coeliac disease does not affect the large intestine.

D Diverticulosis

This does not go with the clinical picture, and there are no obvious diverticulae on the barium film.

E Colorectal cancer

There is no narrowing of the bowel on the barium film.

6341

Rate this question:

Next Question

A 49-year-old white woman presents with a 6-month history of change in bowel habits, mainly consisting of watery diarrhoea and weight loss. She describes the stool as 'greasy'. She feels bloated all the time and finds it embarrassing due to excessive foul-smelling flatus.

History of note includes a cruise to the Mediterranean in the past year. She was investigated privately one week ago and had a small bowel biopsy. This is reported as showing partial shortening of villi.

Investigations:

Hb	10.0 g/dl
WCC	11.1×10^9/l
PLT	202×10^9/l
Na^+	138 mmol/l
K^+	3.7 mmol/l
Creatinine	90 μmol/l
Albumin	28 g/l

Creatinine	90 μmol/l
Albumin	28 g/l
ALT	122 U/l
Ca^{2+}	2.12 mmol/l

Which of the following is the most likely diagnosis?

A Giardiasis

B Tropical sprue

C Crohn's disease

D Lactose intolerance

E Coeliac disease

8491

Submit

with a 6-month history of change in bowel habits, mainly consisting of watery diarrhoea and weight loss. She describes the stool as 'greasy'. She feels bloated all the time and finds it embarrassing due to excessive foul-smelling flatus.

History of note includes a cruise to the Mediterranean in the past year. She was investigated privately one week ago and had a small bowel biopsy. This is reported as showing partial shortening of villi.

Investigations:

Hb	10.0 g/dl
WCC	11.1×10^9/l
PLT	202×10^9/l
Na^+	138 mmol/l
K^+	3.7 mmol/l
Creatinine	90 μmol/l

E Coeliac disease

This lady's symptoms are consistent with small bowel malabsorption. The biopsy from the second part of the duodenum shows villous shortening. This is consistent with coeliac disease, which fits with the anaemia, low albumin and borderline low serum calcium. Anti-TTG antibodies are the logical next investigation.

B Tropical sprue

Tropical sprue is associated with similar symptoms to coeliac disease, including small joint polyarthritis, although it is significantly rarer in the UK than coeliac disease, and infection occurs most commonly in tropical regions.

A Giardiasis

Giardiasis is a cause of small bowel malabsorption and the symptoms in this case, although a more acute

Giardiasis is a cause of small bowel malabsorption and the symptoms in this case, although a more acute presentation would be expected rather than the 6 months of symptoms seen here.

C Crohn's disease

Crohn's disease is associated with inflammatory small bowel changes rather than the villous atrophy seen here.

D Lactose intolerance

True lactose intolerance is associated with villous atrophy, but it is much more common in patients of African or Asian origin.

8491

Rate this question:

Next Question

A 38-year-old woman with previously stable Crohn's disease presents complaining of worsening diarrhoea. She is managed on a small dose of budesonide and mesalazine, and had no symptoms up until 6 months ago.

Most recently, she has been taking a course of sertraline for depression. Currently she opens her bowels many times per day, with voluminous non-bloody diarrhoea.

Investigations:

Hb	12.9 g/dl
WCC	5.0×10^9/l
PLT	203×10^9/l
Na^+	139 mmol/l
K^+	3.9 mmol/l
Cr	100 μmol/l
Colonic biopsies	lymphocytic infiltrate

Which of the following is the most likely diagnosis?

PLT	203×10^9/l
Na^+	139 mmol/l
K^+	3.9 mmol/l
Cr	100 μmol/l
Colonic biopsies	lymphocytic infiltrate

Which of the following is the most likely diagnosis?

A Coeliac disease

B Tropical sprue

C Lymphocytic colitis

D Ulcerative colitis

E Crohn's reactivation

course of sertraline for depression. Currently she opens her bowels many times per day, with voluminous non-bloody diarrhoea.

Investigations:

Hb	12.9 g/dl
WCC	5.0×10^9/l
PLT	203×10^9/l
Na^+	139 mmol/l
K^+	3.9 mmol/l
Cr	100 μmol/l
Colonic biopsies	lymphocytic infiltrate

Which of the following is the most likely diagnosis?

Your answer was correct

A Coeliac disease

B Tropical sprue

C Lymphocytic colitis

Lymphocytic colitis may occur in patients with other forms of GI pathology, including Crohn's and coeliac disease. Sertraline also appears to be associated with the development of lymphocytic colitis. Withdrawal of the offending agent is preferable, and loperamide is often used as first-line therapy to reduce the severity of diarrhoea, with cholestyramine an alternative if there is additional evidence of bile salt malabsorption. Other alternatives include immune-modulating agents such as azathioprine, although a response to therapy may take many months to appear. Approximately 20% of patients have a spontaneous remission without specific intervention.

A Coeliac disease

Coeliac disease does not lead to the colonic changes seen here, but does show subtotal villous atrophy within

B Tropical sprue

Like coeliac disease, tropical sprue is associated with villous atrophy rather than the colonic changes seen here.

D Ulcerative colitis

UC biopsy shows infiltration of the mucosa and submucosa with neutrophils, crypt abscess formation, lymphoid aggregates, mast cells, eosinophils and shortening and branching of crypts.

E Crohn's reactivation

In Crohn's disease, transmural lymphoid infiltrates are seen although there is also usually evidence of non-caseating granuloma formation. The proximity to prescription of sertraline is also a better pointer to lymphocytic colitis as the diagnosis.

20612

Rate this question:

A 43-year-old man is seen in the clinic with a 6-month history of abdominal pain, 6 kg weight loss and intermittently he has noticed dark urine which lasted for a few days. He also has noticed night sweats, which soak his nightclothes. There is a history of ulcerative colitis which is currently well controlled; he does not smoke and drinks a couple of pints of beer at the weekend.

On examination, he looks well and has no jaundice, clubbing or lymphadenopathy. He has a 4 cm non-tender hepatomegaly and the rest of his examination is normal.

Investigations:

White cell count (WCC)	$6.7 \times 10^9/l$
Haemoglobin (Hb)	13.5 g/dl
Platelets (PLT)	$379 \times 10^9/l$
Alanine aminotransferase (ALT)	61 U/l

Bilirubin	21 μmol/l
Alkaline phosphatase (ALP)	245 U/l
γ-glutamyl transferase (GGT)	256 U/l
Albumin	36 g/l
Serum electrophoresis	Polyclonal increase in immunoglobulins
Auto-antibodies (ANA)	1:64
c-ANCA	-
p-ANCA	1:320
Abdominal US	Hepatomegaly but no bile duct dilation

What is the most likely diagnosis?

A	Primary biliary cirrhosis

Serum electrophoresis	increase in immunoglobulins
Auto-antibodies (ANA)	1:64
c-ANCA	-
p-ANCA	1:320
Abdominal US	Hepatomegaly but no bile duct dilation

What is the most likely diagnosis?

A	Primary biliary cirrhosis
B	Primary sclerosing cholangitis
C	Chronic active hepatitis
D	Polyarteritis nodosa
E	Hydatid disease

B Primary sclerosing cholangitis

Primary sclerosing cholangitis (PSC) is a chronic cholestatic liver disease of unknown aetiology. The diagnosis is based a combination of clinical features which often come on insidiously, including hepatomegaly, intermittent jaundice, fevers of unknown origin, pruritus, abdominal pain and weight loss. This, together with a cholestatic biochemical profile and typical cholangiographic abnormalities of generalized beading and stenosis of the intrahepatic and extra-hepatic biliary tree, characterise PSC. PSC is usually progressive, leading to cirrhosis, portal hypertension and liver failure. Ultrasound is normal in 50% of patients at an early stage of the disease. Pathognomonic histology shows a concentric obliterative fibrosis of interlobular bile ducts, with the presence of intrahepatic cholangiectasis and ductal obliteration.

Therapeutic interventions, such as

extra-hepatic biliary tree, characterise PSC. PSC is usually progressive, leading to cirrhosis, portal hypertension and liver failure. Ultrasound is normal in 50% of patients at an early stage of the disease. Pathognomonic histology shows a concentric obliterative fibrosis of interlobular bile ducts, with the presence of intrahepatic cholangiectasis and ductal obliteration.

Therapeutic interventions, such as dilation of strictures or placement of an endoprosthesis, can be performed during endoscopic retrograde cholangiopancreatography (ERCP). Many pharmacological therapies have been tried, without great success. Dietary replacement of vitamins A, D, E and K should be commenced. Liver transplantation is an option in terminal liver failure.

A	Primary biliary cirrhosis

Primary biliary cirrhosis is interlobular bile duct damage caused by granulomatous autoimmune

inflammation. This can result in fibrosis, cirrhosis and portal hypertension. It is associated with antimitochondiral antibodies, and is far more common in females, typically at 50 years of age. Presentation is typically asymptomatic with incidental biochemical cholestasis, but can cause lethargy and pruritus progressing to ascites. The presence of night sweats and absence of pruritis, as well as the demographics, makes this an unlikely diagnosis.

C	Chronic active hepatitis

Viral hepatitis causes fever, malaise, anorexia and nausea, which can progress to jaundice. In patients with chronic infection this may progress to cirrhosis, which may lead to episodes of acute decompensation of liver disease. The blood tests suggest a primarily cholestatic injury as opposed to a hepatic cause, and there is no clear history of risk factors.

D	Polyarteritis nodosa

Polyarteritis nodosa is a necrotising vasculitis that causes thrombosis, and can also cause aneurysms, in medium-diameter arteries, which can lead to organ infarction. It is more common in men and with hepatitis B. The absence of systemic features and rash makes this an unlikely diagnosis, and the demographics of the patient are not supportive.

E	Hydatid disease

Cystic hydatid disease occurs following transmission of ingesting the eggs of parasites such as *Echinococcus*. It is common in China, Russia, Japan, India, Pakistan and Wales. Clinically the organs most commonly affected are the liver and lungs. In the liver it can cause obstructive jaundice whilst in the lungs it can cause haemoptysis and dyspnoea, and rupture can lead to anaphylaxis. The absence of travel history and of potential exposure makes this very unlikely, as does the weight loss

A 54-year-old man presents to the emergency department with a history of recently worsening indigestion. He also complains of fatigue, weight loss and recent night sweats.

Clinical examination shows a BP of 147/86 mmHg, pulse of 70/min and regular and a BMI of 26. He is mildly tender in the epigastrium. Upper gastrointestinal endoscopy reveals a suspicious area of mucosa in the stomach with particularly rigid folds. Biopsy reveals large numbers of lymphocytes with irregular nuclear contours and abundant cytoplasm.

Which of the following diagnoses fits best with this clinical picture?

A	Gastric carcinoma
B	Gastric adenoma
C	Gastric mucosa-associated lymphoid tissue (MALToma)

tender in the epigastrium. Upper gastrointestinal endoscopy reveals a suspicious area of mucosa in the stomach with particularly rigid folds. Biopsy reveals large numbers of lymphocytes with irregular nuclear contours and abundant cytoplasm.

Which of the following diagnoses fits best with this clinical picture?

A	Gastric carcinoma
B	Gastric adenoma
C	Gastric mucosa-associated lymphoid tissue (MALToma)
D	Non-Hodgkin's lymphoma
E	Helicobacter infection

33055

Submit

gastrointestinal endoscopy reveals a suspicious area of mucosa in the stomach with particularly rigid folds. Biopsy reveals large numbers of lymphocytes with irregular nuclear contours and abundant cytoplasm.

Which of the following diagnoses fits best with this clinical picture?

Your answer was correct

A	Gastric carcinoma
B	Gastric adenoma
C	Gastric mucosa-associated lymphoid tissue (MALToma)
D	Non-Hodgkin's lymphoma
E	Helicobacter infection

Explanation

C Gastric mucosa-associated lymphoid tissue (MALToma)

MALT is characterised by large numbers of immunocompetent cells in the lamina propria. MALTomas are B-cell lymphomas comprising large numbers of lymphocytes with irregular nuclear contours and abundant cytoplasm. Higher-grade lymphomas show clusters or sheets of blast-like cells. Up to 75% of small low-grade lymphomas may regress completely after antibiotic therapy for helicobacter eradication. Where treatment fails, surgical therapy or combinations with radio- and chemotherapy may be considered. In addition, imatinib (Glivec) has recently shown a good deal of success in achieving remission in this condition.

A Gastric carcinoma

Gastric carcinomas can be tubular, mucinous, poorly cohesive or unclassified in histology. A hallmark on histology is submucosal invasion

Gastric carcinomas can be tubular, mucinous, poorly cohesive or unclassified in histology. A hallmark on histology is submucosal invasion.

B Gastric adenoma

Gastric adenomas are rare in Western populations, and rather than showing growth without evidence of invasion, histology normally reveals at least some evidence of carcinomatous transformation.

D Non-Hodgkin's lymphoma

High grade mature B cell lymphomas in a Western population often present with symptoms of CNS lymphoma or mediastinal lymphadenopathy picked up with other symptoms such as night sweats and weight loss over a period of time.

E Helicobacter infection

A 54-year-old woman is referred to the Hepatology Clinic for review. She presented to her GP complaining of tiredness and lethargy. There is no other past medical history of note apart from mild asthma, for which she takes a low-dose fluticasone/salmeterol inhaler and PRN salbutamol. She admits to drinking four bottles of wine per day.

On examination, her BP is 122/82 mmHg, with pulse 80/min and regular. She has a BMI of 30. Laboratory investigations show AST 293 U/l, ALT 135 U/l, ALP 158 U/l, GGT 178 U/l. Ultrasound examination shows fatty infiltration in the liver.

Which piece of data points towards alcoholic rather than non-alcoholic fatty liver?

A	AST:ALT ratio >2
B	Elevated ALP
C	Elevated GGT

takes a low-dose fluticasone/salmeterol inhaler and PRN salbutamol. She admits to drinking four bottles of wine per day.

On examination, her BP is 122/82 mmHg, with pulse 80/min and regular. She has a BMI of 30. Laboratory investigations show AST 293 U/l, ALT 135 U/l, ALP 158 U/l, GGT 178 U/l. Ultrasound examination shows fatty infiltration in the liver.

Which piece of data points towards alcoholic rather than non-alcoholic fatty liver?

A	AST:ALT ratio >2
B	Elevated ALP
C	Elevated GGT
D	Units of alcohol/week
E	USS liver

mmHg, with pulse 80/min and regular. She has a BMI of 30. Laboratory investigations show AST 293 U/l, ALT 135 U/l, ALP 158 U/l, GGT 178 U/l. Ultrasound examination shows fatty infiltration in the liver.

Which piece of data points towards alcoholic rather than non-alcoholic fatty liver?

Your answer was correct

A	AST:ALT ratio >2
B	Elevated ALP
C	Elevated GGT
D	Units of alcohol/week
E	USS liver

Explanation

A AST:ALT ratio >2

An AST:ALT ratio of >2 is highly suggestive of relatively advanced alcoholic steatohepatitis and is therefore the best option. In even milder cases of alcoholic liver disease, AST may be the only diagnostic clue.

B Elevated ALP

ALP levels are mildly elevated in this patient. Moreover, elevated levels mainly suggest biliary infiltration or obstruction.

C Elevated GGT

Normal levels of GGT help to exclude alcohol as a cause of liver disease. Despite an increased level seen in this patient, it is not helpful in distinguishing simple alcoholism and alcoholic liver disease.

D Units of alcohol/week

Despite an increased level seen in this patient, it is not helpful in distinguishing simple alcoholism and alcoholic liver disease.

D	Units of alcohol/week

Assessment of alcohol units per day is unreliable in patients with alcoholic liver disease, as consumption can easily be underestimated during history taking.

E	USS liver

Ultrasound liver provides a good evaluation of the structure and is a useful imaging method in patients with suspected alcoholic liver disease. However, USS shows fatty infiltration in both non-alcoholic steatohepatitis (NASH) and alcoholic steatohepatitis.

40121

Rate this question:

Next Question

A 36-year-old woman is admitted to the Emergency Department complaining of worsening nausea and vomiting, general malaise and anorexia. She is 36 weeks' pregnant with her first child.

On examination, there is pain in the epigastrium and right upper quadrant of the abdomen on palpation.

Investigations:

ALT	420 U/l
Bilirubin	85 μmol/l
Albumin	27g/l
Prothrombin time and activated partial thromboplastin time	Prolonged
Hb	10.1 g/dl
WCC	13.2×10^9/l
Platelets	75×10^9/l

Which of the following diagnoses fits best with this clinical picture?

Prothrombin time and activated partial thromboplastin time	Prolonged
Hb	10.1 g/dl
WCC	13.2 × 10^9/l
Platelets	75 × 10^9/l

Which of the following diagnoses fits best with this clinical picture?

A	Hepatitis A
B	Cholecystitis
C	Intrahepatic cholestasis of pregnancy
D	Fatty liver of pregnancy
E	Hyperemesis gravidarum

complaining of worsening nausea and vomiting, general malaise and anorexia. She is 36 weeks' pregnant with her first child.

On examination, there is pain in the epigastrium and right upper quadrant of the abdomen on palpation.

Investigations:

ALT	420 U/l
Bilirubin	85 μmol/l
Albumin	27g/l
Prothrombin time and activated partial thromboplastin time	Prolonged
Hb	10.1 g/dl
WCC	13.2 × 10^9/l
Platelets	75 × 10^9/l

Which of the following diagnoses fits best with this clinical picture?

Your answer was correct

D Fatty liver of pregnancy

This condition presents with nausea and vomiting and pain in the epigastrium or right upper quadrant of the abdomen. Mean gestational age at presentation is 37 weeks, although it may occur in the 28–42-week range. Abnormal investigations include hypoglycaemia, raised ammonia levels, elevated aminotransferase levels, elevated white cell count, low albumin and disseminated intravascular coagulation in up to 75% of cases. Ultrasound is the best imaging modality and allows the exclusion of other conditions such as cholecystitis. Spontaneous resolution of the condition usually follows delivery. Stabilisation on the intensive therapy unit (ITU) may be required first, and this may involve the use of intravenous (IV) fluids and glucose, correction of coagulopathy with fresh-frozen plasma, and reduction of exogenous ammonia intake through protein restriction or dietary laxatives to speed evacuation of nitrogenous wastes.

A Hepatitis A

Hepatitis A can be contracted by faecal–oral spread or consumption of shellfish. It is present in Africa and South America and causes fever, malaise, anorexia and nausea, followed by jaundice. The absence of a travel history and fever, as well as a prodromal period, makes this unlikely.

B Cholecystitis

Acute cholecystits follows impaction of the neck of the gall bladder. This causes right upper quadrant pain, fever, vomiting and peritonism locally. It is also associated with Murphy's sign and there may be a mass on palpation. The absence of fever and RUQ pain, as opposed to tenderness, makes this unlikely.

C Intrahepatic cholestasis of pregnancy

This condition is caused by a bile acid

C	Intrahepatic cholestasis of pregnancy

This condition is caused by a bile acid transporter defect and usually manifests in the last trimester. It is not associated with significant constitutional symptoms for the mother, although the risk of stillbirth and post-partum haemorrhage is slightly increased. Milder episodes may have occurred earlier in life associated with hormonal contraception, and it recurs in subsequent pregnancies. Prothrombin time may be prolonged in any cholestatic process due to deficiency of vitamin K. The presence of constitutional symptoms makes this diagnosis less likely.

E	Hyperemesis gravidarum

Hyperemesis gravidarum is intractable vomiting associated with weight loss, dehydration and disruption of electrolytes. It is more common in the first trimester and, if the patient is

A 45-year-old woman with a long history of Crohn's disease presents with increased lethargy, weight loss and diarrhoea over a period of several months.

She had undergone a very extensive small bowel resection an unknown length of time ago and has recently returned from a period of work in Thailand. While abroad, she was admitted with an episode of renal pain due to kidney stones.

On examination, she has a midline scar and is thin with a BMI of 18.5. Her BP is 125/72 mmHg.

Investigations reveal:

Blood count and film	Features suggestive of megaloblastic anaemia
Prothrombin time	21.2 s
Albumin	28 g/l
Corrected calcium	2.05 mmol/l
C-reactive	

Albumin	28 g/l
Corrected calcium	2.05 mmol/l
C-reactive protein	15 mg/l
ESR	17 mm/h

Which of the following diagnoses fits best with this clinical picture?

A Active Crohn's disease

B Short bowel syndrome

C Coeliac disease

D Tropical sprue

E Ulcerative colitis

33063

9:08
tps://mypastest.pastest.com
10

with increased lethargy, weight loss and diarrhoea over a period of several months.

She had undergone a very extensive small bowel resection an unknown length of time ago and has recently returned from a period of work in Thailand. While abroad, she was admitted with an episode of renal pain due to kidney stones.

On examination, she has a midline scar and is thin with a BMI of 18.5. Her BP is 125/72 mmHg.

Investigations reveal:

Blood count and film	Features suggestive of megaloblastic anaemia
Prothrombin time	21.2 s
Albumin	28 g/l
Corrected calcium	2.05 mmol/l
C-reactive	

B Short bowel syndrome

In patients who have removal of more than one-half of the small intestine, malabsorption syndrome may result. It may occur in patients with Crohn's disease or those with ischaemic bowel who have undergone significant bowel resection. Patients present with diarrhoea and steatorrhoea, weight loss, anaemia, osteoporosis/osteomalacia, electrolyte disturbances and hypovolaemia. In patients with more than 100 cm of jejunum, oral intake is still possible. Diarrhoea may reduce with lactose exclusion or with a course of metronidazole to eradicate bacterial overgrowth. In patients with less than 100 cm of jejunum, total parenteral nutrition is recommended as the only way to maintain adequate nutritional intake.

A Active Crohn's disease

Active Crohn's disease is unlikely given

A 31-year-old woman has been diagnosed with seronegative arthritis. She has a long history of fatigue, malaise and joint pains. She now attends for review because of the development of tremors and ataxia. Previous blood tests include elevated transaminases, serum immunoglobulin G (IgG), positive antinuclear antibody and positive anti-smooth muscle antibody. Anti-LKM antibodies are negative.

Examination reveals stigmata of chronic liver disease and a gold-yellow ring at the periphery of the iris.

Which of the following additional blood tests would fit best with this clinical picture?

A	Low serum “free” copper
B	Raised serum caeruloplasmin
C	Low serum caeruloplasmin

Examination reveals stigmata of chronic liver disease and a gold-yellow ring at the periphery of the iris.

Which of the following additional blood tests would fit best with this clinical picture?

A	Low serum “free” copper
B	Raised serum caeruloplasmin
C	Low serum caeruloplasmin
D	Raised serum uric acid
E	Raised serum phosphate

33059

Submit

antibody. Anti-LKM antibodies are negative.

Examination reveals stigmata of chronic liver disease and a gold-yellow ring at the periphery of the iris.

Which of the following additional blood tests would fit best with this clinical picture?

Your answer was correct

A	Low serum "free" copper
B	Raised serum caeruloplasmin
C	Low serum caeruloplasmin
D	Raised serum uric acid
E	Raised serum phosphate

Explanation

C Low serum caeruloplasmin

C Low serum caeruloplasmin

This patient has a picture of chronic active hepatitis, with fatigue, arthralgia and abnormal autoimmune screen, coupled with stigmata of chronic liver disease and raised transaminases. The additional new neurological symptoms point to the possibility of Wilson's disease, characterised by low serum caeruloplasmin, increased serum "free" copper, raised urinary copper excretion, low serum uric acid and phosphate and haematuria. Wilson's disease is caused by defective metabolism of dietary copper and its incorporation into caeruloplasmin, leading to decreased biliary copper excretion. Penicillamine in a dose range 0.75–1.5 g/day is standard maintenance copper chelator therapy for Wilson's disease. The starting dose is 1.5-2g daily in divided doses. Urea and electrolytes and urine analysis should be frequently undertaken. Zinc may also be employed at a standard dose of 50 mg per os tds as it inhibits intestinal absorption of copper.

should be frequently undertaken. Zinc may also be employed at a standard dose of 50 mg per os tds as it inhibits intestinal absorption of copper. Prognosis for Wilson's disease is generally good with early chelator treatment.

A Low serum "free" copper

Due to defective incorporation of copper into caeruloplasmin, serum free copper is actually increased.

B Raised serum caeruloplasmin

Low serum caeruloplasmin is a hallmark of Wilson's disease, although in patients with significant hepatic inflammation, caeruloplasmin may be falsely increased.

D Raised serum uric acid

Uric acid is actually low in patients suffering from Wilson's disease.

inflammation, caeruloplasmin may be falsely increased.

D	Raised serum uric acid

Uric acid is actually low in patients suffering from Wilson's disease.

E	Raised serum phosphate

Wilson's may present with features of renal tubular disease, leading to increased phosphate excretion. Hence normal or low phosphate, rather than increased phosphate levels are usually seen in association with the disease.

33059

Rate this question:

A 42-year-old former intravenous (IV) drug abuser presents to the Hepatology Clinic. He has been diagnosed with chronic hepatitis B infection, and has just completed a 48-week course of Peg-Interferon alpha-2a. He is noted to be Hepatitis B eAg positive. Liver disease is stable with no signs of portal hypertension and an ALT of 122 U/l.

Which of the following is the most appropriate next step?

A	Continue Interferon
B	Switch to Tenofovir
C	Switch to Lamivudine
D	Switch to Boceprevir
E	Switch to Ribavirin

Hepatology Clinic. He has been diagnosed with chronic hepatitis B infection, and has just completed a 48-week course of Peg-Interferon alpha-2a. He is noted to be Hepatitis B eAg positive. Liver disease is stable with no signs of portal hypertension and an ALT of 122 U/l.

Which of the following is the most appropriate next step?

Your answer was incorrect

A	Continue Interferon
B	Switch to Tenofovir
C	Switch to Lamivudine
D	Switch to Boceprevir
E	Switch to Ribavirin

Explanation

B Switch to Tenofovir

The management of hepatitis B and C has been revolutionised over recent years by the introduction of novel anti-viral agents. In this situation, Tenofovir is a logical next step and is recommended by NICE. Tenofovir is a nucleotide reverse transcriptase inhibitor which inhibits hepatitis B DNA replication.

C Switch to Lamivudine

Lamivudine is less effective versus modern agents such as entecavir or tenofovir, it does however carry a lower acquisition cost versus more modern agents.

A Continue Interferon

Given that interferon has failed to achieve clearance of hepatitis B, alternative therapy is required.

modern agents.

A Continue Interferon

Given that interferon has failed to achieve clearance of hepatitis B, alternative therapy is required.

D Switch to Boceprevir

Boceprevir inhibits NS3/4A serine protease and is used in the treatment of hepatitis C.

E Switch to Ribavirin

Ribavirin is used in combination with interferon for the treatment of hepatitis C, although the combination is less effective than more modern agents such as boceprevir and has therefore been largely superseded.

70041

Rate this question:

Next Question

An 82-year-old woman is admitted to the Emergency Department in the early hours of the morning after vomiting blood. Her blood pressure is 125/85 mmHg, with a pulse of 89/min, you arrange routine bloods.

Around 30 min after arrival, she has a further small (100 ml) haematemesis. Her daughter is briefly questioned and reports that her mother has been previously well apart from mild indigestion and occasional angina.

She has not been taking any medication, has no history of gastrointestinal (GI) or liver disease and does not drink alcohol.

She is taken into the resuscitation room and her initial assessment is outlined below.

Bilirubin	10 μmol/l (1–22)
Alanine aminotransferase (ALT)	21 U/l (5–35)
Albumin	40 g/l (37–49)

Hb	8.0 g/dl
WCC	10×10^9/l
PLT	300×10^9/l
PT	12 s (11.5–15.5)
Pulse	125 bpm
Blood pressure	80/40 mmHg
Respiratory rate	38/min

Which of the following would you instigate immediately?

A	Triple lumen central line placement
B	O negative (uncrossed) transfusion
C	0.9% normal saline via peripheral cannula

	15.5)
Pulse	125 bpm
Blood pressure	80/40 mmHg
Respiratory rate	38/min

Which of the following would you instigate immediately?

A Triple lumen central line placement

B O negative (uncrossed) transfusion

C 0.9% normal saline via peripheral cannula

D High dose intravenous (IV) proton pump inhibitor

E IV Terlipressin

PT	12.3 (11.5 15.5)
Pulse	125 bpm
Blood pressure	80/40 mmHg
Respiratory rate	38/min

Which of the following would you instigate immediately?

Your answer was correct

A Triple lumen central line placement

B O negative (uncrossed) transfusion

C 0.9% normal saline via peripheral cannula

D High dose intravenous (IV) proton pump inhibitor

C 0.9% normal saline via peripheral cannula

The initial step in the management of upper GI haemorrhage is the assessment of hemodynamic state. A systolic blood pressure of 80mmHg identifies the patient as 'High risk' with severe acute bleeding. 0.9% saline via peripheral cannula is given immediately to stabilize the patient, making it the best answer. Urgent GI endoscopy is indicated as soon as possible in this patient after adequate resuscitation as there is increased risk of death due to bleeding in this patient in view of his age, blood pressure reading and history of ischemic heart disease.

A Triple lumen central line placement

Triple lumen Central line is desirable in conditions of significant cardiac overload, but it should not interfere with rapid volume resuscitation via

Triple lumen Central line is desirable in conditions of significant cardiac overload, but it should not interfere with rapid volume resuscitation via large bore peripheral cannula.

B	O negative (uncrossed) transfusion

Patients with evidence of hemodynamic compromised state are given IV fluids and cross-matched for 2-4 units of red blood cells. However, it is rarely required to administer type specific or O-negative transfusion. Blood loss seen in this patient should be replaced with crystalloid initially, followed by typed and cross-matched blood. Unmatched blood should only be used in patients with uncontrolled blood loss who are unresponsive to other fluid resuscitation.

D	High dose intravenous (IV) proton pump inhibitor

High dose IV proton pump inhibitors

	proton pump inhibitor

High dose IV proton pump inhibitors have been shown to be of benefit in upper GI haemorrhage but only to prevent re-bleeding, and do not form an integral part of initial resuscitation attempts.

E	IV Terlipressin

According to British Society of Gastroenterology guidelines on upper gastrointestinal (GI) haemorrhage , it is important to exclude variceal haemorrhage due to liver disease in any patient with significant hematemesis. Normal liver function tests and lack of history makes 'oesophageal varices' highly unlikely. Thus IV terlipressin is not recommended in this case. Teripressin is preferred in reducing bleeding, as it reduces blood flow in splanchnic circulation and decreases portal blood pressure.

33008

Rate this question:

A 45-year-old man presents with weight loss of 3 kg over the last few months, abdominal pain and diarrhoea. He complains of lethargy and crampy abdominal bloating. There is no history of travel abroad and he is currently taking no medications.

Examination is unremarkable except for some minor buttock and shoulder muscle wasting and several oral aphthous ulcers.

Investigations:

Hb	9.0 g/dl
Corrected calcium	2.05 mmol/l
Albumin	35 g/l
MCV	70 fl
Serum ferritin	12 µg/l
IgG	9.0 g/l
IgA	0.1 g/l (low)
IgM	1.7 g/l

IgA	0.1 g/l (low)
IgM	1.7 g/l
Anti-endomysial antibody	-

What is the most likely diagnosis?

A Whipple's disease

B Crohn's disease

C Coeliac disease

D Lymphoma

E Jejunal diverticulosis

9831

Submit

C Coeliac disease

The symptomatology, hypocalcaemia and iron-deficiency anaemia all point towards a diagnosis of coeliac disease, which is often under-diagnosed in middle age. It can present with lethargy, non-specific gastrointestinal symptoms and anaemia of any type. A correct diagnosis with subsequent monitored adherence to a gluten-free diet is important, as untreated coeliac disease is associated with an increased risk of metabolic bone disease and gastrointestinal malignancy. Diagnosis is often made by serological testing, and this should be a routine test in the investigation of all anaemia.

Virtual absence of serum and secretory IgA is relatively common, affecting 1 in 600 people. It may be either familial or acquired following toxoplasmosis, measles or other viral infections. The basic defect is a failure of maturation of IgA-positive B cells. Immature forms are present in normal numbers. As a serological diagnosis of coeliac disease relies on the detection of IgA

serological diagnosis of coeliac disease relies on the detection of IgA antibodies to antigens, such as endomysial proteins and gliadin, selective IgA deficiency makes this test uninterpretable. Tests for IgM and IgG wheat protein antibodies are not widely utilised but can be performed if there is a strong clinical suspicion of coeliac as the underlying diagnosis.

A Whipple's disease

Whipple's disease is much rarer than coeliac disease although it can present with similar symptoms. It is thought to be acquired through enteric exposure (hence it is commoner in sewage workers), via exposure to soil.

B Crohn's disease

In Crohn's, more severe abdominal pain and diarrhoea would be expected than the picture seen here, and osteomalacia is less common in Crohn's versus coeliac disease.

than the picture seen here, and osteomalacia is less common in Crohn's versus coeliac disease.

D	Lymphoma

Small bowel lymphoma usually occurs in patients with long-standing coeliac disease, particularly when control is poor, rather than in patients with relatively short-term GI symptoms as is seen here.

E	Jejunal diverticulosis

Jejunal diverticulosis is much rarer than diverticular disease, affecting the left -side of the colon, and occur as a result of small bowel dysmotility. It can lead to bleeding and abdominal pain, and can result in abscess formation.

9831

Rate this question:

Next Question

You are asked to see an 18-year-old woman who is being treated with intravenous (IV) N-acetylcysteine for a paracetamol overdose.

She is 20 minutes into the infusion and develops facial flushing, severe itching and her blood pressure drops by 12 mmHg. The infusion has been stopped and the Foundation Year 1 (FY1) has given IV antihistamine.

Which of the following is the most appropriate next step?

A	Do not restart N-acetylcysteine
B	Give activated charcoal
C	Restart the N-acetylcysteine infusion at the same rate
D	Re-start the N-acetylcysteine infusion at half rate
E	Switch to oral therapy

You are asked to see an 18-year-old woman who is being treated with intravenous (IV) N-acetylcysteine for a paracetamol overdose.

She is 20 minutes into the infusion and develops facial flushing, severe itching and her blood pressure drops by 12 mmHg. The infusion has been stopped and the Foundation Year 1 (FY1) has given IV antihistamine.

Which of the following is the most appropriate next step?

Your answer was correct

A	Do not restart N-acetylcysteine
B	Give activated charcoal
C	Restart the N-acetylcysteine infusion at the same rate

D Re-start the N-acetylcysteine infusion at half rate

Patient on intravenous N-acetylcysteine can experience immediate or infusion-related side effects. Immediate side effects, including anaphylactoid or hypersensitivity-like reactions, have been reported in 0.3–3% of patients, in patients with low or absent paracetamol concentrations and in patients with liver cirrhosis. Infusion-related side effects occur due to rapid administration of the infusion, and are usually related to a higher incidence of hypersensitivity reactions. This patient was appropriately treated with antihistamine and N-acetylcysteine was stopped, which should be restarted at a slower rate after the adverse reaction has settled.

A Do not restart N-acetylcysteine

Paracetamol overdose can result in

liver damage that may be fatal. Intravenous acetylcysteine is the antidote to treat paracetamol overdose, and is virtually 100% effective in preventing liver damage when given within 8 h of the overdose. Therefore, this option is wrong as N-acetylcysteine should restart after adverse effects have settled, but at a slower rate.

B	Give activated charcoal

Activated charcoal is administered in patients who are clinically stable with patent airway, and if presented to the A&E within 1 h of paracetamol ingestion.

C	Restart the N-acetylcysteine infusion at the same rate

This is an incorrect option as the infusion should be restarted at a slower rate to minimise the recurrence of adverse effects.

A 31-year-old adopted man presents to his general practitioner (GP) with rectal bleeding and a change in bowel habit. Previous history of note includes osteomas of both tibia and skull osteomas. His brother is noted to suffer from ulcerative colitis and his uncle died at the age of 44 years from colon cancer.

On examination, his blood pressure (BP) is 132/72 mmHg, pulse is 72/min and regular. His BMI is 22 and his abdomen is soft and non-tender. He is anaemic with an Hb of 11.2 g/dl.

Which of the following is the most appropriate investigation in this case?

A	Rigid sigmoidoscopy
B	Flexible sigmoidoscopy
C	Colonoscopy
D	Barium enema

osteomas. His brother is noted to suffer from ulcerative colitis and his uncle died at the age of 44 years from colon cancer.

On examination, his blood pressure (BP) is 132/72 mmHg, pulse is 72/min and regular. His BMI is 22 and his abdomen is soft and non-tender. He is anaemic with an Hb of 11.2 g/dl.

Which of the following is the most appropriate investigation in this case?

A	Rigid sigmoidoscopy
B	Flexible sigmoidoscopy
C	Colonoscopy
D	Barium enema
E	Barium follow-through

33046

A 31-year-old adopted man presents to his general practitioner (GP) with rectal bleeding and a change in bowel habit. Previous history of note includes osteomas of both tibia and skull osteomas. His brother is noted to suffer from ulcerative colitis and his uncle died at the age of 44 years from colon cancer.

On examination, his blood pressure (BP) is 132/72 mmHg, pulse is 72/min and regular. His BMI is 22 and his abdomen is soft and non-tender. He is anaemic with an Hb of 11.2 g/dl.

Which of the following is the most appropriate investigation in this case?

Your answer was correct

A	Rigid sigmoidoscopy
B	Flexible sigmoidoscopy
C	Colonoscopy

This patient has altered bowel habit with rectal bleeding, coupled with the history of osteomas; it is therefore important to rule out colonic carcinoma as an underlying cause. The suspicion is that he has Gardner's syndrome, which is an autosomal dominant condition characterised by multiple adenomatous intestinal polyposis, osteomas and soft tissue tumours (epidermoid cysts, fibromas and lipomas). Individuals with the syndrome develop a multitude of colonic polyps. Colonic carcinoma develops in 7% of individuals with Gardner's syndrome by age 21 years, 50% by age 39 years and 90% by age 45 years. Colectomy is recommended once polyps appear.

A	Rigid sigmoidoscopy

Rigid sigmoidoscopy is only useful to visualise the rectum and the distal portion of the sigmoid. It isn't suitable in this case to rule out an underlying carcinoma.

B Flexible sigmoidoscopy

Flexible sigmoidoscopy can visualise the distal colon and rectum only. Genetic causes of colon cancer often result in right sided lesions, which means flexible sigmoidoscopy is inadequate in evaluating this patient.

D Barium enema

Although barium enema is an option for patients who are unable to tolerate colonoscopy, colonoscopy is preferred because of a higher identification rate for colon cancers, and the chance of making a tissue diagnosis.

E Barium follow-through

Barium follow-through is most useful to visualise the small bowel, whereas colonic polyps are associated with Gardner's syndrome.

33046

Rate this question:

A 72-year-old woman presents with dull abdominal pain and bloating. She tells you on further questioning that she has suffered intermittent episodes of abdominal pain after a heavy meal, and episodes of diarrhoea with dark blood over the past few months.

She has a history of hypertension and is clinically in atrial fibrillation. Her abdomen is distended and bowel sounds are absent.

Blood tests show an elevated white cell count, renal impairment with a creatinine of 160 μmol/l and metabolic acidosis.

What would be the most appropriate diagnostic test in the emergency situation?

A	Plasma lactates
B	Plain abdominal X-ray
C	Conventional mesenteric angiography

She has a history of hypertension and is clinically in atrial fibrillation. Her abdomen is distended and bowel sounds are absent.

Blood tests show an elevated white cell count, renal impairment with a creatinine of 160 μmol/l and metabolic acidosis.

What would be the most appropriate diagnostic test in the emergency situation?

A	Plasma lactates
B	Plain abdominal X-ray
C	Conventional mesenteric angiography
D	CT abdomen with contrast
E	Colonoscopy

D CT abdomen with contrast

This patient's history and the investigation results are very suggestive of mesenteric ischaemia. The patient's antecedent history of postprandial abdominal pain suggests there may be a degree of chronic ischaemia, and her atrial fibrillation is a risk factor for acute mesenteric arterial embolism.

Of the tests listed, mesenteric angiography is the gold standard, although it is much less obtainable in the emergency situation. Rapid diagnosis is essential among patients with clinical features and risk factors suggestive of acute intestinal ischemia to reduce the potential for intestinal infarction. The usual initial test for patients suspected of having mesenteric ischemia, such as in the case above, is contrast computed tomographic (CT) angiography without oral contrast. CT angiography has a high degree of accuracy for diagnosing mesenteric ischemia, and is also useful in excluding other causes of

also useful in excluding other causes of acute abdominal pain. The creatinine of 160, whilst being associated with an increased risk of contrast nephropathy, does not altogether preclude the examination, and attempts should be made to minimise the risk with optimal hydration.

C	Conventional mesenteric angiography

This has the advantage of offering therapeutic as well as diagnostic options, including administration of intra-arterial thrombolytic agents for acute arterial thrombosis. However, the investigation is highly invasive and unsuitable for critically ill patients; it often is not readily available, and may delay surgical management. Angiography also has a relatively high negative rate in patients presenting early in the course of acute mesenteric ischaemia. Arteriography can also precipitate acute ischaemia; thus, it is important to make sure that the patient is well hydrated.

Although mesenteric ischemia is likely to cause a raised lactate, this is non-specific and non-diagnostic, as it will rise as a result of any cause of tissue hypoperfusion.

B	Plain abdominal X-ray

In the context of mesenteric ischaemia, positive findings (ileus, small bowel obstruction, oedematous or thickened bowel walls and paucity of gas in the intestines) on plain abdominal radiography are usually late and non-specific. More specific signs, such as pneumatosis intestinalis, thumbprinting of the bowel wall and portal vein gas, are also late findings.

E	Colonoscopy

Colonoscopy, or flexible sigmoidoscopy, is usually required to confirm a diagnosis of ischaemic colitis, often after suggestive cross-sectional imaging. It does not carry any diagnostic merit in small bowel

A 43-year-old actress presents to her GP with worsening pruritus, which she finds embarrassing at work. She has a past medical history of hypothyroidism and mild rheumatoid arthritis. She is on levothyroxine only. She drinks on average one glass of wine a night.

On examination, she has mildly jaundiced sclera, xanthelasma, clubbing and hepatomegaly on examination. Her BP is 142/82 mmHg, pulse is 75/min and regular and her BMI is 25.

Given the likely clinical diagnosis, which of the following tests is most likely to be elevated /abnormal?

A	Serum IgG
B	Anti-mitochondrial antibodies
C	HDL cholesterol
D	Vitamin A

9:32
tps://mypastest.pastest.com

A 43-year-old actress presents to her GP with worsening pruritus, which she finds embarrassing at work. She has a past medical history of hypothyroidism and mild rheumatoid arthritis. She is on levothyroxine only. She drinks on average one glass of wine a night.

On examination, she has mildly jaundiced sclera, xanthelasma, clubbing and hepatomegaly on examination. Her BP is 142/82 mmHg, pulse is 75/min and regular and her BMI is 25.

Given the likely clinical diagnosis, which of the following tests is most likely to be elevated /abnormal?

Your answer was incorrect

A	Serum IgG
B	Anti-mitochondrial antibodies

B Anti-mitochondrial antibodies

This patient has a typical presentation of primary biliary cirrhosis, a condition of gradual destruction of the intrahepatic bile ducts, leading to fibrosis and cholestasis and ultimately hepatic cirrhosis, usually presented in middle aged women. Pruritis, fatigue and elevated alkaline phosphatase are some of the characteristic features seen in PBC. Anti-mitochondrial antibodies test is specific to PBC, as these antibodies are present in more than 90 % of cases.

C HDL cholesterol

High lipid and cholesterol levels (especially HDL) may be increased in patients with PBC. However, it is not the best option to select in the presence of anti-mitochondrial antibodies test, which is more specific and present in more than 90% of patients with PBC.

A	Serum IgG

Serum IgG levels are raised in cases of autoimmune pancreatitis, which is a predisposing factor of chronic pancreatitis, characterized by recurrent or persistent epigastric pain, steatorrhea and weight loss. None of these symptoms are present in this case and given the likely diagnosis of PBC, makes this option less likely to be correct. Anti-mitochondrial antibodies and *raised serum IgM* is also seen in cases of PBC.

D	Vitamin A

In patients with PBC, lack of bile can lead to inability to absorb fats and fat soluble vitamins A, D, E and K. Abnormal vitamin A level is non-specific for the diagnosis of PBC, which is a possible diagnosis here.

E	Haemoglobin

Patients with PBC can present with

A 25-year-old art student is brought into the casualty department by her flatmates following one cupful of haematemesis. She has been vomiting earlier that day after an alcohol binge over the weekend. There is no past medical problem and she is on the oral contraceptive pill. She drinks 15 units of alcohol per week, mainly during the weekends. Her mother suffers from primary biliary cirrhosis.

On examination, her heart rate is 82/minute and her blood pressure is 124/70 mmHg. There is mild epigastric discomfort. The rest of the examination is normal.

Her blood tests are as below:

Haemoglobin (Hb)	12.0 g/dl
White blood count (WBC)	6.0×10^9/l
Platelets	192×10^9/l
Mean cell volume (MCV)	85 fL
International normalised ratio (INR)	1.1

ratio (INR)	1.1
Na^+	133 mmol/l
K^+	3.2 mmol/l
Urea	6.0 mmol/l
Creatinine	61 µmol/l
Bilirubin	14 µmol/l
Alanine aminotransferase (ALT)	24 U/l (5–35)
Alkaline phosphatase (ALP)	140 U/l (30–150)
Gamma GT (GGT)	104
Albumin	38 glL

Upper gastrointestinal endoscopy shows no source of active bleeding, although a small linear tear is identified in the mucosal surface. There is no evidence of blood in the oesophagus, stomach or duodenum.

What is the most appropriate step of management?

Albumin	38 gIL

Upper gastrointestinal endoscopy shows no source of active bleeding, although a small linear tear is identified in the mucosal surface. There is no evidence of blood in the oesophagus, stomach or duodenum.

What is the most appropriate step of management?

A	Check autoantibody screen
B	Liver ultrasound
C	Prescribe non-selective beta blocker
D	Repeat endoscopy in 2 weeks
E	Discharge home with General Practitioner follow-up

E Discharge home with General Practitioner follow-up

This is a case of Mallory–Weiss tear, which is a longitudinal mucosa tear at the gastro-oesophageal junction as a consequence of forced retching or vomiting. This is produced by a sudden increase in intra-abdominal pressure. It is a common cause of upper gastrointestinal bleeding in the young, classically after an alcohol binge, and the linear tear can be seen on endoscopy. Bleeding is usually mild and transitory; therefore, management is largely conservative and patients do not require further specialist follow-up.

A Check autoantibody screen

There are no clinical signs of chronic liver disease, and liver function tests are normal. The endoscopic findings are not suggestive of a variceal bleed, which would prompt the clinician to search for an underlying cause of cirrhosis.

B Liver ultrasound

There are no clinical signs of chronic liver disease, and liver function tests are normal. Further imaging of the liver is not indicated.

C Prescribe non-selective beta blocker

Non-selective beta blockade has proven benefit in the prophylaxis of variceal bleeding. There is no role for beta blockade in the management of a Mallory-Weiss tear.

D Repeat endoscopy in 2 weeks

Provided the patient remains well, with no further bleeding, a simple Mallory-Weiss tear prompted by an obvious trigger event (vomiting after an alcohol binge) does not require a repeat endoscopy.

7396

Rate this question:

A 53-year-old woman is referred to the clinic by her general practitioner (GP) for fatigue, lethargy, mild itching, muscle and joint pains. She has a history of hypothyroidism which is treated with 100 mcg of thyroxine daily. Her TSH has been stable for the past 5 years.

On examination, there is jaundice, with mild hepatomegaly and more than five spider naevi on the upper body.

Investigations reveal:

Bilirubin	125 μmol/l
ALT	230 U/l
ALP	185 U/l
Albumin	28 g/l
Hypergammaglobulinaemia	polyclonal
Anti-smooth muscle antibodies	positive
Anti-nuclear antibody	positive

Which of the following diagnoses fits

ALP	185 U/l
Albumin	28 g/l
Hypergammaglobulinaemia	polyclonal
Anti-smooth muscle antibodies	positive
Anti-nuclear antibody	positive

Which of the following diagnoses fits best with this clinical picture?

A	Primary sclerosing cholangitis
B	Primary biliary cirrhosis
C	Type 1 autoimmune hepatitis
D	Type 2 autoimmune hepatitis
E	Type 3 autoimmune hepatitis

C Type 1 autoimmune hepatitis

Autoantibodies associated with type 1 autoimmune hepatitis include anti-smooth muscle antibodies, antinuclear antibodies and anti-actin antibodies. Autoimmune hepatitis is much more common in women. Diagnosis and prognostic assessment is best informed via liver biopsy. After an initial period of high-dose prednisolone, azathioprine is often added as a steroid-sparing agent. A number of physicians employ a maintenance regime of prednisolone 10 mg and azathioprine 50 mg per day as maintenance therapy. Initial remission is possible in around 80% of patients, though relapse often occurs if therapy is withdrawn. Liver transplant is successful in patients who fail medical therapy.

A Primary sclerosing cholangitis

Primary sclerosing cholangitis is associated with inflammatory bowel

9:41
tps://mypastest.pastest.com
10

B Primary biliary cirrhosis

Primary biliary cirrhosis is associated with an obstructive liver function test picture, and positive anti-mitochondrial antibodies.

D Type 2 autoimmune hepatitis

Type 2 autoimmune hepatitis occurs predominantly in children and is associated with anti-liver kidney microsomal antibodies.

E Type 3 autoimmune hepatitis

Type 3 autoimmune hepatitis is associated with soluble liver or liver-kidney antigens.

33050

Rate this question:

The following are serial liver function tests of a 75-year-old, retired, white businessman. He had an abdominal aortic aneurysm repair for ruptured aneurysm in the 1980s while on holiday in Turkey.

He takes antacids for dyspepsia and drinks approximately 5 units of alcohol per week. He was prescribed atorvastatin five years ago by his general practitioner (GP) for hypercholesterolaemia.

Apart from mild jaundice, physical examination is unremarkable. His body mass index (BMI) is 25.

Liver function tests:

	1988	1994	2006	2
Bilirubin (mmol/) (< 17 l)	16	21	28	4
Alanine aminotransferase (U/l) (5–35)	35	36	45	5
Aspartate aminotransferase	43	49	70	7

aminotransferase (U/l) (10–40)	43	49	70	7
Alkaline phosphatase (U/l) (30–150)	111	135	156	1

Anti-mitochondrial antibodies: negative

Anti-smooth muscle antibodies: negative

What is the most likely cause for his abnormal liver function tests?

A	Chronic active hepatitis due to autoimmune pathology
B	Primary biliary cirrhosis
C	Drug-induced hepatitis
D	Chronic active hepatitis due to hepatitis C
E	Non-alcoholic steatohepatitis

The following are serial liver function tests of a 75-year-old, retired, white businessman. He had an abdominal aortic aneurysm repair for ruptured aneurysm in the 1980s while on holiday in Turkey.

He takes antacids for dyspepsia and drinks approximately 5 units of alcohol per week. He was prescribed atorvastatin five years ago by his general practitioner (GP) for hypercholesterolaemia.

Apart from mild jaundice, physical examination is unremarkable. His body mass index (BMI) is 25.

Liver function tests:

	1988	1994	2006	2
Bilirubin (mmol/) (< 17 l)	16	21	28	4
Alanine aminotransferase (U/l) (5–35)	35	36	45	5

D Chronic active hepatitis due to hepatitis C

The man has had major surgery in the past that almost certainly required blood transfusion. Both hepatitis B and C are easily contracted from blood transfusion. Since screening donated blood for hepatitis B was initiated in the 1980s, hepatitis C has become the most common cause of post-transfusion hepatitis in the Western world. Given that his repair had occurred in Turkey many years ago, the risk of blood-borne viruses may be significantly increased.

Twenty per cent of patients with hepatitis B infection will develop chronic active hepatitis, whereas the incidence is higher (50%) in hepatitis C infection. Patients are usually asymptomatic or may present with a slowly progressive hepatitis. The aminotransferase and bilirubin are usually mildly raised. The histological landmark of chronic active hepatitis is piecemeal necrosis.

C Drug-induced hepatitis

Drugs known to cause hepatitis include methyldopa and isoniazid. Statins may result in subclinical myositis, which is associated with transaminase elevation.

A Chronic active hepatitis due to autoimmune pathology

Although autoimmune chronic active hepatitis is a differential here, the history of major surgery in Turkey means that viral hepatitis should be ruled out first.

B Primary biliary cirrhosis

Primary biliary cirrhosis is associated with anti-mitochondrial antibodies, itching, lethargy and an obstructive picture on liver function testing.

E Non-alcoholic steatohepatitis

A 37-year-old lawyer attends the Outpatient Clinic with deranged liver function tests noted at an insurance medical. She feels well, has no past medical history and takes no medications.

Her family history includes a grandmother with type 2 diabetes. She is a non-smoker and drinks one glass of wine every other day.

On examination, she is obese with a body mass index (BMI) of 31 kg/m^2 and some mild right upper quadrant (RUQ) tenderness is elicited on palpation. An ultrasound scan of the abdomen reveals an enlarged homogenous echo-bright liver with normal spleen size.

Some of her investigations are outlined below.

Alanine aminotransferase (ALT)	102 U/l (5–35)
Albumin	40 g/l (37–49)
Autoantibodies	Negative

Autoantibodies	Negative
Bilirubin	20 μmol/l (1–22)
Cholesterol	7.6 mmol/l (< 5.2)
Fasting blood glucose	11.5 mmol/l
γ-Glutamyl transferase (GGT)	80 U/l (4–35)
Liver transaminase (AST)	80 U/l (1–31)
Triglycerides	2.0 mmol/l (0.45–1.69)

Which of the following is likely to have the greatest impact in improving her liver function tests?

A	Rapid weight loss aiming for a minimum of 2.5 kg/week
B	Vitamin E

transferase (GGT)	80 U/l (4–35)
Liver transaminase (AST)	80 U/l (1–31)
Triglycerides	2.0 mmol/l (0.45–1.69)

Which of the following is likely to have the greatest impact in improving her liver function tests?

A	Rapid weight loss aiming for a minimum of 2.5 kg/week
B	Vitamin E
C	Ursodeoxycholic acid
D	Supervised exercise programme with group weight loss counselling
E	Metformin

D Supervised exercise programme with group weight loss counselling

Non-alcoholic fatty liver disease (NAFLD) should always be considered in obese individuals with abnormal liver function tests (LFTs) without evidence of alcohol excess. It is often asymptomatic but hepatic enlargement due to lipid deposition within hepatocytes (making them appear bright in ultrasound) can lead to RUQ pain. It is impossible to tell from liver function tests alone whether fatty liver is associated with inflammation (steatohepatitis) and eventually a small percentage of patients will go on to develop fibrosis and cirrhosis. As yet, there has been no strong genetic association found in NAFLD or the metabolic syndrome.

NAFLD is considered to exist as part of a wider metabolic syndrome that also includes insulin resistance and dyslipidaemia. Patients with NAFLD are therefore at high risk of developing cardiovascular disease and diabetes.

dyslipidaemia. Patients with NAFLD are therefore at high risk of developing cardiovascular disease and diabetes. Treatment of the other elements of the metabolic syndrome such as diabetes and hyperlipidaemia will reduce mortality and morbidity. Statins are not contraindicated in NAFLD despite the widespread misconception that they cause significant derangement of LFTs.

Weight loss of 1 kg/week with an initial target loss of 10% bodyweight has been shown to be effective at restoring normal liver function. Exercise programmes with group weight loss counselling are the most effective way to aid weight loss and reduce insulin resistance. Surgical aids to weight loss have been shown to be effective but are recommended for the morbidly obese (BMI >35 kg/m^2) in whom other strategies have failed.

A	Rapid weight loss aiming for a minimum of 2.5 kg/week

Non-alcoholic fatty liver disease is improved by weight loss but rapid

Non-alcoholic fatty liver disease is improved by weight loss but rapid weight loss has been associated with worsening liver disease; as such, a more gradual reduction in weight is advised.

B Vitamin E

Previously, vitamin E has been proposed to provide an antioxidant effect in NAFLD. However, there is currently no evidence to support the use of vitamin E in clinical practice.

C Ursodeoxycholic acid

Previously, ursodeoxycholic acid has been proposed for use in NAFLD to provide a cytoprotective effect. However, there is currently no evidence to support the use of ursodeoxycholic acid in clinical practice.

D Metformin

You review a 36-year-old man in the Dermatology Clinic. He has developed some nasty-looking pustules on his shin that have now formed an ulcerated patch, look blue-black and are very unsightly.

The general practitioner (GP) is concerned that he may have a spreading bacterial infection. There is a past history of diarrhoea but nil else of note.

Blood testing reveals elevated viscosity, C-reactive protein (CRP) and alkaline phosphatase. Biopsy of the ulcer edge reveals an intense neutrophilic infiltrate and evidence of vasculitis.

Which of the following represents the most likely underlying reason for his bowel symptoms and skin changes?

A	Ulcerative colitis
B	Systemic lupus erythematosus (SLE)

Blood testing reveals elevated viscosity, C-reactive protein (CRP) and alkaline phosphatase. Biopsy of the ulcer edge reveals an intense neutrophilic infiltrate and evidence of vasculitis.

Which of the following represents the most likely underlying reason for his bowel symptoms and skin changes?

A	Ulcerative colitis
B	Systemic lupus erythematosus (SLE)
C	Primary biliary cirrhosis (PBC)
D	Coeliac disease
E	Lymphocytic colitis

33072

Submit

Dermatology Clinic. He has developed some nasty-looking pustules on his shin that have now formed an ulcerated patch, look blue-black and are very unsightly.

The general practitioner (GP) is concerned that he may have a spreading bacterial infection. There is a past history of diarrhoea but nil else of note.

Blood testing reveals elevated viscosity, C-reactive protein (CRP) and alkaline phosphatase. Biopsy of the ulcer edge reveals an intense neutrophilic infiltrate and evidence of vasculitis.

Which of the following represents the most likely underlying reason for his bowel symptoms and skin changes?

Your answer was correct

A	Ulcerative colitis
B	Systemic lupus erythematosus (SLE)

A Ulcerative colitis

The ulcerated lesion is pyoderma gangrenosum, which may be associated with inflammatory bowel disease, rheumatoid arthritis, haematological malignancy, primary biliary cirrhosis or idiopathic (up to 20%). Treatment is with topical and/or high-dose oral steroids. The raised alkaline phosphatase raises the possibility that he may have co-existent primary sclerosing cholangitis. Up to 75% of cases of primary sclerosing cholangitis occur in patients with co-existent inflammatory bowel disease, and PSC is commoner in males. Ultrasound followed by magnetic resonance cholangiopancreatography (MRCP) is the investigational plan of choice.

B Systemic lupus erythematosus (SLE)

SLE doesn't usually result in pyoderma gangrenosum but results in lupus

SLE doesn't usually result in pyoderma gangrenosum but results in lupus panniculitis, which can resemble erythema nodosum.

C	Primary biliary cirrhosis (PBC)

Primary biliary cirrhosis may be associated with pyoderma gangrenosum, but the absence of itching and the presence of diarrhoea counts against PBC as the underlying diagnosis.

D	Coeliac disease

Coeliac disease is associated with dermatitis herpetiformis rather than with pyoderma gangrenosum.

E	Lymphocytic colitis

Lymphocytic colitis is associated with diarrhoea but not with pyoderma gangrenosum. Drug causes of lymphocytic colitis include drugs such as proton pump inhibitors, ranitidine

A 60-year-old woman is seen in the cardiology outpatient with a new murmur. She also describes intermittent episodes of flushing and diarrhoea for the last 4 months. She has a history of hay fever and complains of intermittent wheeziness which she has never had before.

On examination, the blood pressure and jugular venous pressure are normal. There is a diastolic murmur in the pulmonary area which increases with inspiration. Her chest is clear. There is a palpable liver edge with right upper quadrant tenderness. Neurological examination is normal.

Which of the following investigations is most appropriate?

A	Fasting gut hormones
B	Thyroid function test
C	Urinary catecholamines

complains of intermittent wheeziness which she has never had before.

On examination, the blood pressure and jugular venous pressure are normal. There is a diastolic murmur in the pulmonary area which increases with inspiration. Her chest is clear. There is a palpable liver edge with right upper quadrant tenderness. Neurological examination is normal.

Which of the following investigations is most appropriate?

A	Fasting gut hormones
B	Thyroid function test
C	Urinary catecholamines
D	Urinary 5-hydroxyindoleacetic acid (HIAA)
E	Urinary serotonin

D Urinary 5-hydroxyindoleacetic acid (HIAA)

The presentation is consistent with a diagnosis of carcinoid syndrome. 90% of all carcinoid tumours are present in the GI tract (favouring the appendix and terminal ileum). Presentations include cutaneous flushing, diarrhoea, bronchospasm and cardiac abnormalities secondary to the paraneoplastic effects of the secretion of hormones. Cardiac abnormalities tend to be right-sided, resulting in tricuspid and pulmonary stenosis or regurgitation; the murmur here implies pulmonary regurgitation (diastolic, louder on inspiration) making the diagnosis most likely.

Carcinoid tumours take up tryptophan and convert it to serotonin, which is responsible for the symptoms of flushing, diarrhoea and bronchospasm. Serotonin is in turn broken down to 5-HIAA, almost all of which is excreted in urine and therefore the investigation of choice is urinary 5-HIAA. Altered

HIAA, almost all of which is excreted in urine and therefore the investigation of choice is urinary 5-HIAA. Altered tryptophan metabolism occurs in almost all patients with carcinoid, where up to 70% is converted to serotonin.

A	Fasting gut hormones

Gut hormones include a panel of glucagon, gastrin, vasoactive intestinal peptide and somatostatin that are tested when certain secreting neuroendocrine tumours are suspected. Gastrin is elevated in Zollinger–Ellison syndrome/gastrinoma/MEN type I. One would expect a history of recurrent peptic ulcers. VIP is measured when a suspected VIPoma occurs. This causes diarrhoea and flushing with hypotension (hence not the diagnosis here). Glucagon is measured when a glucagon-secreting tumour of the pancreas is noted (seen with diabetes and a characteristic rash – necrolytic migratory erythema). A

with diabetes and a characteristic rash – necrolytic migratory erythema). A somatostatin-secreting tumour will present with symptoms of diabetes, gallstones and steatorrhea.

B	Thyroid function test

Although the diarrhoea and flushing could be explained by hyperthyroidism, it would not explain the wheeze and enlarged liver; therefore an alternative diagnosis is more likely.

C	Urinary catecholamines

Urinary catecholamines are used to detect phaechromocytoma.

E	Urinary serotonin

Serotonin is metabolised to 5-HIAA, which is secreted in the urine, and therefore measurement of urinary serotonin would be pointless.

A 31-year-old lawyer was referred by his general practitioner (GP) who had investigated him for tiredness.

As part of a screen of blood tests, he had been found to have abnormal liver function tests. He had occasionally used intravenous (iv) drugs as a student but had not done so recently. He is married and has had no other sexual partners for the last 4 years.

Other than feeling tired, he is asymptomatic. He takes no regular medications and drinks 40 units of alcohol a week.

Blood tests:

Bilirubin	21 μmol/l
AST	85 U/l
ALT	165 U/l
ALP	112 U/l
Hepatitis serology:	
Hepatitis A IgM	negative
Hepatitis A IgG	negative

Hepatitis A IgM	negative
Hepatitis A IgG	negative
HBsAg	positive
HBeAg	positive
Anti-HBc antibody	positive
Anti-HBe antibody	negative
Hepatitis C virus antibody	negative

Which one of the following is the most appropriate initial intervention?

A Boceprevir

B Ribavirin

C Tenofovir

D Hepatitis B vaccination

E Peginterferon alpha-2a

Hepatitis serology:	
Hepatitis A IgM	negative
Hepatitis A IgG	negative
HBsAg	positive
HBeAg	positive
Anti-HBc antibody	positive
Anti-HBe antibody	negative
Hepatitis C virus antibody	negative

Which one of the following is the most appropriate initial intervention?

Your answer was incorrect

A Boceprevir

B Ribavirin

C Tenofovir

E Peginterferon alpha-2a

NICE guidelines recommend an initial period of treatment for 48 months with peginterferon for chronic hepatitis B infection, the most likely diagnosis here. Where treatment failure occurs, other agents are then considered.

C Tenofovir

Tenofovir is recommended as an option for the treatment of hepatitis B in patients who fail to respond to interferon alone.

A Boceprevir

Boceprevir is an inhibitor of NS3/4A serine protease, a key enzyme involved in the replication of hepatitis C, it therefore has no role in the treatment of chronic hepatitis B.

B Ribavirin

E Peginterferon alpha-2a

NICE guidelines recommend an initial period of treatment for 48 months with peginterferon for chronic hepatitis B infection, the most likely diagnosis here. Where treatment failure occurs, other agents are then considered.

C Tenofovir

Tenofovir is recommended as an option for the treatment of hepatitis B in patients who fail to respond to interferon alone.

A Boceprevir

Boceprevir is an inhibitor of NS3/4A serine protease, a key enzyme involved in the replication of hepatitis C, it therefore has no role in the treatment of chronic hepatitis B.

B Ribavirin

A Boceprevir

Boceprevir is an inhibitor of NS3/4A serine protease, a key enzyme involved in the replication of hepatitis C, it therefore has no role in the treatment of chronic hepatitis B.

B Ribavirin

Ribavirin is an option in combination with interferon in the initial treatment of hepatitis C, although this combination has now been overtaken by agents such as boceprevir.

D Hepatitis B vaccination

Hepatitis B vaccination has no role here and doesn't significantly impact on viral clearance.

70151

Rate this question:

Next Question

A 29-year-old woman is admitted acutely with severe abdominal pain, nausea and vomiting. She has a history of poorly-controlled epilepsy.

On questioning, she denies any unusual behaviour other than commencing a 'low-carb' diet 2 weeks previously. As well as her normal gabapentin, she has been taking paracetamol and aspirin for her abdominal pain.

On examination, she has peritonism and appears to have some proximal muscle weakness. The nurses notice that her urine is dark and changes colour on standing.

Tests reveal:

Urea	15.0 mmol/l
Creatinine	85 µmol/l
Sodium	125 mmol/l
Potassium	4.0 mmo/l
	5.0

Blood glucose	5.0 mmol/l
Full blood count (FBC)	Normal
Arterial pH	7.31
Computed tomography (CT) of the abdomen	Normal
Urinalysis	Ketones ++
Urinary porphobilinogen	300 µmol//dl (0–18)

Given the likely diagnosis, which one of the following is the most suitable therapeutic option?

A	Intravenous insulin infusion
B	Discontinuation of paracetamol and aspirin
C	Intravenous haem arginate

Urinary porphobilinogen	300 µmol//dl (0–18)

Given the likely diagnosis, which one of the following is the most suitable therapeutic option?

A	Intravenous insulin infusion
B	Discontinuation of paracetamol and aspirin
C	Intravenous haem arginate
D	Intravenous metoclopramide
E	Intravenous lorazepam

33006

Submit

C Intravenous haem arginate

The presentation of severe abdominal pain in young people, particularly accompanied by neurological symptoms, should alert to the possibility of an acute porphyria. This diagnosis is confirmed by the increased levels of urinary porphobilinogens although the type of porphyria cannot be determined by this test alone. Attacks can be precipitated by drugs, infections, smoking and crash dieting, particularly low carbohydrate intake. Symptoms include severe neuropathic abdominal pain (85–95%) vomiting (50–90%) paresis (40–70%) and seizures (10–20%). Hypertension and hyponatraemia are often features, and should be corrected due to the increased risk of seizures.

Paracetamol and aspirin are safe in porphyria as well as gabapentin (used to control seizure activity). Most other anti-epileptics (including clonazepam) may exacerbate attacks, as does metoclopramide (phenothiazines

anti-epileptics (including clonazepam) may exacerbate attacks, as does metoclopramide (phenothiazines should be used to control nausea).

The treatment of choice in acute porphyria is intravenous haem arginate, although high-glucose diets or infusions have been used for mild attacks of pain without neurological symptoms.

A	Intravenous insulin infusion

Ketoacidosis is due to the high-protein low-carbohydrate diet, and in the presence of a normal blood glucose, does not respond to an insulin infusion.

B	Discontinuation of paracetamol and aspirin

Both paracetamol and aspirin are safe to use in porphyria and therefore there is no indication to stop them in this patient.

to use in porphyria and therefore there is no indication to stop them in this patient.

D	Intravenous metoclopramide

Metoclopramide may exacerbate an acute porphyria and therefore should be avoided.

E	Intravenous lorazepam

Intravenous lorazepam would be indicated in the presence of status epilepticus and is safe to use in patients with porphyria but there is no indication that the patient is currently experiencing any seizure activity. Clonazepam should however be avoided is it can exacerbate an acute porphyria.

33006

Rate this question:

Next Question

A 35-year-old Greek man was referred to the Hepatology Clinic with abnormal liver function tests and a positive hepatitis B surface antigen. He works as a taxi driver and drinks three cans of beer in the evening. He has never had any blood transfusion or intravenous drug abuse.

Investigations:

Bilirubin	24 μmol/l
Alanine transferase (ALT)	78 U/l (5-35)
Alkaline phosphatase (ALP)	143 U/l (30–150)
Albumin	35 g/l
Serum ferritin	400 μg/l

Further hepatitis B serology reveals:

Hepatitis B e antigen	Negative
Anti-hepatitis B core IgM	Negative
Total anti-HB core	Positive

Further hepatitis B serology reveals:

Hepatitis B e antigen	Negative
Anti-hepatitis B core IgM	Negative
Total anti-HB core	Positive
Hepatitis B DNA	Positive

Which of the following best describes his likely diagnosis?

A	Acute hepatitis B infection
B	Hepatitis B with delta virus superinfection
C	Chronic hepatitis B carrier of high infectivity
D	Hepatitis B infection with pre-core mutant
E	Previous hepatitis B infection

Serum ferritin	400 µg/l

Further hepatitis B serology reveals:

Hepatitis B e antigen	Negative
Anti-hepatitis B core IgM	Negative
Total anti-HB core	Positive
Hepatitis B DNA	Positive

Which of the following best describes his likely diagnosis?

Your answer was correct

A Acute hepatitis B infection

B Hepatitis B with delta virus superinfection

C Chronic hepatitis B carrier of high infectivity

D Hepatitis B infection with pre-core mutant

D Hepatitis B infection with pre-core mutant

Chronic hepatitis B is defined as the persistence of hepatitis B surface antigen (HBsAg) in the circulation for more than six months after clinical infection. HBeAg is a marker of infectivity in all patients except those who have hepatitis B virus (HBV) pre-core mutant or the core promoter mutant, because they do not synthesise HbeAg (as seen in this case). This is most commonly due to a stop-codon mutation at nucleotide 1896. So the learning here is that although the e antigen is negative, this patient still has active hepatitis B and is still infective.

Response to interferon is not good and relapse rates tend to be high. Treatment of chronic hepatitis is aimed at patients with active disease and viral replication, preferably at a stage before cirrhosis has developed. Patients are selected for antiviral therapy if they have an increased

is still infective.

Response to interferon is not good and relapse rates tend to be high. Treatment of chronic hepatitis is aimed at patients with active disease and viral replication, preferably at a stage before cirrhosis has developed. Patients are selected for antiviral therapy if they have an increased alanine transferase on two occasions, detectable HBV DNA and/or HbeAg in their serum, and a liver biopsy that show fibrosis.

A	Acute hepatitis B infection

This is unlikely, firstly because the clinical history does not suggest an acute infection as acute RUQ pain and jaundice are missing. Secondly, one would expect there to be a greater ALT rise and IgM to be positive.

B	Hepatitis B with delta virus superinfection

Delta virus, or hepatitis D virus, is an

A 68-year-old man presents to the clinic complaining of further tiredness and lethargy. He had been previously diagnosed by his GP with iron deficiency anaemia and started on iron replacement. A colonoscopy conducted two years ago was reported as normal. As his Hb had fallen to 88 g/l he received a 2-unit blood transfusion. He has no other symptoms and notably his appetite is good and there is no weight loss. You review him in the clinic some three weeks later and his results are summarised below.

Investigations:

Hb	8.6 g/dl
WCC	4.5×10^9/l
PLT	390×10^9/l
Na^+	139 mmol/l
K^+	5.3 mmol/l
Creatinine	123 μmol/l
Upper GI endoscopy	Normal

endoscopy	Normal
Colonoscopy	No abnormality visualised
Faecal occult blood sample	+

Which of the following is the investigation most likely to contribute to the diagnosis?

A	Radionucleotide scanning
B	Selective mesenteric angiography
C	Repeat colonoscopy
D	Repeat upper GI endoscopy
E	Capsule endoscopy

18648

Submit

E Capsule endoscopy

It is clear from the investigations shown that this patient is experiencing continued bleeding from the GI tract. It is possible that angiodysplasia affecting the right side of the colon has been missed. After diverticulosis, angiodysplasia is the second leading cause of lower GI bleeding in patients older than 60 years, and the ascending colon and caecum are the most commonly affected sites. Treatment of angiodysplasia involves endoscopic therapy such as cautery or sclerotherapy, angioembolisation or selective surgical resection as an alternative.

A Radionucleotide scanning

Radionucleotide scanning is only really effective as a diagnostic tool when frank GI bleeding is taking place.

B Selective mesenteric angiography

A Radionucleotide scanning

Radionucleotide scanning is only really effective as a diagnostic tool when frank GI bleeding is taking place.

B Selective mesenteric angiography

Evidence suggests that capsule endoscopy is better than abdominal CT or selective mesenteric angiography with respect to detection of obscure bleeding sites.

C Repeat colonoscopy

Repeating colonoscopy is unlikely to provide any further information leading to diagnosis, as he had a previously normal and recent colonoscopy. Had the colonoscopy been reported as limited due to insufficient bowel prep, then this would be a possible choice.

A previously fit and well 32-year-old man presents with a 2-year history of watery diarrhoea, which he says does not float. There is no history of blood, and faecal occult blood and faecal elastase testing have been normal.

He has taken lansoprazole for treatment of gastroesophageal reflux disease for most of those 24 months.

Blood tests for endomysial antibody and thyroid function have been normal, but his white cell count was slightly elevated at 12.6×10^9/l and erythrocyte sedimentation rate elevated at 32 mm/h. Colonic imaging has not yet been performed.

Which is the most appropriate next step?

A	Colonscopy with biopsy
B	Ultrasound abdomen
C	Barium enema

treatment of gastroesophageal reflux disease for most of those 24 months.

Blood tests for endomysial antibody and thyroid function have been normal, but his white cell count was slightly elevated at 12.6×10^9/l and erythrocyte sedimentation rate elevated at 32 mm/h. Colonic imaging has not yet been performed.

Which is the most appropriate next step?

A	Colonscopy with biopsy
B	Ultrasound abdomen
C	Barium enema
D	CT colonography
E	Reassure and discharge

9522

Submit

A Colonscopy with biopsy

The fact that the diarrhoea doesn't float, and endomysial antibodies are normal, makes significant small bowel malabsorption less likely. Long-term use of lansoprazole raises the possibility of lymphocytic colitis, a condition associated with long-term use of PPIs. Colonoscopy with biopsy is therefore the most appropriate next step in investigation. Withdrawal of the PPI usually leads to gradual resolution of inflammation.

B Ultrasound abdomen

Ultrasound of the abdomen is most useful if a hepatic or pancreatic lesion is suspected. The fact that malabsorption isn't present counts against pancreatitis as the underlying cause of his symptoms, and there is no history of excess alcohol consumption.

C Barium enema

against pancreatitis as the underlying cause of his symptoms, and there is no history of excess alcohol consumption.

C	Barium enema

Colonoscopy is preferred to barium enema because it offers the possibility of biopsy to confirm the underlying diagnosis.

D	CT colonography

CT colonography is suboptimal versus barium enema with respect to imaging, and again doesn't permit biopsy.

E	Reassure and discharge

The symptoms fit with colitis, and are debilitating. As such, reassurance and discharge is clearly not appropriate.

9522

Rate this question:

Next Question

A 38-year-old woman is referred to the clinic for abnormal liver function tests. She denies illicit drug or excess alcohol use. Her general practitioner (GP) is concerned as her alanine aminotransferase is twice the normal limit and alkaline phosphatase is also slightly elevated.

On examination, she is grossly obese with a body mass index (BMI) of 36; her BP is also elevated at 155/82 mmHg. No other significant findings are noted. Hepatitis B and C serology is negative.

Which of the following is the most useful initial investigation in this case?

A	Ferritin estimation
B	Autoimmune profile
C	Abdominal CT scan
D	Abdominal ultrasound scan

D Abdominal ultrasound scan

This patient is obese with abnormal liver function tests and the most likely diagnosis is non-alcoholic steatohepatitis (NASH). Ultrasound will rule out significant other disease of the liver or biliary tract and is likely to be hyperechogenic; fatty infiltration may be visualised when it is above 30% of the liver mass. Further investigations for NASH include an MRI to provide more accurate estimation of liver fat, magnetic resonance elastography (MRE) to estimate liver stiffness, and liver biopsy. Weight loss is the mainstay of treatment for this condition. Orlistat has been shown to reduce hepatic fat, as has pioglitazone, although neither is licensed for the treatment of hepatic steatosis.

A Ferritin estimation

Although ferritin may be elevated, it is a non-specific finding in chronic liver disease and is therefore not useful in

B Autoimmune profile

Transaminases are elevated, which makes autoimmune hepatitis a possibility, although with the marked elevation in BMI, NASH should be considered the most likely diagnosis.

C Abdominal CT scan

CT scan is less useful with respect to elucidating liver architecture than MRI. The correct sequence of investigations is therefore liver USS followed by MRI scanning later.

E Liver biopsy

Liver biopsy is usually required to confirm the diagnosis of NASH and provide evidence on histological staging of cirrhosis, although it is usually done after initial radiological investigations.

33056

Rate this question:

You are asked to review a 32-year-old woman with a history of ulcerative colitis. She was admitted 3 days earlier with a flare of her ulcerative colitis and treated with intravenous (iv) corticosteroids and broad-spectrum antibiotics, although the nurses tell you she has not really improved. She is still opening her bowels 10 times per day with watery, blood-stained diarrhoea.

Examination reveals a temperature of 38.4 °C; her BP is 105/70 mmHg, with pulse 90/min and regular. Her abdomen is generally tender, although soft, and she has active bowel sounds.

Investigations:

Hb	10.1 g/dl
WCC	13.9×10^9/l
PLT	155×10^9/l
Na^+	137 mmol/l
K^+	3.5 mmol/l
Creatinine	110 micromol/l
ESR	85 mm/1st h

Na^+	137 mmol/l
K^+	3.5 mmol/l
Creatinine	110 micromol/l
ESR	85 mm/1st h
CRP	180 mg/l
Abdominal X-ray	Colon diameter 5.5 cm

Which of the following is the most appropriate next step?

A Azathioprine

B Colectomy

C Ciclosporin

D Cyclophosphamide

E Rectal Mesalazine

C Ciclosporin

Intravenous ciclosporin has a role in induction of remission in patients with severe or fulminant colitis. According to NICE guidelines, it is usually offered to patients who are on steroids for 72 h without any improvement. Thus it is an appropriate next step in this case, but is not effective for long-term use. Ciclosporin is given as a continuous IV infusion of 2 mg/kg over 24 h, which can be adjusted according to concentration of the drug in the blood and its response.

A Azathioprine

Azathioprine is recommended in patients with corticosteroid-dependent ulcerative colitis, and is an effective agent for relapse prevention. NICE guidelines suggest that if aminosalicylate does not work well in preventing flare-ups, then azathioprine or mertcaptopurine can be used.

C Ciclosporin

Intravenous ciclosporin has a role in induction of remission in patients with severe or fulminant colitis. According to NICE guidelines, it is usually offered to patients who are on steroids for 72 h without any improvement. Thus it is an appropriate next step in this case, but is not effective for long-term use. Ciclosporin is given as a continuous IV infusion of 2 mg/kg over 24 h, which can be adjusted according to concentration of the drug in the blood and its response.

A Azathioprine

Azathioprine is recommended in patients with corticosteroid-dependent ulcerative colitis, and is an effective agent for relapse prevention. NICE guidelines suggest that if aminosalicylate does not work well in preventing flare-ups, then azathioprine or mertcaptopurine can be used.

B Colectomy

Colectomy is indicated in patients with fulminant colitis and who fail to respond to cyclosporin (due to either a failure to respond or relapse) within 4–7 days, and in those with toxic megacolon (diameter ≥6 cm or caecum >9 cm and systemic toxicity) who do not respond to therapy within 72 h. Surgery is also indicated if the patient experiences frequent flare-ups and whose quality of life is adversely affected by the condition.

D Cyclophosphamide

Cyclophosphamide has a role in cases of Crohn's disease, but has no role in the management of ulcerative colitis flare-ups. Cyclophosphamide is also used in cases of rheumatoid arthritis with severe systemic manifestation.

E Rectal Mesalazine

Mesalazine (5-aminosalicylic acid) is

A 66-year-old woman is seen in clinic with a 3-month history of watery diarrhoea 5–10 times per day. She is otherwise in reasonable health but takes regular non-steroidal anti-inflammatory drugs for her osteoarthritis. She also takes omeprazole. She has the watery diarrhoea regardless of whether she eats or not. She has no associated abdominal pain or vomiting and she has no blood mixed in with the stool. She has lost 5 kg in weight.

On examination, she looks well and is afebrile. Her abdomen is soft with no organomegaly.

Investigations:

Sodium	141 mmol/l
Potassium	3.4 mmol/l
Creatinine	68 μmol/l
Albumin	35 g/l
White cell count (WCC)	6.4×10^9/l

C-reactive protein (CRP)	10 µg/l
Erythrocyte sedimentation rate (ESR)	16 mm/h
Stool microscopy	Leukocytes present, no organisms seen
C difficile toxin	-
Colonoscopy	Normal appearance macroscopically – increased cellular infiltrate in the lamina propria

What is the most likely diagnosis?

A Crohn's colitis

B Ulcerative colitis

C Microscopic colitis

Stool microscopy	Leukocytes present, no organisms seen
C difficile toxin	-
Colonoscopy	Normal appearance macroscopically – increased cellular infiltrate in the lamina propria

What is the most likely diagnosis?

A Crohn's colitis

B Ulcerative colitis

C Microscopic colitis

D Giardiasis

E Amyloidosis

C Microscopic colitis

This condition is defined by the triad of watery diarrhoea, normal colonoscopy and increased inflammation of the lamina propria of the colon. This disease includes collagenous and lymphocytic colitis. It is an uncommon disease with an incidence of 5/100,000 per year and affects older patients (mean age 55–68 years) and women. There is a link with non-steroidal anti-inflammatory drugs (NSAIDs), omeprazole, lansoprazole, ticlopidine and cimetidine. Treatment includes simply stopping the offending medication. Corticosteroids, azathioprine, cholestyramine and now bismuth have been used as treatment with some effect in patients who do not respond adequately to cessation of the causative agent. Recurrence however, does occur.

A Crohn's colitis

A 46-year-old man is admitted from the clinic with dysphagia and weight loss. Over the last few months, he has found that it has been progressively harder to swallow solids. He was able to swallow them but he had to regurgitate them about 30 minutes later.

Over the last few weeks, he has been having increasing difficulty with fluids. He has previously been in good health and never smoked. He drinks half a bottle of wine at weekends and the only other history of note has been long-term dyspepsia for which he uses antacids.

On examination, there is nothing to find except some mild tenderness on palpation in the epigastric area.

Barium swallow – oesophagus appears dilated and the distal oesophagus is narrowed. Oesophageal manometry – incomplete relaxation of the lower oesophageal sphincter in response to swallowing with high resting pressure. Absent oesophageal peristalsis.

What is the most likely diagnosis?

On examination, there is nothing to find except some mild tenderness on palpation in the epigastric area.

Barium swallow – oesophagus appears dilated and the distal oesophagus is narrowed. Oesophageal manometry – incomplete relaxation of the lower oesophageal sphincter in response to swallowing with high resting pressure. Absent oesophageal peristalsis.

What is the most likely diagnosis?

A	Achalasia
B	Oesophageal cancer
C	Plummer–Vinson syndrome
D	Oesophageal candidiasis
E	Gastro-oesophageal reflux disease

Achalasia is a primary oesophageal motility disorder characterised by failure of a hypertensive lower oesophageal sphincter to relax and the absence of normal oesophageal peristalsis. Oesophageal manometry will demonstrate findings as for our patient. An OGD should be carried out to make sure there is no cancer.

The goal of therapy for achalasia is to relieve symptoms by eliminating the outflow resistance caused by the hypertensive and non-relaxing sphincter. This can be accomplished by mechanical disruption of the muscle fibres of the lower oesophageal sphincter (e.g. pneumatic dilation, surgical myotomy or per-oral endoscopic myotomy) or by pharmacological reduction of oesophageal sphincter pressure (e.g. injection of botulinum toxin, oral nitrates or calcium channel blockers).

B	Oesophageal cancer

A 25-year-old male patient presents with non-bloody diarrhoea with mucus and 1-stone weight loss over six weeks. He has had no recent travel except to France for a holiday one year ago. All his family and friends are well but his uncle has diarrhoea for which he has to take tablets.

On examination, he looks unwell, his BMI is 21, BP is 110/70 mmHg, pulse is 75/min and regular. His abdomen is soft but there is mild tenderness. You suspect inflammatory bowel disease and perform a sigmoidoscopy and biopsy.

Which one of the following clinical findings would most favour a diagnosis of ulcerative colitis over Crohn's disease?

A	Crypt abscesses
B	Ileitis
C	Skip lesions

take tablets.

On examination, he looks unwell, his BMI is 21, BP is 110/70 mmHg, pulse is 75/min and regular. His abdomen is soft but there is mild tenderness. You suspect inflammatory bowel disease and perform a sigmoidoscopy and biopsy.

Which one of the following clinical findings would most favour a diagnosis of ulcerative colitis over Crohn's disease?

A	Crypt abscesses
B	Ileitis
C	Skip lesions
D	Non-caseating granulomas
E	Large joint arthritis

33016

A Crypt abscesses

Ulcerative colitis is inflammation confined to the mucosa and lamina propria with crypt abscesses. The mucosal appearance is characterized by erosions, mucopus, and edema with a diffused involvement of large intestine

B Ileitis

One third of crohn's disease cases involve the small intestine (especially the terminal ileum) causing ileitis.

C Skip lesions

Skip lesions are seen characteristically in crohn's disease, which are areas of normal appearing mucosa adjacent to inflamed mucosa.

D Non-caseating granulomas

Non-caseating granuloma are present in less than 25 % of patients but highly

An 18-year-old man is admitted to hospital with severe upper abdominal pain radiating to his back, associated with nausea and vomiting. He opens his bowels 3–4 times per day with loose stools and mucus. He was diagnosed with ulcerative colitis six months ago, and has had several flare-ups of his disease requiring steroids over the last three months. He is a non-smoker and non-drinker. His current medications are azathioprine 50 mg daily, prednisolone 10 mg daily and omeprazole. He consulted his general practitioner with similar symptoms a few weeks ago and was started on high-dose steroids for exacerbation of colitis.

On examination, he looks unwell. His temperature is 37.6 °C. Blood pressure is 100/50 mmHg, with pulse 100/and min regular. Chest and cardiovascular examination are unremarkable. There is tenderness in the left hypochondrial region and epigastrium with normal bowel sounds. Rectal examination is very tender but empty.

Investigations:

Hb	11.4 g/dl
WCC	13.5×10^9/l
PLT	494×10^9/l
Na^+	133 mmol/l
K^+	3.3 mmol/l
Creatinine	110 μmol/l
Urea	8.2 mmol/l
Bilirubin	43 μmol/l
ALT	51 U/l (5–35)
ALP	170 U/l (30–150)
Albumin	35 g/l
Corrected Ca^{++}	2.08 mmol/l
CRP	65 mg/l (0–10)
Chest and abdominal radiography:	Normal

CRP	65 mg/l (0–10)
Chest and abdominal radiography	Normal

What is the most likely diagnosis to explain his current admission?

A	Steroid-refractory ulcerative colitis
B	Acute pancreatitis
C	Cholecystitis
D	Infective gastroenteritis
E	Peptic ulcer disease

8482

Submit

B Acute pancreatitis

The diagnosis lies mainly in the symptoms, which are consistent with pancreatitis and one would expect his amylase to be high. Pancreatitis due to medications is an unusual event, but has been reported to be associated with drugs used for inflammatory bowel disease including sulphasalazine, 5- aminosalicylic acid compounds, 6-mercaptopurine and azathioprine. The pathogenesis of drug-induced pancreatitis may be due to an idiosyncratic response in some cases (e.g. 6-mercaptopurine, azathioprine).

Drug-induced pancreatitis has no distinguishing clinical features. A high index of suspicion and careful drug history are therefore essential for making the diagnosis. The time course of developing the disorder depends upon the drug involved, and can vary from weeks to months. The prognosis of drug-induced pancreatitis is generally excellent

The diagnosis lies mainly in the symptoms, which are consistent with pancreatitis and one would expect his amylase to be high. Pancreatitis due to medications is an unusual event, but has been reported to be associated with drugs used for inflammatory bowel disease including sulphasalazine, 5- aminosalicylic acid compounds, 6-mercaptopurine and azathioprine. The pathogenesis of drug-induced pancreatitis may be due to an idiosyncratic response in some cases (e.g. 6-mercaptopurine, azathioprine).

Drug-induced pancreatitis has no distinguishing clinical features. A high index of suspicion and careful drug history are therefore essential for making the diagnosis. The time course of developing the disorder depends upon the drug involved, and can vary from weeks to months. The prognosis of drug-induced pancreatitis is generally excellent.

A 42-year-old pre-menopausal woman presented to her general practitioner (GP) with a 3-week history of epigastric pain, occasionally retrosternal and worse at night. She had tried over-the-counter antacid preparations but had achieved no relief. Her weight was steady and bowel habit normal. There was no history of gastric malignancy in the family.

Examination was unremarkable except for obesity. Full blood count is normal.

Which of the following describes the next best management step?

A	Prescribe a proton pump inhibitor (PPI) and review symptoms in one month
B	Arrange upper gastrointestinal (GI) endoscopy
C	Start a PPI and perform a Carbon 13 urea breath test. If

next best management step?

A	Prescribe a proton pump inhibitor (PPI) and review symptoms in one month
B	Arrange upper gastrointestinal (GI) endoscopy
C	Start a PPI and perform a Carbon 13 urea breath test. If this is positive, prescribe *pylori* eradication therapy
D	Check repeat haemoglobin in three months. If low, then refer for upper gastrointestinal (GI) endoscopy.
E	Arrange upper gastrointestinal (GI) endoscopy if symptoms do not settle in two weeks on a proton pump inhibitor

A Prescribe a proton pump inhibitor (PPI) and review symptoms in one month

NICE guidelines state in this age group that dyspepsia, in the absence of alarm symptoms, should be treated with lifestyle advice and PPI if needed. In the event that symptoms of indigestion have not been relieved, *H. pylori* testing or upper GI endoscopy can then be considered.

B Arrange upper gastrointestinal (GI) endoscopy

A routine endoscopy would be considered where symptoms don't improve after 1 month of empirical PPI treatment.

C Start a PPI and perform a Carbon 13 urea breath test. If this is positive, prescribe *pylori* eradication therapy

A 53-year-old businessman presented with upper abdominal pain, jaundice, anorexia and general malaise. He recently travelled to South East Asia for work. Prior to his travel, he was vaccinated against typhoid, cholera, yellow fever and hepatitis A, but admits to not taking any malaria prophylaxis. He has been well up to five days after his return. He was in Thailand two days before flying back and was invited to a dinner function by a client. He was drinking heavily that evening and in order to prevent a hangover, he took two paracetamol tablets and went to bed. He looked at himself in the mirror the next morning and found that his sclera and skin had turned yellow. He smokes 30 cigarettes a day and drinks approximately five whiskies per night, although admits that he may have drunk more whilst in Thailand.

On examination, he looks unwell and is deeply jaundiced. He has a mild hepatic flap. He is mildly pyrexial. His blood pressure is 95/50 mmHg, with pulse 110/min and irregularly irregular.

blood pressure is 95/50 mmHg, with pulse 110/min and irregularly irregular. He has normal heart sounds. On chest examination, there are left basal crackles. Abdominal examination reveals right upper quadrant tenderness and the flanks are dull to percussion. Neurological examination is normal.

Investigations:

Hb	14.0 g/dl
WCC	14.0×10^9/l
PLT	152×10^9/l
Na^+	133 mmol/l
K^+	3.4 mmol/l
Creatinine	60 μmol/l
MCV	101 fl
INR	1.6
Urea	2.0 mmol/l
Bilirubin	165 μmol/l
ALT	56 U/l (5–35)

AST	119 U/l (10–40)
ALP	235 U/l (30–150)
GGT	199 U/l
Albumin	32 g/l
Ferritin	801 µg/l
Paracetamol level	Not detectable
Chest & abdominal X-ray	Normal
Electrocardiography	Atrial fibrillation

Which of the following best fits with the cause of his acute presentation?

A Acute on chronic alcoholic liver disease

B Acute viral hepatitis

Paracetamol level	Not detectable
Chest & abdominal X-ray	Normal
Electrocardiography	Atrial fibrillation

Which of the following best fits with the cause of his acute presentation?

A	Acute on chronic alcoholic liver disease
B	Acute viral hepatitis
C	Haemochromatosis
D	Paracetamol toxicity
E	Dengue fever

A Acute on chronic alcoholic liver disease

This gentleman has evidence of long-standing liver disease which is most likely to be secondary to alcohol consumption, supported by high mean cell volume, low urea and poor synthetic function (low albumin and prolonged international normalised ratio).

In this case, his recent step-up in alcohol intake is likely to explain the cause of alcoholic hepatitis. It is less likely to be due viral hepatitis, as one would expect the alanine transferase (ALT) level to be much higher in acute viral hepatitis. Ferritin is a non-specific acute phase reactant and is normally elevated in alcoholic liver disease, rather than haemochromatosis.

This man's atrial fibrillation is probably secondary to alcoholic cardiomyopathy. In alcoholic hepatitis, patients are usually pyrexial and 50% have peripheral leucocytosis, irrespective of infection. Hepatic decompensation with coagulopathy

secondary to alcoholic cardiomyopathy. In alcoholic hepatitis, patients are usually pyrexial and 50% have peripheral leucocytosis, irrespective of infection. Hepatic decompensation with coagulopathy, encephalopathy and ascites is not unusual. The aspartate aminotransferase (AST)/ALT ratio is usually greater than 2.0, and remains so well into the recovery period.

Discriminant function (DF) may be used to identify patients at high risk of mortality and to select patients for corticosteroid therapy. DF = 4.6 x (prothrombin time-control) + bilirubin (in mg/dl). DF >32 indicates a 1-month mortality of 50%.

The new Glasgow alcoholic hepatitis score based on age, serum bilirubin, blood urea, prothrombin time and peripheral blood white blood cell count has recently been shown to be a better scoring system in predicting mortality.

B	Acute viral hepatitis

B Acute viral hepatitis

Although hepatitis E can't be ruled out as a cause of his acute presentation, the admission of recent drinking, coupled with evidence of long-standing alcoholic liver disease, fits better with ethanol as the cause of his acute presentation.

C Haemochromatosis

Haemochromatosis presents with symptoms of chronic liver disease, type 2 diabetes and erectile dysfunction, rather than the acute hepatitis seen here.

D Paracetamol toxicity

Assuming the history of only taking two paracetamol tablets is correct, paracetamol toxicity is unlikely. In paracetamol toxicity there is more usually a marked elevation in transaminases.

A 72-year-old female is admitted with a 2-month history of diarrhoea. She has loose motions with no blood, four times per day. Her stool cultures are negative and her examination is normal. She has a background of rheumatoid arthritis for which she is in remission; hypertension, chronic renal impairment with a creatinine of 151 μmol/l and depression.

Colonoscopy demonstrates mild diverticular disease. Biopsy shows evidence of colitis with lymphocytic infiltration. Her daughter finds a list of her medications that she is taking and shows them to you.

Which one of the following medications is most likely to be causing her diarrhoea?

A	Ramipril
B	Amlodipine
C	Furosemide

rheumatoid arthritis for which she is in remission; hypertension, chronic renal impairment with a creatinine of 151 μmol/l and depression.

Colonoscopy demonstrates mild diverticular disease. Biopsy shows evidence of colitis with lymphocytic infiltration. Her daughter finds a list of her medications that she is taking and shows them to you.

Which one of the following medications is most likely to be causing her diarrhoea?

A	Ramipril
B	Amlodipine
C	Furosemide
D	Lansoprazole
E	Spironolactone

D Lansoprazole

Many drugs contribute to causing diarrhoea and it is very important to get a good drug history when evaluating a patient with chronic diarrhoea. The list is endless and one must use the BNF to check whenever one is not sure. Drugs causing diarrhoea include broad-spectrum antibiotics, antihypertensives such as diuretics, digoxin, some cholesterol-lowering drugs, sodium valproate, thyroxine, levodopa, antacids, theophylline, colchicines, non-steroidals and oral hypoglycaemic drugs. Mechanisms leading to diarrhoea are diverse, including effects on transit time, alterations in bowel flora, and impact on colonic inflammation, such as the development of lymphocytic colitis seen with non-steroidals. With respect to lansoprazole it appears to result in the development of microscopic colitis.

A Ramipril

A 78-year-old man is referred to the hospital by his dentist due to concern about his clinical condition. He had initially consulted his dentist with bleeding gums and the loss of several teeth. He had a fall several days ago which had resulted in a swollen, painful right knee and a laceration to the skin that was showing no signs of healing.

He was a widower and had lived alone since the death of his wife 1 year ago. There is no family support nearby as his only son lives in Australia.

He had a past medical history of hypertension and transient ischaemic attacks, for which he was taking aspirin and a beta-blocker. He smokes 10 cigarettes per day and denies drinking alcohol.

He is noted to be pale, slightly confused and undernourished on examination in the Emergency Assessment Unit. He has widespread skin ecchymoses and petechial haemorrhages.

Cardiorespiratory examination is normal with a blood pressure of

122/82; pulse is 78 and regular. His abdomen is soft and non-tender with no masses, his BMI is 19. There are no focal neurological signs. It is also noted that he has swollen, spongy and friable gums, halitosis and hyperkeratosis of his hair follicles. His right knee is swollen, hot and tender.

Investigations:

Hb	96 g/dl
WCC	6.0×10^9/l
PLT	240×10^9/l
Na^+	135 mmol/l
K^+	3.5 mmol/l
Creatinine	98 μmol/l
MCV	98 fl
Urea	5.2 mmol/l
Ca^{2+}	2.42 mmol/l
Bilirubin	14 μmol/l
ALP	80 u/l
[illegible]	[illegible]

ALP	80 u/l
AST	32 U/l
GGT	40 U/l
Albumin	34 g/l
PT	12 s
INR	1.1

What is the most likely diagnosis?

A Acquired haemophilia

B Vitamin C deficiency

C Coeliac disease

D Vitamin K deficiency

E Acute myeloid leukaemia

B Vitamin C deficiency

This patient has the classic features of scurvy. Vitamin C (ascorbic acid) is a powerful reducing agent in the body that is involved in the hydroxylation of proline to hydroxyproline, which is necessary for the formation of collagen. It is present in most fresh fruit and vegetables but can be reduced or eliminated by certain cooking methods, particularly boiling. In scurvy, defective collagen formation leads to impaired wound healing, capillary haemorrhage and abnormal platelet function. There is occasionally bleeding into joints or muscles. Vitamin C deficiency is usually seen in elderly people living on a 'tea and toast' diet, alcoholics and food faddists. It is also more common in smokers because ascorbate is consumed in removing free radicals from smoke. The diagnosis can be made by measurement of plasma ascorbate or leucocyte ascorbate content. Treatment is with 250 mg ascorbic

free radicals from smoke. The diagnosis can be made by measurement of plasma ascorbate or leucocyte ascorbate content. Treatment is with 250 mg ascorbic acid per day to replenish stores, and dietary education. Sometimes iron and folate supplements are indicated in addition if the patient is anaemic.

A Acquired haemophilia

Acquired haemophilia is seen against a background of autoimmune disease, and although it is associated with bleeding it isn't associated with the other features seen here such as hyperkeratosis of hair follicles.

C Coeliac disease

Coeliac disease is associated with anaemia, although not usually with the degree of bruising and skin changes seen here.

D Vitamin K deficiency

Coeliac disease is associated with anaemia, although not usually with the degree of bruising and skin changes seen here.

D	Vitamin K deficiency

Vitamin K deficiency is associated with easy bruising, but not with the skin changes related to defective collagen formation which are seen here.

E	Acute myeloid leukaemia

Although there are some features here that might be seen in AML, others are missing, including thrombocytopaenia, neutrophil depletion, blast cells in the peripheral blood film and splenomegaly.

6751

Rate this question:

A 62-year-old man with a long history of diabetes and previous cerebrovascular accident is admitted with early satiety, postprandial vomiting and abdominal distension. There is no history of haematemesis or abdominal pain. He opens his bowels regularly. He is on insulin therapy, digoxin and aspirin.

On examination, he is overweight and he is in atrial fibrillation. His abdomen is distended and tympanic, but is otherwise soft and non-tender with active bowel sounds. Rectal examination reveals soft brown stool. Neurology examination reveals a residual right-sided paralysis.

Investigations:

Hb	13.4 g/dl
WCC	12.7×10^9/l
PLT	319×10^9/l
Na^+	133 mmol/l
K^+	3.1 mmol/l

K^+	3.1 mmol/l
Creatinine	117 μmol/l
MCV	81 fl
INR	1.2
Urea	10.4 mmol/l
Albumin	36 g/l
Ca^{2+}	2.06 mmol/l
Glucose	11.2 mmol/l
CXR	Normal
AXR	Dilated stomach

Upper GI endoscopy is normal.

Which of the following is the most appropriate initial therapy?

A	Recommend less frequent meals
B	Trial of high-fibre diet
C	Trial of nifedipine

Glucose	11.2 mmol/l
CXR	Normal
AXR	Dilated stomach

Upper GI endoscopy is normal.

Which of the following is the most appropriate initial therapy?

A Recommend less frequent meals

B Trial of high-fibre diet

C Trial of nifedipine

D Trial of a gastric pacemaker

E Trial of domperidone

33028

Submit

E Trial of domperidone

Gastric motility is frequently affected in diabetes mellitus, with a reported prevalence of gastroparesis of 10%, although in reality this is probably significantly higher. Patients should initially be investigated with an endoscopy to exclude anatomical lesions such as pyloric stenosis. Gastric emptying scans using solid-phase meals are usually necessary. Treatment is often difficult and improving diabetic control can be beneficial, but a prokinetic drug has the added effects of increasing locally released acetylcholine at the myenteric plexus. Domperidone is now the initial intervention of choice, with metoclopramide having fallen out of favour because of long-term neurological sequelae associated with its use.

A Recommend less frequent meals

A 21-year-old female healthcare assistant is under investigation for chronic diarrhoea which has been going on for one year. She describes it as profuse and watery, but with no associated blood or mucus. She has also lost approximately 1 stone in weight over this period. The diarrhoea has not responded to multiple anti-diarrhoeal agents.

She has had numerous investigations at multiple hospitals in the past, including negative stool cultures, a normal abdominal ultrasound scan and small bowel barium follow-through.

A recent sigmoidoscopy was normal except for some abnormally pigmented mucosa around the rectum.

On clinical examination, she was underweight, but there were no other specific findings.

Investigations:

Hb	14.0 g/dl
WCC	7.0×10^9/l
PLT	200×10^9/l

WCC	7.0×10^9/l
PLT	200×10^9/l
Na^+	136 mmol/l
K^+	2.9 mmol/l
Creatinine	90 µmol/l
MCV	82 fl
Urea	4.2 mmol/l
CRP	< 4 mg/l
Bilirubin	14 µmol/l
ALP	70 IU/l
AST	32 IU/l
GGT	44 IU/l

What is the most likely diagnosis?

A Laxative abuse

B Irritable bowel syndrome

C Bile salt malabsorption

Urea	4.2 mmol/l
CRP	< 4 mg/l
Bilirubin	14 μmol/l
ALP	70 IU/l
AST	32 IU/l
GGT	44 IU/l

What is the most likely diagnosis?

A Laxative abuse

B Irritable bowel syndrome

C Bile salt malabsorption

D Thyrotoxicosis

E Carcinoid syndrome

A Laxative abuse

Surreptitious laxative abuse is usually seen in young women who have an underlying eating disorder or psychiatric illness. It presents with large volumes (>1 l/day) of watery diarrhoea. This may lead to weight loss, dehydration and hypokalaemia as is seen here. These patients commonly deny laxative use, which they then continue to take during sometimes extensive investigations. The diagnosis is often difficult to make and may require hospital admission. Chemical analysis of the stools can sometimes identify which laxatives are being used. If the patient is abusing an anthraquinone purgative (e.g. senna), then pigmented mucosa ('melanosis coli') may be seen at sigmoidoscopy. In prolonged cases of laxative abuse the barium enema may show a dilated colon with loss of the normal haustral pattern. Management is difficult and usually requires psychiatric input.

B Irritable bowel syndrome

Irritable bowel syndrome is only considered once organic pathology is ruled out. The hypokalaemia seen here counts against IBS as the likely diagnosis.

C Bile salt malabsorption

Bile salt malabsorption results from bowel resection, and is seen in conjunction with use of certain drugs such as metformin that interfere with normal reabsorption of bile salts. Neither bowel resection nor use/abuse of metformin seems likely given the scenario here.

D Thyrotoxicosis

Diarrhoea associated with thyrotoxicosis would not usually be associated with the marked hypokalaemia seen here, or with melanosis coli seen on imaging.

A 38-year-old man with a 10-year history of coeliac disease presents for review. He is worried because despite claiming that he conforms to a recommended diet he has suffered weight loss of 5 kg over the past 6 months. This weight loss is accompanied by night sweats, although diarrhoea has not increased markedly.

On examination, he looks thin and his BMI is only 17.

Investigations:

Hb	10.0 g/dl
WCC	4.0×10^9/l
PLT	205×10^9/l
Na^+	140 mmol/l
K^+	5.0 mmol/l
Creatinine	125 μmol/l
PT	23 s
Visc	2.3 mPa/s
Ca^{2+}	2.05 mmol/l

Creatinine	125 µmol/l
PT	23 s
Visc	2.3 mPa/s
Ca^{2+}	2.05 mmol/l

Which of the following is the most likely diagnosis?

A	Lactose intolerance
B	Coeliac diet non-compliance
C	Hodgkin's lymphoma
D	Enteropathy associated T-cell lymphoma
E	Primary sclerosing cholangitis

18635

Submit

claiming that he conforms to a recommended diet he has suffered weight loss of 5 kg over the past 6 months. This weight loss is accompanied by night sweats, although diarrhoea has not increased markedly.

On examination, he looks thin and his BMI is only 17.

Investigations:

Hb	10.0 g/dl
WCC	4.0×10^9/l
PLT	205×10^9/l
Na^+	140 mmol/l
K^+	5.0 mmol/l
Creatinine	125 μmol/l
PT	23 s
Visc	2.3 mPa/s
Ca^{2+}	2.05 mmol/l

Which of the following is the most likely diagnosis?

D Enteropathy associated T-cell lymphoma

The raised viscosity, weight loss and night sweats raise the possibility of an underlying malignancy here. Symptoms of upper GI obstruction would be expected if he had oesophageal carcinoma, making this option less likely. Whilst Both T- and B-cell lymphomas occur with increased frequency in association with coeliac disease, the strongest association is with enteropathy-associated T-cell lymphoma. Poor compliance to coeliac diet may increase the propensity for malignancy.

A Lactose intolerance

New-onset lactose intolerance would be associated with an increase in diarrhoea, and not with the night sweats seen here.

B Coeliac diet non-compliance

B	Coeliac diet non-compliance

Like lactose intolerance, coeliac non-compliance would be expected to lead to a worsening in diarrhoea, not consistent with the relatively stable diarrhoea and onset of night sweats seen here.

C	Hodgkin's lymphoma

Hodgkin's lymphoma is usually associated with peripheral lymphadenopathy, night sweats and weight loss, and isn't associated with coeliac disease.

E	Primary sclerosing cholangitis

Primary sclerosing cholangitis is associated with progressive hepatic impairment with obstructive liver function tests, and is associated with inflammatory bowel disease rather than coeliac disease.

18635

Rate this question:

A 35-year-old patient with a diagnosis of ulcerative colitis (UC) has suffered a number of episodes of pan-colitis over the last 11 years. He is currently managed with infliximab and has stable disease.

He has read on the Internet that people with UC have an increased risk of cancer and liver disease and wishes to discuss this. He has not had any weight loss or additional bloody diarrhoea.

The general practitioner (GP) measures his carcino-embryonic antigen level (CEA) and alpha fetoprotein, and a surveillance colonoscopy is arranged.

Which of the following is the correct advice to give him?

A	CEA is a useful screening test for bowel cancer
B	Faecal calprotectin elevation indicates a possible neoplasm

measures his carcino-embryonic antigen level (CEA) and alpha fetoprotein, and a surveillance colonoscopy is arranged.

Which of the following is the correct advice to give him?

A	CEA is a useful screening test for bowel cancer
B	Faecal calprotectin elevation indicates a possible neoplasm
C	Cancers tend to present earlier in patients with UC and are therefore easier to treat
D	Alpha-fetoprotein is a good marker for primary sclerosing cholangitis (PSC) in this case
E	He is at risk of PSC despite good control of his UC at the current time

E He is at risk of PSC despite good control of his UC at the current time

Although this patient's UC is currently well controlled, it won't significantly impact on future risk of PSC, which is strongly associated with inflammatory bowel disease.

A CEA is a useful screening test for bowel cancer

CEA is not reliable as a test for diagnosing early colon cancer, but is considered as a test for cancer recurrence in those who have undergone a surgical resection.

B Faecal calprotectin elevation indicates a possible neoplasm

Faecal calprotectin is a measure of active inflammatory bowel disease.

C Cancers tend to present

B	Faecal calprotectin elevation indicates a possible neoplasm

Faecal calprotectin is a measure of active inflammatory bowel disease.

C	Cancers tend to present earlier in patients with UC and are therefore easier to treat

Due to the fact that symptoms may be confused with active inflammatory bowel disease, diagnosis is often made late.

D	Alpha-fetoprotein is a good marker for primary sclerosing cholangitis (PSC) in this case

Alpha-fetoprotein is a marker for hepatocellular carcinoma, not for PSC.

6854

Rate this question:

Next Question

A 35-year-old woman comes to the Emergency Department complaining of severe epigastric pain, nausea and vomiting. You understand that she was recently started on medication for epilepsy.

On examination, her blood pressure is 100/65 mmHg, her pulse 105 bpm regular. She is mildly pyrexial at 37.8 °C. Her epigastrium is very tender and she complains of severe pain on relatively minimal palpation.

Investigations:

Hb	12.1 g/dl
WCC	13.1×10^9/l
PLT	130×10^9/l
Na^+	138 mmol/l
K^+	4.5 mmol/l
Creatinine	142 μmol/l
Ca^{2+}	2.14 mmol/l
Amylase	1020 U/l

K	4.5 mmol/l
Creatinine	142 μmol/l
Ca^{2+}	2.14 mmol/l
Amylase	1020 U/l

Which of the following medications is most likely to be responsible?

A	Gabapentin
B	Phenytoin
C	Vigabatrin
D	Valproate
E	Lamotrigine

21207

Submit

D Valproate

There is a good level of evidence to suggest valproate administration is associated with acute pancreatitis. Other medications associated with acute pancreatitis include, but are not limited to: azathioprine, 6-mercaptopurine, didanosine, codeine, isoniazid, 5-ASAs, metronidazole, pravastatin, procainamide, simvastatin, sulfamethoxazole, tetracycline, amiodarone, dexamethasone and lamivudine.

B Phenytoin

Phenytoin has not been reported to cause acute pancreatitis.

A Gabapentin

The woman has acute pancreatitis. Gabapentin has not been reported to induce acute pancreatitis.

The woman has acute pancreatitis. Gabapentin has not been reported to induce acute pancreatitis.

C	Vigabatrin

There is one case report of pancreatitis associated with vigabatrin and lamotrogine administration that has not been reproduced.

E	Lamotrigine

There is minimal evidence to suggest lamotrigine administration is associated with acute pancreatitis.

Reference

Hung WY. Contemporary review of drug-induced pancreatitis: A different perspective. WJGP, 2014, 5, 405–415.

21207

Rate this question:

Next Question

A 78-year-old ex-medical secretary presents with a 6-month history of intermittent rectal bleeding, loose stool and weight loss. Her past medical history includes multi-nodular goitre and cervical carcinoma diagnosed 1 year ago. She received treatment at a different hospital. She takes carbimazole.

On examination, she looks thin and pale. Abdominal examination is unremarkable.

Investigations:

Haemoglobin (Hb)	8.9 g/dl
White blood count (WBC)	11.2×10^9/l
Platelets (PLT)	170×10^9/l
Mean cell volume (MCV)	74 fl

Barium enema shows luminal narrowing of the distal sigmoid colon with some irregularity of the bowel wall, with no focal lesions.

Barium enema shows luminal narrowing of the distal sigmoid colon with some irregularity of the bowel wall, with no focal lesions.

Colonoscopy is performed, the appearance of which is shown below:

What is the most likely diagnosis?

A	Diverticulitis
B	Radiation enteritis
C	Ulcerative colitis

appearance of which is shown below:

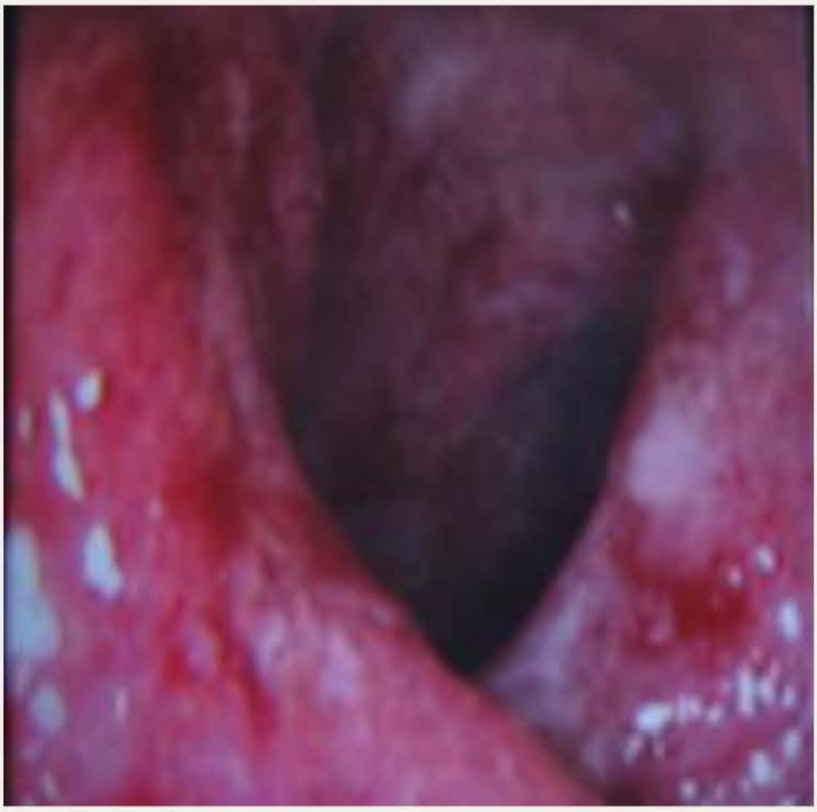

What is the most likely diagnosis?

A	Diverticulitis
B	Radiation enteritis
C	Ulcerative colitis
D	Microscopic colitis
E	Pseudomembranous colitis

B Radiation enteritis

Radiation injury to the rectum and sigmoid colon is commonly seen following treatment of cancers of the cervix, uterus, prostate and bladder. It often occurs 9–14 months following radiation exposure and results in a chronically ischaemic intestinal segment that may lead to stricture. Symptoms include diarrhoea, obstructed defaecation, bleeding, rectal pain or urgency. Diagnosis can be confirmed with colonoscopy, and mucosal features consistent with radiation injury include pallor, friability and telangiectasias. Biopsy is not diagnostic but is helpful to exclude other causes. There have been no large controlled trials to evaluate the treatment of radiation proctitis, but a systemic review of available trials shows promising results for rectal sucralfate and metronidazole combined with topical anti-inflammatory treatment and heater probe.

A Diverticulitis

A diverticulum is an outpouching of the gut which usually occurs at the site of entry of perforating arteries. Diverticulitis is inflammation of a diverticulum. The presence of a diverticulum, termed diverticulosis, may cause altered bowel habits and left lower abdominal pain relieved by defaecation. In diverticulitis there would be added features of fever and peritonism, which can progress to haemorrhage or perforation. The history of chronic weight loss, chronic bleeding and narrowing sigmoid colon makes this an unlikely diagnosis.

C Ulcerative colitis

Ulcerative colitis (UC) is a type of inflammatory bowel disease. In UC, gut involvement starts from the rectum and may spread to involve the entire colon. It causes episodic or chronic diarrhoea, which can include blood and mucus. There is commonly crampy

and may spread to involve the entire colon. It causes episodic or chronic diarrhoea, which can include blood and mucus. There is commonly crampy abdominal pain with bowel frequency and urgency relating to severity. Patients also develop fever, malaise, anorexia and weight loss. The history would generally fit, but the age of the patient is much higher than would be expected for UC, which normally presents between 15 and 30 years old. Also, the absence of abdominal signs makes it less likely.

D	Microscopic colitis

Microscopic colitis is a chronic inflammatory disease of the colon characterised by chronic and watery diarrhoea, typically in a middle-aged female patient. It is not bloody, but can be associated with abdominal pain. The presence of anaemia and the late age of presentation, as well as the findings of sigmoid narrowing, makes this a less likely diagnosis.

A 59-year-old man presents to his general practitioner (GP) complaining of difficulty in swallowing. This problem had initially been for solids and the patient had thought it was related to his episodes of heartburn, but he has recently started having problems swallowing liquids as well.

Consequent to this problem, he has lost about 8 kg of weight in the last 2 months. His other symptoms include pain in the retrosternal area and bouts of coughing at night.

He is otherwise fit and well and apart from self-medicating in the form of aluminum hydroxide and magnesium trisilicate for heartburn, he is on no other medications. He is a smoker of a pack of cigarettes per day and has been so for about 20 years.

Which of the following is the most appropriate next step for this patient?

A	Barium swallow
B	*Helicobacter pylori*

months. His other symptoms include pain in the retrosternal area and bouts of coughing at night.

He is otherwise fit and well and apart from self-medicating in the form of aluminum hydroxide and magnesium trisilicate for heartburn, he is on no other medications. He is a smoker of a pack of cigarettes per day and has been so for about 20 years.

Which of the following is the most appropriate next step for this patient?

A	Barium swallow
B	*Helicobacter pylori* eradication therapy
C	Trial of omeprazole
D	Trial of ranitidine
E	Urgent upper GI endoscopy

E Urgent upper GI endoscopy

This patient is above the age of 55, with unexplained symptoms of indigestion, swallowing problems and significant weight loss. He has significant risk for upper GI cancer (he is a heavy smoker), and urgent upper GI endoscopy in keeping with NICE guidance is clearly the most appropriate next step.

A Barium swallow

Upper GI endoscopy is preferred as small lesions may be missed by barium swallow, and endoscopy allows the potential to biopsy any lesions at the same time as the investigation.

B *Helicobacter pylori* eradication therapy

Giving that a course of *H. pylori* eradication therapy risks significant delay in diagnosing a likely malignancy,

B *Helicobacter pylori* eradication therapy

Giving that a course of *H. pylori* eradication therapy risks significant delay in diagnosing a likely malignancy, in this situation only progression to endoscopy is advised.

C Trial of omeprazole

Although omeprazole may have an effect on some symptoms of reflux, again it will lengthen the time to diagnose any underlying neoplasm.

D Trial of ranitidine

Ranitidine is less effective than proton pump inhibition with respect to acid suppression, and risks delay in diagnosing underlying malignancy.

71125

Rate this question:

Next Question

A 42-year-old man who has a 20-year history of ulcerative colitis (UC) presents to the gastroenterology clinic for review. His UC is relatively quiescent, although most recently he has begun to suffer from tiredness, itching and vague right upper quadrant pain.

On examination, you can feel two fingers'-breadth hepatomegaly. His only medication is salazopyrine.

Investigations:

Hb	12.1 g/dl
WCC	6.0×10^9/l
PLT	320×10^9/l
ALP	420 U/l
ALT	74 U/l

Which of the following is the most effective therapy for his underlying condition?

A	Cholestyramine

Hb	12.1 g/dl
WCC	6.0×10^9/l
PLT	320×10^9/l
ALP	420 U/l
ALT	74 U/l

Which of the following is the most effective therapy for his underlying condition?

A Cholestyramine

B Penicillamine

C Liver transplantation

D Prednisolone

E Azathioprine

C Liver transplantation

Liver transplantation is the definitive treatment for patients with decompensated cirrhosis with a background of PSC. Increased levels of alkaline phosphatase and a positive history of ulcerative colitis make PSC a likely diagnosis. Complications of this condition include advanced-stage liver disease with hepatic decompensation. Around 70% of patients diagnosed with PSC are men, with an average age of around 40 years. Up to 90% of patients diagnosed with PSC have co-existent inflammatory bowel disease, normally ulcerative colitis. Cholangiocarcinoma is also an established complication of PSC. Indications for liver transplantation in patients with PSC do not differ from those with other forms of chronic liver disease, which primarily relate to complications of portal hypertension, chronic liver failure and impaired quality of life. Moreover, patients with PSC have specific indications for liver

chronic liver failure and impaired quality of life. Moreover, patients with PSC have specific indications for liver transplant, which include recurrent bacterial cholangitis, intractable pruritis and cholangiocarcinoma.

A Cholestyramine

Cholestyramine, a bile acid sequestrant, is used to treat hyperlipidaemia and for the pruritus of biliary obstruction and chronic liver disease.

B Penicillamine

As described in a systemic review by Klingenberg et al., there is insufficient evidence to refute or support the use of penicillamine for patients with primary sclerosing cholangitis (PSC).

Reference: Klingenberg, S.L. and Chen, W. (2006). D-penicillamine for primary sclerosing cholangitis. *Cochrane Database Syst Rev*. Jan 25(1):CD004182.

Corticosteroids, e.g. prednisolone, have not demonstrated any improvement in disease activity or outcome of PSC patients, as evident in a systemic review by Giljaca et al.

Reference: Giljaca, V., Poropat, G., Stimac, D. et al. (2010). Glucocorticosteroids for primary sclerosing cholangitis. *Cochrane Database Syst Rev*. Jan 20(1):CD004036

E	Azathioprine

Many immunosuppressive agents are used in the management of patients with PSC, However, there no substantial evidence for its role in prognosis of patients with PSC is noted. A review study by Goode et al. mentioned controversial evidence underlying the usage of immunosuppressive therapy and other prospective agents that may bring new hope regarding the treatment of PSC in the 21st century.

Reference: Goode, E.C. and Rushbrook,

A 47-year-old woman attends Outpatients asking for advice. She has a family history of colorectal carcinoma. Her family tree is shown below (Patient arrowed).

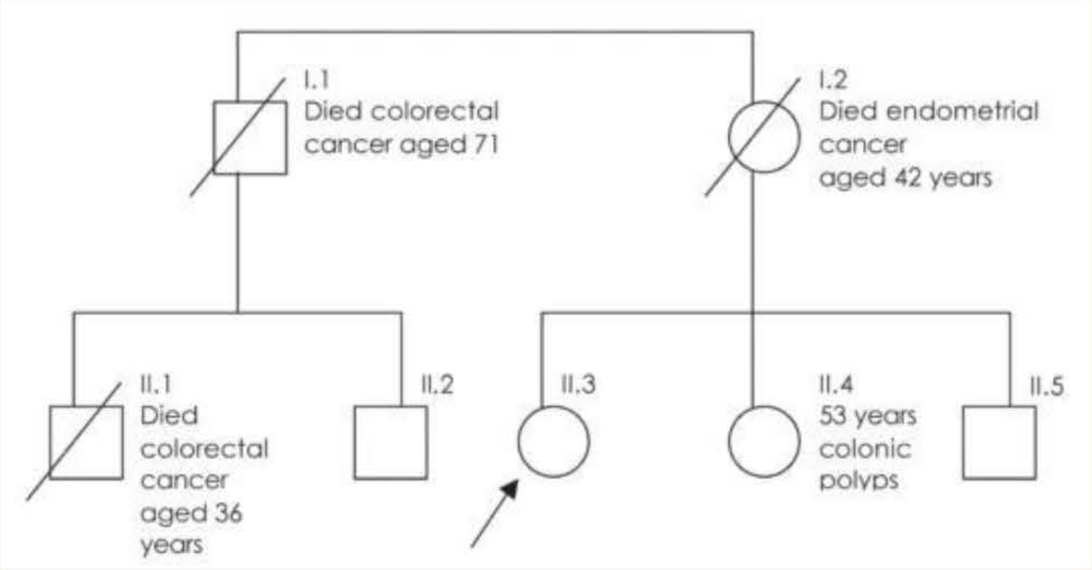

What is the most likely explanation for the family's history?

A	Familial adenomatous polyposis
B	Hereditary non-polyposis colorectal cancer
C	Sporadic colorectal carcinoma

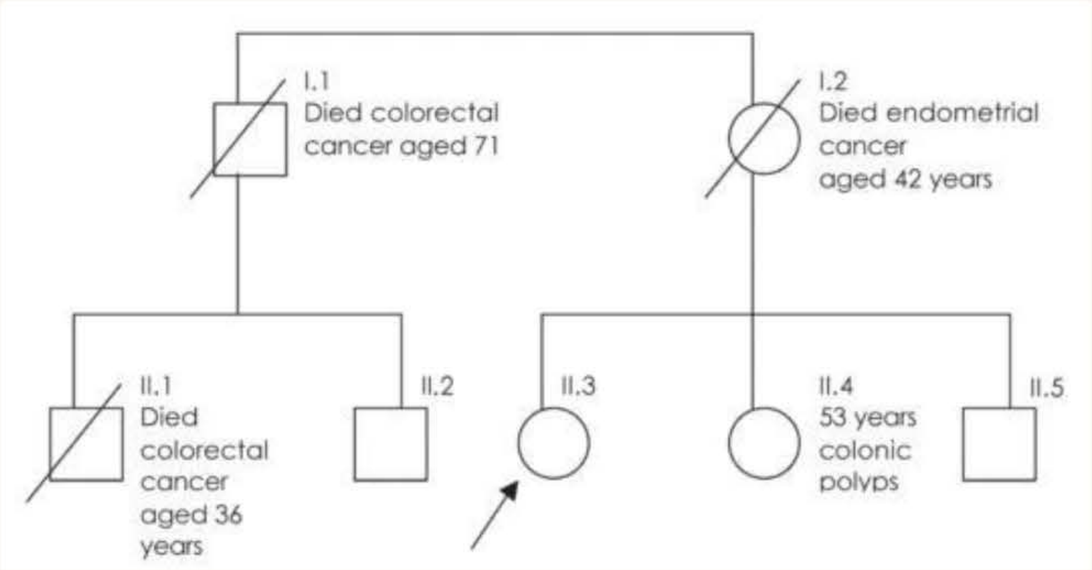

What is the most likely explanation for the family's history?

A	Familial adenomatous polyposis
B	Hereditary non-polyposis colorectal cancer
C	Sporadic colorectal carcinoma
D	Peutz-Jeghers syndrome
E	Attenuated familial adenomatous polyposis

B Hereditary non-polyposis colorectal cancer

HNPCC is an autosomal dominant disorder, caused either through a germline mutation in one of several DNA mismatch repair genes or through loss of expression of a particular mismatch repair gene because of a deletion in another gene, called EPCAM. In addition to colorectal cancer, people with HNPCC are at increased risk of other upper and lower GI tract malignancies, as well as endometrial, ovarian, and other cancers. A number of different criteria are used to seek to identify individuals with HNPCC, with one widely used set of criteria being the Amsterdam II criteria (the so-called '3-2-1' rule):

- Three or more family members affected by cancers that occur as part of the syndrome (as described above), with one a first-degree relative of the other two

- At least two generations affected by these cancers
- One or more cancers diagnosed before the age of 50 years of age.

The use of these and similar criteria is not in confirming a familial cancer syndrome *per se*, but in identifying people who should go on to have genetic testing. HNPCC is a term that refers to people who fulfil the Amsterdam criteria, whilst Lynch syndrome is the diagnosis given to those who have the clinical features of HNPCC and confirmed genetic mutations of the condition. People with HNPCC tend to have fewer polyps than those with either FPA or Peutz–Jeghers syndrome; however, that is not to say that they do not get any polyps.

People with HNPCC are typically screened with colonoscopy from the age of 20–25 years, or five years earlier than the youngest age of diagnosis of colorectal cancer in the family

than the youngest age of diagnosis of colorectal cancer in the family (whichever comes first). There is also a role for gastroscopic surveillance for upper GI cancer, as well as close surveillance for endometrial and ovarian cancers in women, with regular pelvic examination and ultrasound being used in the first instance.

A	Familial adenomatous polyposis

Since FAP is a completely penetrant disorder, the family history presented here cannot be explained by a diagnosis of FAP.

C	Sporadic colorectal carcinoma

There is clearly a familial cancer syndrome, making sporadic colorectal carcinoma highly unlikely as the most likely diagnosis.

D	Peutz-Jeghers syndrome

There is clearly a familial cancer syndrome, making sporadic colorectal carcinoma highly unlikely as the most likely diagnosis.

D	Peutz-Jeghers syndrome

There is no mention of small bowel hamartomas, intussusception or perioral pigmented lesions as would be expected were Peutz-Jeghers syndrome the explanation here.

E	Attenuated familial adenomatous polyposis

Attenuated FAP is associated with different mutations in the APC gene, and presents with a less severe phenotype with fewer polyps than classic FAP. Since FAP is a completely penetrant disorder, the family history presented here cannot be explained by a diagnosis of FAP. Furthermore, FAP is not associated with gynaecological malignancy.

An 82-year-old woman with poorly-controlled chronic obstructive pulmonary disease (COPD) is admitted with an exacerbation. She is managed with high-dose intravenous (iv) co-amoxiclav and makes an initially good recovery.

Unfortunately, on her last day of antibiotic therapy, she develops abdominal tenderness and profuse, intractable diarrhoea. Rigid sigmoidoscopy on the ward reveals yellowish plaques.

What diagnosis fits best with this clinical picture?

A	Crohn's disease
B	Ulcerative colitis
C	Pseudomembranous colitis
D	*Campylobacter* infection
E	*Cryptosporidium* infection

11:38
:tps://mypastest.pastest.com

recovery.

Unfortunately, on her last day of antibiotic therapy, she develops abdominal tenderness and profuse, intractable diarrhoea. Rigid sigmoidoscopy on the ward reveals yellowish plaques.

What diagnosis fits best with this clinical picture?

Your answer was correct

A	Crohn's disease
B	Ulcerative colitis
C	Pseudomembranous colitis
D	*Campylobacter* infection
E	*Cryptosporidium* infection

C Pseudomembranous colitis

This is an elderly patient who has been treated with intravenous (IV) co-amoxiclav, associated with *C. difficile* infection, the cause of pseudomembranous colitis. The antibiotic associated with the highest rate of pseudomembranous colitis is clindamycin, used for bone infections where rates are as high as 10%. Mortality related to pseudomembranous colitis is high, and in elderly patients it may be as high as 10%. Vancomycin has virtually no systemic absorption when administered via the oral route and is an ideal choice for the treatment of *C. difficile*; either this or metronidazole may be used. Both drugs should be used for a period of 10–14 days. Cholestyramine may be useful in reducing severe diarrhoea.

You have switched to your mobile data connection.

A Crohn's disease

Crohn's may affect the colon, although

Crohn's may affect the colon, although it leads to areas of ulceration rather than the formation of a pseudomembrane seen here.

B	Ulcerative colitis

Ulcerative colitis is highly unlikely to present for the first time at age 82, and the proximity to antibiotics makes pseudomembranous colitis much more likely.

D	*Campylobacter* infection

Although *Campylobacter* infection can present with diarrhoea, the fact that diarrhoea began a few days after hospital admission makes antibiotic-related diarrhoea much more likely.

E	*Cryptosporidium* infection

This is a cause of diarrhoea associated with contaminated water, usually in patients who are immunocompromised, and it is not

A 20-year-old man presents with a 3-week history of bloody diarrhoea and abdominal pain.

On examination, he is unwell with a temperature of 38.6 °C, heart rate of 130 beats/min, pallor and diffuse abdominal tenderness. His abdomen is distended, but bowel sounds are present on auscultation.

His abdominal X-ray is shown below:

Image courtesy of Nicholas Oldnall, X

Image courtesy of Nicholas Oldnall, X Ray 2000.

What would your immediate management be?

A	Urgent colectomy
B	Hydrocortisone and fluids
C	Observation and IV fluids
D	IV antibiotics
E	Start azathioprine

B Hydrocortisone and fluids

This is toxic megacolon, a severe colitis (almost always pan-colitis) defined radiologically as dilatation of the colon >5.5 cm. It commonly occurs in the context of ulcerative colitis, but can also occur in Crohn's, pseudomembranous colitis, ischaemic colitis and other colitides. The treatment of toxic megacolon in ulcerative colitis should initially start with high-dose steroids and IV fluids, but if no improvement then early surgery (usually colectomy) is indicated.

A Urgent colectomy

Although it is appropriate to refer this patient for a surgical review, it would not be the initial step to go straight for a colectomy without a trial of medical management.

C Observation and IV fluids

A Urgent colectomy

Although it is appropriate to refer this patient for a surgical review, it would not be the initial step to go straight for a colectomy without a trial of medical management.

C Observation and IV fluids

The patient is unlikely to settle with conservative measures alone.

D IV antibiotics

This will not treat the underlying aetiology of ulcerative colitis; these are more necessary in infective colitis.

E Start azathioprine

Azathioprine is not used to induce remission in inflammatory bowel disease; it is used for maintenance therapy only.

A 79-year-old man was referred by his GP with a 4 month history of dysphagia. He was unable to pinpoint the site of his symptoms accurately but noted that his dysphagia worsened as he ate. At times he would regurgitate food during his meals, which would temporarily relieve his symptoms.

According to his GP, who had weighed him, he had lost 1 kg in weight over the past 2 months. His medications include Bendroflumethiazide for hypertension, and Ranitidine, which he takes intermittently for symptoms of gastro-oesophageal reflux disease.

A barium swallow is shown below;

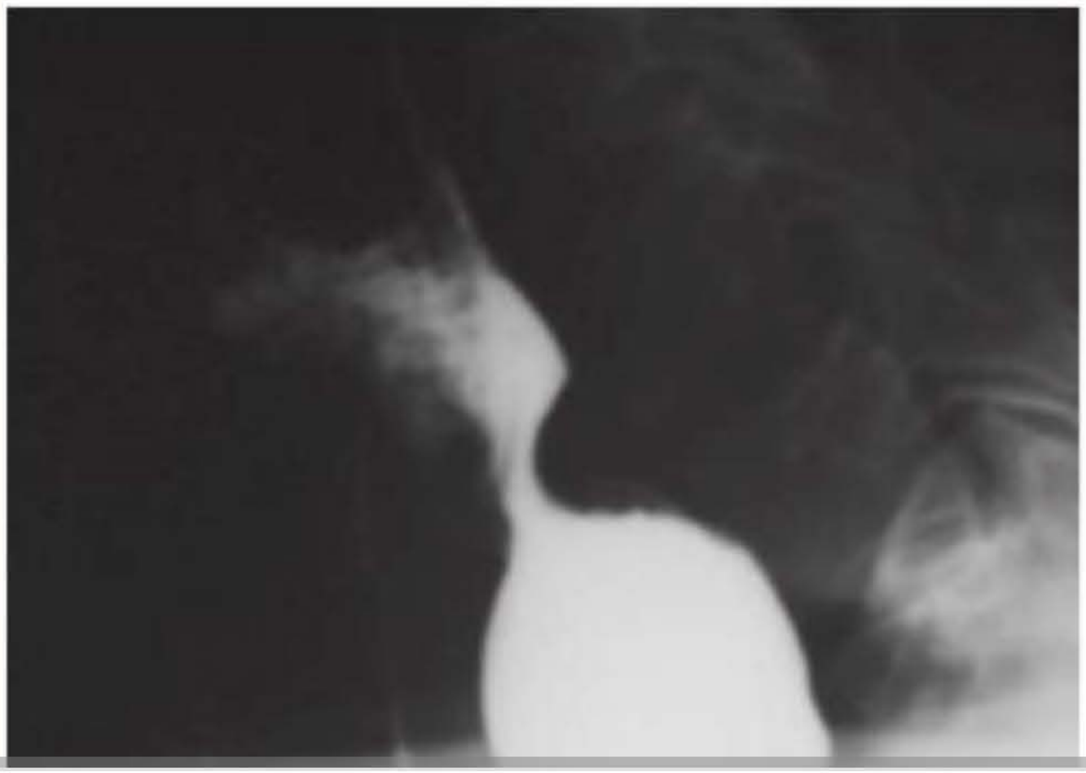

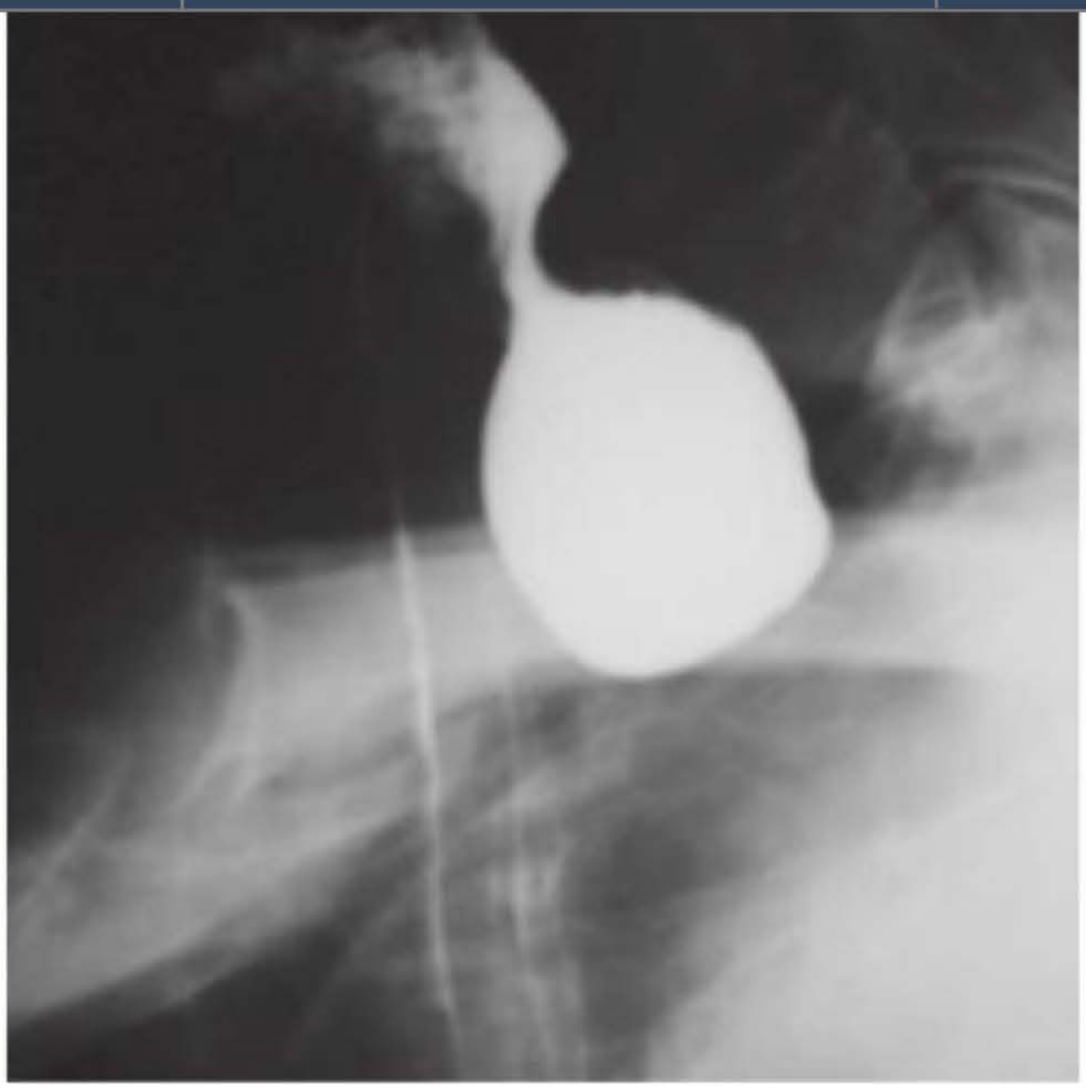

What is the diagnosis?

A	Schatzki ring
B	Achalasia
C	Benign oesophageal stricture
D	Pharyngeal pouch
E	Post-cricoid web

D Pharyngeal pouch

The barium swallow shows a pharyngeal pouch (or Zenker's diverticulum). These occur predominantly in elderly men (male: female of 5: 1), and are rare before the age of 40 years. The aetiology is unclear, although they may be related to poor relaxation of the upper oesophageal sphincter. An association with gastro-oesophageal reflux disease has also been noted.

Pharyngeal pouches commonly cause dysphagia, regurgitation and aspiration, and are a rare cause of halitosis. If large, they may cause a mass in the neck that gurgles on palpation (Boyce's sign). Regurgitation of the contents of the pouch may temporarily ease dysphagia until the pouch refills with food and fluid.

Upper gastrointestinal endoscopy is risky, since the pouches are thin-walled and easy to perforate; this is the reason why a barium swallow may be the preferable first-line investigation in

the preferable first-line investigation in elderly patients with dysphagia. Treatment is surgical, with either an open or endoscopic approach.

E Post-cricoid web

This would give a very different appearance on barium swallow to those of a pharyngeal pouch. Post-cricoid webs occur near the upper oesophageal sphincter and may occur in association with iron-deficiency anaemia (Patterson-Brown-Kelly syndrome).

A Schatzki ring

This would give a very different appearance on barium swallow to those of a pharyngeal pouch. Schatzki rings are benign narrowings in the distal oesophagus.

B Achalasia

This would give a very different

B Achalasia

This would give a very different appearance on barium swallow to those of a pharyngeal pouch. Barium swallow in people with achalasia is associated with a very tight tapering at the gastro-oesophageal junction, generating a so-called 'bird's beak' or 'rat's tail' appearance, together with a dilated oesophagus.

C Benign oesophageal stricture

This would give a very different appearance on barium swallow to those of a pharyngeal pouch. Barium studies in those with benign oesophageal strictures typically produce a smooth, tapering narrowing of the oesophagus.

70158

Rate this question:

A 78-year-old retired banker was reviewed in the Outpatients Department after a recent admission with right lower lobe pneumonia. She has had two similar episodes, managed by her GP, over the last 2 years. She has mild angina for which she is taking Aspirin and Atenolol.

She is otherwise fit and well. She smoked 15 cigarettes a day from the age of 20, and drinks 15 units of alcohol per week. Throughout her life, she has travelled widely in Africa and Asia.

Examination revealed no abnormal signs and her blood tests were unremarkable.

Her plain chest X-ray is shown below:

C Achalasia

A fluid level is visible behind the heart and the oesophagus is dilated. This is suggestive of chronic oesophageal obstruction. From the scenario given and the radiological evidence supplied, achalasia is the most likely diagnosis.

Achalasia can present at any age but is rare in childhood. Dysphagia is universal, and occurs for liquids and solids relatively early in the condition. Other typical symptoms may include regurgitation, weight loss, chest and abdominal pain, as well as possible aspiration pneumonitis (which may be the presenting complaint). Achalasia is caused by degeneration of the myenteric plexus, causing failure of relaxation of the lower oesophageal sphincter (LOS), and absent peristalsis in the body of the oesophagus. Diagnosis is confirmed by oesophageal manometry, but prior upper gastrointestinal endoscopy is mandatory to exclude a tumour of the cardia. Tumours of the cardia may

mandatory to exclude a tumour of the cardia. Tumours of the cardia may mimic achalasia, and chronic achalasia slightly increases the risk of oesophageal carcinoma.

A number of treatment options are available. Pharmacological therapy includes calcium channel blockers (including Nifedipine) and nitrates, but tends to be only minimally effective. Injection of botulinum toxin into the LOS also produces variable degrees of success, but has a role in affected people who are unable to tolerate more invasive therapies. The major definitive choice of therapy, however, is between endoscopic dilatation (which carries the risk of perforation), or surgical intervention (Heller's myotomy). There is also a growing role for an alternative combined surgical and endoscopic treatment called peroral endoscopic myotomy (POEM).

A	Tracheo-oesophageal fistula

Outside of the paediatric setting, tracheo-oesophageal fistula (TOF) is

A 43-year-old woman had an orthotopic liver transplant for decompensated alcoholic cirrhosis. Sixteen days post-transplant, she is found to have abnormal liver function tests.

On examination, she is deeply jaundiced but is alert. She is afebrile. There is a new maculopapular rash on her palms and soles. Respiratory and cardiovascular examinations are normal, the abdomen is soft and non-tender with no palpable masses, and there is no hepatic bruit; a finger-prick glucose is normal. She has not been started on any new antibiotics and is currently taking tacrolimus.

Investigations:

Hb	13.5 g/dl
WCC	12.7×10^9/l
PLT	54×10^9/l
MCV	81 fl
INR	1.6
Na^+	137 mmol/l

INR	1.8
Na^+	137 mmol/l
K^+	3.6 mmol/l
Urea	7.4 mmol/l
Creatinine	76 µmol/l
Albumin	36 g/l
Calcium	2.46 mmol/l
Bilirubin	87 µmol/l
ALP	301 U/l (30–150)
ALT	76 U/l (5-35)
GGT	105

Which of the following is an important next management step?

A Check ammonia

B Check viral hepatitis screen

C Start broad-spectrum antibiotics

ALP	301 U/l (30-130)
ALT	76 U/l (5-35)
GGT	105

Which of the following is an important next management step?

A	Check ammonia
B	Check viral hepatitis screen
C	Start broad-spectrum antibiotics
D	Urgent hepatic ultrasound scan with Doppler
E	Add mycophenolate mofetil and high-dose corticosteroids

33030

Submit

D Urgent hepatic ultrasound scan with Doppler

The liver is the second most commonly involved organ in acute graft-versus-host disease (GVHD). It develops from 15 days after transplantation, as marrow engulfment appears. Presentation is with jaundice, hepatomegaly and abnormal liver function tests, with the earliest and most common finding being a rise in the serum levels of conjugated bilirubin and alkaline phosphatase. This reflects damage to the bile canaliculi, leading to cholestasis. Hepatic ultrasound and Doppler flow are likely to be abnormal, and this investigation therefore represents an ideal non-invasive initial step in investigation.

E Add mycophenolate mofetil and high-dose corticosteroids

In the event that GVHD is confirmed, the most effective initial option is high-dose methylprednisolone. If higher doses of steroids are not successful in

controlling GVHD by 3–5 days, second-line treatments are less successful. These include cyclosporine, tacrolimus, antithymocyte globulin and mycophenolate mofetil.

A	Check ammonia

Although she is jaundiced she is alert. Ammonia may be slightly elevated but in the absence of significant hepatic encephalopathy it isn't as useful an investigation here as ultrasound.

B	Check viral hepatitis screen

Hepatic infections including viral hepatitis should be excluded if possible, and hence viral hepatitis screen is an important part of the work-up but is less likely to reveal the underlying diagnosis.

C	Start broad-spectrum antibiotics

Broad-spectrum antibiotics don't have

A 34-year-old farm worker presents with an acute upper gastrointestinal haemorrhage. On admission, she is severely shocked with a pulse of 105/min and a postural drop of 30 mmHg. There is evidence of hepatosplenomegaly. After fluid resuscitation and blood transfusion, she is endoscopied; somewhat surprisingly, there are oesophageal varices evidence of adherent clot. You note on a blood sample performed when she attended for a DVT about a year earlier that her APTT was significantly prolonged. She tells you that she drinks 3 glasses of wine on a Friday and a Saturday night.

Which of the following is the most appropriate treatment for her varices?

A	Banding
B	Oral omeprazole 40 mg daily
C	Propanolol 40mg daily

resuscitation and blood transfusion, she is endoscopied; somewhat surprisingly, there are oesophageal varices evidence of adherent clot. You note on a blood sample performed when she attended for a DVT about a year earlier that her APTT was significantly prolonged. She tells you that she drinks 3 glasses of wine on a Friday and a Saturday night.

Which of the following is the most appropriate treatment for her varices?

A	Banding
B	Oral omeprazole 40 mg daily
C	Propanolol 40mg daily
D	Helicobacter eradication
E	Spironolactone 50mg daily

33058

A Banding

Banding is the most appropriate treatment for acutely bleeding varices, and is useful in conjunction with surveillance endoscopy to prevent further complications. The prolonged activated partial thromboplastin time (APTT) points to antiphospholipid antibody syndrome with hepatic vein thrombosis as a possible cause of her chronic liver disease. Over the longer term a shunting procedure to relieve portal hypertension is likely to be required.

C Propanolol 40mg daily

Propanolol reduces portal hypertension and is useful to reduce further complications, particularly associated with alcoholic cirrhosis, although once varices are established, surveillance with banding is most effective.

B Oral omeprazole 40 mg daily

surveillance with banding is most effective.

B	Oral omeprazole 40 mg daily

Regular Omeprazole only reduces acid secretion and is ineffective in reducing risk of bleeding from oesophageal varices.

D	Helicobacter eradication

Helicobacter eradication is effective in reducing the risk of recurrent peptic ulcer disease.

E	Spironolactone 50mg daily

Spironolactone is most useful in controlling oedema associated with hepatic failure.

33058

Rate this question:

A 29-year-old drug abuser is referred to the Rheumatology Clinic for review. She has suffered from intermittent fevers, joint and muscle pains and a skin rash over the past few months. She admits to continued use of iv heroin over the past three years.

Other past history of note includes an episode of left common peroneal nerve palsy some 6 months earlier. Her only medication is the combined oral contraceptive pill.

On examination, her BP is 145/90 mmHg, with pulse 80/min and regular. She has an erythematous skin rash and you notice some spider naevi on examination of the upper body.

Investigations:

Hb	10.9 g/dl
WCC	10.2×10^9/l
PLT	112×10^9/l
Na^+	137 mmol/l
K^+	4.3 mmol/l

Creatinine	133 μmol/l
ESR	65 mm/1st hour
Urine	blood ++ protein ++
HepBsAg	+
HepBeAg	+
HepBsAb	-ve
HepBcAb	+

Which of the following is the most likely diagnosis?

A	Churg–Strauss syndrome
B	Goodpasture syndrome
C	Polyarteritis nodosa (PAN)
D	Systemic lupus erythematosus
E	Wegener's granulomatosis

C Polyarteritis nodosa (PAN)

PAN, a vasculitic disorder characterised by peripheral neuropathy, kidney disease and arthritis, is associated with hepatitis B infection. Ordinarily, immunosuppression would be the intervention of choice for PAN, although here it is likely to have a deleterious effect on the course of the hepatitis B. Interferon alpha-based regimens, coupled with plasmapheresis and a short course of corticosteroids, have been used successfully to treat the condition. The incidence of hepatitis B (HBV)-PAN has decreased significantly due to access to hepatitis B vaccination worldwide. HBV was once considered to be the cause of 30% of PAN cases, However, it now accounts for <8% of all PAN cases.

A Churg–Strauss syndrome

Churg–Strauss disease is a systemic small-vessel vasculitis, characterised by bronchial asthma, rhinitis, sinusitis

by bronchial asthma, rhinitis, sinusitis and bronchitis. Bronchial asthma is the initial disease manifestation.

B	Goodpasture syndrome

Goodpasture syndrome is an autoimmune disorder, characterised by glomerulonephritis with or without pulmonary haemorrhage and the presence of antiglomerular (anti-GBM) antibodies.

D	Systemic lupus erythematosus

SLE is a possible diagnosis in this case, but mononeuritis is associated more with PAN than SLE.

E	Wegener's granulomatosis

Wegener's granulomatosis is a necrotising granulomatous inflammation and pauci-immune vasculitis in small and medium-sized blood vessels, characterised mainly by

A 42-year-old businessman who travels twice per month to Africa, the Indian subcontinent and Eastern Europe is requesting some medication to reduce the duration and severity of travellers' diarrhoea which he seems to suffer from nearly every time he goes abroad. He says this is crampy in nature and accompanied by multiple episodes of non-bloody diarrhoea. He is otherwise completely well.

Which of the following agents is proven to reduce the severity of symptoms?

A	Ciprofloxacin and loperamide taken at the onset of symptoms
B	Metronidazole if symptoms continue for longer than 24h
C	Co-amoxiclav taken daily during the trip
D	Loperamide taken at the

to reduce the duration and severity of travellers' diarrhoea which he seems to suffer from nearly every time he goes abroad. He says this is crampy in nature and accompanied by multiple episodes of non-bloody diarrhoea. He is otherwise completely well.

Which of the following agents is proven to reduce the severity of symptoms?

A	Ciprofloxacin and loperamide taken at the onset of symptoms
B	Metronidazole if symptoms continue for longer than 24h
C	Co-amoxiclav taken daily during the trip
D	Loperamide taken at the onset of symptoms
E	Oral rehydration solution

A Ciprofloxacin and loperamide taken at the onset of symptoms

Most travellers' diarrhoea (defined as > 3 loose stools / 24 h with or without cramps, nausea, vomiting or fever) is a self-limiting illness and mild to moderate symptoms can be treated conservatively with a bismuth or anti motility agent. Treatment with antibiotics and loperamide has been shown to reduce the length of illness by 2-3 days but this must be weighed against potential risks. In this case the frequency of episodes warrants treatment. Severe symptoms (for example, those with fever, blood or mucus in the stool) would also benefit from antibiotic treatment. Where antibiotics are indicated then a combination of ciprofloxacin and loperamide at onset can be recommended. Traveller's diarrhoea is typically caused by bacterial infections (*campylobacter* being the most common along with *Ecoli, salmonella, shigella* and rarely

shigella and rarely *V.cholerae*).Ciprofloxacin provides good cover for most of these infections. In areas of high resistance to fluoroquinolones (i.e. south and south east Asia) then azithromycin is recommended. In areas where E.coli is the most common pathogen (Latin America and parts of Africa) then rifaximin may be used.

B	Metronidazole if symptoms continue for longer than 24h

Metronidazole is used for the treatment of parasitic gastroenteritis (e.g. amoebiasis or giardiasis). It should be considered if diarrhoea fails to settle and stool is examined for ova, cysts and parasites.

C	Co-amoxiclav taken daily during the trip

Antibiotic prophylaxis is not recommended for travellers' diarrhoea as it tends to be a self-limiting illness and therefore the risk of adverse

as it tends to be a self-limiting illness and therefore the risk of adverse effects (eg C.diff, candida, antibiotic resistance) are deemed to be greater than potential benefit.

D	Loperamide taken at the onset of symptoms

For milder symptoms (ie bowels opening 2-3 times per day) then symptomatic treatment alone with bismuth subsalicylate or loperamide can be used. However, it will not shorten the duration of the illness.

E	Oral rehydration solution

Oral rehydration solution is useful for replenishing water and salts lost due to diarrhoea, but does not impact on symptoms.

21429

Rate this question:

A 32-year-old man is seen with a long history of anaemia. He denies haematemesis or melaena. His past medical history includes an episode of intussusception 1 year ago. He has been investigated previously with an upper gastrointestinal endoscopy and a colonoscopy, which are normal. Lower duodenal biopsies are normal. He has since been started on iron tablets.

On examination, the only significant findings are melanin spots on his buccal mucosa and fingers.

Investigations:

Haemoglobin (Hb)	9.1 g/l
White blood count (WBC)	6.0 × 10^9/l
Platelets	192 × 10^9/l
Mean cell volume (MCV)	71 fl
Ferritin	3 μg/l

Platelets	10^9/l
Mean cell volume (MCV)	71 fl
Ferritin	3 μg/l

A barium meal and follow-through is abnormal and an enteroscopy shows multiple hamartomatous polyps.

What is the most likely diagnosis?

A Gardner syndrome

B Peutz–Jeghers syndrome

C Cowden syndrome

D Familial adenomatosis polyposis

E Pseudo-polyps

B Peutz-Jeghers syndrome

Perioral freckling is seen in Peutz-Jeghers syndrome. Other areas that may be affected by dark melanin flecks include the fingers, toes and perianal skin. It is an autosomal dominant condition with small intestinal hamartomas and an increased risk of gastrointestinal malignancies. It usually presents in the second or third decade of life and patients may develop anaemia or intussusception. Current surveillance recommendations include biennial upper and lower endoscopy plus barium meal and follow-through.

A Gardner syndrome

Gardner syndrome is a form of familial adenomatosis polyposis with osteomas and neuromas. These can especially affect the skull. Like all familial adenomatosis polyposis, monitoring for malignancy is needed.

Cowden syndrome is characterised by multiple hamartomas of the skin, mucous membranes, thyroid and breast, associated with hamartomatous polyps of the gastrointestinal and urinary tracts.

D	Familial adenomatosis polyposis

Familial adenomatosis polyposis (FAP) is associated with hundreds to thousands of colonic adenomas. This can cause rectal bleeding and anaemia, and may progress to malignancy. Serial monitoring with colonoscopy is needed.

E	Pseudo-polyps

Pseudo-polyps are projecting masses that occur from scar tissue following repeated healing in bowel ulceration. These can cause bowel obstruction, but not intussusception and would need an underlying inflammatory bowel diagnosis to qualify as a viable

A 55-year-old woman with a known history of coeliac disease was reviewed in Outpatients complaining of watery diarrhoea ten times per day and abdominal cramping pains of 10 months' duration. There was no accompanying weight loss.

She claimed to have been adhering to her gluten free diet and gave no history of foreign travel or changes in her medication. She took Aspirin and Digoxin for chronic atrial fibrillation and Ibuprofen for osteoarthritis.

Examination revealed a well-looking lady who was in rate-controlled atrial fibrillation. No other abnormalities were noted.

Full blood count, electrolytes, serum calcium, immunoglobulins, CRP and the ESR were normal. IgA anti-endomysial antibodies were negative.

The colonic mucosa looked normal at colonoscopy. A biopsy specimen taken at the time is shown below:

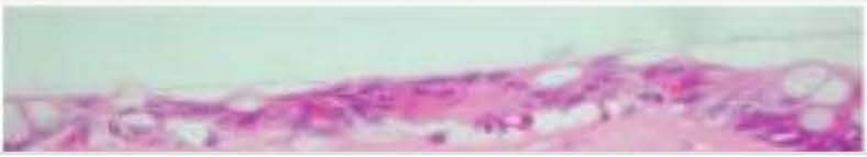

at the time is shown below:

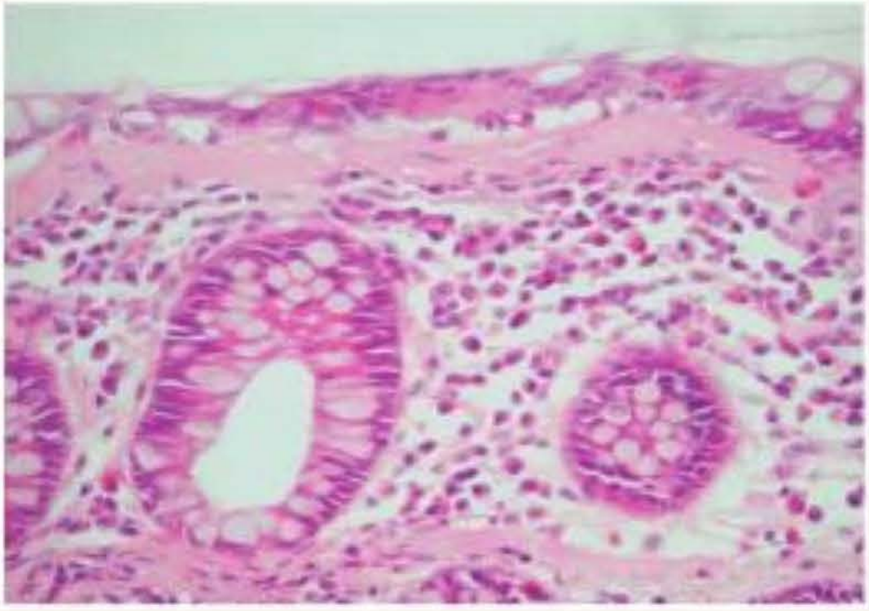

Which of the following is the most likely diagnosis?

A	Ulcerative colitis
B	Poorly controlled coeliac disease
C	Coeliac disease-related lymphoma
D	Ischaemic colitis
E	Collagenous colitis

E Collagenous colitis

Collagenous colitis is one of the forms of microscopic colitis, i.e. a condition in which the colon appears normal on colonoscopy, but where the diagnosis is made based on the abnormal histology of colonic biopsies. The condition predominantly affects women (male: female of 1: 4) in the fifth and sixth decades of life. The aetiology is unknown, although an association with several medications – in particular, non-steroidal anti-inflammatory drugs - is well-recognised. There is also an association with coeliac disease and other autoimmune disorders.

The condition typically causes chronic watery diarrhoea (which tends to be worse during the day than at night), and is also often accompanied by crampy, diffuse abdominal pain. Blood tests are normally unremarkable and both radiological and macroscopic appearances tend to be normal. The diagnosis is made based on the typical histological appearances of a

histological appearances of a thickened subepithelial collagen band, a moderate inflammatory cell infiltrate, and an increase in intraepithelial lymphocytes.

Treatments for collagenous colitis include antidiarrhoeal agents (such as Loperamide), 5-aminosalicyclate drugs, corticosteroids, and bile acid sequestrants, all of which are variably effective.

C	Coeliac disease-related lymphoma

In a patient with coeliac disease who follows a gluten-free diet and who has negative IgA anti-endomysial antibodies, coeliac disease-related lymphoma is unlikely.

A	Ulcerative colitis

The description that her colonic mucosa appeared normal on colonoscopy – together with normal blood tests – is inconsistent with a

A Ulcerative colitis

The description that her colonic mucosa appeared normal on colonoscopy – together with normal blood tests – is inconsistent with a diagnosis of ulcerative colitis.

B Poorly controlled coeliac disease

In a patient with coeliac disease who follows a gluten-free diet and who has negative IgA anti-endomysial antibodies, poorly-controlled coeliac disease is unlikely.

D Ischaemic colitis

The description that her colonic mucosa appeared normal on colonoscopy – together with normal blood tests – is inconsistent with a diagnosis of ischaemic colitis.

70156

Rate this question:

A 72-year-old heavy smoker presents with indigestion, which is now complicated by progressive dysphagia, first to solids such as toast and now to liquids as well. Bloods taken by his general practitioner (GP) suggest iron deficiency anaemia and his viscosity is elevated.

On examination, he has palpable lymph nodes in the left supraclavicular fossa, and wheeze throughout both lung fields.

Which of the following would be the investigation of choice in this patient?

A	Upper gastrointestinal endoscopy
B	Barium swallow
C	Chest X-ray
D	Bronchoscopy
E	CT scan of the thorax

A Upper gastrointestinal endoscopy

The presence of dysphagia and the enlarged left supraclavicular nodes raises the possibility of upper GI carcinoma, most likely oesophageal. As such, the investigation of choice would be upper GI endoscopy with biopsy. Carcinomas of the oesophagus may be squamous or adenocarcinomas; there is an association with smoking, alcohol consumption, ingestion of nitrate-containing foods, Plummer–Vinson syndrome, and chronic gastro-oesophageal reflux disease. Taking into account there is already lymph node enlargement, this patient is highly unlikely to be a candidate for oesophagectomy. Squamous cell carcinoma is more responsive than adenocarcinoma to radiotherapy, so this is at least an option for some patients. Unfortunately, 5 year survival for oesophageal carcinoma is very poor.

A 17-year-old girl is referred by her general practitioner (GP) with weight loss and vomiting. During the consultation, it becomes apparent that she has an altered body image.

Which of the following would best assess her nutritional status?

A	Serum albumin
B	FSH:oestrogen ratio
C	Mid-thigh:hip ratio
D	Mid-arm muscle circumference and skin-fold thickness
E	Height (m)/weight (kg)

2283

Submit

Previous Question Skip Question

Calculator

Normal Values

Blog About Pastest Contact Us Help

© Pastest 2019

D Mid-arm muscle circumference and skin-fold thickness

Anthropometry allows for an assessment of body composition, and a number of anthropometric measurements can be used.

B FSH:oestrogen ratio

Amenorrhoea is associated with anorexia nervosa, but the FSH:oestrogen ratio is not routinely used to assess nutrition.

A Serum albumin

The serum albumin level can fall in conditions such as sepsis and liver disease, and should therefore not be considered a good indicator of nutritional status.

C Mid-thigh:hip ratio

The waist:hip ratio is a useful measure in the context of central obesity, but the mid-thigh:hip ratio is a fictitious measurement.

E Height (m)/weight (kg)

The body mass index (BMI) can be used to stratify patients, but is calculated by weight/(height)^2 rather than height/weight. The BMI measurement takes into account neither the difference between fat and non-fat mass, such as bone and muscle, nor the changes in body composition that occur with age.

2283

Rate this question:

A 27-year-old man travelling in Bolivia wakes up with watery diarrhoea and stomach cramps. He continues to have diarrhoea and cramps for the next couple of days. He is also very weak and tired but is managing to drink good volumes of boiled water.

He phones you, his physician, in London for advice and whether he should take antibiotics. He tells you that he has had his blood pressure checked at the local pharmacy and it is 100/60 mmHg, his pulse was 85/min when he checked it himself.

Which of the following is an indication for antibiotic therapy?

A	He should have started antibiotics on Day 1 of the illness
B	He should start antibiotics if his condition persists for >3 days
C	He should only start

when he checked it himself.

Which of the following is an indication for antibiotic therapy?

A	He should have started antibiotics on Day 1 of the illness
B	He should start antibiotics if his condition persists for >3 days
C	He should only start antibiotics if he has more than ten episodes of diarrhoea per day
D	He should start antibiotics if he has swallowed water from the local river
E	He should start antibiotics if there is fresh blood when he wipes himself clean

A 64-year-old man presents to the Emergency Department with abdominal pain and distension and a 2-day history of persistent vomiting. He has had intermittent abdominal pain for the last 5 weeks and diarrhoea for 3 days prior to the onset of vomiting. He has not passed a bowel motion since.

His past medical history includes hypertension and coeliac disease, from which he has been asymptomatic for the past 10 years. He has lost 4 kg in weight over the past 5 months.

Physical examination shows a distended abdomen. Bowel sounds are tinkling in nature.

What is the most likely cause of this patient's symptoms?

A	Adhesions
B	Carcinoma of the colon
C	Meckel's diverticulum

has not passed a bowel motion since.

His past medical history includes hypertension and coeliac disease, from which he has been asymptomatic for the past 10 years. He has lost 4 kg in weight over the past 5 months.

Physical examination shows a distended abdomen. Bowel sounds are tinkling in nature.

What is the most likely cause of this patient's symptoms?

A	Adhesions
B	Carcinoma of the colon
C	Meckel's diverticulum
D	Small bowel lymphoma
E	Small bowel carcinoma

5:49
tps://mypastest.pastest.com

days prior to the onset of vomiting. He has not passed a bowel motion since.

His past medical history includes hypertension and coeliac disease, from which he has been asymptomatic for the past 10 years. He has lost 4 kg in weight over the past 5 months.

Physical examination shows a distended abdomen. Bowel sounds are tinkling in nature.

What is the most likely cause of this patient's symptoms?

Your answer was correct

A	Adhesions
B	Carcinoma of the colon
C	Meckel's diverticulum
D	Small bowel lymphoma

D Small bowel lymphoma

Coeliac disease is a common and underdiagnosed condition, which may present at any age. It is a hypersensitivity to gluten found in wheat, rye and barley. The gliadin fraction of the protein provokes an inflammatory response causing subtotal or total villous atrophy of the small bowel, resulting in malabsorption. It classically presents with a history of diarrhoea, weight loss, lethargy and anaemia (folate, B_{12} or iron-deficient). It is associated with an increased risk of developing small bowel lymphoma, which thankfully only occurs in a very small proportion of coeliac patients. It is the rapid deterioration seen here, with weight loss, which points us towards malignant transformation of the coeliac to small bowel lymphoma.

A Adhesions

There is no previous history of bowel

surgery or abdominal surgery to suggest that adhesions may be present to cause small bowel obstruction.

B	Carcinoma of the colon

The history of coeliac disease makes small bowel lymphoma a more likely cause than carcinoma of the bowel, especially in the absence of lower GI symptoms before the presentation with acute abdomen.

C	Meckel's diverticulum

Meckel's diverticulum is the most common congenital anomaly of the gastrointestinal tract. It results from incomplete obliteration of the vitelline duct leading to the formation of a true diverticulum of the small intestine. Meckel's diverticulum is a true diverticulum, containing all layers of the small bowel wall. It arises from the anti-mesenteric surface of the middle-to-distal ileum. The diverticulum represents a persistent remnant of the

to-distal ileum. The diverticulum represents a persistent remnant of the omphalo-mesenteric duct, which connects the midgut to the yolk sac in the foetus. Meckel's diverticula are uncommon and often clinically silent, particularly in the adult. Asymptomatic Meckel's diverticulum may be discovered during abdominal exploration for the evaluation of unrelated pathology. Less commonly, it is found incidentally on diagnostic imaging. When symptomatic, Meckel's diverticulum may present with abdominal pain or symptoms of gastrointestinal bleeding or bowel obstruction. In this scenario, the past medical history of coeliac disease makes Meckel's diverticulum a less likely diagnosis.

E	Small bowel carcinoma

The history of coeliac disease makes small bowel lymphoma a more likely cause than carcinoma of the bowel, although carcinoma of the small bowel can also cause weight loss and small

A 44-year-old man with a long history of diarrhoea presented with a painful lesion on his leg. He had noticed what he thought was an insect bite some days previously, which rapidly progressed to the lesion depicted below. He had started feeling unwell with the development of the lesion and described general malaise and arthralgia.

His barium enema is shown below:

What is the cause of his diarrhoea?

A Crohn's disease

B Ulcerative colitis

C Ogilvie's syndrome

D Ischaemic colitis

E Colonic carcinoma

70162

Submit

B Ulcerative colitis

The barium enema shows the typical 'hosepipe' colonic appearance found in chronic ulcerative colitis. The colonic wall is featureless here, consistent with chronic inflammation. Incidentally, this man also has situs inversus. The lesion on his leg is pyoderma gangrenosum.

A Crohn's disease

Crohn's disease produces skip lesions, so would not typically manifest with uniform involvement of the whole large bowel, as is the case here.

C Ogilvie's syndrome

Ogilvie's syndrome is associated with dilated large bowel, but not with inflammation.

D Ischaemic colitis

The findings here are not suggestive of

A 29-year old social worker is brought to the Emergency Department after having taken 40 paracetamol tablets with half a bottle of vodka 5 h prior to admission, following an argument with her boyfriend. She feels nauseous and complains of abdominal pain. There is no past medical history of note and she takes occasional codeine tablets. She drinks about 15 units of alcohol per week. Physical examination is normal.

Investigations:

Na^+	139 mmol/l
K^+	3.7 mmol/l
Urea	5.0 mmol/l
Creatinine	60 μmol/l
Bicarbonate	19 μmol/l
INR	1.1
Serum paracetamol level	200 mg/l (100-200)

Which of the following is the most useful prognostic indicator when

Bicarbonate	19 µmol/l
INR	1.1
Serum paracetamol level	200 mg/l (100-200)

Which of the following is the most useful prognostic indicator when tested the following day?

A Serum bilirubin

B Paracetamol

C Prothrombin time

D Plasma glucose

E Serum albumin

33032

Submit

C Prothrombin time

aracetamol toxicity is likely to occur with single ingestions >250 mg/kg or those >12 g over a 24 h period. The patient has taken 20 g of paracetamol. Virtually all patients who ingest doses in excess of 350 mg/kg develop severe liver toxicity. Appropriate paracetamol doses produce a small amount of N-acetyl-benzoquinoneimine (NAPQI), which is rapidly conjugated with hepatic glutathione, forming non-toxic cysteine and mercaptate compounds that are excreted in the urine. In paracetamol overdose, the glucuronidation pathways are saturated and more paracetamol is metabolised to NAPQI via the cytochrome P450 enzymes. The liver is unable to deactivate NAPQI, which is responsible for massive hepatic necrosis and hepatic failure. Patients may have nausea, anorexia or vomiting on the first day. After 72 h, features of liver and kidney disease may become apparent. In paracetamol-induced fulminant liver failure, there are two

fulminant liver failure, there are two broad criteria for referral for orthotopic liver transplantation: an arterial pH of <7.3, irrespective of grade of encephalopathy; or a prothrombin time (PT) >100 s and a serum creatinine concentration >300 μmol/l in patients who have grade III or IV encephalopathy. A rise in serum creatinine is a bad prognostic marker and is associated with 70% mortality. A pH <7.3 is associated with only 15% chance of survival due to failure of clearance of lactate by the liver.

A	Serum bilirubin

Bilirubin is a breakdown product from haem in catabolism. Following conjugation in the liver, it is excreted via stool. Bilirubin may rise in paracetamol overdose as the liver fails to properly conjugate and excrete bilirubin. However, the rate at which this occurs correlates poorly to disease severity.

B Paracetamol

Serum paracetamol is a useful measurement in non-staggered paracetamol overdoses 4 h following ingestion. However, the concentration of serum paracetamol does not guide the severity of liver injury that follows and it is therefore not a prognostically useful test.

D Plasma glucose

In acute liver decompensation, metabolic processes of the liver can break down. These include gluconeogenesis, which can lead to hypoglycaemia. However, the extent of hypoglycaemia correlates poorly with the extent of acute liver disease and can easily be affected by other factors such as co-morbidities or other drugs taken.

E Serum albumin

Albumin is a protein made the liver and

metabolic processes of the liver can break down. These include gluconeogenesis, which can lead to hypoglycaemia. However, the extent of hypoglycaemia correlates poorly with the extent of acute liver disease and can easily be affected by other factors such as co-morbidities or other drugs taken.

E	Serum albumin

Albumin is a protein made the liver and which functions partially to maintain colloid oncotic pressure. In measuring albumin it acts as a negative acute phase reactant – i.e. it is lower in acute inflammatory conditions. It is also lower in chronic liver disease as the synthetic function of the liver deteriorates. However, it is not a reliable marker in the acute setting and does not help guide prognosis.

33032

Rate this question:

Next Question

A 53-year-old man is referred to the Gastroenterology Clinic for investigation into the cause of his deranged liver function tests found incidentally at preoperative assessment. He denies any abdominal pain or jaundice. He has hypertension and type 2 diabetes mellitus, treated with atenolol, gliclazide and metformin. He consumes approximately 10 units of alcohol per week and is an ex-smoker. He stopped smoking 10 years ago.

On physical examination, he is obese with a body mass index (BMI) 37 kg/m^2. There are no stigmata of chronic liver disease, but on abdominal examination he has hepatomegaly 4 cm below the right costal margin. There is no splenomegaly or ascites.

Liver function tests:

Bilirubin	18 µmol/l
Alkaline phosphatase	134 IU/l
Alanine aminotransferase	160 IU/l
Aspartate transaminase	110 IU/l

Albumin	40 g/l
Erythrocyte sedimentation rate	48 mm/h
Ferritin	380 mg/l

An abdominal ultrasound scan revealed an echo-bright enlarged liver and multiple gallstones within a thin-walled gall bladder.

What is the most likely cause of this patient's liver disease?

A	Alcoholic cirrhosis
B	Cholestasis secondary to gallstones
C	Drug-induced hepatitis
D	NASH (non-alcoholic steatohepatitis)
E	Haemachromatosis

D NASH (non-alcoholic steatohepatitis)

NASH may be described as a 'silent' liver disease. It is almost always asymptomatic and diagnosed incidentally. It is characterised by hepatomegaly, elevated transaminases and the histological appearance of alcoholic liver disease on biopsy, in the absence of alcohol abuse. It affects both men and women and is more common in the obese and those with diabetes mellitus. Whilst only approximately 2% of patients with fatty infiltration progress to cirrhosis and liver failure, where steatohepatitis exists, progression to cirrhosis is as high as 10%. There is no proven treatment for NASH, but patients should be advised to lose weight.

A Alcoholic cirrhosis

This man's alcoholic consumption is not excessive and therefore alcoholic cirrhosis is a less likely diagnosis. His

cirrhosis is a less likely diagnosis. His alcohol consumption is unlikely to be responsible for the picture seen here.

B	Cholestasis secondary to gallstones

The liver function tests do not show a cholestatic picture and therefore cholestasis secondary to gallstones is unlikely. There may be a history of abdominal pain with gallstones and there is no hepatomegaly.

C	Drug-induced hepatitis

Drug-induced hepatitis will not produce hepatomegaly. Drug-induced hepatitis will present with disproportionate elevation in serum aminotransferases compared with alkaline phosphatase, bilirubin may be elevated and tests of synthetic function may be abnormal. Drug-associated hepatic injury may occur in a dose-dependent, predictable way or in an unpredictable idiosyncratic fashion. The latter may be either

associated hepatic injury may occur in a dose-dependent, predictable way or in an unpredictable idiosyncratic fashion. The latter may be either immune mediated or metabolic.

E	Haemachromatosis

Hereditary hemochromatosis (HH), most commonly due to mutations in the HFE gene, is an autosomal recessive disorder in which these mutations cause increased intestinal iron absorption. Less common causes of HH include mutations in the genes for haemojuvelin, hepcidin and ferroportin. The clinical manifestations of this disorder, and of other forms of iron overload, are related to excessive iron deposition in tissues, especially the liver, heart, pancreas and pituitary. An abdominal ultrasound scan revealing an echo-bright enlarged liver goes against this diagnosis. The ferritin level also makes haemochromatosis unlikely.

9519

Rate this question:

A 65-year-old man is seen in the clinic after he presents to his general practitioner (GP) with a 1-year history of tiredness, and is found to be anaemic. He has no previous medical history and takes no medication. He reports no weight loss and denies a change in bowel habit. He has a varied diet including red meat. There is nothing to find on examination.

Investigations:

Hb	11.5 g/dl
WCC	10.0×10^9/l
PLT	300×10^9/l
MCV	70 fl
MCH	20 pg
Ferritin	10 μg/l
B_{12}	500 ng/l
Serum folate	9 μg/l

Which investigation would you perform next?

PLT	300 × 10^9/l
MCV	70 fl
MCH	20 pg
Ferritin	10 µg/l
B_{12}	500 ng/l
Serum folate	9 µg/l

Which investigation would you perform next?

A Urinalysis

B OGD

C Colonoscopy

D Faecal occult blood (FOB)

E Capsule endoscopy

71089

A Urinalysis

In the developed world, iron deficiency anaemia (IDA) has a prevalence of 2–5% among adult men and post-menopausal women. The British Society of Gastroenterology published guidelines on the investigation of such patients. For the investigation of IDA, urinalysis for blood is recommended, as an estimated 1% of patients with IDA will have renal tract malignancy caused by haematuria and haemosiderin deposition in the tumour. This is a non-invasive test and therefore should be performed next in this patient.

D Faecal occult blood (FOB)

This test is of no benefit in the investigation of established IDA as it is insensitive and non-specific, although it has a role in population screening for colorectal cancer.

B OGD

B OGD

In all men, post-menopausal women and women aged over 50 years, mandatory investigations for IDA include an OGD, but this would not be the next test you would perform.

C Colonoscopy

This would be indicated, particularly to exclude malignancy as a cause for this patient's anaemia, but it would not be the next test you perform as it is an invasive procedure.

E Capsule endoscopy

This investigation is usually reserved for patients who have a normal OGD and colonoscopy but remain anaemic despite iron replacement therapy. This investigation is then performed to rule out a small bowel cause for their anaemia, such as Crohn's disease or angiodysplasia.

A 65-year-old man is seen in the clinic after he presents to his general practitioner (GP) with a 1-year history of tiredness, and is found to be anaemic. He has no previous medical history and takes no medication. He reports no weight loss and denies a change in bowel habit. He has a varied diet including red meat. There is nothing to find on examination.

Investigations:

Hb	11.5 g/dl
WCC	10.0×10^9/l
PLT	300×10^9/l
MCV	70 fl
MCH	20 pg
Ferritin	10 µg/l
B_{12}	500 ng/l
Serum folate	9 µg/l

A 67-year-old woman with rheumatoid arthritis comes to the clinic for review, complaining of tiredness. She takes non-steroidal anti-inflammatory drugs (NSAIDs), low-dose prednisolone and methotrexate for her rheumatoid, and additionally has hypertension, for which she takes amlodipine 5 mg daily.

Investigations:

Hb	11.0 g/dl
MCV	86 fl
Ferritin	400 μmol/l
Iron	9 μmol/l (low)

You are keen to differentiate definitively between iron deficiency anaemia and anaemia of chronic disease.

Which of the following is most useful to differentiate between the two?

A	Erythropoietin levels

Hb	11.0 g/dl
MCV	86 fl
Ferritin	400 µmol/l
Iron	9 µmol/l (low)

You are keen to differentiate definitively between iron deficiency anaemia and anaemia of chronic disease.

Which of the following is most useful to differentiate between the two?

A	Erythropoietin levels
B	Upper GI endoscopy
C	Small bowel follow-through
D	Colonoscopy
E	Bone marrow biopsy

E Bone marrow biopsy

Estimation of iron content in a bone marrow aspiration rules out iron deficiency anaemia if it is normal. Although the other investigations may be pointers to one or the other diagnosis, they don't definitely rule out the alternative.

A Erythropoietin levels

EPO levels are reduced in anaemia of chronic disease, although for example in diseases such as chronic kidney disease, both iron deficiency anaemia and low EPO can co-exist. This makes it impossible to rule out iron deficiency anaemia on EPO levels alone.

B Upper GI endoscopy

Upper GI endoscopy may reveal ulcers, although this wouldn't rule iron deficiency anaemia in or out, or rule anaemia of chronic disease out.

and low EPO can co-exist. This makes it impossible to rule out iron deficiency anaemia on EPO levels alone.

B Upper GI endoscopy

Upper GI endoscopy may reveal ulcers, although this wouldn't rule iron deficiency anaemia in or out, or rule anaemia of chronic disease out.

C Small bowel follow-through

We are given no indication of symptoms consistent with small bowel malabsorption.

D Colonoscopy

Colonoscopy is not indicated by an Hb of 11.0 g/dl, although it may be required in the event that iron deficiency is confirmed as the prevailing pathology.

21006

Rate this question:

A 58-year-old Greek woman attended the Emergency Department with a 4 week history of discomfort in the right upper quadrant.

Examination revealed that she was mildly tender in the right upper quadrant and had 4 cm hepatomegaly. She had a previous laparotomy scar, having had a duodenal ulcer oversewn 20 years previously.

Liver function tests were normal, as was the full blood count. Her abdominal X-ray is shown below:

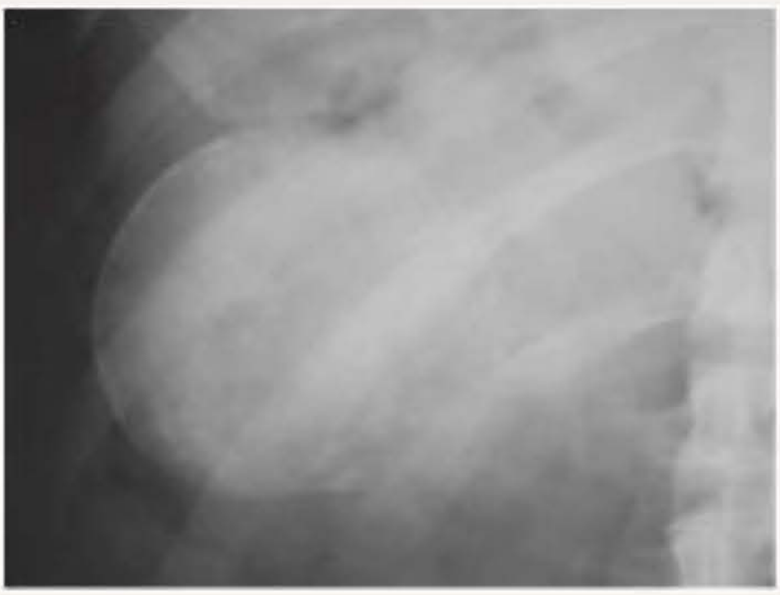

What is the most likely diagnosis?

A	Porcelain gallbladder

Liver function tests were normal, as was the full blood count. Her abdominal X-ray is shown below:

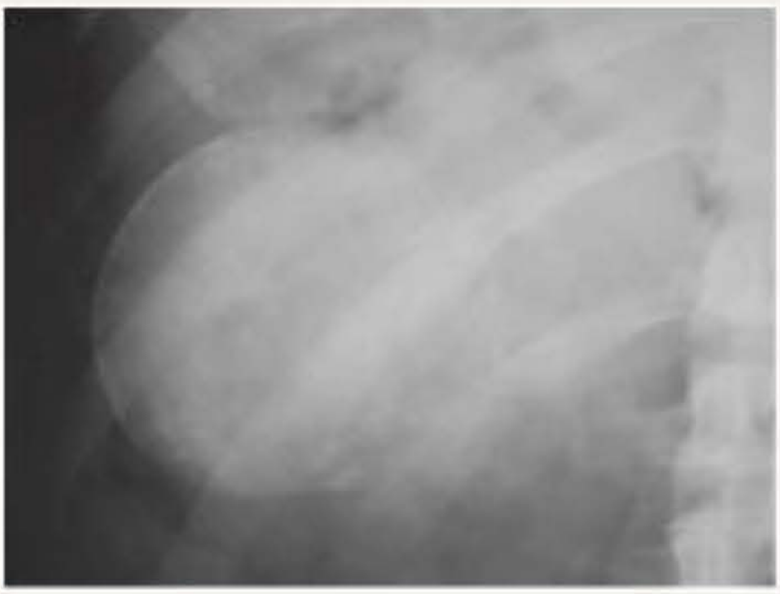

What is the most likely diagnosis?

A	Porcelain gallbladder
B	Hydatid disease
C	Amoebic liver abscess
D	Pyogenic liver abscess
E	Retained foreign body from previous surgery

B Hydatid disease

Hydatid disease is caused by the ingestion of Echinococcus granulosus, a dog tapeworm. It is common in parts of the world associated with raising sheep or cattle, including the Eastern Mediterranean, South America, the Middle East, Australia, and North and East Africa.

The life cycle of E. granulosus includes a stage in pigs, cattle or sheep. It is passed to humans by direct contact with dogs or their faeces. Penetration through the duodenal wall permits the parasite to pass into the liver, from where it can spread to almost any organ. The liver is by far the most common site for hydatid cysts (60%), followed by the lungs (20%). Hydatid cysts can be asymptomatic, but enlarging cysts may cause localised pressure effects, such as pain or jaundice. Up to one-third of affected people have a peripheral eosinophilia.

Complement fixation or haemagglutination tests are often (if not invariably) positive, with assays

not invariably) positive, with assays involving ELISA becoming increasingly prevalent too. About 40% of cysts calcify, and ultrasound or CT imaging frequently shows daughter cysts. Many asymptomatic cysts can be left alone. Pharmacological therapy with Albendazole can shrink cysts, a measure that may be used prior to surgery. Although aspiration was traditionally avoided due to the risk of anaphylaxis, it may now be used therapeutically under chemotherapeutic cover. Complications of untreated hydatid disease include involvement of other organs, secondary infection and cyst rupture.

A Porcelain gallbladder

Firstly, affected people tend to describe a long history of gallstone disease (much longer than the four weeks of symptoms described), and would not be expected to have hepatomegaly. Secondly, radiographs of people with porcelain gallbladder

C	Amoebic liver abscess

Amoebic liver abscess is not typically associated with calcification, so cannot explain the radiograph findings. Furthermore, a leukocytosis and abnormal liver enzymes would be expected if this were the diagnosis here.

D	Pyogenic liver abscess

Pyogenic liver abscess is not typically associated with calcification, so cannot explain the radiograph findings. Furthermore, a leukocytosis and abnormal liver enzymes would be expected if this were the diagnosis here.

E	Retained foreign body from previous surgery

It is unlikely that a foreign body would have been retained for twenty years after surgery without complication before now, and there is no surgical equipment that would typically have

A 62-year-old woman is reviewed in the Psychiatric Clinic for monitoring of her response to lithium therapy. She has a history of previous alcoholism, although she is now alcohol free, and has begun lithium therapy for bipolar disease some 6 months earlier.

Physical examination in the clinic is unremarkable.

You are concerned about the possibility of this leading to hepatic dysfunction.

Which of the following is the most sensitive measure for lithium related hepatotoxicity?

A	AST
B	ALT
C	Alkaline phosphatase
D	Bilirubin
E	Gamma GT

E Gamma GT

Lithium use is particularly associated with a rise in gamma GT, and this is therefore the most sensitive way to monitor its effect on the liver.

A AST

AST is most useful in monitoring for alcoholic liver disease, where a ratio of AST:ALT >2 is suggestive of alcoholic liver disease.

B ALT

ALT is elevated in non-alcoholic steatohepatitis and may elevated in patients taking lithium, although GGT is a more sensitive measure of lithium-related hepatotoxicity.

C Alkaline phosphatase

Elevation in transaminases and gamma GT representing hepatocellular

AST/ALT > 2 is suggestive of alcoholic liver disease.

B ALT

ALT is elevated in non-alcoholic steatohepatitis and may elevated in patients taking lithium, although GGT is a more sensitive measure of lithium-related hepatotoxicity.

C Alkaline phosphatase

Elevation in transaminases and gamma GT representing hepatocellular dysfunction, rather than raised alkaline phosphatase, is more likely to be seen.

D Bilirubin

Acute liver injury with hyperbilirubinaemia is not usually associated with lithium use.

18538

Rate this question:

A 55-year-old man is admitted with a 1-month history of dysphagia to solids. He has previously been fit and well and, on direct questioning, denies previous episodes of dysphagia or reflux.

On examination, he appears cachectic, but there are no palpable masses on abdominal examination. An upper endoscopy is performed, which reveals a lower oesophageal mass. Biopsy of this mass reveals an adenocarcinoma.

Which would be most appropriate test to perform next?

A	Oesophageal manometry
B	CT chest, abdomen and pelvis
C	Barium swallow
D	CXR
E	Genetic screening of family members

B CT chest, abdomen and pelvis

The role of CT chest, abdomen and pelvis in oesophageal carcinoma is to stage the disease. The initial diagnostics can be confirmed from histology of oesphageal biopsies at endoscopy. The incidence of adenocarcinoma in the UK is rising, while that of squamous cell carcinoma is falling.

A Oesophageal manometry

This investigation will not provide you with any additional information on this tumour. Oesphageal manometry is usually performed to rule out dysmotility disorders of the oesophagus, such as achalasia.

C Barium swallow

An OGD has already been performed, so performing a barium swallow will not add any additional useful information to your findings

C	Barium swallow

An OGD has already been performed, so performing a barium swallow will not add any additional useful information to your findings.

D	CXR

This will not provide any additional information on the tumour and so will have a limited use in this setting.

E	Genetic screening of family members

Currently there is no role for genetic testing in oesphageal cancer, so this option is incorrect.

70905

Rate this question:

Next Question

A 45-year-old man presents with an upper gastrointestinal (GI) haemorrhage. He is a non-smoker and drinks only occasional wine. On further questioning, he admits to problems with indigestion over the past few months, for which he has tried over-the-counter Ranitidine tablets, and increasing diarrhoea.

Upper GI endoscopy reveals multiple small gastric ulcers and helicobacter testing is negative. He is willing to have a short period off Ranitidine to be properly investigated.

Which of the following is the most appropriate investigation in this case?

A	Single fasting gastrin level
B	Fasting gastrin on three different days
C	Basal acid output estimation
D	Secretin stimulation test

drinks only occasional wine. On further questioning, he admits to problems with indigestion over the past few months, for which he has tried over-the-counter Ranitidine tablets, and increasing diarrhoea.

Upper GI endoscopy reveals multiple small gastric ulcers and helicobacter testing is negative. He is willing to have a short period off Ranitidine to be properly investigated.

Which of the following is the most appropriate investigation in this case?

A	Single fasting gastrin level
B	Fasting gastrin on three different days
C	Basal acid output estimation
D	Secretin stimulation test
E	Protein meal test

haemorrhage. He is a non-smoker and drinks only occasional wine. On further questioning, he admits to problems with indigestion over the past few months, for which he has tried over-the-counter Ranitidine tablets, and increasing diarrhoea.

Upper GI endoscopy reveals multiple small gastric ulcers and helicobacter testing is negative. He is willing to have a short period off Ranitidine to be properly investigated.

Which of the following is the most appropriate investigation in this case?

Your answer was correct

A	Single fasting gastrin level
B	Fasting gastrin on three different days
C	Basal acid output estimation
D	Secretin stimulation test

B Fasting gastrin on three different days

There is a suspicion that this patient may have Zollinger–Ellison syndrome as a result of a gastrinoma. The best initial screen is a fasting gastrin level on three separate days, as the secretion of gastrin is pulsatile. Three samples in the normal range make a gastrinoma unlikely. This is usually followed by basal acid output estimation and a secretin stimulation test. After this, patients usually move on to imaging studies. In the absence of metastases, surgical resection is advised. Octreotide, interferon and chemotherapy may be useful in non-surgically resectable lesions.

A Single fasting gastrin level

Gastrin has a short half-life and release is cyclical, hence re-measuring on 3 separate days is recommended.

C Basal acid output estimation

Gastrin has a short half-life and release is cyclical, hence re-measuring on 3 separate days is recommended.

C Basal acid output estimation

Basal acid output estimation is a subsequent test after elevated gastrin has been established.

D Secretin stimulation test

Like basal acid output estimation, secretin stimulation test is an investigation which follows the three gastrin measurements.

E Protein meal test

An arginine stimulation test is used in the evaluation of growth hormone deficiency.

33053

Rate this question:

A 60-year-old woman is referred to the Gastroenterology Clinic by her general practitioner (GP) with a 4-month history of diarrhoea. She feels lethargic and has lost 3 kg in weight over the last few weeks. She has not passed any fresh blood or melaena *per rectum*.

Over the past few months, she has had recurrent painful oral ulcers and has developed a particularly itchy skin rash. Her only past medical history is of hypertension, for which she takes an angiotensin-converting enzyme inhibitor.

Routine blood tests reveal a normocytic anaemia.

Which of the following tests is likely to be most useful in diagnosis?

A	Barium enema
B	Endoscopy and jejunal biopsy
C	Colonoscopy

passed any fresh blood or melaena per *rectum*.

Over the past few months, she has had recurrent painful oral ulcers and has developed a particularly itchy skin rash. Her only past medical history is of hypertension, for which she takes an angiotensin-converting enzyme inhibitor.

Routine blood tests reveal a normocytic anaemia.

Which of the following tests is likely to be most useful in diagnosis?

A	Barium enema
B	Endoscopy and jejunal biopsy
C	Colonoscopy
D	Small bowel follow-through
E	Stool microscopy and culture

3G 7:19
tps://mypastest.pastest.com 10

general practitioner (GP) with a 4-month history of diarrhoea. She feels lethargic and has lost 3 kg in weight over the last few weeks. She has not passed any fresh blood or melaena *per rectum*.

Over the past few months, she has had recurrent painful oral ulcers and has developed a particularly itchy skin rash. Her only past medical history is of hypertension, for which she takes an angiotensin-converting enzyme inhibitor.

Routine blood tests reveal a normocytic anaemia.

Which of the following tests is likely to be most useful in diagnosis?

Your answer was correct

A Barium enema

B Endoscopy and jejunal biopsy

B Endoscopy and jejunal biopsy

Coeliac disease is a common and underdiagnosed condition, which may present at any age. It is a hypersensitivity to gluten found in wheat, rye and barley. The gliadin fraction of the protein provokes an inflammatory response causing subtotal or total villous atrophy of the small bowel resulting in malabsorption. It classically presents with a history of diarrhoea, weight loss, oral ulceration, lethargy and anaemia (folate, B_{12} or iron-deficient). There is an association with dermatitis herpetiformis, a very pruritic polymorphic skin rash, and an increased risk of developing gastrointestinal malignancy. Treatment is by maintaining a strict diet avoiding foods containing wheat, rye, oats or barley.

A Barium enema

Coeliac disease affects the small bowel rather than the large bowel, and

rather than the large bowel, and therefore a barium enema which would investigate the large bowel is not useful.

C	Colonoscopy

Coeliac disease affects the small bowel rather than the large bowel, and therefore a colonoscopy is not useful.

D	Small bowel follow-through

It is important to get a tissue diagnosis for coeliac disease, and therefore the jejunal biopsy would be diagnostic rather than a small bowel follow-through.

E	Stool microscopy and culture

Coeliac disease is not an infective process, and therefore stool microscopy and culture would be normal.

A 50-year-old man presents with shortness of breath. He is a known alcoholic and has a past history of ischaemic heart disease.

On examination, he looks jaundiced but his abdomen is soft and non-tender. His blood pressure is 109/82 mmHg, pulse is 80 and regular and his chest sounds clear with good breath sounds bilaterally.

Investigations:

Hb	7.0 g/dl (elevated reticulocytes)
WCC	8.2×10^9/l
PLT	92×10^9/l
Na^+	137 mmol/l
K^+	3.9 mmol/l
Creatinine	85 μmol/l
Bilirubin	35 μmol/l
GGT	400 IU/l
Cholesterol	10 mmol/l

Creatinine	85 µmol/l
Bilirubin	35 µmol/l
GGT	400 IU/l
Cholesterol	10 mmol/l

Which of the following diagnoses do you think he has?

A	Zieve syndrome
B	Whipple's disease
C	Crigler Najjar syndrome
D	Gilbert syndrome
E	Non-alcoholic steatohepatitis syndrome (NASH)

6853

Submit

shortness of breath. He is a known alcoholic and has a past history of ischaemic heart disease.

On examination, he looks jaundiced but his abdomen is soft and non-tender. His blood pressure is 109/82 mmHg, pulse is 80 and regular and his chest sounds clear with good breath sounds bilaterally.

Investigations:

Hb	7.0 g/dl (elevated reticulocytes)
WCC	8.2×10^9/l
PLT	92×10^9/l
Na^+	137 mmol/l
K^+	3.9 mmol/l
Creatinine	85 µmol/l
Bilirubin	35 µmol/l
GGT	400 IU/l
Cholesterol	10 mmol/l

Which of the following diagnoses do

A Zieve syndrome

Zieve syndrome occurs in patients with excessive alcohol consumption, with haemolysis and severe hyperlipidaemia, abdominal pain and transient mildly raised bilirubin. It usually occurs in males and resolves once alcohol consumption is stopped.

B Whipple's disease

Whipple's disease is a cause of gastrointestinal (GI) malabsorption, and is caused by the Gram-positive bacterium *Tropheryma whippelii*. It is also associated with joint pains.

C Crigler Najjar syndrome

Crigler–Najjar syndrome is a rare congenital disorder of bilirubin conjugation. It has two distinct forms, type 1 and type 2: type 2 patients can survive to adulthood without any neurological impairment, whereas this impairment is seen in neonates in type

C Crigler Najjar syndrome

Crigler–Najjar syndrome is a rare congenital disorder of bilirubin conjugation. It has two distinct forms, type 1 and type 2: type 2 patients can survive to adulthood without any neurological impairment, whereas this impairment is seen in neonates in type 1 cases.

D Gilbert syndrome

Gilbert syndrome is a benign cause of isolated hyperbilirubinaemia episodes of jaundice can be triggered by illness, surgery or dehydration.

E Non-alcoholic steatohepatitis syndrome (NASH)

NASH is fatty liver disease unrelated to alcohol exposure and is seen in obese patients with insulin resistance, including those with type 2 diabetes.

6853

Rate this question:

A 32-year-old psychiatric patient was found to have iron deficiency anaemia on routine blood testing and was referred for an opinion. She complained of anorexia, fullness in her abdomen and, more recently, vomiting after eating solids. She was not vegetarian and said that she ate a varied diet, although she does suffer from menorrhagia. She has lost a little weight recently.

Examination reveals a large mass in her upper abdomen. This is found to be non-tender, non-pulsatile and not to move on ventilation. Other than pale conjunctivae and thinning hair, no other signs were found. Her blood tests confirmed iron deficiency anaemia, but were otherwise normal.

Her plain abdominal X-ray is shown:

Her plain abdominal X-ray is shown:

Which of the following is the most likely diagnosis?

A	Bezoar
B	Gastric carcinoma
C	Duodenal ulcer
D	Pancreatic carcinoma
E	Cystocele of the gallbladder

A 32-year-old psychiatric patient was found to have iron deficiency anaemia on routine blood testing and was referred for an opinion. She complained of anorexia, fullness in her abdomen and, more recently, vomiting after eating solids. She was not vegetarian and said that she ate a varied diet, although she does suffer from menorrhagia. She has lost a little weight recently.

Examination reveals a large mass in her upper abdomen. This is found to be non-tender, non-pulsatile and not to move on ventilation. Other than pale conjunctivae and thinning hair, no other signs were found. Her blood tests confirmed iron deficiency anaemia, but were otherwise normal.

Her plain abdominal X-ray is shown:

A Bezoar

The X-ray shows a mass arising from the upper central abdomen. This appears to contain both air and some other material. The rest of the bowel is displaced inferiorly. The mass is therefore likely to be gastric in origin.

This woman had a bezoar, which when removed was found to have a weight of 3kg. Bezoars are concretions of foreign material within the gastrointestinal tract, and are described in many forms, including hair (trichobezoar), vegetable matter (phytobezoar) and persimmon. Predisposing factors include ingesting indigestible matter (which may be part of a psychiatric disorder), inadequate chewing, gastric stasis (which may be caused by the bezoar itself), and previous gastric surgery. Trichophagia (hair-eating) is often found in people with trichotillomania (compulsive pulling out of hair).

Treatments include enzymatic or chemical dissolution of the bezoar (i.e.

Treatments include enzymatic or chemical dissolution of the bezoar (i.e. pancreatic enzymes, cola, pineapple juice, etc), mechanical methods (i.e. endoscopic disruption), and laser fragmentation. Larger bezoars, however, often require surgical intervention.

B	Gastric carcinoma

Although gastric malignancy can cause gastric outflow obstruction, for the stomach to enlarge to this size must have taken a considerable period of time. Furthermore, gastric outflow obstruction tends to present with vomiting before the stomach becomes as dilated as this.

C	Duodenal ulcer

Although duodenal ulcer can cause gastric outflow obstruction, for the stomach to enlarge to this size must have taken a considerable period of time. Furthermore, gastric outflow

have taken a considerable period of time. Furthermore, gastric outflow obstruction tends to present with vomiting before the stomach becomes as dilated as this.

D Pancreatic carcinoma

Although pancreatic carcinoma can cause gastric outflow obstruction, for the stomach to enlarge to this size must have taken a considerable period of time. Furthermore, gastric outflow obstruction tends to present with vomiting before the stomach becomes as dilated as this.

E Cystocele of the gallbladder

Although gallbladder cystocele can cause gastric outflow obstruction, for the stomach to enlarge to this size must have taken a considerable period of time. Furthermore, gastric outflow obstruction tends to present with vomiting before the stomach becomes as dilated as this.

A 62-year-old heavy smoker presents to his general practitioner with increasingly severe heartburn and indigestion. He currently works as a postman and is able to cycle his bike around the local villages delivering mail. A recent trial of ranitidine has not affected his symptoms. He also admits to drinking 20 units of alcohol per week. There was an admission with chest pain some 6 months previously and he has lost 3 kg in weight over the past month.

On examination, his BP is 122/72 mmHg, with pulse 72/min and regular. He has mild epigastric tenderness. Full blood count is normal.

Which of the following is the investigation of choice in this case?

A	Oesophageal manometry
B	Upper gastrointestinal endoscopy
C	Barium swallow

affected his symptoms. He also admits to drinking 20 units of alcohol per week. There was an admission with chest pain some 6 months previously and he has lost 3 kg in weight over the past month.

On examination, his BP is 122/72 mmHg, with pulse 72/min and regular. He has mild epigastric tenderness. Full blood count is normal.

Which of the following is the investigation of choice in this case?

A	Oesophageal manometry
B	Upper gastrointestinal endoscopy
C	Barium swallow
D	Chest X-ray
E	Exercise ECG

A 62-year-old heavy smoker presents to his general practitioner with increasingly severe heartburn and indigestion. He currently works as a postman and is able to cycle his bike around the local villages delivering mail. A recent trial of ranitidine has not affected his symptoms. He also admits to drinking 20 units of alcohol per week. There was an admission with chest pain some 6 months previously and he has lost 3 kg in weight over the past month.

On examination, his BP is 122/72 mmHg, with pulse 72/min and regular. He has mild epigastric tenderness. Full blood count is normal.

Which of the following is the investigation of choice in this case?

Your answer was correct

A Oesophageal manometry

B Upper gastrointestinal

B Upper gastrointestinal endoscopy

Taking into account this patient's smoking and alcohol history and his age, upper GI malignancy must be excluded. The gold standard investigation of choice would be endoscopy. Even if no malignancy is found, Barrett's oesophagus needs excluding as this has a 30–50-fold increased risk of adenocarcinoma of the oesophagus compared to the general population. For this reason, patients are usually managed with high-dose proton pump inhibitor therapy and re-endoscopied every 2–3 years when Barrett's is found. Where there is high-grade dysplasia, oesophagectomy may be recommended.

A Oesophageal manometry

Oesophageal manometry is usually considered when reflux is suspected and endoscopy is equivocal, or for example where there are nocturnal

Oesophageal manometry is usually considered when reflux is suspected and endoscopy is equivocal, or for example where there are nocturnal reflux symptoms.

C	Barium swallow

Barium swallow may miss small malignant lesions and is therefore ill-advised here.

D	Chest X-ray

Chest X-ray is not of value in determining whether myocardial ischaemia or reflux is the cause of his symptoms.

E	Exercise ECG

Given that this patient cycles for his job, it is highly unlikely that an exercise tolerance test will be useful.

33067

Rate this question:

A 41-year-old woman is referred with fatigue and general body itching. She has a history of hypothyroidism and is on thyroxine as replacement therapy. Her clinical examination is normal. She drinks approximately 10 units of alcohol per week and is a non-smoker.

On examination, her BP is 142/85 mmHg, pulse is 75/min and regular. Cardiovascular and respiratory examination is unremarkable. There are scratch marks on examination of her upper body, and spider naevi consistent with chronic liver disease.

Bloods:

Bilirubin	16 μmol/l
ALP	321 U/l
ALT	124 U/l
Albumin	36 g/l
fT4	17.5 pmol/l (10–22)
TSH	2.13 mU/l (0.4–5)
WCC	8.2×10^9/l

WCC	$8.2 \times 10^9/l$
Hb	14.3 g/dl
PLT	$345 \times 10^9/l$
Renal function	Normal
Serum electrophoresis	Increase in the IgM fraction

Which investigation is most likely to be positive in this scenario?

A Myeloma screen

B Smooth muscle autoantibodies

C Anti-mitochondrial antibodies

D Anti-liver kidney microsomes (LKM) antibody

E Bone marrow aspiration

C Anti-mitochondrial antibodies

Most likely diagnosis in this patient is Primary biliary cirrhosis (PBC), which is a condition of gradual destruction of the intrahepatic bile ducts, leading to fibrosis and cholestasis and ultimately hepatic cirrhosis, usually presented in middle aged women. Pruritis, fatigue and elevated alkaline phosphatase are some of the characteristic features seen in PBC. Anti-mitochondrial antibodies test is specific to PBC, as these antibodies are present in more than 90 % of cases.

A Myeloma screen

Myeloma is a disease of older adults, characterized by bone pain, anaemia and kidney disease. Majority of patients with myeloma will have a monoclonal spike in the gamma or beta regions on protein electrophoresis, however, myeloma screening in this patient is less likely to

D	Anti-liver kidney microsomes (LKM) antibody

Anti-liver kidney microsomes (LKM) antibody also known as CYP2D6 antibody, is useful in diagnosis of autoimmune hepatitis. Patients with type 2 autoimmune hepatitis show a positive anti-LKM-1 antibody, but the result is not definitive. A liver biopsy may be performed to help confirm the diagnosis. If the anti-LKM-1 test is negative, but smooth muscle antibodies and/or antinuclear antibodies are positive, then it is likely to be type 1 autoimmune hepatitis. This patient is most likely suffering from PBC.

E	Bone marrow aspiration

Bone marrow aspiration is non – specific for the diagnosis of PBC.

33019

Rate this question:

A 55-year-old actor is referred to outpatients after a routine medical revealed abnormal liver function tests with elevated γ-glutamyl transferase (GGT). He feels well in himself apart from occasional bouts of breathlessness. He has no past medical history. He takes occasional non-steroidal anti-inflammatory drugs (NSAIDs) for aching joints in his hands; he smokes 20 cigarettes per day but is teetotal.

Examination reveals no abnormality except mild ankle oedema. Further blood examinations are outlined below. An ultrasound scan of the liver reveals no abnormalities.

Hb	15.2 g/dl
Urea	7.0 mmol/l
Creatinine	100 μmol/l
Random blood glucose	4.5 mmol/l
Bilirubin	12 μmol/l (1–22)
Aspartate transaminase	10 U/l (1–

Aspartate transaminase (AST)	10 U/l (1–31)
Alanine amino transferase (ALT)	14 U/l (5–35)
Alkaline phosphatase	60 U/l (45–105)
Albumin	45 g/l (37–49)
Serum ferritin	900 µg/l
Transferrin saturation	90%
HBSAg	Negative
HBeAb	Positive
Auto-antibodies	Negative
Prothrombin time (PT)	12 s (11.5–15.5)

Which one of the following would be the most appropriate treatment for him?

A Venesection

Auto-antibodies	Negative
Prothrombin time (PT)	12 s (11.5–15.5)

Which one of the following would be the most appropriate treatment for him?

A	Venesection
B	Penicillamine treatment
C	Desferrioximine treatment
D	Ursodeoxycholic acid
E	Referral for liver transplantation

33004

Submit

A Venesection

The high serum ferritin and transferrin saturation in the absence of biochemical or ultrasonographic evidence of cirrhosis points to a diagnosis of genetic haemochromatosis.
Haemochromatosis is a recessive condition caused by mutations of the *HFE* gene, which can be confirmed by genetic screening. Liver biopsy is not necessary for diagnosis and is only recommended for those patients who have features associated with a high probability of cirrhosis (abnormal alanine aminotransferase, ferritin >1000 μg/l and hepatomegaly). Iron overload affects several organs in the body including the heart, pancreas and pituitary, however only 17% of non-cirrhotic patients will have manifest diabetes at diagnosis. Repeated venesection until iron indices return to normal is the cheapest and most effective treatment.

C Desferrioximine treatment

C Desferrioximine treatment

Desferrioxamine, an iron chelator, is not used for the treatment of haemochromatosis except in rare situations, when venesection is impracticable.

B Penicillamine treatment

Penicillamine is a copper chelator that can be used in the treatment of Wilson's disease, not haemochromatosis.

D Ursodeoxycholic acid

Ursodeoxycholic acid is used in the treatment of primary biliary cirrhosis (PBC), and does not have a role in the management of haemochromatosis.

E Referral for liver transplantation

Liver transplantation is an option for

A 53-year-old woman presents with jaundice and generalised itching. She has been feeling 'washed out' for many months, but has been very busy at home and didn't want to bother the doctor. She has a past history of hypothyroidism for which she takes thyroxine replacement, and she received a blood transfusion some 12 years earlier.

On examination, her BP is mildly elevated at 155/94 mmHg and her BMI is 29. She has xanthelasma and scratch marks consistent with her history of itching. She has jaundiced sclerae.

Investigations:

Hb	12.1 g/dl
WCC	9.2×10^9/l
PLT	201×10^9/l
Na^+	139 mmol/l
K^+	4.9

Creatinine	145 µmol/l
TSH	2.1 U/l
IgM	elevated
ALT	135 U/l
ALK P	425 U/l
Bilirubin	82 µmol/l
Anti-mitochondrial antibodies	positive

Which of the following is the most likely diagnosis?

A Primary sclerosing cholangitis

B Primary biliary cirrhosis

C Autoimmune hepatitis

D Chronic hepatitis B infection

E Pancreatic carcinoma

B Primary biliary cirrhosis

Anti-mitochondrial antibodies are present in 90-95% of patients with primary biliary cirrhosis, and are said to be 98% specific for the disease. The history of chronic fatigue, slowly progressive itching and jaundice is typical of the condition. It is also strongly associated with other autoimmune disorders.
Ursodeoxycholic acid is the medical treatment of choice, although any evidence of effect on treatment progression is somewhat unclear, with no evidence of an effect on mortality seen in clinical studies. Evidence of an effect of immune modifying agents is also mixed, with none showing a definitive effect on disease progression. Inevitably, liver transplant is the late treatment of choice, with up to 16% of patients showing a recurrence of their disease after 5 years.

A Primary sclerosing cholangitis

A Primary sclerosing cholangitis

Primary sclerosing cholangitis may be asymptomatic or patients may complain of itching, fatigue, jaundice or pale/oily stools (steatorrhoea) secondary to malabsorption. It is associated with pANCA, antinuclear antibodies and anti-smooth muscle antibodies. Imaging either by ERCP or MRCP typically shows 'beading' of the bile ducts secondary to strictures.

C Autoimmune hepatitis

Although this condition occurs mainly in females and is associated with the presence of other autoimmune conditions, patients usually have positive antinuclear, anti-smooth muscle and anti-liver kidney microsomal-1 antibodies.

D Chronic hepatitis B infection

This patient has previously received a blood transfusion and therefore could

D	Chronic hepatitis B infection

This patient has previously received a blood transfusion and therefore could potentially have contracted hepatitis B infection. However, the presence of elevated IgM levels and anti-mitochondrial antibodies is not consistent with hepatitis B infection. In chronic hepatitis B infection you would expect to see HBcAg (also present if previous infection), anti-HBc IgG (marker of current or past infection) and HBeAg.

E	Pancreatic carcinoma

Pancreatic carcinoma would usually present with abdominal pain, typically radiating through to the back, weight loss and obstructive jaundice.

21538

Rate this question:

Next Question

A 36-year-old female presents with a 3-week history of anorexia, malaise and nausea. She has now developed some RUQ tenderness. Her past history includes developing Hashimoto's disease after her first pregnancy. Her medication includes thyroxine. She smokes 20 cigarettes/day and drinks anything up to a bottle of wine with her dinner. She is married with two children.

On examination, she is jaundiced and has palmar erythema. She has spider naevi over her upper arms and chest. She has a 3 cm tender liver edge below the right costal margin and a 2 cm splenic edge beneath the left costal margin.

On examination of the peripheral nervous system, there is evidence of decreased sensation to light touch at L5/S1 bilaterally.

Investigations:

ALT	874 u/l
Bilirubin	164 μmol/l

ALT	874 u/l
Bilirubin	164 µmol/l
ALP	235 U/l
Albumin	24 g/l
INR	1.5
Total protein	80 g/l
IgG	30 g/l (6–13)
IgA	2.1 g/l (0.8–3.0)
IgM	4.6 g/l (0.4–2.5)
Anti-smooth muscle antibody titre	1:320

What is the most likely diagnosis?

A	Primary biliary cholangitis
B	Auto-immune hepatitis

IgA	2.1 g/l (0.8–3.0)
IgM	4.6 g/l (0.4–2.5)
Anti-smooth muscle antibody titre	1:320

What is the most likely diagnosis?

A Primary biliary cholangitis

B Auto-immune hepatitis

C Alcoholic liver disease

D Sclerosing cholangitis

E Chronic viral hepatitis

6867

Submit

B Auto-immune hepatitis

Auto-immune hepatitis has an unknown aetiology, although 60% of patients will have an associated condition such as Hashimoto's thyroiditis, keratoconjunctivitis sicca, rheumatoid arthritis, peripheral neuropathy or ulcerative colitis. It can either have a slow onset or present with a rapid history of jaundice, hepatosplenomegaly and deranged liver function, with a low albumin, prolonged INR and evidence of extensive hepatic necrosis.

The hallmark of the diagnosis is liver biopsy. IgG will usually be elevated with a normal IgM and IgA, although some elevation in IgM may be seen. Anti-nuclear antibody (ANA) and anti-smooth muscle are also elevated. Treatment is with high-dose corticosteroids. Azathioprine and occasionally cyclosporin are used as steroid-sparing agents in remission. In end-stage hepatic failure, liver transplantation is the treatment of choice.

The main complaint in PBC is fatigue and pruritus. One would expect to see a more striking rise in ALP and Gamma GT, relative to the aminotransferase levels. The important serological test is anti-mitochondrial antibodies, which are present in 95% of cases.

C	Alcoholic liver disease

This could present similarly to AIH, with chronic elevation of aminotransferases. In addition, the patient in this case does drink in excess of the recommended weekly alcohol intake. However, one would not expect positive autoantibodies.

D	Sclerosing cholangitis

Clinical features of primary sclerosing cholangitis can overlap with autoimmune hepatitis. However, the former is more common in men, particularly those with a history of inflammatory bowel disease. One would also expect to see a markedly

You are asked to review a 78-year-old woman who is recovering from a fractured femoral neck on the Orthopaedic Ward. She was given broad-spectrum intravenous (iv) antibiotics for a large sacral pressure sore and has now developed profuse watery diarrhoea with abdominal cramps and blood. She has a history of multi-infarct dementia and has become progressively more confused after the past 48 h.

On examination, she is pyrexial (38.4 °C), her BP is 100/60 mmHg and pulse is 88/min and regular. Stool is positive for *C. difficile* toxin. She is commenced on an IV infusion.

Which of the following is the most appropriate antibiotic treatment?

A	Amoxycillin
B	Cefotaxime
C	Ciprofloxacin

D Metronidazole

Oral metronidazole is a standard therapy for mild and moderate cases of CDI. Oral vancomycin is used in severe cases, while fidaxomicin is indicated in cases not responding to vancomycin.

CDI is the major identifiable cause of antibiotic-associated diarrhoea, and is responsible for 15–25 % of all cases.

Data from the USA and Europe suggest that the incidence of CDI may have reached a crescendo in recent years and is levelling off or slightly declining. However, the overall incidence has increased to the point of surpassing rates of methicillin-resistant *S. aureus* infections.

Reference : Loo, V.G., Poirier, L., Miller, M.A. et al. (2005). A predominantly clonal multi-institutional outbreak of *Clostridium difficile*-associated diarrhea with high morbidity mortality. *N Engl J Med* 353:2442–9.

1. Antibiotic classes with highest risk

N Engl J Med 353:2442–9.

1. Antibiotic classes with highest risk regarding *C. difficile* (odds ratio 5 or more). Clindamycin carries the highest risk of CDI, with an odds ratio of about 17–20 compared to no antibiotic exposure. Fluoroquinolones, cephalosporins, aztreonam and carbapenems carry a fairly high risk, all being associated with an odds ratio of approximately 5 compared to no antibiotic exposure.
2. Antibiotic classes with moderate risk regarding *C. difficile* (odds ratio 1–5). Macrolides, sulfonamides/trimethoprim and penicillins are associated with a moderate risk of CDI, with odds ratios between about 1.8 and 3.3. Within this group, penicillins are generally associated with a slightly higher risk (odds ratio about 50% higher) compared to macrolides and sulfonamides/trimethoprim.

One study performed by Fred et al. compared the effectiveness of

One study performed by Fred et al. compared the effectiveness of metronidazole and vancomycin, and found the latter more effective in patients with severe *C. difficile*-associated diarrhoea.

Reference: Fred, A., Zar Srinivasa, R., Bakkanagari, K.M., Moorthi and Davis, M.B. (2017). A comparison of vancomycin and metronidazole for the treatment of Clostridium difficile-associated diarrhea, Stratified by disease severity.

A	Amoxycillin

Increased incidence of *C. difficile* infection (CDI) has been attributed to various risk factors, including resistance to fluoroquinolones, use of penicillin and clindamycin, a newly discovered virulent strain of *C. difficile* (B1/NAP1/027) and an elderly patient population. Thus, aSeveral case reports have shown penicillin to be among the major independent factors for development of CDI. Studies by McFarland et al. (1990) and Barbut et

A 52-year-old man with a long-standing history of ulcerative colitis attends the clinic for review. He was also diagnosed with primary sclerosing cholangitis (PSC) some years earlier and his LFTs have been monitored. Recently, he has become severely jaundiced and requested an urgent hospital appointment.

Ultrasound demonstrated ductal dilatation with other areas of stricturing consistent with the PSC. MRI cholangiography demonstrated marked ductal dilatation and a hilar lesion consistent with a cholangiocarcinoma. There was evidence of local lymphatic invasion with enlarged lymph nodes around the porta hepatis.

Which of the following represents the most appropriate management of this case?

A	Referral for chemotherapy
B	Stenting of the lesion

stricturing consistent with the PSC. MRI cholangiography demonstrated marked ductal dilatation and a hilar lesion consistent with a cholangiocarcinoma. There was evidence of local lymphatic invasion with enlarged lymph nodes around the porta hepatis.

Which of the following represents the most appropriate management of this case?

A	Referral for chemotherapy
B	Stenting of the lesion
C	Referral for lobectomy
D	Referral for liver transplantation
E	Referral for Whipple's procedure

A 52-year-old man with a long-standing history of ulcerative colitis attends the clinic for review. He was also diagnosed with primary sclerosing cholangitis (PSC) some years earlier and his LFTs have been monitored. Recently, he has become severely jaundiced and requested an urgent hospital appointment.

Ultrasound demonstrated ductal dilatation with other areas of stricturing consistent with the PSC. MRI cholangiography demonstrated marked ductal dilatation and a hilar lesion consistent with a cholangiocarcinoma. There was evidence of local lymphatic invasion with enlarged lymph nodes around the porta hepatis.

Which of the following represents the most appropriate management of this case?

Your answer was incorrect

A 52-year-old man with a long-standing history of ulcerative colitis attends the clinic for review. He was also diagnosed with primary sclerosing cholangitis (PSC) some years earlier and his LFTs have been monitored. Recently, he has become severely jaundiced and requested an urgent hospital appointment.

Ultrasound demonstrated ductal dilatation with other areas of stricturing consistent with the PSC. MRI cholangiography demonstrated marked ductal dilatation and a hilar lesion consistent with a cholangiocarcinoma. There was evidence of local lymphatic invasion with enlarged lymph nodes around the porta hepatis.

Which of the following represents the most appropriate management of this case?

Your answer was incorrect

Explanation

B	Stenting of the lesion

There is evidence from the MRI scan that this patient has cholangiocarcinoma with local invasion. As such, attempted surgical removal is likely to be unsuccessful. For this reason the treatment of choice is stenting via ERCP. The procedure is successful at relieving symptoms of jaundice and may also relieve associated lethargy and fatigue. Most patients with severe PSC are surveyed for the possible development of cholangiocarcinoma and are recommended for liver transplantation before this occurs. Stent replacement may be required every 3–6 months, and adjuvant radiotherapy post stent placement may prolong survival for as long as 17 months. Resectable lesions are associated with a 5-year survival as high as 40%.

D	Referral for liver

By the time local invasion has occurred, liver transplantation isn't an option. Where lesions are resectable, however, 5-year survival may be as high as 40%. Transplantation is the aim for severe disease before cancer develops.

A	Referral for chemotherapy

5-FU and cisplatin are commonly used agents for cholangiocarcinoma, their effects are however limited, meaning that chemotherapy isn't the preferred option.

C	Referral for lobectomy

Local lymph node invasion has already occurred hence lobectomy isn't an option for treatment here. In any case lobectomy risks a new focus of cancer developing in the unresected portion of the liver.

E	Referral for Whipple's

A 55-year-old man attended the Emergency Department with haematemesis 30 min previously. He is visiting the UK from Africa, but had been well prior to presentation.

On arrival, he was shocked and pale and therefore underwent upper gastrointestinal endoscopy after adequate resuscitation.

Investigations:

Hb	6.6 g/dl
MCV	65 fl
WCC	6.0×10^9/l
PLT	87×10^9/l
Albumin	40 g/l
Bilirubin	5 μmol/l
AST	12 U/l
ALT	12 U/l
ALP	66 U/l
INR	1.0

ALP	66 U/l
INR	1.0

Examination of the oesophagus revealed two large varices with stigmata of recent bleeding. No blood was seen but two red worms, about 10 mm in length, were noted adherent to the mucosa in the duodenum.

Which of the following is he most likely to be infected with?

A	*Trichuris trichiura*
B	*Schistosoma haematobium*
C	*Strongyloides stercoralis*
D	*Enterobius vermicularis*
E	*Necator americanus*

8:05
Ringtone

Although part of the explanation for this man's anaemia may be his haemorrhage, GI haemorrhage does not typically cause haemodilution this quickly, and his very marked microcytosis also implies that another factor is contributing to this. The presence of worms is the probable explanation here; the commonest cause of iron-deficiency anaemia worldwide being hookworm infection (*N. americanus* and *Ancylostoma duodenale*), which affects 25% of the global population. Mebendazole or albendazole is the treatment of choice.

B	*Schistosoma haematobium*

S. haematobium affects the urinary tract rather than the liver and GI tract. Treatment is with praziquantel.

A	*Trichuris trichiura*

T. trichiura infests the distal ileum and

E *Necator americanus*

Although part of the explanation for this man's anaemia may be his haemorrhage, GI haemorrhage does not typically cause haemodilution this quickly, and his very marked microcytosis also implies that another factor is contributing to this. The presence of worms is the probable explanation here; the commonest cause of iron-deficiency anaemia worldwide being hookworm infection (*N. americanus* and *Ancylostoma duodenale*), which affects 25% of the global population. Mebendazole or albendazole is the treatment of choice.

B *Schistosoma haematobium*

S. haematobium affects the urinary tract rather than the liver and GI tract. Treatment is with praziquantel.

A *Trichuris trichiura*

T. trichiura infests the distal ileum and

S. haematobium affects the urinary tract rather than the liver and GI tract. Treatment is with praziquantel.

A *Trichuris trichiura*

T. trichiura infests the distal ileum and colon, and with heavy infestation may cause diarrhoea and GI bleeding.

C *Strongyloides stercoralis*

S. stercoralis is not visible to the naked eye, and may cause malabsorption.

D *Enterobius vermicularis*

E. vermicularis lives in the colon, is more common in temperate climates and may cause pruritus ani.

70165

Rate this question:

Next Question

A 43-year-old medical secretary with dermatomyositis is referred from the dermatologist with a short history of dysphagia. She has been using the food processor to liquidise her solid food but now find fluids increasingly difficult, too. The pain is worse in the throat at the beginning of each meal and eases with each mouthful.

She has no previous history of dyspepsia. She is a long-term heavy smoker and drinks socially. Her mother had a gastrectomy for peptic ulcer disease. She now wakes up at night very breathless. She finds eating very distressing and feels that she has lost weight.

Investigations:

Hb	9.0 g/dl
WCC	8.5×10^9/l
PLT	199×10^9/l
Na^+	138 mmol/l
K^+	3.9 mmol/l
Creatinine	95 umol/l

PLT	199×10^9/l
Na^+	138 mmol/l
K^+	3.9 mmol/l
Creatinine	95 μmol/l
ESR	78 mm/1st h

Which of the following is the most likely diagnosis?

A Oesophageal carcinoma

B Systemic sclerosis

C Benign peptic stricture

D Tracheo-oesophageal fistula

E Bronchial carcinoma with oesophageal metastases

A Oesophageal carcinoma

The history of rapid progression from solid to liquid dysphagia is suggestive of a malignant oesophageal lesion, which like bronchial carcinoma is associated with dermatomyositis. In order to confirm the diagnosis of oesophageal malignancy, a histology sample is required. Once diagnosis is confirmed, a computed tomography scan is necessary to assess for disease extent to consider surgical resectability. The following are risk factors for oesophageal carcinoma: male sex, heavy smoking, Barrett's oesophagus, achalasia, coeliac disease, and tylosis pylori (autosomal dominant, hyperkeratosis of the palms and soles).

E Bronchial carcinoma with oesophageal metastases

In this situation more marked respiratory symptoms would be expected with a bronchial carcinoma

respiratory symptoms would be expected with a bronchial carcinoma than those seen here (which are likely to be associated to muscle weakness).

B Systemic sclerosis

Oesophageal involvement occurs in 90% of those with systemic sclerosis, and symptoms are usually of heartburn or acid regurgitation (due to failure of the gastro-oesophageal physiological sphincter to close).

C Benign peptic stricture

Benign oesophageal stricture is often associated with mixed dysphagia to liquids and solids, and isn't associated with as much weight loss as a malignant lesion.

D Tracheo-oesophageal fistula

A tracheo-oesophageal fistula presents with recurrent symptoms of aspiration, rather than the picture seen here.

An 18-year-old male student presents to his general practitioner (GP) with a 6-day history of sore throat, fever and flu-like symptoms. He has been unable to eat for the past few days and is concerned because his sclerae have turned yellow. He says that he's been yellow on a couple of previous occasions but recovered with no particular problems.

On examination, he is jaundiced. Serum bilirubin is 62 μmol/l; aspartate transaminase (AST) and alkaline phosphatase (ALP) are within the normal range, his full blood count is normal.

Which of the following is the best intervention for this patient?

A	Hepatitis C antibody testing
B	Monospot test
C	Reassurance and repeat liver function testing in 2 weeks

occasions but recovered with no particular problems.

On examination, he is jaundiced. Serum bilirubin is 62 μmol/l; aspartate transaminase (AST) and alkaline phosphatase (ALP) are within the normal range, his full blood count is normal.

Which of the following is the best intervention for this patient?

A	Hepatitis C antibody testing
B	Monospot test
C	Reassurance and repeat liver function testing in 2 weeks
D	Haemolysis screen
E	Hepatitis A antibody testing

C Reassurance and repeat liver function testing in 2 weeks

The most likely diagnosis here is Gilbert syndrome. It is due to a deficiency of UDP-glucuronosyl transferase that is responsible for the conjugation of bilirubin. It affects 2–7% of the population. Jaundice is exacerbated by periods of fasting which occur in conjunction with illness, and it is also exacerbated by oestrogens and is improved by low-dose barbiturate therapy. In this case the student should be reassured that retesting in 2 weeks is likely to show that bilirubin has returned to the normal range.

A Hepatitis C antibody testing

We are given no indication that this patient has indulged in behaviour likely to lead to hepatitis C exposure, and the typical picture with an elevation in transaminases and alkaline phosphatase isn't seen here.

B Monospot test

Monospot testing is the diagnostic test for Epstein–Barr virus, which presents with pharyngitis and evidence of viral hepatitis (with abnormal transaminases), rather than the isolated rise in bilirubin seen here.

D Haemolysis screen

Although bilirubin is elevated, haemoglobin is normal, which counts against underlying haemolysis being the cause.

E Hepatitis A antibody testing

Hepatitis A is associated with a flu-like illness followed by a raise in transaminases, accompanied by symptoms of nausea and anorexia, rather than the isolated increase in bilirubin seen here.

13485

Rate this question:

A 20-year-old man presents to the gastroenterology clinic complaining of vague abdominal pain, he tells you that he has also occasional bouts of diarrhoea. He has no previous medical history of note and takes no medication. Apparently, his cousin has been treated for depression and symptoms consistent with Parkinson's disease from the age of 28 years.

On examination, you notice a mild tremor and early problems with co-ordination consistent with Parkinson's.

Investigations:

Hb	10.2 g/dl
MCV	106 fl
WCC	5.6×10^9/l
PLT	200×10^9/l
Na^+	140 mmol/l
K^+	4.9 mmol/l
ALT	235 U/l
Bilirubin	67 μmol/l

Na^+	140 mmol/l
K^+	4.9 mmol/l
ALT	235 U/l
Bilirubin	67 μmol/l
Albumin	32 g/l

Given the probable diagnosis, which treatment is he likely to require?

A L-dopa

B Prednisolone

C Zinc acetate

D Penicillamine

E Cyclosporin

20532

Submit

D Penicillamine

This patient has evidence of early signs of Parkinson's, a macrocytic anaemia which may be haemolytic, and a raised ALT. We are also told that his cousin developed symptoms of depression and Parkinson's, which may be a pointer to an inherited condition. Putting these symptoms together, the suggestion is that he may have Wilson's disease. Laboratory tests to further suggest the diagnosis would include low serum copper and caeruloplasmin, and increased urinary copper excretion. Penicillamine leads to copper chelation and is the default treatment for Wilson's; zinc acetate is used in some patients, particularly where symptoms are yet to develop, although it may promote decompensation in patients with significant hepatic disease.

A L-dopa

L-dopa is effective as a symptomatic

L-dopa is effective as a symptomatic treatment for Parkinson's disease, but given copper accumulation is the underlying cause, it isn't the optimal intervention here.

B Prednisolone

Prednisolone is an effective intervention for autoimmune hepatitis, but won't prevent accumulation of copper here and is therefore not appropriate.

C Zinc acetate

Zinc acetate is most effective for early Wilson's disease, but in later-stage disease it may precipitate hepatic decompensation.

E Cyclosporin

Cyclosporin is a second-line, steroid-sparing agent for the treatment of autoimmune hepatitis.

A 74-year-old woman presents with a 4-month history of colicky abdominal pain after eating, and diarrhoea. Over the past few days, this pain has got much worse and she has a dull ache across her abdomen most of the time now. She has lost 6 kg in weight over the last few months.

A recent gastroscopy and colonoscopy were normal. Her past medical history includes angina and a right carotid endarterectomy at the age of 62 years. Her current medication includes aspirin, atenolol, simvastatin and losartan.

Blood tests revealed:

Hb	118 g/l
MCV	80 fl
WCC	12.3×10^9/l
Platelets	210×10^9/l
Na^+	133 mmol/l
K^+	5.2 mmol/l
Urea	8.1 mmol/l

Platelets	210×10^9/l
Na^+	133 mmol/l
K^+	5.2 mmol/l
Urea	8.1 mmol/l
Creatinine	134 mmol/l

Which of the following investigations is most likely to point towards the underlying diagnosis?

A	Gastroscopy
B	Contrast CT of the abdomen with angiography
C	Mesenteric Doppler ultrasound
D	Colonoscopy
E	Barium enema

B Contrast CT of the abdomen with angiography

The diagnosis here is ischaemic colitis, which is mainly seen in the older age group and is caused by atheroma of the mesenteric vessels. It typically affects the watershed areas of the bowel at the splenic flexure and rectosigmoid junction. The radiological features of ischaemic colitis are non-specific. Plain X-ray is often normal, although mucosal oedema and 'thumb printing' may be evident, making it a useful investigation for differentiating from other causes of an acute abdomen. This would be done prior to progression to CT. Computed tomography (CT) is a valuable non-invasive tool for the diagnosis of intestinal ischaemia providing information about both the bowel wall and mesenteric blood supply. One caveat here would be the use of contrast media in view of the patient's mildly elevated creatinine; weighing the pros and cons of the procedure should be carried out in collaboration

with radiology colleagues with discussion as to whether protective measures such as pre-hydration are necessary. In her case the diagnostic advantages of the procedure would be likely to outweigh the risk. (See guidelines, European Society of Urogenital Radiology for further information). Other investigations that may be useful include mesenteric Doppler ultrasound and barium enema. ECG would of course be part of the pre-operative assessment as she has significant pre-existing vascular pathology.

A	Gastroscopy

Although this patient does have abdominal pain, the pain associated with gastric ulceration would usually be relieved by eating, making that less likely as the underlying cause.

C	Mesenteric Doppler ultrasound

be relieved by eating, making that less likely as the underlying cause.

C	Mesenteric Doppler ultrasound

Although doppler may indicate reduced blood flow, it won't demonstrate physical evidence of colitis, unlike a CT scan.

D	Colonoscopy

Given that a recent colonoscopy was reported as normal there seems little value in repeating it.

E	Barium enema

Barium enema is most useful in diagnosing a large adenoma or underlying carcinoma, and given the recent normal colonoscopy, it is unlikely to add further information.

33037

Rate this question:

B Whipple's disease

Whipple's disease is a rare, multi-system disease which typically affects middle-aged men and is caused by the bacterium *Tropheryma whippleii*. Other clinical features include cardiac involvement (pericarditis, endocarditis, conduction defects), pulmonary involvement (pleurisy, lung infiltrates) and other neurological features including fits, myoclonus and cranial nerve lesions. The diagnosis is made histologically, with periodic acid–Schiff-positive (PAS) macrophages found in the small intestinal mucosa. Electron microscopy may reveal widened, flattened villi with small, Gram-positive bacilli seen within the macrophages. The disease is fatal if untreated, but there is usually a good response to antibiotic therapy (penicillin, tetracycline or sulphonamides). Relapse occurs in 30% of patients and therefore long-term follow-up is essential. The main differential diagnosis in this case is coeliac disease, but the cerebellar

differential diagnosis in this case is coeliac disease, but the cerebellar signs, skin pigmentation, lymphadenopathy and absence of macrocytosis point more towards Whipple's disease.

A	Carcinoid syndrome

Carcinoid syndrome is associated with episodes of flushing and marked diarrhoea, rather than the discomfort, bloating and diarrhoea seen here. More marked anaemia and abnormal LFTs due to hepatic metastases would be expected.

C	Pancreatic carcinoma with brain metastases

More marked weight loss with a rapid deterioration, epigastric pain radiating to the back, and obstructive jaundice would be expected in pancreatic carcinoma.

D	Coeliac disease

Coeliac disease is the main differential, but the cerebellar signs, increased skin pigmentation and absence of anaemia are better pointers to Whipple's disease.

E	Haemochromatosis

Haemochromatosis is associated with abnormal liver function tests and progressive cirrhosis, diabetes, erectile dysfunction and increased skin pigmentation. It isn't associated with the symptoms of diarrhoea and bloating seen here.

6740

Rate this question:

Difficulty: Average

A 44-year-old woman attends the Emergency Department complaining of shortness of breath and tiredness. She had recently started oral treatment for an intensely itchy, vesicular rash on the elbows, knees, buttocks and back. She also gives a history of mild diarrhoea and abdominal bloating, and has lost a stone in weight.

Investigations:

Hb	56 g/l
MCV	90 fl
WCC	5.8×10^9/l
PLT	387×10^9/l
Red cell distribution width	22%
Na^+	138 mmol/l
K^+	4.4 mmol/l
	4.4

Urea	4.4 mmol/l
Creatinine	99 μmol/l
Albumin	32 g/l
Corrected calcium	2.0 mmol/l
Bilirubin	25 μmol/ll

Which of the following is most likely to be contributing to her anaemia?

A Autoimmune haemolysis

B Iron deficiency due to malabsorption

C Vitamin B_{12} deficiency

D Anaemia of chronic disease

E Gastrointestinal blood loss

B Iron deficiency due to malabsorption

The constellation of anaemia, weight loss, diarrhoea and bloating – together with a pruritic rash on extensor surfaces – is highly-suggestive of this woman having coeliac disease and dermatitis herpetiformis.

Coeliac disease may present in various ways, but iron deficiency anaemia is not an infrequent presentation. Folate deficiency may also occur in the condition; B_{12} deficiency, in contrast, is less common, as this vitamin is absorbed in the terminal ileum. Hypocalcaemia may also occur, due to malabsorption of calcium and vitamin D. Dermatitis herpetiformis is an intensely pruritic, vesicular rash that typically affects the elbows, scalp, extensor surfaces of the forearms and buttocks. It is more common in males and may occur at any age, although it tends to present in young adulthood. It is normally – if not exclusively – associated with gluten-sensitive

Treatment of dermatitis herpetiformis includes strict adherence to a gluten-free diet. Dapsone may be effective in controlling the rash, but is often associated with a mild, dose-related haemolytic anaemia. Haemolysis can, however, be dramatic in people with G6PD deficiency. Monitoring of liver function tests and a full blood count is advised, as Dapsone may also rarely cause liver dysfunction and aplastic anaemia. Drug treatment can often be withdrawn after a period of adherence to a gluten-free diet.

A Autoimmune haemolysis

Although it may not be definitively ruled out based on the information given, based upon the clinical scenario it is not the most likely cause here.

C Vitamin B_{12} deficiency

Although it may not be definitively ruled out based on the information given, based upon the clinical scenario

it is not the most likely cause here.

C Vitamin B_{12} deficiency

Although it may not be definitively ruled out based on the information given, based upon the clinical scenario it is not the most likely cause here.

D Anaemia of chronic disease

Although it may not be definitively ruled out based on the information given, based upon the clinical scenario it is not the most likely cause here.

E Gastrointestinal blood loss

Although it may not be definitively ruled out based on the information given, based upon the clinical scenario it is not the most likely cause here.

70170

Rate this question:

Next Question

A 42-year-old woman comes to the clinic complaining of chronic diarrhoea. She underwent an extensive small bowel resection for Crohn's disease 2 years earlier and has not been well since.

On examination, she has a BMI of 17, with multiple scars on the abdomen. Additionally she is suffering from dermatitis, glossitis and angular stomatitis.

Investigations:

Hb	10.4 g/dl (MCV 106 fl)
WCC	5.6×10^9/l
PLT	232×10^9/l
ESR	12 mm/hr
Na^+	139 mmol/l
K^+	3.9 mmol/l
Creatinine	100 μmol/l
Albumin	29 g/l
ALT	52 U/l

Albumin	29 g/l
ALT	52 U/l
MCV	106 fl

Which of the following is the most likely diagnosis?

A	Reactivated Crohn's disease
B	Coeliac disease
C	Short bowel syndrome
D	Bacterial overgrowth
E	Cryptosporidium infection

20596

Submit

C Short bowel syndrome

Short bowel syndrome has many causes, but in adult patients it is usually the result of extensive surgery undertaken for either Crohn's disease or mesenteric infarction. We can see from the patient's blood results that she has a macrocytic anaemia, likely indicating a failure to absorb B_{12}. Her low albumin of 29 also suggests significant malabsorption. Dermatitis is a feature of failure to absorb essential fatty acids (linoleic acid and linolenic acid). These patients also commonly exhibit dehydration and signs of hypovolaemia due to extensive gastrointestinal fluid losses. In some individuals adequate oral intake may be impossible; parenteral nutrition may be the only option, but is associated with significant long-term morbidity and mortality.

A Reactivated Crohn's disease

The fact that the patient has a low ESR

The fact that the patient has a low ESR level makes a diagnosis of active inflammation unlikely. The chronicity of her symptoms going back 2 years also makes an exacerbation of her Crohn's less likely as the answer here.

B	Coeliac disease

Coeliac disease more often presents with generalised symptoms of tiredness, weight loss and iron deficiency anaemia, though it can present with features of florid malabsorption in severe cases. However, given that we already know that this patient has had an extensive small bowel resection, that represents a far more likely explanation for her clinical picture.

D	Bacterial overgrowth

Bacterial overgrowth tends to present with chronic diarrhoea and/or steatorrhoea with anaemia. Given that both Crohn's disease and extensive

steatorrhoea with anaemia. Given that both Crohn's disease and extensive small bowel resection can predispose to the condition, it should certainly be considered in this case. However, the fact that the patient has evidence of chronic malabsorption is more easily explained by a loss of surface area for digestion and absorption caused by short bowel syndrome.

E	Cryptosporidium infection

Cryptosporidium is a protozoal parasite and generally causes a short illness with voluminous watery diarrhoea and abdominal cramps. The exception is in severely immunocompromised patients such as those with AIDS, where it can develop into a serious chronic condition with persistent severe diarrhoea and weight loss. We are given nothing in the history to suggest that degree of severe immunocompromise in this patient.

20596

Rate this question:

B He should start antibiotics if his condition persists for >3 days

This patient is most likely suffering from traveller's diarrhoea, which is usually caused by either enterotoxigenic escherichia coli, shigella species, campylobacter jejuni or rotavirus. Antibiotics are used for traveller's diarrhoea with significant symptoms (persistence of symptoms for more than 3 days or diarrhoea of more than 6 times/day. Drug of choice is ciprofloxacin 500 mg bid for 1–3 days.

A He should have started antibiotics on Day 1 of the illness

Most episodes of diarrhoea are brief and self-limited or can be treated with non-antimicrobial medications, eg loperamide. Thus, it is not essential to start antibiotics on day 1 of the illness.

Antibiotics can be started if there is significant diarrhoea for more than 3 days or frequent diarrheal episodes of more than 6. Thus this option is incorrect as ten episodes of diarrhoea is *NOT THE ONLY* indication of starting the antibiotics.

D	He should start antibiotics if he has swallowed water from the local river

This option is not an indication for starting antibiotics, as it depends on frequency of diarrhoea and chronicity of symptoms, which determine the start of antibiotics. However, antibiotics can be given prophylactically if a person is travelling to endemic areas.

E	He should start antibiotics if there is fresh blood when he wipes himself clean

There is a need for further evaluation

A patient with known ulcerative colitis (UC) presents with an exacerbation. He has eight bloody motions per day. He has had weight loss of 3 kg in one week. He has had a temperature of 38 °C, pulse rate 100 bpm and blood pressure 100 mmHg systolic for three consecutive days. His abdomen is soft and he has active bowel sounds, and there is significant tenderness, particularly on the left-hand side.

His blood tests show the following:

pH	7.31
Hb	10 g/dL
Albumin	33 g/dl
Potassium	3.0 mmol/l

Which of these clinical findings below would classify this as a severe exacerbation, as defined by the guidelines of the European Society of Gastroenterology?

A	Albumin

Hb	10 g/dL
Albumin	33 g/dl
Potassium	3.0 mmol/l

Which of these clinical findings below would classify this as a severe exacerbation, as defined by the guidelines of the European Society of Gastroenterology?

A	Albumin
B	Number of bloody stools in one day
C	Blood pressure
D	Potassium
E	Weight loss

B Number of bloody stools in one day

Bloody diarrhea is a hallmark for ulcerative colitis. Patient should be asked about stool frequency, urgency and tenesmus. Patients with severe disease have more than six bloody bowel movements per day, which can lead to hypovolemia and severe anaemia. Out of all the options, number of bloody stools per day is one of the criteria of classifying the disease activity as severe. Stool frequency of <4 and 4-6 fall under mild and moderate disease, respectively.

A Albumin

Patients with moderate or severe ulcerative colitis develop hypoalbuminemia with an albumin levels of 30-35 g/l and <30 g/l , respectively. Albumin levels of 33g/l which falls under moderate disease activity. In mild disease, albumin levels remain normal.

In Patients with ulcerative colitis, Volume status is regularly assessed by focusing on orthostatic blood pressure, pulse measurement and nutritional status. However, blood pressure value is not a part of a criteria for severity of disease activity.

D Potassium

Hypokalaemia is very common finding in patients with ulcerative colitis as seen in this patient. But it is not useful to classify the disease activity.

E Weight loss

Patients with ulcerative colitis can show significant weight loss, depending upon level of impairment of nutrition due to frequent diarrheal episodes. However, this option does not all under the criteria for severe ulcerative colitis according to the guidelines of the European Society of Gastroenterology.

A 50-year-old female Chinese patient who has recently moved to the UK presents with chronic diarrhoea. Her family report that she has worsening memory loss, depression and on direct questioning admits to insomnia.

On examination, you find dermatitis, tremor and ataxia. She has a normal full blood count, renal function, liver function and bone profile in her blood results. You are concerned she may have a nutritional deficiency.

Which vitamin is she most likely to be deficient in?

A	Vitamin A
B	Vitamin C
C	Vitamin B_{12}
D	Vitamin B_1
E	Nicotinic acid

E Nicotinic acid

Deficiency in nicotinic acid (niacin) can cause pellagra, which presents with the triad of dermatitis, diarrhoea and dementia. It can also present with additional features of tremor, ataxia, insomnia, fits and neuropathy. It most commonly presents in China and Africa and can be a side effect of tuberculosis (TB) treatment and carcinoid syndrome.

D Vitamin B_1

Thiamine (vitamin B_1) deficiency can cause wet beriberi (heart failure, peripheral oedema) or dry beriberi (neuropathy).

A Vitamin A

Vitamin A deficiency causes xerophthalmia, which is a major cause of blindness in the tropics.

A Vitamin A

Vitamin A deficiency causes xerophthalmia, which is a major cause of blindness in the tropics.

B Vitamin C

Vitamin C can cause scurvy, which results in infections, anorexia, hyperkeratosis, bleeding tendency and halitosis.

C Vitamin B_{12}

Vitamin B_{12} deficiency results in megaloblastic anaemia and can lead to neuropathy and neuropsychiatric problems. As the patient has a normal full blood count it is unlikely that her symptoms are related to B_{12} deficiency.

6852

Rate this question:

Next Question

A 17-year-old girl is referred to hospital for investigation of her short stature. She has had intermittent episodes of abdominal pain and diarrhoea over the last 2 years, which have settled. Her general practitioner has previously diagnosed gastroenteritis. She also complains of recent-onset hip pain that is affecting her walking, and she has missed college on a few occasions.

She takes occasional ibuprofen and does not smoke. Her grandmother is under surveillance for colonic polyps.

On examination, she is pale. There is no lymphadenopathy. She has generalised abdominal tenderness, but there is no organomegaly.

Investigations:

Hb	8.4 g/dl
WCC	3.1×10^9/l
PLT	80×10^9/l
MCV	110 fl
ESR	84 mm/1st h

ESR	84 mm/1st h

Biochemistry is normal. She subsequently underwent a barium follow-through and a bone marrow aspirate, which shows a megaloblastic picture.

The radiologist commented on the 'Kantor's string sign' seen on the barium meal and follow-through.

What is the most likely diagnosis?

A	Peutz–Jeghers syndrome (PJS)
B	Jejunal diverticulosis
C	Pneumatosis coli
D	Small bowel Crohn's disease
E	Familial adenomatosis polypoisis

Investigations:

Hb	8.4 g/dl
WCC	3.1×10^9/l
PLT	80×10^9/l
MCV	110 fl
ESR	84 mm/1st h

Biochemistry is normal. She subsequently underwent a barium follow-through and a bone marrow aspirate, which shows a megaloblastic picture.

The radiologist commented on the 'Kantor's string sign' seen on the barium meal and follow-through.

What is the most likely diagnosis?

Your answer was incorrect

A	Peutz–Jeghers syndrome (PJS)
B	Jejunal diverticulosis

100% 10:42
tps://mypastest.pastest.com

Explanation

D	Small bowel Crohn's disease

Barium meal and follow-through in Crohn's disease may show thickening of the valvulae conniventes and narrow stricture at the distal end of the terminal ileum, which represents the string sign (of Kantor). These radiological signs are pathognomonic for Crohn's disease. A plain abdominal radiograph may be useful in active disease as it may show mucosal oedema ('thumb-printing'), loss of haustrations (colonic Crohn's) and sacroiliitis. Her hip pain may be secondary to sacroiliitis. The bone marrow appearances are those of megaloblastic anaemia. The nucleated red cells show an open nuclear chromatic pattern. The likeliest cause of megaloblastic anaemia in Crohn's disease is malabsorption of vitamin B_{12} due to disease of the terminal ileum.

B Jejunal diverticulosis

Jejunal diverticulosis is much rarer than colonic diverticular disease, and isn't associated with the inflammatory picture and megaloblastic anaemia seen here.

A Peutz–Jeghers syndrome (PJS)

PJS is an autosomal dominant genetic disorder characterised by the development of benign hamartomatous polyps in the gastrointestinal tract and hyperpigmented macules on the lips and oral mucosa, which doesn't fit with the evidence of inflammation seen here.

C Pneumatosis coli

Pneumatosis coli is a benign condition with multiple, gas-filled submucosal cysts in the colon, commonly associated with chronic obstructive

hamartomatous polyps in the gastrointestinal tract and hyperpigmented macules on the lips and oral mucosa, which doesn't fit with the evidence of inflammation seen here.

C	Pneumatosis coli

Pneumatosis coli is a benign condition with multiple, gas-filled submucosal cysts in the colon, commonly associated with chronic obstructive airway disease.

E	Familial adenomatosis polypoisis

Familial adenomatous polyposis results in the development of multiple colonic polyps, with associated increased risk of colonic carcinoma.

8480

Rate this question:

A Coeliac disease

The combination of diarrhoea, malabsorption and family history of two T-cell mediated autoimmune disorders, (Type 1 diabetes and Hashimoto's disease) points towards coeliac disease or pernicious anaemia. However, pernicious anaemia does not usually present with intermittent diarrhoea. Although coeliac disease traditionally presents with iron deficiency anaemia, both folate and B12 deficiency are also commonly reported. The presence of an itchy rash on the arms and trunk is suggestive of dermatitis herpetiformis, which is strongly associated with coeliac disease and makes this the most likely answer.

The next line of investigation would involve testing for coeliac antibodies (anti TTG or endomysial) followed by a duodenal biopsy, which should demonstrate increased intraepithelial lymphocytes and villous atrophy.

For more information see BSG

B Crohn's disease

The history of diarrhoea and malabsorption mean this would be on the differential, particularly in the presence of classical terminal ileal involvement leading to B12 malabsorption. However, the description of dermatitis herpetiformis points towards coeliac as the more likely diagnosis. Cutaneous manifestations of Crohn's include erythema nodosum and pyoderma gangrenosum.

C Hypothyroidism

Hypothyroidism would more commonly present with constipation and weight gain. Although hypothyroidism can cause a macrocytic anaemia, in this case it seems more likely to be secondary to malabsorption due to coeliac disease.

D Pernicious anaemia

100% 10:47
tps://mypastest.pastest.com

Pernicious anaemia occurs as a result of intrinsic factor deficiency. Intrinsic factor is produced by the parietal cells in the stomach and pernicious anaemia is commonly seen in autoimmune and atrophic gastritis. Pernicious anaemia does not present with diarrhoea or dermatitis herpetiformis.

E	Blind loop syndrome

More commonly referred to as small bowel intestinal overgrowth this can indeed lead to malabsorptive diarrhoea, vitamin B12 deficiency and unintentional weight loss. However, patients tend to have a predisposing reason for the overgrowth (for example previous bowel surgery, inflammatory bowel disease, small bowel diverticulae or scleroderma), none of which are reported in this case.

21503

Rate this question:

A 27-year-old woman recently diagnosed with inflammatory bowel disease attends the Emergency Department with severe upper abdominal pain. She also has epilepsy which is difficult to control, requiring recent manipulation of her drug therapy.

On examination, she is tachycardic (110 bpm), hypotensive (95/55 mmHg) and has marked epigastric tenderness.

Investigations:

Hb	8.6 g/dl
MCV	85 fl
WCC	13.0×10^9/l
PLT	387×10^9/l
Na^+	137 mmol/l
K^+	4.5 mmol/l
Urea	5.4 mmol/l
Creatinine	98 μmol/l
Corrected calcium	2.1 mmol/l
[illegible]	[illegible]

K^+	4.5 mmol/l
Urea	5.4 mmol/l
Creatinine	98 μmol/l
Corrected calcium	2.1 mmol/l
Amylase	1635 U/l

Which of the following drugs that she is taking is unlikely to be the cause of her acute presentation?

A 6-Mercaptopurine

B Clonazepam

C Prednisolone

D 5-Aminosalicylic acid

E Sodium valproate

B Clonazepam

This patient has acute pancreatitis. Clonazepam has only very rarely been documented as a cause of acute pancreatitis.

Drugs known to cause pancreatitis (other than those mentioned in the other options for the question) include Azathioprine, Furosemide, thiazides, tetracyclines, oestrogens and sulphonamides. Serum amylase levels of more than three times the upper limit of normal are highly suggestive of acute pancreatitis, and there is also a role for serum lipase in diagnosis.

Different prognostic scoring systems for acute pancreatitis exist, with one such scoring system (the Modified Glasgow Criteria, validated for both gallstone and alcohol-related acute pancreatitis) identifying the following criteria as predicting a poor prognosis when present within the first 48 hours of admission:

- Age > 55 years
- Blood glucose > 10mmol/l
- Neutrophil count > 15.0 x 10^9/l
- Urea > 16mmol/l
- Albumin < 32g/l
- AST > 200 U/l, LDH > 600 IU/l
- Calcium < 2.0mmol/l
- PO_2 < 8.0kPa

By the modified Glasgow criteria, the presence of three or more of these criteria represents severe acute pancreatitis, and identifies those people likely to need critical care support. Others have recommended CRP as a useful marker of severity, describing a peak CRP of > 210 mg/l in the first four days after the onset of pancreatitis (or > 120 mg/l at the end of the first week) as indicative of a severe attack. Identification of acute severe pancreatitis is important as the condition is often complicated by multiple organ failure, and may be associated with mortality rates as high as 30%.

as 30%.

A 6-Mercaptopurine

6-Mercaptopurine is a known cause of pancreatitis.

C Prednisolone

Prednisolone is a known cause of pancreatitis.

D 5-Aminosalicylic acid

5-Aminosalicylic acid is a known cause of pancreatitis.

E Sodium valproate

Sodium valproate is a known cause of pancreatitis.

70157

Rate this question:

Next Question

A 54-year-old businessman presents with a 12-month history of intermittent lower back and right knee pain and diarrhoea. He has previously undergone investigations for diarrhoea, when a gastroscopy and colonoscopy performed 8 months ago revealed a small area of non-specific inflammation in the ascending colon, but investigations were otherwise normal.

He has lost approximately 3 kg in weight over the last 18 months. He takes no regular medication, drinks occasional alcohol and smokes 10 cigarettes per day.

Cardiovascular and abdominal examination is unremarkable. Examination of his spine reveals tenderness over the sacroiliac joints but no restriction in movement. He has a small right knee effusion.

Investigations:

Haemoglobin (Hb)	120 g/l
Mean corpuscular volume (MCV)	108 fl

Haemoglobin (Hb)	120 g/l
Mean corpuscular volume (MCV)	108 fl
White cell count (WCC)	5.6×10^9/l
Platelets	206×10^9/l
Erythrocyte sedimentation rate (ESR)	38 mm/h
Sodium	136 mmol/l
Potassium	3.8 mmol/l
Urea	5.3 mmol/l
Creatinine	84 mmol/l
Albumin	40 g/l
Bilirubin	12 μmol/l

What is the most likely diagnosis?

Urea	5.3 mmol/l
Creatinine	84 mmol/l
Albumin	40 g/l
Bilirubin	12 µmol/l

What is the most likely diagnosis?

A	Chronic pancreatitis
B	Coeliac disease
C	Whipple's disease
D	Increased plasma renin activity
E	Ulcerative colitis

C Whipple's disease

Whipple's disease is caused by infection with *Tropheryma whippelii*. The organism can be identified by PAS staining of a jejunal biopsy. It is an uncommon condition classically affecting men aged 40–60 years. Gastrointestinal symptoms of diarrhoea, malabsorption and steatorrhoea are often preceded by arthropathy. In the past, various antibiotic regimens (including penicillins) were used on an empirical basis. Tetracycline treatment seems to be associated with a high frequency of relapse, so trimethoprim-sulfamethoxazole (160/800 mg orally twice daily) or long-term ampicillin given for around a year is now recommended.

A Chronic pancreatitis

Chronic pancreatitis is a syndrome involving progressive inflammatory changes in the pancreas that result in permanent structural damage, which

changes in the pancreas that result in permanent structural damage, which can lead to impairment of exocrine and endocrine function. Chronic pancreatitis may be asymptomatic over long periods of time, can present with a fibrotic mass or there may be symptoms of pancreatic insufficiency without pain. The serum amylase and lipase concentrations tend to be normal in patients with chronic pancreatitis, but are almost always elevated with acute disease. Morphologically, chronic pancreatitis is a patchy focal disease characterised by a mononuclear infiltrate and fibrosis. There are no joint symptoms associated with chronic pancreatitis.

B	Coeliac disease

Coeliac disease is a common and underdiagnosed condition, which may present at any age. It is a hypersensitivity to gluten found in wheat, rye and barley. The gliadin fraction of the protein provokes an inflammatory response causing

fraction of the protein provokes an inflammatory response causing subtotal or total villous atrophy of the small bowel, resulting in malabsorption. It classically presents with a history of diarrhoea, weight loss, oral ulceration, lethargy and anaemia (folate, B_{12} or iron-deficient). There is an association with dermatitis herpetiformis, a very pruritic polymorphic skin rash, and an increased risk of developing gastrointestinal malignancy. Treatment is by maintaining a strict diet avoiding foods containing wheat, rye, oats or barley. The clinical picture in this scenario is not consistent with Coeliac disease.

D	Increased plasma renin activity

Patients with renin-secreting tumours are typically young (average age 22 years) and have severe hypertension and hypokalaemia. Contrast-enhanced computed tomography (CT) appears to be the diagnostic procedure of

Ulcerative colitis is characterised by recurring episodes of inflammation limited to the mucosal layer of the colon. It commonly involves the rectum and may extend in a proximal and continuous fashion to involve other parts of the colon. Patients with ulcerative colitis usually present with diarrhoea, which may be associated with blood. Bowel movements are frequent and small in volume as a result of rectal inflammation. Associated symptoms include colicky abdominal pain, urgency, tenesmus and incontinence. Patients with mainly distal disease may have constipation accompanied by frequent discharge of blood and mucus. The endoscopic findings in patients with ulcerative colitis include loss of vascular markings due to engorgement of the mucosa, giving it an erythematous appearance. In addition, granularity of the mucosa, petechiae, exudates, oedema, erosions, touch friability and spontaneous bleeding may be present. More severe cases may be associated with macro-ulcerations, profuse bleeding and copious exudates. The endoscopic

A 45-year-old man presents with a recent change in bowel habits. He had a colonoscopy which was normal.

He is still concerned about colorectal cancer as a colleague has recently been diagnosed with metastatic colorectal cancer. He would like some advice on prevention.

Which of the following lifestyle measures will have the most impact on reducing his risk of colorectal carcinoma?

A	Reduce dietary sugar intake
B	Avoid contact sports
C	Dietary supplement with micronutrients
D	Stop smoking
E	Veganism

D Stop smoking

Colorectal cancer is the second commonest cause of cancer death, after bronchial carcinoma, in the United Kingdom. It is thought that just over half (54%) of bowel cancer cases in the UK are linked to lifestyle risk factors.

Public Health England guidance currently advises the following, with regard to modifiable risk factors in bowel cancer risk:

1. Exercise regularly

2. Stop smoking

3. Reduce the amount of alcohol consumed

4. Maintain or achieve a healthy weight

5. Eat a healthy balanced diet

Meta-analysis suggests that smokers have an 18% increased relative risk of developing colorectal cancer.

A Reduce dietary sugar intake

While weight gain has been shown to carry a 15-20% increase in relative risk of colorectal cancer, depending on when in life the weight is gained, current guidance does not draw a specific relationship between sugar intake and colorectal carcinoma.

B Avoid contact sports

Meta-analysis has shown an approximately 26% reduced risk of colon cancer when comparing the most- versus the least-active individuals.

C Dietary supplement with micronutrients

There is no evidence to suggest that dietary supplementation with vitamins / micronutrients has a significant effect on bowel cancer risk.

E Veganism

There is no evidence to suggest that dietary supplementation with vitamins / micronutrients has a significant effect on bowel cancer risk.

E	Veganism

Long-term consumption of red and processed meat appears to be associated with a raised risk of colorectal cancer. Public Health England advise limiting the amount of red meat consumed to 500 grams or less (cooked weight) per week, and limiting the amount of processed meats one consumes. The practice of veganism carries the risk of other nutrient deficiencies, and such a practice is not currently advised.

71461

Rate this question:

Next Question

A 39-year-old man with a 20-year history of alcohol misuse is being investigated as an outpatient. He undergoes endoscopy and is found to have three columns of oesophageal varices that occlude the lumen.

On questioning, he denies any previous episodes of melaena or haematemesis. He admits to still drinking 7–10 cans of lager per day. Physical examination reveals stigmata of chronic liver disease and moderate ascites. There is no evidence of encephalopathy.

Investigations:

Hb	15.0 g/dl
WCC	6.5×10^9/l
PLT	120×10^9/l
Bilirubin	45 μmol/l (1–22)
AST	80 U/l (1-31)
ALT	35 U/l (5-35)
Albumin	30 g/l (37-49)
PT	23 s (11.5-15.5)

ALT	35 U/l (5-35)
Albumin	30 g/l (37-49)
PT	23 s (11.5-15.5)

Which of the following is the most appropriate initial treatment option with respect to reducing portal hypertension?

A	Trans-jugular intrahepatic porto-systemic shunt (TIPSS)
B	Injection sclerotherapy to the varices
C	Cyanoacrylate gluing of the varices
D	Banding ligation of the varices
E	Propranolol

E	Propranolol

The blood results here are consistent with a diagnosis of alcoholic cirrhosis. Portal hypertension is suggested by the low platelet count (due to hypersplenism) and varices at endoscopy. Guidelines published by the British Society of Gastroenterology in 2015 suggest primary prophylaxis with pharmacological treatment with propranolol as first line, so option E is correct. Non-cardioselective β-blockers such as propranolol cause splanchnic vasoconstriction (via blockade of vasodilatory adrenoreceptors of the splanchnic circulation), reducing portal and collateral blood flow.

A	Trans-jugular intrahepatic porto-systemic shunt (TIPSS)

TIPSS is a shunt created between the portal and hepatic vein in order to reduce portal pressure. A reduction in portal hypertension will reduced the risk of bleeding from varices, but

TIPSS is a shunt created between the portal and hepatic vein in order to reduce portal pressure. A reduction in portal hypertension will reduced the risk of bleeding from varices, but carries a risk of chronic encephalopathy. It is therefore only currently recommended for the treatment of recurrent variceal bleeding.

B	Injection sclerotherapy to the varices

The results of trials of sclerotherapy as primary prophylaxis have produced mixed results and it is therefore not recommended.

C	Cyanoacrylate gluing of the varices

This technique is used only to treat gastric varices, not oesphageal varices.

D	Banding ligation of the varices

primary prophylaxis have produced mixed results and it is therefore not recommended.

C	Cyanoacrylate gluing of the varices

This technique is used only to treat gastric varices, not oesphageal varices.

D	Banding ligation of the varices

Pharmacological treatment with propranolol is less invasive and can be as equally as effective in reducing portal hypertension.

6444

Rate this question:

100% 11:04
tps://mypastest.pastest.com

Distal amplitude	25 mmHg (64–154)

Which one of the following is the most likely diagnoses?

A	Scleroderma
B	Diffuse oesophageal spasm
C	Globus
D	Achalasia
E	Non-specific oesophageal dysmotility

33007

Submit

A 50-year-old woman is being investigated for intermittent dysphagia and has had a normal upper gastrointestinal endoscopy. She undergoes oesophageal manometry and some of the results are outlined below. She has symptoms of Raynaud's, and some skin thickening over her hands, but no other significant medical problems.

Lower oesophageal sphincter resting pressure	8 mmHg (17–36)
Residual lower oesophageal sphincter relaxing pressure	7 mmHg (< 8)

Peristalsis:

Proximal amplitude	80 mmHg (33–91)
Distal amplitude	25 mmHg (64–154)

Proximal amplitude	80 mmHg (33–91)
Distal amplitude	25 mmHg (64–154)

Which one of the following is the most likely diagnoses?

A	Scleroderma
B	Diffuse oesophageal spasm
C	Globus
D	Achalasia
E	Non-specific oesophageal dysmotility

33007

Submit

Rose: OK

A 50-year-old woman is being investigated for intermittent dysphagia and has had a normal upper gastrointestinal endoscopy. She undergoes oesophageal manometry and some of the results are outlined below. She has symptoms of Raynaud's, and some skin thickening over her hands, but no other significant medical problems.

Lower oesophageal sphincter resting pressure	8 mmHg (17–36)
Residual lower oesophageal sphincter relaxing pressure	7 mmHg (< 8)

Peristalsis:

Proximal amplitude	80 mmHg (33–91)
Distal amplitude	25 mmHg (64–154)

Which one of the following is the most

A Scleroderma

The finding of a low resting lower oesophageal sphincter (LOS) pressure is a requirement for a diagnosis of scleroderma-associated dysmotility. It may also be found in the hypocontractile oesophagus associated with reflux disease. However, in the presence of skin thickening and symptoms of Raynaud's, the most likely diagnosis is systemic sclerosis.

D Achalasia

Absent distal peristalsis, high resting LOS pressures and failure of LOS relaxation would be expected in cases of achalasia.

B Diffuse oesophageal spasm

This is a condition where thin membranes of normal oesophageal tissue obstruct part of the oesophagus.

B Diffuse oesophageal spasm

This is a condition where thin membranes of normal oesophageal tissue obstruct part of the oesophagus. It would be associated with dysphagia to solids more than liquids and normal findings on manometry.

C Globus

Globus is a psychological condition which would only be diagnosed in the absence of abnormal finding on investigation.

E Non-specific oesophageal dysmotility

This is a disorder of peristalsis but would not be associated with the other features of systemic sclerosis (thickened skin and Raynaud's) that are present in this case.

33007

Rate this question:

A 47-year-old woman is referred to the Gastroenterology Clinic due to abnormal liver function tests which were a finding on a battery of blood tests checked by her GP. She attended the general practitioner (GP) because of increased fatigue and symptoms of itching. She was diagnosed with irritable bowel syndrome several years ago, but this has since become quiescent. She has no other significant past medical history except for hormone replacement therapy and takes no regular medication. She is a non-smoker and drinks 6 units of alcohol per week. She has no risk factors for hepatitis.

On examination she looked well, her BMI is 22. Some xanthelasmata were noted, but there was no jaundice, clubbing or lymphadenopathy. Her abdomen was soft and non-tender and the liver edge was palpable 1 cm below the costal margin. Cardiorespiratory and neurological examination was unremarkable.

Investigation results are below:

A 47-year-old woman is referred to the Gastroenterology Clinic due to abnormal liver function tests which were a finding on a battery of blood tests checked by her GP. She attended the general practitioner (GP) because of increased fatigue and symptoms of itching. She was diagnosed with irritable bowel syndrome several years ago, but this has since become quiescent. She has no other significant past medical history except for hormone replacement therapy and takes no regular medication. She is a non-smoker and drinks 6 units of alcohol per week. She has no risk factors for hepatitis.

On examination she looked well, her BMI is 22. Some xanthelasmata were noted, but there was no jaundice, clubbing or lymphadenopathy. Her abdomen was soft and non-tender and the liver edge was palpable 1 cm below the costal margin. Cardiorespiratory and neurological examination was unremarkable.

Investigation results are below:

Investigation results are below:

Haemoglobin (Hb)	13 g/dl
White cell count	6.0×10^9/l
Platelets	220×10^9/l
Mean corpuscular volume (MCV)	82 fl
International normalised ratio (INR)	1.1
Erythrocyte sedimentation rate(ESR)	4 mm/h
Na^+	140 mmol/l
K^+	3.8 mmol/l
Urea	5.2 mmol/l
Creatinine	100 µmol/l
Fasting glucose	4.1 mmol/l
C-reactive	< 4 mg/l

C reactive protein (CRP)	< 4 mg/l
Cholesterol	7.8 mmol/l
Bilirubin	16 μmol/l
Alkaline phosphatase	850 IU/l
Gamma-glutamyl transferase	52 IU/l
Alanine aminotransferase (ALT)	48 IU/l
Albumin	38 g/dl
Abdominal ultrasound	Slight hepatomegaly, no other focal abnormality, no biliary obstruction

Which further investigation would be most specific in making the diagnosis?

A Magnetic resonance cholangiopancreatography (MRCP)

Abdominal ultrasound	hepatomegaly, no other focal abnormality, no biliary obstruction

Which further investigation would be most specific in making the diagnosis?

A	Magnetic resonance cholangiopancreatography (MRCP)
B	Computed tomography (CT) scan of abdomen
C	Anti-mitochondrial antibodies
D	Hepatitis serology
E	Anti-nuclear antibodies

33010

Submit

C Anti-mitochondrial antibodies

Clinical features are pointing towards a diagnosis of primary biliary cirrhosis (PBC), which is a chronic progressive disorder with gradual destruction of the intrahepatic bile ducts, leading to fibrosis and cholestasis and ultimately hepatic cirrhosis. PBC is usually presented in middle aged females with early symptoms of pruritis, fatigue, which can progress to development of obstructive jaundice and portal hypertension. 50% of patients may be asymptomatic at the time of diagnosis and are detected by abnormal liver function tests especially elevated alkaline phosphatase. Anti-mitochondrial antibody is the most specific test for PBC as it is positive in more than 95% of cases. Treatment options include colestyramine for pruritis (*naltrexone and rifampicin may also help*), ursodeoxycholic acid and liver transplantation for end staged disease (e.g. bilirubin > 100 μmol/L). Once jaundice develops, survival rate is < 2 years without liver transplantation.

A Magnetic resonance cholangiopancreatography (MRCP)

MRCP can help to exclude chronic biliary obstruction (stone or stricture), however it is not specific for Primary biliary Cirrhosis.

B Computed tomography (CT) scan of abdomen

CT scan of abdomen can be helpful in differentiating PBC from other biliary conditions e.g. carcinoma of bile duct, but not specific for PBC. There is a high risk of hepatocellular carcinoma in patients with PBC.

D Hepatitis serology

PBC must be differentiated from chronic hepatitis (due to viral infections) by performing hepatic serology tests. Hepatic serology is not specific for underlying possible diagnosis of PBC.

A 31-year-old man who recently emigrated from China had some routine blood work by his general practitioner (GP).

His hepatitis-B screen came back showing positive HBs and hepatitis-B IgG core antibodies. Anti-HBe was positive, but he is e-antigen negative and s-antigen negative.

The GP immediately referred the patient to your clinic, but before doing this sent some liver function tests.

Investigations:

Bilirubin	12 μmol/l
ALT	42 U/l
ALP	67 U/l
Albumin	36 g/l
HBV DNA	Negative

The patient seems to be in good health.

What is the most appropriate management of this patient?

ALP	67 U/l
Albumin	36 g/l
HBV DNA	Negative

The patient seems to be in good health.

What is the most appropriate management of this patient?

A	Elective liver biopsy
B	Discharge back to the GP
C	Start interferon therapy
D	Start combined lamivudine and interferon therapy
E	Offer an HIV, Hep-C test and discharge the patient back to the GP if negative

E Offer an HIV, Hep-C test and discharge the patient back to the GP if negative

A patient who is HBs antibody positive indicates previous infection unless they have been vaccinated against Hep-B. The phenomenon of loss of HbeAg and seroconversion to anti-Hbe-positive status indicates a reduction of inflammation accompanied by histological change from active to inactive hepatitis. E-antigen negativity implies that he no longer has active infection. Guidance suggests that in this case it is worth offering an HIV test, as exposure to hepatitis B may well indicate exposure to other blood-borne viruses.

For indications for treatment, refer to NICE guidance CG165.

A Elective liver biopsy

In patients with HBe-negative chronic hepatitis and mildly raised ALT, liver biopsy is usually only considered in

B Discharge back to the GP

He should be tested for other blood borne viruses, and offered transient elastography testing.

C Start interferon therapy

Antiviral therapy is not currently indicated for a man over 30 years old, with normal LFTs and negative HBV DNA.

D Start combined lamivudine and interferon therapy

Antiviral therapy is not currently indicated for a man over 30 years old, with LFTs and negative HBV DNA. Antiviral treatments for HBe-Ag-negative chronic hepatitis-B include PEGinterferon alfa-2a (first line), entacavir and tenofivir.

6865

Rate this question:

A 35-year-old woman is referred to you for further investigation of her anaemia discovered by her general practitioner (GP). She feels fit and well apart from feeling tired occasionally, which she attributes to the stress of her high-powered job.

On specific questioning, she denies weight loss or dyspepsia and there is no change of bowel habit. She is not pregnant and has noticed no change in her menses.

She is slightly concerned as her father died of colorectal cancer at the age of 62 years.

Investigations:

Hb	10.0 g/dl
WCC	10.0×10^9/l
PLT	300×10^9/l
MCV	75 fl
MCH	22 pg
Ferritin	12.0 µg/l
B	450 ng/l

WCC	10.0 × 10⁹/l
PLT	300 × 10^9/l
MCV	75 fl
MCH	22 pg
Ferritin	12.0 µg/l
B_{12}	450 ng/l
Serum folate	7 nmol/l (4.5-45.3)

Which of the following is an appropriate next step?

A	Tissue transglutaminase (TTG)
B	Faecal occult blood (FOB)
C	OGD
D	Colonoscopy
E	Thyroid function tests (TFTs)

A Tissue transglutaminase (TTG)

In women aged less than 50 years who menstruate regularly, menstrual blood loss is the most common cause of iron deficiency anaemia (IDA), although coeliac disease with minimal symptoms is increasingly recognised and, as such, coeliac serology is recommended as an initial step. Therefore TTG is the correct answer. Only if coeliac screening is normal and there are no features of concern is a period of iron replacement then recommended. In this scenario, the combination of microcytic anaemia and low-normal folate raises the possibility of small bowel pathology and increases the likelihood of coeliac versus large bowel pathology.

B Faecal occult blood (FOB)

This stool test is not used as a diagnostic test for anaemia, but is implemented in the bowel cancer

screening programme

C	OGD

Although this may be appropriate for further investigation of this patient's iron deficiency anaemia, it is an invasive test so it would not be the next step that you would perform.

D	Colonoscopy

Although appropriate for the investigation of iron deficiency anaemia, it is an invasive test and would not be the next investigation you would choose to perform.

E	Thyroid function tests (TFTs)

Although you might want to perform this test to investigation her tiredness, thyroid dysfunction does not usually cause iron deficiency anaemia.

6442

Rate this question:

A 42-year-old man presents with pruritus, right upper quadrant (RUQ) pain and malaise. He has had ulcerative colitis for the past 10 years. He takes sulfasalazine and has had good control, with only two acute episodes since diagnosis. He now presents with a 6-month history of itching. He drinks fewer than 10 units of alcohol per week.

On examination, he has hepatosplenomegaly, spider naevi and scratch marks.

Investigations:

Bilirubin	150 μmol/l (1–22)
ALT	40 μ/l (5–35)
ALP	600 μ/l (45–105)

What investigation is most likely to yield a diagnosis?

A Liver biopsy

B Endoscopic retrograde

Investigations:

Bilirubin	150 μmol/l (1–22)
ALT	40 μ/l (5–35)
ALP	600 μ/l (45–105)

What investigation is most likely to yield a diagnosis?

A	Liver biopsy
B	Endoscopic retrograde cholangiopancreatography/mag resonance cholangiopancreatography
C	Anti-mitochondrial antibodies
D	Serum ferritin
E	Ultrasound scan (USS)

B Endoscopic retrograde cholangiopancreatography/mag resonance cholangiopancreatography

The history of a cholestatic illness (suggested by the itching) and evidence of chronic liver disease (cutaneous signs) against a background of inflammatory bowel disease suggests a possible diagnosis of primary sclerosing cholangitis (PSC). This is an inflammatory obliterative cholangiopathy that can lead to chronic liver disease cirrhosis and liver failure. It is commoner in men and presents in the second to fifth decade. A total of 3–10% of cases of ulcerative colitis will develop PSC. The diagnosis rests on the demonstration of destruction of the biliary tree and this is best demonstrated by cholangiopancreatography. The disease is progressive with recurrent episodes of cholangitis complicating cirrhosis. Liver transplantation is now used in end-stage disease. The risk of cholangiocarcinoma is high, and the development of cancer is a

cholangiocarcinoma is high, and the development of cancer is a contraindication to transplant and associated with a poor survival.

A Liver biopsy

Rarely only smaller bile ducts are damaged and diagnosis is made at liver biopsy when PSC is mistaken fo more focal liver disease, although this is only in exceptional circumstances where the liver biopsy is performed because of apparent local changes only.

C Anti-mitochondrial antibodies

AMA is positive in 98% of cases of primary biliary cirrhosis, not in primary sclerosing cholangitis. ANA, SMA and ANCA may be positive, but these are unlikely to lead to a diagnosis.

D Serum ferritin

High levels of serum ferritin may

AMA is positive in 98% of cases of primary biliary cirrhosis, not in primary sclerosing cholangitis. ANA, SMA and ANCA may be positive, but these are unlikely to lead to a diagnosis.

D	Serum ferritin

High levels of serum ferritin may suggest haemochromatosis, but may be slightly raised as an acute phase reactant in most inflammatory conditions.

E	Ultrasound scan (USS)

Ultrasound would be useful to exclude an extra-hepatic cause for cholestasis, but would not lead to the diagnosis. It is far more useful in jaundice secondary to gallstone and to diagnose cholecystitis.

33074

Rate this question:

A 42-year-old woman is referred to the Hepatology Clinic with liver failure. She drinks no alcohol but over the past few months has suffered from increasing tiredness, upper abdominal discomfort, nausea, anorexia and itching. Most recently, she has noticed markedly increased bruising if she takes a knock on something.

On examination, her blood pressure is 105/70 mmHg. You notice signs of chronic liver disease including scratch marks on her skin, spider naevi and evidence of mild jaundice. She also has extensive bruising on her limbs. Hepatomegaly is also present.

Investigations:

Hb	10.5 g/dl
WCC	5.5×10^9/l
PLT	110×10^9/l
Na^+	134 mmol/l
K^+	4.2 mmol/l
Creatinine	90 μmol/l

Creatinine	90 μmol/l
PT	27.3 s
Albumin	22 g/l
ALT	765 U/l
Bilirubin	100 μmol/l
Anti-soluble liver antigen antibody	+
Gamma-globulins	Increased
Liver biopsy	Hepatic cirrhosis

Which of the following is the most likely diagnosis?

A Wilson's disease

B Haemochromatosis

C Autoimmune hepatitis Type 1

D Primary biliary cirrhosis

100% 11:38
tps://mypastest.pastest.com

Liver biopsy	Hepatic cirrhosis

Which of the following is the most likely diagnosis?

Your answer was incorrect

A	Wilson's disease
B	Haemochromatosis
C	Autoimmune hepatitis Type 1
D	Primary biliary cirrhosis
E	Autoimmune hepatitis Type 3

Explanation

E	Autoimmune hepatitis Type 3

E Autoimmune hepatitis Type 3

This patient has an autoantibody pattern consistent with autoimmune hepatitis type 3, and features of cirrhosis which are said to occur in around 75% of patients with the condition. It is commonest in those of the 30–50-year group, the vast majority being women. The prolonged PT is likely to be as the result of severe hepatic dysfunction. Corticosteroids achieve remission in around 2/3 of patients, although the relapse rate is as high as 80% after steroid withdrawal. Azathioprine is the main steroid-sparing agent used in the treatment of the condition.

A comparison between subtypes of autoimmune hepatitis is listed below:

Clinical Features	Type 1	Type 2	Ty
Diagnostic autoantibodies	ASMA ANA	Anti-LKM P-450 IID6 Synthetic	Sc liv an

Clinical Features	Type 1	Type 2	Type 3
Diagnostic autoantibodies	ASMA ANA Anti-actin	Anti-LKM P-450 IID6 Synthetic core motif peptides 254-271	Soluble liver-kidney antigen Cytokeratins 8 and 18
Age	10y - elderly	Paediatric (2-14y) Rare in adults	Adults (30-50y)
Women (%)	78	89	90

Women (%)	78	89	90
Concurrent immune disease %	41	34	58
Gamma globulin elevation	+++	+	++
Low IgA	No	Occasional	No
HLA association	B8, DR3, DR4	B14, DR3, C4AQO	Uncertain

Low IgA	No	Occasional	No
HLA association	B8, DR3, DR4	B14, DR3, C4AQO	Uncertain
Steroid response	++	++	+++
Progression to cirrhosis	45	82	75

C Autoimmune hepatitis Type 1

A 24-year-old woman with constipation is referred to you by her GP. She describes opening her bowels once every 2 weeks and the stools are usually very hard. She has to strain on each occasion and has resorted to using her fingers to help expel her stool. She has tried dietary fibre and many different types of laxatives, which are no longer effective. She now complains of headache, malaise and poor concentration. She was adopted and does not know of any family history.

Examination of the abdomen is normal. Blood tests are normal, including thyroid function test and serum calcium level. Rigid sigmoidoscopy shows changes consistent with melanosis coli.

Which of the following is the most appropriate management step?

A	Carry out a whole-gut transit study
B	Refer to a dietician for advice

Blood tests are normal, including thyroid function test and serum calcium level. Rigid sigmoidoscopy shows changes consistent with melanosis coli.

Which of the following is the most appropriate management step?

A	Carry out a whole-gut transit study
B	Refer to a dietician for advice on a high-fibre diet
C	Admit for colonoscopy with double-strength bowel prep
D	Trial of low-dose amitriptyline
E	Refer for anorectal myectomy

33024

Submit

A 24-year-old woman with constipation is referred to you by her GP. She describes opening her bowels once every 2 weeks and the stools are usually very hard. She has to strain on each occasion and has resorted to using her fingers to help expel her stool. She has tried dietary fibre and many different types of laxatives, which are no longer effective. She now complains of headache, malaise and poor concentration. She was adopted and does not know of any family history.

Examination of the abdomen is normal. Blood tests are normal, including thyroid function test and serum calcium level. Rigid sigmoidoscopy shows changes consistent with melanosis coli.

Which of the following is the most appropriate management step?

Your answer was incorrect

A Carry out a whole-gut transit study

Patients referred to hospital with constipation tend to be those with more severe impairment of quality of life and who have failed trials of dietary fibre supplementation or laxatives. Reintroducing fibre is usually not helpful and may exacerbate bloating. Up to 50% of women who present with constipation are victims of sexual or physical abuse, and therefore it is important to take a good social history. Abdominal radiography is important to exclude a dilated colon caused by megacolon or Hirschsprung's disease. A radio-opaque marker study measuring whole-gut transit not only measures generalised intestinal motor function, but is also non-invasive and easy to interpret.

B Refer to a dietician for advice on a high-fibre diet

This patient has already trialled a high-

therefore further advice on a high-fibre diet is unlikely to have any significant impact.

C	Admit for colonoscopy with double-strength bowel prep

It's unlikely that any anatomical abnormality will be revealed on colonoscopy, hence it isn't advised here.

D	Trial of low-dose amitriptyline

Agents such as tricyclic antidepressants, antipsychotics, opiates, calcium channel blockers and iron are all recognised to worsen symptoms of constipation.

E	Refer for anorectal myectomy

This is the intervention of choice for short-segment Hirschsprung's disease, although it shouldn't be instituted until the diagnosis is confirmed.

A 74-year-old man presents to the Emergency Department with inability to swallow either solids or liquids for the past 3 days. On further questioning, he admits to having progressive difficulty, first for solids then for liquids, with respect to swallowing over the last 4 months.

He has lost 5 kg in weight. He has a 60 pack-year smoking history and drinks 8 units of spirits per day.

Examination reveals a BP of 110/79 mmHg, pulse is 85/min and regular and he looks dehydrated. His BMI is 19, he has an irregular liver edge and a large left supraclavicular lymph node is palpable.

Investigations:

Hb	8.5 g/dl
WCC	$12.3 \times 10^9/l$
PLT	$179 \times 10^9/l$
Na^+	137 mmol/l
K^+	4.3 mmol/l

Creatinine	151 micromol/l
Urea	15.2 mmol/l
Albumin	27 g/l
ALT	282 U/l
ALP	321 U/l
Bilirubin	24 μmol/l
USS abdomen	Evidence of liver metastases
Upper GI endoscopy	Ulcerated lesion within the lower 1/3 of the oesophagus

Intravenous (iv) fluids have been commenced over the past 24 h.

Which of the the following is the most appropriate next intervention?

A Local mucosal resection

B Oesophagectomy

C Oesophageal stenting

abdomen	metastases
Upper GI endoscopy	Ulcerated lesion within the lower 1/3 of the oesophagus

Intravenous (iv) fluids have been commenced over the past 24 h.

Which of the the following is the most appropriate next intervention?

A	Local mucosal resection
B	Oesophagectomy
C	Oesophageal stenting
D	Photodynamic therapy
E	Trastuzumab

39050

Submit

A 26-year-old man with human immunodeficiency virus (HIV) infection presents with spiking temperatures over the past two weeks, right upper quadrant pain and abnormal liver function tests. He has a low CD4 count. Ultrasound scan and computed tomography (CT) scan are normal.

Blood tests show:

Hb	12.0 g/dl
White blood count	4.0×10^9/l
Platelets	151×10^9/l
International normalised ratio (INR)	1.0
Bilirubin	20 μmol/l
Alanine aminotransferase (ALT)	37 U/l (5–35)
Alkaline phosphatase (ALP)	380 U/l (30–150)
Gamma GT (GGT)	189
Albumin	35 g/l

Alkaline phosphatase (ALP)	380 U/l (30–150)
Gamma GT (GGT)	189
Albumin	35 g/l

What is the most useful investigation/intervention?

A	Blood culture
B	Liver biopsy
C	Magnetic resonance cholangiopancreatography (MRCP)
D	Endoscopic retrograde cholangiopancreatography (ERCP)
E	CT abdomen

A 26-year-old man with human immunodeficiency virus (HIV) infection presents with spiking temperatures over the past two weeks, right upper quadrant pain and abnormal liver function tests. He has a low CD4 count. Ultrasound scan and computed tomography (CT) scan are normal.

Blood tests show:

Hb	12.0 g/dl
White blood count	4.0×10^9/l
Platelets	151×10^9/l
International normalised ratio (INR)	1.0
Bilirubin	20 μmol/l
Alanine aminotransferase (ALT)	37 U/l (5–35)
Alkaline phosphatase (ALP)	380 U/l (30–150)
Gamma GT (GGT)	189
Albumin	35 g/l

D Endoscopic retrograde cholangiopancreatography (ERCP)

Biliary involvement in HIV infection is commonly known as AIDS (acquired immunodeficiency syndrome) cholangiopathy, and is a syndrome of biliary obstruction resulting from infection-related strictures of the biliary tract. There is a spectrum of involvement including acute acalculous cholecystitis, papillary stenosis and sclerosing cholangitis. Cholangiopathy is mostly associated with cryptosporidium parvum, but other pathogens have also been identified, including cytomegalovirus (CMV) and Microsporidium.

The definitive diagnosis of cholangiopathy is made with direct visualisation by endoscopic retrograde cholangiopancreatography (ERCP), which can reveal several patterns of biliary abnormality; the combination of papillary stenosis and sclerosing cholangitis is the most unique to AIDS cholangiopathy. ERCP also allows both

cholangitis is the most unique to AIDS cholangiopathy. ERCP also allows both confirmation of the diagnosis and the performance of therapeutic procedures, if indicated. Biliary brushings and biopsy, biliary aspiration, and small bowel biopsy can also be performed to aid in diagnosis, including detection of the etiologic agent using appropriate stains. However, other studies (particularly ultrasound and magnetic resonance cholangiopancreatography [MRCP]) can be helpful in early evaluation, and in selecting patients for ERCP.

Symptomatic patients with papillary stenosis have responded symptomatically to endoscopic sphincterotomy. Antibiotics have not been shown to be useful. Some clinicians use ursodeoxycholic acid in patients with intrahepatic disease, with an observed improvement in liver enzymes.

C Magnetic resonance cholangiopancreatography (MRCP)

C Magnetic resonance cholangiopancreatography (MRCP)

This is a cost-effective and sensitive initial screening investigation, but ECRP is considered the definitive modality, and carries further diagnostic and therapeutic options.

A Blood culture

This would not particularly contribute to diagnosis - imaging of the biliary tree is required to explore this patient's symptoms pattern of liver enzyme derangement.

B Liver biopsy

Liver biopsy has little value in the diagnosis of AIDS cholangiopathy; diagnosis is informed by imaging of the biliary tree.

E CT abdomen

Liver biopsy has little value in the diagnosis of AIDS cholangiopathy; diagnosis is informed by imaging of the biliary tree.

E	CT abdomen

CT is more useful than ultrasound in identifying intrahepatic strictures, and can be effective in identifying intrahepatic masses, abdominal adenopathy, and pancreatic disease in jaundiced patients. But CT is inferior to ERCP in its ability to display the necessarily precise biliary anatomical details for the definitive diagnosis of AIDS cholangiopathy.

71395

A 30-year-old woman with a history of Crohn's disease returns to the clinic for review after formation of an ileostomy. She is worried as she has some ulcerated areas which have begun to form on the skin around the stoma.

On examination, she is apyrexial and her abdomen is soft and non-tender. There are three deep ulcerated areas with a violaceous border around the edge of the stoma overlying where the colostomy bags stick on to the surrounding skin. She tells you the bags do not stick well and it hurts to attach them.

Investigations:

Hb	10.9 g/dl
WCC	5.0×10^9/l
PLT	182×10^9/l
Na^+	139 mmol/l
K^+	4.5 mmol/l
Creatinine	130 μmol/l
ESR	13 mm/hr

WCC	5.0×10^9/l
PLT	182×10^9/l
Na^+	139 mmol/l
K^+	4.5 mmol/l
Creatinine	130 µmol/l
ESR	13 mm/hr

What is the most appropriate way to manage these?

A Topical terbinafine

B IV flucloxacillin

C Oral sulphasalazine

D Oral prednisolone

E Surgical debridement

D Oral prednisolone

This patient has classic pyoderma gangrenosum, which occurs in patients with a history of inflammatory bowel disease, and may be found around the stoma in patients with Crohn's who have recently undergone stoma formation. Biopsy of pyoderma gangrenosum lesions shows neutrophil infiltration, haemorrhage and epidermal necrosis. However, findings are not specific and it is a diagnosis of exclusion. Topical or systemic corticosteroids are the treatment of choice for pyoderma gangrenosum. Anti-TNF treatment with infliximab or adalimumab has also been shown to be effective and should be considered if a rapid response to corticosteroids is not achieved. Topical or oral calcinerin inhibitors (eg tacrolimus) are an alternative. Repeated local trauma from applying and removing stoma bags may increase the chance of a recurrence. Further information is available.

Generally surgery is not recommended in pyoderma gangrenosum. Lesions are commonly preceded by trauma (pathergy) so in theory may worsen the condition. Closure of the stoma site can, in some cases, lead to resolution of the lesions.

A Topical terbinafine

The patient has pyoderma gangrenosum. There is no role for antifungal treatment unless cultures indicate superadded fungal infection.

B IV flucloxacillin

Pyoderma gangrenosum is sterile on culture unless secondary infection has occurred.

C Oral sulphasalazine

5ASA are not effective for the treatment of pyoderma gangrenosum.

A 62-year-old woman is referred to the clinic with worsening diarrhoea, intermittent wheeze and facial flushing. There is a past medical history of hypertension, for which she takes ramipril, but nil else of note.

On examination, her BP 149/88 mmHg, pulse is 88/min, her BMI is 21. Her abdomen is soft and only mildly tender with active bowel sounds. There is facial telangiectasia and evidence of tricuspid regurgitation.

Routine bloods undertaken by her general practitioner reveal:

Hb	10.8 g/dl
Na^+	135 mmol/l
K^+	3.2 mmol/l
ALT	215 U/l

Which of the following diagnoses fits best with this clinical picture?

A	Phaeochromocytoma

general practitioner reveal:

Hb	10.8 g/dl
Na^+	135 mmol/l
K^+	3.2 mmol/l
ALT	215 U/l

Which of the following diagnoses fits best with this clinical picture?

A	Phaeochromocytoma
B	Thyrotoxicosis
C	Carcinoid syndrome
D	Cushing's disease
E	Iron deficiency anaemia

33052

Submit

A 62-year-old woman is referred to the clinic with worsening diarrhoea, intermittent wheeze and facial flushing. There is a past medical history of hypertension, for which she takes ramipril, but nil else of note.

On examination, her BP 149/88 mmHg, pulse is 88/min, her BMI is 21. Her abdomen is soft and only mildly tender with active bowel sounds. There is facial telangiectasia and evidence of tricuspid regurgitation.

Routine bloods undertaken by her general practitioner reveal:

Hb	10.8 g/dl
Na^+	135 mmol/l
K^+	3.2 mmol/l
ALT	215 U/l

Which of the following diagnoses fits best with this clinical picture?

Your answer was incorrect

C Carcinoid syndrome

Carcinoid syndrome presents with facial flushing (75–90%), diarrhoea (>70%) and intermittent bronchospasm in 25% of patients. Associated clinical findings include facial telangiectasia and tricuspid regurgitation. It is caused by the action of serotonin, bradykinin and histamine produced by tumours arising from neuroendocrine cells. Diagnosis is by measuring an increase in urinary 5-hydroxyindoleacetic acid, a metabolite of 5-HT (serotonin). It is likely that this patient's abnormal alanine aminotransferase is due to the presence of liver metastases. Pellagra is nicotinic acid deficiency which can occur as a result of increased requirements for nicotinamide as a result of the carcinoid tumour. It is an important substrate in the metabolic formation of 5-HT, deficiency in pellagra can lead to dementia in patients with extensive carcinoid metastases.

E Iron deficiency anaemia

Iron deficiency alone is unlikely given the other symptoms including facial flushing, diarrhoea, and evidence of tricuspid regurgitation, fitting better with carcinoid.

A Phaeochromocytoma

This is associated with marked hypertension and headaches, and maybe associated with hypokalaemia, but is not associated with significant diarrhoea.

B Thyrotoxicosis

Although thyrotoxicosis may be associated with weight loss and diarrhoea, features such as telangiectasia, tricuspid regurgitation and elevated transaminases would be unexpected in the context of hyperthyroidism.

A 38-year-old woman presents to the Emergency Department with nausea, vomiting and an upper GI haemorrhage. She admits that she went foraging for mushrooms some 3 days earlier and cooked some that she found in the forest, but no one else in the family wanted to take the risk of eating them. A sample of leftover mushrooms suggests they were Death Cap.

On examination, her BP is 110/72 mmHg, with pulse 92/min and regular. She is tender in the epigastrium and right upper quadrant of her abdomen. There is dried blood around her lips and evidence of bruising on her arms and legs.

Investigations:

Hb	9.1 g/dl
WCC	10.5×10^9/l
PLT	121×10^9/l
Na^+	138 mmol/l
K^+	5.2 mmol/l

WCC	10.5×10^9/l
PLT	121×10^9/l
Na^+	138 mmol/l
K^+	5.2 mmol/l
Creatinine	255 μmol/l

Which of the following would be in indicator for transplant according to the King's College Hospital criteria (non-paracetamol induced liver failure)?

A	Age 34
B	ALT 2300 U/l
C	Alkaline phosphatase 430 U/l
D	Bilirubin 320 μmol/l
E	INR 3.2

D Bilirubin 320 μmol/l

Bilirubin levels of >300 μmol/l is one of the prognostic indicators that determines referral for liver transplantation.

Several factors are important in the prognosis of patients with acute liver failure. Several criteria have been developed to predict when liver transplantation is indicated, the most widely accepted being the King's College Hospital criteria:

- INR >6.5; or,

Three of the following five criteria:

- Patient age <11 or >40;
- Serum bilirubin >300 micromoles per litre;
- Time from onset of jaundice to the development of coma >7 days;
- INR >3.5; or
- Drug toxicity, regardless of

- Drug toxicity, regardless of whether it was the cause of the acute liver failure.

E INR 3.2

INR of >6.5 is considered one of the positive indicators that determines referral for liver transplantation.

A Age 34

Age of less than 11 years or more than 40 years is considered to be one of the prognostic indicator criteria for liver transplantation.

B ALT 2300 U/l

ALT level is not included in the King's College Hospital criteria of prognostic indictors for liver transplantation.

C Alkaline phosphatase 430 U/l

A 62-year-old man presents with a 3-week history of watery diarrhoea and abdominal pain. Prior to this, he had been feeling generally unwell for a few months with malaise, anorexia, weight loss and increasing exertional dyspnoea. His only past medical history was hypertension which had been well controlled for many years on a beta-blocker. He did not smoke and rarely drank alcohol.

On examination, he was thin and wasted. He had marked facial telangiectasia, a raised jugular venous pressure and a palpable right ventricular heave. There was an ejection systolic murmur at the upper left sternal edge.

On chest auscultation, he had scattered expiratory wheeze. His abdomen was soft and not distended, with tender hepatomegaly but no palpable spleen. He had pitting ankle oedema bilaterally. Neurological examination did not reveal any abnormalities.

Investigation results are below:

Investigation results are below:

Haemoglobin (Hb)	11.2 g/dl
White cell count	7.0×10^9/l
Platelets	300×10^9/l
Mean corpuscular volume (MCV)	86 fl
Na^+	135 mmol/l
K^+	3.8 mmol/l
Urea	5.2 mmol/l
Ca^{2+}	2.34 mmol/l
Creatinine	110 μmol/l
Bilirubin	20 μmol/l
Alkaline phosphatase	160 IU/l
Aspartate transaminase (AST)	42 IU/l
Albumin	34 g/l
Gamma-glutamyl	72 IU/l

Gamma-glutamyl transferase	72 IU/l
Chest radiograph	Prominent pulmonary artery, clear lung fields
Electrocardiogram (ECG)	Sinus rhythm, right ventricular hypertrophy

Which investigation would be most useful in making the diagnosis?

A	24 h urine collection for vanillylmandelic acid (VMA)
B	Stool microscopy and culture
C	24 h urine collection for 5-hydroxyindoleacetic acid (5-HIAA)
D	Colonoscopy

C 24 h urine collection for 5-hydroxyindoleacetic acid (5-HIAA)

Carcinoid syndrome is caused by tumours originating from enterochromaffin cells which secrete 5-HT (serotonin) as well as other hormones, such as kinins and histamine. Patient presents with paroxysmal facial flushing, wheeze, abdominal pain, watery diarrhoea and weight loss. Diagnosis is made by an elevated 24 h urinary excretion of 5-hydroxyindoleactic acid (5-HIAA) in combination with ultrasonography to visualise the liver metastases.

A 24 h urine collection for vanillylmandelic acid (VMA)

24 h urine collection for vanillylmandelic acid (VMA), catecholamines and metanephrines are standard tests for the diagnosis of pheochromocytoma, a tumour of

pheochromocytoma, a tumour of sympathetic nervous system. This tumour is characterized by headache, hypertension, perspiration, palpitation and anxiety. VMA is an end staged metabolite of catecholamines, epinephrine and norepinephrine.

B	Stool microscopy and culture

Stool should be sent for microscopy and culture, if diarrhoea persists for more than a week. Stool evaluation will be useful in this case, however, it is not the best choice of investigation leading to a definitive diagnosis.

D	Colonoscopy

In most patients with chronic persistent diarrhea diarrhea of more than 4 weeks) , Colonoscopy is indicated with a mucosal biopsy to exclude inflammatory bowel disease, colonic carcinoma and microscopic colitis.

A 52-year-old man with chronic renal impairment and previous splenectomy for hereditary spherocytosis presents to the Emergency Department with fever and rigors. He has been complaining of right upper quadrant pain over the past few days. His wife tells you that he has been avoiding fatty foods recently as he feels nauseous and sometimes vomits after eating them.

On examination, he is pyrexial (39.2 °C) with BP 105/70 mmHg, pulse 102/min. There is obvious right upper quadrant tenderness.

Investigations:

Hb	11.9 g/dl
WCC	13.2×10^9/l
PLT	193×10^9/l
Na^+	139 mmol/l
K^+	4.5 mmol/l
Creatinine	134 µmol/l

Which of the following would be the

WCC	13.2×10^9/l
PLT	193×10^9/l
Na^+	139 mmol/l
K^+	4.5 mmol/l
Creatinine	134 μmol/l

Which of the following would be the most appropriate antibiotic intervention?

A Gentamicin

B Ciprofloxacin

C Erythromycin

D Vancomycin

E Amoxycillin

A 52-year-old man with chronic renal impairment and previous splenectomy for hereditary spherocytosis presents to the Emergency Department with fever and rigors. He has been complaining of right upper quadrant pain over the past few days. His wife tells you that he has been avoiding fatty foods recently as he feels nauseous and sometimes vomits after eating them.

On examination, he is pyrexial (39.2 °C) with BP 105/70 mmHg, pulse 102/min. There is obvious right upper quadrant tenderness.

Investigations:

Hb	11.9 g/dl
WCC	13.2×10^9/l
PLT	193×10^9/l
Na^+	139 mmol/l
K^+	4.5 mmol/l
Creatinine	134 μmol/l

Which of the following would be the

B Ciprofloxacin

He is at increased risk of gallstones due to haemolysis related to his hereditary spherocytosis. It is likely that the presence of stones within the bile duct has led to ascending infection. Ciprofloxacin has a broad spectrum of activity including against *Streptococcus*, *Pseudomonas*, *Staphylococcus epidermidis* and Gram-negative organisms, and it is therefore the default choice here. Antibiotic treatment is usually followed by ERCP and sphincterotomy to allow any stones or sludge to pass.

A Gentamicin

This is an alternative although it must be carefully dosed given that creatinine is already elevated, blood pressure is at the lower end of the normal range and there is potential Gram-negative sepsis.

C Erythromycin

C Erythromycin

Erythromycin isn't an appropriate choice here because it has poor coverage against potential Gram-negative pathogens.

D Vancomycin

Like gentamicin, vancomycin requires dose adjustment for kidney disease and is potentially nephrotoxic; it's therefore a less appropriate choice versus ciprofloxacin.

E Amoxycillin

There is extensive resistance to amoxicillin amongst *Pseudomonas* and Gram-negatives, and so it isn't an appropriate choice here.

20510

Rate this question:

A 45-year-old woman attended the Emergency Department with a 4-h history of acute severe central abdominal pain that was colicky in nature and associated with nausea and vomiting.

Other than hypertension, for which she had recently started a beta-blocker and an angiotensin-converting enzyme inhibitor, she was fit and well with no past medical or surgical history and no family history of note.

Her plain abdominal X-ray is shown below:

What is the most likely diagnosis?

What is the most likely diagnosis?

A	Ogilvie syndrome
B	Angio-oedema of the bowel
C	Gallstone ileus
D	Adhesions
E	Irritable bowel syndrome

70166

Submit

B Angio-oedema of the bowel

Angio-oedema is a rare but recognised cause of small bowel obstruction. Hereditary forms of the disease may occur in association with C1 esterase deficiency; such cases are likely to present earlier in life, and are usually associated with a family history. The clue in this scenario is the recent use of ACE inhibitors, as these are the drugs most commonly implicated in non-hereditary angio-oedema. Symptoms may occur between a matter of minutes up to many years after starting drug treatment, but usually occur within a few weeks of starting (or taking an increased dose of) the ACE inhibitor. The condition is related to low levels of angiotensin II and a consequent increase in bradykinins. Alternative drugs should be used to minimise the risk of recurrence.

A Ogilvie syndrome

The abdominal X-ray shown demonstrates small bowel obstruction. This makes Ogilvie syndrome unlikely, as this is a condition of chronic intestinal pseudo-obstruction that tends to first present with features of small and large bowel obstruction, and tends to be much less acute in onset than in the scenario here.

C	Gallstone ileus

Large gallstones may erode from the gallbladder directly into the small bowel, forming a fistulous connection. Subsequent intestinal obstruction may occur as the gallstone impacts. This occurs most often at the ileocaecal valve. Such stones may occasionally be seen on X-rays but often are not, as these tend not to be calcified. As such, CT is usually the means by which the diagnosis is made. In the scenario described, there is neither any history given to suggest gallstone disease, nor any radiological signs that might support this as the diagnosis.

demonstrates small bowel obstruction. This makes Ogilvie syndrome unlikely, as this is a condition of chronic intestinal pseudo-obstruction that tends to first present with features of small and large bowel obstruction, and tends to be much less acute in onset than in the scenario here.

C	Gallstone ileus

Large gallstones may erode from the gallbladder directly into the small bowel, forming a fistulous connection. Subsequent intestinal obstruction may occur as the gallstone impacts. This occurs most often at the ileocaecal valve. Such stones may occasionally be seen on X-rays but often are not, as these tend not to be calcified. As such, CT is usually the means by which the diagnosis is made. In the scenario described, there is neither any history given to suggest gallstone disease, nor any radiological signs that might support this as the diagnosis.

D	Adhesions

CT is usually the means by which the diagnosis is made. In the scenario described, there is neither any history given to suggest gallstone disease, nor any radiological signs that might support this as the diagnosis.

D	Adhesions

Adhesions are very unlikely to be the cause of obstruction in people without a history of abdominal surgery (although rarely, idiopathic fibrous bands are seen at laparotomy for small bowel obstruction).

E	Irritable bowel syndrome

Irritable bowel syndrome will not cause features of a mechanical obstruction.

70166

Rate this question:

Next Question

A 60-year-old man presents with a 6-week history of dysphagia for solids, poor appetite and weight loss. He has no significant past medical history but admits that he has suffered from indigestion and heartburn for many years and has been self-medicating with antacid tablets and Gaviscon. He smokes 20 cigarettes per day and consumes approximately 20 units of alcohol per week. He is referred for endoscopy, which reveals a tumour within the lower third of the oesophagus.

What is the most likely aetiology of this tumour?

A	Barrett's oesophagus
B	HPV virus exposure
C	Candidal oesophagitis
D	Achalasia

with antacid tablets and Gaviscon. He smokes 20 cigarettes per day and consumes approximately 20 units of alcohol per week. He is referred for endoscopy, which reveals a tumour within the lower third of the oesophagus.

What is the most likely aetiology of this tumour?

A	Barrett's oesophagus
B	HPV virus exposure
C	Candidal oesophagitis
D	Achalasia
E	*pylori* infection

9520

Submit

smokes 20 cigarettes per day and consumes approximately 20 units of alcohol per week. He is referred for endoscopy, which reveals a tumour within the lower third of the oesophagus.

What is the most likely aetiology of this tumour?

Your answer was correct

A	Barrett's oesophagus
B	HPV virus exposure
C	Candidal oesophagitis
D	Achalasia
E	*pylori* infection

Explanation

A	Barrett's oesophagus

A Barrett's oesophagus

Chronic acid reflux predisposes to the development of Barrett's oesophagus, where the normal oesophageal squamous epithelial lining is replaced with metaplastic columnar epithelium. In this case the self-medication for a number of years with anti-indigestion medication is likely to represent significant long-term acid exposure.

B HPV virus exposure

Although HPV virus exposure is an emergent risk factor for oesophageal cancer, in this case smoking and alcohol consumption are much more likely significant risk factors.

C Candidal oesophagitis

Candida oesophagitis is a cause of acute symptoms of indigestion; chronic carriage is usually not seen in immunocompetent patients, where they present for therapy early

C Candidal oesophagitis

Candida oesophagitis is a cause of acute symptoms of indigestion; chronic carriage is usually not seen in immunocompetent patients, where they present for therapy early.

D Achalasia

Achalasia presents with long-term symptoms of dysphagia for both liquids and solids, is due to lower oesophageal spasm, and is not associated with significant weight loss.

E *pylori* infection

H. pylori infection is a risk factor for both peptic ulcer disease and gastric lymphoma, but isn't considered a significant risk factor for oesophageal cancer.

9520

Rate this question:

A 36-year-old woman with a 15-year history of severe ileo-colonic Crohn's disease is admitted for assessment and management of a severe flare-up of her disease. Her symptoms are severe lower abdominal pain, diarrhoea, weight loss and lethargy. She has also recently developed a vesico-colic fistula.

She is currently taking mycophenolate mofetil (MMF), which had been controlling her symptoms for the last few months, but was now losing its efficacy. Her treatment history consists of multiple courses of steroids which, when tapered off resulted in severe disease recurrence. She also failed on azathioprine and 6-mercaptopurine and an elemental diet.

She had an ileal segmental resection with end-to-end anastomosis 8 years ago. Her blood tests show a normochromic normocytic anaemia, leucocytosis, elevated erythrocyte sedimentation rate (ESR) and C-reactive protein (CRP) and a low albumin.

normochromic normocytic anaemia, leucocytosis, elevated erythrocyte sedimentation rate (ESR) and C-reactive protein (CRP) and a low albumin.

What is the most appropriate next line as steroid-sparing therapy?

A	Oral ciclosporin
B	Intravenous infliximab
C	Total colectomy with ileo-anal pouch formation
D	Alpha-interferon therapy
E	Intravenous cyclophosphamide

6749

Submit

A 36-year-old woman with a 15-year history of severe ileo-colonic Crohn's disease is admitted for assessment and management of a severe flare-up of her disease. Her symptoms are severe lower abdominal pain, diarrhoea, weight loss and lethargy. She has also recently developed a vesico-colic fistula.

She is currently taking mycophenolate mofetil (MMF), which had been controlling her symptoms for the last few months, but was now losing its efficacy. Her treatment history consists of multiple courses of steroids which, when tapered off resulted in severe disease recurrence. She also failed on azathioprine and 6-mercaptopurine and an elemental diet.

She had an ileal segmental resection with end-to-end anastomosis 8 years ago. Her blood tests show a normochromic normocytic anaemia, leucocytosis, elevated erythrocyte sedimentation rate (ESR) and C-reactive protein (CRP) and a low

B Intravenous infliximab

Infliximab is a biological therapy for Crohn's disease and is a monoclonal antibody to the cytokine tumour necrosis factor-alpha. It is licensed for use in the management of steroid- and immunosuppressant-resistant Crohn's disease. It is also particularly useful in healing fistulae. It has been reported to induce a remission in 60–80% of patients. If the patient responds to the initial dose, then the usual treatment regime is a further four infusions at 8-weekly intervals. Allergic reactions are seen in 5% of cases. It is important to exclude tuberculosis prior to starting this treatment as it can cause reactivation.

A Oral ciclosporin

Ciclosporin is a treatment option for ulcerative colitis rather than Crohn's disease.

C Total colectomy with ileo-anal

failed. Surgery is also necessary as an emergency treatment for GI obstruction from stricturing or bowel perforation. As surgery is never curative, it should be reserved after medical options have been exhausted.

D	Alpha-interferon therapy

Alpha-interferon therapy is appropriate in CML, hairy cell leukaemia, follicular lymphoma and chronic hepatitis B and C. It is not useful in Crohn's disease.

E	Intravenous cyclophosphamide

Cyclophosphamide is a chemotherapeutic agent that can be used against rheumatoid arthritis, vasculitis and in various forms of leukaemia and lymphoma. It should not be used in Crohn's disease.

6749

Rate this question:

A 32-year-old woman comes to the clinic with chronic diarrhoea, which she finds hard to flush away. She has visited the general practitioner (GP) three times in the past year and has been told that she has irritable bowel syndrome, but she is increasingly tired and lethargic.

Investigations:

Hb	10.6 g/dl (MCV 106 fl)
WCC	5.0×10^9/l
PLT	203×10^9/l
Na+	139 mmol/l
K+	4.5 mmol/l
Creatinine	100 μmol/l
Albumin	29 g/l
Anti-TTG antibody	+

Which of the following is the most likely diagnosis?

K+	4.5 mmol/l
Creatinine	100 µmol/l
Albumin	29 g/l
Anti-TTG antibody	+

Which of the following is the most likely diagnosis?

A Crohn's disease

B Pancreatic insufficiency

C Coeliac disease

D Lactose intolerance

E Irritable bowel syndrome

20613

Submit

C Coeliac disease

The presence of positive anti-TTG antibodies, probable B_{12}/folate deficiency and diarrhoea that is difficult to flush away raises the possibility of malabsorption due to coeliac disease. Diagnosis is confirmed with small bowel biopsy, which is likely to reveal villous atrophy. Treatment is with gluten exclusion. Long-term risks associated with coeliac disease include oesophageal carcinoma and small bowel lymphoma, particularly in patients who fail to follow the gluten-free regime.

A Crohn's disease

Crohn's disease is not associated with anti-TTG antibody positivity and it is unlikely for two diagnoses to co-exist in this patient. The pattern of diarrhoea is very suggestive of fat malabsorption, which fits best with coeliac disease.

B	Pancreatic insufficiency

Although pancreatic insufficiency can lead to fat malabsorption, discrete episodes of pancreatitis leading to exocrine failure would be expected and anti-TTG antibody would likely be negative.

D	Lactose intolerance

Lactose intolerance is not related to anti-TTG antibodies, although it can present with symptoms of malabsorption. It responds to avoidance of dairy products.

E	Irritable bowel syndrome

The abnormal investigations here essentially rule out IBS as an underlying diagnosis.

20613

Rate this question:

Next Question

A 74-year-old man presents to the Emergency Department with inability to swallow either solids or liquids for the past 3 days. On further questioning, he admits to having progressive difficulty, first for solids then for liquids, with respect to swallowing over the last 4 months.

He has lost 5 kg in weight. He has a 60 pack-year smoking history and drinks 8 units of spirits per day.

Examination reveals a BP of 110/79 mmHg, pulse is 85/min and regular and he looks dehydrated. His BMI is 19, he has an irregular liver edge and a large left supraclavicular lymph node is palpable.

Investigations:

Hb	8.5 g/dl
WCC	$12.3 \times 10^9/l$
PLT	$179 \times 10^9/l$
Na^+	137 mmol/l
K^+	4.3 mmol/l

Na^+	137 mmol/l
K^+	4.3 mmol/l
Creatinine	151 micromol/l
Urea	15.2 mmol/l
Albumin	27 g/l
ALT	282 U/l
ALP	321 U/l
Bilirubin	24 μmol/l
USS abdomen	Evidence of liver metastases
Upper GI endoscopy	Ulcerated lesion within the lower 1/3 of the oesophagus

Intravenous (iv) fluids have been commenced over the past 24 h.

Which of the the following is the most appropriate next intervention?

A	Local mucosal resection

abdomen	metastases
Upper GI endoscopy	Ulcerated lesion within the lower 1/3 of the oesophagus

Intravenous (iv) fluids have been commenced over the past 24 h.

Which of the the following is the most appropriate next intervention?

A	Local mucosal resection
B	Oesophagectomy
C	Oesophageal stenting
D	Photodynamic therapy
E	Trastuzumab

39050

Submit

6:11
tps://mypastest.pastest.com

Urea	15.2 mmol/l
Albumin	27 g/l
ALT	282 U/l
ALP	321 U/l
Bilirubin	24 μmol/l
USS abdomen	Evidence of liver metastases
Upper GI endoscopy	Ulcerated lesion within the lower 1/3 of the oesophagus

Intravenous (iv) fluids have been commenced over the past 24 h.

Which of the the following is the most appropriate next intervention?

Your answer was correct

A Local mucosal resection

C Oesophageal stenting

Oesophageal stenting can be used as a long-term palliation for dysphagia, as seen in this patient. The primary goal of oesophageal stenting in patients with advanced disease is to relieve dysphagia and to prevent malnutrition. In comparison to parenteral nutrition, endoscopic stent placement significantly improves the quality of life of patients by restoring the ability of oral intake of fluids and food.

A Local mucosal resection

The cancer has already progressed too far for this to be effective. Mucosal resection should be considered in patients with oesophageal mucosal cancer and patients with early stage of carcinoma. NICE guidelines (see weblink below) also point out that role of mucosal section in patients with Barrett's oesophagus, and ablation of residual areas of dysplasia requires further research.

B	Oesophagectomy

Oesophagectomy is no longer considered for palliation of symptoms. Thus, this option cannot be used in this patient. It is more useful in the early stages of carcinoma.

D	Photodynamic therapy

Photodynamic therapy is used as a debulking option, but because this patient has an advanced case and disease has spread too far, this option would not be effective. Endoscopic therapies can be offered to patients with high-grade dysplasia and intramucosal cancer (T1a), as an alternative to oesophagectomy. These therapies include endoscopic mucosal resection and ablative therapies (radiofrequency ablation or photodynamic therapy). Radiofrequency ablation alone is considered for flat, high-grade dysplasia.

alternative to oesophagectomy. These therapies include endoscopic mucosal resection and ablative therapies (radiofrequency ablation or photodynamic therapy). Radiofrequency ablation alone is considered for flat, high-grade dysplasia.

E	Trastuzumab

Trastuzumab is used in HER 2-positive cancers at the oesophago-gastric junction, in combination with cisplatin/fluropyrimidine. There is a documented improvement in disease-free survival and overall survival with the use of this regimen. However, chemotherapy is not the best option in this patient due to his poor functional status.

39050

Rate this question:

Next Question

A 36-year-old shop assistant presents with a 3-month history of diarrhoea. Her symptoms include increased stool frequency (particularly in the mornings) bloating and vague abdominal pains. The stool is soft with no blood.

On examination, her BP is 112/72 mmHg, pulse is 80/min and regular, she is thin with a body mass index (BMI) of 22, but apparently her weight is stable.

Initial blood tests arranged by the general practitioner (GP) are outlined below.

Urea and electrolytes	Normal
Hb	10.0 g/dl
WCC	6.0×10^9/l
PLT	350×10^9/l
MCV	100 fl
B_{12}	160 ng/l
Serum folate	1.5 μg/l

Serum folate	1.5 µg/l
Serum total protein	63 g/l
IgG	12.0 g/l (6.0 - 13.0)
IgA	0.2 g/l (0.8 - 3.0)
IgM	1.5g/l (0.4 - 2.5)

Which one of the following would be the most useful diagnostic test?

A	Anti-tissue transglutaminase IgA antibodies
B	Anti-endomysial IgA antibodies
C	Colonoscopy
D	Upper gastrointestinal tract endoscopy with duodenal biopsies

D Upper gastrointestinal tract endoscopy with duodenal biopsies

Young people with diarrhoea should all be screened for coeliac disease, which is the commonest cause of small bowel disease in the West. The best initial screening tests are serological, either tissue transglutaminase or anti-endomysial antibodies, but these tests may be invalid in the presence of selective immunoglobulin A (IgA) deficiency, which is much commoner in patients with coeliac disease (2.6%). More modern tests now incorporate testing for IgG anti-TTG antibodies, which is a valid screening test. However, from the options provided here upper gastrointestinal tract endoscopy with duodenal biopsies is the best investigation to exclude coeliac disease.

The symptoms in this case are non-specific and in the absence of abnormalities in screening blood tests would be sufficient to make a diagnosis of functional bowel disease

abnormalities in screening blood tests would be sufficient to make a diagnosis of functional bowel disease without further investigation in someone under the age of 45 years. In this case however there is evidence of some small bowel malabsorption (folate deficiency) which would warrant further investigation. Small bowel examination would include in this case duodenal biopsy to exclude coeliac disease, and barium follow-through to image the terminal ileum.

A	Anti-tissue transglutaminase IgA antibodies

This would be a good initial screening test but may invalid in the presence of selective IgA deficiency which is seen in this patient.

B	Anti-endomysial IgA antibodies

This would be a good initial screening test but may invalid in the presence of selective IgA deficiency which is seen

B	Anti-endomysial IgA antibodies

This would be a good initial screening test but may invalid in the presence of selective IgA deficiency which is seen in this patient.

C	Colonoscopy

In the absence of red flag symptoms, such as weight loss, symptoms overnight and iron deficiency anaemia, colonoscopy would not be required in this patient.

E	Three-day faecal fat collection

Three-day faecal fat determination is unpleasant and has a low yield in the investigation of malabsorption and is not recommended for routine use.

33005

Rate this question:

A 34-year-old waiter presents with several weeks history of steatorrhoea and abdominal pain. He also reports 4 kg unintentional weight loss in the past 6 months. He has a long history of alcohol dependence and was recently diagnosed with diabetes by his GP.

Examination reveals a palpable epigastric abdominal mass.

Which investigation is most likely to confirm the diagnosis?

A	Endoscopic retrograde cholangiopancreatography (ERCP)
B	CT abdomen
C	CA 19-9 levels
D	Faecal elastase
E	Abdominal ultrasound

A 34-year-old waiter presents with several weeks history of steatorrhoea and abdominal pain. He also reports 4 kg unintentional weight loss in the past 6 months. He has a long history of alcohol dependence and was recently diagnosed with diabetes by his GP.

Examination reveals a palpable epigastric abdominal mass.

Which investigation is most likely to confirm the diagnosis?

Your answer was incorrect

A	Endoscopic retrograde cholangiopancreatography (ERCP)
B	CT abdomen
C	CA 19-9 levels
D	Faecal elastase
E	Abdominal ultrasound

B CT abdomen

The history of long-standing alcohol excess, coupled with a recent diagnosis of diabetes, suggests an underlying diagnosis of chronic pancreatitis. The clinical examination suggests the development of a pancreatic pseudocyst and so a CT abdomen is the best investigation for detecting pancreatic pathology of this nature.

A Endoscopic retrograde cholangiopancreatography (ERCP)

ERCP is no longer used as primary diagnostic test as it is an invasive test that carries a 5% risk of causing pancreatitis.

C CA 19-9 levels

CA 19-9 is a tumour marker which, if elevated, can be indicative of pancreatic cancer, but should not be

pancreatitis.

C	CA 19-9 levels

CA 19-9 is a tumour marker which, if elevated, can be indicative of pancreatic cancer, but should not be used in isolation to make a diagnosis.

D	Faecal elastase

This is a test performed for pancreatic insufficiency and would still not explain the epigastric mass seen in this case.

E	Abdominal ultrasound

This may be useful but will not give as much information as a CT scan.

2287

Rate this question:

A 50-year-old woman presents with a 1-year history of pruritus. She is otherwise asymptomatic. There is no other past medical history and she is not taking any regular medications. She is a non-smoker and does not drink any alcohol.

On examination, there is evidence of scratch marks and xanthelasma, but no features of chronic liver disease.

Investigations:

Hb	13.7 g/dl
WCC	9.0×10^9/l
PLT	200×10^9/l
Na^+	143 mmol/l
K^+	4.3 mmol/l
Creatinine	100 μmol/l
Urea	6.0 mmol/l
Billirubin	45 U/l
ALT	45 U/l
ALP	180 U/l

Billirubin	45 U/l
ALT	45 U/l
ALP	180 U/l
IgM	Raised
ANA	-

What is the most likely diagnosis?

A Primary biliary cirrhosis

B Sclerosing cholangitis

C Autoimmune hepatitis

D Non-alcoholic steatohepatitis (NASH)

E Drug-induced hepatitis

A Primary biliary cirrhosis

The combination of pruritus, xanthelasma and elevated ALP and IgM is highly specific for primary biliary cirrhosis. Anti-mitochondrial antibodies are highly specific and are seen in 95% of patients with PBC. Pruritis is the commonest presenting symptom of PBC, and the bilirubin can be often normal at presentation. It is raised late in the disease and is indicative of a poor prognosis. Ursodeoxycholic acid (UDCA) is the only approved therapy. Bile acid sequestrants such as cholestyramine can help with pruritis.

B Sclerosing cholangitis

This is not associated with xanthelasma but with inflammatory bowel disease, particularly ulcerative colitis.

C Autoimmune hepatitis

colitis.

C	Autoimmune hepatitis

This is associated with raised IgG levels, not those of IgM and ALP.

D	Non-alcoholic steatohepatitis (NASH)

NASH is less likely here because again you would expect a raised ALT/ALP ratio and it would not explain the raised IgM levels.

E	Drug-induced hepatitis

The question tells you that the patient is not on any regular medications.

2313

Rate this question:

Next Question

A woman who is 34 weeks' pregnant is admitted with anorexia, nausea and vomiting. She is started on intravenous (iv) fluids and ranitidine. Six hours later, her vomiting persists and she becomes confused. She is a non-smoker and does not drink any alcohol.

On examination, she is afebrile. Her blood pressure is 160/90 mmHg and she is tachycardic. Cardiovascular and chest examinations are normal. Her abdomen is tender in the right upper quadrant but there is no rebound or rigidity. There are no focal neurological signs.

Investigations:

Hb	12.0 g/dl
WBC	20.0×10^9/l (75% neutrophils)
PLT	160×10^9/l
MCV	82 fl
INR	1.6
Na^+	133 mmol/l

Na^+	133 mmol/l
K^+	4.5 mmol/l
Urea	13.0 mmol/l
Creatinine	124 μmol/l
Bilirubin	40 μmol/l
ALP	201 U/l (30–150)
ALT	520 U/l (5-35)
GGT	101 U/l (4.35)
Albumin	32 g/l
Blood glucose	3.9 mmol/l
Blood film	Schistocytes seen
Urinalysis	2+ protein

Ultrasound scan of the abdomen shows fatty changes in the liver. She is given FFP and iv dextrose.

Which of the following is the most appropriate next management step?

Blood film	Schistocytes seen
Urinalysis	2+ protein

Ultrasound scan of the abdomen shows fatty changes in the liver. She is given FFP and iv dextrose.

Which of the following is the most appropriate next management step?

A	Broad-spectrum antibiotics
B	Urgent liver biopsy to determine prognosis
C	Urgent abdominal CT with contrast
D	Upper GI endoscopy
E	Prompt delivery by caesarean section

E Prompt delivery by caesarean section

This patient has acute fatty liver disease of pregnancy (AFLP) and disseminated intravascular coagulation. It is a condition of the third trimester and is common in first pregnancies and multiple pregnancies. The diagnosis is a clinical one and there is characteristically an elevated white blood cell (WBC) count, low glucose, low albumin and evidence of disseminated intravascular coagulation. The management involves aggressive correction of hypoglycaemia and coagulopathy followed by expeditious delivery which results in the dramatic recovery of the mother. The development of hepatic failure requires the patient to be transferred to a liver unit for assessment for transplantation. The haemolysis, elevated liver enzymes and low platelet count syndrome (HELLP) is associated with pre-eclampsia and there is a degree of overlap with haemolytic uraemic syndrome and

is associated with pre-eclampsia and there is a degree of overlap with haemolytic uraemic syndrome and thrombotic thrombocytopenic purpura.

A	Broad-spectrum antibiotics

There is no indication of acute infection and with hypertension, abnormal LFTs and evidence of haemolysis, broad-spectrum antibiotics are not of benefit.

B	Urgent liver biopsy to determine prognosis

There are inherent risks of liver biopsy with respect to bleeding in this patient, and the biopsy will almost certainly show evidence of fatty infiltration and hepatocellular necrosis. As such, it won't contribute to the diagnosis.

C	Urgent abdominal CT with contrast

A 19-year-old student presents to the university health service complaining of flu-like symptoms, lethargy and jaundiced sclerae and an inability to eat due to a sore throat. He remembered that his father may have suffered from a liver condition.

On examination, he is pyrexial 38.2 °C, BP is 110/70 mmHg, pulse is 82/min and regular. He has signs of pharyngitis on examination of his throat.

Investigations reveal:

ALT	23 U/l
AST	28 U/l
Bilirubin	78 μmol/l
Albumin	41g/l

Which of the following is the most appropriate next intervention in this case given the most likely diagnosis?

A	Phenobarbitone

8:20
tps://mypastest.pastest.com

Albumin	41g/l

Which of the following is the most appropriate next intervention in this case given the most likely diagnosis?

A Phenobarbitone

B Diazepam

C Observation

D Hepatic ultrasound scan

E Hepatitis screen

33048

Submit

C Observation

The clinical picture is highly suggestive of Gilbert's syndrome, and as such, observation and supportive therapy for the acute flu-like illness is the management of choice. When jaundice is severe (as occurs only rarely in Gilbert's), phenobarbitone can rapidly decrease unconjugated serum bilirubin levels. This condition is autosomal recessive and is characterised by unconjugated hyperbilirubinaemia caused by impaired glucuronyl transferase activity. Jaundice may be precipitated by fasting, excessive alcohol consumption or acute illness. Other liver function tests apart from bilirubin level are generally normal. It is likely that a viral illness has led to a period of fasting and the symptoms seen here.

A Phenobarbitone

Phenobarbitone is usually only considered for severe jaundice. At this

considered for severe jaundice. At this stage it's more appropriate to manage this patient conservatively.

B Diazepam

Phenobarbitone, rather than diazepam is used as an enzyme inducer in the treatment of acute Gilbert's syndrome.

D Hepatic ultrasound scan

Given transaminases are normal, and this patient has evidence of an inherited liver problem, Gilbert's is much more likely than obstructive liver disease.

E Hepatitis screen

Isolated elevated bilirubin in the context of an inherited liver condition is consistent with Gilbert's syndrome, not with hepatitis. In hepatitis a marked elevation in transaminases would be expected.

A 55-year-old woman was admitted via the Emergency Department complaining of intermittent epigastric pain. She had had a cholecystectomy 1 year ago for these symptoms but continued to have pain after the procedure. The pain was severe, typically coming on when she was eating, radiating to the back and was accompanied by nausea and sometimes vomiting. It tended to last for several hours and did not vary in intensity. She has had five such attacks over the last year.

Investigations:

Bilirubin	21 μmol/l
AST	100 U/l
ALT	110 U/l
ALP	176 U/l
Amylase	220 U/l

An ultrasound scan showed a moderately dilated common bile duct (12 mm) but no stones were seen.

moderately dilated common bile duct (12 mm) but no stones were seen. Consequently, she underwent an endoscopic retrograde cholangiogram which, again showed mildly dilated ducts. A sphincterotomy was performed along with trawling of the bile duct, again revealing no cause. Post-procedure she developed acute pancreatitis from which she recovered with conservative management. Subsequently, her symptoms resolved.

Which of the following is the most likely diagnosis?

A	Recurrent biliary stones
B	Non-ulcer dyspepsia
C	Chronic pancreatitis
D	Sphincter of Oddi dysfunction
E	Primary sclerosing cholangitis

D Sphincter of Oddi dysfunction

The symptoms described by this woman and her response to sphincterotomy are characteristic of sphincter of Oddi dysfunction (SOD), which causes non-calculous obstruction of flow of biliary and/or pancreatic fluid.

In SOD, the sphincter is hypertonic (>40 mmHg on manometry) and may also be dyskinetic. SOD typically occurs in middle-aged women, but may present in any age group, including children. The usual presenting symptoms are those of biliary-type pain, i.e. epigastric or right hypochondrial pain that is severe, steady and may radiate to the back or shoulder.

Since the symptoms of SOD are usually so similar to that of gallstone disease, the diagnosis of SOD is often only made after cholecystectomy. SOD may also manifest as recurrent episodes of apparently idiopathic pancreatitis, but jaundice is rare.

There are three categories of SOD:

- Type I: People with typical biliary pain, abnormal liver enzymes and radiological evidence of impaired biliary drainage
- Type II: People with typical biliary pain, with either abnormal liver enzymes or radiological evidence of impaired biliary drainage
- Type III: People with typical biliary pain, but no other abnormalities.

Definitive diagnosis of SOD is made by manometry, although delayed drainage of contrast at ERCP is also a classic sign (>45 min). Rates of post-ERCP pancreatitis are increased five-fold in people with SOD.

Treatment of SOD with smooth muscle relaxants (such as nifedipine) improves symptoms in a proportion of affected people, but at rates similar to placebo

There are three categories of SOD:

- Type I: People with typical biliary pain, abnormal liver enzymes and radiological evidence of impaired biliary drainage
- Type II: People with typical biliary pain, with either abnormal liver enzymes or radiological evidence of impaired biliary drainage
- Type III: People with typical biliary pain, but no other abnormalities.

Definitive diagnosis of SOD is made by manometry, although delayed drainage of contrast at ERCP is also a classic sign (>45 min). Rates of post-ERCP pancreatitis are increased five-fold in people with SOD.

Treatment of SOD with smooth muscle relaxants (such as nifedipine) improves symptoms in a proportion of affected people, but at rates similar to placebo overall. Endoscopic sphincterotomy is

often effective in treating people with type I SOD, and may help people with type II SOD, but is usually of no benefit in people with type III SOD. Botulinum toxin injection into the sphincter of Oddi may have a role in treatment, particularly for people with type III SOD.

A Recurrent biliary stones

Recurrent biliary stones may be ruled out given that none were seen on her ERCP.

B Non-ulcer dyspepsia

Non-ulcer dyspepsia does not explain this woman's abnormal liver enzymes and imaging findings.

C Chronic pancreatitis

No typical risk factors for chronic pancreatitis are given, and it is unusual for chronic pancreatitis to cause such marked biliary dilatation.

A 54-year-old woman, who works as an accountant, presents to her general practitioner (GP) with fatigue. She has also noticed troublesome itching over the past few months, which is worse at night and in hot weather. She is teetotal.

Examination reveals jaundice, evidence of excoriation, telangiectasia and mild ascites. Alkaline phosphatase is elevated at 242 IU/L.

Which of the following autoantibodies is most likely to be positive in this case?

A	Anti-thyroid antibody
B	Anti-endomysial antibody
C	Anti-smooth muscle antibody
D	Anti-mitochondrial antibodies
E	Anti-nuclear antibodies

D Anti-mitochondrial antibodies

Given this clinical picture the most likely diagnosis is primary biliary cirrhosis, and AMAs are found in 95% of patients with the condition. Onset typically occurs between the ages of 30 and 65 years, the condition is much more common in women, and it may be asymptomatic or present most commonly with tiredness and itching. Ursodeoxycholic acid improves bilirubin and symptoms of jaundice, but may mask the need for transplantation. A limited number of studies have shown positive effects on survival although there is still some debate in this area. Liver transplantation is the definitive treatment and there is 85–90% post-transplant survival at 1 year. Overall, survival from time of diagnosis with primary biliary cirrhosis is put at between 7 and 16 years.

A Anti-thyroid antibody

Anti-thyroid antibodies are found in

Anti-thyroid antibodies are found in Grave's disease and Hashimoto's thyroiditis, a small percentage of patients with thyroid carcinoma, and approximately 3% of normal individuals.

B	Anti-endomysial antibody

Anti-endomysial antibodies are found in association with coeliac disease which is not suggested by the symptoms seen here. It is usually associated with weight loss and diarrhoea.

C	Anti-smooth muscle antibody

Anti-smooth muscle antibodies are associated with autoimmune hepatitis, not with primary biliary cirrhosis. In autoimmune hepatitis a hepatocellular picture of liver function test abnormalities would be expected.

E	Anti-nuclear antibodies

which is not suggested by the symptoms seen here. It is usually associated with weight loss and diarrhoea.

C	Anti-smooth muscle antibody

Anti-smooth muscle antibodies are associated with autoimmune hepatitis, not with primary biliary cirrhosis. In autoimmune hepatitis a hepatocellular picture of liver function test abnormalities would be expected.

E	Anti-nuclear antibodies

Anti-nuclear antibodies are less specific indicators of autoimmune disease, most likely to be associated with systemic lupus erythematosus.

33043

Rate this question:

Next Question

A 32-year-old woman has been referred to the clinic by her GP who suspects she may have irritable bowel syndrome. She suffers intermittent bouts of diarrhoea, problems with bloating, and flatulence. On further questioning, it transpires that she has been feeling a little tired over the past few months.

On examination, her BP is 125/72 mmHg, pulse is 72/min and regular. She looks a little pale, her BMI is 22. Abdominal examination is unremarkable.

Investigations:

Hb	10.5 g/dl
WCC	5.4×10^9/l
PLT	201×10^9/l
Na^+	139 mmol/l
K^+	4.1 mmol/l
Creatinine	110 μmol/l
Small	villous atrophy, increased

Na^+	139 mmol/l
K^+	4.1 mmol/l
Creatinine	110 µmol/l
Small bowel biopsy	villous atrophy, increased epithelial lymphocytes

Which of the following represents the most appropriate intervention?

A	Metronidazole
B	Lactose free diet
C	Gluten free diet
D	Doxycycline
E	Prednisolone

C Gluten free diet

This patient has symptoms consistent with coeliac disease. She is also anaemic, which likely reflects iron deficiency from malabsorption. Her small bowel biopsy shows increased intraepithelial lymphocytes and villous atrophy, which is characteristic of the condition. As such the most appropriate therapy is a trial of gluten free diet.

Coeliac disease is caused by an immune response to gluten exposure causing a small bowel enteropathy in patients with a genetic predisposition. It is associate with HLA-DR3 + DQ2. Diagnosis is made on the basis of serology (IgA for endomysial or tissue transglutaminase (EMA/TTG) and duodenal biopsy. NB there is an association with IgA deficiency. In these cases patients should be tested for IgG to tissue transglutaminase. (TG2). The histological findings are not pathognomic and may also be seen in other disorders, such as immune deficiency, AI enteropathy, tropical

deficiency, AI enteropathy, tropical sprue, Whipple's disease and microscopic colitis amongst others so combination with positive serology is key to the diagnosis.

A	Metronidazole

Metronidazole would be used to treat giardiasis, a protozoal infection that can cause chronic diarrhoea with bloating and malabsorption. However, there is no history of travel and although one can see an increase in intraepithelial lymphocytes, villous atrophy is not typical.

B	Lactose free diet

Lactose avoidance may be of value in patients with symptoms of irritable bowel syndrome, particularly those of an ethnic origin where congenital lactase deficiency is increased. An increase in intraepithelial lymphocytes may be seen in cow's milk hypersensitivity, but *not* villous

an ethnic origin where congenital lactase deficiency is increased. An increase in intraepithelial lymphocytes may be seen in cow's milk hypersensitivity, but *not* villous atrophy.

D	Doxycycline

Treatment with a tetracycline would be indicated in Whipple's disease, which is a differential for the finding of villous atrophy on small bowel biopsy. However, one would also see PAS positive macrophages on histology.

E	Prednisolone

Corticosteroids may be of value in Crohn's, but are not used in the management of coeliac disease. Histology in small bowel Crohn's might yield cryptitis or crypt abscesses in addition to intraepithelial lymphocytes.

21448

Rate this question:

A 29-year-old woman, who has previously stable Crohn's disease, presents with bloody diarrhoea. She is currently 11 weeks pregnant with her first child. She is opening her bowels some 10 times per day and is extremely troubled by her symptoms.

On examination, she is tender to PR.

Investigations:

Hb	10.9 g/dl
WCC	9.8×10^9/l
PLT	203×10^9/l
Na^+	140 mmol/l
K^+	3.9 mmol/l
Creatinine	110 μmol/l
Faecal occult blood test	+ to blood

Which of the following investigations is most appropriate?

A Barium enema

K^+	3.9 mmol/l
Creatinine	110 μmol/l
Faecal occult blood test	+ to blood

Which of the following investigations is most appropriate?

A Barium enema

B Barium follow through

C Flexible sigmoidoscopy

D Colonoscopy

E Upper GI endoscopy

21430

Submit

A 29-year-old woman, who has previously stable Crohn's disease, presents with bloody diarrhoea. She is currently 11 weeks pregnant with her first child. She is opening her bowels some 10 times per day and is extremely troubled by her symptoms.

On examination, she is tender to PR.

Investigations:

Hb	10.9 g/dl
WCC	9.8×10^9/l
PLT	203×10^9/l
Na^+	140 mmol/l
K^+	3.9 mmol/l
Creatinine	110 μmol/l
Faecal occult blood test	+ to blood

Which of the following investigations is most appropriate?

Your answer was incorrect

C Flexible sigmoidoscopy

This patient has distal disease as suggested by the bloody diarrhoea and tender rectal examination. A flexible sigmoidoscopy would in theory allow same day assessment of the distal colon from rectum to the splenic flexure to give a rapid assessment of severity and extent of her Crohn's disease. As she is opening her bowels 10 times per day no bowel preparation would be required and could also be done without the use of sedation/analgesia both of which would be preferred in pregnancy.

For more information see European Crohn's and Colitis guidelines - Gomollón, F et al. 3rd European Evidence-based Consensus on the Diagnosis and Management of Crohn's Disease 2016: Part 1: Diagnosis and Medical Management. *J Crohns Colitis* 2017; 11 (1): 3-25.

D Colonoscopy

D Colonoscopy

Whilst no link is established between colonoscopy and increased risk of miscarriage, the bowel preparation is much more severe than that for flexible sigmoidoscopy and the procedure causes significantly more discomfort. Full colonoscopy is also relatively contraindicated in an acute severe flare of colitis (and a stool frequency of 10 times per day would meet criteria) due to the increased perforation risk.

A Barium enema

Barium enemas are no longer recommended for the investigation of inflammatory bowel disease unless the patient cannot tolerate colonoscopy or MRI/CT enterography.

B Barium follow through

Barium follow through is used to assess for small bowel disease in

Barium follow through is used to assess for small bowel disease in Crohn's such as strictures. This investigation may be warranted if the patient had presented with obstructive symptoms (i.e. post-prandial abdominal pain). This patient has fresh red bleeding suggestive of distal/rectal disease therefore a barium follow through would not be helpful. Barium follow through has largely been superseded by MRI enterography.

E	Upper GI endoscopy

The patient presents with bloody diarrhoea suggesting distal disease. Patients with Crohn's disease presenting with dyspepsia, abdominal pain and vomiting may benefit from an upper GI endoscopy to assess for upper GI disease but these are not the predominant symptoms here and it is unlikely to add anything in this scenario.

21430

Rate this question:

A 34-year-old woman is investigated for iron deficiency anaemia. She has a past history of Crohn's disease for which she took azathioprine for up to 2 years during her late 20s, but her symptoms have been stable over the past few years on no regular medication. Her bowels are open 3-4 times per day with loose motion. She has no regular periods as she currently uses the progesterone-releasing IUD for contraception.

The only other history of note is epigastric pain for which her GP has prescribed a PPI.

On examination, her BP is 112/80 mmHg, pulse is 75/min and regular. She looks pale. Abdomen is soft and non tender and her BMI is 22.

Investigations;

Hb	94 g/l
MCV	76 fl
WCC	6.1×10^9/l
PLT	171×10^9/l

PLT	171×10^9/l
Na^+	139 mmol/l
K^+	4.5 mmol/l
Creatinine	90 micromol/l
Albumin	32 g/l
ALT	32 U/l
ALP	90 U/l
Ca^{++}	2.21 mmol/l
Barium follow-through	gastroduodenal stricture, confirmed to be ulcerated on endoscopy, biopsy appearance typical of active Crohn's disease

Which of the following is the most important step?

A	Endoscopic dilatation
B	IV iron transfusion

Barium follow-through	gastroduodenal stricture, confirmed to be ulcerated on endoscopy, biopsy appearance typical of active Crohn's disease

Which of the following is the most important step?

A	Endoscopic dilatation
B	IV iron transfusion
C	Prednisolone
D	Re-start azathioprine
E	Surgical resection

70914

Submit

ALT	32 U/l
ALP	90 U/l
Ca^{++}	2.21 mmol/l
Barium follow-through	gastroduodenal stricture, confirmed to be ulcerated on endoscopy, biopsy appearance typical of active Crohn's disease

Which of the following is the most important step?

Your answer was incorrect

A Endoscopic dilatation

B IV iron transfusion

C Prednisolone

D Re-start azathioprine

E Surgical resection

C Prednisolone

Prednisolone, is required for induction of immunosuppression given that this patient has been off medication for 2 years. Of course it's likely that azathioprine will be required over the longer term, although it's less efficient at achieving remission when used as initial monotherapy. .

E Surgical resection

Surgical resection, is incorrect. This is avoided if possible in Crohn's because of the risks associated with recurrent bowel resection and potential short bowel syndrome.

A Endoscopic dilatation

Endoscopic dilatation, is incorrect. Dilatation is reserved for cases of obstruction, not currently a concern.

B IV iron transfusion

A	Endoscopic dilatation

Endoscopic dilatation, is incorrect. Dilatation is reserved for cases of obstruction, not currently a concern.

B	IV iron transfusion

IV iron transfusion, is incorrect. This may be required, but it is more important to begin treatment for the underlying active gastroduodenal Crohn's.

D	Re-start azathioprine

Gastroduodenal stricture in Crohn's is rare, reported to occur in only 0.5-4% of patients. In the absence of obstruction, the mainstay of management is medical therapy. As this patient has been off therapy for up to 2 years, induction of immunosuppression followed by regular azathioprine, rather than azathioprine monotherapy is the most appropriate intervention.

A 42-year-old Turkish restaurant owner presents to the Emergency Department with a 12 h history of severe abdominal pain, fever and myalgia.

On examination, he is pyrexial, temperature 39 °C and has generalised abdominal tenderness and guarding. Bowel sounds are quiet. He has a healed laparotomy scar from a previous hospital admission with similar symptoms. The laparotomy was inconclusive.

On this occasion, plain abdominal X-ray is unremarkable. He is reviewed by the surgical team and commenced on broad-spectrum intravenous antibiotics. Eighteen hours after admission, his symptoms have resolved. He comments that his brother has also had previous hospital admissions with similar symptoms.

Which medication would you prescribe to affect long-term outcomes in this condition?

A Colchicine

8:43
tps://mypastest.pastest.com

admissions with similar symptoms.

Which medication would you prescribe to affect long-term outcomes in this condition?

A	Colchicine
B	Tramadol
C	Prednisolone
D	Diclofenac
E	Indometacin

9521

Submit

Previous Question Skip Question

Department with a 12 h history of severe abdominal pain, fever and myalgia.

On examination, he is pyrexial, temperature 39 °C and has generalised abdominal tenderness and guarding. Bowel sounds are quiet. He has a healed laparotomy scar from a previous hospital admission with similar symptoms. The laparotomy was inconclusive.

On this occasion, plain abdominal X-ray is unremarkable. He is reviewed by the surgical team and commenced on broad-spectrum intravenous antibiotics. Eighteen hours after admission, his symptoms have resolved. He comments that his brother has also had previous hospital admissions with similar symptoms.

Which medication would you prescribe to affect long-term outcomes in this condition?

Your answer was correct

A Colchicine

A Colchicine

This patient has familial Mediterranean fever (FMF), an inherited, autosomal recessive condition characterised by short, recurrent episodes of fever and peritonitis. Other associated symptoms include pleuritis, arthritis and skin rashes. It most commonly occurs in people of Mediterranean origin, but not exclusively. Attacks usually last 24–72 h. The abdominal symptoms often mimic an acute surgical abdomen and consequently many patients have undergone laparotomy. Despite the severity of the symptoms during an attack, patients quickly recover and are well between episodes. Colchicine is extremely effective in treating and preventing attacks of familial Mediterranean fever.

B Tramadol

Tramadol may exacerbate abdominal symptoms because of slowing GI transit, and can drive opiate addiction, and hence it is a suboptimal choice

C Prednisolone

Prednisolone may be used for severe acute episodes of Mediterranean fever during the short term, although where tolerated colchicine has a superior benefit risk profile, and is therefore the preferred choice.

D Diclofenac

Non-steroidals may be particularly useful in the treatment of spondyloarthritis associated with Mediterranean fever, although they don't affect the progression of other features of the condition.

E Indometacin

Indometacin is an intervention for pericarditis in FMF, although colchicine is also advised to impact on disease progression.

9521

Rate this question:

A 24-year-old man visited his general practitioner (GP) some 10 days after returning from holiday with his friends in Turkey. He admitted to drinking up to 10 pints of lager per day during his 2-week holiday and frequently bought food from street sellers.

Since his holiday, he has given up smoking as he said he did not enjoy it any more. There was a history of paracetamol use in the past few days for a sprained ankle sustained when slipping in the street, and there was some concern that he may have taken a couple of extra tablets. Most recently, he has been suffering from fever and anorexia.

On examination, he was jaundiced.

Investigations:

Serum bilirubin	345 µmol/l
Serum aspartate transaminase	400 IU/l

Which of the following investigations

Investigations:

Serum bilirubin	345 µmol/l
Serum aspartate transaminase	400 IU/l

Which of the following investigations is most likely to give the diagnosis?

A Conjugated bilirubin

B Clotting screen

C Paracetamol level

D Hepatitis serology

E Serum ammonia

33073

Submit

D Hepatitis serology

It seems likely that this man has an acute hepatitis. This is unlikely to be an acute alcohol-related phenomenon as he has taken some 10 days to present. The clue is in his visit to Turkey, where he is likely to have been exposed to hepatitis A. This is the commonest cause of viral hepatitis worldwide, transmitted via the faeco-oral route, and is associated with non-specific symptoms such as nausea, anorexia and distaste for cigarettes. Hepatitis A is not associated with progression to chronic liver disease. During the convalescent period, 5–15% of patients may have relapses of their hepatitis but these resolve spontaneously. Occasionally a more severe jaundice with prolonged cholestasis may occur over the course of 7–20 weeks. Mortality (due to fulminant hepatic necrosis) is rare at around 0.1%, but increases with age.

C Paracetamol level

In a patient presenting 10 days after his holiday, paracetamol levels are not of value in determining whether excess paracetamol during the trip contributed to his symptoms.

A Conjugated bilirubin

Given that transaminases are elevated, Gilbert's disease can be ruled out as a cause of his symptoms.

B Clotting screen

Although this man has acute hepatitis, synthetic liver function is highly unlikely to be affected and clotting won't reveal an underlying cause of liver disease.

E Serum ammonia

Serum ammonia is most useful in the evaluation of hepatic encephalopathy.

33073

Rate this question:

A 68-year-old man presents to the Accident and Emergency Department. He is unkempt and an alcoholic. He complains of fevers, weight loss and malaise over the past four months, and a dry cough with sputum which is occasionally blood-stained.

On examination, he is febrile at 37.5 °C and has moderate ascites.

Investigations:

Alkaline phosphatase	220 u/l
γ-Glutamyl transpeptidase (γ-Gt)	300 U/l
AST	60 U/l
Hb	11.0 g/dl
MCV	101 fl
INR	1.1
Ascitic tap – total protein	25 g/l
Ascitic tap –	18 g/l

Ascitic tap – albumin	18 g/l
Serum albumin	28 g/l
White cell count (peritoneal fluid)	400/mm^3 (98% lymphocytes)
Plain abdominal film	Adrenal calcification

Which of these investigations is most likely to yield a diagnosis?

A	Laparoscopy and peritoneal biopsy
B	Liver biopsy
C	α-Fetoprotein levels
D	Abdominal computed tomography (CT)
E	Abdominal ultrasound scan (USS)

A Laparoscopy and peritoneal biopsy

Abdominal tuberculosis should always be suspected in the severely malnourished patient, and is difficult to diagnose. Constitutional symptoms are common, including fever, anorexia and weight loss.

The cut-off for considering ascitic fluid to be exudative would be 30 g/l, but in the setting of hypoproteinaemia, this is less relevant. The marked increase in white cell count is strongly supportive of a diagnosis of infective ascites.

The diagnostic yield of ascitic culture for mycobacteria is very low (<10%) even with closed culture systems. Although PCR of ascitic cells/fluid has increased non-invasive diagnosis, the best yield remains from laparoscopy and peritoneal biopsy, which in recent series led to a diagnosis in 95% of cases.

D Abdominal computed

A CT of the abdomen is unlikely to give significant information about peritoneal disease as it is difficult on CT imaging to distinguish the differences between the possible soft tissue causes of ascites. It would be helpful if there was evidence of metastatic disease, but this is unlikely for this patient.

B	Liver biopsy

This patient has primarily a peritoneal rather than a liver problem, and therefore a liver biopsy would be less useful than a peritoneal biopsy. This is suggested by the absence of evidence of extensive chronic liver disease, such as spider naevi or abnormal clotting.

C	α-Fetoprotein levels

This is only useful when screening for liver cancer. As there is no evidence of liver cirrhosis or signs of liver disease beyond ascites, this is not useful and is very unlikely to lead to a diagnosis.

C	α-Fetoprotein levels

This is only useful when screening for liver cancer. As there is no evidence of liver cirrhosis or signs of liver disease beyond ascites, this is not useful and is very unlikely to lead to a diagnosis.

E	Abdominal ultrasound scan (USS)

An USS is unlikely to lead to a diagnosis directly unless there was extrahepatic biliary compression, cholecystitis or thrombosis, of which the latter could be identified on Doppler studies. These are all unlikely diagnoses in this patient.

9832

Rate this question:

An 80-year-old man presents with a 4-week history of increasing confusion and diarrhoea. He has lost weight over the last 2–3 months although he is unable to say how much. He has noticed that his clothes are much looser.

His son tells you that he has long-standing ankle oedema and had noticed a mauve discoloration of his face approximately 12 months ago. His only past medical history is an appendicectomy 8 years ago. He had always appeared well and was living independently. Apparently on occasions the episodes of diarrhoea are associated with facial flushing and tachycardia.

On physical examination, he appears frail and cachectic. His BP is 105/80 mmHg, pulse is 85/min and regular. He has a pansystolic murmur, which is augmented by inspiration, and hepatomegaly 2 cm below the right costal margin.

What one of the following is the most appropriate investigation in this case?

tachycardia.

On physical examination, he appears frail and cachectic. His BP is 105/80 mmHg, pulse is 85/min and regular. He has a pansystolic murmur, which is augmented by inspiration, and hepatomegaly 2 cm below the right costal margin.

What one of the following is the most appropriate investigation in this case?

A	Colonoscopy
B	Gastroscopy and biopsy
C	Urine collection for 5-hydroxyindoleacetic acid
D	Small bowel follow-through
E	Abdominal x-ray

33040

Submit

C Urine collection for 5-hydroxyindoleacetic acid

This patient has carcinoid syndrome secondary to a metastatic carcinoid tumour. Carcinoid tumours are neuroendocrine tumours, which originate from the enterochromaffin cells of the intestine. They are indolent tumours secreting more than 20 different hormones. They are most commonly found in the appendix and terminal ileum. Carcinoid syndrome only occurs once the tumour has metastasised to the liver. The triad of mauve-coloured facial flushing, diarrhoea and cardiac involvement represents more than 85% of the symptoms of carcinoid syndrome. Approximately 50% of those patients who develop carcinoid syndrome have cardiac involvement, classically right heart valvular stenosis. The two most appropriate investigations to obtain a diagnosis are chest and abdominal computed tomography (CT) and a 24-h urine collection for 5-hydroxyindoleacetic acid (5-HIAA), a metabolite of serotonin secreted by

not given as an option here), pentreotide imaging has been shown to have a sensitivity of 80%+ for detection of carcinoid.

A Colonoscopy

The most likely diagnosis is small bowel related diarrhoea linked to carcinoid, hence colonoscopy is not the most useful investigation.

B Gastroscopy and biopsy

This patient has secretory diarrhoea related to carcinoid rather than inflammatory diarrhoea, hence there is unlikely to be utility in gastroscopy and biopsy in this case.

D Small bowel follow-through

Small bowel follow-through is most useful in identifying small bowel inflammatory disorders such as Crohn's disease; as such it isn't a preferred investigation here.

A 47-year-old woman is admitted with a history of progressive shortness of breath of 1 week duration. The patient is known to have liver cirrhosis secondary to chronic hepatitis C, and is taking furosemide 40 mg BD, spironolactone 100 mg BD, propranolol 20 mg TDS and lactulose 30 ml TDS.

On examination, the patient has signs of right-sided pleural effusion, mild to moderate ascites and peripheral oedema. The chest X-ray shows a large, right-sided pleural effusion. She is placed on a low-salt diet; furosemide is increased to 60 mg BD and spironolactone to 150 mg BD. Thoracocentesis is performed and 2.5 l of fluid removed.

Analysis of the fluid:

pH	7.5
Glucose	4.8 mmol/l
Protein	11.0 g/l (serum 27 g/l)
LDH	115 U/l (serum 220 U/l)
WCC	200 × 10^9/l, predominantly

WCC	200 × 10^9/l, predominantly neutrophils
CT chest	No abnormality other than effusion

The patient improves over the next 2 days, and a further 2 litres of fluid is aspirated. After 7 days, the patient again re-accumulates a right-sided effusion occupying half of the right hemithorax.

Which of the following is the best option to prevent re-accumulation of pleural effusion?

A Transjugular intrahepatic portosystemic shunt placement (TIPS)

B Large-bore chest drain

C Chemical pleurodesis

D Videothoracoscopic closure of diaphragmatic defects

is increased to 60 mg BD and spironolactone to 150 mg BD. Thoracocentesis is performed and 2.5 l of fluid removed.

Analysis of the fluid:

pH	7.5
Glucose	4.8 mmol/l
Protein	11.0 g/l (serum 27 g/l)
LDH	115 U/l (serum 220 U/l)
WCC	200 × 10^9/l, predominantly neutrophils
CT chest	No abnormality other than effusion

The patient improves over the next 2 days, and a further 2 litres of fluid is aspirated. After 7 days, the patient again re-accumulates a right-sided effusion occupying half of the right hemithorax.

Which of the following is the best option to prevent re-accumulation of pleural effusion?

E Liver transplant

This patient has hepatic hydrothorax, which is the presence of a pleural effusion >500 ml in a patient with cirrhosis and in whom no other cause of effusion is found. The negative intrathoracic pressure during inspiration sucks the peritoneal fluid through small diaphragmatic defects into the pleural space. It usually occurs on the right side.

Management involves ruling out other causes by pleural fluid analysis and CT scan of chest. Effusion can be managed by a low-salt diet and diuretics. Patients with persistent hydrothorax despite adequate diet and diuretic therapy should undergo evaluation and referral for liver transplantation, as this is the best treatment to resolve the hydrothorax. In this case, attempted eradication of hepatitis C with anti-virals should occur first.

C Chemical pleurodesis

C Chemical pleurodesis

Chemical pleurodesis is less effective in treating hepatic hydrothorax versus malignant pleural effusion.

A Transjugular intrahepatic portosystemic shunt placement (TIPS)

TIPS is the intervention of choice where patients are unfit to undergo liver transplantation. It can result in significant improvement in hydrothorax in 60–80% of cases.

B Large-bore chest drain

Chest drains don't prevent re-accumulation of fluid, and it would be impractical to leave a large-bore chest drain in place long term because of risk of it dislodging, haemorrhage and infection.

D Videothoracoscopic closure

TIPS is the intervention of choice where patients are unfit to undergo liver transplantation. It can result in significant improvement in hydrothorax in 60–80% of cases.

B	Large-bore chest drain

Chest drains don't prevent re-accumulation of fluid, and it would be impractical to leave a large-bore chest drain in place long term because of risk of it dislodging, haemorrhage and infection.

D	Videothoracoscopic closure of diaphragmatic defects

Although diaphragmatic herniae related to accumulation of ascites and increased intra-abdominal pressure may worsen accumulation of pleural effusion, fixing the defects will not prevent accumulation from occurring.

7717

Rate this question:

A 56-year-old man is brought to the hospital after collapsing in the street. On arrival, he is alert but disorientated and smells strongly of alcohol. He complains of a sore tongue.

Examination reveals that he is unkempt and malnourished, with angular stomatitis and glossitis.

A picture of his hands is shown below.

Which vitamin deficiency is most likely to have resulted in the changes on his hands?

A	Vitamin B_{12}
B	Vitamin C

A picture of his hands is shown below.

Which vitamin deficiency is most likely to have resulted in the changes on his hands?

A	Vitamin B_{12}
B	Vitamin C
C	Thiamine
D	Niacin
E	Riboflavin

D Niacin

The changes described are typical of pellagra, which is caused by niacin deficiency. Although pellagra is classically described as occurring with the triad of dementia, dermatitis and diarrhoea, not all of these changes are always present – in fact, it is not unusual for constipation to occur. The dermatitis predominantly affects sun-exposed areas, and progresses from erythema (with dryness and cracking) through to more chronic changes (with thickening and pigmentation). Cognitive impairment is often a late effect, and is often preceded by apathy, depression and irritability.

Pellagra is now rare, as niacin is found in many foods and is used to fortify breakfast cereals. However, people with severe malabsorptive disease, alcohol dependence or eating disorders are still amongst those at risk of niacin deficiency. Pyridoxine is needed for the synthesis of nicotinamide, and pyridoxine deficiency may therefore also cause

deficiency may therefore also cause pellagra.

A Vitamin B_{12}

Vitamin B_{12} deficiency is rarely caused by inadequate intake, although this may occur in vegans. Typical features include a macrocytic anaemia, glossitis, and – over time – neurological changes. If left untreated, subacute combined degeneration of the spinal cord may occur.

B Vitamin C

Vitamin C is particularly found in fresh fruit and vegetables. Deficiency initially causes non-specific symptoms, but features including corkscrew hair follicles, swollen gums, perifollicular haemorrhages, bruising and anaemia may develop as the deficiency progresses. Ascorbic acid supplementation and resumption of a normal diet will rapidly remove features of deficiency.

C Thiamine

Thiamine deficiency in the UK is predominantly found in those with alcohol dependence, and normally presents as Wernicke's encephalopathy. Ataxia, nystagmus, ophthalmoplegia and confusion are the classic findings, and need treating promptly if more permanent cognitive impairment (Korsakoff' syndrome) is to be prevented. Wet beriberi (causing oedema) and dry beriberi (usually presenting with a polyneuropathy) tend not to be seen outside of South East Asia.

E Riboflavin

Riboflavin deficiency has a less clearly defined deficiency syndrome, although angular stomatitis, glossitis and dermatitis may occur.

70164

Rate this question:

A 42-year-old man with known ulcerative colitis is admitted to hospital.

His medication includes azathioprine and intravenous (iv) hydrocortisone. He initially improves on treatment after 3 days, but then his clinical condition deteriorates.

Biopsies from a flexible sigmoidoscopy are consistent with underlying ulcerative colitis, but they also show a significant number of inclusion bodies.

Which treatment is most likely to improve his condition?

A	Combination of rifampicin, pyrazinamide and isoniazid
B	Methotrexate
C	Infliximab
D	Metronidazole
E	Ganciclovir

E Ganciclovir

The presence of inclusion bodies on colonic histology is suggestive of cytomegalovirus infection of the colon. Inflammatory bowel disease, and the history of immunosuppressive therapy with azathioprine and steroids, have put the patient at risk of CMV infection. CMV colitis increases the biological severity of colitis, and given this patient's clinical deterioration, treatment with ganciclovir should be initiated.

A Combination of rifampicin, pyrazinamide and isoniazid

This would be the treatment for an underlying mycobacterial infection, the presence of which is not suggested in this case.

B Methotrexate

Methotrexate is not indicated in the setting of an acute exacerbation of

Methotrexate is not indicated in the setting of an acute exacerbation of ulcerative colitis (NICE guideline CG166).

C Infliximab

Infliximab is recommended as an option for the treatment of acute exacerbations of severely active ulcerative colitis only in patients in whom ciclosporin is contraindicated or clinically inappropriate (NICE guideline TA163).

D Metronidazole

Metronidazole can be of benefit in the treatment of perianal Crohn's disease and pouchitis. In addition, antibiotics are sometimes prescribed if systemic toxicity is present in the context of an acute exacerbation of colitis. However, the important histological finding of inclusion bodies points towards CMV disease.

A 46-year-old man is referred to the dermatologist for a 2-year history of skin discolouration which has been increasing over the last 3 months. He also complains of general fatigue and arthralgia. He works as a building site worker and puts his tanned skin down to the high sun exposure.

Unfortunately, the patient's notes are not available as he was recently seen in the Psychotherapy Department for treatment of impotence. He started taking gliclazide for diabetes mellitus 1 year ago. He smokes ten cigarettes a day and drinks five cans of lager per day, but admits to drinking excessively several years ago following his divorce.

Cardiovascular, respiratory and abdominal examinations are unremarkable except for a non-tender palpable liver edge.

Liver functions tests are as below:

Bilirubin	22 μmol/l
ALT	88 U/l (5-35)
ALP	450 U/l (30–150)

Bilirubin	22 μmol/l
ALT	88 U/l (5-35)
ALP	450 U/l (30–150)
GGT	101 U/l (5-30)
Albumin	33 g/l

Which is the next most useful test to help confirm the diagnosis?

A Serum ferritin

B Caeruloplasmin

C Urinary copper

D Transferrin saturation index

E Alpha fetoprotein

33033

Submit

D Transferrin saturation index

Patients with haemochromatosis typically present with weakness or fatigue, abnormal liver function tests, arthralgia/arthritis, impotence, diabetes of late onset, cirrhosis or bronze pigmentation. It is most commonly due to C282Y mutation on the haemochromatosis (HFE) gene. A fasting transferrin saturation of >55% indicates iron accumulation and in most cases genotyping will confirm 95% of the population. Liver biopsy may show the presence of cirrhosis and histological grading of iron concentration can be carried out. Treatment of all patients with haemochromatosis includes weekly venesections until transferrin saturation is <16%. The serum ferritin should be kept below 50 μg/l.

A Serum ferritin

Ferritin is an acute phase protein which may be elevated in other cases

of chronic liver disease. It is therefore not as useful as serum transferrin saturation for confirming the diagnosis.

B Caeruloplasmin

Urinary copper testing and caeruloplasmin are investigations useful in the evaluation of Wilson's disease.

C Urinary copper

Urinary copper testing is utilised in the investigation of possible Wilson's disease, which presents at an earlier age with neurological dysfunction or unexplained elevated transaminases.

E Alpha fetoprotein

AFP is elevated in hepatocellular carcinoma, which would be suggested by worsening of ascites and a rapid deterioration in liver function tests.

An 84-year-old woman is admitted with a fluctuating conscious level. She was found by her carer having last been seen in the village about a week earlier, buying painkillers for her arthritis from the chemist.

On examination, she is deeply jaundiced, hypotensive with a tachycardia and has a hepatic flap.

Her blood test results on admission are as follows:

ALT	1000 U/l
ALP	600 U/l
INR	3.4
Bilirubin	250 μmol/l

These are repeated 6 hours later and show:

ALT	550 U/l
ALP	702 U/l
INR	4.6
Bilirubin	245 μmol/l

INR	4.6
Bilirubin	245 μmol/l

In addition:

Paracetamol and salicyclate	-
Hepatitis B surface antibody	+
Hepatitis B surface antigen	-

Which of the following would best explain her clinical condition?

A	Reactivation of hepatitis B infection
B	Alcoholic hepatitis
C	Wilson's disease
D	Drug-induced hepatitis
E	Primary biliary cholangitis (PBC)

D Drug-induced hepatitis

This woman has liver failure. If she had taken a staggered overdose of paracetamol over a number of days ago, the serum levels may now be undetectable and so are not reliable and therefore cannot be used to exclude this diagnosis. The rising INR and falling ALT in this context represent worsening liver function and a poor prognosis.

A Reactivation of hepatitis B infection

The hepatitis B serology suggests prior vaccination or clearance of virus following exposure. If the hepatitis surface antigen is negative, then the patient does not have hepatitis B.

B Alcoholic hepatitis

You would not expect to see an ALT of 1000 in this condition. The causes of a

marked increase in ALT include drug-induced, ischaemia, acute Budd-Chiari (hepatic vein thrombosis), autoimmune hepatitis and viral hepatitis.

C	Wilson's disease

This condition is extremely rare in this age group. It is a rare autosomal recessive genetic disorder that leads to a deficiency in copper metabolism and most commonly presents in adolescents and young adults.

E	Primary biliary cholangitis (PBC)

Although it is a possible cause of her presentation, you would not expect such as high transaminitis (i.e. an ALT of 1000). Between 95-98% of patients with PBC will be positive for anti-mitochondrial antibody.

2290

Rate this question:

Next Question

A 67-year-old man who uses continuous ambulatory peritoneal dialysis (CAPD) for chronic kidney disease comes to see you because he has severe abdominal pain and nausea lasting for the past 36 h, and his peritoneal dialysis bags have become cloudy.

On examination, he is pyrexial 37.8 °C and has a blood pressure of 125/75 mmHg, with a resting pulse of 90 bpm. His abdomen is generally tender and there are sparse bowel sounds.

Investigations:

Hb	10.4 g/dl
WCC	13.2×10^9/l (Neutrophilia)
PLT	245×10^9/l
Na^+	139 mmol/l
K^+	4.5 mmol/l
Creatinine	245 μmol/l
Dialysis fluid	> 100 white cells/ml, Gram positive cocci

Dialysis fluid	> 100 white cells/ml, Gram positive cocci
Erect abdominal film	Distended loops of small bowel

How would you manage this patient?

A	Iv cefuroxime and metronidazole and stop dialysis
B	Intraperitoneal gentamicin and vancomycin via the dialysis catheter
C	Laparotomy and washout
D	Switch to haemodialysis and give antibiotics through the line
E	Arrange abdominal CT

B Intraperitoneal gentamicin and vancomycin via the dialysis catheter

The International Society for Peritoneal Dialysis (ISPD) also recommends that intraperitoneal antibiotics are the 'preferred route of administration unless the patient has features of systemic sepsis'.

A Iv cefuroxime and metronidazole and stop dialysis

The ISPD recommends empirical antibiotic coverage is given in cases of peritoneal dialysis associated peritonitis. They recommend Gram-positive organisms be covered by vancomycin or a first-generation cephalosporin, and Gram-negative organisms by a third-generation cephalosporin or an aminoglycoside.

C Laparotomy and washout

The majority of patients with peritonitis associated with peritoneal dialysis can be managed conservatively. When multiple enteric pathogens are cultured from the effluent this raises the possibility of intra-abdominal pathology. In this case a laparotomy may be indicated if a perforated viscus is suspected, for example.

D	Switch to haemodialysis and give antibiotics through the line

Most patients who develop peritonitis with peritoneal dialysis can continue with their renal replacement therapy. Approximately 20% require transfer to haemodialysis. This is determined by failure of treatment or presence of fungi in effluent cultures.

E	Arrange abdominal CT

In cases of severe sepsis and faecal organisms in the effluent suggestive of

A 35-year-old Nigerian office worker presents with a 3-month history of epigastric pain and alternating diarrhoea and constipation. There is occasionally a small amount of blood in his stool. He describes nausea and vomiting associated with weight loss and a recurrent urticaric rash across the trunk and abdomen.

Past medical history includes a kidney transplant and hay fever. He has become more wheezy recently requiring admissions for nebulisers. Examination is normal.

Blood tests are as below:

Haemoglobin (Hb)	11.0 g/dl
White blood count (WBC)	$16.0 \times 10^9/l$
Eosinophil count	$1.0 \times 10^9/l$
Platelets	$152 \times 10^9/l$
Mean cell volume (MCV)	90 fL

What is the most likely diagnosis?

(WBC)	$10^9/l$
Eosinophil count	$1.0 \times 10^9/l$
Platelets	$152 \times 10^9/l$
Mean cell volume (MCV)	90 fL

What is the most likely diagnosis?

A Amoebiasis

B Clostridium difficile

C Campylobacter jejuni

D Shigella infection

E Strongyloidosis stercoralis

7392

Submit

E Strongyloidosis stercoralis

Strongyloidiasis is an infection with *Strongyloides stercoralis*, a round worm occurring widely in tropical and subtropical areas. Patients who are immunosuppressed or on immunosuppressive therapy (such as this gentleman) are most at risk, especially those with human immunodeficiency virus (HIV) or haematological malignancies. Infected individuals can be asymptomatic, and ongoing low level autoinfection means that they may harbour infections for decades after leaving endemic areas. Larva currens (a creeping, pruritic eruption on the skin) and eosinophilic pneumonia are occasional manifestations. Eosinophil counts may be normal in helminth infection.

Diagnostic procedures include repeated stool microscopy and duodenal aspiration. Culture may improve diagnostic yield. Serology is more sensitive. Treatment is difficult

more sensitive. Treatment is difficult because in contrast to other helminthic infections, the worm burden must be eradicated completely. Ivermectin or albendazole can be used.

A Amoebiasis

Intestinal amoebiasis, caused by the protozoan Entamoeba histolytica, typically presents subacutely, usually over one to three weeks. Symptoms range from mild diarrhoea to severe dysentery, producing abdominal pain, diarrhoea, and bloody stools. Fulminant colitis with bowel necrosis leading to perforation and peritonitis can occur, as can toxic megacolon. Rarely, it can result in pleuropulmonary infection, causing serous pleural effusions.It does not usually cause an eosinophilia.

B Clostridium difficile

Clostridium difficile is a spore-forming, toxin-producing, gram-positive

anaerobic bacterium that causes antibiotic-associated colitis. It would not account for the eosinophila, rash, or the respiratory symptoms.

C	Campylobacter jejuni

Campylobacter can cause an infective gastroenteritis, and can be food- (poultry, milk) or water-borne. It causes bloody diarrhoea, abdominal pain, and fever, but would not account for the eosinophila, rash, or respiratory symptoms.

D	Shigella infection

Shigella is an infection of the lower gastrointestinal tract. Patients with *Shigella* gastroenteritis typically present with high fever, abdominal cramps, and bloody, mucoid diarrhoea. It would not account for the eosinophila, rash, or respiratory symptoms.

7392

Rate this question:

A 37-year-old social worker is referred to you with a long history of diarrhoea and abdominal discomfort. She was diagnosed with irritable bowel syndrome 10 years ago and takes mebeverine, peppermint tablets and combined sodium alginate, calcium carbonate and sodium bicarbonate. She is a vegetarian and rarely drinks or smokes.

Examination of all systems is normal. Her blood tests show macrocytic anaemia. An upper gastrointestinal endoscopy reveals oesophagitis, hypertrophy of the gastric body and multiple duodenal ulcers.

What is the most likely diagnosis?

A	Untreated peptic ulcer disease
B	Dyspepsia overlapped with irritable bowel syndrome
C	Zollinger–Ellison syndrome

She is a vegetarian and rarely drinks or smokes.

Examination of all systems is normal. Her blood tests show macrocytic anaemia. An upper gastrointestinal endoscopy reveals oesophagitis, hypertrophy of the gastric body and multiple duodenal ulcers.

What is the most likely diagnosis?

A	Untreated peptic ulcer disease
B	Dyspepsia overlapped with irritable bowel syndrome
C	Zollinger–Ellison syndrome
D	Pernicious anaemia
E	Somatostatinoma

C Zollinger–Ellison syndrome

The key to diagnosis is the multiple duodenal ulcers, which should alert one to this syndrome. This is a rare condition characterised by multiple duodenal or jejunal ulcerations. Diarrhoea may be the only presenting symptom, due to acid deconjugation of bile salts and inactivation of lipases, resulting in fat malabsorption. Vitamin B_{12} deficiency may be a feature. Fasting serum gastrin levels are high and this should be taken after patients have stopped proton-pump inhibition for at least 1 week, to avoid false-positive results. Radioisotope scans may show hot spots of tumour expressing somatostatin receptors. High-dose proton-pump inhibitors relieve symptoms, and octreotide has been used to reduce gastrin secretion. The syndrome is under-diagnosed and is malignant in approximately 60% of cases.

A Untreated peptic ulcer

disease

Peptic ulcers are present on endoscopy of this patient, but the presence of multiple ulcers suggests a more significant underlying diagnosis. Had there been only one ulcer then this would be correct. The long history is also suggestive of a more significant problem.

B	Dyspepsia overlapped with irritable bowel syndrome

Whilst dyspepsia can cause acid reflux resulting in oesophagitis, neither dyspepsia nor IBS can cause ulceration. Neither would explain the macrocytic anaemia, but could otherwise explain all of the symptoms.

D	Pernicious anaemia

Pernicious anaemia is caused by autoimmune atrophic gastritis leading to a lack of intrinsic factor secretion, which in turn causes B_{12} deficiency.

Pernicious anaemia is caused by autoimmune atrophic gastritis leading to a lack of intrinsic factor secretion, which in turn causes B_{12} deficiency. This could explain the macrocytic anaemia, but it would not explain the presence of oesophagitis or ulceration.

E	Somatostatinoma

This is a malignant tumour of delta cells of the pancreas. These are associated with inhibition of insulin and cholecystokinin release, which causes diabetes, steatorrhoea and gallstones. This would not account for the endoscopy findings.

7395

Rate this question:

10:19
tps://mypastest.pastest.com

You review a 27-year-old man who has recently moved house and is referred by his GP for investigation of jaundice. His blood results reveal raised conjugated bilirubin with normal haptoglobins. A liver biopsy is performed, which reveals a number of dark granules within the hepatocytes.

What diagnosis fits best with this clinical picture?

A	Dubin–Johnson syndrome
B	Crigler–Najjar syndrome
C	Rotor syndrome
D	Gilbert syndrome
E	Haemolytic anaemia

recently moved house and is referred by his GP for investigation of jaundice. His blood results reveal raised conjugated bilirubin with normal haptoglobins. A liver biopsy is performed, which reveals a number of dark granules within the hepatocytes.

What diagnosis fits best with this clinical picture?

Your answer was incorrect

A	Dubin–Johnson syndrome
B	Crigler–Najjar syndrome
C	Rotor syndrome
D	Gilbert syndrome
E	Haemolytic anaemia

Explanation

A Dubin–Johnson syndrome

Dubin-Johnson syndrome is a rare cause of isolated conjugated bilirubinaemia. This is due to mutations in the MRP2 transporter gene, responsible for transport of bilirubin and a number of other compounds. It is an autosomal recessive disorder; the granules seen in the liver histology of this patient are thought to arise from melanin deposition.

C Rotor syndrome

Although this rare benign disorder can cause a conjugated hyperbilirubinaemia, it is associated with normal liver histology.

B Crigler–Najjar syndrome

This rare disorder causes an unconjugated, not a conjugated, bilirubinaemia. A gene mutation results in the defective production or absence

This rare disorder causes an unconjugated, not a conjugated, bilirubinaemia. A gene mutation results in the defective production or absence of the enzyme glucuronosyl transferase in the liver – a key enzyme involved in the conjugation of bilirubin.

D	Gilbert syndrome

This condition is associated with an unconjugated hyperbilirubinaemia.

E	Haemolytic anaemia

This patient's haptoglobulin level is normal, and this would be expected to be low in intravascular hemolysis, as the free haemoglobin released into circulation binds with haptoglobin to form a complex, so circulating levels of free haptoglobulin become lower.

6635

Rate this question:

Next Question

conditions such as sepsis and liver disease, and should therefore not be considered a good indicator of nutritional status.

C	Mid-thigh:hip ratio

The waist:hip ratio is a useful measure in the context of central obesity, but the mid-thigh:hip ratio is a fictitious measurement.

E	Height (m)/weight (kg)

The body mass index (BMI) can be used to stratify patients, but is calculated by weight/(height)^2 rather than height/weight. The BMI measurement takes into account neither the difference between fat and non-fat mass, such as bone and muscle, nor the changes in body composition that occur with age.

2283

Rate this question:

A 69-year-old man presented to the Emergency Department claiming to have swallowed a foreign object 2 h previously.

He has a long history of mental health problems and had presented with a similar history in the past.

He denied any dysphagia, odynophagia or abdominal pain, and physical examination was unremarkable.

His plain abdominal X-ray is shown below:

What course of action would you advise?

What course of action would you advise?

A	Laparotomy and removal of the object
B	Endoscopic removal of the object
C	Reassure and discharge the patient
D	Monitor with weekly X-rays to ensure passage through the gastrointestinal tract
E	Metoclopramide or other gastrointestinal stimulants

B Endoscopic removal of the object

Whilst most ingested foreign objects will pass through the GI tract without complication, there are certain instances where intervention – sometimes urgently – is required.

High-grade oesophageal obstruction (which presents with an inability for someone to swallow even their saliva) is an indication for urgent intervention. High-risk objects impacted in the oesophagus (including sharp objects) should also be urgently intervened upon.

Long objects that are unlikely to negotiate the duodenum often require endoscopic removal, as do large objects that will not progress beyond the pylorus. In the absence of symptoms, the latter can be monitored initially for several weeks to see whether they leave the stomach by themselves without any further intervention.

Objects that have already progressed

Objects that have already progressed beyond the duodenum can normally be monitored with weekly X-rays, with surgical intervention being typically prompted either by the object being stationary for over a week or by the onset of symptoms.

Once in the stomach (as is the case here), sharp objects usually pass through the gastrointestinal tract safely. A small proportion, however, can cause perforation, and sharp objects within the stomach and proximal duodenum should therefore be carefully removed endoscopically, making B the best option here. Where this is not possible or contraindicated, an alternative strategy is for daily X-rays to monitor the progress of more distal objects, and for surgery to be considered for objects that do not move for 72 h and/or people in whom symptoms develop.

Of note, narcotic packages should probably not be removed endoscopically, because of the risk of accidental rupture.

A	Laparotomy and removal of the object

This is not the optimum course of action for this situation. Currently the object is easily accessible via endoscopy.

C	Reassure and discharge the patient

Harm cannot be definitively ruled out until the object has either moved distally or been removed.

D	Monitor with weekly X-rays to ensure passage through the gastrointestinal tract

Where endoscopic removal is not possible or is contraindicated, an alternative strategy is for daily X-rays to monitor the progress of more distal objects, and for surgery to be considered for objects that do not move for 72 h and/or people in whom symptoms develop. This would be the

Where endoscopic removal is not possible or is contraindicated, an alternative strategy is for daily X-rays to monitor the progress of more distal objects, and for surgery to be considered for objects that do not move for 72 h and/or people in whom symptoms develop. This would be the alternative strategy if the patient was deemed to have capacity and refused endoscopy.

E	Metoclopramide or other gastrointestinal stimulants

Because of where the object appears to be lodged, this runs the risk of significant pain and even potentially oesophageal rupture.

70172

Rate this question:

A 17-year-old art student is referred with the following blood results. He recently had a upper respiratory tract infection. His mother has autoimmune hepatitis. His last travel was 4 months ago to Brazil for a school trip.

Physical examination is normal. He is concerned that he may have the same liver disorder as his mother.

Liver function test results:

Bilirubin (unconjugated)	57 µmol/l
ALT	20 U/l (5–35)
ALP	75 U/l (30–150)
GGT	34 U/l

What is the most likely diagnosis?

A	Infectious mononucleosis
B	Cytomegalovirus hepatitis

Bilirubin (unconjugated)	57 µmol/l
ALT	20 U/l (5–35)
ALP	75 U/l (30–150)
GGT	34 U/l

What is the most likely diagnosis?

A Infectious mononucleosis

B Cytomegalovirus hepatitis

C Gilbert's syndrome

D Chronic active hepatitis

E Crigler Najjar Type II

C Gilbert's syndrome

This is a harmless disorder of bilirubin metabolism and is the commonest form of inherited non-haemolytic hyperbilirubinaemia. Individuals with this syndrome have a normal lifespan. There are several precipitating factors in the raising of bilirubin including fasting, physical exertion, psychological stress, febrile illness and menstruation. A diagnosis of Gilbert syndrome can be made if a patient has had hyperbilirubinaemia either constantly or on at least two occasions over a 6-month period. The remainder of the liver tests should be normal. Haemolysis can be excluded with a blood film, reticulocyte or serum haptoglobin. The prognosis is benign and treatment is largely not necessary.

A Infectious mononucleosis

Typically, Epstein–Barr infection (EBV) presents with fever and myalgia with an exudative pharyngitis

an exudative pharyngitis. Hepatosplenomegaly and a transaminitis occur later. This patient is asymptomatic and his ALT is normal, and therefore this is the wrong diagnosis. EBV infection can be tested by heterophile antibodies (either Monospot or Paul Bunnell). Tests may be negative in the earlier phase of the infection.

B	Cytomegalovirus hepatitis

Acute CMV infection in immunocompetent patients is usually asymptomatic, but it may present in a similar manner to EBV, although not usually with pharyngitis. This patient's ALT is normal, therefore making this diagnosis incorrect. Evidence of CMV infection can be tested for by IgM (acute) and IgG (previous).

D	Chronic active hepatitis

In patients with an active hepatitis, one would expect a moderately elevated

This is a rare autosomal recessive disorder of bilirubin metabolism. Patients have deficient activity of the enzyme uridine diphosphate glucuronosyltransferase (as opposed to Crigler–Naliar type I where there is *absent* activity of the UDG enzyme). This leads to an impairment in conjugation and excretion of bilirubin, resulting in an isolated unconjugated hyperbilirubinaemia. Jaundice typically presents in the neonate, infancy or later in childhood – it would be atypical for this patient to present at 17 with the condition, making Gilbert syndrome the more likely answer.

In Crigler–Najjar, jaundice may be precipitated by intercurrent infection, anaesthesia or medications (such as salicylates and penicillin). Treatment during episodes of jaundice includes phenobarbital, phototherapy or exchange transfusion as encephalopathy is a risk. Patients have a normal life expectancy.

Crigler–Najjar type I presents in the neonate and requires rapid treatment

A 28-year-old woman with known Crohn's disease attends the gastroenterology outpatients clinic. Her disease is currently well controlled on 125 mg of azathioprine once daily. She and her partner wish to try for a baby.

Physical examination is normal, with a BMI of 24.

How would you best advise her?

A	Stop azathioprine and commence folic acid
B	Stop azathioprine and advise her to continue using contraception for 3 months before trying to conceive
C	Commence folic acid supplements and continue the current dose of azathioprine
D	Increase the dose of azathioprine to 150 mg daily

baby.

Physical examination is normal, with a BMI of 24.

How would you best advise her?

A	Stop azathioprine and commence folic acid
B	Stop azathioprine and advise her to continue using contraception for 3 months before trying to conceive
C	Commence folic acid supplements and continue the current dose of azathioprine
D	Increase the dose of azathioprine to 150 mg daily
E	Continue the current dose of azathioprine and add prednisolone 20 mg daily

C Commence folic acid supplements and continue the current dose of azathioprine

Women with well-controlled inflammatory bowel disease should have no increased difficulty in conceiving; however, active Crohn's disease may reduce fertility. Folate deficiency is common, making supplementation crucial. With respect to continuing azathioprine in pregnancy, the consensus appears to be that azathioprine can be used during pregnancy if the benefits outweigh the risks. This has been supported in a recent update to the BSG guidelines on management of inflammatory bowel disease in pregnancy, which suggest that in general, azathioprine can be continued at the same dose.

A Stop azathioprine and commence folic acid

Stopping azathioprine risks significant

A 40-year-old man has returned from a secondment in Southern China. He complains of passing copious amounts of watery, foul-smelling diarrhoea which is difficult to flush away. He received treatment at the time for traveller's diarrhoea but this has persisted since return. He also complains of anorexia, lethargy and fatigue and joint pains.

On examination, his BMI is 17.5. His blood pressure is 125/77 mmHg. His abdomen is distended with mild tenderness and he also has atrophic glossitis and stomatitis. There is bilateral ankle swelling.

Investigations:

Hb	10.1 g/dl
WCC	9.9×10^9/l
PLT	176×10^9/l
Na^+	141 mmol/l
K^+	4.2 mmol/l
Creatinine	125 μmol/l

K^+	4.2 mmol/l
Creatinine	125 μmol/l
Albumin	24 g/l
Duodenal biopsy	Partial villous atrophy with PAS positive macrophages

Which of the following is the most likely diagnosis?

A Bacterial overgrowth syndrome

B Coeliac disease

C Tropical sprue

D Whipple's disease

E Giardiasis

D Whipple's disease

The presence of malabsorption, weight loss, arthralgia and diarrhoea with PAS-positive macrophages identified on biopsy is typical for Whipple's. The causative organism is *Tropheryma whipplei*. PCR for *T. whipplei* DNA is only sparsely available, and a large number of control patients show IgG for *T. whipplei*. As such the diagnosis is a clinical one supported by small bowel biopsy results. Rarely there can also be neurologic, pulmonary and cardiac involvement. Long-term antibiotic therapy with a penicillin, tetracycline or co-trimoxazole is a potential treatment option.

A Bacterial overgrowth syndrome

Bacterial overgrowth is characterised by an increase in number of bacteria within the small intestine leading to excess fermentation, inflammation and malabsorption. Symptoms can mimic this presentation with bloating

excess fermentation, inflammation and malabsorption. Symptoms can mimic this presentation with bloating, flatulence, diarrhoea and abdominal discomfort common symptoms. Malabsorption can manifest with weight loss and vitamin B12, D and A deficiency. However, the PAS-positive macrophages indicate a diagnosis of Whipple's disease. Investigation for bacterial overgrowth syndrome is usually by breath testing although cultures of small bowel aspirates are possible they are rarely used in practice. Most patients with bacterial overgrowth have a known underlying condition (eg small intestinal diverticulosis, strictures, slowed motility due to diabetes, fistulae).

B	Coeliac disease

Coeliac disease results from an autoimmine intolerance to gluten. The gold standard for diagnosis is on histological appearances from duodenal biopsies (classically showing villous atrophy) and can be supported

villous atrophy) and can be supported by the presence of anti-TTG or anti-endomysial antibodies in the serum. However, the presence of PAS-positive macrophages indicates this is Whipple's disease. Coeliac disease is treated by exclusion of gluten from the diet resulting in resolution of the villous changes on histology. For more information see British Society of Gastroenterology guidelines on management and diagnosis of coeliac disease.

C	Tropical sprue

Although the clinical picture would fit with tropical sprue, the PAS-positive macrophages are diagnostic for Whipple's disease. Tropical sprue is commonly found in the Caribbean (eg Pureto Rico, Haiti, Cuba and the Dominican Republic) but is rare in Europe, Africa, China and the Middle East. It may develop after an acute diarrhoeal illness and is thought to be caused by overgrowth of toxogenic coliforms in the small intestine leading

diarrhoeal illness and is thought to be caused by overgrowth of toxogenic coliforms in the small intestine leading to malabsorption (commonly megaloblastic anaemia and steatorrhoea). Treatment is with 3–6 months of tetracycline and folic acid supplementation. For further information see Ramakrishna et al.

E	Giardiasis

First-line treatment is with metronidazole or tinidazole and the fact the patient has previously received treatment previously makes this less likely. *Giardia* is a protozoal parasite that is a common cause of travellers' diarrhoea. It typically causes acute illness but can cause chronic infection that leads to malabsorption. Investigation is by stool microscopy for cysts and stool antigen can be tested.

References

Ludvigsson JF, Bai JC, Biagi F, Card TR, Ciacci C, Ciclitira PJ. Diagnosis and management of adult coeliac disease:

You review a 48-year-old publican who is awaiting discharge from the Gastroenterology Ward after an episode of haematemesis related to oesophageal varices. He received injection sclerotherapy at the time. You review his investigations and decide on medication to reduce further bleeding. He is already on spironolactone.

Investigations:

Hb	11.5 g/dl
WCC	6.1×10^9/l
PLT	230×10^9/l
Na^+	137 mmol/l
K^+	3.9 mmol/l
Creatinine	90 μmol/l
Hepatic ultrasound scan	small shrunken liver
Liver biopsy	advanced cirrhosis

Which one of the following would be most appropriate strategy to reduce

Creatinine	90 μmol/l
Hepatic ultrasound scan	small shrunken liver
Liver biopsy	advanced cirrhosis

Which one of the following would be most appropriate strategy to reduce portal blood pressure in this man?

A Atenolol

B Isosorbide dinitrate

C Propranolol

D Furosemide

E Lactulose

33042

Submit

C Propranolol

Propranolol is a non-selective beta-blocker with high hepatic first pass metabolism and in clinical trials has been shown to be the most effective oral agent in long-term therapy for portal hypertension. Porto-systemic shunting is usually reserved for patients who re-bleed and have symptoms of worsening portal hypertension.

A Atenolol

Atenolol has greater B1 receptor selectivity than propranolol and lower first pass hepatic metabolism, this makes it a less ideal choice for the treatment of portal hypertension.

B Isosorbide dinitrate

Isosorbide dinitrate is less effective in controlling portal hypertension in this situation because of potential difficulties with postural hypotension

A 50-year-old woman presents with a 3-month history of intermittent jaundice and right upper quadrant pain.

She drinks minimal alcohol and is a non-smoker. She had an emergency surgery many years ago, but she is not able to remember what it was for.

On examination, she is mildly icteric. There is no lymphadenopathy. There is a visible scar on the abdomen.

Investigations:

Bilirubin	101 μmol/l
ALT	54 U/l (5–35)
ALP	370 U/l (30–150)
GGT	240 U/l

What is the most likely operation she has had in the past?

A	Partial gastrectomy for gastric ulcer

Bilirubin	101 μmol/l
ALT	54 U/l (5–35)
ALP	370 U/l (30–150)
GGT	240 U/l

What is the most likely operation she has had in the past?

A	Partial gastrectomy for gastric ulcer
B	Ileal resection for Crohn's disease
C	Right hemicolectomy for caecal carcinoma
D	Left lobectomy of the liver for carcinoid tumour
E	Jejunal resection for gastrointestinal lymphoma

B Ileal resection for Crohn's disease

Her predominantly cholestatic liver function tests and abdominal pain would be consistent with biliary calculi/choledocolithiasis. Ileal resection reduces the reabsorption of bile salts and as a result, a reduction in the enterohepatic circulation of bile salts. This, in turn increases the risk of cholesterol stone formation.

A Partial gastrectomy for gastric ulcer

This is associated with an increased frequency of iron deficiency anaemia and B_{12} deficiency (due to the reduced acidic environment required to convert Fe3+ to the more absorbable Fe2+ and the reduction in parietal cells to produce intrinsic factor).

C Right hemicolectomy for caecal carcinoma

Although part of the ileum may be resected in a right hemicolectomy (and thus lead to bile salt malabsorption), this is not guaranteed whereas ileal resection for Crohn's disease is much more likely to lead to this side effect.

D	Left lobectomy of the liver for carcinoid tumour

Left liver lobectomy is not associated with the formation of gallstones. Indeed, depending on the position of the tumour the gall bladder may need to be resected as well.

E	Jejunal resection for gastrointestinal lymphoma

Depending on the length resected, small bowel resection may result in short bowel syndrome characterised by malabsorption, maldigestion and malnutrition and frequently diarrhoea. However, it is not associated with the formation of gallstones.

A 48-year-old man is seen in clinic with a 3-month history of chronic epigastric discomfort. The pain comes and goes and radiates to his back and his right shoulder tip at times. It is worse after meals but there is no relieving factor. He feels nauseous most of the time and has foul-smelling stools. He has lost 2 stones in weight. He also complains of intermittent light-headedness. He drinks a bottle of wine on most nights and smokes 20 cigarettes/day.

On examination, he is thin and looks neglected. His abdomen is soft, but tender on deep palpation in the epigastric area. He has a 2 cm non-tender liver edge. He also has decreased sensation to light touch on both feet.

Investigations:

Hb	10.2 g/dl	
WCC	$12.1 \times 10^9/l$	
PLT	$462 \times 10^9/l$	
Na^+	131 mmol/l	

PLT	462×10^9/l	
Na^+	131 mmol/l	
K^+	4.2 mmol/l	
Creatinine	64 μmol/l	
Amylase	35 U/l	
ALT	104 U/l	
ALP	121 U/l	
Bilirubin	24 μmol/l	
Ca^{2+}	2.01 mmol/l	
Abdominal X-ray (AXR)	Normal	
Oesophago-gastro duodenoscopy (OGD)	Mild gastritis	
Campylobacter-like organisms (CLOs)	-	
Ultrasound	Mildly enlarged	

(CLOs)		
Ultrasound abdomen	Mildly enlarged liver with fatty change	
Spleen & kidneys	Normal	
Pancreas	Partially obscured by overlying bowel gas	
Faecal elastase	110 E1/g of stool	200 to > 500 E1/g of stool

He is referred for a secretin test:

Volume collected	110 ml
Bicarbonate	52 mEq/l

		of stool

He is referred for a secretin test:

Volume collected	110 ml
Bicarbonate	52 mEq/l

What is the most likely diagnosis?

A Chronic pancreatitis

B Bacterial overgrowth of the gut

C Coeliac disease

D Vasoactive intestinal polypeptide-secreting tumour (VIPoma)

E Caecal carcinoma

Campylobacter-like organisms (CLOs)	-	
Ultrasound abdomen	Mildly enlarged liver with fatty change	
Spleen & kidneys	Normal	
Pancreas	Partially obscured by overlying bowel gas	
Faecal elastase	110 E1/g of stool	200 to > 500 E1/g of stool

He is referred for a secretin test:

A Chronic pancreatitis

This patient has a history of excess ethanol consumption and chronic abdominal pain. In early disease there may be no X-ray calcification of the pancreas, and endoscopic retrograde cholangiopancreatogram (ERCP) and computed tomography (CT) of the abdomen can also be normal. Faecal elastase is in the mild-to-moderate pancreatic insufficiency range, and the most likely diagnosis therefore is chronic pancreatitis. Treatment acutely is as for acute pancreatitis, but chronic pain control is often difficult and patients become opiate dependent. Pancreatic enzyme replacement is used. These patients also usually become diabetic and should be monitored for symptoms of hyperglycaemia such as polyuria, polydipsia, lethargy and dehydration.

B Bacterial overgrowth of the gut

range.

C	Coeliac disease

Coeliac disease is associated with symptoms of malabsorption, positive anti-TTG antibodies, and faecal elastase remains in the normal range.

D	Vasoactive intestinal polypeptide-secreting tumour (VIPoma)

VIPomas are vanishingly rare and are associated with large-volume diarrhoea, hypokalaemia and dehydration. The chronic excess alcohol consumption counts towards an alternative diagnosis here.

E	Caecal carcinoma

Caecal carcinoma is often symptomless in the early stages, and presents late with iron deficiency anaemia or ultimately obstruction, rather than the chronic diarrhoea seen

A 52-year-old man is referred to the Gastroenterology Clinic with symptoms consistent with long-standing reflux.

His general practitioner (GP) has tried lifestyle advice, H2 antagonists and proton pump inhibitor therapy but the symptoms seem to be getting no better. He has not lost weight and if anything is actually a few pounds overweight. He is currently taking omeprazole 40 mg per day.

On examination, his BP is 149/89 mmHg. His BMI is 28.

Investigations:

Hb	13.1 g/dl
WCC	5.4×10^9/l
PLT	205×10^9/l
Na^+	139 mmol/l
K^+	4.3 mmol/l
Creatinine	103 μmol/l
ALT	31 U/l

Albumin	40 g/l
Upper GI endoscopy	6cm of columnar epithelium, consistent with Barrett's, biopsies indicate low grade dysplasia

Which of the following is the most appropriate management?

A	Refer for consideration of oesophagectomy
B	Refer for radiofrequency ablation
C	Continue high dose PPI and reassure
D	Continuous PPI therapy and yearly surveillance endoscopy
E	Surveillance endoscopy at 6 months

E Surveillance endoscopy at 6 months

The amended BSG guidelines recommend repeat endoscopy at 6 months. If there is *still* evidence of low grade dysplasia the BSG now recommend referral for consideration of endoscopic ablation after MDT discussion based on a recent retrospective analysis that demonstrated a progression rate of 9.1%/year to high grade dysplasia or oesophageal cancer.

For further information see British Society of Gastroenterology Guidelines on the diagnosis and Management of Barrett's Oesophagus. Fitzgerald RC, di Pietro M, Ragunath K, et al. Gut. doi:10.1136/gutjnl- 2013-305372 and supplementary text "LGD: surveillance or ablation?" available on the BSG website in guidelines.

D Continuous PPI therapy and yearly surveillance endoscopy

PPI therapy should be tailored to symptoms but there is not robust enough evidence to suggest PPIs alone can prevent progression to cancer. Low grade dysplasia has an uncertain clinical history and as such should be surveyed more frequently (BSG recommends 6 monthly) to catch progression early.

A	Refer for consideration of oesophagectomy

Dysplasia of the intestinal metaplasia seen in Barrett's is highly unstable and there is a risk of conversion to adenocarcinoma of the oesophagus. However, there is also a chance it may regress at follow up endoscopy, therefore referral straight for oesophagectomy would be premature.

B	Refer for radiofrequency ablation

Low grade dysplasia is unstable and may regress, therefore referral for treatment based on one endoscopy

oesophagectomy would be premature.

B	Refer for radiofrequency ablation

Low grade dysplasia is unstable and may regress, therefore referral for treatment based on one endoscopy would be premature.

C	Continue high dose PPI and reassure

PPIs should be continued for symptom control. The evidence to support continuous PPI therapy alone as a chemopreventive agent for the development of dysplasia is not sufficient and is not recommended by the British Society of Gastroenterology. Due to the chance of dysplasia progressing to carcinoma, further surveillance is required.

21488

Rate this question:

A 54-year-old woman has chronic autoimmune hepatitis. She is managed on prednisolone and azathioprine.

You review her in the clinic and notice that she has worsening of her jaundice with a rising bilirubin and increasing ascites.

You admit her; the nurses call you to see her urgently the following morning as she has become increasingly drowsy. Her blood pressure is 100/50 mmHg, with pyrexia of 38.2 °C.

Which investigation is most likely to confirm the suspected diagnosis?

A	Computed tomography (CT) head
B	Electroencephalograpm (EEG)
C	Blood culture
D	Lumbar puncture

E	Peritoneal tap for microscopy and culture

Spontaneous bacterial peritonitis occurs in around 8% of cirrhotic patients with ascites, infecting organisms probably gaining access to the peritoneum via haematological spread. Most frequent infecting organisms are *Escherichia coli*, *Klebsiella* and enterococci. Pain and pyrexia may frequently be absent. A raised neutrophil count alone in ascitic fluid is enough to commence treatment. Mortality is high, at up to 25%, and recurs in 70% of patients within one year. Oral quinolones may be used as prophylaxis

A	Computed tomography (CT) head

CT head would be a useful investigation in confusion during which an intracranial cause is suspected or needs to be excluded. This can be considered in, for example, subdural haematomas (worsening pain and

needs to be excluded. This can be considered in, for example, subdural haematomas (worsening pain and confusion), subarachnoid haemorrhage (sudden occipital severe headache) or abscess (recent sinusitis or other infection, headache and fever). In this patient there is a clear cause for confusion – acute decompensation of the liver.

B	Electroencephalograpm (EEG)

EEG can demonstrate encephalopathy, but it is unlikely to be of significant aid in decision making as there is sufficient evidence of liver decompensation clinically.

C	Blood culture

Blood culture should be taken in this patient to help guide antibiotic therapy, but is unlikely to be very specific in making the diagnosis. It can demonstrate bowel organisms in this setting, but may not give much help

This chest radiograph is from a 36-year-old man who presented with severe abdominal pain, having collapsed at home. He has suffered from intermittent bloody diarrhoea, which has increased in severity over the past few months.

On examination, his blood pressure is 100/70, pulse is 90 and regular. He is pyrexial at 38.4 °C. Abdomen is generally tender and rigid with guarding.

His chest X-ray is shown below:

What is the most likely underlying

What is the most likely underlying cause of his presentation?

A	Ulcerative colitis
B	Acute pancreatitis
C	Acute cholecystitis
D	Ischaemic bowel
E	Diverticulitis

6754

Submit

under the diaphragm, which is due to perforation of an abdominal viscus. Although the heart shadow looks a little large, remember that it is an AP film. The most likely cause in this patient would be perforated large bowel secondary to ulcerative colitis, which fits well with the previous history of chronic diarrhoea.

B	Acute pancreatitis

Acute pancreatitis presents with vomiting and epigastric pain, rather than the clinical picture seen here.

C	Acute cholecystitis

Cholecystitis presents with epigastric and right upper quadrant pain, and gall bladder perforation is very rare.

D	Ischaemic bowel

C Acute cholecystitis

Cholecystitis presents with epigastric and right upper quadrant pain, and gall bladder perforation is very rare.

D Ischaemic bowel

Ischaemic bowel does cause diarrhoea, although it usually occurs in patients with a history of atherosclerosis and who are considerably older than 36.

E Diverticulitis

Diverticulitis is seen in a more elderly population, although it does present with left-sided abdominal pain and diarrhoea.

6754

Rate this question:

A 24-year-old man was diagnosed with Crohn's disease at the age of 17 years. He has been admitted to hospital on a yearly basis since his diagnosis with acute flare-ups requiring courses of systemic corticosteroids.

He has no extra-enteric manifestations of Crohn's disease, but has had a problematic perianal fistula requiring frequent courses of antibiotics. He is finding it difficult to maintain attendance at work because of ill health.

Which of the following steps is recommended next to maintain remission in this patient?

A	6-Mercaptopurine
B	Polymeric diet
C	Budesonide
D	Ciclosporin

A 6-Mercaptopurine

Thiopurines (azathioprine and 6-mercaptopurine) are the most effective agents in maintaining remission in Crohn's disease long term. If not tolerated, methotrexate could be used as an alternative. Thiopurines are thought to be particularly effective in patients with fistulating disease. Infliximab is of value in long-term remission in fistulating Crohn's disease (and possibly in non-fistulating disease) but is generally used alongside a thiopurine. Over the long term, it may prove a superior option to methotrexate, but currently it is still considered only after a traditional second line therapy has failed to gain control.

E Sulphasalazine

ASA (5-Aminosalycilic acid) compounds such as balsalazide and sulphasalazine have a role in maintaining remission and are

compounds such as balsalazide and sulphasalazine have a role in maintaining remission and are generally well tolerated but are not as effective as thiopurines.

B Polymeric diet

This has most value in reducing the severity of acute flares and their frequency, rather than resolving fistulae.

C Budesonide

Steroids do not have a role in maintaining remission, their main value is in treating acute flares of Crohn's disease.

D Ciclosporin

Cyclosporine is of most use in the treatment of severe ulcerative colitis which is unresponsive to high dose corticosteroids and 5-ASA compounds.

A 27-year-old lawyer is referred to the Gastroenterology Clinic in view of a strong family history of bowel cancer. He is otherwise asymptomatic.

His general practitioner (GP) comments on a normal colonoscopy, which he had privately one week ago.

He reports that his grandmother died of bowel cancer aged 68 years. His mother was diagnosed with bowel cancer aged 45 years and is currently receiving chemotherapy for endometrial cancer. His uncle had bowel surgery for cancer at the age of 49 years.

He is still very concerned and would like some advice about whether he needs any further investigations.

Which one of the following is the most appropriate management with respect to bowel cancer surveillance?

A	Arrange double contrast barium enema to re-assess bowel

49 years.

He is still very concerned and would like some advice about whether he needs any further investigations.

Which one of the following is the most appropriate management with respect to bowel cancer surveillance?

A	Arrange double contrast barium enema to re-assess bowel
B	Arrange flexible sigmoidoscopy in 3 months
C	Repeat colonoscopy in 2 years
D	Repeat colonoscopy in 5 years
E	Computed tomography of the abdomen with contrast

C Repeat colonoscopy in 2 years

This gentleman is clearly at risk of hereditary non-polyposis colorectal cancer syndrome (HNPCC) in view of the strong family history. It is an autosomal dominant syndrome characterised by early-onset colorectal cancer. It may account for 1-2% of all cases of colorectal cancer (CRC). In 55-60% of cases, cancers are right sided and affected individuals are also at increased risk of cancer of the endometrium, stomach, small bowel and genitourinary tract. Mutations responsible for HNPCC are found in DNA repair genes.

The diagnostic criteria for HNPCC families are:

(a) Histologically verified CRC or HNPCC-related cancers in three or more relatives, one of whom is a first-degree relative of the other two;

(b) CRC affecting at least two generations;

(a) Histologically verified CRC or HNPCC-related cancers in three or more relatives, one of whom is a first-degree relative of the other two;

(b) CRC affecting at least two generations;

(c) One or more cases of cancer diagnosed before the age of 50 years.

Individuals at risk should be offered colonoscopic screening at 2-year intervals from the age 20-25 years, which should be continued up to the age of 40 years, when screening should be increased to an annual basis. The optimal interval between colonoscopic examinations is not known. There is some evidence that progression from adenoma to carcinoma is accelerated in this syndrome, thus colonoscopic intervals of 1-3 years are recommended. The above are based on retrospective observational studies and panel expert consensus.

D	Repeat colonoscopy in 5 years

A 42-year-old woman presents with pins and needles in her hands and feet. She incidentally describes weight loss and offensive-smelling stool. She has a history of small bowel diverticulae and anaemia. She is a non-smoker and non-drinker. She eats red meat.

On examination, the power and tone in her legs are normal. There are exaggerated knee jerks and absent ankle jerks. Joint position and vibration sense are absent below her ankles. The plantar responses are extensor.

Investigations:

Hb	10.3 g/dl
White blood count (WBC)	5.0×10^9/l
Platelets	142×10^9/l
Mean cell volume (MCV)	107 fl
Bilirubin	32 μmol/l
Alanine aminotransferase (ALT)	22 U/l (5–35)

Alanine aminotransferase (ALT)	22 U/l (5–35)
Alkaline phosphatase (ALP)	45 U/l (30–150)
Albumin	35 g/l

Blood film	Macrocytosis and hypersegmented neutrophils
Ferritin	46 µg/l (4–120)
Serum B12	80 ng/l (160–900)
Folate	50 µg/l (2-11)

Schilling test (oral labelled vitamin B_{12} secreted in urine):

Pre-intrinsic factor	3%
Post-intrinsic factor	4%

What is the most likely diagnosis?

A	Terminal ileal Crohn's disease

Serum B12	80 ng/l (160–900)
Folate	50 µg/l (2-11)

Schilling test (oral labelled vitamin B_{12} secreted in urine):

Pre-intrinsic factor	3%
Post-intrinsic factor	4%

What is the most likely diagnosis?

A Terminal ileal Crohn's disease

B Chronic pancreatitis

C Bacterial overgrowth

D Pernicious anaemia

E R-binder deficiency

C Bacterial overgrowth

This lady has evidence of subacute combined degeneration of the cord, as shown by dorsal column signs, peripheral neuropathy and upper motor neuron signs. She has macrocytic anaemia. This is due to vitamin B_{12} deficiency. The clue comes from her history of small bowel diverticular disease and elevated folate. Vitamin B_{12} malabsorption occurs in this diverticulosis due to bacterial overgrowth; the bacteria synthesise folate, which becomes markedly elevated.

A Terminal ileal Crohn's disease

Crohn's disease is an inflammatory bowel disease which can affect any part of the GI tract, but commonly causes terminal ileal inflammation. The presentation is diarrhoea with urgency, often at night, fever, malaise and abdominal pain. The absence of a

abdominal pain. The absence of a strong history of diarrhoea, abdominal pain and fever makes this diagnosis unlikely, but malnutrition can also cause B_{12} deficiency.

B	Chronic pancreatitis

Chronic pancreatitis can be caused by alcohol, pancreatic duct obstruction or CF. It causes epigastric pain radiating to the back, weight loss and malabsorption. Whilst it could cause diarrhoea and result in B_{12} deficiency and therefore neurological deficit, the absence of abdominal pain and an underlying cause for pancreatitis makes it unlikely.

D	Pernicious anaemia

Pernicious anaemia is caused by autoimmune atrophic gastritis leading to a lack of intrinsic factor secretion, which in turn causes B_{12} deficiency. However, pernicious anaemia is excluded in the Schilling test which fails to correct with intrinsic factor

D Pernicious anaemia

Pernicious anaemia is caused by autoimmune atrophic gastritis leading to a lack of intrinsic factor secretion, which in turn causes B_{12} deficiency. However, pernicious anaemia is excluded in the Schilling test which fails to correct with intrinsic factor, indicating normal levels of intrinsic factor.

E R-binder deficiency

Deficiency in R-binder is a rare genetic cause for B_{12} deficiency as the R-binder, an extracellular transport molecule of vitamin B_{12}, is absent. It most commonly presents in infants.

7412

Rate this question:

An 18-year-old Kenyan from Nairobi and who has recently moved to the UK presents with right upper quadrant pain, worse on inspiration. She has had normal bowel movements but has noticed night sweats which have increased in frequency over the past 4–6 weeks.

On examination, she feels hot, has tender hepatomegaly and a dull right base on chest examination. Her temperature is 38.8 °C and her chest X-ray shows a raised right hemidiaphragm. She has an elevated white cell count and mildly low albumin, but normal liver function tests and clotting results.

Which is the most likely diagnosis?

A	Amoebic liver abscess
B	Hepatitis C
C	Hepatitis B
D	*Schistosoma haematobium*

increased in frequency over the past 4–6 weeks.

On examination, she feels hot, has tender hepatomegaly and a dull right base on chest examination. Her temperature is 38.8 °C and her chest X-ray shows a raised right hemidiaphragm. She has an elevated white cell count and mildly low albumin, but normal liver function tests and clotting results.

Which is the most likely diagnosis?

A	Amoebic liver abscess
B	Hepatitis C
C	Hepatitis B
D	*Schistosoma haematobium*
E	Hydatid cyst

An 18-year-old Kenyan from Nairobi and who has recently moved to the UK presents with right upper quadrant pain, worse on inspiration. She has had normal bowel movements but has noticed night sweats which have increased in frequency over the past 4–6 weeks.

On examination, she feels hot, has tender hepatomegaly and a dull right base on chest examination. Her temperature is 38.8 °C and her chest X-ray shows a raised right hemidiaphragm. She has an elevated white cell count and mildly low albumin, but normal liver function tests and clotting results.

Which is the most likely diagnosis?

Your answer was correct

A Amoebic liver abscess

B Hepatitis C

A Amoebic liver abscess

Amoebic liver abscess presents without bowel changes in up to 50% of cases. The liver abscess is usually a single mass in the right lobe and the swelling can migrate upwards, causing the raised right hemidiaphragm and dullness on examination. There is usually a high swinging fever with right upper quadrant pain. A CT abdomen or ultrasound should show an isolated abscess, particularly in the right lobe. Serology is positive in >95%, but this could be past or present infection. CT chest doesn't help in the diagnosis but may show atelectasis above the abscess. Stool examination may show *Entamoeba histolytica*, blood and pus cells, although this test has limitations in terms of sensitivity. Stool antigen detection may be helpful and facilitates early diagnosis before an antibody response occurs (<7 days), and differentiates pathogenic from non-pathogenic *Entamoeba* infection. The primary drawback is the requirement for fresh, unpreserved

antibody response occurs (<7 days), and differentiates pathogenic from non-pathogenic *Entamoeba* infection. The primary drawback is the requirement for fresh, unpreserved stool specimens. Liver biopsy is not helpful, but aspirating the abscess would be helpful.

B Hepatitis C

Hepatitis C leading to active hepatitis is more usually a chronic condition, leading to abnormal liver function tests and not to a marked elevation in white blood cell count.

C Hepatitis B

Like hepatitis C, hepatitis B presents with abnormal liver function tests or features of early cirrhosis, rather than the features of acute infection seen here.

D *Schistosoma haematobium*

D	*Schistosoma haematobium*

Schistosoma haematobium is often seen in East Africa and usually presents with urinary symptoms. The acute illness, Katayama fever, is seen more frequently with *S. mansoni* and *S. japonicum*, where these may present in the early stages of infection with hepatomegaly, cough or wheeze and fever as the flukes migrate via the lungs to the liver.

E	Hydatid cyst

Hydatid cyst is often asymptomatic, but can present with hepatomegaly, obstructive jaundice, fever and cholangitis in people living near rural sheep farms, for example in China, Russia, Wales and Japan. It is less likely to be seen in city dwellers.

33069

Rate this question:

A 65-year-old builder presents with a 4-week history of increasing abdominal swelling and swollen ankles. There has been one admission with acute pancreatitis a few years ago and he reports a similar episode of severe vomiting and epigastric pain after a curry and beers a few weeks earlier.

He has a history of hypertension and normally takes a ß-blocker. He smokes 30 cigarettes per day and drinks 28 units of alcohol per week. His abdomen is soft and non-tender with shifting dullness. Ultrasound scan of his abdomen shows large amount of ascites.

A diagnostic ascitic tap shows the following results:

Polymorphic neutrophil count	30 cells/mm^3
Fluid amylase	1800 IU/l (normal < 40 IU/l)
Total protein	30 g/l (normal 10–20 g/l)

	IU/l)
Total protein	30 g/l (normal 10–20 g/l)
Glucose concentration	2.0 mmol/l (normal < 5 mmol/l)
Carcinoembryonic antigen (CEA)	1 ng/ml (normal < 5ng/ml)

Which of the following is the MOST likely cause of his ascites?

A	Congestive cardiac failure
B	Pancreatitis
C	Budd–Chiari syndrome
D	Alcoholic cirrhosis
E	Nephrotic syndrome

abdominal swelling and swollen ankles. There has been one admission with acute pancreatitis a few years ago and he reports a similar episode of severe vomiting and epigastric pain after a curry and beers a few weeks earlier.

He has a history of hypertension and normally takes a ß-blocker. He smokes 30 cigarettes per day and drinks 28 units of alcohol per week. His abdomen is soft and non-tender with shifting dullness. Ultrasound scan of his abdomen shows large amount of ascites.

A diagnostic ascitic tap shows the following results:

Polymorphic neutrophil count	30 cells/mm^3
Fluid amylase	1800 IU/l (normal < 40 IU/l)
Total protein	30 g/l (normal 10–20 g/l)
Glucose	2.0 mmol/l (normal < 5

B Pancreatitis

This question tests knowledge on causes of ascites, traditionally ascites was divided into transudates and exudates. This case would have thus been classified as an exudate (protein content 30g/l). Causes of transudate ascites are cirrhosis and portal hypertension, cardiac failure, Budd–Chiari syndrome, myxodema. Causes of an exudate ascites include hepatic or peritoneal malignancy, intra-abdominal tuberculosis, and pancreatitis. However the serum-ascites albumin gradient (SAAG) has now largely replaced this concept and is the best single test for classifying ascites into portal hypertensive (SAAG > 11 g/L) and non–portal hypertensive (SAAG < 11 g/L) causes. (N.B. this may also be expressed in g/dl in which case the cut-off is 1.1 g/dl). Calculated by subtracting the ascitic fluid albumin value from the serum albumin value, it correlates directly with portal pressure. The specimens should be obtained relatively simultaneously. The accuracy

relatively simultaneously. The accuracy of the SAAG results is approximately 97% in classifying ascites. The terms high-albumin gradient and low-albumin gradient should replace the terms transudative and exudative in the description of ascites. An increased ascitic amylase concentration generally of the order of 2000 IU/l, is typical of pancreatic ascites. The ascitic total white cell count of > 500/μl or neutrophil count of > 250/μl is diagnostic of bacterial peritonitis.

A	Congestive cardiac failure

Congestive cardiac failure would usually cause a transudative ascities (with a SAAG > 11). The biochemistry from this case suggests an exudative (non-portal hypertensive) cause.

C	Budd–Chiari syndrome

Budd-Chiari syndrome (Option C) is incorrect. Budd-Chiari syndrome usually presents as a classical trial of

the hepatic vein. The ascites in Budd-Chiari syndrome is a transudate (with a SAAG > 11) via portal hypertension. The biochemistry from this case suggests an exudative cause.

D	Alcoholic cirrhosis

Alcoholic (Option D) is incorrect. The ascites in the context of cirrhosis is a transudate (with a SAAG > 11), as a result of portal hypertension. The biochemistry from this case suggests an exudative cause.

E	Nephrotic syndrome

Nephrotic syndrome (proteinuria, hypoalbuminemia, and oedema) has many causes, including primary kidney diseases such as minimal-change nephropathy, focal glomerulosclerosis, and membranous nephropathy. Nephrotic syndrome can also result from systemic diseases that affect other organs in addition to the kidneys, such as diabetes, amyloidosis, and lupus erythematosus. In patients with

D	Alcoholic cirrhosis

Alcoholic (Option D) is incorrect. The ascites in the context of cirrhosis is a transudate (with a SAAG > 11), as a result of portal hypertension. The biochemistry from this case suggests an exudative cause.

E	Nephrotic syndrome

Nephrotic syndrome (proteinuria, hypoalbuminemia, and oedema) has many causes, including primary kidney diseases such as minimal-change nephropathy, focal glomerulosclerosis, and membranous nephropathy. Nephrotic syndrome can also result from systemic diseases that affect other organs in addition to the kidneys, such as diabetes, amyloidosis, and lupus erythematosus. In patients with nephrotic ascites, usually the SAAG is < 11 g/L, but with a total protein in the ascites of < 25 g/L.

7394

Rate this question:

A 32-year-old chef from Pakistan presents with abdominal pain, abdominal swelling and weight loss.

His blood test shows elevated alkaline phosphatase and alanine transaminase enzyme levels. He has clinically detectable ascites.

A diagnostic tap was performed which shows the below results:

Total ascites white cell count	150/µl (< 500/µl)
Serum-ascites albumin gradient	21 g/l (< 11g/L)

What is the most likely cause of his ascites?

A Tuberculous peritonitis

B Peritoneal carcinomatosis

C Pancreatic ascites

D Biliary ascites

enzyme levels. He has clinically detectable ascites.

A diagnostic tap was performed which shows the below results:

Total ascites white cell count	150/µl (< 500/µl)
Serum-ascites albumin gradient	21 g/l (< 11g/L)

What is the most likely cause of his ascites?

A Tuberculous peritonitis

B Peritoneal carcinomatosis

C Pancreatic ascites

D Biliary ascites

E Acute portal vein thrombosis

E Acute portal vein thrombosis

Diagnostic paracentesis is useful in determining the cause of ascites. In more than 97% of cases, calculation of the serum to ascites albumin gradient (SAAG) complements the clinical assessment to help differentiate between those with ascites related to portal hypertension (gradient > 11g/L) from those whose aetiology is not related to portal hypertension (gradient < 11g/L). (N.B. this may also be expressed in g/dl in which case the cut-off is 1.1 g/dl).

Causes of increased SAAG include cirrhosis, alcoholic hepatitis, schistosomiasis, fulminant hepatic failure, Budd–Chiari syndrome, acute or chronic portal vein obstruction, cardiac diseases and spontaneous bacterial peritonitis secondary to cirrhosis. Causes of low or normal SAAG include nephrotic syndrome, protein losing enteropathy, peritoneal carcinomatosis, tuberculous peritonitis, pancreatic duct leak and biliary ascites.

cirrhosis. Causes of low or normal SAAG include nephrotic syndrome, protein losing enteropathy, peritoneal carcinomatosis, tuberculous peritonitis, pancreatic duct leak and biliary ascites. The ascites white cell count is also commonly normal in uncomplicated portal hypertension-related ascites.

B	Peritoneal carcinomatosis

Ascites in peritoneal carcinomatosis would typically have a total WCC > 500, but with < 50% polymorphonuclear neutrophils.

The SAAG would usually be < 11. Subsequent cross-sectional imaging would likely be suggestive of disseminated malignancy. Samples should be sent for cytology.

A	Tuberculous peritonitis

Tuberculous peritonitis (Option A) is incorrect. Ascites in Tuberculous peritonitis would classically have a total WCC > 500, but with < 50%

Incorrect. Ascites in tuberculous peritonitis would classically have a total WCC > 500, but with < 50% polymorphonuclear neutrophils. The SAAG would usually be < 11. Samples should be sent for mycobacterial analysis.

C	Pancreatic ascites

Ascites from pancreatic causes may have total ascitic WCC more, or less, than 500/µl, but regardless of the total ascitic WCC, usually the % PMN (polymorphonuclear neutrophils) should be > 50%. The SAAG is < 11. The ascites amylase level should be sent, and is usually > 1000 IU/l. If ascetic analysis is suggestive of a pancreatic cause, a pancreatic-protocol CT should be arranged to investigate further.

D	Biliary ascites

Biliary ascites (eg from gallbladder rupture) should have a SAAG < 11, and a raised ascites bilirubin content.

A 65-year-old woman is brought to the Emergency Department by her husband, complaining of upper abdominal and lower chest pain radiating to the back. As part of their 40th wedding anniversary celebrations, they had been out for a large meal, at which they had consumed more alcohol than they were normally used to.

On returning home, she had become nauseated and had vomited three times. Concurrently with the vomiting, she developed sudden-onset upper abdominal and lower chest pain and, subsequently, shortness of breath.

On examination, she was tachycardic at 105 bpm, tachypnoeic at 25 breaths per minute and pyrexial at 37.8 °C. She had firmness in the upper abdomen.

A chest X-ray was completed, and an image from it is shown below.

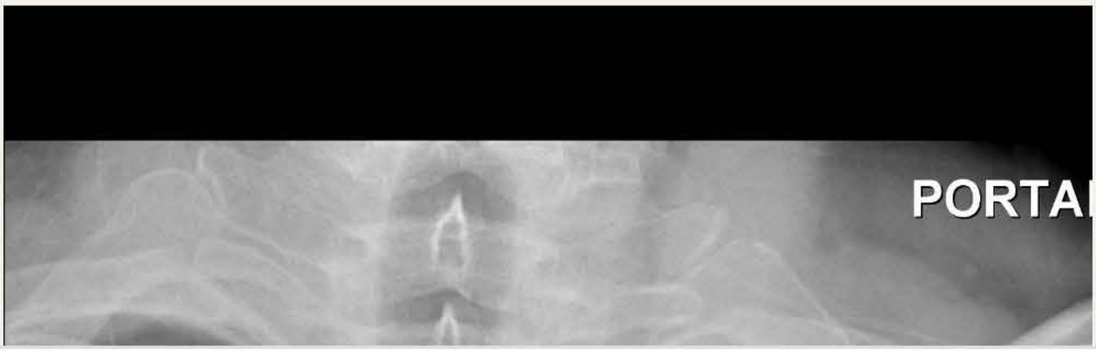

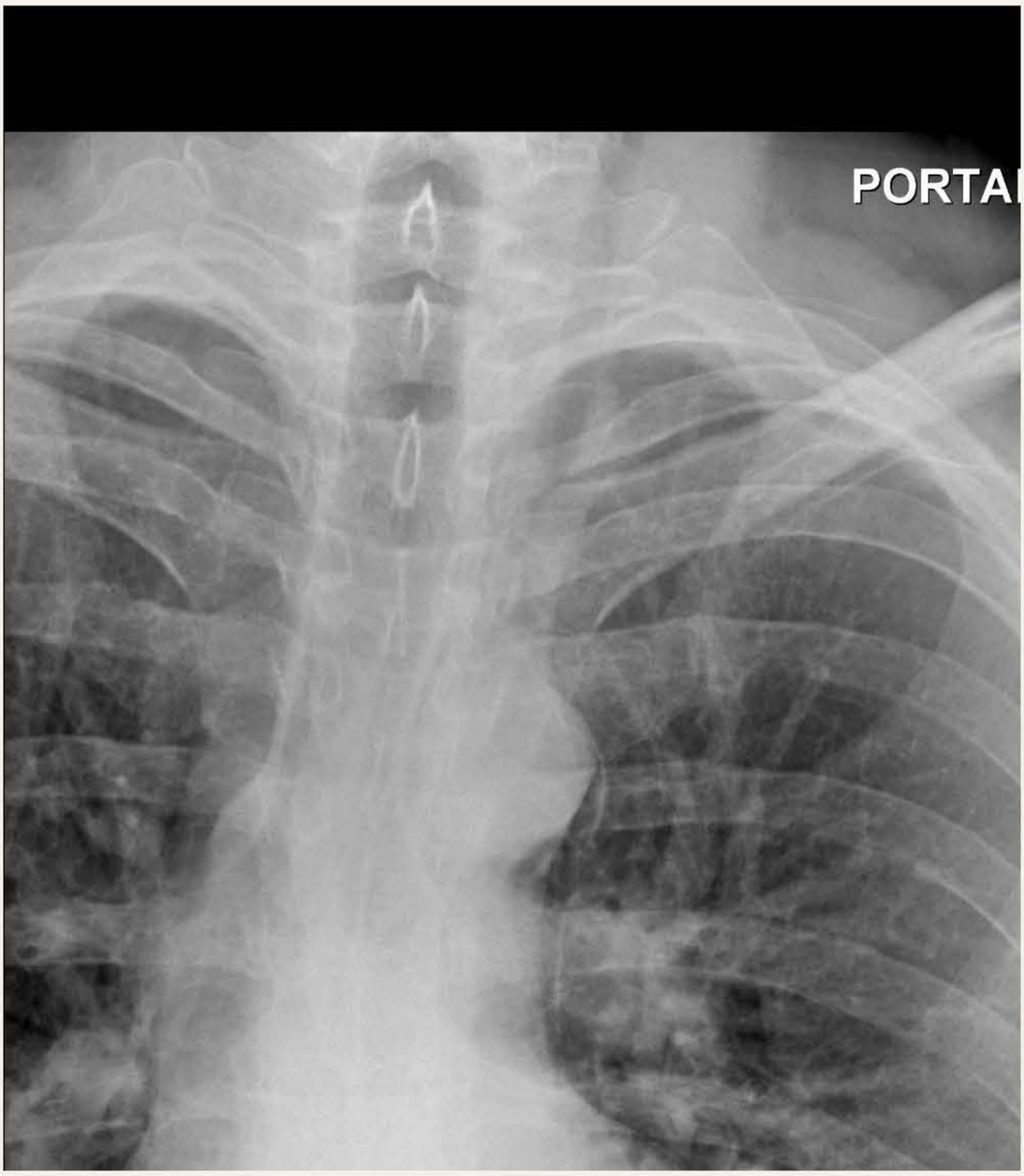

By Jto410 (In my work as a radiologist) [GFDL (http://www.gnu.org/copyleft/fdl.html) or CC BY-SA 3.0 (https://creativecommons.org/licenses/by-sa/3.0)], via Wikimedia Commons

Which of the following is the most likely diagnosis?

A Mallory–Weiss tear

7:39
:tps://mypastest.pastest.com
10

Which of the following is the most likely diagnosis?

A	Mallory–Weiss tear
B	Spontaneous pneumothorax
C	Acute pancreatitis
D	Perforated peptic ulcer
E	Boerhaave syndrome

70168

Submit

Previous Question Skip Question

Calculator

were normally used to.

On returning home, she had become nauseated and had vomited three times. Concurrently with the vomiting, she developed sudden-onset upper abdominal and lower chest pain and, subsequently, shortness of breath.

On examination, she was tachycardic at 105 bpm, tachypnoeic at 25 breaths per minute and pyrexial at 37.8 °C. She had firmness in the upper abdomen.

A chest X-ray was completed, and an image from it is shown below.

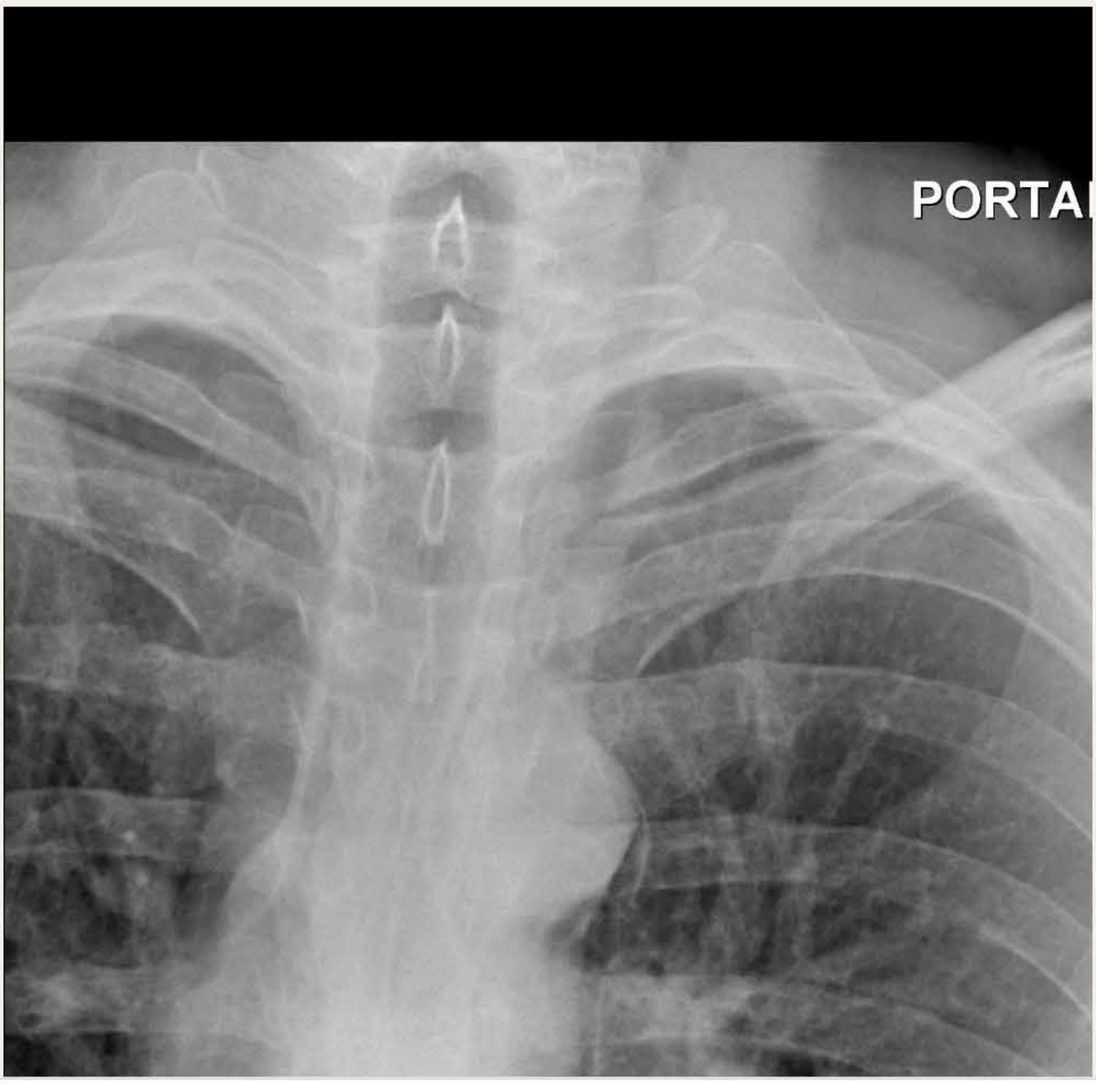

E Boerhaave syndrome

Boerhaave syndrome, described by Herman Boerhaave in the eighteenth century, is defined as a spontaneous (as opposed to iatrogenic) oesophageal rupture. It is classically associated with violent vomiting and is more common in men than in women. It most commonly occurs in the distal oesophagus and typically affects the left posterior wall. Unlike in Mallory–Weiss syndrome (in which a partial-thickness tear occurs), haematemesis is uncommon in Boerhaave syndrome.

Instead, the classic presentation is of vomiting, followed by the sudden onset of severe retrosternal chest pain/upper abdominal pain. Other symptoms may include shortness of breath, odynophagia and pleuritic pain.

Clinical findings include surgical emphysema, pleural effusions (normally left-sided, as this is where the perforation tends to be) and – depending upon the interval between

the perforation tends to be) and – depending upon the interval between onset and presentation – features of mediastinitis.

Chest X-rays may be normal early in the disease process but can demonstrate pneumomediastinum, pneumothorax, subcutaneous emphysema and/or pleural effusions as the condition progresses. The X-ray in this case demonstrates pneumomediastinum, with evidence of subcutaneous emphysema in the tissues surrounding the trachea.

Computed tomography (CT) scans may confirm the diagnosis and demonstrate any associated collections, while the pattern of contrast extravasation on a water-soluble contrast swallow helps to define the anatomy and extent of the leak. Definitive management of the condition is surgical.

A	Mallory–Weiss tear

Mallory–Weiss tear is unlikely here,

A Norwegian woman who is living in England is reviewed in the Gastroenterology Clinic. She is 31 weeks pregnant with her first child and has severe and uncontrollable itching.

On examination, she looks relatively well, her BP is 105/60 mmHg, pulse 75/min, and her abdomen is consistent with a 31-week pregnancy.

Investigations:

Hb	10.9 g/dl
WCC	5.4×10^9/l
PLT	195×10^9/l
Na^+	139 mmol/l
K^+	4.3 mmol/l
Creatinine	90 μmol/l
ALT	320 U/l
Alk Phos	420 U/l
Bilirubin	67 μmol/l

Which of the following is the most appropriate way to manage her?

ALT	320 U/l
Alk Phos	420 U/l
Bilirubin	67 μmol/l

Which of the following is the most appropriate way to manage her?

A	Ursodeoxycholic acid
B	Urgent delivery of the fetus
C	Anti-coagulation
D	Oral corticosteroids
E	Observe

21447

Submit

A Norwegian woman who is living in England is reviewed in the Gastroenterology Clinic. She is 31 weeks pregnant with her first child and has severe and uncontrollable itching.

On examination, she looks relatively well, her BP is 105/60 mmHg, pulse 75/min, and her abdomen is consistent with a 31-week pregnancy.

Investigations:

Hb	10.9 g/dl
WCC	5.4×10^9/l
PLT	195×10^9/l
Na^+	139 mmol/l
K^+	4.3 mmol/l
Creatinine	90 μmol/l
ALT	320 U/l
Alk Phos	420 U/l
Bilirubin	67 μmol/l

Which of the following is the most

K^+	4.3 mmol/l
Creatinine	90 µmol/l
ALT	320 U/l
Alk Phos	420 U/l
Bilirubin	67 µmol/l

Which of the following is the most appropriate way to manage her?

A Ursodeoxycholic acid

B Urgent delivery of the fetus

C Anti-coagulation

D Oral corticosteroids

E Observe

PLT	195 × 10^9/l
Na^+	139 mmol/l
K^+	4.3 mmol/l
Creatinine	90 µmol/l
ALT	320 U/l
Alk Phos	420 U/l
Bilirubin	67 µmol/l

Which of the following is the most appropriate way to manage her?

Your answer was correct

A Ursodeoxycholic acid

B Urgent delivery of the fetus

C Anti-coagulation

D Oral corticosteroids

A Ursodeoxycholic acid

The presentation with pruritus, raised ALP and ALT with only mildly elevated bilirubin is consistent with a diagnosis of cholestasis of pregnancy. The condition is characterised by pruritus (typically starting on the palms and soles of the feet) with raised fasting and post prandial serum bile acids. Total bilirubin is rarely raised. The condition occasionally presents with pale stool and dark urine. It typically occurs in the 3rd trimester and resolves up to 6 weeks post partum. Treatment is for pruritus with ursodeoxycholic acid and rifampicin. It is more common in Scandinavian women.

B Urgent delivery of the fetus

Cholestasis of pregnancy is associated with a slight increase in prematurity and post partum haemorrhage, however most pregnancies proceed to term without serious complications therefore urgent pre-term delivery is

C Anti-coagulation

Anticoagulation would be indicated in Budd-Chiari syndrome. However, this tends to present with abdominal pain and features of portal hypertension. Her ALT would probably be much higher representing hepatocyte ischaemia due to congestion. It is characterised by obstruction of the hepatic vein, sinusoidal congestion and portal hypertension. Pregnancy is a hypercoagulable state and risk of Budd Chiari is increased although remains rare. Most patients presenting with de novo occlusion tend to have an undiagnosed underlying thombophillia and should be investigated.

D Oral corticosteroids

There is no role for the use of steroids in cholestasis of pregnancy. Treatment is supportive aimed at reducing pruritus.

E Observe

A 29-year-old sales assistant undergoes upper endoscopy for symptoms of dyspepsia. The OGD demonstrates a duodenal lesion and biopsies have returned showing a MALT lymphoma.

What would be the best initial therapeutic strategy?

A	Duodenal stent insertion
B	Radiotherapy
C	Chemotherapy
D	Laparoscopic resection
E	Test and treat for *Helicobacter pylori*

E Test and treat for *Helicobacter pylori*

A MALT lymphoma is a B-cell tumour caused by an immune response to chronic *H. pylori* (HP) infection. The first therapeutic strategy in treating a GI MALT lymphoma is to eradicate HP *with a regimen of standard antibiotics and PPI, which leads to remission in 75% of cases.* HP eradication regimens are usually given to all patients, due to the possibility of negative HP results. Patients should undergo a Carbon-13 urea breath test (UBT) approximately ≥6 weeks after eradication therapy and ≥2 weeks after PPI withdrawal, to confirm eradication.

The carbon-13 UBT is based on the detection of the products created when urea is split by the organism. Patients are asked to drink urea (usually with a beverage) labelled with a carbon isotope (carbon-13 or -14). After a certain duration, the concentration of the labelled carbon is measured on the breath. The concentration is high only when urease

concentration is high only when urease is present in the stomach. Because the human stomach does not produce urease, such a reaction is possible only with HP infection. Problems include negative results due to infection with coccoid forms of HP that do not produce as much urease; and intake of antibiotics, bismuth, histamine-2 (H2) blockers, or proton pump inhibitors.

In the minority of patients who do not achieve lymphoma regression following antibiotic therapy, irradiation and systemic oncological therapies should be considered, depending on the stage of disease.

A Duodenal stent insertion

There is no suggestion from the history that the patient is suffering from symptoms of upper gastrointestinal tract or gastric outlet obstruction.

B Radiotherapy

In patients who do not achieve

In patients who do not achieve lymphoma regression following antibiotic therapy, radiotherapy with curative intent might be the preferred option for localised-stage disease. However, this is not an initial treatment strategy for this patient.

C Chemotherapy

In patients who do not achieve lymphoma regression following antibiotic therapy, chemo-immunotherapy with cyclophosphamide or chlorambucil may play a role in management, but this would not be an initial treatment strategy for this patient.

D Laparoscopic resection

Endoscopic mucosal resection and resectional surgery are rarely needed. In such instances, this would follow failure of initial medical therapies.

A 19-year-old man presents with an acute episode of bleeding per rectum. He had no abdominal pain or change in bowel habit.

On examination, he is pale but otherwise well. His pulse is 68/min and blood pressure (BP) 110/65 mmHg. His abdomen is soft and per rectal examination is unremarkable.

Investigations:

Hb	11.1 g/dl
MCV	77.2 fl
WCC	6.4×10^9/l
Platelets	542×10^9/l

Barium enema: normal scan. Colonoscopy: evidence of recent bleeding, no lesion seen. Technetium-99m pertechnetate scintigraphy: an abnormal focus of radiotracer accumulation in the suprapubic region of the abdomen; the focus of activity is visible 1 min after injection (same time stomach becomes visible) and gradually disappears over 30 min.

of the abdomen, the focus of activity is visible 1 min after injection (same time stomach becomes visible) and gradually disappears over 30 min.

What is the most likely diagnosis?

A	Carcinoid tumour
B	Crohn's disease
C	Meckel's diverticulum
D	Intestinal duplication cyst containing gastric mucosa
E	Non-Meckel's diverticulum-related intussusception

6876

Submit

WCC	$6.4 \times 10^9/l$
Platelets	$542 \times 10^9/l$

Barium enema: normal scan. Colonoscopy: evidence of recent bleeding, no lesion seen. Technetium-99m pertechnetate scintigraphy: an abnormal focus of radiotracer accumulation in the suprapubic region of the abdomen; the focus of activity is visible 1 min after injection (same time stomach becomes visible) and gradually disappears over 30 min.

What is the most likely diagnosis?

Your answer was correct

A Carcinoid tumour

B Crohn's disease

C Meckel's diverticulum

D Intestinal duplication cyst

C Meckel's diverticulum

Meckel's diverticulum occurs in approximately 2–3% of the population, predominantly in males, but is only symptomatic in 2% of those individuals. It is a remnant of structures within the fetal digestive tract that were not fully reabsorbed before birth. Most patients remain asymptomatic; complications however, may include haemorrhage, volvulus and intussusception, mostly in children younger than 10 years of age.

In virtually all patients who present with bleeding, ectopic gastric mucosa can be demonstrated in the diverticulum. Tc-99m pertechnetate scintigraphy has an overall specificity and sensitivity of 90% in establishing the diagnosis. Once bleeding occurs, surgery is recommended.

A Carcinoid tumour

It would be unusual for a small bowel carcinoid tumour to present with acute

It would be unusual for a small bowel carcinoid tumour to present with acute rectal bleeding. The tumours are often found incidentally and, if symptomatic, the most common symptom is vague abdominal pain, or occasionally, intermittent obstruction.

B	Crohn's disease

This would be an unusual presentation of Crohn's disease, which more commonly presents with abdominal pain, diarrhoea and weight loss. Colonoscopy may also reveal colitis or terminal ileitis.

D	Intestinal duplication cyst containing gastric mucosa

A small bowel duplication cyst is a possible cause of a false-positive Tc-99m pertechnetate scintigraphy 'Meckel's scan'. Gastrointestinal duplication cysts are rare congenital malformations, and can be found at any level of the GI tract. While they

frequently do not communicate with the bowel lumen, gastric mucosa (present in approximately 50% of duplication cysts) can ulcerate, perforate and form fistulas. Formation of a gastric duplication-colonic fistula is unusual but can result in a lower gastrointestinal bleed. In addition, a duplication cyst that communicates with the intestine can result in bleeding into the GI tract. While the presentation may be difficult to differentiate from that of a bleeding Meckel's diverticulum, an intestinal duplication cyst containing gastric mucosa communicating with the GI tract is a much rarer phenomenon, and hence Meckel's diverticulum is a better answer.

E	Non-Meckel's diverticulum-related intussusception

Non-Meckel's diverticulum-related intussusception typically presents between 5 and 7 months of age with vomiting. Older children also complain of abdominal pain. There may be a

with the intestine can result in bleeding into the GI tract. While the presentation may be difficult to differentiate from that of a bleeding Meckel's diverticulum, an intestinal duplication cyst containing gastric mucosa communicating with the GI tract is a much rarer phenomenon, and hence Meckel's diverticulum is a better answer.

E	Non-Meckel's diverticulum-related intussusception

Non-Meckel's diverticulum-related intussusception typically presents between 5 and 7 months of age with vomiting. Older children also complain of abdominal pain. There may be a preceding history of lethargy and a recent viral illness. A palpable abdominal mass or abdominal distension may be found on examination.

6876

Rate this question:

A 65-year-old man with a long history of alcohol abuse was brought to the Emergency Department by his son. He had been diagnosed with liver cirrhosis several years in the past, but had not had any contact with medical services since then.

His son stated that he had been deteriorating over the last few weeks, with confusion, irritability, disturbed sleep and recurrent falls. Neighbours had called the son after the patient had not been seen out for 48 hours. He had been consuming even more alcohol than usual since the death of his wife 3 months ago. His only other past medical history was osteoarthritis, for which he took codeine and paracetamol as required.

On examination, he had a Glasgow Coma Scale of 9 and was deeply jaundiced. He was pyrexial, tachycardic and hypotensive. There were stigmata of chronic liver disease and asterixis was present. He had a large, tense distended tender abdomen with scanty bowel sounds. Rectal examination was

Cardiorespiratory examination was unremarkable. He was poorly co-operative with the neurological examination; however, his pupils were equal and reactive and he had increased tone and reflexes throughout all four limbs.

Investigation results are below:

Hb	12.8 g/dl
WCC	14.0×10^9/l
PLT	100×10^9/l
MCV	108 fl
Na^+	130 mmol/l
K^+	3.6 mmol/l
Urea	7.6 mmol/l
Creatinine	170 μmol/l
Glucose	3.4 mmol/l
Bilirubin	110 μmol/l
Alanine aminotransferase (ALT)	520 IU/l

Alkaline phosphatase	320 IU/l
Gamma-glutamyl transferase	600 IU/l
Prothrombin time	22 s
Chest X-ray	No focal abnormality
Urinalysis	Protein +

What is the most important investigation to rule out a cause of his encephalopathy?

A	Urgent oesophagogastroduodenoscopy
B	Electroencephalogram (EEG)
C	Paracetamol levels
D	Serum alpha-fetoprotein levels
E	Serum ammonia levels

C Paracetamol levels

Possible causes of this patient's deterioration of heath include; Drug over-dosage, Infection (e.g. spontaneous bacterial peritonitis), subdural hematoma and alcohol binge. In this patient, possibility of hepatotoxic drug over-dosage or exposure must first be excluded, in view of recent family bereavement. Thus, paracetamol levels should be checked initially to exclude paracetamol-induced acute liver Injury. Management of such patient includes; identifying and removing the cause by activated charcoal in those presented < 4 hours after oral dosage of paracetamol. N-acetylcysteine can be started if patient presents < 10-12 hours since overdose with no vomiting and high plasma levels of paracetamol.

E Serum ammonia levels

Serum ammonia levels is typically elevated in acute liver injury and also

correlates with development of encephalopathy. The possibility of paracetamol overdose must be excluded before testing for other causes and complications of acute liver disease.

A	Urgent oesophagogastroduodenoscopy

There is no evidence of acute GI bleeding at this stage of the disease. Upper GI endoscopy may be indicated at a later stage to visualize any variceal bleeding, according to clinical signs and symptoms.

B	Electroencephalogram (EEG)

Acute liver injury and hepatic encephalopathy can lead to increased intracranial pressure (ICP) with cerebral oedema, which is the leading cause of death. EEG is useful in monitoring of hepatic encephalopathy and predicts outcomes of acute liver disease. EEG can be requested in

cerebral oedema, which is the leading cause of death. EEG is useful in monitoring of hepatic encephalopathy and predicts outcomes of acute liver disease. EEG can be requested in accordance with the clinical picture of the patient. Due to the recent history of falls and depressed conscious level, computed tomography (CT) of the head should also be performed to exclude a subdural haematoma.

D	Serum alpha-fetoprotein levels

Serum alpha-fetoprotein level is used to evaluate prognosis in patients with paracetamol-induced fulminant hepatic failure, thus a wrong option to select. Increased levels of alpha-fetoprotein predicts favourable outcomes in paracetamol induced hepatic failure cases.

33009

Rate this question:

Next Question

A 46-year-old man complains of acute epigastric pain radiating to his back. This is associated with vomiting. The pain is improved when he sits forward. He drinks half a bottle of whisky per day.

On examination, he is mildly pyrexial. He looks jaundiced and unwell. He is tachycardic and slightly hypotensive. There is generalised tenderness of the abdomen. There is no guarding or rebound rigidity. Bowel sounds are normal.

Electrocardiography, erect chest and abdominal radiography are normal. Abdominal ultrasonography shows a small liver, normal bile ducts and minimal fluid around the pancreas.

Which of the following is an indicator of poor prognosis for his condition?

A	PaO_2 = 9.5 kPa
B	Serum albumin = 34 g/l
C	Serum sodium = 131 mmol/l

normal.

Electrocardiography, erect chest and abdominal radiography are normal. Abdominal ultrasonography shows a small liver, normal bile ducts and minimal fluid around the pancreas.

Which of the following is an indicator of poor prognosis for his condition?

A	PaO_2 = 9.5 kPa
B	Serum albumin = 34 g/l
C	Serum calcium = 1.91 mmol/l
D	Aspartate aminotransferase = 98 IU/l
E	Serum creatinine = 150 mmol/l

C | Serum calcium = 1.91 mmol/l

The patient has acute pancreatitis secondary to alcohol (95% of acute pancreatitis is attributable to gallstones and alcohol). The pain in pancreatitis can be very severe and is relieved by leaning forward. In severe cases, patients are shocked.

There are several severity scoring systems used to assess prognosis/predict mortality. The Ranson criteria use the following parameters (assessed at admission and 48h) to predict mortality in alcoholic pancreatitis: age > 55, WCC > 16.0 × 10^9/l, fasting blood glucose > 11 mmol/l, LDH > 350 IU/l, serum AST >250 IU/l; within 48 h of admission: haematocrit decrease by >10%, arterial PaO_2 <8 kPa, serum calcium < 2.0 mmol/l, blood urea nitrogen increase > 1.8 mmol/l, base deficit > 4 mmol/l, fluid sequestration > 6 l. Mortality ranges from 1% for those with <3 criteria to 90% for those with >6 criteria.

Other assessment systems include the

Other assessment systems include the Glasgow score and Acute Physiology and Chronic Health Evaluation (APACHE) II scoring system.

There are limitations to most scoring systems (as most require 48 h to determine predicted outcome) and the patient needs to be aggressively fluid resuscitated early to reduce the chance of progression to end organ dysfunction (250–500 ml/h isotonic crystalloid during first 12–24 h). The most recent British Society of Gastroenterology guidelines are from 2005. For more recent guidelines see American College of Gastroenterology: Management of Acute Pancreatitis (2013), *Am J Gastroenterol* 2013; 108:1400–1415.

A	PaO_2 = 9.5 kPa

In the Glasgow prognostic criteria for alcoholic and gallstone pancreatitis, a Pa O_2 of <8kPa in room air is a marker of poor prognosis. Other criteria include:

A	PaO_2 = 9.5 kPa

In the Glasgow prognostic criteria for alcoholic and gallstone pancreatitis, a Pa O_2 of <8kPa in room air is a marker of poor prognosis. Other criteria include:

Age	>55
Serum albumin	<32g/l
Serum Ca	<2 mmol/l
Blood glucose	>10 mmol/l
Serum LDH	>600 units/l
Serum urea nitrogen	>16.1 mmol/l
WBC	>15

With a score <3, severe pancreatitis (defined as the presence of persistent organ failure >48 h) is unlikely to occur.

B	Serum albumin = 34 g/l

In the Glasgow prognostic criteria for

An 18-year-old woman is admitted on the adult take. She has been working as an assistant in a nursery where she contracted chicken pox. She initially recovered well and had been given a proprietary cold preparation containing aspirin and paracetamol by her parents.

She was even well enough to attend the 18th birthday party of a friend, and on arriving home she appeared happy but not intoxicated. Now she presents with intractable and uncontrollable vomiting.

On admission by ambulance to the Emergency Department, she is unrousable and suffers a generalised tonic-clonic seizure. Examination of the abdomen reveals hepatomegaly.

Investigations:

ALT	570 U/l
AST	460 U/l
Bilirubin	85 μmol/l

Which of the following diagnoses fits

tonic-clonic seizure. Examination of the abdomen reveals hepatomegaly.

Investigations:

ALT	570 U/l
AST	460 U/l
Bilirubin	85 μmol/l

Which of the following diagnoses fits best with this clinical picture?

A	Paracetamol overdose
B	Reye syndrome
C	Alcohol-related hepatic encephalopathy
D	Aspirin overdose
E	Varicella-related encephalopathy

An 18-year-old woman is admitted on the adult take. She has been working as an assistant in a nursery where she contracted chicken pox. She initially recovered well and had been given a proprietary cold preparation containing aspirin and paracetamol by her parents.

She was even well enough to attend the 18th birthday party of a friend, and on arriving home she appeared happy but not intoxicated. Now she presents with intractable and uncontrollable vomiting.

On admission by ambulance to the Emergency Department, she is unrousable and suffers a generalised tonic-clonic seizure. Examination of the abdomen reveals hepatomegaly.

Investigations:

ALT	570 U/l
AST	460 U/l
Bilirubin	85 μmol/l

B Reye syndrome

This syndrome is the rarely occurring triad of encephalopathy, fatty liver degeneration and elevated transaminases during a post-infectious period. The condition is documented as occurring predominantly in patients under the age of 18 years and is most commonly associated with influenza or varicella infection. Case fatality rate is very high, at between 25 and 50% of patients. The key factor in avoiding the syndrome is the cessation of aspirin use in children and teenagers. Unfortunately, there is no specific antidote and treatment is supportive, a key factor being recognition and treatment of raised intracranial pressure.

A Paracetamol overdose

Given that the only legitimate source of paracetamol for this patient is from her parents, and there is no evidence of underlying depression, paracetamol

overdose is unlikely.

C	Alcohol-related hepatic encephalopathy

Hepatic encephalopathy is unlikely given that she was not particularly intoxicated on her return home from the birthday party.

D	Aspirin overdose

Aspirin overdose in its earliest stages is associated with hyperventilation, vomiting and tinnitus.

E	Varicella-related encephalopathy

This is associated with progressive short-term memory loss and confusion. It may be associated with significantly decreased conscious level and seizures, but the history here of exposure to aspirin means that Reye syndrome should first be excluded.

A 60-year-old retired teacher presents with an itchy rash on her trunk and elbows. She has a 20-year history of coeliac disease and claims to be on a gluten-free diet. She had a thyroidectomy 10 years ago. She drinks two cans of beer per day.

On examination, she has xanthelasma and excoriation marks on her body. There are no stigmata of chronic liver disease. The rest of the physical examination is normal.

Investigations

Haemoglobin	10.7 g/dl
White blood count (WBC)	3.7×10^9/l
Platelets	148×10^9/l
Mean cell volume (MCV)	76 fl
Bilirubin	29 μmol/l
Alanine aminotransferase (ALT)	308 U/l (5–35)
Alkaline phosphatase (ALP)	1063 U/l (30–150)

Alanine aminotransferase (ALT)	308 U/l (5–35)
Alkaline phosphatase (ALP)	1063 U/l (30–150)
Gamma GT (GGT)	520 U/l
Albumin	36 g/l
Erythrocyte sedimentation ratio	81 mm/1st h
Lactate dehydrogenase	459 U/l
Anti-smooth muscle antibody (ASMA)	Negative
Anti-mitochondrial antibody (AMA)	Positive (1 in 80)
Ultrasound scan of liver	Normal

What is the most appropriate treatment?

A	Penicillamine
B	Ursodeoxycholic acid

sedimentation ratio	h
Lactate dehydrogenase	459 U/l
Anti-smooth muscle antibody (ASMA)	Negative
Anti-mitochondrial antibody (AMA)	Positive (1 in 80)
Ultrasound scan of liver	Normal

What is the most appropriate treatment?

A	Penicillamine
B	Ursodeoxycholic acid
C	Phenobarbitone
D	Corticosteroids
E	Azathioprine

B Ursodeoxycholic acid

This woman has evidence of dermatitis herpetiformis, likely to be a result of lack of compliance with her diet. She also has other autoimmune disease such as thyroid disorder. She has now developed PBC associated with her coeliac disease. In PBC, liver function tests are cholestatic, and the presence of anti-mitochondrial antibody at a titre of >1:40 is highly suggestive of PBC. Ursodeoxycholic acid is widely used, and meta-analysis has shown that it improves liver biochemistry and delays disease progression, although only if used very early in the course of the disease. Other drugs such as methotrexate, azathioprine, corticosteroids, cyclosporine and penicillamine have been tried, but clinical benefit is unproven and side effects may be significant.

A Penicillamine

Penicillamine would be the correct treatment for Wilson's disease.

treatment for Wilson's disease. Wilson's is an inherited disorder of failure of biliary copper excretion leading to copper accumulation, causing deposition in the liver and CNS. This would have been suggested by evidence of liver disease, tremor or dysarthria, amongst other symptoms. The liver function tests suggest a cholestatic rather than a hepatic picture, making this a less likely diagnosis.

C	Phenobarbitone

Phenobarbitone is an anti-epileptic drug which can be used in nearly all forms of epilepsy. It can also be used to lower levels of unconjugated hyperbilirubinaemia, such as in Gilbert syndrome.

D	Corticosteroids

Corticosteroids could be considered as treatment for inflammatory conditions. A possible relevant inflammatory

to lower levels of unconjugated hyperbilirubinaemia, such as in Gilbert syndrome.

D	Corticosteroids

Corticosteroids could be considered as treatment for inflammatory conditions. A possible relevant inflammatory condition is autoimmune hepatitis, which would have been suggested by anti-smooth muscle antibody rather than anti-mitochondrial antibodies.

E	Azathioprine

This is an immunosuppressive agent used generally for rheumatoid arthritis, inflammatory bowel disease and following organ transplantation. As there is no evidence of any of these conditions, there is no need for azathioprine.

7411

Rate this question:

A 58-year-old man is referred for investigation of dysphagia. This had been gradually worsening over the last year, but was intermittent in nature and was for both solids and liquids. He also described the frequent regurgitation of old food several hours after eating.

Recently, he had been experiencing occasional episodes of severe retrosternal chest pain. He denied weight loss and heartburn. He had no significant past medical history and was on no regular medication. He was a non-smoker and rarely drank alcohol.

A full clinical examination was entirely normal, as was his full blood count, urea and electrolytes and liver function tests. A chest X-ray was normal, and barium swallow was reported as showing a dilatation in the upper portion of the oesophagus, with tapering at the lower end. He underwent upper gastrointestinal endoscopy, which showed some old food in the oesophagus but no other abnormality.

barium swallow was reported as showing a dilatation in the upper portion of the oesophagus, with tapering at the lower end. He underwent upper gastrointestinal endoscopy, which showed some old food in the oesophagus but no other abnormality.

Which one of the following investigations should be performed next?

A	Oesophageal manometry
B	CT scan of the abdomen
C	Endoscopic ultrasound scan
D	Double-contrast barium meal
E	24 h intraluminal oesophageal pH monitoring

A Oesophageal manometry

The diagnosis is achalasia, where a range of investigations including endoscopy may be normal. The barium swallow is suggestive of achalasia and the definitive diagnostic test is oesophageal manometry, which will confirm a high oesophageal resting tone, weak or absent peristalsis and a non-relaxing lower oesophageal sphincter. Treatment options include endoscopic pneumatic dilation of the LOS (successful in 80% of cases), intra-sphincteric botulinum toxin injection and surgical division of the LOS (Heller's cardiomyotomy). There is an increased risk of carcinoma of the oesophagus in patients with achalasia.

Achalasia has an incidence of 1 per 100,000 per year and is defined as reduced or absent peristalsis and failure of the lower oesophageal sphincter (LOS) to relax when swallowing. It is due to the degeneration of ganglionic cells in the nerve plexi of the oesophageal wall. It can present at any age with

intermittent dysphagia to both solids and liquids, regurgitation, severe retrosternal chest pain and aspiration pneumonia.

B	CT scan of the abdomen

Given the barium swallow points towards achalasia and endoscopy has ruled out oesophageal malignancy, the next important step is manometry. CT of the abdomen is more useful for investigation of intra-abdominal masses.

C	Endoscopic ultrasound scan

Endoscopic ultrasound of the oesophagus may be of value in investigating underlying oesophageal carcinoma, but doesn't have a role here.

D	Double-contrast barium meal

A double-contrast barium meal

Endoscopic ultrasound of the oesophagus may be of value in investigating underlying oesophageal carcinoma, but doesn't have a role here.

D	Double-contrast barium meal

A double-contrast barium meal wouldn't add further information to that already known about this patient's oesophageal dysmotility, and is therefore not useful here.

E	24 h intraluminal oesophageal pH monitoring

Intraluminal pH monitoring is most useful when oesophageal reflux is suspected, particularly when it occurs at night, but the endoscopy examination is equivocal.

6745

Rate this question:

Next Question

A 52-year-old man presented with an attack of acute upper abdominal pain associated with vomiting.

On examination, he had epigastric tenderness and guarding. Serum amylase was 1300 IU/l. He was treated with intravenous antibiotics, fluids and analgesia. His pain settled and he made a good recovery and was discharged from hospital several days later.

Eight weeks later, he was readmitted with malaise and persistent abdominal pain.

On examination, he had a low-grade pyrexia and there was a tender mass palpable in the upper abdomen. His heart rate is 96 bpm and his blood pressure is 124/81 mmHg.

Investigations:

Haemoglobin (Hb)	11.2 g/l
White cell count	14×10^9/l
Platelets	390×10^9/l

Mean corpuscular volume (MCV)	82 fl
C-reactive protein (CRP)	200mg/l
Na^+	137 mmol/l
K^+	4.3 mmol/l
Urea	4.8 mmol/l
Creatinine	120 µmol/l
Ca^{2+}	2.50 mmol/l
Bilirubin	22 µmol/l
Alkaline phosphatase	160 IU/l
Gamma-glutamyl transferase	78 IU/l
Aspartate transaminase (AST)	42 IU/l
Amylase	1000 IU/l

Gamma-glutamyl transferase	78 IU/l
Aspartate transaminase (AST)	42 IU/l
Amylase	1000 IU/l

What is the most likely diagnosis?

A	Pancreatic pseudocyst
B	Pyogenic liver abscess
C	Chronic pancreatitis
D	Recurrent attack of acute pancreatitis
E	Pancreatic carcinoma

6743

Submit

A 52-year-old man presented with an attack of acute upper abdominal pain associated with vomiting.

On examination, he had epigastric tenderness and guarding. Serum amylase was 1300 IU/l. He was treated with intravenous antibiotics, fluids and analgesia. His pain settled and he made a good recovery and was discharged from hospital several days later.

Eight weeks later, he was readmitted with malaise and persistent abdominal pain.

On examination, he had a low-grade pyrexia and there was a tender mass palpable in the upper abdomen. His heart rate is 96 bpm and his blood pressure is 124/81 mmHg.

Investigations:

Haemoglobin (Hb)	11.2 g/l
White cell count	14×10^9/l
	390 ×

A Pancreatic pseudocyst

Pancreatic pseudocysts are an uncommon complication of acute pancreatitis, and are localised collections of pancreatic fluid and debris, usually in the lesser sac. They are initially contained within a fragile wall of granulation tissue which eventually forms a fibrous capsule. They cannot be diagnosed until more than 6 weeks after the acute attack, and may present with abdominal pain or a mass, fever and persistently raised amylase and liver function tests. Small pseudocysts usually resolve on their own, but those that are greater than 6 cm in diameter seldom disappear spontaneously and may lead to complications such as haemorrhage and infection. They are usually managed by endoscopic or percutanous drainage or surgical intervention.

D Recurrent attack of acute pancreatitis

Recurrent acute pancreatitis can occur, and in some patients this becomes a regular problem necessitating surgery if very severe. The presence of a tender and palpable mass makes this a less likely diagnosis.

B Pyogenic liver abscess

Liver abscesses mostly occur following peritonitis due to leaking of bowel content with spread to the liver by portal circulation. Alternatively, there can be direct spread from the biliary system or haematogenous seeding from systemic infection. Liver abcesses commonly cause fever and abdominal pain, whilst patients can also have anorexia, vomiting and weight loss. The low-grade, as opposed to a high-grade, fever, as well as the very delayed timing, makes this an unlikely diagnosis.

C Chronic pancreatitis

Chronic pancreatitis occurs with progressive inflammatory changes

C	Chronic pancreatitis

Chronic pancreatitis occurs with progressive inflammatory changes causing permanent structural damage, which results in impaired exocrine and endocrine function. It can present as chronic epigastric pain with nausea and vomiting which radiates to the back, or with pancreatic insufficiency causing malabsorption and steatorrhea. The acute abdominal signs and elevated amylase make this a less likely differential.

E	Pancreatic carcinoma

Pancreatic carcinoma is a cause of a painless epigastric mass and progressively worsening jaundice. The presence of pain and tenderness reduces the likelihood of this diagnosis, as does the absence of jaundice.

6743

Rate this question:

A 60-year-old woman undergoes investigation after presenting with intermittent diarrhoea alternating with constipation over a period of several months. In addition, she complains of cramping abdominal pains.

Her weight is steady. Her general practitioner has checked her routine bloods: haemoglobin is 98 g/l, erythrocyte sedimentation rate 20 mm/h and electrolytes and liver function tests are normal.

A view obtained at colonoscopy is shown below:

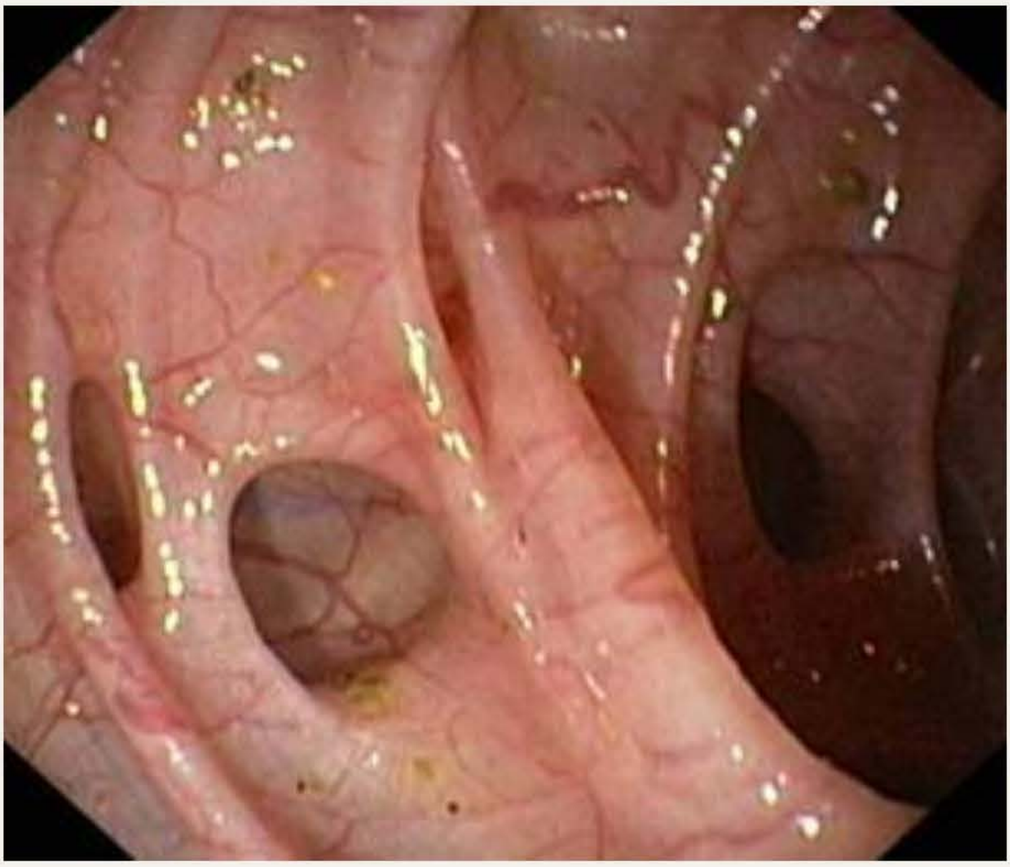

Image courtesy of Dr Hans Bjorknas, Gastrolab, Vasa, Finland.

What is the most likely deficiency underlying the anaemia?

A	Vitamin B_{12} deficiency
B	Vitamin B_{12} and folate deficiency
C	Iron deficiency
D	Folate deficiency
E	Ferritin deficiency

C Iron deficiency

he image shows colonic diverticulae, and her symptoms are typical of diverticular disease. This disorder, whose aetiology is poorly understood, may affect any part of the gastrointestinal (GI) tract, the sigmoid being the most commonly affected (involved in >90% of cases). The rest of the colon and the small intestine can also be affected. Lower GI blood loss may occur as frank haemorrhage or occult losses, as in this case; this results from rupture of the small blood vessels that are stretched while coursing over the dome of the diverticulae. Occult blood in the stool is present in approximately 25% of patients with diverticulitis. Iron deficiency is therefore a more common overall cause of anaemia related to this condition than is Vitamin B_{12} deficiency. Acute diverticulitis is a possible complication of diverticular disease; this results from the inspissation of faecal material in the neck of the diverticulum and resultant

inspissation of faecal material in the neck of the diverticulum and resultant bacterial replication. Cultural dietary factors may play a role in aetiology – it is a disease of Westernised societies and links have been demonstrated to low-fibre diets and high consumption of red meat and animal fats. However, genetic causes also exist. It is rare under the age of 40 years.

A	Vitamin B_{12} deficiency

Vitamin B_{12} is found in meat, fish and dairy products. It binds intrinsic factor in the stomach and is subsequently absorbed in the terminal ileum. It is a cause of macrocytic anaemia, and the patient may also have glossitis, angular cheilosis and may develop neurological complications. Chronic deficiency can cause psychosis, peripheral neuropathy and subacute combined degeneration of the spinal cord. Causes can be dietary lack, pernicious anaemia or due to factors affecting absorption in the terminal ileum, such as resection in Crohn's disease, bacterial overgrowth or tapeworms

B	Vitamin B_{12} and folate deficiency

As this patient is unlikely to have either B_{12} or folate deficiency as a primary cause for anaemia, this is unlikely.

D	Folate deficiency

Folate is found in green vegetables, nuts, yeast and liver and is absorbed in the duodenum and jejunum. Deficiency can lead to macrocytic anaemia and fetal neural tube defects. It can be caused by poor diet, increased demand (e.g. malignancy and renal dialysis, malabsorption in coeliac and other conditions) and can also occur from drug usage, including alcohol, methotrexate, phenytoin and valproate. Treatment is to address the underlying cause but only to replace folate with adequate vitamin B_{12}, as otherwise this can cause subacute demyelination of the spinal cord.

E	Ferritin deficiency

A 54-year-old businessman is brought in by ambulance from the airport with sudden-onset, excruciating upper abdominal pain radiating to his back following a flight. He has had recurrent vomiting during the whole of his flight. He has a history of hiatus hernia but no history of cardiac problems. He drinks 10 units of alcohol per week.

On examination, he is dyspnoeic and cyanosed. Blood pressure is equal on both arms and there is no radial–radial delay. His saturation is 88% on high-flow oxygen. Heart sounds are normal.

On chest examination, there is reduced air entry and dullness to percussion on the left side. There is marked epigastric tenderness and rigidity. His pain fails to improve with morphine or pethidine. Amylase and cardiac enzymes are within normal range.

Electrocardiography demonstrates sinus tachycardia but no other abnormalities.

Chest X-ray shows a left pleural effusion.

improve with morphine or pethidine. Amylase and cardiac enzymes are within normal range.

Electrocardiography demonstrates sinus tachycardia but no other abnormalities.

Chest X-ray shows a left pleural effusion.

Which of the following is the most likely diagnosis?

A	Dissecting thoracic aneurysm
B	Aspiration pneumonia
C	Acute pancreatitis
D	Perforated duodenal ulcer
E	Boerhaave's syndrome

7401

Submit

E Boerhaave's syndrome

Repeated vomiting followed by epigastric pain and pleural effusion should lead one to consider the diagnosis of spontaneous rupture of the oesophagus, also known as Boerhaave syndrome. It is relatively uncommon but serious and potentially fatal. It is complete transmural laceration of the lower part of the oesophagus, with gastric contents entering the mediastinum and pleural cavity. If one were to perform a pleural fluid aspirate, one is likely to aspirate gastric contents. It is usually caused by vomiting against a closed glottis.

Other clinical features that may suggest the diagnosis include odynophagia and surgical emphysema in the neck. It is more common in men than women and typically present in those between 50–70 years old. Early operation after appropriate resuscitation offers the best chance of survival.

Patients presenting with dissection classically have a history of hypertension. One would also expect a disparity in the blood pressure and pulse in acute dissections. Patients may also present with a neurological deficit due to involvement of the spinal and carotid arteries.

B Aspiration pneumonia

Although the recurrent vomiting and hiatus hernia would certainly be a risk factor, the persistent, excruciating pain would be uncharacteristic for an aspiration pneumonia as would such a rapid onset of a pleural effusion.

C Acute pancreatitis

A rise in amylase >3× the upper limit of normal is one of the diagnostic criteria for pancreatitis, and therefore the normal amylase level precludes this. See AGA guidelines on management of acute pancreatitis. Reference:

A 56-year-old retired teacher presents with acute epigastric pain and melaena. He had an upper gastrointestinal endoscopy 1 week prior to this and was found to have a non-bleeding gastric ulcer. He was started on a proton pump inhibitor. He previously took regular non-steroidal anti-inflammatory drugs for arthritis.

On examination, his heart rate is 100 bpm, and his blood pressure is 90/60 mmHg. His abdomen is tender and rigid, with absent bowel sounds. An erect chest X-ray is shown below.

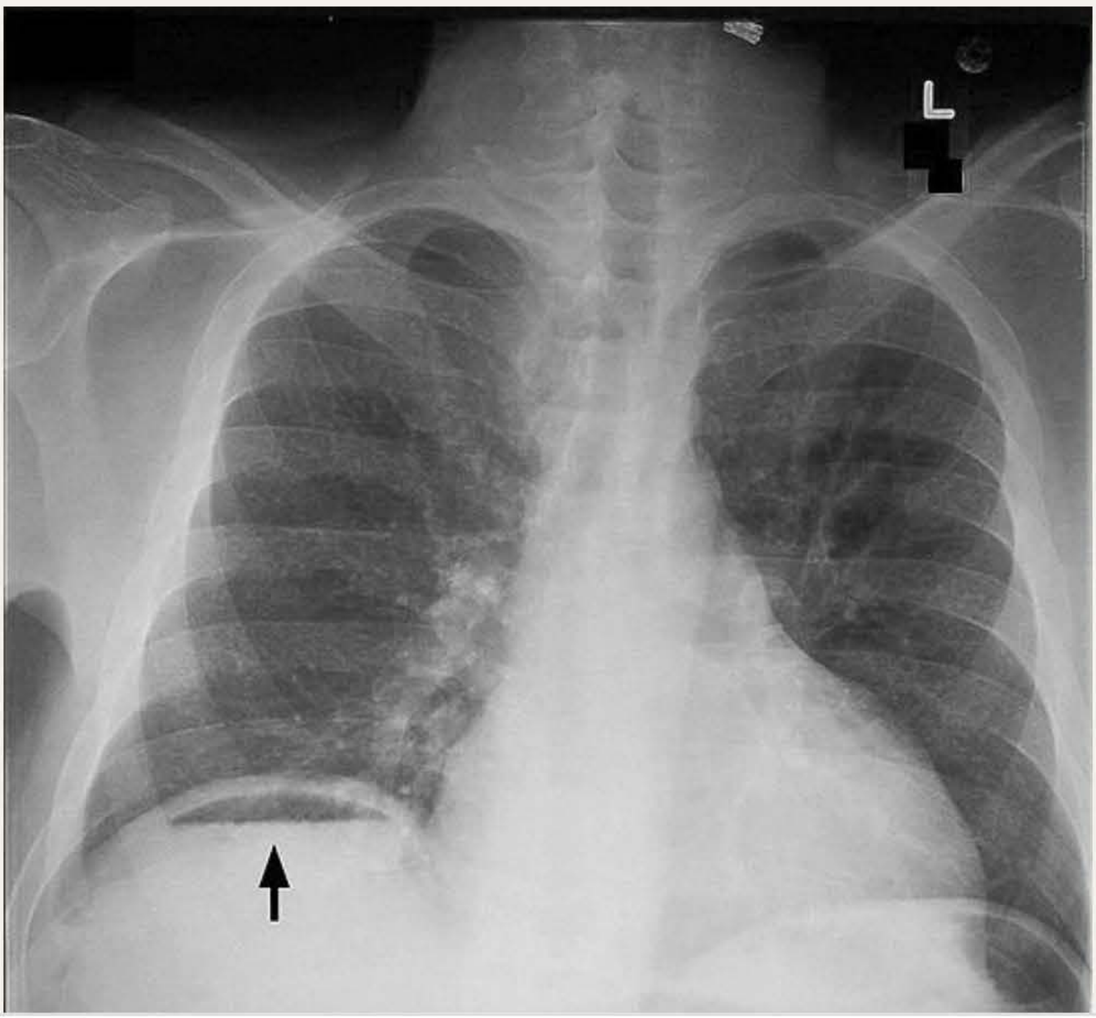



By Clinical_Cases: I made the photo myself, licensed under Creative Commons license. [CC BY-SA 2.5 (https://creativecommons.org/licenses/by-sa/2.5)], via Wikimedia Commons

He subsequently underwent surgery.

Following his surgery, he is most likely to have reduced absorption of which of the following?

A	Folate
B	Iron
C	Glucose
D	Vitamin D
E	Nicotinic acid

B Iron

Given the endoscopy findings and the pneumoperitoneum demonstrated on the chest X-ray, this patient is most likely to have gone on to have a gastrectomy.

Following gastrectomy, iron deficiency is common (occurring in 100% of total gastrectomy patients). This is due to the absence of the acidic environment that normally leads to ferric (3+) forms of iron being reduced to the more absorbable ferrous (2+) form, which is subsequently absorbed in the duodenum.

A Folate

The patient has most likely undergone a partial or total gastrectomy. Folate is absorbed in the jejunum, and absorption should therefore be unaffected. Common causes of folate deficiency are alcoholism and dietary causes.

C Glucose

Glucose is absorbed in the small intestine along the brush border membrane, and thus absorption should not be affected by gastrectomy.

D Vitamin D

Dietary vitamin D is absorbed in the small intestine, or in the skin through sunlight exposure. Diseases affecting the liver or kidney can lead to deficiency.

E Nicotinic acid

Nicotinic acid/vitamin B3 deficiency leads to pellagra. Absorption is in the duodenum and requires an alkaline environment for absorption.

7400

Rate this question:

Next Question

A 44-year-old man with a long history of diarrhoea presented with a painful lesion on his leg. He had noticed what he thought was an insect bite some days previously, which rapidly progressed to the lesion depicted below. He had started feeling unwell with the development of the lesion and described general malaise and arthralgia.

What is the diagnosis?

A	Pyoderma gangrenosum
B	Acanthosis nigricans
C	Erythema nodosum

days previously, which rapidly progressed to the lesion depicted below. He had started feeling unwell with the development of the lesion and described general malaise and arthralgia.

What is the diagnosis?

A	Pyoderma gangrenosum
B	Acanthosis nigricans
C	Erythema nodosum
D	Erythema multiforme
E	Dermatomyositis

A Pyoderma gangrenosum

Typically, this starts as a small papule or pustule that may often be mistaken for an insect bite. This rapidly spreads into an ulcerating lesion, with pain being a predominant feature. Although PG may occur at any age, it is most common in the fourth and fifth decades of life. Sex distribution is equal, and about half of cases occur in association with a systemic illness.

Inflammatory bowel disease is the strongest association, although less than 1% of people with IBD develop PG; other associations include rheumatological conditions (rheumatoid arthritis, seronegative spondyloarthropathies, etc.), liver disease (particularly autoimmune hepatitis) and haematological conditions (including both lympho- and myeloproliferative disorders).

Diagnosis is primarily based upon clinical findings. There are no really characteristic histological features, although biopsy is useful in helping to

although biopsy is useful in helping to exclude other diagnoses.

Topical corticosteroids are the typical first-line treatment, with systemic corticosteroids reserved for refractory disease. In the most severe cases, other potent immunosuppressants (including ciclosporin, mycophenolate mofetil or anti-TNF-α agents) may be required.

B	Acanthosis nigricans

Acanthosis nigricans is not typically associated with skin ulcers. Acanthosis nigricans manifests as velvety, hyperpigmented areas of skin, and most commonly occurs in skin folds or around the neck.

C	Erythema nodosum

Erythema nodosum is not typically associated with skin ulcers. IBD is a well-recognised risk factor for erythema nodosum, but this manifests as red–purple subcutaneous nodules

C Erythema nodosum

Erythema nodosum is not typically associated with skin ulcers. IBD is a well-recognised risk factor for erythema nodosum, but this manifests as red–purple subcutaneous nodules, particularly in the pre-tibial region.

D Erythema multiforme

Erythema multiforme is not typically associated with skin ulcers. Erythema multiforme classically produces 'target lesions' of the skin.

E Dermatomyositis

Dermatomyositis is not typically associated with skin ulcers, but is associated with a violaceous, scaly papular rash on extensor surfaces (known as Gottron's papules), as well as a purple-coloured 'heliotrope rash' around the eyes.

A 70-year-old man presents to the Emergency Department complaining of left iliac fossa tenderness, fevers and intermittent diarrhoea over the course of the past week.

On further questioning, he admits to having suffered from vague abdominal pains and bloating over the past few months. He has seen the dietician at his GP surgery for obesity management and also has a history of hypertension for which he is taking ramipril.

On examination, his blood pressure is 141/78 mmHg, he is pyrexial 37.8 °C and is diffusely tender in the left iliac fossa.

Investigations:

Hb	12.1 g/dl
WCC	13.1×10^9/l (neutrophilia)
PLT	190×10^9/l
Na^+	140 mmol/l
K^+	4.7 mmol/l

Hb	12.1 g/dl
WCC	13.1×10^9/l (neutrophilia)
PLT	190×10^9/l
Na^+	140 mmol/l
K^+	4.7 mmol/l
Creatinine	120 μmol/l
Urine	red cells+, white cells+

Which of the following is the most appropriate investigation?

A Intravenous urogram (IVU)

B Plain abdominal X-ray

C Urine culture

D Abdominal CT

E USS urinary tract

D Abdominal CT

The obesity, previous symptoms suggestive of irritable bowel and recent-onset diarrhoea are suggestive of diverticulitis [1]. The neutrophilia and left-sided abdominal tenderness also support the diagnosis. Red and white cells in the MSU are the result of periureteric inflammation. CT scanning helps with assessment of severity of diverticular disease, degree of local inflammation, evidence of local perforation and possible abscess formation. Management depends on disease severity: less complicated cases may be managed with IV antibiotics only, but GI surgical opinion as to the necessity for operative intervention is crucial.

A Intravenous urogram (IVU)

The symptoms are suggestive of diverticulitis. An IVU will give structural information about the urinary tract, which is of little utility here.

B Plain abdominal X-ray

An abdominal X-ray can show bowel obstruction and features of colitis but a CT abdomen will give more information and may point to the underlying diagnosis.

C Urine culture

Although a UTI/pyelonephritis could explain the left iliac fossa pain and fever, it would not explain the diarrhoea.

E USS urinary tract

It will give no information pertaining to the bowel and a CT is therefore preferable.

Reference

O'Neill S, Ross P, McGarry P, Yalamarthi S. Latest diagnosis and management of diverticulitis. BJMP, 2011, 4, a443.

A 42-year-old man presents to his general practitioner (GP) with jaundice. He gives a 20-year history of ulcerative colitis which is managed with Sulfasalazine, and he has been relatively well with respect to his colitis.

Over the past few months, he has been feeling increasingly tired and suffering from itching. He presents now because he has noticed that his urine has become dark and the whites of his eyes have gone yellow.

Investigations:

Hb	11.0 g/dl
WCC	6.1×10^9/l
PLT	210×10^9/l
Na^+	138 mmol/l
K^+	4.3 mmol/l
Creatinine	100 μmol/l
ALP	420 U/l
ALT	95 U/l

K^+	4.3 mmol/l
Creatinine	100 μmol/l
ALP	420 U/l
ALT	95 U/l
Bilirubin	110 μmol/l

Which of the following would be the preferred investigation?

A	Liver biopsy
B	Auto-antibody testing
C	Magnetic resonance cholangiopancreatography
D	Ultrasound
E	Hepatitis serology

C Magnetic resonance cholangiopancreatography

This patient has a positive history of ulcerative colitis and now presents with symptoms of obstructive jaundice with fatigue and pruritus. The most likely diagnosis here is PSC. Magnetic resonance cholangiopancreatography (MRCP) is considered to be the preferred imaging modality for cases of PSC. It is superior to endoscopic retrograde cholangiopancreatography (ERCP) due to its safety profile and diagnostic accuracy. MRCP has an accuracy of diagnosis for PSC of 90%, compared to 97% for ERCP.

A Liver biopsy

Liver biopsy is generally not necessary to establish a diagnosis of primary sclerosing cholangitis (PSC). However, it helps in diagnosing suspected cases of small duct PSC in patients with normal cholangiograms.

B	Auto-antibody testing

Auto-antibody testing for anti-smooth muscle, anti-nuclear and anti-neutrophil cytoplasmic antibodies, can be useful in cases of PSC, but these antibodies are not specific for PSC and are also present in other conditions.

D	Ultrasound

Ultrasound can be used for imaging of the biliary tract in patients with persistent cholestatic liver tests, but other methods such as MRCP and ERCP are regarded as preferred methods.

E	Hepatitis serology

There is no reason to request hepatitis serology at this stage of management, keeping in mind the likely diagnosis of PSC and a positive history of ulcerative colitis.

33076

A 21-year-old woman returns from a gap year trip to Thailand, where she was working at a village school. She is worried as she has begun losing weight, is feeling tired all the time and has chronic diarrhoea which she says is voluminous and difficult to flush away.

On examination, she looks very thin, with a BMI of 17. She is also pale and has bilateral ankle swelling.

Investigations:

Hb	10.4 g/dl (MCV 106 fl)
WCC	5.3×10^9/l
PLT	220×10^9/l
Na^+	139 mmol/l
K^+	4.0 mmol/l
Creatinine	100 μmol/l
Albumin	24 g/l

Jejunal biopsy shows mild villous atrophy, increased crypts and mononuclear cell infiltrates, and lipid accumulation below the basement

Creatinine	100 μmol/l
Albumin	24 g/l

Jejunal biopsy shows mild villous atrophy, increased crypts and mononuclear cell infiltrates, and lipid accumulation below the basement membrane. Coliform bacteria are isolated.

Which of the following is the most likely underlying diagnosis?

A Crohn's disease

B Coeliac disease

C Whipple's disease

D Tropical sprue

E Cryptosporidium

weight, is feeling tired all the time and has chronic diarrhoea which she says is voluminous and difficult to flush away.

On examination, she looks very thin, with a BMI of 17. She is also pale and has bilateral ankle swelling.

Investigations:

Hb	10.4 g/dl (MCV 106 fl)
WCC	5.3×10^9/l
PLT	220×10^9/l
Na^+	139 mmol/l
K^+	4.0 mmol/l
Creatinine	100 μmol/l
Albumin	24 g/l

Jejunal biopsy shows mild villous atrophy, increased crypts and mononuclear cell infiltrates, and lipid accumulation below the basement membrane. Coliform bacteria are isolated.

Which of the following is the most

D Tropical sprue

Tropical sprue occurs in tropical regions, predominantly central America and South-Eastern Asia. It is thought that an initial GI infection results in small bowel stasis, opportunistic colonisation by organisms such as coliforms, and then a degree of villous atrophy leading to malabsorption and B_{12}/folate deficiency. Treatment with vitamin replacement and a prolonged course of tetracycline for 3–6 months is recommended, although she should be warned not to get pregnant while taking the antibiotics. It is the clinical features of this condition, including the history prior to presentation, that drive us to a diagnosis of tropical sprue rather than Crohn's or coeliac disease.

C Whipple's disease

Whipple's disease shows infiltration of the lamina propria in the duodenum with PAS-positive macrophages.

the lamina propria in the duodenum with PAS-positive macrophages. Symptoms other than GI disturbance, including polyarthritis, are also seen.

A Crohn's disease

The presence of villous atrophy and enteropathic coliform bacteria is more consistent with tropical sprue. Crohn's disease is associated with lymphocytic infiltration and crypt abscess formation.

B Coeliac disease

Coeliac disease is associated with villous atrophy, although enteropathic coliform bacteria are not usually seen.

E Cryptosporidium

Cryptosporidium is associated with acute-onset watery diarrhoea, rather than the picture of chronic fat malabsorption seen here.

A 31-year-old woman, who is known to be hepatitis C-positive, comes to your clinic. She is 28 weeks' pregnant and she asks for information about risk of transmission of the virus to her baby. She is HIV-negative.

Which of the following is the most appropriate advice for her?

A	The risk of transmission to the baby is approximately 15%
B	Testing of any offspring for hepatitis C should not happen before 2 months
C	Elective caesarean is preferred to reduce the risk of vertical infection
D	Ribavirin should be given during late pregnancy to reduce the risk of transmission

B Testing of any offspring for hepatitis C should not happen before 2 months

The diagnosis of HCV infection is often made by detecting antibodies to hepatitis C, but because of maternal transmission of IgG, serological testing is therefore not reliable for up to the first 12 months of life. It's therefore recommended that infants are tested for HCV RNA on two occasions between 2 and 6 months of life, and for hepatitis C antibodies after 15 months.

C Elective caesarean is preferred to reduce the risk of vertical infection

Mode of delivery doesn't impact on risk of vertical hepatitis C transmission, and caesarean is therefore not recommended unless there are other reasons for retaining it as an option.

A The risk of transmission to the

The risk of vertical transmission is thought to be between 1.5 and 5%, although the risk is much higher in patients who are co-infected with HIV.

D	Ribavirin should be given during late pregnancy to reduce the risk of transmission

Ribavirin is teratogenic and is therefore not used in pregnancy. If possible, patients with hepatitis C should undergo eradication anti-viral therapy before trying for a family.

E	Breastfeeding is not advised because of the risk of vertical infection

Although HCV has been detected in maternal colostrum, transmission of HCV via breastfeeding has not been documented.

33020

Rate this question:

A 74-year-old man, who has recently returned from Singapore, presents to the Emergency Department with severe pneumonia. He is treated with intravenous (iv) co-amoxiclav and then transferred to oral after four days, but begins to develop severe diarrhoea. This worsens over the next 24 h until he is opening his bowels 8-10 times per day and beginning to get dehydrated.

On examination, his BP is 120/70 mmHg, his pulse is 92/min, but his BP decreases to 95/60 mmHg and his pulse increases to 105/min on standing. His temperature is 37.8 °C. His chest signs have significantly improved.

Investigations:

Hb	12.9 g/dl
WCC	12.1×10^9/l
PLT	187×10^9/l
CRP	44 mg/l (down from 187) (< 10)
Na^+	143 mmol/l

Hb	12.9 g/dl
WCC	12.1×10^9/l
PLT	187×10^9/l
CRP	44 mg/l (down from 187) (< 10)
Na^+	143 mmol/l
K^+	3.9 mmol/l
Creatinine	147 µmol/l

Which of the following is the most appropriate antibiotic choice?

A Metronidazole

B Mebendazole

C Ciprofloxacin

D Clindamycin

E Co-amoxiclav

A Metronidazole

This patient in all likelihood has *Clostridium difficile* infection resulting in the development of pseudomembranous colitis. Symptoms are typically said to occur between 5 and 10 days after commencing antibiotic therapy. Diagnosis is via stool samples detecting *Cl. difficile* toxin. Sigmoidoscopy is not used routinely, but can reveal distal ulceration and a possible yellow slough or pseudomembrane in around half of patients. Treatment of choice for psuedomembranous colitis is oral metronidazole (or intravenous metronidazole if there is no oral route), with oral vancomycin as a possible alternative. Supportive therapy with appropriate rehydration is also essential to avoid pre-kidney disease, and already debilitated patients have a significant mortality which may approach as high as 25%.

B Mebendazole

B Mebendazole

This is a medication used to treat parasitic worm infections, such as giardia and hookworm.

C Ciprofloxacin

This is a fluoroquinolone antibiotic that is associated with *Cl. difficile* infection.

D Clindamycin

This is an antibiotic that is associated with *Cl. difficile* infection.

E Co-amoxiclav

This is amoxicillin with clavulanic acid and is the antibiotic the patient has received for his pneumonia; it is likely that this was a significant contributing factor to his *Cl. difficile* infection.

23356

Rate this question:

work since. She also mentioned that her mother had had similar problems with shakiness for many years.

On examination, she has a tremor in both arms that was present when holding the arms outstretched, but is not there at rest. Tone is normal in all four limbs and gait is normal. There are no other neurological abnormalities on examination.

What is the best initial management for this patient?

A	Levodopa
B	Propranolol
C	Paroxetine
D	Ropinirole
E	Benzhexol

it had started just after losing her job when she noticed her hands became shaky whenever she was doing something. She had become particularly anxious since losing her job as she had not been able to find work since. She also mentioned that her mother had had similar problems with shakiness for many years.

On examination, she has a tremor in both arms that was present when holding the arms outstretched, but is not there at rest. Tone is normal in all four limbs and gait is normal. There are no other neurological abnormalities on examination.

What is the best initial management for this patient?

Your answer was correct

A Levodopa

B Propranolol

C Paroxetine

B Propranolol

The most likely diagnosis is of an essential tremor. It is a postural tremor, not present at rest, made worse by anxiety. There are no parkinsonian features on examination and there is a family history of a similar tremor. Around 50% of patients will show some response to a beta-blocker. Clozapine, mirtazapine, topiramate and gabapentin are all potential alternatives.

A Levodopa

Anti-parkinsonian medications are ineffective in controlling essential tremor.

C Paroxetine

Although the tremor has become more noticeable, it isn't linked to social anxiety and there is therefore no value in treatment with an SSRI.

noticeable, it isn't linked to social anxiety and there is therefore no value in treatment with an SSRI.

D	Ropinirole

This is a dopamine agonist which is a therapy option in Parkinson's disease and restless legs syndrome, but has no value in the treatment of essential tremor.

E	Benzhexol

There is little evidence to support the use of benzhexol in essential tremor, but it does have value in the treatment of Parkinson's disease.

6944

Rate this question:

A 23-year-old airline stewardess presented to her GP complaining of severe headaches and blurring of her vision. She is on medication for treatment of facial acne and also takes the oral contraceptive pill.

On examination, her weight is 70 kg, height 152 cm and blood pressure 136/82 mmHg. There is evidence of bilateral papilloedema.

With respect to making the diagnosis, which of the following would be the most appropriate next step after CT brain?

A	Brain magnetic resonance venography
B	CT angiography
C	Neurosurgical advice
D	Stop oral contraceptive pill and monitor visual fields over next 2 weeks to look for spontaneous resolution

6:23
tps://mypastest.pastest.com

A 26 year old Emma Stewardess presented to her GP complaining of severe headaches and blurring of her vision. She is on medication for treatment of facial acne and also takes the oral contraceptive pill.

On examination, her weight is 70 kg, height 152 cm and blood pressure 136/82 mmHg. There is evidence of bilateral papilloedema.

With respect to making the diagnosis, which of the following would be the most appropriate next step after CT brain?

Your answer was correct

A	Brain magnetic resonance venography
B	CT angiography
C	Neurosurgical advice

A Brain magnetic resonance venography

This clinical scenario is highly suggestive of idiopathic intracranial hypertension (IIH, previously called benign intracranial hypertension, BIH). The clues are the presentation in a young, obese woman and the association of acne treatment may be relevant, as both tetracyclines and retinoids have been implicated in this condition (whose precise pathophysiology is, however, still unclear). Before making this diagnosis, however, cerebral venous sinus thrombosis (CVST) causing raised intracranial pressure must first be excluded, as must a space-occupying lesion. Risk factors for IIH include tetracyclines and retinoids for treatment of acne vulgaris, obesity and the oral contraceptive pill. Magnetic resonance venography or CT venography will be required, as plain MR or CT does not exclude the condition. Sinus thrombosis may occur during or after pregnancy, or

during or after pregnancy, or secondary to the use of oral contraceptives, deficiencies of protein C, protein S, antithrombin III or factor V, dehydration, polycythaemia vera, leukaemia, Bechet's disease, trauma, surgical procedures and malignancy. Management of IIH includes stopping all possible precipitating drugs, encouraging weight loss, serial lumbar punctures to remove CSF, acetazolamide and ventriculo-peritoneal shunting in resistant cases. If venous thrombosis is found, anticoagulation should be commenced.

B	CT angiography

Magnetic resonance venography is the investigation of choice to exclude sinus thrombosis, rather than CT angiography, which primarily detects arterial abnormalities.

C	Neurosurgical advice

It is important to first establish the

A 16-year-old girl is brought to the Casualty Department by her concerned mother. The patient has been complaining of severe diffuse back pain for 3 days and which has not been relieved with regular analgesics. She has also suffered increased clumsiness and difficulty carrying heavier objects.

Over the last 48 h, she has also had a rapid onset of weakness in both her legs to the extent that she is unable to lift her legs off the bed. She is not known to suffer from any other medical conditions but she has had a number of upper respiratory tract infections in the preceding weeks. She is on no medications. The only past medical history of note is that she had an episode of meningitis 4 years previously from which she recovered well and was discharged from hospital 2 months later.

On examination, she is noted to have normal sensation but reduced power in both her legs. The reduction in power is symmetrical. Her tendon reflexes are absent but she has normal abdominal reflexes. Examination of her cranial

On examination, she is noted to have normal sensation but reduced power in both her legs. The reduction in power is symmetrical. Her tendon reflexes are absent but she has normal abdominal reflexes. Examination of her cranial nerves confirms that she has weakness of eye closure, but fundoscopic appearance of the optic nerves is normal. No other cranial nerve abnormalities were elicited. She has mild shortness of breath, has no fever and is not tachycardic. Routine investigations are performed in the casualty department, including a lumbar puncture (LP). The results of the LP show slightly raised protein levels and normal cell counts. Her serum white cell count is $11 \times 10^9/l$.

Which of the following investigations is most useful for her immediate management?

A	MRI of the lumbosacral spine
B	Auto-antibody screen

abnormalities were elicited. She has mild shortness of breath, has no fever and is not tachycardic. Routine investigations are performed in the casualty department, including a lumbar puncture (LP). The results of the LP show slightly raised protein levels and normal cell counts. Her serum white cell count is $11 \times 10^9/l$.

Which of the following investigations is most useful for her immediate management?

A	MRI of the lumbosacral spine
B	Auto-antibody screen
C	Nerve conduction studies
D	Forced vital capacity measurement
E	Visual evoked potentials

D Forced vital capacity measurement

The patient is suffering from Guillain–Barré syndrome, an acute ascending neuropathy that usually manifests as a progressive weakness of all four limbs and areflexia. It is the proximal muscles that are more affected, but the muscles of the trunk and respiration can also be affected. The weakness is almost always symmetrical. Progressive respiratory involvement poses the greatest danger, which drives measurement of the FVC as the most important next investigation.

A MRI of the lumbosacral spine

Gadolinium-enhanced MRI of the lumbosacral spine typically shows enhancement of cauda equina nerve roots in the majority of patients with a classical presentation, although this isn't helpful in determining the risk of respiratory failure.

respiratory failure.

B Auto-antibody screen

Auto-antibodies to peripheral nerve and CNS antigens may be seen, although they do not contribute to determination of prognosis.

C Nerve conduction studies

Nerve conduction studies may help in determining the potential for and speed of recovery, although they are not usually helpful in the first two weeks of onset of symptoms.

E Visual evoked potentials

These are most useful in confirming a diagnosis of MS, particularly when there has been evidence of optic neuritis.

6823

Rate this question:

A 67-year-old right-handed woman is referred to the Stroke Unit. She is a lifelong heavy smoker but has no past medical history. She describes rapid onset facial paralysis that has persisted for a day. She further describes an awareness of sounds seeming louder on the left.

On examination, there is flattening of the nasolabial fold on the left, and she is unable to raise her eyebrow or close her eye on that side. Blood pressure is 155/70 mmHg. There is no rash or adenopathy. The remainder of neurological examination, including auroscopy, assessment of parotids and mucous membranes, is normal.

Choose the most appropriate management plan.

A	Admission to an acute stroke unit
B	Oral steroids and eye taping
C	Oral aciclovir and eye taping

is unable to raise her eyebrow or close her eye on that side. Blood pressure is 155/70 mmHg. There is no rash or adenopathy. The remainder of neurological examination, including auroscopy, assessment of parotids and mucous membranes, is normal.

Choose the most appropriate management plan.

A	Admission to an acute stroke unit
B	Oral steroids and eye taping
C	Oral aciclovir and eye taping
D	Eye taping and ophthalmology referral
E	Magnetic resonance imaging (MRI) of the brain

B Oral steroids and eye taping

Complete facial paralysis with no sparing of the frontalis muscle suggests a lower motor neurone facial nerve palsy. The most common cause is Bell's palsy. There are no other features in this case to suggest an alternative cause. Optimal management of a suspected case of Bell's palsy has been traditionally controversial. Most results from systematic reviews of steroids and antivirals have been conflicting. However, an adequately powered randomised controlled trial conducted in Scotland, of early (<72 h after symptom onset) treatment by oral prednisolone, oral aciclovir or both was published in 2007 (Sullivan et al., NEJM 2007; 357:1598-1607). This study found a significant effect of steroids but not aciclovir in 3- and 9-month assessment of facial power recovery. No adverse effects occurred.

A Admission to an acute stroke unit

A	Admission to an acute stroke unit

This patient has evidence of a lower motor neurone facial nerve palsy, so stroke care is not indicated.

C	Oral aciclovir and eye taping

Antiviral drugs do not have a benefit in Bell's palsy compared to steroids.

D	Eye taping and ophthalmology referral

Protecting the exposed cornea is certainly important, but steroids will also confer a better recovery.

E	Magnetic resonance imaging (MRI) of the brain

There are no additional cranial nerve or upper motor neurone signs here to suggest that MRI is indicated

7319

Rate this question:

As the medical registrar, you are called to see an 83-year-old woman on the surgical wards who is recovering from a total hip replacement operation. She has gradually become confused over the last 24 h and has hit and kicked out at the nurses. She has told them that others on the ward are trying to poison her. Her past medical history is significant for type 2 diabetes, for which she takes metformin, and hypertension.

You are not able to hold a conversation with her, since she appears to be disorientated in time and place with perseveration of speech. She keeps complaining that she can see ants crawling over her body and struggles to maintain concentration on questions that you ask her.

She is apyrexial, her blood pressure is 155/85 mmHg and her pulse is 85 and regular. She appears sweaty and tremulous. Routine blood tests are performed, which are unremarkable, and an electrocardiogram (ECG) is requested. A catheter specimen of urine is obtained.

tremulous. Routine blood tests are performed, which are unremarkable, and an electrocardiogram (ECG) is requested. A catheter specimen of urine is obtained.

Which of the following is most likely to be the cause of this patient's symptoms?

A	Urinary tract infection
B	Opiate analgesia
C	Hypoglycaemia
D	Transient ischaemic attack
E	Alcohol withdrawal

71127

Submit

E Alcohol withdrawal

This patient is potentially 48–72 h from when she consumed her last alcoholic drink, and it's important to note that many elderly people drink significant amounts at home, to self-medicate for low mood, anxiety or just to aid sleep. The features of sympathetic activation and tactile hallucinations are typical of delirium tremens. Chlordiazepoxide or lorazepam are typical interventions.

A Urinary tract infection

Urinary tract infections (UTIs) are a common precipitant of delirium in elderly people. This patient would be at particular risk of a UTI as she has a catheter inserted. However, it is important that objective evidence of the infection is obtained. Hypertension rather than hypotension counts against a diagnosis of Gram-negative sepsis, and there is no evidence of infection on routine blood tests (which are normal).

B Opiate analgesia

Medications with sedative or hypnotic effects are common precipitants of delirium. Culprit drugs should be sought by review of all recent prescriptions. In this case the increased anxiety, hallucinations and hypertension are more typical of alcohol withdrawal.

C Hypoglycaemia

The patient is a diabetic and thus at risk of fluctuations in blood sugar levels. In reality, however, the risk of hypoglycaemia is zero in patients taking metformin monotherapy.

D Transient ischaemic attack

Any acute medical issue may precipitate delirium in an at-risk individual (such as those with dementia, multiple co-morbidities, alcohol misuse and visual or hearing impairment), although the

A 72-year-old man attends clinic after his recent cerebral infarct. He has been a heavy smoker in the past and has a history of hypertension, for which he takes ramipril.

He has made a generally good recovery and is left with some left-sided motor weakness and spasticity affecting his hand as his only residual deficit. He is able to perform the usual activities of daily living without assistance. Carotid Doppler showed 90% stenosis of the right internal carotid. He is taking clopidogrel.

What would be the most appropriate treatment for this man?

A	Start warfarin
B	Add aspirin
C	Refer for endarterectomy
D	Add dipyridamole

history of hypertension, for which he takes ramipril.

He has made a generally good recovery and is left with some left-sided motor weakness and spasticity affecting his hand as his only residual deficit. He is able to perform the usual activities of daily living without assistance. Carotid Doppler showed 90% stenosis of the right internal carotid. He is taking clopidogrel.

What would be the most appropriate treatment for this man?

A	Start warfarin
B	Add aspirin
C	Refer for endarterectomy
D	Add dipyridamole
E	Switch to aspirin and dipyridamole

He has made a generally good recovery and is left with some left-sided motor weakness and spasticity affecting his hand as his only residual deficit. He is able to perform the usual activities of daily living without assistance. Carotid Doppler showed 90% stenosis of the right internal carotid. He is taking clopidogrel.

What would be the most appropriate treatment for this man?

Your answer was correct

A	Start warfarin
B	Add aspirin
C	Refer for endarterectomy
D	Add dipyridamole
E	Switch to aspirin and dipyridamole

C Refer for endarterectomy

People with non-disabling carotid artery territory stroke or TIA should be considered for carotid revascularisation if the symptomatic internal carotid artery has a stenosis of greater than or equal to 50%. Increased benefits have been demonstrated in those >70 years old. Ideally, referral for consideration of endarterectomy should have been contemplated much earlier, with the operation completed within one week of the initial presentation. However, there are likely to be benefits of surgery even at this late stage.

A Start warfarin

Anticoagulation with warfarin or 'new oral anticoagulants' (NOAC) would be the treatment of choice if the aetiology of this man's stroke was atrial fibrillation. However, the treatment of choice for patients with symptomatic carotid artery stenosis is endarterectomy

B Add aspirin

Dual antiplatelet therapy is rarely of any benefit. In the past, aspirin and dipyridamole were used in combination, but clopidogrel monotherapy is more effective for the secondary prevention of ischaemic stroke.

D Add dipyridamole

Dipyridamole is never added to clopidogrel. In the past, aspirin and dipyridamole were used in combination, but clopidogrel monotherapy is more effective for the secondary prevention of ischaemic stroke and is now the preferred option.

E Switch to aspirin and dipyridamole

Clopidogrel is more effective than this combination for the secondary prevention of stroke. However, endarterectomy should be the

A 33-year-old man complained of severe neck pain while shooting at a rifle range. This was followed shortly afterwards by vertigo, nausea, and vomiting.

A few hours afterwards, he was brought by ambulance to Accident and Emergency having been found collapsed at home. His Glasgow Coma Scale (GCS) score was 10 out of 15.

Which one of the following is the most likely cause for his presentation?

A	Sub-arachnoid haemorrhage
B	Carotid artery dissection
C	Extradural bleed
D	Vertebral artery dissection
E	Basilar artery occlusion

D Vertebral artery dissection

The sudden onset of symptoms in this case is in keeping with a vascular event, and the severe neck pain suggests arterial dissection. Vertigo, nausea and vomiting are in keeping with vertebral artery dissection, which is often associated with infarction in the territory of the posterior inferior cerebellar artery. Dissections may occur spontaneously or are secondary to major or minor trauma, such as in this case where the event was likely precipitated by rifle shooting. Other reported triggers include nose blowing or violent sneezing. In some patients they are associated with an underlying arteriopathy; 15% of cases are bilateral and one-half of these occur in patients with underlying fibromuscular dysplasia. Cervicocephalic dissections are responsible for 1–2.5% of ischemic strokes in the general population and for 5–20% of strokes in individuals younger than 45 years.

A Sub-arachnoid haemorrhage

A Sub-arachnoid haemorrhage

This would present with sudden onset severe or 'thunderclap' headache rather than neck pain. Although patients with subarachnoid haemorrhage may develop reduced GCS, vomiting and nausea, vertigo would not be typically seen in this presentation.

B Carotid artery dissection

This would present with headache, Horner syndrome of the affected side and can lead to an anterior circulation ischaemic stroke of the affected side. Patients may develop contralateral hemiparesis, hemianopia and impairment of higher cortical function. This presentation can also be associated with neck trauma or injury.

C Extradural bleed

Patients would present with a brief lucid interval and then rapid reduction in GCS. This presentation is usually a

impairment of higher cortical function. This presentation can also be associated with neck trauma or injury.

C	Extradural bleed

Patients would present with a brief lucid interval and then rapid reduction in GCS. This presentation is usually a result of head trauma and is caused by bleeding from meningeal arteries in the temporal region.

E	Basilar artery occlusion

This would present with motor and bulbar symptoms, which can be sudden in onset. This pathology may result in a locked-in syndrome where patients develop complete paralysis (often with the exception of some eye movement) but have preserved consciousness.

8495

Rate this question:

You are asked to review a 71-year-old woman who has a history of type 2 diabetes mellitus, smoking and hypertension. She complains of diplopia, nausea, vomiting and vertigo.

On examination, her blood pressure is 185/95 mmHg. There is nystagmus on looking left and a left-sided conjugate gaze palsy. On walking, she veers to the left.

Investigations:

LDL cholesterol	5.5 mmol/l (normal < 3.4)
HDL cholesterol	1.0 mmol/l (normal < 1.5)
Triglycerides	2.1 mmol/l (normal < 1.7)

Where is the most likely site of the vascular occlusion?

A	Right internal carotid artery territory

LDL cholesterol	5.5 mmol/l (normal < 3.4)
HDL cholesterol	1.0 mmol/l (normal < 1.5)
Triglycerides	2.1 mmol/l (normal < 1.7)

Where is the most likely site of the vascular occlusion?

A	Right internal carotid artery territory
B	Left anterior cerebral artery territory
C	Left vertebral artery territory
D	Anterior communicating artery territory
E	Left internal carotid artery territory

You are asked to review a 71-year-old woman who has a history of type 2 diabetes mellitus, smoking and hypertension. She complains of diplopia, nausea, vomiting and vertigo.

On examination, her blood pressure is 185/95 mmHg. There is nystagmus on looking left and a left-sided conjugate gaze palsy. On walking, she veers to the left.

Investigations:

LDL cholesterol	5.5 mmol/l (normal < 3.4)
HDL cholesterol	1.0 mmol/l (normal < 1.5)
Triglycerides	2.1 mmol/l (normal < 1.7)

Where is the most likely site of the vascular occlusion?

Your answer was correct

C Left vertebral artery territory

This patient has diplopia, vertigo, vomiting and an eye movement disorder. This constellation of symptoms and signs localizes to the medulla, which acquires is blood supply from the two vertebral arteries. The patient often leans towards the side of the brainstem lesion, and the fast phase of the nystagmus is also directed towards the side of the brainstem lesion in a medullary stroke.

Acute management includes aggressive blood pressure control, prevention of aspiration due to dysphagia, and antiplatelet agents.

A Right internal carotid artery territory

The patient's symptoms and signs do not localize to one cerebral hemisphere, i.e. she has neither hemiparesis nor hemi-sensory loss. Therefore, there is no reason to suspect a stroke in the anterior or

middle cerebral arteries, both branches of the internal carotid artery on that side.

B	Left anterior cerebral artery territory

The patient does not have right leg weakness or sensory loss. There is no suggestion of higher cortical dysfunction such as dyspraxia to suggest a lesion in the frontal lobe, which acquires its vascular supply from the anterior cerebral artery. Therefore this answer is incorrect.

D	Anterior communicating artery territory

The anterior communicating artery is part of the Circle of Willis, forming a connection between the left and right anterior cerebral arteries. An occlusion in this artery will not cause major neurological dysfunction, as the blood will simply by-pass the occlusion providing the other arteries in the circle are patent. An aneurysm here

anterior cerebral arteries. An occlusion in this artery will not cause major neurological dysfunction, as the blood will simply by-pass the occlusion providing the other arteries in the circle are patent. An aneurysm here will compress the optic chiasm and frontal lobe structures causing visual field defects, and personality changes, but this patient has diplopia rather than hemianopia.

E	Left internal carotid artery territory

The patient's symptoms and signs do not localize to one cerebral hemisphere, i.e. she has neither hemiparesis, hemi-sensory loss nor dysphasia. Therefore, there is no reason to suspect a stroke in the left anterior or middle cerebral arteries, both branches of the left internal carotid artery.

9271

Rate this question:

An 18-year-old woman with insulin-dependent diabetes mellitus (IDDM) presents to the neurology clinic with recurrent episodes of collapse. The episodes consist of a feeling of weakness which then causes her to collapse to the ground. The episodes started about 6 months ago and occur several times a week.

She does not think that she loses consciousness during these episodes and has noticed that emotional situations, particularly when she is laughing, can trigger the attacks. She has been feeling anxious and rather down recently, sleeping poorly with frequent nightmares.

Her diabetes control has been poor in the past few months and she has recently changed her insulin regime to try to get better control.

She has a brother who has a history of febrile convulsions.

What is the most likely diagnosis?

A	Complex partial seizures

situations, particularly when she is laughing, can trigger the attacks. She has been feeling anxious and rather down recently, sleeping poorly with frequent nightmares.

Her diabetes control has been poor in the past few months and she has recently changed her insulin regime to try to get better control.

She has a brother who has a history of febrile convulsions.

What is the most likely diagnosis?

A	Complex partial seizures
B	Psychogenic non-epileptic seizures
C	Recurrent hypoglycaemia
D	Periodic paralysis
E	Cataplexy

E Cataplexy

Cataplexy is an abrupt loss of voluntary muscular function and tone, which can be provoked by emotional stimuli such as laughter, anger or excitement. Cataplexy is rarely found in isolation but is found in 70% of individuals affected by narcolepsy. Narcolepsy itself is a condition causing excessive daytime somnolence and an overwhelming desire to sleep. Symptoms include excessive daytime sleepiness (EDS), involuntary sleep episodes – 'microsleeps', cataplexy, sleep paralysis with hallucinations – hypnagogic (at the onset of sleep) and hypnopompic (on awakening). HLA DQB1*0602 is found in 95% of patients who have both narcolepsy and cataplexy, which is also found in many patients with other autoimmune conditions such as diabetes mellitus type 1.

A Complex partial seizures

A Complex partial seizures

In complex partial seizures patients lose awareness but not consciousness; they may exhibit uncontrolled repetitive movements, such as chewing and swallowing, repeatedly scratching the head or searching for an object (automatisms).

B Psychogenic non-epileptic seizures

These attacks may present very like epileptic seizure with blackouts and shaking. Sudden collapses without loss of consciousness can be a manifestation of psychogenic attacks, but in this case the history of sleep disturbance makes cataplexy more likely.

C Recurrent hypoglycaemia

This could also be a possibility considering her poor glycaemic control and recent change in medications, but

manifestation of psychogenic attacks, but in this case the history of sleep disturbance makes cataplexy more likely.

C	Recurrent hypoglycaemia

This could also be a possibility considering her poor glycaemic control and recent change in medications, but one would not expect sudden loss of muscle tone and collapse (with preserved consciousness) as the only manifestation of hypoglycaemia.

D	Periodic paralysis

This leads to muscle weakness, often with associated derangement of potassium levels, and there is no link to emotional stimuli.

9839

Rate this question:

Next Question

You are asked to see a 75-year-old man on the orthopaedic ward at 3 am. He has been very agitated at night since his admission five days ago, and his team prescribed as-required doses of haloperidol on his drug chart earlier in the day. When he became agitated he was given 2 mg of intramuscular haloperidol, and the nurses are now worried as he is not moving very much in his bed.

Examination is difficult, but he is rigid and not moving his limbs very much although he is fully alert.

On further questioning of the nursing staff, they comment that the daytime staff have had no problems and that he has been sleeping for much of the day. They also tell you that when he has been agitated he has been reaching out in front of him as if there was something there.

You read the medical notes and there is no mention of any previous problems before coming in to hospital (although he has been living with his wife and daughter for many years).

out in front of him as if there was something there.

You read the medical notes and there is no mention of any previous problems before coming in to hospital (although he has been living with his wife and daughter for many years).

What is the most likely diagnosis?

A	Dementia with Lewy bodies
B	Alzheimer's disease
C	Frontotemporal dementia
D	Vascular dementia
E	Wernicke–Korsakoff syndrome

6951

Submit

A Dementia with Lewy bodies

Dementia with Lewy bodies (DLB) is a progressive disorder of cognitive impairment, most commonly starting over the age of 65 years. The clues to the diagnosis in this case are the sensitivity to neuroleptic drugs causing severe parkinsonian features of akinesia and rigidity, fluctuations in his cognitive function, daytime sleeping with night-time restlessness and agitation associated with possible visual hallucinations. It is often missed, as the usual tremor seen in idiopathic Parkinson's disease may well be absent.

B Alzheimer's disease

Alzheimer's disease is not associated with prominent visual hallucinations, particularly in its early stages; deficiencies of short-term memory and executive function are much more prominent.

C	Frontotemporal dementia

Frontotemporal dementia is associated with prominent behavioural changes including disinhibition, which are not reported here.

D	Vascular dementia

Vascular dementia is associated with a step-wise deterioration in executive function, and is usually linked to prominent vascular risk factors which are not reported here.

E	Wernicke–Korsakoff syndrome

The most prominent features of Wernicke–Korsakoff, linked to thiamine deficiency, are short-term memory loss, conjugate gaze palsy and inability to look down or up.

6951

Rate this question:

A 57-year-old white woman, with type 2 diabetes, accompanied by her daughter, presents to the Emergency Department complaining of a headache and right-sided weakness which has worsened over the past 3 days. The daughter became increasingly concerned after the patient started to become confused and her speech became slurred. The patient is on some medications for her diabetes, but the daughter does not know which. Apart from the diabetes, the daughter is not aware of any other medical problems suffered by her mother, but she knows that there have been difficulties with the control of the diabetes.

On examination, the patient is tachycardic, pyrexial and has a mental score of 5/10. Communication with her is difficult due to dysphasia. Neurological examination confirms the presence of right-sided weakness. Cardiovascular and respiratory examinations are normal.

Apart from routine bloods, a chest X-ray and an ECG, an urgent CT scan of

is difficult due to dysphasia.

Neurological examination confirms the presence of right-sided weakness. Cardiovascular and respiratory examinations are normal.

Apart from routine bloods, a chest X-ray and an ECG, an urgent CT scan of the head is requested. The CT without contrast shows a lesion in the left frontoparietal area, and with contrast, a ring enhancement pattern is seen.

What is the underlying diagnosis?

A	Brain metastasis
B	Tuberculoma
C	Cerebral abscess
D	Septic embolus
E	Embolic stroke

diabetes, but the daughter does not know which. Apart from the diabetes, the daughter is not aware of any other medical problems suffered by her mother, but she knows that there have been difficulties with the control of the diabetes.

On examination, the patient is tachycardic, pyrexial and has a mental score of 5/10. Communication with her is difficult due to dysphasia. Neurological examination confirms the presence of right-sided weakness. Cardiovascular and respiratory examinations are normal.

Apart from routine bloods, a chest X-ray and an ECG, an urgent CT scan of the head is requested. The CT without contrast shows a lesion in the left frontoparietal area, and with contrast, a ring enhancement pattern is seen.

What is the underlying diagnosis?

Your answer was incorrect

A Brain metastasis

C Cerebral abscess

A cerebral abscess may follow spread from a contiguous focus of infection, such as otitis media, mastoiditis, infection of the paranasal sinuses or dental infection. In neonates, bacterial meningitis is the most common cause of cerebral abscess whereas fungal and nocardial infections tend to occur in patients with diabetes or other causes of immunosuppression. The clinical manifestations are dependent on the size and location of the abscess, although the most usual site of abscess formation is at the corticomedullary junction within the frontal and parietal lobes. Diagnosis can be made with cranial CT scans with and without contrast, although the preferred imaging modality is MRI with and without gadolinium enhancement. The CT findings depend on the stage of formation of the abscess, but in general CT with contrast shows an ill-defined contrast-enhancing area within an oedematous region with an irregular enhancing rim

region with an irregular enhancing rim that surrounds a central low-attenuating area.

A Brain metastasis

The relatively short history of symptoms, coupled with evidence of sepsis, is more supportive of sepsis as the underlying cause of this patient's presentation.

B Tuberculoma

Tuberculomas appear as a well-defined granulomatous mass, often with calcification on CT scanning. The history of neurological deficit would be expected to be more chronic versus that seen here.

D Septic embolus

A septic embolism would be expected to occur against a background of endocarditis, and no symptoms or signs of endocarditis feature here.

B Tuberculoma

Tuberculomas appear as a well-defined granulomatous mass, often with calcification on CT scanning. The history of neurological deficit would be expected to be more chronic versus that seen here.

D Septic embolus

A septic embolism would be expected to occur against a background of endocarditis, and no symptoms or signs of endocarditis feature here.

E Embolic stroke

A well-circumscribed lesion with ring enhancement on contrast administration does not fit with a diagnosis of embolic stroke.

6822

Rate this question:

Next Question

A 40-year-old woman, with a history of depression, presents to the Emergency Department complaining of feeling unwell with headaches and blurred vision. She says the headaches have been getting worse over the last two weeks and seem to be worse in the mornings.

Her pulse is 40 bpm and her blood pressure (BP) is 190/110 mmHg. Fundoscopy reveals bilateral swollen discs and there is diplopia on lateral gaze bilaterally.

What is the best next step in her management?

A	Request an urgent CT of the brain
B	Perform a lumbar puncture and measure the CSF pressure
C	Commence cefotaxime and aciclovir

mornings.

Her pulse is 40 bpm and her blood pressure (BP) is 190/110 mmHg. Fundoscopy reveals bilateral swollen discs and there is diplopia on lateral gaze bilaterally.

What is the best next step in her management?

A	Request an urgent CT of the brain
B	Perform a lumbar puncture and measure the CSF pressure
C	Commence cefotaxime and aciclovir
D	Administer steroids urgently
E	MRI angiography

depression, presents to the Emergency Department complaining of feeling unwell with headaches and blurred vision. She says the headaches have been getting worse over the last two weeks and seem to be worse in the mornings.

Her pulse is 40 bpm and her blood pressure (BP) is 190/110 mmHg. Fundoscopy reveals bilateral swollen discs and there is diplopia on lateral gaze bilaterally.

What is the best next step in her management?

Your answer was correct

A	Request an urgent CT of the brain
B	Perform a lumbar puncture and measure the CSF pressure
C	Commence cefotaxime and aciclovir

A Request an urgent CT of the brain

This patient presents with symptoms consistent with raised intracranial pressure. The combination of morning headaches, papilloedema and cranial neuropathies should always warrant urgent cranial imaging to rule out a space-occupying lesion.

B Perform a lumbar puncture and measure the CSF pressure

Patients with raised intracranial pressure who have no had cerebral imaging to rule out a space-occupying lesion should not undergo LP, due to the risk of cerebellar tonsillar herniation.

C Commence cefotaxime and aciclovir

This patient does not present with symptoms consistent with meningitis

aciclovir

This patient does not present with symptoms consistent with meningitis or encephalitis.

D Administer steroids urgently

This patient's symptoms may be attributable a tumour with surrounding oedema, for which steroids would be indicated. However, the differential remains wide and some basic investigations should be performed prior to commencing any treatment.

E MRI angiography

Urgent cerebral imaging is indicated, and in most centres this would be CT-based. If available an MRI brain would be more informative, although an MRI angiography is of unlikely benefit in this case without clear indication of a vascular pathology.

2596

Rate this question:

A 29-year-old PhD student with blurred vision is referred to the Neurology Clinic by her general practitioner (GP). She gives a 4-day history of very severe headache and blurred and double vision. Her double vision is worse on looking to the left. Systemic review reveals a long history of menstrual irregularity and she tells you that the headaches have been worsening over the past 4 months.

On examination, there is no neck stiffness and fundoscopy shows bilateral papilloedema. External ocular examination reveals weakness of the left eye on abduction. The rest of the examination is unremarkable. Her BMI is 32.

Given this clinical history, which investigation from those listed below should be performed next?

A	Lumbar puncture
B	Cerebral angiography

you that the headaches have been worsening over the past 4 months.

On examination, there is no neck stiffness and fundoscopy shows bilateral papilloedema. External ocular examination reveals weakness of the left eye on abduction. The rest of the examination is unremarkable. Her BMI is 32.

Given this clinical history, which investigation from those listed below should be performed next?

A	Lumbar puncture
B	Cerebral angiography
C	Skull X-ray
D	Ocular pressure
E	CT head and venography

practitioner (GP). She gives a 1-day history of very severe headache and blurred and double vision. Her double vision is worse on looking to the left. Systemic review reveals a long history of menstrual irregularity and she tells you that the headaches have been worsening over the past 4 months.

On examination, there is no neck stiffness and fundoscopy shows bilateral papilloedema. External ocular examination reveals weakness of the left eye on abduction. The rest of the examination is unremarkable. Her BMI is 32.

Given this clinical history, which investigation from those listed below should be performed next?

Your answer was correct

A	Lumbar puncture
B	Cerebral angiography
C	Skull X-ray

E CT head and venography

This patient has idiopathic intracranial hypertension, a condition typically associated with obese women. The condition is not benign and can sometimes rapidly lead to severe visual loss. She has a left 6th nerve palsy, which is a false localising sign and is due to raised intracranial pressure. The most urgent investigation required is a CT brain and venography to rule out a space-occupying lesion and cerebral venous sinus thrombosis, so a lumbar puncture can be safely performed to make the diagnosis.

A Lumbar puncture

This patient presents with symptoms and signs of raised intracranial pressure. Although the likely diagnosis is idiopathic intracranial hypertension (which is confirmed by lumbar puncture), cerebral imaging is urgently indicated to rule out a space-occupying lesion. Performing a lumbar

occupying lesion. Performing a lumbar puncture in a patient with a space-occupying lesion risks cerebellar tonsillar herniation and death.

B	Cerebral angiography

The presentation is unlikely to be secondary to an arterial vascular pathology, such as cerebral aneurysm or arteriovenous malformation. Therefore this investigation is not a first-line investigation in this patient.

C	Skull X-ray

Skull X-rays are rarely used in modern clinical practice.

D	Ocular pressure

The patient's papilloedema and 6th nerve palsy indicate raised intracranial, rather than raised intraocular, pressure.

2525

Rate this question:

A 23-year-old secretary presents to the Neurology Outpatients with continuous all-day headaches. She describes a 1-year history of frontal throbbing pain, worse at the end of the day but occurring throughout the day without relief. In addition, she describes occasional exacerbations of unilateral head and facial pain lasting for hours to days at a time every week and associated with intolerance of light.

She denies any nausea, vomiting or other neurological symptoms. She is an otherwise fit and well young woman with no significant past medical history. She takes paracetamol up to 4 g/day and codeine phosphate 120 mg/day without relief from her head pain. She also takes the oral contraceptive pill. She has been taking the same preparation for around 5 years.

On examination, there are no focal neurological signs. Fundoscopy is normal and there are visible venous pulsations.

the same preparation for around 5 years.

On examination, there are no focal neurological signs. Fundoscopy is normal and there are visible venous pulsations.

Which plan would most likely improve her condition?

A	Instigation of triptan therapy for exacerbations
B	Addition of ibuprofen 400 mg tds
C	Graded reduction in paracetamol and codeine use
D	Cessation of oral contraceptive pill
E	Indomethacin 50 mg tds

for hours to days at a time every week and associated with intolerance of light.

She denies any nausea, vomiting or other neurological symptoms. She is an otherwise fit and well young woman with no significant past medical history. She takes paracetamol up to 4 g/day and codeine phosphate 120 mg/day without relief from her head pain. She also takes the oral contraceptive pill. She has been taking the same preparation for around 5 years.

On examination, there are no focal neurological signs. Fundoscopy is normal and there are visible venous pulsations.

Which plan would most likely improve her condition?

Your answer was incorrect

A Instigation of triptan therapy

C Graded reduction in paracetamol and codeine use

This young woman has constant daily headache almost certainly caused by excessive analgesic use (analgesia overuse headache). The history suggests that she has underlying migrainous headaches, and it may be these that have triggered her increasing analgesic taking. It is a common vicious cycle of exacerbation of the headaches with analgesic use leading to ever-increasing usage. Many patients are sceptical of the effect of reducing analgesic intake, but with careful and slow reduction (especially with agents such as codeine, which can be highly addictive) many find great relief by these means.

A Instigation of triptan therapy for exacerbations

Following cessation of regular analgesics, a triptan may be indicated for any acute migrainous component, although care would have to be taken

some patients, which can again cause worsening headaches.

B	Addition of ibuprofen 400 mg tds

Non-steroidal use can be helpful when reducing paracetamol and codeine usage, but care must be taken to avoid their overuse, possibly leading to a third tablet being (mis)used.

D	Cessation of oral contraceptive pill

Her use of the OCP significantly predates her headache worsening and the regular analgesic use is far more likely to be the problem.

E	Indomethacin 50 mg tds

This drug is useful in the treatment of paroxysmal hemicranias and hemicrania continua, but the symptoms in this case are more suggestive of analgesia overuse and

A 41-year-old Asian man is seen in the Emergency Department with a history of generalised headache, polydipsia and polyuria. Prior to admission he developed sudden onset weakness affecting his left arm and leg and had had three generalised seizures en route in the ambulance.

His wife who accompanied him said he had become increasingly confused in the last few days and was sleeping more often.

He had a history of hypertension, treated with bendroflumethiazide, and had recently seen his general practitioner, complaining of bone pain affecting his back and knees. He smoked 30 cigarettes per day.

On examination he appeared confused and dehydrated. His blood pressure was 110/70 mmHg, pulse was 89/min and temperature 37.8 °C. There was evidence of a right LMN (lower motor neurone) facial nerve palsy and both eyes were red and inflamed. Fundoscopy and the remaining cranial nerves appeared normal. On

examination of the limbs, there was a left-sided hemiparesis with left extensor plantar and brisk reflexes. The reflexes on the right however revealed a mute plantar with depressed reflexes at the ankle and knee.

This patient had a computerised tomography scan brain, which revealed a right anterior circulation infarct.

Chest X-ray showed hilar lymphadenopathy with fibrotic changes throughout both lung fields.

Investigations:

Hb	13.4 g/l
WCC	11.0×10^9/l
PLT	395×10^9/l
Na^+	157 mmol/l
K^+	3.5 mmol/l
Creatinine	239 μmol/l
Urea	3.9 mmol/l
Glucose	5.8 mmol/l
	2.84

Calcium	2.84 mmol/l
Plasma osmolality	450 mosmol/kg (278–305)
Urine osmolality	250 mosmol/kg (350–1000)
cANCA (cytoplasmic ANCA (Anti-neutrophil cytoplasmic antibodies)	-
Serum oligoclonal bands	+

Lumbar puncture (CSF):

Opening pressure	18 cm H_2O (5–18)
Cerebrospinal fluid(CSF)protein	2.3 g/l (0.15–0.45)
CSF WCC	120 cells/ml (90% lymphocytes) (≤ 5)

CSF red cell count	5 cells/ml (≤ 5)
CSF glucose	3.4 mmol/l (3.3–4.4)
CSF culture	-
CSF cytology	-
Oligoclonal bands	+
Serum OCB(oligoclonal bands)	+
CSF angiotensin-converting enzyme	Normal

In view of the above findings, what is the likely diagnosis in this patient?

A Tuberculous meningitis

B Granulomatous polyangiitis (GPA)

OCB(oligoclonal bands)	+
CSF angiotensin-converting enzyme	Normal

In view of the above findings, what is the likely diagnosis in this patient?

A	Tuberculous meningitis
B	Granulomatous polyangiitis (GPA)
C	Small cell lung carcinoma and leptomeningeal involvement
D	Cerebral lymphoma
E	Sarcoidosis

7199

Submit

E Sarcoidosis

This patient presents with a complex history and paraclinical findings. He has had a right anterior circulation infarct, has evidence of a right LMN (lower motor neurone) facial nerve palsy and possibly a background neuropathy. In addition he is encephalopathic, dehydrated and pyrexial, and has evidence of bilateral iritis. His blood tests show hypercalcaemia and hypernatraemia with evidence for diabetes insipidus. His lumbar puncture clearly shows intrathecal immunoglobulin G (IgG) synthesis and a lymphocytosis. His chest X-ray shows bilateral fibrosis and lymphadenopathy. These findings are all in keeping with sarcoidosis.

A Tuberculous meningitis

This can present with cranial neuropathies, vasculopathy and focal signs but is more likely to be associated with a syndrome of inappropriate antidiuretic hormone

inappropriate antidiuretic hormone (SIADH), and cerebrospinal fluid (CSF) analysis invariably shows a markedly reduced glucose level.

B	Granulomatous polyangiitis (GPA)

Formerly known as Wegener's granulomatosis, this vasculitic illness presents often with upper respiratory tract symptoms but can present with mononeuropathies or vasculitic stroke. cANCA (cytoplasmic ANCA (anti-neutrophil cytoplasmic antibodies), however, is positive in 90% of cases, making the diagnosis less likely here.

C	Small cell lung carcinoma and leptomeningeal involvement

Small cell neoplasm with meningeal spread could conceivably cause some of the neurological findings here. However, it would be hard to account for the CXR findings and in the CSF one might expect abnormal cytology

cANCA (cytoplasmic ANCA (anti-neutrophil cytoplasmic antibodies), however, is positive in 90% of cases, making the diagnosis less likely here.

C	Small cell lung carcinoma and leptomeningeal involvement

Small cell neoplasm with meningeal spread could conceivably cause some of the neurological findings here. However, it would be hard to account for the CXR findings and in the CSF one might expect abnormal cytology and very low glucose.

D	Cerebral lymphoma

This can present with meningeal and parenchymal brain disease, and can also cause a vasculopathy. However, the systemic signs (such as iritis) cannot be explained, nor can the CXR appearance.

7199

Rate this question:

An 18-year-old man presents to his GP with pain over his right shoulder. He says it developed suddenly a few days after he had received an influenza vaccination.

Past medical history of note includes mild asthma for which he uses a salbutamol inhaler on an occasional PRN basis.

On examination, he has severe right shoulder pain on palpation. When he faces the wall and pushes against it with both palms flat, there is winging of the scapula on the right-hand side. He is able to raise his arms above his head. There is no facial or cranial involvement.

What is the most likely diagnosis?

A	Fascioscapulohumeral dystrophy
B	Spinal muscular atrophy
C	Brachial neuritis

mild asthma for which he uses a salbutamol inhaler on an occasional PRN basis.

On examination, he has severe right shoulder pain on palpation. When he faces the wall and pushes against it with both palms flat, there is winging of the scapula on the right-hand side. He is able to raise his arms above his head. There is no facial or cranial involvement.

What is the most likely diagnosis?

A	Fascioscapulohumeral dystrophy
B	Spinal muscular atrophy
C	Brachial neuritis
D	Osteosarcoma
E	Rotator cuff injury

C Brachial neuritis

Knowing the associations between brachial neuritis and causative factors helps justify this as the best answer. Notably this man had a vaccination recently and developed sudden onset of pain. Typically the right side is involved. It is managed with physiotherapy and analgesia. Weakness and wasting can also develop.

A Fascioscapulohumeral dystrophy

There is simply not enough evidence in the question to support this answer. The sudden onset in nature and the recent vaccination make brachial neuritis more likely. Moreover there are no facial symptoms and no reported weakness, which you would expect to see here.

B Spinal muscular atrophy

The sudden onset, pain and lack of weakness or walking abnormalities would count against this being the best answer.

D	Osteosarcoma

Although osteosarcoma can present in the upper part of the humerus, you would expect some restriction in movement and a palpable mass. In the MRCP, if details are not included in a question assume they are unremarkable and therefore not present. The acute onset and link to the recent vaccination would make brachial neuritis the better answer.

E	Rotator cuff injury

There is no history of trauma and, at the age of 18, degenerative changes are unlikely to be responsible for this. Typically, the patient is unable to raise their affected arm above their head. In this question the patient is able to do this therefore this is not the best answer.

A 65-year-old man complained of a limp in his right leg that had developed over the last few months, associated with pain in his back and down the front of his leg.

On examination, of his lower limbs he had normal tone, weakness of knee extension, foot inversion and foot dorsiflexion on the right but full power in other groups; a decreased knee reflex on the right, but all other reflexes were present and plantars were flexor. Sensation to pin-prick and light touch was decreased over the medial part of the right calf.

Which nerve root on the right side is affected?

A	L2
B	L3
C	L4
D	L5

On examination, of his lower limbs he had normal tone, weakness of knee extension, foot inversion and foot dorsiflexion on the right but full power in other groups; a decreased knee reflex on the right, but all other reflexes were present and plantars were flexor. Sensation to pin-prick and light touch was decreased over the medial part of the right calf.

Which nerve root on the right side is affected?

Your answer was correct

A	L2
B	L3
C	L4
D	L5
E	S1

C L4

The L4 dermatome is over the anteromedial part of the shin. L4 is also part of the knee reflex and is involved in hip adduction, knee extension, ankle dorsiflexion and foot inversion. The back pain and radicular pain down the leg are clues to the diagnosis of a radiculopathy. It is important to consider red flags for spinal cord or cauda equina compression. Careful examination of the reflexes and sensation is usually most helpful in localising the lesion. Weakness is not usually prominent. The cause of the lesion is best evaluated with an MRI scan of the lumbosacral spine.

A L2

The L2 dermatome includes the anterior aspect of the thigh. The L2 nerve root contributes to hip flexion and adduction power.

B L3

The L3 dermatome includes the medial aspect of the thigh and knee (this can be easily remembered as 'three' rhymes with 'knee'). The L3 nerve root contributes to knee extension and hip adduction power.

D L5

The L5 dermatome is over the anterolateral shin and dorsum of the foot. L5 is involved in hip extension, knee flexion, ankle dorsiflexion and big toe extension.

E S1

The S1 dermatome is mainly over the sole of the foot. S1 is part of the ankle reflex and is involved in hip extension, ankle plantar flexion and foot eversion.

6962

Rate this question:

A 50-year-old publican is admitted with poor short-term memory. He admits to drinking up to eight pints per day. He tells a quite fanciful story about his activities that day.

You note bilateral internuclear ophthalmoplegia on central nervous system (CNS) examination. He has mild anaemia, with a mean corpuscular volume (MCV) of 108 fl, and random blood glucose is 3.9 mmol/l.

Which of the following is the treatment of choice?

A	Thiamine
B	Aspirin
C	Vitamin B_{12}
D	Glucose IV
E	Iron supplementation

A Thiamine

This man has Wernicke–Korsakoff syndrome, with poor short-term memory and confabulation. Thiamine should be given parenterally as treatment of choice in all patients who present in this way. Untreated, memory loss may become permanent. Other signs include a broad-based gait, cerebellar signs and vestibular paralysis. Nystagmus is present on eye examination.

B Aspirin

There is no suggestion that this patient's symptoms are related to cerebral ischaemia, and therefore aspirin is not effective in managing his neurological dysfunction.

C Vitamin B_{12}

Although the macrocytosis may represent co-existent B_{12} deficiency, it may also be associated with alcohol

represent co-existent B_{12} deficiency, it may also be associated with alcohol abuse *per se*. In practice most patients admitted with alcoholism are of course managed with a combination B vitamin preparation.

D	Glucose IV

Although this patient has borderline hypoglycaemia, thiamine deficiency is the main driver for his presentation, and glucose replacement without thiamine may actually worsen memory dysfunction.

E	Iron supplementation

The elevated MCV seen here is most likely to be associated with alcoholism or B_{12} deficiency, rather than iron deficiency.

6621

Rate this question:

Next Question

Submit

Previous Question Skip Question

Calculator

Normal Values

Troponin:<0.1 ng/ml

Diabetes

Glucose

Random:3.5 - 5.5 mmol/l*

Fasting:<7 mmol/l/

Hb A_{1C}:<53 mmol/mol (<7.0%)

Endocrinology

TSH:0.17 - 3.2 μU/l

fT_4:11 - 22 pmol/l

fT_3:3.5 - 5 pmol/l

A 64-year-old man is seen in General Medical Outpatients after referral by his general practitioner (GP). He had a single episode of transient right arm weakness four weeks ago while on holiday, which resolved after a period of several hours. The weakness was associated with some speech disturbance and difficulty being understood by his family. There was no associated headache. There has been no recurrence since this time. He has no significant medical history and is a lifelong non-smoker. His GP started him on clopidogrel following his return from holiday.

On examination, he is in sinus rhythm with a blood pressure of 126/68 mmHg. There are no neurological signs. There is no carotid bruit on auscultation of the neck.

The GP has already performed some blood tests, the results of which are as follows:

Hb	12.4 g/dl
WCC	6.7×10^9/l – normal

WCC	6.7×10^9/l – normal differential
PLT	198×10^9/l
Na^+	139 mmol/l
K^+	4.2 mmol/l
Urea	4.5 mmol/l
Creatinine	69 μmol/l
Cholesterol	4.4 mmol/l

What would be the best medication to add to his regimen?

A	Commencement of ezetimibe and simvastatin
B	Commencement of atorvastatin 40 mg/day
C	Commencement of dipyridamole 200 mg/day
D	Commencement of atenolol

K^+	4.2 mmol/l
Urea	4.5 mmol/l
Creatinine	69 µmol/l
Cholesterol	4.4 mmol/l

What would be the best medication to add to his regimen?

A	Commencement of ezetimibe and simvastatin
B	Commencement of atorvastatin 40 mg/day
C	Commencement of dipyridamole 200 mg/day
D	Commencement of atenolol 50 mg/day
E	Commencement of perindopril 4 mg/day

Medical Outpatients after referral by his general practitioner (GP). He had a single episode of transient right arm weakness four weeks ago while on holiday, which resolved after a period of several hours. The weakness was associated with some speech disturbance and difficulty being understood by his family. There was no associated headache. There has been no recurrence since this time. He has no significant medical history and is a lifelong non-smoker. His GP started him on clopidogrel following his return from holiday.

On examination, he is in sinus rhythm with a blood pressure of 126/68 mmHg. There are no neurological signs. There is no carotid bruit on auscultation of the neck.

The GP has already performed some blood tests, the results of which are as follows:

Hb	12.4 g/dl
WCC	6.7×10^9/l – normal differential

B	Commencement of atorvastatin 40 mg/day

Current evidence supports the use of statin therapy for secondary prevention of vascular events in patients who have suffered a TIA, even in the absence of elevated serum cholesterol. Blood pressure control is important out of the acute setting (usually two weeks post-event). However, this man's blood pressure is normal and extra reduction in blood pressure may not be tolerated symptomatically. The case raises other important management points: This man has had a TIA and should have been referred urgently to a TIA clinic, with the aim of being seen within 24 h of his symptoms. He will need investigations to look for the cause of his TIA and, in the first instance, carotid Dopplers would be performed.

A	Commencement of ezetimibe and simvastatin

There is no reason to add ezetimibe as

A	Commencement of ezetimibe and simvastatin

There is no reason to add ezetimibe as well as a statin, unless there was evidence of familial hypercholesterolaemia.

C	Commencement of dipyridamole 200 mg/day

In the acute setting (2 weeks) after TIA, aspirin 300 mg/day is recommended. Thereafter clopidogrel 75 mg daily is the drug of choice.

D	Commencement of atenolol 50 mg/day

Current guidelines would suggest assessing blood pressure as part of secondary prevention, but only treating it medically if it was elevated – this patient's blood pressure is satisfactory.

E	Commencement of

A 34-year-old woman presents to casualty with left-sided weakness. This began suddenly the previous day during an argument with her husband. There are no associated headache, speech or swallowing symptoms. She has a history of irritable bowel syndrome and chronic pelvic pain, for which multiple diagnostic interventions have failed to find a cause. In addition, she has presented to casualty twice previously with atypical chest pain. She also suffers from migraine and describes her headaches being heralded by difficulty seeing in the centre of her vision. This has only happened since she started the combined oral contraceptive pill six months ago. She takes codeine and paracetamol for her pelvic pain.

On examination, she appears well. There are no cranial nerve abnormalities. Fundoscopy is normal and there are no visual field defects. Tone is normal in all four limbs. Power testing reveals weakness in the left arm and leg, but there is some variability. In particular, it is noticed

that she is able to walk into the cubicle but on formal testing has difficulty lifting her leg against gravity. Reflexes are brisk throughout, with equivocal plantars but no ankle clonus. Sensory examination shows some subjective decrease in soft touch on the left side.

What is the most likely diagnosis?

A	Intracranial space-occupying lesion
B	Hemiplegic migraine
C	Functional neurological disorder
D	Right middle cerebral artery infarction
E	Multiple sclerosis

6998

Submit

C Functional neurological disorder

Functional neurological disorder is very common, accounting for up to a third of new referrals in neurology clinics. The commonest neurological manifestations are functional weakness, sensory symptoms and non-epileptic seizures. It is important to be aware of the possibility of functional weakness and to include it in your differential.

It is not a diagnosis of exclusion and should be made based of the presence of positive evidence for a functional disorder – this often includes inconsistent physical examination findings or specific functional signs such as 'Hoover's sign'. Functional neurological disorder can be difficult to understand (for both patients and some doctors), and so it is critical to appreciate that for the patient the symptoms are real (i.e. not feigned) and are often disabling. There is no structural neurological disease present, but often significant psychological

stresses seem to play a part in producing the syndrome.

E	Multiple sclerosis

Whilst it is always worth considering this diagnosis in younger people presenting with neurological problems, there are a number of features that make it unlikely here: Firstly, the symptoms were sudden in onset. In MS the symptoms tend to build up over hours or days. Secondly, one would expect a clearer set of examination findings, with definite weakness (rather than the inconsistent pattern here). Thirdly, MS is characterised by multiple episodes of neurological dysfunction affecting multiple parts of the nervous system (lesions disseminated in time and space) and so this first episode would not be MS.

A	Intracranial space-occupying lesion

The symptoms have come on too quickly for this to be the diagnosis, and

neurological signs.

B	Hemiplegic migraine

The symptoms in this case started suddenly, whereas migraine symptoms tend to spread over several minutes; in addition, there was no headache.

D	Right middle cerebral artery infarction

Whilst the sudden onset of hemiplegia should raise the suspicion of stroke, there are a number of features here that make it unlikely – firstly the distribution of weakness; in MCA stroke one expects predominantly face and arm weakness, whereas here we have arm and leg. Secondly one would expect a clearer set of examination findings, with definite weakness (rather than the inconsistent pattern here) and potentially a visual field defect. Thirdly, she is only 34 so the 'pre-test' probability of this being a stroke is very low.

On examination, she appears well. There are no cranial nerve abnormalities. Fundoscopy is normal and there are no visual field defects. Tone is normal in all four limbs. Power testing reveals weakness in the left arm and leg, but there is some variability. In particular, it is noticed that she is able to walk into the cubicle but on formal testing has difficulty lifting her leg against gravity. Reflexes are brisk throughout, with equivocal plantars but no ankle clonus. Sensory examination shows some subjective decrease in soft touch on the left side.

What is the most likely diagnosis?

Your answer was incorrect

A	Intracranial space-occupying lesion
B	Hemiplegic migraine

A softly speaking 24-year-old man is brought to his general practitioner (GP) by his mother, with symptoms of depression, poor concentration and 'personality change'. He tends to cry very easily. He also complains of a resting tremor in one hand that has become progressively more noticeable over the last few months. He has also found getting dressed in the mornings to be particularly difficult due to a lack of coordination.

On examination, the patient has a relatively expressionless face with a paucity of blinking. A fine resting tremor of the left hand is noted. Examination of the patient's wrists shows rigidity of movement on flexion and extension. Mental examination shows a mini-mental score of 26/30. Observing the patient walking shows the left arm not to swing fully and the left foot mildly scraping the floor. General examination reveals hepatomegaly. Routine blood screen reveals elevated transaminases.

Taking all these features into account, which one of the following conditions

Observing the patient walking shows the left arm not to swing fully and the left foot mildly scraping the floor. General examination reveals hepatomegaly. Routine blood screen reveals elevated transaminases.

Taking all these features into account, which one of the following conditions should be suspected?

A	Idiopathic Parkinson's disease
B	New-variant Creutzfeld–Jakob disease
C	Haemochromatosis
D	Wilson's disease
E	Whipple's disease

6657

Submit

over the last few months. He has also found getting dressed in the mornings to be particularly difficult due to a lack of coordination.

On examination, the patient has a relatively expressionless face with a paucity of blinking. A fine resting tremor of the left hand is noted. Examination of the patient's wrists shows rigidity of movement on flexion and extension. Mental examination shows a mini-mental score of 26/30. Observing the patient walking shows the left arm not to swing fully and the left foot mildly scraping the floor. General examination reveals hepatomegaly. Routine blood screen reveals elevated transaminases.

Taking all these features into account, which one of the following conditions should be suspected?

Your answer was correct

A	Idiopathic Parkinson's disease
B	New variant Creutzfeldt-Jakob

D Wilson's disease

Although presentation of this autosomal recessive disorder of copper metabolism is typically in children or adolescents (usually around 10–12 years for liver disease and 18–20 years for neuropsychiatric symptoms), later presentations can more rarely occur, even in patients >40 years. Copper and caeruloplasmin levels should therefore be tested even in older patients with this type of presentation.

The most common presenting neurologic feature is asymmetric tremor, occurring in approximately half of individuals with Wilson disease. A parkinsonian picture is the most common presentation but dystonic, pseudo-sclerotic (resembling multiple sclerosis) or choreiform presentations can also occur. About 10–20 % of patients have neuropsychiatric features (emotional lability, disinhibition, cognitive impairment). Kayser–Fleischer rings are observed in up to 90% of individuals with

up to 90% of individuals with symptomatic Wilson's disease and are almost invariably present in those with neurologic manifestations.

A	Idiopathic Parkinson's disease

Although familial forms of Parkinson's disease do exist with presentation at a young age, this would be inconsistent with the liver dysfunction seen here.

B	New-variant Creutzfeld–Jakob disease

New-variant CJD presents with psychiatric features and gait ataxia, which progress to dementia with increased motor tone and myoclonus.

C	Haemochromatosis

Haemochromatosis presents with increased pigmentation, features of liver cirrhosis, diabetes and erectile dysfunction.

A 21-year-old student at home during the holidays is brought to the Emergency Department by her parents. She was initially complaining of headache and photophobia which has become more marked over the last couple of hours. She has vomited once.

On examination, she has a fever of 38 °C but no evidence of a rash. She has enlarged cervical lymph nodes but auscultation of the chest was clear. Following routine blood investigations, a computed tomography (CT) scan of her head is performed, which excluded a mass lesion and assessed that there was no significant risk in progressing to lumbar puncture.

A lumbar puncture was subsequently performed and the cerebrospinal fluid (CSF) results are shown below:

Appearance	Clear
Cells	Mononuclear predominantly
White cell count	4.52/ml (5/ml)

count	
Glucose	3.9 mmol/l
Plasma glucose	5.1 mmol/l
Protein	0.53 g/l (0.15-0.45 g/l)

What diagnosis would best fit this clinical picture?

A Herpes simplex encephalitis

B Coxsackie meningitis

C Meningococcal meningitis

D Pneumococcal meningitis

E Tuberculous meningitis

parents. She was initially complaining of headache and photophobia which has become more marked over the last couple of hours. She has vomited once.

On examination, she has a fever of 38 °C but no evidence of a rash. She has enlarged cervical lymph nodes but auscultation of the chest was clear. Following routine blood investigations, a computed tomography (CT) scan of her head is performed, which excluded a mass lesion and assessed that there was no significant risk in progressing to lumbar puncture.

A lumbar puncture was subsequently performed and the cerebrospinal fluid (CSF) results are shown below:

Appearance	Clear
Cells	Mononuclear predominantly
White cell count	4.52/ml (5/ml)
Glucose	3.9 mmol/l
Plasma glucose	5.1 mmol/l

B Coxsackie meningitis

The CSF analysis is consistent with an aseptic meningitis. In the context of an acute febrile meningitic disease process at this time of year, this is most likely to be due to viral meningitis. The most common aetiologies include enteroviruses (e.g. Coxsackie), herpes simplex virus, West Nile virus, mumps and varicella zoster. Other causes of aseptic meningitis include Mollaret's meningitis, Spirochaetes (e.g. syphilis or Lyme disease), fungal infections, partially treated bacterial meningitis, drug-induced meningitis (e.g. NSAIDS, trimethoprim or IVIg) or leptomeningeal infiltration (e.g. large cell lymphoma or carcinomatous meningitis). The treatment for Coxsackie virus meningitis is supportive.

A Herpes simplex encephalitis

This patient has symptoms consistent with an acute meningitis, and there is

A Herpes simplex encephalitis

This patient has symptoms consistent with an acute meningitis, and there is no evidence of encephalopathy (altered mental status, motor/ sensory deficits or seizures), making an encephalitis unlikely.

C Meningococcal meningitis

A bacterial meningitis cannot be ruled out on clinical grounds (even in the absence of a meningococcal rash), and therefore any suspected meningitis should be treated urgently with IV antibiotics. The CSF result is not consistent with bacterial meningitis, in which you would expect to see polymorph cells, a low glucose and possibly a raised protein. The CSF may appear purulent, and the Gram stain is likely to be positive.

D Pneumococcal meningitis

D Pneumococcal meningitis

The CSF is not consistent with bacterial meningitis, in which you would expect to see polymorph cells, a low glucose and possibly a raised protein. The CSF may appear purulent, and the Gram stain is likely to be positive.

E Tuberculous meningitis

The CSF of tuberculous meningitis typically shows elevated protein (1.0–5.0 g/l), very low glucose and a mononuclear pleocytosis. Three serial CSF samples should be obtained for acid-fast bacilli smear and culture. The presentation of tuberculous meningitis is typically with a subacute meningism in patients with risk factors such as exposure or immune compromise.

6078

Rate this question:

Next Question

A 48-year-old woman presents to the Emergency Department with a second transient ischaemic attack (TIA) over the last 6 months. She was previously thoroughly investigated with MRI/MRA brain, prolonged ambulatory cardiac rhythm monitoring, blood pressure monitoring and a thrombophilia screen.

An echocardiogram showed a large right-to-left shunt caused by a patent foramen ovale (PFO). She had been compliant with the secondary preventative medication: clopidogrel 75 mg and simvastatin 40 mg.

The event completely resolves and neurological examination in the Emergency Department some 4 h after presentation is entirely normal.

Which of the following is the best way to manage her for the long term?

A	Dual antiplatelet therapy – add aspirin 75 mg
B	Commence anticoagulation

compliant with the secondary preventative medication: clopidogrel 75 mg and simvastatin 40 mg.

The event completely resolves and neurological examination in the Emergency Department some 4 h after presentation is entirely normal.

Which of the following is the best way to manage her for the long term?

A	Dual antiplatelet therapy – add aspirin 75 mg
B	Commence anticoagulation with warfarin, stop clopidogrel
C	No changes
D	Percutaneous closure of PFO
E	Commence anticoagulation with warfarin, continue clopidogrel

A 48-year-old woman presents to the Emergency Department with a second transient ischaemic attack (TIA) over the last 6 months. She was previously thoroughly investigated with MRI/MRA brain, prolonged ambulatory cardiac rhythm monitoring, blood pressure monitoring and a thrombophilia screen.

An echocardiogram showed a large right-to-left shunt caused by a patent foramen ovale (PFO). She had been compliant with the secondary preventative medication: clopidogrel 75 mg and simvastatin 40 mg.

The event completely resolves and neurological examination in the Emergency Department some 4 h after presentation is entirely normal.

Which of the following is the best way to manage her for the long term?

Your answer was correct

D Percutaneous closure of PFO

Recent results of two large randomised trials (CLOSE and Gore-REDUCE) have shown benefit from percutaneous closure of high-risk PFOs in young patients with cryptogenic ischaemic strokes. High-risk is defined as having a co-existent atrial septal aneurysm or a large shunt. Long-term antiplatelet therapy should be continued. The procedure is generally low-risk but is associated with an increased risk of new-onset atrial fibrillation which, if managed appropriately, does not affect the overall cerebrovascular event recurrence rate.

A Dual antiplatelet therapy – add aspirin 75 mg

There is no evidence base for stroke prevention with dual antiplatelet therapy in this situation. The risk of bleeding would be unacceptably high without alleviating the risk of further

B	Commence anticoagulation with warfarin, stop clopidogrel

There is no conclusive evidence for the superiority of anticoagulation over antiplatelet therapy in the management of PFOs. There is certainly no role for a combined antiplatelet/anticoagulant therapy in secondary stroke prevention as the risk of bleeding complications would be unacceptably high.

C	No changes

Until recently this would have been the practice in most centres, and may well still be in many centres. However, as discussed below, we should now recommend PFO closure in this circumstance.

E	Commence anticoagulation with warfarin, continue clopidogrel

Until recently this would have been the practice in most centres, and may well still be in many centres. However, as discussed below, we should now recommend PFO closure in this circumstance.

E	Commence anticoagulation with warfarin, continue clopidogrel

There is no evidence for the use of anticoagulation above/ in addition to antiplatelets in the management of PFOs; see answer B) above. The risk of bleeding would be unacceptably high in this patient, and percutaneous closure, which is safe and effective, should be opted for instead.

70494

Rate this question:

A 34-year-old man with a history of schizophrenia was brought to the Emergency Department after being found confused with a fever at home by his key worker. He was found in bed and his key worker suspected that he had probably been there and not moved for the preceding three days. His only prescribed medication was fluphenazine.

The patient's observations were as follows: blood pressure 90/50 mmHg, pulse 130 bpm, temperature 38 °C, saturations 97% on air, respiratory rate 22/min.

On examination, he was mildly confused and sweating profusely. He had no neck stiffness and did not appear to have any photophobia. Neurological examination showed a marked increase in tone in all four limbs, and the patient found it difficult to move any of his limbs. Cardiovascular, respiratory and abdominal examinations did not reveal any further abnormalities.

Which one of the following

Neurological examination showed a marked increase in tone in all four limbs, and the patient found it difficult to move any of his limbs. Cardiovascular, respiratory and abdominal examinations did not reveal any further abnormalities.

Which one of the following interventions is the most suitable in this patient's case?

A	Prednisolone
B	IV fluid replacement
C	Atenolol
D	Carbamazepine
E	Urinary alkalinisation

32700

Submit

A 34-year-old man with a history of schizophrenia was brought to the Emergency Department after being found confused with a fever at home by his key worker. He was found in bed and his key worker suspected that he had probably been there and not moved for the preceding three days. His only prescribed medication was fluphenazine.

The patient's observations were as follows: blood pressure 90/50 mmHg, pulse 130 bpm, temperature 38 °C, saturations 97% on air, respiratory rate 22/min.

On examination, he was mildly confused and sweating profusely. He had no neck stiffness and did not appear to have any photophobia. Neurological examination showed a marked increase in tone in all four limbs, and the patient found it difficult to move any of his limbs. Cardiovascular, respiratory and abdominal examinations did not reveal any further abnormalities.

Which one of the following

B IV fluid replacement

The diagnosis in this case is neuroleptic malignant syndrome, a life-threatening adverse drug reaction seen in patients taking antipsychotic drugs. The condition is characterised by rigidity, fever, autonomic dysfunction and delirium. A high creatinine kinase and white cell count are often seen in affected patients. Rhabdomyolysis and acute kidney injury are recognised complications. Supportive treatment is key, with aggressive cooling and maintenance of hydration with IV fluids being particularly important in the management of this condition. Bromocriptine and dantrolene may be used, but there is a scarcity of good evidence to support this. It is presumed that an increase in the dose of the patient's fluphenazine has precipitated the development of neuroleptic malignant syndrome in this case.

A Prednisolone

This is not used in the management of neuroleptic malignant syndrome. The steroid dexamethasone is useful in the management of meningoencephalitis, but the findings in this case are not in keeping with this diagnosis.

C Atenolol

This is not useful in the management of neuroleptic malignant syndrome. Autonomic dysfunction can result in labile blood pressure and treatment with atenolol may exacerbate this and result in dangerous hypotension.

D Carbamazepine

This is not useful in the management of neuroleptic malignant syndrome. Carbamazepine is an anti-epileptic drug used in the management of partial and generalised seizures and neuropathic pain.

E Urinary alkalinisation

result in dangerous hypotension.

D	Carbamazepine

This is not useful in the management of neuroleptic malignant syndrome. Carbamazepine is an anti-epileptic drug used in the management of partial and generalised seizures and neuropathic pain.

E	Urinary alkalinisation

This is not useful in the management of neuroleptic malignant syndrome. Urinary alkalinisation may be useful in patients presenting with salicylate or phenobarbital overdoses as it can increase excretion of these drugs. It has been suggested that this may be a useful intervention in the management of rhabdomyolysis (which may complicate neuroleptic malignant syndrome), but there is limited evidence to support this.

32700

Rate this question:

A 29-year-old woman from Malawi is admitted with a 2-week history of weight loss, fever, difficulty walking and abnormal speech. In the Accident and Emergency Department she is witnessed to have a focal seizure involving her right arm and right leg.

On examination, she has mild right-sided weakness, ataxia and dysphasia. A CT brain scan shows multiple ring-enhancing lesions in both cerebral and cerebellar hemispheres. An HIV antibody test is positive. An MRI brain scan confirms bilateral cerebral and cerebellar ring-enhancing lesions. CSF findings are unremarkable.

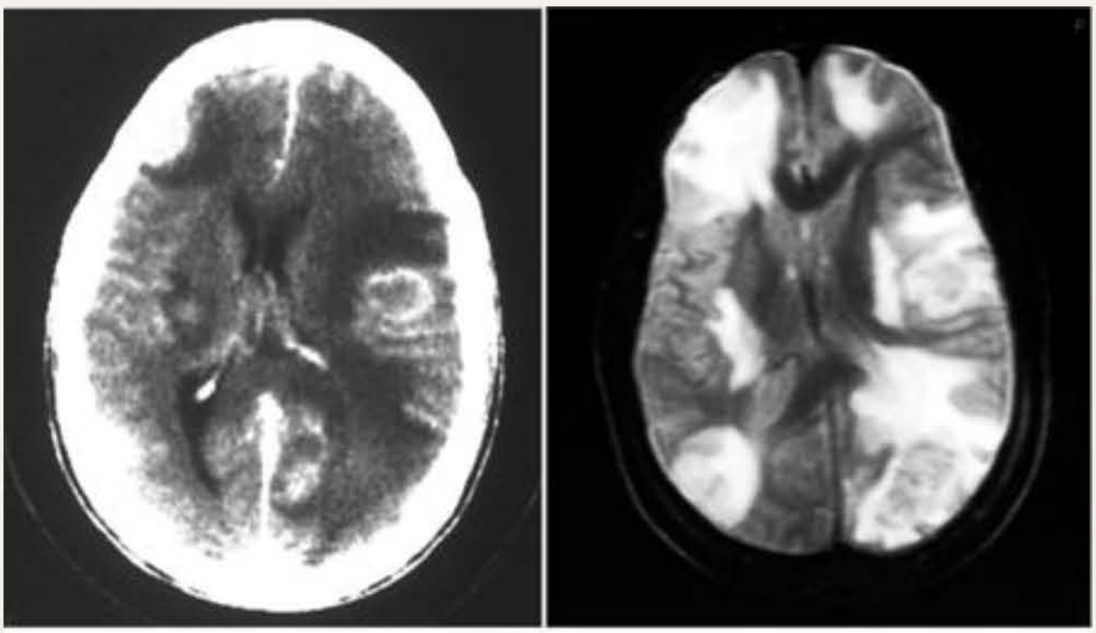

A

Copyright © 2005, 2004, 2000, 1995, 1990, 1985, 1979 by Elsevier Inc.

The images above shows the findings from a CT brain scan (A) with contrast

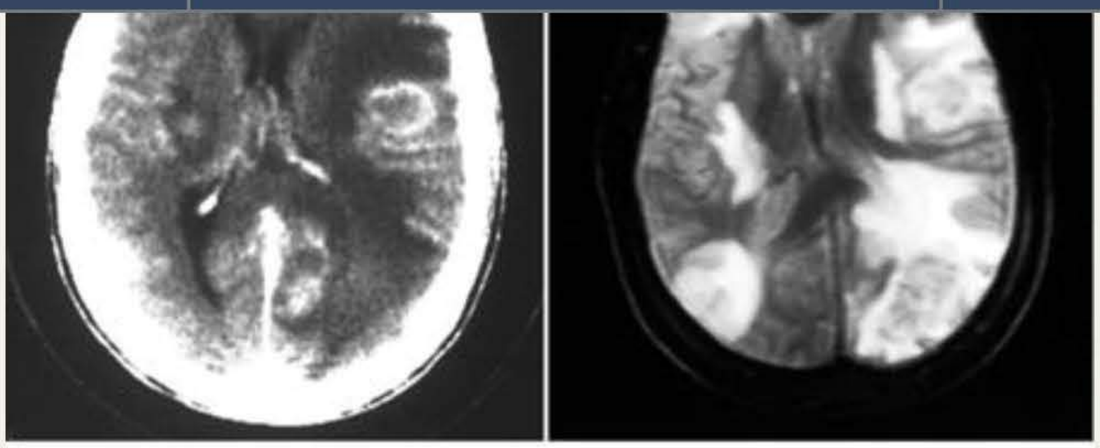

A

Copyright © 2005, 2004, 2000, 1995, 1990, 1985, 1979 by Elsevier Inc.

The images above shows the findings from a CT brain scan (A) with contrast and a T2-weighted MRI brain scan (B).

Which drugs would be included in empirical therapy for this condition?

A	Dexamethasone and ceftriaxone
B	Ceftriaxone and amphotericin B
C	Sulfadiazine, pyrimethamine and folinic acid
D	Foscarnet and ganciclovir
E	Aciclovir

weight loss, fever, difficulty walking and abnormal speech. In the Accident and Emergency Department she is witnessed to have a focal seizure involving her right arm and right leg.

On examination, she has mild right-sided weakness, ataxia and dysphasia. A CT brain scan shows multiple ring-enhancing lesions in both cerebral and cerebellar hemispheres. An HIV antibody test is positive. An MRI brain scan confirms bilateral cerebral and cerebellar ring-enhancing lesions. CSF findings are unremarkable.

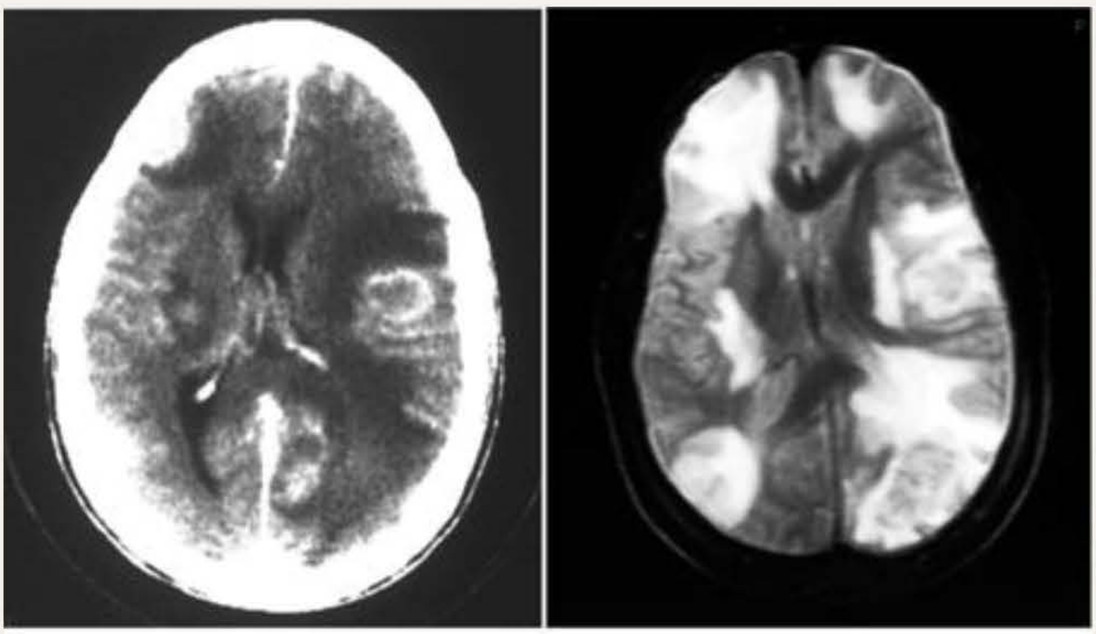

A

Copyright © 2005, 2004, 2000, 1995, 1990, 1985, 1979 by Elsevier Inc.

The images above shows the findings from a CT brain scan (A) with contrast and a T2-weighted MRI brain scan (B).

Which drugs would be included in

C Sulfadiazine, pyrimethamine and folinic acid

The likely diagnosis in the setting of HIV infection is cerebral toxoplasmosis. This presents in the setting of advanced immunosuppression, but is still seen as a first presentation of HIV infection. The most common presenting symptoms are fever, focal neurological symptoms and seizures. Patients are nearly always seropositive for *Toxoplasma gondii*, so negative serology should suggest an alternative diagnosis. Imaging studies characteristically show multiple ring-enhancing lesions. The main differential diagnoses are primary cerebral lymphoma, tuberculosis, cryptococcal disease and progressive multifocal leucoencephalopathy (PML). Often, empirical therapy for toxoplasmosis is started on the basis of findings from imaging studies, and therapy should result in radiological improvement within 2–3 weeks. The initial treatment of choice is sulfadiazine and pyrimethamine with

sulfadiazine and pyrimethamine with folinic acid. If there is no improvement, then brain biopsy is indicated. Steroids are often used if there is significant oedema or mass effect, but there is no evidence for their use otherwise.

A	Dexamethasone and ceftriaxone

This is the treatment for suspected pneumococcal meningitis, but the ring-enhancing lesions seen here suggest toxoplasmosis.

B	Ceftriaxone and amphotericin B

This would cover bacterial infection and also fungal infections such as *Cryptococcus*. The multiple ring-enhancing lesions favour toxoplasmosis.

D	Foscarnet and ganciclovir

This is the treatment for CMV

A 23-year-old secretary in a law firm presents with a one-day history of sudden-onset left-sided facial weakness. She first noticed this when she was putting her make-up on in the morning. She has noticed hyperacusis in her left ear and altered taste. She is very anxious because two years ago she had problems with her vision and was told that multiple sclerosis was a possibility. At this time, she declined further investigation when it was offered. Past medical history of note includes type 1 diabetes mellitus. Regular medications include insulin and the combined oral contraceptive pill. She denies any tick bites, head injury or recent painful blistering on her outer ear.

On examination, she has entire paralysis of the 7th cranial nerve, including weakness of the forehead and some difficulty closing her left eye. There is no objective hearing loss, and no sensory signs. Examination of the auditory meatus and canal is unremarkable. The remainder of the neurological examination is normal.

and some difficulty closing her left eye. There is no objective hearing loss, and no sensory signs. Examination of the auditory meatus and canal is unremarkable. The remainder of the neurological examination is normal. There are no visible rashes. You offer her an eye patch.

What is the most likely diagnosis?

A	Stroke
B	Lyme's disease
C	Multiple sclerosis
D	Ramsay Hunt syndrome
E	Bell's palsy

6994

Submit

morning. She has noticed hyperacusis in her left ear and altered taste. She is very anxious because two years ago she had problems with her vision and was told that multiple sclerosis was a possibility. At this time, she declined further investigation when it was offered. Past medical history of note includes type 1 diabetes mellitus. Regular medications include insulin and the combined oral contraceptive pill. She denies any tick bites, head injury or recent painful blistering on her outer ear.

On examination, she has entire paralysis of the 7th cranial nerve, including weakness of the forehead and some difficulty closing her left eye. There is no objective hearing loss, and no sensory signs. Examination of the auditory meatus and canal is unremarkable. The remainder of the neurological examination is normal. There are no visible rashes. You offer her an eye patch.

What is the most likely diagnosis?

Your answer was correct

E Bell's palsy

Bell's palsy is an idiopathic palsy or paralysis of the 7th cranial nerve. It typically has a sudden onset of action and affects regions innervated by the facial nerve. The present scenario includes altered taste and hyperacusis. The lower motor neurone presentation here, with all facial muscles involved, is the key differentiating factor when comparing Bell's palsy to a stroke, which spares the forehead. Treatment includes oral prednisolone and an eye patch to protect the eye, given the inability to close it.

A Stroke

This is false because in a stroke you have an upper motor neurone presentation whereby there is sparing of the forehead muscles. This lady clearly has a lower motor neurone lesion in view of the fact that she has entire paralysis of the facial nerve including the forehead.

B Lyme's disease

This is a favourite of the MRCP but in this case is not correct. Although this can cause facial palsy, one would expect a history of tick bites and a rash to be present. Without any further evidence to support Lyme's disease, it simply cannot be the best answer.

C Multiple sclerosis

Multiple sclerosis was a possible diagnosis when this lady had optic neuritis previously. This option is not the best answer because MS typically presents as an upper motor neurone lesion. This basic knowledge can allow you to rule out MS when considering which option is the most correct.

D Ramsay Hunt syndrome

Ramsay Hunt syndrome, also known as herpes zoster oticus, presents with painful blisters on the outer ear. There was no evidence of this in the scenario

A 73-year-old man known to be suffering from small cell lung cancer is brought to his general practitioner (GP) by his daughter since she is concerned that her father has grown considerably weaker, and she feels he may not be able to cope alone at home.

On further questioning, the patient does report problems with walking up stairs or bending his legs to dress in the mornings, and that has got progressively worse over the last few months. He also reports problems with a dry mouth and swallowing, as if the food gets stuck in his throat.

On examination, the patient is mildly cachectic. Neurological examination confirms weakness of the muscles of the thighs and hips. Depressed lower limb reflexes were also observed.

Given the likely clinical diagnosis, which of the following observations would best help distinguish this syndrome from myasthenia gravis?

A Involvement of the autonomic

On examination, the patient is mildly cachectic. Neurological examination confirms weakness of the muscles of the thighs and hips. Depressed lower limb reflexes were also observed.

Given the likely clinical diagnosis, which of the following observations would best help distinguish this syndrome from myasthenia gravis?

A	Involvement of the autonomic nervous system
B	Hyper-reflexia
C	Marked response to edrophonium
D	Facilitation shown on testing of several muscle groups
E	Involvement of the respiratory and oropharyngeal muscles

A 73-year-old man known to be suffering from small cell lung cancer is brought to his general practitioner (GP) by his daughter since she is concerned that her father has grown considerably weaker, and she feels he may not be able to cope alone at home.

On further questioning, the patient does report problems with walking up stairs or bending his legs to dress in the mornings, and that has got progressively worse over the last few months. He also reports problems with a dry mouth and swallowing, as if the food gets stuck in his throat.

On examination, the patient is mildly cachectic. Neurological examination confirms weakness of the muscles of the thighs and hips. Depressed lower limb reflexes were also observed.

Given the likely clinical diagnosis, which of the following observations would best help distinguish this syndrome from myasthenia gravis?

A Involvement of the autonomic nervous system

Lambert–Eaton myasthenic syndrome (LEMS) usually occurs in association with malignancy, and results from an autoimmune attack directed against the voltage-gated calcium channels (VGCC) on the presynaptic motor nerve terminal. VGCC antibodies can be detected in the serum. Around 50–70% of LEMS cases have an identifiable malignancy, the majority being small cell lung cancer. Most patients with LEMS present with slowly progressive proximal muscle weakness, particularly involving the legs. Deep tendon reflexes are typically depressed or absent – their recovery following vigorous brief muscle activation is pathognomonic. Autonomic dysfunction is often present. Dry mouth from reduced salivation is the most common autonomic symptom (77%), while erectile dysfunction is common in men (45%). These are only

rarely a feature of myasthenia gravis.

D	Facilitation shown on testing of several muscle groups

Brief, maximal isometric contraction of the relevant muscle can sometimes lead to temporary reappearance of previously depressed or absent reflexes. This can also be seen electrophysiologically in nerve conduction studies. The interpretation is quite subjective and therefore not as good an answer as the presence of autonomic symptoms.

B	Hyper-reflexia

NMJ disorders present with normal, depressed or absent reflexes, and therefore hyper-reflexia is not helpful in distinguishing between MG and LEMS.

C	Marked response to edrophonium

A 58-year-old sales assistant is referred to the general neurology clinic by her general practitioner (GP). She complains of dizziness on standing, particularly worse after eating. Her symptoms have deteriorated over the past 12 months, during which time she has also noticed clumsiness of her hands, with deterioration of her handwriting. In addition, she is rather embarrassed about recent episodes of urinary incontinence.

On examination, her blood pressure is 168/96 mmHg lying, 126/70 mmHg standing. Examination of her limbs is significant for rigidity, with some finger-nose ataxia and dysdiadochokinesis bilaterally. Reflexes are symmetrically brisk with flexor plantars. Sensory examination is unremarkable.

What is the most likely diagnosis?

A	Idiopathic Parkinson's disease
B	Multiple systems atrophy (MSA)

On examination, her blood pressure is 168/96 mmHg lying, 126/70 mmHg standing. Examination of her limbs is significant for rigidity, with some finger-nose ataxia and dysdiadochokinesis bilaterally. Reflexes are symmetrically brisk with flexor plantars. Sensory examination is unremarkable.

What is the most likely diagnosis?

A	Idiopathic Parkinson's disease
B	Multiple systems atrophy (MSA)
C	Progressive supranuclear palsy (PSP)
D	Multiple sclerosis
E	Paraneoplastic encephalopathy

A 58-year-old sales assistant is referred to the general neurology clinic by her general practitioner (GP). She complains of dizziness on standing, particularly worse after eating. Her symptoms have deteriorated over the past 12 months, during which time she has also noticed clumsiness of her hands, with deterioration of her handwriting. In addition, she is rather embarrassed about recent episodes of urinary incontinence.

On examination, her blood pressure is 168/96 mmHg lying, 126/70 mmHg standing. Examination of her limbs is significant for rigidity, with some finger-nose ataxia and dysdiadochokinesis bilaterally. Reflexes are symmetrically brisk with flexor plantars. Sensory examination is unremarkable.

What is the most likely diagnosis?

Your answer was correct

A	Idiopathic Parkinson's disease

B Multiple systems atrophy (MSA)

The most likely diagnosis for this case is multiple system atrophy (MSA). Autonomic and urinary symptoms are common. Patients may have parkinsonian symptoms with poorly sustained response to levodopa. Motor impairment may also be caused by cerebellar dysfunction. Orthostatic hypotension and associated symptoms are common. Syncopal episodes may occur. Parkinsonism may be the initial feature in up to half of patients, and ultimately develops in 90%. Cerebellar symptoms may present as gait or limb ataxia. Neuro-imaging may be normal in MSA. Hyperintensity of the lateral margin of the putamen in T2-weighted magnetic resonance imaging (MRI) is a characteristic finding in patients with MSA involving the extrapyramidal system. Autonomic function testing is useful in evaluation of the distribution and severity of parasympathetic and sympathetic function. Sphincter electromyography is useful for demonstrating hyper-reflexia of

detrusor in MSA and may guide the management of bladder dysfunction.

A	Idiopathic Parkinson's disease

Whilst this patient does have evident rigidity, the cerebellar features and very prominent autonomic disturbance make MSA more likely.

C	Progressive supranuclear palsy (PSP)

There is no evidence of early falls or a vertical supranuclear gaze palsy, so PSP seems unlikely.

D	Multiple sclerosis

MS is unlikely to present at this age. Whilst MS can cause cerebellar features, signs such as rigidity and postural hypotension are not typically seen.

E	Paraneoplastic

6:50

https://www.google.com/sea 16

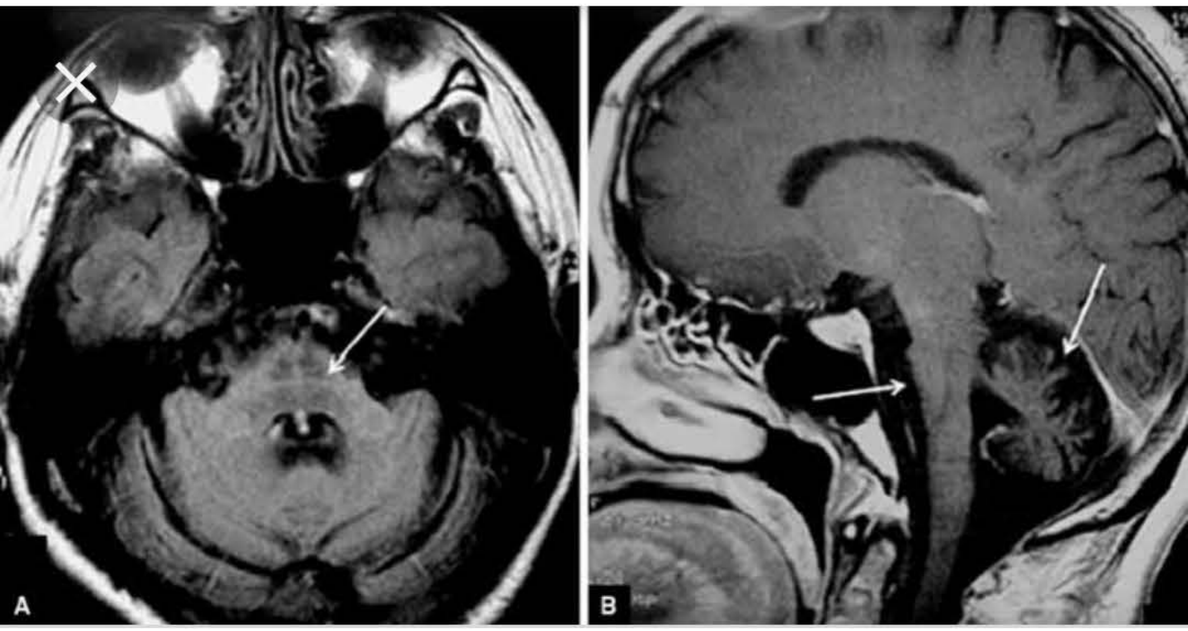

ResearchGate

Brain MRI of a patient with multiple system atrophy, cerebe...

Brain MRI of a patient with multiple system atrophy, cerebellar form (MSA-C). Axial T1-weighted sequence: note the “ hot cross bun" sign indicated by the ...

Images may be subject to copyright. Learn More

RELATED IMAGES

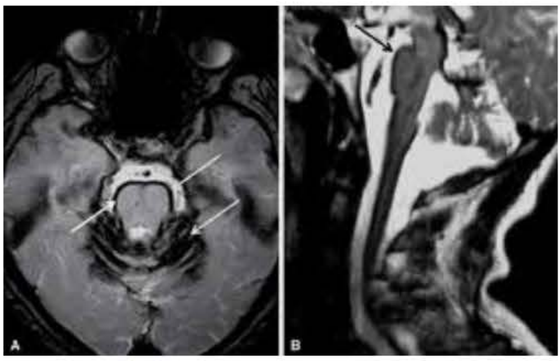

Brain MRI of a patient with su...
researchgate.net

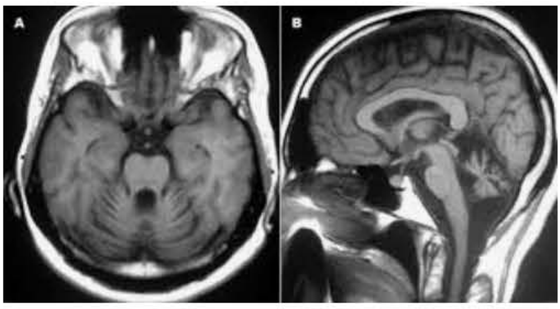

Brain MRI scan images: gene...
researchgate.net

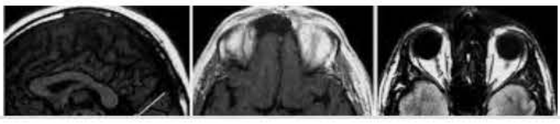

6:50

https://www.google.com/sea 16

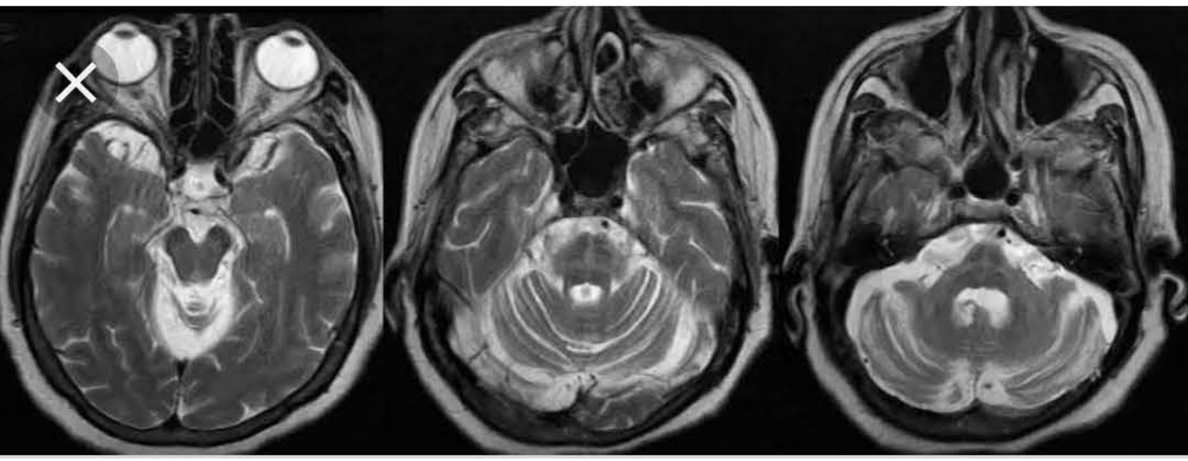

Dr Balaji Anvekar's Neuror...

Multiple System Atrophy MRI

Images may be subject to copyright. Learn More

RELATED IMAGES

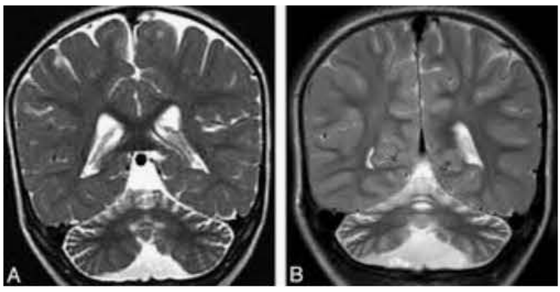

Fig 1. | Inherited Cerebellar A...
ajnr.org

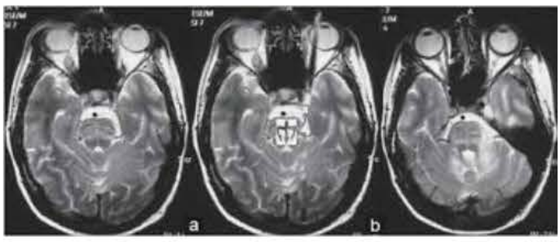

View Image
neurologyindia.com

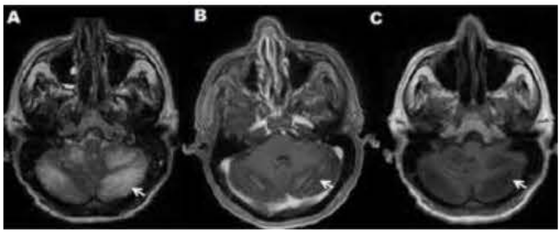

Cryptococcal cerebellitis in n...
scielo.org.co

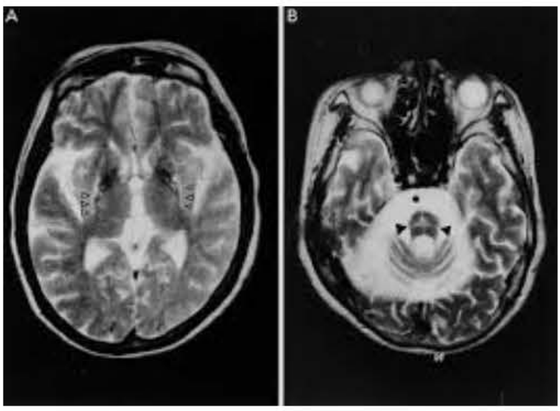

MRI signal abnormalities in p...
researchgate.net

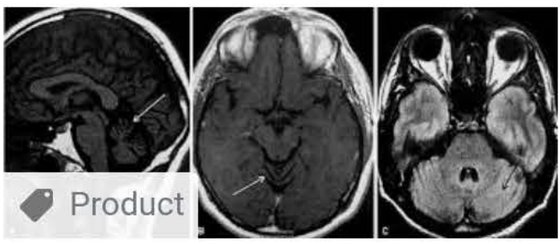

Product

Brain MRI of a patient with al...

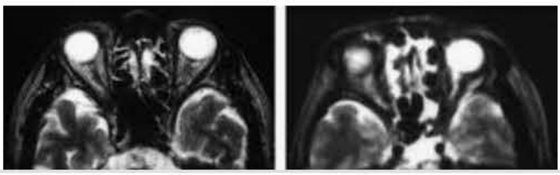

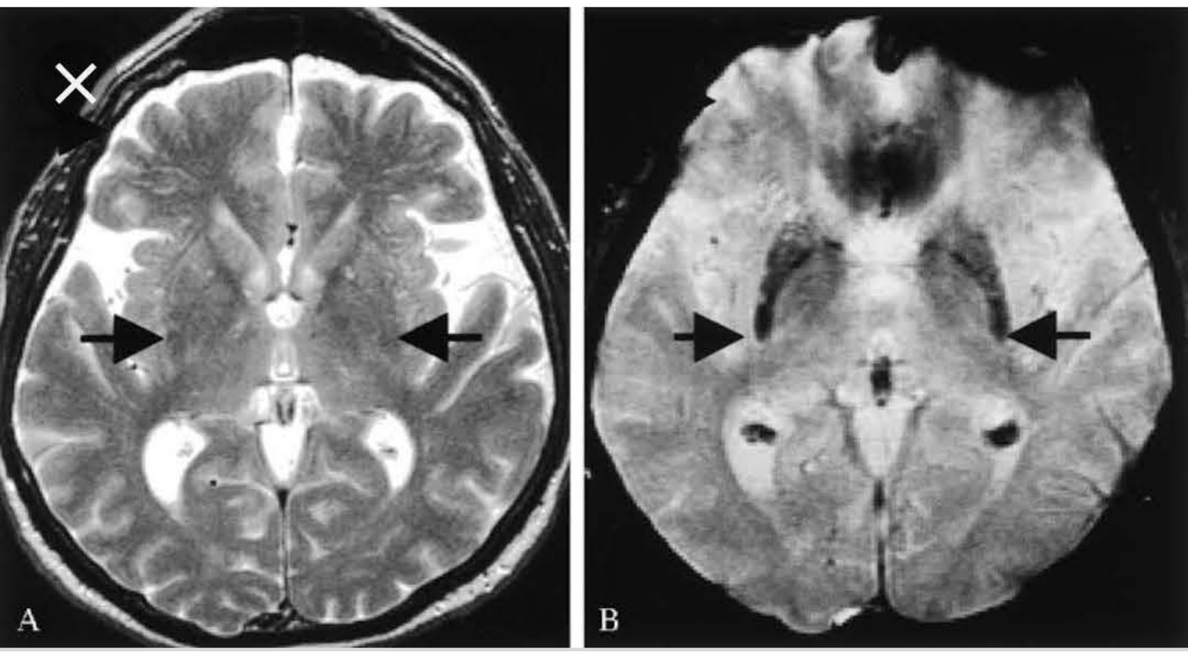

Neurology

T2*-weighted MRI differentiates multiple system atrophy from ...

Download figure ...

Images may be subject to copyright. Learn More

RELATED IMAGES

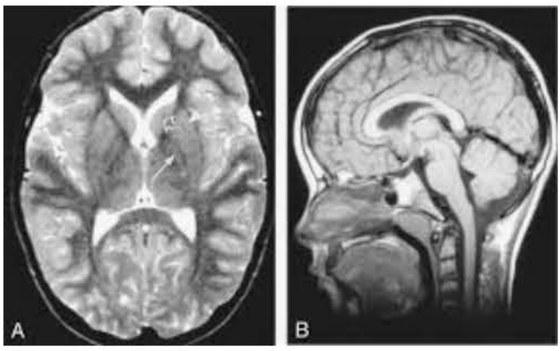

Fig 1. | New Syndrome Chara...
ajnr.org

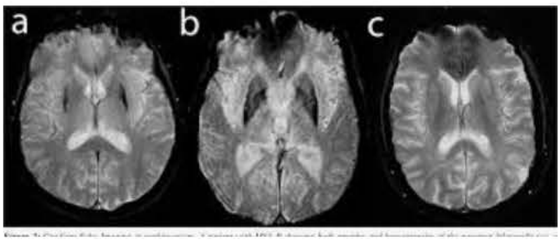

Figure 2 from The value of G...
semanticscholar.org

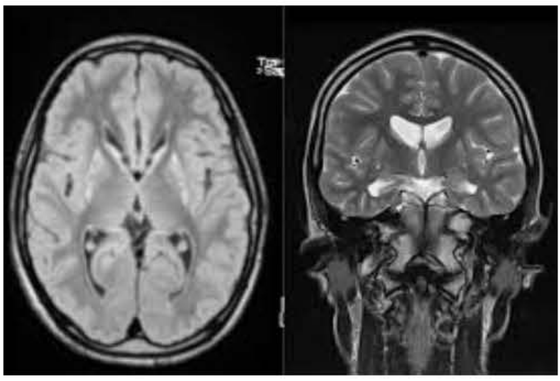

Radiology MRI: Huntington Di...

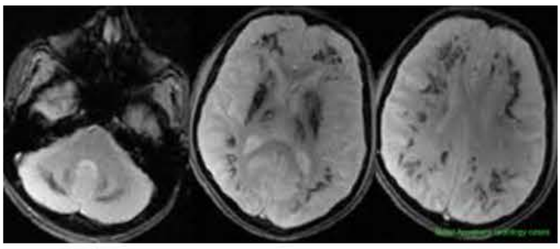

Dr Balaji Anvekar's Neuroradi...
neuroradiologycases.com

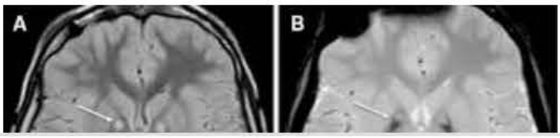

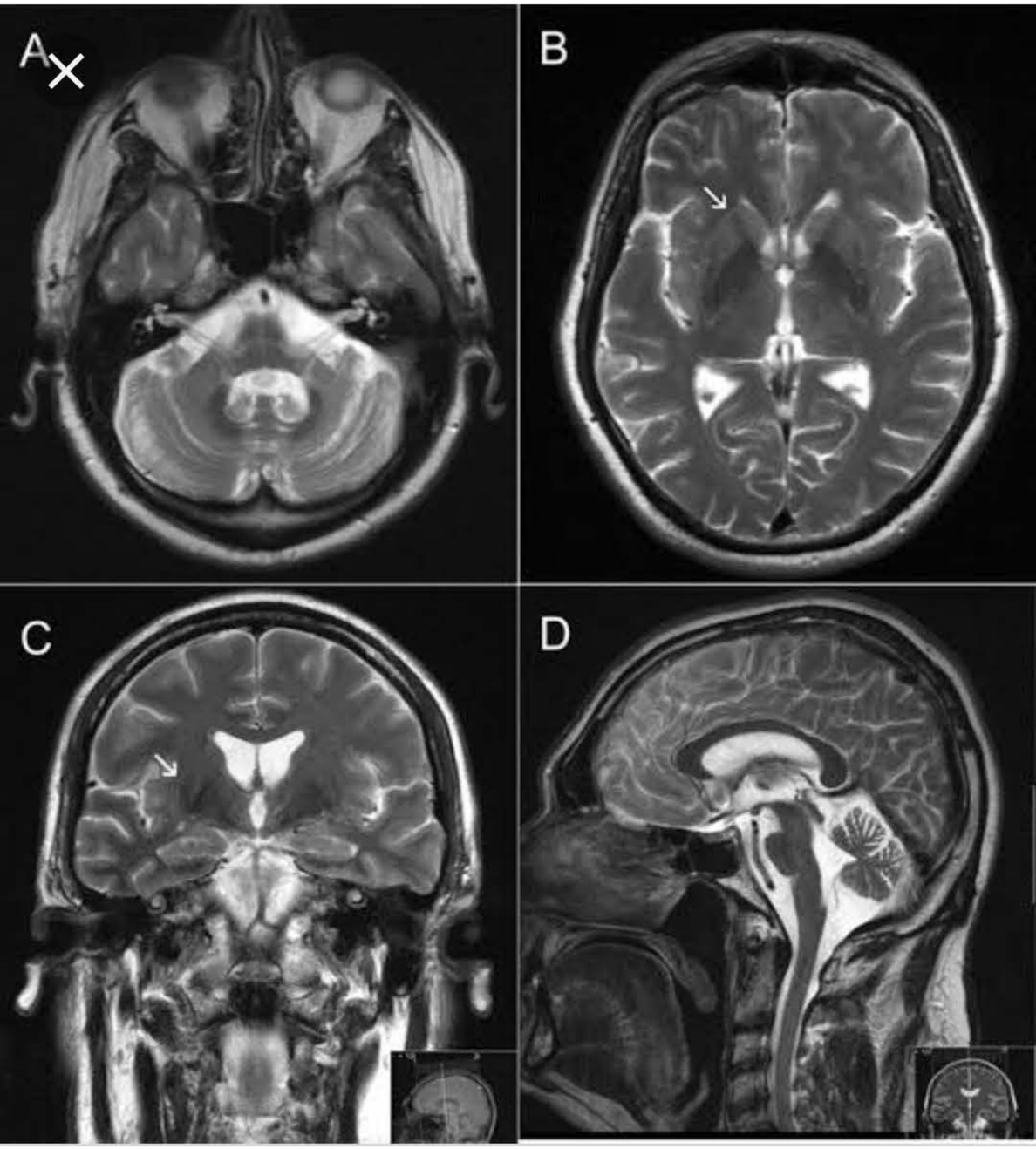

Neurology

Teaching NeuroImage: MRI in multiple system atrophy | Neuro...

Download figure ...

Images may be subject to copyright. Learn More

RELATED IMAGES

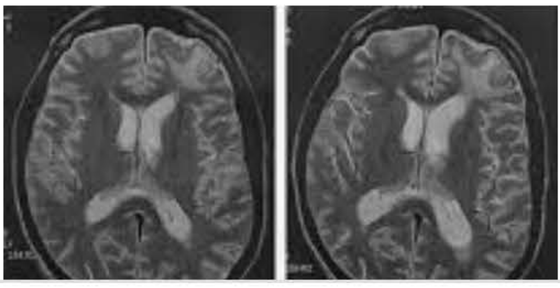

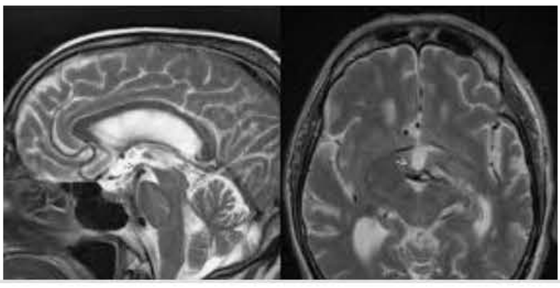

A 32-year-old painter presented with a two-day history of sudden-onset occipital headache associated with nausea and vomiting. The next day his right hand became weak for a few hours. Later that day he had an episode of sensory disturbance in his right upper limb, consisting of tingling in his hand that spread up the arm to his shoulder over the 60 s and lasted 120 s in total. On the day of admission, he had a similar episode of sensory disturbance lasting 30 s in total.

On examination, he had bilateral papilloedema, no neck stiffness and an otherwise normal neurological examination.

What is the most likely diagnosis?

A	Migraine
B	Viral meningitis
C	Cerebral venous sinus thrombosis

his shoulder over the 60 s and lasted 120 s in total. On the day of admission, he had a similar episode of sensory disturbance lasting 30 s in total.

On examination, he had bilateral papilloedema, no neck stiffness and an otherwise normal neurological examination.

What is the most likely diagnosis?

A	Migraine
B	Viral meningitis
C	Cerebral venous sinus thrombosis
D	Multiple transient ischaemic attacks
E	Carotid dissection

6943

Submit

A 32-year-old painter presented with a two-day history of sudden-onset occipital headache associated with nausea and vomiting. The next day his right hand became weak for a few hours. Later that day he had an episode of sensory disturbance in his right upper limb, consisting of tingling in his hand that spread up the arm to his shoulder over the 60 s and lasted 120 s in total. On the day of admission, he had a similar episode of sensory disturbance lasting 30 s in total.

On examination, he had bilateral papilloedema, no neck stiffness and an otherwise normal neurological examination.

What is the most likely diagnosis?

Your answer was incorrect

A	Migraine

C Cerebral venous sinus thrombosis

Cerebral venous sinus thrombosis (CVST) has an annual incidence of 0.22 per 100 000 and is associated with headache (>90% of cases), seizures (focal, with or without secondary generalisation – almost 50%), focal weakness (40%) and papilloedema (40%), all seen in this patient. Risk factors for CVST include genetic or acquired prothrombotic disorders, pregnancy, the oral contraceptive pill, vasculitis, malignancy, dehydration and infection. However, there are multiple other associated factors.

E Carotid dissection

Carotid dissection is associated with amaurosis fugax, partial Horner syndrome and other features such pulsatile tinnitus and change in taste, depending on the extent of any underlying dissecting aneurysm.

A Migraine

Migraine is not usually associated with an occipital headache; presentation with a frontal headache, preceded by an aura and accompanied by nausea and vomiting, would be expected. Papilloedema is not seen.

B Viral meningitis

Papilloedema would be unusual in the context of viral meningitis, and there are no features to suggest acute viral infection.

D Multiple transient ischaemic attacks

Multiple TIAs usually occur in the same territory, are not associated with headaches and we are given no evidence of vascular risk factors here.

6943

Rate this question:

A 28-year-old nurse presents with a 1-month history of progressive gait unsteadiness. She also complains of clumsiness of her hands and numbness and tingling over the right side of her face. Eighteen months ago, she was forced to take time off work because of weakness and stiffness in her legs.

On examination, Ishihara colour-plate testing demonstrated deficits in the left eye. Visual acuity is 6/6 on the right and 6/36 on the left. Testing of eye movements demonstrates nystagmus of the right eye on looking towards the right, with failure of full adduction of the left eye. There is also evidence of bilateral finger nose ataxia and impaired rapid alternating movements of the hands.

What would be the most appropriate initial investigation?

A	Serum ANA and ANCA
B	Lumbar puncture

6:57
tps://mypastest.pastest.com
16

evidence of bilateral finger nose ataxia and impaired rapid alternating movements of the hands.

What would be the most appropriate initial investigation?

A	Serum ANA and ANCA
B	Lumbar puncture
C	MRI brain
D	CT brain
E	Serum and cerebrospinal fluid angiotensin-converting enzyme quantification

32728

Submit

A 28-year-old nurse presents with a 1-month history of progressive gait unsteadiness. She also complains of clumsiness of her hands and numbness and tingling over the right side of her face. Eighteen months ago, she was forced to take time off work because of weakness and stiffness in her legs.

On examination, Ishihara colour-plate testing demonstrated deficits in the left eye. Visual acuity is 6/6 on the right and 6/36 on the left. Testing of eye movements demonstrates nystagmus of the right eye on looking towards the right, with failure of full adduction of the left eye. There is also evidence of bilateral finger nose ataxia and impaired rapid alternating movements of the hands.

What would be the most appropriate initial investigation?

Your answer was incorrect

A	Serum ANA and ANCA

C MRI brain

The clinical scenario is suggestive of multiple sclerosis. Typical manifestations include relapses of paralysis, paraesthesia, optic neuritis and bladder dysfunction. There is evidence of an internuclear opthalmoplegia in this case. The first-line investigation is MRI brain to look for typical demyelinating plaques.

D CT brain

CT is insensitive to white matter demyelinating lesions, so would be an unhelpful test and an inappropriate use of ionising radiation.

A Serum ANA and ANCA

These are tests used in the investigation of lupus and vasculitis. There are no systemic features (e.g. arthralgia, rashes, sino-nasal problems) in this case to suggest those condition

are likely.

B	Lumbar puncture

LP may be performed after MRI scanning if diagnostic doubt remains. However, in a case with typical symptoms, signs and imaging it is often unnecessary.

E	Serum and cerebrospinal fluid angiotensin-converting enzyme quantification

These tests are traditionally associated with the investigation of neurosarcoid (which occasionally mimics MS), but they have low sensitivity and specificity. There are no systemic markers of sarcoid (arthralgia, uveitis, rashes) here in any case.

32728

Rate this question:

Next Question

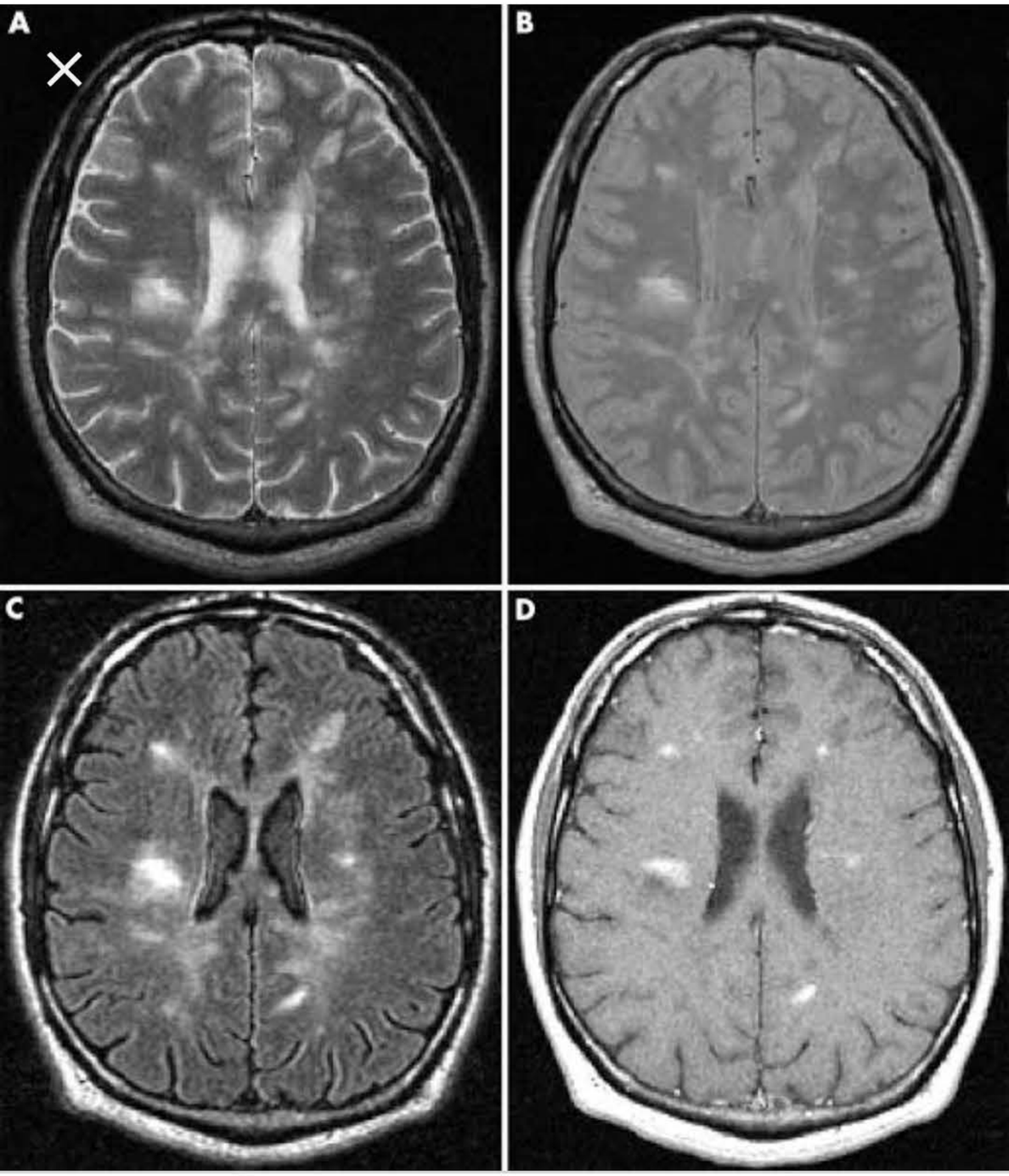

Journal of Neurology, Neur...

Imaging in multiple sclerosis | Journal of Neurology, Neurosur...

T2 and PD weighted imaging

Images may be subject to copyright. Learn More

RELATED IMAGES

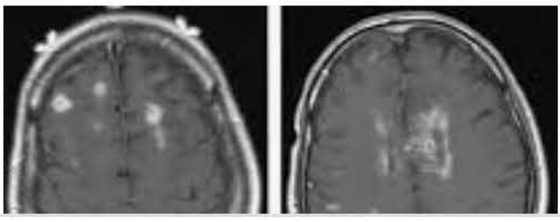

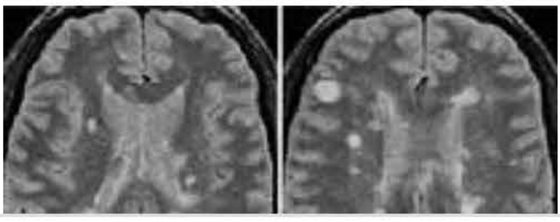

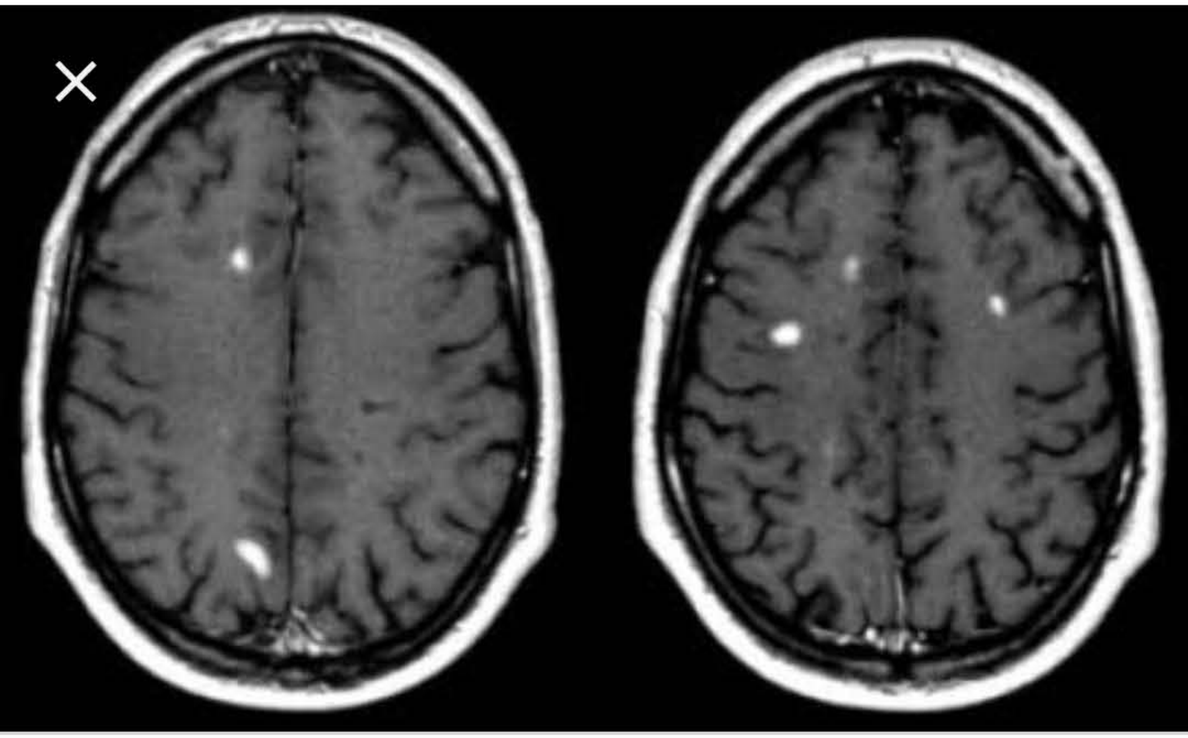

The Radiology Assistant

The Radiology Assistant : Multiple Sclerosis

T1WI: multiple enhancing lesions

Images may be subject to copyright. Learn More

RELATED IMAGES

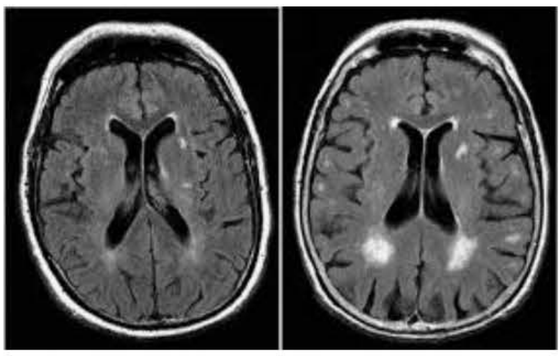

5-Minute Brain MRI Can Reve...
alzheimersnewstoday.com

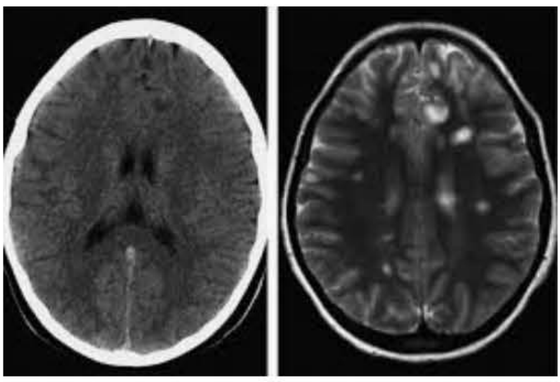

Comparison of CT (left) and ...
researchgate.net

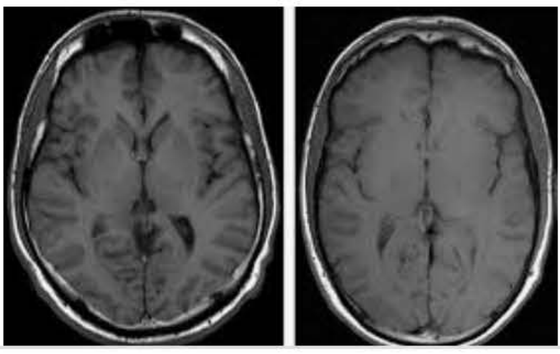

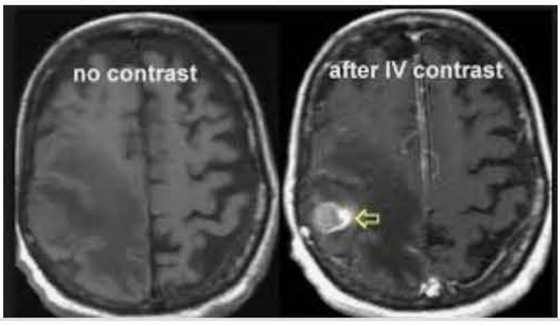

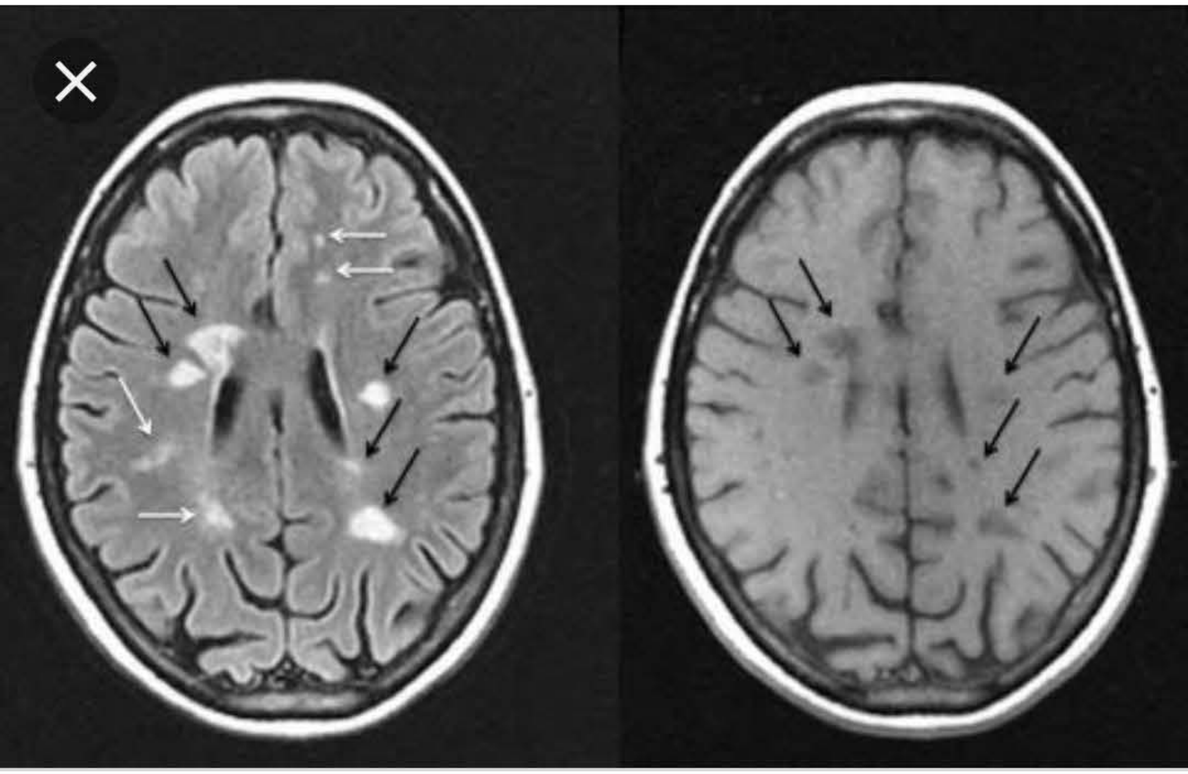

Multiple Sclerosis Discove...

More Than Meets the Eye | Multiple Sclerosis Discovery Fo...

Fig. 1. Bright spots represent lesions on a T2 FLAIR (fluid-attenuated

Images may be subject to copyright. Learn More

RELATED IMAGES

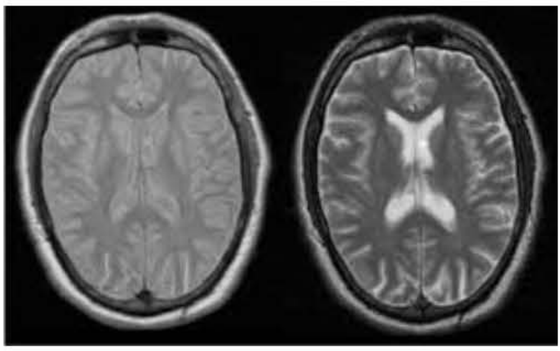

Dual echo FSE - Questions an...
mriquestions.com

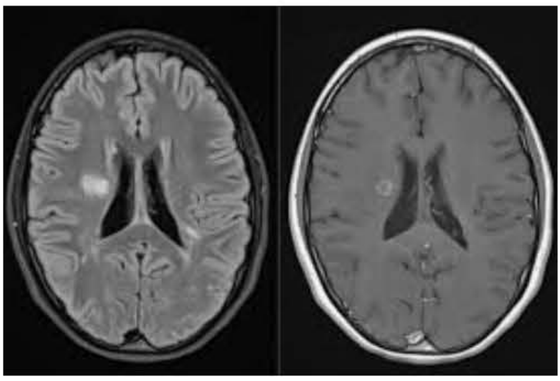

Radiology MRI: Active MS pla...
radiologymri.blogspot.com

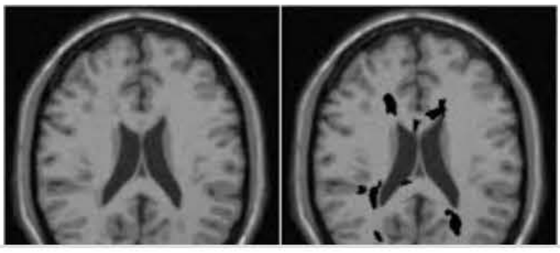

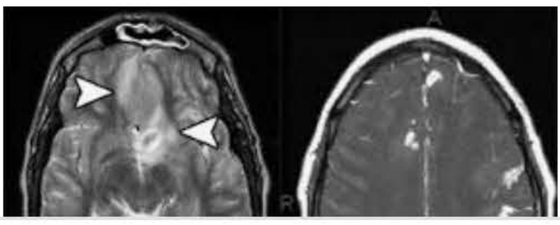

A 66-year-old man presents with lumbar back pain, which started 2 days ago. The pain occurred at rest. Since then, he has noted pain radiating to both legs and progressive difficulty walking. He admits to mild dyspnoea; otherwise, there are no features of note in the systemic inquiry. There is no significant past medical history other than a recent attendance at his general practitioner with loose stool secondary to a *Campylobacter* infection.

On examination, you note a regular resting tachycardia of 110 beats/min. On neurological examination of the lower limbs, he has 3/5 power at the ankles, 4/5 power at the knees and normal power at the hips. You are unable to elicit knee or ankle reflexes with reinforcement; plantars are flexor. Vibration sense is diminished at the toes; otherwise, sensory examination is normal. In the upper limbs, you record 4/5 power at the wrists, 5/5 all other groups. Biceps and supinator reflexes are equal bilaterally; however, you are unable to elicit triceps in either arm.

unable to elicit knee or ankle reflexes with reinforcement; plantars are flexor. Vibration sense is diminished at the toes; otherwise, sensory examination is normal. In the upper limbs, you record 4/5 power at the wrists, 5/5 all other groups. Biceps and supinator reflexes are equal bilaterally; however, you are unable to elicit triceps in either arm.

Which of the following is most closely associated with prognosis with respect to his underlying condition?

A	Pulse rate
B	Blood pressure
C	Urea
D	Abnormal nerve conduction studies
E	Forced vital capacity

A 66-year-old man presents with lumbar back pain, which started 2 days ago. The pain occurred at rest. Since then, he has noted pain radiating to both legs and progressive difficulty walking. He admits to mild dyspnoea; otherwise, there are no features of note in the systemic inquiry. There is no significant past medical history other than a recent attendance at his general practitioner with loose stool secondary to a *Campylobacter* infection.

On examination, you note a regular resting tachycardia of 110 beats/min. On neurological examination of the lower limbs, he has 3/5 power at the ankles, 4/5 power at the knees and normal power at the hips. You are unable to elicit knee or ankle reflexes with reinforcement; plantars are flexor. Vibration sense is diminished at the toes; otherwise, sensory examination is normal. In the upper limbs, you record 4/5 power at the wrists, 5/5 all other groups. Biceps and supinator reflexes are equal bilaterally; however, you are unable to elicit triceps in either arm.

E Forced vital capacity

The original description by Guillain, Barré and Stohl of the constellation of progressive weakness, areflexia and paraesthesia with minimal sensory signs remains helpful today. Other clinical features that support a diagnosis of Guillain–Barré syndrome (GBS) include symmetry of findings: cranial nerve palsies and autonomic dysfunction (note tachycardia). In the majority of cases (70%) there is antecedent infection – lower respiratory tract or gastrointestinal. Back pain radiating to the lower limbs is an extremely common presenting feature of early GBS, and may persist throughout the illness in some cases. The mechanisms of this are incompletely understood but probably relate to proximal nerve root inflammation.

Investigations are used to confirm the clinical diagnosis. Cerebrospinal fluid examination will show raised protein and normal cells, although protein may be normal in the first stages of disease.

and normal cells, although protein may be normal in the first stages of disease. Likewise nerve conduction studies may initially be normal, only later showing a multifocal demyelination picture. The most important aspect of initial management is monitoring of respiratory and autonomic function. The decrease in mortality from GBS has been secondary to better monitoring and early institution of respiratory support. Patients displaying a decrease in forced vital capacity need anaesthetic assessment with a view to elective intubation. Specific therapies for GBS include plasma exchange and intravenous immunoglobulin.

A Pulse rate

Alterations in pulse rate may occur due to autonomic involvement, but there is no correlation between pulse rate and prognosis.

B Blood pressure

An 18-year-old woman is referred by a general practitioner (GP) for neurological evaluation. She was born to first cousins and is part of a traveller family who rarely consult medical services. Their daughter has been hard of hearing for 4–5 years and needs a hearing aid. Over the past 4 months, she has become more and more unsteady and her speech is slurred. She does, however, continue to do well at school.

On examination, both optic discs are pale. Fine nystagmus is seen. Her speech is dysarthric. Intention tremor is present bilaterally. Wasting of distal muscles is seen in both arms and legs, tendon reflexes are absent and plantars are extensor. Romberg's test is positive. Her blood pressure (BP) is 105/60 mmHg with no postural drop.

What is the most likely diagnosis?

A	Friedrich's ataxia
B	Refsum's disease

unsteady and her speech is slurred. She does, however, continue to do well at school.

On examination, both optic discs are pale. Fine nystagmus is seen. Her speech is dysarthric. Intention tremor is present bilaterally. Wasting of distal muscles is seen in both arms and legs, tendon reflexes are absent and plantars are extensor. Romberg's test is positive. Her blood pressure (BP) is 105/60 mmHg with no postural drop.

What is the most likely diagnosis?

A	Friedrich's ataxia
B	Refsum's disease
C	Motor neurone disease
D	Spinal muscular atrophy
E	Multiple sclerosis

An 18-year-old woman is referred by a general practitioner (GP) for neurological evaluation. She was born to first cousins and is part of a traveller family who rarely consult medical services. Their daughter has been hard of hearing for 4–5 years and needs a hearing aid. Over the past 4 months, she has become more and more unsteady and her speech is slurred. She does, however, continue to do well at school.

On examination, both optic discs are pale. Fine nystagmus is seen. Her speech is dysarthric. Intention tremor is present bilaterally. Wasting of distal muscles is seen in both arms and legs, tendon reflexes are absent and plantars are extensor. Romberg's test is positive. Her blood pressure (BP) is 105/60 mmHg with no postural drop.

What is the most likely diagnosis?

Your answer was incorrect

A Friedrich's ataxia

This is an autosomal recessive disease where the patient is deaf but has preserved cognitive function. She has progressive spinocerebellar ataxia and bilateral optic atrophy. Progressive muscular wasting and weakness, with areflexia and loss of vibration sense, is suggestive of peripheral neuropathy, and bilateral extensor plantars indicate pyramidal tract involvement. Sensorineural deafness, dysarthric speech and oculomotor disturbance in the form of jerky pursuit are other neurological signs. Non-neurological associations of Friederich's ataxia include cardiomyopathy, diabetes mellitus, pes cavus, equinovarus deformity and scoliosis. Nerve conduction study reveals either low amplitude or absent sensory nerve action potentials. Motor nerve conduction velocities are usually normal.

B Refsum's disease

B Refsum's disease

Refsum's disease is an autosomal recessive disorder which has its onset in childhood or adolescence, and is associated with ataxia, hearing loss, retinitis pigmentosa and ichthyosis. The ophthalmic examination is not consistent with a diagnosis of Refsum's disease.

C Motor neurone disease

The optic atrophy and hearing loss here are inconsistent with a diagnosis of motor neurone disease.

D Spinal muscular atrophy

Although spinal muscular atrophy does lead to loss of muscle power and reflexes, the hearing loss and optic atrophy seen here are inconsistent with the diagnosis.

E Multiple sclerosis

C Motor neurone disease

The optic atrophy and hearing loss here are inconsistent with a diagnosis of motor neurone disease.

D Spinal muscular atrophy

Although spinal muscular atrophy does lead to loss of muscle power and reflexes, the hearing loss and optic atrophy seen here are inconsistent with the diagnosis.

E Multiple sclerosis

Multiple sclerosis is associated with mixed signs of demyelination rather than the symmetrical muscle weakness and bilateral optic atrophy seen here. The fact the condition has occurred in a traveller family also raises the possibility that it is an inherited condition.

32772

Rate this question:

D	Spinal muscular atrophy

Although spinal muscular atrophy does lead to loss of muscle power and reflexes, the hearing loss and optic atrophy seen here are inconsistent with the diagnosis.

E	Multiple sclerosis

Multiple sclerosis is associated with mixed signs of demyelination rather than the symmetrical muscle weakness and bilateral optic atrophy seen here. The fact the condition has occurred in a traveller family also raises the possibility that it is an inherited condition.

32772

Rate this question:

A 22-year-old man presented with progressive weakness of both legs over the last 3 years. He complained of being unable to see well at night and hearing loss.

On examination, he had a shortened fourth toe bilaterally, with pes cavus. Neurological examination revealed a loss of pinprick sensation to the knee bilaterally, and weakness of both legs more prominent distally. He had restricted visual fields and sensorineural deafness bilaterally.

Which of these blood tests is most likely to lead to the diagnosis?

A	ANCA
B	Phytanic acid
C	Vitamin E
D	Vitamin B_{12}
E	Thyroid function tests

A 22-year-old man presented with progressive weakness of both legs over the last 3 years. He complained of being unable to see well at night and hearing loss.

On examination, he had a shortened fourth toe bilaterally, with pes cavus. Neurological examination revealed a loss of pinprick sensation to the knee bilaterally, and weakness of both legs more prominent distally. He had restricted visual fields and sensorineural deafness bilaterally.

Which of these blood tests is most likely to lead to the diagnosis?

Your answer was correct

A ANCA

B Phytanic acid

C Vitamin E

B Phytanic acid

The diagnosis is Refsum's disease. This is an autosomal recessive disorder that causes a sensorimotor peripheral neuropathy. It is caused by defective alpha oxidation of phytanic acid leading to its accumulation in tissues. Phytanic acid is present in a wide variety of foods including dairy products, fish, beef and lamb. The onset of the disease is normally in the late teens or 20s. Other neurological features include sensorineural deafness, anosmia, cerebellar ataxia and pes cavus. Night blindness and visual problems occur secondary to retinitis pigmentosa. Cardiac conduction abnormalities and cardiomyopathies may also occur. Epiphyseal dysplasia causes a characteristic shortening of the fourth toe. Serum phytanic acid levels are elevated. Treatment is by dietary restriction of foods containing phytanic acid.

A ANCA

A ANCA

ANCA-positive vasculitis can present with neuropathy, although classically this is an acute mononeuritis multiplex. The signs here suggest a much more long-standing and symmetrical disease process.

C Vitamin E

Deficiency of vitamin E can produce a chronic ataxia, but could not explain all of the other features seen in this case.

D Vitamin B_{12}

Deficiency of B_{12} produces a subacute syndrome rather than the chronic illness described here. In B_{12} deficiency, one sees a myeloneuropathy with a combination of upper and lower motor neurone signs due to simultaneous damage to peripheral nerve and selected spinal cord tracts.

C Vitamin E

Deficiency of vitamin E can produce a chronic ataxia, but could not explain all of the other features seen in this case.

D Vitamin B_{12}

Deficiency of B_{12} produces a subacute syndrome rather than the chronic illness described here. In B_{12} deficiency, one sees a myeloneuropathy with a combination of upper and lower motor neurone signs due to simultaneous damage to peripheral nerve and selected spinal cord tracts.

E Thyroid function tests

Whilst one can see a peripheral neuropathy in hypothyroidism, the other features in this case, which clearly suggest a chronic and complex neurological disorder, cannot be explained by thyroid dysfunction alone.

A 48-year-old man has been unwell for about 6 months. The problem seems to be recurrent, with repetitive behaviour on each occasion. His wife accompanies him to the Neurology Clinic to supplement the details of his problem, describing that the symptoms are episodic, where he becomes suddenly confused and starts to smack his lips. He moves about and resists any physical restraint. Within a few minutes he recovers, but remains unaware of the preceding few minutes.

He remembers that as a child he had febrile convulsions. There is no family history of epilepsy.

The neurological examination is normal.

Which of the following is the most likely diagnosis?

A	Conversion reaction
B	Schizophrenia
C	Gelastic seizures

becomes suddenly confused and starts to smack his lips. He moves about and resists any physical restraint. Within a few minutes he recovers, but remains unaware of the preceding few minutes.

He remembers that as a child he had febrile convulsions. There is no family history of epilepsy.

The neurological examination is normal.

Which of the following is the most likely diagnosis?

A	Conversion reaction
B	Schizophrenia
C	Gelastic seizures
D	Catamenial epilepsy
E	Complex partial seizures

A 45 year old man has been unwell for about 6 months. The problem seems to be recurrent, with repetitive behaviour on each occasion. His wife accompanies him to the Neurology Clinic to supplement the details of his problem, describing that the symptoms are episodic, where he becomes suddenly confused and starts to smack his lips. He moves about and resists any physical restraint. Within a few minutes he recovers, but remains unaware of the preceding few minutes.

He remembers that as a child he had febrile convulsions. There is no family history of epilepsy.

The neurological examination is normal.

Which of the following is the most likely diagnosis?

Your answer was correct

A	Conversion reaction
B	Schizophrenia

E Complex partial seizures

Complex partial seizures of temporal lobe origin (temporal lobe epilepsy (TLE), accounting for about 2/3 of all partial epilepsies) arise most commonly from foci in the medial temporal lobe, amygdaloid nucleus and hippocampus. Such seizures may exhibit various features including: (1) aura (which may be a visual hallucination or perceptual illusion, psychic illusion like déja-vu 'increased familiarity' or jamais-vu 'strange unfamiliarity'; (2) a motor component like lip smacking, chewing, etc. or gestural automatisms; or (3) two-thirds of the patients having complex partial seizures are prone to secondarily generalise. The seizure lasts for 2–3 min followed by post-ictal confusion. Electroencephalography (EEG), especially a sleep (stage II) record with extra scalp leads in the anterior frontal and temporal region, may pick up the paroxysmal discharges which may not be seen in the routine record.

Magnetic resonance imaging (MRI) is an important diagnostic tool to detect structural abnormalities such as mesial temporal sclerosis (here the history of febrile convulsions is important), glial scars, porencephalic cyst, tumours and heterotopias, although a careful clinical history is most crucial in making the diagnosis.

A Conversion reaction

A conversion reaction presents with functional symptoms in response to a psychological stressor, for example weakness or paralysis of a limb.

B Schizophrenia

Hallmarks of schizophrenia include loss of insight and primary delusional perceptions, neither of which is suggested by the scenario seen here.

C Gelastic seizures

Gelastic seizures are manifest by

7:38
tps://mypastest.pastest.com
16

Hallmarks of schizophrenia include loss of insight and primary delusional perceptions, neither of which is suggested by the scenario seen here.

C Gelastic seizures

Gelastic seizures are manifest by apparent uncontrolled crying or giggling, neither of which is seen here. These are typically related to a hypothalamic hamartoma.

D Catamenial epilepsy

Catamenial is used to describe epilepsy in women where seizures occur more frequently at certain points in the menstrual cycle.

32750

Rate this question:

Next Question

A 16-year-old female with no past medical history attends the Neurology Outpatients. She is accompanied by her mother who relates most of the history. Over the last few months, she has noticed episodic arm jerking. This seems to occur most often in the morning, and her mother believes attacks worsen when she has been to a nightclub the previous evening. Her school work is suffering as she has frequent 'blank spells' both in the classroom and at home.

An emergency clinic appointment was requested after she had a 'turn' in class. You contact the school nurse who witnessed the attack. She helpfully describes the girl letting out a cry and falling to the ground. She then appeared to go blue and demonstrated rhythmic shaking of arms and legs for a few seconds. This lasted less than a minute. The patient remembers little of the attack but remembers feeling sleepy and nauseated for most of the morning. She has been flagged at risk because of her behaviour, to Social Services.

arms and legs for a few seconds. This lasted less than a minute. The patient remembers little of the attack but remembers feeling sleepy and nauseated for most of the morning. She has been flagged at risk because of her behaviour, to Social Services.

Which of the following is the optimal management of this patient?

A	Urinary toxicology screen
B	Oral phenytoin
C	Referral to adolescent psychiatry services
D	Oral Lamotrigine
E	Oral carbamazepine

A 16-year-old female with no past medical history attends the Neurology Outpatients. She is accompanied by her mother who relates most of the history. Over the last few months, she has noticed episodic arm jerking. This seems to occur most often in the morning, and her mother believes attacks worsen when she has been to a nightclub the previous evening. Her school work is suffering as she has frequent 'blank spells' both in the classroom and at home.

An emergency clinic appointment was requested after she had a 'turn' in class. You contact the school nurse who witnessed the attack. She helpfully describes the girl letting out a cry and falling to the ground. She then appeared to go blue and demonstrated rhythmic shaking of arms and legs for a few seconds. This lasted less than a minute. The patient remembers little of the attack but remembers feeling sleepy and nauseated for most of the morning.

D Oral Lamotrigine

The history of teenage-onset morning myoclonus, absence seizures and generalised tonic-clonic seizures are consistent with a diagnosis of juvenile myoclonic epilepsy (JME). Sleep deprivation and alcohol are common causes of lowered seizure threshold in patients with idiopathic generalised epilepsy.

The traditional treatment is Sodium valproate, with an 80% response rate. JME is a life-long disorder and the majority of patients require continued drug treatment for years, even after prolonged remission of seizures. The Medicines and Healthcare Products Regulatory Agency (MHRA) recently advised that Sodium valproate should not be used in post-pubertal girls. This is because of its teratogenic risks - serious developmental disorders (in up to 30-40% of cases) and/or congenital malformations (in approximately 10% of cases). If it is used, a shared-risk approach should be taken with the patient, with particular attention to

approach should be taken with the patient, with particular attention to contraception and family planning. Lamotrigine or Levetiracetam are becoming increasingly popular and are effective in JME. They do not convey the same risks in pregnancy and therefore would be a preferred option in young females.

C	Referral to adolescent psychiatry services

This patient does not demonstrate any psychiatric morbidity.

A	Urinary toxicology screen

Intoxication should be considered in a patient presenting acutely with generalised seizures, but it is unlikely to be relevant in a patient with multiple seizure types over this time period.

B	Oral phenytoin

This can exacerbate myoclonus and

A 72-year-old woman is brought to the Emergency Department by ambulance. She was found by her home help not moving in the bed, and she does not move or respond to questions on admission to the hospital. There is a history of hypertension for the past 10 years, currently managed with ramipril and amlodipine, and she has had three previous emergency attendances over the past 5 months for unexplained collapses.

On examination, her BP is 185/100 mmHg, and she does not move her arms or legs to commands, although appears to be able to blink to commands. Plantar responses are extensor.

Which of the following is the most likely site for the vascular lesion?

A	Distal basilar artery
B	Left carotid artery
C	Right carotid artery

and amlodipine, and she has had three previous emergency attendances over the past 5 months for unexplained collapses.

On examination, her BP is 185/100 mmHg, and she does not move her arms or legs to commands, although appears to be able to blink to commands. Plantar responses are extensor.

Which of the following is the most likely site for the vascular lesion?

A	Distal basilar artery
B	Left carotid artery
C	Right carotid artery
D	Proximal and middle basilar artery segments
E	Middle and distal basilar artery segments

A 72 year old woman is brought to the Emergency Department by ambulance. She was found by her home help not moving in the bed, and she does not move or respond to questions on admission to the hospital. There is a history of hypertension for the past 10 years, currently managed with ramipril and amlodipine, and she has had three previous emergency attendances over the past 5 months for unexplained collapses.

On examination, her BP is 185/100 mmHg, and she does not move her arms or legs to commands, although appears to be able to blink to commands. Plantar responses are extensor.

Which of the following is the most likely site for the vascular lesion?

Your answer was incorrect

A	Distal basilar artery

D Proximal and middle basilar artery segments

This woman has locked-in syndrome, a condition usually precipitated by infarction of the proximal and middle basilar artery segments. Changes in conscious level are associated with more distal basilar artery involvement. Many patients have stuttering symptoms consistent with multiple transient ischaemic attacks (TIAs) over the weeks and months before a major stroke. Given the possibility that brainstem ischaemia may be associated with bulbar palsy, assessment of airway protection is a crucial part of early management of this patient population. Unfortunately, patients who suffer basilar artery infarction suffer a mortality rate of around 85%; in patients who are treated with thrombolysis, case series do indicate, however, that as many as 35% achieve a reasonable functional outcome.

E Middle and distal basilar

E Middle and distal basilar artery segments

More distal occlusion of the basilar artery is not usually associated with motor symptoms such as those seen here.

A Distal basilar artery

The terminal branch of the basilar artery is the posterior cerebral artery. Distal occlusion of the artery results in visual and oculomotor defects, behavioural dysfunction and dream-like behaviour. Motor defects are often absent.

B Left carotid artery

Left carotid artery occlusion is associated with right-sided face and limb weakness, and speech disturbance.

C Right carotid artery

A 69-year-old woman is referred to the Neurology Clinic. She describes a few days of facial pain against a background of lethargy, weight loss and early morning stiffness. The pain is especially marked around the temporal region. She feels that she can see less well with the right eye. She finds the pain worsens after prolonged speaking and whilst eating, and it is interfering with her job as a part-time lecturer. She also tells you that her hips and shoulders are stiff.

On examination, you note a relative afferent papillary defect on the right with reduced acuity. Ocular movements are normal. The remainder of neurological examination including the other cranial nerves is unremarkable. You note no rashes, no nodules and no active synovitis. Her BP is slightly elevated at 155/72 mmHg.

Which of the following is the priority with respect to treatment?

A	Ramipril

She also tells you that her hips and shoulders are stiff.

On examination, you note a relative afferent papillary defect on the right with reduced acuity. Ocular movements are normal. The remainder of neurological examination including the other cranial nerves is unremarkable. You note no rashes, no nodules and no active synovitis. Her BP is slightly elevated at 155/72 mmHg.

Which of the following is the priority with respect to treatment?

A	Ramipril
B	Intravenous heparin
C	High-dose oral corticosteroids
D	Intravenous aciclovir
E	Aspirin and dipyridamole

A 69-year-old woman is referred to the Neurology Clinic. She describes a few days of facial pain against a background of lethargy, weight loss and early morning stiffness. The pain is especially marked around the temporal region. She feels that she can see less well with the right eye. She finds the pain worsens after prolonged speaking and whilst eating, and it is interfering with her job as a part-time lecturer. She also tells you that her hips and shoulders are stiff.

On examination, you note a relative afferent papillary defect on the right with reduced acuity. Ocular movements are normal. The remainder of neurological examination including the other cranial nerves is unremarkable. You note no rashes, no nodules and no active synovitis. Her BP is slightly elevated at 155/72 mmHg.

Which of the following is the priority with respect to treatment?

Your answer was correct

C High-dose oral corticosteroids

The subacute temporal facial pain, facial claudication symptoms and constitutional symptoms raise the possibility of giant cell arteritis. The examination findings suggest early visual loss. This is a neurological emergency and treatment with high-dose steroid must be instituted to preserve sight. Definitive diagnosis requires temporal artery biopsy, but the above features combined with elevated inflammatory markers (C-reactive protein and/or erythrocyte sedimentation rate) are enough to warrant empirical treatment. The response to treatment *per se* is a pointer towards the underlying diagnosis. Note, a negative biopsy does not exclude the diagnosis because of the focal nature of the disease. Patients should respond to steroids within 24–48 h and ongoing symptoms should alert the clinician to other possible diagnosis. Treatment is usually continued for at least 1 year, using C-reactive protein or erythrocyte

using C-reactive protein or erythrocyte sedimentation rate (ESR) to monitor disease activity, and tapering steroid as appropriate.

A Ramipril

The features suggest giant cell arteritis and urgent steroid therapy is required. She has mild systolic hypertension, but that is not the priority.

B Intravenous heparin

In giant cell arteritis there is no evidence for anticoagulation.

D Intravenous aciclovir

There are no features to suggest serious herpes virus infection of the nervous system, so this drug is not warranted.

E Aspirin and dipyridamole

A 39-year-old man presented with a 2-day history of nausea and abdominal pain and a 1-day history of double vision and difficulty keeping his eyes open.

Neurological examination revealed a bilateral ptosis, dilated unreactive pupils, complete ophthalmoplegia and bilateral facial weakness. The rest of the neurological examination was normal including sensory testing.

He is apyrexial and there is no postural drop on moving from a lying to a sitting position, his BP is 110/70 mmHg with a pulse of 75 bpm.

Which test would you perform to support the diagnosis?

A	Serum acetylcholine receptor antibodies
B	Abdominal ultrasound
C	Serum anti-GQ1b antibodies

bilateral ptosis, dilated unreactive pupils, complete ophthalmoplegia and bilateral facial weakness. The rest of the neurological examination was normal including sensory testing.

He is apyrexial and there is no postural drop on moving from a lying to a sitting position, his BP is 110/70 mmHg with a pulse of 75 bpm.

Which test would you perform to support the diagnosis?

A	Serum acetylcholine receptor antibodies
B	Abdominal ultrasound
C	Serum anti-GQ1b antibodies
D	Serum bacterial toxin testing
E	Serum creatine kinase

A 39-year-old man presented with a 2-day history of nausea and abdominal pain and a 1-day history of double vision and difficulty keeping his eyes open.

Neurological examination revealed a bilateral ptosis, dilated unreactive pupils, complete ophthalmoplegia and bilateral facial weakness. The rest of the neurological examination was normal including sensory testing.

He is apyrexial and there is no postural drop on moving from a lying to a sitting position, his BP is 110/70 mmHg with a pulse of 75 bpm.

Which test would you perform to support the diagnosis?

Your answer was incorrect

A	Serum acetylcholine receptor antibodies
B	Abdominal ultrasound

D Serum bacterial toxin testing

The diagnosis is food-borne botulism, which is caused by the anaerobic Gram-positive rod *Clostridium botulinum*. Presynaptic neuromuscular junction pathology on electromyogram (EMG) and testing for botulinum toxin in serum can support the diagnosis, although the diagnosis is essentially made on history and examination. It occurs following ingestion of preformed neurotoxin from bacteria that have contaminated poorly processed food. The incubation period between ingestion of the toxin and onset of symptoms is commonly of the order of 12–48 h. In over half the cases of food-borne botulism there is an initial period of nausea, vomiting and/or abdominal pain and cramps. Botulism classically causes a descending flaccid paralysis, with the early symptoms of ocular and bulbar weakness being followed by upper and then lower limb weakness. In some cases involvement of the diaphragm and intercostal muscles causes

and intercostal muscles causes respiratory problems. Reflexes remain intact and sensation is normal. Dilated, unreactive (or sluggishly reactive) pupils are commonly seen. Other signs and symptoms of autonomic dysfunction include dry mouth, postural hypotension, constipation and urinary retention. Treatment is mainly supportive, particularly monitoring of respiration. Patients occasionally need elective intubation and ventilation within an intensive care setting. Polyvalent botulinum antitoxin can be given.

C	Serum anti-GQ1b antibodies

This test is useful in Miller-Fisher syndrome, a subtype of GBS characterised by ophthalmoplegia and sensory ataxia. The prominent weakness seen in this case make it a less likely diagnosis.

A	Serum acetylcholine receptor antibodies

A 26-year-old woman with known epilepsy is seen in the Outpatient Clinic. She has been taking carbamazepine as her only anti-epileptic medication for the last three years and has had no seizures for the last year on her current dose. She is keen to start the oral contraceptive pill and comes to you for advice.

What is the best management for her?

A	Start the progesterone-only contraceptive pill
B	Start the combined oral contraceptive pill at a lower dose than normal
C	Start the combined oral contraceptive pill and change her anti-epileptic medication to lamotrigine
D	Start the combined oral contraceptive pill with a preparation containing at

What is the best management for her?

A	Start the progesterone-only contraceptive pill
B	Start the combined oral contraceptive pill at a lower dose than normal
C	Start the combined oral contraceptive pill and change her anti-epileptic medication to lamotrigine
D	Start the combined oral contraceptive pill with a preparation containing at least 50 μg of ethinyloestradiol
E	Start the combined oral contraceptive pill and change her anti-epileptic medication to sodium valproate

8:05
:tps://mypastest.pastest.com
16

A 26-year-old woman with known epilepsy is seen in the Outpatient Clinic. She has been taking carbamazepine as her only anti-epileptic medication for the last three years and has had no seizures for the last year on her current dose. She is keen to start the oral contraceptive pill and comes to you for advice.

What is the best management for her?

Your answer was incorrect

A	Start the progesterone-only contraceptive pill
B	Start the combined oral contraceptive pill at a lower dose than normal
C	Start the combined oral

D Start the combined oral contraceptive pill with a preparation containing at least 50 µg of ethinyloestradiol

The effectiveness of the combined oral contraceptive and the progestogen-only contraceptive may be reduced by interaction with carbamazepine and other drugs that induce liver enzyme activity. Advice is therefore to take a preparation containing at least 50 µg of ethinyloestradiol.

C Start the combined oral contraceptive pill and change her anti-epileptic medication to lamotrigine

Although lamotrigine is considered to have an acceptable safety profile in pregnancy, and no interaction with the OCP, given her epilepsy is stable on carbamazepine it's currently unwise to switch therapy.

The progesterone-only contraceptive is less effective than the combined preparation, particularly in patients who are taking enzyme-inducing agents.

B	Start the combined oral contraceptive pill at a lower dose than normal

In the presence of an enzyme inducer such as carbamazepine, higher doses of the combined oral contraceptive pill are required.

E	Start the combined oral contraceptive pill and change her anti-epileptic medication to sodium valproate

Sodium valproate carries risks of teratogenicity in pregnancy and is to be avoided as far as possible in women of child-bearing age. In any case, a switch of treatment is unwise given that her epilepsy is stable on carbamazepine alone.

A 22-year-old woman presented with progressive dysarthria, ataxia and horizontal nystagmus.

On examination, she had upper limb muscle wasting, especially of the small muscles of the hand. Lower limb deep tendon reflexes were absent. She had bilateral extensor plantars and loss of joint position and vibration sense.

What is the most likely diagnosis?

A	Friedrich's ataxia (FA)
B	Chiari I malformation
C	Multiple sclerosis
D	Subacute combined degeneration of spinal cord
E	Motor neurone disease

A 22-year-old woman presented with progressive dysarthria, ataxia and horizontal nystagmus.

On examination, she had upper limb muscle wasting, especially of the small muscles of the hand. Lower limb deep tendon reflexes were absent. She had bilateral extensor plantars and loss of joint position and vibration sense.

What is the most likely diagnosis?

Your answer was correct

A	Friedrich's ataxia (FA)
B	Chiari I malformation
C	Multiple sclerosis
D	Subacute combined degeneration of spinal cord
E	Motor neurone disease

A Friedrich's ataxia (FA)

FA is characterised by progressive limb and gait ataxia before the age of 25 years, and absent lower limb deep tendon reflexes. FA has an equal sex incidence. The genetic mutation responsible is a GAA trinucleotide repeat expansion in the FXN gene on chromosome 9. Diagnostic evaluation involves documentation of an axonal sensory neuropathy. A magnetic resonance imaging (MRI) scan shows shrinkage of the cervical spinal cord. An electrocardiogram (ECG) shows widespread T-wave inversion and LVH (left ventricular hypertrophy) in around 65% of patients.

B Chiari I malformation

Chiari I malformations are often identified incidentally and are asymptomatic. In symptomatic cases, the patient may complain of headaches, particularly induced by coughing or sneezing. Chiari I malformations are also associated with

such cases, upper limb weakness and a suspended sensory loss to pinprick and temperature can occur, with spasticity and hyper-reflexia in the lower limbs.

C	Multiple sclerosis

The prominent muscle wasting seen in this case would be very unusual for MS, which is a disease purely of the central (not peripheral) nervous system.

D	Subacute combined degeneration of spinal cord

Degeneration of the lateral or posterior aspect of the spinal cord may cause the weakness and sensory findings described in this case. However, the described brainstem signs (dysarthria and nystagmus) are not a feature of subacute combined degeneration of the cord.

E	Motor neurone disease

aspect of the spinal cord may cause the weakness and sensory findings described in this case. However, the described brainstem signs (dysarthria and nystagmus) are not a feature of subacute combined degeneration of the cord.

E	Motor neurone disease

Motor neurone disease does not affect the sensory aspects of the nervous system and is therefore not the correct answer.

6530

Rate this question:

Next Question

Previous Question | Tag Question

Feedback | End Session

Difficulty: Average

Peer Responses %

An 18-year-old man was brought in by his mother to the Accident and Emergency Department as he had become aggressive and difficult to manage, both at school and home, for the past year. He had an annoying habit of touching other people and he would episodically sniff, snort and shout obscenities without provocation.

On examination, he repeatedly shrugged his right shoulder and had involuntary grunts. Otherwise, the neurological examination was unremarkable. There were no significant findings on general physical examination, including a normal pulse of 74 bpm and blood pressure of 110/70 mmHg.

What is the most likely diagnosis?

A	Huntington's disease
B	Cerebral palsy
C	Dentato-rubro-pallido-luysian atrophy

On examination, he repeatedly shrugged his right shoulder and had involuntary grunts. Otherwise, the neurological examination was unremarkable. There were no significant findings on general physical examination, including a normal pulse of 74 bpm and blood pressure of 110/70 mmHg.

What is the most likely diagnosis?

A	Huntington's disease
B	Cerebral palsy
C	Dentato-rubro-pallido-luysian atrophy
D	Tourette syndrome
E	Munchausen syndrome

32761

Submit

An 18-year-old man was brought in by his mother to the Accident and Emergency Department as he had become aggressive and difficult to manage, both at school and home, for the past year. He had an annoying habit of touching other people and he would episodically sniff, snort and shout obscenities without provocation.

On examination, he repeatedly shrugged his right shoulder and had involuntary grunts. Otherwise, the neurological examination was unremarkable. There were no significant findings on general physical examination, including a normal pulse of 74 bpm and blood pressure of 110/70 mmHg.

What is the most likely diagnosis?

Your answer was correct

D Tourette syndrome

Gilles de la Tourette syndrome presents with multiple tics, including sniffing, snorting and involuntary vocalisations. Some patients display repetitive and annoying motor behaviour. An attention deficit–hyperactivity disorder and obsessive–compulsive traits are associated at some point of time in the course of the illness. Intelligence does not deteriorate. Dopamine (particularly D2)-receptor blockers such as haloperidol are an effective treatment, supporting the concept of dopaminergic abnormality in the basal ganglia – more so in the caudate nucleus. Streptococcal infection has been implicated in the genesis of abruptly appearing Tourette syndrome and associated obsessive–compulsive behaviour, although the link is far from categorical.

A Huntington's disease

Huntington's disease is an autosomal dominant disorder which presents with progressive dementia accompanied by choreo-athetoid movements and permanently disordered speech, rather than the intermittent disruption seen here.

B	Cerebral palsy

Cerebral palsy occurs due to a period of hypoxia at birth. Bearing in mind symptoms began only 1 year ago, this is inconsistent with the clinical picture.

C	Dentato-rubro-pallido-luysian atrophy

This is an autosomal dominant spino-cerebellar degeneration, and is characterised by ataxia, choreo-athetosis and dementia, which doesn't fit with the clinical picture seen here.

E	Munchausen syndrome

Munchausen is characterised by

Cerebral palsy occurs due to a period of hypoxia at birth. Bearing in mind symptoms began only 1 year ago, this is inconsistent with the clinical picture.

C	Dentato-rubro-pallido-luysian atrophy

This is an autosomal dominant spino-cerebellar degeneration, and is characterised by ataxia, choreo-athetosis and dementia, which doesn't fit with the clinical picture seen here.

E	Munchausen syndrome

Munchausen is characterised by deliberate generation of symptoms of a physical illness; the involuntary nature of the tics and vocalisations seen here doesn't fit with Munchausen.

32761

Rate this question:

Next Question

You are called to the vascular ward during the evening to assess a 68-year-old diabetic, who had undergone balloon angioplasty to his right leg that morning. Post-procedure recovery was uneventful although he had required sedation for anxiety. He awoke with right-sided weakness and language difficulty. From past medical history you note poorly controlled diabetes and hyperlipidaemia.

On examination, his blood pressure is 158/95 mmHg and he is in sinus rhythm with a Glasgow coma scale of 14/15. A bedside glucose test is 9.5 mmol/l. He has a dense right hemiparesis, homonymous hemianopia and expressive dysphasia. Initial computerised tomography (CT) scan has been performed and is unremarkable. He has been given 300 mg of aspirin. Ward staff tell you that it was 16.20 when he awoke; it is now 18.35.

What is the optimal management of this patient?

mmol/l. He has a dense right hemiparesis, homonymous hemianopia and expressive dysphasia. Initial computerised tomography (CT) scan has been performed and is unremarkable. He has been given 300 mg of aspirin. Ward staff tell you that it was 16.20 when he awoke; it is now 18.35.

What is the optimal management of this patient?

A	Admit to the acute stroke unit
B	Thrombolysis with intravenous tissue plasminogen activator
C	Intravenous labetalol
D	Insulin 'sliding scale' therapy
E	Thrombolysis with intravenous streptokinase

You are called to the vascular ward during the evening to assess a 68-year-old diabetic, who had undergone balloon angioplasty to his right leg that morning. Post-procedure recovery was uneventful although he had required sedation for anxiety. He awoke with right-sided weakness and language difficulty. From past medical history you note poorly controlled diabetes and hyperlipidaemia.

On examination, his blood pressure is 158/95 mmHg and he is in sinus rhythm with a Glasgow coma scale of 14/15. A bedside glucose test is 9.5 mmol/l. He has a dense right hemiparesis, homonymous hemianopia and expressive dysphasia. Initial computerised tomography (CT) scan has been performed and is unremarkable. He has been given 300 mg of aspirin. Ward staff tell you that it was 16.20 when he awoke; it is now 18.35.

What is the optimal management of this patient?

A Admit to the acute stroke unit

The clinical picture is consistent with a dominant middle cerebral artery infarct. Evidence-based strategies for infarct in the acute stage include aspirin, admission to a dedicated stroke unit and, if eligible, thrombolysis. Thrombolysis has been proven to reduce disability in non-haemorrhagic infarcts when given within 3 h of symptom onset, and guidelines support thrombolysis for some patients out to a 4.5 h limit. Important contraindications include recent trauma; hypertension (systolic pressure over 180 mmHg); and active bleeding. His recent angioplasty would not exclude him from therapy. However, as he awoke with symptoms there is no certainty over the time of stroke onset and as such, thrombolysis cannot be advised. It has been shown that patients who suffer a stroke on a non-medical ward and are subsequently managed in that ward have poor outcomes.

C Intravenous labetalol

This is an effective treatment for acute blood pressure control, but there is no clear indication for that in this patient. **NICE guidance** on acute stroke care suggests lowering blood pressure only if there is hypertensive emergency (or if BP is >185/110 and thrombolysis is being considered).

B Thrombolysis with intravenous tissue plasminogen activator

The precise time of onset of his stroke is not known.

D Insulin 'sliding scale' therapy

NICE guidelines suggest maintaining blood glucose between 4-11 mmol/l.

E Thrombolysis with intravenous streptokinase

A 31-year-old woman presents to the Neurology Outpatient Clinic. She has a history of primary generalised epilepsy with tonic-clonic seizures managed with lamotrigone 100 mg BD.

She attends because she is 8 weeks pregnant. The pregnancy is planned and she has been taking 5 mg folic acid per day. She has not suffered any seizures since becoming pregnant.

On examination, she looks well. Her BP is 100/70 mmHg and her pulse is 75 bpm.

Investigations:

Hb	12.3 g/dl
WCC	5.6×10^9/l
PLT	187×10^9/l
Na^+	138 mmol/l
K^+	4.3 mmol/l
Creatinine	88 μmol/l

Which of the following is the most appropriate advice?

Na^+	138 mmol/l
K^+	4.3 mmol/l
Creatinine	88 μmol/l

Which of the following is the most appropriate advice?

A She should undergo a termination

B She should immediately stop the lamotrigine

C She should increase her folate supplementation to 10 mg

D She should continue her lamotrigine and folic acid and initiate prenatal monitoring

E She should swap her lamotrigine for topiramate

A 31-year-old woman presents to the Neurology Outpatient Clinic. She has a history of primary generalised epilepsy with tonic-clonic seizures managed with lamotrigone 100 mg BD.

She attends because she is 8 weeks pregnant. The pregnancy is planned and she has been taking 5 mg folic acid per day. She has not suffered any seizures since becoming pregnant.

On examination, she looks well. Her BP is 100/70 mmHg and her pulse is 75 bpm.

Investigations:

Hb	12.3 g/dl
WCC	5.6×10^9/l
PLT	187×10^9/l
Na^+	138 mmol/l
K^+	4.3 mmol/l
Creatinine	88 μmol/l

Which of the following is the most appropriate advice?

D She should continue her lamotrigine and folic acid and initiate prenatal monitoring

She will require enhanced levels of prenatal care and should be seen regularly by her neurologist. Some practitioners advocate monitoring lamotrigine levels in pregnancy, as these may fall in the second and third trimesters. There is, however, little evidence to support this.

A She should undergo a termination

There is no guidance to suggest this is appropriate. Lamotrigine does of course pose a small risk to the pregnancy, but this was a planned event and such risks will have been explained to her.

B She should immediately stop the lamotrigine

Abruptly stopping anti-epileptics

B She should immediately stop the lamotrigine

Abruptly stopping anti-epileptics should always be avoided, especially in pregnancy. The risk of developing seizures and the harm associated with this could be detrimental to both mother and foetus.

C She should increase her folate supplementation to 10 mg

Five milligrams of folic acid is the advised dose and therefore there is no reason or indication to increase this further.

E She should swap her lamotrigine for topiramate

Once established on an effective anti-epileptic it is not recommended to switch between agents once pregnant. Topirimate also poses a risk during pregnancy and may be less effective in controlling her seizures.

A 54-year-old woman comes to the clinic complaining of arm and leg weakness that has been present for at least 6 months. She says that the condition waxes and wanes a little, and that some weeks are worse than others, but she is now having problems even getting up out of a chair or climbing the stairs.

On examination, she has proximal upper and lower limb weakness. Tone is decreased, as are bilateral tendon reflexes. There are no specific sensory defects identified.

Investigations:

Hb	12.3 g/dl
WCC	4.1×10^9/l
PLT	193×10^9/l
Na^+	139 mmol/l
K^+	4.3 mmol/l
Creatinine	104 μmol/l
CT head	Unremarkable

MRI spine with gadolinium	Nerve root enhancement

CSF analysis:

Cells	Mild lymphocytic pleocytosis
Protein	1.8 g.dl

Which of the following is the most likely diagnosis?

A	Multiple sclerosis (MS)
B	Chronic inflammatory demyelinating polyradiculopathy (CIDP)
C	Acute inflammatory demyelinating polyradiculopathy (AIDP)
D	Syringomyelia
E	Dermatomyositis

clinic complaining of arm and leg weakness that has been present for at least 6 months. She says that the condition waxes and wanes a little, and that some weeks are worse than others, but she is now having problems even getting up out of a chair or climbing the stairs.

On examination, she has proximal upper and lower limb weakness. Tone is decreased, as are bilateral tendon reflexes. There are no specific sensory defects identified.

Investigations:

Hb	12.3 g/dl
WCC	4.1×10^9/l
PLT	193×10^9/l
Na^+	139 mmol/l
K^+	4.3 mmol/l
Creatinine	104 μmol/l
CT head	Unremarkable
MRI spine with gadolinium	Nerve root enhancement

B Chronic inflammatory demyelinating polyradiculopathy (CIDP)

CIDP usually follows a relapsing and remitting or slowly progressive course, and is characterised by a non-length-dependent pattern of weakness with a variable degree of sensory impairment (from very mild distal paraesthesia to severe sensory ataxia. There is usually raised CSF protein, and nerve root enhancement on gadolinium MRI scanning may be seen. Supportive physiotherapy and occupational therapy is essential. Medical therapy consists of immunomodulatory treatments including corticosteroids and azathioprine. Immunoglobulins and/or plasma exchange can also be considered. Neuropathic pain may be treated with agents such as gabapentin and amitriptyline.

A Multiple sclerosis (MS)

MS is associated with upper motor

neurone signs rather than the lower motor neurone picture seen here.

C	Acute inflammatory demyelinating polyradiculopathy (AIDP)

AIDP (also known as Guillain–Barré syndrome) presents with progressive, subacute areflexic weakness and mild sensory deficit, which progresses to reach maximum weakness over a period of around 4 weeks. Weakness usually begins distally.

D	Syringomyelia

Syringomyelia is associated with upper motor neurone weakness affecting the lower limbs; sensory loss occurs in a shawl-like distribution over the shoulders and upper arms.

E	Dermatomyositis

Dermatomyositis is associated with painful proximal myopathy, a

A 32-year-old man is admitted from the Emergency Department after suffering a collapse with severe headache while chasing a man who had stolen alcohol from his shop. He has no other past medical history of note, although you understand his father and an aunt died at a young age of strokes.

On examination, he has a blood pressure (BP) of 185/105 mmHg and retinal changes consistent with hypertensive retinopathy.

Investigations:

Haemoglobin (Hb)	12.3 g/dl
White cell count (WCC)	4.9×10^9/l
Platelets (PLT)	202×10^9/l
Sodium (Na^+)	138 mmol/l
Potassium (K^+)	4.3 mmol/l

Creatinine (Cr)	110 μmol/l
Abdominal ultrasound scan	Right adrenal mass, multiple bilateral renal cysts
Computed tomography (CT) brain	Evidence of possible cerebellar mass, no evidence of intracerebral haemorrhage
Urine dipstick	Protein +, blood +

Which of the following is the most appropriate next investigation?

A	Adrenal biopsy
B	24-h urinary catecholamine
C	24-h urinary 5-hydroxyindoleacetic acid (5-HIAA)

Computed tomography (CT) brain	Evidence of possible cerebellar mass, no evidence of intracerebral haemorrhage
Urine dipstick	Protein +, blood +

Which of the following is the most appropriate next investigation?

A	Adrenal biopsy
B	24-h urinary catecholamine
C	24-h urinary 5-hydroxyindoleacetic acid (5-HIAA)
D	Magnetic resonance imaging (MRI) brain
E	Cystoscopy

B 24-h urinary catecholamine

The correct answer is 24-h urinary catecholamine (Option B).

The suspicion from the history and the investigation findings given above is that he is suffering from a phaeochromocytoma. His cerebellar mass may be a cerebellar haemangioblastoma. Both central nervous system (CNS) haemangioblastomas and retinal lesions are commonly encountered in patients with von Hippel–Lindau syndrome. Multiple renal cysts, which may be subject to malignant transformation, are another common finding.

Most importantly of all, however, is appropriate confirmation of the possible phaeochromocytoma, so that appropriate antihypertensive therapy can be instigated before this man undergoes a number of operative procedures and investigations.

Adrenal biopsy (Option A) is incorrect.

Adrenal biopsy is not indicated in the diagnosis of phaeochromocytoma. Any surgical procedures or invasive investigation should only be undertaken after appropriate antihypertensive therapy has been instituted, to avoid precipitating hypertensive crises.

C	24-h urinary 5-hydroxyindoleacetic acid (5-HIAA)

24-h urinary 5-hydroxyindoleacetic acid (5-HIAA) (Option C) is incorrect.

This is the most useful test in diagnosing carcinoid syndrome. Typically, carcinoid syndrome presents with flushing and diarrhoea. It occurs due to the excess production of serotonin by carcinoid tumours in amounts that overwhelm the liver's metabolic capabilities.

D	Magnetic resonance imaging (MRI) brain

due to the excess production of serotonin by carcinoid tumours in amounts that overwhelm the liver's metabolic capabilities.

D	Magnetic resonance imaging (MRI) brain

Magnetic resonance imaging (MRI) brain (Option D) is incorrect.

This may be of help in the diagnosis of a cerebellar tumour but would not aid in the diagnosis of the phaeochromocytoma, which is the pressing problem here.

E	Cystoscopy

Cystoscopy (Option E) is incorrect.

The presence of a one-off positive dipstick for microscopic haematuria in this patient would not warrant a cystoscopy.

32783

Rate this question:

A 62-year-old woman presents to the Neurology Clinic with an 8-month history of pulsatile tinnitus, dysarthria and difficulty in eating and swallowing food. She also reports episodes of severe sweatiness and palpitations that resolve spontaneously. She had previously been well.

On examination, she had a depressed cough reflex, sternocleidomastoid weakness and tongue wasting, all on the right-hand side, suggesting X, XI and XII nerve lesions. The remainder of the neurological examination was unremarkable.

What is the most likely diagnosis?

A	Paraganglioma
B	Acoustic neuroma
C	Hypoglossal tumour
D	Motor neurone disease

food. She also reports episodes of severe sweatiness and palpitations that resolve spontaneously. She had previously been well.

On examination, she had a depressed cough reflex, sternocleidomastoid weakness and tongue wasting, all on the right-hand side, suggesting X, XI and XII nerve lesions. The remainder of the neurological examination was unremarkable.

What is the most likely diagnosis?

A	Paraganglioma
B	Acoustic neuroma
C	Hypoglossal tumour
D	Motor neurone disease
E	Nasopharyngeal carcinoma

A 62-year-old woman presents to the Neurology Clinic with an 8-month history of pulsatile tinnitus, dysarthria and difficulty in eating and swallowing food. She also reports episodes of severe sweatiness and palpitations that resolve spontaneously. She had previously been well.

On examination, she had a depressed cough reflex, sternocleidomastoid weakness and tongue wasting, all on the right-hand side, suggesting X, XI and XII nerve lesions. The remainder of the neurological examination was unremarkable.

What is the most likely diagnosis?

Your answer was incorrect

A Paraganglioma

B Acoustic neuroma

C Hypoglossal tumour

A Paraganglioma

The symptoms of pulsatile tinnitus and combined X, XI and XII nerve palsies are suggestive of a paraganglioma. These are usually benign, slow-growing tumours and are commonly found in the ear.

Their mass effect can block sound transmission in the middle ear, causing conductive hearing loss, and the high blood flow within them is usually perceived as a pulsating sound (a form of tinnitus). With larger tumors, structures in the temporal bone can be invaded, including the X, XI and XII nerves. Rarely, these tumors can produce hormones such as adrenaline, which can cause episodes of sweating, flushing, headache and a rapid heartbeat.

C Hypoglossal tumour

This causes a XII nerve palsy alone, and therefore is an incorrect option.

B Acoustic neuroma

This may result in palsies of cranial nerves V–VIII, which makes it an incorrect option.

D Motor neurone disease

This can affect any part of the body, but symptoms affecting swallowing and the tongue in particular are often sub-categorised into progressive bulbar palsy (PBP). It is extremely rare to see PBP alone without any abnormalities in the legs and arms, and is therefore an incorrect option.

E Nasopharyngeal carcinoma

Other skull base causes of this combined nerve palsy include nasopharyngeal carcinoma, neurofibroma and trauma, but one would not expect to see sweating and palpations with these conditions.

6:42

https://www.google.com/sea

16

Radiopaedia

Paraganglioma | Radiology Reference Article | Radiopaedia...

Images may be subject to copyright. Learn More

RELATED IMAGES

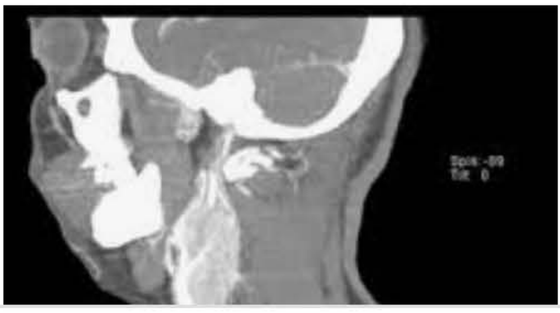

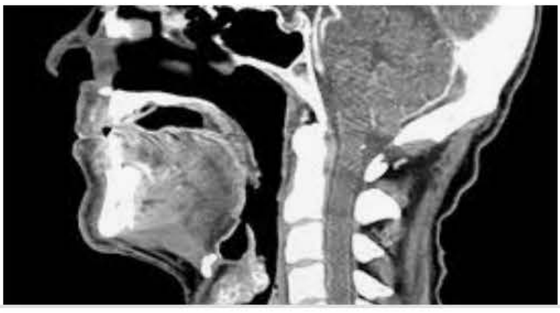

Radiopaedia

Glomus tympanicum paraganglioma | Radiology Cas...

Sign up

Images may be subject to copyright. Learn More

RELATED IMAGES

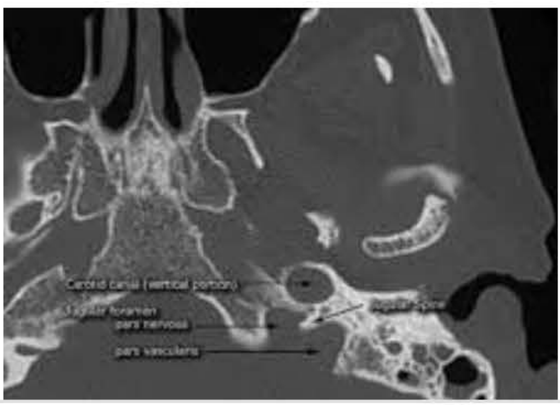

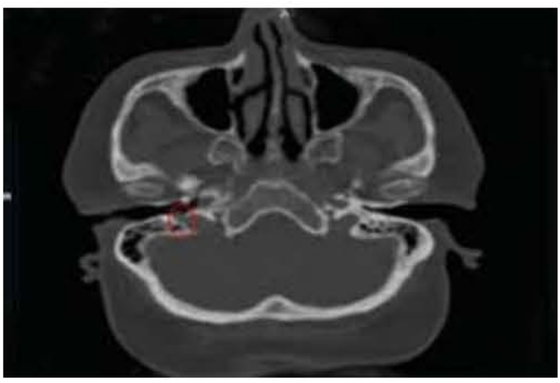

A 28-year-old woman with known alcohol abuse and a previous history of haematemesis presents semi-conscious to the Emergency Department. She is resuscitated adequately with fluids, and blood sugar is normal in the Emergency Department. She made a recovery over the next 24 h.

In the course of her treatment, she was given 5 mg diazepam for alcohol withdrawal, and IV thiamine. The next morning, she was found unresponsive. You check her blood sugar and turn her on her side with an airway in place.

Investigations:

Na^+	137 mmol/l
K^+	3.3 mmol/l
Urea	3.8 mmol/l
Creatinine	118 μmol/l
Bilirubin	17 μmol/l
AST	62 U/l
ALT	38 U/l

Bilirubin	17 μmol/l
AST	62 U/l
ALT	38 U/l
GGT	59 U/l
Glucose	5.8 mmol/l

Which of the following is the most appropriate next management step?

A	Neurological observation and IV fluids
B	Aciclovir and cefotaxime IV
C	Naloxone IV
D	Computed tomography (CT) brain
E	Flumazenil IV

A 28-year-old woman with known alcohol abuse and a previous history of haematemesis presents semi-conscious to the Emergency Department. She is resuscitated adequately with fluids, and blood sugar is normal in the Emergency Department. She made a recovery over the next 24 h.

In the course of her treatment, she was given 5 mg diazepam for alcohol withdrawal, and IV thiamine. The next morning, she was found unresponsive. You check her blood sugar and turn her on her side with an airway in place.

Investigations:

Na^+	137 mmol/l
K^+	3.3 mmol/l
Urea	3.8 mmol/l
Creatinine	118 μmol/l
Bilirubin	17 μmol/l

D Computed tomography (CT) brain

Although this woman may be encephalopathic and deterioration could have been precipitated by diazepam treatment, it is crucial to exclude subdural haematoma in a patient with obvious alcoholism. As such, a CT brain scan would be the next investigation of choice and surgical decompression considered if a large subdural haematoma is identified. Assessment of the alcoholic patient is fraught with difficulty. Sadly, many patients have died from reversible causes because their presentation has been put down to intoxication. Such patients should be carefully assessed. Concern should be given to detecting occult trauma, electrolyte disturbances, the effects of malnutrition and the possibility that the patient may have had a seizure.

E Flumazenil IV

The patient has been given a small

The patient has been given a small dose of benzodiazepine, but it is very unlikely that this has precipitated the acute deterioration. Furthermore, flumazenil can precipitate seizures and should be used cautiously.

A	Neurological observation and IV fluids

This patient has acutely deteriorated, and urgent action is required to try and determine the cause.

B	Aciclovir and cefotaxime IV

Antiviral and antibiotic therapy might be considered if CNS infections were thought to be the cause of the deterioration. However, the sudden loss of consciousness in this case would be atypical for encephalitis or meningitis, which usually present more gradually with fever, confusion, meningism and/or seizures.

C	Naloxone IV

IV fluids

This patient has acutely deteriorated, and urgent action is required to try and determine the cause.

B Aciclovir and cefotaxime IV

Antiviral and antibiotic therapy might be considered if CNS infections were thought to be the cause of the deterioration. However, the sudden loss of consciousness in this case would be atypical for encephalitis or meningitis, which usually present more gradually with fever, confusion, meningism and/or seizures.

C Naloxone IV

There would be little reason to give naloxone – this is an opiate antagonist. There is no suggestion of opiate excess in this case.

6527

Rate this question:

A 22-year-old woman presented to the Emergency Department with a 5-day history of progressive weakness and lethargy. She had initially complained of a constant dry mouth and nausea associated with some swallowing difficulties.

However, in the last few days, she had noticed blurring of vision and more recently upper limb weakness and breathlessness on exertion. She denied haemoptysis, sputum production or cough but did complain of a sore throat. Preceding her symptoms she had experienced some abdominal pain, but thought it may have been due to her period.

She denied any medical problems and is a smoker of 20 cigarettes per day.

On examination, she was alert and orientated. Her temperature was 36.7 °C, blood pressure 110/60 mmHg, pulse 78 bpm and respiratory rate 20/min. There was evidence of intravenous (IV) drug abuse, with several track marks and puncture sites found on both thighs.

On cranial nerve examination she had mild bilateral ptosis with restricted ocular movements on right lateral and right superior gaze. There were reduced palatal movements and neck extension was weak.

Examination of the upper limb revealed reduced reflexes bilaterally with some proximal weakness, but sensory examination was normal. On examination of the lower limb, reflexes were all depressed; power and sensory examination was normal.

Chest examination was normal other than slightly reduced expansion (4 cm), and abdominal examination was entirely normal.

Full blood count (FBC) and urea and electrolytes were all normal.

Lumbar puncture (CSF):

Opening pressure	12 cmH_2O (5–18)
Protein	0.45 g/l (0.15–0.45)
White cell count	

Protein	0.45 g/l (0.15–0.45)
White cell count (WCC)	3/ml (≤ 5)
Red cell count (RCC)	2/ml (≤ 5)
Tensilon (edrophonium) test	Positive

What is the likely diagnosis for this patient?

A	Myasthenia gravis
B	Miller Fisher variant of Guillain–Barré syndrome
C	Botulism
D	Cerebrovascular disease of the brainstem
E	Lambert–Eaton syndrome

She denied any medical problems and is a smoker of 20 cigarettes per day.

On examination, she was alert and orientated. Her temperature was 36.7 °C, blood pressure 110/60 mmHg, pulse 78 bpm and respiratory rate 20/min. There was evidence of intravenous (IV) drug abuse, with several track marks and puncture sites found on both thighs.

On cranial nerve examination she had mild bilateral ptosis with restricted ocular movements on right lateral and right superior gaze. There were reduced palatal movements and neck extension was weak.

Examination of the upper limb revealed reduced reflexes bilaterally with some proximal weakness, but sensory examination was normal. On examination of the lower limb, reflexes were all depressed; power and sensory examination was normal.

Chest examination was normal other than slightly reduced expansion (4 cm), and abdominal examination was entirely normal.

C Botulism

The patient has an acute-onset neuromuscular junction pattern of weakness (complex ophthalmoplegia, proximal limb weakness and intact sensation) with early involvement of facial, swallowing, neck and respiratory muscles.

In addition, she complains of autonomic features such as dry mouth. The preceding abdominal pain and vomiting point to a food-borne source of the causative pathogen, *Clostridium botulinum*, which produces a neurotoxin.

This toxin binds irreversibly to the presynaptic membranes of peripheral neuromuscular and autonomic nerve junctions. Toxin binding blocks acetylcholine release, resulting in weakness, flaccid paralysis and (often) respiratory arrest. Botulism can be food-borne or develop from wound infection.

This is a neuromuscular junction problem that is not directly caused by

This is a neuromuscular junction problem that is not directly caused by the infection, and therefore the CSF and blood tests are unremarkable. Botulism can cause a false-positive Tensilon test result.

A	Myasthenia gravis

While the ptosis and ophthalmoplegia can point towards myasthenia gravis (MG), there is no suggestion that it is worse at the end of the day. Neck flexion is usually also weak in MG. Therefore these reasons make MG less likely. The Tensilon test can be positive in other neuromuscular conditions and is not specific to MG.

B	Miller Fisher variant of Guillain–Barré syndrome

Miller-Fisher syndrome (MFS) is a triad of ophthalmoplegia, areflexia and ataxia. She is not ataxic. MFS and Guillain-Barré are post-infectious immune-mediated disorders; there is

immune mediated disorders, there is no suggestion that she has had a recent acute infection to trigger such a reaction, and therefore this is unlikely to be MFS.

D	Cerebrovascular disease of the brainstem

This option is not correct because the onset is slow for cerebrovascular disease. She also does not have vertigo or nystagmus, which is usually seen in lateral medullary syndrome. She also has no signs of damage to other tracts in the brainstem, such as sensory signs, coma or a pyramidal pattern of limb weakness.

E	Lambert–Eaton syndrome

Lambert-Eaton myasthenic syndrome (LEMS) is a paraneoplastic disorder seen in conjunction with small cell lung cancer, with antibodies against the voltage-gated calcium channel (VGCC) found at the neuromuscular junction. It usually has a subacute course, rather

weakness.

E	Lambert–Eaton syndrome

Lambert-Eaton myasthenic syndrome (LEMS) is a paraneoplastic disorder seen in conjunction with small cell lung cancer, with antibodies against the voltage-gated calcium channel (VGCC) found at the neuromuscular junction. It usually has a subacute course, rather than the acute picture seen here. Although autonomic features such as dry mouth are often present, the other features such as abdominal pain and frank respiratory muscle weakness, and the absence of predisposing factors to lung cancer, do not support this diagnosis.

8533

Rate this question:

A 17-year old girl is referred with a 2-week history of poor coordination. She has become generally clumsier, with increasing difficulty using her cutlery, and her handwriting has also deteriorated. Her mother had noted that her speech was more slurred.

She had no significant past medical history of note, and had achieved her developmental milestones normally. She had just finished her GCSEs in which she achieved good grades, and had just started at a sixth form college to study for her A-levels.

Her only family history of note was that her father had partial epilepsy, which was well controlled. She denied smoking, alcohol or recreational drug use. Her appetite was good and her weight was stable.

On examination, she appears well. Her pulse is 72/min, regular and jugular venous pressure is not raised. Blood pressure is 116/68 mmHg. Heart sounds are normal and her chest is clear. Abdominal examination is unremarkable. Neurological

unremarkable. Neurological examination reveals bilateral nystagmus on lateral gaze, mild tremor affecting her hands, scanning dysarthria, bilateral dysmetria and dysdiadochokinesis, and an ataxic gait.

Investigations:

Hb	14.4 g/dl
WCC	5.6×10^9/l
PLT	324×10^9/l
Na^+	144 mmol/l
K^+	4.4 mmol/l
Creatinine	68 μmol/l
Urea	3.2 mmol/l
Bilirubin	22 μmol/l
ALT	110 IU/l
ALP	108 IU/l
Albumin	44 g/l
Glucose	6.2 mmol/l
	[illegible]

ALP	108 IU/l
Albumin	44 g/l
Glucose	6.2 mmol/l
Ferritin	290 µg/l (15–200)
Caeruloplasmin	0.36 g/l (0.2–0.6)
MRI brain and spinal cord	Normal

What is the most likely diagnosis?

A	Wilson's disease
B	Haemochromatosis
C	Phenytoin toxicity
D	Spinocerebellar syndrome
E	Demyelinating disorder

which she achieved good grades, and had just started at a sixth form college to study for her A-levels.

Her only family history of note was that her father had partial epilepsy, which was well controlled. She denied smoking, alcohol or recreational drug use. Her appetite was good and her weight was stable.

On examination, she appears well. Her pulse is 72/min, regular and jugular venous pressure is not raised. Blood pressure is 116/68 mmHg. Heart sounds are normal and her chest is clear. Abdominal examination is unremarkable. Neurological examination reveals bilateral nystagmus on lateral gaze, mild tremor affecting her hands, scanning dysarthria, bilateral dysmetria and dysdiadochokinesis, and an ataxic gait.

Investigations:

Hb	14.4 g/dl
WCC	5.6×10^9/l
PLT	324×10^9/l

C Phenytoin toxicity

Phenytoin toxicity can cause mental slowing, unsteadiness and a cerebellar-like syndrome. Nystagmus occurs even with mild toxicity. Phenytoin can result in abnormal liver function values.

D Spinocerebellar syndrome

The normal MRI of the brain and spinal cord make spinocerebellar ataxia less likely, as atrophy is often present. In addition there are no myelopathic signs in conjunction with the cerebellar signs to make one suspicious of this.

A Wilson's disease

Wilson's disease is associated with tremor, parkinsonism and dystonia. The ataxic signs seen here are not typical. Caeruloplasmin within the normal range makes Wilson's less likely as the underlying diagnosis. It should be noted that in some cases of acute hepatitis related to Wilson's,

be noted that in some cases of acute hepatitis related to Wilson's, caeruloplasmin may be within the normal range, and 24 h urinary copper excretion is the best test.

B	Haemochromatosis

This disorder does not present with an ataxic syndrome. Clinical symptoms associated with haemochromatosis and consequent iron overload are not normally seen in women until they enter the post-menopausal period.

E	Demyelinating disorder

Signs confined to the cerebellum would be very unusual in the context of a demyelinating disorder, in MS, optic neuritis is also a usual presenting feature.

7592

Rate this question:

Next Question

A 70-year-old man with no previous medical history was admitted to the Emergency Department, brought in by his son. He had been well only 2 days previously at a family Christmas dinner, although the family had noticed him slowing down, not mobilising much around the house and tending to stay downstairs in the lounge for much of the day.

Other past history of note is one previous choking episode 6 months earlier, and two episodes of pneumonia. His son had him brought in as he was not answering the telephone, and when he visited the house found him confined to bed.

On admission, he was conscious, alert and 'disorientated but not confused'. Blood pressure was on the low side, with pulse 40 bpm. Oral temperature was 35.6 °C. Chest X-ray showed right lower lobe changes. Electrocardiogram (ECG) taken on the ward later revealed slow atrial fibrillation, 54 beats/min. Muscle fasciculation and some muscle wasting was noted by the admitting

Blood pressure was on the low side, with pulse 40 bpm. Oral temperature was 35.6 °C. Chest X-ray showed right lower lobe changes. Electrocardiogram (ECG) taken on the ward later revealed slow atrial fibrillation, 54 beats/min. Muscle fasciculation and some muscle wasting was noted by the admitting senior house officer. He has IV fluid replacement running.

What is the next most appropriate management step?

A	Arrange muscle biopsy
B	Arrange nerve and muscle conduction studies
C	Make him nil by mouth pending swallow assessment
D	Start oral antibiotic therapy
E	Start anti-cholinesterase therapy

medical history was admitted to the Emergency Department, brought in by his son. He had been well only 2 days previously at a family Christmas dinner, although the family had noticed him slowing down, not mobilising much around the house and tending to stay downstairs in the lounge for much of the day.

Other past history of note is one previous choking episode 6 months earlier, and two episodes of pneumonia. His son had him brought in as he was not answering the telephone, and when he visited the house found him confined to bed.

On admission, he was conscious, alert and 'disorientated but not confused'. Blood pressure was on the low side, with pulse 40 bpm. Oral temperature was 35.6 °C. Chest X-ray showed right lower lobe changes. Electrocardiogram (ECG) taken on the ward later revealed slow atrial fibrillation, 54 beats/min. Muscle fasciculation and some muscle wasting was noted by the admitting senior house officer. He has IV fluid replacement running.

C Make him nil by mouth pending swallow assessment

It is likely that if his swallow has deteriorated resulting in aspiration pneumonia, then further spill-over of liquid into the lungs is likely. He should be assessed by a speech and language therapist and started on thickened fluids if necessary to prevent further aspiration. Clearly antibiotic therapy is important, as is proving the underlying neuromuscular diagnosis, but protecting the airway is most important at this stage. Given the findings on examination, including muscle fasciculation and wasting and the previous history of choking/pneumonia, motor neurone disease with bulbar palsy is a definite possibility as to his underlying neurological diagnosis.

A Arrange muscle biopsy

Although this patient may well have motor neurone disease, muscle biopsy is rarely needed to confirm the

is rarely needed to confirm the diagnosis; nerve conduction studies and needle electromyography are the investigations of choice.

B	Arrange nerve and muscle conduction studies

This is the standard investigation panel for possible motor neurone disease, although it isn't the next most important management step.

D	Start oral antibiotic therapy

In the event that this patient has aspiration pneumonia, IV antibiotics are likely to be most appropriate, with prevention of further aspiration a key step.

E	Start anti-cholinesterase therapy

Anti-cholinesterase agents are used in the treatment of myasthenia gravis, not the most likely diagnosis here.

A 23-year-old right-handed man presents to the Emergency Department with sudden-onset left-sided weakness. The weakness began today when he was playing squash and forced him to stop playing after he had fallen when trying to continue. He also reports pain in his neck, which he attributes to having twisted his neck during the game. He has no past medical history of note and is a non-smoker. However, he admits to some occasional cocaine use but not in the last few days. There is no family history to note. He has a stressful job in the city and is keen to be discharged as he has an important meeting to attend the next day.

On examination, he has normal tone, and grade 4/5 weakness in a pyramidal distribution in the left arm and leg. Reflexes are normal and the plantars are up-going, cranial nerves intact and pupillary responses are equal and reactive. There is mild tenderness on palpation on the right side of his neck and behind his right ear.

Which is the most likely diagnosis in

the next day.

On examination, he has normal tone, and grade 4/5 weakness in a pyramidal distribution in the left arm and leg. Reflexes are normal and the plantars are up-going, cranial nerves intact and pupillary responses are equal and reactive. There is mild tenderness on palpation on the right side of his neck and behind his right ear.

Which is the most likely diagnosis in this case?

A	Hemiplegic migraine
B	Right carotid artery dissection
C	Right middle cerebral artery infarction
D	Right lacunar infarct secondary to cocaine use
E	Transient ischaemic attack

A 23-year-old right-handed man presents to the Emergency Department with sudden-onset left-sided weakness. The weakness began today when he was playing squash and forced him to stop playing after he had fallen when trying to continue. He also reports pain in his neck, which he attributes to having twisted his neck during the game. He has no past medical history of note and is a non-smoker. However, he admits to some occasional cocaine use but not in the last few days. There is no family history to note. He has a stressful job in the city and is keen to be discharged as he has an important meeting to attend the next day.

On examination, he has normal tone, and grade 4/5 weakness in a pyramidal distribution in the left arm and leg. Reflexes are normal and the plantars are up-going, cranial nerves intact and pupillary responses are equal and reactive. There is mild tenderness on palpation on the right side of his neck

B Right carotid artery dissection

Carotid artery dissection is a relatively common cause of stroke in young people, accounting for up to 20% of cases. The neck pain and young age of this patient make a dissection the best answer. It can be idiopathic but is commonly associated with mild trauma. Many present with neurological deficits including hemiparesis, Horner syndrome and cranial nerve palsies. However, it should be remembered that a number present simply with pain in the neck. The main complications are completed stroke, usually from thrombus formation associated with damage to the endothelium. Therefore anticoagulation or antiplatelet medication is often advised if not otherwise contraindicated, although there is a lack of conclusive evidence of its benefit.

A Hemiplegic migraine

Migraine can rarely present with hemiplegia; however, given the lack of headache and family history, this would not fit. The hemiplegia itself is temporary.

C	Right middle cerebral artery infarction

The neck pain and young age are important details that should caution against making this the best answer. Strokes do not typically present with headache or neck pain as in this case. Moreover, activity at the onset of symptoms should also make you consider dissection.

D	Right lacunar infarct secondary to cocaine use

Although this man admits to cocaine use, and illicit drug use is important in the history of young strokes, it is less likely a cause here as it is some time after last use.

likely a cause here as it is some time after last use.

E	Transient ischaemic attack

In the same way that carotid artery dissection is a better answer than MCA infarct, a TIA would be less likely than dissection. More importantly, you can only diagnose a TIA once the symptoms have resolved within less than 24 h. The onset of symptoms was today and therefore one would be unable to accurately diagnose a TIA. Moreover, NICE advise that in a suspected case of TIA in which symptoms have resolved within 24 h, a specialist review should take place within one week to determine whether brain imaging is required. In a high-risk patient with suspected TIA (ABCD2 score of ≥4), management should include urgent brain imaging.

6996

Rate this question:

Next Question

A 38-year-old woman presents with weakness and paraesthesia of her right leg, which is limiting her mobility. Thirteen months previously, she had been investigated for an episode of painful loss of vision in left eye with associated left-sided pyramidal weakness.

Visual evoked potentials confirmed delay on the left side; spinal fluid analysis revealed normal cells and protein but the presence of unmatched oligoclonal bands; magnetic resonance imaging (MRI) of the brain and cervical spinal cord showed periventricular areas of high T2 signal.

At that time, she was treated with steroids, made a good recovery and has been symptom free until this presentation. On this occasion, MRI showed an increased number of periventricular high-intensity lesions.

Choose the most appropriate management plan.

A	Oral methyl prednisolone 500 mg daily for 5 days and

steroids, made a good recovery and has been symptom free until this presentation. On this occasion, MRI showed an increased number of periventricular high-intensity lesions.

Choose the most appropriate management plan.

A	Oral methyl prednisolone 500 mg daily for 5 days and referral for consideration of disease-modifying treatment
B	IV methyl prednisolone 1 g daily for 3 days
C	MR angiography
D	Oral prednisolone 40 mg, gradually reducing over one month
E	Repeat CSF analysis

A Oral methyl prednisolone 500 mg daily for 5 days and referral for consideration of disease-modifying treatment

This patient has multiple sclerosis with two typical relapses. The investigations are entirely in keeping with this diagnosis. High-dose steroids are effective in speeding up recovery from a relapse, so in a disabling attack this may be offered. Oral methylprednisolone 500 mg for 5 days has been shown to be non-inferior to IV methyl prednisolone. As she has had two relapses in less than 2 years she is a candidate for disease-modifying treatment, but will need to see a specialist for this.

B IV methyl prednisolone 1 g daily for 3 days

Although this treatment will speed up recovery from this episode, she also needs consideration of disease-modifying treatment to control her

condition in the longer term.

C	MR angiography

There are no features in the case suspicious for a vasculitic condition mimicking MS, so this test is not required.

D	Oral prednisolone 40 mg, gradually reducing over one month

High-dose, short courses of corticosteroids are effective in MS relapses, but longer-term treatment courses such as this are not beneficial.

E	Repeat CSF analysis

There is no indication to repeat the CSF analysis for each MS relapse. Once present, the oligoclonal bands do not change. Repeating MRI scans can be helpful as this allows radiological assessment of disease activity.

You assess a 28-year-old woman in the Outpatient Clinic. She was diagnosed with myasthenia gravis 3 years ago and initially improved with oral anticholinesterase medication and immunosuppression.

In the last 6 weeks, she has worried about a return of her symptoms despite compliance with medication. She describes generalised lethargy as worse at the end of the day and occasional diplopia. On systemic enquiry, she admits weight gain and ankle oedema.

On general examination, you note palmar erythema, and resting tachycardia.

What is the first-line investigation?

A	Thyroid function testing and autoantibodies
B	Echocardiogram
C	Computerised tomography (CT) chest

She describes generalised lethargy as worse at the end of the day and occasional diplopia. On systemic enquiry, she admits weight gain and ankle oedema.

On general examination, you note palmar erythema, and resting tachycardia.

What is the first-line investigation?

A	Thyroid function testing and autoantibodies
B	Echocardiogram
C	Computerised tomography (CT) chest
D	Human chorionic gonadotrophin assay
E	Rheumatoid factor assay

You assess a 28-year-old woman in the Outpatient Clinic. She was diagnosed with myasthenia gravis 3 years ago and initially improved with oral anticholinesterase medication and immunosuppression.

In the last 6 weeks, she has worried about a return of her symptoms despite compliance with medication. She describes generalised lethargy as worse at the end of the day and occasional diplopia. On systemic enquiry, she admits weight gain and ankle oedema.

On general examination, you note palmar erythema, and resting tachycardia.

What is the first-line investigation?

Your answer was incorrect

A Thyroid function testing and autoantibodies

D Human chorionic gonadotrophin assay

This patient describes some symptoms suggestive of myasthenia relapse. The majority of her other symptoms and signs are consistent with pregnancy, a common cause of myasthenia relapse. Pregnancy has a variable effect on the course of myasthenia. Women with myasthenia that is stable prior to pregnancy are likely to remain stable throughout pregnancy, although a small proportion may have post-partum worsening. In poorly controlled myasthenia before pregnancy, flares are most likely to occur in the first trimester and the postpartum period.

A Thyroid function testing and autoantibodies

Autoimmune thyroid disease is common (3-8%) in those with myasthenia gravis, and should form part of the initial diagnostic work up. In this case, however, although resting

associated with hyperthyroidism, weight gain and ankle oedema would be associated with hypothyroidism.

B	Echocardiogram

It may be used to investigate oedema and tachycardia but would not be a first-line investigation in this context.

C	Computerised tomography (CT) chest

This may be used to investigate for thymoma in myasthenia patients, but the presence of a thymoma would not explain her deterioration. Furthermore, the pregnancy status of a woman of child-bearing age should be established prior to exposing her to such high doses of radiation.

E	Rheumatoid factor assay

Rheumatoid antibodies are found in 10-40% of the population and there is

A 42-year-old woman presents to the GP complaining of excruciating headaches which feel like pain penetrating through her right eye. These headaches appear to come on at the worst possible moments, particularly when she has most stress at work or even during the middle of the night. They are unbearable and stop her doing anything. Apparently, when they come on, people tell her that her face is furrowed and creased with pain, and she becomes very restless. She has noticed that, during the attack, her eye waters and her nose runs on the same side as the headache. The pain lasts around 15 minutes and then subsides. She typically has several severe attacks over the space of a few weeks, and then several months with no episodes at all. BP in the clinic is 120/70 mmHg and neurological examination is normal.

Which one of the following would be most appropriate initial maintenance therapy for prophylaxis of this condition?

headache. The pain lasts around 15 minutes and then subsides. She typically has several severe attacks over the space of a few weeks, and then several months with no episodes at all. BP in the clinic is 120/70 mmHg and neurological examination is normal.

Which one of the following would be most appropriate initial maintenance therapy for prophylaxis of this condition?

A	High-flow oxygen therapy
B	Verapamil
C	Lithium carbonate
D	Amlodipine
E	Nifedipine

particularly when she has most stress at work or even during the middle of the night. They are unbearable and stop her doing anything. Apparently, when they come on, people tell her that her face is furrowed and creased with pain, and she becomes very restless. She has noticed that, during the attack, her eye waters and her nose runs on the same side as the headache. The pain lasts around 15 minutes and then subsides. She typically has several severe attacks over the space of a few weeks, and then several months with no episodes at all. BP in the clinic is 120/70 mmHg and neurological examination is normal.

Which one of the following would be most appropriate initial maintenance therapy for prophylaxis of this condition?

Your answer was incorrect

A	High-flow oxygen therapy

B Verapamil

This woman has a history which is very typical of cluster headache. Treatments are divided into acute treatments for rapid termination of clusters and maintenance prophylaxis. High-flow oxygen is very effective for aborting attacks, its use being limited by practical difficulties of delivery out with the hospital setting. Injectable triptans can also be used. Steroids may be effectively used to terminate a severe cluster. In terms of maintenance prophylaxis, verapamil is the most-effective drug for cluster headache.

E Nifedipine

This drug is ineffective in managing cluster headache.

A High-flow oxygen therapy

This is an effective acute treatment but is not effective as a maintenance drug.

7:42
tps://mypastest.pastest.com
16

This drug is ineffective in managing cluster headache.

A High-flow oxygen therapy

This is an effective acute treatment but is not effective as a maintenance drug.

C Lithium carbonate

This drug can be used as prophylaxis in cluster headache, but due to the narrow therapeutic window, the need for blood monitoring and an adverse side effect profile it is not used as first line.

D Amlodipine

This drug is ineffective in managing cluster headache.

32743

Rate this question:

A 29-year-old man is reviewed in the General Neurology Clinic. He has experienced progressive deterioration in his gait over the past 11 years, such that he currently needs the assistance of a frame.

Over the last 2 years, his hearing has progressively worsened. A detailed family history reveals that his maternal grandmother had epilepsy, his mother experienced progressive deafness in middle age and his mother's sister had difficulty walking and was told she had multiple sclerosis.

Which one of the following is the most likely diagnosis in this case?

A	Friedreich's ataxia
B	Huntington's disease
C	Miller–Fisher syndrome
D	Mitochondrial disorder

in his gait over the past 11 years, such that he currently needs the assistance of a frame.

Over the last 2 years, his hearing has progressively worsened. A detailed family history reveals that his maternal grandmother had epilepsy, his mother experienced progressive deafness in middle age and his mother's sister had difficulty walking and was told she had multiple sclerosis.

Which one of the following is the most likely diagnosis in this case?

A	Friedreich's ataxia
B	Huntington's disease
C	Miller–Fisher syndrome
D	Mitochondrial disorder
E	Spinocerebellar ataxia type 4

A 29-year-old man is reviewed in the General Neurology Clinic. He has experienced progressive deterioration in his gait over the past 11 years, such that he currently needs the assistance of a frame.

Over the last 2 years, his hearing has progressively worsened. A detailed family history reveals that his maternal grandmother had epilepsy, his mother experienced progressive deafness in middle age and his mother's sister had difficulty walking and was told she had multiple sclerosis.

Which one of the following is the most likely diagnosis in this case?

Your answer was incorrect

A	Friedreich's ataxia
B	Huntington's disease

D Mitochondrial disorder

This case highlights an inherited neurological condition with ataxia and deafness. The family history on the mother's side of the family suggests a mutation in mitochondrial DNA.. There are a number of well-described mitochondrial syndromes including Kearns–Sayre syndrome, Leigh syndrome, mitochondrial encephalomyopathy, lactic acidosis and stroke-like episodes (MELAS), mitochondrial neuro-gastro-intestinal encephalomyopathy (MNGIE), neuropathy, ataxia and retinitis pigmentosa (NARP) and progressive external ophthalmoplegia (PEO). However, it is increasingly recognised that many patients do not have one of these classical phenotypes. Ataxia, deafness, epilepsy, diabetes and eye movement problems are common features in mitochondrial diseases in general.

A Friedreich's ataxia

A Friedreich's ataxia

Friedreich's ataxia is an autosomal recessive inherited disease that causes progressive damage to the nervous system. It manifests in initial symptoms of poor coordination such as gait disturbance; it can also lead to scoliosis, heart disease and diabetes. In this case the family history favours a mitochondrial disorder.

B Huntington's disease

Huntington's disease, also known as Huntington's chorea, is an autosomal dominant condition. The earliest symptoms are often subtle problems with mood or mental abilities. A general lack of coordination and an unsteady gait often follow. As the disease advances, uncoordinated, jerky body movements become more apparent. Physical abilities gradually worsen until coordinated movement becomes difficult and the person is unable to talk. Mental abilities generally decline into dementia. The

mechanisms that are not fully understood.

C	Miller–Fisher syndrome

In the 'Miller–Fisher variant' subtype of Guillain–Barré syndrome, a triad of weakness of the eye muscles, abnormalities in coordination, as well as absent reflexes can be found. It is an acute disorder. The underlying mechanism involves an autoimmune disorder in which the body's immune system mistakenly attacks the peripheral nerves and damages their myelin insulation.

E	Spinocerebellar ataxia type 4

Spinocerebellar ataxia (SCA) type 4 is one of a group of genetic disorders characterised by slowly progressive incoordination of gait, and is often associated with poor coordination of hand, speech and eye movements. SCA 4 is associated with sensory neuropathy and is of autosomal

A 52-year-old man presented with seizures that had started 2 months ago. The attacks consisted of jerky movements involving the right upper limb followed by loss of consciousness, then spread of the jerks to the other limbs. His wife had noticed that over the short period of 2 months her husband had significant mental dulling and progressive drowsiness. He complained of generalised headaches over the past 20 days.

On examination, he was drowsy and confused. An upper motor neurone facial palsy was evident on the right side. The right upper limb was mildly spastic and weak distally. Both lower limbs had muscle strength of grade 4/5, with absent knee and ankle reflexes on the right side and brisk knee and ankle jerks on the left side. Both plantars were extensor. Magnetic resonance imaging (MRI) of the brain revealed multi-focal nodular lesions on T2-weighted imaging throughout the white matter, enhancing on gadolinium.

Investigations reveal:

Hb	12.1 g/dl
WCC	8.9×10^9/l
PLT	235×10^9/l
ESR	39 mm/hr
Na^+	137 mmol/l
K^+	4.3 mmol/l
Creatinine	110 μmol/l
ALT	54 U/l
Bilirubin	18 μmol/l

What is the most likely diagnosis?

A	Diffuse large B cell cerebral lymphoma
B	Creutzfeldt–Jakob disease
C	Gliomatosis cerebri

ESR	39 mm/hr
Na^+	137 mmol/l
K^+	4.3 mmol/l
Creatinine	110 μmol/l
ALT	54 U/l
Bilirubin	18 μmol/l

What is the most likely diagnosis?

A	Diffuse large B cell cerebral lymphoma
B	Creutzfeldt–Jakob disease
C	Gliomatosis cerebri
D	Multiple sclerosis
E	Subacute sclerosing panencephalitis

A 52-year-old man presented with seizures that had started 2 months ago. The attacks consisted of jerky movements involving the right upper limb followed by loss of consciousness, then spread of the jerks to the other limbs. His wife had noticed that over the short period of 2 months her husband had significant mental dulling and progressive drowsiness. He complained of generalised headaches over the past 20 days.

On examination, he was drowsy and confused. An upper motor neurone facial palsy was evident on the right side. The right upper limb was mildly spastic and weak distally. Both lower limbs had muscle strength of grade 4/5, with absent knee and ankle reflexes on the right side and brisk knee and ankle jerks on the left side. Both plantars were extensor. Magnetic resonance imaging (MRI) of the brain revealed multi-focal nodular lesions on T2-weighted imaging throughout the white matter, enhancing on gadolinium.

A Diffuse large B cell cerebral lymphoma

Diffuse large B-cell cerebral lymphoma (DLBCL) is comprised of immunoblasts or centroblasts that have a predilection for blood vessels. Seizures or focal neurological deficits consistent with a mass lesion are the usual modes of presentation. There is a low rate of CNS dissemination, and therefore lumbar puncture results may actually be normal. SPECT scanning may be of value in differentiating infectious from inflammatory lesions, although in practice the optimal method of confirming diagnosis is biopsy of an area seen as abnormal on radiology. Methotrexate is the mainstay of chemotherapy for the condition. Routine blood test results may be variable, particularly with respect to a rise in LDH, raised viscosity or ESR, and not necessarily always abnormal.

C Gliomatosis cerebri

Gliomatosis cerebri is a diffuse infiltrative tumour characterised by glial thickening on MRI scan; the MRI findings here count against that as the underlying diagnosis.

B	Creutzfeldt–Jakob disease

CJD is most classically manifest by basal ganglia enhancement on T2-weighted scan. The initial period of psychiatric disturbance that is common in CJD is also absent.

D	Multiple sclerosis

Although the MRI picture could potentially be multiple sclerosis, the short, progressive nature of his symptoms would be unusual for MS.

E	Subacute sclerosing panencephalitis

SSPE shows predominantly parietal and temporal lobe changes. There is also no evidence of earlier

findings here count against that as the underlying diagnosis.

B	Creutzfeldt–Jakob disease

CJD is most classically manifest by basal ganglia enhancement on T2-weighted scan. The initial period of psychiatric disturbance that is common in CJD is also absent.

D	Multiple sclerosis

Although the MRI picture could potentially be multiple sclerosis, the short, progressive nature of his symptoms would be unusual for MS.

E	Subacute sclerosing panencephalitis

SSPE shows predominantly parietal and temporal lobe changes. There is also no evidence of earlier immunosuppression, which could be a driver for measles virus re-activation.

7:53

https://www.google.com/sea 16

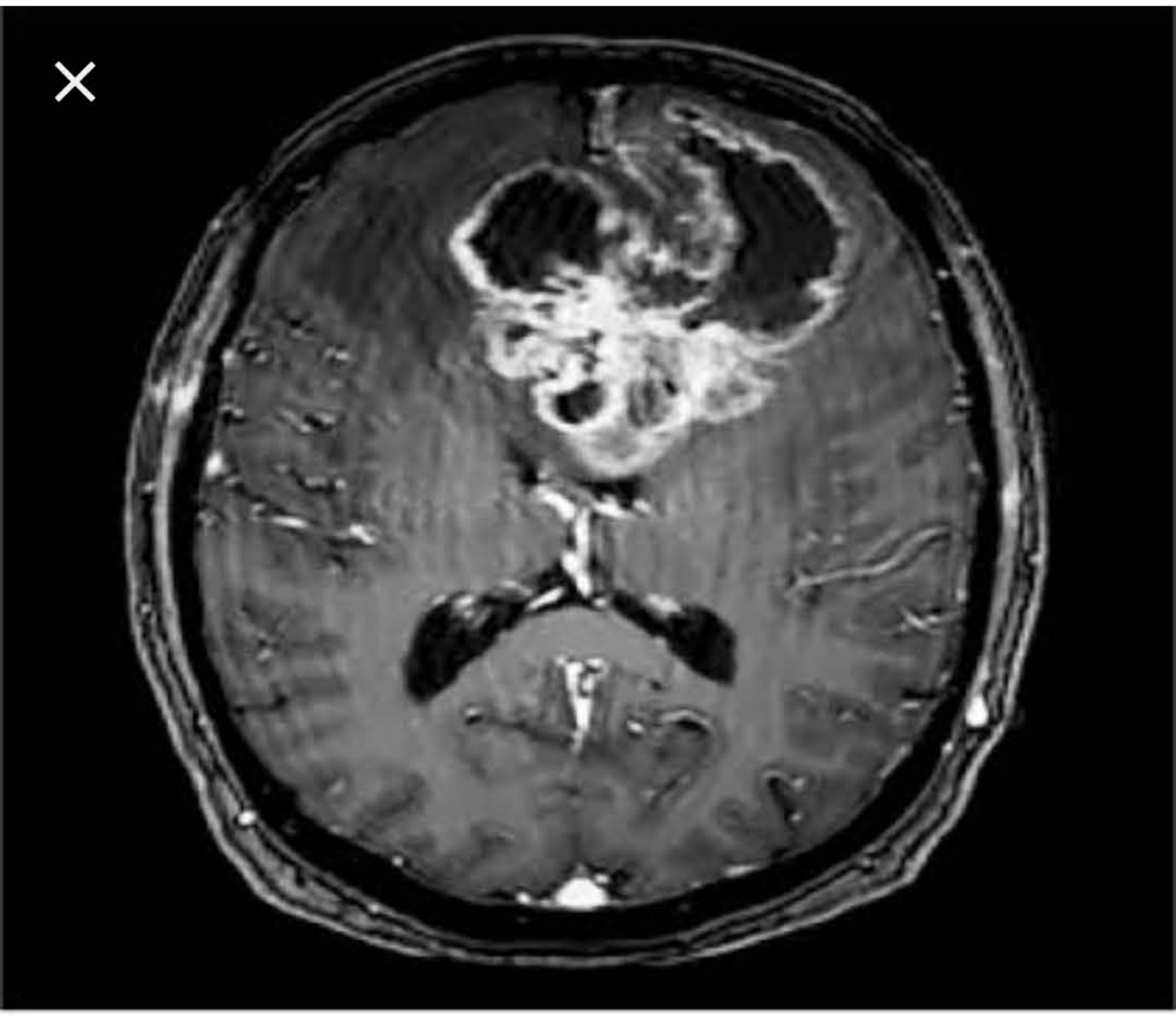

Fig. 2: This axial T1-weighted postcontrast brain MRI shows a heterogeneously enhancing lesion, which is a glioblastoma. Cystic areas are noted within the lesion, which would not be expected in primary CNS lymphoma.

The ASCO Post

A: Primary Diffuse Large B-Cell Lymphoma of the Central Nervo...

2: This axial T1-weighted postcontrast brain MRI shows a heterogeneously enhancing lesion, which is a glioblastoma. Cystic areas are noted within the lesion ...

Images may be subject to copyright. Learn More

RELATED IMAGES

7:54

https://www.google.com/sea 16

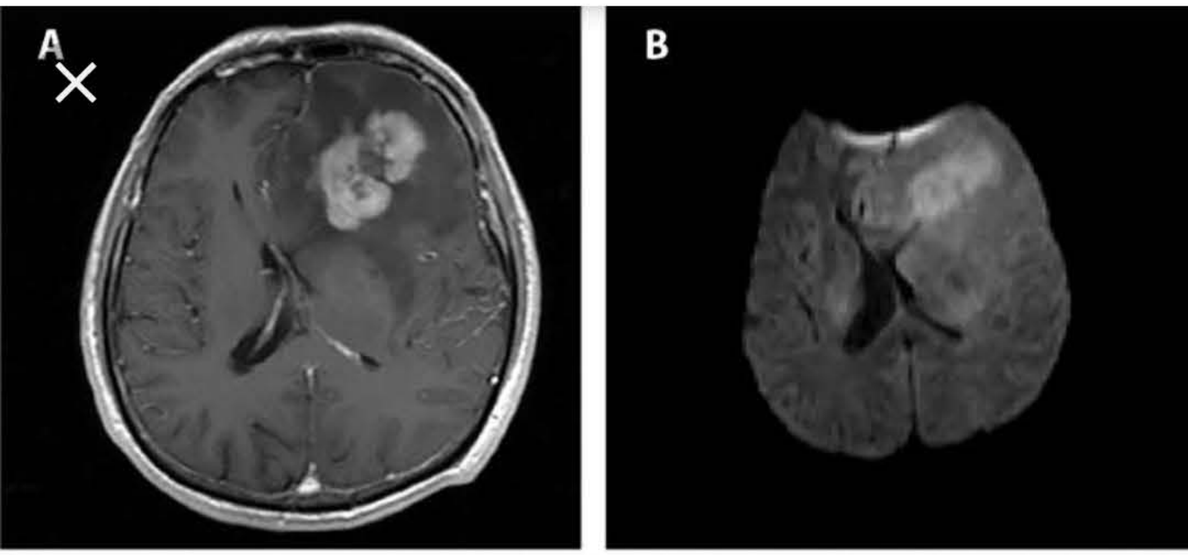

Fig. 1: (A) This axial T1-weighted postcontrast brain MRI image shows a homogeneously enhancing lesion in the left frontal lobe. A smaller similar appearing lesion (not shown) was also present in the right frontal lobe of the brain. (B) Axial diffusion-weighted imaging sequence demonstrates restricted diffusion throughout the area of the enhancing lesion, which was confirmed on the apparent diffusion coefficient sequence (not shown).

The ASCO Post

Q: Primary Diffuse Large B-Cell Lymphoma of the Central Nervo...

1: (A) This axial T1-weighted postcontrast brain MRI image shows a homogeneously enhancing lesion in the left frontal lobe. A smaller similar appearing ...

Images may be subject to copyright. Learn More

RELATED IMAGES

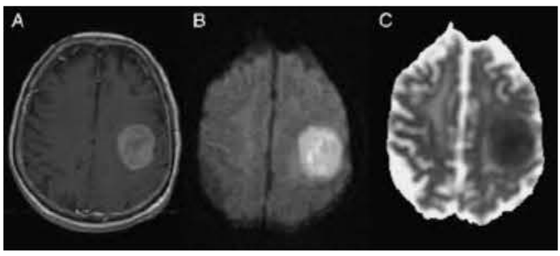

Restricted diffusion in CNS ly...
researchgate.net

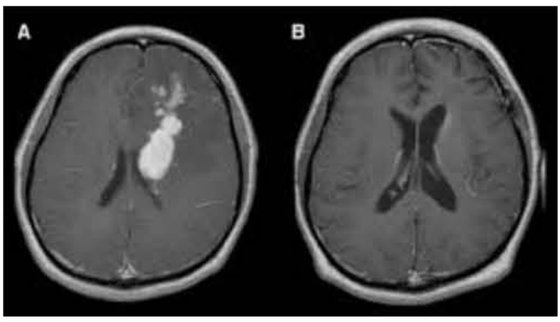

New Brain Cancer Treatment ...
ucsf.edu

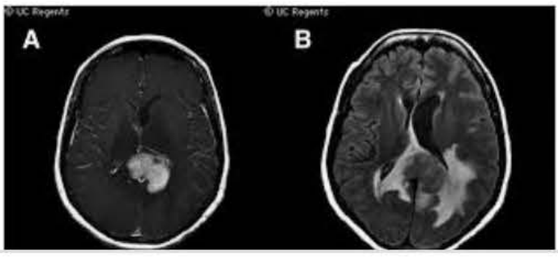

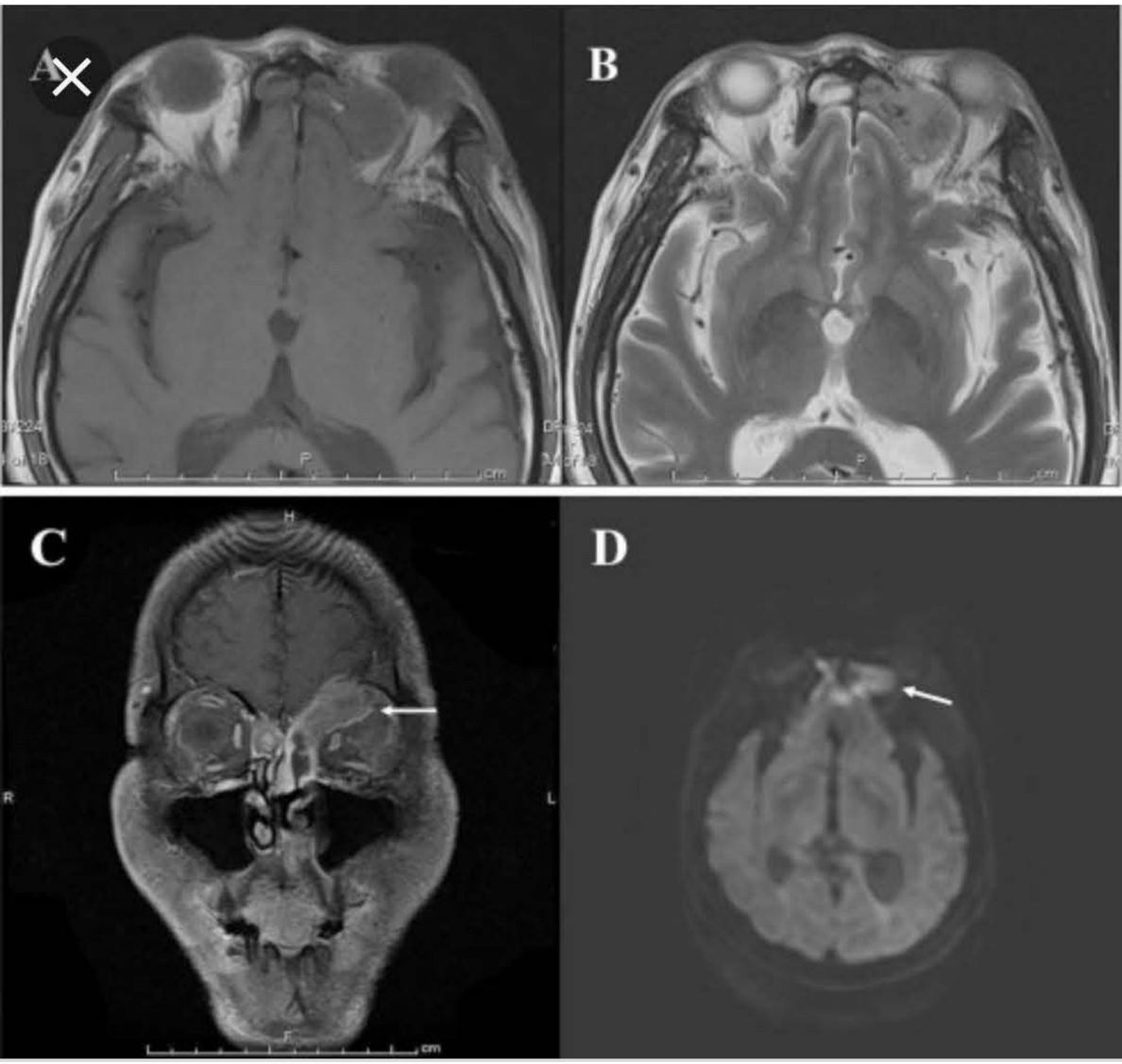

ScienceDirect.com

Primary diffuse large B-cell lymphoma of the frontal sinus: ...

... Download full-size image

Images may be subject to copyright. Learn More

RELATED IMAGES

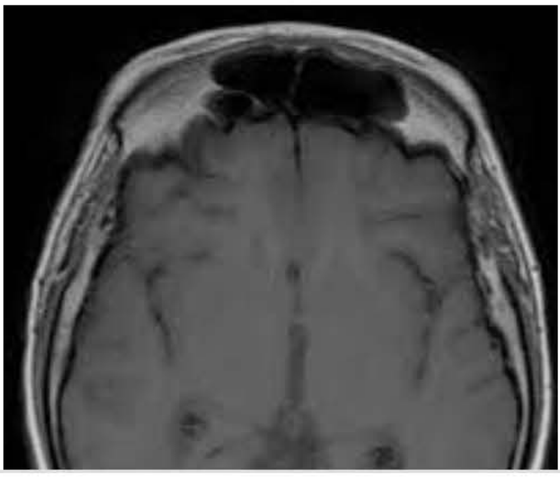

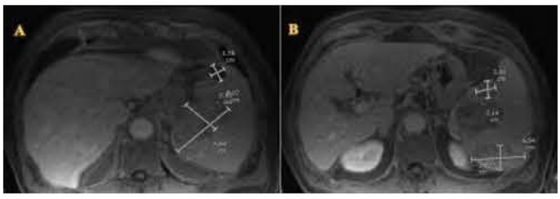

Primary Splenic Diffuse Larg...
cureus.com

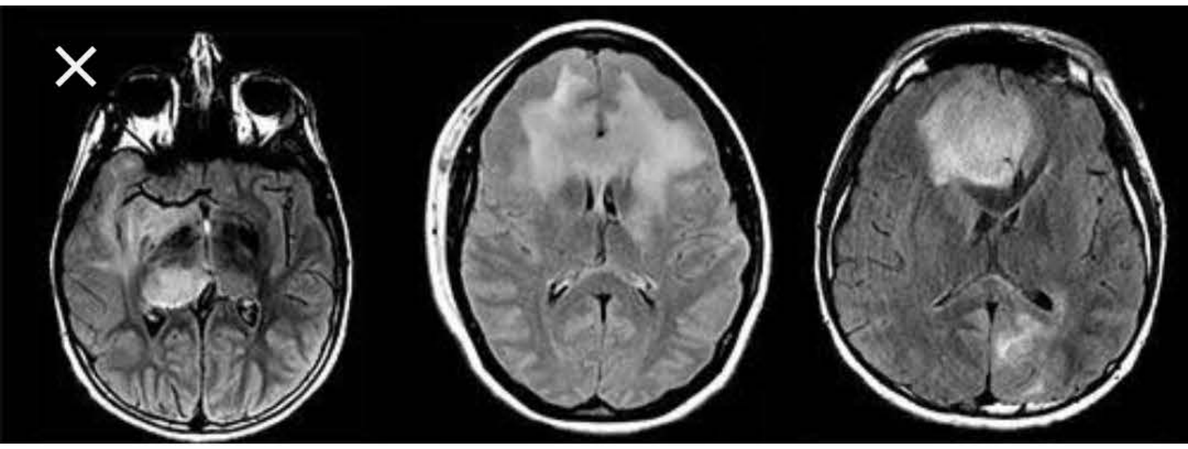

Gliomatosis Cerebri Intern...

Gliomatosis Cerebri | Gliomatosis Cerebri Internation...

Gliomatosis Cerebri

Images may be subject to copyright. Learn More

RELATED IMAGES

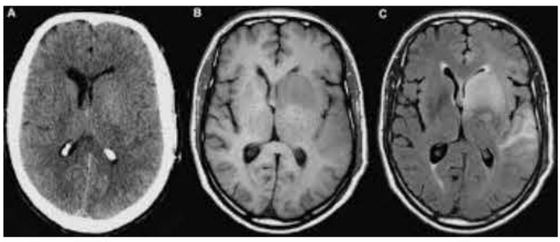

Gliomatosis cerebri, imaging ...
sciencedirect.com

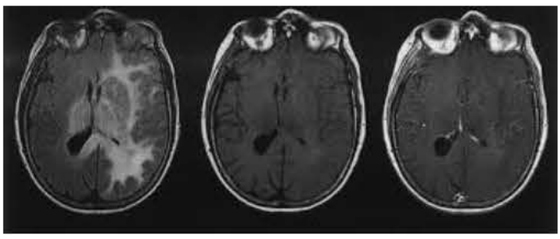

Proton MR Spectroscopy of G...
ajnr.org

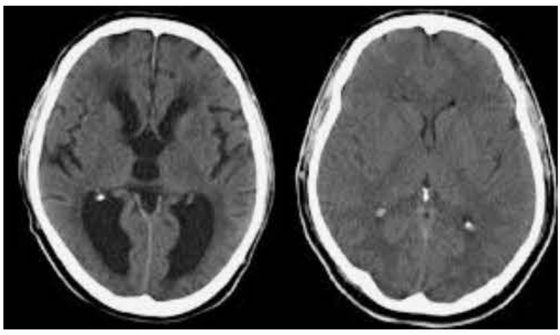

Pseudotumor Cerebri vs Hydr...
medlegalpro.com

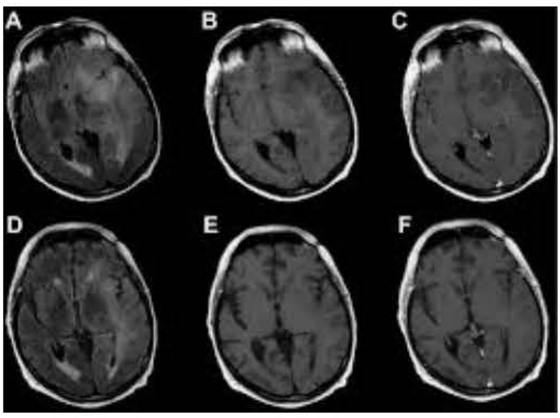

First Experiences with Low-d...
ar.iiarjournals.org

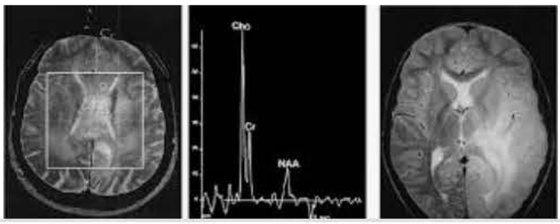

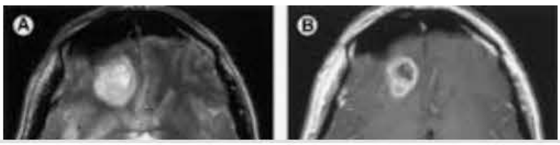

7:59

https://www.google.com/sea

16

URMC - University of Roch...

Gliomatosis Cerebri - Conditions - Neurooncology - Specialties ...

Gliomatosis Cerebri · Gliomatosis Cerebri

Images may be subject to copyright. Learn More

RELATED IMAGES

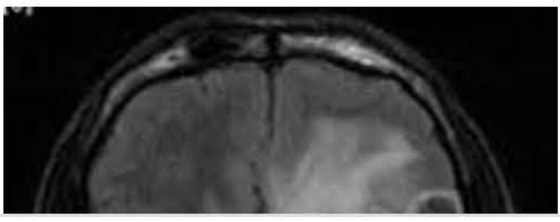

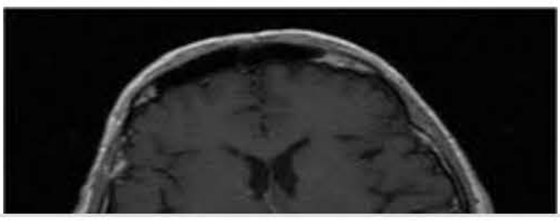

7:59

Images may be subject to copyright. Learn More

RELATED IMAGES

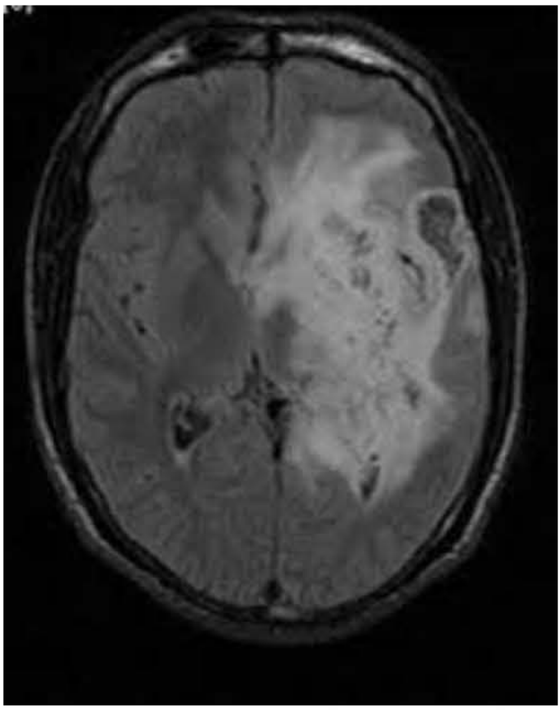

Gliomatosis Cerebri-MRI & M...
sumerdoc.blogspot.com

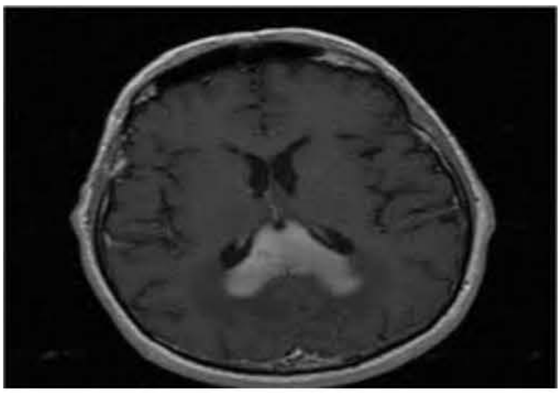

Glioblastoma Cerebri - Condit...
urmc.rochester.edu

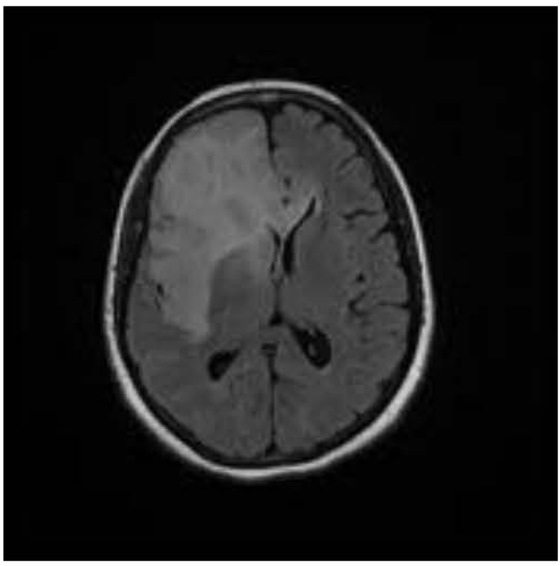

Gliomatosis cerebri | Radiolo...
radiopaedia.org

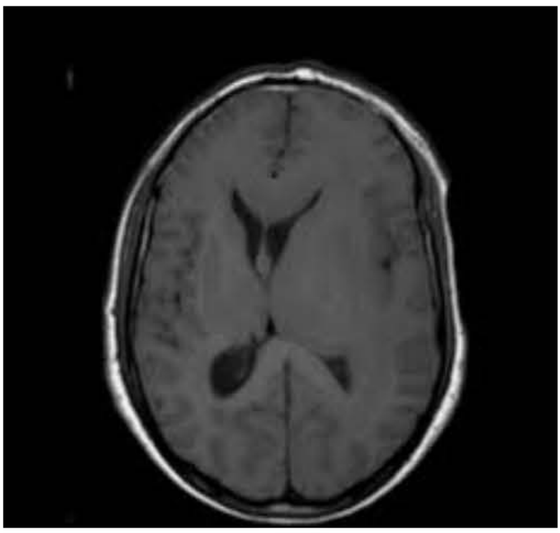

Radiology Quiz 40197 | Radio...
radiopaedia.org

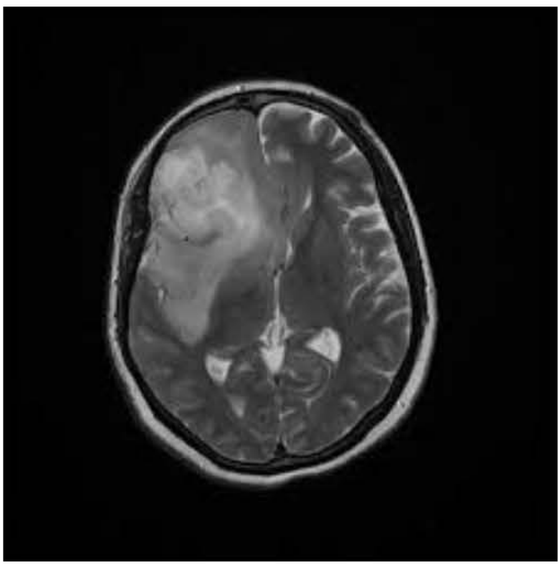

Gliomatosis cerebri | Radiolo...
radiopaedia.org

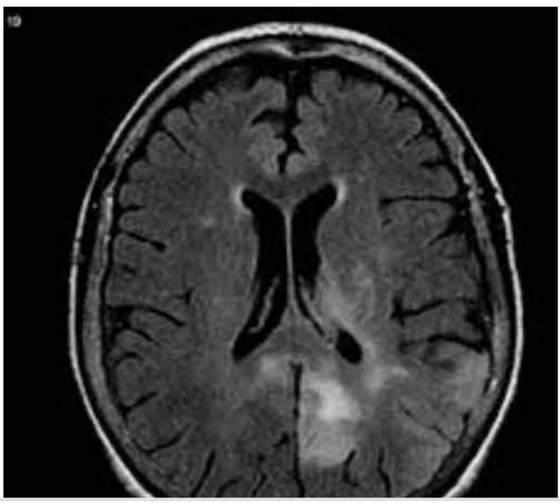

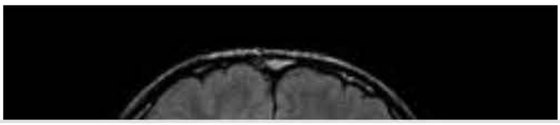

8:03

Diffuse large B-cell lymphoma (**DLBCL** or **DLBL**) is a cancer of B cells, a type of white blood cell responsible for producing antibodies. It is the most common type of non-Hodgkin lymphoma among adults,[1] with an annual incidence of 7–8 cases per 100,000 people per year in the USA and the UK.[2][3] This cancer occurs primarily in older individuals, with a median age of diagnosis at approximately 70 years of age,[3] though it can also occur in children and young adults in rare cases.[4] DLBCL is an aggressive tumor which can arise in virtually any part of the body,[5] and the first sign of this illness is typically the observation of a rapidly growing mass, sometimes associated with B symptoms—fever, weight loss, and night sweats.[6]

Diffuse large B cell lymphoma

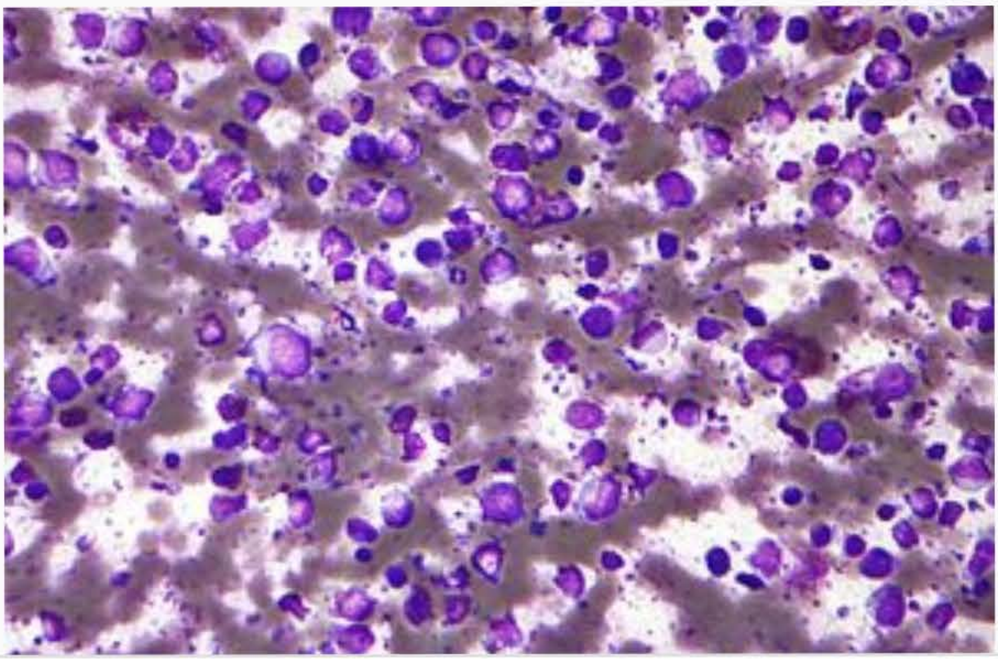

A 67-year-old carpenter was reviewed in an out-patient clinic complaining of weakness in his arms and 'twitching' of his thighs. His symptoms started 8 months ago when he noticed difficulties shelving heavy objects in his garage.

Three weeks ago, he noticed weakness affecting his left hand. His children have noticed that his speech has become slurred and that he is uncharacteristically tearful. He has lost 5 kg in weight in the past year. He has smoked 10 cigarettes a day for the past 25 years and drinks 5 pints of cider per week.

On examination, cranial-nerve examination was unremarkable with the exception of a mild dysarthria. Fasciculation was noted over both scapular regions with wasting of the small muscles of the right hand. Power was reduced in all muscle groups of the right upper limb. Examination of the lower limbs demonstrated fasciculation over the quadriceps bilaterally with difficulty rising from a low chair. Reflexes were symmetrically

was reduced in all muscle groups of the right upper limb. Examination of the lower limbs demonstrated fasciculation over the quadriceps bilaterally with difficulty rising from a low chair. Reflexes were symmetrically brisk, with bilateral extensor plantars. Examination of coordination and sensation was grossly normal.

Which one of the following investigations is most likely to confirm the suspected diagnosis?

A	Cerebrospinal fluid cytology
B	Anti-Hu antibody
C	MRI cervical spine
D	Nerve conduction studies and electromyography
E	Creatine kinase estimation

have noticed that his speech has become slurred and that he is uncharacteristically tearful. He has lost 5 kg in weight in the past year. He has smoked 10 cigarettes a day for the past 25 years and drinks 5 pints of cider per week.

On examination, cranial-nerve examination was unremarkable with the exception of a mild dysarthria. Fasciculation was noted over both scapular regions with wasting of the small muscles of the right hand. Power was reduced in all muscle groups of the right upper limb. Examination of the lower limbs demonstrated fasciculation over the quadriceps bilaterally with difficulty rising from a low chair. Reflexes were symmetrically brisk, with bilateral extensor plantars. Examination of coordination and sensation was grossly normal.

Which one of the following investigations is most likely to confirm the suspected diagnosis?

Your answer was correct

D Nerve conduction studies and electromyography

The clinical scenario is suggestive of motor neurone disease (MND) with mixed upper and lower motor neurone signs in the limbs. MND presents with asymmetrical weakness of the limbs, or with bulbar dysfunction. Deficits are often accompanied by leg cramps and fasciculation in the proximal limb muscles. Nerve conduction studies and electromyography are helpful in confirming the diagnosis and in excluding other potentially treatable conditions, notably multifocal motor neuropathy. Nerve conduction studies are normal in MND, although EMG shows fibrillation potentials and fasciculations. Imaging of the brain and cervical cord is important in excluding underlying inflammatory processes and compressive cervical myeloradiculopathy. A lumbar puncture is rarely needed, but can be useful for excluding an inflammatory or malignant process.

The case here is highly suggestive of MND, and a lumbar puncture is not usually needed. If there is a suspicion of malignant infiltration affecting nerve roots and spinal cord this test can be useful, although the diagnostic yield is actually quite low.

B Anti-Hu antibody

This is one of the paraneoplastic antibodies, most often associated with small cell lung cancer. Various neurological syndromes are seen with this antibody, most notably cerebellar degeneration or limbic encephalitis.

C MRI cervical spine

The signs here suggest upper and lower motor neurone involvement in the arms and the legs, plus possible brainstem involvement with the dysarthria. Thus, MRI of the cervical spine could not possibly reveal a unifying diagnosis.

A 20-year-old professional cyclist presents to the Neurology Clinic for review. He tells you that for the past few months he has noticed involuntary fasciculation, predominantly in his forearms and calves, over the past few months. This is particularly a problem after a long cycle ride.

On examination, he looks fit, and his BMI is 22. He has very well-demarcated limb musculature. Neurological examination is entirely normal.

Investigations:

Hb	13.1 g/dl
WCC	6.1×10^9/l
PLT	192×10^9/l
Na^+	140 mmol/l
K^+	4.5 mmol/l
Creatinine	82 μmol/l
ESR	9 mm/h
Electromyography (EMG)	Normal conduction

Na^+	140 mmol/l
K^+	4.5 mmol/l
Creatinine	82 μmol/l
ESR	9 mm/h
Electromyography (EMG)	Normal conduction velocity

Which of the following is the most likely diagnosis?

A	Amyotrophic lateral sclerosis
B	Polymyositis
C	Myotonic dystrophy
D	McArdle disease
E	Benign fasciculations

A 20-year-old professional cyclist presents to the Neurology Clinic for review. He tells you that for the past few months he has noticed involuntary fasciculation, predominantly in his forearms and calves, over the past few months. This is particularly a problem after a long cycle ride.

On examination, he looks fit, and his BMI is 22. He has very well-demarcated limb musculature. Neurological examination is entirely normal.

Investigations:

Hb	13.1 g/dl
WCC	6.1×10^9/l
PLT	192×10^9/l
Na^+	140 mmol/l
K^+	4.5 mmol/l
Creatinine	82 μmol/l
ESR	9 mm/h
Electromyography (EMG)	Normal conduction velocity

E Benign fasciculations

Benign fasciculations are relatively common in patients who have undergone a period of very strenuous exercise, and are also seen after an alcohol binge. The underlying cause of benign fasciculations is unclear, but it is thought that the activity is primarily generated by distal motor axons. Given that the fasiculations have occurred after exercise and he is otherwise well, the prognosis of this condition is entirely benign. Benzodiazepines are generally ineffective in the management of benign fasciculations, but carbamazepine and phenytoin are effective; in this case, however, pharmacotherapy is unnecessary.

D McArdle disease

This is glycogen storage disease type 5, which can lead to muscle necrosis during exercise, precipitating severe pain.

A Amyotrophic lateral sclerosis

Given that the fasciculations are confined to muscles which are utilised during cycling, and there are no other features, a benign cause is much more likely versus motor neurone disease here.

B Polymyositis

Polymyositis is associated with proximal myopathy with pain and other features, including elevated ESR and CK.

C Myotonic dystrophy

Myotonic dystrophy is an inherited condition associated with progressive muscle wasting and weakness, with delayed relaxation of grip due to myotonia. Frontal hair loss is a further feature.

21180

Rate this question:

An 18-year-old woman attends the Emergency Department with sudden-onset headache. She describes the headache as worst in the morning and exacerbated by coughing. There is associated nausea and diplopia.

Past medical history is unremarkable save for a recent episode of gastroenteritis. She is on no regular medication other than the oral contraceptive pill. Her BMI is elevated at 35. Acuity is 6/6 bilateral. There is mild bilateral papilloedema. She is unable to abduct her left eye. The remainder of her general and neurological examination is unremarkable. Plain computerised tomography (CT) is performed and this is reported as normal.

The results of cerebrospinal fluid (CSF) examination are:

Opening pressure	38 cm
Protein	0.12 g/l (0.15–0.45)
Glucose	4 mmol/l

Glucose	4 mmol/l
Xanthocromia	-
WBC	> 5/mm^3

Serum glucose is 6 mmol/l.

What is the next most important management step?

A	Commence intravenous dexamethasone
B	Perform CT-venography
C	Perform magnetic resonance imamging (MRI) of cervical spine
D	Commence intravenous acyclovir
E	Refer for neurosurgical opinion

An 18-year-old woman attends the Emergency Department with sudden-onset headache. She describes the headache as worst in the morning and exacerbated by coughing. There is associated nausea and diplopia.

Past medical history is unremarkable save for a recent episode of gastroenteritis. She is on no regular medication other than the oral contraceptive pill. Her BMI is elevated at 35. Acuity is 6/6 bilateral. There is mild bilateral papilloedema. She is unable to abduct her left eye. The remainder of her general and neurological examination is unremarkable. Plain computerised tomography (CT) is performed and this is reported as normal.

The results of cerebrospinal fluid (CSF) examination are:

Opening pressure	38 cm
Protein	0.12 g/l (0.15–0.45)
Glucose	4 mmol/l

B Perform CT-venography

The headache description is suggestive of raised intracranial pressure. Physical examination supports this diagnosis – the sixth nerve palsy is a 'false localising sign'. Negative initial imaging, and high cerebrospinal fluid (CSF) opening pressure and low protein, suggest idiopathic intracranial hypertension. However, this is a diagnosis of exclusion and the most important condition to rule out in this case is cerebral venous sinus thrombosis. Investigation of choice would be computerised tomography (CT) or magnetic resonance image (MRI) venography. Risk factors for venous sinus thrombosis include: dehydration (note recent gastroenteritis) and oral contraceptive pill or any other pro-thrombotic condition. Once the diagnosis is made, treatment is with anticoagulation. Regular monitoring of visual acuity and fields will be required initially. Loss of vision is a common sequel of intracranial hypertension (hence the

term benign intracranial hypertension is no longer considered appropriate).

A	Commence intravenous dexamethasone

Prednisolone may be useful in acute treatment of idiopathic intracranial hypertension, although it isn't of value in the treatment of a cerebral venous thrombosis.

C	Perform magnetic resonance imamging (MRI) of cervical spine

The 6th nerve palsy and raised CSF opening pressure count against the cervical spine as the cause of her symptoms.

D	Commence intravenous acyclovir

Herpes encephalitis is suggested by gradually decreasing consciousness and loss of memory/mood change

C	Perform magnetic resonance imamging (MRI) of cervical spine

The 6th nerve palsy and raised CSF opening pressure count against the cervical spine as the cause of her symptoms.

D	Commence intravenous acyclovir

Herpes encephalitis is suggested by gradually decreasing consciousness and loss of memory/mood change, rather than the localising signs seen here.

E	Refer for neurosurgical opinion

Without a diagnosis (i.e. ruling out a venous thrombosis first), referral to the neurosurgeons is not appropriate.

7339

Rate this question:

A 65-year-old diabetic man has recovered from a lacunar stroke. On discharge from the Stroke Unit, he was commenced on simvastatin, aspirin and perindopril. Regular medications prior to the event included metformin, allopurinol and quinine.

On return home, he was meticulous about secondary prevention using nicotine replacement patches to help him stop smoking, exercising regularly, and changing his diet to include fresh fruit and red wine.

At clinic review, he complains of tender calves, thighs and shoulders.

Blood testing reveals:

Creatine kinase	1055 IU/l (23–175)
Aspartate aminotransferase	222 IU/l (10–40)
Alanine aminotransferase	184 IU/l (5–30)

Which factor in his diet is most likely to have caused this problem?

tender calves, thighs and shoulders.

Blood testing reveals:

Creatine kinase	1055 IU/l (23–175)
Aspartate aminotransferase	222 IU/l (10–40)
Alanine aminotransferase	184 IU/l (5–30)

Which factor in his diet is most likely to have caused this problem?

A Orange juice

B Red wine

C Grapefruit juice

D Multivitamins

E Kippers

C Grapefruit juice

The blood results indicate moderate–severe muscle damage and a high risk of rhabdomyolysis. The statins are associated with a spectrum of muscle pathologies, from asymptomatic elevation of creatine kinase, through myositis to frank rhabdomyolysis. Interactions with other medications often precipitate the problem. Well-recognised interactions include certain antibiotics (e.g. macrolides), grapefruit juice, immunosuppressants (e.g. ciclosporin) and fibrates. It is known that increasing age, renal impairment and diabetes further increase the risk.

A Orange juice

This does not interact with statins or cause muscle damage directly.

B Red wine

This does not interact with statins or

cause muscle damage directly.

B Red wine

This does not interact with statins or cause muscle damage directly. Excess alcohol may result in a myopathy, but this does not usually produce a significantly elevated CK.

D Multivitamins

These do not interact with statins or cause muscle damage directly, assuming they are regular over-the-counter multivitamins. Some dietary supplements (especially body-building supplements) have been implicated in causing health problems, including liver damage.

E Kippers

These do not interact with statins or cause muscle damage directly.

A 42-year-old woman presents with progressively severe fatigue. She is a heavy smoker of 40 cigarettes per day and suffers from type 1 diabetes. There have been previous intermittent episodes of dizziness and unsteadiness, which largely resolved spontaneously. Her GP had diagnosed recurrent vestibular neuronitis. She has been prescribed a tricyclic anti-depressant for the past 6 months.

On examination, there were some signs of cerebellar dysfunction. MRI brain revealed hypo-intense areas on the T1-weighted scan, and a number of hyper-intense lesions on the T2-weighted scan in the periventricular areas and brain stem.

What is the most likely diagnosis?

A	Cerebrovascular disease
B	Multiple sclerosis
C	Cerebral vasculitis

recurrent vestibular neuronitis. She has been prescribed a tricyclic anti-depressant for the past 6 months.

On examination, there were some signs of cerebellar dysfunction. MRI brain revealed hypo-intense areas on the T1-weighted scan, and a number of hyper-intense lesions on the T2-weighted scan in the periventricular areas and brain stem.

What is the most likely diagnosis?

A	Cerebrovascular disease
B	Multiple sclerosis
C	Cerebral vasculitis
D	Encephalitis
E	Central pontine myelinolysis

A 42-year-old woman presents with progressively severe fatigue. She is a heavy smoker of 40 cigarettes per day and suffers from type 1 diabetes. There have been previous intermittent episodes of dizziness and unsteadiness, which largely resolved spontaneously. Her GP had diagnosed recurrent vestibular neuronitis. She has been prescribed a tricyclic anti-depressant for the past 6 months.

On examination, there were some signs of cerebellar dysfunction. MRI brain revealed hypo-intense areas on the T1-weighted scan, and a number of hyper-intense lesions on the T2-weighted scan in the periventricular areas and brain stem.

What is the most likely diagnosis?

Your answer was correct

A	Cerebrovascular disease

B Multiple sclerosis

The relapsing and remitting history, coupled with multiple changes on the T_1- and T_2-weighted scans, are highly suggestive of multiple sclerosis (MS). Fatigue is an extremely common symptom in MS and can occasionally be what brings the disease to attention.

A Cerebrovascular disease

Although this lady has vascular risk factors in the form of smoking and diabetes, this is still a relatively young age to present with symptomatic cerebrovascular disease. Overall the history of episodic neurological dysfunction and fatigue favours MS. Often the distribution and nature of white matter signal change on MRI scanning is able to differentiate between vascular and demyelinating disease, but when there is doubt a lumbar puncture can be performed as oligoclonal bands are found in most

oligoclonal bands are found in most patients with MS and are not seen in vascular disease.

C	Cerebral vasculitis

This might form part of the differential diagnosis depending on the precise nature of the signal change seen on MRI. However, cerebral vasculitis is extremely rare compared to MS, so is a less appropriate answer here.

D	Encephalitis

'Encephalitis' is a non-specific term simply meaning inflammation of the brain. Many different conditions can cause this, although the most frequently encountered are autoimmune (usually antibody mediated) or infective (most commonly herpes simplex 1). The principle symptoms are headache, confusion, seizures and fever.

E	Central pontine myelinolysis

'Encephalitis' is a non-specific term simply meaning inflammation of the brain. Many different conditions can cause this, although the most frequently encountered are autoimmune (usually antibody mediated) or infective (most commonly herpes simplex 1). The principle symptoms are headache, confusion, seizures and fever.

E	Central pontine myelinolysis

This condition is most frequently associated with rapid shifts in serum sodium concentration, and presents with signs of brainstem dysfunction. MRI scanning reveals high signal T2 change in the mid-pons.

9272

Rate this question:

8:30

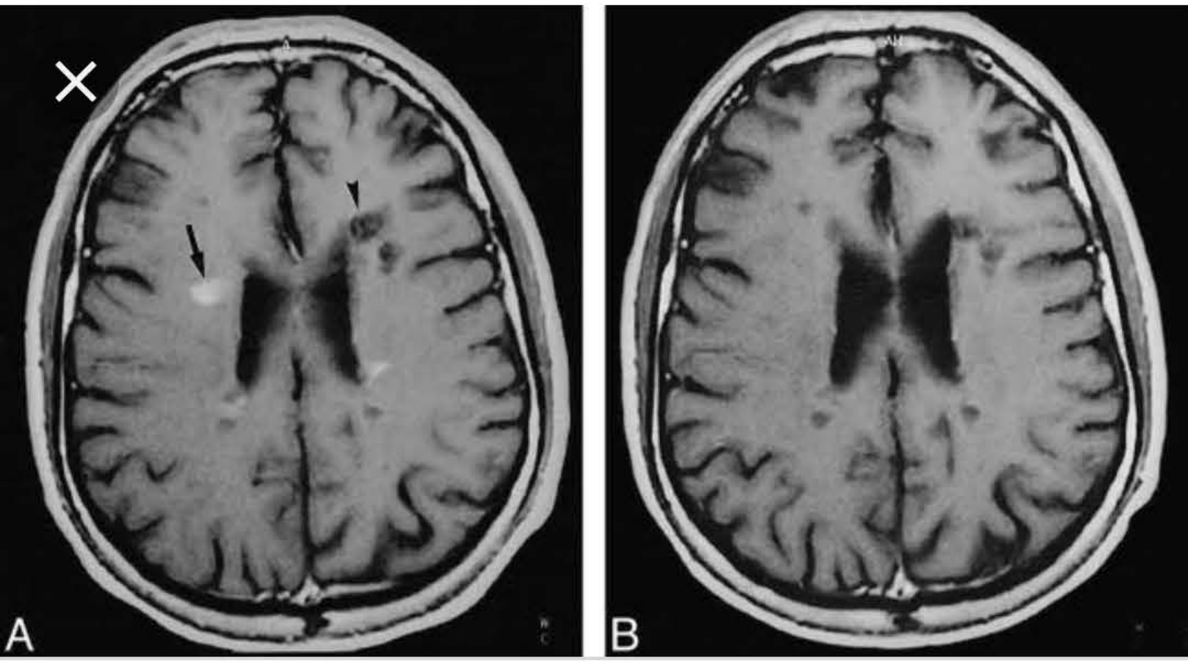

American Journal of Neur...

Evolution of Multiple Sclerosis Lesions on Serial Contrast ...

fig 4.

Images may be subject to copyright. Learn More

RELATED IMAGES

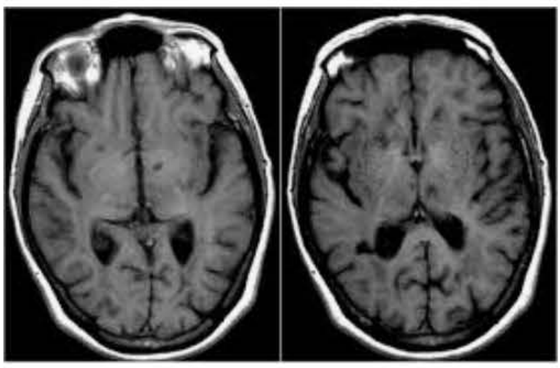

T1 weighted magnetic resona...
researchgate.net

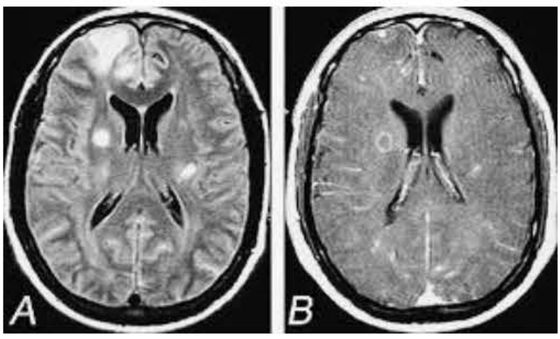

Cryptococcosis. A, Axial FLAI...
researchgate.net

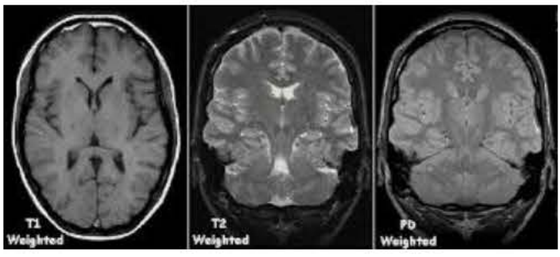

File:T1t2PD.jpg - Wikimedia C...
commons.wikimedia.org

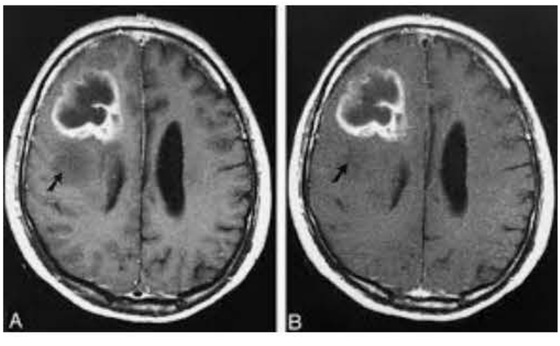

fig 2. | Contrast Enhancement...
ajnr.org

A 30-year-old woman attends a Walk-in Medical Centre accompanied by her friend, who is concerned since she has noticed the patient has developed occasional slurring of speech associated with reduced facial expressions. The patient herself also complains of intermittent regurgitation of food through her nose, a situation that she has found to be terribly embarrassing. She also reports difficulty reading and complains of double vision after short periods of time when attempting to read a book.

Her symptoms tend to be worst at the end of the day. The patient maintains that she has always been in good health and has not seen a doctor for over 10 years. She is not on any medication and is a non-smoker.

Which of the following would be LEAST helpful in your clinical examination of this patient?

A	Glabellar tap

double vision after short periods of time when attempting to read a book.

Her symptoms tend to be worst at the end of the day. The patient maintains that she has always been in good health and has not seen a doctor for over 10 years. She is not on any medication and is a non-smoker.

Which of the following would be LEAST helpful in your clinical examination of this patient?

A	Glabellar tap
B	Ice-pack test
C	Ask the patient to look up for one minute
D	Assessing speech with prolonged counting
E	Testing for diplopia

A 30-year-old woman attends a Walk-in Medical Centre accompanied by her friend, who is concerned since she has noticed the patient has developed occasional slurring of speech associated with reduced facial expressions. The patient herself also complains of intermittent regurgitation of food through her nose, a situation that she has found to be terribly embarrassing. She also reports difficulty reading and complains of double vision after short periods of time when attempting to read a book.

Her symptoms tend to be worst at the end of the day. The patient maintains that she has always been in good health and has not seen a doctor for over 10 years. She is not on any medication and is a non-smoker.

Which of the following would be LEAST helpful in your clinical examination of this patient?

Your answer was correct

A Glabellar tap

The diagnosis in this case is myasthenia gravis (MG), which is an autoimmune disorder characterised by the formation of antibodies against acetylcholine (ACh) receptors. Patients typically present with painless weakness that becomes worse on repetitive movement or activity. Patients may complain of general weakness, ptosis, diplopia, dysphagia and difficulty chewing, especially tough foods such as meat. The condition is slightly more prevalent in females. The range of presentations is wide and depends on the severity of the disease. Thyroid disorders may be seen in as many as 10% of patients with MG. The diagnosis is based on the characteristic history and general examination and two positive tests, preferably serological (serum anti-ACh antibodies) and electrodiagnostic (e.g. repetitive nerve stimulation). Treatment modalities include cholinesterase inhibitors, immunosuppressive drugs,

plasmapheresis and immunotherapy.

Glabellar tap is an examination sometimes performed in patients with suspected Parkinson's disease. The forehead is repetitively tapped; in a normal test, patients will blink on only the first two to three taps then stop. Persistent blinking is a sign of frontal release and may be seen in patients with Parkinson's disease, although this also occurs in other neurodegenerative diseases. It is not seen in MG.

B	Ice-pack test

In patients with MG, application of an ice pack for several minutes to the patient's eyelids can result in improvement of ptosis. This transient improvement occurs as the cooling results in slower breakdown of acetylcholine at the neuromuscular junction.

C	Ask the patient to look up for one minute

improvement occurs as the cooling results in slower breakdown of acetylcholine at the neuromuscular junction.

C	Ask the patient to look up for one minute

This test will demonstrate fatiguability of eye movements and may reveal fatigable ptosis.

D	Assessing speech with prolonged counting

This may reveal fatigable dysarthria, seen in some patients with myasthenia.

E	Testing for diplopia

This is a vital test as patients with MG often have complex ophthalmoplegias that can result in diplopia. The diplopia would be worse on repetitive testing.

7638

Rate this question:

A 24-year-old male jockey had recently bought a new pair of boots and a saddle for his horse. He had a long history of low back pain and his general practitioner (GP) had given him analgesics intermittently. He had just returned from an exhausting horse race, in which his horse had won.

As he got down from the saddle, he felt an excruciating pain in his right leg and he was not able to walk.

On examination, he had a right foot drop, and the evertors and dorsiflexors of the right ankle were 2/5 and inversion of both ankles was 5/5. The straight leg-raising test was 80° on both sides. Tendon reflexes were normal. Pinprick was diminished over the right foot.

Choose the most likely diagnosis

A	Right L5 radiculopathy
B	Right common peroneal nerve palsy

and he was not able to walk.

On examination, he had a right foot drop, and the evertors and dorsiflexors of the right ankle were 2/5 and inversion of both ankles was 5/5. The straight leg-raising test was 80° on both sides. Tendon reflexes were normal. Pinprick was diminished over the right foot.

Choose the most likely diagnosis

A	Right L5 radiculopathy
B	Right common peroneal nerve palsy
C	Right lumbar plexopathy
D	Right femoral nerve palsy
E	Right sural nerve palsy

6:31
:tps://mypastest.pastest.com 16

As he got down from the saddle, he felt an excruciating pain in his right leg and he was not able to walk.

On examination, he had a right foot drop, and the evertors and dorsiflexors of the right ankle were 2/5 and inversion of both ankles was 5/5. The straight leg-raising test was 80° on both sides. Tendon reflexes were normal. Pinprick was diminished over the right foot.

Choose the most likely diagnosis

Your answer was correct

A	Right L5 radiculopathy
B	Right common peroneal nerve palsy
C	Right lumbar plexopathy

B Right common peroneal nerve palsy

The common peroneal nerve swings round the head of fibula to the anterior aspect of the leg giving off the superficial peroneal nerve which provides branches to the peroneal muscles and deep peroneal nerve, which supplies branches to the dorsiflexors of the foot and toes. It carries sensory fibres from the dorsum of the foot and the lateral aspect of the leg. Compression may occur during an operation, from obstetric stirrups, tight knee boots (as in this case) or fracture of the upper end of fibula.

A Right L5 radiculopathy

This also causes weakness of foot inversion. In addition, one might expect back pain with an acute nerve root lesion.

C Right lumbar plexopathy

inversion. In addition, one might expect back pain with an acute nerve root lesion.

C	Right lumbar plexopathy

That would have caused more diffuse weakness and reflex changes.

D	Right femoral nerve palsy

Damage to the femoral nerve leads to weakness of the quadriceps and loss of knee jerk.

E	Right sural nerve palsy

The sural nerve is a sensory nerve and does not cause motor weakness.

7219

Rate this question:

A 52-year-old woman presents to her general practitioner with recurring headaches.

He refers her as an emergency to your clinic after observing the fundal appearance shown below.

What is the most likely diagnosis?

A	Hypertensive retinopathy
B	Retinitis pigmentosa
C	Optic neuritis
D	Diabetic retinopathy

clinic after observing the fundal appearance shown below.

What is the most likely diagnosis?

A	Hypertensive retinopathy
B	Retinitis pigmentosa
C	Optic neuritis
D	Diabetic retinopathy
E	Central retinal vein occlusion

A Hypertensive retinopathy

This is severe (stage III) retinopathy occurring as the result of previously undiagnosed hypertension.
The stages are classified as:

- Stage I – focal/diffuse thinning of arterioles relative to venules
- Stage II – obvious arteriolar narrowing with focal areas of attenuation. Vessels with a wide light reflex exhibit 'copper wiring'. As the vessels become fibrotic, the light reflex becomes a thin white stripe, a phenomenon known as 'silver-wiring'. Continued thickening of the arterioles causes indentation of the venule in the common adventitial arteriovenous (AV) sheath, referred to as A–V nipping
- Stage III – Stage II plus cotton wool spots, exudates, and

- Stage III – Stage II plus cotton wool spots, exudates, and haemorrhages
- Stage IV – Stage III plus swollen optic disc resembling papilloedema.

Stages I and II are similar to arteriosclerosis of ageing. Stages III and IV are medical emergencies referred to as malignant hypertension, which is a rare but serious cause of headache.

B	Retinitis pigmentosa

The image reveals changes of severe hypertensive retinopathy. Retinitis pigmentosa presents with visual failure rather than headache.

C	Optic neuritis

The image reveals changes of severe hypertensive retinopathy. Optic neuritis presents with visual blurring

C Optic neuritis

The image reveals changes of severe hypertensive retinopathy. Optic neuritis presents with visual blurring and there may be retro-orbital pain and discomfort. On fundoscopy things may look normal or there may be optic nerve head swelling.

D Diabetic retinopathy

The image reveals changes of severe hypertensive retinopathy. Diabetic retinopathy presents with visual failure rather than headache.

E Central retinal vein occlusion

This presents with sudden monocular visual loss and the retina has a congested, 'stormy' appearance.

6334

Rate this question:

6:37
You
Just now
10:08 PM
1.26K/s
44%
Post
dr_rosecool

e 4 hypertensive retino

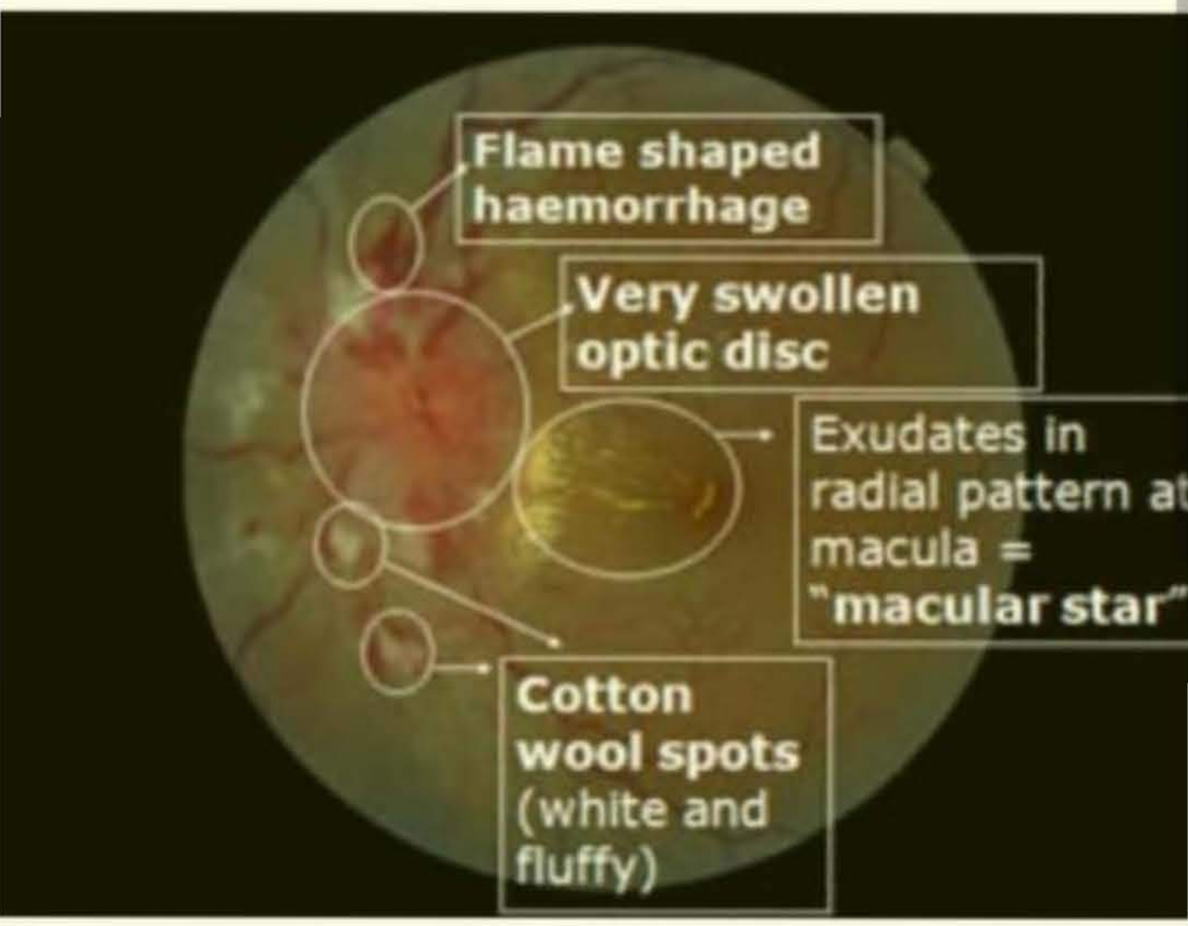

A right-handed smoker is referred by his general practitioner for assessment of likely stroke. His wife describes a sudden onset of left-sided weakness and bumping into objects on the left.

On examination, you note left-sided motor weakness sensory inattention and a possible field defect. The patient's agitation prevents you from characterising the field defect further. You admit him to the wards and organise brain imaging. While awaiting imaging he is assessed by the neuro-ophthalmology team and visual fields are formally plotted.

Which of the following visual field defect do you expect?

A	Macular sparing homonymous hemianopia
B	Non-congruent homonymous hemianopia with no macular sparing
C	Bitemporal hemianopia

On examination, you note left-sided motor weakness sensory inattention and a possible field defect. The patient's agitation prevents you from characterising the field defect further. You admit him to the wards and organise brain imaging. While awaiting imaging he is assessed by the neuro-ophthalmology team and visual fields are formally plotted.

Which of the following visual field defect do you expect?

A	Macular sparing homonymous hemianopia
B	Non-congruent homonymous hemianopia with no macular sparing
C	Bitemporal hemianopia
D	Inferior quadrantanopia
E	Superior quadrantanopia

A right-handed smoker is referred by his general practitioner for assessment of likely stroke. His wife describes a sudden onset of left-sided weakness and bumping into objects on the left.

On examination, you note left-sided motor weakness sensory inattention and a possible field defect. The patient's agitation prevents you from characterising the field defect further. You admit him to the wards and organise brain imaging. While awaiting imaging he is assessed by the neuro-ophthalmology team and visual fields are formally plotted.

Which of the following visual field defect do you expect?

Your answer was incorrect

A	Macular sparing homonymous hemianopia
B	Non-congruent homonymous hemianopia with no macular

D Inferior quadrantanopia

Optic fibres travel from the lateral geniculate nucleus through the optic radiations to the visual cortex of the occipital lobe. Optic fibres of the lower visual fields pass superiorly through the parietal lobe, while upper fields pass through the temporal lobe (Meyer's loop). Thus a lesion involving parietal cortex will produce a homonymous inferior quadrantanopia. This patient has evidence of non-dominant frontal (weakness) and parietal lobe involvement (sensory inattention) making this the most likely answer.

C Bitemporal hemianopia

A bitemporal hemianopia is caused by a lesion affecting the nasal fibres of the optic nerves in both eyes at the optic chiasm. It is unlikely due to a stroke and anatomically would not fit with this patient's other symptoms.

A Macular sparing homonymous

A	Macular sparing homonymous hemianopia

The posterior cerebral artery is the main blood supply to the occipital lobe, but a branch of the middle cerebral artery supplements the circulation at the occipital pole, where the macular is represented. Therefore, in posterior cerebral artery occlusion the contribution from the middle cerebral artery may prevent infarction of the pole, giving a homonymous hemianopia with macular sparing.

B	Non-congruent homonymous hemianopia with no macular sparing

Congruent field defects are identical homonymous defects in the fields of both eyes, and conversely when not identical in both eyes, they are incongruent. It is classically believed that congruity of a hemianopic defect suggests a lesion in the visual cortex or posterior visual radiations, whereas incongruity suggests a lesion in the

suggests a lesion in the visual cortex or posterior visual radiations, whereas incongruity suggests a lesion in the anterior visual radiations or the optic tract (i.e. the more congruent the homonymous hemianopia, the more posterior is the lesion). However, this rule should be used cautiously; at least 50% of lesions in other locations also produce congruent homonymous hemianopia, especially if these lesions are stroke-related [*Kedar S. Am J Ophth. 2007;143(5):772-80*].

E	Superior quadrantanopia

Lesions to the contralateral temporal lobe will affect the optic radiation, giving rise to a homonymous superior quadrantanopia. This patient has signs consistent with frontal and parietal cortical involvement, but no temporal lobe signs making this answer less likely.

7350

Rate this question:

Next Question

A 17-year-old Chinese man was brought to the Accident and Emergency Department on a stretcher as he was found lying on the floor of his apartment unable to move by his neighbour. He had participated in a 10-mile race at a local club, the day before and had eaten a full vanilla ice cream cake before retiring to bed. He got up around 0300 h to go to the toilet and noticed heaviness in his limbs. He could hardly get up from the toilet seat and finally fell on the carpet of his living room. Over the past few weeks, he has suffered from increasing palpitations and anxiety about work related matters.

On examination, he was of thin build and apprehensive. He gave a succinct account of the evolution of his illness. Pulse was 100/min and irregularly irregular. Blood pressure was 120/80 mmHg. Cranial nerves were unremarkable. Neck muscle power was 4/5. Shoulder girdle, truncal and pelvic girdle muscles 3/5. Tendon reflexes were hypoactive and plantar were mute. Sensation was preserved.

On examination, he was of thin build and apprehensive. He gave a succinct account of the evolution of his illness. Pulse was 100/min and irregularly irregular. Blood pressure was 120/80 mmHg. Cranial nerves were unremarkable. Neck muscle power was 4/5. Shoulder girdle, truncal and pelvic girdle muscles 3/5. Tendon reflexes were hypoactive and plantar were mute. Sensation was preserved.

What is the most likely diagnosis?

A	Guillain–Barré syndrome
B	Transverse myelitis
C	Polymyositis
D	Periodic paralysis
E	Embolic stroke

A 17-year-old Chinese man was brought to the Accident and Emergency Department on a stretcher as he was found lying on the floor of his apartment unable to move by his neighbour. He had participated in a 10-mile race at a local club, the day before and had eaten a full vanilla ice cream cake before retiring to bed. He got up around 0300 h to go to the toilet and noticed heaviness in his limbs. He could hardly get up from the toilet seat and finally fell on the carpet of his living room. Over the past few weeks, he has suffered from increasing palpitations and anxiety about work related matters.

On examination, he was of thin build and apprehensive. He gave a succinct account of the evolution of his illness. Pulse was 100/min and irregularly irregular. Blood pressure was 120/80 mmHg. Cranial nerves were unremarkable. Neck muscle power was 4/5. Shoulder girdle, truncal and pelvic girdle muscles 3/5. Tendon reflexes were hypoactive and plantar were mute. Sensation was preserved.

D Periodic paralysis

Thyrotoxicosis with hypokalaemic periodic paralysis has a higher prevalence in people of Chinese and Japanese extraction. The paralytic disorder is unrelated to the severity of hyperthyroid state. Clinically the attacks are similar to those of familial hypokalaemic periodic paralysis, and there is genetic homology between the two conditions. Typical attacks consist of proximal weakness and come on during the second half of the night, after a day of unusually strenuous exercise. A meal rich in carbohydrate may also precipitate the attack. Potassium chloride restores muscle power to normal and treatment of hyperthyroidism prevents further attacks. In this case routine venous bloods on admission are likely to reveal significant hypokalaemia.

A Guillain–Barré syndrome

The proximal pattern of weakness and

A Guillain-Barre syndrome

The proximal pattern of weakness and normal sensation suggest GBS is a less likely diagnosis.

B Transverse myelitis

The lack of upper motor neurone signs and preserved sensation make this diagnosis less likely.

C Polymyositis

This is a reasonable differential diagnosis given the proximal pattern of weakness and normal sensation. However, the very rapid onset makes a periodic paralysis disorder more likely.

E Embolic stroke

The lack of upper motor neurone signs and symmetry of the weakness make any form of embolic stroke very unlikely

A 42-year-old man attends the clinic with his wife. He has a long past history of severe migraines, but most recently his wife has become very concerned as she has noticed a change in his behaviour, with increased aggression. Last month he attended the Emergency Department with transient weakness of the left side of his face, which resolved after a few hours. Apparently, he had a similar attack involving the right-hand side of his face a year ago, but this too resolved.

On examination, his BP is 155/85 mmHg. He looks depressed. There is gait apraxia with mild limb rigidity. He has brisk reflexes throughout with bilateral extensor plantar responses. He is cognitively slow.

Investigations:

Hb	12.4 g/dl
WCC	6.2×10^9/l
PLT	201×10^9/l
Na^+	140 mmol/l

WCC	6.2×10^9/l
PLT	201×10^9/l
Na^+	140 mmol/l
K^+	4.5 mmol/l
Creatinine	130 μmol/l
Glucose	4.9 mmol/l

Which of the following would be most useful to confirm the underlying diagnosis?

A ApoE4 genetic testing

B NOTCH-3 genetic testing

C MRI brain

D HIV testing

E Skin biopsy

A 42-year-old man attends the clinic with his wife. He has a long past history of severe migraines, but most recently his wife has become very concerned as she has noticed a change in his behaviour, with increased aggression. Last month he attended the Emergency Department with transient weakness of the left side of his face, which resolved after a few hours. Apparently, he had a similar attack involving the right-hand side of his face a year ago, but this too resolved.

On examination, his BP is 155/85 mmHg. He looks depressed. There is gait apraxia with mild limb rigidity. He has brisk reflexes throughout with bilateral extensor plantar responses. He is cognitively slow.

Investigations:

Hb	12.4 g/dl
WCC	6.2×10^9/l

B NOTCH-3 genetic testing

This history of migraine, followed by behavioural and cognitive changes suggestive of frontal lobe involvement, and multiple TIAs is suggestive of cerebral autosomal dominant arteriopathy with subcortical infarcts and leukoencephalopathy (CADASIL). MRI of the brain shows periventricular and deep white matter hyper-intensities on T2-weighted scan, with involvement of the temporal poles, but the scan is not, in itself, diagnostic. As such, the optimal investigation is NOTCH-3 genetic testing, with more than 90% of patients with CADASIL having mutations in the NOTCH-3 gene.

A ApoE4 genetic testing

ApoE4 is the main genetic risk factor in Alzheimer's disease. However, it is not causative – possession of one or more E4 alleles merely confers greater risk of the condition. ApoE4 testing is

risk of the condition. ApoE4 testing is not routinely performed in the diagnosis of Alzheimer's disease. In any event, this patient's clinical presentation is in no way suggestive of Alzheimer's.

C	MRI brain

This would be an entirely reasonable investigation to perform in this sort of case. However, because the history here suggests CADASIL, MRI will not be able to 'confirm the underlying diagnosis' – which is what the question asks.

D	HIV testing

It would be reasonable to exclude HIV in patients presenting with early-onset cognitive/behavioural change. However, the features in this case point to an alternative diagnosis, namely CADASIL, so NOTCH-3 testing is the better answer.

investigation to perform in this sort of case. However, because the history here suggests CADASIL, MRI will not be able to 'confirm the underlying diagnosis' – which is what the question asks.

D	HIV testing

It would be reasonable to exclude HIV in patients presenting with early-onset cognitive/behavioural change. However, the features in this case point to an alternative diagnosis, namely CADASIL, so NOTCH-3 testing is the better answer.

E	Skin biopsy

A small proportion of patients with CADASIL do not have a detectable mutation in NOTCH-3, and in such cases a skin biopsy can be performed to demonstrate histological evidence of the condition.

21457

Rate this question:

A 37-year-old bricklayer presented with a history of increasing difficulty in mixing cement and holding bricks with his right hand, for the past several months. He did not recall any trauma of note. However, he has been concerned about crepitus in his neck for nearly seven years.

On examination, some of the small muscles of his right hand were wasted, and a 3/5 weakness of the adductor pollicis, dorsal interossei, palmar interossei and abductor digiti minimi was noted. Tendon reflexes were normal (++/++) for all limbs. Pin-prick and light touch sensation were dulled over the hypothenar eminence.

What is the likely underlying pathology?

A	C8 cervical radiculopathy
B	Syringomyelia
C	Motor neurone disease

for nearly seven years.

On examination, some of the small muscles of his right hand were wasted, and a 3/5 weakness of the adductor pollicis, dorsal interossei, palmar interossei and abductor digiti minimi was noted. Tendon reflexes were normal (++/++) for all limbs. Pin-prick and light touch sensation were dulled over the hypothenar eminence.

What is the likely underlying pathology?

A	C8 cervical radiculopathy
B	Syringomyelia
C	Motor neurone disease
D	Ulnar nerve palsy
E	Brachial plexopathy

his right hand, for the past several months. He did not recall any trauma of note. However, he has been concerned about crepitus in his neck for nearly seven years.

On examination, some of the small muscles of his right hand were wasted, and a 3/5 weakness of the adductor pollicis, dorsal interossei, palmar interossei and abductor digiti minimi was noted. Tendon reflexes were normal (++/++) for all limbs. Pin-prick and light touch sensation were dulled over the hypothenar eminence.

What is the likely underlying pathology?

Your answer was correct

A	C8 cervical radiculopathy
B	Syringomyelia
C	Motor neurone disease
D	Ulnar nerve palsy

D Ulnar nerve palsy

The ulnar nerve innervates the ulnar flexors of the wrist, the ulnar half of the flexor digitorum profundus, the adductors and abductors of the fingers, the adductor policis, the 3rd and 4th lumbricals and muscles of the hypothenar eminance. Complete ulnar palsy presents with a claw hand. Sensory loss occurs typically over the ulnar border of the hand, 5th finger and ulnar half of the 4th. It may be compressed at the elbow, under the aponeurosis of the flexor carpi ulnaris (cubital tunnel) or distally at the wrist, when no sensory loss is demonstrable.

A C8 cervical radiculopathy

This is associated with neck pain and also with weakness of flexion of the index and middle finger.

B Syringomyelia

This is associated with sensory loss in a

B Syringomyelia

This is associated with sensory loss in a cape-like distribution, the hands may be wasted and there can be upper motor neurone signs in the lower limbs.

C Motor neurone disease

This is associated with pure motor loss. There is typically a combination of upper motor neurone signs (increased tone, brisk reflexes) and lower motor neurone signs (wasting, fasciculation).

E Brachial plexopathy

This is often associated with pain over the shoulder and posterior neck, not seen here. In addition, the weakness and sensory loss would not be limited to ulnar-innervated areas.

7220

Rate this question:

A 47-year-old man attends the Neurology Clinic. He first presented to the clinic 20 years ago with classical migraine that was difficult to control. In the last 5 years he has had three admissions with stroke, and a prolonged admission to the Psychiatry Ward for treatment-resistant depression. He has a family history of migraine and early-onset cerebrovascular and ischaemic heart disease.

On formal mental state testing, he performs poorly. A magnetic resonance image (MRI) of the brain shows a number of subcortical infarcts. He has none of the classical risk factors for cerebrovascular disease.

Which of the following best describes the likely genetics of this man's stroke syndrome?

A	X-linked inheritance
B	Mitochondrial inheritance

depression. He has a family history of migraine and early-onset cerebrovascular and ischaemic heart disease.

On formal mental state testing, he performs poorly. A magnetic resonance image (MRI) of the brain shows a number of subcortical infarcts. He has none of the classical risk factors for cerebrovascular disease.

Which of the following best describes the likely genetics of this man's stroke syndrome?

A	X-linked inheritance
B	Mitochondrial inheritance
C	Trinucleotide repeat disorder
D	Autosomal dominant
E	Autosomal recessive

D Autosomal dominant

This is the syndrome of CADASIL (cerebral autosomal dominant arteriopathy with subcortical infarcts and leukoencephalopathy). First recognised around 20 years ago, it has stimulated great interest in the stroke community as increasing numbers of cases are reported. Clinical features are as described above: migraine with aura, followed by multiple infarcts, mood disturbance and cognitive impairment. Diagnosis is based on history and imaging, supported by genetic testing and electron microscopy of a skin biopsy. There is no consensus on treatment and prognosis is poor, with severe dementia often evident 20 years from first symptoms.

A X-linked inheritance

X-linked causes of adult-onset ataxia and dementia exist, as does X-linked adult adrenoleukodystrophy. The

and dementia exist, as does X-linked adult adrenoleukodystrophy. The clinical picture described here is, however, more consistent with CADASIL.

B	Mitochondrial inheritance

Mitochondrial dysfunction is thought to be associated with early onset and progression of Alzheimer's disease, but isn't thought to be associated with CADASIL.

C	Trinucleotide repeat disorder

Trinucleotide repeats are the underlying cause of Huntington's chorea.

E	Autosomal recessive

Autosomal recessive CADASIL has been described, although it is less common than the dominant form.

7358

Rate this question:

A 52-year-old man presented with a 3-week history of confusion and difficulty remembering where he had put things in the house. He had recently had to ask his wife to drive him to work as he could no longer remember how to get there. The admission to hospital was precipitated by a generalised tonic–clonic seizure at home, witnessed by his wife, lasting 2 min. He was apyrexial with otherwise normal general observations.

Respiratory, cardiovascular and abdominal examinations were normal. Cognitive examination was difficult because of his confusion, but the rest of the neurological examination was normal.

Investigations:

Hb	13.2 g/dl
WCC	10.5×10^9/l
PLT	255×10^9/l
Na^+	128 mmol/l
K^+	4.2 mmol/l

Hb	13.2 g/dl
WCC	10.5×10^9/l
PLT	255×10^9/l
Na^+	128 mmol/l
K^+	4.2 mmol/l
Creatinine	110 µmol/l
Urea	7.5 mmol/l

What is the most likely diagnosis?

A	TB meningitis
B	Limbic encephalitis
C	Wernicke–Korsakoff syndrome
D	Subdural haematoma
E	Alzheimer's disease

A 52-year-old man presented with a 3-week history of confusion and difficulty remembering where he had put things in the house. He had recently had to ask his wife to drive him to work as he could no longer remember how to get there. The admission to hospital was precipitated by a generalised tonic–clonic seizure at home, witnessed by his wife, lasting 2 min. He was apyrexial with otherwise normal general observations.

Respiratory, cardiovascular and abdominal examinations were normal. Cognitive examination was difficult because of his confusion, but the rest of the neurological examination was normal.

Investigations:

Hb	13.2 g/dl
WCC	10.5×10^9/l
PLT	255×10^9/l

B Limbic encephalitis

Subacute cognitive dysfunction, particularly affecting cognitive domains referable to the temporal lobe, and seizures are the key clinical features of limbic encephalitis. An important differential diagnosis would be viral encephalitis (and such patients are often treated empirically for this possibility), but the lack of fever would be against this. Limbic encephalitis is normally either a paraneoplastic or autoimmune disease. Medial temporal lobe changes are seen on magnetic resonance imaging (MRI) in 60% of cases. Cerebrospinal fluid (CSF) shows raised protein and unmatched oligoclonal bands in the majority of patients, with around half of patients having white cells present. Many patients have antibodies directed against the voltage-gated potassium channel complex, in which case hyponatremia (as seen here) is common. A myriad of other autoantibody associations has also

common. A myriad of other autoantibody associations has also been discovered recently (e.g. AMPA, GABA-B, NMDA). Treatment involves immunosuppression/immunomodulation (intravenous immunoglobulin [IVIg], plasma exchange, steroids) and/or treatment of any underlying malignancy.

A	TB meningitis

This case describes a presentation of encephalitis (i.e. infection/inflammation of the brain parenchyma) rather than meningitis (i.e. infection/inflammation of the coverings of the brain). In meningitis, the most prominent clinical features are headache, neck stiffness, photophobia and fever.

C	Wernicke–Korsakoff syndrome

This syndrome is caused by thiamine deficiency and patients present with anterograde amnesia and

patients with Wernicke–Korsakoff syndrome also usually have nystagmus and/or ophthalmoplegia and ataxia.

D	Subdural haematoma

A slowly expanding subdural haematoma is sometimes the explanation for progressive cognitive disturbance, particularly in the elderly or alcoholics. However, the symptoms of topographical dysfunction described in this case are very typical of temporal lobe dysfunction, as seen in limbic encephalitis. Furthermore, one would not expect the neurological examination of the limbs and cranial nerves to be normal in a patient with a sufficiently large subdural haematoma to cause cognitive disturbance.

E	Alzheimer's disease

Whilst some of the cognitive deficits in this case might resemble Alzheimer's disease, the subacute onset described here is simply too rapid to be explained by degenerative pathology

explained by degenerative pathology. Seizures can occur in Alzheimer's, but are generally a late phenomenon.

Limbic encephalitis is normally either a paraneoplastic or autoimmune disease. It presents with a subacute onset of memory impairment, disorientation +/– seizures and psychiatric disturbances (hallucinations, agitation and sleep disturbance). Hypothalamic disease (hyperthermia, weight gain, endocrine dysfunction, hypersomnia) is also seen. Medial temporal lobe changes are seen on magnetic resonance imaging (MRI). Cerebrospinal fluid (CSF) shows raised protein and unmatched oligoclonal bands in the majority of patients, with around half the patients having white cells present. A recently described subgroup of patients has antibodies to voltage-gated potassium channels. Most of them (around 80%) have resistant hyponatraemia. Other features are similar to above, but only 10% of those described had unmatched oligoclonal bands. This group has shown an improvement with immunosuppressive treatment (IVIg,

seizures and psychiatric disturbances (hallucinations, agitation and sleep disturbance). Hypothalamic disease (hyperthermia, weight gain, endocrine dysfunction, hypersomnia) is also seen. Medial temporal lobe changes are seen on magnetic resonance imaging (MRI). Cerebrospinal fluid (CSF) shows raised protein and unmatched oligoclonal bands in the majority of patients, with around half the patients having white cells present. A recently described subgroup of patients has antibodies to voltage-gated potassium channels. Most of them (around 80%) have resistant hyponatraemia. Other features are similar to above, but only 10% of those described had unmatched oligoclonal bands. This group has shown an improvement with immunosuppressive treatment (IVIg, plasma exchange, steroids) – both clinically and with a decrease in the titre of voltage-gated potassium channel antibodies.

6960

Rate this question:

A 32-year-old man presented with a 5-day history of progressive weakness. Initially, he developed a foot drop on the right and some weakness of hand grip on the left, but over the next few days this progressed to weakness of all four limbs. He had just come back from a three-week holiday to Spain where he had spent the first few days in bed with a cough and feeling generally unwell.

On examination, there was weakness, decreased tone and areflexia in all four limbs. Plantar responses were downgoing. Cranial nerves, coordination and sensation were normal.

Which one of the following is the most useful investigation in making a diagnosis in this case?

A	Atypical pneumonia serology
B	Serum immunoglobulins
C	CT of the whole spine

with a cough and feeling generally unwell.

On examination, there was weakness, decreased tone and areflexia in all four limbs. Plantar responses were downgoing. Cranial nerves, coordination and sensation were normal.

Which one of the following is the most useful investigation in making a diagnosis in this case?

A	Atypical pneumonia serology
B	Serum immunoglobulins
C	CT of the whole spine
D	Lumbar puncture
E	Serum creatinine kinase

A 32-year-old man presented with a 5-day history of progressive weakness. Initially, he developed a foot drop on the right and some weakness of hand grip on the left, but over the next few days this progressed to weakness of all four limbs. He had just come back from a three-week holiday to Spain where he had spent the first few days in bed with a cough and feeling generally unwell.

On examination, there was weakness, decreased tone and areflexia in all four limbs. Plantar responses were downgoing. Cranial nerves, coordination and sensation were normal.

Which one of the following is the most useful investigation in making a diagnosis in this case?

Your answer was incorrect

A	Atypical pneumonia serology

D Lumbar puncture

The likely diagnosis in this case is Guillain–Barré syndrome (GBS), as evidenced by the acute onset of rapidly progressive lower motor neurone pattern of weakness and the history of prodromal illness. Lumbar puncture is important in the diagnosis of this condition as it can be used to exclude other potential causes of similar presentations, such as infection or malignancy. A raised protein count and normal white cell count in the CSF are characteristic findings in GBS. In almost 70% of cases there is a prodromal infection, with the most common types being *Campylobacter jejuni*, *Mycoplasma pneumoniae*, Epstein–Barr virus and cytomegalovirus. In a number of cases, anti-ganglioside antibodies are found (particularly GM1, and in the Miller–Fisher variant GQ1b). Treatment is usually with intravenous immunoglobulins and supportive interventions, including monitoring of respiratory function, prophylactic

respiratory function, prophylactic anticoagulation and monitoring for cardiac arrhythmias. Early and regular measurement of forced vital capacity (FVC) is extremely important, and any suggestion of low or decreasing vital capacity requires immediate intensive care team involvement.

B	Serum immunoglobulins

Although serum immunoglobulins may be raised in Guillain–Barré syndrome, this is not a response that is specific to this condition. Raised serum immunoglobulins may be seen in response to a range of different infections, and therefore this does not help confirm the diagnosis in this case.

A	Atypical pneumonia serology

This would not help to arrive at a diagnosis of Guillain–Barré syndrome in this case. Although infection with atypical pathogens can precipitate the development of GBS, a positive result would not confirm the diagnosis.

C CT of the whole spine

This investigation would not help make a diagnosis of Guillain–Barré syndrome. CT of the spine is useful to identify bony abnormalities such as fractures or bony lesions. The findings in this case could not be attributed to a spinal or central cause of weakness as the examination findings are in keeping with a lower motor neurone distribution.

E Serum creatinine kinase

This investigation would not help make a diagnosis of Guillain–Barré syndrome. This investigation would be useful in the diagnosis of inflammatory myopathies such as polymyositis or dermatomyositis, which do present with weakness but with reflexes preserved.

32699

Rate this question:

An 84-year-old woman presents with increasing forgetfulness. Her general practitioner (GP) commenced her on a low dose of haloperidol for agitation a year ago. Her daughter, who lives with her, has become concerned that her mother seems to be more confused and has developed twitching movements in her face.

Three weeks ago, the GP went to see her at home and stopped the haloperidol, but it seems that the twitching has actually got worse. The only other medications she takes are aspirin and amlodipine. The MTS score was 5/10.

On examination, there were some semi-purposeful movements of her arms and legs, intermittent yawning-type jaw movements and evidence of bilateral cogwheel rigidity on examination of her upper limbs. A CT brain scan revealed cerebral atrophy and calcification of the basal ganglia.

What is the most likely diagnosis that underlies the twitching?

was 5/10.

On examination, there were some semi-purposeful movements of her arms and legs, intermittent yawning-type jaw movements and evidence of bilateral cogwheel rigidity on examination of her upper limbs. A CT brain scan revealed cerebral atrophy and calcification of the basal ganglia.

What is the most likely diagnosis that underlies the twitching?

A	Extrapyramidal side-effect of haloperidol
B	Parkinson's disease
C	Multiple system atrophy
D	Dementia of Lewy body type
E	Alzheimer's disease

An 84-year-old woman presents with increasing forgetfulness. Her general practitioner (GP) commenced her on a low dose of haloperidol for agitation a year ago. Her daughter, who lives with her, has become concerned that her mother seems to be more confused and has developed twitching movements in her face.

Three weeks ago, the GP went to see her at home and stopped the haloperidol, but it seems that the twitching has actually got worse. The only other medications she takes are aspirin and amlodipine. The MTS score was 5/10.

On examination, there were some semi-purposeful movements of her arms and legs, intermittent yawning-type jaw movements and evidence of bilateral cogwheel rigidity on examination of her upper limbs. A CT brain scan revealed cerebral atrophy and calcification of the basal ganglia.

What is the most likely diagnosis that underlies the twitching?

A Extrapyramidal side-effect of haloperidol

Drug-induced parkinsonism is the most common cause of secondary parkinsonism, with typical culprits including antipsychotics and anti-emetics. It is an often missed diagnosis as it can take up to a year to resolve, and therefore the patient may not be on the offending drug at the time. Movement disorders such as akathisia and (as in this case) orofacial dyskinesia can be associated with chronic neuroleptic use and can be useful in distinguishing from other causes of parkinsonism. The CT findings in this case are not remarkable for a patient of this age.

B Parkinson's disease

Idiopathic Parkinson's disease would feature in the differential diagnosis, but given the medication history and lack of asymmetry a drug-induced condition should be considered first.

The radionucleotide dopamine transporter scan (DaTscan) can help distinguish in tricky cases.

C	Multiple system atrophy

MSA is a neurodegenerative condition with either predominant parkinsonism (MSA-P) or cerebellar ataxia (MSA-C), or a mixture. MSA-P presents with a symmetrical akinetic-rigid parkinsonism, autonomic failure, urogenital dysfunction, pyramidal signs and cerebellar ataxia of varying degrees depending on the subtype. Cognitive function in MSA tends to be relatively well preserved. It is typically a disease with an earlier age of onset (usually in the patient's 50s).

D	Dementia of Lewy body type

DLB is the second most common form of dementia after Alzheimer's disease. It is characterised by fluctuating attentional and visuospatial cognitive impairment, recurrent visual

It is characterised by fluctuating attentional and visuospatial cognitive impairment, recurrent visual hallucinations, REM sleep behaviour disorder and motor features of parkinsonism. Patients with DLB are very sensitive to neuroleptic medications.

E	Alzheimer's disease

Alzheimer's disease is characterised by an insidious onset of progressive decline in memory and at least one other cognitive domain (typically executive dysfunction and visuospatial impairment). Neurological features, including pyramidal and extrapyramidal motor signs, myoclonus and seizures, can occur in the late stages but are uncommon early on.

2358

Rate this question:

Next Question

A 42-year-old man is brought to the clinic by ambulance, accompanied by his male partner. He has become confused and increasingly drowsy over the past 24 h, with severe headache and neck stiffness. This is given against a background of increasing tiredness and headaches over the past week.

On examination, he is pyrexial, with a temperature of 38.2 °C, and drowsy. His blood pressure is 95/60 mmHg, with a pulse of 100 bpm.

Investigations:

Haemoglobin (Hb)	13.4 g/dl
White cell count (WCC)	10.1×10^9/l
Platelets (PLT)	203×10^9/l
CD4 count	42
Sodium (Na^+)	139 mmol/l
Potassium (K^+)	4.3 mmol/l

Creatinine (Cr)	120 μmol/l
Erythrocyte sedimentation rate (ESR)	65 mm/h
Computed tomography (CT) brain	Unremarkable
Lumbar puncture (LP)	High opening pressure (25 cmH_2O), cerebrospinal fluid (CSF) protein 0.79 g/dl, 15 lymphocytes/mm^3, glucose 1.7 mmol/l)

Which of the following represents the most likely diagnosis?

A	Cytomegalovirus (CMV) meningitis
B	Tuberculous meningitis

Lumbar puncture (LP)	High opening pressure (25 cmH_2O), cerebrospinal fluid (CSF) protein 0.79 g/dl, 15 lymphocytes/mm^3, glucose 1.7 mmol/l)

Which of the following represents the most likely diagnosis?

A Cytomegalovirus (CMV) meningitis

B Tuberculous meningitis

C HIV seroconversion

D Cryptococcal meningitis

E Herpes encephalitis

7:50

https://www.google.com/sea 16

Normal scan — Inconsistent with a parkinsonian syndrome

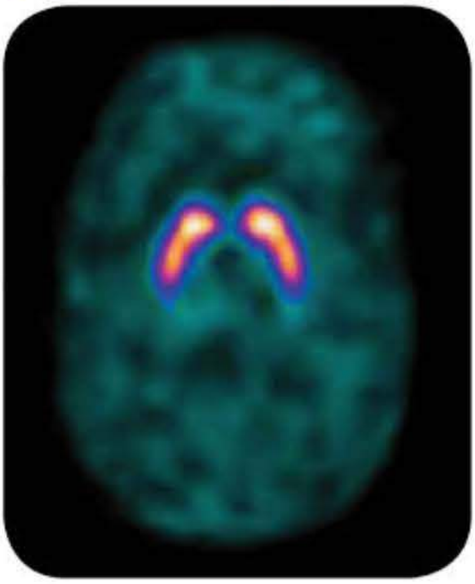

DaTscan will be distributed in the striata and appear as mirrored comma or crescent shapes if dopaminergic neurons are intact or not affected[1,4]

Abnormal scan — Consistent with a parkinsonian syndrome

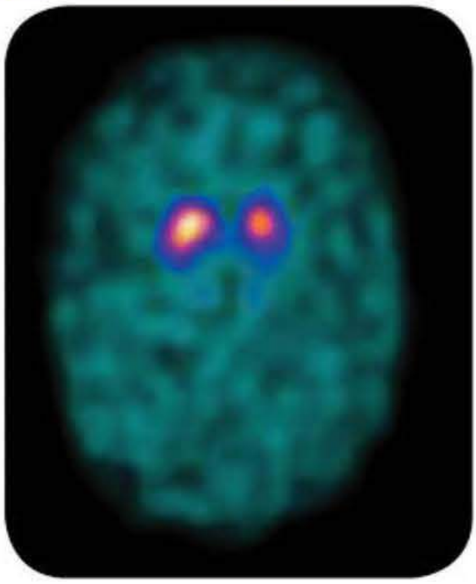

A decrease in DaTscan activity will result in period or oval shapes and reduced image intensity on one or both sides[1,4]

DaTscan™ Ioflupane I123 I...

Image Reporting | DaTscan™ Ioflupane I123 Injection

DaTscan Provides An Accurate Assessment of Dopamine Transporter (DaT) Status

Images may be subject to copyright. Learn More

RELATED IMAGES

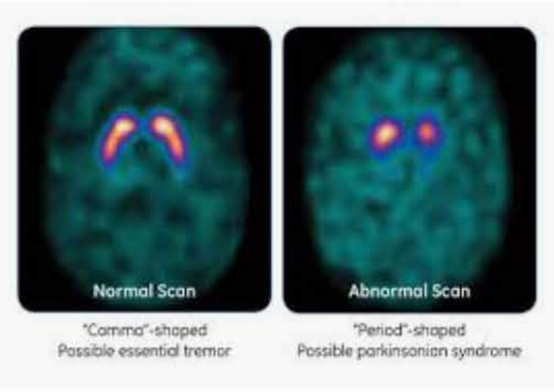

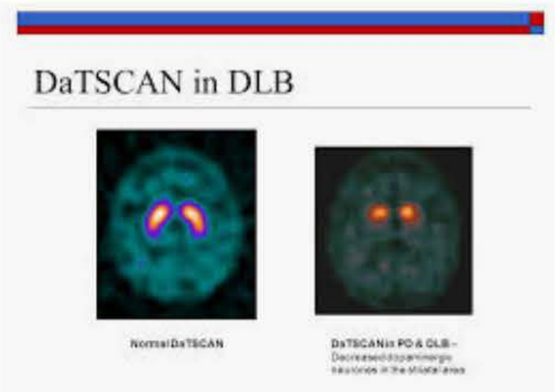

DOTmed.com - Health Canad

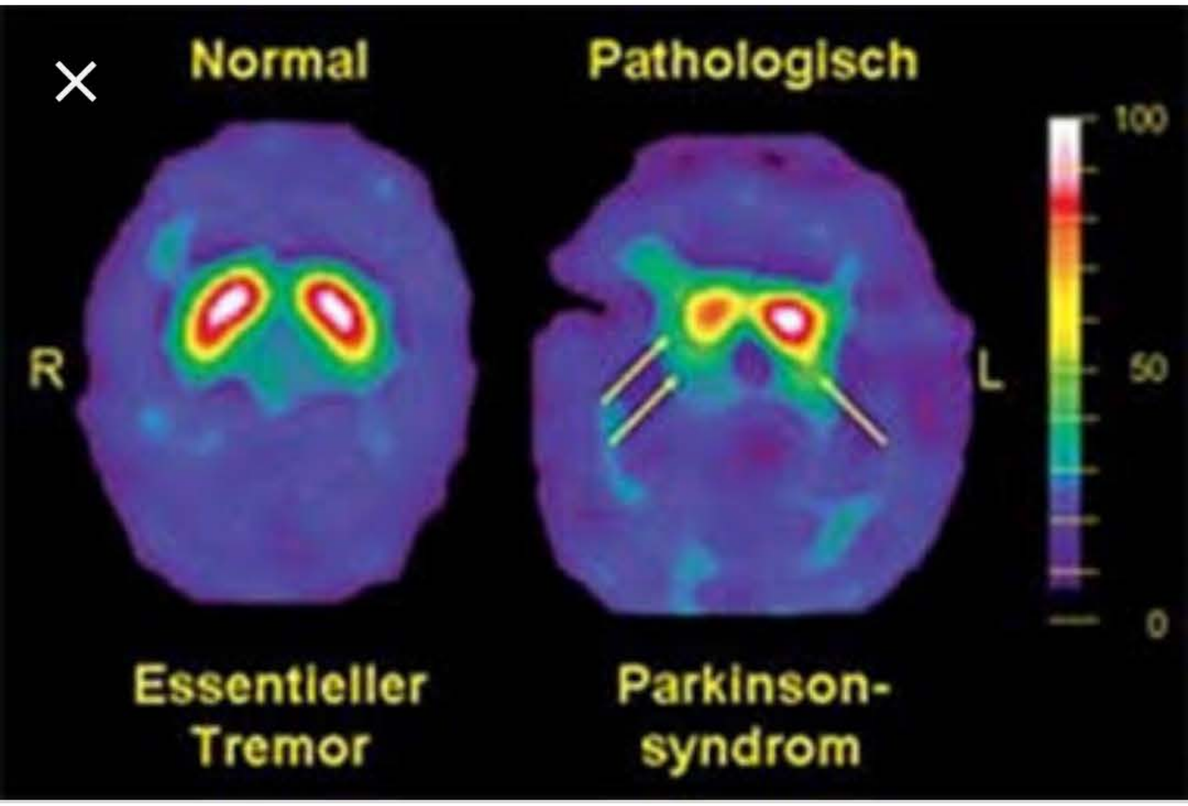

Parkinson's Foundation: B...

Parkinson's Foundation: Better Lives. Together.

An example of a PET scan is below and it reveals: in the top panel a normal scan, in the middle panel abnormalities in the putamen (red uptake in the ...

Images may be subject to copyright. Learn More

RELATED IMAGES

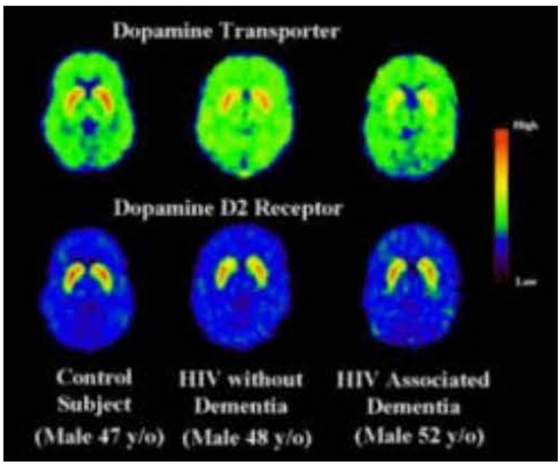

HIV Dementia Mechanism Dis...
sciencedaily.com

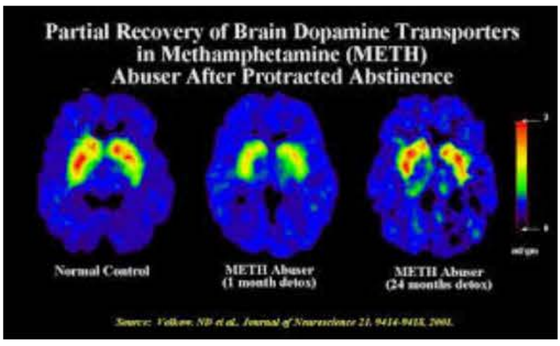

Effects of drugs on brain biol...
helpmegetoffdrugs.com

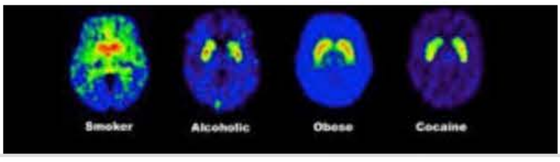

D Cryptococcal meningitis

The correct answer is Cryptococcal meningitis (Option D).

Patients may present with a very rapid deterioration in their mental state, with LP findings indicating a high opening pressure, raised CSF protein, lymphocytes or neutrophils in the CSF and low CSF glucose. Occasionally, *Cryptococcus* is actually identified in the CSF. His CD4 count is low, which makes it highly likely he has coexisting human immunodeficiency virus (HIV) infection. Amphotericin B is the drug of choice for treating the condition.

B Tuberculous meningitis

Tuberculous meningitis (Option B) is incorrect.

Tuberculous meningitis is likely to present with a more chronic course. The CSF usually has a high protein level, a low glucose level and a raised number of lymphocytes. Acid-fast bacilli are sometimes seen on a CSF

bacilli are sometimes seen on a CSF smear, but more commonly *Mycobacterium tuberculosis* is grown in culture. A spiderweb clot in the collected CSF is characteristic of tuberculous meningitis but is a rare finding.

A	Cytomegalovirus (CMV) meningitis

Cytomegalovirus (CMV) meningitis (Option A) is incorrect.

CSF findings that suggest a viral cause of meningitis include an elevated white blood cell count, with a lymphocytic predominance, in combination with normal glucose and protein levels.

C	HIV seroconversion

HIV seroconversion (Option C) is incorrect.

The clinical appearance of HIV seroconversion consists of a self-limiting flu-like illness that lasts for a

The clinical appearance of HIV seroconversion consists of a self-limiting flu-like illness that lasts for a period of about 7 days. The symptomatology and severity of the patient's condition are not indicative of this diagnosis.

E	Herpes encephalitis

Herpes encephalitis (Option E) is incorrect.

A decreased level of consciousness and an altered mental state are common changes. Increased numbers of white blood cells can be found in the CSF. Imaging by CT or magnetic resonance imaging (MRI) shows characteristic changes in the temporal lobes. Definite diagnosis requires polymerase chain reaction (PCR) on the CSF. Results may take days, and patients with suspected herpes encephalitis should be treated with aciclovir while waiting for test results.

32782

Rate this question:

A 66-year-old man presented to the Emergency Department with a history of dizziness and vomiting. He had been symptomatic for the past 2 days and noticed that he had a tendency to sway towards his right side while walking. He had been hypertensive for the past several years and was taking atenolol 100 mg/day.

On examination, the blood pressure was 160/100 mmHg, with a pulse of 78 bpm. He was alert and orientated to place and time. Fundi were unremarkable. Conjugate lateral gaze to the right side was impaired, and a right-sided gaze-evoked nystagmus was evident. The right orbicularis oculi and oris were mildly weak. Right upper and lower limbs were hypotonic and ataxic. Plantar were flexors on both sides. Pinprick sensation was impaired over the left-sided trunk and limbs.

What is the most likely vascular territory involved?

A	Right posterior cerebral artery

place and time. Fundi were unremarkable. Conjugate lateral gaze to the right side was impaired, and a right-sided gaze-evoked nystagmus was evident. The right orbicularis oculi and oris were mildly weak. Right upper and lower limbs were hypotonic and ataxic. Plantar were flexors on both sides. Pinprick sensation was impaired over the left-sided trunk and limbs.

What is the most likely vascular territory involved?

A	Right posterior cerebral artery
B	Right superior cerebellar artery
C	Right anterior inferior cerebellar artery
D	Right anterior cerebral artery
E	Right posterior inferior cerebellar artery

C Right anterior inferior cerebellar artery

The correct answer is Right anterior inferior cerebellar artery (Option C).

The occlusion of the anterior inferior cerebellar artery causes a lateral inferior pontine infarction. The principal findings are vertigo, vomiting, horizontal and vertical nystagmus and ipsilateral tinnitus. A lower motor neurone facial weakness, paresis of the conjugate lateral gaze, cerebellar ataxia, Horner syndrome and, rarely, deafness all occur ipsilaterally. On the contralateral side, impaired pain and temperature over the half of the body is observed due to spinothalamic tract involvement.

E Right posterior inferior cerebellar artery

Right posterior inferior cerebellar artery (Option E) is incorrect.

A disrupted blood supply to this artery will lead to lateral medullary syndrome

include sensory deficits of the trunk and extremities contralaterally to the lesion, and sensory deficits of the face and cranial nerves ipsilaterally. Ataxia, nystagmus, dysphagia, dysarthria and dysphonia are also common. Damage to the hypothalamospinal fibres may disrupt the sympathetic nervous system relay and give rise to symptoms similar to those caused by Horner syndrome.

A	Right posterior cerebral artery

Right posterior cerebral artery (Option A) is incorrect.

Depending upon the location and severity of the posterior cerebral artery (PCA) occlusion, signs and symptoms may vary. Blockages of the proximal portion of the vessel produce only minor deficits due to collateral blood flow from the opposite hemisphere via the posterior communicating artery. In contrast, distal occlusions result in more serious complications. Visual deficits, such as agnosia,

prosopagnosia or cortical blindness, may be a product of ischaemic damage to the occipital lobe. Occlusion of the branches of the PCA that supply the thalamus can result in central post-stroke pain, and lesions to the subthalamic branches can lead to a wide range of deficits.

B	Right superior cerebellar artery

Right superior cerebellar artery (Option B) is incorrect.

Headache, nausea and vomiting, vertigo, gait imbalance and diplopia are the most common complaints at onset of the occlusion. Other common findings include dysmetria and dysdiadochokinesia, dysarthria, ataxia and vertigo.

D	Right anterior cerebral artery

Right anterior cerebral artery (Option D) is incorrect.

Depending upon the area and severity

findings include dysmetria and dysdiadochokinesia, dysarthria, ataxia and vertigo.

D	Right anterior cerebral artery

Right anterior cerebral artery (Option D) is incorrect.

Depending upon the area and severity of the occlusion, signs and symptoms may vary. Blockages to the proximal segment of the vessel produce only minor deficits due to collateral blood flow from the opposite hemisphere via the anterior communicating artery. Occlusions distal to this segment will result in more severe presentations. Contralateral hemiparesis and hemisensory loss of the lower extremity is the most common symptom associated with anterior cerebral artery occlusion.

71458

Rate this question:

Next Question

Medial inferior pontine syndrome

(occlusion of paramedian branch of basilar artery)

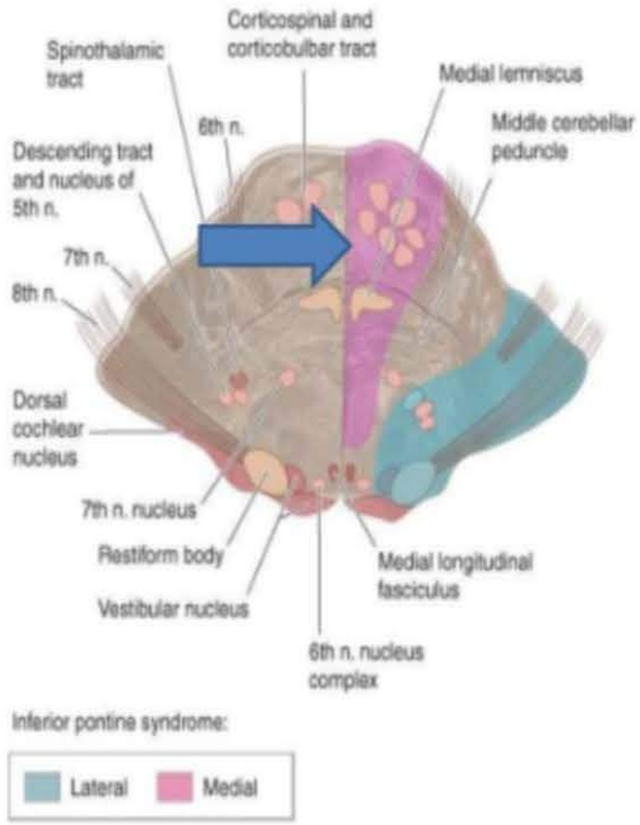

- **Common Symptoms**
  - Contralateral weakness and numbness
  - Ipsilateral facial weakness
  - Diplopia

- **On side of lesion**
  - Paralysis of conjugate gaze to side of lesion (preservation of convergence): *Center for conjugate lateral gaze(PPRF)*
  - Nystagmus: *Vestibular nucleus*
  - Ataxia of limbs and gait: Likely *middle cerebellar peduncle*
  - Diplopia on lateral gaze: *Abducens nerve*
  - Internuclear ophthalmoplegia or one-and-a-half syndrome

- **On side opposite lesion**
  - Paralysis of face, arm, and leg: *Corticobulbar and corticospinal tract in lower pons*
  - Impaired tactile and proprioceptive sense over one-half of the body: *Medial lemniscus*

Midpontine syndrome

- **Medial midpontine syndrome(paramedian branch of midbasilar artery)**
  - On side of lesion
    - Ataxia of limbs and gait
  - On side opposite lesion
    - Paralysis of face, arm and leg
    - Variable impaired touch sensation touch and proprioception when lesion extends posteriorly

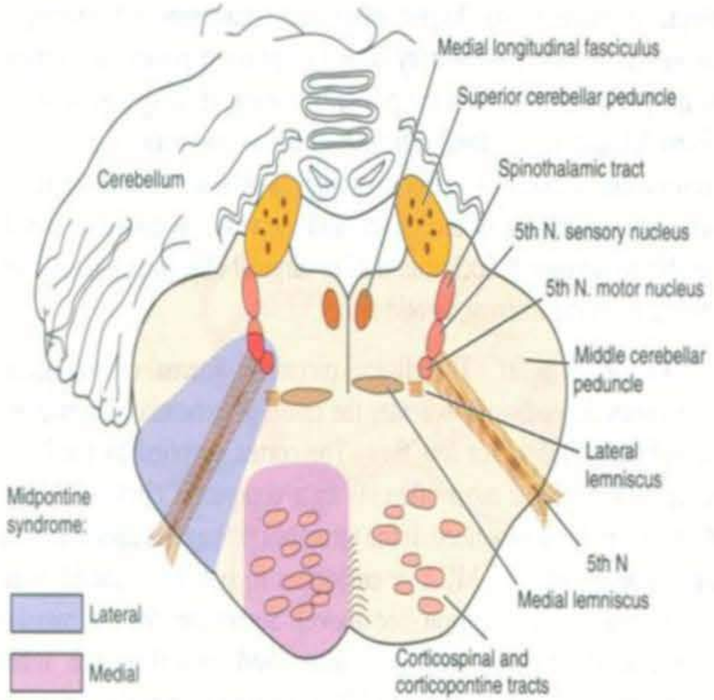

PONS

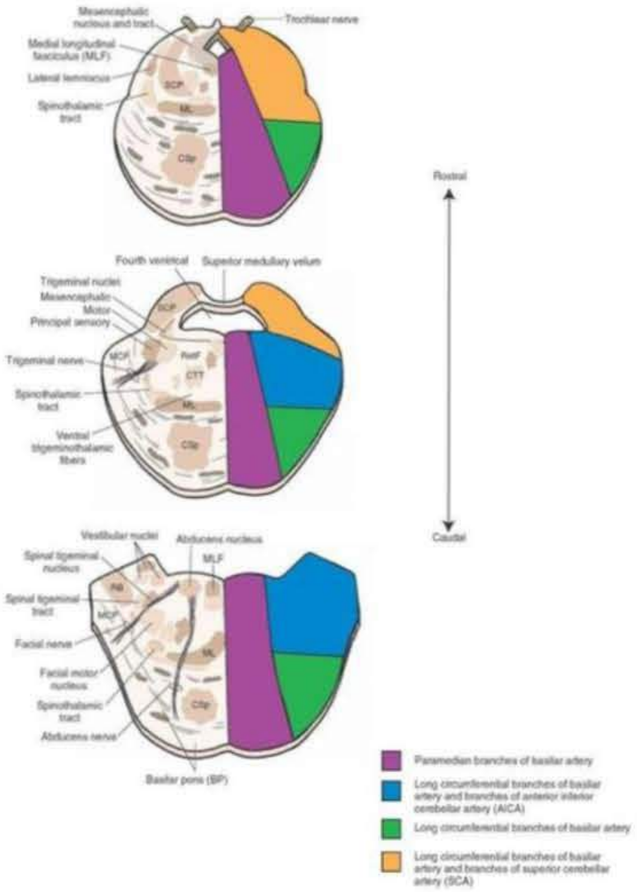

Cranial

Medial – Basilar
(Paramedian perforators)

Lateral – Basilar
(lateral pontine arteries = circumferentials)

Tectum - SCA

Caudal

Medial - Basilar
(paramedian perforators)

Lateral - AICA

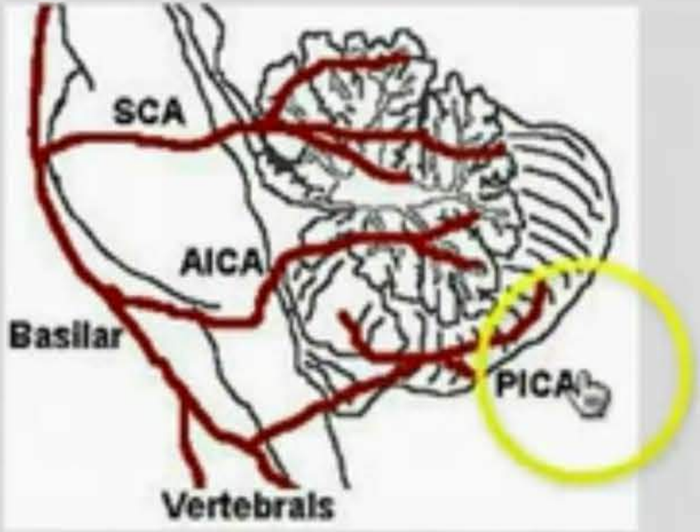
SCA
AICA
Basilar
PICA
Vertebrals

Lateral inferior pontine syndrome

(occlusion of anterior inferior cerebellar artery)

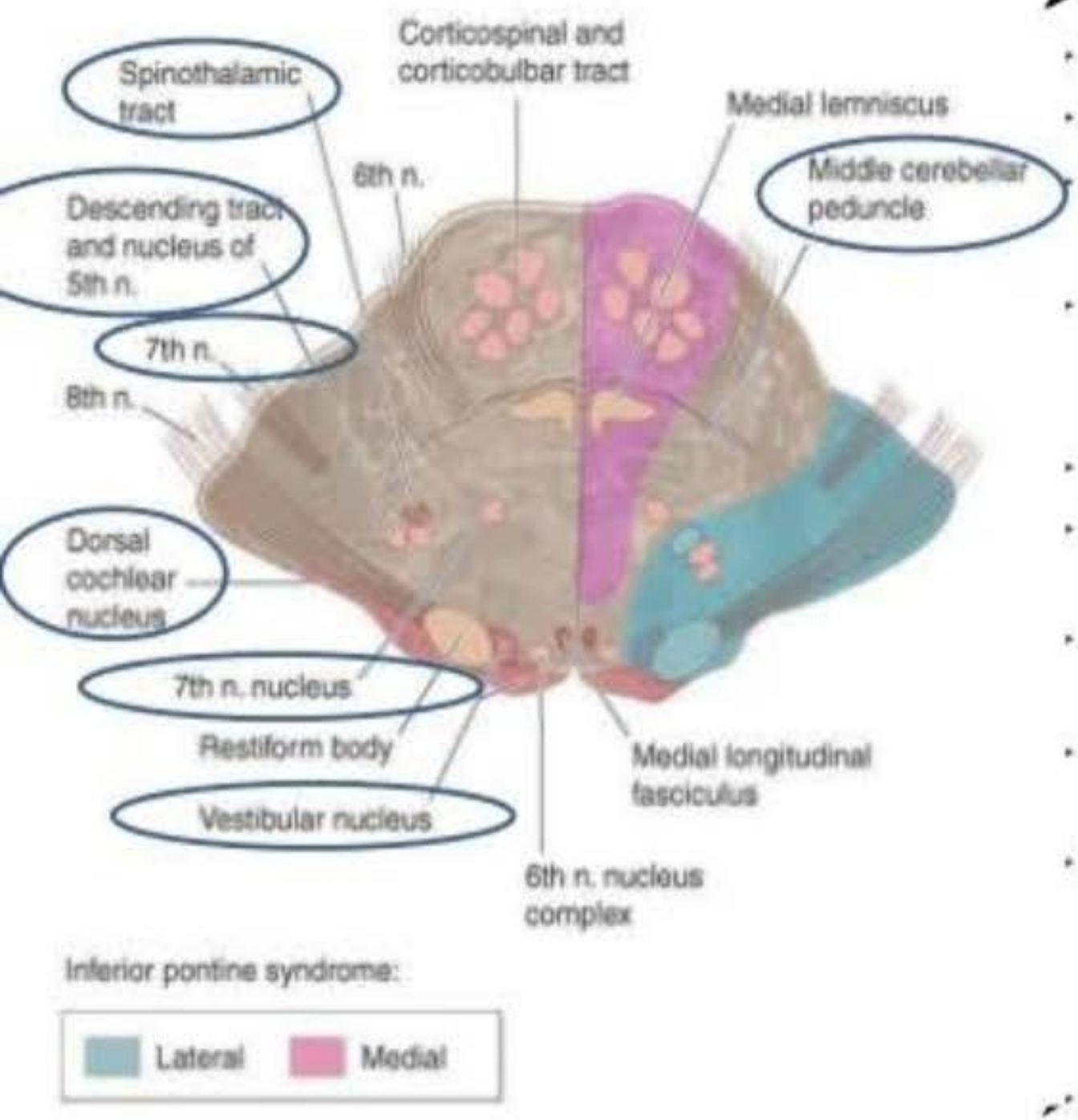

- **Common Symptoms**
  - Vertigo, nausea, vomiting
  - Oscillopsia
  - Deafness, tinnitus
  - Facial numbness
  - Incoordination

On side of lesion

- Horizontal and vertical nystagmus, vertigo, nausea, vomiting, oscillopsia: *Vestibular nerve or nucleus*
- Facial paralysis: *Seventh nerve*
- Paralysis of conjugate gaze to side of lesion: *Center for conjugate lateral gaze-PPRF*
- Deafness, tinnitus: *Auditory nerve or cochlear nucleus*
- Ataxia: *Middle cerebellar peduncle and cerebellar hemisphere*
- Impaired sensation over face: *Descending tract and nucleus fifth nerve*

On side opposite lesion

- Impaired pain and thermal sense over one-half the body (may include face): *Spinothalamic tract*

A 58-year-old man is referred to a neurologist with a 3-month history of clumsiness and weakness affecting the right arm. He has noticed significantly reduced dexterity in the hand and fingers and weakness of grip. He has not noticed any reduced sensation in the right hand/forearm.

He has a past medical history of asthma, osteoarthritis affecting the hands and knees and hypertension. He is a smoker of 20 cigarettes per day and drinks 18 units of alcohol per week.

On examination, he is of slim build and there is evidence of muscle wasting affecting the right dorsal interossei and right thenar muscles. Fasciculations are detected. Tone is slightly reduced in the right arm and power is significantly reduced on testing right finger flexion/extension, thumb abduction and opposition and wrist flexion/extension. Proximal muscle groups have preserved power. Reflexes are asymmetrically depressed on the right, however sensation appears intact.

Lower limb examination appear normal. Chest and abdominal examination are both normal.

The patient is investigated with magnetic resonance of the cervical spine, which shows evidence of degenerative joint disease affecting C3–6 vertebrae.

Lumbar puncture (CSF) reveals:

Protein	0.4 g/l (0.15–0.45)
WCC	4 cells/ml (≤ 5)
RCC	1 cell/ml (≤ 5)
Glucose	3.8 mmol/l (3.3–4.4)

Electromyogram shows fasciculations affecting small muscles of the right hand/forearm. No fasciculations are detected proximally or in the unaffected left arm.

Nerve conduction studies show patchy block of motor nerve conduction innervating fasciculating muscles. Sensory conduction is normal.

Given the above findings, what is the

detected proximally or in the unaffected left arm.

Nerve conduction studies show patchy block of motor nerve conduction innervating fasciculating muscles. Sensory conduction is normal.

Given the above findings, what is the likely diagnosis in this patient?

A	Chronic inflammatory demyelinating neuropathy (CIDP)
B	Motor neurone disease
C	Cervical myelopathy secondary to degenerative joint disease
D	Multifocal motor neuropathy (MMN)
E	Right ulnar nerve palsy

spine, which shows evidence of degenerative joint disease affecting C3–6 vertebrae.

Lumbar puncture (CSF) reveals:

Protein	0.4 g/l (0.15–0.45)
WCC	4 cells/ml (≤ 5)
RCC	1 cell/ml (≤ 5)
Glucose	3.8 mmol/l (3.3–4.4)

Electromyogram shows fasciculations affecting small muscles of the right hand/forearm. No fasciculations are detected proximally or in the unaffected left arm.

Nerve conduction studies show patchy block of motor nerve conduction innervating fasciculating muscles. Sensory conduction is normal.

Given the above findings, what is the likely diagnosis in this patient?

Your answer was correct

A Chronic inflammatory

D Multifocal motor neuropathy (MMN)

This patient's findings are in keeping with a diagnosis of multifocal motor neuropathy (MMN). This is an autoimmune neuropathy typically presenting with progressive weakness affecting an isolated limb without sensory involvement. Early on in the disease there is profound weakness disproportionate to the amount of wasting. Fasciculations can occur in the affected muscles and rarely there is cranial nerve or respiratory involvement. The clues to MMN are persistent motor conduction block of the innervating nerves and depressed reflexes. A GM1 anti-ganglioside antibody may be detected in the serum in a proportion of cases (approx. 80%), which supports the diagnosis. The condition can be treated with IVIG.

A Chronic inflammatory demyelinating neuropathy

Sensory nerves would usually also be involved, and onset in a single limb is rare in CIDP. In addition, one would expect the cerebrospinal fluid (CSF) protein to be elevated.

B	Motor neurone disease

In order to make this diagnosis on clinical grounds one would need to see a mixture of upper and lower motor neurone signs. Conduction block would not be seen on neurophysiology.

C	Cervical myelopathy secondary to degenerative joint disease

This would cause upper motor neurone signs in the lower limbs and may lead to upper motor signs or hyper-reflexia in the upper limb. One would not see changes of conduction block in the neurophysiology.

E	Right ulnar nerve palsy

neurone signs. Conduction block would not be seen on neurophysiology.

C	Cervical myelopathy secondary to degenerative joint disease

This would cause upper motor neurone signs in the lower limbs and may lead to upper motor signs or hyper-reflexia in the upper limb. One would not see changes of conduction block in the neurophysiology.

E	Right ulnar nerve palsy

This would account for weakness of the small muscles in the hand, but would not account for thenar and forearm muscle involvement. In addition, depressed reflexes, absence of sensory symptoms and the NCS (nerve conduction studies) findings would go against this diagnosis.

7194

Rate this question:

A 17-year-old girl presents to the Emergency Department, brought by her parents as she has been acting strangely over the last 6 months. Her parents are particularly concerned about her going out without her parents' permission and drinking alcohol. Her parents have noticed her walking has become progressively more unsteady and they often have difficulty understanding what she is saying. Her mother has depression and her father suffers from epilepsy.

On examination, she has slurred speech, coarse nystagmus to lateral gaze bilaterally, and an ataxic gait. The rest of her neurological examination is normal.

What is the most likely diagnosis?

A	Alcohol-related cerebellar disease
B	Friedreich's ataxia
C	Phenytoin toxicity

alcohol. Her parents have noticed her walking has become progressively more unsteady and they often have difficulty understanding what she is saying. Her mother has depression and her father suffers from epilepsy.

On examination, she has slurred speech, coarse nystagmus to lateral gaze bilaterally, and an ataxic gait. The rest of her neurological examination is normal.

What is the most likely diagnosis?

A	Alcohol-related cerebellar disease
B	Friedreich's ataxia
C	Phenytoin toxicity
D	Hypothyroidism
E	Spinocerebellar ataxia

6:43
:tps://mypastest.pastest.com 15

A 17-year-old girl presents to the Emergency Department, brought by her parents as she has been acting strangely over the last 6 months. Her parents are particularly concerned about her going out without her parents' permission and drinking alcohol. Her parents have noticed her walking has become progressively more unsteady and they often have difficulty understanding what she is saying. Her mother has depression and her father suffers from epilepsy.

On examination, she has slurred speech, coarse nystagmus to lateral gaze bilaterally, and an ataxic gait. The rest of her neurological examination is normal.

What is the most likely diagnosis?

Your answer was incorrect

A Alcohol-related cerebellar

C Phenytoin toxicity

The patient has most likely been taking her father's supply of phenytoin, which causes cerebellar symptoms in toxic doses. With the rest of the neurological examination being normal, there are no features to suggest any of the other diagnoses.

A Alcohol-related cerebellar disease

Chronic excess alcohol consumption is required to cause cerebellar damage. It is unlikely that this would have occurred over the 6-month period described.

B Friedreich's ataxia

Friedreich's ataxia is characterised by slowly progressive limb and gait ataxia before the age of 25 years and absent lower limb deep tendon reflexes. The genetic mutation responsible is a GAA trinucleotide repeat expansion in the

lower limb deep tendon reflexes. The genetic mutation responsible is a GAA trinucleotide repeat expansion in the *FXN* gene on chromosome 9. The pure cerebellar syndrome described here makes this diagnosis unlikely.

D	Hypothyroidism

The symptoms described here are not typical of hypothyroidism (e.g. tiredness, weight gain, depression, cold sensitivity).

E	Spinocerebellar ataxia

This is a group of rare autosomal dominant genetic disorders that cause ataxia, usually in combination with other neurological features. The lack of family history here and the relatively short duration of onset make this unlikely.

6969

Rate this question:

A 72-year-old man is brought to the Emergency Department by ambulance. He was found collapsed on the floor by his wife when she returned from the local supermarket. He has a history of hypertension, for which he takes ramipril, and has recently been taking pain relief and diazepam for a back injury.

On examination, his blood pressure (BP) is 185/100 mmHg, and pulse 85 bpm and regular. The respiratory rate is 21 breaths/min. His Glasgow Coma Scale (GCS) score is 4, and he has bilateral dilated pupils, which are poorly reactive.

Which of the following is the most appropriate next step?

A	Intubation and ventilation
B	Intravenous (IV) flumazenil
C	IV mannitol

pain relief and diazepam for a back injury.

On examination, his blood pressure (BP) is 185/100 mmHg, and pulse 85 bpm and regular. The respiratory rate is 21 breaths/min. His Glasgow Coma Scale (GCS) score is 4, and he has bilateral dilated pupils, which are poorly reactive.

Which of the following is the most appropriate next step?

A	Intubation and ventilation
B	Intravenous (IV) flumazenil
C	IV mannitol
D	IV sodium nitroprusside
E	IV labetalol

36474

Submit

A	Intubation and ventilation

The correct answer is Intubation and ventilation (Option A).

The patient has a very low GCS score and is at significant risk of airway compromise; intubation and ventilation are therefore the most appropriate next step before urgent computed tomography (CT) scanning.

B	Intravenous (IV) flumazenil

Intravenous (IV) flumazenil (Option B) is incorrect.

Although this patient has been taking diazepam for his back, given a respiratory rate of 21 breaths/min, a benzodiazepine overdose is very unlikely. The sudden collapse with hypertension and a GCS score of 4 fit much better with an acute stroke.

C	IV mannitol

IV mannitol (Option C) is incorrect.

raised intracranial pressure until more definitive treatment can be applied. The use of BP-lowering agents in this patient's situation is very debatable because of the risk of precipitating a watershed infarct.

D	IV sodium nitroprusside

IV sodium nitroprusside (Option D) is incorrect.

Sodium nitroprusside is a fast-acting, short-duration antihypertensive that is used in situations of acute hypertensive crises. Given the risk of precipitating a watershed infarct, its use is debatable.

E	IV labetalol

IV labetalol (Option E) is incorrect.

Labetalol is a dual alpha and beta antagonist that is used to treat hypertensive emergencies. It has a particular indication in the treatment of pregnancy-induced hypertension,

A 48-year-old woman is seen in Neurology Outpatients. She has a 6-month history of progressive hearing loss associated with tinnitus on the right side. In the last 2 months, she has experienced some headaches. She has never suffered from headaches previously. She states that these headaches are worst in the morning and improve after she has been up for an hour or two and after paracetamol and codeine use.

Over the preceding month, she has noticed that when she leans on her hand the right side of her face feels numb. Her husband has also told her that the right side of her face appears less mobile than the left. She recently saw her GP, who diagnosed Bell's palsy, but has written to you concerned that there may be some other more sinister diagnosis.

On examination, she has some reduced soft touch and pinprick sensation on the right side of her face. There is diplopia on extreme rightward gaze, but there are no other eye movement

On examination, she has some reduced soft touch and pinprick sensation on the right side of her face. There is diplopia on extreme rightward gaze, but there are no other eye movement abnormalities. She has reduced power in the muscles of facial expression on the right side. There is sensorineural deafness in the right ear.

Which of the following would be the most appropriate investigation?

A	Computed tomography (CT) brain scan
B	Magnetic resonance imaging (MRI) of the brain
C	Pure tone audiometry
D	Lumbar puncture for cytology
E	Lyme serology

B Magnetic resonance imaging (MRI) of the brain

This history is highly suspicious for a right cerebellopontine angle space-occupying lesion. This woman has progressive right V, VI, VII and VIII nerve lesions. The differential diagnosis for this lesion would include vestibular schwannoma, vascular malformation, meningioma, cholesteatoma and hemangioma. An MRI brain scan is the investigation of choice.

A Computed tomography (CT) brain scan

In order to adequately visualise the cerebellopontine angle (the area where the signs suggest the lesion must be), an MRI scan will be required; it has better sensitivity for detecting lesions in such areas.

C Pure tone audiometry

This test will only quantify the degree

C Pure tone audiometry

This test will only quantify the degree of hearing loss, not detect the likely lesion that is causing it (and the other cranial nerve deficits).

D Lumbar puncture for cytology

Lumbar puncture would be contraindicated here, as there is the suspicion of an intracranial space-occupying lesion. Until cranial imaging is performed it would be dangerous to perform an LP. In some instances where imaging cannot confirm a diagnosis, CSF analysis can be useful.

E Lyme serology

Lyme disease is a very rare cause of facial palsy (there is usually a preceding history of tick bite and erythema chronicum migrans), but it cannot explain all the other features seen here.

A 16-year-old male presented to the hospital with heaviness of the left upper and lower limbs of 24 h duration. He was known to have had high blood pressure from the age of 10 years and was taking irregular treatment.

He could not participate in school sports since early childhood since he would get severe, sharp burning pain in his limbs on running.

On examination, there was neither lymph node enlargement nor clubbing. There were red macules and papules around the umbilicus, which partially blanched on pressure. Blood pressure was 150/100 mmHg. He was alert and his cognition was normal. Fundi revealed arteriovenous nipping and soft exudates. Central nervous system examination revealed mild left-sided upper motor neurone facial palsy and a mild left-sided hemi paresis with no sensory or cerebellar deficit.

Investigations:

Hb	10 g/dl

Hb	10 g/dl
WCC	6.0×10^9/l
PLT	159×10^9/l
Urea	8.5 mmol/l
Creatinine	270 μmol/l

Computerised tomography of the head reveals a hypo-dense lesion in the right subcortical white matter.

Choose the most likely diagnosis

A	Fibromuscular dysplasia
B	MELAS (mitochondrial myopathy, encephalopathy, lactic acidosis, and stroke-like episodes)
C	Homocystinuria
D	Fabry's disease
E	Mc Ardle's disease

A 16-year-old male presented to the hospital with heaviness of the left upper and lower limbs of 24 h duration. He was known to have had high blood pressure from the age of 10 years and was taking irregular treatment.

He could not participate in school sports since early childhood since he would get severe, sharp burning pain in his limbs on running.

On examination, there was neither lymph node enlargement nor clubbing. There were red macules and papules around the umbilicus, which partially blanched on pressure. Blood pressure was 150/100 mmHg. He was alert and his cognition was normal. Fundi revealed arteriovenous nipping and soft exudates. Central nervous system examination revealed mild left-sided upper motor neurone facial palsy and a mild left-sided hemi paresis with no sensory or cerebellar deficit.

Investigations:

Hb	10 g/dl

D Fabry's disease

Fabry's disease is an X-linked recessive trait. It usually becomes manifest clinically in childhood or adolescence, with intermittent lancinating pain of the extremities. This pain is evoked by vigorous exercise, hot weather or febrile illness. A diffuse vascular involvement leads to hypertension, cardiomegaly and kidney disease, and thrombotic infarction occurs in various viscera. In the present example, the patient has suffered a right-sided capsular infarction. Characteristic angiokeratomas tend to be most prominent peri-umbilically. The primary deficit is in the enzyme alpha-galactosidase A, and accumulation of ceremide trihexoside in the damaged viscera. Enzyme replacement leads to improvement in kidney and other organ functions.

B MELAS (mitochondrial myopathy, encephalopathy, lactic acidosis, and stroke-like

It is a mitochondrial cytopathy. These patients have seizures, transient ischaemic attacks and strokes. Other features of mitochondrial disorders may be seen, such as deafness, ptosis and diabetes.

A	Fibromuscular dysplasia

This is a segmental, non-atheromatous, non-inflammatory arterial disease of unknown aetiology. It affects medium-sized arteries predominantly in young females. Most frequently the stroke occurs in the distribution of the internal carotid artery, followed by the vertebral and the intra-cerebral arteries. In 26% of patients, more than one arterial system may be affected. Claudication limb pain may occur in FMD, but not burning or lancinating pain as in Fabry's disease.

C	Homocystinuria

This presents with marfanoid features, learning disability and a tendency to

pain as in Fabry's disease.

C	Homocystinuria

This presents with marfanoid features, learning disability and a tendency to young stroke.

E	Mc Ardle's disease

This usually presents with muscle cramps on exercise. Stroke is not seen in this disease. It is a glycogen storage myopathy secondary to deficiency of myophosphorylase, which prevents the conversion of glycogen to glucose-6 phosphate.

7215

Rate this question:

Medscape eMedicine

Angiokeratoma Corporis Diffusum (Fabry Syndrome) Cli...

Angiokeratoma is the small punctate reddish-to-blu

Images may be subject to copyright. Learn More

RELATED IMAGES

7:03

https://www.google.com/sea 15

curvetube.com

What is Fabry Disease? [USMLE]

Watch (8:17)

14.5M Views

Fabry disease is an inherited disorder that results from the buildup of a particular type of fat, called globotriaosylceramide, in the body's cells. Beginning in childhood, this buildup causes signs ...

Images may be subject to copyright. Learn More

RELATED IMAGES

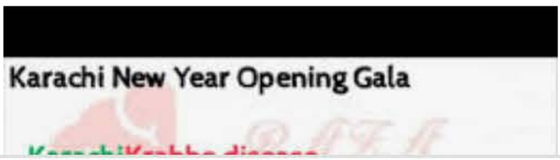

A 38-year old gardener presents with a 2-day history of slurred speech, blurred vision, diplopia, colicky abdominal pain and diarrhoea. Over the past 24 h, he has developed weakness in his arms and difficulty swallowing. He has no past history of note, and is not on any regular medications. He smokes 20 cigarettes per day and drinks 8 units of alcohol per week. He denies recreational drug use.

On examination, he is afebrile. His pulse is 80 bpm and regular, blood pressure 112/58 mmHg, heart sounds are normal and his chest is clear. His abdomen is diffusely tender, but without guarding or rebound tenderness; bowel sounds are normal. Per rectum examination reveals some liquid stool but no blood or masses. Neurological examination reveals dilated pupils bilaterally which react sluggishly to light. There is binocular diplopia but no obvious ophthalmoplegia. He is dysarthric and the gag reflex is impaired. Peripheral nerve examination revealed grade 3

power affecting upper and lower limbs. Reflexes were present only with reinforcement. Sensation was intact and coordination was limited by his limb weakness.

Investigations:

Hb	13.2 g/dl
WCC	6.6×10^9/l
PLT	324×10^9/l
Na+	138 mmol/l
K+	4.4 mmol/l
Creatinine	98 μmol/l
ESR	12 mm/1st h
Urea	6.6 mmol/l
Bilirubin	15 μmol/l
ALT	46 IU/l
ALP	136 IU/l
Albumin	39 g/l
Ca2+	2.1 mmol/l

Phosphate	1.64 mmol/l
TSH	2.66 mu/l
CRP	22 mg/l
Antinuclear antibodies, ANCA, rheumatoid factor	Negative
ECG	Normal sinus rhythm
Chest X-ray	Lung fields clear; normal cardiac silhouette
CT brain	Normal

What is the most likely diagnosis?

A	Guillian–Barré syndrome
B	Myasthenia gravis
C	Lyme disease

Antinuclear antibodies, ANCA, rheumatoid factor	Negative
ECG	Normal sinus rhythm
Chest X-ray	Lung fields clear; normal cardiac silhouette
CT brain	Normal

What is the most likely diagnosis?

A	Guillian–Barré syndrome
B	Myasthenia gravis
C	Lyme disease
D	Acute poliomyelitis
E	Botulism

E Botulism

Classically, botulism is characterised by the acute onset of bilateral cranial neuropathies associated with a symmetric descending weakness. There is no sensory involvement, no fever, and the patient remains responsive.

Botulism is caused by neurotoxins produced by the anaerobic spore-forming bacterium *Clostridium botulinum*. These neurotoxins block the release of acetylcholine at the neuromuscular junction, resulting in a flaccid paralysis. The commonest mechanism of disease spread is food-borne or via wounds.

Neurological symptoms are of a descending symmetrical flaccid paralysis; neurological symptoms are the same irrespective of the route of entry of the toxin, but may develop more quickly with toxin inhalation. Cranial nerve palsies produce diplopia, ptosis, facial weakness, dysphagia and dysarthria. This is followed by

ptosis, facial weakness, dysphagia and dysarthria. This is followed by weakness affecting the neck and arms. After this, the respiratory muscles and muscles of the lower body are affected. Respiratory muscle involvement can be fatal. There may be autonomic signs with dry mouth, fixed or dilated pupils and cardiovascular, gastrointestinal and urinary autonomic dysfunction. Diagnosis is by isolating the toxin in the blood, urine or stool. Nerve conduction studies and electromyography (EMG) can be supportive of the diagnosis, showing incremental responses to repeated nerve stimulation.

A	Guillian–Barré syndrome

Guillain–Barré syndrome typically causes bilateral ascending muscle weakness with absent deep tendon reflexes. Paraesthesia of the hands and feet occurs in 80% of patients, and dysautonomia occurs in 70%.

B	Myasthenia gravis

B	Myasthenia gravis

Myasthenia gravis is characterised by fatiguable muscle weakness, particularly resulting in ptosis, diplopia secondary to complex ophthalmoplegia and bulbar symptoms. It is associated with neither autonomic symptoms nor descending weakness as in this case.

C	Lyme disease

Lyme disease is a tick-borne spirochaete infection; initial infection is associated with the typical erythema migrans skin rash. Whilst the neurological manifestations of early disseminated disease are varied, the classical triad of symptoms is meningitis, cranial neuropathy and motor or sensory radiculoneuropathy.

D	Acute poliomyelitis

Acute poliomyelitis is rare. Typical symptoms include asymmetrical

ophthalmoplegia and bulbar symptoms. It is associated with neither autonomic symptoms nor descending weakness as in this case.

C	Lyme disease

Lyme disease is a tick-borne spirochaete infection; initial infection is associated with the typical erythema migrans skin rash. Whilst the neurological manifestations of early disseminated disease are varied, the classical triad of symptoms is meningitis, cranial neuropathy and motor or sensory radiculoneuropathy.

D	Acute poliomyelitis

Acute poliomyelitis is rare. Typical symptoms include asymmetrical weakness and reduced tone in a muscle or group of muscles. Proximal muscles are more affected than distal and legs more so than arms.

70919

Rate this question:

A 45-year-old painter is admitted from his place of work after collapsing in the afternoon. He is a smoker of 20 cigarettes per day but is otherwise well.

On rousing at the building site, he was noted to have slurred speech, dizziness and some transient symptoms affecting the right side of the body. This had recovered by the time he reached the Emergency Department. Angiography revealed a proximal stenosis of the left subclavian and carotid arteries.

EEG showed no evidence of spike activity.

Which of the following diagnoses fits best with this clinical picture?

A	Transient Ischaemic attack
B	Migraine attack
C	Subclavian steal syndrome

affecting the right side of the body. This had recovered by the time he reached the Emergency Department. Angiography revealed a proximal stenosis of the left subclavian and carotid arteries.

EEG showed no evidence of spike activity.

Which of the following diagnoses fits best with this clinical picture?

A	Transient Ischaemic attack
B	Migraine attack
C	Subclavian steal syndrome
D	Complex partial seizure
E	Generalised epilepsy

7:20
:tps://mypastest.pastest.com
15

A 19-year-old man presented with blurred vision which had been slowly worsening over the previous 5 months. It was accompanied by increased difficulty seeing at night and unsteadiness on walking.

On examination, he had an ataxic gait and a bilateral ptosis, greater on the right than left. He also had decreased up-gaze and abduction in the right eye.

What is the most likely diagnosis?

A	A Kearns–Sayre syndrome
B	Multiple sclerosis (MS)
C	Abetalipoproteinaemia
D	Refsum's disease
E	Friedreich's ataxia

A 19-year-old man presented with blurred vision which had been slowly worsening over the previous 5 months. It was accompanied by increased difficulty seeing at night and unsteadiness on walking.

On examination, he had an ataxic gait and a bilateral ptosis, greater on the right than left. He also had decreased up-gaze and abduction in the right eye.

What is the most likely diagnosis?

Your answer was correct

A	A Kearns–Sayre syndrome
B	Multiple sclerosis (MS)
C	Abetalipoproteinaemia
D	Refsum's disease

A | A Kearns–Sayre syndrome

This is one of the mitochondrial diseases and normally starts before the age of 20 years. It has the following features: chronic progressive external ophthalmoplegia, ptosis, retinitis pigmentosa (giving the night blindness described here), cardiac conduction defects and a cerebellar syndrome. Other features include sensorineural hearing loss and endocrine pathology. Chronic progressive external ophthalmoplegia (CPEO) can occur as an isolated finding without the other features of Kearns–Sayre syndrome.

B | Multiple sclerosis (MS)

The five-month history of gradually progressive symptoms is not consistent with the most common form of MS (relapsing-remitting). Whilst you might consider primary progressive MS, the ptosis and external ophthalmoplegia (as opposed to internuclear ophthalmoplegia due to brainstem disease) described would be

brainstem disease) described would be very unusual, making this possibility unlikely.

C	Abetalipoproteinaemia

This is a very rare autosomal recessive disorder that affects the absorption of dietary fats, cholesterol and fat-soluble vitamins, particularly Vitamin E. The onset is usually during the first months of life, although milder forms can present in adulthood. Gastrointestinal symptoms relating to malabsorption are prominent. From a neurological perspective, retinitis pigmentosa and ataxia can occur, but ophthalmoplegia and ptosis are not described.

D	Refsum's disease

This is a very rare autosomal recessive condition characterised by accumulation of phytanic acid. Retinitis pigmentosa and neuropathy can occur. Ataxia and hearing loss are also common. Ptosis and ophthalmoplegia

ataxia can occur, but ophthalmoplegia and ptosis are not described.

D	Refsum's disease

This is a very rare autosomal recessive condition characterised by accumulation of phytanic acid. Retinitis pigmentosa and neuropathy can occur. Ataxia and hearing loss are also common. Ptosis and ophthalmoplegia are not features.

E	Friedreich's ataxia

This is characterised by progressive limb and gait ataxia before the age of 25 years and absent lower limb deep tendon reflexes. The genetic mutation responsible is a GAA trinucleotide repeat expansion in the FXN gene on chromosome 9. Retinitis pigmentosa is not a feature.

6963

Rate this question:

Next Question

A 25-year-old right-handed woman is admitted with sudden-onset hemiparesis and expressive dysphasia. She has no past medical or family history and is no medication. She is admitted to the Acute Stroke Unit.

Initial computerised tomography (CT) brain is unremarkable, subsequent magnetic resonance imaging (MRI) reveals a small infarct in the middle cerebral artery territory. Investigations for a secondary cause of stroke are performed.

Investigations:

ESR	15mm/1st hour
Echocardiogram	Normal left ventricular function, possible atrial septal aneurysm
Cholesterol	3.8 mmol/l (< 5.2 mmol/l)

On the basis of the above, what further test should be performed?

Cholesterol	3.8 mmol/l (< 5.2 mmol/l)

On the basis of the above, what further test should be performed?

A	Anti-neutrophil cytoplasmic antibody
B	Skin biopsy to screen for CADASIL (cerebral autosomal dominant arteriopathy with subcortical infarcts and leukoencephalopathy)
C	24 h telemetry
D	Contrast-enhanced echocardiogram after the acute episode
E	Thrombophilia screen

A 25-year-old right-handed woman is admitted with sudden-onset hemiparesis and expressive dysphasia. She has no past medical or family history and is no medication. She is admitted to the Acute Stroke Unit.

Initial computerised tomography (CT) brain is unremarkable, subsequent magnetic resonance imaging (MRI) reveals a small infarct in the middle cerebral artery territory. Investigations for a secondary cause of stroke are performed.

Investigations:

ESR	15mm/1st hour
Echocardiogram	Normal left ventricular function, possible atrial septal aneurysm
Cholesterol	3.8 mmol/l (< 5.2 mmol/l)

D Contrast-enhanced echocardiogram after the acute episode

When a young patient presents with stroke, a number of investigations are used that would not be routinely ordered in the older stroke patient. The first step is confirmation of the diagnosis; this may require repeat imaging with magnetic resonance imaging (MRI). In the young, differentials such as migraine, epilepsy or metabolic disturbances are more common. An increasingly recognised association is patent foramen ovale (PFO) and stroke. A PFO is present in 45% of young stroke cases, compared with 20% of the general population. The combination of PFO and atrial septal aneurysm greatly increases stroke risk. In this patient with possible atrial septal aneurysm, a trans-oesophageal echo should be performed to characterise the septal abnormality further. PFO is then diagnosed by contrast-enhanced echocardiography (the bubble test –

echocardiography (the bubble test – injecting agitated saline intravenously and looking for bubbles crossing to the left heart). Trials examining surgical closure of PFO are ongoing.

B	Skin biopsy to screen for CADASIL (cerebral autosomal dominant arteriopathy with subcortical infarcts and leukoencephalopathy)

CADASIL is associated with multiple strokes related to small vessel disease, inflammation and amyloid deposition, rather than the isolated lesion seen here.

A	Anti-neutrophil cytoplasmic antibody

There are no symptoms to suggest active vasculitis here, and ESR doesn't suggest increased viscosity as the likely cause of her stroke.

C	24 h telemetry

A	Anti-neutrophil cytoplasmic antibody

There are no symptoms to suggest active vasculitis here, and ESR doesn't suggest increased viscosity as the likely cause of her stroke.

C	24 h telemetry

Although rhythm disturbance is a possibility, the most likely cause of a stroke in this case is a PFO, rather than a clot related to turbulent blood flow and arrhythmia.

E	Thrombophilia screen

In this case, with a potential significant abnormality of cardiac anatomy, thrombophilia screening isn't indicated. There is significant risk of a false positive screen.

7362

Rate this question:

A 52-year-old woman presents to the Neurology Clinic with easy fatigue, diplopia and eyelid drooping towards the end of the day. She also has problems climbing the stairs and getting up from low chairs in her living room. She has a history of autoimmune hypothyroidism, but nil else of note. Medication includes thyroxine 100 µg daily.

On examination, her blood pressure (BP) is 110/60 mmHg. She has fatiguable diplopia and proximal muscle weakness.

Investigations:

Haemoglobin (Hb)	13.1 g/dl
White cell count (WCC)	8.0×10^9/l
Platelets (PLT)	189×10^9/l
Sodium (Na^+)	138 mmol/l
Potassium (K^+)	4.1

Sodium (Na^+)	mmol/l
Potassium (K^+)	4.1 mmol/l
Creatinine (Cr)	112 µmol/l
Thyroid-stimulating hormone (TSH)	3.5 u/l
Anti-acetylcholine receptor (AChR) antibody	Positive

Which of the following is the most appropriate initial therapy?

A Prednisolone

B Plasma exchange

C Ciclosporin

D Immunoglobulins

E Pyridostigmine

A Prednisolone

The correct answer is Prednisolone (Option A).

In more advanced disease (more than just ocular disease), prednisolone is the initial step of choice.

E Pyridostigmine

Pyridostigmine (Option E) is incorrect.

Even though acetylcholinesterase inhibitors are the most valuable medicine in early disease, this patient's weakness has progressed too far for isolated acetylcholinesterase inhibitors to be enough.

Various drugs may exacerbate the symptoms of myasthenia gravis. Some examples include the following:

Antibiotics:

- aminoglycosides, eg gentamicin
- ciprofloxacin
- macrolides, eg erythromycin,

- macrolides, eg erythromycin, azithromycin
- tetracycline
- ampicillin
- clindamycin.

Beta-blockers:

- propranolol
- atenolol
- timolol eye drops.

Anti-arrhythmic drugs:

- verapamil.

Other drugs:

- lithium
- *D*-penicillamine
- opiates, eg pethidine
- phenytoin
- statins
- magnesium
- chloroquine

B	Plasma exchange

Plasma exchange (Option B) is incorrect.

Even though plasma exchange has been used in the management of severe myasthenia gravis, its exact role remains unclear.

C	Ciclosporin

Ciclosporin (Option C) is incorrect.

Ciclosporin is the disease-modifying (steroid-sparing) agent with the best available evidence.

D	Immunoglobulins

Immunoglobulins (Option D) is incorrect.

Similarly to plasma exchange, the use of immunoglobulins has also been advocated, with some success, but is not backed by significant evidence. Give the rarity of this condition, studies are relatively small and therefore

A 29-year-old woman, whose husband died of colonic carcinoma 1 year ago, has attended the Emergency Department six times in the past 5 months complaining of acute abdominal pain. Each time, nothing abnormal is found. She also complains of tiredness and chronic back pain, which have been ongoing for the past 4 years.

Investigations:

Hb	13.5 g/dl
WCC	5.4×10^9/l
PLT	230×10^9/l
Na^+	140 mmol/l
K^+	5.0 mmol/l
Creatinine	90 μmol/l
ESR	9 mm/h
Faecal occult blood	Negative

Which of the following is the most likely diagnosis?

PLT	230×10^9/l
Na^+	140 mmol/l
K^+	5.0 mmol/l
Creatinine	90 μmol/l
ESR	9 mm/h
Faecal occult blood	Negative

Which of the following is the most likely diagnosis?

A Irritable bowel syndrome

B Hypochondriasis

C Adjustment disorder

D Somatic symptom disorder

E Munchausen's syndrome

D Somatic symptom disorder

SSD often arises in conjunction with disorders such as depression and anxiety, but this does not have to be the case. In SSD the symptoms are real and may be debilitating – the patient is not 'faking it'. This woman has been exposed to a significant period of stress and bereavement and it's possible that may be contributing to her unexplained physical symptoms. Treatment of this condition centres on explanation of the diagnosis, treating any underlying depression and possibly using cognitive behavioural therapy.

A Irritable bowel syndrome

IBS is a functional bowel disorder which presents with intermittent episodes of abdominal bloating and diarrhoea, in contrast to the picture here. Symptoms may of course worsen during times of psychological stress.

B Hypochondriasis

Hypochondriasis is similar to SSD, but in hypochondriasis patients may typically accept that symptoms are minor, yet still harbour the abnormal belief they have a serious underlying disease.

C Adjustment disorder

Adjustment disorder is associated with depressive symptoms, rather than the physical symptoms seen in this patient. It may be triggered by a stressful life event including the death of a loved one.

E Munchausen's syndrome

Munchausen syndrome, which is very rare, is associated with repeated and deliberate portrayal of symptoms of a disorder when the patient is not actually unwell. It is a form of factitious disorder.

A 64-year-old woman was admitted with a history of urinary incontinence of 3 months duration. Her daughter noticed that she had become clumsy and forgetful even before she had developed incontinence. Her handwriting had deteriorated, with her hand shaking too much to produce anything legible at all.

On examination, her BP was 152/82 mmHg, pulse 85 bpm and regular. She was quiet and subdued, failed the 7 subtraction test but could identify her daughter and remember her date of birth. With respect to objects, whilst she could name them correctly she was unable to recall them. Tremor was clearly evident when you asked her to stretch out both her hands. Tendon reflexes were brisk, with down-going plantars. When you asked her to walk her gait was slow and wide-based with only small steps.

Investigations:

Hb	13.1 g/dl
WCC	8.0×10^9/l

PLT	203×10^9/l
Na^+	138 mmol/l
K^+	4.3 mmol/l
Creatinine	122 μmol/l
ALT	45 U/l
Bilirubin	18 μmol/l
CSF	Normal constituents, opening pressure 22 cm H_2O

Once the suspected diagnosis is confirmed, what is the most appropriate treatment?

A Memantine

B Donepezil

C Piracetam

D CSF drainage

K^+	4.3 mmol/l
Creatinine	122 μmol/l
ALT	45 U/l
Bilirubin	18 μmol/l
CSF	Normal constituents, opening pressure 22 cm H_2O

Once the suspected diagnosis is confirmed, what is the most appropriate treatment?

A	Memantine
B	Donepezil
C	Piracetam
D	CSF drainage
E	Deep brain stimulation

D CSF drainage

The triad of cognitive impairment, gait disturbance and incontinence raises the possibility of normal pressure hydrocephalus. Drainage of 20–30 ml of CSF may lead to clinical improvement. The degree of cognitive improvement determines whether future therapeutic lumbar puncture is planned or whether the patient is a candidate for shunting. Computed tomography (CT) or MRI of the head shows hydrocephalus with no obstruction to CSF flow. On T2-weighted images, periventricular oedema may be seen.

A Memantine

Memantine NDMA receptor antagonist which is used in the treatment of dementia. The raised opening CSF pressure, however, means that normal-pressure hydrocephalus should first be excluded as a diagnosis.

excluded as a diagnosis.

B	Donepezil

This is a cholinesterase inhibitor used for the treatment of Alzheimer's dementia. The CSF opening pressure, however, suggests that hydrocephalus should be excluded first before considering pharmacotherapy for memory loss.

C	Piracetam

Piracetam is prescribed in the UK for myoclonus, and as such it has no role here in the treatment of normal-pressure hydrocephalus.

E	Deep brain stimulation

Deep brain stimulation is a treatment for Parkinson's disease resistant to pharmacological intervention.

32773

Rate this question:

A 27-year-old man presents to the GP surgery complaining of a general feeling of weakness. He says that he has also noticed that towards the evenings his eyelids begin to droop.

On clinical examination, you are able to demonstrate fatiguability. There is no muscle tenderness and no rashes on examination of his skin. His blood pressure is 128/70 mmHg, pulse is 70/min and regular and his BMI is 28.

Which of one the following may be associated with his neurological condition?

A	Diabetes insipidus
B	Friedrich's ataxia
C	Hypothyroidism
D	Myotonia congenita
E	Orofacial dyskinesia

7:43
tps://mypastest.pastest.com 15

A 27-year-old man presents to the GP surgery complaining of a general feeling of weakness. He says that he has also noticed that towards the evenings his eyelids begin to droop.

On clinical examination, you are able to demonstrate fatiguability. There is no muscle tenderness and no rashes on examination of his skin. His blood pressure is 128/70 mmHg, pulse is 70/min and regular and his BMI is 28.

Which of one the following may be associated with his neurological condition?

Your answer was correct

A	Diabetes insipidus
B	Friedrich's ataxia
C	Hypothyroidism

C Hypothyroidism

The hallmark of myasthenia gravis is fatiguable weakness. The disease tends to affect two age groups, with one peak in the second and third decade, which usually affects women, and a second peak in the sixth and seventh decade, usually affecting men. The following muscle groups are commonly affected, in decreasing order of likelihood: extra-ocular, bulbar, face, neck, limb girdle, distal limbs and trunk. Treatment modalities include the use of the cholinesterase inhibitor pyridostigmine for symptom control, immunosuppression with prednisolone and azathioprine for longer-term maintenance. Disorders associated with myasthenia include: thyrotoxicosis, hypothyroidism, rheumatoid arthritis, diabetes mellitus, dermatomyositis, pernicious anaemia and thymic tumour.

A Diabetes insipidus

Diabetes insipidus is a condition characterised by large amounts of dilute urine and increased thirst due to ADH deficiency or lack of response to ADH. This is not associated with myasthenia gravis.

B	Friedrich's ataxia

Friedreich's ataxia is an autosomal recessive inherited disease that causes progressive damage to the nervous system. It manifests in initial symptoms of poor coordination, such as gait disturbance; it can also lead to scoliosis, heart disease and diabetes, but does not affect cognitive function. This is not associated with myasthenia gravis.

D	Myotonia congenita

Myotonia congenita is a congenital neuromuscular channelopathy that affects skeletal muscles. It is a genetic

This is not associated with myasthenia gravis.

D	Myotonia congenita

Myotonia congenita is a congenital neuromuscular channelopathy that affects skeletal muscles. It is a genetic disorder. The hallmark of the disease is the failure of initiated contraction to terminate, often referred to as delayed relaxation of the muscles (myotonia) and rigidity. This is not associated with myasthenia gravis.

E	Orofacial dyskinesia

Orofacial or tardive dyskinesias are involuntary repetitive movements of the mouth and face. In most cases, these occur following long-term treatment with antipsychotic drugs. This is not associated with myasthenia gravis.

71069

Rate this question:

A 65-year-old woman was admitted to the medical wards with a week-long history of morning headaches and vomiting. She has no other past medical history and does not take any regular medication.

A computerised tomography (CT) scanning revealed a single contrast enhancing supratentorial mass, with little surrounding oedema causing mass effect. She was commenced on oral dexamethasone with good symptomatic effect. She was referred to the neuro-oncology MDT who felt it was most likely a high-grade glioma.

Which of the following is the most likely definitive management plan?

A	Whole-brain irradiation
B	Intravenous dexamethasone
C	Stereotactic radiotherapy
D	Surgical resection with adjuvant post-operative

little surrounding oedema causing mass effect. She was commenced on oral dexamethasone with good symptomatic effect. She was referred to the neuro-oncology MDT who felt it was most likely a high-grade glioma.

Which of the following is the most likely definitive management plan?

A	Whole-brain irradiation
B	Intravenous dexamethasone
C	Stereotactic radiotherapy
D	Surgical resection with adjuvant post-operative radiotherapy and chemotherapy (e.g. temozolomide)
E	Symptom control only

D	Surgical resection with adjuvant post-operative radiotherapy and chemotherapy (e.g. temozolomide)

The 2016 WHO classification system has dramatically changed with regard to astrocytic and oligodendroglial tumours. These are now classified on the basis of isocitrate dehydrogenase (IDH) mutation status along with other key molecular genetic alterations, rather than strictly by histopathologic features. Typically, high-grade gliomas are managed with a combined approach of adjuvant post-operative radiotherapy and chemotherapy (e.g. temozolomide).

A	Whole-brain irradiation

Whole-brain irradiation therapy (WBRT) is typically used in patients with multiple brain metastases and as post-surgical prophylaxis for microscopic disease. The use of WBRT

microscopic disease. The use of WBRT is less common due to both advances in radiation technology, allowing for a more localised delivery of radiation, and growing concerns regarding its delayed toxicity profile.

B	Intravenous dexamethasone

This patient is already receiving oral dexamethasone and if tolerated there is no indication to change to an intravenous formulation. Dexamethasone should be given with a proton-pump inhibitor for gastric protection.

C	Stereotactic radiotherapy

Stereotactic radiotherapy is focussed radiotherapy and is used in small, clearly defined cerebral tumours (both low and high-grade and metastasis). This patient requires additional debulking surgery (for the added benefit of a biopsy for molecular classification) and chemotherapy.

A 55-year-old man presents to the General Medical Clinic with weakness affecting both his hands for the last 6 months. He has had difficulty working as a gardener because he has been dropping his tools. He has had cramping pain in his legs and aching pain, worse at the end of the day, in his neck. His wife feels that he has also been increasingly forgetful and his behaviour has been unpredictable. There is no medical history of note, no surgical history and he and his wife deny other symptoms.

On examination, there is no deficit on bedside cognitive testing, although he does appear to respond inappropriately to some questions. There is wasting of the small hand muscles bilaterally, and occasional fasciculations are visible in the lower limbs. There is mild spasticity of all four limbs with brisk reflexes throughout, and equivocal plantar responses. There is grade 4/5 weakness in the muscles of both hands with reduced speed and accuracy of movements. There are no sensory

throughout, and equivocal plantar responses. There is grade 4/5 weakness in the muscles of both hands with reduced speed and accuracy of movements. There are no sensory findings. Systemic examination is unremarkable. MRI of brain and spinal cord reveals no significant structural lesions.

What investigation would be most useful in establishing a cause for this man's symptoms?

A	Electromyography (EMG)
B	HIV test
C	Syphilis serology
D	FDG positron emission tomography (PET) of the head
E	Serum B12 level

A Electromyography (EMG)

The symptoms and signs suggest motor neurone disease (MND). A significant proportion of patients with MND have cognitive impairment and some fulfil diagnostic criteria for frontotemporal dementia. Structural imaging is often normal. EMG will show active denervation of affected muscles and helps to confirm the diagnosis.

B HIV test

HIV can cause a myriad of neurological presentations, including cognitive impairment. However, it is not associated with features of MND as seen here.

C Syphilis serology

Syphilis can cause a myriad of neurological presentations, including cognitive impairment. However, it is not associated with features of MND as

A 22-year old man, unemployed since he dropped out of school early, presented to the Emergency Department with an acute, right-sided hemiparesis. His mother said that he had been admitted to a general hospital 3 years ago for chest pain. She did not have the details of this admission.

He smokes cigarettes whenever he can afford it.

On examination, he had a malar flush and livedo reticularis on his shins. He was 1.85 m in height and had kyphoscoliosis. Heart sounds and blood pressure were normal. Mini-mental scale score was 24/30. A mild right-sided facial paresis and pyramidal weakness of the right-sided limbs was noted. Speech and the sensory system were normal.

Choose the most likely underlying diagnosis

A	Marfan's syndrome with dissection of left internal carotid artery

blood pressure were normal. Mini mental scale score was 24/30. A mild right-sided facial paresis and pyramidal weakness of the right-sided limbs was noted. Speech and the sensory system were normal.

Choose the most likely underlying diagnosis

A	Marfan's syndrome with dissection of left internal carotid artery
B	Fibromuscular dysplasia with stroke
C	Stroke due to recreational drug use
D	Homocystinuria
E	Chronic rheumatic heart disease with embolic stroke

D Homocystinuria

This is as an autosomal recessive inborn error of methionine metabolism. Phenotypically there are similarities to Marfan syndrome. This clinical scenario is typical. Patients are tall, with slender habitus, large arm span, kyphoscoliosis and arachnodactyly. The skin examination usually reveals livedo reticularis and malar flush. The hair is blonde, sparse and brittle and the lenses of the eyes may be dislocated downwards. Mild mental retardation is typical, which differentiates the somatic features of this disease from Marfan. A platelet abnormality favouring clot formation and thrombosis of the cerebral arteries has been observed, as seen in this patient, who presented with left internal capsular stroke.

A Marfan's syndrome with dissection of left internal carotid artery

Whilst this is a cause for young stroke, it would not explain all the features of this case, such as the rash and the cognitive impairment.

B	Fibromuscular dysplasia with stroke

This is another cause of young stroke, more often seen in women. This diagnosis does not explain the rash or cognitive impairment.

C	Stroke due to recreational drug use

There is no clear history of drug use, or physical stigmata to suggest it, so this seems a less likely explanation. In addition, this diagnosis cannot explain the skin rashes.

E	Chronic rheumatic heart disease with embolic stroke

Rheumatic heart disease is now very rare in the UK. There was no evidence

7:59

https://www.google.com/sea 15

Medindia

Homocystinuria | Amino Acid Metabolism Disorder - Causes, ...

Symptoms and Signs of Homocystinuria

Images may be subject to copyright. Learn More

RELATED IMAGES

Marfanoid Features #rytir
rytir.info

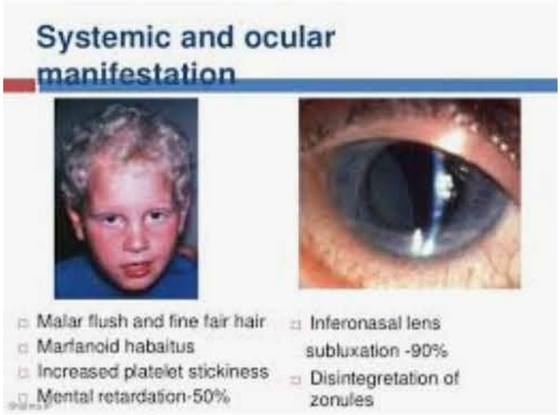

Patient V Doctor Rap Battle ...
lespigeries.be

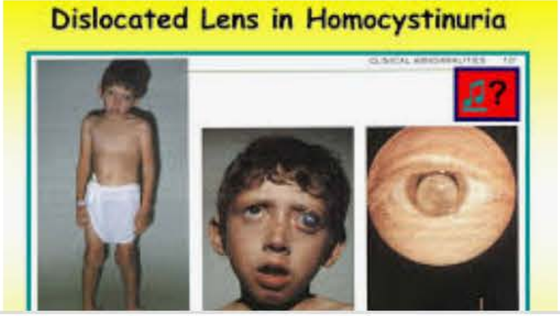

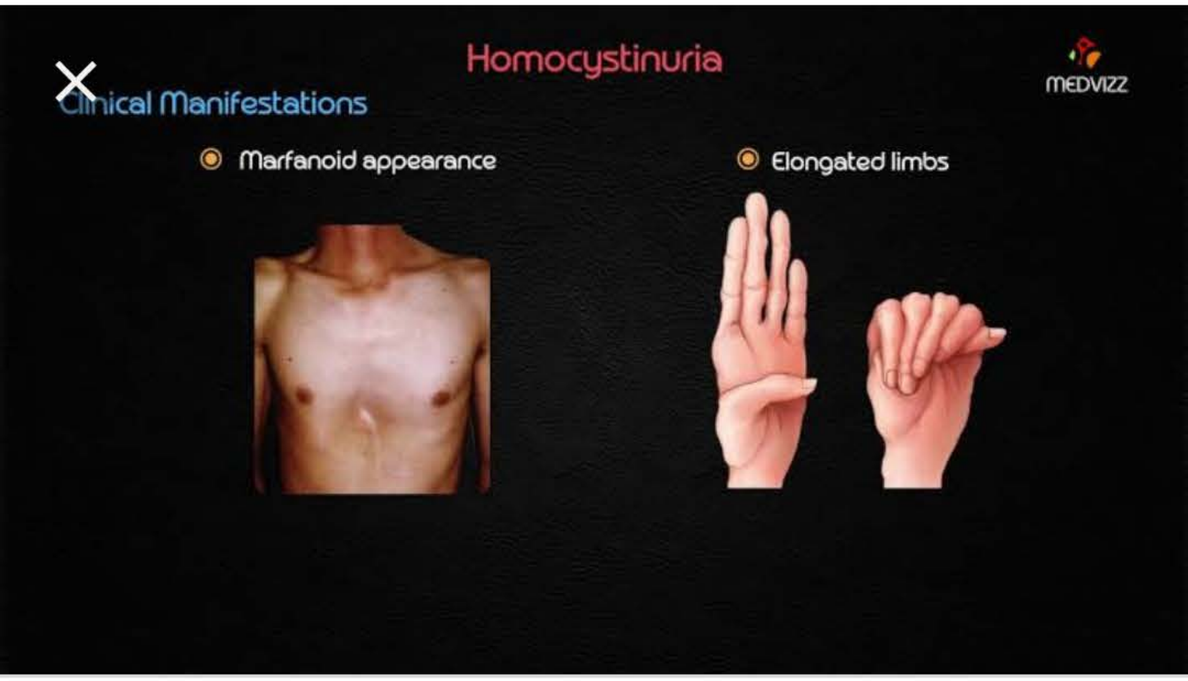

YouTube

Homocystinuria - Usmle step 1 biochemistry Webinar based le...

Watch (6:49)

Uploaded by: Dr.G.Bhanu Prakash - Usmle , FMGE anc

2.92K Views · 37 Likes

Homocystinuria is an autosomal recessive inherited disorder of methionine amino acid metabolism. Homocystinuria encompasses a group of inborn errors of metab...

Images may be subject to copyright. Learn More

RELATED IMAGES

Homocystinuria: Cystathionin...

A 56-year-old man has been admitted to the Stroke Unit after having suffered a stroke. He had no past medical history of stroke, myocardial infarction, hypertension, hypercholesterolaemia or diabetes mellitus.

On examination, his blood pressure is 170/105 mmHg, and his pulse is 66 bpm and regular. Neurological examination reveals severe left-sided weakness, left homonymous hemianopia and left sensory inattention. The computed tomography (CT) scan shows haemorrhage in the right middle cerebral artery area. Echocardiography reveals evidence of left ventricular hypertrophy, with a normal ejection fraction. Chest X-ray, full blood count, erythrocyte sedimentation rate (ESR) and blood biochemistry are normal.

What is the most important next step in the management of this patient?

A	Aggressive antihypertensive treatment should be started to reduce mortality

haemorrhage in the right middle cerebral artery area. Echocardiography reveals evidence of left ventricular hypertrophy, with a normal ejection fraction. Chest X-ray, full blood count, erythrocyte sedimentation rate (ESR) and blood biochemistry are normal.

What is the most important next step in the management of this patient?

A	Aggressive antihypertensive treatment should be started to reduce mortality
B	Aspirin should be started
C	Rehabilitation and meticulous nursing support
D	The patient should be anticoagulated
E	The patient should be thrombolysed

C Rehabilitation and meticulous nursing support

Rehabilitation plays a vital role in the management of stroke. There is evidence that patients cared for in specialised units with meticulous nursing have a better outcome than those nursed on general wards.

A Aggressive antihypertensive treatment should be started to reduce mortality

This patient has had a haemorrhage in the middle cerebral artery territory, resulting in total anterior circulation syndrome. Most strokes are occlusive, and only about 10% of strokes are haemorrhagic in origin. Aggressive control of hypertension has not been shown to impact on mortality or severe disability but has been associated with some improvement in functional status.

B Aspirin should be started

In the immediate post-haemorrhage period, patients should not be given aspirin or other antiplatelet therapy because of concerns about further bleeding. In the long-term, the pros and cons of ischaemic stroke and heart attack prevention need to weighed against those of recurrent bleeding.

D	The patient should be anticoagulated

This patient should not be anticoagulated because the CT scan shows that the stroke is haemorrhagic in nature. Aspirin is given in ischaemic strokes.

E	The patient should be thrombolysed

Given the haemorrhagic nature of the stroke, thrombolysis should not be administered.

A 72-year-old man presents with a 12-week history of weakness affecting his lower limbs, constipation, dry mouth and urinary hesitancy. He has a cough productive of yellow/brown sputum. He is also noted to have mild drooping of his eyelids. He has a history of chronic obstructive pulmonary disease (COPD), for which he takes a Combivent two puffs QDS.

He has had two infective exacerbations of COPD in the past six months, for which his general practitioner prescribed him oral antibiotics. However, he has not required hospital admission. He has smoked 30 cigarettes per day for 40 years, drinks 12 units of alcohol per week, and lives with his wife.

On examination, he has mild bilateral ptosis. He has bilateral proximal weakness of his lower limbs with reduced reflexes and normal sensation. Although grip strength is reduced, it improves with repeated testing.

Investigations reveal:

Investigations reveal:

White cell count (WCC)	8.6×10^9/l
Haemoglobin	11.2×10^9/l
Platelets	224×10^9/l
Na^+	131 mmol/l
K^+	3.6 mmol/l
Urea	6.8 mmol/l
Creatinine	98 μmol/l
Chest X-ray	Hyperexpanded lung fields; opacification of the right heart border

What is the likely diagnosis?

A	Guillain–Barré syndrome
B	Myasthenia gravis
C	Motor neurone disease

Platelets	224 × 10⁹/l
Na^+	131 mmol/l
K^+	3.6 mmol/l
Urea	6.8 mmol/l
Creatinine	98 μmol/l
Chest X-ray	Hyperexpanded lung fields; opacification of the right heart border

What is the likely diagnosis?

A	Guillain–Barré syndrome
B	Myasthenia gravis
C	Motor neurone disease
D	Lambert–Eaton syndrome
E	Polymyositis

K^+	3.6 mmol/l
Urea	6.8 mmol/l
Creatinine	98 μmol/l
Chest X-ray	Hyperexpanded lung fields; opacification of the right heart border

What is the likely diagnosis?

Your answer was correct

A Guillain–Barré syndrome

B Myasthenia gravis

C Motor neurone disease

D Lambert–Eaton syndrome

E Polymyositis

Explanation

D Lambert–Eaton syndrome

Lambert-Eaton myasthenic syndrome is a presynaptic syndrome characterised by impaired release of acetylcholine from nerve terminals. It is believed to be caused by circulating antibodies to voltage-gated calcium channels. The presentation of Lambert–Eaton syndrome is with gradual onset of limb weakness, usually in the legs in a proximal pattern. Patients usually describe fatigue on exercise, though there is a paradoxical increase in strength on repeated muscle stimulation. Reflexes are usually absent or depressed, but also show post-tetanic potentiation. Ocular symptoms and signs may occur in LEMS but are less common and less severe than in myasthenia gravis. Mild ptosis occurs in 25% of cases. Autonomic features such as dry mouth, constipation and impotence may be present. Sixty per cent of patients with Lambert–Eaton syndrome have small-cell lung cancer. This patient most likely has Lambert

This patient most likely has Lambert Eaton syndrome as a complication of lung cancer which is suggested by his history of cough, heavy smoking and abnormal chest X-ray findings.

A Guillain–Barré syndrome

Guillain Barré syndrome is incorrect because the distribution of weakness and other neurological findings are not in keeping with this diagnosis.This usually presents with an acute onset of ascending weakness with a lower motor neurone pattern.

B Myasthenia gravis

Myasthenia gravis is incorrect as fatigable weakness seen in this condition rather than improvement with repetitive testing.

C Motor neurone disease

Motor neurone disease is incorrect as the weakness in this condition does

Myasthenia gravis is incorrect as fatigable weakness seen in this condition rather than improvement with repetitive testing.

C	Motor neurone disease

Motor neurone disease is incorrect as the weakness in this condition does not improve with repetitive testing and no other suggestive features such as fasiculations are mentioned. This condition is not associated with cancer.

E	Polymyositis

Polymyositis is incorrect as the weakness in this condition does not improve with repetitive testing. This condition can, however, be associated with cancer and also results in proximal weakness.

7599

Rate this question:

9:41
https://mypastest.pastest.com

A Unfractionated heparin

This patient has ongoing chest pain. Given her cardiac history, she is at significant risk of further infarct. Cardiac risk is calculated using risk-scoring systems such as GRACE. Using that score, this patient's 6-month risk of death is around 10%, deemed 'highest risk' according to NICE guidance (see weblink below). This has significant implications for her ongoing management and means that she is likely to have angiography within the next 24 h. In this situation, NICE recommends unfractionated heparin over fondaparinux. A glycoprotein inhibitor such as tirofiban or abciximab is also indicated in high-risk patients such as this.

E Bivalirudin

Bivalirudin, is an alternative to unfractionated heparin with a glycoprotein inhibitor where angiography is considered within 24 h. It is also used in patients who suffer from heparin-induced thrombocytopenia.

B Enoxaparin

Enoxaparin, was formerly used for acute coronary syndrome (ACS), and still is in some trusts, though is no longer part of NICE guidance.

C Fraxiparin

Fraxiparin is a low-molecular weight heparin similar to enoxaparin.

D Fondaparinux

Fondaparinux, is the antithrombin agent of choice if

Share Favorite Delete Edit More

9:37

A 70-year-old woman is admitted to the Emergency Department with central crushing chest pain, nausea, sweating and syncope. She has had two inferior myocardial infarctions in the past 3 years. She has type 2 diabetes, for which she takes metformin. Recent echocardiography revealed an ejection fraction of 30%.

On examination, BP is 124/80 mmHg and pulse 85/min. There are bi-basal crackles on auscultation of the chest. A dull chest pain persists.

Investigations:

Hb	12.9 g/dl
WCC	10.2 x10^9/l
PLT	243 x10^9/l
Na^+	138 mmol/l
K^+	4.3 mmol/l
Creatinine	131 micromol/l
6hr troponin	3.9
ECG	ST depression in V1-V4

She is given aspirin 300 mg and clopidogrel 300 mg. Her pain gradually settles.

Which of the following is the most appropriate next step (according to current NICE guidelines)?

A Unfractionated heparin

B Enoxaparin

C Fraxiparin

D Fondaparinux

Share Favorite Delete Edit More

A 29-year-old woman presents to her GP complaining of having had zig-zag lights in her peripheral vision that resolved after about 15 min, but were followed by a unilateral throbbing headache that has been present for 2 days. She has also felt very nauseated and consequently her mood has been depressed. She has had these headaches before, but they have been less severe and not necessarily on the same side. She recalls that her mother used to have similar headaches.

Medication includes the oral contraceptive pill. She recently started a new office job, working in software design.

Which of the following is the most likely trigger for this patient's headaches and the recent increase in severity?

A	Caffeine
B	Fever

used to have similar headaches.

Medication includes the oral contraceptive pill. She recently started a new office job, working in software design.

Which of the following is the most likely trigger for this patient's headaches and the recent increase in severity?

A	Caffeine
B	Fever
C	NSAIDs (non-steroidal anti-inflammatory drugs)
D	Pineapple juice
E	Pregnancy

32697

Submit

A 29-year-old woman presents to her GP complaining of having had zig-zag lights in her peripheral vision that resolved after about 15 min, but were followed by a unilateral throbbing headache that has been present for 2 days. She has also felt very nauseated and consequently her mood has been depressed. She has had these headaches before, but they have been less severe and not necessarily on the same side. She recalls that her mother used to have similar headaches.

Medication includes the oral contraceptive pill. She recently started a new office job, working in software design.

Which of the following is the most likely trigger for this patient's headaches and the recent increase in severity?

Your answer was correct

A Caffeine

A Caffeine

Migraine is a recurrent headache causing sleep disruption, depression and misery to sufferers. Evidence suggests that it is a genetic disorder, the mechanisms of which are not completely understood. It has a preponderance for affecting women. The typical headache is throbbing or pulsatile and begins unilaterally and anteriorly, progressing posteriorly over 1–2 h. It may last from several hours to several days. The migraine aura is a complex of neurological symptoms that precede or accompany the headache phase, or they may occur in isolation. The characteristic visual aura begins with flashing zig-zag lights in the centre of a visual hemi-field, which expand peripherally (zig-zag fortification spectra) and are associated with a scotoma. Patients may also complain of dots or spots in their visual field, or the jumbling of words on a line when reading. There are several known triggers for migraine, only some of which are dietary. Common triggers include sleep

migraine, only some of which are dietary. Common triggers include sleep deprivation and hunger. Of the dietary triggers, caffeine is seen commonly and is always worth asking about as cessation may bring about significant improvement. Other dietary triggers include chocolate, cheese, alcohol and citrus fruits. In approximately half of all migraine sufferers, no trigger for their attack is found.

B	Fever

Fever is not a feature of migraine, nor is it a typical trigger.

C	NSAIDs (non-steroidal anti-inflammatory drugs)

NSAIDs are not generally a trigger for migraine, although analgesia overuse is associated with chronic headache.

D	Pineapple juice

Pineapple juice is not a typical trigger

Migraine is a recurrent headache causing sleep disruption, depression and misery to sufferers. Evidence suggests that it is a dominantly inherited disorder the mechanisms of which are not completely understood. It has preponderance for affecting women. The typical headache is throbbing or pulsatile and begins unilaterally and anteriorly, progressing posteriorly over 1–2 hours. It may last from several hours to several days. The migraine aura is a complex of neurological symptoms that precede or accompany the headache phase or they may occur in isolation. The characteristic visual aura begins with flashing zigzag lights in the centre of a visual hemifield, which expand peripherally (zigzag fortification spectra) and are associated with a scotoma. Patients may also complain of dots or spots in their visual field or the jumbling of words on a line when reading. There are known triggers for migraine, only a fraction of which are dietary. These include chocolate, aged cheese and meats, alcohol, citrus fruits, anxiety, travel or exercise. In

A 22-year-old man presents to the GP complaining of difficulty walking up the stairs at home. He tells you that his father died in his early 50s after a severe pneumonia, but he had to sleep propped up in bed and seemed short of breath for many months before his death. You understand that his parents were first cousins. The patient tells you that he has always found exercise difficult, and struggled particularly with sport at school. He now has a sedentary job in an office.

On examination, he has proximal weakness in his legs, with lower motor neurone signs. There is mild upper limb weakness, but this is much less marked than in the lower limbs.

Which of the following is the most likely diagnosis?

A	Myotonic dystrophy
B	Myasthenia gravis
C	Amyotrophic lateral sclerosis

that he has always found exercise difficult, and struggled particularly with sport at school. He now has a sedentary job in an office.

On examination, he has proximal weakness in his legs, with lower motor neurone signs. There is mild upper limb weakness, but this is much less marked than in the lower limbs.

Which of the following is the most likely diagnosis?

A	Myotonic dystrophy
B	Myasthenia gravis
C	Amyotrophic lateral sclerosis
D	Spinal muscular atrophy (SMA) type 1
E	Spinal muscular atrophy (SMA) type 3

6:52
tps://mypastest.pastest.com 15

A 22-year-old man presents to the GP complaining of difficulty walking up the stairs at home. He tells you that his father died in his early 50s after a severe pneumonia, but he had to sleep propped up in bed and seemed short of breath for many months before his death. You understand that his parents were first cousins. The patient tells you that he has always found exercise difficult, and struggled particularly with sport at school. He now has a sedentary job in an office.

On examination, he has proximal weakness in his legs, with lower motor neurone signs. There is mild upper limb weakness, but this is much less marked than in the lower limbs.

Which of the following is the most likely diagnosis?

Your answer was incorrect

A Myotonic dystrophy

E Spinal muscular atrophy (SMA) type 3

The hereditary spinal muscular atrophies comprise a group of autosomal recessive disorders characterised by progressive lower motor neurone weakness. Type 3 SMA is known as the chronic juvenile form, the symptoms of which first appear after the age of 18 months. It may be associated with a normal life expectancy, and patients may have near normal motor function apart from difficulties climbing the stairs due to proximal lower limb weakness. Bulbar palsy occurs late in the disease and may have been responsible for the recurrent pneumonia and progressive respiratory failure suffered by his father. Pathological study reveals the progressive loss of anterior horn cells in the spinal cord and cranial nerve nuclei.

A Myotonic dystrophy

Myotonic dystrophy is an inherited condition associated with progressive muscle wasting and weakness, with delayed relaxation of grip due to myotonia. Frontal hair loss, cataract formation and male infertility are further features (the male infertility making it unlikely to be the diagnosis here).

B	Myasthenia gravis

Myasthenia gravis presents with gradually worsening proximal muscle weakness and is autoimmune in origin. It is not inherited.

C	Amyotrophic lateral sclerosis

Features seen in amyotrophic lateral sclerosis, such as earlier bulbar palsy, muscle weakness affecting both upper and lower limbs, and fasciculations, are absent here.

D	Spinal muscular atrophy (SMA) type 1

formation and male infertility are further features (the male infertility making it unlikely to be the diagnosis here).

B Myasthenia gravis

Myasthenia gravis presents with gradually worsening proximal muscle weakness and is autoimmune in origin. It is not inherited.

C Amyotrophic lateral sclerosis

Features seen in amyotrophic lateral sclerosis, such as earlier bulbar palsy, muscle weakness affecting both upper and lower limbs, and fasciculations, are absent here.

D Spinal muscular atrophy (SMA) type 1

This leads to death a few weeks after birth due to rapid motor neuron death.

A 50-year-old woman was admitted with a history of unremitting headache of 4 months' duration. Two months ago, she noticed a dirty discharge from her left ear and culture grew *Aspergillus fumigatus*. The symptom resolved, however, after she used some eardrops prescribed by the ENT specialist.

One week ago, she noticed double vision and was also concerned about a new onset of sciatic pain along the left lower limb. She had undergone (right) breast resection surgery for carcinoma 5 years ago and had had chemotherapy subsequently.

Tamoxifen was the only drug she was taking at the present time. On examination, she was alert and oriented. Her BP was 148/88, with pulse 88 and regular. Her BMI was 25. Bilateral papilloedema was evident. Both lateral recti were paretic. A mild lower motor neurone facial paresis was present on the left side. The left ankle jerk was hypoactive and planters were flexors on both sides.

Investigations:

Hb	10 g/l
WCC	14.0×10^9/l
Urea	6.0 mmol/l
Glucose	6.6 mmol/l
Creatinine	104 µmol/l
ALT	80 IU/l
ESR	104 mm/h
MRI brain	Scattered leptomeningeal enhancement on the T1 gadolinium enhanced scan

Cerebrospinal fluid (CSF):

Opening pressure	22 cm H_2O
Lymphocytes	25/mm^3
Cytospin	No malignant cells seen
Protein	500 mg/l

pressure	
Lymphocytes	25/mm^3
Cytospin	No malignant cells seen
Protein	500 mg/l
Glucose	4.0 mmol/l

Bacterial cultures, India ink preparation for cryptococci and Ziehl-Neelsen stain for acid-fast bacilli were all negative.

What is the most likely diagnosis?

A	Carcinomatous meningitis
B	Fungal meningitis
C	Idiopathic intracranial hypertension
D	Tuberculous meningitis
E	Lyme's disease

A 50-year-old woman was admitted with a history of unremitting headache of 4 months' duration. Two months ago, she noticed a dirty discharge from her left ear and culture grew *Aspergillus fumigatus*. The symptom resolved, however, after she used some eardrops prescribed by the ENT specialist.

One week ago, she noticed double vision and was also concerned about a new onset of sciatic pain along the left lower limb. She had undergone (right) breast resection surgery for carcinoma 5 years ago and had had chemotherapy subsequently.

Tamoxifen was the only drug she was taking at the present time. On examination, she was alert and oriented. Her BP was 148/88, with pulse 88 and regular. Her BMI was 25. Bilateral papilloedema was evident. Both lateral recti were paretic. A mild lower motor neurone facial paresis was present on the left side. The left ankle jerk was hypoactive and planters were flexors on both sides.

A Carcinomatous meningitis

Meningeal carcinomatosis is seen in 5% of cases of adenocarcinoma of the breast, lung, gastrointestinal tract, melanoma, lymphoma etc. The clinical presentation is variable and hence diagnosis is difficult. It may present with headache, sciatic pain, cauda equina syndrome, multiple cranial nerve palsies, confusional state, seizures, focal neurological deficits or poly-radiculoneuropathy. The diagnosis is established by identifying tumour cells in the cerebrospinal fluid (CSF) using cytospin, millipore filtering and flow cytometry.

It is important to note that several CSF examinations are usually required using generous quantities of CSF to arrive at the diagnosis, and tumour cells are not always seen on the initial sample. CSF opening pressure is increased and lymphocytic pleocytosis up to 100 cells/mm^3, elevation of protein and low glucose are common findings. Prognosis is bleak. The median duration of survival is 6

median duration of survival is 6 months. Intrathecal chemotherapy is the mainstay of therapy, as this allows hydrophilic agents to overcome the blood brain barrier.

B	Fungal meningitis

Fungal meningitis is less likely to be the cause of her symptoms, given that no focus of infection was identified on the MRI scan, and the changes are consistent with leptomeningeal metastases.

C	Idiopathic intracranial hypertension

IIH is unlikely given the BMI is 25, the CSF sample is abnormal and the elevated inflammatory markers raise the possibility of carcinomatous meningitis, which should be excluded first.

D	Tuberculous meningitis

A 26-year-old woman, who is 25 weeks' pregnant, presents to the GP complaining of her right foot dragging and tripping her up, particularly when she walks up stairs. Previously her health has been very good, with only mild asthma managed with a Seretide 50 inhaler.

On examination she looks well, with a BP of 105/75 mmHg; neurological examination reveals mild foot drop consistent with a right common peroneal nerve palsy.

Investigations:

Hb	10.9 g/dl
WCC	5.4×10^9/l
PLT	202×10^9/l
Na^+	140 mmol/l
K^+	4.9 mmol/l
Creatinine	80 μmol/l
ESR	10 mm/hr
CRP	< 3

K^+	4.9 mmol/l
Creatinine	80 µmol/l
ESR	10 mm/hr
CRP	< 3
ANCA	Negative

Which of the following is the most appropriate management step for this patient?

A Oral prednisolone

B Lumbar puncture

C Referral for occupational therapy and physiotherapy

D MRI brain and spinal cord

E Nerve conduction studies

C Referral for occupational therapy and physiotherapy

This patient has a common peroneal nerve palsy. This is most likely due to compression of the nerve around the fibular head. This commonly occurs due to either sitting cross-legged or repetitive crouching – such factors should be sought in the history and the patient needs to be told to avoid this. The problem usually resolves spontaneously and a conservative approach is reasonable, especially given her pregnancy. She should be followed up and, if her symptoms worsened or changed, she may need further investigation.

A Oral prednisolone

Oral prednisolone is effective in improving recovery of nerve function in Bell's palsy, but there is no evidence to support its use in peroneal nerve palsy.

in Bell's palsy, but there is no evidence to support its use in peroneal nerve palsy.

B	Lumbar puncture

Given the absence of any CNS dysfunction, there is no evidence to support lumbar puncture as in investigation in this case.

D	MRI brain and spinal cord

There is no evidence of CNS disease and thus MRI will not be helpful. MRI is generally avoided in pregnancy unless there is urgent need.

E	Nerve conduction studies

Nerve conduction studies will merely confirm peroneal nerve dysfunction, but are unlikely to contribute to further management.

20624

Rate this question:

A 22-year-old saleswoman is admitted to the emergency department with a 2-day history of generalised headache, vomiting, unsteadiness, dizziness and blurred vision.

The unsteadiness has been progressive over a number of weeks, and colleagues have mentioned to her that her speech has become slurred. She has also lost 1 stone in weight within the last month, although she has attributed this to pressure at work, as she feels increasingly nauseated and tired.

She has a past medical history of epilepsy diagnosed at the age of 8 years and has had photocoagulation of her left eye for multiple angioma. Her current medication includes phenytoin and the oral contraceptive pill.

On examination she is lethargic and has marked dysarthria. Her blood pressure is 143/89 mmHg and pulse 82/min. Fundoscopy examination reveals bilateral papilloedema and evidence of previous photocoagulation. She has reduced

visual acuity of 6/9 in both eyes. Pupils are equal and reactive to light. The rest of the cranial nerves are normal. On examination of the upper and lower limbs, tone, power and reflexes all appear normal; however, there is a marked intention tremor bilaterally and her gait is broad based and ataxic. Sensory examination appears normal.

Chest examination appears normal, but on abdominal examination there is a palpable right flank mass.

Her magnetic resonance scan of the brain reveals bilateral haemangioma in both cerebellar hemispheres and enlarged lateral and third ventricles.

Investigations:

Hb	17.5 g/dl
RBC	7.0 × 1012 (3.9–5.6)
MCV	88 fl (80–96)
WCC	9.8×10^9/l
PLT	399×10^9/l
Na^+	133 mmol/l

K^+	4.5 mmol/l
Urea	8.0 mmol/l
Creatinine	220 µmol/l
Ca++	2.7 mmol/l
Phenytoin	81 µmol/l (40–80)
Urine	Blood+++, protein++

Given the above findings, what is the likely underlying diagnosis in this patient?

A	Phenytoin toxicity
B	Renal carcinoma with cerebellar metastases
C	Von Hippel–Lindau disease (VHL)
D	Neurofibromatosis type II
E	Tuberous sclerosis

C	Von Hippel-Lindau disease (VHL)

This patient has features in keeping with a diagnosis of VHL. Diagnosis is based on haemangioblastomas of the central nervous system or retina and the presence of one associated VHL tumour (renal cell carcinoma, islet cell tumour or adenoma).

This patient has bilateral cerebellar haemangioma, which have led to compression of the fourth ventricle, and hydrocephalus manifest by headache, papilloedema and vomiting.

There is a history given of retinal angioma, and it appears she has developed a renal cell carcinoma with secondary polycythaemia as evidenced by right flank mass, haematuria and deranged biochemistry.

A	Phenytoin toxicity

This is a cause of ataxia, headache and vomiting but is not the cause in this case and cannot account for all the

cerebellar metastases

The patient likely has renal cell carcinoma with polycythaemia (ectopic EPO production), but there are features here to suggest this is just part of the broader syndrome of VHL.

D Neurofibromatosis type II

NF type II causes acoustic schwannomas, which may be bilateral, and meningiomas with fewer skin stigmata compared to type I.

E Tuberous sclerosis

This presents with seizures, retinal hamartomas and calcified tubers on imaging. In some cases patients can develop cerebellar astrocytomas. Renal cell carcinomas are very rare, although patients may develop renal angiomyolipomas. Almost all patients have skin manifestations such as facial angiofibromas, periungal fibromas and hypomelanotic macules (ash leaf

A 19-year-old man is referred to the Neurology Outpatient Department by his general practitioner (GP) who suspects that he may have neurofibromatosis (NF). He is of short stature and has mild learning difficulties. He also suffers from mild hypertension.

A photograph of the affected area is shown below.

Which of the following combinations of criteria would establish the diagnosis in this patient?

A	Six or more café-au-lait macules > 5 mm and axillary freckling
B	Six or more café-au-lait macules > 15 mm and the presence of a juvenile cataract
C	Two or more neurofibromas of any type and a Lisch nodule
D	Sphenoid dysplasia and two or more Lisch nodules
E	Renal artery stenosis and freckling in the inguinal region

D	Sphenoid dysplasia and two or more Lisch nodules

Sphenoid wing dysplasia is characteristic, but not pathognomonic of type 1 NF. In company with Lisch nodules, this is consistent with a diagnosis of type 1 NF.

A	Six or more café-au-lait macules > 5 mm and axillary freckling

Type 1 NF (von Recklinghausen's disease) is an autosomal dominant condition with variable expression. The affected gene is on chromosome 17. Mild learning difficulties are common in these patients, and hypertension may occur in association with renal artery stenosis or phaeochromocytoma.

The diagnosis of NF in this adult patient fails to meet the following criterion: six or more café-au-lait macules > 15 mm in size.

B	Six or more café-au-lait macules > 15 mm and the presence of a juvenile cataract

The presence of juvenile cataracts does not form part of the diagnostic criteria for type 1 NF.

C	Two or more neurofibromas of any type and a Lisch nodule

Two or more Lisch nodules would need to be present for the diagnosis of type 1 NF to be made.

E	Renal artery stenosis and freckling in the inguinal region

The diagnosis of type 1 NF is made of two or more of the following criteria present:

- six or more café-au-lait macules > 5 mm (prepubertal) or > 15 mm

E	Renal artery stenosis and freckling in the inguinal region

The diagnosis of type 1 NF is made of two or more of the following criteria present:

- six or more café-au-lait macules > 5 mm (prepubertal) or > 15 mm (post-pubertal)
- two or more neurofibromas of any type or one plexiform
- freckling in the axillary or inguinal regions
- optic glioma
- two or more Lisch nodules on the iris
- distinctive osseous lesion typical of type 1 NF, eg sphenoid dysplasia, thickening of the long bone cortex with or without pseudo-arthrosis
- a first-degree relative with type 1 NF.

7:29
https://www.google.com/sea
15

Radiopaedia

Sphenoid wing dysplasia | Radiology Reference Article ...

Sphenoid wing dysplasia | Radiology Reference Article | Radiopaedia.org

American Journal of Neur...

Reassessment of Sphenoid Dysplasia Associated with ...

Download figure ...

Images may be subject to copyright. Learn More

RELATED IMAGES

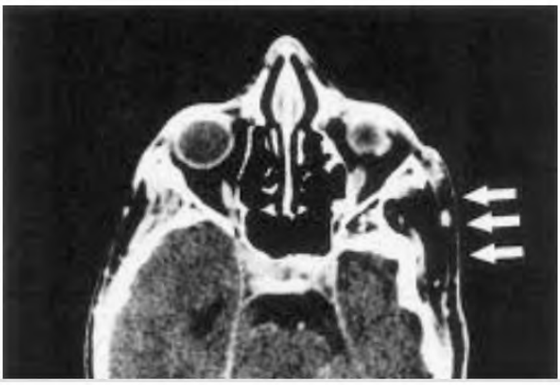

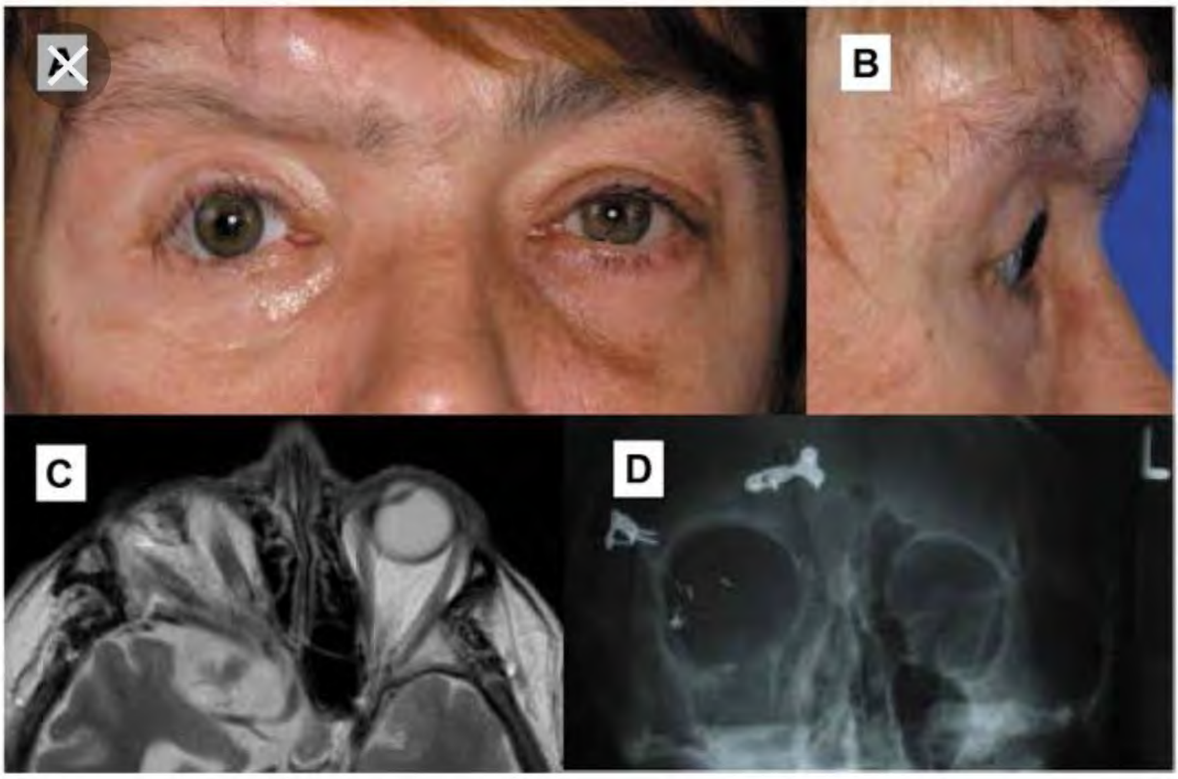

Anticancer Research - Inte...

Ipsilateral Sphenoid Wing Dysplasia, Orbital Plexiform ...

Ipsilateral Sphenoid Wing Dysplasia, Orbital Plexiform Neurofibroma and Fronto-Parietal Dermal Cylindroma in a Patient with Segmental Neurofibromatosis

Images may be subject to copyright. Learn More

RELATED IMAGES

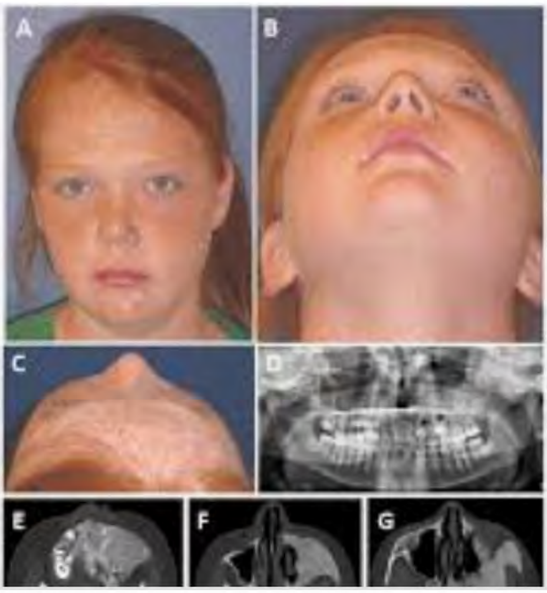

Neurofibromatosis Type 1 As...
touchophthalmology.com

JAMA Network

Absence of the Greater Sphenoid Wing in Neurofibromatosis 1 ...

Photograph showing craniofacial abnormalities in neurofibromatosis 1 with absence of greater sphenoid wing.

Images may be subject to copyright. Learn More

RELATED IMAGES

7:33
https://www.google.com/sea
15

Science Direct

Congenital pseudarthrosis of the tibia - ScienceDirect

Download full-size image

Images may be subject to copyright. Learn More

RELATED IMAGES

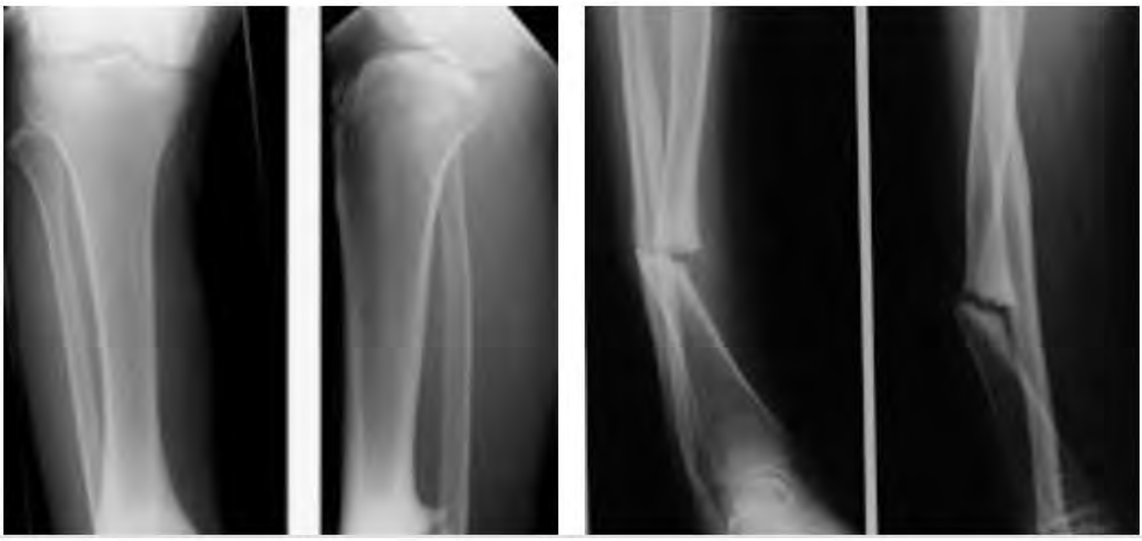

OrthopaedicsOne

Neurofibromatosis - OrthopaedicsOne Review - Orth...

Congenital pseudoarthrosis of the tibia in neurofibromatosis

Images may be subject to copyright. Learn More

RELATED IMAGES

Dysplasia Epiphysealis Hemi...
sciencedirect.com

A 58-year old woman presents to the Emergency Department with a 2-week history of facial asymmetry, first noticed by her husband who had commented that her smile was crooked. She had noted difficulty in closing her left eye fully.

For the past 6 months, she had been troubled intermittently by dizziness and pulsatile tinnitus affecting the left ear, and had noted that her hearing was getting worse. Her only past medical history was hypertension, for which she took bendroflumethiazide.

On examination, her pulse was 78 bpm and regular. Jugular venous pressure (JVP) was not raised. Blood pressure was 146/82 mmHg and heart sounds were normal. Respiratory and abdominal examinations were unremarkable. Cranial nerve examination revealed mild left facial weakness, with normal facial sensation. There appeared to be palatal deviation to the right, and on testing the gag reflex, sensation on the left side of the pharynx was diminished. Hallpike's manoeuvre was negative. Peripheral

weakness, with normal facial sensation. There appeared to be palatal deviation to the right, and on testing the gag reflex, sensation on the left side of the pharynx was diminished. Hallpike's manoeuvre was negative. Peripheral nerve examination revealed normal tone, power, reflexes, sensation and coordination bilaterally.

What is the most likely diagnosis?

A	Posterior inferior cerebellar artery aneurysm
B	Acoustic neuroma
C	Glomus jugulare tumour
D	Nasopharyngeal carcinoma
E	Carotid artery aneurysm

7585

Submit

noticed by her husband who had commented that her smile was crooked. She had noted difficulty in closing her left eye fully.

For the past 6 months, she had been troubled intermittently by dizziness and pulsatile tinnitus affecting the left ear, and had noted that her hearing was getting worse. Her only past medical history was hypertension, for which she took bendroflumethiazide.

On examination, her pulse was 78 bpm and regular. Jugular venous pressure (JVP) was not raised. Blood pressure was 146/82 mmHg and heart sounds were normal. Respiratory and abdominal examinations were unremarkable. Cranial nerve examination revealed mild left facial weakness, with normal facial sensation. There appeared to be palatal deviation to the right, and on testing the gag reflex, sensation on the left side of the pharynx was diminished. Hallpike's manoeuvre was negative. Peripheral nerve examination revealed normal tone, power, reflexes, sensation and coordination bilaterally.

C Glomus jugulare tumour

The patient's symptoms and signs indicate a lesion affecting CN VIII (dizziness, pulsatile tinnitus, reduced hearing), CN VII (left facial weakness) and CN IX (reduced sensation of gag reflex, deviation of palate to the right indicating weakness on the left side). Glomus jugulare tumours are slow-growing, highly vascular tumours derived from neural tissue and arising within the jugular foramen of the temporal bone. Cranial nerves IX–XI pass through the jugular foramen, and so are commonly involved. Less commonly, the tumours can enlarge sufficiently to cause affect cranial nerves VII and XII. The tumours grow slowly and may extend into the middle ear. Only about 4% metastasise. This patient had symptoms for 6 months, indicating a slow-growing lesion.

Glomus jugular tumours are rare, with an annual incidence is around 1 in 1.3 million people. There is a female preponderance (female:male ratio

million people. There is a female preponderance (female:male ratio between 3 and 6:1). The commonest symptoms are deafness and pulsatile tinnitus. Hearing loss may be conductive or sensorineural; with the latter there may be vertigo. Intracranial extension can produce headache, hydrocephalus and raised intracranial pressure. Otoscopic examination may reveal a characteristic pulsatile, reddish-blue mass behind the tympanic membrane.

A	Posterior inferior cerebellar artery aneurysm

Posterior inferior cerebellar artery aneurysms are rare. Most present following rupture, giving rise to typical features of subarachnoid haemorrhage. Those patients who present prior to rupture show signs of mass effect on the medulla, often resulting in palsies of CN V, VI or VII.

B	Acoustic neuroma

B	Acoustic neuroma

Acoustic neuromas are tumours of CN VIII, typically presenting with progressive, unilateral hearing loss, tinnitus or balance disturbance. Acoustic neuromas may affect other cranial nerves in the cerebellar pontine angle causing facial sensation loss or pain (CN V) and rarely facial weakness (CV VII).

D	Nasopharyngeal carcinoma

Nasopharyngeal carcinomas are notorious for involving multiple cranial nerves (usually II–VI or IX–XII). Most commonly, CN V and VI are affected, causing facial numbness, pain and diplopia. There is frequently evidence of lymph node enlargement indicating metastatic spread, and non-specific symptoms of nasal obstruction, discharge or aural fullness.

E	Carotid artery aneurysm

Nasopharyngeal carcinomas are notorious for involving multiple cranial nerves (usually II–VI or IX–XII). Most commonly, CN V and VI are affected, causing facial numbness, pain and diplopia. There is frequently evidence of lymph node enlargement indicating metastatic spread, and non-specific symptoms of nasal obstruction, discharge or aural fullness.

E	Carotid artery aneurysm

Extracranial carotid artery aneurysms are uncommon and may present as cervical or parapharyngeal masses, which may or may not be pulsatile. Compressive symptoms can rarely occur affecting CN IX (dysphagia, auricular pain), CN XII (tongue deviation), CN X (hoarseness) and occasionally Horner syndrome secondary to sympathetic chain involvement.

7585

Rate this question:

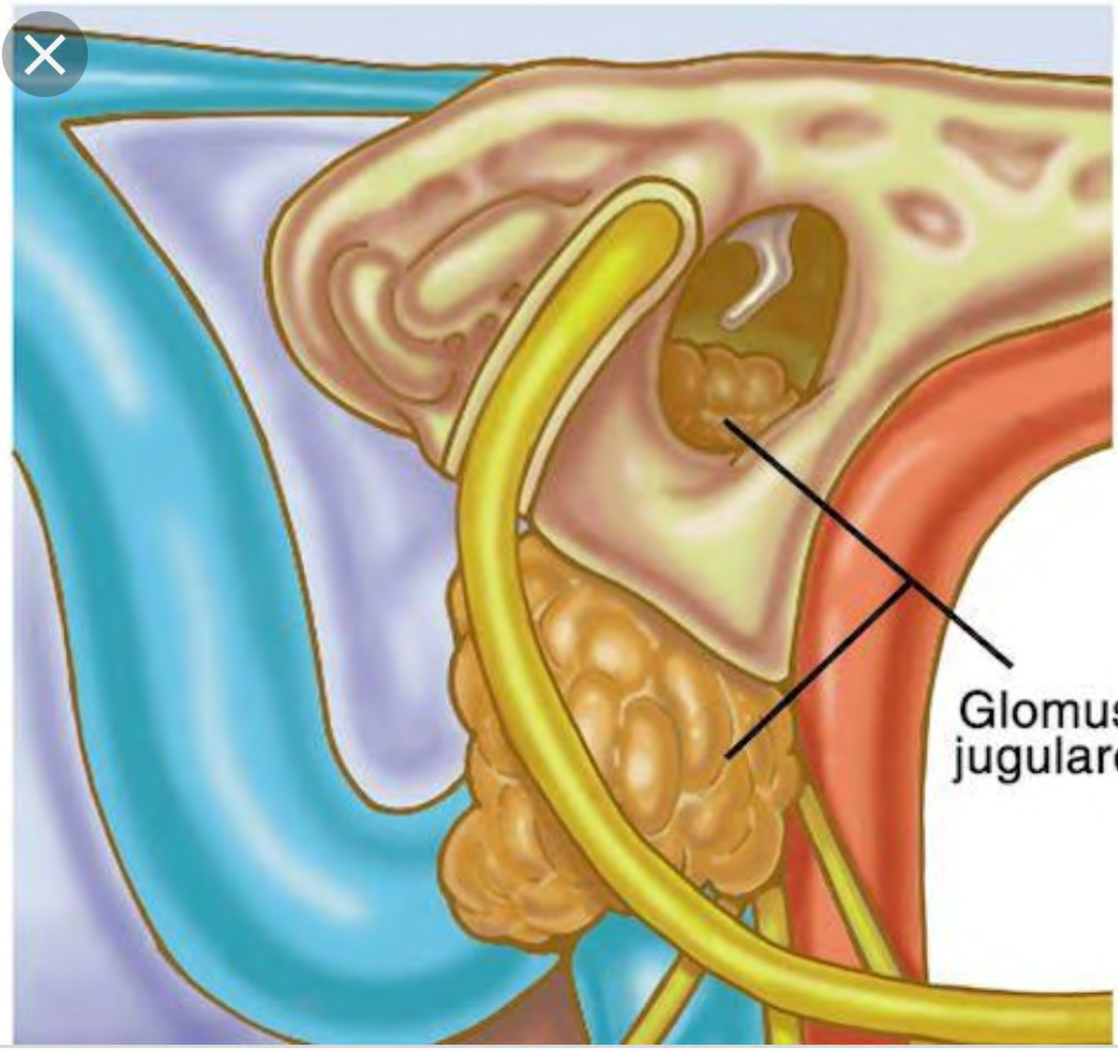

Darius Kohan, MD

Glomus Jugulare Tumor Surgery - Otologist NYC

Glomus Jugulare Tumor Surgery

Images may be subject to copyright. Learn More

RELATED IMAGES

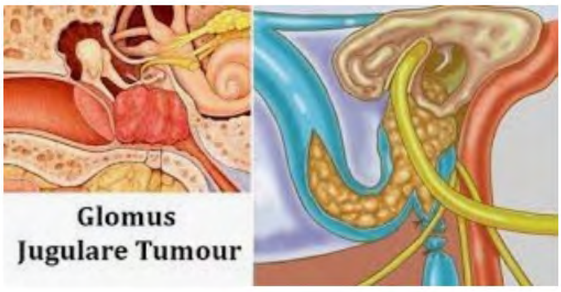

Natural Treatment of Glomus ...
scoop.it

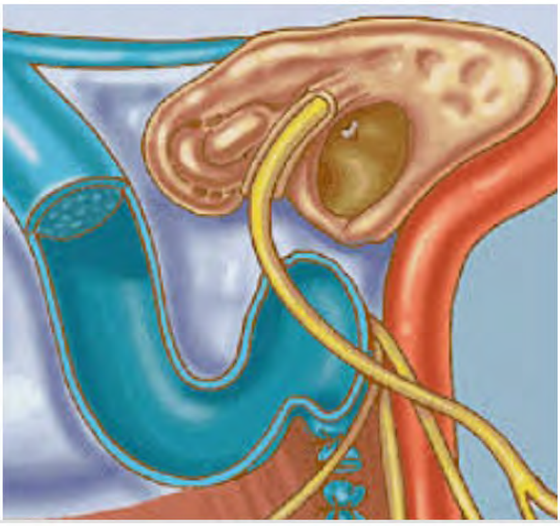

7:44
https://www.google.com/sea
15

padmaviewpoint

padmaviewpoint: Glomus Jugulare

Glomus Jugulare

Images may be subject to copyright. Learn More

RELATED IMAGES

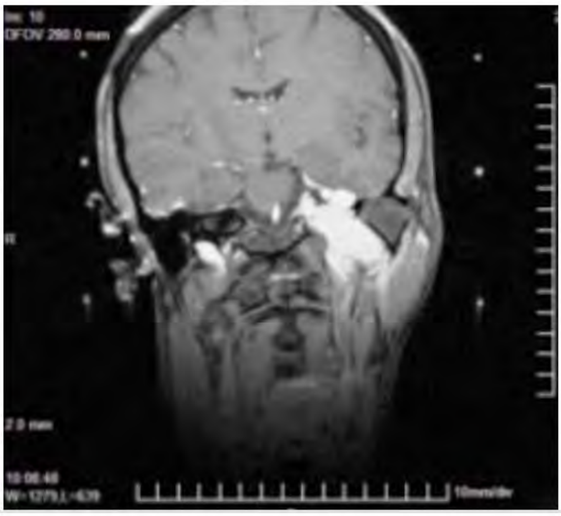

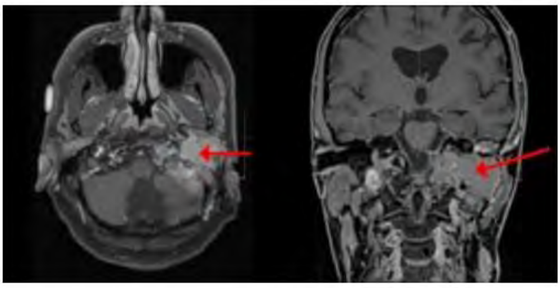

Paraganglioma Management:...
consultqd.clevelandclinic.org

Open-i

Glomus jugulare tumour. Coronal (A), sagittal (B) and a | Open-i

Glomus jugulare tumour. Coronal (A), sagittal (B) and axial (

Images may be subject to copyright. Learn More

RELATED IMAGES

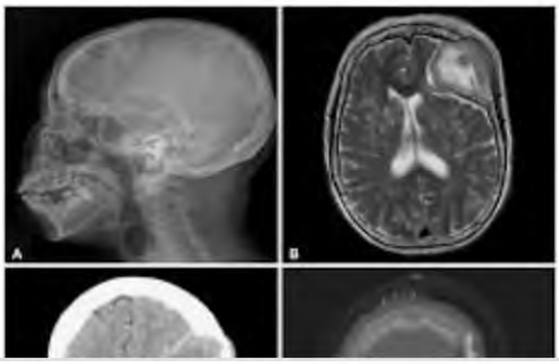

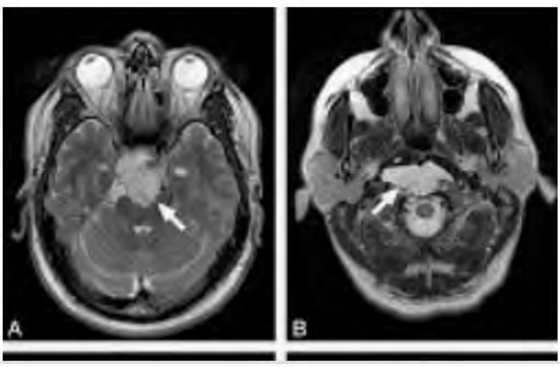

A 70-year-old man was admitted to the Emergency Department, brought in by his son. He had been well only 2 days previously at a family Christmas dinner. His son had him brought in as he was not answering the telephone. Two previous casualty admissions with pneumonia over the past 9 months are noted. According to the family he has been increasingly tired and is barely able to mobilise around the house.

On admission, he was conscious, alert and 'disorientated but not confused'. Blood pressure was on the low side, with pulse 40 beats/min. Oral temperature was 35.6 °C. Chest X-ray shows right lower lobe changes. An electrocardiogram (ECG) taken on the ward later revealed slow atrial fibrillation, 54 beats/min. Muscle fasciculation and some muscle wasting was noted by the admitting senior house officer.

What is the most likely diagnosis here?

A Acute stroke

electrocardiogram (ECG) taken on the ward later revealed slow atrial fibrillation, 54 beats/min. Muscle fasciculation and some muscle wasting was noted by the admitting senior house officer.

What is the most likely diagnosis here?

A	Acute stroke
B	Motor neurone disease
C	Guillain-Barré syndrome
D	Metastatic bronchocarcinoma
E	Multi-infarct dementia

32754

Submit

the Emergency Department, brought in by his son. He had been well only 2 days previously at a family Christmas dinner. His son had him brought in as he was not answering the telephone. Two previous casualty admissions with pneumonia over the past 9 months are noted. According to the family he has been increasingly tired and is barely able to mobilise around the house.

On admission, he was conscious, alert and 'disorientated but not confused'. Blood pressure was on the low side, with pulse 40 beats/min. Oral temperature was 35.6 °C. Chest X-ray shows right lower lobe changes. An electrocardiogram (ECG) taken on the ward later revealed slow atrial fibrillation, 54 beats/min. Muscle fasciculation and some muscle wasting was noted by the admitting senior house officer.

What is the most likely diagnosis here?

Your answer was correct

B Motor neurone disease

The lower motor neurone signs seen here are suggestive of MND. This condition generally progresses slowly but more rarely can present subacutely; in any case the initial symptoms and signs may have gone unnoticed by the family. It is likely that the acute onset confusion is as a result of lower respiratory tract infection, possibly due to aspiration pneumonia. He is likely to have a bulbar palsy related to his MND causing an inability to swallow safely and reliably. He should of course be kept nil by mouth pending a swallow assessment; over the longer term he may require thickened fluids or even PEG feeding to avoid further episodes of pneumonia.

A Acute stroke

In acute stroke, elevated blood pressure with focal neurology consistent with the distribution of

A 26-year-old right-handed woman is referred to the Urgent Neurology Clinic. She describes an orbito-temporal left-sided headache that is 'throbbing' in character. The headache lasts around 10 min, but can occur up to 25 times a day, with no pattern. The headache is associated with eye watering and nasal stuffiness. She denies past medical or family history. Neurological examination is normal. At the end of the consultation she experiences a headache, during which you note left ptosis, conjunctival injection, lacrimation and unilateral sweating.

A computerised tomography (CT) of the brain is performed that day, which is normal.

What is the most effective therapy for her headache?

A	Indomethacin
B	Sumatriptan

Neurological examination is normal. At the end of the consultation she experiences a headache, during which you note left ptosis, conjunctival injection, lacrimation and unilateral sweating.

A computerised tomography (CT) of the brain is performed that day, which is normal.

What is the most effective therapy for her headache?

A	Indomethacin
B	Sumatriptan
C	Carbamazepine
D	Topical beta-blocker to the eye
E	Prednisolone

A 26-year-old right-handed woman is referred to the Urgent Neurology Clinic. She describes an orbito-temporal left-sided headache that is 'throbbing' in character. The headache lasts around 10 min, but can occur up to 25 times a day, with no pattern. The headache is associated with eye watering and nasal stuffiness. She denies past medical or family history. Neurological examination is normal. At the end of the consultation she experiences a headache, during which you note left ptosis, conjunctival injection, lacrimation and unilateral sweating.

A computerised tomography (CT) of the brain is performed that day, which is normal.

What is the most effective therapy for her headache?

Your answer was correct

A Indomethacin

A Indomethacin

The history and examination are classical of paroxysmal hemicrania. Although rare, physicians should be aware of this headache syndrome as it is increasing in frequency, is potentially disabling and is very responsive to treatment. The treatment of choice is indomethacin. It shares some clinical features with cluster headache, i.e. unilateral excruciating headache with ipsilateral autonomic activation. It differs from cluster headache in having a female preponderance, increased frequency of daily attacks (up to 50 versus 1–4), shorter duration of attacks (2–25 min versus 10–60 min) and excellent response to indomethacin.

B Sumatriptan

Triptans are the intervention of choice in patients presenting with acute migraine. The short multiple, unilateral attacks, versus a more prolonged headache, preceded by an aura, favour

headache, preceded by an aura, favour paroxysmal hemicrania over migraine.

C	Carbamazepine

Cluster headache may respond to carbamazepine therapy, but the multiple daily attacks point more towards paroxysmal hemicrania where indomethacin is the preferred choice.

D	Topical beta-blocker to the eye

Intra-ocular beta blockade is an intervention for acute glaucoma. The multiple, short headaches rather than continuous pain count against glaucoma as the underlying diagnosis.

E	Prednisolone

Prednisolone given as a short course over 2–5 days is a potential option for initial treatment of cluster headache, in conjunction with verapamil.

A 28-year-old man is seen in Casualty in the early hours of the morning. He has presented with a 1-week history of progressive weakness of his arms and legs preceded by pins and needles in his feet and hands. He describes the weakness as 'creeping up me'.

In the last day, he has also developed weakness in his face and describes difficulty making expressions. He also complains of breathlessness, slurring of his speech and difficulty swallowing food. He has recently returned from a 6-month trip to India and the Far East. He suffered several bouts of diarrhoea, the last of which was around 4 weeks ago. At this point, he had noticed blood in his stool. He has no significant previous medical history and is on no regular medications.

On examination, he has bilateral lower motor neuron VII nerve weakness. He has dysarthria. There are no other significant cranial nerve signs, but his neck is weak. He has reduced power, more marked distally than proximally, with reduced ankle jerks and knee jerks

Sensory examination reveals reduced soft touch and pinprick sensation in the hands and feet.

What would be the most appropriate initial management step?

A Admission to hospital awaiting further investigations, preferably to a neurology ward bed if one is available

B Admission to hospital following IV immunoglobulin administration

C Admission to an acute medical bed with 2 h spirometry awaiting further investigations

D Admission to a bed with cardiac monitoring, and 2 h spirometry awaiting further investigations

initial management step?

A Admission to hospital awaiting further investigations, preferably to a neurology ward bed if one is available

B Admission to hospital following IV immunoglobulin administration

C Admission to an acute medical bed with 2 h spirometry awaiting further investigations

D Admission to a bed with cardiac monitoring, and 2 h spirometry awaiting further investigations

E Discharge from hospital with urgent outpatient neurology referral

8:13
Copy Share Select all Web search

D	Admission to a bed with cardiac monitoring, and 2 h spirometry awaiting further investigations

This man has classical symptoms and signs for Guillain–Barré syndrome (GBS). This is an acute inflammatory polyradiculoneuropathy, which may occur after an episode of infection. It usually presents with progressive flaccid paralysis of varying severity. Treatment is with IV immunoglobulin and supportive therapy. Patients with deteriorating respiratory function should be managed on an intensive therapy unit. The mortality associated with GBS is not insignificant (even up to 10% in some series) and is related to respiratory and cardiovascular complications. Frequent spirometry and cardiac monitoring is important to reduce the chance of missing the development of potentially life-threatening respiratory compromise or dysautonomias. Arrhythmias may include symptomatic bradycardia requiring temporary pacemaker

8:13
Copy Share Select all Web search

requiring temporary pacemaker insertion, or supraventricular tachycardia.

B	Admission to hospital following IV immunoglobulin administration

This patient should be admitted to a higher care setting for further assessment and to ensure he is stable (from a respiratory and cardiovascular point of view). Prior to treatment with IVIG he would undergo investigations, especially lumbar puncture to look for the typical picture of raised protein and normal cells.

A	Admission to hospital awaiting further investigations, preferably to a neurology ward bed if one is available

Due to the symptoms of breathlessness, dysphagia and the signs of neck weakness, this patient should initially be admitted to a higher

breathlessness, dysphagia and the signs of neck weakness, this patient should initially be admitted to a higher care setting to ensure he is stable.

C	Admission to an acute medical bed with 2 h spirometry awaiting further investigations

Due to the symptoms of breathlessness, dysphagia and the signs of neck weakness, this patient should initially be admitted to a higher care setting to ensure he is stable.

E	Discharge from hospital with urgent outpatient neurology referral

This patient has an acute neurological emergency and must be admitted to hospital.

7003

Rate this question:

A 53-year-old woman presented with a 5-month history of deteriorating mobility and several falls. She also complained of pain in her feet. She had been previously well apart from taking levothyroxine for hypothyroidism.

On examination, the cranial nerves and upper limbs were normal. Lower limb examination revealed normal tone bilaterally with mild hip flexion weakness bilaterally. Knee reflexes were brisk, but ankle jerks were absent and the plantars were extensor. Coordination was normal. There was decreased proprioception and vibration sense to the ankles.

Given the suspected diagnosis based on these clinical findings, which blood test would you expect to be abnormal in this patient?

A	Cortisol
B	Folate
C	Haemoglobin A1c (HbA1c)

upper limbs were normal. Lower limb examination revealed normal tone bilaterally with mild hip flexion weakness bilaterally. Knee reflexes were brisk, but ankle jerks were absent and the plantars were extensor. Coordination was normal. There was decreased proprioception and vibration sense to the ankles.

Given the suspected diagnosis based on these clinical findings, which blood test would you expect to be abnormal in this patient?

A	Cortisol
B	Folate
C	Haemoglobin A1c (HbA1c)
D	Syphilis serology
E	Vitamin B_{12}

8:17
tps://mypastest.pastest.com 14

A 53-year-old woman presented with a 5-month history of deteriorating mobility and several falls. She also complained of pain in her feet. She had been previously well apart from taking levothyroxine for hypothyroidism.

On examination, the cranial nerves and upper limbs were normal. Lower limb examination revealed normal tone bilaterally with mild hip flexion weakness bilaterally. Knee reflexes were brisk, but ankle jerks were absent and the plantars were extensor. Coordination was normal. There was decreased proprioception and vibration sense to the ankles.

Given the suspected diagnosis based on these clinical findings, which blood test would you expect to be abnormal in this patient?

Your answer was correct

E Vitamin B_{12}

The most likely diagnosis is vitamin B_{12} deficiency, which causes subacute combined degeneration of the cord and a peripheral neuropathy. It can also cause optic atrophy and cognitive impairment. Abnormal blood tests would be a low serum vitamin B_{12} and a megaloblastic anaemia on full blood count/blood film. Causes include pernicious anaemia, Crohn's disease, post-gastrectomy, atrophic gastritis, vegan diet and blind loop syndrome among others. Treatment is with hydroxocobalamin injections.

A Cortisol

Cortisol levels would be important in diagnosing Cushing syndrome or Addison's disease, but would not cause the neurological symptoms described.

B Folate

Addison's disease, but would not cause the neurological symptoms described.

B Folate

Isolated folate deficiency does not cause the described neurological symptoms.

C Haemoglobin A1c (HbA1c)

Diabetes mellitus can cause peripheral neuropathy, but not the spinal cord signs seen here.

D Syphilis serology

Neurosyphilis may produce a similar clinical picture to that seen here (tabes dorsalis), but is now extremely rare.

71064

Rate this question:

Next Question

A 52-year-old woman attended her GP and reported that she had noticed difficulty holding her head up for the last few months. She had been previously well and her only existing medical condition was hypothyroidism, for which she took 50 micrograms of levothyroxine.

On examination, she had weakness of neck flexion and extension and a mild fatiguable bilateral ptosis. There was also mild weakness of shoulder abduction, but the remainder of the neurological examination was normal.

Which one of the following is the most useful investigation in making a diagnosis?

A	MRI cervical spine
B	Nerve conduction studies and electromyography
C	Nerve biopsy
D	Lumbar puncture

previously well and her only existing medical condition was hypothyroidism, for which she took 50 micrograms of levothyroxine.

On examination, she had weakness of neck flexion and extension and a mild fatiguable bilateral ptosis. There was also mild weakness of shoulder abduction, but the remainder of the neurological examination was normal.

Which one of the following is the most useful investigation in making a diagnosis?

A	MRI cervical spine
B	Nerve conduction studies and electromyography
C	Nerve biopsy
D	Lumbar puncture
E	Serum creatine kinase

8:20
tps://mypastest.pastest.com 14

A 52-year-old woman attended her GP and reported that she had noticed difficulty holding her head up for the last few months. She had been previously well and her only existing medical condition was hypothyroidism, for which she took 50 micrograms of levothyroxine.

On examination, she had weakness of neck flexion and extension and a mild fatiguable bilateral ptosis. There was also mild weakness of shoulder abduction, but the remainder of the neurological examination was normal.

Which one of the following is the most useful investigation in making a diagnosis?

Your answer was correct

A MRI cervical spine

B Nerve conduction studies and electromyography

The most likely diagnosis in this case is myasthenia gravis, as evidenced by fatiguable ptosis and neck and limb weakness. This is an autoimmune condition and patients may be positive for acetylcholine receptor antibodies or antibodies to muscle-specific kinase (MuSK). These antibodies are positive in at least 85% of cases. The diagnosis can be confirmed by completing nerve conduction studies, which show a decrement with repetitive nerve stimulation testing. A Tensilon test where Tensilon, an acetylcholinesterase inhibitor, is administered intravenously, has been used in the diagnosis of the condition but this is less common now as it can result in life-threatening cardiac arrhythmias. Patients diagnosed with myasthenia gravis should have imaging of their mediastinum as there is an association between the condition and thymoma. Treatment is with an acetylcholinesterase inhibitor and

acetylcholinesterase inhibitor and immunosuppression. In severe presentations or acute deteriorations, intravenous immunoglobulins or plasma exchange may be considered.

A	MRI cervical spine

This investigation would not help in the diagnosis of myasthenia gravis. It would be useful in the diagnosis of cervical spinal pathology such as degenerative disease, bony lesion, nerve root compression or spinal cord compression. The history and examination findings in this case are not suggestive of any of these conditions, with fatiguable weakness and no sensory symptoms.

C	Nerve biopsy

This investigation would not help in the diagnosis of myasthenia gravis. This investigation can be useful in the diagnosis of peripheral neuropathy. The examination finding of fatiguable weakness in this case is not suggestive

D Lumbar puncture

This investigation would not help in the diagnosis of myasthenia gravis. It may be useful in the diagnosis of a range of conditions including multiple sclerosis, where oligoclonal bands may be seen, and Guillain–Barré syndrome, where the CSF protein can be raised. The history in this case is not suggestive of either of these conditions.

E Serum creatine kinase

This investigation would not help in the diagnosis of myasthenia gravis. Creatinine kinase is raised in inflammatory myopathies, including polymyositis and dermatomyositis. The history in this case is not suggestive of either of these conditions, which would present with proximal weakness and muscle pain. A heliotrope rash may also be seen in dermatomyositis.

32701

Rate this question:

A 42-year-old man presents with weakness in his hands and legs. In particular, he reports difficulties playing football with his sons.

On examination, bilateral ptosis with a smooth forehead is noted. Fundoscopy proves difficult because of bilateral cataracts. Facial expression is reduced, with wasting of the temporalis muscles, masseters and sternomastoids. Slow release of hand grip is present bilaterally, with distal weakness and wasting in the upper limb muscles. There is bilateral foot drop. Deep tendon jerks are depressed.

Which one of the following best explains the underlying aetiology of this condition?

A	Inherited phosphofructokinase deficiency
B	Trinucleotide repeat disorder affecting the DMPK gene

weakness and wasting in the upper limb muscles. There is bilateral foot drop. Deep tendon jerks are depressed.

Which one of the following best explains the underlying aetiology of this condition?

A	Inherited phosphofructokinase deficiency
B	Trinucleotide repeat disorder affecting the DMPK gene
C	Underlying mitochondrial DNA mutation
D	Antibodies directed against the nicotinic acetylcholine receptor
E	Disorder due to mutation in gene-encoding dystrophin

A 42-year-old man presents with weakness in his hands and legs. In particular, he reports difficulties playing football with his sons.

On examination, bilateral ptosis with a smooth forehead is noted. Fundoscopy proves difficult because of bilateral cataracts. Facial expression is reduced, with wasting of the temporalis muscles, masseters and sternomastoids. Slow release of hand grip is present bilaterally, with distal weakness and wasting in the upper limb muscles. There is bilateral foot drop. Deep tendon jerks are depressed.

Which one of the following best explains the underlying aetiology of this condition?

Your answer was correct

A	Inherited phosphofructokinase deficiency

B Trinucleotide repeat disorder affecting the DMPK gene

This man has features consistent with myotonic dystrophy type 1, which is caused by excessive repeats of the nucleotides C-T-G in an untranslated region of the dystrophia myotonica protein kinase (DMPK) gene, inherited in an autosomal dominant fashion. The other clinical features of myotonic dystrophy are frontal balding, a lean face due to wasted temporalis and masseter muscles; cardiac dysrhythmias such as heart block (look for a pacemaker); smooth muscle abnormalities resulting in abdominal pain; dysphagia and pseudo-obstruction; respiratory muscle weakness; insulin resistance or diabetes; hypogonadism; and susceptibility to cancer.

As a trinucleotide repeat disorder (like Huntington's disease), myotonic dystrophy type 1 becomes symptomatic progressively earlier in each successive generation due to expansion of the trinucleotide repeat -

each successive generation due to expansion of the trinucleotide repeat - a phenomenon called anticipation. This can lead to neonates presenting with hypotonia and respiratory muscle weakness – congenital myotonic dystrophy.

EMG changes are found in almost any muscle (waxing and waning of potentials, termed the 'dive bomber effect').

A	Inherited phosphofructokinase deficiency

While phosphofructokinase deficiency (PFKD) can present in adulthood with progressive weakness, it usually presents in childhood with muscle cramps and fatigue. Patients do not usually have cataracts

C	Underlying mitochondrial DNA mutation

Whilst ptosis can be a feature of

C	Underlying mitochondrial DNA mutation

Whilst ptosis can be a feature of mitochondrial disease, it is usually accompanied by diplopia, ophthalmoplegia and proximal muscle weakness. This man's weakness is more distal. He has evidence of wasted facial musculature, and myotonia, which are not usually seen in mitochondrial disease.

D	Antibodies directed against the nicotinic acetylcholine receptor

This option alludes to myasthenia gravis (MG), which can present with fatiguable ptosis. We are not told that his ptosis is fatiguable. His muscle weakness is distal, whereas MG features fatiguable proximal weakness (shoulders and hips). Muscle wasting, myotonia and cataracts are not usually seen in MG.

E	Disorder due to mutation in

features fatiguable proximal weakness (shoulders and hips). Muscle wasting, myotonia and cataracts are not usually seen in MG.

E	Disorder due to mutation in gene-encoding dystrophin

Duchenne and Becker muscular dystrophies are caused by mutations in the dystrophin gene. They start in childhood or adolescence, affect mostly males (they are inherited in an X-linked fashion) and cause muscle pseudo-hypertrophy (especially in the calves) rather than wasting. Cataracts and myotonia are not features of these muscular dystrophies.

Some female carriers may have clinically detectable weakness and high serum creatine kinase concentrations, but are only fully affected clinically if a copy of the X-chromosome is deleted (i.e. if they also have Turner syndrome), or inactivated.

8497

Rate this question:

a 12-month history of worsening memory problems and confusion. His wife had noted that his sleep was becoming more disturbed, as he complains of vivid nightmares and visual hallucinations.

Over the past few months, he had found it increasingly difficult to dress and undress himself, and his mobility has deteriorated.

On examination, he is bradykinesic with rigidity affecting his arms and legs. His mini-mental state examination (MMSE) is 18/30.

What is the most likely diagnosis?

A	Parkinson's disease
B	Frontotemporal dementia
C	Vascular dementia
D	Lewy body disease
E	Alzheimer's disease

A 74-year-old man is seen in clinic with a 12-month history of worsening memory problems and confusion. His wife had noted that his sleep was becoming more disturbed, as he complains of vivid nightmares and visual hallucinations.

Over the past few months, he had found it increasingly difficult to dress and undress himself, and his mobility has deteriorated.

On examination, he is bradykinesic with rigidity affecting his arms and legs. His mini-mental state examination (MMSE) is 18/30.

What is the most likely diagnosis?

Your answer was correct

A	Parkinson's disease
B	Frontotemporal dementia
C	Vascular dementia

D Lewy body disease

Lewy body dementia is the second most common cause of dementia in the elderly after Alzheimer's disease. The core feature is a progressive dementia, but other characteristic features include parkinsonism, visual hallucinations, fluctuating cognitive abilities, an increased risk of falls and autonomic failure. Tremor may be reduced or absent compared with idiopathic Parkinson's disease. REM sleep behaviour disorder (as seen here) is very common. Hallucinations can be a very troublesome problem in patients with Lewy body dementia, and most patients are intolerant of the usual neuroleptic medication. Indeed, such drugs should be avoided because of extreme sensitivity to their extrapyramidal side effects. The mainstay of treatment is ensuring a safe, non-threatening environment and supporting the carer. Cholinesterase inhibitors are often beneficial in Lewy body dementia. Clonazepam helps the symptoms of REM sleep behaviour

symptoms of REM sleep behaviour disorder.

A Parkinson's disease

Idiopathic Parkinson's is more likely to be associated with an asymmetric upper limb onset of tremor, rigidity and bradykinesia. Features of dementia are a late rather than an early presenting feature.

B Frontotemporal dementia

Frontotemporal dementia, predominantly an early-onset dementia, is a disorder characterised by progressive behavioural change (apathy, disinhibition, stereotyped actions) and executive dysfunction.

C Vascular dementia

Vascular dementia is seen in patients with pre-existing atherosclerosis or risk factors such as diabetes mellitus and hypertension. It is classically

A 26-year-old man is referred by his GP for neurological evaluation of muscle weakness and stiffness. His father also had similar problems and had died due to respiratory failure. He also gives a history of progressive visual impairment of a couple of years' duration. The other problem is recurrent dislocation of his jaw. He is a known diabetic on insulin and has recently attended the endocrinologist for evaluation of impotence.

On examination, he has bilateral cataracts, bilateral mild ptosis is evident and there is frontal balding. Ocular movements are normal but there is wasting of the temporalis, masseter and sternocleidomastoid muscles on both sides. Muscles of both hands are wasted and both wrists are weak. When you shake his hand he can only slowly relax his grip. There is bilateral foot drop and tendon reflexes are reduced.

Which of the following is the most likely diagnosis?

evident and there is frontal balding. Ocular movements are normal but there is wasting of the temporalis, masseter and sternocleidomastoid muscles on both sides. Muscles of both hands are wasted and both wrists are weak. When you shake his hand he can only slowly relax his grip. There is bilateral foot drop and tendon reflexes are reduced.

Which of the following is the most likely diagnosis?

A	Facioscapulohumeral muscular dystrophy
B	Polymyositis
C	Hashimoto's disease
D	Myotonic dystrophy
E	Becker's muscular dystrophy

A 26-year-old man is referred by his GP for neurological evaluation of muscle weakness and stiffness. His father also had similar problems and had died due to respiratory failure. He also gives a history of progressive visual impairment of a couple of years' duration. The other problem is recurrent dislocation of his jaw. He is a known diabetic on insulin and has recently attended the endocrinologist for evaluation of impotence.

On examination, he has bilateral cataracts, bilateral mild ptosis is evident and there is frontal balding. Ocular movements are normal but there is wasting of the temporalis, masseter and sternocleidomastoid muscles on both sides. Muscles of both hands are wasted and both wrists are weak. When you shake his hand he can only slowly relax his grip. There is bilateral foot drop and tendon reflexes are reduced.

Which of the following is the most likely diagnosis?

D Myotonic dystrophy

This is an autosomal dominant disorder caused by increased trinucleotide repeats (CTG) on chromosome 19q. The muscles of the face (a typical 'hatchet face' due to wasting of temporalis, masseters and sternocleidomastoids), neck and distal extremities are typically involved. Patients are prone to recurrent jaw dislocation. With progressive disease the proximal muscles, bulbar muscles and even the diaphragm are involved. Myotonia is the hallmark and is characterised by inability to quickly relax a contracted muscle.

The usual age of presentation is between 10 and 30 years. Frontal baldness, progressive dementia, and abnormal immunoglobulins, with the risk of increased infection, are other features of this disease.

A Facioscapulohumeral muscular dystrophy

Weakness associated with fascioscapularhumeral muscular dystrophy most commonly affects muscles of the face, shoulder blades and upper arms, rather than the picture seen here.

B Polymyositis

This is associated with features of muscle pain and proximal weakness, with signs and symptoms consistent with connective tissue disease, rather than the picture seen here.

C Hashimoto's disease

Although hypothyroidism is associated with proximal muscle weakness and reduced tendon reflexes, other obvious features including weight gain are not seen here.

E Becker's muscular dystrophy

The onset of Becker's muscular dystrophy is usually earlier than age

B	Polymyositis

This is associated with features of muscle pain and proximal weakness, with signs and symptoms consistent with connective tissue disease, rather than the picture seen here.

C	Hashimoto's disease

Although hypothyroidism is associated with proximal muscle weakness and reduced tendon reflexes, other obvious features including weight gain are not seen here.

E	Becker's muscular dystrophy

The onset of Becker's muscular dystrophy is usually earlier than age 26, and the most prominent muscle groups affected are those of the legs and pelvis rather than the pattern seen here.

32774

Rate this question:

A 42-year-old woman with a long history of poorly controlled type 1 diabetes mellitus presents as an emergency appointment to the clinic with severe burning pain affecting her right thigh and proximal limb weakness. She has some peripheral sensory loss and has had previous laser therapy in both eyes.

On examination, her blood pressure (BP) is 132/72 mmHg, and pulse is 75 bpm and regular. Her body mass index (BMI) is 22. Her right thigh is painful on light touch, and there is evidence of proximal muscle weakness.

Which of the following is the most likely diagnosis?

A	Amyotrophic lateral sclerosis
B	Diabetic amyotrophy
C	Lumbar spondylosis
D	Lumbar spine disc prolapse

emergency appointment to the clinic with severe burning pain affecting her right thigh and proximal limb weakness. She has some peripheral sensory loss and has had previous laser therapy in both eyes.

On examination, her blood pressure (BP) is 132/72 mmHg, and pulse is 75 bpm and regular. Her body mass index (BMI) is 22. Her right thigh is painful on light touch, and there is evidence of proximal muscle weakness.

Which of the following is the most likely diagnosis?

A	Amyotrophic lateral sclerosis
B	Diabetic amyotrophy
C	Lumbar spondylosis
D	Lumbar spine disc prolapse
E	Spinal stenosis

B Diabetic amyotrophy

The correct answer is Diabetic amyotrophy (Option B).

This scenario is typical of diabetic amyotrophy (although the condition is rarer in type 1 vs type 2 diabetes). Weakness and wasting are limited to proximal muscle groups, and sensory loss is minimal. The condition is thought to be at least partially immune-driven, although it is also associated with periods of inadequate glucose control and may be precipitated by a period of rapid improvement in glucose levels.

A Amyotrophic lateral sclerosis

Amyotrophic lateral sclerosis (Option A) is incorrect.

Amyotrophic lateral sclerosis is a type of motor neurone disease. It is characterized by worsening weakness and progressive difficulty in speaking, swallowing and eventually breathing.

and progressive difficulty in speaking, swallowing and eventually breathing. The cause is genetic in 5–10% of cases, and unknown in the remaining 90–95%. Sensory nerves and the autonomic nervous system are generally unaffected.

C	Lumbar spondylosis

Lumbar spondylosis (Option C) is incorrect.

Lumbar spondylosis is associated with back pain and usually with bilateral lower limb symptoms.

D	Lumbar spine disc prolapse

Lumbar spine disc prolapse (Option D) is incorrect.

In lumbar disc prolapse, motor and sensory loss can be related to impingement of a particular nerve root, which is not the case here.

E	Spinal stenosis

A 78-year-old woman with no past medical history is admitted as an emergency. Initial presentation was with headache, fever and meningism. Her husband also described her as becoming increasingly drowsy for around 48 h prior to admission,

They have recently returned from a weekend away in France. Her temperature on admission was noted to be 38.2 °C, with a BP of 110/70 mmHg and a pulse of 90 bpm. She was given intravenous (IV) benzylpenicillin, and cerebrospinal fluid was obtained by the emergency team. The on-call microbiologist calls to report Gram-positive rods on the initial Gram stain.

What would be the most appropriate medication for this patient?

A	IV cefotaxime and dexamethasone
B	IV cefotaxime and rifampicin
C	IV ampicillin and gentamicin

They have recently returned from a weekend away in France. Her temperature on admission was noted to be 38.2 °C, with a BP of 110/70 mmHg and a pulse of 90 bpm. She was given intravenous (IV) benzylpenicillin, and cerebrospinal fluid was obtained by the emergency team. The on-call microbiologist calls to report Gram-positive rods on the initial Gram stain.

What would be the most appropriate medication for this patient?

A	IV cefotaxime and dexamethasone
B	IV cefotaxime and rifampicin
C	IV ampicillin and gentamicin
D	IV cefotaxime and aciclovir
E	IV chloramphenicol

A 78-year-old woman with no past medical history is admitted as an emergency. Initial presentation was with headache, fever and meningism. Her husband also described her as becoming increasingly drowsy for around 48 h prior to admission,

They have recently returned from a weekend away in France. Her temperature on admission was noted to be 38.2 °C, with a BP of 110/70 mmHg and a pulse of 90 bpm. She was given intravenous (IV) benzylpenicillin, and cerebrospinal fluid was obtained by the emergency team. The on-call microbiologist calls to report Gram-positive rods on the initial Gram stain.

What would be the most appropriate medication for this patient?

Your answer was incorrect

A IV cefotaxime and dexamethasone

C IV ampicillin and gentamicin

The Gram-positive rods reported on the Gram stain probably represent *Listeria monocytogenes*. Listeria is the second most common form of meningitis in the elderly and immunosuppressed (including the mild relative immunosuppression occurring in pregnant women). Clinical infection often spreads to involve brain parenchyma, in particular the brainstem. Thus a meningo-encephalitic picture with headache, meningism and cranial nerve palsies is common. Cerebrospinal fluid Gram stain yields an organism in less than 50% of cases of *Listeria* meningitis. The cerebrospinal fluid (CSF) examination further differs from the more common bacterial meningitis with a lower white cell count and protein. Some cases may resemble a viral CSF profile. Treatment consists of ampicillin and gentamicin; however, even with treatment mortality remains high (>60 % in some series).

In cases where initial clinical details and results fail to discriminate between a bacterial and viral cause, it is common practice to cover for both in this way, but here the Gram stain has confirmed a bacterial pathogen so aciclovir is not needed.

A	IV cefotaxime and dexamethasone

The role of steroids is proven in paediatric practice and there is some evidence for its use in adults with pneumococcal meningitis. At present steroids are not recommended for proven *Listeria* meningitis in adults.

B	IV cefotaxime and rifampicin

In cases where there is a relevant travel history or where drug-resistant *Pneumococcus* is suspected, rifampicin is added to cefotaxime. However, here the Gram stain result suggests that *Pneumococcus* is not the pathogen involved.

8:49
tps://mypastest.pastest.com 14

B	IV cefotaxime and rifampicin

In cases where there is a relevant travel history or where drug-resistant *Pneumococcus* is suspected, rifampicin is added to cefotaxime. However, here the Gram stain result suggests that *Pneumococcus* is not the pathogen involved.

E	IV chloramphenicol

This drug is used in cases of suspected meningitis when there is a history of true allergy to penicillin or cephalosporins.

32713

Rate this question:

A 63-year-old plumber was referred to Neurology Clinic for investigation of difficulty in walking. His wife reported that he has been more irritable over the past 6 months and had become increasingly forgetful, often missing appointments, losing personal items and having difficulties remembering the content of recent conversations. More recently, he has accused his neighbours of continuously watching his house and is now reluctant to go outdoors alone. His general practitioner recently prescribed quetiapine tablets to help him relax.

On examination, his blood pressure was 148/78 mmHg lying, 112/72 mmHg standing. Bedside cognitive tests demonstrated a Mini-Mental State Examination score of 18 out of 30, with deficits in orientation, concentration and recall. Facial expression was reduced. Examination of eye movements demonstrated mild limitation of up-gaze. Tone was increased in the limbs, with symmetrical reflexes and bilateral down-going plantars. There was

limitation of up-gaze. Tone was increased in the limbs, with symmetrical reflexes and bilateral down-going plantars. There was impairment of rapid alternating finger movements and evidence of micrographia. Gait demonstrated reduced stride length and arm-swing.

Which one of the following therapeutic strategies is most appropriate with respect to maintaining his mobility?

A	Oral levodopa challenge
B	Stop quetiapine
C	Trial of oral fludrocortisone
D	Trial of oral olanzapine
E	Trial of oral ropinirole

A 63-year-old plumber was referred to Neurology Clinic for investigation of difficulty in walking. His wife reported that he has been more irritable over the past 6 months and had become increasingly forgetful, often missing appointments, losing personal items and having difficulties remembering the content of recent conversations. More recently, he has accused his neighbours of continuously watching his house and is now reluctant to go outdoors alone. His general practitioner recently prescribed quetiapine tablets to help him relax.

On examination, his blood pressure was 148/78 mmHg lying, 112/72 mmHg standing. Bedside cognitive tests demonstrated a Mini-Mental State Examination score of 18 out of 30, with deficits in orientation, concentration and recall. Facial expression was reduced. Examination of eye movements demonstrated mild limitation of up-gaze. Tone was increased in the limbs, with symmetrical reflexes and bilateral down-going plantars. There was

B Stop quetiapine

The clinical scenario is suggestive of dementia with Lewy bodies (DLB). This condition is characterised by fluctuating cognitive impairment, extrapyramidal symptoms and visual hallucinations; paranoid ideation may also be present. Autonomic symptoms are commonly seen. Patients can be very sensitive to any dopamine-blocking or -depleting drugs (causing significant parkinsonism) and, as such, antipsychotics ought to be avoided. The hallucinations often respond to cholinesterase inhibitors such as rivastigmine.

A Oral levodopa challenge

The better option is to withdraw the offending drug (quetiapine) rather than add in another agent. In addition, dopaminergic drugs may worsen hallucinosis and confusion in DLB.

C Trial of oral fludrocortisone

C Trial of oral fludrocortisone

Fludrocortisone is used to treat adrenal insufficiency and postural hypotension. That is not the major issue here. so would not be useful.

D Trial of oral olanzapine

Olanzapine is an antipsychotic treatment used to treat schizophrenia and bipolar disorder. It is an atypical antipsychotic and is associated with a lower risk of causing movement disorders than typical anti-psychotics, but is still best avoided in DLB and Parkinson's disease.

E Trial of oral ropinirole

The better option is to withdraw the offending drug (quetiapine) rather than add in another agent. In addition, dopaminergic drugs may worsen hallucinosis and confusion in DLB.

8:58
tps://mypastest.pastest.com 14

A 36-year-old woman is referred to the Emergency Department by her GP for a bilateral 6th nerve palsy. She reports severe, dull headaches, worse in the mornings, over the past 3 months. There has also been a deterioration in her vision, with intermittent diplopia, particularly when she strains or bends forward. The only medication of note includes the combined oral contraceptive pill.

Examination reveals a BP of 155/90 mmHg, and pulse is 75 bpm and regular. Her BMI is 34. There is bilateral papilloedema and bilateral 6th nerve palsy. Routine blood testing is unremarkable. MRI scanning reveals flattening of the sclera and distension of the perioptic subarachnoid space. Magnetic resonance venography is unremarkable.

Which of the following is the most appropriate next intervention?

8:58
tps://mypastest.pastest.com 14

flattening of the sclera and distension of the perioptic subarachnoid space. Magnetic resonance venography is unremarkable.

Which of the following is the most appropriate next intervention?

A	Acetazolamide
B	Furosemide
C	Indomethacin
D	Lumbar puncture
E	Prednisolone

40243

Submit

A 36-year-old woman is referred to the Emergency Department by her GP for a bilateral 6th nerve palsy. She reports severe, dull headaches, worse in the mornings, over the past 3 months. There has also been a deterioration in her vision, with intermittent diplopia, particularly when she strains or bends forward. The only medication of note includes the combined oral contraceptive pill.

Examination reveals a BP of 155/90 mmHg, and pulse is 75 bpm and regular. Her BMI is 34. There is bilateral papilloedema and bilateral 6th nerve palsy. Routine blood testing is unremarkable. MRI scanning reveals flattening of the sclera and distension of the perioptic subarachnoid space. Magnetic resonance venography is unremarkable.

Which of the following is the most appropriate next intervention?

Your answer was incorrect

D Lumbar puncture

New-onset morning headaches should always be investigated with cerebral imaging to rule out a space-occupying lesion or cerebral venous sinus thrombosis. The history and demographic of this patient is consistent with idiopathic intracranial hypertension. Most patients present with postural headaches, transient visual obscurations and pulsatile tinnitus. Clinical examination will reveal papilloedema, potentially enlarged blind spot with impaired visual acuity and sometimes cranial nerve VI palsies. A diagnosis is made by demonstrating raised intracranial pressure on lumbar puncture (>25 cm CSF) – often the patient will have instantaneous relief of their symptoms. The major morbidity associated with IIH is visual loss (hence the change in name from benign intracranial hypertension), and therefore patients should have an ophthalmology review for regular retinal photography and visual field assessment. The most effective and enduring treatment is weight loss.

enduring treatment is weight loss. Pharmacological therapy aims to reduce CSF production, such as with acetazolamide or topiramate. For patients with progressive visual loss, surgical intervention can be considered – optic nerve sheath fenestration and/or CSF shunts.

E	Prednisolone

Corticosteroids have previously been used in the treatment of IIH. However, they are no longer recommended as they can cause weight gain which is disadvantageous, withdrawal can cause rebound IIH associated with marked visual loss and there are significant deleterious side effects from prolonged steroid use. In any case, the diagnosis should be confirmed with a lumbar puncture in the first instance.

A	Acetazolamide

Acetazolamide is a carbonic anhydrase inhibitor that reduces CSF production

A Acetazolamide

Acetazolamide is a carbonic anhydrase inhibitor that reduces CSF production. This is a recognised pharmacological treatment for IIH, but first the diagnosis needs to be confirmed with a lumbar puncture.

B Furosemide

Furosemide is a loop diuretic and is a recognised pharmacological treatment for IIH, but first the diagnosis needs to be confirmed with a lumbar puncture.

C Indomethacin

Indomethacin is a NSAID which is used in the treatment of indomethacin-responsive primary headache disorders, such as hemicrania continua and paroxysmal hemicrania. These are side-locked headaches often associated with unilateral autonomic symptoms.

A 72-year-old man is referred to the Emergency Department by his GP with a pneumonia. The family have reported that over the past few months he has been slurring his words and occasionally choking on his food. Occasionally, he has choked and subsequently vomited.

On examination, he is pyrexial at 37.9 °C, his BP is 110/72 mmHg and his pulse is 95/min and regular. Chest auscultation reveals right-sided crackles and reduced air entry. You also notice that he has tongue fasciculations and wasting, weakness and hyperreflexia on limb examination. Sensation and gait appear intact.

Investigations:

Hb	11.9 g/dl
WCC	15.2×10^9/l
PLT	190×10^9/l
Na^+	141 mmol/l
K^+	4.9 mmol/l
Creatinine	195 umol/l

WCC	15.2×10^9/l
PLT	190×10^9/l
Na^+	141 mmol/l
K^+	4.9 mmol/l
Creatinine	195 μmol/l
Creatinine kinase	50 U/l (< 195)

Which of the following is the most likely diagnosis?

A	Amyotrophic lateral sclerosis
B	Hereditary motor and sensory neuropathy
C	Parkinson's disease
D	Polymyositis
E	Acute stroke

that over the past few months he has been slurring his words and occasionally choking on his food. Occasionally, he has choked and subsequently vomited.

On examination, he is pyrexial at 37.9 °C, his BP is 110/72 mmHg and his pulse is 95/min and regular. Chest auscultation reveals right-sided crackles and reduced air entry. You also notice that he has tongue fasciculations and wasting, weakness and hyperreflexia on limb examination. Sensation and gait appear intact.

Investigations:

Hb	11.9 g/dl
WCC	15.2×10^9/l
PLT	190×10^9/l
Na^+	141 mmol/l
K^+	4.9 mmol/l
Creatinine	195 μmol/l
Creatinine kinase	50 U/l (< 195)

A Amyotrophic lateral sclerosis

ALS is a form of motor neurone disease. There are numerous pieces of evidence to support this diagnosis. The description of a bulbar palsy which appears to be progressive is strong evidence to support ALS. The mixed pattern of upper and lower motor neurone signs is typically seen in ALS. The pneumonia has subsequently developed and is likely to be aspiration pneumonia.

B Hereditary motor and sensory neuropathy

This is sometimes referred to as Charcot–Marie–Tooth disease. Whilst the progressive nature of this man's symptoms could support this answer, the lack of sensory symptoms, his normal gait and the hyper-reflexia make this answer unlikely.

C Parkinson's disease

In Parkinson's you would expect to see bradykinesia, rigidity and tremor. We do not see these symptoms here and therefore this is not correct.

D	Polymyositis

This inflammatory muscle condition can result in problems leading to dysphagia, as we have seen in this question. However, the normal creatinine kinase should make you reluctant to select this as the best answer because this marker is much higher in polymyositis. In addition, he has upper motor neurone signs, not seen in muscle disease.

E	Acute stroke

Whilst aspiration pneumonia may be seen in stroke patients, there is no clinical evidence to suggest that this man has had a stroke. His presentation is of gradual onset and he has mixed upper and lower motor neurone weakness, whereas stroke would

A 36-year-old self-employed designer presents to casualty with complaints of problems with his vision. These began suddenly while he was working late at night at home. He has a high-pressure and stressful job ('If I don't finish on time, I can't pay the mortgage') and as a result he tends to work long hours.

He reports reaching up for a file on an upper shelf when he felt dizzy and unwell. He sat down and noticed that he could not see the left side of his computer screen clearly. He denies headache or pain in his neck. He is a smoker and drinks around 35–40 units of alcohol per week. Past medical history includes sinusitis, for which he has bought a nasal steroid inhaler, he takes no other regular medications.

On examination, he appears well although he is anxious. His pulse is 90/min and regular with a blood pressure of 128/84 mmHg. Cranial nerve examination reveals a left homonymous hemianopia. There are no eye movement abnormalities and the remainder of the neurological examination is normal.

the remainder of the neurological examination is normal.

Hb	13.2 g/dl
WCC	6.7×10^9/l
PLT	354×10^9/l
Na^+	139 mmol/l
K^+	4.9 mmol/l
Urea	7.8 mmol/l
Creatinine	105 µmol/l

Which of the following is most likely to assist with the diagnosis?

A Fundoscopy

B Erythrocyte sedimentation rate (ESR)

C Urinary catecholamines analysis

D Fasting blood sugar analysis

PLT	354 x 10^9/l
Na^+	139 mmol/l
K^+	4.9 mmol/l
Urea	7.8 mmol/l
Creatinine	105 µmol/l

Which of the following is most likely to assist with the diagnosis?

A	Fundoscopy
B	Erythrocyte sedimentation rate (ESR)
C	Urinary catecholamines analysis
D	Fasting blood sugar analysis
E	Detailed enquiry about illicit drug use

E Detailed enquiry about illicit drug use

Stimulant drug use (especially cocaine) is prevalent among young professionals and is a not uncommon association with young-onset ischaemic events, both cerebral and coronary. Cocaine is thought to cause acute vasospasm and so may lead to vascular events taking place with no visible arterial wall abnormalities. A detailed drug history is very important, particularly in younger age-group patients presenting with ischaemic events. Most patients will not volunteer it unless asked and may not recognise its importance.

A Fundoscopy

The finding of homonymous hemianopia means the lesion is behind the optic chiasm, so fundoscopy is unlikely to reveal anything specific in this case (although all patients with neurological symptoms should have a thorough examination that includes

thorough examination that includes this).

B	Erythrocyte sedimentation rate (ESR)

Vasculitic conditions can cause young strokes but in someone without any significant systemic symptoms (rashes, hair loss, joint pains, fevers) the ESR is not likely to lead to a diagnosis. In older patients (>50 years) the possibility of giant cell arteritis would have to be borne in mind and ESR is a useful test.

C	Urinary catecholamines analysis

This test can be done to investigate phaeochromocytoma, which is a rare cause of secondary hypertension. This man's blood pressure seems normal so there is no indication for this test at the current time.

D	Fasting blood sugar analysis

have to be borne in mind and ESR is a useful test.

C	Urinary catecholamines analysis

This test can be done to investigate phaeochromocytoma, which is a rare cause of secondary hypertension. This man's blood pressure seems normal so there is no indication for this test at the current time.

D	Fasting blood sugar analysis

Whilst diabetes is a risk factor for young strokes, it would be an extremely unusual presenting feature (i.e. no known history of poorly controlled diabetes).

7001

Rate this question:

Next Question

A 31-year-old woman with a known diagnosis of HIV presented to the Emergency Department with a 2-week history of headache, multiple episodes of vomiting and feeling generally unwell. In the last few days she had become feverish and preferred to be in a dark room.

On examination, her BP was 110/72 mmHg, pulse 80 bpm and regular and her temperature was elevated at 37.9 °C. There was mild neck stiffness on clinical examination.

A lumbar puncture was performed and the cerebrospinal fluid (CSF) showed the following results:

Opening pressure	28cm H_2O
White cell count	220 per mm^3 (80% lymphocytes)
Red cell count	55 per mm^3
Protein	2.2 g/l
Glucose	2.1 (serum glucose 6.6)

count	lymphocytes)
Red cell count	55 per mm^3
Protein	2.2 g/l
Glucose	2.1 (serum glucose 6.6)

Which other test would most help decide on the underlying diagnosis?

A	Cytomegalovirus PCR
B	Epstein–Barr virus (EBV) polymerase chain reaction (PCR)
C	India ink stain
D	JC virus PCR
E	Syphilis serology

A 31-year-old woman with a known diagnosis of HIV presented to the Emergency Department with a 2-week history of headache, multiple episodes of vomiting and feeling generally unwell. In the last few days she had become feverish and preferred to be in a dark room.

On examination, her BP was 110/72 mmHg, pulse 80 bpm and regular and her temperature was elevated at 37.9 °C. There was mild neck stiffness on clinical examination.

A lumbar puncture was performed and the cerebrospinal fluid (CSF) showed the following results:

Opening pressure	28cm H_2O
White cell count	220 per mm^3 (80% lymphocytes)
Red cell count	55 per mm^3
Protein	2.2 g/l
Glucose	2.1 (serum glucose 6.6)

C India ink stain

With the history and the cerebrospinal fluid (CSF) findings of a raised opening pressure, a lymphocytic meningitis, markedly raised protein and low glucose, the differential diagnosis is between TB meningitis and cryptococcal meningitis. TB meningitis may be diagnosed by positive Ziehl–Nielsen (or auramine) staining, TB polymerase chain reaction (PCR) and/or TB culture of the CSF. Cryptococcal meningitis may be diagnosed by positive India ink staining or cryptococcal antigen. A negative India ink stain or screen for cryptococcal antigen would significantly raise the suspicion of underlying TB.

A Cytomegalovirus PCR

The CSF fluid would have normal glucose and less significantly elevated protein in viral meningitis.

B Epstein–Barr virus (EBV)

protein in viral meningitis.

B	Epstein–Barr virus (EBV) polymerase chain reaction (PCR)

The CSF fluid would have normal glucose and less significantly elevated protein in viral meningitis.

D	JC virus PCR

JC virus causes progressive multifocal leukoencephalopathy in immunosuppressed individuals. It does not cause meningitis.

E	Syphilis serology

In neurosyphilis the CSF findings would be a normal or raised pressure, clear fluid, less severely elevated protein, and normal glucose. The cell count is usually elevated with lymphocytosis, and VDRL and TPHA are positive.

You see a 43-year-old man with rigors. He suddenly became unwell 12 h ago and had four episodes of diarrhoea. According to his home help, she found him lying on the floor when she arrived. He was discharged from hospital 2 weeks ago after treatment for osteomyelitis. His medications included paracetamol, tramadol, fluoxetine and linezolid.

On examination, he was confused and agitated, with a temperature of 40.7 °C. His pulse was 142 bpm and regular and his respirations were 32 breaths per min.

Cranial nerve examination revealed rapid sustained eye movements. Peripheral nerve examination demonstrated generally increased tone, rapid contraction and relaxation of his ankle and hyper-reflexia.

Investigations:

Sodium (Na^+)	143 mmol/l
Potassium (K^+)	6.1 mmol/l
Creatinine (Cr)	181 μmol/l

Potassium (K^+)	6.1 mmol/l
Creatinine (Cr)	181 μmol/l
Urea	12.2 mmol/l
Creatine kinase	24,000 U/l
C-reactive protein (CRP)	243 μg/l
White cell count (WCC)	24.1×10^9/l
Haemoglobin (Hb)	12.4 g/dl
Platelets (PLT)	93×10^9/l
Pro time test (PT)	21 s

What is the most likely diagnosis?

A Neuroleptic malignant syndrome

B Meningitis

C Haemolytic Uraemic Syndrome

C-reactive protein (CRP)	243 μg/l
White cell count (WCC)	24.1×10^9/l
Haemoglobin (Hb)	12.4 g/dl
Platelets (PLT)	93×10^9/l
Pro time test (PT)	21 s

What is the most likely diagnosis?

A Neuroleptic malignant syndrome

B Meningitis

C Haemolytic Uraemic Syndrome

D Serotonin syndrome

E Lethal catatonia

You see a 43-year-old man with rigors. He suddenly became unwell 12 h ago and had four episodes of diarrhoea. According to his home help, she found him lying on the floor when she arrived. He was discharged from hospital 2 weeks ago after treatment for osteomyelitis. His medications included paracetamol, tramadol, fluoxetine and linezolid.

On examination, he was confused and agitated, with a temperature of 40.7 °C. His pulse was 142 bpm and regular and his respirations were 32 breaths per min.

Cranial nerve examination revealed rapid sustained eye movements. Peripheral nerve examination demonstrated generally increased tone, rapid contraction and relaxation of his ankle and hyper-reflexia.

Investigations:

Sodium (Na^+)	143 mmol/l
Potassium (K^+)	6.1 mmol/l

D Serotonin syndrome

Serotonin syndrome is associated with increased serotonergic activity, and the diagnosis is made on clinical grounds using the Hunter criteria. To fulfil these criteria a patient must have taken a serotonergic agent and meet one of the following conditions:

- Spontaneous clonus
- Inducible clonus plus agitation or sweating
- Ocular clonus plus agitation or sweating
- Tremor plus hyperreflexia
- Hypertonia plus temperature >38 plus ocular or inducible clonus

Serotonin syndrome is often misdiagnosed as neuroleptic malignant syndrome (NMS), but the two can readily be distinguished on the basis of

readily be distinguished on the basis of history, examination findings and clinical course. NMS develops over days to weeks, whereas serotonin syndrome develops over 24 h. Serotonin syndrome is characterised by neuromuscular hyper-reactivity (tremor, hyper-reflexia, myoclonus), while NMS involves sluggish neuromuscular responses (rigidity, bradyreflexia). Hyper-reflexia and myoclonus are rare in NMS. This patient takes a combination of high-risk medications: linezolid (monoamine oxidase inhibitor) and fluoxetine (selective serotonin reuptake inhibitor). Importantly, tramadol has effects on serotonin and noradrenalin and can cause serotonin syndrome, especially when in combination with other medications. Treatment involves stopping the offending medications. Cyproheptadine and propranolol have been used as they block serotonin. The patient may need to be managed in ITU and treated for hyperthermia, rhabdomyolysis, acute kidney disease and disseminated intravascular coagulation. In cases of hyperthermia

coagulation. In cases of hyperthermia, supportive measures and standard treatments include muscle relaxants, cooling and intubation.

A Neuroleptic malignant syndrome

NMS is a life-threatening condition associated with the use of neuroleptic agents. Features include mental status change, rigidity, fever or dysautonomia occurring in the setting of neuroleptic use or dopamine withdrawal. It typically develops over days to weeks.

B Meningitis

Although this patient has a fever and raised inflammatory markers, the presenting symptoms do not suggest meningitis, especially in the absence of any meningism.

C Haemolytic Uraemic Syndrome

HUS is defined by the triad of micro-angiopathic haemolytic anaemia, thrombocytopenia and acute kidney injury. It can be primary (complement gene mutations, antibodies to complement factor H) or secondary (infection, drug toxicity or autoimmune). HUS usually presents with bloody diarrhoea, oliguria, abdominal pain and acute kidney injury.

E	Lethal catatonia

Catatonia is a behavioural syndrome characterised by the inability to move normally, often occurring in the context of an underlying psychiatric disorder. Malignant catatonia is a subtype and consists of fever, autonomic instability, delirium and rigidity. The signs and symptoms overlap with NMS, and are indistinguishable in 20% of cases. NMS is considered a drug-induced form of malignant catatonia.

A 22-year-old woman has been an inpatient on the Medical Ward for 2 days. She was admitted with headache, fever and drowsiness. Cerebrospinal fluid examination was consistent with viral infection. A provisional diagnosis of herpes simplex encephalitis was made and she is receiving treatment with intravenous aciclovir. To confirm the diagnosis, magnetic resonance imaging of the brain, electroencephalogram and viral polymerase chain reaction of spinal fluid are requested. She has had no seizure activity.

Which EEG finding would be classically associated with herpes simplex encephalitis?

A	Normal activity
B	Bursts of focal frontal spike and wave activity
C	Isoelectric activity

with intravenous aciclovir. To confirm the diagnosis, magnetic resonance imaging of the brain, electroencephalogram and viral polymerase chain reaction of spinal fluid are requested. She has had no seizure activity.

Which EEG finding would be classically associated with herpes simplex encephalitis?

A	Normal activity
B	Bursts of focal frontal spike and wave activity
C	Isoelectric activity
D	Generalised spike and wave activity
E	Fronto-temporal slowing with periodic sharp wave complexes

E	Fronto-temporal slowing with periodic sharp wave complexes

The electroencephalogram, although less often used in the diagnosis of herpes simplex encephalitis, can still provide useful information. Typical changes are diffuse slowing and/or focal abnormality over the temporal and frontal lobes. There are reports that electroencephalogram changes can precede changes on imaging. Important other investigations in diagnosis of suspect herpes simplex encephalitis include imaging and cerebrospinal fluid examination. Viral polymerase chain reaction (PCR) of spinal fluid is highly sensitive (94–96%) and specific (98–100%). Magnetic resonance imaging of the brain is the imaging of choice, with changes seen in the medial temporal and inferior frontal lobes.

A	Normal activity

A	Normal activity

Given that this patient has evidence of neurological impairment, it is rather unlikely that normal activity would be observed. Changes at least in temporal lobe activity would be expected.

B	Bursts of focal frontal spike and wave activity

This is the picture that might be expected in frontal lobe epilepsy.

C	Isoelectric activity

An isoelectric EEG usually indicates absence of measurable brain activity, not consistent with the clinical picture seen here.

D	Generalised spike and wave activity

Generalised spike and wave activity is associated with generalised epilepsy.

You assess a 78-year-old man in the medical receiving unit. His history is of sudden onset weakness and diplopia.

On examination, pupils are equal and reactive. The right pupil is difficult to visualise due to a low-hanging eyelid and displacement of the eye in a temporal–inferior direction. There is flaccid weakness of the left arm and leg with an upgoing left plantar. The consultant neurologist phones to discuss the patient.

Where is the lesion most likely to be?

A	Right midbrain
B	Left lateral medulla
C	Left parietal lobe
D	Right hemi-cord
E	Corpus callosum

9:41
tps://mypastest.pastest.com 14

You assess a 78-year-old man in the medical receiving unit. His history is of sudden onset weakness and diplopia.

On examination, pupils are equal and reactive. The right pupil is difficult to visualise due to a low-hanging eyelid and displacement of the eye in a temporal–inferior direction. There is flaccid weakness of the left arm and leg with an upgoing left plantar. The consultant neurologist phones to discuss the patient.

Where is the lesion most likely to be?

Your answer was incorrect

A	Right midbrain
B	Left lateral medulla
C	Left parietal lobe

A Right midbrain

Historically, neurology has been rife with eponymous syndromes. Their use should be avoided as they are rarely pure and can lead to confusion. Localising a lesion neuroanatomically aids pathophysiological understanding and focuses investigation. However, knowledge of eponymous syndromes may still be tested in membership examinations. Note that acute central (upper motor neurone) lesions will cause a flaccid paralysis before spasticity and hyperreflexia develop; don't let this confuse you.

E Corpus callosum

The corpus callosum connects the left and right cerebral hemispheres and aids interhemispheric communication. Pathology of the splenium of the corpus callosum can give rise to alexia without agraphia. *Marchiafava-Bignami syndrome* is caused by callosal degeneration from chronic alcohol abuse and causes dementia, spasticity

A Right midbrain

Historically, neurology has been rife with eponymous syndromes. Their use should be avoided as they are rarely pure and can lead to confusion. Localising a lesion neuroanatomically aids pathophysiological understanding and focuses investigation. However, knowledge of eponymous syndromes may still be tested in membership examinations. Note that acute central (upper motor neurone) lesions will cause a flaccid paralysis before spasticity and hyperreflexia develop; don't let this confuse you.

E Corpus callosum

The corpus callosum connects the left and right cerebral hemispheres and aids interhemispheric communication. Pathology of the splenium of the corpus callosum can give rise to alexia without agraphia. *Marchiafava-Bignami syndrome* is caused by callosal degeneration from chronic alcohol abuse and causes dementia, spasticity,

dysarthria and an inability to walk.

B	Left lateral medulla

A lesion of the posterior inferior cerebellar artery would cause *Wallenberg's syndrome*. This consists of nystagmus, *ipsilateral* Horner's syndrome, *ipsilateral* temperature and pain facial sensory loss, *contralateral* limb sensory loss (pain and temperature), *ipsilateral* limb ataxia and *ipsilateral* palatal and vocal cord paralysis.

C	Left parietal lobe

Cortical pathology in the dominant parietal lobe (including the angular and supramarginal gyri) can cause *Gerstmann's syndrome:* finger agnosia; left–right disorientation; dysgraphia and acalculia.

D	Right hemi-cord

Hemi-cord lesions give rise to *Brown–*

and *ipsilateral* palatal and vocal cord paralysis.

C	Left parietal lobe

Cortical pathology in the dominant parietal lobe (including the angular and supramarginal gyri) can cause *Gerstmann's syndrome:* finger agnosia; left–right disorientation; dysgraphia and acalculia.

D	Right hemi-cord

Hemi-cord lesions give rise to *Brown–Séquard syndrome,* which consists of *ipsilateral* paresis and dorsal column sensory loss (vibration and proprioception) and *contralateral* spinothalamic sensory loss (pain and temperature) a few levels below the lesion.

7346

Rate this question:

A 42-year-old woman presents 12 h after a sudden-onset occipital headache, which began suddenly during sexual intercourse.

Computed tomography (CT) scan is unremarkable; lumbar puncture reveals evidence of xanthochromia. Her blood pressure on admission is 145/95 mmHg.

What is the most appropriate management for this patient?

A	Reassurance and discharge
B	Commence aspirin therapy
C	Commence angiotensin-converting enzyme (ACE) inhibitor therapy and discharge
D	Refer for magnetic resonance angiography
E	Commence sumatriptan

D Refer for magnetic resonance angiography

This patient has xanthochromia, which is suggestive of subarachnoid haemorrhage (SAH). Around 4% of subarachnoid haemorrhages occur after sexual intercourse, but not all post-coital headaches are due to SAH. This patient should definitely be considered for magnetic resonance angiography to determine whether she has a lesion that is likely to bleed again or is amenable to intervention.

A Reassurance and discharge

Given the presence of xanthochromia, a vascular lesion at further risk of bleeding should be excluded.

B Commence aspirin therapy

The xanthochromia is indicative of a potential intracerebral haemorrhage, and there is no role in the management of this case for aspirin.

of this case for aspirin.

C	Commence angiotensin-converting enzyme (ACE) inhibitor therapy and discharge

There is little evidence to support acute blood pressure control in this situation, and discharge without ruling out a significant vascular lesion is inappropriate.

E	Commence sumatriptan therapy

Only in the absence of xanthochromia would atypical migraine be considered as an alternative diagnosis here. Prescription of a tryptan at this point is therefore not appropriate.

6617

Rate this question:

Next Question

A 53-year-old man is referred by his general practitioner with a tremor affecting his left wrist and hand. This has been observed for the past 8 months and is present intermittently, but seems to worsen with stress or anxiety. He also reports feeling generally fatigued and low in mood. He has noticed a subtle decrease in dexterity and lack of coordination with activities such as playing golf.

On examination, he is noted to have a simple oscillating tremor of the left hand, which is present at rest. The same tremor is noticed with the arms outstretched. Assessment of tone reveals cogwheeling in the distal left upper limb. Examination of his gait demonstrates small steps, with reduced arm swing of the left upper limb and mild postural instability on tests of retropulsion.

Which of the following therapeutic strategies is most appropriate in this case?

outstretched. Assessment of tone reveals cogwheeling in the distal left upper limb. Examination of his gait demonstrates small steps, with reduced arm swing of the left upper limb and mild postural instability on tests of retropulsion.

Which of the following therapeutic strategies is most appropriate in this case?

A	Amantadine 100 mg twice daily
B	Co-careldopa 100 mg three times daily
C	Entacapone 200 mg three times daily
D	Propranolol 80 mg twice daily
E	Ropinirole 0.25 mg daily

A 53-year-old man is referred by his general practitioner with a tremor affecting his left wrist and hand. This has been observed for the past 8 months and is present intermittently, but seems to worsen with stress or anxiety. He also reports feeling generally fatigued and low in mood. He has noticed a subtle decrease in dexterity and lack of coordination with activities such as playing golf.

On examination, he is noted to have a simple oscillating tremor of the left hand, which is present at rest. The same tremor is noticed with the arms outstretched. Assessment of tone reveals cogwheeling in the distal left upper limb. Examination of his gait demonstrates small steps, with reduced arm swing of the left upper limb and mild postural instability on tests of retropulsion.

Which of the following therapeutic strategies is most appropriate in this case?

B Co-careldopa 100 mg three times daily

The clinical scenario is suggestive of Parkinson's disease (PD). Onset is typically asymmetrical, with the most common initial finding being resting tremor in an upper extremity. Over time, patients notice symptoms related to progressive bradykinesia, rigidity and gait difficulty. Other initial symptoms of PD may be non-specific and include fatigue and depression. The three cardinal signs of PD are resting tremor, rigidity and bradykinesia. Of these features, two of three including bradykinesia are required to make the clinical diagnosis. The goal of medical management in PD is to provide control of signs and symptoms for as long as possible while minimising adverse effects. Medications usually provide good symptomatic control for 4–6 years. After this, disability progresses despite best medical management, and many patients develop long-term motor complications including fluctuations and dyskinesia. Levodopa, coupled

and dyskinesia. Levodopa, coupled with a peripheral decarboxylase inhibitor (PDI), remains the mainstay of symptomatic treatment for PD. It provides the greatest anti-parkinsonian benefit with the fewest adverse effects.

E	Ropinirole 0.25 mg daily

Whilst a dopamine agonist would be a reasonable first-line therapy, most clinicians now favour L-Dopa as it is more effective in relieving symptoms. In addition, there are increasing concerns with dopamine agonists regarding side effects, such as impulse control disorder.

A	Amantadine 100 mg twice daily

Amantadine is a weak antagonist of the NMDA-type glutamate receptor, increases dopamine release and blocks dopamine re-uptake. This makes it a weak therapy for Parkinson's disease.

dopamine re-uptake. This makes it a weak therapy for Parkinson's disease. It can be used to treat L-DOPA-related motor fluctuations (i.e. shortening of L-DOPA duration of clinical effect, probably related to progressive neuronal loss) and L-DOPA-related dyskinesias (choreiform movements associated with long-term L-DOPA use, probably related to chronic pulsatile stimulation of dopamine receptors).

C	Entacapone 200 mg three times daily

Entacapone is a selective and reversible inhibitor of the enzyme catechol-O-methyltransferase (COMT). When taken together with levodopa (L-DOPA) and carbidopa, entacapone prevents catechol-O-methyltransferase from breaking down and metabolising levodopa, resulting in an overall increase of levodopa levels remaining in the brain and body. This can be used to help manage motor fluctuations.

D	Propranolol 80 mg twice daily

A 47-year-old man attends the clinic having become unsteady on walking over a period of 8 weeks. There has been trouble with poor performance at work because of memory issues over the past few weeks, and he has been disciplined. There have been intermittent fevers and he has abdominal pain, diarrhoea and bloating, and has lost 6 kg in weight. In addition, his wife has noticed that for the past 10 days he developed involuntary movements of his jaw, mouth and tongue, which were persistent while he was awake.

On examination, the Mini-Mental State Score is 20/30. Diffuse hyperpigmentation is noted over the face, trunk and limbs. Extra-ocular movements are restricted for superior gaze and saccadic movements are slow and fragmented. Bell's phenomenon can be elicited and oculo-masticatory involuntary movements are noted. Tendon reflexes are normal and the plantar response is flexor on both sides.

Investigations:

A 47-year-old man attends the clinic having become unsteady on walking over a period of 8 weeks. There has been trouble with poor performance at work because of memory issues over the past few weeks, and he has been disciplined. There have been intermittent fevers and he has abdominal pain, diarrhoea and bloating, and has lost 6 kg in weight. In addition, his wife has noticed that for the past 10 days he developed involuntary movements of his jaw, mouth and tongue, which were persistent while he was awake.

On examination, the Mini-Mental State Score is 20/30. Diffuse hyperpigmentation is noted over the face, trunk and limbs. Extra-ocular movements are restricted for superior gaze and saccadic movements are slow and fragmented. Bell's phenomenon can be elicited and oculo-masticatory involuntary movements are noted. Tendon reflexes are normal and the plantar response is

C Whipple's disease

Whipple's disease is caused by a Gram-positive bacillus that resides predominantly in the gut. Systemic features have been described in the scenario and include fever, weight loss, anaemia and gastrointestinal symptoms like steatorrhoea and abdominal pain. Hyperpigmentation and lymphadenopathy are usual manifestations. Neurological manifestations include slowly progressive memory loss and supranuclear ophthalmoplegia, where superior gaze is restricted; Bell's phenomenon is elicitable. Nystagmus, ataxia, myoclonus and seizures and highly characteristic oculo-masticatory movements complete the clinical picture. This patient's long term bowel symptoms and gradual neurological deterioration fits well with this as a diagnosis. The diagnosis is made mainly by Periodic acid–Schiff (PAS) staining of an intestinal (jejunal) biopsy; and PAS-positive material in the CSF.

Acute porphyrias without skin manifestations are associated with short periods of psychiatric disturbance, hyponatraemia and hypertension, rather than the picture seen here.

A Alzheimer's disease

The short duration of onset and age of the patient counts against a diagnosis of Alzheimer's, as do the gastrointestinal symptoms seen here.

B Meig syndrome

Meig syndrome is the association of a benign ovarian tumour with pleural and peritoneal fluid accumulation.

D Adrenoleucodystrophy

Adult onset adrenoleucodystrophy presents with progressive dementia leading eventually to a vegetative state without intervention, but without the GI symptoms seen here.

A 17-year-old girl presents to the Neurology Clinic for review.

She reports that over the last 5-6 years, she has gradually become increasingly less mobile and now has to rely on a wheelchair. She also reports that her speech has deteriorated. Her parents report she was well prior to this.

On examination, she has horizontal nystagmus, upper limb ataxia and a spastic paraparesis with bilateral pes cavus, absent knee and ankle reflexes and an extensor plantar reflex bilaterally. She has poor coordination of her upper limbs and her speech is dysarthric.

Her mother, father and brother are all well.

What is the most likely diagnosis?

A	Brainstem glioma
B	Abetalipoproteinaemia

nystagmus, upper limb ataxia and a spastic paraparesis with bilateral pes cavus, absent knee and ankle reflexes and an extensor plantar reflex bilaterally. She has poor coordination of her upper limbs and her speech is dysarthric.

Her mother, father and brother are all well.

What is the most likely diagnosis?

A	Brainstem glioma
B	Abetalipoproteinaemia
C	Charcot-Marie-Tooth disease type 1 (hereditary sensorimotor neuropathy)
D	Friedreich's ataxia (FA)
E	Multiple sclerosis

A 17-year-old girl presents to the Neurology Clinic for review.

She reports that over the last 5-6 years, she has gradually become increasingly less mobile and now has to rely on a wheelchair. She also reports that her speech has deteriorated. Her parents report she was well prior to this.

On examination, she has horizontal nystagmus, upper limb ataxia and a spastic paraparesis with bilateral pes cavus, absent knee and ankle reflexes and an extensor plantar reflex bilaterally. She has poor coordination of her upper limbs and her speech is dysarthric.

Her mother, father and brother are all well.

What is the most likely diagnosis?

Your answer was incorrect

D Friedreich's ataxia (FA)

Friedreich's ataxia (FA) is the most common hereditary, early-onset ataxia. It is caused by degeneration of multiple spinal cord pathways and peripheral nervous system axon degeneration. It is autosomal recessive, with peak incidence in the 8–15-year age band, and the defect responsible is thought to lie on chromosome 9.

Neurological signs include ataxia with decreased coordination, balance and reflexes. Eye movements and speech can be impaired and there are often associated electrocardiogram (ECG) abnormalities, with widespread T-wave inversion and evidence of left ventricular hypertrophy occurring in around 65% of patients.

There is unfortunately no disease-modifying treatment for the condition and the focus is on symptom management.

A Brainstem glioma

This is a cancerous tumour of the brainstem most commonly seen in teenagers and young adults. Symptoms include weakness and loss of balance, but also other signs of raised intracranial pressure such as headache, visual disturbance, nausea and seizure. It is therefore an incorrect option.

B	Abetalipoproteinaemia

This is a rare genetic disorder that interferes with absorption of fats and certain vitamins. Symptoms usually appear in the first few months of life and include failure to thrive and steatorrhea; this then leads onto central nervous system signs resulting from severe vitamin deficiency. With the absence of symptoms from birth, this diagnosis is less likely and therefore an incorrect option.

C	Charcot-Marie-Tooth disease type 1 (hereditary sensorimotor neuropathy)

therefore an incorrect option.

C	Charcot-Marie-Tooth disease type 1 (hereditary sensorimotor neuropathy)

This is one of a group of hereditary disorders that produces a progressive peripheral sensorimotor deficit similar to that of FA, but not usually dysarthria, and therefore this is an incorrect option.

E	Multiple sclerosis

This is a disease causing demyelination of nerves in the central nervous system and can lead to both sensory and motor deficits. It is uncommon, however, and it would be extremely uncommon to see disease onset in a patient this young, let alone of a severity that would cause her to be wheelchair bound.

13487

Rate this question:

An 18-year-old nursing student is admitted for investigation of severe headache and neck stiffness. Her CT scan was normal and the on call physicians want to carry out an LP. She is worried about post-lumbar puncture headache.

Which technique, that has been shown to reduce the frequency of post-lumbar puncture headache, would be suitable in this patient?

A	No local anaesthetic prior to insertion of spinal needle
B	Four hours' bed rest post-procedure
C	Use of atraumatic needle
D	Full explanation of the frequency and clinical features of post-procedure headache
E	Lumbar puncture in the

C Use of atraumatic needle

Headache post-lumbar puncture is a common complication. A number of strategies have been suggested to prevent its occurrence, but the use of atraumatic (or 'non-cutting') needles has the best evidence base.

A No local anaesthetic prior to insertion of spinal needle

Use of local anaesthetic prior to insertion of a spinal needle has not been shown to reduce the first pass success rate, and is recommended for patient comfort.

B Four hours' bed rest post-procedure

There is no clear benefit from enforced bed rest immediately post-procedure.

D Full explanation of the frequency and clinical

procedure

There is no clear benefit from enforced bed rest immediately post-procedure.

D	Full explanation of the frequency and clinical features of post-procedure headache

It is good practice to tell patients what to expect in terms of possible risks, but this will not prevent adverse events occurring.

E	Lumbar puncture in the sitting position

There is no evidence to suggest this reduces post-LP headache rates.

7321

Rate this question:

Next Question

A 64-year-old diabetic man has come to his GP after having sustained a minor head injury following a faint. He reports that he has often felt faint after standing from a lying position, and has actually previously fainted on a couple of these occasions. He lives by himself and consequently has become rather worried about these fainting episodes. Their onset has been gradual over a number of months.

On further questioning, although the patient is reluctant to talk about this, he does also report that he has become impotent and that his skin has become very dry. The positive findings on examination include orthostatic hypotension, a resting tachycardia and bilateral small pupils with a sluggish reaction to light.

Which of the following conditions could give rise to this clinical picture?

A	Amyloidosis
B	Diabetes insipidus

On further questioning, although the patient is reluctant to talk about this, he does also report that he has become impotent and that his skin has become very dry. The positive findings on examination include orthostatic hypotension, a resting tachycardia and bilateral small pupils with a sluggish reaction to light.

Which of the following conditions could give rise to this clinical picture?

A	Amyloidosis
B	Diabetes insipidus
C	Endocarditis
D	Extrinsic allergic alveolitis
E	Hyperparathyroidism

minor head injury following a faint. He reports that he has often felt faint after standing from a lying position, and has actually previously fainted on a couple of these occasions. He lives by himself and consequently has become rather worried about these fainting episodes. Their onset has been gradual over a number of months.

On further questioning, although the patient is reluctant to talk about this, he does also report that he has become impotent and that his skin has become very dry. The positive findings on examination include orthostatic hypotension, a resting tachycardia and bilateral small pupils with a sluggish reaction to light.

Which of the following conditions could give rise to this clinical picture?

Your answer was correct

A Amyloidosis

B Diabetes insipidus

A Amyloidosis

Autonomic neuropathy refers to a group of syndromes that affect the autonomic neurons, either sympathetic, parasympathetic or both. It can be primary, with no known cause or it can occur secondary to a range of conditions that include diabetes mellitus, amyloidosis, drugs, as part of a polyneuropathy (e.g. Guillain–Barré), infections (HIV, Chagas disease, leprosy), metabolic neuropathy (uraemic neuropathy, hepatic disease-related neuropathy), immune-mediated causes (rheumatoid arthritis, SLE) and causes related to systemic disease (coeliac disease). Typical signs include postural hypotension, impotence, decrease in sweating, nocturnal diarrhoea, constipation, post-prandial dizziness, nocturia, bladder urgency and a Horner's pupil. Treatment is aimed at treating the underlying causes and advice with regards to how to decrease the symptoms: for example, raising head of bed at night to increase renin release and so decrease fluid loss, eating little and

example, raising head of bed at night to increase renin release and so decrease fluid loss, eating little and often to reduce post-prandial dizziness and increased salt intake. Pharmacological treatment, e.g. fluid-retaining drugs, is reserved for more difficult cases or where conservative treatment is unsuccessful.

B	Diabetes insipidus

Diabetes insipidus is a condition characterised by large amounts of dilute urine and increased thirst due to ADH deficiency or lack of response to ADH. Diabetes insipidus is not associated with autonomic neuropathy, whereas diabetes mellitus is.

C	Endocarditis

Neurological consequences of endocarditis include ischaemic or haemorrhagic stroke, infected intracranial aneurysm, meningitis, brain abscess, spinal epidural abscess,

encephalopathy, mononeuropathy and seizure. Autonomic neuropathy is not a feature.

D	Extrinsic allergic alveolitis

Extrinsic allergic alveolitis is an immunologically mediated disease resulting in a hypersensitivity pneumonitis with T-cell lymphocytic infiltration and granulomatous inflammation in the bronchioles and alveoli, from the repeated inhalation of certain antigens in a sensitised person. Autonomic neuropathy is not a feature.

E	Hyperparathyroidism

Hyperparathyroidism is increased parathyroid hormone (PTH) levels in the blood. This occurs either from the parathyroid glands inappropriately producing too much PTH (primary hyperparathyroidism) or other events triggering this (secondary hyperparathyroidism). Most people with primary disease have no symptoms at the time of diagnosis. In

infiltration and granulomatous inflammation in the bronchioles and alveoli, from the repeated inhalation of certain antigens in a sensitised person. Autonomic neuropathy is not a feature.

E	Hyperparathyroidism

Hyperparathyroidism is increased parathyroid hormone (PTH) levels in the blood. This occurs either from the parathyroid glands inappropriately producing too much PTH (primary hyperparathyroidism) or other events triggering this (secondary hyperparathyroidism). Most people with primary disease have no symptoms at the time of diagnosis. In those with symptoms the most common is kidney stones, with other potential symptoms including weakness, depression, bone pains, confusion and increased urination. Both types increase the risk of weak bones. Autonomic neuropathy is not a feature.

A 17-year-old woman attends the Epilepsy Clinic. She has suffered tonic-clonic seizures for 5 years. After initial poor response, her epilepsy is now well-controlled on sodium valproate 1 g daily. She has been seizure-free for 2 years. Her compliance with therapy is good

From review of her case sheet, you note a family history of cerebrovascular disease with both grandparents suffering stroke.

At time of diagnosis, computerised tomography (CT) brain showed no structural abnormality and interictal electroencephalogram (EEG) was unremarkable.

She is concerned over weight gain and hair loss that she attributes to her anticonvulsant therapy. She is considering stopping her sodium valproate.

What feature in her history predicts seizure recurrence on discontinuation of therapy?

structural abnormality and interictal electroencephalogram (EEG) was unremarkable.

She is concerned over weight gain and hair loss that she attributes to her anticonvulsant therapy. She is considering stopping her sodium valproate.

What feature in her history predicts seizure recurrence on discontinuation of therapy?

A	Female sex
B	Need for high-dose anticonvulsant
C	Early age at diagnosis
D	Family history
E	Tonic clonic seizures

A 17-year-old woman attends the Epilepsy Clinic. She has suffered tonic-clonic seizures for 5 years. After initial poor response, her epilepsy is now well-controlled on sodium valproate 1 g daily. She has been seizure-free for 2 years. Her compliance with therapy is good

From review of her case sheet, you note a family history of cerebrovascular disease with both grandparents suffering stroke.

At time of diagnosis, computerised tomography (CT) brain showed no structural abnormality and interictal electroencephalogram (EEG) was unremarkable.

She is concerned over weight gain and hair loss that she attributes to her anticonvulsant therapy. She is considering stopping her sodium valproate.

What feature in her history predicts

E Tonic clonic seizures

The decisions to start and stop anti-epileptic drugs (AED) in a patient with epilepsy are complicated. Factors such as nature of seizures, type of epilepsy, driving restrictions, occupation and desire to conceive need to be considered. Combining all types of epilepsy, in a patient who has been seizure free for more than 2 years, the chance of recurrence in the next 2 years is 43% if they stop therapy compared with 10% if drugs are continued. Factors that have been shown to increase the risk include older age at diagnosis, use of multiple anticonvulsants, history of myoclonic or tonic-clonic seizure, previous abnormal imaging or electroencephalogram (EEG). In this patient it would be wise to complete neuro-imaging with cerebral MRI prior to taking the decision about treatment.

Traditionally, sodium valproate was an effective first-line agent for generalised seizures; however, it is now restricted in its use in females of child-

restricted in its use in females of child-bearing age and is now considered appropriate only if no other drug option is available. The patient is correct that this agent is associated with weight gain; other common side effects include hair loss, sedation and tremor. As a result of such side-effects and especially the risk of teratogenicity, and other pregnancy-related issues, with valproate more than with certain other AED, neurologists now favour lamotrigine in young female patients.

A	Female sex

The sex of the patient has no bearing on prognosis.

B	Need for high-dose anticonvulsant

The use of multiple drugs predicts seizure recurrence, but not high doses of a single drug.

A Female sex

The sex of the patient has no bearing on prognosis.

B Need for high-dose anticonvulsant

The use of multiple drugs predicts seizure recurrence, but not high doses of a single drug.

C Early age at diagnosis

This does not have an impact on risk of seizure recurrence.

D Family history

Her family history of cerebrovascular disease in elderly relatives is not pertinent to her seizure risk.

32726

Rate this question:

Next Question

A 40-year-old lady who has had insulin-dependent diabetes mellitus (IDDM) for 15 years, and who underwent resection of carcinoma of the left breast 5 years ago, was brought to the Emergency Department with history of painful spasms of the lower limbs. She has also noticed progressive stiffness of her limbs for the past four weeks.

On examination, she was alert. Her cranial nerves were normal. Gait was unusual, with lumbar lordosis and taut paraspinal and lower limb muscles. There was no weakness of the limbs; tendon reflexes could not be assessed well. Planters were flexors.

Choose the most likely diagnosis

A	Tetanus
B	Dystonia
C	Stiff person syndrome
D	Compressive myelopathy

with history of painful spasms of the lower limbs. She has also noticed progressive stiffness of her limbs for the past four weeks.

On examination, she was alert. Her cranial nerves were normal. Gait was unusual, with lumbar lordosis and taut paraspinal and lower limb muscles. There was no weakness of the limbs; tendon reflexes could not be assessed well. Planters were flexors.

Choose the most likely diagnosis

A	Tetanus
B	Dystonia
C	Stiff person syndrome
D	Compressive myelopathy
E	Paraneoplastic encephalomyelitis

A 40-year-old lady who has had insulin-dependent diabetes mellitus (IDDM) for 15 years, and who underwent resection of carcinoma of the left breast 5 years ago, was brought to the Emergency Department with history of painful spasms of the lower limbs. She has also noticed progressive stiffness of her limbs for the past four weeks.

On examination, she was alert. Her cranial nerves were normal. Gait was unusual, with lumbar lordosis and taut paraspinal and lower limb muscles. There was no weakness of the limbs; tendon reflexes could not be assessed well. Planters were flexors.

Choose the most likely diagnosis

Your answer was correct

A	Tetanus
B	Dystonia

C Stiff person syndrome

This is a condition of persistent spasms, particularly of the proximal lower limbs and lumbar paraspinals, leading to exaggerated lumbar lordosis. The onset is insidious, usually in middle life. Males and females are equally affected. Trismus does not occur; thus differentiating it from tetanus. Muscle spasms typically disappear in sleep. Anti-GAD antibodies may be found in the serum and are supportive of the diagnosis. EMG may show continuous motor unit activity.

A Tetanus

The lack of trismus and several-week history of stiffness make this unlikely.

B Dystonia

Dystonia is defined as the involuntary, repetitive, patterned movement of a muscle or group of muscles. In adults

B	Dystonia

Dystonia is defined as the involuntary, repetitive, patterned movement of a muscle or group of muscles. In adults the commonest form is cervical dystonia (torticollis). Lower limb onset dystonia in adults is incredibly rare, thus making it an unlikely diagnosis here.

D	Compressive myelopathy

Whilst thoracic cord compression could cause spasticity in the legs one would expect weakness, brisk reflexes, up-going plantars, sensory loss and bladder disturbance.

E	Paraneoplastic encephalomyelitis

In this disorder one would expect to see cognitive impairment and/or seizures, as well as signs suggesting spinal cord dysfunction.

A 70-year-old obese male smoker presents to Casualty with unilateral ptosis, diplopia and fatigue. He is assessed by the neurology team that day, and a provisional diagnosis of myasthenia gravis is made. He is admitted for investigation and treatment.

On electromyography, repetitive stimulation gives a series of progressively smaller complexes. He is commenced on oral pyridostigmine 60 mg qds. You assess him the following morning. He feels stronger but is having difficulty swallowing the tablets.

Full neurological examination is limited as he is too breathless to lie on the examination couch. You note fatigability of limbs and eyes, along with brisk reflexes and head drooping.

What is the next step in his management?

A	Auto-antibodies and CT chest

commenced on oral pyridostigmine 60 mg qds. You assess him the following morning. He feels stronger but is having difficulty swallowing the tablets.

Full neurological examination is limited as he is too breathless to lie on the examination couch. You note fatigability of limbs and eyes, along with brisk reflexes and head drooping.

What is the next step in his management?

A	Auto-antibodies and CT chest
B	NG tube and double-dose pyridostigmine
C	Oral prednisolone
D	Oral 3,4-diaminopyridine
E	IV immunoglobulin

presents to casualty with unilateral ptosis, diplopia and fatigue. He is assessed by the neurology team that day, and a provisional diagnosis of myasthenia gravis is made. He is admitted for investigation and treatment.

On electromyography, repetitive stimulation gives a series of progressively smaller complexes. He is commenced on oral pyridostigmine 60 mg qds. You assess him the following morning. He feels stronger but is having difficulty swallowing the tablets.

Full neurological examination is limited as he is too breathless to lie on the examination couch. You note fatigability of limbs and eyes, along with brisk reflexes and head drooping.

What is the next step in his management?

Your answer was incorrect

E IV immunoglobulin

This patient has severe myasthenia gravis. His dyspnoea on lying supine indicates diaphragmatic weakness, while swallowing difficulties point to bulbar problems. He is already on reasonable dose anticholinesterase and quickly increasing this medication may precipitate cholinergic crises. Immunosuppression in the form of oral steroid as a single agent or with azathioprine should be initiated but may initially exacerbate the weakness. Intravenous immunoglobulin and plasma exchange have been shown to rapidly relieve weakness in the short term and should be used in this patient while other immunosuppressive therapy is titrated.

C Oral prednisolone

Although corticosteroids are appropriate in managing myasthenia gravis, their speed of onset is such that immunoglobulin is required to avoid

gravis, their speed of onset is such that immunoglobulin is required to avoid deterioration towards intubation and ventilation.

A Auto-antibodies and CT chest

Although these may be useful in confirming the diagnosis, waiting for these investigations to conclude risks this patient deteriorating to the extent that she needs intubation and ventilation.

B NG tube and double-dose pyridostigmine

Even doubling the dose of pyridostigmine is unlikely to overcome his symptoms without immune intervention.

D Oral 3,4-diaminopyridine

This agent is used in the treatment of weakness related to Lambert–Eaton myasthenic syndrome.

A 42-year-old Jamaican man was referred for the evaluation of a complaint of progressive weakness and tingling of his lower limbs for the past 4 months. Over the past 2 months, his vision has been deteriorating and he observed that he had difficulty in hearing the television in his flat. He is currently unemployed and admits he has been struggling for money to buy food.

On examination, he had excoriations around the mucocutaneous junction of his mouth. Fundus examination revealed pale optic discs on both sides. Rinne's test revealed air conduction to be better than bone conduction. Audiogram revealed that he could hear 8000 Hz at 60 decibels and 250 Hz at 20 decibels.

The distal groups of muscles of all limbs were weak with 4/5 power, and tendon reflexes were reduced. Romberg's test was positive.

What is the most likely diagnosis?

A Combination B vitamin deficiency

Strachan's syndrome was originally observed by Strachan in 1897 among Jamaican sugarcane workers, but has also been described in prisoners from Japanese POW camps in World War II. It is certainly nutritional in origin but does not conform clinically to beriberi or pellagra, and is thought to result from a combination of B vitamin deficiencies as it doesn't resolve with replacement of B_{12} alone. Symptoms include painful peripheral neuropathy and optic atrophy, with progression to blindness if left untreated.

B Hartnup's disease

Hartnup's disease is an autosomal recessive amino acid disorder, and presents in childhood with features of skin rash resembling pellagra, emotional liability and episodic cerebellar ataxia.

A Combination B vitamin deficiency

Strachan's syndrome was originally observed by Strachan in 1897 among Jamaican sugarcane workers, but has also been described in prisoners from Japanese POW camps in World War II. It is certainly nutritional in origin but does not conform clinically to beriberi or pellagra, and is thought to result from a combination of B vitamin deficiencies as it doesn't resolve with replacement of B_{12} alone. Symptoms include painful peripheral neuropathy and optic atrophy, with progression to blindness if left untreated.

B Hartnup's disease

Hartnup's disease is an autosomal recessive amino acid disorder, and presents in childhood with features of skin rash resembling pellagra, emotional liability and episodic cerebellar ataxia.

C	Neuropathic beriberi

Neuropathic beriberi is associated with features of Wernicke's encephalopathy, bilateral lower limb parasthesias, burning pain and muscle cramps. The optic atrophy seen here is not a usual feature of neuropathic beriberi.

D	Peroneal muscular atrophy

This is Charcot–Marie–Tooth disease, associated with foot drop and weakness of distal lower limb muscles. High-arched feet and hammer toes are other features of the condition, and presentation of the commonest form is usual by 10 years of age.

E	Hereditary motor and sensory neuropathy type 3

This is an autosomal dominant motor and sensory neuropathy that presents in the majority of cases by age 30. Calf muscle weakness is the usual presenting symptom.

6:55
https://mypastest.paste

A 72-year-old man presents to the Emergency Department with severe flinging movements of his right arm.

Where is the causative lesion?

Your answer was correct

A	Right cerebellum
B	Left subthalamic nucleus
C	Medial longitudinal fasciculus (MLF)
D	Right brachial plexus
E	Left thalamus

Explanation

Audio Video Stop Share Participants More

6:55
https://mypastest.paste

B Left subthalamic nucleus

Hemiballismus is a movement disorder which manifests as unilateral involuntary flinging movements of the proximal upper limbs. The lesion is in the contralateral subthalamic nucleus of Luys. In the elderly, the usual cause is a vascular event such as a stroke, whereas in younger patients, the aetiology may be infectious or inflammatory. Hemiballismus patients require treatment, both for the underlying aetiology and for the movements themselves. There are no large controlled clinical trials to guide anti-ballismus therapy. Dopamine receptor-blocking agents have been shown to suppress choreic and ballistic movements. Standard neuroleptic drugs, such as haloperidol, are started at low doses and titrated, as tolerated, until the movements are controlled.

Audio Video Stop Share Participants More

6:55
https://mypastest.paste

Catecholamine-depleting agents, such as tetrabenazine, may be considered when long-term therapy is required.

A	Right cerebellum

A cerebellar lesion could present with vertigo, headache, vomiting and ataxia. On examination, the patient may have dysdiadochokinesia, dysarthria, ataxia, nystagmus and past-pointing. Also there could be weakness. The severe flinging movements described seem greater than inco-ordination, and the absence of this and other signs makes a cerebellar lesion unlikely.

C	Medial longitudinal fasciculus (MLF)

The MLF is a heavily myelinated tract connecting the paramedian pontine reticular formation abducens complex

Audio Video Stop Share Participants More

6:55
https://mypastest.paste

contralateral side. Lesions results in internuclear ophthalmoplegia, in which conjugate gaze is impaired in induction. It can occur most commonly with multiple sclerosis or, in more elderly patients, stroke.

D	Right brachial plexus

A right brachial plexus injury would result in lower motor neurone weakness and sensory loss of part of C5–C8 and T1. Clinically, this can present as Erb's palsy; the arm hangs in medial rotation, with an extended and pronated forearm, or Klumpke's paralysis – weakness of the forearm with an ulnar clawed hand. Common causes include trauma and shoulder dystocia in childbirth.

E	Left thalamus

Audio Video Stop Share Participants More

6:58
https://mypastest.paste

A 69-year-old man presented with a history of progressive weakness of his lower limbs for the past four months. It was difficult for him to get up from his armchair and to walk. He has noticed that he tires very easily in any activity. There was some aching pain in his thighs. He was concerned that for the past several months he had a dry mouth and he needed laxatives to move his bowels effectively; sometimes this was very painful and he felt that he had not completely emptied. His GP has identified a positive faecal occult blood sample and he has lost 3 kg in weight over the past 2 months.

On examination, his blood pressure was 180/90 mmHg, heart rate 102/min. There was no clubbing or skin rash. His BMI was 24.

He was alert and cognition was normal. Pupils were 2.5 mm on each side and

Audio Video Stop Share Participants More

7:00
https://mypastest.paste

Pupils were 2.5 mm on each side and were non-reactive to light. He also had slight bilateral ptosis. Other cranial nerves were normal. Hip flexors were 4/5. His grip strength also appeared weak bilaterally, but improved with reinforcement. Tendon reflexes were symmetrical and hypoactive. Planters were flexors. No muscle tenderness was present.

What is the most likely diagnosis?

A	Polymyositis
B	Lumbosacral disc disease
C	Cauda equina syndrome
D	Lambert–Eaton myasthenic syndrome

Audio Video Stop Share Participants More

7:01
https://mypastest.paste

nerves were normal. Hip flexors were 4/5. His grip strength also appeared weak bilaterally, but improved with reinforcement. Tendon reflexes were symmetrical and hypoactive. Planters were flexors. No muscle tenderness was present.

What is the most likely diagnosis?

A	Polymyositis
B	Lumbosacral disc disease
C	Cauda equina syndrome
D	Lambert–Eaton myasthenic syndrome
E	Spinal-muscular atrophy

Audio Video Stop Share Participants More

7:02
https://mypastest.paste

D Lambert-Eaton myasthenic syndrome

LEMS is a particular form of myasthenia, typically occurring in the context of a paraneoplastic syndrome, observed more often in patients with oat cell carcinoma of the lung (60%) or carcinomas of the breast, prostate, stomach, rectum and lymphoma. It is characterised by temporary increase in muscle power during the first few contractions, followed by increasing weakness after exertion.
Unlike in myasthenia gravis, the muscles of the pelvic and shoulder girdles and trunk are the ones that become fatiguable and weak. Tendon reflexes are often diminished.
Autonomic disturbances are usually seen, such as dry mouth, impotence, constipation, difficulty in micturition and non-reactive pupils. Cranial nerves may be involved, with ptosis occurring

Audio Video Stop Share Participants More

7:02
https://mypastest.paste

and non-reactive pupils. Cranial nerves may be involved, with ptosis occurring in around half of patients. Given the positive faecal occult blood sample and sensation of incomplete emptying, it is possible that he has an underlying rectal tumour.
Repetitive nerve stimulation reveals an incremental response (marked increase in the amplitude of action potentials).

Most patients benefit from 3,4-diaminopyridine 20 mg, five times daily. It may be combined with pyridostigmine. Intravenous immunoglobulin, plasmapheresis and corticosteroids have all been used with variable responses. Excision of the primary tumour is also known to positively affect symptom control.

A	Polymyositis

Polymyositis is associated with painful

Audio Video Stop Share Participants More

7:02
https://mypastest.paste

proximal myopathy, not the painless progressive proximal weakness seen here.

B Lumbosacral disc disease

Bilateral ptosis and weak grip strength are inconsistent with lumbosacral disc disease as the primary diagnosis.

C Cauda equina syndrome

The upper limb signs and ptosis don't fit with a diagnosis of cauda equina syndrome, which is associated with saddle anaesthesia.

E Spinal-muscular atrophy

Spinal muscular atrophy of adulthood presents in the third decade of life with gradually progressive proximal muscle

Audio Video Stop Share Participants More

7:03
https://mypastest.paste

A 23-year-old man presented to the Outpatient Clinic complaining of difficulty with his memory over the last few years. He had been unable to hold down a regular job because of this. He had found it very difficult to concentrate at work, feeling extremely tired most of the time and occasionally falling asleep at his desk.

He suffered from recurrent headaches, which happened on most days of the week for 1–4 h and were bi-frontal and throbbing in nature. He had recently had a few episodes where he had fallen to the ground without warning.

On further questioning, he complained of problems with sleeping at night, occasionally waking up in the middle of the night with a feeling that he could not move.

What would be the best treatment for this condition?

Audio Video Stop Share Participants More

7:05
https://mypastest.paste

of problems with sleeping at night, occasionally waking up in the middle of the night with a feeling that he could not move.

What would be the best treatment for this condition?

A	Sodium valproate
B	Paroxetine
C	Amitriptyline
D	Carbamazepine
E	Modafinil

6952

Submit

Audio Video Stop Share Participants More

7:05
https://mypastest.paste

E Modafinil

The most likely diagnosis is narcolepsy. This is a condition that presents in the teens or 20s and consists of a tetrad of excessive daytime sleepiness, cataplexy (a sudden loss of voluntary muscle tone, often triggered by emotional stimuli), sleep paralysis (feeling that you are awake but cannot move) and hypnagogic/hypnopompic hallucinations (hallucinations on going to sleep/waking). However, not all of these have to be present to make a diagnosis. There is a human leucocyte antigen (HLA) association in a number of patients: DR2 and DQB1*0602 are both associated with narcolepsy with cataplexy (around 90% of patients). Diagnosis can be confirmed with a multiple sleep latency test. Excessive sleepiness can be alleviated by use of modafinil.

Audio Video Stop Share Participants More

7:06
https://mypastest.paste

An 18-year-old man is referred to the neurologist for the evaluation of sudden, shock-like contractions of his limbs, occurring particularly in the early morning for the past 4 years. These contractions may be precipitated by touch or even just a loud noise. He is unsteady on his feet and clumsy with his hands, and academically he's failing to achieve and has been recognised in class as hard of hearing.

One week before the appointment, he lost consciousness with a tonic-clonic seizure. His father is entirely normal. All of his three siblings have deafness and are diabetic, taking insulin.

On examination, he has mild cognitive impairment. His height is 140 cm. Both optic discs are pale. A grade 1 horizontal gaze-evoked nystagmus is evident. Incoordination is seen in all limbs. Shoulder girdle and pelvic girdle

Audio Video Stop Share Participants More

7:09
https://mypastest.paste

An 18-year-old man is referred to the neurologist for the evaluation of sudden, shock-like contractions of his limbs, occurring particularly in the early morning for the past 4 years. These contractions may be precipitated by touch or even just a loud noise. He is unsteady on his feet and clumsy with his hands, and academically he's failing to achieve and has been recognised in class as hard of hearing.

One week before the appointment, he lost consciousness with a tonic-clonic seizure. His father is entirely normal. All of his three siblings have deafness and are diabetic, taking insulin.

On examination, he has mild cognitive impairment. His height is 140 cm. Both optic discs are pale. A grade 1 horizontal gaze-evoked nystagmus is evident. Incoordination is seen in all limbs. Shoulder girdle and pelvic girdle

Audio Video Stop Share Participants More

7:09
https://mypastest.paste

muscles are weak, with power 4/5. Tendon reflexes are reduced in the upper limbs and absent in the lower limbs. You cannot evoke a plantar response and vibration sense is diminished to mid-shin.

What is the most likely diagnosis?

A	Bassen–Kornzweig syndrome
B	Mitochondrial myopathic syndrome
C	Paraneoplastic cerebellar degeneration
D	Spinocerebellar ataxia
E	Lafora body disease

32770
Audio Video Stop Share Participants More

7:10
https://mypastest.paste

An 18-year-old man is referred to the neurologist for the evaluation of sudden, shock-like contractions of his limbs, occurring particularly in the early morning for the past 4 years. These contractions may be precipitated by touch or even just a loud noise. He is unsteady on his feet and clumsy with his hands, and academically he's failing to achieve and has been recognised in class as hard of hearing.

One week before the appointment, he lost consciousness with a tonic-clonic seizure. His father is entirely normal. All of his three siblings have deafness and are diabetic, taking insulin.

On examination, he has mild cognitive impairment. His height is 140 cm. Both optic discs are pale. A grade 1 horizontal gaze-evoked nystagmus is evident. Incoordination is seen in all limbs. Shoulder girdle and pelvic girdle

Audio Video Stop Share Participants More

7:10
https://mypastest.paste

B Mitochondrial myopathic syndrome

When a young adult develops myoclonus elicited by startle, with other types of seizures and then is found to have ataxia, mental decline, optic atrophy, deafness, short stature or peripheral neuropathy, a mitochondrial disease should be suspected. A family history of diabetes mellitus, unexplained deafness, unexplained neonatal deaths and seizure disorders with progressive neurological deficits, and a pattern which suggests a maternal inheritance, further complements this thought process. A mild proximal myopathy may be associated. Around 80% of such patients (with myoclonic epilepsy and ragged-red fibre disease (MERRF)) have a point mutation of the mitochondrial genome at locus 8344. Resting and post-exercise serum

Audio Video Stop Share Participants More

7:11
https://mypastest.paste

Resting and post-exercise serum lactate and pyruvate determination are helpful. Cerebrospinal fluid (CSF) lactic acid and CSF pyruvic acid should be measured – for example, lactic acid levels may be normal in blood but elevated in CSF. EEG may also be useful here, especially given the presentation with myoclonic jerks.

A	Bassen–Kornzweig syndrome

Bassen–Kornzweig syndrome is the most well-known form of neuroacanthosis, which results in acanthosis of red blood cells and progressive ataxia. It doesn't therefore fit with the clinical picture seen here.

C	Paraneoplastic cerebellar degeneration

There is no evidence of underlying

Audio Video Stop Share Participants More

7:11
https://mypastest.paste

There is no evidence of underlying malignancy (PCD is usually associated with lung or breast cancer), and the predominant symptoms seen here are muscle weakness rather than cerebellar symptoms.

D	Spinocerebellar ataxia

Twenty-nine autosomal recessive spinocerebellar ataxias are now identified. The absence of cerebellar signs clearly counts against this as the underlying diagnosis.

E	Lafora body disease

Lafora body disease is a benign myoclonic epilepsy of infancy, and therefore doesn't fit with the clinical presentation seen here. Sodium valproate is the mainstay of therapy.

Audio Video Stop Share Participants More

7:14
https://mypastest.paste

A 19-year-old student comes to the Neurology Clinic. He is falling behind in his university studies. He is having disturbed nights of sleep and falls asleep suddenly during class in the daytime. This is hugely embarrassing and tends to occur in stressful situations or during a particularly animated conversation. In an attempt to sleep well at night, he has been drinking large amounts of alcohol in the evening.

Further questioning reveals that he has also been suffering from hypnagogic hallucinations. A friend recommended he try amphetamines to try and stay awake in the day.

Neurological examination is unremarkable.

Investigations:

Hb	12.3 g/dl

Audio Video Stop Share Participants More

7:15
https://mypastest.paste

Hb	12.3 g/dl
WCC	5.6×10^9/l
PLT	209×10^9/l
Na^+	140 mmol/l
K^+	4.8 mmol/l
Creatinine	100 µmol/l
Urine toxicology screen	Amphetamines+

Which of the following is the most likely diagnosis?

A	Narcolepsy
B	Rapid eye movement (REM) sleep disorder
C	Restless legs syndrome

Audio Video Stop Share Participants More

7:15
https://mypastest.paste

Urine toxicology screen	Amphetamines+

Which of the following is the most likely diagnosis?

A	Narcolepsy
B	Rapid eye movement (REM) sleep disorder
C	Restless legs syndrome
D	Alcohol dependency
E	3,4-Methylenedioxymethamphetami (MDMA)-related sleep disorder

21176
Audio Video Stop Share Participants More

7:15
https://mypastest.paste

A Narcolepsy

Narcolepsy is characterised by excessive daytime sleepiness, cataplexy, hypnagogic hallucinations and sleep paralysis. Patients frequently use alcohol and other sedatives aiming to enhance their sleep at night, and try amphetamines in the day to keep them from suddenly falling asleep. The condition is most common in the Japanese population, and the prevalence in Caucasian populations is around 5:10,000. Encouraging good sleep hygiene is the mainstay of therapy, coupled with the use of either amphetamine-related agents or modafinil.

B Rapid eye movement (REM) sleep disorder

REM sleep disorder is identified as an

Audio Video Stop Share Participants More

7:15
https://mypastest.paste

REM sleep disorder is identified as an early feature of idiopathic Parkinson's disease and patients may be seen to kick, laugh, punch or fight invisible enemies during REM sleep.

C	Restless legs syndrome

Restless legs syndrome is associated with irritability and an uncontrollable urge to move the legs at night, often associated with burning pain or discomfort. It is treated with dopamine agonists.

D	Alcohol dependency

Although patients with sleep disorders may self-medicate with alcohol, the sudden episodes of daytime sleep associated with episodes of emotion are much more consistent with narcolepsy.

Audio Video Stop Share Participants More

7:16
https://mypastest.paste

You are asked to see a 19-year-old woman who has been admitted following multiple seizures. She has had several seizures on the ward that have either terminated spontaneously after a few minutes or following the administration of intravenous lorazepam. The nurses suspect the seizures are not epileptic in origin and ask you to review the patient during her next seizure. On examination her BP is 135/72 mmHg, her pulse is 80/min and regular and BMI is 29. There are deliberate self-harm scars on both of her forearms. Neurological examination appears normal and she is not confused following the attack.

Which of the following features is most suggestive that this is a non-epileptic seizure?

A Friction burns on the legs

Audio Video Stop Share Participants More

7:16
https://mypastest.paste

There are deliberate self-harm scars on both of her forearms. Neurological examination appears normal and she is not confused following the attack.

Which of the following features is most suggestive that this is a non-epileptic seizure?

A	Friction burns on the legs
B	Resistance to eyelid opening
C	Turning the head consistently to the right
D	Lack of tongue biting
E	Absent pupillary light reflex

32703

Audio Video Stop Share Participants More

7:17
https://mypastest.paste

B Resistance to eyelid opening

Functional (or non-epileptic) seizures are common and occur in at least 10–20% of patients referred to specialist epilepsy clinics with intractable seizures. The history and description of the attacks is usually suggestive, but may not always be diagnostic of their functional nature. Non-epileptic attacks are broadly divided into: (1) hyperkinetic/thrashing attacks and (2) akinetic/motionless attacks. The 'strangeness' of an attack should in itself not imply a diagnosis of non-epileptic attack. Features that may help to distinguish functional from epileptic seizures include: asynchronous limb movements, undulating motor activity, purposeful movements, rhythmic pelvic movements, side-to-side head shaking, biting the tip of the tongue (as opposed to the side), ictal crying,

Audio Video Stop Share Participants More

7:18
https://mypastest.paste

itself not imply a diagnosis of non-epileptic attack. Features that may help to distinguish functional from epileptic seizures include: asynchronous limb movements, undulating motor activity, purposeful movements, rhythmic pelvic movements, side-to-side head shaking, biting the tip of the tongue (as opposed to the side), ictal crying, vocalisation during the 'tonic–clonic' phase, closed eyelids, resistance to eyelid opening, lack of cyanosis and rapid post-ictal reorientation. Video telemetry is the gold standard investigation for possible functional seizures. Prolactin is often elevated 15–20 min after a tonic–clonic seizure, but due to several problems with this test (may rise in syncope, may remain normal in partial seizures) it is not recommended outside specialist centres.

Audio Video Stop Share Participants More

7:19
https://mypastest.paste

A 21-year-old man has recently been diagnosed with Becker's muscular dystrophy (BMD). Appropriate genetic counselling is arranged for the patient.

What would you advise him clinically about his condition?

A	It would affect any male and female offspring of his equally
B	He is likely to suffer from heart rhythm problems as he gets older
C	Any children he has with the condition are unlikely to live into their third decade due to increased penetrance
D	Any children he has will suffer symptoms in the first few

Audio Video Stop Share Participants More

7:19
https://mypastest.paste

A It would affect any male and female offspring of his equally

B He is likely to suffer from heart rhythm problems as he gets older

C Any children he has with the condition are unlikely to live into their third decade due to increased penetrance

D Any children he has will suffer symptoms in the first few years of life

E Hypertrophy of his calf muscles and contractures over time will definitely be seen

Audio Video Stop Share Participants More

7:20
https://mypastest.paste

B He is likely to suffer from heart rhythm problems as he gets older

While cardiomyopathy is less frequent in patients with BMD than in those with Duchenne's muscular dystrophy, conduction abnormalities may dominate and even necessitate the implantation of a defibrillator. Some rhythm disturbance over time is likely.

A It would affect any male and female offspring of his equally

BMD is X-linked, and hence any male offspring of his will be free of the condition. Any female children will carry the BMD gene.

C Any children he has with the condition are unlikely to live into their third decade due to

Audio Video Stop Share Participants More

7:21
https://mypastest.paste

produce children with the condition. In fact patients with BMD may suffer only mild symptoms and have a near-normal life span.

D	Any children he has will suffer symptoms in the first few years of life

Although Duchenne's presents by age 7, BMD follows a much more variable course, with symptoms manifest at any age from 3 years to middle age.

E	Hypertrophy of his calf muscles and contractures over time will definitely be seen

Calf muscle hypertrophy and contractures are not an invariable feature of BMD compared to other forms of muscular dystrophy.

Audio Video Stop Share Participants More

7:21
https://mypastest.paste

A 28-year-old woman presents to Casualty with progressive difficulty in swallowing, which has developed over the last 6 weeks. This has become worse acutely and she has been unable to drink for the last two days. In addition to the swallowing problems, she has slurring of her speech. She reports that her symptoms seem to be worst in the evenings. She denies any arm or leg weakness; there are no sensory symptoms, no recent infections and no urinary symptoms.

On examination, her observations are within normal limits and oxygen saturations are 97% on air. She has bilateral ptosis with a complex ophthalmoplegia that is worst on up-gaze. She reports that these symptoms get worse as the day goes on. The pupillary responses are normal. The remainder of the cranial nerve examination is unremarkable, except for dysarthria. The gag reflex is

Audio Video Stop Share Participants More

7:25
https://mypastest.paste

examination is unremarkable, except for dysarthria. The gag reflex is preserved. Limb examination reveals normal tone, power, preserved reflexes and normal sensory responses.

What would be the most useful investigation in confirming the diagnosis in this case?

A	CSF analysis for oligoclonal bands
B	CSF for elevated protein level
C	Nerve conduction studies
D	Single-fibre electromyography
E	1% edrophonium chloride 'Tensilon® test'

Audio Video Stop Share Participants More

7:26
https://mypastest.paste

D Single-fibre electromyography

The most likely diagnosis in this case is myasthenia gravis, and the patient has a typical history for this. The lack of sensory or peripheral signs, along with preserved reflexes and the more prolonged time course of symptoms, makes Guillain–Barré syndrome (GBS) (or its cranial nerve variant, Miller Fisher syndrome) unlikely. Myasthenia gravis is diagnosed by completing an assay for anti-acetylcholine receptor antibodies, electromyography (repetitive nerve stimulation and single-fibre EMG) and the so-called 'Tensilon® test'.

Remember that MG is associated in some cases with thymoma and, for this reason, chest imaging is indicated to look for this lesion. However, this in itself is clearly not a diagnostic test. Although she has predominantly

Audio Video Stop Share Participants More

7:27
https://mypastest.paste

Although she has predominantly bulbar symptoms, she is very likely to have widespread subclinical involvement of other muscle groups, which should therefore be diagnostically useful if tested with EMG.

The condition is treated with acetyl cholinesterase inhibitors (pyridostigmine, neostigmine) and immunomodulators (steroids and azathioprine). Plasmapheresis and intravenous immunoglobulin infusions (IVIG) are also used. Thymectomy may be carried out and can improve symptoms and prognosis. Given the rare nature of this condition there are only a few randomised controlled studies, but they do support thymectomy as a treatment option.

Regular spirometry is essential in the context of acute myasthenic deterioration in order to detect incipient respiratory failure early and

Audio Video Stop Share Participants More

7:27
https://mypastest.paste

deterioration in order to detect incipient respiratory failure early and take action accordingly. However, it is not diagnostic of the cause of the failure.

A	CSF analysis for oligoclonal bands

This investigation would not help make a diagnosis of myasthenia gravis. Oligoclonal bands are seen in the CSF of some patients affected with multiple sclerosis, and this test is useful in the diagnosis of this condition. The symptoms and signs described in the case are not in keeping with multiple sclerosis.

B	CSF for elevated protein level

This investigation would not help make a diagnosis of myasthenia gravis. It

Audio Video Stop Share Participants More

7:27
https://mypastest.paste

may be useful in the diagnosis of Guillain–Barré syndrome (GBS). The lack of sensory or peripheral signs, along with preserved reflexes and the more prolonged time course of symptoms in this case, makes GBS (or its cranial nerve variant, Miller Fisher syndrome) unlikely. It should be remembered, however, that the presentation of GBS is variable and can be almost pure motor and quite limited in its extent in some cases.

C	Nerve conduction studies

This investigation is not the most useful test in the diagnosis of myasthenia gravis. As there is no abnormality of the nerves themselves in myasthenia, nerve conduction is often normal. Specific testing with repetitive nerve stimulation and preferably single-fibre EMG is needed.

Audio Video Stop Share Participants More

7:27
https://mypastest.paste

E	1% edrophonium chloride 'Tensilon® test'

Although this investigation would help make the diagnosis of myasthenia gravis, it is difficult to administer effectively and carries the risk of precipitating cardiac arrhythmias. For these reasons, its use has become much less common. This test is most useful in the presence of clear objective clinical signs, ideally those that can be quantified or video-recorded in order to prove response (e.g. eyelid droop, which can be measured in terms of height of palpebral opening). Measuring improvement in bulbar function would be practically difficult unless the clinical improvement was dramatic, which is relatively rarely the case with a Tensilon test.

32707

Audio Video Stop Share Participants More

7:27
https://mypastest.paste

A 66-year-old man is seen in the Emergency Department with a history of increasing confusion. His wife reports that since he retired two years ago, he had become increasingly apathetic and had lost interest in activities. He had worked as a local councillor for years, and his wife thought that he might have become depressed since his retirement.

She had taken him to see his general practitioner (GP) who started him on fluoxetine. However, he started becoming more forgetful, with his wife having to take over management of their finances. His wife also reports that his mobility had been gradually deteriorating, and she had eventually bought him a Zimmer frame, but he could no longer use this properly. For the past few weeks, his clothes would be frequently soaked with urine.

What treatment should be considered

Audio Video Stop Share Participants More

7:27
https://mypastest.paste

that his mobility had been gradually deteriorating, and she had eventually bought him a Zimmer frame, but he could no longer use this properly. For the past few weeks, his clothes would be frequently soaked with urine.

What treatment should be considered for this patient?

A	Trimethoprim
B	Trial of levodopa
C	Thiamine
D	Ventriculoperitoneal shunt
E	Donepezil (Aricept)

Audio Video Stop Share Participants More

7:31
https://mypastest.paste

thought that he might have become depressed since his retirement.

She had taken him to see his general practitioner (GP) who started him on fluoxetine. However, he started becoming more forgetful, with his wife having to take over management of their finances. His wife also reports that his mobility had been gradually deteriorating, and she had eventually bought him a Zimmer frame, but he could no longer use this properly. For the past few weeks, his clothes would be frequently soaked with urine.

What treatment should be considered for this patient?

Your answer was correct

A Trimethoprim

B Trial of levodopa

Audio Video Stop Share Participants More

7:31
https://mypastest.paste

D Ventriculoperitoneal shunt

This patient has normal pressure hydrocephalus (NPH) as evidenced by the triad of gait apraxia, cognitive impairment and urinary incontinence. The usual sequence is of gait disturbance, followed by cognitive decline, and then urinary incontinence.

Diagnosis is by computed tomography (CT) of the brain which demonstrates enlarged ventricles in the presence of normal sulci (i.e. without significant superficial cortical atrophy).

Ventriculoperitoneal shunt is correct as patients with NPH may experience improvement in symptoms with drainage of excess cerebrospinal fluid. Predicting response to shunting requires a large-volume lumbar puncture: neuropsychological testing and timed walking test are performed before and after removal of 20-50 ml

Audio Video Stop Share Participants More

7:32
https://mypastest.paste

Predicting response to shunting requires a large-volume lumbar puncture: neuropsychological testing and timed walking test are performed before and after removal of 20-50 ml of CSF via lumbar puncture. There is wide variability in patient response to cerebrospinal fluid (CSF) diversion.

A	Trimethoprim

Trimethoprim is incorrect as this is used in the management of urinary tract infection and would not improve symptoms of normal pressure hydrocephalus (NPH). The existence of gait disturbance, followed by cognitive decline, and then urinary incontinence makes the diagnosis of NPH much more likely than a urinary tract infection – although this should routinely be excluded.

Audio Video Stop Share Participants More

7:32
https://mypastest.paste

A 52-year-old electrician is referred to the Outpatient Clinic complaining of pain in his feet and difficulty in walking. On more detailed questioning, he reports noticing numbness over the soles of his feet for the past 10 months. He has been troubled by a 'pins and needles' sensation and, more recently, burning pains in both his feet. He also reports that his legs 'seem weaker' and that his walking has become increasingly unsteady such that he has recently given up work.

He takes no regular prescription medications, although he has been purchasing increasing quantities of painkillers from the supermarket for symptom relief. He has smoked 20 cigarettes a day for the past 35 years and admits to spending more time in the pub since giving up work.

Examination reveals symmetrical distal sensory loss in the lower limbs. Ankle reflexes are absent even with

Audio Video Stop Share Participants More

7:34
https://mypastest.paste

Examination reveals symmetrical distal sensory loss in the lower limbs. Ankle reflexes are absent even with reinforcement. There is no significant postural drop in his blood pressure.

Investigations:

Haemoglobin (Hb)	11.8 g/dl
White cell count (WCC)	6.4×10^9/l
Haematocrit (Hct)	0.465
Mean corpuscular volume (MCV)	101.6 fl
Platelets	287×10^9/l
Sodium	137 mmol/l
Potassium	4.4 mmol/l
Urea	4.1 mmol/l
Creatinine	71 μmol/l

Audio Video Stop Share Participants More

7:34
https://mypastest.paste

Bilirubin	30 mmol/l
Alanine aminotransferase	82 U/l
Albumin	43 U/l
Alkaline phosphatase	44 U/l
Gamma-glutamyl transpeptidase	110 IU/l
Calcium	2.15 mmol/l
Thyroid-stimulating hormone	2.25 mU/l
Thyroxine (T_4)	14.5 nmol/l
B_{12}	185 ng/l
Folate	10.9 µg/l
Random glucose	7.8 mmol/l
Fasting glucose	4.2 mmol/l
Erythrocyte	8

Audio Video Stop Share Participants More

7:35
https://mypastest.paste

Erythrocyte sedimentation rate	8
C-reactive protein	4
Serum protein electrophoresis	Normal
Rheumatoid factor	Negative
Random cholesterol	8
Chest X-ray	Unremarkable

Which one of the following is the most appropriate next course of action?

A Magnetic resonance imaging of the thoraco-lumbar spine

B Obtaining an accurate history of alcohol intake and recommending a detox programme

Audio Video Stop Share Participants More

7:35
https://mypastest.paste

Which one of the following is the most appropriate next course of action?

A	Magnetic resonance imaging of the thoraco-lumbar spine
B	Obtaining an accurate history of alcohol intake and recommending a detox programme
C	Oral supplementation of all B vitamins
D	Recommending cessation of all non-prescription analgesia and initiating a trial of amitriptyline
E	Sural nerve biopsy

Audio Video Stop Share Participants More

7:37
https://mypastest.paste

B Obtaining an accurate history of alcohol intake and recommending a detox programme

This case highlights alcoholic neuropathy. Sensory symptoms, which are usually distal and symmetrical, include early numbness, followed by dysaesthesias, particularly at night. Progression to severe pain that is described as burning or lancinating may occur. Motor manifestations tend to be mild. Autonomic disturbances are less common than in other neuropathies. The diagnosis is based on an accurate history of prolonged and excessive alcohol intake, clinical signs and symptoms, and electrophysiological testing. Management is directed at limiting degeneration of peripheral nerves and promoting restoration of normal function, primarily through abstinence

Audio Video Stop Share Participants More

7:39
https://mypastest.paste

function, primarily through abstinence of alcohol. Nutritional support via a balanced diet and B vitamin supplementation are adjuncts to therapy, along with active rehabilitation. The prognosis of alcoholic neuropathy is generally good, provided that alcohol intake is discontinued and other causes of neuropathy (such as malignancy and diabetes) are carefully excluded. Clinical and electrophysiological examinations are reported to improve, independent of age.

C	Oral supplementation of all B vitamins

It would be important to give vitamin B supplementation in conjunction with rehab therapy. However, it would first be important to establish diagnosis by an accurate history.

Audio Video Stop Share Participants More

7:40
https://mypastest.paste

A 25-year-old man presented to the Outpatient Clinic with a history of intermittent headaches for the last 5 months. These occur up to three times per day and last 30–50 min each time. He described two periods during these 5 months, one lasting 4 weeks and the other lasting 6 weeks, when the headaches occurred and that he had been headache free in between these times. He described experiencing severe right-sided pain behind the eye and he often noticed that the right eye became red and teary.

On examination, his BP is 122/72 mmHg, pulse is 70 bpm and regular and his BMI is 21. Physical examination, including full neurological exam, is entirely normal.

Which one of the following drugs is likely to be most effective in preventing further headaches?

Audio Video Stop Share Participants More

7:41
https://mypastest.paste

became red and teary.

On examination, his BP is 122/72 mmHg, pulse is 70 bpm and regular and his BMI is 21. Physical examination, including full neurological exam, is entirely normal.

Which one of the following drugs is likely to be most effective in preventing further headaches?

A	Sumatriptan
B	Propranolol
C	Indomethacin
D	Enalapril
E	Verapamil

Audio Video Stop Share Participants More

7:42
https://mypastest.paste

E Verapamil

The most likely diagnosis in this case is cluster headache, as supported by the description of severe, unilateral, periorbital headache associated with the autonomic feature of eye watering. Cluster headaches also characteristically last 15–180 min and occur 1–8 times per day in clusters lasting between 7 and 365 days, with intervening periods of at least 4 weeks where there are no headaches. Men are more commonly affected by cluster headaches than women. Autonomic features that may be experienced in association with these headaches include: conjunctival injection, lacrimation, nasal congestion, rhinorrhoea, sweating, miosis, ptosis and eyelid oedema. High-flow oxygen and triptans may be useful in terminating an acute attack but verapamil is the first-line option for

Audio Video Stop Share Participants More

7:42
https://mypastest.paste

and triptans may be useful in terminating an acute attack but verapamil is the first-line option for prophylaxis of cluster headaches, which is why it is the correct answer in this case.

A Sumatriptan

While this medication is useful in the termination of an acute attack of cluster headache, it does not act to prevent future attacks. Sumatriptan can also be used to terminate headache due to migraine in an acute attack.

B Propranolol

This medication is not useful in the prophylaxis of cluster headache. Propranolol may be used as a first-line option in the prophylaxis of migraine.

Audio Video Stop Share Participants More

7:42
https://mypastest.paste

A 36-year-old painter and decorator presents with sudden-onset back pain. He was sitting on the floor painting a fence when he realised after some time that he was unable to get up.

On examination, he has bilateral leg weakness with lower limb hyporeflexia. He has pinprick sensory loss to the level of the umbilicus. Vibration sense is mildly impaired at the ankles and clearly present at the knee. He is in urinary retention.

Past medical history of note includes hypertension, for which he takes ramipril 10 mg daily.

Which of the following represents the most likely diagnosis?

A	Anterior spinal cord syndrome
B	Cervical cord compression

Audio Video Stop Share Participants More

7:42
https://mypastest.paste

clearly present at the knee. He is in urinary retention.

Past medical history of note includes hypertension, for which he takes ramipril 10 mg daily.

Which of the following represents the most likely diagnosis?

A	Anterior spinal cord syndrome
B	Cervical cord compression
C	Transverse myelitis
D	Guillain–Barré syndrome
E	Miller Fisher syndrome

20530

Audio Video Stop Share Participants More

7:46
https://mypastest.paste

A 36-year-old painter and decorator presents with sudden-onset back pain. He was sitting on the floor painting a fence when he realised after some time that he was unable to get up.

On examination, he has bilateral leg weakness with lower limb hyporeflexia. He has pinprick sensory loss to the level of the umbilicus. Vibration sense is mildly impaired at the ankles and clearly present at the knee. He is in urinary retention.

Past medical history of note includes hypertension, for which he takes ramipril 10 mg daily.

Which of the following represents the most likely diagnosis?

Your answer was correct

Audio Video Stop Share Participants More

7:46
https://mypastest.paste

A Anterior spinal cord syndrome

This artery supplies the anterior two-thirds of the spinal cord. Symptoms occur because there is complete motor paralysis below the level of the lesion due to interruption of the corticospinal tract. There is loss of pain sensation below the level of the lesion due to interruption of the spinothalamic tract. There is, however, relatively good preservation of vibration sense due to intact dorsal column function.

B Cervical cord compression

Cervical cord compression is essentially ruled out because of the sensory level at the umbilicus.

C Transverse myelitis

Audio Video Stop Share Participants More

7:47
https://mypastest.paste

C Transverse myelitis

This occurs against a background of inflammatory disease (i.e. multiple sclerosis) or due to infection. The very sudden onset in this case favours an acute vascular cause.

D Guillain–Barré syndrome

This usually presents with ascending weakness beginning in the lower limbs, with sensory loss and neuropathic pain. Onset is usually approximately 3 weeks after a viral illness.

E Miller Fisher syndrome

This condition typically leads to a triad of weakness of the eye muscles, abnormalities of coordination and absent reflexes. It is a variant of Guillain–Barré syndrome.

Audio Video Stop Share Participants More

7:47
https://mypastest.paste

A 45-year old woman presented with 4-month history of an erythematous rash over her cheeks, her anterior upper chest and the backs of her hands. Over the same period she had become short of breath on exertion. In the last month, she had also complained of difficulty walking up the stairs at home.

General examination revealed a rash as noted above and dilated capillaries at the base of some of the fingernails.

On examination of the chest, there were a few bibasal crepitations. Neurological examination revealed mild weakness of hip flexion but it was an otherwise normal exam.

What is the most likely diagnosis?

A	Dermatomyositis
B	Eosinophilic granulomatosis

Audio Video Stop Share Participants More

7:48
https://mypastest.paste

the base of some of the fingernails.

On examination of the chest, there were a few bibasal crepitations. Neurological examination revealed mild weakness of hip flexion but it was an otherwise normal exam.

What is the most likely diagnosis?

A	Dermatomyositis
B	Eosinophilic granulomatosis with polyangiitis (E-GPA)
C	Rheumatoid arthritis (RA)
D	Acute intermittent porphyria (AIP)
E	Systemic lupus erythematosus

Audio Video Stop Share Participants More

7:49
https://mypastest.paste

A 45-year old woman presented with 4-month history of an erythematous rash over her cheeks, her anterior upper chest and the backs of her hands. Over the same period she had become short of breath on exertion. In the last month, she had also complained of difficulty walking up the stairs at home.

General examination revealed a rash as noted above and dilated capillaries at the base of some of the fingernails.

On examination of the chest, there were a few bibasal crepitations. Neurological examination revealed mild weakness of hip flexion but it was an otherwise normal exam.

What is the most likely diagnosis?

Your answer was correct

Audio Video Stop Share Participants More

7:49
https://mypastest.paste

A Dermatomyositis

This patient has a rash which is typical for dermatomyositis. The rash over the chest probably represents the 'V-sign' and the rash on the back of the hands is likely to be Gottron's papules. Proximal weakness is manifest as difficulty walking upstairs. The shortness of breath and bi-basal crepitation are likely to represent complicating interstitial lung disease.

B Eosinophilic granulomatosis with polyangiitis (E-GPA)

E-GPA is a systemic vasculitis of small vessels and is associated with p-ANCA. It usually occurs in persons with a history of airway allergic hypersensitivity. Eosinophilia occurs in association with systemic features such as weight loss and night sweats. Vasculitis, particularly of the peritoneal

Audio Video Stop Share Participants More

7:49
https://mypastest.paste

such as weight loss and night sweats. Vasculitis, particularly of the peritoneal vasculature, usually occurs in the final stages of evolution of the illness.

C	Rheumatoid arthritis (RA)

This case description is not at all typical of RA, which is primarily an inflammatory disease of the joints. Skin manifestations can occur occasionally in RA, including nodules, pyoderma gangrenosum, erythema nodosum and palmar erythema. Pulmonary fibrosis can also occur as a complication of RA. However, the lack of joint involvement in this case makes RA extremely unlikely.

D	Acute intermittent porphyria (AIP)

This case description is not at all

Audio Video Stop Share Participants More

7:49
https://mypastest.paste

This case description is not at all typical for AIP, in which the most common manifestations are abdominal pain and psychiatric disturbances.

E	Systemic lupus erythematosus

Patients with systemic lupus erythematosus (SLE) can have a rash similar to that seen in dermatomyositis. The rash in SLE is photosensitive and most commonly seen in sun-exposed areas – the cheeks (i.e. a malar distribution), upper anterior and posterior chest and over the backs of the hands. Whilst not really described clearly in this case, a heliotrope (i.e. peri-orbital ring) rash, rather than a malar rash, is more typical of dermatomyositis. Despite the potential similarity of the rash, dermatomyositis is a more likely answer in this case because of the co-existing muscle

Audio Video Stop Share Participants More

7:50
https://mypastest.paste

A 19-year-old secretary presents with a 1-year history of progressive slowness of walking and tremor in his arms. He was sacked from his job after his line manager complained of an increasing number of mistakes at work, a general lack of motivation and irritable nature. In his family history, his mother is alive and well, his father committed suicide in his early forties and he has one younger sister who is alive and well.

On examination, he is noted to be in an unkempt state with decreased facial expression. His Mini-Mental State Examination score was 22 out of 30. Eye examination was normal. Tone was increased in the limbs, with decreased speed and amplitude of repetitive fine finger movements. An action tremor was also noted.

Which one of the following tests is most likely to establish the diagnosis in this case?

Audio Video Stop Share Participants More

7:51
https://mypastest.paste

Which one of the following tests is most likely to establish the diagnosis in this case?

A	Levodopa challenge test
B	Free serum copper, total serum copper and serum caeruloplasmin
C	Molecular genetic analysis for CAG repeats in Huntingtin gene
D	Molecular genetic analysis in the gene coding for superoxide dismutase 1
E	Molecular genetic analysis to identify a mutation in the gene coding for dystrophin

Audio Video Stop Share Participants More

7:52
https://mypastest.paste

C Molecular genetic analysis for CAG repeats in Huntingtin gene

This patient presents with the Westphal variant of Huntington's disease (HD), which manifests as presentation in youth with associated parkinsonian symptoms. The family history of suicide is of relevance and may be associated with behavioural features of the disease or retained insight during emergence of neurological symptoms. HD is inherited in an autosomal dominant pattern with complete penetrance. The gene for HD is on the short arm of chromosome 4, which contains CAG repeats (coding for glutamine). Healthy subjects have 11–34 repeats, while patients with HD have more than 40. Paternal inheritance is associated with anticipation (increasingly earlier age of onset in subsequent generations).

Audio Video Stop Share Participants More

7:54
https://mypastest.paste

A levodopa challenge test is occasionally used in the diagnosis of Parkinsons' disease.

B	Free serum copper, total serum copper and serum caeruloplasmin

This test is used for confirmation of Wilson's disease. Wilson's disease is a genetic disorder with autosomal recessive inheritance in which copper builds up in the body. Keyser–Fleischer rings are seen in the eyes of those affected neurologically.

D	Molecular genetic analysis in the gene coding for superoxide dismutase 1

Superoxide dismutase (Cu-Zn), also known as superoxide dismutase 1 or SOD1, is an enzyme that in humans is

Audio Video Stop Share Participants More

7:55
https://mypastest.paste

Superoxide dismutase (Cu-Zn), also known as superoxide dismutase 1 or SOD1, is an enzyme that in humans is encoded by the SOD1 gene, located on chromosome 21. SOD1 is one of three human superoxide dismutases. It is implicated in apoptosis and amyotrophic lateral sclerosis.

E	Molecular genetic analysis to identify a mutation in the gene coding for dystrophin

Dystrophin deficiency has been definitively established as one of the root causes of the general class of myopathies collectively referred to as muscular dystrophy.

Muscular dystrophy (MD) is a group of muscle diseases that results in increasing weakening and breakdown of skeletal muscles over time. The disorders differ in which muscles are

Audio Video Stop Share Participants More

7:55
https://mypastest.paste

Muscular dystrophy (MD) is a group of muscle diseases that results in increasing weakening and breakdown of skeletal muscles over time. The disorders differ in which muscles are primarily affected, the degree of weakness, how fast they worsen and when symptoms begin. Many people will eventually become unable to walk. Some types are also associated with problems in other organs.

This patient presents with the Westphal variant of Huntington's disease (HD) which manifests as presentation in youth with associated Parkinsonian symptoms. The family history of suicide is of relevance and may be associated with behavioural features of the disease or retained insight during emergence of neurological symptoms. HD is inherited in an autosomal dominant pattern with complete penetrance. The gene for HD is on the short arm of chromosome 4

Audio Video Stop Share Participants More

7:56
https://mypastest.paste

will eventually become unable to walk. Some types are also associated with problems in other organs.

This patient presents with the Westphal variant of Huntington's disease (HD) which manifests as presentation in youth with associated Parkinsonian symptoms. The family history of suicide is of relevance and may be associated with behavioural features of the disease or retained insight during emergence of neurological symptoms. HD is inherited in an autosomal dominant pattern with complete penetrance. The gene for HD is on the short arm of chromosome 4, which contains CAG repeats (coding for glutamine). Healthy subjects have 11–34 repeats, while patients with HD have more than 40. Paternal inheritance is associated with anticipation (increasingly earlier age of onset in subsequent generations).

Audio Video Stop Share Participants More

7:56
https://mypastest.paste

A 40-year-old Egyptian man patient is under neurosurgical follow-up after MRI performed for headache revealed a deep-seated aneurysm in the left thalamic area. He is considering proton beam radiotherapy as a potential option.

He had planned to fly to Cairo, but at the airport he was becoming progressively drowsy and disoriented and so was brought back to the hospital where a neurologist was asked to evaluate him. His wife gave further details. He had had a recent attack of unilateral red eye for which he was given steroids by an eye doctor. She also knew that her husband had received prolonged treatment for his swollen left leg 3 years ago while in Egypt. He had, however, recurrent pain in his mouth and was attending the dentist regularly.

On examination, he was stuporous with

Audio Video Stop Share Participants More

7:57
https://mypastest.paste

On examination, he was stuporous with open eyes to painful stimuli – he was localising pain with both hands. A grade 4 papilloedema was found on both sides and bilateral lateral rectus palsies were seen. Lower limbs were spastic and severely weak (1/5). Plantars were extensor on both sides. An urgent MR venogram demonstrates a superior sagittal sinus thrombosis.

What is the most likely underlying cause of his presentation?

A	Traumatic brain injury
B	Sickle cell disease
C	Anti-thrombin III deficiency
D	Behçet's disease

Audio Video Stop Share Participants More

7:57
https://mypastest.paste

grade 4 papilloedema was found on both sides and bilateral lateral rectus palsies were seen. Lower limbs were spastic and severely weak (1/5). Plantars were extensor on both sides. An urgent MR venogram demonstrates a superior sagittal sinus thrombosis.

What is the most likely underlying cause of his presentation?

A	Traumatic brain injury
B	Sickle cell disease
C	Anti-thrombin III deficiency
D	Behçet's disease
E	Paroxysmal nocturnal haemoglobinuria

Audio Video Stop Share Participants More

7:58
https://mypastest.paste

and so was brought back to the hospital where a neurologist was asked to evaluate him. His wife gave further details. He had had a recent attack of unilateral red eye for which he was given steroids by an eye doctor. She also knew that her husband had received prolonged treatment for his swollen left leg 3 years ago while in Egypt. He had, however, recurrent pain in his mouth and was attending the dentist regularly.

On examination, he was stuporous with open eyes to painful stimuli – he was localising pain with both hands. A grade 4 papilloedema was found on both sides and bilateral lateral rectus palsies were seen. Lower limbs were spastic and severely weak (1/5). Plantars were extensor on both sides. An urgent MR venogram demonstrates a superior sagittal sinus thrombosis.

What is the most likely underlying cause of his presentation?

Audio Video Stop Share Participants More

7:58
https://mypastest.paste

D Behçet's disease

Behçet's disease is the most likely diagnosis, as the anterior uveitis, mucosal ulceration, deep vein thrombosis and aneurysm formation all support it. Corticosteroids are the mainstay of immunotherapy, with the addition of cyclophosphamide, methotrexate, colchicine or azothioprine all reasonable second-line options. Where aneurysm formation has occurred or there is a significant thrombotic episode, then cyclophosphamide becomes the second line agent of choice. Mortality from Behçet's is usually low, but neurological involvement is associated with a poor prognosis, as is male sex.

A Traumatic brain injury

This is very unlikely as the cause of his

Audio Video Stop Share Participants More

7:59
https://mypastest.paste

This is very unlikely as the cause of his symptoms given the lack of significant injury. The signs of raised intracranial pressure are entirely consistent with a venous sinus thrombosis.

B	Sickle cell disease

Sickle cell disease isn't associated with increased risk of aneurysm and wouldn't lead to first presentation at age 40. It may, however, be associated with increased risk of thrombosis.

C	Anti-thrombin III deficiency

Although anti-thrombin III deficiency is associated with increased risk of thrombosis, it wouldn't fit with other features here including uveitis and aneurysm formation.

Audio Video Stop Share Participants More

8:00
https://mypastest.paste

A 56-year-old man attends the movement disorder clinic with his wife. He reports disabling tremor in his arms. He is unsure of the duration of symptoms, but believes he has had tremor for 'years'. He recalls that his father had a similar tremor.

Over the last year, the tremor has worsened, such that he is now unable to hold a cup without spilling. He is on no regular medication, is a non-smoker and does not take alcohol.

On examination, he is euthyroid. The right and left arm show a large-amplitude action tremor that worsens throughout the consultation. There is no nystagmus and gait is normal.

Choose the most appropriate initial management.

A Propranolol

Audio Video Stop Share Participants More

8:00
https://mypastest.paste

On examination, he is euthyroid. The right and left arm show a large-amplitude action tremor that worsens throughout the consultation. There is no nystagmus and gait is normal.

Choose the most appropriate initial management.

A	Propranolol
B	Dopamine agonist
C	Reassurance
D	Benzodiazepine
E	L-dopa with dopa-decarboxylase inhibitor

Audio Video Stop Share Participants More

8:01
https://mypastest.paste

He reports disabling tremor in his arms. He is unsure of the duration of symptoms, but believes he has had tremor for 'years'. He recalls that his father had a similar tremor.

Over the last year, the tremor has worsened, such that he is now unable to hold a cup without spilling. He is on no regular medication, is a non-smoker and does not take alcohol.

On examination, he is euthyroid. The right and left arm show a large-amplitude action tremor that worsens throughout the consultation. There is no nystagmus and gait is normal.

Choose the most appropriate initial management.

Your answer was correct

A Propranolol

Audio Video Stop Share Participants More

8:02
https://mypastest.paste

The clinical history is one of essential tremor. This is one of the most common movement disorders, with estimated prevalence of between 0.4% and 4% of the population. Symptoms are chronic, persistent and often progressive. A positive family history is common. Exacerbation by anxiety and relief with alcohol are classical. There are few good-quality randomised controlled trials of therapy in this condition. Propranolol has been shown to improve tremor in the short term; it is unclear whether other beta-blockers have the same effect.

B	Dopamine agonist

This is a treatment for Parkinson's disease, but there are no features of that condition here. In Parkinson's the tremor is usually asymmetric and worse at rest.

Audio Video Stop Share Participants More

8:02
https://mypastest.paste

A 62-year-old man presented with a progressive worsening of memory over a 3-month period since arriving back from a summer holiday in Australia. His wife said that he had initially put this down to the fact he had been having difficulties sleeping while on holiday and his concentration had suffered. However, he now had difficulty remembering what day it was or where he was. His past history included recent depression and also stable angina, hypertension and asthma.

On examination he had severe cognitive impairment but cranial nerve and limb examination appeared, normal apart from occasional jerky movements of the hands and a somewhat ataxic gait. Magnetic resonance imaging (MRI) of the brain revealed signal changes in the putamen and head of the caudate.

Which further investigation would

Audio Video Stop Share Participants More

8:03
https://mypastest.paste

and limb examination appeared, normal apart from occasional jerky movements of the hands and a somewhat ataxic gait. Magnetic resonance imaging (MRI) of the brain revealed signal changes in the putamen and head of the caudate.

Which further investigation would help support the diagnosis?

A	Electroencephalography
B	Genetic testing
C	Serum antinuclear antibodies
D	Serum syphilis serology
E	Serum vitamin B_{12}

71066
Audio Video Stop Share Participants More

8:04
https://mypastest.paste

However, he now had difficulty remembering what day it was or where he was. His past history included recent depression and also stable angina, hypertension and asthma.

On examination he had severe cognitive impairment but cranial nerve and limb examination appeared, normal apart from occasional jerky movements of the hands and a somewhat ataxic gait. Magnetic resonance imaging (MRI) of the brain revealed signal changes in the putamen and head of the caudate.

Which further investigation would help support the diagnosis?

Your answer was correct

A Electroencephalography

B Genetic testing

Audio Video Stop Share Participants More

8:04
https://mypastest.paste

A Electroencephalography

The most likely diagnosis is sporadic Creutzfeldt–Jakob disease (sCJD). He has rapidly progressive cognitive impairment with prodromal insomnia and depression. Myoclonus is often a prominent feature and other features include seizures, cerebellar signs, extrapyramidal signs and cortical blindness. Electroencephalography (EEG) may reveal characteristic bi- or triphasic periodic complexes superimposed on a slow background rhythm. Cerebrospinal fluid (CSF) examination may reveal a positive 14-3-3 protein (which is a marker of rapid neuronal destruction), and the newly developed RTQuIC test can also be performed – this helps support the diagnosis and is the other investigation which should be considered. Magnetic resonance imaging (MRI) of the brain may show signal changes in the

Audio Video Stop Share Participants More

8:05
https://mypastest.paste

resonance imaging (MRI) of the brain may show signal changes in the putamen, head of the caudate and cortex, in comparison to the findings in variant CJD in which increased signal in the pulvinar may be seen.

B	Genetic testing

Genetic testing would be normal in sporadic Creutzfeldt–Jakob disease. Inherited prion diseases do occur due to mutations in the PRNP gene, but are rarer disorders than sporadic CJD.

C	Serum antinuclear antibodies

Serum antinuclear antibodies would be normal in Creutzfeldt–Jakob disease. Anti-nuclear antibodies are elevated in autoimmune conditions such as systemic lupus erythematosus.

Audio Video Stop Share Participants More

impairment with prodromal insomnia and depression. Myoclonus is often a prominent feature and other features include seizures, cerebellar signs, extrapyramidal signs and cortical blindness. Electroencephalography (EEG) may reveal characteristic bi- or triphasic periodic complexes superimposed on a slow background rhythm. Cerebrospinal fluid (CSF) examination may reveal a positive 14-3-3 protein (which is a marker of rapid neuronal destruction), and the newly developed RTQuIC test can also be performed – this helps support the diagnosis and is the other investigation which should be considered. Magnetic resonance imaging (MRI) of the brain may show signal changes in the putamen, head of the caudate and cortex, in comparison to the findings in variant CJD in which increased signal in the pulvinar may be seen.

B Genetic testing

Spotlight Pen Highligh... Color Erase Clear

8:07
https://mypastest.paste

Serum antinuclear antibodies would be normal in Creutzfeldt–Jakob disease. Anti-nuclear antibodies are elevated in autoimmune conditions such as systemic lupus erythematosus.

D	Serum syphilis serology

Neurosyphilis may produce neurological symptoms such as abnormal gait, blindness, confusion, sudden personality changes and dementia. In this case the MRI already strongly suggests sCJD.

E	Serum vitamin B_{12}

Vitamin B_{12} deficiency causes subacute combined degeneration of the cord and a peripheral neuropathy. It can also cause optic atrophy and cognitive impairment.

Audio Video Stop Share Participants More

8:07
https://mypastest.paste

A 23-year-old secretary in a law firm presents with a 1-day history of left-sided facial weakness. She first noticed this when she was putting her make-up on in the morning. She has noticed increased sensitivity to noise in her left ear. She is very anxious because, 2 years ago, she had some problems with her vision and was told that multiple sclerosis was a possibility. At this time, she declined further investigation when it was offered. She has no medical history of note and is taking only the combined oral contraceptive pill.

On examination, she has a lower motor neurone-pattern left facial weakness with Bell's phenomenon and some difficulty closing her left eye. There is no objective hearing loss and no sensory signs. Examination of the auditory meatus and canal is unremarkable. The remainder of the neurological examination is normal

Audio Video Stop Share Participants More

8:08
https://mypastest.paste

unremarkable. The remainder of the neurological examination is normal, besides some subjective numbness over the dorsum of her right foot.

She has already started artificial tears and an appointment has been made for the Eye Clinic.

What is the most appropriate next management step in her care?

A	Urgent computed tomography (CT) brain
B	Watch and wait policy
C	Cerebral MRI
D	Start oral prednisolone
E	Start oral aciclovir

Audio Video Stop Share Participants More

8:10
https://mypastest.paste

years ago, she had some problems with her vision and was told that multiple sclerosis was a possibility. At this time, she declined further investigation when it was offered. She has no medical history of note and is taking only the combined oral contraceptive pill.

On examination, she has a lower motor neurone-pattern left facial weakness with Bell's phenomenon and some difficulty closing her left eye. There is no objective hearing loss and no sensory signs. Examination of the auditory meatus and canal is unremarkable. The remainder of the neurological examination is normal, besides some subjective numbness over the dorsum of her right foot.

She has already started artificial tears and an appointment has been made for the Eye Clinic.

What is the most appropriate next

Audio Video Stop Share Participants More

8:10
https://mypastest.paste

D Start oral prednisolone

This young woman has a unilateral acute-onset hemi-facial weakness. The most common cause of this is Bell's palsy. Steroids given early in the course of the disease have been shown to improve outcomes.

There is no evidence in the history or examination to suggest involvement of any other cranial nerves, which might raise the possibility of a space-occupying lesion or demyelinating, vasculitic or infiltrative processes.

Optimal management of a suspected case of Bell's palsy has been traditionally controversial. Most results from systematic reviews of steroids and antivirals have been conflicting. However an adequately powered randomised controlled trial conducted in Scotland, of early (<72 h after symptom onset) treatment by oral

Audio Video Stop Share Participants More

8:11
https://mypastest.paste

However an adequately powered randomised controlled trial conducted in Scotland, of early (<72 h after symptom onset) treatment by oral prednisolone, oral aciclovir or both was published in 2007 (Sullivan et al., *NEJM* 2007; Vol 357:1598-1607). This study found a significant effect of steroids but not aciclovir in 3- and 9-month assessment of facial muscle recovery. No adverse effects occurred.

A	Urgent computed tomography (CT) brain

CT brain is a test for a quick look at intracranial structures, to exclude mass lesions or haemorrhage. There is no suggestion of other cranial neuropathies or limb weakness, making a large lesion or haemorrhage unlikely, thus making a CT brain unjustifiable in this situation.

Audio Video Stop Share Participants More

8:11
https://mypastest.paste

This patient has a Bell's palsy and there is evidence to suggest that treating with oral steroids gives better outcomes than not treating.

C	Cerebral MRI

Cerebral MRI, in addition to detecting mass lesions and strokes, can also detect demyelination and infiltration (sarcoidosis). However, such processes would have a more widespread effect, involving other cranial nerves or the limbs, which is not the case here. Importantly, her facial weakness is of a lower motor neuron pattern, and therefore we are unlikely to see a lesion in the motor cortex or cerebral white matter, which would cause an UMN pattern of facial weakness with forehead sparing. Therefore, a cerebral MRI cannot be justified at this stage but may be done on a non-urgent basis by a neurologist.

Audio Video Stop Share Participants More

8:12
https://mypastest.paste

A 32-year-old woman is admitted to the Emergency Department having had several generalised tonic-clonic seizures at home. In the preceding 24 h, she had been complaining of a severe generalised headache and had been vomiting extensively.

She had recently returned from a trekking holiday in the Andes, and while there had suffered a bout of viral gastroenteritis. Otherwise, she has no known medical history. Her regular medication is the oral contraceptive pill, and she is still completing a course of malaria prophylaxis for her holiday.

On examination, she is postictal and drowsy with a Glasgow coma score of 13/15. Her temperature was 37.2 °C; blood pressure is 115/70 mmHg and pulse 92/min, and mucous membranes are dry. There is no evidence of a rash; however, non-infected insect bites are found on both shins.

Audio Video Stop Share Participants More

8:12
https://mypastest.paste

Fundoscopy examination reveals bilateral papilloedema; however, pupillary responses are intact. Cranial nerve examination reveals left-sided facial asymmetry, but otherwise no abnormalities are noted. On peripheral nerve examination there is increased tone, and pathologically brisk reflexes are found in the left upper and lower limbs. The left plantar reflex is extensor.

She undergoes a computerised tomography (CT) scan of the brain with contrast, which shows an 'empty delta sign' and generalised cerebral oedema with no evidence of cerebral haemorrhage or abscess.

Other investigations revealed:

Hb	122 g/l
WCC	11.0×10^9/l
PLT	253×10^9/l

Audio Video Stop Share Participants More

8:12
https://mypastest.paste

Na^+	138 mmol/l
K^+	3.1 mmol/l
Creatinine	110 µmol/l
PT	11.5 s (11.5–15.5)
APTP	32 s (30–40 s)
CRP	7 mg/l (< 10 mg/l)
Blood film	Negative for malaria parasites
Urea	11.0 mmol/l

An urgent MR venogram is arranged and IV fluids are commenced.

Which of the following is the optimal way to manage this patient?

A IV quinine

B IV cefotaxime

Audio Video Stop Share Participants More

8:12
https://mypastest.paste

film	parasites
Urea	11.0 mmol/l

An urgent MR venogram is arranged and IV fluids are commenced.

Which of the following is the optimal way to manage this patient?

A	IV quinine
B	IV cefotaxime
C	S/C low-molecular weight (LMW) heparin
D	IV unfractionated heparin
E	IV dexamethasone

Audio Video Stop Share Participants More

8:16
https://mypastest.paste

the Emergency Department having had several generalised tonic-clonic seizures at home. In the preceding 24 h, she had been complaining of a severe generalised headache and had been vomiting extensively.

She had recently returned from a trekking holiday in the Andes, and while there had suffered a bout of viral gastroenteritis. Otherwise, she has no known medical history. Her regular medication is the oral contraceptive pill, and she is still completing a course of malaria prophylaxis for her holiday.

On examination, she is postictal and drowsy with a Glasgow coma score of 13/15. Her temperature was 37.2 °C; blood pressure is 115/70 mmHg and pulse 92/min, and mucous membranes are dry. There is no evidence of a rash; however, non-infected insect bites are found on both shins.

Fundoscopy examination reveals

Audio Video Stop Share Participants More

8:16
https://mypastest.paste

Fundoscopy examination reveals bilateral papilloedema; however, pupillary responses are intact. Cranial nerve examination reveals left-sided facial asymmetry, but otherwise no abnormalities are noted. On peripheral nerve examination there is increased tone, and pathologically brisk reflexes are found in the left upper and lower limbs. The left plantar reflex is extensor.

She undergoes a computerised tomography (CT) scan of the brain with contrast, which shows an 'empty delta sign' and generalised cerebral oedema with no evidence of cerebral haemorrhage or abscess.

Other investigations revealed:

Hb	122 g/l
WCC	11.0×10^9/l
PLT	253×10^9/l

Audio Video Stop Share Participants More

C S/C low-molecular weight (LMW) heparin

This patient presents with a classic history for cerebral venous thrombosis. The combination of headache, seizures, focal signs (left-sided pyramidal signs with left facial nerve involvement) and evidence of raised intracranial pressure (bilateral papilloedema) would be in keeping with this diagnosis. She also has risk factors including the oral contraceptive pill, dehydration secondary to excessive vomiting and recent viral enteritis. The 'absent delta sign' on computerised tomography (CT) scan implies a filling defect in one of the venous sinuses, although often in this condition the CT scan is normal.

The causes of cerebral venous thrombosis can be divided into septic and non-septic. Septic causes include otitis media, facial cellulitis and meningitis, and non-septic causes include pregnancy, thrombophilia and Behçet syndrome.

E IV dexamethasone

There is no evidence that corticosteroids are effective in managing cerebral oedema related to cerebral venous thrombosis.

A IV quinine

Cerebral malaria should be considered in this patient, even though she is taking prophylaxis, although one would expect a much worse consciousness level and clinical picture. The most common picture is one of symmetrical encephalopathy with no focal signs. Cranial nerve involvement is rare. In addition one might expect evidence of anaemia or disseminated intravascular coagulation on the biochemical picture. Three negative blood films are required to exclude this diagnosis.

B IV cefotaxime

Although meningitis and viral

one of symmetrical encephalopathy with no focal signs. Cranial nerve involvement is rare. In addition one might expect evidence of anaemia or disseminated intravascular coagulation on the biochemical picture. Three negative blood films are required to exclude this diagnosis.

B	IV cefotaxime

Although meningitis and viral encephalitis cannot be excluded in this patient, the focal signs and lack of immune activation fit better with cerebral venous thrombosis.

D	IV unfractionated heparin

Small studies suggest a marginal benefit for LMW heparin over unfractionated in this situation.

32745

Rate this question:

Next Question

3:53
https://mypastest.paste

A 25-year-old man and his 20-year-old fiancée were travelling on a motorbike that skidded, throwing both of them off it. The man was flung onto the road and his left shoulder was locked. They are brought to the Emergency Department where they are reviewed by the orthopaedic SHO.

A dislocated left shoulder is diagnosed and reduced under sedation. There are no other injuries identified and he is discharged with analgesia. He presents 3 days later with inability to abduct the arm.

On examination, there is only 2/5 power in the shoulder, and between 15 ° and 90 ° degrees of abduction. Sensation is impaired over the outer aspect of the shoulder. The remainder of the neurological examination is normal.

What is the most likely neuroanatomical localisation of the

Audio Video Stop Share Participants More

3:54
https://mypastest.paste

power in the shoulder, and between 15 ° and 90 ° degrees of abduction. Sensation is impaired over the outer aspect of the shoulder. The remainder of the neurological examination is normal.

What is the most likely neuroanatomical localisation of the lesion?

A	C5–7 radiculopathy
B	Long thoracic nerve injury
C	Musculocutaneous nerve injury
D	Axillary nerve injury
E	Suprascapular nerve injury

Audio Video Stop Share Participants More

3:55
https://mypastest.paste

Department where they are reviewed by the orthopaedic SHO.

A dislocated left shoulder is diagnosed and reduced under sedation. There are no other injuries identified and he is discharged with analgesia. He presents 3 days later with inability to abduct the arm.

On examination, there is only 2/5 power in the shoulder, and between 15 ° and 90 ° degrees of abduction. Sensation is impaired over the outer aspect of the shoulder. The remainder of the neurological examination is normal.

What is the most likely neuroanatomical localisation of the lesion?

Your answer was correct

A C5–7 radiculopathy

Audio Video Stop Share Participants More

3:56
https://mypastest.paste

D Axillary nerve injury

This nerve arises from the posterior cord of the brachial plexus and supplies the teres minor and deltoid muscles. It may be involved in dislocation of the shoulder joint as in the present scenario, fractures of the neck of the humerus or serum- and vaccine-induced neuropathies. The anatomic diagnosis depends on the recognition of paralysis of abduction of the arm between 15° and 90° , wasting of the deltoid muscle and slight impairment of sensation over the outer aspect of the shoulder. Physiotherapy with continued mobilisation of the shoulder is the treatment of choice.

A C5–7 radiculopathy

C6 and C7 radiculopathy lead to

Audio Video Stop Share Participants More

3:57
https://mypastest.paste

A C5-7 radiculopathy

C6 and C7 radiculopathy lead to weakness and abnormal sensation in the distal arm and hand, not seen here.

B Long thoracic nerve injury

The long thoracic nerve supplies the serratus anterior muscle, initial injury leading to burning pain over the scapula; over the longer term winging of the scapula may be seen.

C Musculocutaneous nerve injury

Lesions of the musculocutaneous nerve lead to weakness of flexion and supination at the elbow.

E Suprascapular nerve injury

Audio Video Stop Share Participants More

3:57
https://mypastest.paste

The long thoracic nerve supplies the serratus anterior muscle, initial injury leading to burning pain over the scapula; over the longer term winging of the scapula may be seen.

C	Musculocutaneous nerve injury

Lesions of the musculocutaneous nerve lead to weakness of flexion and supination at the elbow.

E	Suprascapular nerve injury

Suprascapular nerve injury leads to weakness of the supraspinatus and infraspinatus muscles. Pain associated with nerve injury is variable, from nothing to a dull ache, to neuralgic amyotrophy.

32762

Rate this question:

Audio Video Stop Share Participants More

3:57
https://mypastest.paste

A 76-year old man presents with a history of painless loss of vision affecting his left eye, which resolved after about 3 min.

His past medical history is of hypertension, and a previous transient ischaemic attack 2 years earlier when he had transient weakness of his right arm and dysarthria.

His current medications are aspirin 75 mg, atenolol and bendroflumethiazide. His blood pressure is 126/64 mmHg.

Carotid Dopplers are as follows:

Internal carotid artery	External carotid artery
L. 45% stenosis	L. 90% stenosis
R. 45% stenosis	R. 65% stenosis

What is the next most appropriate treatment?

Audio Video Stop Share Participants More

3:57
https://mypastest.paste

L. 45% stenosis	L. 90% stenosis
R. 45% stenosis	R. 65% stenosis

What is the next most appropriate treatment?

A	Increase aspirin to 150 mg OD
B	Left carotid endarterectomy
C	Add dipyridamole MR 100 mg BD
D	Change aspirin to clopidogrel 75 mg OD
E	Commence rivaroxaban 10 mg OD

Audio Video Stop Share Participants More

4:00
https://mypastest.paste

artery	artery
L. 45% stenosis	L. 90% stenosis
R. 45% stenosis	R. 65% stenosis

What is the next most appropriate treatment?

A	Increase aspirin to 150 mg OD
B	Left carotid endarterectomy
C	Add dipyridamole MR 100 mg BD
D	Change aspirin to clopidogrel 75 mg OD
E	Commence rivaroxaban 10 mg OD

Audio Video Stop Share Participants More

4:02
https://mypastest.paste

D Change aspirin to clopidogrel 75 mg OD

NICE guidance recommends clopidogrel 75 mg OD for secondary prevention of stroke and in patients who suffer TIAs whilst on aspirin.

B Left carotid endarterectomy

There is no indication for carotid endarterectomy with internal carotid artery (ICA) stenosis under 50%.

A Increase aspirin to 150 mg OD

Increasing aspirin does not offer a reduction in rates of secondary stroke over a 75 mg daily dose, but does increase the risk of GI haemorrhage.

C Add dipyridamole MR 100 mg

Audio Video Stop Share Participants More

4:03
https://mypastest.paste

over a 75 mg daily dose, but does increase the risk of GI haemorrhage.

C	Add dipyridamole MR 100 mg BD

Aspirin and dipyridamole in combination became the treatment of choice for secondary prevention after stroke or TIA following the results of the ESPS-2 study. Original guidance has been superseded by NICE guidance supporting use of clopidogrel.

E	Commence rivaroxaban 10 mg OD

This patient is not in atrial fibrillation, and therefore there is no indication for anticoagulation.

7588

Rate this question:

Audio Video Stop Share Participants More

4:03
https://mypastest.paste

A 74-year-old man presents to the Emergency Department with acute onset of dizziness, palpitations and tingling and pain down his legs while tending to his vegetables in the garden that morning. He is unable to stand or weight-bear. He denies any weakness affecting his upper limbs, and denies headache, diplopia, dysarthria or dysphagia. His past medical history is of hypertension, type 2 diabetes and hypercholesterolaemia, and he currently takes bendroflumethiazide 2.5 mg OD, gliclazide 40 mg OD and simvastatin 40 mg nocte. He smokes 20 cigarettes per day and drinks the occasional glass of whisky.

On examination he is afebrile. His pulse is 118 bpm and irregular. Blood pressure is 164/88 mmHg. Heart sounds are normal and his chest is clear. O_2 saturations are 97% on air. His abdomen is soft and non-tender, with normal bowel sounds. He has a flaccid

Audio Video Stop Share Participants More

4:05
https://mypastest.paste

abdomen is soft and non-tender, with normal bowel sounds. He has a flaccid paraparesis affecting his lower limbs. Knee and ankle reflexes are absent, and you are unable to elicit a plantar response. He has reduced sensation to pin-prick in his lower limbs with a sensory level at T12. Vibration and joint position sensation are normal.

Investigations:

Hb	13.2 g/dl
WCC	5.6×10^9/l
PLT	314×10^9/l
Na^+	144 mmol/l
K^+	4.2 mmol/l
Creatinine	144 µmol/l
Urea	6.6 mol/l
Glucose	8.2 mmol/l

Audio Video Stop Share Participants More

4:05
https://mypastest.paste

Glucose	8.2 mmol/l
ECG	Atrial fibrillation, rate 110 beats/min; left axis deviation
Chest X-ray	No appreciable disease

What is the most likely diagnosis?

A Transverse myelitis

B Guillain–Barré syndrome

C Prolapsed intervertebral disc

D Spinal cord metastasis

E Anterior spinal artery occlusion

Audio Video Stop Share Participants More

4:07
https://mypastest.paste

of hypertension, type 2 diabetes and hypercholesterolaemia, and he currently takes bendroflumethiazide 2.5 mg OD, gliclazide 40 mg OD and simvastatin 40 mg nocte. He smokes 20 cigarettes per day and drinks the occasional glass of whisky.

On examination he is afebrile. His pulse is 118 bpm and irregular. Blood pressure is 164/88 mmHg. Heart sounds are normal and his chest is clear. O_2 saturations are 97% on air. His abdomen is soft and non-tender, with normal bowel sounds. He has a flaccid paraparesis affecting his lower limbs. Knee and ankle reflexes are absent, and you are unable to elicit a plantar response. He has reduced sensation to pin-prick in his lower limbs with a sensory level at T12. Vibration and joint position sensation are normal.

Investigations:

Hb	13.2 g/dl

Audio Video Stop Share Participants More

4:07
https://mypastest.paste

E Anterior spinal artery occlusion

The combination of paraparesis with spinothalamic sensory loss and dorsal column sparing suggests an anterior spinal cord syndrome. The anterior spinal artery is one of the major arteries of the spinal cord. It is formed from branches of the vertebral arteries as they unite in the median fissure of the spinal cord. The anterior spinal artery is vulnerable to the effects of vascular disease since it has a relatively poor collateral supply. Areflexia occurs due to spinal cord shock. Vibration and joint position sense are usually unaffected because the dorsal columns are supplied by the posterior spinal arteries. This patient is noted to have new-onset atrial fibrillation, which may have caused an embolic occlusion of the anterior spinal artery.

Audio Video Stop Share Participants More

4:08
https://mypastest.paste

A Transverse myelitis

Transverse myelitis is unlikely given the rapid onset of symptoms and the patient's older age.

B Guillain–Barré syndrome

Guillain–Barré is typically associated with subacute ascending motor weakness; sensory symptoms may also be seen, usually in the form of distal paraesthesiae.

C Prolapsed intervertebral disc

This is a reasonable differential diagnosis, but the posterior column sparing and new AF make a vascular event more likely.

D Spinal cord metastasis

Audio Video Stop Share Participants More

4:08
https://mypastest.paste

with subacute ascending motor weakness; sensory symptoms may also be seen, usually in the form of distal paraesthesiae.

C Prolapsed intervertebral disc

This is a reasonable differential diagnosis, but the posterior column sparing and new AF make a vascular event more likely.

D Spinal cord metastasis

With no history of chronic illness suggestive of underlying cancer, and the posterior column sparing, anterior spinal artery syndrome is much more likely to be the cause of the symptoms seen here.

7593

Rate this question:

Audio Video Stop Share Participants More

4:08
https://mypastest.paste

A 78-year-old retired accountant presented to the Emergency Department with a history of rather rapid onset of hoarseness of voice, dizziness, vomiting and some difficulty in eating his breakfast that morning.

He had had similar symptoms one month ago, which had resolved over a day. He smoked 20 cigarettes a day and took a glass of wine each weekend.

On examination, his pulse was 66/min and blood pressure was 170/100 mmHg. He was alert and his higher mental functions were unremarkable. Fundoscopy revealed arteriovenous nipping and a mild, right-sided ptosis was noted. Pupils were 2.0 mm on the right side and 3.0 mm on the left. Extra-ocular movements were full, and nystagmus was noted in both the vertical and horizontal directions. The gag reflex was impaired on the right

Audio Video Stop Share Participants More

4:10
https://mypastest.paste

gag reflex was impaired on the right side.

Motor power was intact in all four limbs. Incoordination was evident in the right upper limb and he could not walk tandem. Romberg sign was negative. There was dulling of pinprick sensation over the left upper limb, trunk and the left lower limb.

What is the most likely diagnosis?

A	Brainstem metastasis
B	Lateral medullary syndrome
C	Arnold–Chiari malformation
D	Paraneoplastic cerebellar degeneration
E	Brainstem encephalitis

Audio Video Stop Share Participants More

4:14
https://mypastest.paste

Department with a history of rather rapid onset of hoarseness of voice, dizziness, vomiting and some difficulty in eating his breakfast that morning.

He had had similar symptoms one month ago, which had resolved over a day. He smoked 20 cigarettes a day and took a glass of wine each weekend.

On examination, his pulse was 66/min and blood pressure was 170/100 mmHg. He was alert and his higher mental functions were unremarkable. Fundoscopy revealed arteriovenous nipping and a mild, right-sided ptosis was noted. Pupils were 2.0 mm on the right side and 3.0 mm on the left. Extra-ocular movements were full, and nystagmus was noted in both the vertical and horizontal directions. The gag reflex was impaired on the right side.

Motor power was intact in all four

Audio Video Stop Share Participants More

4:14
https://mypastest.paste

and blood pressure was 170/100 mmHg. He was alert and his higher mental functions were unremarkable. Fundoscopy revealed arteriovenous nipping and a mild, right-sided ptosis was noted. Pupils were 2.0 mm on the right side and 3.0 mm on the left. Extra-ocular movements were full, and nystagmus was noted in both the vertical and horizontal directions. The gag reflex was impaired on the right side.

Motor power was intact in all four limbs. Incoordination was evident in the right upper limb and he could not walk tandem. Romberg sign was negative. There was dulling of pinprick sensation over the left upper limb, trunk and the left lower limb.

What is the most likely diagnosis?

Your answer was correct

Audio Video Stop Share Participants More

4:14
https://mypastest.paste

B Lateral medullary syndrome

Lateral medullary syndrome typically presents with (1) vertigo, vomiting, oscillopsia, nystagmus, which occur due to vestibular nucleus involvement; (2) ataxia due to restiform body and cerebellar involvement; (3) descending sympathetic involvement causing Horner syndrome; (4) 9th and 10th cranial nerve involvement causing hoarseness and dysphagia; (5) spinothalamic tract involvement causing crossed pain and temperature impairment and, if the spinal tract and the trigeminal nucleus were involved, there would be ipsilateral facial numbness; (6) loss of taste due to tractus solitarius involvement is seen rarely. All of these features may not be present in all patients, since fragmentary syndromes are more common. Atherothrombosis is the likely cause of this stroke, as there is

Audio Video Stop Share Participants More

4:16
https://mypastest.paste

common. Atherothrombosis is the likely cause of this stroke, as there is history of a transient ischaemic attack one month ago.

A Brainstem metastasis

The symptoms and signs do localise to the brainstem, but the very rapid onset and previous brief spell of symptoms make this diagnosis very unlikely.

C Arnold–Chiari malformation

This abnormality of cerebellar tonsil descent through the foramen magnum is more often picked up incidentally on MRI scans than actually being the cause for symptoms. It can be associated with cough headache, high cervical myelopathy and syringomyelia.

Audio Video Stop Share Participants More

4:18
https://mypastest.paste

A 33-year-old patient with known epilepsy is brought to the Casualty Department by blue-light ambulance following a generalised tonic-clonic seizure (GTCS). Although the seizure has now stopped, the patient continues to be drowsy. He consumes no alcohol, is a non-smoker and has no other illnesses. He takes regular lamotrigine to control his epilepsy.

Following taking a history from the accompanying family members and performing of a clinical examination, you want to undertake some blood investigations.

Which of the following metabolic abnormalities is most likely to be found in this patient?

A Hypoglycaemia

B Hyperphosphataemia

Audio Video Stop Share Participants More

4:20
https://mypastest.paste

performing of a clinical examination, you want to undertake some blood investigations.

Which of the following metabolic abnormalities is most likely to be found in this patient?

A	Hypoglycaemia
B	Hyperphosphataemia
C	Hyponatraemia
D	Hypocalcaemia
E	Hyperprolactinaemia

71109

Submit

Audio Video Stop Share Participants More

4:20
https://mypastest.paste

E Hyperprolactinaemia

When measured 10–20 min after a generalised tonic–clonic or complex partial seizure, prolactin levels may be elevated up to three times the upper limit of normal. In some cases, the test may be of value in differentiating between psychogenic non-epileptic seizures (PNES) and epilepsy.

D Hypocalcaemia

Phenytoin, not lamotrigine is associated with hypocalcaemia.

A Hypoglycaemia

Hypoglycaemia is unlikely given the absence of other past medical history of note outside epilepsy, such as treated diabetes mellitus.

Audio Video Stop Share Participants More

4:21
https://mypastest.paste

Hypoglycaemia is unlikely given the absence of other past medical history of note outside epilepsy, such as treated diabetes mellitus.

B Hyperphosphataemia

Hypophosphataemia is associated with drowsiness and muscle weakness, and is seen as part of re-feeding syndrome. Hyperphosphataemia is seen in patients with significant muscle necrosis and kidney disease.

C Hyponatraemia

Seizures do occur when there is marked hyponatraemia, although in the absence of a metabolic or infectious cause it is less likely to be found on investigation than hyperprolactinaemia.

Audio Video Stop Share Participants More

4:23
https://mypastest.paste

A 45-year-old man is admitted to the Emergency Department, having developed an onset of severe generalized headache, meningism and vomiting. In the last hour, he has noticed diplopia, particularly on left lateral gaze, and loss of both temporal fields of vision.

Past medical history includes hypertension and previous anterior cruciate ligament surgery to his left knee. He had recently been to see his general practitioner (GP) because of increasing lethargy and dizzy spells.

On examination, he is noted to be drowsy and dehydrated, with a Glasgow Coma Scale (GCS) score of 14/15. His temperature is 37.1 °C, blood pressure (BP) 85/50 mmHg and pulse 102 bpm, with evidence of meningism but no rash. Cranial nerve examination reveals a left ptosis, left cranial nerve VI palsy and bitemporal superior

Audio Video Stop Share Participants More

4:25
https://mypastest.paste

reveals a left ptosis, left cranial nerve VI palsy and bitemporal superior quadrantanopic field defect. Fundoscopy appears normal, although he exhibits marked photophobia. No abnormality can be detected within the peripheral nervous system. An urgent computed tomography (CT) head scan is requested, which does not reveal any abnormalities.

Blood tests reveal:

Sodium (Na^+)	122 mmol/l
Potassium (K^+)	5.8 mmol/l
Urea	18.3 mmol/l
Creatinine (Cr)	202 µmol/l
Haemoglobin (Hb)	13.5 g/dl
White cell count (WCC)	9.0×10^9/l
Platelets (PLT)	234×10^9/l

Audio Video Stop Share Participants More

4:26
https://mypastest.paste:

Platelets (PLT)	234×10^9/l
C-reactive protein (CRP)	5 mg/l (< 10 mg/l)
Glucose	2.9 mmol/l

Lumbar puncture reveals:

Opening pressure	21 cmH_2O (5–18)
Protein	0.7 g/l (0.15–0.45)
White cell count (WCC)	5/ml (monocytes) (≤ 5)
Red cell count (RCC)	20/ml (≤ 5)
Xanthochromia	No

What is the likely diagnosis in this patient?

Audio Video Stop Share Participants More

4:26
https://mypastest.paste

(WCC)	5)
Red cell count (RCC)	20/ml (≤ 5)
Xanthochromia	No

What is the likely diagnosis in this patient?

A	Bacterial meningitis
B	Cavernous sinus thrombosis
C	Pituitary apoplexy
D	Posterior communicating artery aneurysm
E	Subarachnoid haemorrhage

32779
Audio Video Stop Share Participants More

4:31
https://mypastest.paste

C Pituitary apoplexy

The correct answer is Pituitary apoplexy (Option C).

This patient presents with a classical history for pituitary apoplexy causing compression around the optic chiasm and a bitemporal visual field defect. In addition, there is also involvement of the cavernous sinus and a left cranial nerve VI palsy. He is also in Addisonian crisis, as evidenced by dehydration, hypotension and a typical biochemical picture.

Pituitary apoplexy is a rare and life-threatening condition, which occurs as a result of haemorrhage into the pituitary gland. Often, this occurs in a normal pituitary gland; however, a proportion of patients have an underlying endocrinologically silent adenoma. In this case, it is likely that compression from an adenoma had led to the bitemporal field defects

Audio Video Stop Share Participants More

4:32
https://mypastest.paste

to the bitemporal field defects identified. The management of this patient would be to resuscitate with fluids and correct the metabolic disturbance. An urgent magnetic resonance imaging (MRI) scan and pituitary function tests should be carried out, as around 50% of patients with this condition have negative findings on CT scan.

D	Posterior communicating artery aneurysm

Posterior communicating artery aneurysm (Option D) is incorrect.

A posterior communicating artery aneurysm would have been likely to cause pupillary dilatation and hemiparesis, neither of which are present in this case.

Audio Video Stop Share Participants More

4:32
https://mypastest.paste

The possibility of bacterial or viral meningoencephalitis appears unlikely, in view of the fact that this patient is apyrexial, with a normal WCC and CRP on blood tests and a normal WCC on lumbar puncture.

B	Cavernous sinus thrombosis

Cavernous sinus thrombosis (Option B) is incorrect.

The clinical presentation of cavernous sinus thrombosis can be varied, with both acute and subacute presentations having been reported in the literature. The most common signs are related to the anatomical structures affected within the cavernous sinus, notably cranial nerves III–VI, as well as symptoms resulting from impaired venous drainage from the orbit and the eye. Typical presentations include a combination of abrupt-onset unilateral

Audio Video Stop Share Participants More

4:32
https://mypastest.paste

The clinical presentation of cavernous sinus thrombosis can be varied, with both acute and subacute presentations having been reported in the literature. The most common signs are related to the anatomical structures affected within the cavernous sinus, notably cranial nerves III–VI, as well as symptoms resulting from impaired venous drainage from the orbit and the eye. Typical presentations include a combination of abrupt-onset unilateral periorbital oedema, headaches, photophobia and proptosis.

E	Subarachnoid haemorrhage

Subarachnoid haemorrhage (Option E) is incorrect.

A subarachnoid haemorrhage can be ruled out, based on the normal CT findings and the absence of xanthochromia on lumbar puncture.

Audio Video Stop Share Participants More

@Oselk admin

Following successful eradication of low-grade dysplasia, surveillance endoscopy should be performed every 6 months for the first year and then annually thereafter. After eradication of high-grade dysplasia or intra-mucosal carcinoma, surveillance should be more frequent: every 3 months for the first year, every 6 months for the second year and then annually thereafter.

7:03 PM

325

the left lower extremity that has been gradually developing over the past 4 months.

On further questioning, he also describes occasional brief and unprovoked episodes of rhythmic jerking along the length of the left limb and less marked weakness affecting the right leg. He also reports headache, which is worst in the morning.

Neurological examination reveals weakness of both lower limbs that is more pronounced on the left side, and bilateral extensor (up-going) plantar responses. Sensory examination reveals mild reduction of vibration sense of the left leg, but is otherwise normal.

Which one of the following investigations is most appropriate to complete first?

Your answer was incorrect

A	Visual evoked potentials (VEPs)
B	Magnetic resonance imaging (MRI) of the thoracic and lumbar spine
C	MRI of the head
D	Computed tomography (CT) of the dorsal and lumbar spine
E	Electroencephalography (EEG)

Explanation

A 68-year-old man is seen in the clinic with a history of weakness in his arms and legs. His problems started 6 months earlier when he developed onset of weakness affecting his right hand over the course of 5 days. He had seen his general practitioner, who had prescribed aspirin. Despite this, the weakness had spread to his right arm and leg. Three weeks ago he developed slurring of his speech, and noticed that the muscles in his arm would twitch occasionally.

His past medical history included rheumatoid arthritis, for which he took azathioprine and ibuprofen. He smoked 25 cigarettes per day and drank the occasional pint of beer. He had noticed that he had lost a stone in weight in the past 6 months.

On examination he appeared emaciated. Cardiovascular, respiratory and abdominal examinations were unremarkable. Cranial nerve examination was unremarkable, with normal jaw jerk and no tongue fasciculations. Upper limb examination revealed fasciculations over the biceps

fasciculations. Upper limb examination revealed fasciculations over the biceps and triceps of his right arm. There was wasting of the small muscles of his hands bilaterally. He had grade 4 power his upper limbs. Biceps and triceps reflexes were brisk bilaterally. Sensation was normal. Lower limb examination revealed bilateral quadriceps wasting with occasional fasciculations over the right quadriceps. Tone was normal bilaterally. Power was reduced to grade 4/5 in a pyramidal distribution in the lower limbs. Knee reflexes were brisk bilaterally, with absent ankle jerks. Plantar responses were withdrawal. Sensation was unimpaired.

What is the most likely diagnosis?

A	Cervical myelopathy
B	Lambert–Eaton syndrome
C	Syringomyelia

Sensation was normal. Lower limb examination revealed bilateral quadriceps wasting with occasional fasciculations over the right quadriceps. Tone was normal bilaterally. Power was reduced to grade 4/5 in a pyramidal distribution in the lower limbs. Knee reflexes were brisk bilaterally, with absent ankle jerks. Plantar responses were withdrawal. Sensation was unimpaired.

What is the most likely diagnosis?

A	Cervical myelopathy
B	Lambert–Eaton syndrome
C	Syringomyelia
D	Amyotrophic lateral sclerosis
E	Chronic inflammatory demyelinating polyneuropathy (CIDP)

azathioprine and ibuprofen. He smoked 25 cigarettes per day and drank the occasional pint of beer. He had noticed that he had lost a stone in weight in the past 6 months.

On examination he appeared emaciated. Cardiovascular, respiratory and abdominal examinations were unremarkable. Cranial nerve examination was unremarkable, with normal jaw jerk and no tongue fasciculations. Upper limb examination revealed fasciculations over the biceps and triceps of his right arm. There was wasting of the small muscles of his hands bilaterally. He had grade 4 power his upper limbs. Biceps and triceps reflexes were brisk bilaterally. Sensation was normal. Lower limb examination revealed bilateral quadriceps wasting with occasional fasciculations over the right quadriceps. Tone was normal bilaterally. Power was reduced to grade 4/5 in a pyramidal distribution in the lower limbs. Knee reflexes were brisk bilaterally, with absent ankle jerks. Plantar responses were

D Amyotrophic lateral sclerosis

This patient has a combination of upper and lower motor neurone signs affecting his arms and legs, without evidence of sensory impairment. Thus the most likely diagnosis is amyotrophic lateral sclerosis (ALS). ALS is the commonest form of motor neurone disease, accounting for 65–85% of cases. It is a devastating disorder of the anterior horn cells of the spinal cord and motor cranial nuclei. It begins insidiously as weakness, atrophy or fasciculations in one or more limbs; fasciculations and atrophy of the tongue may also be noted. Respiratory insufficiency is usually a late complication. Riluzole, a glutamate antagonist. has been licensed for ALS with the aim to extend life or time to ventilation for individuals with ALS. It is thought that excessive stimulation of glutamate receptors on neurones may cause or play an important role in the destruction of motor neurones in motor neurone disease. Riluzole works

motor neurone disease. Riluzole works by inhibiting the release of glutamate, decreasing the firing of motor neurones and protecting them from glutamate-mediated damage.

A Cervical myelopathy

The absence of sensory symptoms seen here counts against a diagnosis of cervical myelopathy.

B Lambert–Eaton syndrome

Lambert–Eaton syndrome is associated with muscle weakness which improves with reinforcement; it is not associated with fasciculations.

C Syringomyelia

Syringomyelia is associated with dissociated sensory loss, which isn't a feature of the presentation seen here.

E Chronic inflammatory

B	Lambert–Eaton syndrome

Lambert–Eaton syndrome is associated with muscle weakness which improves with reinforcement; it is not associated with fasciculations.

C	Syringomyelia

Syringomyelia is associated with dissociated sensory loss, which isn't a feature of the presentation seen here.

E	Chronic inflammatory demyelinating polyneuropathy (CIDP)

CIDP is associated with both muscle weakness and symptoms of peripheral sensory neuropathy, not seen in this patient.

7595

Rate this question:

Next Question

A 40-year-old journalist has been having difficulty in keeping her important appointments for the past 3 years. She was finding it difficult to handle even simple tasks at work and had been fired by her boss. Her husband brings her to the hospital as she has become irritable and unkempt. He also remarks that she has become fidgety and clumsy. Her father and two older siblings have been diagnosed with Parkinsonism and are now residents in a nursing home, as they were unmanageable at home due to their mental deterioration.

On examination, there are involuntary movements of the face and limbs, and her speech is punctuated by a series of grunts. There is no coprolalia. Cranial nerves examination is normal. Tendon reflexes are brisk and the plantar response is flexor.

What is the most likely diagnosis?

A	Wilson's disease

older siblings have been diagnosed with Parkinsonism and are now residents in a nursing home, as they were unmanageable at home due to their mental deterioration.

On examination, there are involuntary movements of the face and limbs, and her speech is punctuated by a series of grunts. There is no coprolalia. Cranial nerves examination is normal. Tendon reflexes are brisk and the plantar response is flexor.

What is the most likely diagnosis?

A	Wilson's disease
B	Cortico-basal ganglionic degeneration
C	Huntington's disease
D	Anti-phospholipid syndrome
E	Creutzfeldt–Jakob disease

A 40-year-old journalist has been having difficulty in keeping her important appointments for the past 3 years. She was finding it difficult to handle even simple tasks at work and had been fired by her boss. Her husband brings her to the hospital as she has become irritable and unkempt. He also remarks that she has become fidgety and clumsy. Her father and two older siblings have been diagnosed with Parkinsonism and are now residents in a nursing home, as they were unmanageable at home due to their mental deterioration.

On examination, there are involuntary movements of the face and limbs, and her speech is punctuated by a series of grunts. There is no coprolalia. Cranial nerves examination is normal. Tendon reflexes are brisk and the plantar response is flexor.

What is the most likely diagnosis?

Your answer was correct

C Huntington's disease

This patient has progressive dementia with choreo-athetosis in a dominantly inherited pattern suggestive of Huntington's disease. Gross atrophy of the caudate nucleus and putamen on both sides is the characteristic abnormality seen in patients with the condition. DNA analysis to look for trinucleotide repeats is the diagnostic modality of choice. Parkinsonian features occur in a group of Huntington's disease patients (Westphal variant, which is more common with childhood onset of the disease).

A Wilson's disease

Wilson's disease always presents much earlier in life, with psychiatric disturbance, abnormal movements worse on one side of the body than the other, or elevated transaminases with no other symptoms.

B	Cortico-basal ganglionic degeneration

Abnormal posturing of the hand, so-called alien hand, is characteristic of the condition and is not seen here.

D	Anti-phospholipid syndrome

Anti-phospholipid syndrome is characterised by a prothrombotic tendency not seen here. Features such as multiple TIAs, migraine, stroke or peripheral venous thrombosis are absent here.

E	Creutzfeldt–Jakob disease

This is a rapidly progressive dementia with initial psychiatric disturbance and rapidly deteriorating movement disorder, initially characterised by myoclonic jerks. A family history is not seen.

32760

Rate this question:

A 49-year-old woman presents to casualty with sudden-onset severe headache. The pain came on instantaneously while she was at home cooking. She describes it as 'bursting' in character and feels that it is coming from behind the eye and also in the back of the head. She is having difficulty elevating her right eyelid. She has a history of hypertension and mild renal impairment. There is no history of other medical problems. She takes atenolol 25 mg/day but no other regular medications. She is extremely anxious and frightened about what the pain represents, particularly that it might be a brain tumour.

On examination, she is clearly in pain and is intolerant of the light in the cubicle where she is being examined. Her blood pressure is 176/110 mmHg. She has a complete ptosis of her right eye. When her eyelid is lifted up her eye is deviated downwards and outwards and the pupil is large and only sluggishly responsive to light. There is no proptosis or chemosis. There are no abnormalities of the left

There is no proptosis or chemosis. There are no abnormalities of the left eye. There are no other abnormalities on neurological examination.

Urgent blood results are as follows:

Hb	11.9 g/dl
WCC	4.3×10^9/l
PLT	233×10^9/l
Na^+	138 mmol/l
K^+	4.2 mmol/l
Ures	7.6 mmol/l
Creatinine	129 μmol/l

Which investigation is most likely to establish a diagnosis?

A Computed tomography scan of the brain

B Magnetic resonance imaging of the brain

Na^+	138 mmol/l
K^+	4.2 mmol/l
Ures	7.6 mmol/l
Creatinine	129 µmol/l

Which investigation is most likely to establish a diagnosis?

A Computed tomography scan of the brain

B Magnetic resonance imaging of the brain

C Ultrasound scan of abdomen and kidneys

D Computed tomography of brain and CT angiography

E Duplex ultrasound of the right side of the neck

A 49-year-old woman presents to casualty with sudden-onset severe headache. The pain came on instantaneously while she was at home cooking. She describes it as 'bursting' in character and feels that it is coming from behind the eye and also in the back of the head. She is having difficulty elevating her right eyelid. She has a history of hypertension and mild renal impairment. There is no history of other medical problems. She takes atenolol 25 mg/day but no other regular medications. She is extremely anxious and frightened about what the pain represents, particularly that it might be a brain tumour.

On examination, she is clearly in pain and is intolerant of the light in the cubicle where she is being examined. Her blood pressure is 176/110 mmHg. She has a complete ptosis of her right eye. When her eyelid is lifted up her eye is deviated downwards and outwards and the pupil is large and only sluggishly responsive to light. There is no proptosis or chemosis. There are no abnormalities of the left

D Computed tomography of brain and CT angiography

This woman's presentation with sudden-onset, acute severe headache suggests subarachnoid haemorrhage. The signs of a pupil involving third nerve palsy suggest an aneurysm of the posterior communicating artery. A CT scan of the brain is needed to look for evidence of subarachnoid blood, and CT angiography is required to look for the underlying cause.

A Computed tomography scan of the brain

Whilst this scan may show subarachnoid bleeding, it will not show the underlying cause and, due to the signs of a 3rd nerve palsy, the suspicion of a posterior communicating aneurysm is very high. Therefore computed tomography of brain and CT angiography

B Magnetic resonance imaging of the brain

B	Magnetic resonance imaging of the brain

This would add little benefit over CT in the detection of acute subarachnoid blood (and often takes longer to organise/perform). In addition, it would be unlikely to confirm or rule out the presence of the suspected aneurysm.

C	Ultrasound scan of abdomen and kidneys

The priority is to diagnose the direct cause of the patient's symptoms (probably subarachnoid bleeding from a ruptured aneurysm). There is an association between berry aneurysms and polycystic kidney disease, so in this lady with renal impairment there would be an argument for doing this test after the acute problem has been managed.

E	Duplex ultrasound of the right side of the neck

A 34-year-old man is referred by his general practitioner (GP) to the Neurology Clinic. He has a 2-year history of involuntary movements in his hands associated with weight loss. His wife describes these as 'piano playing'. More recently he has been emotionally labile with aggressive outbursts and has begun to have some memory problems. He has a family history of 'Parkinson's disease', which affected his paternal grandfather in later life and affects a paternal aunt. His own father died in his late twenties in an accident.

On examination, he has hypometric saccadic eye movements with broken pursuit movements and some nystagmus at the extremes of gaze. He has continuous fidgety movements of his fingers and arms. There is extrapyramidal rigidity in all four limbs with a shuffling gait. 'Bedside' higher function testing reveals some disinhibition with irritability and impaired episodic memory.

Magnetic resonance imaging (MRI) of

Magnetic resonance imaging (MRI) of the brain reveals no significant abnormalities beside some possible cerebral atrophy. Electroencephalogram (EEG) is non-specifically abnormal. Cerebrospinal fluid (CSF) analysis reveals an acellular fluid:

Glucose	3.7 mmol/l (serum 7.1 mmol/l)
Protein	0.45 g/dl
14-3-3 protein	Negative
S100b	Normal range

Choose the test most likely to confirm the diagnosis.

A	Prion protein gene analysis
B	Serum copper studies and liver biopsy
C	Blood film for acanthocytes

Glucose	3.7 mmol/l (serum 7.1 mmol/l)
Protein	0.45 g/dl
14-3-3 protein	Negative
S100b	Normal range

Choose the test most likely to confirm the diagnosis.

A	Prion protein gene analysis
B	Serum copper studies and liver biopsy
C	Blood film for acanthocytes
D	Genetic Parkinson's disease next-generation gene chip
E	Huntingtin gene analysis

A 34-year-old man is referred by his general practitioner (GP) to the Neurology Clinic. He has a 2-year history of involuntary movements in his hands associated with weight loss. His wife describes these as 'piano playing'. More recently he has been emotionally labile with aggressive outbursts and has begun to have some memory problems. He has a family history of 'Parkinson's disease', which affected his paternal grandfather in later life and affects a paternal aunt. His own father died in his late twenties in an accident.

On examination, he has hypometric saccadic eye movements with broken pursuit movements and some nystagmus at the extremes of gaze. He has continuous fidgety movements of his fingers and arms. There is extrapyramidal rigidity in all four limbs with a shuffling gait. 'Bedside' higher function testing reveals some disinhibition with irritability and impaired episodic memory.

Magnetic resonance imaging (MRI) of the brain reveals no significant

E Huntingtin gene analysis

Huntington's disease (HD) is the most likely diagnosis. There are a number of features here such as the choreoform movements, rigidity, eye movement abnormalities and cognitive problems , which are classical for Huntington's. The associated gene, coding for the protein huntingtin, is found on chromosome 4.

Huntington's is a trinucleotide repeat disorder, which demonstrates genetic anticipation where successive generations tend to show an earlier onset of a more marked phenotype. This is due to expansion of the repeat length with successive generations. In addition, patients who inherit the disorder from their father seem to have an earlier onset than patients who inherit it from their mother, again apparently due to expansion of the trinucleotide repeat region. There is currently no treatment and the disease is universally fatal. Patients who are at risk but asymptomatic can choose to be tested predictively. However, they

are obliged to undergo a standardised protocol of genetic counselling including a 'cooling off' time before the test is completed.

A	Prion protein gene analysis

In this case the features strongly suggest Huntington's disease (HD), so this should be tested for first. Some patients with a HD phenotype have a negative genetic test – so-called HD phenocopies. Genetic prion disease is one of the rare causes of this.

B	Serum copper studies and liver biopsy

These are tests to investigate possible Wilson's disease. In this case the presence of an apparently autosomal dominant mode of inheritance suggests Wilson's is unlikely (it is autosomal recessive).

C	Blood film for acanthocytes

C	Blood film for acanthocytes

Neuroacanthocytosis describes a group of very rare causes of adult-onset movement disorders. Patients with this condition may have chorea, often markedly involving the mouth and tongue. Other, more common, causes (such as HD) should be looked for first.

D	Genetic Parkinson's disease next-generation gene chip

Next-generation sequencing allows a panel of genes to be tested simultaneously. This is useful for certain diseases where the phenotype-genotype correlation is low and predicting which gene will be positive can be challenging. However, in this case the clinical features strongly suggest HD (and are not really compatible with Parkinson's disease), so a single gene test for this condition ought to be sent.

A 50-year old man is referred with a 4-month history of worsening disorientation and behavioural disturbance. His wife had noted that he would walk away in the middle of a conversation, and had been found wandering purposelessly around the house and garden. He found it impossible to buy a list of groceries from the local supermarket, and had recently been cautioned by the police for driving the wrong way down a one-way street. He would become increasingly frustrated when trying to use the computer, and had frequent angry or emotional outbursts.

He normally worked as accountant, but his colleagues had expressed concern that his performance had deteriorated. He had no significant past medical history of note.

On clinical examination, his BP is 132/80 mmHg, pulse is 72 bpm and regular. Cardiovascular and respiratory examination is normal. He has signs of significant cognitive impairment in all domains. The other main abnormal finding is some asymmetric jerky

On clinical examination, his BP is 132/80 mmHg, pulse is 72 bpm and regular. Cardiovascular and respiratory examination is normal. He has signs of significant cognitive impairment in all domains. The other main abnormal finding is some asymmetric jerks affecting all four limbs on neurological examination, as well as a broad-based, rather ataxic gait.

What would be the most appropriate initial investigation?

A	Visual evoked potentials
B	Electroencephalography (EEG)
C	Magnetic resonance imaging (MRI) of the brain
D	Lumbar puncture for 14-3-3 protein
E	Electromyography (EMG)

would walk away in the middle of a conversation, and had been found wandering purposelessly around the house and garden. He found it impossible to buy a list of groceries from the local supermarket, and had recently been cautioned by the police for driving the wrong way down a one-way street. He would become increasingly frustrated when trying to use the computer, and had frequent angry or emotional outbursts.

He normally worked as accountant, but his colleagues had expressed concern that his performance had deteriorated. He had no significant past medical history of note.

On clinical examination, his BP is 132/80 mmHg, pulse is 72 bpm and regular. Cardiovascular and respiratory examination is normal. He has signs of significant cognitive impairment in all domains. The other main abnormal finding is some asymmetric jerks affecting all four limbs on neurological examination, as well as a broad-based, rather ataxic gait.

C	Magnetic resonance imaging (MRI) of the brain

Rapid cognitive decline in a person with ataxia and myoclonic jerks is highly suggestive of sporadic Creutzfeld–Jakob disease (sCJD). Magnetic resonance imaging (MRI) of the brain is a relatively non-invasive and generally available test, which in sCJD can show characteristic abnormalities in the basal ganglia and cortex. It is best seen on the FLAIR (fluid attenuation inversion recovery) and diffusion-weighted imaging (DWI) sequences. The stage of illness at which the scan becomes positive is unclear. MRI of the brain is also useful in excluding other disease processes. Because no single test is perfect for assessing CJD, a combination of MRI, CSF and EEG is frequently used in clinical practice.

A	Visual evoked potentials

This test is used to assess for the presence of optic neuropathy, so

would be of no value here.

B	Electroencephalography (EEG)

In sporadic CJD the normal electrical rhythms of the electroencephalogram (EEG) are gradually lost. In the majority of cases, generalised biphasic or triphasic periodic sharp wave complexes appear with a frequency of 12/s. However, the EEG change can be a relatively late stage occurrence and is less specific than the MRI changes.

D	Lumbar puncture for 14-3-3 protein

CSF analysis is useful in the assessment of possible CJD. Raised levels of 14-3-3 are usually seen, but as this is a non-specific brain breakdown product other conditions can also cause high levels. Therefore MRI brain is needed first to exclude other conditions. A newer CSF test, termed RTQuIC (real-time quaking induced

D	Lumbar puncture for 14-3-3 protein

CSF analysis is useful in the assessment of possible CJD. Raised levels of 14-3-3 are usually seen, but as this is a non-specific brain breakdown product other conditions can also cause high levels. Therefore MRI brain is needed first to exclude other conditions. A newer CSF test, termed RTQuIC (real-time quaking induced conversion) appears to be the most sensitive and specific CSF test available, but one would still perform MRI first, if possible.

E	Electromyography (EMG)

This is used to assess peripheral nerve and muscle disease so would be of no value here.

32732

Rate this question:

A 73-year-old hypertensive woman presents with a total anterior circulation ischaemic stroke. There is a history of a previous minor stroke leading to poor co-ordination some 2 years earlier.

She makes good progress with rehabilitation in the Stroke Unit after this latest episode and is ready for discharge two weeks later. She is in sinus rhythm with a BP of 154/84 mmHg on the day of discharge.

Results of inpatient investigations are as follows:

Lying blood pressure	156/92 mmHg
Standing blood pressure	160/98 mmHg
Total cholesterol	5.1 mmol/l
Random glucose	10.3 mmol/l
24-h electrocardiogram (ECG)	Sinus rhythm with a few ventricular ectopics

Carotid dopplers	Plaque disease only
Echocardiography	mild left ventricular hypertrophy, enlarged left atrium

According to current best evidence what combination of drugs should she be discharged home with, with respect to stroke prevention?

A	Clopidrogel, simvastatin, perindopril, metformin
B	Aspirin, atenolol, perindopril
C	Simvastatin, clopidogrel, perindopril
D	Warfarin, simvastatin, atenolol, perindopril
E	Aspirin, clopidrogel,

	enlarged left atrium

According to current best evidence what combination of drugs should she be discharged home with, with respect to stroke prevention?

A	Clopidrogel, simvastatin, perindopril, metformin
B	Aspirin, atenolol, perindopril
C	Simvastatin, clopidogrel, perindopril
D	Warfarin, simvastatin, atenolol, perindopril
E	Aspirin, clopidrogel, simvastatin, atenolol, perindopril

C Simvastatin, clopidogrel, perindopril

patients with an ischemic stroke or transient ischemic attack (TIA) should be treated with all available risk reduction strategies wherever possible. Currently viable strategies include blood pressure reduction (<140/90), single antithrombotic therapy, statin therapy, and lifestyle modification. Patients with symptomatic carotid artery disease may benefit from revascularisation and those with atrial fibrillation should be anticoagulated.

A major randomised controlled trial, PROGRESS, examined perindopril (plus indapamide if second agent required) vs placebo in secondary stroke prevention. A reduction in blood pressure of 9/4 mmHg in the perindopril group (vs placebo) decreased the rate of stroke (relative risk reduction 28%) and all cardiovascular events by 26%. The stroke prevention benefit was related to the degree of blood pressure

A	Clopidrogel, simvastatin, perindopril, metformin

There are no investigation results suggesting that this patient has type 2 diabetes; diagnosed with an elevated HbA1c [*WHO, 2011*]. Therefore, metformin is not indicated.

B	Aspirin, atenolol, perindopril

There is no convincing evidence to suggest any particular class of anti-hypertensives are more effective at preventing recurrent ischaemic strokes, furthermore two anti-hypertensives should only be initiated upon failure of an adequate trial of one. More importantly there is no statin in this combination, which is indicated in all patients for secondary stroke prevention, irrespective of their cholesterol level.

D	Warfarin, simvastatin, atenolol, perindopril

A 35-year-old fashion designer woke up with a severe occipital pain radiating to the neck and profound weakness of all limbs; she could not pass urine. The day before, she had gone for a sauna, followed by a session of hair care treatment.

On examination, her pulse was 90/min and regular, and blood pressure was 130/90 mmHg in both arms. She was fully conscious and had unimpaired higher mental functions.

On eye movement testing, she mentioned diplopia, and you were able to elucidate nystagmus. Abductors of the right shoulder were 1/5 and those of the left side were 2/5. Hip and knee flexors were 2/5 on both sides. All limbs were flaccid and the tendon reflexes were universally absent.

Pinprick was impaired over both shoulders, but joint position sense and vibration were intact for all the limbs.

Investigations:

Urea	4.3 mmol/l

reflexes were universally absent.

Pinprick was impaired over both shoulders, but joint position sense and vibration were intact for all the limbs.

Investigations:

Urea	4.3 mmol/l
Na^+	136 mmol/l
K^+	4.0 mmol/l
Creatinine	80 μmol/l

What is the most likely diagnosis?

A	Carotid artery dissection
B	Cervical spondylosis and disc prolapse
C	Subarachnoid haemorrhage
D	Vertebral artery dissection
E	Top of the Basilar syndrome

6:27
tps://mypastest.pastest.com
14

A 35-year-old fashion designer woke up with a severe occipital pain radiating to the neck and profound weakness of all limbs; she could not pass urine. The day before, she had gone for a sauna, followed by a session of hair care treatment.

On examination, her pulse was 90/min and regular, and blood pressure was 130/90 mmHg in both arms. She was fully conscious and had unimpaired higher mental functions.

On eye movement testing, she mentioned diplopia, and you were able to elucidate nystagmus. Abductors of the right shoulder were 1/5 and those of the left side were 2/5. Hip and knee flexors were 2/5 on both sides. All limbs were flaccid and the tendon reflexes were universally absent.

Pinprick was impaired over both shoulders, but joint position sense and vibration were intact for all the limbs.

Investigations:

D Vertebral artery dissection

Vertebral artery dissection may originate in the neck and extend to the intracranial portion of the vessel or remain isolated to either segment. Rapid and extreme rotation of the neck, such as a chiropractic manipulation or extension of the neck to have one's hair washed, and forceful coughing, are common causes. Ehlers–Danlos syndrome and fibromuscular dysplasia are risk factors. Symptoms may fluctuate over minutes and hours. These consist of posterior circulation deficits (such as vertigo, diplopia, dysarthria) or infarction of the cervical spinal cord from occlusion of the anterior spinal artery, as was the case in this patient. The severe weakness, areflexia and hypotonia represent 'spinal shock'. Axial magnetic resonance imaging (MRI) T1-weighted images show a double lumen in the dissected vessel and may reveal areas of infarction.

E Top of the Basilar syndrome

This is a posterior circulation stroke syndrome, often embolic, causing rostral midbrain and thalamic infarction. Patients may have preserved motor function but seem confused, may hallucinate and have oculomotor deficits.

A Carotid artery dissection

This presents with neck or facial pain and then anterior circulation infarction – hemiplegia and aphasia, for example.

B Cervical spondylosis and disc prolapse

A large central disc prolapse could present with sudden quadriparesis and neck pain, but the diplopia and nystagmus could not be explained.

C Subarachnoid haemorrhage

A 42-year-old man attends the clinic with his 72-year-old father, who is treated with L-dopa for Parkinson's. He tells you that his uncle is also affected by Parkinson's and is worried that he may develop the condition.

Which of the following signs is most associated with early Parkinson's?

A	Somnambulance
B	Rapid eye movement (REM) sleep behaviour disorder
C	Hypnogogic hallucinations
D	Day time somnolence
E	Insomnia

B Rapid eye movement (REM) sleep behaviour disorder

REM sleep behaviour disorder is associated with imperfect abolition of muscle tone during REM sleep, and is potentially caused by lesions in the area of the pons responsible for REM sleep atonia. It is identified as an early feature of idiopathic Parkinson's disease and patients may be seen to kick, laugh, punch or fight invisible enemies during REM sleep. They do, however, rarely actually get up out of bed and walk. Interestingly, the side most affected by Parkinson's appears to adopt near normal movement during REM sleep (see weblink below).

A Somnambulance

Sleepwalking is more commonly seen in children and may be associated with other diagnoses such as sleep disorder breathing.

C Hypnogogic hallucinations

breathing?

C Hypnogogic hallucinations

Hypnogogic hallucinations are a normal phenomenon associated with the transition between wakefulness and sleep, and are not linked to a diagnosis of Parkinson's disease.

D Day time somnolence

Daytime somnolence is a later feature of Parkinson's disease, related to the development of more pervasive REM sleep disorder.

E Insomnia

Although late Parkinson's may be associated with insomnia and daytime somnolence, in the early stages of the disease REM sleep disorder is a more prominent feature.

21167

Rate this question:

A 63-year-old plumber was referred to a Neurology Clinic for investigation of difficulty in walking. His wife reported that he has been more irritable over the past 6 months and has become increasingly forgetful, often missing appointments, losing personal items and having difficulties remembering the content of recent conversations. More recently, he has accused his neighbours of standing outside continuously watching his house and is now reluctant to go outdoors alone.

On examination, his blood pressure was 148/78 mmHg lying, 112/72 mmHg standing. Bedside cognitive tests demonstrated a Mini-Mental State Examination score of 18 out of 30 with deficits in orientation, concentration and recall. Facial expression was reduced.

Examination of eye movements demonstrated mild limitation of up-gaze. Tone was increased in the limbs, with symmetrical reflexes and bilateral down-going plantars. There was impairment of rapid alternating finger movements and evidence of

Examination of eye movements demonstrated mild limitation of up-gaze. Tone was increased in the limbs, with symmetrical reflexes and bilateral down-going plantars. There was impairment of rapid alternating finger movements and evidence of micrographia. Gait demonstrated reduced stride length and arm swing.

What would be the next most appropriate investigation?

A	Anal sphincter electromyography
B	Blood film and serum lead level
C	Cortical brain biopsy
D	Fluoridopa positron emission tomography of the brain
E	Magnetic resonance imaging of the brain

a Neurology Clinic for investigation of difficulty in walking. His wife reported that he has been more irritable over the past 6 months and has become increasingly forgetful, often missing appointments, losing personal items and having difficulties remembering the content of recent conversations. More recently, he has accused his neighbours of standing outside continuously watching his house and is now reluctant to go outdoors alone.

On examination, his blood pressure was 148/78 mmHg lying, 112/72 mmHg standing. Bedside cognitive tests demonstrated a Mini-Mental State Examination score of 18 out of 30 with deficits in orientation, concentration and recall. Facial expression was reduced.

Examination of eye movements demonstrated mild limitation of up-gaze. Tone was increased in the limbs, with symmetrical reflexes and bilateral down-going plantars. There was impairment of rapid alternating finger movements and evidence of micrographia. Gait demonstrated

E Magnetic resonance imaging of the brain

The clinical scenario is suggestive of dementia with Lewy bodies (DLB). This condition is characterised by fluctuating cognitive impairment, extrapyramidal symptoms and visual hallucinations; paranoid ideation may also be present. Autonomic symptoms are commonly seen. The diagnosis can only be confirmed by post-mortem examination, or cortical brain biopsy in life – but this is not routinely performed. MRI brain is the most appropriate investigation here; all patients with symptoms of dementia must undergo structural brain imaging. This helps to exclude alternative pathologies such as chronic subdurals or tumours. MRI also allows assessment of atrophy, which can be helpful in distinguishing the dementias. For example, medial temporal lobe atrophy is common in Alzheimer's, frontal atrophy in frontotemporal dementia and anterior temporal volume loss in semantic dementia. In DLB there is no focal atrophy, just a

DLB there is no focal atrophy, just a generalised pattern of volume loss.

A	Anal sphincter electromyography

Anal sphincter electromyography may be clinically useful in the evaluation of patients with urinary, bowel and sexual dysfunction. It is also sometime s used in the diagnosis of multiple systems atrophy (MSA), but is not useful for the diagnosis in this case.

B	Blood film and serum lead level

Chronic lead poisoning can of course lead to behavioural changes similar to those seen here, including irritability and difficulty sleeping. However, there are usually other neurological signs such as a motor neuropathy.

C	Cortical brain biopsy

This is very rarely performed and

those seen here, including irritability and difficulty sleeping. However, there are usually other neurological signs such as a motor neuropathy.

C	Cortical brain biopsy

This is very rarely performed and generally has a low diagnostic yield. In the past it has been used in the diagnosis of prion disease, but advances in MRI scanning and CSF assays have made it a largely unnecessary test.

D	Fluoridopa positron emission tomography of the brain

Whilst dynamic changes in fluoridopa PET scanning may be seen, they are not definitive with respect to confirming the diagnosis and abnormalities would be seen in any degenerative parkinsonian disorder. In addition, this imaging test is not widely available.

A 45-year-old woman presented with a 6-month history of difficulty in swallowing. She had been well until 18 months ago when she noticed she could not hear as well in her left ear. Shortly after this, she noticed she could hear her heart beating loudly in her left ear. These problems had continued over the last year and a half but in the last 6 months she had also noticed problems in swallowing, particularly liquids. Her husband had commented that over the same time period her voice was much hoarser than it had been previously.

On examination she had a hoarse voice, wasting of the sternocleidomastoid and trapezius on the left and a decreased gag reflex. Rinne's test showed AC > BC on the right and BC > AC on left (AC = air conduction, BC = bone conduction); Weber's test lateralised to the left ear. The remainder of the neurological examination was normal.

What is the most likely diagnosis?

6:41
tps://mypastest.pastest.com 14

than it had been previously.

On examination she had a hoarse voice, wasting of the sternocleidomastoid and trapezius on the left and a decreased gag reflex. Rinne's test showed AC > BC on the right and BC > AC on left (AC = air conduction, BC = bone conduction); Weber's test lateralised to the left ear. The remainder of the neurological examination was normal.

What is the most likely diagnosis?

A	Multiple sclerosis
B	Carcinomatous meningitis
C	Acoustic neuroma
D	Motor neurone disease
E	Glomus jugulare tumour

A 45-year-old woman presented with a 6-month history of difficulty in swallowing. She had been well until 18 months ago when she noticed she could not hear as well in her left ear. Shortly after this, she noticed she could hear her heart beating loudly in her left ear. These problems had continued over the last year and a half but in the last 6 months she had also noticed problems in swallowing, particularly liquids. Her husband had commented that over the same time period her voice was much hoarser than it had been previously.

On examination she had a hoarse voice, wasting of the sternocleidomastoid and trapezius on the left and a decreased gag reflex. Rinne's test showed AC > BC on the right and BC > AC on left (AC = air conduction, BC = bone conduction); Weber's test lateralised to the left ear. The remainder of the neurological examination was normal.

What is the most likely diagnosis?

E Glomus jugulare tumour

This combination of cranial nerve lesions (IX, X, XI) is often caused by a jugular foramen syndrome, and in this case it is most likely to be secondary to a glomus jugulare tumour. The onset of conductive hearing loss and pulsatile tinnitus in the left ear about one year before the onset of other cranial nerve signs is common in glomus jugulare tumours. These vascular, slow-growing tumours are rare, the annual incidence being approximately one in a million. However, they are still the most frequently found tumour of the middle ear. They are more common in women, and the age of onset is normally between 40 and 70 years of age.

A Multiple sclerosis

The lateralising signs here with gradually progressive onset of symptoms count against a diagnosis of MS, and optic neuritis, a presenting feature in many patients with MS, is

The lateralising signs here with gradually progressive onset of symptoms count against a diagnosis of MS, and optic neuritis, a presenting feature in many patients with MS, is absent here.

B Carcinomatous meningitis

The prolonged course of symptoms, coupled with lateralising signs, counts against a diagnosis of carcinomatous meningitis.

C Acoustic neuroma

Tinnitus and hearing loss are presenting features of acoustic neuroma, but tinnitus is absent here.

D Motor neurone disease

Motor neurone disease presents with a mix of upper and lower motor neurone signs, without any sensory deficit.

A 29-year-old man presents to the Accident and Emergency Department complaining of progressive weakness of both legs that has been getting progressively worse over the last 2 weeks. The weakness appears to be symmetrical and he is now struggling to walk. He is also complaining of pain in his lower back and buttocks. He has noticed that the left side of his face has become weak and this is evident in his speech, as the left mouth does not move properly and his speech sounds slurred.

On further questioning, he reports that he has recently recovered from a flu-like illness. He admits to intermittent use of intravenous (IV) heroin.

Which of the following organisms is the most likely cause of this clinical picture?

A	*Streptococcus pneumoniae*
B	Human immunodeficiency virus (HIV)

in his lower back and buttocks. He has noticed that the left side of his face has become weak and this is evident in his speech, as the left mouth does not move properly and his speech sounds slurred.

On further questioning, he reports that he has recently recovered from a flu-like illness. He admits to intermittent use of intravenous (IV) heroin.

Which of the following organisms is the most likely cause of this clinical picture?

A	*Streptococcus pneumoniae*
B	Human immunodeficiency virus (HIV)
C	*Mycobacterium tuberculosis*
D	*Shigella*
E	*Yersinia*

A 29-year-old man presents to the Accident and Emergency Department complaining of progressive weakness of both legs that has been getting progressively worse over the last 2 weeks. The weakness appears to be symmetrical and he is now struggling to walk. He is also complaining of pain in his lower back and buttocks. He has noticed that the left side of his face has become weak and this is evident in his speech, as the left mouth does not move properly and his speech sounds slurred.

On further questioning, he reports that he has recently recovered from a flu-like illness. He admits to intermittent use of intravenous (IV) heroin.

Which of the following organisms is the most likely cause of this clinical picture?

Your answer was correct

A *Streptococcus pneumoniae*

B Human immunodeficiency virus (HIV)

This patient is at risk of contracting HIV, given his use of IV heroin. HIV seroconversion illness is associated with Guillain–Barré syndrome (GBS) and HIV can also cause a radiculitis, mimicking GBS. Classic GBS is an acute, ascending, progressive neuropathy characterised by flaccid limb weakness, paraesthesia and hyporeflexia. In severe cases, muscle weakness may involve the respiratory muscles leading to progressive respiratory failure, which is the major cause of mortality. Autonomic involvement can also occur leading to cardiac arrhythmia. GBS is thought of as a post-infectious disorder. The body mounts a misdirected immune response against the nervous system due to molecular mimicry. Two-thirds of patients have a history of gastrointestinal (GI) or respiratory infection from 1–4 weeks before the onset of weakness. Common infections preceding GBS include *Campylobacter*

preceding GBS include *Campylobacter jejuni* (25%), cytomegalovirus (CMV), Epstein–Barr virus (EBV), influenza A virus, *Mycoplasma pneumoniae*, HIV and *Haemophilus influenzae*. Other infections can mimic GBS, including diphtheria and Lyme's disease.

A	*Streptococcus pneumoniae*

Streptococcus pneumoniae can cause pneumonia, sinusitis and meningitis but is not known to cause an acute paralytic neuropathy.

C	*Mycobacterium tuberculosis*

TB has a myriad of neurological manifestations (e.g. intracranial abscess, arachnoiditis, meningitis) and this patient might be considered at high risk of contracting TB. If the syndrome was confined to the legs, one might consider Pott's disease of the spine, or arachnoiditis, as a cause. However, TB is not a common cause of an acute paralytic neuropathy.

high risk of contracting TB. If the syndrome was confined to the legs, one might consider Pott's disease of the spine, or arachnoiditis, as a cause. However, TB is not a common cause of an acute paralytic neuropathy.

D	*Shigella*

This patient has GBS. Species within the *Shigella* genus can cause dysentery, and are also associated with haemolytic uraemic syndrome. However, *Shigella* is not associated with an acute paralytic neuropathy.

E	*Yersinia*

Species within the *Yersinia* genus are associated with diarrhoeal illnesses (yersiniosis), Crohn's disease and reactive arthritis. *Yersinia* is not commonly associated with any neurological manifestations.

6085

Rate this question:

A 66-year-old retired soldier presents to the clinic for assessment of difficulty walking. He describes 2 years of progressive gait disturbance, commenting that he often falls at night or on uneven surfaces. You note he had defaulted from previous clinic appointments. He admits that today's attendance was prompted by new-onset double vision. Review of his case sheet reveals an episode of admission to the army hospital with fever, arthralgia, headache and neck stiffness. At that time, a provisional diagnosis of viral meningitis was made. He is due to see the urology team for investigation of urinary symptoms.

On examination, you note irregular tonic pupils, lower limb areflexia, extensor plantar responses and loss of vibration sense to the hips.

Haematology investigations:

Hb	15.2 g/dl
WCC	6.0×10^9/l
PLT	500×10^9/l

ESR	60 mm/1st h
B_{12}	500 pmol/l (160–900)

CSF investigations:

Appearance	Clear, colourless
Opening pressure	18 mmHg (6–20)
WCC	30/mm, mostly lymphocytes
Protein	0.8 g/l (<0.45 g/l)

Other investigations:

Venereal Disease Research Laboratory (VDRL) slide test	-
Oligoclonal bands	-

What further test would you perform?

A	MRI lumbar spine
B	Anti-neutrophil cytoplasmic antibody

7:10
tps://mypastest.pastest.com

Venereal Disease Research Laboratory (VDRL) slide test	-
Oligoclonal bands	-

What further test would you perform?

A	MRI lumbar spine
B	Anti-neutrophil cytoplasmic antibody
C	Schilling test
D	*Treponema pallidum* haemagglutination
E	CSF polymerase chain reaction (PCR) for Japanese encephalitis

to the clinic for assessment of difficulty walking. He describes 2 years of progressive gait disturbance, commenting that he often falls at night or on uneven surfaces. You note he had defaulted from previous clinic appointments. He admits that today's attendance was prompted by new-onset double vision. Review of his case sheet reveals an episode of admission to the army hospital with fever, arthralgia, headache and neck stiffness. At that time, a provisional diagnosis of viral meningitis was made. He is due to see the urology team for investigation of urinary symptoms.

On examination, you note irregular tonic pupils, lower limb areflexia, extensor plantar responses and loss of vibration sense to the hips.

Haematology investigations:

Hb	15.2 g/dl
WCC	6.0×10^9/l
PLT	500×10^9/l
ESR	60 mm/1st h

D *Treponema pallidum* haemagglutination

This patient has absent ankle reflexes and upgoing plantars. Possible causes include syringomyelia, Friedreich's ataxia, motor neurone disease, conus medullaris lesion, subacute degeneration of the cord and the taboparesis form of tertiary neurosyphilis. Taboparesis is the answer in this case. The admission with 'viral meningitis' probably represented the secondary stage of syphilitic infection. His presenting complaint of difficulty walking in the dark is classical of severe proprioceptive loss. Other neurological features of late syphilis include cranial nerve palsies, cognitive impairment, and autonomic dysfunction. Diagnosis of syphilis in the late stages can cause some difficulty. The non-specific Venereal Disease Research Laboratory (VDRL) assay gives a number of false positives. Furthermore VDRL titre varies with disease activity and may be low in late disease – only 50% of confirmed cases

have a positive cerebrospinal fluid (CSF) VDRL. The more specific treponemal haemagglutination test will make the diagnosis. Treatment is high-dose penicillin.

A	MRI lumbar spine

A lumbar spine problem is inconsistent with both the double vision seen here and the CSF lymphocytosis.

B	Anti-neutrophil cytoplasmic antibody

Apart from the CNS features seen here there are no other features to suggest ANCA-positive vasculitis, and so ANCA isn't a useful investigation in this case.

C	Schilling test

B_{12} is within the normal range, and hence a Schilling test would not be informative here.

B	Anti-neutrophil cytoplasmic antibody

Apart from the CNS features seen here there are no other features to suggest ANCA-positive vasculitis, and so ANCA isn't a useful investigation in this case.

C	Schilling test

B_{12} is within the normal range, and hence a Schilling test would not be informative here.

E	CSF polymerase chain reaction (PCR) for Japanese encephalitis

Japanese encephalitis is mosquito-borne and presents with symptoms of encephalitis after an incubation period of 5–15 days.

7341

Rate this question:

Next Question

A 52-year-old builder presents to his general practitioner having developed weakness of his right hand. He complains of reduced grip, which he has noticed significantly while at work. His symptoms have come on over a period of months following an accident when he fell from some scaffolding. More recently he has noticed some slight weakness and pain of his right shoulder, particularly when trying to lift building materials above his head. He has a history of asthma and is a smoker of 40 cigarettes per day. He complains that his breathing has been steadily worsened over the last few weeks particularly when lying in bed.

On examination, he is of slim build. Chest examination is normal and there is a full range of movement at the neck. There is evidence of dorsal interossei wasting over the right hand. In addition, there is evidence of wasting affecting the thenar eminence. Tone is reduced at the right wrist and elbow, and triceps jerk is absent. The bicep and supinator jerks are present with re-enforcement.

On examination of power, there is significantly reduced right wrist extension, finger flexion and extension and opposition of the thumb. There is some slight weakness affecting right shoulder abduction, but rhomboid testing is normal.
There is some reduced sensation affecting the right middle, ring and little finger and the medial aspect of the forearm. The rest of the neurological examination is normal

Chest X-ray shows hyperinflated lung fields and slightly raised right diaphragm.

Electromyogram/nerve conduction studies show:

- Fibrillation potentials and positive waves affecting small muscles of right hand and wrist extensors
- Sensory nerve action potentials absent
- No abnormalities in the left arm.

positive waves affecting small muscles of right hand and wrist extensors

- Sensory nerve action potentials absent
- No abnormalities in the left arm.

In view of the above history and findings, what is the likely location of the lesion in this patient?

A	Ulnar nerve palsy
B	C8 and T1 root lesion
C	Brachial plexopathy
D	Anterior horn cell disease
E	High cervical myelopathy

7202

Submit

period of months following an accident when he fell from some scaffolding. More recently he has noticed some slight weakness and pain of his right shoulder, particularly when trying to lift building materials above his head. He has a history of asthma and is a smoker of 40 cigarettes per day. He complains that his breathing has been steadily worsened over the last few weeks particularly when lying in bed.

On examination, he is of slim build. Chest examination is normal and there is a full range of movement at the neck. There is evidence of dorsal interossei wasting over the right hand. In addition, there is evidence of wasting affecting the thenar eminence. Tone is reduced at the right wrist and elbow, and triceps jerk is absent. The bicep and supinator jerks are present with re-enforcement.

On examination of power, there is significantly reduced right wrist extension, finger flexion and extension and opposition of the thumb. There is some slight weakness affecting right shoulder abduction, but rhomboid

C Brachial plexopathy

This patient presents with a history consistent with traumatic brachial plexopathy following a fall. He has a distribution of weakness, which does not fit with an individual mononeuropathy, and the root levels involved are C5–T1.

B C8 and T1 root lesion

Involvement of muscles such as the shoulder abductors means this must be more widespread than just C8 and T1 roots. Absent sensory nerve action potentials on NCS point to a lesion distal to the dorsal root ganglion. Therefore, multiple root lesions are unlikely in this patient and the lesion must lie within the brachial plexus.

A Ulnar nerve palsy

The distribution of weakness and sensory loss are wider than simply ulnar innervated structures (small

T1 roots. Absent sensory nerve action potentials on NCS point to a lesion distal to the dorsal root ganglion. Therefore, multiple root lesions are unlikely in this patient and the lesion must lie within the brachial plexus.

A	Ulnar nerve palsy

The distribution of weakness and sensory loss are wider than simply ulnar innervated structures (small muscles of hand and sensation to medial border of hand).

D	Anterior horn cell disease

Whilst this diagnosis could cause progressive weakness and wasting, there would be no sensory signs or sensory problems on neurophysiology.

E	High cervical myelopathy

This would cause a spastic weakness of the upper and lower limbs.

A 26-year-old man, recently arrived in the UK from New York, attends the Accident and Emergency Department. He has a past history of insulin-dependent diabetes mellitus. He describes a few days of fever, headache and myalgia. Admission was prompted by worsening headache and back pain. While waiting in the medical receiving unit he becomes progressively drowsier.

Examination revealed flaccid paralysis and depressed tendon reflexes. He was reviewed by the intensive care team and arrangements were made for ventilation. A computerised tomography (CT) brain is performed, that is normal.

Cerebrospinal fluid examination:

Protein	0.9 g/l (< 0.45 g/l)
Glucose	4 mmol/l
WCC	230/mm^3 (mostly lymphocytes)

Blood testing:

PLT	600 × 10^9/l (150–400)
WCC	12 × 10^9/l (4–11)
Na^+	136 mmol/l (137–144)
K^+	4.7 mmol/l (3.5–4.9)
Creatinine	120 µmol/l (60–110)
Urea	7.0 mmol/l (2.5–7.5)
Glucose	6.0 mmol/l

What is the most likely infective process?

A	Lyme disease
B	West Nile disease
C	Human immunodeficiency virus
D	Tuberculosis
E	Lassa fever

A 26-year-old man, recently arrived in the UK from New York, attends the Accident and Emergency Department. He has a past history of insulin-dependent diabetes mellitus. He describes a few days of fever, headache and myalgia. Admission was prompted by worsening headache and back pain. While waiting in the medical receiving unit he becomes progressively drowsier.

Examination revealed flaccid paralysis and depressed tendon reflexes. He was reviewed by the intensive care team and arrangements were made for ventilation. A computerised tomography (CT) brain is performed, that is normal.

Cerebrospinal fluid examination:

Protein	0.9 g/l (< 0.45 g/l)
Glucose	4 mmol/l
WCC	230/mm^3 (mostly lymphocytes)

Blood testing:

B West Nile disease

West Nile virus (WNV) is a single-stranded RNA flavivirus transmitted via the culex mosquito. This previously 'tropical' disease has become topical in recent years following a large-scale outbreak in the New York area. The virus has spread rapidly, with reports of infection across the continent. According to the US Centers for Disease Control and Prevention (CDC), over 15,000 people in the US have tested positive for WNV infection since 1999. To date there have been over 500 deaths; recent hurricanes and subsequent damage to water infrastructure may increase these numbers. The number of subclinical or mild infections not presenting to hospital is likely to be much higher still. Incidence of neurological involvement is usually quoted at around 1%, although some suggest that the incidence of meningoencephalitis in the USA is higher than in other parts of the world. Risk factors for neurological involvement include increasing age, and any form of immunosuppression

and any form of immunosuppression. The usual picture is of sudden-onset fever and myalgia with nausea and vomiting and a non-specific rash. Transient meningitis is occasionally seen. Frank meningo-encephalitis is seen in two-thirds of cases with neurological involvement; 15% progress to coma. A flaccid paralysis similar to acute Guillain–Barré is increasingly recognised. Diagnosis is initially clinical with subsequent serological confirmation. Treatment is supportive; results from trials of antivirals have yielded disappointing results.

E	Lassa fever

Lassa is acute viral haemorrhagic fever, and is endemic amongst the rodent population of West Africa. Ribavirin, if given early enough, may be an effective intervention.

A	Lyme disease

Lyme disease is associated with a tick

population of West Africa. Ribavirin, if given early enough, may be an effective intervention.

A Lyme disease

Lyme disease is associated with a tick bite, and we're given no evidence to support exposure to a tick such as an eschar or erythema chronicum migrans. As well as encephalitis, mononeuritis and heart block are possible features.

C Human immunodeficiency virus

HIV is unlikely given the short history of illness and no significant prodrome.

D Tuberculosis

TB meningitis is lymphocytic, and the absence of chest symptoms or other features such as chronic night sweats counts against TB infection.

A 27-year-old woman with recently diagnosed juvenile Parkinson's disease was taking levodopa + carbidopa (125 mg qid) with fair control of her symptoms. She was brought to the Emergency Department with high fever and a confusional state of 2 days' duration. Apparently she has been refusing medication and her mother wonders whether she has a urinary tract infection.

On examination, pulse rate was 120/min and blood pressure was 80/60 mmHg. Temperature was 40 °C. Diaphoresis was noted. She was drowsy but answered questions relevantly. Cranial nerves were unremarkable. Her limbs were rigid. Tendon reflexes were normal (++/++). Plantar responses were flexor.

Investigations:

WCC	8.0×10^9/l
Hb	11.5 g/dl
Urea	5.0 mmol/l
Creatinine	140 umol/l

Cerebrospinal fluid (CSF) examination:

White cells	2 lymphocytes cells/mm^3
Red cells	20 red cells/ mm^3
Protein	400 mg/l
Glucose	7.0 mmol/l (blood glucose 7.3mmol/l)

What is the most likely diagnosis?

A	Malignant hyperthermia
B	End of dose wearing-off effect
C	Stiff person syndrome
D	Peak of dose dyskinesia
E	Neuroleptic malignant-like syndrome

A 27 year old woman with recently diagnosed juvenile Parkinson's disease was taking levodopa + carbidopa (125 mg qid) with fair control of her symptoms. She was brought to the Emergency Department with high fever and a confusional state of 2 days' duration. Apparently she has been refusing medication and her mother wonders whether she has a urinary tract infection.

On examination, pulse rate was 120/min and blood pressure was 80/60 mmHg. Temperature was 40 °C. Diaphoresis was noted. She was drowsy but answered questions relevantly. Cranial nerves were unremarkable. Her limbs were rigid. Tendon reflexes were normal (++/++). Plantar responses were flexor.

Investigations:

WCC	8.0×10^9/l
Hb	11.5 g/dl
Urea	5.0 mmol/l
Creatinine	140 μmol/l

E Neuroleptic malignant-like syndrome

A clinical picture termed neuroleptic malignant-like syndrome has been described in patients with Parkinson's disease (PD) who suddenly stop their L-dopa treatment. The sudden withdrawal of the drug is deemed to lead to an acute deficiency state in a patient who has an iatrogenic increase in dopaminergic transmission. The mortality is 15–30% if it is not recognised and treated properly. Neuroleptic malignant syndrome consists of generalised rigidity, hyperthermia, stupor, unstable blood pressure and profuse sweating. It is most commonly associated with anti-psychotic neuroleptic medication. Serum creatine phosphokinase may rise up to 60 000 units/l and can lead to myoglobinuria and kidney disease. Treatment should be started early, when consciousness is first altered and temperature is rising. Treatment is given by reinstituting dopaminergic medication.

A	Malignant hyperthermia

This is a rare genetic disorder that occurs in the context of inhaled anaesthetic agents.

B	End of dose wearing-off effect

This is a type of motor fluctuation seen in patients with Parkinson's disease, typically on high levodopa doses. As the effect of the dose wears off the patient feels increasing Parkinsonian symptoms such as tremor, rigidity and bradykinesia. It can lead to 'freezing'. The next dose of levodopa reverses the symptoms temporarily. Such motor fluctuations are one of the main problems with long-term levodopa usage.

C	Stiff person syndrome

This is a presumed autoimmune disease associated with anti-GAD antibodies. The condition in associated

fluctuations are one of the main problems with long-term levodopa usage.

C	Stiff person syndrome

This is a presumed autoimmune disease associated with anti-GAD antibodies. The condition in associated with axial and appendicular increased tone, and constant muscle over-activity can be detected on EMG.

D	Peak of dose dyskinesia

This is a type of motor fluctuation seen in patients with Parkinson's disease, typically on high levodopa doses. After the patient has taken their levodopa dose they develop involuntary dyskinetic movements that then resolve as the dose wears off. It can be seen in conjunction with end of dose wearing-off.

7224

Rate this question:

A 22-year-old man with no past medical history presents to the Neurology Clinic complaining of muscle pain. He describes severe bilateral cramping calf pain on minimal exercise. This has been present since his late teens and as such he has avoided exercise.

Recently, he has attended the local gym to try and lose weight, but attempts at exercise have been hampered by the pain. He does note that if he perseveres with exercise the pain settles. He has noticed passing dark urine in the evenings following a prolonged bout of exercise.

Which of the following investigations will be most useful in this patient?

A	Lumbar spine magnetic resonance imaging (MRI)
B	Lower limb angiogram
C	Creatine kinase (CK)

his late teens and as such he has avoided exercise.

Recently, he has attended the local gym to try and lose weight, but attempts at exercise have been hampered by the pain. He does note that if he perseveres with exercise the pain settles. He has noticed passing dark urine in the evenings following a prolonged bout of exercise.

Which of the following investigations will be most useful in this patient?

A	Lumbar spine magnetic resonance imaging (MRI)
B	Lower limb angiogram
C	Creatine kinase (CK)
D	Muscle biopsy
E	Provocative exercise test

A 22-year-old man with no past medical history presents to the Neurology Clinic complaining of muscle pain. He describes severe bilateral cramping calf pain on minimal exercise. This has been present since his late teens and as such he has avoided exercise.

Recently, he has attended the local gym to try and lose weight, but attempts at exercise have been hampered by the pain. He does note that if he perseveres with exercise the pain settles. He has noticed passing dark urine in the evenings following a prolonged bout of exercise.

Which of the following investigations will be most useful in this patient?

Your answer was correct

A	Lumbar spine magnetic resonance imaging (MRI)
B	Lower limb angiogram

D Muscle biopsy

The syndrome described is McArdle's disease (myophosphorylase deficiency or Glycogen Storage Disease V). It is the most common of the Glycogen Storage Diseases, characterised by impaired glycogen metabolism in skeletal muscle. It is caused by an autosomal recessive mutation in the PYGM gene, located on chromosome 11.

It presents in adolescence or early adulthood with early exercise intolerance, fatigue, myalgia, cramps, muscle swelling and fixed weakness. A 'second wind' phenomenon is recognised in which there is relief of symptoms after a few minutes of rest, due to increased blood flow and delivery of free fatty acids and activation of fatty acid metabolism.

Investigation findings include raised resting CK and myoglobinuria (causing dark urine), however these are non-specific. Definitive diagnosis can be achieved through genetic sequencing

achieved through genetic sequencing and muscle biopsy. Sequencing of the *PYGM* gene is readily available and is the most efficient and least invasive means of confirming the diagnosis.

Treatment includes a carbohydrate-rich diet and ingestion of sucrose 5 minutes before all types of aerobic exercise.

A	Lumbar spine magnetic resonance imaging (MRI)

Although lumbar canal stenosis is in the differential of bilateral exercise-induced leg pain, the patient's age and history would make this very unlikely. Spinal claudication usually develops over time, is intermittent and exacerbated by particular postures or activities and relieved by rest or lumbar flexion.

B	Lower limb angiogram

Although vascular claudication is in the differential of bilateral exercise-

B	Lower limb angiogram

Although vascular claudication is in the differential of bilateral exercise-induced leg pain, the patient's age and lack of risk factors would make this very unlikely.

C	Creatine kinase (CK)

Myopathy is in the differential diagnosis for this patient, and a raised CK can narrow the differential diagnosis. However, it is not specific and therefore not the most useful investigation offered here.

E	Provocative exercise test

Exercising the muscle to induce symptoms and raise CK is not recommended as it may precipitate rhabdomyolysis.

7342

Rate this question:

A 21-year-old woman presents to her general practitioner (GP) complaining of headaches and occasional greying of vision, worse upon awakening. She also suffers from occasional dizziness and nausea, but which are independent of the headache. She is otherwise fit and well and the only medication she takes is the oral contraceptive pill.

On examination, she is noted to be overweight. General examination is normal but on ophthalmoscopy she is noted to have bilateral but asymmetrical optic disc swelling. A computed tomography (CT) scan of the head and a venogram are performed, which rule out the presence of a space-occupying lesion or venous sinus thrombosis. She then undergoes a lumbar puncture which shows a high opening pressure but which is otherwise normal in colour and clarity. The results from the laboratory investigations on the cerebrospinal fluid (CSF) are all within normal limits, as are her routine blood tests.

or venous sinus thrombosis. She then undergoes a lumbar puncture which shows a high opening pressure but which is otherwise normal in colour and clarity. The results from the laboratory investigations on the cerebrospinal fluid (CSF) are all within normal limits, as are her routine blood tests.

Which of the following treatments is not indicated in the medical management of this patient?

A	Weight loss
B	Discontinuation of her use of the oral contraceptive pill
C	Oral acetazolamide
D	Topiramate
E	A short course of oral corticosteroids

medication she takes is the oral contraceptive pill.

On examination, she is noted to be overweight. General examination is normal but on ophthalmoscopy she is noted to have bilateral but asymmetrical optic disc swelling. A computed tomography (CT) scan of the head and a venogram are performed, which rule out the presence of a space-occupying lesion or venous sinus thrombosis. She then undergoes a lumbar puncture which shows a high opening pressure but which is otherwise normal in colour and clarity. The results from the laboratory investigations on the cerebrospinal fluid (CSF) are all within normal limits, as are her routine blood tests.

Which of the following treatments is not indicated in the medical management of this patient?

Your answer was incorrect

E | A short course of oral corticosteroids

Although corticosteroids have been recommended in the past for IIH, they are usually avoided because they can cause weight gain; steroid withdrawal can cause severe rebound headaches associated with visual loss, and there are systemic side effects from prolonged use. In the setting of acute visual loss, a short course of intravenous corticosteroids may be useful as a temporary measure prior to surgical intervention.

D | Topiramate

Topiramate is an antiepileptic that inhibits carbonic anhydrase activity. It is commonly used in the pharmacological management of IIH and is particularly useful in patients with coexistent migraine. It has the added benefit of weight loss. Case studies show that is has a similar efficacy to acetazolamide. Unfortunately, like many antiepileptics,

Unfortunately, like many antiepileptics, it has teratogenic potential and therefore appropriate contraception must be taken in women of child-bearing age.

A	Weight loss

This patient has idiopathic intracranial hypertension (IIH). Although the vast majority of patients with IIH are obese, the evidence for weight loss as a treatment for IIH is mainly based on uncontrolled or small retrospective studies. As there is a suggestion of improvement in many patients and there are other health benefits to weight loss, all patients with IIH are recommended to lose weight.

B	Discontinuation of her use of the oral contraceptive pill

There is no clear relationship between oestrogen and the development of IIH. However, common practice is to withdraw the OCP in patients with IIH

weight loss, all patients with IIH are recommended to lose weight.

B	Discontinuation of her use of the oral contraceptive pill

There is no clear relationship between oestrogen and the development of IIH. However, common practice is to withdraw the OCP in patients with IIH especially if there is a strong temporal correlation. In IIH patients wishing to start contraception there is no absolute contraindication to the combined pill (unless coexistent migraine with aura), but more frequent follow-up should be arranged early on.

C	Oral acetazolamide

Carbonic anhydrase inhibitors and loop diuretics are the mainstay of pharmacological treatment for IIH. Acetazolamide is a carbonic anhydrase inhibitor, which acts by reducing CSF production.

A 32-year-old woman presents to the Emergency Department with a sudden-onset left-sided hemiparesis left facial weakness and left-sided limb twitching. In the ED she was noted to be drowsy. Prior to the event, she had been out shopping with her sister when she had started to develop one of her migraine attacks and vomiting.

Her past medical history included troublesome migraine with aura, for which she was taking pizotifen and sumatriptan, and impaired glucose tolerance diagnosed several years ago. She had recently visited her general practitioner (GP), complaining of progressive weakness in her legs.

On examination, she had short stature and was initially drowsy, but easily rousable. Her temperature was 37.3 ºC, blood pressure 135/75 mmHg, pulse 88/min and body mass index 21.2. There was evidence of a left UMN (upper motor neuron) facial weakness. Fundoscopy was normal.

On examination of the limbs, there was

On examination of the limbs, there was evidence of proximal muscle weakness of the legs and arms, and associated left-sided pyramidal tract signs: all left sided reflexes were pathologically brisk and the left plantar response was extensor. There was no myoclonus. She was investigated with blood tests and a magnetic resonance imaging (MRI)/MRV (MR venogram) brain scan.

Investigations:

Hb	12.5g/dl
WCC	11×10^9/l
PLT	245×10^9/l
Glucose	11.4 mmol/l
Na^+	135 mmol/l
K^+	3.3 mmol/l
Urea	6.4 mmol/l
Creatinine	128 μmol/l
Lactate	3.0 mmol/l (0.6–1.8)

MRI brain scan showed several areas of

A 32-year-old woman presents to the Emergency Department with a sudden-onset left-sided hemiparesis left facial weakness and left-sided limb twitching. In the ED she was noted to be drowsy. Prior to the event, she had been out shopping with her sister when she had started to develop one of her migraine attacks and vomiting.

Her past medical history included troublesome migraine with aura, for which she was taking pizotifen and sumatriptan, and impaired glucose tolerance diagnosed several years ago. She had recently visited her general practitioner (GP), complaining of progressive weakness in her legs.

On examination, she had short stature and was initially drowsy, but easily rousable. Her temperature was 37.3 ºC, blood pressure 135/75 mmHg, pulse 88/min and body mass index 21.2. There was evidence of a left UMN (upper motor neuron) facial weakness. Fundoscopy was normal.

On examination of the limbs, there was evidence of proximal muscle weakness

of the legs and arms, and associated left-sided pyramidal tract signs: all left sided reflexes were pathologically brisk and the left plantar response was extensor. There was no myoclonus. She was investigated with blood tests and a magnetic resonance imaging (MRI)/MRV (MR venogram) brain scan.

Investigations:

Hb	12.5g/dl
WCC	11×10^9/l
PLT	245×10^9/l
Glucose	11.4 mmol/l
Na^+	135 mmol/l
K^+	3.3 mmol/l
Urea	6.4 mmol/l
Creatinine	128 μmol/l
Lactate	3.0 mmol/l (0.6–1.8)

MRI brain scan showed several areas of cortical high signal intensity abnormality on T_2-weighted imaging,

abnormality on T_2-weighted imaging, particularly in the occipital lobes. No intracranial haemorrhage or space-occupying lesion was detected. MRV was normal.

In light of the current findings, what is the most likely diagnosis for this patient?

A	Hemiplegic migraine
B	Cerebral venous sinus thrombosis (CVST)
C	MELAS (mitochondrial encephalomyopathy, lactic acidosis and stroke-like episodes)
D	Right anterior circulation infarct
E	CADASIL (cerebral autosomal dominant arteriopathy with subcortical infarcts and leucoencephalopathy

A 32-year-old woman presents to the Emergency Department with a sudden-onset left-sided hemiparesis left facial weakness and left-sided limb twitching. In the ED she was noted to be drowsy. Prior to the event, she had been out shopping with her sister when she had started to develop one of her migraine attacks and vomiting.

Her past medical history included troublesome migraine with aura, for which she was taking pizotifen and sumatriptan, and impaired glucose tolerance diagnosed several years ago. She had recently visited her general practitioner (GP), complaining of progressive weakness in her legs.

On examination, she had short stature and was initially drowsy, but easily rousable. Her temperature was 37.3 ºC, blood pressure 135/75 mmHg, pulse 88/min and body mass index 21.2. There was evidence of a left UMN (upper motor neuron) facial weakness. Fundoscopy was normal.

On examination of the limbs, there was evidence of proximal muscle weakness

C MELAS (mitochondrial encephalomyopathy, lactic acidosis and stroke-like episodes)

This patient presents with a typical history for MELAS. Clues to the diagnosis include history of migraine, glucose intolerance, short stature, proximal myopathy and the current stroke-like event with seizure activity. The magnetic resonance imaging (MRI) scan shows multiple cortical lesions, which do not respect vascular territories. The diagnosis can be confirmed with mitochondrial DNA genetic analysis.

A Hemiplegic migraine

Whilst this could account for the acute event, this diagnosis cannot explain all the other important points in the history and examination.

B Cerebral venous sinus thrombosis (CVST)

It is an important differential diagnosis in a young patient presenting with stroke and seizures. However, one would expect to find a filling defect on MRI and MRV (MR venogram) imaging in this patient.

D	Right anterior circulation infarct

This could produce a left hemiparesis but cannot account for the other features described in the case. In addition, the MRI changes do not suggest this diagnosis.

E	CADASIL (cerebral autosomal dominant arteriopathy with subcortical infarcts and leucoencephalopathy

CADASIL, which causes strokes in young migraineurs, is not associated with myopathy and does not cause a high lactate. Mutations in the NOTCH 3 gene can be found and support the diagnosis.

You assess two new patients in the Cerebrovascular Clinic.

Mrs X is a 68-year-old woman with background hypertension. She has had one episode of presumed left amaurosis fugax one week previously. Carotid Doppler ultrasound scanning shows a 76% stenosis of the left internal carotid.

Mr Y is a 74-year-old man with stable angina and peripheral vascular disease. Three days previously he had a transient episode of dysphasia lasting 20 min. Carotid Doppler ultrasound scanning shows a 75% stenosis of the left internal carotid.

Who would benefit most from carotid endarterectomy?

A	Mrs X
B	Mr Y
C	Mrs X and Mr Y would derive equal benefit

internal carotid.

Mr Y is a 74-year-old man with stable angina and peripheral vascular disease. Three days previously he had a transient episode of dysphasia lasting 20 min. Carotid Doppler ultrasound scanning shows a 75% stenosis of the left internal carotid.

Who would benefit most from carotid endarterectomy?

A	Mrs X
B	Mr Y
C	Mrs X and Mr Y would derive equal benefit
D	Neither patient would benefit
E	A computerised tomography (CT) scan of brain is needed before surgery could be considered

You assess two new patients in the Cerebrovascular Clinic.

Mrs X is a 68-year-old woman with background hypertension. She has had one episode of presumed left amaurosis fugax one week previously. Carotid Doppler ultrasound scanning shows a 76% stenosis of the left internal carotid.

Mr Y is a 74-year-old man with stable angina and peripheral vascular disease. Three days previously he had a transient episode of dysphasia lasting 20 min. Carotid Doppler ultrasound scanning shows a 75% stenosis of the left internal carotid.

Who would benefit most from carotid endarterectomy?

Your answer was incorrect

A	Mrs X

B Mr Y

Carotid endarterectomy has been proven to be of benefit in symptomatic patients with greater than 70% stenosis of carotids (as measured by European Carotid Surgery Trial (ECST) criteria). In meta-analyses of endarterectomy trials the following factors have been shown to correlate with increasing benefit from surgery: male sex; increasing age; increasing medical co-morbidity; a prior hemispheric event (as in this case); ulcerated plaque and early intervention. In short the greater the baseline risk, the more the patient has to gain from surgery versus conservative medical management.

NB: There are two methods for reporting the degree of carotid stenosis that give differing results, derived from the North American Symptomatic Carotid Endarterectomy Trial (NASCET) and the ECST. Both are valid but have different cut-offs – in the NASCET method the level of significant stenosis is set at >50%.

considered

In such patients, who have made a full recovery, CT brain will not add anything to the diagnostic work-up.

A	Mrs X

Due to the 'lower risk' event of amaurosis fugax vs hemispheric TIA, she is in a group likely to have less proven benefit from surgery.

C	Mrs X and Mr Y would derive equal benefit

Mr Y will gain more benefit based on his sex, greater age and the nature of the TIA he suffered.

D	Neither patient would benefit

Given the non-disabling TIA, vascular risk factors and significant stenosis, carotid endarterectomy could be offered to both.

A 50-year-old man is referred by the general surgical outpatient team for assessment. He has been investigated over two years for abdominal pain and loose stool. Upper and lower endoscopy and plain computerised tomography (CT) of the abdomen were unremarkable. An initial diagnosis of irritable bowel syndrome was made. Since then he has been treated in the community for depression.

On returning to the Outpatient Clinic today, he has deteriorated with marked weight loss, obvious cognitive impairment and abnormal facial movement.

On examination, he is drowsy with borderline pyrexia. Enlarged axillary, cervical and femoral nodes are noted. Eye examination reveals up-gaze palsy and pendular oscillation of both eyes, and with each eye movement there is concurrent jaw contraction.

Which investigation would confirm the likely diagnosis?

A Urinary porphyrins

impairment and abnormal facial movement.

On examination, he is drowsy with borderline pyrexia. Enlarged axillary, cervical and femoral nodes are noted. Eye examination reveals up-gaze palsy and pendular oscillation of both eyes, and with each eye movement there is concurrent jaw contraction.

Which investigation would confirm the likely diagnosis?

A	Urinary porphyrins
B	Vitamin E assay
C	HIV test
D	Jejunal biopsy
E	Electroencephalogram

7320

Submit

general surgical outpatient team for assessment. He has been investigated over two years for abdominal pain and loose stool. Upper and lower endoscopy and plain computerised tomography (CT) of the abdomen were unremarkable. An initial diagnosis of irritable bowel syndrome was made. Since then he has been treated in the community for depression.

On returning to the Outpatient Clinic today, he has deteriorated with marked weight loss, obvious cognitive impairment and abnormal facial movement.

On examination, he is drowsy with borderline pyrexia. Enlarged axillary, cervical and femoral nodes are noted. Eye examination reveals up-gaze palsy and pendular oscillation of both eyes, and with each eye movement there is concurrent jaw contraction.

Which investigation would confirm the likely diagnosis?

D Jejunal biopsy

The diagnosis is Whipple's disease. This is a multi-system disorder caused by infection with *Tropheryma whippelii*. Classical features are abdominal pain, steatorrhoea, weight loss and arthropathy. Neurological involvement includes depression, cognitive impairment and peripheral neuropathy. The eye movement disorder described is oculomasticatory myorhythmia, and although occurring in only 20% of cases it is said to be pathognomic. Confirmation of diagnosis is with jejunal biopsy, revealing macrophages positive for periodic acid–Schiff staining and allowing for polymerase chain reaction (PCR) analysis. Treatment is prolonged therapy with an antibiotic that crosses the blood–brain barrier.

C HIV test

Whilst it is always worth considering HIV testing in patients with undiagnosed neurological conditions

undiagnosed neurological conditions (due to the varied ways HIV can affect the nervous system), the features in this case are specific enough to suggest Whipple's disease.

A	Urinary porphyrins

Acute intermittent porphyria can present with acute episodes of abdominal pain and neurological signs, but a chronic, 2-year history of abdominal pain is not seen in this condition.

B	Vitamin E assay

Vitamin E deficiency causes an ataxic syndrome so would not fit with the features of this case.

E	Electroencephalogram

This test very rarely provides a specific diagnosis (possibly with the exception of certain primary generalised epilepsy syndromes) and in a case such as this

A 26-year-old man and his 35-year-old brother attend the clinic. The 26-year-old, who has no significant past medical history, is consulting because of a strong family history of early-onset cognitive change and abnormal movements. Movement disorder was first evident in his older brother 2 years ago. They lost contact with their father when he was arrested for lewd behaviour. The paternal uncle was affected with dementia and committed suicide at the age of 44. Their grandmother was described as being 'odd' in her later years and died in an 'institution'.

On examination of the brother, you note writhing movements of the limbs, neck and trunk. There is spasticity of all four limbs. On cognitive testing, he performs poorly.

Throughout the interview, you note emotional lability. Both brothers are aware of the high chance of a genetic neurodegenerative condition and have consulted a clinical geneticist. They are awaiting the results of genetic analysis. The first brother, who is recently

consulted a clinical geneticist. They are awaiting the results of genetic analysis. The first brother, who is recently married, asks of the implications for his future children.

What advice regarding inheritance do you give him?

A	Only male children will be affected
B	No children will be affected if his wife does not carry an abnormal gene
C	Children are likely to be affected at a younger age than his brother
D	Screening of children is essential to begin treatment early
E	The condition often skips a generation

A 26-year-old man and his 35-year-old brother attend the clinic. The 26-year-old, who has no significant past medical history, is consulting because of a strong family history of early-onset cognitive change and abnormal movements. Movement disorder was first evident in his older brother 2 years ago. They lost contact with their father when he was arrested for lewd behaviour. The paternal uncle was affected with dementia and committed suicide at the age of 44. Their grandmother was described as being 'odd' in her later years and died in an 'institution'.

On examination of the brother, you note writhing movements of the limbs, neck and trunk. There is spasticity of all four limbs. On cognitive testing, he performs poorly.

Throughout the interview, you note emotional lability. Both brothers are aware of the high chance of a genetic neurodegenerative condition and have consulted a clinical geneticist. They are

C Children are likely to be affected at a younger age than his brother

The phenotype described by the family is Huntington's disease. This neurodegenerative condition is characterised by chorea, psychiatric symptoms and cognitive decline. The inheritance is autosomal dominant with full penetrance. Analysis of the family tree described, with affected grandmother, uncle (and probably father) and brother, is in keeping with an autosomal dominant condition.
The molecular genetics of Huntington's is well understood. A mutation in a trinucleotide repeat sequence for the gene coding the protein Huntingtin is responsible for disease. The size of the affected sequence is thought to correlate with clinical severity. The repeat sequence increases in size through progressive generations; thus affected children will often present earlier than their parents. This is the genetic phenomena of anticipation.

A 39-year-old man is referred to the neurology outpatient department with a history of several episodes of neurological dysfunction. The first of these dates back to two years ago when he had a subacute hemiparesis affecting his right side. This lasted for several weeks before resolving. He was so frightened by this that he did not seek medical advice. About six months ago he presented with painful loss of visual acuity in his left eye. This was treated by the ophthalmologists and resolved after around 10 days. He has since suffered an episode of vertigo, which started just over two months ago with dizziness and vomiting initially put down to labyrinthitis by his doctor. This again resolved over a period of a couple of weeks or so and he no longer feels dizzy. He is able to walk unaided for 200 yards to his local shop each morning to buy the newspaper, but for longer distances has some difficulty with fatigue and leg spasms, in which case he tends to use a stick. He is otherwise systemically well.

On examination, he has a pale left optic disc. There is evidence of an afferent papillary defect. On examination of the eye movements, his right eye fails to adduct when following a visual target across the midline. At the same time he has nystagmus in the left eye. He has normal accommodation. There are no other cranial nerve abnormalities. Peripheral nervous system examination reveals moderately increased tone in all four limbs with some non-sustained beats of ankle clonus at both ankles. The plantars are down-going bilaterally. There is some unsteadiness on tandem gait examination. Romberg's test is negative.

Investigations:

ESR	32 mm/h
Rheumatoid factor	+

Magnetic resonance imaging (MRI) of the brain shows two white matter lesions adjacent to the corpus callosum and in the periventricular

Protein	0.3 g/dl
Glucose (CSF/serum)	4.6/7.8 mmol/l
Cells	<1 WBC and <1 RBC/mm^3
Oligoclonal band analysis	-

Choose the most appropriate intervention.

A	IV methylprednisolone 1 g/day for three days
B	Commence monthly natalizumab infusions
C	Azathioprine 100 mg/day
D	Methotrexate 7.5 mg once per week
E	None pending further investigations

B Commence monthly natalizumab infusions

This man has multiple sclerosis (MS). The dissemination of events in time and anatomical location, the clinical signs (intranuclear ophthalmoplegia) and location of the magnetic resonance imaging (MRI) lesions are all typical for MS. Remember that oligoclonal bands may be negative in a small proportion of MS patients. It is important to remember that if they are detected, it needs to be established whether or not they are present in the serum as they may reflect systemic and not central nervous system inflammation. It is for this reason that a serum sample must be taken when cerebrospinal fluid (CSF) is sent for oligoclonal band analysis. Although this man has a mildly elevated erythrocyte sedimentation rate (ESR), the diagnosis is still most likely to be MS based on all the available evidence. Rheumatoid factor can be positive in a proportion of the population (at least 4%) who do not have rheumatoid arthritis (RA), and it is a false-positive

arthritis (RA), and it is a false-positive result in this context. This patient's MS is highly active (3 relapses in 2 years) and he would be a candidate for one of the newer disease-modifying treatments such as natalizumab.

A	IV methylprednisolone 1 g/day for three days

Steroids are only used in acute relapses where there is some evidence that they may speed up recovery rate, although they do not improve the recovery itself. This patient is not currently having a relapse.

C	Azathioprine 100 mg/day

Although very occasionally used in multiple sclerosis, azathioprine efficacy is not well established.

D	Methotrexate 7.5 mg once per week

This drug is not used to treat MS. It is

C	Azathioprine 100 mg/day

Although very occasionally used in multiple sclerosis, azathioprine efficacy is not well established.

D	Methotrexate 7.5 mg once per week

This drug is not used to treat MS. It is first-line treatment for RA, but this patient does not have RA, merely a false-positive rheumatoid factor.

E	None pending further investigations

This man has completed his investigations and the diagnosis is MS. He should be offered disease-modifying treatment and would normally be given a range of drugs to choose from, and would have guidance from specialist MS nurses to help with his decision.

7008

Rate this question:

A 25-year-old man visits his general practitioner (GP) complaining of a resting tremor in one hand that has become progressively more noticeable over the last few months. He has also found getting dressed in the mornings to be particularly difficult due to a lack of co-ordination.

On further questioning, he reports that he 'feels tired all the time' and admits to feeling depressed and lonely. He has not worked since leaving college and lives with his parents.

On examination, the patient has a relatively expressionless face with a paucity of blinking. A fine resting tremor of the left hand is noted. Examination of the patient's wrists shows rigidity of movement on flexion and extension. Mental examination shows some slowing of higher functions and a mildly blunted affect. Observing the patient walking shows the left arm not to swing fully and the left foot mildly scraping the floor.

Given this clinical presentation, which one of the following conditions should

and extension. Mental examination shows some slowing of higher functions and a mildly blunted affect. Observing the patient walking shows the left arm not to swing fully and the left foot mildly scraping the floor.

Given this clinical presentation, which one of the following conditions should be considered within the differential diagnosis?

A	Erythema induratum
B	Epidemic pleurodynia
C	Menetrier's disease
D	Wilson's disease
E	Whipple's disease

6082

Submit

over the last few months. He has also found getting dressed in the mornings to be particularly difficult due to a lack of co-ordination.

On further questioning, he reports that he 'feels tired all the time' and admits to feeling depressed and lonely. He has not worked since leaving college and lives with his parents.

On examination, the patient has a relatively expressionless face with a paucity of blinking. A fine resting tremor of the left hand is noted. Examination of the patient's wrists shows rigidity of movement on flexion and extension. Mental examination shows some slowing of higher functions and a mildly blunted affect. Observing the patient walking shows the left arm not to swing fully and the left foot mildly scraping the floor.

Given this clinical presentation, which one of the following conditions should be considered within the differential diagnosis?

D Wilson's disease

Wilson's disease is a neurodegenerative disease of copper metabolism. It typically presents in childhood or adolescence and rarely presents after the 3rd decade. Clinical manifestations are predominantly hepatic, neurologic and psychiatric.

Patients who present with fulminant liver failure have a mortality rate as high as 70%. Liver disease is the most common initial manifestation in children. Older individuals often present with neuropsychiatric symptoms. Neurological symptoms and signs include parkinsonism, but may present in many other forms including dystonias, particularly of the face (rictus), eye movement disorders and psychiatric changes including emotional lability, personality changes and depression. This condition should therefore be excluded in any young person presenting with a movement disorder; this includes liver biochemistry, serum ceruloplasmin, 24 h urinary copper excretion and slit-

h urinary copper excretion and slit-lamp examination for Kayser–Fleischer rings.

A Erythema induratum

Erythema induratum (Bazin's disease) is an inflammatory disorder of subcutaneous fat tissue. It can be associated with TB, autoimmune conditions, inflammatory bowel disease and haematological conditions. It does not fit this patient's presenting symptoms.

B Epidemic pleurodynia

Epidemic pleurodynia (Bornholm disease) is a febrile illness caused by Coxsackie B viral infection. Symptoms include paroxysmal chest pain, fever, headache and myalgia. It does not fit this patient's presenting symptoms.

C Menetrier's disease

Protein-losing hypertrophic

C Menetrier's disease

Protein-losing hypertrophic gastropathy (Menetrier's disease) is an acquired gastrointestinal condition most frequently affecting middle-aged males. Symptoms include epigastric pain, fatigue, anorexia and weight loss. It does not fit this patient's presenting symptoms.

E Whipple's disease

Infection with *Tropheryma whipplei* can give rise to neurological symptoms in 10–40% of patients, but isolated neurological disease is rare. Cognitive impairment is the most common neurological manifestation. Oculomasticatory myorhythmia and oculo-facial-skeletal myorhythmia are considered pathognomonic. Wilson's disease should always be ruled out first in a young patient with the combination of a psychiatric condition and movement disorder.

You review the magnetic resonance imaging (MRI) scans of a 42-year-old man who presents with a 15-month history of chronic lower back pain.

The scan looks very abnormal, with high signal on T2-weighted scan within the spinal cord itself, which appears to extend from T12 to L3. The signal intensity of the cord is higher than that of the vertebral bodies.

What diagnosis fits best with this clinical picture?

A	Osteomyelitis
B	Metastasis within the spinal cord
C	Vertebral fracture
D	Chronic disc prolapse
E	Ependymoma

You review the magnetic resonance imaging (MRI) scans of a 42-year-old man who presents with a 15-month history of chronic lower back pain.

The scan looks very abnormal, with high signal on T2-weighted scan within the spinal cord itself, which appears to extend from T12 to L3. The signal intensity of the cord is higher than that of the vertebral bodies.

What diagnosis fits best with this clinical picture?

Your answer was correct

A	Osteomyelitis
B	Metastasis within the spinal cord
C	Vertebral fracture

E Ependymoma

Ependymomas appear as an area of intense high signal on T2-weighted MRI within the spinal cord. These are glial tumours which arise from ependymal cells within the CNS. Those which affect the filum terminale present with chronic back pain ± sciatica over a number of months. Ependymomas of the filum terminale are usually of the myxopapillary type and are seen more commonly in younger male patients. They make up around 13% of ependymomas. When interpreting the findings from MRI scans, it is of paramount importance to consider the clinical context. Many conditions can be ruled out simply by understanding the cadence of onset and natural history of the disorder. For example, the description in this case of a 15-month history of back pain would make the possibility of spinal cord metastases extremely unlikely.

A Osteomyelitis

A Osteomyelitis

This is an infection of the *bone* and would not cause diffuse signal change within the spinal cord itself.

B Metastasis within the spinal cord

Such widespread signal change on non-contrast-enhanced MRI is unlikely to represent spinal cord metastasis, which usually causes a 'lumpy bumpy' appearance best visualised on gadolinium-enhanced sequences. Furthermore, the long history is incompatible with spinal metastases, which would be associated with a very rapid mortality.

C Vertebral fracture

Vertebral fracture would cause a localised signal change in the affected vertebral body, not a widespread change in the spinal cord.

A 42-year-old man presents with weakness in his hands and legs. In particular, he reports difficulties playing football with his sons.

On examination, bilateral ptosis with a smooth forehead and balding is noted. Fundoscopy proves difficult because of bilateral cataracts. Facial expression is reduced, with wasting of the temporalis muscles, masseters and sternocleidomastoids. Slow release of hand grip is present bilaterally, with weakness and wasting in the distal muscles of the upper limb. Deep tendon jerks are depressed.

Following a review by his local neurologist, he has been informed that his complaints are related to an inherited condition. The patient's sister is concerned regarding risks to her offspring.

Which of the following tests would be the most appropriate next step to confirm the likely diagnosis?

A	Anti-acetylcholine receptor

muscles of the upper limb. Deep tendon jerks are depressed.

Following a review by his local neurologist, he has been informed that his complaints are related to an inherited condition. The patient's sister is concerned regarding risks to her offspring.

Which of the following tests would be the most appropriate next step to confirm the likely diagnosis?

A	Anti-acetylcholine receptor antibodies
B	Edrophonium chloride challenge (tensilon test)
C	Electromyography
D	Muscle biopsy
E	Jo-1 antibody

A 42-year-old man presents with weakness in his hands and legs. In particular, he reports difficulties playing football with his sons.

On examination, bilateral ptosis with a smooth forehead and balding is noted. Fundoscopy proves difficult because of bilateral cataracts. Facial expression is reduced, with wasting of the temporalis muscles, masseters and sternocleidomastoids. Slow release of hand grip is present bilaterally, with weakness and wasting in the distal muscles of the upper limb. Deep tendon jerks are depressed.

Following a review by his local neurologist, he has been informed that his complaints are related to an inherited condition. The patient's sister is concerned regarding risks to her offspring.

Which of the following tests would be the most appropriate next step to confirm the likely diagnosis?

C	Electromyography

The clinical case is compatible with myotonic dystrophy. The condition is characterised by frontal balding, myotonia, cataracts, wasting of the sternocleidomastoids, dysphagia and muscle weakness. The disease is inherited in an autosomal dominant fashion and genetic anticipation is seen due to the disorder being caused by a trinucleotide repeat. EMG changes are found in almost any muscle (waxing and waning of potentials, termed the 'dive bomber effect'). Genetic testing is available and can provide confirmation of diagnosis.

A	Anti-acetylcholine receptor antibodies

Anti-acetylcholine receptor antibody testing is used in the diagnosis of myasthenia gravis but not myotonic dystrophy. Myasthenia gravis is an autoimmune disorder characterised by weakness and fatiguability of skeletal

muscles. Muscle weakness due to dysfunction of the neuromuscular junction (myasthenia) may be an acquired disorder. The vast majority of patients who develop myasthenia in adolescence or adulthood have auto-antibodies that play a pathogenetically important role by attacking the acetylcholine receptor (AChR), fixing complement and reducing the number of AChRs over time. These autoantibodies are thought to originate in hyperplastic germinal centres in the thymus, where myoid cells expressing AChR are clustered.

B	Edrophonium chloride challenge (tensilon test)

The edrophonium test has traditionally been used in the investigation of myasthenia, but should be used only in those patients with obvious ptosis or ophthalmoparesis in whom improvement after injection of the drug can easily be observed. The difficulty in quantifying strength independent of volition in other muscle

improvement after injection of the drug can easily be observed. The difficulty in quantifying strength independent of volition in other muscle groups makes the interpretation of the response to edrophonium too unreliable. It is now rarely performed.

D	Muscle biopsy

Muscle biopsies are helpful in the diagnosis of primary muscle disease (inflammatory, metabolic or genetic myopathy) but not in myotonic dystrophy.

E	Jo-1 antibody

Jo-1 antibody is associated with autoimmune myositis but not myotonic dystrophy. Dermatomyositis and polymyositis are idiopathic inflammatory myopathies, characterised by the shared features of proximal skeletal muscle weakness and evidence of muscle inflammation.

A 30-year-old rugby player is admitted to the Emergency Department with an enlarging swelling of the neck. He had been involved in a particularly bad rugby tackle three days ago. Since then, he has noticed swelling occurring over the left side of his neck and some weakness affecting the left shoulder, although he has attributed this to a muscle strain. What worries him most is a specific problem with swallowing, which has come on within the last 48 h.

He is a fit man with no known history and is not taking any regular medication.

On examination, he has a large, hard swelling over the left lateral aspect of the neck. There is evidence of a left Horner syndrome. Examination of the cranial nerves reveals reduced palatal elevation on the left and weakness of shoulder elevation on the left. Sensation and ocular movements are intact. Examination of the limbs does not reveal any abnormalities.

In view of the above findings, what is

swelling over the left lateral aspect of the neck. There is evidence of a left Horner syndrome. Examination of the cranial nerves reveals reduced palatal elevation on the left and weakness of shoulder elevation on the left. Sensation and ocular movements are intact. Examination of the limbs does not reveal any abnormalities.

In view of the above findings, what is the likely diagnosis in this man?

A	Intracranial carotid artery dissection
B	Extracranial vertebral artery dissection
C	Extracranial carotid artery dissection
D	Lateral medullary syndrome
E	Intracranial vertebral artery dissection

A 30-year-old rugby player is admitted to the Emergency Department with an enlarging swelling of the neck. He had been involved in a particularly bad rugby tackle three days ago. Since then, he has noticed swelling occurring over the left side of his neck and some weakness affecting the left shoulder, although he has attributed this to a muscle strain. What worries him most is a specific problem with swallowing, which has come on within the last 48 h.

He is a fit man with no known history and is not taking any regular medication.

On examination, he has a large, hard swelling over the left lateral aspect of the neck. There is evidence of a left Horner syndrome. Examination of the cranial nerves reveals reduced palatal elevation on the left and weakness of shoulder elevation on the left. Sensation and ocular movements are intact. Examination of the limbs does not reveal any abnormalities

C Extracranial carotid artery dissection

This patient presents with a history in keeping with the diagnosis of extracranial carotid artery dissection. This is associated with blunt trauma, arteriopathies (of which fibromuscular dysplasia is the commonest) and other collagen vascular disorders. The neck swelling is an expanding haematoma and he has subsequently developed left-sided compressive cranial nerve palsies (IX, X and XI) and a left-sided Horner syndrome as a result of compression of the sympathetic chain.

A Intracranial carotid artery dissection

This condition presents with headache followed by major anterior circulation stroke. Some intracranial dissections present as subarachnoid haemorrhage.

B Extracranial vertebral artery dissection

B	Extracranial vertebral artery dissection

This condition presents with neck pain and ischaemia of the posterior circulation.

D	Lateral medullary syndrome

Infarcts of the posterior inferior cerebellar artery cause the lateral medullary syndrome. This is characterised by ipsilateral Horner syndrome, ipsilateral reduced pain and temperature sensation of the face and other ipsilateral cranial nerve involvement, and contralateral loss of pain and temperature sensation of the limbs.

E	Intracranial vertebral artery dissection

This presents with posterior circulation ischaemia and subarachnoid haemorrhage in some cases

A 36-year-old woman presents to the clinic because over the past few weeks because she has noticed blurring of vision when reading. She had become aware of this problem while she was holidaying in Sweden, a couple of years ago.

There is no significant past medical history, and her only medication of note is the oral contraceptive pill.

On examination, the right pupil is slightly larger than the left and the reaction to light is greatly reduced, although it reacts better to accommodation. Tendon reflexes are absent and plantars are down-going. Peripheral sensation is normal.

What is the most likely diagnosis?

A	Tabes dorsalis
B	Pinealoma
C	Holmes–Adie syndrome

holidaying in Sweden, a couple of years ago.

There is no significant past medical history, and her only medication of note is the oral contraceptive pill.

On examination, the right pupil is slightly larger than the left and the reaction to light is greatly reduced, although it reacts better to accommodation. Tendon reflexes are absent and plantars are down-going. Peripheral sensation is normal.

What is the most likely diagnosis?

A	Tabes dorsalis
B	Pinealoma
C	Holmes–Adie syndrome
D	Right optic neuropathy
E	Posterior communicating artery aneurysm

C Holmes–Adie syndrome

The larger pupil on the right side that reacts worse to light than the left localises the defective pupil to the right side. There is no associated ptosis or extra-ocular muscle paresis – hence this is not due to a third nerve lesion. There are no features of mid-brain involvement. Absent tendon reflexes are suggestive of peripheral neuropathy. These findings, typically in females, raise the possibility of Holmes–Adie syndrome. This is due to degeneration of ciliary ganglia and postganglionic parasympathetic fibres. Here the affected pupil is larger than the other, is unusually sensitive to 0.1% pilocarpine and constricts promptly. On the other hand, the normal pupil is minimally affected by this concentration. This condition represents a mild form of inherited polyneuropathy.

A Tabes dorsalis

The lack of other neurological features, including dorsal column loss, counts against tertiary syphilis as the underlying diagnosis.

B	Pinealoma

Although pinealomas do present with a pupil reaction where accommodation is normal but light reaction is absent, other features such as paralysis of upward gaze, convergence retraction nystagmus and eyelid retraction are normally seen.

D	Right optic neuropathy

Right optic neuropathy would result in significantly decreased visual acuity and impairment of accommodation, both of which are normal here.

E	Posterior communicating artery aneurysm

Posterior communicating artery aneurysms present with facial pain

Although pinealomas do present with a pupil reaction where accommodation is normal but light reaction is absent, other features such as paralysis of upward gaze, convergence retraction nystagmus and eyelid retraction are normally seen.

D	Right optic neuropathy

Right optic neuropathy would result in significantly decreased visual acuity and impairment of accommodation, both of which are normal here.

E	Posterior communicating artery aneurysm

Posterior communicating artery aneurysms present with facial pain, and in larger lesions oculomotor nerve palsy is also seen.

A 26-year-old woman presents to the Emergency Department with a 6-week history of increasing headaches, which have become dramatically worse over the past 10 days. She describes a constant pain behind her eyes that is unrelieved by paracetamol.

Initially, the headaches would only appear in the morning, but now they are constant throughout the day. She has also noticed that her vision becomes occasionally blurred when she gets up in the mornings. She has been feeling much more tired during the day for the past month, but attributes this to poor sleeping due to her headache. Her boyfriend feels that she is depressed.

She has no significant past medical history of note, and her only medication is the oral contraceptive pill. She smokes 20 cigarettes per day, and drinks 12 units of alcohol per week.

On examination, she is tearful. Her body mass index (BMI) is 31 kg/m^2. Her temperature is 36.8 °C. There is no obvious neck rigidity. Her pulse is 70

and drinks 12 units of alcohol per week.

On examination, she is tearful. Her body mass index (BMI) is 31 kg/m^2. Her temperature is 36.8 °C. There is no obvious neck rigidity. Her pulse is 70 bpm, regular, and jugular venous pressure and heart sounds are normal. Her blood pressure is 126/76 mmHg. Respiratory and abdominal examinations are unremarkable. Neurological examination is normal except for bilateral optic disc swelling. CT head is reported as normal.

Which investigation would be most useful in guiding treatment?

A	Electroencephalogram (EEG)
B	Visual evoked potentials
C	Thyroid function tests
D	Overnight pulse oximetry
E	Lumbar puncture

E Lumbar puncture

This patient likely has idiopathic intracranial hypertension. The term 'idiopathic' is now preferred to 'benign', as the clinical course may have significant morbidity. There is raised intracranial pressure in the absence of a mass lesion or hydrocephalus. Incidence is 1/100 000, with a female preponderance (F:M 3.8:1). Up to 90% of patients are overweight. Other risk factors include smoking and oral contraceptive pill use. Symptoms include headaches which are worse in the mornings, and with coughing or straining. This is attributable to the raised intracranial pressure. Other symptoms include blurred vision, scotomata and horizontal diplopia. The commonest sign is papilloedema. Lumbar puncture is required to demonstrate an elevated opening pressure and to exclude chronic meningitic illnesses that could mimic this presentation. Magnetic resonance venography is important in excluding venous sinus thrombosis as a

excluding venous sinus thrombosis as a secondary cause of raised pressure. Treatment includes weight loss if the patient is obese; intracranial pressure may be controlled by serial lumbar puncture. Drugs that may be successful include acetazolamide and thiazide diuretics. Visual loss is the single most threatening complication of idiopathic intracranial hypertension, and treatment is with urgent large-volume lumbar puncture, followed by shunting if required. Optic nerve fenestration is an alternative, although there are no comparative studies between the two interventions.

A	Electroencephalogram (EEG)

EEG is useful in the investigation of epilepsy (especially primary generalised epilepsy) and encephalopathy, but there would be no indication for it here.

B	Visual evoked potentials

This test can be used to assess causes

B Visual evoked potentials

This test can be used to assess causes of visual failure, particularly if one is trying to demonstrate optic neuropathy.

C Thyroid function tests

Whilst this patient does have some non-specific general symptoms that could be compatible with hypothyroidism, the headache and papilloedema suggest that raised intracranial pressure is the issue that needs to be addressed.

D Overnight pulse oximetry

Nocturnal hypoxia and hypercapnia can cause headache, but the features seen here are suggestive of raised ICP and so lumbar puncture is required.

32735

Rate this question:

A 47-year-old woman is seen by her general practitioner (GP) with lethargy and weakness. She has noticed feeling completely drained at the end of the day. She struggles to comb her hair in the morning and can sometimes have problems walking down stairs. More recently she has noticed that her eyes are excessively droopy and on occasions she has experienced double vision.

She is a smoker of 20 cigarettes per day, has rheumatoid arthritis and has recently started propranolol for tension headaches.

On examination, she had nasal speech and obvious bilateral ptosis. There was oculoparesis on right lateral gaze and she had weakness of neck extension. On examination of the upper limb, tone, reflexes and sensation were all normal; however, she exhibited marked proximal weakness, which was fatiguable with no associated wasting.

On examination of the lower limb, there was marked proximal weakness but no wasting. Chest expansion was 5

but no wasting. Chest expansion was 5 cm and she was able to count up to 20 in one breath. Chest examination appeared normal.

The patient had a computerised tomography (CT) of the thorax, which showed thymic atrophy, nil other masses.

Blood tests revealed:

Anti-acetylcholine receptor antibodies	Negative
Muscle-specific kinase antibodies	Positive

Given the above findings, how would you manage this patient initially?

A	Commence on intravenous immunoglobulin and arrange for thymectomy
B	Stop propranolol and commence on pyridostigmine 30 mg qds

receptor antibodies	Negative
Muscle-specific kinase antibodies	Positive

Given the above findings, how would you manage this patient initially?

A	Commence on intravenous immunoglobulin and arrange for thymectomy
B	Stop propranolol and commence on pyridostigmine 30 mg qds
C	Arrange for plasmapheresis and HDU (high-dependency unit) transfer
D	Stop propranolol and commence on azathioprine 50 mg/day
E	Monitor the peak flow

B Stop propranolol and commence on pyridostigmine 30 mg qds

This patient has a diagnosis of generalised myasthenia gravis with bulbar, ocular and limb involvement. In late-onset myasthenia gravis, patients have thymic atrophy as opposed to early-onset myasthenia where patients are more likely to have thymic hyperplasia. In 40% of patients negative for acetylcholine receptor antibodies, there is an antibody found to a postsynaptic protein muscle-specific kinase (MuSK antibodies).

An important factor to determine is whether there is impending respiratory muscle weakness. In this patient, clinical evaluation showed normal chest expansion and breath counting. However, all patients should have their forced vital capacity (not the peak flow) monitored on the ward. In the first instance this patient should therefore be commenced on pyridostigmine 30 mg qds and observed for clinical response.

pyridostigmine 30 mg qds and observed for clinical response. Thereafter the patient will likely require prednisolone, normally at an escalating regimen on alternate days. The reason for this is that if larger doses are given it can paradoxically cause worsening of muscle weakness. In addition. propranolol should be stopped as this can exacerbate myasthenia. Guidelines for the management of myasthenia gravis are available.

A	Commence on intravenous immunoglobulin and arrange for thymectomy

Intravenous immunoglobulin (IVIG) is reserved for patients with severe symptoms, including respiratory dysfunction with vital capacity <1 l, and is not routinely used as first line.

C	Arrange for plasmapheresis and HDU (high-dependency unit) transfer

C	Arrange for plasmapheresis and HDU (high-dependency unit) transfer

Like IVIG, this treatment would be reserved for severe cases, typically when respiratory compromise is present.

D	Stop propranolol and commence on azathioprine 50 mg/day

Azathioprine is a long-term, steroid-sparing treatment that can be used once remission is induced with corticosteroids.

E	Monitor the peak flow

Peak flow is an insensitive tool for assessing neuromuscular ventilator compromise; FVC is a much more reliable indicator.

32711

Rate this question:

A 55-year-old solicitor is referred to the General Medical Clinic by his general practitioner (GP). He has a 6-month history of difficulty walking and writing, which started gradually and appears to be slowly worsening. He feels that his movements are slow and that he has difficulty getting started when trying to rise from a chair or get out of bed. There have been no falls. He denies any tremor.

He used to be very active and played squash two evenings a week, which he has had to stop doing. He is still able to wash and dress, albeit slowly. He has had no episodes of fainting, no cognitive symptoms and no incontinence. He has no significant past medical history and is on no medications. He is a lifelong non-smoker.

On examination, he appears slow in his movements, with reduced facial expression. He has a slightly stooped posture with reduced arm swing, but once walking he appears to mobilise well with reasonable speed and no obvious unsteadiness even on turning

once walking he appears to mobilise well with reasonable speed and no obvious unsteadiness even on turning. There are no cognitive deficits on bedside testing. Cranial nerve examination reveals only reduced blinking. There are no abnormalities of eye movements. Tone is mildly increased in his right hand, with some cog-wheeling. He has a very mild tremor of the right hand, which increases when he is asked to perform a task with his left hand. The reflexes are brisk but symmetrical and the plantars are down going bilaterally. There are no sensory abnormalities.

The patient is very keen to try anything that might improve his symptoms.

What is the most appropriate first medication to try in this man's care?

A	Amantadine
B	Ropinirole
C	Procyclidine

eye movements. Tone is mildly increased in his right hand, with some cog-wheeling. He has a very mild tremor of the right hand, which increases when he is asked to perform a task with his left hand. The reflexes are brisk but symmetrical and the plantars are down going bilaterally. There are no sensory abnormalities.

The patient is very keen to try anything that might improve his symptoms.

What is the most appropriate first medication to try in this man's care?

A	Amantadine
B	Ropinirole
C	Procyclidine
D	Rasagiline
E	Selegiline

to wash and dress, albeit slowly. He has had no episodes of fainting, no cognitive symptoms and no incontinence. He has no significant past medical history and is on no medications. He is a lifelong non-smoker.

On examination, he appears slow in his movements, with reduced facial expression. He has a slightly stooped posture with reduced arm swing, but once walking he appears to mobilise well with reasonable speed and no obvious unsteadiness even on turning. There are no cognitive deficits on bedside testing. Cranial nerve examination reveals only reduced blinking. There are no abnormalities of eye movements. Tone is mildly increased in his right hand, with some cog-wheeling. He has a very mild tremor of the right hand, which increases when he is asked to perform a task with his left hand. The reflexes are brisk but symmetrical and the plantars are down going bilaterally. There are no sensory abnormalities.

The patient is very keen to try anything

B Ropinirole

This patient presents with symptoms consistent with Parkinson's disease, and at this point there is little differentiation between beginning treatment with a dopamine agonist or with L-dopa. Guidelines make little distinction between the two. Non-ergot derived dopamine agonists, such as ropinirole, are preferred amongst the class. They may result in excessive somnolence and can drive risk-taking behavior. Patients should be warned of this.

A Amantadine

Amantadine is a glutamate antagonist that reduces dyskinesia in patients with Parkinson's. It only has weak effects on symptoms of tremor and rigidity, so is not a first-choice option for patients with early disease.

C Procyclidine

Procyclidine is an anti-cholinergic

Procyclidine is an anti-cholinergic, which may have effects on hypersalivation in Parkinson's and reduce tremor, although it is not an option for patients with early disease.

D	Rasagiline

Rasagiline is a monoamine oxidase B (MAOB) inhibitor, which inhibits breakdown of dopamine. It can be used to smooth fluctuations in motor symptoms in patients with more advanced Parkinson's.

E	Selegiline

Like rasagiline, selegiline is a MAOB inhibitor used to smooth motor fluctuations in more advanced Parkinson's.

8595

Rate this question:

A 74-year-old man presented with a 6-week history of generalised fatigue and weakness. It had started initially with a feeling of heaviness in his arms and legs, and by 2 weeks into the illness he was having difficulty getting out of his chair and going upstairs. When walking he often had to stop for a rest before being able to carry on. He suffered from hypothyroidism for which he took levothyroxine tablets, but he was otherwise well with no other prescription medications. He drank about 10 units of alcohol per week and smoked 30 cigarettes per day, which he had done since being young. Systemic enquiry revealed some difficulty swallowing and constipation for the last few months, and he had also lost a stone in weight over the previous 6 weeks.

General examination was normal. Cranial nerve examination was normal. Limb examination showed normal tone with mild proximal weakness in his upper and lower limbs. Reflexes were decreased throughout but were normal after exercising the particular

General examination was normal. Cranial nerve examination was normal. Limb examination showed normal tone with mild proximal weakness in his upper and lower limbs. Reflexes were decreased throughout but were normal after exercising the particular muscle group. Coordination and sensation were normal.

What test would confirm the diagnosis?

A	Nerve conduction and EMG studies
B	Acetylcholine receptor antibodies
C	Serum creatine kinase (CK)
D	Magnetic resonance imaging (MRI) of the cervical spine
E	Muscle biopsy

A Nerve conduction and EMG studies

The diagnosis is Lambert–Eaton myasthenic syndrome (LEMS). This is a disorder of the neuromuscular junction and is an autoimmune disease with antibodies to voltage-gated calcium channels. It can be either primary autoimmune or a paraneoplastic syndrome – if the latter, it is most frequently associated with small cell lung carcinoma. It commonly presents with insidious onset of proximal muscle weakness (legs greater than arms and rarely ocular or bulbar muscles) and autonomic symptoms. Neuromuscular symptoms include generalised fatigue and proximal muscle weakness. Respiratory failure is rare as a presenting feature but can develop later. Autonomic symptoms occur in up to 75% of patients and include dry mouth, constipation, blurred vision, postural hypotension and impaired sweating. Signs on examination include proximal muscle weakness (legs greater than arms) and characteristically hypoactive or absent

characteristically hypoactive or absent reflexes that return after brief exercise of the appropriate muscle. Other signs include sluggish pupillary reflexes, postural hypotension and a dry mouth. There are two parts to investigations: first to confirm the disease, and second to search for an underlying malignancy. The disease is confirmed with characteristic findings on nerve conduction studies: compound motor action potentials have small amplitudes which. after exercise or with repetitive stimulation, will immediately increase by more than 100%. Single-fibre examination may demonstrate jitter and block. Voltage-gated calcium channel antibodies are seen in almost 100% of LEMS patients with cancer and in more than 90% of individuals without cancer. Management is of the underlying cancer if there is one and symptomatically, normally with the potassium channel blocker 3,4-diaminopyridine, which helps to maintain depolarisation of the nerve terminal by preventing repolarisation, leading to more calcium entering the

leading to more calcium entering the nerve terminal.

B	Acetylcholine receptor antibodies

These antibodies are associated with myasthenia gravis, which is much more likely to present with prominent ocular and bulbar problems rather than the lower limb and autonomic symptoms described here.

C	Serum creatine kinase (CK)

CK estimation can be useful in the investigation of myopathies but is rarely a diagnostic test in itself. In neuromuscular junction disorders such as Lambert Eaton and myasthenia, CK levels are normal.

D	Magnetic resonance imaging (MRI) of the cervical spine

This patient does not have myelopathic signs on examination (increased tone,

C Serum creatine kinase (CK)

CK estimation can be useful in the investigation of myopathies but is rarely a diagnostic test in itself. In neuromuscular junction disorders such as Lambert Eaton and myasthenia, CK levels are normal.

D Magnetic resonance imaging (MRI) of the cervical spine

This patient does not have myelopathic signs on examination (increased tone, brisk reflexes, sensory level) so this test will not be helpful

E Muscle biopsy

This is often the most helpful investigation in primary muscle disease but in neuromuscular junction disorders such as Lambert–Eaton it will be essentially normal.

6958

Rate this question:

A 52-year-old woman presents to the Emergency Department with a 6-week history of tiredness and unsteadiness on her feet, with some paraesthesia affecting her legs. She has a 3-year history of hypothyroidism, and was diagnosed with type 2 diabetes 6 months earlier.

Her current medications are thyroxine 50 μg OD and metformin 500 mg BD. She is a non-smoker and does not drink alcohol.

Her most recent blood tests revealed normal thyroid function tests and a haemoglobin A_{1c} of 55.2 mmol/L.

On examination, she has a small hypopigmented rash over the dorsum of her left hand. She has a spastic paraparesis with grade 4 power in the lower limbs. Knee reflexes are diminished and ankle jerks are lost. Plantar response is extensor bilaterally. Joint position sense is lost at the toes and ankles, but there is normal pain sensation.

What is the most likely diagnosis?

8:23
tps://mypastest.pastest.com 14

On examination, she has a small hypopigmented rash over the dorsum of her left hand. She has a spastic paraparesis with grade 4 power in the lower limbs. Knee reflexes are diminished and ankle jerks are lost. Plantar response is extensor bilaterally. Joint position sense is lost at the toes and ankles, but there is normal pain sensation.

What is the most likely diagnosis?

A	Syringomyelia
B	Spinal cord meningioma
C	Spinal metastases
D	Multiple sclerosis
E	Subacute combined degeneration of the cord

history of hypothyroidism, and was diagnosed with type 2 diabetes 6 months earlier.

Her current medications are thyroxine 50 µg OD and metformin 500 mg BD. She is a non-smoker and does not drink alcohol.

Her most recent blood tests revealed normal thyroid function tests and a haemoglobin A_{1c} of 55.2 mmol/L.

On examination, she has a small hypopigmented rash over the dorsum of her left hand. She has a spastic paraparesis with grade 4 power in the lower limbs. Knee reflexes are diminished and ankle jerks are lost. Plantar response is extensor bilaterally. Joint position sense is lost at the toes and ankles, but there is normal pain sensation.

What is the most likely diagnosis?

Your answer was correct

A	Syringomyelia

E Subacute combined degeneration of the cord

Subacute combined degeneration of the cord is a metabolic disorder due to vitamin B_{12} deficiency. The posterior columns and corticospinal tracts are specifically damaged, but the clinical picture can be complicated by the early development of coexistent peripheral nerve damage. Symmetrical loss of posterior columns produces an ataxic gait with loss of joint position sensation. Signs include spasticity in the legs, hyporeflexia at the knees and loss of ankle jerks and extensor plantar responses. Occasionally there may be an associated peripheral sensory neuropathy, though relative sparing of spinothalamic tracts is typical. Treatment is with hydroxocobalamin injections, which improve peripheral nerve damage, though resolution of spinal cord function is not always significant. In this patient, the vitamin B_{12} deficiency may be due to pernicious anaemia, which is associated with other organ-specific

associated with other organ-specific immune disorders such as thyroid disease and vitiligo. Metformin is reported to interfere with B_{12} metabolism, although clinically significant B_{12} deficiency with respect to metformin use is virtually never reported.

A Syringomyelia

Syringomyelia is associated with sensory loss in a shawl-like distribution, and upper motor neurone signs in the lower limbs, which are not seen here.

B Spinal cord meningioma

Meningiomas are associated primarily with upper motor neurone deficits below the level of the lesion, a sensory level and bowel/bladder dysfunction may also be seen.

C Spinal metastases

B Spinal cord meningioma

Meningiomas are associated primarily with upper motor neurone deficits below the level of the lesion, a sensory level and bowel/bladder dysfunction may also be seen.

C Spinal metastases

There is no suspicion of a primary tumour here which would lead on to spinal metastases, and the lower limb signs are consistent with subacute combined degeneration.

D Multiple sclerosis

This patient is older than average for a first presentation of MS and does present with features typical of a relapse. In addition, the lower motor neurone signs are inconsistent with MS.

7589

Rate this question:

A 24-year-old man is admitted via the Emergency Department. He was found in the street acting in a peculiar way. He has one previous admission for heroin overdose and has been living in a hostel. According to the hostel manager, he has suffered a chronic cough over the past few months and appears to have been losing weight.

On admission, he appeared acutely confused and drowsy.

Investigations:

CSF cells	Lymphocytic picture with 700 cells/cm per mm cubed
CSF glucose	2.4 mmol/l
CSF protein	1.8 g/l
Blood glucose	5.7 mmol/l
CSF scan	Obstructive hydrocephalus

glucose	2.4 mmol/l
CSF protein	1.8 g/l
Blood glucose	5.7 mmol/l
CSF scan	Obstructive hydrocephalus

Which of the following is the most likely diagnosis?

A	Neisseria meningitis
B	Viral meningitis
C	Cryptococcal meningitis
D	Pneumococcal meningitis
E	Tuberculous meningitis

A 24-year-old man is admitted via the Emergency Department. He was found in the street acting in a peculiar way. He has one previous admission for heroin overdose and has been living in a hostel. According to the hostel manager, he has suffered a chronic cough over the past few months and appears to have been losing weight.

On admission, he appeared acutely confused and drowsy.

Investigations:

CSF cells	Lymphocytic picture with 700 cells/cm per mm cubed
CSF glucose	2.4 mmol/l
CSF protein	1.8 g/l
Blood glucose	5.7 mmol/l
CSF scan	Obstructive hydrocephalus

E Tuberculous meningitis

The very low CSF glucose, marked lymphocytosis and markedly raised CSF protein (with CSF obstruction) all point towards a diagnosis of tuberculous meningitis. It is likely that he has acquired tuberculosis (TB) while living in the hostel and may well be human immunodeficiency virus (HIV) positive. Tuberculosis meningitis may present with a chronic picture involving malaise for a number of weeks, or may present acutely with focal neurological signs, obstructive hydrocephalus or cranial nerve palsies due to an acute vasculitis/ arachnoiditis.

A Neisseria meningitis

An acute presentation would be expected with meningococcus, with neutrophils rather than lymphocytes in the CSF.

B Viral meningitis

B Viral meningitis

In viral meningitis a lower level of CSF protein than that seen here would be expected, and hydrocephalus would be unexpected.

C Cryptococcal meningitis

Cryptococcal meningitis could potentially give a similar clinical and CSF picture, although the protein may tend to be less high than in TB meningitis and the CSF glucose not as low. The chronic cough and weight loss are, however, better pointers to tuberculosis as the underlying cause of his symptoms.

D Pneumococcal meningitis

Like neisseria meningitidis, a higher level of protein, and neutrophils rather than lymphocytes, would be expected in the CSF versus the picture seen here.

A 34-year-old woman is admitted to the Emergency Department after a road traffic accident in which she was shunted in the back by another car while queuing on the motorway. She has no past medical history of note.

On examination, she is on a body board and her c spine is immobilised . Her initial examination reveals a partial ptosis on the left with a small pupil. Examination of her oral cavity reveals tongue deviation to the left. There are no other significant neurological findings. She reports altered taste sensation.

Which of the following is the most likely cause?

A	Carotid artery dissection
B	Spinal accessory nerve injury
C	Subarachnoid haemorrhage
D	Cervical disc prolapse

shunted in the back by another car while queuing on the motorway. She has no past medical history of note.

On examination, she is on a body board and her c spine is immobilised . Her initial examination reveals a partial ptosis on the left with a small pupil. Examination of her oral cavity reveals tongue deviation to the left. There are no other significant neurological findings. She reports altered taste sensation.

Which of the following is the most likely cause?

A	Carotid artery dissection
B	Spinal accessory nerve injury
C	Subarachnoid haemorrhage
D	Cervical disc prolapse
E	Brachial plexus injury

8:42
tps://mypastest.pastest.com 14

the Emergency Department after a road traffic accident in which she was shunted in the back by another car while queuing on the motorway. She has no past medical history of note.

On examination, she is on a body board and her c spine is immobilised . Her initial examination reveals a partial ptosis on the left with a small pupil. Examination of her oral cavity reveals tongue deviation to the left. There are no other significant neurological findings. She reports altered taste sensation.

Which of the following is the most likely cause?

Your answer was incorrect

A Carotid artery dissection

B Spinal accessory nerve injury

A Carotid artery dissection

The trauma from the road traffic accident and subsequent neurological signs all support this. She has developed a left-sided Horner syndrome and hypoglossal palsy due to direct nerve compression from the expanding carotid artery. Spiral CT angiography or magnetic resonance angiography are the diagnostic modalities of choice to confirm the diagnosis. Ultrasound may be useful in confirming abnormal blood flow in the carotid artery, but it is difficult to visualise the carotid bulb and the actual site of aneurysm.

B Spinal accessory nerve injury

Knowledge of cranial nerves will allow you to exclude this as the best answer. Key innervation sites are the trapezius muscle and sternocleidomastoid muscle. These do not appear to be affected and therefore this cannot be the best answer.

A 72-year-old man is brought to the Neurology Clinic by his wife.

She complains that he sleeps very poorly, moving his legs incessantly throughout the night, getting out of bed and rubbing his legs constantly. This in turn disrupts her sleep. He also seems to constantly jiggle his legs when sitting in a chair. He says that his legs feel uncomfortable and moving them helps temporarily.

On examination, there is no focal neurology and he has significant past medical history of note. He takes no regular medication.

Investigations:

Hb	13.9 g/dl
WCC	5.6×10^9/l
PLT	205×10^9/l
Na^+	139 mmol/l
K^+	5.0 mmol/l
Creatinine	130 μmol/l
Urea	8.2 mmol/l

K^+	5.0 mmol/l
Creatinine	130 µmol/l
Urea	8.2 mmol/l
VDRL	Negative
PaO_2	10.3 kPa
$PaCO_2$	4.5 kPa
pH	7.4
Glucose	6.1 mmol/l

What is the most likely diagnosis?

A Sleep apnoea syndrome

B Restless legs syndrome

C Alcohol-related neuropathy

D Diabetic neuropathy

E Uraemic neuropathy

B Restless legs syndrome

This patient's symptoms are very typical of restless legs syndrome, a neurologic disorder of unclear pathogenesis, often associated with sleep disturbance.

It may also be associated with iron deficiency anaemia, chronic kidney disease, COPD, Parkinson's disease, gastric surgery, chronic venous insufficiency, hypothyroidism or a number of medications such as beta-blockers, H2 antagonists or neuroleptics. The prevalence is thought to be as high as 10-15% of the population and the condition is under-diagnosed.

Treatment is primarily with the use of dopamine agonists, usually used to treat Parkinson's disease, as these have been found to be highly effective for the management of restless legs.

A Sleep apnoea syndrome

Sleep apnoea syndrome causes

disturbed sleep as airway obstruction occurs when a patient falls into deep sleep and wakes the patient up. It is not associated with uncomfortable sensations or movement of the legs and is therefore an incorrect option.

C	Alcohol-related neuropathy

Alcohol related neuropathy causes damage to the nerves and a resultant focal neurology. Since this man has no focal neurology of any sort on examination, this is incorrect.

D	Diabetic neuropathy

Diabetic neuropathy causes damage to the nerves and a resultant focal neurology. Since this man has no focal neurology, restless leg syndrome is a more feasible answer.

E	Uraemic neuropathy

Uraemic neuropathy causes damage to the nerves and a resultant focal

C Alcohol-related neuropathy

Alcohol related neuropathy causes damage to the nerves and a resultant focal neurology. Since this man has no focal neurology of any sort on examination, this is incorrect.

D Diabetic neuropathy

Diabetic neuropathy causes damage to the nerves and a resultant focal neurology. Since this man has no focal neurology, restless leg syndrome is a more feasible answer.

E Uraemic neuropathy

Uraemic neuropathy causes damage to the nerves and a resultant focal neurology. Again, as this patient has no focal neurological signs or symptoms, this diagnosis is unlikely.

18630

Rate this question:

An 18-year-old Pakistani man has been referred by the Psychiatry SHO for advice after the following blood test results were obtained:

Hb	10.2 g/dl
WCC	9.3×10^9/l
PLT	290×10^9/l
Na^+	138 mmol/l
K^+	4.8 mmol/l
Creatinine	70 µmol/l
MCV	103 fl
Urea	3.9 mmol/l
Bilirubin	40 µmol/l
Albumin	29 g/l
GGT	120 IU/l
AST	80 IU/l
ALP	270 IU/l

His family report that he has been hostile and irritable for the past 1 year

hostile and irritable for the past 1 year. His A-level grades were significantly worse than anticipated, and teachers have commented that he has been unusually unruly during lessons. He was admitted onto the Short-stay Psychiatric Ward for further evaluation.

On examination, his Mini-Mental State Examination score was 23/30. He had a slurring dysarthria and tremor affecting his right upper limb. His right toe and ankle appeared to be held in a fixed flexed position. Tone was increased in his limbs. Power was preserved in all muscle groups with symmetrical reflexes and down going plantar responses. Rapid alternating movements of the fingers were slow.

Which one of the following investigations is of most diagnostic relevance?

A	Blood film for acanthocytes
B	Voltage-gated potassium channel antibodies

affecting his right upper limb. His right toe and ankle appeared to be held in a fixed flexed position. Tone was increased in his limbs. Power was preserved in all muscle groups with symmetrical reflexes and down going plantar responses. Rapid alternating movements of the fingers were slow.

Which one of the following investigations is of most diagnostic relevance?

A	Blood film for acanthocytes
B	Voltage-gated potassium channel antibodies
C	Bone marrow examination
D	Urinary porphyrins
E	24 h urinary copper quantification

E	24 h urinary copper quantification

The deranged liver function tests in association with neurological signs are suggestive of Wilson's disease. Typical neurological signs include behavioural change, parkinsonism, tremor and dystonia. Kayser–Fleischer rings may require slit lamp examination to visualise. Copper deposition results in hepatosplenomegaly. Hepatic biopsy may demonstrate hepatitis and cirrhosis with increased copper content. Measurement of free serum copper, total serum copper and serum caeruloplasmin may be helpful, but 24 h urinary copper is the most accurate test.

A	Blood film for acanthocytes

Acanthocytes are seen in a range of neurological illnesses, but the clinical picture presented here suggest a combination of liver and brain disease, making Wilson's the most likely explanation.

making Wilson's the most likely explanation.

B	Voltage-gated potassium channel antibodies

VGKC-associated encephalitis presents with seizures and encephalopathy, so doesn't seem to fit the picture presented here.

C	Bone marrow examination

Nothing in the clinical presentation or blood results suggests that a bone marrow biopsy is required.

D	Urinary porphyrins

Patients with acute intermittent porphyria present with combinations of neuropsychiatric disturbance, abdominal pain, hypertension and tachycardia, and may have a predominantly motor polyneuropathy.

An otherwise fit-and-well 36-year-old woman was running along the railway station platform to catch her train when suddenly, according to eye witnesses, she stopped, grabbed the back of her head and collapsed, started shaking and became unconscious. On questioning of her close family, they report that she is a smoker and, apart from the occasional headache, she had no other illnesses and was not on any other medication. An urgent cerebral computed tomography (CT) and CT angiogram confirmed the diagnosis of aneurysmal subarachnoid haemorrhage.

Which of the following treatment modalities is not normally instituted as a means of preventing secondary cerebral ischaemia in such patients?

A	Close monitoring and control of the blood pressure
B	Maintaining adequate hydration of the patient to prevent hypovolaemia

and was not on any other medication. An urgent cerebral computed tomography (CT) and CT angiogram confirmed the diagnosis of aneurysmal subarachnoid haemorrhage.

Which of the following treatment modalities is not normally instituted as a means of preventing secondary cerebral ischaemia in such patients?

A	Close monitoring and control of the blood pressure
B	Maintaining adequate hydration of the patient to prevent hypovolaemia
C	The use of a calcium antagonist, eg nimodipine
D	Administration of aspirin to prevent platelet activation
E	Early surgical intervention to clip the aneurysm

D	Administration of aspirin to prevent platelet activation

Most clinicians favour discontinuation of all anti-platelets and anticoagulants following SAH. The patient may require anti-platelets following treatment of the aneurysm with a coil, but this should be done postoperatively in accordance with local protocols.

A	Close monitoring and control of the blood pressure

Patients with aneurysmal SAH are admitted to ITU/HDU settings for continuous haemodynamic and neurological monitoring. Neurological deterioration can occur in 35% of patients in the first 24 h, and pulmonary oedema and cardiac arrhythmias complicate 23 and 35% of patients, respectively. There are no clear guidelines surrounding BP control in these patients; the 2012 American Stroke Association guidelines state that decreasing systolic BP to <160 mmHg is

reasonable. Ideally BP should be managed in accordance with the cerebral perfusion pressure, which requires continuous intracranial pressure monitoring. Vasodilators such as nitroprusside or nitroglycerin should be avoided due to the risk of raising intracranial pressure.

B	Maintaining adequate hydration of the patient to prevent hypovolaemia

IV fluid administration should target euvolaemia and normal electrolyte balance. Hypovolaemia is a risk factor for ischaemic complications.

C	The use of a calcium antagonist, eg nimodipine

Nimodipine 60 mg 4-hourly should be administered to all patients with aneurysmal SAH for 21 days. Initially thought to reduce the risk of vasospasm (although this is now disputed), nimodipine has been shown

Nimodipine 60 mg 4-hourly should be administered to all patients with aneurysmal SAH for 21 days. Initially thought to reduce the risk of vasospasm (although this is now disputed), nimodipine has been shown to improve outcomes and reduce the risk of death following aneurysmal SAH.

E	Early surgical intervention to clip the aneurysm

Patients are at a substantial risk of re-bleeding following an aneurysmal SAH: 3–4% in the first 24 h and 1–2% each day for the first month. Mortality associated with re-bleeding is around 70%. Aneurysm repair should be performed within 24–72 hours. Surgical clipping and endovascular coiling are the most commonly used techniques, and which is most appropriate depends on the size, location and other morphological features of the aneurysm.

6071

Rate this question:

A 40-year-old woman is admitted with a history of unsteadiness and slurring of speech. This has worsened over a period of three months. In addition, she complains of a tremor affecting her right hand and diplopia on right lateral gaze.

She has a past history of breast carcinoma treated with radiotherapy, and rheumatoid arthritis. She is a smoker of 30 cigarettes a day and takes regular diclofenac for her arthritis.

On examination, she is dysarthric. Fundoscopy is normal, but there is marked horizontal nystagmus and evidence of a right VI nerve palsy. There also appears to be some mild facial weakness on the right side. On testing hearing with Weber's test, a louder tone is heard in the left ear. On conducting the Rinne test, both ears are normal.

On examination of the upper limb, there is a right intention tremor and dysdiadochokinesis. Tone, power and reflexes are normal. On examination of

dysdiadochokinesis. Tone, power and reflexes are normal. On examination of the lower limb, tone, power and reflexes are normal; however, she appears to walk with a broad-based gait and is leaning to the right.

Breast examination, chest and abdomen are entirely normal.

Investigations:

Hb	11.3 g/dl
WCC	9.8×10^9/l
PLT	243×10^9/l
Na^+	134 mmol/l
K^+	3.6 mmol/l
Creatinine	108 μmol/l
Ca^{++}	2.4 mmol/l

Magnetic resonance scan shows a calcified lesion broadly attached to the petrous part of the right temporal bone.

In view of the above history and findings, what is the likely cause of

Ca^{++}	2.4 mmol/l

Magnetic resonance scan shows a calcified lesion broadly attached to the petrous part of the right temporal bone.

In view of the above history and findings, what is the likely cause of this patient's symptoms?

A	Vestibular schwannoma
B	Recurrent breast carcinoma with cerebral metastases
C	Meningioma of the cerebellar pontine angle
D	Cerebellar paraneoplastic syndrome
E	Brainstem infarction

C Meningioma of the cerebellar pontine angle

This patient has a combination of right cerebellar dysfunction with right-sided cranial nerve palsies (VI, VII and VIII). In Weber's test, when sensorineural hearing loss is present, the sound will localise to the good ear, whereas in conductive hearing loss the occluded ear perceives the louder sound (the original observation by Weber being that, 'if the neurologic function is intact, sounds will be perceived to be louder in an occluded ear canal than in an "open" one'). In this case the Weber test therefore either indicates a sensorineural loss in the right ear or conductive hearing loss in the left ear. The Rinne test is a less sensitive test in cases of neural hearing loss, and the results can be rather equivocal as in this case. Magnetic resonance imaging (MRI) shows a meningioma (calcified, broad-based lesion) within the right cerebellar pontine area, which would account for the combination of right VI, VII and VIII palsies as well as cerebellar signs.

A 61-year-old man presented with a 2-year history of erectile dysfunction and incomplete bladder emptying and a 1-year history of progressive unsteadiness and slurred speech.

Examination revealed intact higher mental function but slurred speech. Cranial nerves were otherwise normal. He had a jerky postural tremor but no tremor at rest. His tone was mildly increased in both arms but normal in the legs. Fine movements of the hand were slow. His gait was ataxic. The remainder of the neurological examination was normal.

Which of these is the most likely diagnosis?

A	Progressive supranuclear palsy
B	Spinocerebellar ataxia
C	Friedrich's ataxia

Examination revealed intact higher mental function but slurred speech. Cranial nerves were otherwise normal. He had a jerky postural tremor but no tremor at rest. His tone was mildly increased in both arms but normal in the legs. Fine movements of the hand were slow. His gait was ataxic. The remainder of the neurological examination was normal.

Which of these is the most likely diagnosis?

A	Progressive supranuclear palsy
B	Spinocerebellar ataxia
C	Friedrich's ataxia
D	Multiple system atrophy
E	Normal Pressure Hydrocephalus

A 61-year-old man presented with a 2-year history of erectile dysfunction and incomplete bladder emptying and a 1-year history of progressive unsteadiness and slurred speech.

Examination revealed intact higher mental function but slurred speech. Cranial nerves were otherwise normal. He had a jerky postural tremor but no tremor at rest. His tone was mildly increased in both arms but normal in the legs. Fine movements of the hand were slow. His gait was ataxic. The remainder of the neurological examination was normal.

Which of these is the most likely diagnosis?

Your answer was correct

A	Progressive supranuclear palsy
B	Spinocerebellar ataxia

D Multiple system atrophy

This man has symmetrical arm rigidity, a postural tremor (i.e. he has parkinsonian features) as well as cerebellar and autonomic features (erectile dysfunction and incomplete bladder voiding). This fits with a diagnosis of multi-system atrophy (MSA, also known as Shy-Drager syndrome), which is a Parkinson's-plus syndrome accompanied by cerebellar and/or autonomic features.

Autonomic features include postural hypotension (seen in 70% of MSA patients), urinary incontinence and urinary frequency. Erectile dysfunction occurs in virtually all men with MSA. The autonomic problems described here may be seen in idiopathic Parkinson's disease too, but occur earlier and are more severe in MSA.

Cerebellar features include gait ataxia, slurring dysarthria and limb ataxia.

The parkinsonian features include symmetrical bradykinesia, rigidity and tremor, which is characteristically a

tremor, which is characteristically a jerky tremor of the outstretched hands (postural), but can also be an action tremor or rest tremor. They are poorly responsive to levodopa. Other features of MSA include early instability and falls, orofacial dystonia and rapid eye movement (REM) sleep disturbances. Cognition is usually intact in MSA. Compare this to idiopathic Parkinson's disease which is asymmetrical at onset, has a rest tremor and responds well to levodopa.

MSA can have a parkinsonian-predominant (MSA-P) or cerebellar-predominant (MSA-C) phenotype. It is a progressive disorder with a mean survival of 6-9 months.

A	Progressive supranuclear palsy

Progressive supranuclear palsy (PSP) is a 'Parkinson's-plus' syndrome that features cognitive impairment and restricted vertical eye movements, which this man does not have.

B Spinocerebellar ataxia

The spino-cerebellar ataxias (SCAs) are a group of hereditary ataxias which can be purely cerebellar, or involve other parts of the nervous system, causing dementia, extrapyramidal features or ophthalmoplegia. Autonomic problems such as erectile dysfunction or incomplete bladder emptying are not usually seen in the SCAs.

C Friedrich's ataxia

Although the patient has features of cerebellar ataxia, which is seen in Friedreich's, he does not have any other supporting features such as onset in adolescence, up-going plantars, absent ankle jerks, foot deformity or kyphoscoliosis.

E Normal Pressure Hydrocephalus

Normal-pressure hydrocephalus (NPH)

Hydrocephalus

Normal-pressure hydrocephalus (NPH) is a common disorder in the elderly and has three main symptoms and signs: gait difficulty, cognitive impairment and urinary incontinence.

The gait disturbance is usually apraxic rather than ataxic, i.e. a feeling of feet 'stuck' to the floor, with short steps, slow turning and postural instability. Arm swing is usually preserved, unlike in Parkinson's disease.

Cognitive impairment takes the form of impaired attention, slowness of thought and apathy.

In contrast to multi-system atrophy, patients with NPH have urinary urgency and incontinence, rather than retention. Moreover in NPH, cognition is affected earlier in the course of the disease.

NPH can be detected on imaging (MRI or CT) and treated with a ventriculo-peritoneal shunt; therefore it is important to distinguish between NPH and MSA.

A 26-year-old woman is referred by her general practitioner (GP) with a 24 h history of gradual deterioration in her right visual acuity, associated with pain on eye movement, to the extent that she can now only perceive light. She also complains of a general feeling of fatigue for the past few weeks. She has no other neurological symptoms.

There is nil to find on general examination, but on fundoscopy of her right eye the optic disc appears to be swollen. Her left optic disc is normal in appearance.

What would be the most appropriate investigation to institute at this stage?

A	CT head followed by lumbar puncture
B	HIV testing
C	MRI brain
D	Auto-antibody and inflammatory screen

pain on eye movement, to the extent that she can now only perceive light. She also complains of a general feeling of fatigue for the past few weeks. She has no other neurological symptoms.

There is nil to find on general examination, but on fundoscopy of her right eye the optic disc appears to be swollen. Her left optic disc is normal in appearance.

What would be the most appropriate investigation to institute at this stage?

A	CT head followed by lumbar puncture
B	HIV testing
C	MRI brain
D	Auto-antibody and inflammatory screen
E	Visual evoked response testing

C MRI brain

This patient's symptoms are consistent with acute optic neuritis. This can occur in isolation, but is also strongly associated with multiple sclerosis (MS). Typically patients presenting for the first time with acute optic neuritis are otherwise healthy individuals who complain of a low-level viral illness a few days/weeks before attending with visual loss. MRI has the dual advantage of demonstrating evidence of optic nerve inflammation and demyelination, and ruling out any structural lesion.

A CT head followed by lumbar puncture

Although lumbar puncture is likely to show a rise in total protein and potentially oligoclonal banding, an MRI is much more useful with respect to detecting any structural abnormality.

B HIV testing

is much more useful with respect to detecting any structural abnormality.

B	HIV testing

HIV is associated with CMV retinitis, and only rarely on presentation with acute optic neuritis. We're given no risk factors here to suggest HIV infection, however.

D	Auto-antibody and inflammatory screen

Although inflammatory markers may be elevated, they are relatively non-specific versus an MRI scan.

E	Visual evoked response testing

We already know that this patient has evidence of optic neuritis, and hence MRI scanning to confirm inflammatory changes and rule out a structural lesion is much more useful.

A 40-year-old man, who has been doing some work repairing his car, is found by his neighbour lying down under the car, unable to get up due to dizziness. He tells the ambulance crew that he was straining to get to a particular part of the engine when he began to get a severe occipital headache and neck pain. Symptoms then increased over a period of a few hours. There is no past medical history of note apart from mild hypertension, which is managed with amlodipine 5 mg.

On examination his BP is 155/95 mmHg. He has pain and numbness affecting the right side of his face, hoarseness of his voice when he tries to speak, loss of pain and temperature sensation on the left side of the body, diplopia and dysphagia, and Horner syndrome.

Which of the following is the most appropriate investigation?

A	Computerised tomography (CT) head

On examination his BP is 155/95 mmHg. He has pain and numbness affecting the right side of his face, hoarseness of his voice when he tries to speak, loss of pain and temperature sensation on the left side of the body, diplopia and dysphagia, and Horner syndrome.

Which of the following is the most appropriate investigation?

A	Computerised tomography (CT) head
B	Carotid artery duplex scanning
C	Magnetic resonance angiography (MRA)
D	Prothrombin time (PT)
E	Erythrocyte sedimentation rate (ESR)

A 40-year-old man, who has been doing some work repairing his car, is found by his neighbour lying down under the car, unable to get up due to dizziness. He tells the ambulance crew that he was straining to get to a particular part of the engine when he began to get a severe occipital headache and neck pain. Symptoms then increased over a period of a few hours. There is no past medical history of note apart from mild hypertension, which is managed with amlodipine 5 mg.

On examination his BP is 155/95 mmHg. He has pain and numbness affecting the right side of his face, hoarseness of his voice when he tries to speak, loss of pain and temperature sensation on the left side of the body, diplopia and dysphagia, and Horner syndrome.

Which of the following is the most appropriate investigation?

C Magnetic resonance angiography (MRA)

There is a very strong suspicion that this man has suffered a vertebral artery dissection. Often any history of trauma is relatively minor, and in this case it is probably due to hyperextension of the neck while working under the car. Magnetic resonance angiography is the investigation of choice: disturbed arterial flow, a pseudo-lumen and aneurismal dilatation can all be identified on scanning. The neurological features seen are typical of lateral medullary syndrome, seen after a vertebral artery dissection. Anticoagulation is the treatment of choice to prevent distal thromboembolic phenomena.

B Carotid artery duplex scanning

The symptoms here, including dizziness and neck pain, are much more suggestive of a posterior territory lesion. Carotid duplex

scanning

The symptoms here, including dizziness and neck pain, are much more suggestive of a posterior territory lesion. Carotid duplex scanning is therefore likely to be uninformative.

A	Computerised tomography (CT) head

CT is relatively insensitive in detecting posterior territory vascular lesions, and therefore it isn't the investigation of choice here.

D	Prothrombin time (PT)

Given that this patient has no significant past medical history, a clotting disorder characterised by abnormal PT is unlikely to be a feature with respect to his presentation.

A 52-year old woman presents to the Emergency Department with a 10-day history of pins and needles in her fingers and toes.

Over the past few days, she had noted that her legs felt slightly weak. She had tripped over while going to the toilet a couple of nights ago. She had had some diarrhoea 3 weeks earlier, but this had settled. Her only past medical history was of diet-controlled type 2 diabetes.

Baseline observations are:

Temperature	36.4 °C
Heart rate	116/min
Blood pressure	168/94 mmHg
O_2 saturation	95% on air

On examination, she was clammy, with a sinus tachycardia. Heart sounds were normal and her chest was clear. The abdomen was soft and non-tender. Cranial nerve examination revealed bilateral facial weakness. Peripheral nerve examination revealed grade 4

bilateral facial weakness. Peripheral nerve examination revealed grade 4 weakness distally, affecting the upper and lower limbs. Biceps, triceps supinator and knee reflexes were just present with reinforcement. Ankle reflexes were absent; plantars were flexor. She had reduced joint position and vibration sensation affecting the toes, ankles and fingers. There was no sensory level.

Investigations were as follows:

WCC	9.2×10^9/l
Haemoglobin	13.6 g/dl
Platelets	214×10^9/l
Na^+	144 mmol/l
K^+	3.9 mmol/l
Urea	6.4 mmol/l
Creatinine	108 μmol/l
Bilirubin	12 μmol/l
Alanine aminotransferase	32 IU/l

9:24
tps://mypastest.pastest.com

Chest X-ray	Normal cardiac silhouette. No focal consolidation

What investigation is most likely to contribute to the suspected clinical diagnosis?

A	Anti-acetylcholine receptor antibodies
B	Muscle biopsy
C	Magnetic resonance imaging (MRI) of the brain
D	Nerve conduction studies (NCS) and electromyography (EMG)
E	MRI cervical spine

some diarrhoea 3 weeks earlier, but this had settled. Her only past medical history was of diet-controlled type 2 diabetes.

Baseline observations are:

Temperature	36.4 °C
Heart rate	116/min
Blood pressure	168/94 mmHg
O_2 saturation	95% on air

On examination, she was clammy, with a sinus tachycardia. Heart sounds were normal and her chest was clear. The abdomen was soft and non-tender. Cranial nerve examination revealed bilateral facial weakness. Peripheral nerve examination revealed grade 4 weakness distally, affecting the upper and lower limbs. Biceps, triceps supinator and knee reflexes were just present with reinforcement. Ankle reflexes were absent; plantars were flexor. She had reduced joint position and vibration sensation affecting the toes, ankles and fingers. There was no

D Nerve conduction studies (NCS) and electromyography (EMG)

This patient has Guillain–Barré syndrome (GBS), or acute inflammatory demyelinating polyradiculoneuropathy. The incidence is 1–2 per 100 000 population per year in the UK. The case here that describes weakness in all four limbs and the face is typical. Sensory loss is often relatively mild. Autonomic involvement is frequently seen.

GBS probably represents an immune-mediated attack on peripheral nerves. Many cases follow a viral infection, such as Epstein–Barr virus (EBV), cytomegalovirus (CMV) or infectious mononucleosis. *Campylobacter jejuni* enteritis is important and associated with more severe forms of GBS. Lumbar puncture is usually performed and is expected to show raised protein and normal cells. By 10 days post-symptom onset, nerve conduction studies may become abnormal, showing changes of demyelination.

Treatment is with IVIG or plasma exchange.

C	Magnetic resonance imaging (MRI) of the brain

The features described in this case are of a lower motor neurone syndrome, so MRI brain is unnecessary.

A	Anti-acetylcholine receptor antibodies

This is the test for myasthenia gravis – the distal weakness and sensory loss make this diagnosis untenable.

B	Muscle biopsy

In GBS muscle biopsy would be normal.

E	MRI cervical spine

In many cases of GBS there will be concern as to whether limb symptoms

A 35-year-old man presented with a 9-month history of tremor of his right hand with increasing difficulty over the same period with writing. In the last few months, he had also felt increasingly nauseated and had lost his appetite. He described his uncle as developing similar problems with writing at about the same age.

On examination, he was mildly icteric. Respiratory, cardiovascular and abdominal examinations were otherwise normal.

On neurological examination, he had a mild tremor that was present at rest and also when his hands were outstretched. The tremor was bilateral but more prominent on the right. He had difficulty with fine finger movements and there was a mild increase in tone in his upper limbs bilaterally. The rest of the neurological examination was normal.

Which investigation is most likely to help support the diagnosis?

On neurological examination, he had a mild tremor that was present at rest and also when his hands were outstretched. The tremor was bilateral but more prominent on the right. He had difficulty with fine finger movements and there was a mild increase in tone in his upper limbs bilaterally. The rest of the neurological examination was normal.

Which investigation is most likely to help support the diagnosis?

A	Vitamin B12
B	Liver function tests
C	Iron studies
D	Genetic testing
E	Copper studies (serum and urine)

A 35-year-old man presented with a 9-month history of tremor of his right hand with increasing difficulty over the same period with writing. In the last few months, he had also felt increasingly nauseated and had lost his appetite. He described his uncle as developing similar problems with writing at about the same age.

On examination, he was mildly icteric. Respiratory, cardiovascular and abdominal examinations were otherwise normal.

On neurological examination, he had a mild tremor that was present at rest and also when his hands were outstretched. The tremor was bilateral but more prominent on the right. He had difficulty with fine finger movements and there was a mild increase in tone in his upper limbs bilaterally. The rest of the neurological examination was normal.

Which investigation is most likely to help support the diagnosis?

E Copper studies (serum and urine)

The most likely diagnosis is Wilson's disease. This is an autosomal recessive condition due to mutations of a copper-transporting protein gene (*ATP7B*) on chromosome 13. The major features are neurological (normally a progressive extrapyramidal disorder due to copper deposition in the basal ganglia), psychiatric (behavioural changes being prominent), hepatic (presenting with features of liver failure/cirrhosis) and ocular (the brownish-coloured Kayser–Fleischer rings – copper deposition in Descemet's membrane, best seen on slit-lamp examination). Diagnosis can be made on copper studies (increased urinary copper excretion, reduced serum caeruloplasmin). Treatment is with copper chelation, with the first-line treatment normally being pencillamine.

D Genetic testing

D Genetic testing

Around 90% of patients with Wilson's disease will have mutations in both copies of the *ATP7B* gene. However, over 300 different mutations have been described and as such there is a risk of a false-negative result. Therefore, this investigation is not the most likely to support the diagnosis.

A Vitamin B12

It would be useful to check serum B12 levels in patients with neuropathy or subacute combined degeneration of the cord. However, the tremor and family history are suggestive of an alternative diagnosis.

B Liver function tests

Checking the LFTs would certainly be useful given the icterus. However, it will not confirm the underlying diagnosis.

A 74-year-old man presents to his GP with pain below the left ear followed by the rapid onset of drooping of his mouth for 2 days, resulting in dribbling of his food, which he finds very embarrassing. He has also noticed a change in taste in his mouth as well as a failure of his eye on the same side to close properly; this is also associated with excessive tearing. He reports that he is otherwise fit and well, apart from 'a little blood pressure'.

On examination, all other cranial nerves are normal. The remainder of the neurological examination and general examination is also normal. Auroscope examination shows no abnormality in the left ear.

Which of the following is the most appropriate treatment to institute in this case?

A	Aciclovir
B	High-dose oral prednisolone

close properly; this is also associated with excessive tearing. He reports that he is otherwise fit and well, apart from 'a little blood pressure'.

On examination, all other cranial nerves are normal. The remainder of the neurological examination and general examination is also normal. Auroscope examination shows no abnormality in the left ear.

Which of the following is the most appropriate treatment to institute in this case?

A	Aciclovir
B	High-dose oral prednisolone
C	Lateral tarsorrhaphy of the affected eye
D	Oral antibiotics
E	Oral amitriptyline

A 74-year-old man presents to his GP with pain below the left ear followed by the rapid onset of drooping of his mouth for 2 days, resulting in dribbling of his food, which he finds very embarrassing. He has also noticed a change in taste in his mouth as well as a failure of his eye on the same side to close properly; this is also associated with excessive tearing. He reports that he is otherwise fit and well, apart from 'a little blood pressure'.

On examination, all other cranial nerves are normal. The remainder of the neurological examination and general examination is also normal. Auroscope examination shows no abnormality in the left ear.

Which of the following is the most appropriate treatment to institute in this case?

B High-dose oral prednisolone

Bell's palsy (lower motor neurone facial nerve palsy) is one of the most common disorders to affect the cranial nerves, but it is a diagnosis of exclusion. Patients are often alarmed at the rapid onset of the facial weakness and the resultant cosmetic appearance, commonly fearing that they have suffered a stroke. The onset of the weakness might be preceded by pain below the ear, which usually resolves within a few days. The weakness also stabilises after a couple of days and is always unilateral. Patients often complain of drooling and excessive tearing. They may also report an alteration in taste and/or hearing (hyperacusis). It is important to remember that the involvement of the facial nerve (i.e. a lower motor neurone palsy) results in weakness/paralysis of the entire face on the affected side (i.e. upper and lower halves). Signs include an inability to wrinkle the forehead, to close the eye, to blow out the cheek or to smile.

eye, to blow out the cheek or to smile. No specific laboratory tests exist to confirm the diagnosis of Bell's palsy, since it is a clinical diagnosis. Other causes of facial palsy may require one of a number of imaging studies depending on the clinical setting. Although spontaneous recovery is good if a patient presents within a few days of onset, high-dose oral steroids may be given in an effort to reduce the nerve oedema. Whilst RCT evidence is limited, trials (including a Cochrane analysis) do seem to support use of corticosteroids.

A	Aciclovir

Since there is some concern that Bell's palsy may have a viral aetiology, antiviral treatment was previously considered, but a Cochrane analysis concluded it has no value.

C	Lateral tarsorrhaphy of the affected eye

Priority should be given to protecting

A 30-year-old man is referred urgently to the Neurology Outpatient Clinic. He has a complex past medical history, but unfortunately his previous notes are not available to you. You gather that he was involved in a road traffic accident as a child and required emergency neurosurgery following skull fracture. During the rest of his childhood he required hormone replacement injections and regular assessment by a paediatric endocrinologist. In adult life he has been well, and compliant with thyroxine and hydrocortisone therapy.

He presented to his general practitioner six months ago with weight loss and insomnia. This occurred against a background of worsening self-neglect and mood change. He was commenced on fluoxetine to little effect. He then presented to a general medical clinic with clumsiness and diplopia. A period of inpatient investigation did not reveal a cause for his symptoms.

In the clinic today, you note global cognitive impairment and emotional

cognitive impairment and emotional lability. He has multidirectional nystagmus and severe ataxia. Motor examination reveals globally increased tone with myoclonic jerks.

Investigations to date reveal:

CT brain	No abnormality
Lumbar puncture	Normal biochemistry and cell count
Thyroid function	Euthyroid
Haematinics	Normal

Given the possible aetiology of his neurological deterioration, which investigation would you do next?

A	VDRL testing
B	Short synacthen test
C	Brain biopsy

Investigations to date reveal:

CT brain	No abnormality
Lumbar puncture	Normal biochemistry and cell count
Thyroid function	Euthyroid
Haematinics	Normal

Given the possible aetiology of his neurological deterioration, which investigation would you do next?

A	VDRL testing
B	Short synacthen test
C	Brain biopsy
D	EEG
E	HIV test

occurred against a background of worsening self-neglect and mood change. He was commenced on fluoxetine to little effect. He then presented to a general medical clinic with clumsiness and diplopia. A period of inpatient investigation did not reveal a cause for his symptoms.

In the clinic today, you note global cognitive impairment and emotional lability. He has multidirectional nystagmus and severe ataxia. Motor examination reveals globally increased tone with myoclonic jerks.

Investigations to date reveal:

CT brain	No abnormality
Lumbar puncture	Normal biochemistry and cell count
Thyroid function	Euthyroid
Haematinics	Normal

Given the possible aetiology of his neurological deterioration, which investigation would you do next?

D EEG

The diagnosis is Creutzfeldt–Jacob disease (CJD), most likely secondary to the use of cadaveric human growth hormones in the 1980s. CJD is one of the prion-related neurodegenerative diseases, the pathology of which remains poorly understood. Sporadic CJD has an annual incidence of around 1 per million. A cohort of iatrogenic CJD cases resulting from cadaveric tissue product or infected neurosurgical instrumentation was first recognised in 1985. Change in practice has caused a fall in the numbers of iatrogenic CJD, although with possible incubation up to 30 years, cases may still present.

As a group, iatrogenic CJD is clinically similar to the sporadic form although the age of onset is generally younger and progression of sporadic CJD is more rapid. Common clinical features include: progressive mental deterioration (100%); myoclonus or movement disorder (100%); cerebellar signs (70%); pyramidal weakness

signs (70%); pyramidal weakness (62%); and behavioural abnormality (55%). Investigations are generally normal. In later stages imaging may show cerebral atrophy. Cerebrospinal fluid examination can show a high normal protein and elevation of immunoglobulin G (IgG). 13-3 protein analysis may be useful in confirming a diagnosis of sporadic CJD.

Electroencephalogram changes of 1 or 2 s triphasic sharp waves against a background of depressed activity are seen in fewer cases of variant versus classical CJD, but the investigation is still worth doing. Although brain biopsy is quoted as the gold standard investigation, its antemortem use is controversial and certainly it should not be considered before other less invasive tests.

A	VDRL testing

There is no evidence of exposure to syphilis, in contrast to CJD, where the history is clearly suggestive of

syphilis, in contrast to CJD, where the history is clearly suggestive of exposure to infected material.

B	Short synacthen test

Adrenal insufficiency is associated with hypotension and hyperkalaemia, rather than the features of nystagmus and ataxia seen here.

C	Brain biopsy

Brain biopsy is diagnostic for CJD, but the combination of MRI, EEG and lumbar puncture is usually sufficient to make the diagnosis in life.

E	HIV test

HIV encephalopathy with progressive dementia is seen in the end stages of HIV. The lack of features of immunosuppression counts against this as the underlying diagnosis.

7324

As the CT2 on call, you are asked to review a previously well 30-year-old farmer on the ward. He was admitted with severe lower respiratory tract infection post influenza, and after multiple cutaneous abscesses were noted he was commenced on flucloxacillin and gentamicin.

According to the notes, his neurological examination on examination was entirely normal. You are asked to see him by the nurses some 48 h later as he is complaining of limb weakness, and the nurses note that he has ptosis with lack of facial expression, and his saturations are dipping to below 90% as he is hypoventilating.

On examination, it appears that the degree of limb weakness fluctuates somewhat. Deep tendon reflexes and sensation are preserved.

Investigations:

Hb	12.4 g/dl
WCC	$13.1 \times 10^9/l$

Hb	12.4 g/dl
WCC	13.1×10^9/l
PLT	201×10^9/l
Na^+	140 mmol/l
K^+	4.5 mmol/l
Creatinine	120 μmol/l

Staphylococcus aureus is cultured from cutaneous abscesses.

What is the diagnosis most suggested by this clinical picture?

A	Myasthenia gravis
B	Guillain–Barré syndrome
C	Botulism
D	*Clostridium difficile*
E	Organophosphate poisoning

As the CT2 on call, you are asked to review a previously well 30-year-old farmer on the ward. He was admitted with severe lower respiratory tract infection post influenza, and after multiple cutaneous abscesses were noted he was commenced on flucloxacillin and gentamicin.

According to the notes, his neurological examination on examination was entirely normal. You are asked to see him by the nurses some 48 h later as he is complaining of limb weakness, and the nurses note that he has ptosis with lack of facial expression, and his saturations are dipping to below 90% as he is hypoventilating.

On examination, it appears that the degree of limb weakness fluctuates somewhat. Deep tendon reflexes and sensation are preserved.

Investigations:

Hb	12.4 g/dl

C Botulism

A 'descending paralysis' can be seen with botulism. Here, the skin abscesses may be the source of infection.

A Myasthenia gravis

The acute onset and development following abscess and antibiotic treatment would make MG less likely. However, it is important to realise that aminoglycosides such as gentamicin should not be given to patients with MG in view of their detrimental effect on neuromuscular transmission. This is a key piece of knowledge that the MRCP examiners like to test.

B Guillain–Barré syndrome

GBS typically presents as an acute motor sensory neuropathy. The preservation of reflexes and normal sensation make this less likely.

D *Clostridium difficile*

motor sensory neuropathy. The preservation of reflexes and normal sensation make this less likely.

D	*Clostridium difficile*

There is no history of diarrhoea, and it would not satisfactorily explain the neurological signs that are described here. Diagnosis of *C. difficile* is by stool microscopy.

E	Organophosphate poisoning

Whilst organophosphate poisoning is a possibility given his occupation as a farmer, it seems unlikely given that the symptoms of weakness started after the abscesses.

21475

Rate this question:

Next Question

Previous Question Tag Question

A 19-year-old woman presented with fever and confusion. She had been well until earlier that day when she started to complain of a severe occipital headache and had vomited three times. She had become increasingly confused over the day and was now very agitated and restless. She had been previously well, and the only other history from her mother was that she was allergic to penicillin.

Observations showed a temperature of 39 °C, blood pressure 100/50 mmHg, pulse 110 beats/min, saturations 98% on room air, respiratory rate 17/min.

On examination, the patient was moderately confused. Cardiovascular, respiratory and abdominal examinations were otherwise normal.

Neurological examination showed no neck stiffness and no photophobia. The cranial nerve and limb examination appeared normal. While examining her, she had a short-lived generalised tonic–clonic seizure, lasting less than 1 min. A magnetic resonance imaging (MRI) scan was performed showing abnormal high signal in the right

Neurological examination showed no neck stiffness and no photophobia. The cranial nerve and limb examination appeared normal. While examining her, she had a short-lived generalised tonic–clonic seizure, lasting less than 1 min. A magnetic resonance imaging (MRI) scan was performed showing abnormal high signal in the right temporal lobe.

What is the most appropriate next step in management?

A	IV aciclovir
B	Third-generation cephalosporin
C	IV phenytoin
D	IV methylprednisolone
E	IV clarithromycin

A IV aciclovir

The most likely diagnosis is viral encephalitis (possibly Herpes simplex), and immediate treatment with aciclovir is necessary. Mortality and morbidity in this condition are directly related to the time taken to start antiviral treatment, so acyclovir must be given even before the diagnosis is confirmed. The combination of fever, headache, confusion and seizures is extremely suggestive of viral encephalitis. In addition to urgent brain imaging, this patient requires a lumbar puncture. This would be expected to show raised protein, lymphocytosis and modestly reduced glucose. HSV PCR in the CSF should be sent, and is a sensitive and specific test for this condition.

B Third-generation cephalosporin

This is an appropriate treatment for bacterial meningitis, but the history here is more compatible with encephalitis (confusion and seizures in

encephalitis (confusion and seizures in addition to headache and fever). In addition, there is no evidence on examination of meningism (neck stiffness and photophobia).

C	IV phenytoin

The patient has had a brief, self-terminating generalised seizure, so it would be reasonable to start an antiepileptic drug, but there is no indication to load with IV phenytoin as this is generally only indicated in status epilepticus.

D	IV methylprednisolone

The priority here is to treat for possible Herpes simplex encephalitis. It is recognised that many cases of encephalitis are caused by antibody-mediated disease (e.g. voltage-gated potassium channel complex antibodies), which may be treated with high-dose steroids, but infectious aetiologies need to be ruled out first.

A 21-year-old woman is brought as an emergency to the resuscitation room. She is unaccompanied and from review of her personal possessions does not live in the hospital catchment area. She has a prescription for dihydrocodeine and Creon tablets.

On examination, she is comatose. You note a left false eye, large scar in the right flank region with a related transabdominal scar. At the back of her head you note scars of previous neurosurgery. She undergoes computerised tomography (CT) brain scanning as an emergency. Although the posterior fossa is poorly visualised, there is a suggestion of multiple lesions within the cerebellum and early hydrocephalus. She is referred to the neurological team. In the absence of past medical history they ask if you can suggest a possible aetiology.

Which of the following is the most likely syndrome?

A	Friedreich's ataxia

right flank region with a related transabdominal scar. At the back of her head you note scars of previous neurosurgery. She undergoes computerised tomography (CT) brain scanning as an emergency. Although the posterior fossa is poorly visualised, there is a suggestion of multiple lesions within the cerebellum and early hydrocephalus. She is referred to the neurological team. In the absence of past medical history they ask if you can suggest a possible aetiology.

Which of the following is the most likely syndrome?

A	Friedreich's ataxia
B	Multiple system atrophy
C	Chronic alcohol use
D	Von Hippel–Lindau disease
E	Metastatic melanoma

emergency to the resuscitation room. She is unaccompanied and from review of her personal possessions does not live in the hospital catchment area. She has a prescription for dihydrocodeine and Creon tablets.

On examination, she is comatose. You note a left false eye, large scar in the right flank region with a related transabdominal scar. At the back of her head you note scars of previous neurosurgery. She undergoes computerised tomography (CT) brain scanning as an emergency. Although the posterior fossa is poorly visualised, there is a suggestion of multiple lesions within the cerebellum and early hydrocephalus. She is referred to the neurological team. In the absence of past medical history they ask if you can suggest a possible aetiology.

Which of the following is the most likely syndrome?

Your answer was correct

A Friedreich's ataxia

D Von Hippel–Lindau disease

With no history and no medical records, working out what is going on may at first seem impossible. However, some medical detective work can help narrow the differential. The surgical stigmata suggest previous brain, renal and abdominal resections. Ocular pathology is suggested by the false eye, while her current medication points to a pancreatic disorder. Von Hippel-Lindau is a rare autosomal dominant condition causing a variety of benign and malignant tumours. The mean age of presentation is 26. Clinical features include cerebellar, spinal and retinal capillary haemangioblastomas, renal cell carcinomas, pheochromocytomas, and neuroendocrine tumours of the pancreas. Although benign, haemangioblastomas can cause pressure effects, often necessitating surgical removal, or bleed. Regular screening has improved the prognosis of VHL patients. Screening investigations and frequency vary according to age, but include retinal

investigations and frequency vary according to age, but include retinal and neurological examination, plasma or 24-hour urinary metanephrines, audiology assessment and MRI scans of the neuroaxis and abdomen.

A Friedreich's ataxia

Friedreich's ataxia is the most common inherited ataxia; it does not result in lesions requiring surgery.. Evidence of posterior-column sensory loss, kyphoscoliosis, diabetes mellitus, cardiomyopathy or deafness may be found.

B Multiple system atrophy

Multiple system atrophy (MSA) is a neurodegenerative disorder characterised by parkinsonism, autonomic dysfunction, cerebellar abnormalities, and corticospinal degeneration. Similar to Friedreich's ataxia, it would not account for all the signs and scars seen in this patient.

characterised by parkinsonism, autonomic dysfunction, cerebellar abnormalities, and corticospinal degeneration. Similar to Friedreich's ataxia, it would not account for all the signs and scars seen in this patient.

C	Chronic alcohol use

Chronic alcohol abuse could account for her pancreatic dysfunction, but not the other features seen here. Furthermore, one may expect to see stigmata of chronic liver disease.

E	Metastatic melanoma

The most frequent metastatic sites for melanoma include the brain, liver, lung and bone. No skin lesions are described in the vignette and, although amelanocytic melanoma is recognised, it is rare.

7344

Rate this question:

A 23-year-old secretary is brought to Accident and Emergency by her partner after experiencing what is described as 'a fit' earlier in the day. She has been off work for the past week complaining of a headache, nausea and lethargy. Her partner reports that she has become increasingly confused over the past 2 days, and aggressive towards him. She also mentioned experiencing strange smells and tastes.

Earlier in the day, he noticed that she became less responsive with jerking movements affecting her left arm and hand, which then spread to affect her left leg. The episode lasted about 5 min, after which she gradually became more rousable.

On examination, the patient is disorientated in place and time with an abbreviated mental state examination score of 6 out of 10. There are no focal neurological signs.

Investigations:

Haemoglobin	11.3 g/dl

White cell count	7.4×10^9/l
Haematocrit	0.565
Mean corpuscular volume	88.6 fl
Platelets	247×10^9/l
Sodium	139 mmol/l
Potassium	4.9 mmol/l
Urea	7.1 mmol/l
Creatinine	81 μmol/l
Bilirubin	8 mmol/l
Alanine aminotransferase	22 U/l
Albumin	49 U/l
Alkaline phosphatase	31 U/l
Gamma-glutamyltranspeptidase	40 U/l
Ca^{2+}	2.35 mmol/l
Erythrocyte sedimentation rate	18 mm/1st hour

Ca^{2+}	2.35 mmol/l
Erythrocyte sedimentation rate	18 mm/1st hour
C-Reactive protein	34 mg/l
Chest radiograph	Unremarkable
CT brain	Normal

Which one of the following is the most appropriate next investigation?

A	Cerebrospinal fluid examination
B	Computed tomography venography
C	Electroencephalography
D	Magnetic resonance imaging brain
E	Cortical brain biopsy

11:48
tps://mypastest.pastest.com 14

A 23-year-old secretary is brought to Accident and Emergency by her partner after experiencing what is described as 'a fit' earlier in the day. She has been off work for the past week complaining of a headache, nausea and lethargy. Her partner reports that she has become increasingly confused over the past 2 days, and aggressive towards him. She also mentioned experiencing strange smells and tastes.

Earlier in the day, he noticed that she became less responsive with jerking movements affecting her left arm and hand, which then spread to affect her left leg. The episode lasted about 5 min, after which she gradually became more rousable.

On examination, the patient is disorientated in place and time with an abbreviated mental state examination score of 6 out of 10. There are no focal neurological signs.

A Cerebrospinal fluid examination

The clinical scenario is suggestive of encephalitis such as that caused by herpes simplex virus infection. Herpes simplex encephalitis (HSE) may be associated with a prodrome of malaise, fever, headache and nausea, followed by acute or subacute onset of an encephalopathy with symptoms including lethargy, confusion and delirium. Headaches, seizures and other focal deficits also may occur. Meningeal signs may be present. Laboratory investigations may show evidence of infection or may be normal. Lumbar puncture should always be performed in suspected HSE, but only after a space-occupying lesion has been excluded by imaging. The normal CT scan here has excluded a mass, but is insensitive to the changes seen in HSE. CSF findings include mildly elevated protein, normal glucose and a moderate leucocytosis (mostly lymphocytes). Red blood cells may be seen. Fluid should be sent for HSV-1 and HSV-2 polymerase chain

HSV-1 and HSV-2 polymerase chain reaction (PCR) to detect HSV DNA. PCR is highly specific, but very early in the disease course false-negative results can occur.

C	Electroencephalography

Electroencephalography is quite sensitive and shows abnormalities in four-fifths of biopsy-proven cases of HSE. However, the changes seen are non-specific and will not confirm the cause of encephalitis in this case.

B	Computed tomography venography

The history here strongly suggests viral encephalitis.

D	Magnetic resonance imaging brain

The priority here is to confirm the cause of the encephalitic illness. CSF examination is the most effective way

B	Computed tomography venography

The history here strongly suggests viral encephalitis.

D	Magnetic resonance imaging brain

The priority here is to confirm the cause of the encephalitic illness. CSF examination is the most effective way of achieving that. MRI brain scanning will likely reveal high signal change in the temporal and medial frontal lobe of the brain.

E	Cortical brain biopsy

Cortical brain biopsy is only rarely required for confirmation of diagnosis.

71060

Rate this question:

Next Question

A 48-year-old accountant presents to the Outpatient Clinic with weakness of the left lower extremity that has been gradually developing over the past 4 months.

On further questioning, he also describes occasional brief and unprovoked episodes of rhythmic jerking along the length of the left limb and less marked weakness affecting the right leg. He also reports headache, which is worst in the morning.

Neurological examination reveals weakness of both lower limbs that is more pronounced on the left side, and bilateral extensor (up-going) plantar responses. Sensory examination reveals mild reduction of vibration sense of the left leg, but is otherwise normal.

Which one of the following investigations is most appropriate to complete first?

A	Visual evoked potentials (VEPs)

more pronounced on the left side, and bilateral extensor (up-going) plantar responses. Sensory examination reveals mild reduction of vibration sense of the left leg, but is otherwise normal.

Which one of the following investigations is most appropriate to complete first?

A	Visual evoked potentials (VEPs)
B	Magnetic resonance imaging (MRI) of the thoracic and lumbar spine
C	MRI of the head
D	Computed tomography (CT) of the dorsal and lumbar spine
E	Electroencephalography (EEG)

C MRI of the head

The patient's bilateral lower limb weakness could be due to eithera spinal cord lesion in the dorsal (thoracic) region or a midline/para-sagittal brain lesion. The presence of headache, sensory symptoms on the same side as the weaker limb and the patient's account of partial seizure activity in the same area all point to the brain as the location of the lesion. A para-sagittal meningioma will often manifest in this manner. For this reason, an MRI of the head is the most appropriate first investigation in this case.

B Magnetic resonance imaging (MRI) of the thoracic and lumbar spine

The pattern of symptoms and signs in this case is more suggestive of a brain lesion. However, given that there is bilateral leg weakness and up-going plantar responses, which can be present in spinal lesions. MRI imaging

present in spinal lesions, MRI imaging of the spine would certainly be a consideration after brain imaging and especially if the MRI brain did not show an abnormality.

A	Visual evoked potentials (VEPs)

This is an investigation used to test for evidence of demyelination of the optic nerve in patients with suspected multiple sclerosis. It is not usually the first test to be completed and would usually be done after MRI imaging of the brain and spine had been completed.

D	Computed tomography (CT) of the dorsal and lumbar spine

The pattern of symptoms and signs in this case is more suggestive of a brain lesion. If imaging of the spine was required, MRI would be the more useful modality in this case and so would be preferable to CT

A 24-year-old injecting drug user is admitted with a 2-day history of blurred vision, dysphagia, slurred speech and generalised weakness.

On examination, he has multiple skin lesions and an infected wound on his left thigh. He has ophthalmoplegia with restricted gaze in all directions of movement, bilateral facial nerve weakness and dysphonia. Limb examination reveals global flaccid weakness, worse proximally. Reflexes are diminished. The general medical examination is notable only for shallow breaths.

Spirometry results:

FVC	50% of predicted
FEV_1	50% of predicted
FEV_1/FVC	0.84
TLCO	Low
KCO	High

CSF results:

CSF results:

Glucose	3.5 mmol/l (serum 6.0)
Protein	0.45 g/l (normal 0.3-0.5)
WCC	1 cell/mm^3 (normal < 5)
RCC	None seen
Gram stain	Negative
Culture and PCR	Awaited

What is the most likely causative agent?

A	*Clostridium botulinum*
B	Polio virus
C	*Campylobacter jejuni*

Protein	0.5)
WCC	1 cell/mm^3 (normal < 5)
RCC	None seen
Gram stain	Negative
Culture and PCR	Awaited

What is the most likely causative agent?

A *Clostridium botulinum*

B Polio virus

C *Campylobacter jejuni*

D *Clostridium tetani*

E *Staphylococcus aureus*

A *Clostridium botulinum*

Botulism is an acute, descending, symmetrical, paralytic illness with reduced tone and reflexes. It is caused by an exotoxin released by *Cl. botulinum.* Most cases are food-borne (they may have abdominal pain), but there have been a number of reports of botulism in injecting drug users, usually associated with 'skin-popping', where drugs are injected directly into the subcutaneous tissues. It characteristically affects the cranial and autonomic nerves.

Diagnosis is clinical, but the organism can be cultured from wounds. The spirometry in this patient indicates a restrictive defect due to respiratory muscle weakness. CSF analysis is usually within normal limits as the site of toxin activity is at the neuromuscular junction.

Specific therapy includes botulism antitoxin and antibiotics (benzylpenicillin or metronidazole) in addition to wound debridement, but prolonged cardio-respiratory

supportive therapy in an intensive-care setting is often necessary.

B	Polio virus

Acute poliomyelitis is a flu-like illness with myalgia and sore throat, which progresses over a few days to cause an asymmetric, flaccid paralysis in the limbs with areflexia, but can also affect the bulbar and respiratory muscles. Spread by the faeco-oral route, it usually affects children. We are not told that the patient is from an endemic area, outside of which polio is virtually non-existent.
It causes a pleocytosis in the CSF, which is absent in this patient. Therefore, the demographic of the patient and the CSF results are not consistent with polio infection.

C	*Campylobacter jejuni*

This option alludes to a post-infectious acute inflammatory demyelinating polyradiculoneuropathy (AIDP) or

not neurological symptoms. The patient does not have a history of diarrhoea. AIDP progresses over weeks, rather than days, and it does not usually affect the cranial nerves, or cause ophthalmoplegia (unless it is the Miller-Fisher variant, which produces a triad of areflexia, ataxia and ophthalmoplegia). CSF analysis would usually show increased protein levels in AIDP.

D	*Clostridium tetani*

C. tetani causes tetanus, usually after the spores infect the host through a wound. Importantly, as the name suggests, it causes tetany (increased muscle tone) rather than flaccid weakness, leading to painful muscle spasms and respiratory arrest. The tetanus toxin disinhibits lower motor neurons causing increased tone.

The incubation period usually a week to 10 days, longer than this patient's history. The patient has an acute flaccid paralysis which does not fit with the presentation of tetanus

A 48-year-old librarian complains of clumsiness of her right hand with deterioration in handwriting. Her symptoms have been present for the last 3 months and she thinks they began after an influenza-like illness. More recently, she also has a sensation of the 'world spinning around her'.

Cranial nerve examination demonstrated reduced hearing on the right, diminished sensation on the right side of the face and an absent corneal reflex.

On examination of the limbs, there is impairment of finger–nose coordination in the right upper limb with impaired rapid alternating movement of the right hand. Blood pressure is 141/82 mmHg, with pulse 70 bpm and regular.

Which one of the following investigations is of most diagnostic interest?

A	Influenza serology

reflex.

On examination of the limbs, there is impairment of finger–nose coordination in the right upper limb with impaired rapid alternating movement of the right hand. Blood pressure is 141/82 mmHg, with pulse 70 bpm and regular.

Which one of the following investigations is of most diagnostic interest?

A	Influenza serology
B	Pure tone audiometry
C	Magnetic resonance imaging of the brain
D	CSF examination for oligoclonal bands
E	Paraneoplastic antibodies

A 48-year-old librarian complains of clumsiness of her right hand with deterioration in handwriting. Her symptoms have been present for the last 3 months and she thinks they began after an influenza-like illness. More recently, she also has a sensation of the 'world spinning around her'.

Cranial nerve examination demonstrated reduced hearing on the right, diminished sensation on the right side of the face and an absent corneal reflex.

On examination of the limbs, there is impairment of finger–nose coordination in the right upper limb with impaired rapid alternating movement of the right hand. Blood pressure is 141/82 mmHg, with pulse 70 bpm and regular.

Which one of the following investigations is of most diagnostic interest?

C Magnetic resonance imaging of the brain

The presentation suggests the possibility of a mass lesion in the cerebellopontine angle, including a vestibular schwannoma, cerebellopontine angle glioma or cerebellopontine angle meningioma. Imaging with MRI is the investigation of choice. Together with cerebellar signs, deficits in cranial nerves V, VII and VIII may be seen.

D CSF examination for oligoclonal bands

This test may be used for the assessment of neuro-inflammatory disorders (including MS), but MRI would be performed first.

A Influenza serology

The patient's attribution of her symptoms to a viral illness is likely to be recall bias – it is common for people

A	Influenza serology

The patient's attribution of her symptoms to a viral illness is likely to be recall bias – it is common for people to draw causal relationships where none exist. Whether the patient has had flu or not is irrelevant to the current presentation.

B	Pure tone audiometry

This test may confirm the presence of sensorineural hearing loss, but would not aid in the identification of the cause.

E	Paraneoplastic antibodies

Paraneoplastic cerebellar degeneration can come on subacutely and one would expect to see symmetrical signs rather than the very focal abnormalities seen here.

32730

Rate this question:

A 27-year-old woman is referred to a neurologist. She complains of several years' history of feeling tired in the mornings. Her new partner who accompanied her says that he has been awoken on multiple occasions during the night. He describes her sitting up abruptly, vocalising incomprehensibly, lifting her arms in the air and promptly returning to sleep within 1 minute. He ascribes these events to dreaming but has noticed an increase in their frequency and is genuinely concerned. The patient cannot recollect any of these events; however, they appear to be stereotyped, associated with vocalisation but with no apparent post-event confusion.

Other than having a past history of appendectomy and irritable bowel disease, she is well in herself. She has, however, lost her job and been under significant amounts of emotional stress recently.

Neurological examination is grossly normal; an electrocardiogram shows heart rate 71/min and in sinus rhythm

however, lost her job and been under significant amounts of emotional stress recently.

Neurological examination is grossly normal; an electrocardiogram shows heart rate 71/min and in sinus rhythm, with blood pressure is 122/71 mmHg; full blood count and biochemistry are normal. EEG shows sharp wave activity in bifrontal regions.

What is the likely diagnosis in this patient?

A	Non-epileptic attack disorder
B	Frontal lobe seizures
C	Temporal lobe seizures
D	Rapid eye movement (REM) sleep disorder
E	Paroxysmal kinesogenic choreoathetosis

been awoken on multiple occasions during the night. He describes her sitting up abruptly, vocalising incomprehensibly, lifting her arms in the air and promptly returning to sleep within 1 minute. He ascribes these events to dreaming but has noticed an increase in their frequency and is genuinely concerned. The patient cannot recollect any of these events; however, they appear to be stereotyped, associated with vocalisation but with no apparent post-event confusion.

Other than having a past history of appendectomy and irritable bowel disease, she is well in herself. She has, however, lost her job and been under significant amounts of emotional stress recently.

Neurological examination is grossly normal; an electrocardiogram shows heart rate 71/min and in sinus rhythm, with blood pressure is 122/71 mmHg; full blood count and biochemistry are normal. EEG shows sharp wave activity in bifrontal regions.

B Frontal lobe seizures

This patient appears to be presenting with a history compatible with nocturnal frontal lobe epilepsy. The clues here include short stereotyped events, abrupt onset and termination of motor symptoms associated with bizarre vocalisation, nocturnal nature of the events and relatively little post-ictal confusion. Videosomnography best differentiates frontal lobe seizures from other conditions, showing epileptiform activity in frontal lobe epilepsy.

E Paroxysmal kinesogenic choreoathetosis

PKC is a hyperkinetic movement disorder characterised by a range of abnormal movements including ballism, chorea and dystonia.

A Non-epileptic attack disorder

These episodes are less stereotyped, and are much more likely to be seen

ballism, chorea and dystonia.

A	Non-epileptic attack disorder

These episodes are less stereotyped, and are much more likely to be seen during the day rather than at night.

C	Temporal lobe seizures

Temporal lobe seizures usually last for a few minutes and are associated with automatisms, and are followed by a period of post-ictal confusion.

D	Rapid eye movement (REM) sleep disorder

This is an important differential, which can range from semi-purposeful automatisms to full enactment of dreams often with violent activity and with detailed recall of a nightmare the next day.

32748

Rate this question:

A 40-year-old HIV-positive man is referred to a neurologist with progressive speech problems and altered personality. His partner, who has accompanied him, describes a marked change in mood and aggressive behaviour within the last few weeks. The patient also describes recent dragging of his right leg and increasing stiffness and unsteadiness.

The patient has had HIV for 8 years and has not been on previous antiretroviral therapy.

On examination, he is noted to be thin, apyrexial, and has several cold sores around his mouth. He is alert and there is no clouding of consciousness. He scores 28/30 on mini-mental state examination and has an expressive dysphasia with problems naming objects. Cranial nerve examination appears normal.

On examination of the peripheral nervous system, there is increased tone, pyramidal weakness and pathologically brisk reflexes in the right upper and lower limb and the

right upper and lower limb and the right plantar reflex is extensor. He exhibits an ataxic gait and appears to be leaning to the right.

A magnetic resonance imaging scan shows multiple, non-enhancing white-matter lesions within the frontal and temporal lobes. There is no oedema or mass-effect.

Lumbar puncture reveals:

Opening pressure	13 cm H_2O (5–18)
Protein	0.4 5g/l (0.15–0.45)
WCC	2 cells/ml (≤ 5)
RCC	1 cell/ml (≤ 5)
Oligoclonal bands	+

Oligoclonal bands Present.

Blood tests:

Serum oligoclonal bands	Positive

Blood tests:

Serum oligoclonal bands	Positive
CD4 count	98
Viral load	50 000 copies/ml

What is the most likely diagnosis in this patient?

A	Primary progressive multiple sclerosis
B	HIV encephalopathy
C	Progressive multifocal leucoencephalopathy
D	Central nervous system (CNS) lymphoma
E	Toxoplasma abscesses

around his mouth. He is alert and there is no clouding of consciousness. He scores 28/30 on mini-mental state examination and has an expressive dysphasia with problems naming objects. Cranial nerve examination appears normal.

On examination of the peripheral nervous system, there is increased tone, pyramidal weakness and pathologically brisk reflexes in the right upper and lower limb and the right plantar reflex is extensor. He exhibits an ataxic gait and appears to be leaning to the right.

A magnetic resonance imaging scan shows multiple, non-enhancing white-matter lesions within the frontal and temporal lobes. There is no oedema or mass-effect.

Lumbar puncture reveals:

Opening pressure	13 cm H_2O (5–18)

C Progressive multifocal leucoencephalopathy

This patient presents with a history of right hemiparesis, expressive dysphasia and behavioural changes in clear consciousness.

Progressive multifocal leukoencephalopathy is the result of infection of oligodendrocytes with JC virus, which is a polyomavirus found latent in most healthy adults. With CD4 counts of <100 this virus becomes active, leading to progressive neurological deterioration. Hemiparesis, visual field defects, ataxia and mental change are characteristic.

Whilst a brain biopsy would be the definitive diagnostic test showing asymmetric foci of demyelination and intranuclear inclusions containing the JC virus, viral PCR would be performed as the practical option in most clinical situations.

There is no effective treatment, but progression can be slowed by initiation of HAART (highly active antiretroviral therapy).

A	Primary progressive multiple sclerosis

In primary progressive multiple sclerosis there is oligoclonal band synthesis in the cerebrospinal fluid only, and the white matter lesions have a tendency to be periventricular in location.

B	HIV encephalopathy

HIV encephalopathy usually presents with clouding of consciousness including symptoms of depression, apathy and confusion, rather than the relatively preserved mini-mental state examination seen here.

D	Central nervous system (CNS) lymphoma

Symptoms of CNS lymphoma include fevers and a progressive deterioration in conscious level, neither of which are seen here, and an elevated CNS lymphocyte count would also be

HIV encephalopathy usually presents with clouding of consciousness including symptoms of depression, apathy and confusion, rather than the relatively preserved mini-mental state examination seen here.

D	Central nervous system (CNS) lymphoma

Symptoms of CNS lymphoma include fevers and a progressive deterioration in conscious level, neither of which are seen here, and an elevated CNS lymphocyte count would also be expected.

E	Toxoplasma abscesses

The CSF protein is only just at the upper end of the normal range, and sparse white cells are seen in the sample, so this is unlikely to fit with a diagnosis of toxoplasma.

32747

A 61-year-old woman presented with difficulty in lifting her right arm in the air. Her problems had started shortly after being discharged from hospital 3 weeks previously following an uncomplicated laparoscopic cholecystectomy. She had suddenly developed severe pain in her right shoulder that was excruciating and continuous, despite taking regular paracetamol and codeine phosphate. The pain had slowly improved over the next few weeks, but when it had settled she realised that she could not lift her right arm up.

On examination, there was wasting around the shoulder girdle and weakness of shoulder abduction on the right. There was also winging of the scapula on the same side, but power in other muscle groups was normal. There was a patch of sensory loss over the outer aspect of the upper arm on the right.

What is the most likely diagnosis?

A Axillary nerve palsy

settled she realised that she could not lift her right arm up.

On examination, there was wasting around the shoulder girdle and weakness of shoulder abduction on the right. There was also winging of the scapula on the same side, but power in other muscle groups was normal. There was a patch of sensory loss over the outer aspect of the upper arm on the right.

What is the most likely diagnosis?

A	Axillary nerve palsy
B	C5 root compression
C	Cervical myelopathy
D	Brachial neuritis
E	Syringomyelia

A 61-year-old woman presented with difficulty in lifting her right arm in the air. Her problems had started shortly after being discharged from hospital 3 weeks previously following an uncomplicated laparoscopic cholecystectomy. She had suddenly developed severe pain in her right shoulder that was excruciating and continuous, despite taking regular paracetamol and codeine phosphate. The pain had slowly improved over the next few weeks, but when it had settled she realised that she could not lift her right arm up.

On examination, there was wasting around the shoulder girdle and weakness of shoulder abduction on the right. There was also winging of the scapula on the same side, but power in other muscle groups was normal. There was a patch of sensory loss over the outer aspect of the upper arm on the right.

What is the most likely diagnosis?

Your answer was incorrect

D Brachial neuritis

Brachial neuritis (also called neuralgic amyotrophy) has an uncertain aetiology but sometimes follows an infection, vaccination, surgery or trauma. It classically starts with severe, continuous pain in the upper arm or neck that may radiate down the arm. After a 2–3-week period the pain subsides, and weakness (and sometimes wasting) of muscles around the upper arm/shoulder girdle becomes apparent (most commonly the deltoid, serratus anterior, infraspinatus and supraspinatus). There can be sensory loss, most frequently over the area supplied by the axillary nerve. Most patients will functionally recover, although time to improvement varies between a few months and 12 years. Treatment is symptomatic.

A Axillary nerve palsy

Axillary nerve palsy most commonly leads to weakness of the deltoid and

leads to weakness of the deltoid and sensory loss below the shoulder.

B	C5 root compression

C5 nerve root compression is associated with neck pain and is also associated with weakness of arm flexion, and loss of sensation over the outer portion of the upper arm.

C	Cervical myelopathy

Cervical myelopathy occurs as a result of long-standing osteoarthritis of the neck, leading to narrowing, subsequent neck pain and symptoms of cervical cord compression.

E	Syringomyelia

Syringomyelia classically causes sensory loss in a shawl-like distribution over the upper body, muscle wasting and weakness begins in the hands, later affecting the forearms and shoulders.

12:28
https://mypastest.paste

You are asked to review a 72-year-old man in the Neurology Clinic. He has a past medical history of hypertension for which he takes lisinopril and amlodipine. There is a convergent squint and a left-sided facial weakness.

Where is the most likely site of his lesion?

A	Pons
B	Medulla
C	Parietal lobe
D	Cerebellum
E	Upper spinal cord

Audio Video Stop Share Participants More

12:29
https://mypastest.paste

You are asked to review a 72-year-old man in the Neurology Clinic. He has a past medical history of hypertension for which he takes lisinopril and amlodipine. There is a convergent squint and a left-sided facial weakness.

Where is the most likely site of his lesion?

Your answer was correct

A	Pons
B	Medulla
C	Parietal lobe
D	Cerebellum
E	Upper spinal cord

Audio Video Stop Share Participants More

12:29
https://mypastest.paste

A Pons

The 6th-nerve nucleus is encircled by seventh-nerve fibres in the pons, so pontine lesions of the seventh cranial nerve are often associated with a convergent squint (due to lateral rectus palsy). Causes include pontine tumours (such as a glioma), demyelination due to multiple sclerosis and vascular lesions.

B Medulla

Medial medullary lesions lead to hypoglossal nerve injury, corticospinal tract dysfunction and damage to the medial lemniscus. Lateral medullary syndrome is well described.

C Parietal lobe

Parietal lobe lesions do not result in

Audio Video Stop Share Participants More

12:31
https://mypastest.paste

C Parietal lobe

Parietal lobe lesions do not result in 6th and 7th cranial nerve lesions, although they may result in inferior homonymous quadrantanopia.

D Cerebellum

Cerebellar dysfunction would result in ataxia rather than the 6th and 7th cranial nerve lesions seen here.

E Upper spinal cord

Upper spinal cord lesions can affect cranial nerve XI, which supplies the sternocleidomastoid and trapezius muscles.

6613

Rate this question:

Audio Video Stop Share Participants More

12:31
https://mypastest.paste

A 42-year-old male dancer comes to the Emergency Department complaining of headache and neck stiffness. For the past few months he has felt increasingly tired and has had some difficulty with missed work and sick days. He attends with his male partner, who tells you that the patient has begun forgetting things over the past few weeks and over the past few days has become confused.

On examination, he is pyrexial (38.1 °C), is drowsy and finds it difficult to understand questioning. He has evidence of neck stiffness and photophobia.

Investigations:

Hb	11.0 g/dl
WCC	9.2×10^9/l
PLT	132×10^9/l
Na^+	137 mmol/l

Audio Video Stop Share Participants More

12:31
https://mypastest.paste:

K^+	4.5 mmol/l
Creatinine	124 µmol/l
MRI head	Some ventricular enlargement with ependymal enhancement

Lumbar puncture CSF investigations:

Opening pressure	19
Appearance	Clear
Protein	Slightly raised
Glucose	Decreased
Cells	Lymphocytic pleocytosis

Which of the following is the most likely diagnosis?

Audio Video Stop Share Participants More

12:31
https://mypastest.paste

Glucose	Decreased
Cells	Lymphocytic pleocytosis

Which of the following is the most likely diagnosis?

A	Herpes simplex encephalitis
B	Cytomegalovirus (CMV) meningoencephalitis
C	Meningococcal meningitis
D	Tuberculous (TB) meningitis
E	Cryptococcal meningitis

Audio Video Stop Share Participants More

12:35
https://mypastest.paste

Na^+	137 mmol/l
K^+	4.5 mmol/l
Creatinine	124 μmol/l
MRI head	Some ventricular enlargement with ependymal enhancement

Lumbar puncture CSF investigations:

Opening pressure	19
Appearance	Clear
Protein	Slightly raised
Glucose	Decreased
Cells	Lymphocytic pleocytosis

Which of the following is the most likely diagnosis?

Audio Video Stop Share Participants More

12:35
https://mypastest.paste

B Cytomegalovirus (CMV) meningoencephalitis

The findings seen here, with only a mildly elevated cerebrospinal fluid (CSF) opening pressure, clear-looking CSF with raised protein, decreased glucose and lymphocytic pleocytosis, coupled with ependymal enhancement on magnetic resonance imaging (MRI), are relatively typical of CMV infection against a background of human immunodeficiency virus (HIV). Unfortunately, the appearance of gradual memory loss coupled with confusion is usually associated with rapid progression. IV ganciclovir is the therapy of choice, given as an induction course, followed by maintenance therapy for life.

A Herpes simplex encephalitis

Audio Video Stop Share Participants More

12:35
https://mypastest.paste

Herpes simplex changes are usually confined to the temporal lobe, and memory loss, mood changes and drowsiness may be seen.

C	Meningococcal meningitis

Meningococcal meningitis is associated with a more rapid progression, other signs of systemic sepsis such as a purpuric rash and raised white count. Neutrophilia is usually seen on CSF examination.

D	Tuberculous (TB) meningitis

There are no chest signs or symptoms to indicate TB infection, and diffuse basal enhancement is seen on gadolinium-enhanced scanning of patients with TB meningitis.

Audio Video Stop Share Participants More

12:35
https://mypastest.paste

purpuric rash and raised white count. Neutrophilia is usually seen on CSF examination.

D	Tuberculous (TB) meningitis

There are no chest signs or symptoms to indicate TB infection, and diffuse basal enhancement is seen on gadolinium-enhanced scanning of patients with TB meningitis.

E	Cryptococcal meningitis

Cryptococcal meningitis displays leptomeningeal enhancement on MRI, and is commonly associated with hydrocephalus. A higher opening pressure would therefore be expected.

20972

Rate this question:

Audio Video Stop Share Participants More

12:37
https://mypastest.paste

You are called to see a 35-year-old injection drug user who in the last few days has developed progressive flaccid weakness of his arms and legs. On questioning, the patient reports that he had a wound abscess drained a few days previously and had a stomach bug 2 weeks earlier. Absent bilateral lower limb reflexes are noted on examination. The cranial nerves are normal.

Which of the following diagnoses fit best with this clinical picture?

A	Guillain–Barré syndrome (GBS)
B	Botulism
C	Tetanus
D	Septicaemia

Audio Video Stop Share Participants More

12:37
https://mypastest.paste

questioning, the patient reports that he had a wound abscess drained a few days previously and had a stomach bug 2 weeks earlier. Absent bilateral lower limb reflexes are noted on examination. The cranial nerves are normal.

Which of the following diagnoses fit best with this clinical picture?

A	Guillain–Barré syndrome (GBS)
B	Botulism
C	Tetanus
D	Septicaemia
E	Spinal abscess

Audio Video Stop Share Participants More

12:39
https://mypastest.paste

A Guillain-Barré syndrome (GBS)

GBS is an acute, ascending and progressive neuropathy characterised by flaccid limb weakness, paraesthesia and hyporeflexia. Gastrointestinal infections are common in the preceding four weeks. GBS occurs due to a process of acute demyelination of nerve roots and peripheral nerves. In some cases, it is found to be associated with *Campylobacter* infection. There may be associated sensory symptoms and associated mild glove-and-stocking sensory neuropathy.

B Botulism

Botulism presents with diplopia and blurred vision due to ophthalmoplegia. There is classically a descending

Audio Video Stop Share Participants More

12:39
https://mypastest.paste

paralysis (i.e. cranial nerves, then arms, then legs). In severe cases, respiratory failure can occur. Wound botulism should certainly be considered in this case, but is less likely due to the lack of cranial nerve involvement.

C	Tetanus

Tetanus presents with a prodrome of fever, malaise and headache before the onset of the classical features of trismus, risus sardonicus, opisthotonus and spasms. The flaccid weakness described in this case is not a feature.

D	Septicaemia

Patients with sepsis and/or multi-organ failure can certainly become weak due to development of critical illness myoneuropathy. However, this develops slowly. In this case, the post

Audio Video Stop Share Participants More

12:42
https://mypastest.paste

trismus, risus sardonicus, opisthotonus and spasms. The flaccid weakness described in this case is not a feature.

D	Septicaemia

Patients with sepsis and/or multi-organ failure can certainly become weak due to development of critical illness myoneuropathy. However, this develops slowly. In this case, the post infectious rather rapidly progressive flaccid paralysis is more likely to be due to Guillain–Barré syndrome.

E	Spinal abscess

A spinal abscess compressing the cervical cord might cause progressive arm and leg weakness. However, this is unlikely to be the explanation in this case given the lack of upper motor neurone signs.

Audio Video Stop Share Participants More

12:42
https://mypastest.paste

A 45-year-old secretary presents to the Outpatient Clinic complaining of sharp, burning sensations over the right side of his face. Episodes last from a few seconds to approximately 2 min and occur up to 50 times a day with no symptoms in between.

On further questioning, he reports that the pain is exacerbated by eating, speaking and washing his face. A thorough neurological examination reveals an intact corneal reflex on both sides, intact sensation on both sides of the face and no cranial nerve or limb signs.

Investigations:

Hb	11.5 g/dl
WCC	5.4×10^9/l
PLT	287×10^9/l
Na^+	137 mmol/l

Audio Video Stop Share Participants More

12:42
https://mypastest.paste

K^+	4.4 mmol/l
Creatinine	71 µmol/l
MCV	94.6 fl
Urea	4.1 mmol/l
Ca^{++}	2.15 mmol/l
TSH	2.25 mU/l
T4	14.5 nmol/l
B_{12}	255 ng/l
Folate	10.9 µg/l
Glucose	5.2 mmol/l

Which of the following treatments is likely to be of most benefit?

A Oral sumatriptan 50 mg after onset of attacks

Audio Video Stop Share Participants More

12:42
https://mypastest.paste

Glucose	5.2 mmol/l

Which of the following treatments is likely to be of most benefit?

A	Oral sumatriptan 50 mg after onset of attacks
B	Advice on relaxation and biofeedback therapies
C	A trial of high-dose oral prednisolone (60 mg once daily)
D	Oral propranolol 10 mg 1–3 times daily
E	Oral carbamazepine 100mg 1–2 times daily

Audio Video Stop Share Participants More

12:44
https://mypastest.paste:

E Oral carbamazepine 100mg 1-2 times daily

The history is suggestive of trigeminal neuralgia. This characteristically presents with paroxysmal pain in the distribution of one or more branches of the trigeminal nerve. Sensations may be described as sharp, burning, superficial or electric shock-like, with episodes lasting from seconds to several minutes. Episodes may be triggered by touching a specific area of the face, chewing, talking, washing the face or cleaning the teeth. Examination of trigeminal function can be normal.

Carbamazepine has been shown in several randomized placebo-controlled trials to relieve pain in patients with trigeminal neuralgia. The dose can then be increased to achieve pain relief. For medically refractory patients,

Audio Video Stop Share Participants More

12:44
https://mypastest.paste

then be increased to achieve pain relief. For medically refractory patients, surgical options such as microvascular decompression and ablation of the aberrant vasculature may be explored.

A	Oral sumatriptan 50 mg after onset of attacks

Sumatriptan is used to abort an oncoming migraine attack. This man's short-lasting hemi-facial pain is very uncharacteristic of migraine, and therefore sumatriptan is unlikely to help here.

B	Advice on relaxation and biofeedback therapies

These therapies help modify behaviour in response to a particular stimulus. They are occasionally used as adjunct treatments for a number of disorders

Audio Video Stop Share Participants More

12:44
https://mypastest.paste

treatments for a number of disorders that involve pain or psychological distress. They are not first-line therapy, and there is not a great deal of evidence for their use; therefore, this option is incorrect.

C	A trial of high-dose oral prednisolone (60 mg once daily)

Steroids are useful for inflammatory nervous system conditions resulting in neuralgic pain. However, most (up to 90%) of cases of trigeminal neuralgia, which is what this patient has, are due to compression of the nerve by an aberrant vascular malformation. Steroids will not help here because there is little inflammation to treat, and the high-dose steroids will inevitably lead to side effects such as hyperglycaemia.

Audio Video Stop Share Participants More

12:44
https://mypastest.paste

A 28-year-old asylum seeker from Africa is referred following health screening by her new general practitioner. The referral letter comments on 'abnormal neurology ? cause'. Past medical history is unremarkable, although she does admit to a period as a sex worker.

On examination, you notice that her left pupil is dilated and slowly reactive to light – direct and consensual. Ankle reflexes are absent, even with reinforcement. Plantars are flexor.

What is the most likely underlying diagnosis?

A	HIV neuropathy
B	Tertiary syphilis
C	B_{12} deficiency

Audio Video Stop Share Participants More

12:45
https://mypastest.paste

unremarkable, although she does admit to a period as a sex worker.

On examination, you notice that her left pupil is dilated and slowly reactive to light – direct and consensual. Ankle reflexes are absent, even with reinforcement. Plantars are flexor.

What is the most likely underlying diagnosis?

A	HIV neuropathy
B	Tertiary syphilis
C	B_{12} deficiency
D	Multiple sclerosis
E	Holmes-Adie syndrome

Audio Video Stop Share Participants More

12:46
https://mypastest.paste

unremarkable, although she does admit to a period as a sex worker.

On examination, you notice that her left pupil is dilated and slowly reactive to light – direct and consensual. Ankle reflexes are absent, even with reinforcement. Plantars are flexor.

What is the most likely underlying diagnosis?

Your answer was correct

A	HIV neuropathy
B	Tertiary syphilis
C	B_{12} deficiency
D	Multiple sclerosis
E	Holmes-Adie syndrome

Audio Video Stop Share Participants More

12:47
https://mypastest.paste

E Holmes-Adie syndrome

The patient is asymptomatic and neurological examination reveals the Holmes–Adie syndrome, a variant of normal. Therefore, with normal history and examination, no action need be taken. Holmes–Adie syndrome is the association of a large, irregular and sluggishly reactive pupil with absent deep tendon reflexes. Visual acuity and reaction to accommodation are usually normal. It is most commonly seen in young women. Rarely, similar eye findings result from interruption of the efferent parasympathetic pathway.

A HIV neuropathy

Peripheral neuropathy is usually seen as a side effect of HIV medication, and CNS dysfunction related to HIV infection is linked to progressive dementia

Audio Video Stop Share Participants More

12:48
https://mypastest.paste

B Tertiary syphilis

Other features of tertiary syphilis, including memory impairment and gait ataxia, are absent here. Syphilis testing is, however, appropriate to rule out co-existent syphilis infection.

C B_{12} deficiency

Peripheral loss of vibratory sense and position are early indications of central nervous system (CNS) involvement in B_{12} deficiency, accompanied by loss of reflexes and mild-to-moderate weakness.

D Multiple sclerosis

Multiple sclerosis is associated with patchy CNS demyelination, rather than an isolated sluggishly reactive pupil seen here.

Audio Video Stop Share Participants More

12:49
https://mypastest.paste

You are called to the obstetrics ward to see a 26-year-old primigravid woman who is 12 weeks' pregnant. She had been admitted for treatment of severe morning sickness, and had been prescribed metoclopramide and intravenous fluids.

Over the past week, she had remained unwell and unable to eat any solids due to vomiting. A medical opinion was sought because of increasing drowsiness and irritability. Nursing staff also commented on a clumsy gait 'as if she was drunk'.

On examination, she was drowsy, with a Glasgow Coma Scale of 13/15 (E-3 V-4 M-6). Mucous membranes were dry, blood pressure was 98/50 mmHg and rectal temperature was 34.7 °C. She had coarse horizontal nystagmus on lateral gaze and vertical nystagmus on up-gaze. The remainder of her examination was unremarkable.

Audio Video Stop Share Participants More

12:49
https://mypastest.paste

4 M-6). Mucous membranes were dry, blood pressure was 98/50 mmHg and rectal temperature was 34.7 °C. She had coarse horizontal nystagmus on lateral gaze and vertical nystagmus on up-gaze. The remainder of her examination was unremarkable. Bedside blood glucose was 2.9 mmol/l.

Which of the following is the most likely diagnosis?

A	Wernicke's encephalopathy
B	Tardive dyskinesia
C	Acute dystonia
D	Sagittal sinus thrombosis
E	Subarachnoid haemorrhage

Audio Video Stop Share Participants More

12:51
https://mypastest.paste

You are called to the obstetrics ward to see a 26-year-old primigravid woman who is 12 weeks' pregnant. She had been admitted for treatment of severe morning sickness, and had been prescribed metoclopramide and intravenous fluids.

Over the past week, she had remained unwell and unable to eat any solids due to vomiting. A medical opinion was sought because of increasing drowsiness and irritability. Nursing staff also commented on a clumsy gait 'as if she was drunk'.

On examination, she was drowsy, with a Glasgow Coma Scale of 13/15 (E-3 V-4 M-6). Mucous membranes were dry, blood pressure was 98/50 mmHg and rectal temperature was 34.7 °C. She had coarse horizontal nystagmus on lateral gaze and vertical nystagmus on up-gaze. The remainder of her examination was unremarkable. Bedside blood glucose was 2.9 mmol/l.

Audio Video Stop Share Participants More

12:51
https://mypastest.paste

A Wernicke's encephalopathy

The triad of delirium, ocular signs and ataxia is classical of Wernicke's encephalopathy (WE), a neuropsychiatric syndrome induced by thiamine deficiency. Other common features of WE include hypotension and hypothermia. Most often seen in the context of the malnourished alcoholic, the syndrome can occur in any patient deprived of nutrients and cases of WE associated with hyperemesis gravidarum are well recognized. In a dehydrated, hypotensive, hypoglycaemic patient, fluid resuscitation and intravenous glucose are essential. This lady has already been admitted for IV fluids and this would require to be continued. She now also requires an infusion of 20% or 50% dextrose. However, in this case a carbohydrate load may worsen the encephalopathy and therefore

Audio Video Stop Share Participants More

12:51
https://mypastest.paste:

encephalopathy and therefore intravenous B-vitamin should be co-administered. This is because thiamine acts as a co-factor in a number of pathways associated with oxidative metabolism. As such, administration of large amounts of glucose without thiamine can actually precipitate a worsening of metabolic acidosis and symptoms of Wernicke's. The importance of prompt treatment is that WE is reversible in the early stages. Failure to adequately treat can cause chronic cognitive impairment (Korsakoff's psychosis). WE is underdiagnosed, partly since only 20% of patients exhibit all three of the classical features. Clinicians should therefore have a low threshold for commencing intravenous vitamins in patients with unexplained acute confusional states.

B Tardive dyskinesia

Audio Video Stop Share Participants More

12:52
https://mypastest.paste

A 44-year-old woman comes to the Neurology Clinic for review. She has suffered a third episode of relapse from her multiple sclerosis (MS) a few weeks earlier, from which she has now recovered.

During the previous year, she only suffered two relapses in total and has been treated with beta-interferon for the past 18 months. She can walk up to 150 m but requires a stick, and has trouble with urinary incontinence, but otherwise remains relatively well.

Which of the following is the optimal way to prevent further relapse?

A	Methylprednisolone
B	Fingolimod
C	Campath®

Audio Video Stop Share Participants 4 More

12:53
https://mypastest.paste

During the previous year, she only suffered two relapses in total and has been treated with beta-interferon for the past 18 months. She can walk up to 150 m but requires a stick, and has trouble with urinary incontinence, but otherwise remains relatively well.

Which of the following is the optimal way to prevent further relapse?

A	Methylprednisolone
B	Fingolimod
C	Campath®
D	Plasmapheresis
E	Continued beta interferon

Audio Video Stop Share Participants 4 More

12:55
https://mypastest.paste

B Fingolimod

The correct answer is Fingolimod (Option B).

Fingolimod reduces lymphocyte trafficking across the blood-brain barrier and induces transient lymphopenia. It is recognised to reduce relapses by 50% and is recommended by the National Institute for Health and Care Excellence (NICE).

E Continued beta interferon

Continued beta interferon (Option E) is incorrect.

Beta interferon is less effective than fingolimod. Clinical data reveal that it reduces relapses, on average, by 30-40%, although it is ineffective in some individuals.

Audio Video Stop Share Participants 4 More

12:56
https://mypastest.paste

A	Methylprednisolone

Methylprednisolone (Option A) is incorrect.

The use of intravenous (IV) methylprednisolone is controversial. It may hasten recovery from acute episodes of demyelination, although its impact on long-term disability is limited.

C	Campath®

Campath® (Option C) is incorrect.

Campath® (alemtuzumab) is a monoclonal antibody that binds to CD52. It is used in the treatment of chronic lymphocytic leukaemia (CLL), T-cell lymphoma and MS. Its use is generally reserved for patients who are unresponsive to other interventions.

Audio Video Stop Share Participants 4 More

12:57
https://mypastest.paste

A 26-year-old laboratory technician underwent vaccination for hepatitis B prior to a holiday in Thailand. Two weeks later, while in Bangkok, she developed severe pain over her left shoulder and this gradually subsided over the next week. However, on returning home she noticed increasing weakness of the left upper limb, for which she came to consult at the Neurology Clinic.

On examination, the left supra- and infraspinati, rhomboids, deltoid, biceps and supinator were all 3/5 in power. Small muscles of the hand were 5/5. The left supinator and biceps jerks were reduced. There was no other deficit.

Choose the most likely diagnosis

A	Brachial plexopathy due to haematoma

Audio Video Stop Share Participants 4 More

12:57
https://mypastest.paste

On examination, the left supra- and infraspinati, rhomboids, deltoid, biceps and supinator were all 3/5 in power. Small muscles of the hand were 5/5. The left supinator and biceps jerks were reduced. There was no other deficit.

Choose the most likely diagnosis

A	Brachial plexopathy due to haematoma
B	radiculopathy due to prolapsed disc
C	Brachial neuritis
D	Polio
E	Lyme disease

Audio Video Stop Share Participants 4 More

12:57
https://mypastest.paste

underwent vaccination for hepatitis B prior to a holiday in Thailand. Two weeks later, while in Bangkok, she developed severe pain over her left shoulder and this gradually subsided over the next week. However, on returning home she noticed increasing weakness of the left upper limb, for which she came to consult at the Neurology Clinic.

On examination, the left supra- and infraspinati, rhomboids, deltoid, biceps and supinator were all 3/5 in power. Small muscles of the hand were 5/5. The left supinator and biceps jerks were reduced. There was no other deficit.

Choose the most likely diagnosis

Your answer was correct

A Brachial plexopathy due to haematoma

Audio Video Stop Share Participants 4 More

12:57
https://mypastest.paste

C Brachial neuritis

The history is typical for brachial neuritis. This presumed immune mediated syndrome may occur after vaccination or illness or simply without apparent trigger. The patient typically gets a short spell of severe shoulder pain that resolves, but then progressive weakness and wasting follows. There is usually spontaneous recovery over the following months.

A Brachial plexopathy due to haematoma

Whilst the signs are in keeping with a brachial plexus lesion, the time course here is too prolonged for a compressive cause due to haematoma.

B radiculopathy due to prolapsed disc

Audio Video Stop Share Participants 4 More

12:58
https://mypastest.paste

prolapsed disc

This would usually cause neck pain radiating to the arm. In addition, the signs in this case involve C5- and C6-innervated muscles.

D	Polio

This is very rare, extremely uncommon in adults and has been eradicated in Europe (and Thailand).

E	Lyme disease

Lyme disease is caused by infection with *Borrelia* species and usually a tick bite is involved. Typically a rash is seen first (erythema chronicum migrans). Some patients may then develop a meningitic illness and some can get cranial neuropathy (usually VII), myelopathy or radiculopathy.

Audio Video Stop Share Participants 4 More

12:58
https://mypastest.paste

A 73-year-old man is admitted to the Emergency Department following a collapse.

His past medical history includes type 2 diabetes, treated with metformin and pioglitazone, hypertension treated with ramipril, and he also takes atorvastatin and aspirin. He does not drink any alcohol. His wife reports that he had been suffering from headaches, presyncope and nausea for the past few days.

On examination, his BP is 185/100 mmHg, with pulse 90 bpm. He is quadriplegic but appears conscious and has preserved blinking and upward gaze. He is unable to smile or frown.

Investigations:

Hb	13.1 g/dl
WCC	7.8×10^9/l

Audio Video Stop Share Participants 4 More

12:58
https://mypastest.paste

PLT	232×10^9/l
Na+	139 mmol/l
K+	4.8 mmol/l
Creatinine	130 μmol/l
CT head	No signs of haemorrhage

Which of the following is the most likely diagnosis?

A	Vegetative state
B	Coma
C	Locked-in syndrome
D	Central pontine myelolysis
E	Guillain–Barré syndrome

Audio Video Stop Share Participants 4 More

1:01
https://mypastest.paste

C Locked-in syndrome

The history of headaches, nausea and near blackouts that this patient experienced prior to presenting with collapse is suggestive of basilar artery territory TIAs. Locked-in syndrome is caused by infarction of the basis pontis due to occlusion of the proximal and middle portions of the basilar artery. Sparing of the tegmentum of the pons leads to preservation of consciousness, blinking and upward gaze. MRI scanning has a high level of sensitivity in confirming posterior ischaemia. Unfortunately prognosis is poor, with acute basilar artery occlusion carrying a mortality of over 80% in some case series.

A Vegetative state

Audio Video Stop Share Participants 4 More

1:02
https://mypastest.paste

In a vegetative state, patients are able to make facial expressions though not necessarily in response to a particular stimulus.

B	Coma

The question tells us that this man can open his eyes. In a coma he would be unable to do so. He would be in a state on unconsciousness and therefore unable to open his eyes, for example.

D	Central pontine myelolysis

This typically develops when a patient is being treated for hyponatraemia and the sodium in increased at a rapid rate, resulting in problems with the myelin sheath of neurones. There is no preceding history or other features to suggest recent rapid sodium shifts.

Audio Video Stop Share Participants 4 More

1:02
https://mypastest.paste

A 55-year-old man is admitted to the Emergency Department with a history of progressively increasing left facial pain of 2 months' duration. Two weeks ago, he noticed double vision when he woke up in the morning. He has no other significant history of note.

On examination, his blood pressure is normal at 135/70 mmHg, pulse is 75/min and regular. Heart sounds and auscultation of the chest are normal. There is no papilloedema. Corneal reflex is depressed, hypo-esthesia is detected in all three divisions of the left trigeminal nerve distribution and the left lateral rectus is paretic. Otherwise, the neurological examination is unremarkable.

What is the most likely anatomical localisation for the lesion causing his neurological signs?

A Left pons

Audio Video Stop Share Participants 4 More

1:02
https://mypastest.paste

There is no papilloedema. Corneal reflex is depressed, hypo-esthesia is detected in all three divisions of the left trigeminal nerve distribution and the left lateral rectus is paretic. Otherwise, the neurological examination is unremarkable.

What is the most likely anatomical localisation for the lesion causing his neurological signs?

A	Left pons
B	Left parasellar region
C	Left petrous temporal region
D	Left cerebellopontine angle
E	Left superior orbital fissure

Audio Video Stop Share Participants 4 More

1:04
https://mypastest.paste

Emergency Department with a history of progressively increasing left facial pain of 2 months' duration. Two weeks ago, he noticed double vision when he woke up in the morning. He has no other significant history of note.

On examination, his blood pressure is normal at 135/70 mmHg, pulse is 75/min and regular. Heart sounds and auscultation of the chest are normal. There is no papilloedema. Corneal reflex is depressed, hypo-esthesia is detected in all three divisions of the left trigeminal nerve distribution and the left lateral rectus is paretic. Otherwise, the neurological examination is unremarkable.

What is the most likely anatomical localisation for the lesion causing his neurological signs?

Your answer was incorrect

Audio
Video
Stop Share
Participants
4
More

1:04
https://mypastest.paste

C Left petrous temporal region

The involvement of all three divisions of the trigeminal nerve suggests that the lesion has involved either the Gasserian ganglion or its roots, and since the neighbouring 6th nerve is also affected, the latter localisation at the petrous temporal bone is more likely. Lesions such as meningiomas, schwannomas, metastasis, and nasopharyngeal carcinoma invading the base of the skull, granulomatous infections or carcinomatous meningitis would be likely causes. MRI of the head including the skull base is the investigation of choice. Treatment depends on the underlying diagnosis.

D Left cerebellopontine angle

Cerebellopontine angle tumours present with unilateral hearing loss, tinnitus or vertigo. Involvement of the

Audio Video Stop Share Participants 4 More

1:05
https://mypastest.paste

tinnitus or vertigo. Involvement of the trigeminal nerve from a cerebellopontine angle tumour results in loss of the ipsilateral corneal reflex.

A Left pons

Lateral pontine syndrome leads to ipsilateral loss of pain and temperature sensation from the face. Lesions affecting the vestibular and facial nerves are also seen, which appear absent here, given that hearing is normal, there is no dizziness, and no facial nerve weakness.

B Left parasellar region

Parasellar region tumours lead to visual field defects or, via compressive symptoms, to abnormal release of pituitary hormones.

Audio Video Stop Share Participants 4 More

1:06
https://mypastest.paste

A 26-year-old man who was beaten up a few days earlier presents to the Emergency Department feeling unwell. He says that he was punched and kicked in the head and noticed clear fluid leaking from his nose after event. Most recently, he has begun to suffer increasing drowsiness and fever.

On examination, he is pyrexial (38.5 °C) and drowsy, with signs of meningism. Following a computerised tomography (CT) scan, lumbar puncture is performed.

Investigations:

Hb	13.5 g/dl (135–180)
WCC	13.1×10^9/l (4–11)
PLT	200×10^9/l (150–400)
Na^+	139 mmol/l (136–145)
K^+	4.5 mmol/l (3.5–5.0)

Audio Video Stop Share Participants 4 More

1:06
https://mypastest.paste

Creatinine	120 µmol/l (80–130)
Glucose	5.9 mmol/l (3.9–5.5)

CSF investigations:

Protein	0.85g/dl (0.18–0.45)
Cell count	37/mm^3 (neutrophils) (< 3)
Glucose	3.0 mmol/l (2.5–3.5)

Which of the following is likely to be the most appropriate antibiotic choice?

A IV benzylpenicillin

B IV ciprofloxacin

C IV cefuroxime

Audio Video Stop Share Participants 4 More

1:06
https://mypastest.paste

Protein	0.85g/dl (0.18–0.45)
Cell count	37/mm^3 (neutrophils) (< 3)
Glucose	3.0 mmol/l (2.5–3.5)

Which of the following is likely to be the most appropriate antibiotic choice?

A IV benzylpenicillin

B IV ciprofloxacin

C IV cefuroxime

D IV linezolid

E Oral clarithromycin

Audio Video Stop Share Participants 4 More

1:09
https://mypastest.paste

a few days earlier presents to the Emergency Department feeling unwell. He says that he was punched and kicked in the head and noticed clear fluid leaking from his nose after event. Most recently, he has begun to suffer increasing drowsiness and fever.

On examination, he is pyrexial (38.5 °C) and drowsy, with signs of meningism. Following a computerised tomography (CT) scan, lumbar puncture is performed.

Investigations:

Hb	13.5 g/dl (135–180)
WCC	13.1 × 10^9/l (4–11)
PLT	200 × 10^9/l (150–400)
Na^+	139 mmol/l (136–145)
K^+	4.5 mmol/l (3.5–5.0)
Creatinine	120 µmol/l (80–130)

Audio Video Stop Share Participants 4 More

1:09
https://mypastest.paste

D IV linezolid

This patient had had a cerebrospinal fluid (CSF) leak, which is suggestive of a skull fracture. This could lead to entry of bacteria via the fracture. Gram-positive organisms such as *Staphylococcus aureus* or *S. epidermidis* would be the most important micro-organisms to consider. Of the antibiotic choices given, IV linezolid would be the most appropriate option. Vancomycin would be an alternative, although central nervous system (CNS) penetration is variable where there is meningitis.

C IV cefuroxime

Cefuroxime has no significant CNS penetration, meaning it is unsuitable for the treatment of meningitis.

Audio Video Stop Share Participants 4 More

1:10
https://mypastest.paste

A IV benzylpenicillin

Given that the infection is in the context of a skull fracture, staphylococcal infection is more likely, meaning linezolid is a better choice here.

B IV ciprofloxacin

To achieve adequate CNS penetration, ciprofloxacin must be used at high dose IV, and it is less useful versus linezolid for possible staphylococcal infection.

E Oral clarithromycin

Clarithromycin is a potential alternative for staphylococcal infection for patients who are allergic to other options.

Audio Video Stop Share Participants 4 More

1:10
https://mypastest.paste

A 43-year-old right-handed man presents to the Emergency Department with sudden onset of left-sided weakness. This weakness came on during a game of squash and he was unable to continue playing as a result. He also complains of pain in the back of his head and neck, which has been present since the weakness began. He works in a stressful job in the city and admits to occasional cocaine use, although he reports he has not taken any in the past week. He takes no other regular medication and has no significant medical history.

On examination, he has normal tone, and grade 4/5 weakness in a pyramidal distribution in the left arm and leg. Coordination on the left side is reduced when compared to the right. The reflexes are normal and the right plantar is down-going, the left being equivocal. There are no cranial nerve abnormalities. The pupillary responses

Audio Video Stop Share Participants 4 More

1:11
https://mypastest.paste

equivocal. There are no cranial nerve abnormalities. The pupillary responses are equal and normal. There is mild tenderness on palpation on the right side of his neck and behind his right ear.

Which of the following investigations would you do to confirm the most likely underlying diagnosis?

A	MRI brain
B	Thrombophilia screen
C	Syphilis serology
D	Doppler ultrasound scan of the carotid arteries
E	MRI brain and angiography

Audio Video Stop Share Participants 4 More

1:12
https://mypastest.paste

A 43-year-old right-handed man presents to the Emergency Department with sudden onset of left-sided weakness. This weakness came on during a game of squash and he was unable to continue playing as a result. He also complains of pain in the back of his head and neck, which has been present since the weakness began. He works in a stressful job in the city and admits to occasional cocaine use, although he reports he has not taken any in the past week. He takes no other regular medication and has no significant medical history.

On examination, he has normal tone, and grade 4/5 weakness in a pyramidal distribution in the left arm and leg. Coordination on the left side is reduced when compared to the right. The reflexes are normal and the right plantar is down-going, the left being equivocal. There are no cranial nerve

Audio Video Stop Share Participants 4 More

1:12
https://mypastest.paste

E MRI brain and angiography

The most likely diagnosis in this case is carotid artery dissection that has caused a stroke. Up to 20% of strokes in young patients are as a result of carotid artery dissections. Many present with neurological deficits that may be transient, and include hemiparesis (as in this case). Horner syndrome may occur due to damaged autonomic fibres around the carotid bulb itself. However, it should be remembered that a number present without neurological sequelae, at least acutely, but simply with pain in the neck. A carotid bruit may be detected, but is not a reliable sign. The gold standard for diagnosis of carotid dissection is contrast arteriography. Nowadays, however, non-interventional methods such as magnetic resonance angiography are more commonly performed when it is

Audio Video Stop Share Participants 4 More

1:13
https://mypastest.paste

more commonly performed when it is suspected. Fine-MR axial neck 'cuts' can also make the diagnosis, providing good visualisation of the dissected vessel. In this case MRI brain is needed to confirm the stroke and MR angiography to demonstrate the dissection. Carotid dissections more rarely involve intracranial vessels, but the neck pain in this case makes it likely to be extracranial. Antiplatelet therapy is given; at present there is no evidence to support anticoagulation.

D	Doppler ultrasound scan of the carotid arteries

This test is less accurate than MR in detecting dissection and cannot confirm the stroke.

A	MRI brain

Audio Video Stop Share Participants 4 More

1:14
https://mypastest.paste

A MRI brain

Although this investigation would show evidence of stroke, it would not confirm the underlying diagnosis of carotid artery dissection.

B Thrombophilia screen

This investigation would not help make a diagnosis of carotid artery dissection in this case. A thrombophilia screen, testing for protein C, protein S, antithrombin, factor V Leiden and lupus anticoagulant, is often completed in young patients presenting with otherwise unexplained ischaemic stroke, although the pick-up rate is low as these disorders tend to give rise to venous thrombosis.

C Syphilis serology

Audio Video Stop Share Participants 4 More

1:14
https://mypastest.paste

An 18-year-old man with severe learning difficulty since birth is brought to the Outpatient Clinic by his carer. The carer relates the story. The patient's behaviour has been increasingly challenging over the last few months. He has taken to watching late-night television and falling asleep in a chair. In the morning it is difficult for the carers to wake him and he remains drowsy and irritable for some time.

Frequently, he is found to have been incontinent through the night. He is unable to partake in activities as he complains of headache and muscle pains. The carer has only recently started working with the man and he is unaware of past medical history. Physical examination is unremarkable. Initial blood testing, including serum glucose, thyroid function and C-reactive protein, is normal.

Audio Video Stop Share Participants 4 More

1:15
https://mypastest.paste

started working with the man and he is unaware of past medical history. Physical examination is unremarkable. Initial blood testing, including serum glucose, thyroid function and C-reactive protein, is normal.

What investigation would best aid treatment decisions?

A	Renal tract ultrasound scan
B	Computerised tomography (CT) brain
C	Video electroencephalogram (EEG)
D	Toxicology screen
E	Urine microscopy and culture

Audio Video Stop Share Participants 4 More

1:17
https://mypastest.paste

learning difficulty since birth is brought to the Outpatient Clinic by his carer. The carer relates the story. The patient's behaviour has been increasingly challenging over the last few months. He has taken to watching late-night television and falling asleep in a chair. In the morning it is difficult for the carers to wake him and he remains drowsy and irritable for some time.

Frequently, he is found to have been incontinent through the night. He is unable to partake in activities as he complains of headache and muscle pains. The carer has only recently started working with the man and he is unaware of past medical history. Physical examination is unremarkable. Initial blood testing, including serum glucose, thyroid function and C-reactive protein, is normal.

What investigation would best aid

Audio Video Stop Share Participants 4 More

1:17
https://mypastest.paste

C Video electroencephalogram (EEG)

The combination of stupor, incontinence, post-event drowsiness, headache and muscle pain is highly suggestive of nocturnal seizures. Epilepsy is common in patients with severe learning difficulty and often requires multiple therapies. Lack of sleep or the television may be acting as a trigger for the attacks. Admission for overnight video electroencephalogram (EEG) would be a useful investigation to confirm whether seizure activity is present and, if so, to characterise it. Sleep deprivation and pulsed-light stimuli could be used diagnostically if an ictal EEG is not obtained initially.

A Renal tract ultrasound scan

Given that this patient's routine blood

Audio Video Stop Share Participants 4 More

1:17
https://mypastest.paste

Given that this patient's routine blood testing is normal, it is unlikely that the incontinence seen here is related to any renal tract abnormality.

B	Computerised tomography (CT) brain

In a young patient, gross structural brain pathology acting as a focus for epileptiform activity is unlikely, and thus a computerised tomography (CT) brain would not be the imaging of choice. MRI is potentially much more useful in demonstrating more subtle brain abnormalities.

D	Toxicology screen

Given that this patient is cared for and has severe learning difficulties, access to illicit drugs is very unlikely.

Audio Video Stop Share Participants 4 More

1:18
https://mypastest.paste

A 70-year-old retired gardener was admitted to an Orthopaedic Ward 2 weeks ago following a fall in which he sustained a fractured femoral neck. His family report that he was last completely well 4 months ago.

At that time, a change in his personality was noted with frequent unprovoked emotional outbursts directed at those close to him, inappropriate tearfulness and laughter.

Over the next few weeks, he was reported to be increasingly forgetful. In the following weeks, his family have noticed that he has been increasingly clumsy, often spilling drinks and having difficulty dressing. His walking became increasingly unsteady with frequent falls precipitating his current admission. The surgical team are concerned about continued cognitive deterioration, despite treatment for a recent suspected urinary tract

Audio Video Stop Share Participants 4 More

1:19
https://mypastest.paste

deterioration, despite treatment for a recent suspected urinary tract infection, and have referred him for medical advice. Over the last week, jerking movements have also been noted in his arms.

On examination he is agitated, bed-bound and catheterised with spontaneous and stimulus-sensitive myoclonus. Mini-Mental State Examination reveals a score of 8 out of 30, with global deficits. A bilateral grasp reflex together with pout and snout reflexes are present. Tone is increased in all of the limbs, with symmetrically brisk reflexes and bilateral extensor plantars. Although he has difficulty following commands, there is demonstrable ataxia and apraxia of the upper limbs.

Haematological investigation results:

Hb	12.8 g/dl

Audio Video Stop Share Participants 4 More

1:19
https://mypastest.paste:

Hb	12.8 g/dl
WCC	8.4×10^9/l
PLT	281×10^9/l
Na+	142 mmol/l
K+	4.1 mmol/l
Creatine	101 µmol/l
Haematocrit	0.565
Urea	8.1 mmol/l
Bilirubin	11.0 mmol/l
ALT	22 U/l
Albumin	50 U/l
ALP	14 U/l
Ca^{2+}	2,35 mmol/l
TSH	2.15 mU/l

Audio Video Stop Share Participants 4 More

1:19
https://mypastest.paste

B12	245 ng/l
Folate	13.9 µg/l
Random glucose	5.8 mmol/l
ESR	8 mm/h
CRP	4 mg/l
Serum protein electrophoresis	Normal
Rheumatoid factor	Positive
Anti-nuclear antibody	Negative
ANTA	Negative
Random cholesterol	8
Treponema pallidum haemagglutination test	Negative
Anti-neuronal antibodies	Negative

Audio Video Stop Share Participants 4 More

1:20
https://mypastest.paste

Anti-neuronal antibodies	Negative
CXR	Unremarkable
MCV	92.1 fl

Cerebrospinal fluid examination:

WBC	3
Protein	0.47 g/dl
Glucose	4.3 mmol/l
Cytology	No abnormal cells detected

Which one of the following investigations is most specific in securing the diagnosis in this case?

A	CSF analysis for 14.3.3 protein and RTQuIC

Audio Video Stop Share Participants 4 More

1:20
https://mypastest.paste

Which one of the following investigations is most specific in securing the diagnosis in this case?

A	CSF analysis for 14.3.3 protein and RTQuIC
B	Serial blood film for examination of acanthocytes
C	Electroencephalography (EEG)
D	Polymerase chain reaction of CSF for herpes simplex virus detection
E	Axial T2 weighted, diffusion weighted, and Fluid Attenuation Inversion Recovery (FLAIR) MRI series

Audio Video Stop Share Participants 4 More

1:21
https://mypastest.paste

A CSF analysis for 14.3.3 protein and RTQuIC

The clinical scenario is suggestive of sporadic CJD. MRI, EEG and CSF tests all have their place to play in investigating this condition. The recently developed RTQuIC (Real-Time Quaking Induced Conversion) test appears to be the most sensitive and specific test to date, providing higher levels of accuracy than the well-established 14.3.3 protein test.

E Axial T2 weighted, diffusion weighted, and Fluid Attenuation Inversion Recovery (FLAIR) MRI series

Magnetic resonance imaging is generally undertaken to exclude other illnesses. However, in addition, in a proportion of cases, abnormalities of signal may be seen in the anterior

Audio Video Stop Share Participants 4 More

1:22
https://mypastest.paste

cortex. These changes may be helpful in supporting a diagnosis of sporadic CJD.

B	Serial blood film for examination of acanthocytes

Neuroacanthocytosis describes a range of diseases characterised by hyperkinetic movement disorder and cognitive impairment. The features in this case favour CJD.

C	Electroencephalography (EEG)

EEG examination in sporadic CJD may demonstrate generalised bi- or triphasic periodic sharp wave complexes with a frequency of around 1–2 per second. In an appropriate clinical context, the appearance of this EEG pattern is strongly supportive of a

Audio Video Stop Share Participants 4 More

1:22
https://mypastest.paste

demonstrate generalised bi- or triphasic periodic sharp wave complexes with a frequency of around 1–2 per second. In an appropriate clinical context, the appearance of this EEG pattern is strongly supportive of a diagnosis of sporadic CJD. In 60 to 80% of cases of sporadic CJD, the characteristic periodic picture will eventually develop.

D	Polymerase chain reaction of CSF for herpes simplex virus detection

The long history seen in this case makes viral encephalitis very unlikely.

32731

Rate this question:

Next Question

Audio Video Stop Share Participants 4 More

1:22
https://mypastest.paste

A 64-year-old male patient presented to the neurology clinic with progressive weakness of the lower limbs of 6 months' duration. He had lost 3 kg weight. He has consumed 10 units of alcohol each week for the past 3 years and smokes 10 cigarettes daily. He did not feel that his food habits had changed.

His cranial nerves were unremarkable. Upper limbs were normal for tone. There was some mild weakness of grip strength and thinning of forearm muscles. Reflexes and sensation were normal. In the lower limbs, the quadriceps were wasted and weak, with normal tone. Tendon reflexes and sensation were normal. CK is moderately elevated at 832.

What is the most likely diagnosis?

A Inclusion body myositis

Audio Video Stop Share Participants 4 More

1:23
https://mypastest.paste

His cranial nerves were unremarkable. Upper limbs were normal for tone. There was some mild weakness of grip strength and thinning of forearm muscles. Reflexes and sensation were normal. In the lower limbs, the quadriceps were wasted and weak, with normal tone. Tendon reflexes and sensation were normal. CK is moderately elevated at 832.

What is the most likely diagnosis?

A	Inclusion body myositis
B	Paraneoplastic myopathy
C	Polymyositis
D	Alcohol-related myopathy
E	Motor neurone disease

Audio Video Stop Share Participants 4 More

1:23
https://mypastest.paste

A Inclusion body myositis

Inclusion body myositis is a progressive, late-onset myopathy characterised by weakness and wasting of forearm flexors and quadriceps. The CK level is often only modestly raised, as in this case. It does not respond well to immunotherapy.

B Paraneoplastic myopathy

This tends to be a severe, subacute myopathic illness with very high CK levels. Proximal upper and lower limb muscles are usually involved.

C Polymyositis

This is an acute/subacute immune-mediated myopathy affecting proximal upper and lower limb muscles, with CK usually >10-fold the upper limit of

Audio Video Stop Share Participants 4 More

1:24
https://mypastest.paste

This is an acute/subacute immune mediated myopathy affecting proximal upper and lower limb muscles, with CK usually >10-fold the upper limit of normal. It usually responds well to immunotherapy.

D	Alcohol-related myopathy

The focal involvement of distal upper limb muscles and the history of only moderate alcohol intake go against this diagnosis.

E	Motor neurone disease

In order to make this diagnosis on clinical grounds there needs to be mixed upper and lower motor neurone signs, which is not the case here. Mild elevations in CK can be seen in MND due to muscle damage through denervation.

Audio Video Stop Share Participants 4 More

1:24
https://mypastest.paste:

A 64-year-old man presents to the Emergency Department with a 3-day history of severe back pain. A plain X-ray of his spine is normal and he is discharged home with ibuprofen. Two days later, he starts complaining of tingling in his fingers and toes.

The following day, he develops a rapidly progressive weakness affecting his legs, and then his arms. He is brought to the Emergency Department.

On examination, he has bilateral lower motor neurone VIIth nerve palsy and a tetraparesis with grade 4 power in all four limbs, hyporeflexia in the arms and legs, and flexor plantars. His sensation is unimpaired. Magnetic resonance imaging (MRI) of the brain is normal.

Lumbar puncture (CSF):

Protein	1.6 g/l (< 0.4)

Audio Video Stop Share Participants 4 More

1:27
https://mypastest.paste

The following day, he develops a rapidly progressive weakness affecting his legs, and then his arms. He is brought to the Emergency Department.

On examination, he has bilateral lower motor neurone VIIth nerve palsy and a tetraparesis with grade 4 power in all four limbs, hyporeflexia in the arms and legs, and flexor plantars. His sensation is unimpaired. Magnetic resonance imaging (MRI) of the brain is normal.

Lumbar puncture (CSF):

Protein	1.6 g/l (< 0.4)
Glucose	3.6 mmol/l (plasma glucose 5.2 mmol/l)
Cells	None seen

He subsequently develops respiratory failure and is intubated and ventilated.

Audio Video Stop Share Participants 4 More

1:27
https://mypastest.paste

E IV immunoglobulin

This patient has Guillain–Barré syndrome (GBS), or acute inflammatory demyelinating polyradiculoneuropathy. The rapidly progressive limb and facial weakness, hyporeflexia and back pain are typical features. His CSF shows the classical picture of normal cells and raised protein. IVIG is considered first-line treatment, although plasma exchange is a viable alternative.

A Pyridostigmine

This drug is used in myasthenia gravis, but is not useful in GBS. The hyporeflexia, history of back pain and paraesthesia, and the CSF picture help to guide you to the diagnosis of GBS rather than myasthenia.

Audio Video Stop Share Participants 4 More

1:27
https://mypastest.paste

to guide you to the diagnosis of GBS rather than myasthenia.

B IV methylprednisolone

Corticosteroids are not useful in treating GBS.

C IV aciclovir

This drug is used to treat serious herpes virus infections, but there are no signs to support such a diagnosis here.

D Botulism antitoxin

Botulism typically presents with descending paralysis, starting with the eye muscles. These features are not seen in this case.

Audio Video Stop Share Participants 4 More

1:28
https://mypastest.paste

A 56-year-old anaesthesia nurse, who has worked ardently in the operating theatre for the past 10 years, presents to the Psychiatry Clinic with history of gradually increasing irritability over 3 months. His wife said that he has become suspicious of late and was convinced that she was having an illicit affair with their neighbour. He had recently sold his car at an unusually cheap price. He would become hostile if made to realise his mistakes.

On examination, he was unkempt. He was alert but his recent memory was impaired. Fundus examination revealed bilateral pale optic discs. Other cranial nerves were normal.

Gait was ataxic and mildly spastic. Power of hip flexors and ankle dorsiflexors was 4/5. Tendon reflexes were depressed and planters were up-going on both sides. Vibration was diminished to mid-shins.

Audio Video Stop Share Participants 4 More

1:28
https://mypastest.paste

Blood investigations:

White blood count (WBC)	$4.0 \times 10^9/l$
Hb	10 g/dl
MCV	106 fl
MCH	30.0 pg
Glucose	6.8 mmol/l
HTLV1 (Human T-cell Lymphotrophic virus)	-
VDRL (venereal Disease Research Laboratory)	Non-reactive
TPHA (Treponema Pallidum Haemagglutination Assay)	-
HIV	-

Cerebrospinal fluid (CSF)

Audio
Video
Stop Share
Participants
4
More

1:28
https://mypastest.paste

Cerebrospinal fluid (CSF)

Lymphocytes	$4/mm^3$
Protein	0.45 g/l
Glucose	6.0 mmol/l

Magnetic resonance imaging (MRI) of the cervical spine T2 signal change in the posterior columns.

Choose the most likely diagnosis.

A	Taboparesis
B	Tropical spastic paraparesis
C	Multiple sclerosis
D	Subacute combined degeneration of the cord (SACD)

Audio Video Stop Share Participants 4 More

1:28
https://mypastest.paste

Glucose	6.0 mmol/l

Magnetic resonance imaging (MRI) of the cervical spine T2 signal change in the posterior columns.

Choose the most likely diagnosis.

A	Taboparesis
B	Tropical spastic paraparesis
C	Multiple sclerosis
D	Subacute combined degeneration of the cord (SACD)
E	Disseminated encephalomyelitis

7225
Audio
Video
Stop Share
Participants
4
More

1:31
https://mypastest.paste:

D Subacute combined degeneration of the cord (SACD)

This is a typical subacute combined degeneration of the spinal cord due to Vitamin B_{12} deficiency. The neuropsychiatric manifestations could present without the classical spinal cord and peripheral nerve involvement. The haematological effects of vitamin B_{12} deficiency – i.e. pernicious anaemia – and its neurological manifestations result from failure to transfer minute amounts of this vitamin across the intestinal mucosa – 'starvation in the midst of plenty', as rightly pointed out by Castle. Other malabsorptive disorders like coeliac disease, extensive gastric or ileal resections, and overgrowth of intestinal bacteria in blind loop anastomosis, are other causes leading to the neurological and haematological effects of B_{12}

Audio Video Stop Share Participants 4 More

1:32
https://mypastest.paste

A megaloblastic state, as well as the neurological features of subacute combined degeneration, has been described in operating room personnel who are exposed chronically to nitrous oxide. Such chronic exposure to the gas leads to the interference with methionine synthetase, a methylcobalamin-dependent enzyme. This produces a 'functional' B_{12} deficiency and blood B_{12} measurements may actually be normal. In recent times an increasing number of such cases have been seen due to recreational nitrous oxide use amongst teenagers and young adults.

In such cases, increased levels of methyl malonic acid and homocysteine are more reliable indicators of intracellular cobalamin deficiency.

A Taboparesis

Audio Video Stop Share Participants 4 More

1:33
https://mypastest.paste

Tertiary syphilis could produce all of these symptoms and signs, but the investigations have ruled this illness out (negative VDRL and TPHA). One would expect cellular CSF in tertiary syphilis.

B	Tropical spastic paraparesis

This syndrome, rare in the UK, is caused by HTLV1, which is negative in this case.

C	Multiple sclerosis

Whilst this may present in a progressive manner, especially in older men, the reflexes would be brisk and prominent neuropsychiatric change is rare at the outset.

E	Disseminated

Audio Video Stop Share Participants 4 More

1:33
https://mypastest.paste

this case.

C	Multiple sclerosis

Whilst this may present in a progressive manner, especially in older men, the reflexes would be brisk and prominent neuropsychiatric change is rare at the outset.

E	Disseminated encephalomyelitis

This is a reasonable consideration in terms of explaining the symptoms and signs. However, the macrocytic anaemia and posterior column MRI signal change make subacute combined degeneration more likely.

7225

Rate this question:

Audio Video Stop Share Participants 4 More

1:33
https://mypastest.paste

A 19-year-old woman is seen in the Neurology Outpatient Clinic. She had a first seizure 6 weeks ago, during sleep, with no obvious precipitating factor. In particular there is no history to suggest prior infection, drug or alcohol use or head injury. There is no previous medical history; childhood health and development was normal and there is no history of febrile convulsions. Her maternal aunt apparently suffered from childhood epilepsy. She lives with her partner and they are thinking of trying for a baby in the next few years.

Her partner, who witnessed the attack, reports that he awoke to find her stiff, unresponsive and making rhythmical movements of all four limbs with 'frothing at the mouth' and some groaning noises. The movements lasted for nearly a minute. She nearly fell out of bed and was incontinent of urine. When the movements stopped

Audio
Video
Stop Share
Participants
4
More

1:33
https://mypastest.paste

urine. When the movements stopped she was drowsy for about 15 minutes, and also confused about what had happened.

A magnetic resonance imaging (MRI) brain scan has been reported as normal. An electroencephalogram (EEG) was reported as showing normal background rhythm with abnormal bursts of bilateral synchronous spike-wave activity and a photosensitivity reaction at frequencies between 10 and 20 Hz.

She has been counselled about keeping herself safe during her everyday life and work and about not driving. She has contacted the Driver and Vehicle Licensing Agency (DVLA) to inform them of what has happened.

Choose the most appropriate initial treatment.

Audio Video Stop Share Participants 4 More

1:33
https://mypastest.paste

keeping herself safe during her everyday life and work and about not driving. She has contacted the Driver and Vehicle Licensing Agency (DVLA) to inform them of what has happened.

Choose the most appropriate initial treatment.

A	Carbamazepine 200 mg bd
B	Sodium valproate 300 mg bd
C	Lamotrigine 25 mg/day increasing gradually to 75 mg bd
D	Levetiracetam 500 mg bd
E	No drug treatment as this is a single seizure

Audio Video Stop Share Participants 4 More

1:34
https://mypastest.paste

groaning noises. The movements lasted for nearly a minute. She nearly fell out of bed and was incontinent of urine. When the movements stopped she was drowsy for about 15 minutes, and also confused about what had happened.

A magnetic resonance imaging (MRI) brain scan has been reported as normal. An electroencephalogram (EEG) was reported as showing normal background rhythm with abnormal bursts of bilateral synchronous spike-wave activity and a photosensitivity reaction at frequencies between 10 and 20 Hz.

She has been counselled about keeping herself safe during her everyday life and work and about not driving. She has contacted the Driver and Vehicle Licensing Agency (DVLA) to inform them of what has happened.

Choose the most appropriate initial

Audio Video Stop Share Participants 4 More

1:34
https://mypastest.paste

C Lamotrigine 25 mg/day increasing gradually to 75 mg bd

This woman's history is that of a first generalised tonic-clonic seizure (GTCS) from sleep. The EEG changes of bisynchronous spike-wave and photosensitivity support a diagnosis of primary generalised epilepsy. The positive family history is also likely to be relevant in this context. Although treatment of a single seizure is not indicated as a general rule, in cases of primary generalised epilepsy (or cases of localisation-related epilepsy where a high risk of seizure recurrence is identified, such as with an underlying tumour) where there is a very strong likelihood of recurrent GTCS, treatment with an AED is recommended following the first seizure. As she may consider pregnancy in the near future, lamotrigine is a good choice as it

Audio Video Stop Share Participants 4 More

1:34
https://mypastest.paste

lamotrigine is a good choice as it carries a relatively low risk of foetal complications. It is essential that she has pre-conception counselling with recommendation of folic acid treatment.

A	Carbamazepine 200 mg bd

In primary generalised epilepsy carbamazepine may theoretically worsen seizures, especially myoclonus.

B	Sodium valproate 300 mg bd

Due to very high rates of foetal complications (both major congenital malformations and developmental delay), this drug must be avoided in women of childbearing age unless there is absolutely no alternative.

Audio Video Stop Share Participants 4 More

1:35
https://mypastest.paste

suitable second-choice drug if lamotrigine was ineffective or poorly tolerated.

E	No drug treatment as this is a single seizure

She is at high risk of further seizures based on the diagnosis of primary generalised epilepsy, so some form of treatment ought to be offered. However, the decision to start treatment would always be made in conjunction with the patient and must be in line with their wishes.

7006

Rate this question:

Audio Video Stop Share Participants 4 More

1:35
https://mypastest.paste

A 59-year-old woman with a history of hypertension comes to the Emergency Department with an episode of left sided face and arm weakness which resolves completely over the space of 2 h. She has a previous event which lasted for 30 min earlier on in the week, but did not present to hospital. Usual medication includes lisinopril and indapamide for blood pressure control, and atorvastatin for hypercholesterolaemia. She also takes aspirin 75 mg once a day. She smokes 15 cigarettes per day.

On examination, her BP is 155/90 mmHg, pulse is 70 bpm and regular. There are no heart murmurs and no carotid bruits. Chest is clear, abdomen is soft and non-tender, and neurology assessment is now normal. Routine bloods are unremarkable.

Which of the following is the most appropriate option of long-term

Audio Video Stop Share Participants 4 More

1:35
https://mypastest.paste

carotid bruits. Chest is clear, abdomen is soft and non-tender, and neurology assessment is now normal. Routine bloods are unremarkable.

Which of the following is the most appropriate option of long-term medication to reduce risk of further cerebral events?

A	Switch to aspirin 300mg OD
B	Continue aspirin 75mg OD
C	Switch to dabigatran 75mg BD
D	Switch to clopidogrel 75mg OD
E	Warfarin loading

Audio Video Stop Share Participants 4 More

1:37
https://mypastest.paste

D Switch to clopidogrel 75mg OD

Clopidogrel is indicated in patients who cannot tolerate aspirin or as in this situation for patients who suffer recurrent TIAs whilst on aspirin.

A Switch to aspirin 300mg OD

High dose aspirin is recommended for a period of two weeks treatment after a confirmed stroke.

B Continue aspirin 75mg OD

This is the standard dose for vascular prophylaxis in patients without unstable cerebrovascular disease.

C Switch to dabigatran 75mg BD

Audio Video Stop Share Participants 4 More

1:37
https://mypastest.paste

This is the standard dose for vascular prophylaxis in patients without unstable cerebrovascular disease.

C	Switch to dabigatran 75mg BD

Dabigatran is indicated for stroke prophylaxis in patients with chronic atrial fibrillation, not for patients in sinus rhythm.

E	Warfarin loading

Warfarin would be indicated in the event of atrial fibrillation, which is not present here.

70615

Rate this question:

Next Question

Audio Video Stop Share Participants 4 More

1:37
https://mypastest.paste

A 55-year-old male solicitor is referred to the general medical clinic by his general practitioner (GP). He has a six-month history of difficulty walking and writing, which started gradually and appears to be slowly worsening.. He describes bradykinesia and that he has difficulty getting started when trying to get up from a chair or get out of bed. He has not suffered any falls or experienced any tremor. He was previously very active and played squash two evenings per week, which he has had to stop doing as well as his job. He is still able to wash and dress, albeit slowly. He has had no episodes of fainting, no cognitive symptoms and no incontinence. Past medical history of note is type 2 diabetes for which he takes metformin. He is a lifelong non-smoker.

On examination, he demonstrates bradykinesia and hypomimia. He has a slightly stooped posture with reduced

Audio Video Stop Share Participants 4 More

1:38
https://mypastest.paste:

slightly stooped posture with reduced arm swing, but once walking he appears to mobilise well with reasonable speed and no obvious unsteadiness on turning. GCS 15 cranial nerve examination reveals only reduced blinking but no abnormalities of eye movements. Tone is mildly increased in his right hand, with some cogwheeling. He has a mild tremor of the right hand, which increases when he is asked to perform a task with his left hand. The reflexes are brisk but symmetrical and the plantars are down-going bilaterally. There are no sensory abnormalities.

What is the most appropriate initial treatment to try in this man's case?

A	Selegiline 5 mg bd
B	Combined L-dopa and decarboxylase inhibitor

Audio Video Stop Share Participants 4 More

1:38
https://mypastest.paste

symmetrical and the plantars are down-going bilaterally. There are no sensory abnormalities.

What is the most appropriate initial treatment to try in this man's case?

A	Selegiline 5 mg bd
B	Combined L-dopa and decarboxylase inhibitor preparation titrated up according to side effects and response
C	Pramipexole
D	Benzatropine titrated up to a maximum of 6 mg daily
E	Propranolol

Audio Video Stop Share Participants 4 More

1:40
https://mypastest.paste

B	Combined L-dopa and decarboxylase inhibitor preparation titrated up according to side effects and response

Drugs in this class include co-beneldopa and co-careldopa, and are very effective in the treatment of PD. **NICE guidance** recommends L-dopa as first-line treatment in those with early Parkinson's when motor symptoms are impacting on their daily lives (as is the case here).

A	Selegiline 5 mg bd

This man presents with the cardinal symptoms of idiopathic Parkinson's disease – rigidity, bradykinesia and a resting tremor. Selegiline is a mono-amine oxidase B inhibitor (MAO BI). Selegiline was thought at one point to

Audio Video Stop Share Participants 4 More

1:40
https://mypastest.paste

research and its use in recent years has declined. Selegiline is therefore not the best answer, as an alternative drug – pramipexole – is much suitable for this gentleman.

C	Pramipexole

Pramipexole is a dopamine agonist. Other drugs in this class include ropinirole. Dopamine agonists have been shown in both a systematic review and randomised controlled trials to have a lower incidence of dyskinesia and fluctuation in motor response, which are a genuine problem in the treatment of Parkinson's disease. However, they are less effective in controlling symptoms and improving ADLs than L-dopa. The risk of impulse control disorder and excessive sleepiness is higher with dopamine agonists. Decisions regarding treatment are best made in a shared

Audio Video Stop Share Participants 4 More

1:40
https://mypastest.paste

agonists. Decisions regarding treatment are best made in a shared manner with the patient. See NICE guideline 71 below.

D	Benzatropine titrated up to a maximum of 6 mg daily

Benzatropine is an anticholinergic medication that can be effective in improving tremor and sialorrhoea (excessive drooling), which are not major complaints of this gentleman at this stage.

E	Propranolol

Propranolol belongs to the class of drugs called beta-blockers. It is rarely useful with parkinsonian tremor but is helpful in the management of essential tremor.

6995
Audio Video Stop Share Participants 4 More

1:41
https://mypastest.paste

A 75-year-old woman presented with a 2-year history of recurrent falls. The majority of the falls had been backwards and she had injured her head multiple times. Her walking had become progressively slower over the last 3 years and she had particular difficulty with turning. She had been depressed for many years and had been taking amitriptyline for over 5 years. The only other medication she had been taking was enalapril, for hypertension.

On examination of her cranial nerves, she had difficulty with down-gaze, but a full range of eye movements with the 'doll's head' manoeuvre. She had axial rigidity with symmetrically increased tone in both upper limbs. Power, reflexes and coordination were normal, as was sensation. She had decreased arm swing on walking with a stooped festinating gait.

Audio Video Stop Share Participants 4 More

1:41
https://mypastest.paste

doll's head manoeuvre. She had axial rigidity with symmetrically increased tone in both upper limbs. Power, reflexes and coordination were normal, as was sensation. She had decreased arm swing on walking with a stooped festinating gait.

What is the most likely diagnosis?

A	Wilson's disease
B	Drug-induced parkinsonism
C	Dementia with Lewy bodies (DLB)
D	Multiple system atrophy (MSA)
E	Progressive supranuclear palsy (PSP)

Audio Video Stop Share Participants 4 More

1:42
https://mypastest.paste

E Progressive supranuclear palsy (PSP)

This is a rare, progressive disorder that causes adult-onset parkinsonism, and is often classified as one of the 'Parkinson-plus' syndromes. As well as bradykinesia and rigidity (which is most commonly axial), there is postural instability with multiple (normally backwards) falls early on in the disease. It should be noted that impaired up-gaze can be seen in normal elderly patients, but impaired down-gaze is always pathological. In general, both vertical directions become impaired before horizontal eye movements in supranuclear gaze palsy. Due to the supranuclear nature of the gaze palsy, doll's head movements demonstrate a normal range of gaze. Dysphagia and dysarthria are both seen, as is cognitive impairment particularly of frontal/executive

Audio Video Stop Share Participants 4 More

1:42
https://mypastest.paste

particularly of frontal/executive function. PSP shows poor responsiveness to dopaminergic drugs.

A	Wilson's disease

This is an autosomal recessive condition due to mutations of a copper-transporting protein gene (*ATP7B*) on chromosome 13. The major features are neurological (normally a progressive extrapyramidal disorder due to deposition in the basal ganglia), psychiatric (behavioural changes being prominent), hepatic (presenting with features of liver failure/cirrhosis) and ocular (brownish-coloured Kayser–Fleischer rings – copper deposition in Descemet's membrane, best seen on slit-lamp examination). The age of this patient makes the diagnosis of Wilson's disease very unlikely.

Audio Video Stop Share Participants 4 More

1:43
https://mypastest.paste

A 60-year-old man is referred to a neurologist, with a 3-month history of progressive forgetfulness, agitation and speech problems. He had been working as a shelf stacker in a supermarket but has recently been made redundant because he has become increasingly clumsy with items. Since then, he has been somewhat low in mood. His past medical history includes hypertension, for which he is treated with bendroflumethiazide, and hypothyroidism treated with thyroxine.

On examination, vital signs are normal, with a blood pressure of 138/80 mmHg and a pulse of 84 bpm. He is found to be low in mood and has a marked expressive dysphasia, with a more limited receptive component. On the mini-mental state examination, he scores 21/30, with deficiencies in recall, orientation and visuoconstructive tasks. There is a left palmomental

Audio Video Stop Share Participants 4 More

1:43
https://mypastest.paste

reflex. Peripheral nerve examination reveals marked generalised myoclonus and in the upper limbs an intention tremor. In the lower limbs, he exhibits a broad-based gait, but no other features. Tone, power and reflexes and sensation are all normal.

Blood tests reveal:

Sodium (Na^+)	130 mmol/l
Potassium (K^+)	4.0 mmol/l
Urea	7.2 mmol/l
Creatinine	154 µmol/l
Thyroxine (T4)	60 nmol/l (58–178)
Thyroid-stimulating hormone (TSH)	8.0 mu/l (0.4–5)
Vitamin B_{12}	250 ng/l (160–760)

Audio Video Stop Share Participants 4 More

1:43
https://mypastest.paste

Folate	7.0 μg/l (2.0–11.0)
Haemoglobin (Hb)	13.4 g/dl
Mean corpuscular volume (MCV)	102 fl (80–96)
White cell count (WCC)	8.0×10^9/l
Platelets (PLT)	250×10^9/l
Erythrocyte sedimentation rate (ESR)	15 mm/h (1–20)

What is the most likely cause for this patient's symptoms?

A Hypothyroidism

B Pseudodementia

C Vascular dementia

Audio Video Stop Share Participants 4 More

1:43
https://mypastest.paste

White cell count (WCC)	$8.0 \times 10^9/l$
Platelets (PLT)	$250 \times 10^9/l$
Erythrocyte sedimentation rate (ESR)	15 mm/h (1–20)

What is the most likely cause for this patient's symptoms?

A	Hypothyroidism
B	Pseudodementia
C	Vascular dementia
D	Sporadic Creutzfeldt–Jakob disease
E	Multiple sclerosis (MS)

Audio Video Stop Share Participants 4 More

1:46
https://mypastest.paste

D	Sporadic Creutzfeldt-Jakob disease

The correct answer is Sporadic Creutzfeldt-Jakob disease (Option D).

The clinical picture of generalised myoclonus and a short progressive history is in keeping with sporadic Creutzfeldt-Jakob disease. The diagnosis is confirmed with a combination of electroencephalogram (EEG), lumbar puncture and magnetic resonance imaging (MRI) scan findings.

A	Hypothyroidism

Hypothyroidism (Option A) is incorrect.

This patient presents with a relatively short history of progressive global cognitive dysfunction, dysphasia, cerebellar signs and myoclonus. Examination also reveals frontal

Audio Video Stop Share Participants 4 More

1:47
https://mypastest.paste

Examination also reveals frontal release signs. Although the biochemical picture reveals an elevated level of TSH, his T4) level is within the normal range, and hence it is unlikely that his symptoms could be attributed to hypothyroidism.

B	Pseudodementia

Pseudodementia (Option B) is incorrect.

Depression can cause pseudodementia but would not lead to such abnormal neurological findings.

C	Vascular dementia

Vascular dementia (Option C) is incorrect.

Vascular dementia tends to cause a stepwise deterioration in cognition,

Audio Video Stop Share Participants 4 More

1:47
https://mypastest.paste

Vascular dementia tends to cause a stepwise deterioration in cognition, and one would expect a history or findings of previous cerebrovascular disease.

E	Multiple sclerosis (MS)

Multiple sclerosis (MS) (Option E) is incorrect.

MS can present with almost any neurological symptom or sign. Autonomic, visual, motor and sensory problems are the most common. The specific symptoms are determined by the location of the lesions within the nervous system and can include changes in sensation, muscle weakness, blurred vision and ataxia, as well as bladder and bowel problems. Signs and symptoms are typically disseminated in time and space. The diagnosis is typically made on the

Audio Video Stop Share Participants 4 More

1:47
https://mypastest.paste:

An 18-year-old woman is brought by her mother to the clinic for evaluation of her neurological status. She has suffered deteriorating school performance for the past 5 months, and has been recently noticed by her teacher to have temper tantrums in the classroom.

Her mother is concerned that in the early morning her daughter gets shock-like contractions of her shoulder muscles and complains of vague visual blurring. This has been present for the past 3 weeks. On the morning of her visit, she had lost consciousness for the first time, followed by a generalised tonic–clonic seizure. Early in childhood she had an exanthematous illness from which she recovered uneventfully.

On examination, she is drowsy and uncooperative with the clinical examination. Cranial nerves appear

Audio Video Stop Share Participants 4 More

1:47
https://mypastest.paste

normal. Diffuse shock-like contractions are noted involving all four limbs. Tendon reflexes are brisk with bilateral Babinski's sign. She has a wide-based gait and is unable to tandem. Blood pressure is noted at 105/72 mmHg, with pulse 85 bpm and regular. General physical review is unremarkable, as our routine bloods and a chest X-ray.

What is the most likely diagnosis?

A	Lipid storage disease
B	Schilder's demyelinative disease
C	Neurosarcoidosis
D	Sub-acute sclerosing panencephalitis

Audio Video Stop Share Participants 4 More

1:47
https://mypastest.paste

Babinski's sign. She has a wide-based gait and is unable to tandem. Blood pressure is noted at 105/72 mmHg, with pulse 85 bpm and regular. General physical review is unremarkable, as our routine bloods and a chest X-ray.

What is the most likely diagnosis?

A	Lipid storage disease
B	Schilder's demyelinative disease
C	Neurosarcoidosis
D	Sub-acute sclerosing panencephalitis
E	Ceroid lipofuscinosis

Audio Video Stop Share Participants 4 More

1:47
https://mypastest.paste:

An 18-year-old woman is brought by her mother to the clinic for evaluation of her neurological status. She has suffered deteriorating school performance for the past 5 months, and has been recently noticed by her teacher to have temper tantrums in the classroom.

Her mother is concerned that in the early morning her daughter gets shock-like contractions of her shoulder muscles and complains of vague visual blurring. This has been present for the past 3 weeks. On the morning of her visit, she had lost consciousness for the first time, followed by a generalised tonic–clonic seizure. Early in childhood she had an exanthematous illness from which she recovered uneventfully.

On examination, she is drowsy and uncooperative with the clinical examination. Cranial nerves appear

Audio Video Stop Share Participants 4 More

1:52

https://www.google.com/sea 14

DIFFERENTIAL DIAGNOSIS OF EXANTHEMATOUS FEVER

LESION	DESCRIPTION	PATHOGENS OR INFECTIONS
Utricarial rash	Swelling of the lesions that appear and resolve rapidly	1)Viral: EBV, Hep B, HIV. 2) Bacterial: M. Pneumoniae and group A streptococcus. 3) Others: Drug reaction.
Vesicular, Pustular and Bullous	1) Vesicular: Raised, hemi spherical lesions containing clear fluid and less than 0.5 cm. 2) Pustular, Bullous: Raised hemi spherical lesion that is greater than 0.5 cm containing clear or purulent fever.	1) Viral: HSV, VZV, Cox Sackie virus. 2) Bacterial: Staphylococcus aureus, Bullous impetigo, Streptococcus crusted impetigo. 3) Others: Toxic epidermal necrosis, Steven Johnson syndrome. 4) Ricketessial pox.

SlideShare

Exanthematous pyrexia(Fever with Rash)

3) Others: Kawasakis; 14. DIFFERENTIAL DIAGNOSIS OF EXANTHEMATOUS ...

Images may be subject to copyright. Learn More

RELATED IMAGES

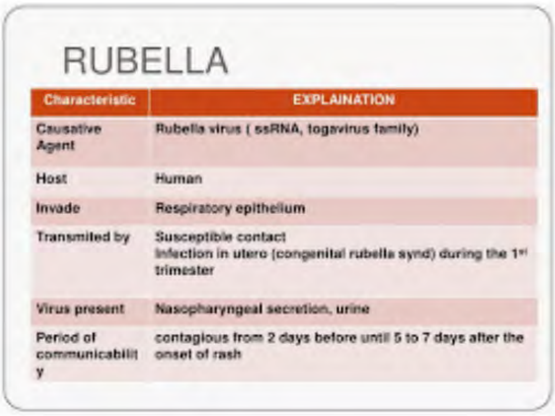

RUBELLA

Characteristic	EXPLAINATION
Causative Agent	Rubella virus (ssRNA, togavirus family)
Host	Human
Invade	Respiratory epithelium
Transmited by	Susceptible contact Infection in utero (congenital rubella synd) during the 1st trimester
Virus present	Nasopharyngeal secretion, urine
Period of communicability	contagious from 2 days before until 5 to 7 days after the onset of rash

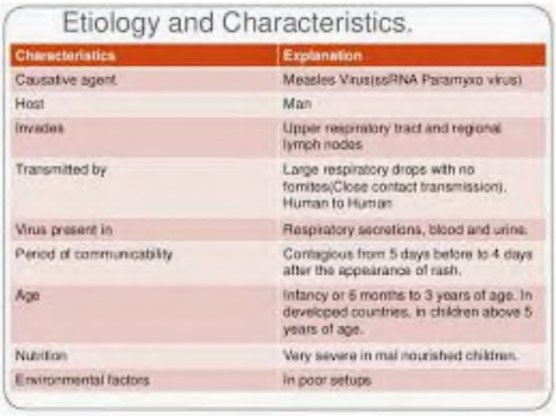

Etiology and Characteristics.

Characteristics	Explanation
Causative agent	Measles Virus(ssRNA Paramyxo virus)
Host	Man
Invades	Upper respiratory tract and regional lymph nodes
Transmitted by	Large respiratory drops with no fomites(Close contact transmission). Human to Human
Virus present in	Respiratory secretions, blood and urine.
Period of communicability	Contagious from 5 days before to 4 days after the appearance of rash.
Age	Infancy or 6 months to 3 years of age. In developed countries, in children above 5 years of age.
Nutrition	Very severe in mal nourished children.
Environmental factors	In poor setups

1:52
https://mypastest.paste

muscles and complains of vague visual blurring. This has been present for the past 3 weeks. On the morning of her visit, she had lost consciousness for the first time, followed by a generalised tonic–clonic seizure. Early in childhood she had an exanthematous illness from which she recovered uneventfully.

On examination, she is drowsy and uncooperative with the clinical examination. Cranial nerves appear normal. Diffuse shock-like contractions are noted involving all four limbs. Tendon reflexes are brisk with bilateral Babinski's sign. She has a wide-based gait and is unable to tandem. Blood pressure is noted at 105/72 mmHg, with pulse 85 bpm and regular. General physical review is unremarkable, as our routine bloods and a chest X-ray.

What is the most likely diagnosis?

Audio Video Stop Share Participants 4 More

1:53
https://mypastest.paste

D Sub-acute sclerosing panencephalitis

This could fit with the rare condition of subacute sclerosing panencephalitis. It is recognised to be the result of chronic measles infection. It is now an uncommon disease after the widespread use of measles vaccination. There is usually a history of measles very early in life followed by 6–8 years of no symptoms. The disease evolves in several stages. Initially there is a decline in proficiency in school. This intellectual deterioration is followed by diffuse myoclonic jerks in association with focal and generalised seizures and visual deterioration due to choroidoretinitis. This is followed by pyramidal signs, rigidity and progressive unresponsiveness. Finally the patient lies decorticated followed by death. The course of the illness is 1–3 years. No effective treatment is

Audio Video Stop Share Participants 4 More

1:55
https://mypastest.paste

Lipid storage diseases, such as Gaucher's, present with progressive hepatosplenomegaly, CNS dysfunction and neuropathy. The apparent onset in late childhood doesn't fit with this picture.

B	Schilder's demyelinative disease

This disease, also known as diffuse myelinoclastic sclerosis, presents in childhood with symptoms similar to multiple sclerosis.

C	Neurosarcoidosis

Although neurosarcoidosis can lead to progressive CNS dysfunction, other clinical features such as erythema nodosum, respiratory symptoms and signs, and CXR changes to suggest sarcoid are absent here.

Audio Video Stop Share Participants 4 More

1:55
https://mypastest.paste

multiple sclerosis.

C	Neurosarcoidosis

Although neurosarcoidosis can lead to progressive CNS dysfunction, other clinical features such as erythema nodosum, respiratory symptoms and signs, and CXR changes to suggest sarcoid are absent here.

E	Ceroid lipofuscinosis

Ceroid lipofuscinosis in children is associated with progressive CNS dysfunction from birth rather than the onset in later childhood seen here. An adult form presents with progressive psychiatric disturbance and parkinsonism.

32768

Rate this question:

Audio Video Stop Share Participants 4 More

1:56
https://mypastest.paste

A 60-year-old man is referred to a neurologist having developed a right flail foot. In the last few weeks he has been stubbing his toes every time he walks and has taken to using a wheelchair, because he cannot feel his foot, and has noticed the numbness extending up the back of the thigh.

He does not complain of any back pain or bowel/bladder problems.
He has a history of benign prostatic hypertrophy, osteoarthritis and has recently had a right total hip arthroplasty.

On examination, there is some evidence of wasting of the right anterior compartments in the lower leg and wasting of the hamstrings.

Tone appears to be significantly reduced at the right ankle and knee, and the right foot is completely flaccid. On examination of power there is absent right dorsiflexion, plantar

Audio Video Stop Share Participants 4 More

1:56
https://mypastest.paste

flexion, eversion and inversion at the foot and weakness of right knee flexion.

There is an absent ankle and plantar reflex on the right, but right knee reflex is preserved. Sensory examination reveals reduced sensation to all modalities over the whole of the right lower leg and back of thigh. The left lower limb is normal.

Where is the likely lesion in this patient?

A	Lumbosacral plexus
B	Common peroneal nerve palsy
C	L5 root lesion
D	Sciatic nerve palsy

Audio Video Stop Share Participants 4 More

1:56
https://mypastest.paste

There is an absent ankle and plantar reflex on the right, but right knee reflex is preserved. Sensory examination reveals reduced sensation to all modalities over the whole of the right lower leg and back of thigh. The left lower limb is normal.

Where is the likely lesion in this patient?

A	Lumbosacral plexus
B	Common peroneal nerve palsy
C	L5 root lesion
D	Sciatic nerve palsy
E	Lumbar segment anterior horn cells

Audio Video Stop Share Participants 4 More

1:59
https://mypastest.paste

and wasting of the hamstrings.

Tone appears to be significantly reduced at the right ankle and knee, and the right foot is completely flaccid. On examination of power there is absent right dorsiflexion, plantar flexion, eversion and inversion at the foot and weakness of right knee flexion.

There is an absent ankle and plantar reflex on the right, but right knee reflex is preserved. Sensory examination reveals reduced sensation to all modalities over the whole of the right lower leg and back of thigh. The left lower limb is normal.

Where is the likely lesion in this patient?

Your answer was incorrect

A Lumbosacral plexus

Audio Video Stop Share Participants 4 More

1:59
https://mypastest.paste

D Sciatic nerve palsy

This patient presents with features suggestive of right sciatic nerve palsy. The sciatic nerve (L4-S3) supplies the anterior and posterior compartment muscles of the lower leg and also the hamstring muscles.
This patient presents with flail foot and weakness of knee flexion, and classical distribution of sensory disturbance affecting the whole of the lower leg and back of the thigh. Other clues include the suggestion of wasting of the hamstrings and a previous history of hip surgery. The sciatic nerve can be injured by neck of femur fractures or hip surgery.

A Lumbosacral plexus

A lesion here would likely cause ill-defined root pain and more diffuse weakness

Audio Video Stop Share Participants 4 More

2:01
https://mypastest.paste

A lesion here would likely cause ill-defined root pain and more diffuse weakness.

B	Common peroneal nerve palsy

This would cause weakness of dorsiflexion and eversion only with sensory disturbance of the outer lower leg and dorsum of the foot. The ankle jerk would not be affected.

C	L5 root lesion

This would cause weakness of dorsiflexion and inversion, and sensory disturbance would be on the outer border of the shin. Reflexes would be unaffected.

E	Lumbar segment anterior horn cells

Audio Video Stop Share Participants 4 More

2:01
https://mypastest.paste

This would cause weakness of dorsiflexion and eversion only with sensory disturbance of the outer lower leg and dorsum of the foot. The ankle jerk would not be affected.

C	L5 root lesion

This would cause weakness of dorsiflexion and inversion, and sensory disturbance would be on the outer border of the shin. Reflexes would be unaffected.

E	Lumbar segment anterior horn cells

A disease affecting only anterior horn cells will have no sensory features.

7192

Rate this question:

Audio Video Stop Share Participants 4 More

2:01
https://mypastest.paste:

An 18-year-old man is assessed in the resuscitation suite. He presented with sudden onset headache and collapse. Emergency computerised tomography (CT) brain confirms subarachnoid blood.

On general examination, you note meningism. He does not respond to his name. On applying a painful stimulus, he lets out a cry, opens his eyes and displays an abnormal flexion response. Pupils are midline and reactive. Plantars bilaterally upgoing.

As you are writing up some notes at the end of the physical examination, you notice that he is moaning. On painful stimulus, he opens his eyes to pain and localises with his right arm. You discuss with the on call neurosurgical team, who ask about his present Glasgow Coma Score.

What is this patient's Glasgow Coma Scale (GCS) at the time you are

Audio Video Stop Share Participants 4 More

2:01
https://mypastest.paste

you notice that he is moaning. On painful stimulus, he opens his eyes to pain and localises with his right arm. You discuss with the on call neurosurgical team, who ask about his present Glasgow Coma Score.

What is this patient's Glasgow Coma Scale (GCS) at the time you are discussing with the neurosurgeons?

A	11
B	9
C	7
D	10
E	GCS measurement is not appropriate

Audio Video Stop Share Participants 4 More

2:04
https://mypastest.paste

On general examination, you note meningism. He does not respond to his name. On applying a painful stimulus, he lets out a cry, opens his eyes and displays an abnormal flexion response. Pupils are midline and reactive. Plantars bilaterally upgoing.

As you are writing up some notes at the end of the physical examination, you notice that he is moaning. On painful stimulus, he opens his eyes to pain and localises with his right arm. You discuss with the on call neurosurgical team, who ask about his present Glasgow Coma Score.

What is this patient's Glasgow Coma Scale (GCS) at the time you are discussing with the neurosurgeons?

Your answer was incorrect

A 11

Audio Video Stop Share Participants 4 More

2:04
https://mypastest.paste

B 9

Calculating the GCS can be seen in the table below. In this patient, at the time of discussion with the neurosurgeons, the best eye-opening is to pain (2), best motor response is localisation to pain (5) and best verbal response is incomprehensible sounds (2).

C 7

The correct formulation of a GCS is outlined in the table

A 11

The correct formulation of a GCS is outlined in the table

D 10

Audio Video Stop Share Participants 4 More

2:04
https://mypastest.paste

The Glasgow Coma Scale (GCS) was developed in 1974 as an aide to assessment of the head-injured patient. It is now used to define level of coma in any patient and is widely understood.

Glasgow Coma Scale		
Eye opening	Spontaneously	4
	To speech	3
	To pain	2
	No response	1
Verbal response	Orientated	5
	Confused	4
	Inappropriate words	3
	Incomprehensible	

Audio Video Stop Share Participants 4 More

2:05
https://mypastest.paste:

	Confused	4
Verbal response	Inappropriate words	3
	Incomprehensible sounds	2
	No response	1
Motor response	Obeys commands	6
	Localises to pain	5
	Flexion withdrawal from pain	4
	Abnormal flexion (decorticate)	3
	Abnormal extension (decerebrate)	2
	No response	1

Audio Video Stop Share Participants 4 More

A 34-year-old woman presents to the Emergency Department with left-sided weakness. This began suddenly the previous day during an argument with her husband. There is no associated headache, speech or swallowing symptoms. She has a history of irritable bowel syndrome and chronic pelvic pain, for which multiple diagnostic interventions have failed to find a cause.

In addition, she has presented to the Emergency Department twice previously with atypical chest pain for which no diagnosis was made. She also suffers from migraine and describes her recent headaches as being heralded by difficulty seeing in the centre of her vision. This has only happened since she started the combined oral contraceptive pill 6 months ago.

She takes codeine and paracetamol for her pelvic pain.

On examination, she appears well. Her BP is 142/82 mmHg, with pulse is 84 bpm and regular. There are no cranial

BP is 142/82 mmHg, with pulse is 84 bpm and regular. There are no cranial nerve abnormalities. Fundoscopy is normal and there are no visual field defects. Tone is normal in all four limbs. Power testing reveals weakness in the left arm and leg, but there is some variability. In particular it is noticed that she is able to walk into the cubicle but on formal testing has difficulty lifting her leg against gravity. Reflexes are brisk throughout, with equivocal plantars but no ankle clonus. Sensory examination shows some subjective decrease in soft touch on the left side. There is a positive Hoover's sign. An MRI scan is arranged, and this is normal.

Choose the most important step in her management

A	Psychiatric assessment and counselling
B	Doppler ultrasound of the neck

lifting her leg against gravity. Reflexes are brisk throughout, with equivocal plantars but no ankle clonus. Sensory examination shows some subjective decrease in soft touch on the left side. There is a positive Hoover's sign. An MRI scan is arranged, and this is normal.

Choose the most important step in her management

A	Psychiatric assessment and counselling
B	Doppler ultrasound of the neck
C	Consider cessation of the oral contraceptive pill
D	Commencement of antidepressant therapy
E	Ophthalmological assessment

suffers from migraine and describes her recent headaches as being heralded by difficulty seeing in the centre of her vision. This has only happened since she started the combined oral contraceptive pill 6 months ago.

She takes codeine and paracetamol for her pelvic pain.

On examination, she appears well. Her BP is 142/82 mmHg, with pulse is 84 bpm and regular. There are no cranial nerve abnormalities. Fundoscopy is normal and there are no visual field defects. Tone is normal in all four limbs. Power testing reveals weakness in the left arm and leg, but there is some variability. In particular it is noticed that she is able to walk into the cubicle but on formal testing has difficulty lifting her leg against gravity. Reflexes are brisk throughout, with equivocal plantars but no ankle clonus. Sensory examination shows some subjective decrease in soft touch on the left side. There is a positive Hoover's sign. An MRI scan is arranged, and this is normal

C Consider cessation of the oral contraceptive pill

The history and examination findings suggest that the current presentation is due to functional neurological disorder. This should be explained to the patient and she could be signposted to sources of useful information (see below). However, there is also clearly a history of migraine with aura that has worsened since she has been on the OCP. In patients with migraine plus aura there is an increased risk of stroke if they use the OCP, so it ought to be avoided.

A Psychiatric assessment and counselling

There is no evidence of a psychiatric condition here. She has presented with functional neurological disorder and may also have previous 'medically unexplained symptoms'. Rather than seeking a psychiatric explanation, it would be better to educate the patient as to how factors such as stress, pain

as to how factors such as stress, pain and other psychological issues can produce physical symptoms. When patients recognise this, they are more likely to be able to manage their symptoms.

B	Doppler ultrasound of the neck

This is an appropriate investigation after stroke or TIA, but there is no evidence of that here.

D	Commencement of antidepressant therapy

There are no features in this case to suggest the presence of a depressive illness that requires pharmacological treatment. Some patients with functional neurological disorder have concomitant affective disorder, in which case it should be treated appropriately.

E	Ophthalmological assessment

A previously fit and well 65-year-old man is brought to the general practitioner (GP) by his wife, who is concerned that his mood, behaviour and mental state have deteriorated over the last 6 months.

Recently, he has been seeing imaginary people in the garden who he says talk to him, saying 'bad things'. His memory has deteriorated and he feels low in mood. His handwriting is now smaller than it used to be. Over the last few months, he has had difficulty in walking.

On examination, he has a mask-like facial appearance, cog-wheel rigidity and difficulty initiating walking. Mini-mental state testing reveals impairment of short-term memory. A handwriting sample confirms micrographia. His blood pressure is 130/70 mmHg lying, 100/60 mmHg standing.

Investigations:

Hb	13.5 g/dl (135–180)
WCC	5.2 × 10^9/l (4–11)

Hb	13.5 g/dl (130–180)
WCC	5.2 × 10^9/l (4–11)
PLT	290 × 10^9/l (150–400)
Na^+	138 mmol/l (136–145)
K^+	4.8 mmol/l (3.5–5.0)
Creatinine	130 μmol/l (80–130)

Magnetic resonance imaging (MRI) of the brain reveals mild generalised atrophy.

Which of the following is the most likely diagnosis?

A	Alzheimer's disease
B	Frontotemporal dementia
C	Vascular dementia
D	Parkinson's disease
E	Lewy body dementia

E Lewy body dementia

The symptoms and signs seen here are suggestive of Lewy body dementia. Hallucinations (usually detailed, well-formed, visual), parkinsonian motor features, mood disorder, delusions and postural hypotension are all features of Lewy body dementia. Tremor is often less prevalent than in patients with idiopathic Parkinson's disease.

A Alzheimer's disease

Visual hallucinations are rarely a presenting feature of Alzheimer's disease. A progressive deterioration in memory and sleep disturbance is more common.

B Frontotemporal dementia

Frontotemporal dementia presents initially with changes in personality that may include inappropriate sexual behaviour, inability to concentrate and features of mood disturbance.

Frontotemporal dementia presents initially with changes in personality that may include inappropriate sexual behaviour, inability to concentrate and features of mood disturbance.

C Vascular dementia

There are no features on the MRI scan to suggest vascular dementia; there is usually a stepwise deterioration in cognitive function, and vascular risk factors are largely absent from the scenario.

D Parkinson's disease

Memory impairment/dementia occurs at a late stage in Parkinson's disease. At the onset of Parkinson's, visual hallucinations are less common and tremor is more prevalent than in the scenario here.

18642

Rate this question:

An intravenous (IV) drug abuser sustains an open head injury and is admitted overnight for observation. The next morning she appears to have recovered and is discharged. A week later, she is re-admitted with fluctuating hard neurological signs.

Blood results show neutrophilia and raised C-reactive protein (CRP). Fundoscopy reveals bilateral papilloedema and bilateral extensor plantar responses. There is erythema and evidence of frank pus over the original left-sided scalp wound. She is mildly confused.

Which of the following is the most appropriate initial step given this clinical picture?

A	Lumbar puncture
B	Computed tomography (CT) scan with contrast
C	IV amphotericin B

fluctuating hard neurological signs.

Blood results show neutrophilia and raised C-reactive protein (CRP). Fundoscopy reveals bilateral papilloedema and bilateral extensor plantar responses. There is erythema and evidence of frank pus over the original left-sided scalp wound. She is mildly confused.

Which of the following is the most appropriate initial step given this clinical picture?

A	Lumbar puncture
B	Computed tomography (CT) scan with contrast
C	IV amphotericin B
D	IV aciclovir
E	IV dexamethasone

9:17
tps://mypastest.pastest.com
14

An intravenous (IV) drug abuser sustains an open head injury and is admitted overnight for observation. The next morning she appears to have recovered and is discharged. A week later, she is re-admitted with fluctuating hard neurological signs.

Blood results show neutrophilia and raised C-reactive protein (CRP). Fundoscopy reveals bilateral papilloedema and bilateral extensor plantar responses. There is erythema and evidence of frank pus over the original left-sided scalp wound. She is mildly confused.

Which of the following is the most appropriate initial step given this clinical picture?

Your answer was incorrect

A Lumbar puncture

B Computed tomography (CT) scan with contrast

The raised white blood cell count and CRP are clearly suggestive of infection, and the fluctuating neurological signs are suggestive of an expanding cerebral mass such as an abscess or haematoma. For this reason, the initial treatment step of choice is CT scan with contrast, which must be carried out before consideration of lumbar puncture. If an abscess is demonstrated on CT scan, then neurosurgical review should be obtained. The patient would also need broad-spectrum IV antibiotic therapy (following blood cultures), as a bacterial cause is by far the most likely source of central nervous system (CNS) infection here. Staphylococci are particularly associated with post-traumatic cases of intra-cranial infection, but many possible causal organisms exist.

A Lumbar puncture

Lumbar puncture should not be performed without a CT scan, given the findings on fundoscopy. Against a background of an intracerebral abscess, it is likely to reveal a CSF neutrophilia with elevated CSF protein.

C	IV amphotericin B

A bacterial abscess is much more likely than CNS fungal infection, and amphotericin B is therefore unlikely to be effective here.

D	IV aciclovir

Herpes encephalitis is suggested by a gradual decrease in conscious level and progressive short-term memory loss.

E	IV dexamethasone

Although corticosteroids may be of value in reducing cerebral oedema, it would be important to look for evidence of intracerebral abscess and

A 57-year-old man presents with slowly worsening walking over the last few years. He has become increasingly slower in his walking and has particular difficulty turning around. In the last 2 years he has developed shaking of his right hand and he has difficulty doing his buttons up on his shirt.

On neurological examination, he is hypomimic with a hypophonic voice, and he has a resting tremor prominent on the right side. He has increased tone with cogwheeling that is greater in the right arm than the left. He also has difficulty with fine finger movements on the right side. He has a stooped gait with decreased arm swing. The rest of his neurological examination is normal.

Which of these drugs would be the most effective initial treatment for this patient?

A	Levodopa
B	Entacapone

and he has a resting tremor prominent on the right side. He has increased tone with cogwheeling that is greater in the right arm than the left. He also has difficulty with fine finger movements on the right side. He has a stooped gait with decreased arm swing. The rest of his neurological examination is normal.

Which of these drugs would be the most effective initial treatment for this patient?

A	Levodopa
B	Entacapone
C	Selegiline
D	Benzhexol
E	Propranolol

A 57-year-old man presents with slowly worsening walking over the last few years. He has become increasingly slower in his walking and has particular difficulty turning around. In the last 2 years he has developed shaking of his right hand and he has difficulty doing his buttons up on his shirt.

On neurological examination, he is hypomimic with a hypophonic voice, and he has a resting tremor prominent on the right side. He has increased tone with cogwheeling that is greater in the right arm than the left. He also has difficulty with fine finger movements on the right side. He has a stooped gait with decreased arm swing. The rest of his neurological examination is normal.

Which of these drugs would be the most effective initial treatment for this patient?

Your answer was correct

A Levodopa

The most likely diagnosis in this gentleman's case is idiopathic Parkinson's disease, exhibiting the classical triad of rigidity, bradykinesia and tremor. Levodopa is the most effective treatment in terms of controlling the motor symptoms. Levodopa is, however, associated with an earlier development of motor fluctuations compared to dopamine agonists. The disadvantage of dopamine agonists is that they are less effective in controlling motor symptoms and are more likely to cause side effects such as impulse control disorder and daytime sleepiness. Thus patient involvement in treatment decision-making is crucial in Parkinson's disease management.

B Entacapone

This is a catechol-O-methyltransferase (COMT) inhibitor and can be added to levodopa to try and reduce motor fluctuations. It is not a first-line

C Selegiline

This is a monoamine oxidase B (MOAB) inhibitor with only modest ability to relieve motor symptoms. For some patients early in the disease course, with mild symptoms, it can be a useful first drug. It can also be added later to try and relieve motor fluctuations, with levodopa.

D Benzhexol

This is an old anticholinergic drug that is now rarely used. It has some modest benefit in treating the tremor of Parkinson's disease.

E Propranolol

Beta-blockers are rarely effective in managing the tremor of Parkinson's disease, although they can be useful in treating essential tremor.

6243

Rate this question:

A 58-year-old man is brought to the Neurology outpatient clinic by his daughter. She is extremely concerned and he has been displaying some very odd behaviour and has had some weakness in his lower limbs.

She reports that about a year ago she and her family noticed that their father's business was beginning to lose money as he had become unable to manage his finances. They had also had complaints from staff who felt their father's behaviour to clients was often rude and disinhibited, laughing or crying at inappropriate times. He had developed a 'sweet tooth' and would hoard such items, eating little else. The daughter reported that over the last few weeks she had noticed her father's speech sounded different and he had difficulty getting out of his chair.

He had previously been fit and well, with no past medical history and took no medications.

On examination, the patient's speech has a nasal quality and he has an

has a nasal quality and he has an impaired swallow with tongue fasciculations. The remainder of the cranial nerve examination is normal and there is no papilloedema. He has proximal limb weakness of 4/5 bilaterally and fasciculations of his left quadriceps. His reflexes are brisk. His sensory exam is normal. His mini-mental state examination (MMSE) scores 28/30, with some subtle word-finding difficulties.

What is the most likely diagnosis?

A	Frontotemporal dementia (FTD)
B	Alzheimer's disease
C	FTD-MND
D	Motor neurone disease (MND)
E	Progressive supranuclear palsy (PSP)

money as he had become unable to manage his finances. They had also had complaints from staff who felt their father's behaviour to clients was often rude and disinhibited, laughing or crying at inappropriate times. He had developed a 'sweet tooth' and would hoard such items, eating little else. The daughter reported that over the last few weeks she had noticed her father's speech sounded different and he had difficulty getting out of his chair.

He had previously been fit and well, with no past medical history and took no medications.

On examination, the patient's speech has a nasal quality and he has an impaired swallow with tongue fasciculations. The remainder of the cranial nerve examination is normal and there is no papilloedema. He has proximal limb weakness of 4/5 bilaterally and fasciculations of his left quadriceps. His reflexes are brisk. His sensory exam is normal. His mini-mental state examination (MMSE) scores 28/30, with some subtle word

C FTD-MND

The frontotemporal dementias (FTD) are a group of clinically and neuropathologically heterogeneous neurodegenerative disorders characterized by prominent changes in social behaviour and personality or aphasia accompanied by degeneration of the frontal and/or temporal lobes. Some patients with FTD also develop concomitant motor neurone disease, like this man is demonstrating. Likewise some patients with classical MND develop FTD. In FTD, memory is often less severely affected than in Alzheimer's and performance on MMSE is often surprisingly high; a detailed behavioural and cognitive history taken from an informant (patients typically lack insight) is required to make the diagnosis. Neuroimaging with MRI or CT may show focal atrophy of the frontal and temporal lobes, but these are not diagnostic tests. MND can be confirmed using EMG in the usual manner. There is often a hereditary trait to FTD, with 10-

often a hereditary trait to FTD, with 10-25% showing autosomal dominant inheritance. Hexanucleotide expansions in the C9ORF72 gene are especially associated with FTD-MND.

A	Frontotemporal dementia (FTD)

Whilst this patient does have features of FTD, one needs to account for the motor signs so FTD-MND is a more accurate diagnosis.

B	Alzheimer's disease

This will usually present with memory symptoms, but prominent behavioural and emotional changes are rare. In addition, there is no link with MND.

D	Motor neurone disease (MND)

Whilst the patient has clinical features to support this diagnosis, the cognitive and behavioural aspects must be accounted for, so FTD-MND is a more

This will usually present with memory symptoms, but prominent behavioural and emotional changes are rare. In addition, there is no link with MND.

D	Motor neurone disease (MND)

Whilst the patient has clinical features to support this diagnosis, the cognitive and behavioural aspects must be accounted for, so FTD-MND is a more accurate diagnosis.

E	Progressive supranuclear palsy (PSP)

PSP is characterised by a vertical supranuclear gaze palsy, parkinsonism, decreased balance and early falls. Behavioural changes are seen, but features of MND would not be present in PSP.

9396

Rate this question:

A 72-year-old man with a long history of visual problems due to bilateral glaucoma is brought by his daughter to the GP. She is concerned as he has become very stubborn and is telling her that he is seeing colours and patterns on the wallpaper which are not actually there, and even says that he sees birds and buildings out of the window. He has had no other significant past medical history, but admits to drinking a glass of whisky per night.

On examination, his BP is 134/82 mmHg, his pulse is 68 bpm and there is atrial fibrillation. Visual acuity testing reveals that he is blind, and his mini-mental state testing is normal.

Which of the following is the most likely diagnosis?

A	Frontotemporal dementia
B	Charles Bonnet syndrome
C	Korsakoff's psychosis

not actually there, and even says that he sees birds and buildings out of the window. He has had no other significant past medical history, but admits to drinking a glass of whisky per night.

On examination, his BP is 134/82 mmHg, his pulse is 68 bpm and there is atrial fibrillation. Visual acuity testing reveals that he is blind, and his mini-mental state testing is normal.

Which of the following is the most likely diagnosis?

A	Frontotemporal dementia
B	Charles Bonnet syndrome
C	Korsakoff's psychosis
D	Alzheimer's disease
E	Multi-infarct dementia

B Charles Bonnet syndrome

This condition is described as visual hallucinations in a patient with a profound visual deficit. Normally the visual hallucinations subside after 12–18 months, and there is no specific treatment required. Often patients are insistent that they are able to see the objects concerned, although screening with a mini-mental state test for dementia is normal.

A Frontotemporal dementia

Frontotemporal dementia is associated with slowly progressive personality and behaviour changes (apathy, disinhibition, stereotyped behaviours), but visual hallucinations are rare.

C Korsakoff's psychosis

Korsakoff's occurs due to thiamine deficiency and is predominantly associated with short-term memory loss and confabulation.

C Korsakoff's psychosis

Korsakoff's occurs due to thiamine deficiency and is predominantly associated with short-term memory loss and confabulation.

D Alzheimer's disease

Alzheimer's is associated with progressive memory loss with other cortical deficits such as aphasia, apraxia and visuospatial impairment. Visual hallucinations are not a prominent feature.

E Multi-infarct dementia

Multi-infarct dementia is associated with a history of vascular disease, and deterioration in higher mental function occurs in stepwise fashion.

20590

Rate this question:

A 58-year-old man presents to the Emergency Department with pain and paraesthesia over the left side of his buttock, radiating down the posterolateral aspect of his left thigh to the dorsum of his foot. There is associated sensory loss to light touch over the dorsum of his foot and the anterolateral aspect of his leg. He notes mild weakness in his knee flexion and dorsiflexion of his left foot and toes. His deep tendon reflexes are normal.

What is the cause of his symptoms?

A	Sciatic nerve palsy
B	L4 radiculopathy
C	Peroneal nerve palsy
D	L5 radiculopathy
E	S1 radiculopathy

9:55
tps://mypastest.pastest.com 14

A 58-year-old man presents to the Emergency Department with pain and paraesthesia over the left side of his buttock, radiating down the posterolateral aspect of his left thigh to the dorsum of his foot. There is associated sensory loss to light touch over the dorsum of his foot and the anterolateral aspect of his leg. He notes mild weakness in his knee flexion and dorsiflexion of his left foot and toes. His deep tendon reflexes are normal.

What is the cause of his symptoms?

Your answer was incorrect

A Sciatic nerve palsy

B L4 radiculopathy

D L5 radiculopathy

L5 lesions result in weakness of the hamstrings, peroneus longus and the extensors of all toes and pain/paraesthesia over the buttock, posterolateral thigh, anterolateral leg and dorsum of the foot. It does not affect any tendon reflexes. The most common cause of lumbar radiculopathy in younger patients is disc herniation causing nerve root compression which may result from heavy lifting. The correct answer is L5 radiculopathy because of the pattern of symptoms and signs described.

A Sciatic nerve palsy

Sciatic nerve palsy is incorrect. A sciatic nerve palsy would result in a foot drop.

B L4 radiculopathy

L4 radiculopathy is incorrect because lesions of L4 result in diminished knee

L4 radiculopathy is incorrect because lesions of L4 result in diminished knee jerk and weak quadriceps, tibialis anterior and tibialis posterior. There will also be pain/paraesthesia and sensory loss over the anteromedial aspect of the leg.

C	Peroneal nerve palsy

Peroneal nerve palsy is incorrect because this would result in a foot drop.

E	S1 radiculopathy

S1 radiculopathy is incorrect because lesions of S1 result in diminished ankle jerk and weak plantar flexors, extensor digitorum brevis, peroneus longus and hamstrings. There will also be pain/paraesthesia over the buttock, back of thigh, calf, lateral border of the foot and sensory disturbance over the lateral border of the foot and the anteromedial aspect of the leg.

An 88-year-old woman presents to the Medical Outpatient Department for assessment. She describes episodic loss of consciousness, which is increasing in frequency. Attacks are stereotyped and consist of a feeling of lightheadedness followed by collapse to the ground. Attacks are always on standing and she has had to attend the Accident and Emergency Department on several occasions with lacerations and bruising from the falls. She believes loss of consciousness is for seconds only and does not occur with all attacks. She has been incontinent of urine on at least one occasion, but otherwise feels well after the attacks. There are no witnesses at the consultation to provide a collateral history. She has no past medical history and is no regular medication.

Her general practitioner has already organised some tests:

Ambulatory electrocardiogram (ECG) monitor	Sinus rhythm throughout

Electroencephalogram (EEG)	Runs of 8–12 cycles/s potentials, most marked over the occipital cortex

Given the EEG findings, she has been commenced on oral phenytoin. This has had no effect on the attack frequency or severity.

What further investigation would you request to elucidate the cause of her falls?

A	CSF examination
B	CT brain
C	Serum phenytoin levels
D	Tilt-table testing
E	Serum glucose after 48 h fast

D Tilt-table testing

This scenario highlights the dangers of inappropriate use of the electroencephalogram (EEG). The clinical history is suggestive of postural hypotension with occasional syncope. Urinary incontinence and brief limb movements are common in syncope and do not suggest generalised seizure (faecal incontinence is more specific for generalised seizures). There are no other features in the history to suggest epileptogenic attacks, e.g. post-event headache, confusion, muscle pain or damage to the oral mucosa. The EEG findings described are normal. Even an 'abnormal' EEG, such as spike and slow-wave complexes, would not diagnose epilepsy in this patient, as such changes are found in 0.5% of the 'normal' population. Diagnosis of postural hypotension can be made in the clinic by measuring lying and standing blood pressures, and looking for a >10 mmHg deficit accompanied by symptoms. Tilt-table testing allows any cause of neurocardiogenic

any cause of neurocardiogenic syncope to be better characterised. Principle management of postural hypotension involves searching for a cause – most often iatrogenic, but occasionally pathology such as adrenal insufficiency is discovered. Therapy consists of compression stockings and advice on slow rising. If drug therapy is needed, fludrocortisone is used first line.

A	CSF examination

CSF examination is not indicated, given that this lady appears to be suffering from multiple syncopal episodes. CSF examination would be indicated were there evidence to support a subarachnoid haemorrhage, or other chronic symptoms consistent with dementia.

B	CT brain

CT brain would be indicated in the event there was fluctuating

chronic symptoms consistent with dementia.

B	CT brain

CT brain would be indicated in the event there was fluctuating consciousness or focal neurological deficit to suggest subdural haematoma.

C	Serum phenytoin levels

There is no history of previous epilepsy, nor phenytoin use, to suggest toxicity as the underlying cause for her symptoms.

E	Serum glucose after 48 h fast

Symptoms of sympathetic activation, such as sweating, tachycardia and anxiety, would be expected if hypoglycaemia were the cause of these episodes.

7365

Rate this question:

An 18-year-old female patient was brought to the Emergency Department by her mother for the evaluation of episodic unawareness that had troubled her for the past couple of years. During the spells, she would stare and would seem stupefied. She could also have some fluttering of her eyelids. The episode would end in few minutes; and she would be normal again.

However, for the past 12 months she had also been experiencing a few sudden shock-like contractions of her limbs, in the early morning. These features were intriguing for the family. A day before the present consultation, she lost consciousness for the first time and had jerky movements of the limbs that continued for a couple of minutes.

There was no family history of note.

Choose the most likely diagnosis

A	Variant Creutzfeldt–Jakob disease

However, for the past 12 months she had also been experiencing a few sudden shock-like contractions of her limbs, in the early morning. These features were intriguing for the family. A day before the present consultation, she lost consciousness for the first time and had jerky movements of the limbs that continued for a couple of minutes.

There was no family history of note.

Choose the most likely diagnosis

A	Variant Creutzfeldt–Jakob disease
B	Subacute sclerosing panencephalitis
C	Juvenile myoclonic epilepsy
D	Rasmussen encephalitis
E	Non-epileptic attack disorder

An 18-year-old female patient was brought to the Emergency Department by her mother for the evaluation of episodic unawareness that had troubled her for the past couple of years. During the spells, she would stare and would seem stupefied. She could also have some fluttering of her eyelids. The episode would end in few minutes; and she would be normal again.

However, for the past 12 months she had also been experiencing a few sudden shock-like contractions of her limbs, in the early morning. These features were intriguing for the family. A day before the present consultation, she lost consciousness for the first time and had jerky movements of the limbs that continued for a couple of minutes.

There was no family history of note.

Choose the most likely diagnosis

Your answer was correct

C Juvenile myoclonic epilepsy

Juvenile myoclonic epilepsy (JME) is the most common form of idiopathic generalised epilepsy in young adults. The patient seeks medical attention because of generalized seizures, often after awakening or because of myoclonic jerks in the morning involving the entire body. Sometimes absence seizures are prominent, as in this patient.

Electroencephalogram (EEG) characteristically shows 4–6 Hz irregular poly-spike and slow wave activity. Intelligence remains unimpaired and the disorder tends not to be progressive. Sodium valproate, lamotrigine and levetiracetam are all useful drugs (but valproate should be avoided in women of childbearing age. Medication should be continued indefinitely.

A Variant Creutzfeldt–Jakob disease

This is a very rare disease that historically occurred due to ingestion of beef infected with bovine spongiform encephalopathy, or iatrogenically from products such as human-derived growth hormone. There have been no new cases in recent years. The illness is characterised by rapidly progressive dementia, myoclonus and ataxia.

B	Subacute sclerosing panencephalitis

This is a progressive and usually fatal condition related to measles infection in childhood. It is characterised by encephalopathy, myoclonus, a movement disorder and eventually coma. Characteristic periodic complexes are seen on EEG.

D	Rasmussen encephalitis

This is a rare inflammatory brain disease of unknown aetiology. It typically affects one hemisphere and results in seizures (often epilepsy

complexes are seen on EEG.

D	Rasmussen encephalitis

This is a rare inflammatory brain disease of unknown aetiology. It typically affects one hemisphere and results in seizures (often epilepsy partialis continua) and progressive hemiparesis.

E	Non-epileptic attack disorder

The features described in this case are consistent with absence seizures, myoclonus and a probable generalised tonic-clonic seizure, making JME highly likely. NEAD is a psychologically mediated disorder with attacks that can look somewhat like generalised epileptic seizures. Several features suggest that an attack may be non-epileptic – back arching, pelvic thrusting, side-to-side head movement, waxing and waning shaking and prolonged spells of pseudo-sleep are all seen in NEAD.

A 55-year-old gentleman is referred to a neurologist with a 5-day history of flu-like symptoms, diplopia and facial weakness. He complains of diplopia, worse on left lateral gaze, but has also noticed a tilting of the print while reading a newspaper. He cannot fully close his eye on the left side and has noticed a similar problem with his right eye. He is a diet-controlled diabetic, but has no other medical history.

He is on no regular medication, and came back four weeks ago from a camping holiday in New England, USA with his wife.

On examination he is alert and orientated. His temperature is 37.2 ºC, blood pressure 140/85 mmHg, pulse 85/min and blood glucose monitoring level 5.2 g/dl. No rash is found. There is mild neck stiffness. Fundoscopy is normal, and pupils are equal and reactive to light. There is oculoparesis affecting the left eye with weak abduction and depression of the eye. There is also evidence of bilateral facial weakness and bilateral Bell's phenomena, and an area of

phenomena, and an area of anaesthesia over the left cheek. The remaining nervous system examination is normal, but he complains of arthralgia in his left knee on testing knee flexion. Magnetic resonance scan of the brain is normal.

Lumbar puncture reveals:

Opening pressure	14 cmH_2O (8–15)
CSF protein	1.1 g/l (0.15–0.45 g/l)
CSF WBC count	90 cells/ml (80% lymphocytes) (0–5)
CSF glucose	3.6 mmol/l (3.3–4.4)

Plasma glucose is 5.5 mmol/l (3.0-6.0).

What is the likely diagnosis for this patient pending further investigations?

A	Multiple sclerosis

protein	1.1 g/l (0.15–0.45 g/l)
CSF WBC count	90 cells/ml (80% lymphocytes) (0–5)
CSF glucose	3.6 mmol/l (3.3–4.4)

Plasma glucose is 5.5 mmol/l (3.0-6.0).

What is the likely diagnosis for this patient pending further investigations?

A	Multiple sclerosis
B	Guillain–Barré syndrome
C	Whipple's disease
D	Neuroborreliosis (Lyme disease)
E	Diabetes-related mononeuritis multiplex

85/min and blood glucose monitoring level 5.2 g/dl. No rash is found. There is mild neck stiffness. Fundoscopy is normal, and pupils are equal and reactive to light. There is oculoparesis affecting the left eye with weak abduction and depression of the eye. There is also evidence of bilateral facial weakness and bilateral Bell's phenomena, and an area of anaesthesia over the left cheek. The remaining nervous system examination is normal, but he complains of arthralgia in his left knee on testing knee flexion. Magnetic resonance scan of the brain is normal.

Lumbar puncture reveals:

Opening pressure	14 cmH_2O (8–15)
CSF protein	1.1 g/l (0.15–0.45 g/l)
CSF WBC count	90 cells/ml (80% lymphocytes) (0–5)
CSF glucose	3.6 mmol/l (3.3–4.4)

D	Neuroborreliosis (Lyme disease)

This gentleman presents with cranial mononeuritis multiplex involving left IV, V, VI, VII and right VII nerves. He also presents with features of a flu-like illness and arthralgia. His lumbar puncture reveals a lymphocytic pleocytosis and raised protein. Considering all the facts, in a patient who has recently returned from a camping holiday in New England, neuroborreliosis (Lyme disease) should be suspected. Most patients present in the early phase of the illness with a characteristically expanding rash (i.e. erythema chronicum migrans) caused by a tick bite; however, by 3–4 weeks post-bite the rash has faded and some patients are unaware of having been bitten in the first place.
Neuroborreliosis may present with meningitis, encephalitis, multiple cranial nerve palsies or radiculitis. Diagnosis is by Borrelia–Burgdorferi serological testing with enzyme-linked immunosorbent assay (ELISA) or immunofluorescence assay (IFA)

immunofluorescence assay (IFA).

A	Multiple sclerosis

MS rarely presents for the first time in a 55-year-old man. Multiple cranial nerve palsy is not typically seen in MS.

B	Guillain–Barré syndrome

GBS can occasionally present with prominent eye movement abnormalities (Miller-Fisher variant), but CSF would be acellular.

C	Whipple's disease

This is a very rare cause of neurological disease. It can present with a brainstem syndrome and patients may have a history of unexplained fever, diarrhoea and arthralgia. One would expect an abnormal MRI scan as it tends to cause parenchymal disease.

A 32-year-old farmer's wife was referred to the Neurology Clinic with a 3-month history of slurred speech.

She had noticed some clumsiness when preparing food in the kitchen and her handwriting had deteriorated; her husband reported that she had seemed depressed and 'not herself' over the past 6 months. Her only past history of note is an emergency caesarean section and blood transfusion at the birth of the couple's only child.

Examination revealed very poor short-term memory and a mini-mental state test of 22/30. She had evidence of cerebellar dysarthria with limb and gait ataxia.

EEG revealed diffuse bilateral independent slow (delta) wave activity but no periodic complexes.

What is the most likely diagnosis?

A	Sporadic CJD

caesarean section and blood transfusion at the birth of the couple's only child.

Examination revealed very poor short-term memory and a mini-mental state test of 22/30. She had evidence of cerebellar dysarthria with limb and gait ataxia.

EEG revealed diffuse bilateral independent slow (delta) wave activity but no periodic complexes.

What is the most likely diagnosis?

A	Sporadic CJD
B	New variant CJD
C	Frontotemporal dementia
D	Huntington's Chorea
E	Alzheimer's disease

A 32-year-old farmer's wife was referred to the Neurology Clinic with a 3-month history of slurred speech.

She had noticed some clumsiness when preparing food in the kitchen and her handwriting had deteriorated; her husband reported that she had seemed depressed and 'not herself' over the past 6 months. Her only past history of note is an emergency caesarean section and blood transfusion at the birth of the couple's only child.

Examination revealed very poor short-term memory and a mini-mental state test of 22/30. She had evidence of cerebellar dysarthria with limb and gait ataxia.

EEG revealed diffuse bilateral independent slow (delta) wave activity but no periodic complexes.

What is the most likely diagnosis?

Your answer was correct

B New variant CJD

This unfortunate woman has variant CJD (vCJD), which is most likely to have been acquired through eating infected meat. The early appearance of her psychiatric symptoms and general deterioration in her motor skills support this diagnosis. Met/Met homozygosity at codon 129 of the prion protein gene (40% of Caucasians) is associated with increased risk of infection.

No sex preponderance is seen and the disease is relentlessly progressive, mean duration from diagnosis to death being around 16 months. Patients are often misdiagnosed with depression during the early stages of the disease. Routine CSF studies are not useful in making the diagnosis, although studies of specific CJD markers may be helpful, as may MRI scanning.

A Sporadic CJD

This condition usually occurs in older

patients (50s–60s), which makes it less likely to be the correct option here, whereas vCJD occurs in younger patients. Periodic sharp and slow wave complexes are strongly supportive of sCJD when seen on EEG - in vCJD the EEG appearance may be more variable.

C	Frontotemporal dementia

Also known as Pick's disease, this condition usually occurs in older patients and leads to changes in behaviour such as increased anxiety and inappropriate behaviour rather than low mood. It also causes cognitive decline. It is associated with motor neurone disease, which can lead to physical symptoms.

D	Huntington's Chorea

This condition has an onset in early middle age with cognitive, behavioural and physical symptoms. A common symptom is a jerky chorea, which is absent in this lady. It is caused by a

decline. It is associated with motor neurone disease, which can lead to physical symptoms.

D	Huntington's Chorea

This condition has an onset in early middle age with cognitive, behavioural and physical symptoms. A common symptom is a jerky chorea, which is absent in this lady. It is caused by a CAG tri-nucleotide repeat mutation which is autosomal dominant and shows anticipation. This lady has no family history or characteristic chorea, and therefore this is a less likely diagnosis and an incorrect option.

E	Alzheimer's disease

This is extremely rare in younger patients, with cognitive and behavioural changes more commonly seen than physical signs - such as this lady has.

18551

Rate this question:

A 22-year-old woman presents to the Emergency Department after a single tonic–clonic seizure lasting 5 min, which was witnessed by her husband.

A computed tomography (CT) brain scan at the time is normal, as are her electrolytes, calcium and magnesium. As an outpatient she has a normal electroencephalogram (EEG) and a normal magnetic resonance imaging (MRI) brain scan. She decides not to start any anti-epileptic medication.

When is the next time that the patient could possibly drive?

A	Never
B	6 months
C	3 years
D	Now
E	1 year

10:35
tps://mypastest.pastest.com 14

A 22-year-old woman presents to the Emergency Department after a single tonic–clonic seizure lasting 5 min, which was witnessed by her husband.

A computed tomography (CT) brain scan at the time is normal, as are her electrolytes, calcium and magnesium. As an outpatient she has a normal electroencephalogram (EEG) and a normal magnetic resonance imaging (MRI) brain scan. She decides not to start any anti-epileptic medication.

When is the next time that the patient could possibly drive?

Your answer was correct

A Never

B 6 months

B 6 months

The Driver and Vehicle Licensing Agency (DVLA) guidelines say that a patient must have 6 months off from driving after a solitary unprovoked seizure, assuming they remain seizure free in that period.

A Never

After a solitary unprovoked seizure, people must inform the DVLA and generally have to refrain from driving for 6 months.

C 3 years

If a person has multiple seizures only while asleep, then they may drive after a 3-year period of only having seizures at night/while asleep.

D Now

After a solitary unprovoked seizure, people must inform the DVLA and

generally have to refrain from driving for 6 months.

C 3 years

If a person has multiple seizures only while asleep, then they may drive after a 3-year period of only having seizures at night/while asleep.

D Now

After a solitary unprovoked seizure, people must inform the DVLA and generally have to refrain from driving for 6 months.

E 1 year

In the case of multiple seizures, or epilepsy, a patient must be seizure free for one year, on or off medication, to be able to drive again.

6968

Rate this question:

A 68-year-old man is brought to the Accident and Emergency Department by his neighbour, who found him lying on the floor of his sitting room, unable to move. He is known to have non-insulin-dependent diabetes mellitus and ischaemic heart disease and takes multiple medications.

On examination, he is conscious and alert. His blood pressure is 190/100 mmHg, with a pulse of 85 bpm, irregular. He understands but cannot communicate except by blinking and vertical eye movements. He cannot swallow and has weakness of eye closure on both sides. There is a flaccid quadriplegia. Both plantar responses are extensor.

Investigations:

Hb	12.3 g/dl
WCC	9.9×10^9/l
PLT	201×10^9/l
Na^+	138 mmol/l
K^+	4.1 mmol/l

Hb	12.3 g/dl
WCC	9.9×10^9/l
PLT	201×10^9/l
Na^+	138 mmol/l
K^+	4.1 mmol/l
Creatinine	132 μmol/l
HbA1c	77.05 mmol/mol (9.2%)

What is the most likely diagnosis?

A	Guillain–Barré syndrome
B	Posterior inferior cerebellar artery occlusion
C	Herpes simplex encephalitis
D	Basilar artery occlusion
E	Left middle cerebral artery occlusion

Accident and Emergency Department by his neighbour, who found him lying on the floor of his sitting room, unable to move. He is known to have non-insulin-dependent diabetes mellitus and ischaemic heart disease and takes multiple medications.

On examination, he is conscious and alert. His blood pressure is 190/100 mmHg, with a pulse of 85 bpm, irregular. He understands but cannot communicate except by blinking and vertical eye movements. He cannot swallow and has weakness of eye closure on both sides. There is a flaccid quadriplegia. Both plantar responses are extensor.

Investigations:

Hb	12.3 g/dl
WCC	9.9×10^9/l
PLT	201×10^9/l
Na^+	138 mmol/l
K^+	4.1 mmol/l
Creatinine	132 μmol/l

D Basilar artery occlusion

The above scenario depicts a clinical state in which the patient is awake but is unable to respond in any way except by vertical gaze and blinking. This is consistent with 'locked-in syndrome' and is due to basilar artery occlusion. The lesion is in the ventral pons, and it essentially interrupts the corticobulbar and corticospinal pathways and spares the somatosensory pathways and the ascending neuronal functions responsible for arousal and wakefulness, as well as certain mid-brain elements that allow certain eye movements.

A Guillain–Barré syndrome

Whilst Guillain–Barré syndrome can cause flaccid quadriplegia, patients would still be able to speak. In addition, the up-going plantar reflexes clearly suggest upper motor neurone pathology.

B	Posterior inferior cerebellar artery occlusion

A stroke affecting this artery leads to lateral medullary syndrome (altered pain and temperature sensation on the ipsilateral face but contralateral body and limbs, dysarthria, dysphagia, ipsilateral limb ataxia and ipsilateral Horner syndrome.

C	Herpes simplex encephalitis

This illness can present with the patient being found in a collapsed state. However, there is usually a prodrome of headache, fever, confusion and seizures. The disease targets the temporal lobes and, if the left side is affected, aphasia may be present. The flaccid quadriplegia is not seen.

E	Left middle cerebral artery occlusion

Large hemispheric strokes caused by

C	Herpes simplex encephalitis

This illness can present with the patient being found in a collapsed state. However, there is usually a prodrome of headache, fever, confusion and seizures. The disease targets the temporal lobes and, if the left side is affected, aphasia may be present. The flaccid quadriplegia is not seen.

E	Left middle cerebral artery occlusion

Large hemispheric strokes caused by proximal occlusion of the MCA can result in reduced conscious level ('malignant MCA syndrome'), but the clinical signs would still reflect damage to a single hemisphere (i.e. hemiparesis) as opposed to the bilateral and symmetrical signs seen here.

32767

Rate this question:

A 20-year-old veterinary nurse is admitted to the Emergency Department with headache, pyrexia, and recent confusional state. She had been well two weeks ago when she had developed lymphadenopathy in her neck and swelling around the angle of the right jaw. Since then she has not been back to work and has become increasingly drowsy, confused and has been complaining of headache and photophobia. Prior to this, she had been playing with her 2-year-old nephew. Otherwise, she is fit and well and does not take any regular medication.

On examination, her temperature is 39.2 °C, blood pressure 110/75 mmHg and pulse 98/min. She appears flushed and confused and has marked generalised cervical lymphadenopathy with a herpetic cold sore on her lip. There is photophobia and some neck stiffness. Fundoscopy is normal. Examination of the peripheral nervous system reveals generalised hyper-reflexia and equivocal plantar responses. There appears to be some

tenderness within the epigastric area on palpation. Computerised tomography scan reveals no evidence of SAH (subarachnoid haemorrhage), intracerebral haemorrhage or space-occupying lesion.

Lumbar puncture CSF) reveals:

Opening pressure	18 cm H_2O (5–18)
Protein	0.48 g/l (0.15–0.45)
WCC	100 cells/ml (mononuclear cells) (=5)
Glucose	3.5 mmol/l (3.3–4.4)
RCC	2 cells/ml (<5)
Culture	-
Oligoclonal bands	-

Blood tests:

Hb	12.6 g/dl
WCC	11.7 × 10^9/l

Hb	12.6 g/dl
WCC	11.7×10^9/l
PLT	237×10^9/l
Na^+	132 mmol/l
K^+	4.2 mmol/l
Creatinine	98 μmol/l
Amylase	400 μmol/l (60–180)
Blood film	Lymphocytosis

Choose the most likely diagnosis

A	Lymphoma
B	Meningococcal meningitis
C	Herpes simplex encephalitis (HSE)
D	Mumps meningoencephalitis
E	toxoplasmosis

D Mumps meningoencephalitis

This patient presents with a history and clinical features suggestive of mumps meningoencephalitis. The clues here are lymphadenopathy and swelling around the angle of the jaw (parotid swelling) with developing meningitic features, headache and confusion 7–10 days later. The lumbar puncture reveals an aseptic meningitic picture with marginally raised protein, normal glucose and a monocytosis. There also appears to be some evidence for pancreatitis, with elevated amylase and epigastric pain.

A Lymphoma

This is unlikely given the rapid onset of symptoms and the high fever.

B Meningococcal meningitis

The time course is too protracted. The CSF would show higher protein, lower glucose and a marked neutrophil

B	Meningococcal meningitis

The time course is too protracted. The CSF would show higher protein, lower glucose and a marked neutrophil leucocytosis.

C	Herpes simplex encephalitis (HSE)

In herpes simplex encephalitis (HSE) one would have expected more temporal lobe features in the history, such as temporal lobe seizures, personality changes, psychotic behaviour or hallucinations. There would be an absence of lymphadenopathy and the pancreatic symptoms would be unexplained.

E	toxoplasmosis

This would have resulted in more focal signs with evidence of ring-enhancing lesions on computerised tomography imaging. It is unusual in people who are not immunocompromised.

A 32-year-old man presents to the Emergency Department with a severe headache which he describes as boring behind his right eye. He has been getting similar recurrent episodes over the past week, two or three times per day. Each episode lasts about an hour, and is associated with drooping of his right eye. He has even been awoken at 0300 h each night with severe episodes associated with what he describes as nasal stuffiness.

He has tried taking paracetamol, but with minimal improvement. He has no significant past medical history and does not take any regular medications, apart from the paracetamol. He does not smoke and denies recreational drug use. He drinks about 5 pints of lager per week. He works as a policeman.

On examination, he appears agitated. He is afebrile, and there is no meningism. He has some watering of his right eye which appears slightly erythematous, and there is a mild right ptosis. Clinical examination is otherwise unremarkable

does not take any regular medications, apart from the paracetamol. He does not smoke and denies recreational drug use. He drinks about 5 pints of lager per week. He works as a policeman.

On examination, he appears agitated. He is afebrile, and there is no meningism. He has some watering of his right eye which appears slightly erythematous, and there is a mild right ptosis. Clinical examination is otherwise unremarkable.

What treatment would be most effective at relieving his symptoms?

A	Amitriptyline
B	Verapamil
C	Propranolol
D	High-flow oxygen
E	Lithium

A 32-year-old man presents to the Emergency Department with a severe headache which he describes as boring behind his right eye. He has been getting similar recurrent episodes over the past week, two or three times per day. Each episode lasts about an hour, and is associated with drooping of his right eye. He has even been awoken at 0300 h each night with severe episodes associated with what he describes as nasal stuffiness.

He has tried taking paracetamol, but with minimal improvement. He has no significant past medical history and does not take any regular medications, apart from the paracetamol. He does not smoke and denies recreational drug use. He drinks about 5 pints of lager per week. He works as a policeman.

On examination, he appears agitated. He is afebrile, and there is no meningism. He has some watering of his right eye which appears slightly erythematous, and there is a mild right

D High-flow oxygen

This patient is suffering from cluster headache, an excruciating unilateral headache usually accompanied by conjunctival injection and lacrimation. Patients also commonly have ipsilateral ptosis, eyelid oedema, forehead and facial sweating and nasal congestion. There is a slight male preponderance, with male:female ratio 2.1:2.0. Patients have at least five attacks that may vary in frequency from one episode every other day to eight attacks per day. Episodes tend to last 15–180 minutes if untreated. Patients fearing an attack may be unable to go to sleep. Aetiology is unclear, but the basic pathophysiology is in the hypothalamic grey matter. High-dose oxygen and sumatriptan have been shown to be effective in the acute treatment of cluster headache. Sumatriptan is available as a subcutaneous injection (6 mg) or nasal spray (20 mg). Verapamil (120–160 mg orally tds) has been shown to be effective for prophylaxis.

A Amitriptyline

This drug can be used to treat migraine and tension-type headache (as prophylaxis), but it is not effective for cluster headache.

B Verapamil

This drug is effective as prophylaxis or long-term treatment for cluster headache, but it is not useful as an acute treatment.

C Propranolol

This is a good drug for migraine prophylaxis but it is not effective in managing cluster headache.

E Lithium

This drug can be used for prophylaxis in cluster headache if the patient is unable to tolerate verapamil, or it is ineffective. It is not used to treat acute attacks of cluster headache.

A 78-year-old woman is referred to the Elderly Care Clinic with frequent falls. She attended with her daughter, who reported that there had been a significant deterioration in her cognitive function, walking and handwriting during the past few months.

On examination, she has cogwheel rigidity, tremor and bradykinesia. There are additional cerebellar signs and a 30 mmHg drop in her blood pressure on standing.

Which diagnosis fits best with this clinical picture?

A	Parkinson's disease
B	Multiple system atrophy
C	Friedreich's ataxia
D	Fronto-temporal dementia
E	Multi-infarct dementia

A 78-year-old woman is referred to the Elderly Care Clinic with frequent falls. She attended with her daughter, who reported that there had been a significant deterioration in her cognitive function, walking and handwriting during the past few months.

On examination, she has cogwheel rigidity, tremor and bradykinesia. There are additional cerebellar signs and a 30 mmHg drop in her blood pressure on standing.

Which diagnosis fits best with this clinical picture?

Your answer was correct

A Parkinson's disease

B Multiple system atrophy

C Friedreich's ataxia

B Multiple system atrophy

There are a number of defined syndromes where there is parkinsonism and a number of other features. Progressive supranuclear palsy consists of parkinsonism, axial rigidity, falls, dementia and inability of lateral and upward gaze. Olivo-ponto-cerebellar degeneration involves parkinsonism and additional cerebellar signs. They are progressive and poorly responsive to dopamine agonist therapy and have a very high rate of mortality within 10 years of diagnosis.

In 1900, Dejerine and Thomas first introduced the term olivopontocerebellar atrophy (OPCA). Since then, the classification of idiopathic acquired ataxias has evolved a great deal. OPCA has not been proven to be a single entity. The nosology of these disorders has been extremely confusing, as the OPCAs overlap with spinocerebellar atrophies (SCAs) and multiple system atrophies (MSAs). Clinical distinction of these entities is based on the dominant

(MSAs). Clinical distinction of these entities is based on the dominant feature, which may be cerebellar ataxia (observed in OPCA, SCA and MSA), parkinsonism (observed in MSA) or autonomic failure (observed in MSA). The term OPCA has been retained to describe a form of progressive ataxia distinguished by pontine flattening and cerebellar atrophy on brain imaging studies and at autopsy. Thus defined, OPCA also may qualify either as an SCA or an MSA.

The autonomic symptoms (severity of orthostatic hypotension) count against pure Parkinson's disease here.

A	Parkinson's disease

Although the movement disorder as described here is supportive of a diagnosis of Parkinson's, the marked postural hypotension, suggestive of autonomic dysfunction, points us towards MSA as the alternative diagnosis.

towards MSA as the alternative diagnosis.

C	Friedreich's ataxia

Friedreich's ataxia does present with movement disorder and may be associated with postural hypotension, although it presents at a significantly younger age than that seen here.

D	Fronto-temporal dementia

Fronto-temporal dementia initially presents with emotional lability and disinhibition, rather than the features seen here.

E	Multi-infarct dementia

Multi-infarct dementia presents with a stepwise deterioration in executive function, potentially corresponding with discrete cerebral infarcts, against a background of risk factors for vascular disease.

A 32-year-old woman presents to the clinic for review. She has had progressively worsening headaches, with onset either last thing at night or on waking in the morning, for the past 6 months. She is worried that she may have a brain tumour. She takes the combined oral contraceptive pill to regulate her periods, but is otherwise well.

Her BP is 148/82 mmHg, with pulse 68 bpm and regular. She is overweight with a BMI of 33, but there are no other abnormal findings apart from moderate bilateral papilloedema. Routine bloods are unremarkable.

Which of the following is the most appropriate next step?

A	Amitriptyline
B	CT and CT venogram head
C	Lumbar puncture

combined oral contraceptive pill to regulate her periods, but is otherwise well.

Her BP is 148/82 mmHg, with pulse 68 bpm and regular. She is overweight with a BMI of 33, but there are no other abnormal findings apart from moderate bilateral papilloedema. Routine bloods are unremarkable.

Which of the following is the most appropriate next step?

A	Amitriptyline
B	CT and CT venogram head
C	Lumbar puncture
D	Propranolol
E	Reassurance

11:10
:tps://mypastest.pastest.com 14

A 32-year-old woman presents to the clinic for review. She has had progressively worsening headaches, with onset either last thing at night or on waking in the morning, for the past 6 months. She is worried that she may have a brain tumour. She takes the combined oral contraceptive pill to regulate her periods, but is otherwise well.

Her BP is 148/82 mmHg, with pulse 68 bpm and regular. She is overweight with a BMI of 33, but there are no other abnormal findings apart from moderate bilateral papilloedema. Routine bloods are unremarkable.

Which of the following is the most appropriate next step?

Your answer was correct

A	Amitriptyline

B CT and CT venogram head

New-onset progressive and early morning headaches are red flags and should always be investigated with cerebral imaging. As in this situation, the cause of raised intracranial pressure cannot easily be determined on clinical examination. The most likely causes would include a space-occupying lesion (primary or metastatic tumour or abscess), cerebral venous sinus thrombosis or idiopathic intracranial hypertension (IIH). Clearly, a space-occupying lesion and CVST should be ruled out urgently and hence CT/ CTV should be the first line of investigation.

The patient is the archetypal demographic for IIH: an overweight female of child-bearing age. Most patients present with postural headaches, transient visual obscurations and pulsatile tinnitus. Clinical examination will reveal papilloedema, potentially enlarged blind spot with impaired visual acuity

blind spot with impaired visual acuity and sometimes cranial nerve VI palsies. A diagnosis is made by demonstrating raised intracranial pressure on lumbar puncture (>25 cm CSF); often the patient will have instantaneous relief of their symptoms.

The major morbidity associated with IIH is visual loss (hence the change in name from benign intracranial hypertension), and therefore patients should have an ophthalmology review for regular retinal photography and visual field assessment. The most effective and enduring treatment is weight loss. Pharmacological therapy aims to reduce CSF production, such as with acetazolamide or topiramate. For patients with progressive visual loss, surgical intervention can be considered – optic nerve sheath fenestration and/ or CSF shunts.

A	Amitriptyline

Tricyclic antidepressants are often used in the prevention of migraine. Although migraine is common in this

Although migraine is common in this demographic, the patient presents with symptoms and signs of raised intracranial pressure and this should be investigated urgently.

C	Lumbar puncture

An LP will be needed to confirm the diagnosis of IIH in this patient. However, performing an LP in a patient with a space-occupying lesion could cause cerebellar tonsillar herniation and severe brainstem damage. Therefore cerebral imaging is an absolute indication in any patient with papilloedema prior to LP.

D	Propranolol

Propranolol is commonly used in migraine prevention. Although migraine is common in this demographic, the patient presents with symptoms and signs of raised intracranial pressure and this should be investigated urgently.

A 67-year-old man is brought to the Accident and Emergency Department, having previously presented to the local police station. He is a lifelong smoker with troublesome gout, but otherwise has no past medical or family history. He describes a sudden-onset loss of memory for recent events. He remained alert and was still able to drive to the police station.

On questioning, you note amnesia for recent events. He seems perplexed by what has happened to him, and continually asks 'Where am I?'.

Neurological examination is unremarkable; there is no evidence of head injury.

Blood testing including biochemistry, urine toxicology and blood inflammatory markers is normal. He is admitted to the ward and a computerised tomography (CT) brain performed, which is reported as normal. The next day his memory has improved substantially and he is allowed home. You see him at clinic the next week. He admits to mild memory problems for 2 days post discharge

performed, which is reported as normal. The next day his memory has improved substantially and he is allowed home. You see him at clinic the next week. He admits to mild memory problems for 2 days post-discharge, but now feels his memory is back to normal. He asks you for prognostic information.

What information do you give him regarding prognosis?

A	The condition is unlikely to occur again
B	His cognitive functioning will decline in a stepwise manner
C	He should not drive
D	He is likely to suffer from recurrent migraines in the future
E	Genetic testing is available for the presumed condition

Accident and Emergency Department, having previously presented to the local police station. He is a lifelong smoker with troublesome gout, but otherwise has no past medical or family history. He describes a sudden-onset loss of memory for recent events. He remained alert and was still able to drive to the police station.

On questioning, you note amnesia for recent events. He seems perplexed by what has happened to him, and continually asks 'Where am I?'.

Neurological examination is unremarkable; there is no evidence of head injury.

Blood testing including biochemistry, urine toxicology and blood inflammatory markers is normal. He is admitted to the ward and a computerised tomography (CT) brain performed, which is reported as normal. The next day his memory has improved substantially and he is allowed home. You see him at clinic the next week. He admits to mild memory problems for 2 days post-discharge,

A The condition is unlikely to occur again

The patient describes a typical attack of transient global amnesia. This is an acute disorder of memory occurring most often in the elderly. Patients experience distressing anterograde and retrograde amnesia, but remain alert and lucid. The diagnosis is clinical, with exclusion of other possible causes of memory loss. The memory loss lasts from a few hours to a day, with recovery completing over the next 2–3 days. The pathology of the condition is poorly understood. Case series have shown that there is a very low recurrence rate and there is no link with dementia. Although some reports have suggested a genetic basis to the condition, no disease-specific gene has been identified.

C He should not drive

This case scenario suggests transient global amnesia (TGA), and driving restrictions do not apply. Transient

restrictions do not apply. Transient epileptic amnesia is a condition with similar clinical presentation, but attacks are typically briefer and recurrent – because it is a form of epilepsy, drivers must inform the DVLA of this diagnosis.

B	His cognitive functioning will decline in a stepwise manner

This case scenario suggests transient global amnesia (TGA), which is an acute, non-progressive condition. Stepwise cognitive decline can be seen in vascular dementia, but there is no evidence to suggest that TGA is a harbinger of vascular dementia.

D	He is likely to suffer from recurrent migraines in the future

This case scenario suggests transient global amnesia (TGA), and it is not especially associated with migraine.

A 26-year-old woman presented with progressive unsteadiness of gait and blurred vision over a 2-week period. The day before admission she became very drowsy, although rousable. Her partner said she had been previously well apart from a recent viral illness a few weeks ago.

On examination, she was mildly confused and drowsy. Her observations were normal and cardiovascular, respiratory and abdominal examinations were unremarkable. She had decreased up-gaze and abduction bilaterally, but her other cranial nerves were normal. Limb examination was normal apart from brisk reflexes throughout and up-going plantars.

What is the most likely diagnosis?

A	Bacterial meningitis
B	TB meningitis
C	Bickerstaff's encephalitis

On examination, she was mildly confused and drowsy. Her observations were normal and cardiovascular, respiratory and abdominal examinations were unremarkable. She had decreased up-gaze and abduction bilaterally, but her other cranial nerves were normal. Limb examination was normal apart from brisk reflexes throughout and up-going plantars.

What is the most likely diagnosis?

A	Bacterial meningitis
B	TB meningitis
C	Bickerstaff's encephalitis
D	Herpes simplex encephalitis
E	Limbic encephalitis

A 26-year-old woman presented with progressive unsteadiness of gait and blurred vision over a 2-week period. The day before admission she became very drowsy, although rousable. Her partner said she had been previously well apart from a recent viral illness a few weeks ago.

On examination, she was mildly confused and drowsy. Her observations were normal and cardiovascular, respiratory and abdominal examinations were unremarkable. She had decreased up-gaze and abduction bilaterally, but her other cranial nerves were normal. Limb examination was normal apart from brisk reflexes throughout and up-going plantars.

What is the most likely diagnosis?

Your answer was incorrect

A	Bacterial meningitis

C Bickerstaff's encephalitis

Bickerstaff's brainstem encephalitis causes a progressive, fairly symmetrical ophthalmoplegia, ataxia, disturbance of consciousness and extensor plantar responses ± hyper-reflexia. It may be related to Guillain–Barré syndrome, and in particular the Miller Fisher variant with which it shares the ophthalmoplegia and ataxia. However, in the Miller Fisher syndrome there is areflexia and, in particular, there is no disturbance of consciousness. Like Miller Fisher, anti-GQ1b antibodies are often positive. There is normally an antecedent illness (often an upper respiratory tract infection). Steroids, immunoglobulins and plasma exchange have all been used as treatment.

D Herpes simplex encephalitis

This presents with headache, fever, confusion and seizures. The bilateral upper motor neurone signs and ophthalmoplegia described in this case

are not seen.

A Bacterial meningitis

This presents with headache, neck stiffness and fever, usually in an acute manner so cannot account for the presentation seen here.

B TB meningitis

This presents with headache, neck stiffness and fever, usually progressing over several weeks. Focal neurological symptoms and signs may be seen due to parenchymal involvement or as false localising features of raised intracranial pressure.

E Limbic encephalitis

This presents with headache, amnesia, confusion and seizures. The bilateral upper motor neurone signs and ophthalmoplegia described in this case are not seen.

A 45-year-old man presented with a 7-month history of pain in his feet. He had also had increased difficulty over the same period with walking and had fallen over a number of times. In the last few months he had had difficulty opening jars and carrying his shopping. He had been generally well but had recently suffered from gastro-oesophageal reflux, for which he was taking lansoprazole. He was an only child and both of his parents had died when he was young.

On neurological examination, he had no wasting or muscle fasciculation. Tone was normal throughout, but there was mild global weakness in all four limbs. He was areflexic, with a loss of vibration and proprioception sensation to the wrists and knees bilaterally.

Nerve conduction studies showed the following:

- Motor conduction velocities were less than 60% of normal in all nerves tested
- Distal motor latencies were

less than 50% of normal in all nerves tested

- Distal motor latencies were prolonged in three out of four of the nerves tested
- There was one region of conduction block in the median nerve
- F waves were absent.

What is the most likely diagnosis?

A	Vitamin B_{12} deficiency
B	Chronic inflammatory demyelinating polyneuropathy (CIDP)
C	Drug-induced neuropathy
D	Vasculitic neuropathy
E	Charcot–Marie–Tooth disease type 2

child and both of his parents had died when he was young.

On neurological examination, he had no wasting or muscle fasciculation. Tone was normal throughout, but there was mild global weakness in all four limbs. He was areflexic, with a loss of vibration and proprioception sensation to the wrists and knees bilaterally.

Nerve conduction studies showed the following:

- Motor conduction velocities were less than 60% of normal in all nerves tested
- Distal motor latencies were prolonged in three out of four of the nerves tested
- There was one region of conduction block in the median nerve
- F waves were absent.

What is the most likely diagnosis?

B Chronic inflammatory demyelinating polyneuropathy (CIDP)

The nerve conduction studies suggest a demyelinating neuropathy (decreased motor conduction velocities, prolonged distal latencies, absent or prolonged F waves and areas of conduction block) and therefore the most likely diagnosis is CIDP. This is commonly sensorimotor, hence the clinical signs here. The causes of a chronic demyelinating neuropathy include CIDP, paraproteinaemic neuropathies, hereditary neuropathies (e.g. Charcot–Marie–Tooth type 1, Refsum's disease) and certain drug-related neuropathies (e.g. amiodarone). Classical CMT disease is associated with ascending weakness beginning in the intrinsic muscles of the feet, which does not fit with the clinical picture seen here. First-line treatment for CIDP is normally either oral prednisolone or intermittent intravenous immunoglobulins: evidence suggests

these are of equal efficacy in the short term, and they have not been compared in the long term. Other immunosuppressants have been tried but there is little evidence for any of them: the most commonly used is azathioprine as a steroid-sparing agent.

A Vitamin B_{12} deficiency

Peripheral loss of vibration and position sense are the earliest features of B_{12} deficiency. Loss of reflexes and mild to moderate weakness are much later features of low vitamin B_{12}.

C Drug-induced neuropathy

Lansoprazole is not associated with drug-induced neuropathy; commonly reported neurological adverse effects of therapy include headache and dizziness.

D Vasculitic neuropathy

Lansoprazole is not associated with drug-induced neuropathy; commonly reported neurological adverse effects of therapy include headache and dizziness.

D	Vasculitic neuropathy

Vasculitis is more commonly associated with mononeuritis multiplex rather than the polyneuropathy seen here.

E	Charcot–Marie–Tooth disease type 2

CMT type 2 is associated with distal muscle weakness and atrophy, which is not seen here on clinical examination.

6953

Rate this question:

Next Question

You are 'fast-bleeped' to assess a 26-year-old woman with headache in the Emergency Department. She describes a sudden-onset headache that peaked in intensity within seconds of onset. The pain was the worst she had ever experienced. The headache has been present for 3 h but is lessening. There is associated nausea, vomiting and photophobia.

She has no past history of note and has not experienced severe headache before.

General and neurological examination is unremarkable. A number of investigations have already been performed by the casualty officer. He admits that the lumbar puncture was a difficult procedure and he obtained a 'bloody tap'.

Computerised tomography (CT) of the brain is normal.

Spinal fluid: 500 RBC/cm^3; < 5 WBC/cm^3; no organisms on Gram stain; no xanthochromia.

Which of the following is the next

performed by the casualty officer. He admits that the lumbar puncture was a difficult procedure and he obtained a 'bloody tap'.

Computerised tomography (CT) of the brain is normal.

Spinal fluid: 500 RBC/cm^3; < 5 WBC/cm^3; no organisms on Gram stain; no xanthochromia.

Which of the following is the next most important management step?

A	Repeat lumbar puncture
B	Reassurance and simple analgesia
C	Subcutaneous sumatriptan
D	Magnetic resonance angiogram
E	IV dexamethasone

11:37
tps://mypastest.pastest.com 14

You are 'fast-bleeped' to assess a 26-year-old woman with headache in the Emergency Department. She describes a sudden-onset headache that peaked in intensity within seconds of onset. The pain was the worst she had ever experienced. The headache has been present for 3 h but is lessening. There is associated nausea, vomiting and photophobia.

She has no past history of note and has not experienced severe headache before.

General and neurological examination is unremarkable. A number of investigations have already been performed by the casualty officer. He admits that the lumbar puncture was a difficult procedure and he obtained a 'bloody tap'.

Computerised tomography (CT) of the brain is normal.

Spinal fluid: 500 RBC/cm^3; < 5

D Magnetic resonance angiogram

The history is classical for subarachnoid haemorrhage (SAH). Any patient with a first-onset, explosive headache needs admission and investigation for SAH. The lack of meningism or other clinical signs should not put you off the diagnosis. The initial investigation of choice is computerised tomography (CT) of the brain. The sooner the CT is performed, the greater the sensitivity. Magnetic resonance imaging (MRI) is less effective at detecting fresh blood. If performed within 24 h, a modern CT scanner will diagnose SAH with 90–95% sensitivity. If the CT is normal the next investigation is cerebrospinal fluid (CSF) examination, preferably 12 h after headache onset. Xanthochromia, the breakdown product of red blood cells, will not be detected until around 12 h post-bleed. If available, a better biochemical test would be spectrophotometry of spun cerebrospinal fluid (CSF should have been spun down and formal

been spun down and formal spectrophotometry requested at the time of analysis, though this casualty officer did not request this. In addition, the LP has been performed too soon after the headache onset). If imaging already provides a diagnosis, there is no need to subject the patient to an unnecessary lumbar puncture. It is recognised that headache can accompany expansion of an aneurysm prior to bleed and so if the history is good, even with negative CT and xanthochromia, the patient should undergo non-invasive imaging of cerebral vessels. As such, MRA is the correct answer from those given as possible options. This patient should receive adequate analgesia, balancing pain relief against interfering with Glasgow coma scale measurement.

A	Repeat lumbar puncture

In this case there is no value in repeating spinal tap to look for xanthochromia, as blood from the previous procedure will make

interpretation impossible.

B	Reassurance and simple analgesia

The history is very suggestive of subarachnoid haemorrhage, and investigations performed to date have not adequately excluded this. Further investigation is warranted.

C	Subcutaneous sumatriptan

The history is of a thunderclap headache and there is no previous suggestion of any habitual migraines presenting with this sort of severe headache. As such, this presentation requires full investigation.

E	IV dexamethasone

There is no evidence to suggest that corticosteroids are helpful in managing thunderclap headache or subarachnoid haemorrhage.

A 23-year-old woman underwent mitral valve repair surgery, and was successfully weaned off from the ventilator on the same day. However it was realised subsequently that she had difficulty in moving the left upper and lower limbs.

On examination, she was alert, but could not comprehend written commands. She understood verbal questions but she ignored the left-sided limbs and denied any weakness. Visual field examination revealed a left-sided superior quadrantinopia. Other cranial nerves were normal. There was a 3/5 motor weakness of the left upper limb and 4/5 weakness of the left lower limb. The left-sided plantar was extensor.

Which vascular territory is likely to have been involved in this patient?

A	Right anterior choroidal artery
B	Right lenticulostriate artery

commands. She understood verbal questions but she ignored the left-sided limbs and denied any weakness. Visual field examination revealed a left-sided superior quadrantinopia. Other cranial nerves were normal. There was a 3/5 motor weakness of the left upper limb and 4/5 weakness of the left lower limb. The left-sided plantar was extensor.

Which vascular territory is likely to have been involved in this patient?

A	Right anterior choroidal artery
B	Right lenticulostriate artery
C	Right posterior cerebral artery
D	Right superior cerebellar artery
E	Right inferior division of the middle cerebral artery

A 23-year-old woman underwent mitral valve repair surgery, and was successfully weaned off from the ventilator on the same day. However it was realised subsequently that she had difficulty in moving the left upper and lower limbs.

On examination, she was alert, but could not comprehend written commands. She understood verbal questions but she ignored the left-sided limbs and denied any weakness. Visual field examination revealed a left-sided superior quadrantinopia. Other cranial nerves were normal. There was a 3/5 motor weakness of the left upper limb and 4/5 weakness of the left lower limb. The left-sided plantar was extensor.

Which vascular territory is likely to have been involved in this patient?

Your answer was incorrect

A	Right anterior choroidal artery

E Right inferior division of the middle cerebral artery

Occlusion of the inferior division of the MCA is nearly always embolic, in this case following heart surgery. The non-dominant hemisphere involvement, as depicted in the present patient, leads to anosognosia, unilateral neglect, dressing apraxia and constructional apraxia. These findings reflect the non-dominant parietal lobe involvement. A superior quadrantanopia is due to involvement of the optic radiations deep to the second temporal convolution.

D Right superior cerebellar artery

Occlusion of this vessel produces ipsilateral cerebellar symptoms and signs (sometimes with midbrain signs if the origin of the artery is occluded).

A Right anterior choroidal artery

A 55-year-old patient is under management for chronic back pain. He is accompanied by his wife, who brought him along to the Emergency Department. She is very concerned, as the patient is increasingly confused and lethargic.

Past medical history includes depression.

On examination, his blood pressure is 125/80 mmHg and Glasgow Coma Scale (GCS) score 14 with E4 M6 V4; the rest of the physical examination is unremarkable.

Investigations:

Haemoglobin (Hb)	12.4 g/dl
White cell count (WCC)	5.9×10^9/l
Platelets (PLT)	219×10^9/l
Sodium (Na)	116 mmol/l
Potassium (K)	4.2 mmol/l
Creatinine (Cr)	105 μmol/l

Which of the following medications is

11:44
tps://mypastest.pastest.com

A 55-year-old patient is under management for chronic back pain. He is accompanied by his wife, who brought him along to the Emergency Department. She is very concerned, as the patient is increasingly confused and lethargic.

Past medical history includes depression.

On examination, his blood pressure is 125/80 mmHg and Glasgow Coma Scale (GCS) score 14 with E4 M6 V4; the rest of the physical examination is unremarkable.

Investigations:

Haemoglobin (Hb)	12.4 g/dl
White cell count (WCC)	5.9×10^9/l
Platelets (PLT)	219×10^9/l
Sodium (Na)	116 mmol/l
Potassium (K)	4.2 mmol/l
Creatinine (Cr)	105 μmol/l

Potassium (K)	4.2 mmol/l
Creatinine (Cr)	105 µmol/l

Which of the following medications is likely to be responsible for the hyponatraemia in this man?

A Diazepam

B Lisinopril

C Oxytetracycline

D Citalopram

E Codeine phosphate

21470

D Citalopram

The answer is Citalopram (Option D).

In a patient presenting with altered mental state and confusion, it is essential not only to check the electrolytes, but also to review the medications. This gentleman is diagnosed with depression and is therefore likely to be on an antidepressant. He has hyponatraemia, possibly syndrome of inappropriate antidiuretic hormone (SIADH), and initial management would involve stopping the drug and monitoring sodium levels. Although fluid restriction forms part of the management of SIADH, fluid restriction in the presence of continued citalopram is unlikely to be successful in improving the serum sodium level.

C Oxytetracycline

Oxytetracycline (Option C) is incorrect.

Oxytetracycline can cause benign intracranial hypertension but is not

intracranial hypertension but is not known to cause hyponatraemia. It is contraindicated in pregnant or breastfeeding women.

A	Diazepam

Diazepam (Option A) is incorrect.

Diazepam most commonly causes confusion, especially in the elderly, and drowsiness and can lead to dependence. It is not known to cause hyponatraemia.

B	Lisinopril

Lisinopril (Option B) is incorrect.

Lisinopril is not known to cause hyponatraemia but can cause a dry cough and rarely causes angio-oedema (which can be several months or even a year after initiation).

E	Codeine phosphate

Codeine phosphate (Option E) is

A 46-year-old woman with a history of relapsing and remitting multiple sclerosis comes to the clinic for review. She has been stable for the past 6 months and is currently treated with oral fingolimod. Neurological examination reveals poor coordination, more marked on the left than the right, although there are no other significant signs.

Which of the following correctly represents the mode of action of fingolimod?

A	B-cell cytotoxic
B	Mimics myelin peptides
C	Prevents lymphocyte movement across the blood–brain barrier
D	T-cell cytotoxic
E	Increases the expression and concentration of anti-

C Prevents lymphocyte movement across the blood–brain barrier

Fingolimod (Gilenya) modulates the sphingosine-1-phosphate receptor and alters lymphocyte migration across the blood–brain barrier (BBB). It is considered one of the more effective drugs in the 'moderate efficacy', or category 1, group of MS disease-modifying treatments, reducing relapse rate by 54%. Fingolimod is a daily oral medication. The most common side effects include first-dose bradycardia, headache, influenza, diarrhoea, back pain, elevated liver enzymes and cough. More serious adverse effects include basal cell carcinoma and macular oedema, and there are case reports of PML associated with fingolimod use.

A B-cell cytotoxic

Ocrelizumab is a recombinant human anti-CD20 monoclonal antibody that

enhances cell-mediated cytotoxicity. It is the first treatment that has been shown to slow progression of primary-progressive MS and has been trialled in relapsing-remitting MS, but it is not yet licensed in Europe.

B	Mimics myelin peptides

Glatiramer acetate (Copaxone) is a mixture of random polymers of four amino acids, which is antigenically similar to myelin basic protein. It binds to MHC molecules and competes with myelin antigens for their presentation to T cells. Furthermore, it is an inducer of specific T-helper 2-type suppressor cells, which express anti-inflammatory cytokines. Glatiramer acetate is administered as a 3-weekly subcutaneous injection, reducing relapse rate by 34%. It is usually better tolerated than other DMTs; side effects include flushing, injection-site reactions, dyspnoea and palpitations. Cases of hepatotoxicity have been reported, but no monitoring is required.

Alemtuzumab (Campath) is a humanised monoclonal antibody that depletes CD-52-expressing T cells, B cells and natural killer cells. Alemtuzumab is drug of 'high efficacy' (category 2) and reduces relapse rate by 50% compared to beta-interferons. It is taken as two intravenous infusions, 12 months apart.

The main side effects include infusion reactions, infections and autoimmune disorders (such thyroid autoimmunity and ITP).

E	Increases the expression and concentration of anti-inflammatory agents

Beta-interferons were the first disease-modifying treatments for MS. There are a variety of formulations of either intramuscular or subcutaneous injections with differing regimes. These reduce relapse rate by 33%. Common side effects include post-injection flu-like symptoms, headaches, myalgia and fever. Injection-site reactions and depression have also been reported.

A 52-year-old woman presents with increasing weakness. She consulted her general practitioner (GP) 4 days earlier, unable to get out of a chair. Her husband has brought her to the Emergency Department as she is choking when she eats and seems only able to mumble sounds.

On examination, there appears to be global weakness with absent reflexes bilaterally. On further questioning, there is a history of recent food poisoning around three weeks ago. Electrophysiological studies show evidence of conduction block at multiple sites.

What is the most likely diagnosis?

A	Motor neurone disease (MND)
B	Multiple sclerosis (MS)
C	Guillain–Barré syndrome (GBS)
D	Poliomyelitis

Emergency Department as she is choking when she eats and seems only able to mumble sounds.

On examination, there appears to be global weakness with absent reflexes bilaterally. On further questioning, there is a history of recent food poisoning around three weeks ago. Electrophysiological studies show evidence of conduction block at multiple sites.

What is the most likely diagnosis?

A	Motor neurone disease (MND)
B	Multiple sclerosis (MS)
C	Guillain–Barré syndrome (GBS)
D	Poliomyelitis
E	Botulism

6:30
:tps://mypastest.pastest.com 14

A 52-year-old woman presents with increasing weakness. She consulted her general practitioner (GP) 4 days earlier, unable to get out of a chair. Her husband has brought her to the Emergency Department as she is choking when she eats and seems only able to mumble sounds.

On examination, there appears to be global weakness with absent reflexes bilaterally. On further questioning, there is a history of recent food poisoning around three weeks ago. Electrophysiological studies show evidence of conduction block at multiple sites.

What is the most likely diagnosis?

Your answer was incorrect

A	Motor neurone disease (MND)

C Guillain–Barré syndrome (GBS)

GBS is an acute inflammatory demyelinating polyradiculopathy, which may follow *Campylobacter* infection. Nerve conduction studies show slowed conduction velocity and conduction block due to impaired transmission along demyelinated nerves.

E Botulism

Botulism and other neuromuscular junction disorders, such as myasthenia gravis, are key differentials when considering a patient with an acute flaccid paralysis. There is a history of 'food poisoning' in this case, but the onset of food-borne botulism is usually within 48 h of exposure. Furthermore, the finding of conduction block on neurophysiology is typical of peripheral nerve demyelination, rather than dysfunction of the neuromuscular junction.

junction.

A Motor neurone disease (MND)

The evolution of symptoms is too rapid for motor neurone disease, which usually evolves over a period of many months.

B Multiple sclerosis (MS)

As MS is a disease of the central nervous system, one would expect to see upper motor neurone signs. These are not present in this case.

D Poliomyelitis

Polio is very rare in the developed world. Furthermore, it would be very unusual for polio to evolve so rapidly and involve the nervous system so diffusely.

6531

Rate this question:

A 28-year-old man was admitted to the Psychiatry Hospital for evaluation of 3 months of insomnia, weight loss, depression, forgetfulness and pins-and-needles sensation in his limbs. He was given amitriptyline, but over the next 8 weeks, it was noticed that he was becoming more forgetful and had become unsteady. He was intermittently incontinent. A medical registrar was asked to review him.

On examination, he was disorientated to place and person. He failed to recall objects at 3 and 5 min. Myoclonic jerks were observed, and he startled on touch and when light was shone in his eyes. Upward gaze was restricted. Limb and gait ataxia was demonstrable. Plantar reflexes were flexor bilaterally.

A computed tomography (CT) scan of the head was normal. An electroencephalogram (EEG) was diffusely slow.

Investigations:

Haemoglobin (Hb)	12.8 g/dl

electroencephalogram (EEG) was diffusely slow.

Investigations:

Haemoglobin (Hb)	12.8 g/dl
White cell count (WCC)	7.9×10^9/l
Platelets (PLT)	198×10^9/l
Sodium (Na^+)	137 mmol/l
Potassium (K^+)	4.3 mmol/l
Creatinine (Cr)	110 µmol/l
Thyroid-stimulating hormone (TSH)	6.9 u/l (0.5-4.5)
Anti-thyroid peroxidase (TPO) antibody	Positive

What is the most likely diagnosis of those given below?

A Alexander's disease

	mmol/l
Creatinine (Cr)	110 µmol/l
Thyroid-stimulating hormone (TSH)	6.9 u/l (0.5-4.5)
Anti-thyroid peroxidase (TPO) antibody	Positive

What is the most likely diagnosis of those given below?

A Alexander's disease

B Hashimoto's encephalopathy

C Kleine–Levin syndrome

D Juvenile myoclonic epilepsy

E Hepatic encephalopathy

32778

Submit

B Hashimoto's encephalopathy

The correct answer is Hashimoto's encephalopathy (Option B).

This young man presents with behavioural and psychiatric disturbances and some sensory phenomena. He subsequently develops subacute cerebellar ataxia and dementia, with widespread myoclonic jerks precipitated by a startle. This is consistent with a diagnosis of Hashimoto's encephalopathy, a relatively poorly known and little understood entity consisting of subacute diffuse encephalopathy characterized by various combinations of clinical features, including neuropsychiatric signs (confusion, apathy, memory deficit), myoclonic encephalopathy, movement disorder (akinetic–rigid extrapyramidal signs) and seizures.

The cases reported in the literature have been associated with positive antithyroid autoantibodies, comparable with Hashimoto's thyroiditis. The exact cause of the

thyroiditis. The exact cause of the disorder is unclear. Electroencephalography is abnormal in most, but the abnormalities usually seen are not specific. Since clinical features of Hashimoto's encephalopathy are non-specific, other aetiologies, such as infectious, metabolic, toxic, vascular, neoplastic and paraneoplastic causes, need to be considered. Women appear to be more affected than men, and the condition is usually steroid-responsive.

A	Alexander's disease

Alexander's disease (Option A) is incorrect.

Alexander's disease is a rare leukodystrophy, the symptoms of which usually begin before the age of 2 years. Signs and symptoms include an enlarged brain and head size, seizures, spasticity and developmental delay.

C	Kleine–Levin syndrome

Kleine–Levin syndrome is a very rare disorder characterised by persistent episodic hypersomnia and cognitive changes. Patients generally experience recurrent episodes of the condition for more than a decade and may return at a later age. Individual episodes generally last more than a week, sometimes lasting for months. The condition greatly affects the personal, professional and social lives of sufferers. The severity of symptoms and the course of the syndrome vary significantly.

D	Juvenile myoclonic epilepsy

Juvenile myoclonic epilepsy (Option D) is incorrect.

Juvenile myoclonic epilepsy is a common form of idiopathic generalized epilepsy, representing 5–10% of all epilepsy cases. This disorder typically first manifests itself between the ages of 12 and 18 with brief episodes of involuntary muscle twitching occurring early in the morning. Other seizure types, such as

An 80-year-old man comes to the Neurology Clinic. He presented to his GP with symptoms suggestive of Parkinson's some 6 years ago and was started on L-dopa by his GP.

During the initial period, his Parkinson's disease symptoms improved, but now his mobility has begun to worsen again and his wife is concerned that his short-term memory has deteriorated.

Mental state testing in the clinic suggests problems across multiple domains, including visuo-spatial difficulties, disorders of executive function and problems with naming words.

She also reports that he appears to see people in the bedroom who are not actually there. Although he has some short-term memory deficit, it is not as bad as might be expected given his other problems.

Investigations:

Mini-mental state score is reduced by 11 points to 19/30.

6:41
tps://mypastest.pastest.com
14

people in the bedroom who are not actually there. Although he has some short-term memory deficit, it is not as bad as might be expected given his other problems.

Investigations:

Mini-mental state score is reduced by 11 points to 19/30.

Which of the following would be the most appropriate treatment for him?

A	Rivastigmine
B	Selegiline
C	Memantine
D	Haloperidol
E	Quetiapine

An 80-year-old man comes to the Neurology Clinic. He presented to his GP with symptoms suggestive of Parkinson's some 6 years ago and was started on L-dopa by his GP.

During the initial period, his Parkinson's disease symptoms improved, but now his mobility has begun to worsen again and his wife is concerned that his short-term memory has deteriorated.

Mental state testing in the clinic suggests problems across multiple domains, including visuo-spatial difficulties, disorders of executive function and problems with naming words.

She also reports that he appears to see people in the bedroom who are not actually there. Although he has some short-term memory deficit, it is not as bad as might be expected given his other problems.

Investigations:

A Rivastigmine

The most likely diagnosis here is dementia related to Parkinson's disease, characterised by Lewy body formation. When symptoms are mild, no medical intervention is required. One large trial of more than 500 patients has, however, indicated that rivastigmine may decrease psychiatric symptoms associated with the dementia, particularly apathy, anxiety, hallucinations and delusions.

C Memantine

This is an N-methyl-D-aspartate (NMDA)-receptor antagonist prescribed for Alzheimer's disease. Although some studies have shown an effect in Parkinson's, results are more variable versus rivastigmine.

B Selegiline

This is a selective irreversible MAO-B inhibitor used in early-stage

This is a selective irreversible MAO-B inhibitor used in early-stage Parkinson's disease. It inhibits the metabolism of dopamine and can worsen depression.

D	Haloperidol

This is a typical antipsychotic. When used in Parkinson's, this type of pharmacological agent may lead to a significant deterioration in motor function.

E	Quetiapine

This is an atypical (newer) antipsychotic. It may be used in the control of behavioural symptoms associated with Parkinson's cognitive dysfunction, but should be prescribed at the lowest possible dose. Rivastigmine is a more appropriate initial therapy, particularly as memory loss is a prevalent feature of this patient's disease.

You are called to assess a 72-year-old left-handed patient with sudden-onset weakness. Past medical history is of hypertension only.

On examination, you note slurred speech, but no expressive or receptive difficulty. There is no field defect or inattention. There is subtle right limb weakness, most pronounced in the hand. This becomes more obvious as the patient performs complex tasks such as fastening a button. You note no sensory loss in the affected limb.

According to the Oxfordshire Community Stroke Subclassification System, how would you define this event?

A	Dominant total anterior circulatory stroke (TACS)
B	Non-dominant TACS
C	Lacunar stroke (LACS)
D	Non-dominant partial anterior

hand. This becomes more obvious as the patient performs complex tasks such as fastening a button. You note no sensory loss in the affected limb.

According to the Oxfordshire Community Stroke Subclassification System, how would you define this event?

A	Dominant total anterior circulatory stroke (TACS)
B	Non-dominant TACS
C	Lacunar stroke (LACS)
D	Non-dominant partial anterior circulatory stroke (PACS)
E	Posterior circulation stroke (POCS)

C Lacunar stroke (LACS)

LACS is defined by a pure motor or pure sensory syndrome, ataxic hemiparesis or dysarthria clumsy-hand syndrome. The lack of sensory loss pushes us more towards a diagnosis of LACS here. Lacunar stroke is often associated with a past history of hypertension.

A Dominant total anterior circulatory stroke (TACS)

TACS is defined by a combination of higher cerebral dysfunction and contralateral sensory/motor deficit and visual field defect.

B Non-dominant TACS

There is little evidence of higher cerebral dysfunction here, and sensory signs are absent.

D Non-dominant partial anterior circulatory stroke (PACS)

B	Non-dominant TACS

There is little evidence of higher cerebral dysfunction here, and sensory signs are absent.

D	Non-dominant partial anterior circulatory stroke (PACS)

PACS is defined as two of the three elements of TACS, or new higher cerebral dysfunction.

E	Posterior circulation stroke (POCS)

POCs is associated with a bilateral motor/sensory deficit, disorder of conjugate eye movement, solitary visual field defect, cerebellar dysfunction or crossed cranial nerve and sensory/motor signs, occurring as a result of interference in areas supplied via the vertebrobasilar circulation.

A 19-year-old university student presented with progressive unsteadiness of walking over the previous year. She had been otherwise well, apart from recent difficulty hearing her lecturer in classes. She took no prescription medication but had occasionally taken cocaine during her first year of college. She drank up to 30 units of alcohol per week and smoked 10 cigarettes a day. Her parents were both well, but she remembers her father's sister having problems with walking before she died.

Examination revealed normal tone and power throughout all four limbs. Reflexes were normal in the upper limbs but decreased at the knees and absent at the ankles. Coordination was normal in all four limbs but her gait was ataxic. Sensation in the upper limbs was normal, but there was decreased vibration sense and proprioception to the ankles bilaterally.

What is the most likely diagnosis?

A	Ataxia telangiectasia

remembers her father's sister having problems with walking before she died.

Examination revealed normal tone and power throughout all four limbs. Reflexes were normal in the upper limbs but decreased at the knees and absent at the ankles. Coordination was normal in all four limbs but her gait was ataxic. Sensation in the upper limbs was normal, but there was decreased vibration sense and proprioception to the ankles bilaterally.

What is the most likely diagnosis?

A	Ataxia telangiectasia
B	Friedreich's ataxia
C	Multiple sclerosis
D	Dentatorubropallidoluysian atrophy (DRPLA)
E	Vitamin B_{12} deficiency

A 19-year-old university student presented with progressive unsteadiness of walking over the previous year. She had been otherwise well, apart from recent difficulty hearing her lecturer in classes. She took no prescription medication but had occasionally taken cocaine during her first year of college. She drank up to 30 units of alcohol per week and smoked 10 cigarettes a day. Her parents were both well, but she remembers her father's sister having problems with walking before she died.

Examination revealed normal tone and power throughout all four limbs. Reflexes were normal in the upper limbs but decreased at the knees and absent at the ankles. Coordination was normal in all four limbs but her gait was ataxic. Sensation in the upper limbs was normal, but there was decreased vibration sense and proprioception to the ankles bilaterally.

What is the most likely diagnosis?

B Friedreich's ataxia

Friedreich's ataxia is an autosomal recessive trinucleotide repeat disorder that normally starts before the end of the teens. It has an annual incidence of around 1 in 50,000. Neurological features are of a progressive ataxia, cerebellar dysarthria, lower limb areflexia, decreased vibration and proprioception, pyramidal weakness and extensor plantar reflexes. Pes cavus and scoliosis are both seen. Cardiomyopathy occurs in over 70% of cases. Less common features are optic atrophy, diabetes mellitus and deafness.

E Vitamin B_{12} deficiency

Peripheral loss of vibration and position sense are the earliest features of B_{12} deficiency. Loss of reflexes and mild to moderate weakness are much later features of low vitamin B_{12}.

A Ataxia telangiectasia

mild to moderate weakness are much later features of low vitamin B_{12}.

A	Ataxia telangiectasia

Ataxia telangiectasia presents in childhood with symptoms of cerebellar dysfunction and ataxia in childhood, rather than for the first time in the late second decade.

C	Multiple sclerosis

Multiple sclerosis usually presents with a patchwork of neurological signs rather than the prominent ataxic gait seen here as an initial feature.

D	Dentatorubropallidoluysian atrophy (DRPLA)

DRPLA presents with symptoms similar to those of Huntington's disease, and is most prominent amongst the Japanese population.

6954

Rate this question:

A 54-year-old man is referred by his GP to the local Neurology Department for intractable headaches for the last 3 months, more recently associated with a constant feeling of nausea. The patient's family have also been concerned since they have noticed that the patient has become increasingly forgetful recently. The patient has otherwise been well apart from mild hypertension controlled by dietary modifications. The only other notable finding in his history is that he worked at a petrochemical plant for 24 years. Routine laboratory investigations were normal and negative for an underlying infective or metabolic process. Imaging studies performed on the patient showed an irregularly shaped hypodense mass with a surrounding ring of cerebral edema located in the left temporal lobe. These findings were consistent with a diagnosis of glioma.

Which of the following clinical signs would have best localised this lesion to the temporal lobe?

normal and negative for an underlying infective or metabolic process. Imaging studies performed on the patient showed an irregularly shaped hypodense mass with a surrounding ring of cerebral edema located in the left temporal lobe. These findings were consistent with a diagnosis of glioma.

Which of the following clinical signs would have best localised this lesion to the temporal lobe?

A	Ipsilateral superior homonymous quadrantanopia
B	Contralateral superior homonymous quadrantanopia
C	Asterognosis
D	Dysdiadochokinesis
E	Ipsilateral deafness

B Contralateral superior homonymous quadrantanopia

A lesion in the temporal lobe that affects Meyer's loop of the optic radiation will cause a contralateral superior homonymous quadrantanopia.

Gliomas account for most brain parenchymal tumours and are classified by their histological appearance and molecular characteristics. Patients employed in the rubber or petrochemical industry are at higher risk of developing glioblastoma multiforme.

A Ipsilateral superior homonymous quadrantanopia

Lesions in the temporal lobe cause contralateral signs due to decussation at the optic chiasm.

C Asterognosis

inability to identify an object by touch. It is tested for by asking the patient to identify an object put in their hand with their eyes closed. Astereognosis is a cortical sensory deficit which can be seen in parietal lobe pathology.

D	Dysdiadochokinesis

This is the impaired ability to perform rapid, alternating movements. It is a feature of cerebellar ataxia, typically caused by lesions in the cerebellar hemispheres, but it can also be seen in frontal lobe lesions.

E	Ipsilateral deafness

Unilateral deafness has a number of causes which can be localised to the outer ear, middle ear and inner ear. The most common tumour that causes unilateral sensorineural hearing loss is an acoustic neuroma, which typically arises from the vestibular portion of cranial nerve VIII. A temporal lobe tumour would not cause ipsilateral deafness

A 48-year-old man has been seen in Accident and Emergency by the orthopaedic team with a suspected disc prolapse. He presented to his GP with stiffness and weakness in both legs, which developed over the last week. He has started to develop difficulty passing urine over the last 12 h. He has long-standing back pain. There is no other medical history. When seen in casualty he is able to walk although he has a stiff-legged gait. Tone is increased in both legs. Power is 4±5 with pathologically brisk reflexes, and sustained beats of clonus at both ankles. The plantars are up-going bilaterally. There is decreased soft touch sensation until a level around the umbilicus. There are no neurological abnormalities in the arms. The cranial nerve examination is also normal.

The orthapaedic registrar reviewed the patient earlier in the day and requested urgent magnetic resonance imaging (MRI) of the lumbar spine. This was reviewed by the radiologist and was reported as showing no structural

was reported as showing no structural lesions. The scan shows from the T9 vertebrae down to the sacral area.

The orthapaedic registrar feels that this is not a surgical problem and wonders whether it might be multiple sclerosis. He asks you, the medical registrar, what you would like to do with the patient. You examine the patient and agree with the physical signs.

What are you going to suggest?

A	Admission to a medical bed overnight pending neurology review
B	Urgent magnetic resonance imaging (MRI) of the entire thoracic spine
C	Urgent nerve conduction studies
D	Urgent MRI of the cervical and thoracic spine

wonders whether it might be multiple sclerosis. He asks you, the medical registrar, what you would like to do with the patient. You examine the patient and agree with the physical signs.

What are you going to suggest?

A	Admission to a medical bed overnight pending neurology review
B	Urgent magnetic resonance imaging (MRI) of the entire thoracic spine
C	Urgent nerve conduction studies
D	Urgent MRI of the cervical and thoracic spine
E	Catheterise and discharge with urgent neurological outpatient appointment

A 48-year-old man has been seen in Accident and Emergency by the orthopaedic team with a suspected disc prolapse. He presented to his GP with stiffness and weakness in both legs, which developed over the last week. He has started to develop difficulty passing urine over the last 12 h. He has long-standing back pain. There is no other medical history. When seen in casualty he is able to walk although he has a stiff-legged gait. Tone is increased in both legs. Power is 4±5 with pathologically brisk reflexes, and sustained beats of clonus at both ankles. The plantars are up-going bilaterally. There is decreased soft touch sensation until a level around the umbilicus. There are no neurological abnormalities in the arms. The cranial nerve examination is also normal.

The orthapaedic registrar reviewed the patient earlier in the day and requested urgent magnetic resonance imaging (MRI) of the lumbar spine. This

D Urgent MRI of the cervical and thoracic spine

This man's syndrome, with spastic paraparesis and urinary symptoms, is a medical/surgical emergency. Although the examination suggests a level at around T10, it must be remembered that these levels can be misleading. In particular, the lesion can be several levels higher than the sensory signs suggest and any delay in identifying and treating a structural problem could result in permanent neurological deficit, impotence and incontinence.

E Catheterise and discharge with urgent neurological outpatient appointment

This would be medically negligent as the case described is an emergency and the patient requires MRI of the spine to exclude a treatable compressive lesion

A Admission to a medical bed

A	Admission to a medical bed overnight pending neurology review

This case is an emergency and the patient requires MRI of the spine to exclude a treatable compressive lesion.

B	Urgent magnetic resonance imaging (MRI) of the entire thoracic spine

This is a reasonable suggestion and would likely identify the problem. However, with acute myelopathic conditions in the cervical area, the signs in the arms can occasionally be very subtle (perhaps just inverted supinator reflexes), so in this situation it is best to be cautious and image cervical and thoracic segments.

C	Urgent nerve conduction studies

The examination findings clearly indicate an upper motor neuron lesion, so neurophysiology will not be helpful

A 46-year-old university lecturer is referred to the Neurology Outpatient Clinic with recurrent headaches. He describes an intense searing pain, which develops over a few minutes on the right side of his head, above his eye. The pain is often so severe that he bangs his head against furniture.

Attacks last from 20 to 60 min and occur up to three times a day. The headaches are particularly troublesome at night, often waking him from sleep, and are frequently associated with a runny nose.

During the consultation, he admits to recent difficulties at work, often missing deadlines for preparing lectures and marking coursework. He often lies in bed worrying about his symptoms and has lost his appetite.

His younger sister suffers from migraines, and his mother takes medication for depression. He drinks about 5 pints of beer at weekends, although he has reduced this recently as he feels it aggravates the headaches.

symptoms and has lost his appetite.

His younger sister suffers from migraines, and his mother takes medication for depression. He drinks about 5 pints of beer at weekends, although he has reduced this recently as he feels it aggravates the headaches.

Which of the following is the most likely to be of long-term benefit?

A	Indomethacin
B	Sumatriptan
C	Lithium
D	Verapamil
E	Carbamazepine

7381

Submit

D Verapamil

Cluster headaches are characterised by severe unilateral orbital, supraorbital or temporal pain lasting 15 to 180 min. Attacks occur at a frequency between one every other day and eight per day, often occurring at night. Patients are typically restless during attacks. The headache is associated with ipsilateral autonomic symptoms, eg lacrimation, rhinorrhoea and nasal congestion. Attacks of cluster headaches typically persist over 4–12 weeks. Verapamil is the treatment of choice for the prevention of cluster headaches. The starting dose is usually 240 mg daily in three divided doses, titrating gradually to effect.

A Indomethacin

Indomethacin is the treatment of choice for hemicrania continua (HC), which is a condition of unilateral headache that is unremitting in nature, whereas this case describes recurrent, short-lived headaches.

B Sumatriptan

Subcutaneous or intra-nasal triptans, eg sumatriptan, are useful as acute therapy for aborting individual attacks of cluster headaches. They do not, however, reduce the duration of the period over which cluster attacks occur. 100% oxygen is also frequently used as an effective abortive therapy.

C Lithium

Lithium can be used as a preventative therapy for cluster headaches where verapamil is contra-indicated or not effective. It is not used as first-line therapy due to its narrow therapeutic window, side effect profile and monitoring requirements.

E Carbamazepine

Carbamazepine is indicated for the treatment of classical trigeminal neuralgia. Trigeminal neuralgia is typified by paroxysmal, stereotyped

Lithium can be used as a preventative therapy for cluster headaches where verapamil is contra-indicated or not effective. It is not used as first-line therapy due to its narrow therapeutic window, side effect profile and monitoring requirements.

E	Carbamazepine

Carbamazepine is indicated for the treatment of classical trigeminal neuralgia. Trigeminal neuralgia is typified by paroxysmal, stereotyped attacks of usually intense, sharp or stabbing pain in the distribution of one or more branches of the trigeminal nerve. The pain is usually maximal at onset and recurs in paroxysms lasting from a fraction of a second to two minutes. The headaches described in this case are much longer than those typically seen in trigeminal neuralgia.

7381

Rate this question:

A 28-year-old woman is referred by her GP for investigation of difficulty walking. She describes months of bilateral shooting arm pain worse on coughing. She has found her legs increasingly clumsy.

On examination, you note wasting of the intrinsic muscles of both hands, with flaccid tone and loss of reflexes. You also note cuts and burns to her fingers. The patient was not aware of injury. There is increased tone in the lower limbs with brisk reflexes and upgoing plantars.

On cranial nerve examination, you note ptosis of the left eye, tongue wasting and fasciculation. You organise appropriate imaging.

What abnormality do you expect to find?

A	Carotid artery dissection
B	Compressive cervical radiculomyelopathy

with flaccid tone and loss of reflexes. You also note cuts and burns to her fingers. The patient was not aware of injury. There is increased tone in the lower limbs with brisk reflexes and upgoing plantars.

On cranial nerve examination, you note ptosis of the left eye, tongue wasting and fasciculation. You organise appropriate imaging.

What abnormality do you expect to find?

A	Carotid artery dissection
B	Compressive cervical radiculomyelopathy
C	Fluid filled cavity within the central cord
D	Left upper lobe neoplasm
E	Cord infarction

A 28-year-old woman is referred by her GP for investigation of difficulty walking. She describes months of bilateral shooting arm pain worse on coughing. She has found her legs increasingly clumsy.

On examination, you note wasting of the intrinsic muscles of both hands, with flaccid tone and loss of reflexes. You also note cuts and burns to her fingers. The patient was not aware of injury. There is increased tone in the lower limbs with brisk reflexes and upgoing plantars.

On cranial nerve examination, you note ptosis of the left eye, tongue wasting and fasciculation. You organise appropriate imaging.

What abnormality do you expect to find?

Your answer was correct

A Carotid artery dissection

C Fluid filled cavity within the central cord

In this case a central syrinx at the cervical level will explain the lower motor neuron signs in the arms and spastic paraparesis of the legs. Extension of the syrinx upwards can cause a Horner syndrome and bulbar symptoms. The painless injuries seen in the hands are due to loss of pain and temperature sensation. The course of syringomyelia is slowly progressive, with occasional acute episodes. Sudden rises in pressure associated with coughing or sneezing are said to provoke extension of the syrinx. There is no curative treatment. Syringomyelia is often associated with herniation of the cerebellar tonsils – the Arnold–Chiari malformation.

A Carotid artery dissection

Whilst this could account for the ptosis (as part of Horner syndrome), it cannot account for bilateral upper limb lower motor neurone signs and lower limb

account for bilateral upper limb lower motor neurone signs and lower limb upper motor neurone signs.

B	Compressive cervical radiculomyelopathy

This could, in principle, account for the upper limb lower motor neurone signs (due to radicular compression) and the lower limb upper motor neurone signs (due to cord compression) but cannot explain the bulbar involvement.

D	Left upper lobe neoplasm

Whilst this could account for the ptosis (as part of Horner syndrome), it cannot account for bilateral upper limb lower motor neurone signs and lower limb upper motor neurone signs.

E	Cord infarction

The relatively chronic history is incompatible with this.

A 38-year old man is admitted to the Emergency Department with severe right occipital headache and neck pain, which came on acutely while he was playing rugby for his local team.

On examination, he has diminished sensation over the right side of his face, with ipsilateral facial weakness. He has diplopia on looking to the right. He has grade 4 power affecting his left arm and leg, with associated sensation loss. Coordination in his right hand is impaired. His blood pressure is 142/80 mmHg, pulse is 85 bpm and regular, and he is anxious.

What is the most likely diagnosis?

A	Basilar artery aneurysm
B	Cervical vertebral fracture
C	Subarachnoid haemorrhage
D	Vertebral artery dissection

playing rugby for his local team.

On examination, he has diminished sensation over the right side of his face, with ipsilateral facial weakness. He has diplopia on looking to the right. He has grade 4 power affecting his left arm and leg, with associated sensation loss. Coordination in his right hand is impaired. His blood pressure is 142/80 mmHg, pulse is 85 bpm and regular, and he is anxious.

What is the most likely diagnosis?

A	Basilar artery aneurysm
B	Cervical vertebral fracture
C	Subarachnoid haemorrhage
D	Vertebral artery dissection
E	Basilar artery dissection

7:52
:tps://mypastest.pastest.com 14

A 38-year old man is admitted to the Emergency Department with severe right occipital headache and neck pain, which came on acutely while he was playing rugby for his local team.

On examination, he has diminished sensation over the right side of his face, with ipsilateral facial weakness. He has diplopia on looking to the right. He has grade 4 power affecting his left arm and leg, with associated sensation loss. Coordination in his right hand is impaired. His blood pressure is 142/80 mmHg, pulse is 85 bpm and regular, and he is anxious.

What is the most likely diagnosis?

Your answer was correct

A	Basilar artery aneurysm

D Vertebral artery dissection

Vertebral artery dissection typically presents with severe occipital headache and neck pain following head or neck injury. The trauma is generally from a trivial mechanism, but is associated with some degree of cervical distortion. Focal neurological signs attributable to ischaemia of the brainstem and cerebellum ultimately develop in 85% of patients, although there may be a latent period of up to 3 days between the onset of pain and the development of central nervous system sequelae.

The commonest reported symptoms are attributable to lateral medullary dysfunction, including ipsilateral facial dysaesthesia, dysarthria or hoarseness, ipsilateral limb or trunk numbness, contralateral loss of pain and temperature sensation, ipsilateral loss of taste, vertigo, dysphagia, diplopia and disequilibrium. Rarely patients may manifest symptoms of a medial medullary syndrome: contralateral weakness/paralysis (pyramidal tract)

weakness/paralysis (pyramidal tract) and contralateral numbness (medial lemniscus). Ipsilateral Horner syndrome occurs in as many as one-third of patients.

Risk factors associated with vertebral artery dissection include spinal manipulation, yoga, ceiling painting, judo, nose blowing, minor neck trauma, fibromuscular dysplasia, cystic medial necrosis, oral contaceptive pill use, chronic headache syndromes and female sex.

A	Basilar artery aneurysm

Basilar artery aneurysms are uncommon, and only rarely rupture; as they increase in size they may present with a 3rd nerve palsy.

B	Cervical vertebral fracture

In cervical vertebral fracture, facial symptoms would not be expected.

Basilar artery aneurysms are uncommon, and only rarely rupture; as they increase in size they may present with a 3rd nerve palsy.

B	Cervical vertebral fracture

In cervical vertebral fracture, facial symptoms would not be expected.

C	Subarachnoid haemorrhage

In subarachnoid haemorrhage, lateralising signs would be unusual unless there is an ischaemic event due to secondary vasospasm.

E	Basilar artery dissection

Basilar artery dissection is very rare and is more likely to present with symptoms of a subarachnoid haemorrhage rather than the lateralising signs seen here.

A 20-year-old right-handed homeless man is admitted with a history of headache and malaise which has been worsening for the past 6–8 weeks. There s a history of previous examination to the hospital some 2 weeks earlier with confusion, but he self-discharged against medical advice.

On examination, his temperature is 39 °C. He is drowsy and confused and has neck stiffness and a positive Kernig's sign. Fundus examination reveals pink optic discs and small, white, glistening bodies on the retina. He has a ptosis of the right eye lid and the eye is deviated downward and laterally. Pupils are round and reactive to light and accommodation. Blinking is reduced on the left side and the nasolabial fold on the left side is smoothed.

Laboratory results are shown below:

WCC	6.0×10^9/l
Na^+	119 mmol/l
Urea	7.0 mmol/l
Glucose	5.5 mmol/l

Glucose	5.5 mmol/l
LFTs	Normal

Cerebrospinal fluid (CSF) opening pressure is 280 mm of H_2O. There are 128 white cells/mm^3, 90% lymphocytes, protein is 3.8 g/l and glucose is 1.2 mmol/l.

Computed tomography (CT) of the head reveals a dilated ventricular system and enhancement of the basal meninges.

What is the most likely diagnosis?

A	Tuberculous meningitis
B	Cryptococcal meningitis
C	Viral meningoencephalitis
D	Partially treated bacterial meningitis
E	Whipple's disease

8:23
tps://mypastest.pastest.com 14

WCC	6.0×10^9/l
Na^+	119 mmol/l
Urea	7.0 mmol/l
Glucose	5.5 mmol/l
LFTs	Normal

Cerebrospinal fluid (CSF) opening pressure is 280 mm of H_2O. There are 128 white cells/mm^3, 90% lymphocytes, protein is 3.8 g/l and glucose is 1.2 mmol/l.

Computed tomography (CT) of the head reveals a dilated ventricular system and enhancement of the basal meninges.

What is the most likely diagnosis?

Your answer was correct

A Tuberculous meningitis

A Tuberculous meningitis

Subacute meningitis raises the potential diagnoses of tuberculous meningitis or cryptococcal, histoplasmal, partially treated bacterial, neoplastic or granulomatous infiltration of the meninges. The clues to the diagnosis of TB meningitis include: subacute onset with confusion; presentation in a homeless person; involvement of the basal meninges (brainstem signs); associated secondary spinal meningitis; characteristic CSF findings, especially the very high protein and very low glucose. The low blood sodium of 119 mmol/l is suggestive of SIADH (secretion of inappropriate antidiuretic hormone). All of these parameters are suggestive of tuberculous infection, but India ink preparation, microbial cultures and immunodiagnostic tests on the CSF are important in confirming the final diagnosis. Despite this, an empirical treatment with four anti-TB agents (e.g. rifampicin, INH, pyrazinamide and ethambutol) is usually started when

ethambutol) is usually started when diagnosis is suspected on clinical grounds.

B	Cryptococcal meningitis

The CT scan points us away from cryptococcosis here; although MRI may be the better investigation, a CT scan would be expected to reveal pseudocysts, which are not seen here. The opening pressure and CSF features are also more severe than those usually seen for *Cryptococcus*.

C	Viral meningoencephalitis

The significantly elevated opening pressure, elevated protein and low glucose count against a viral cause for the presentation here.

D	Partially treated bacterial meningitis

There's no evidence that this patient was previously prescribed antibiotics.

C Viral meningoencephalitis

The significantly elevated opening pressure, elevated protein and low glucose count against a viral cause for the presentation here.

D Partially treated bacterial meningitis

There's no evidence that this patient was previously prescribed antibiotics, and the chronicity of his symptoms counts against partially treated conventional bacterial meningitis.

E Whipple's disease

Although Whipple's can present with neurological symptoms, significantly raised intracranial pressure isn't seen. Malabsorption symptoms and evidence of small joint polyarthritis are usually features.

A 48-year-old merchant seaman presents with recent weight loss of 2 kg. On further questioning, he complains that for some time he has also noticed painful sensations in his legs at night, reduced sensation in his feet and some problems with balanitis and urinary frequency.

On examination, he has diminished proprioception at the toes, his ankle reflexes are absent and a small area of painless ulceration is seen on the ventral aspect of the big toe. His body mass index (BMI) is 28 kg/m^2.

Nerve conduction studies (NCS) demonstrate reduced motor conduction velocities (75% of normal) in the legs, with small, poorly formed sensory nerve action potentials. Electromyography (EMG) shows evidence of active denervation in the lower limbs with positive sharp waves and fibrillations.

What is the most likely diagnosis?

A	Alcoholic neuropathy

mass index (BMI) is 28 kg/m².

Nerve conduction studies (NCS) demonstrate reduced motor conduction velocities (75% of normal) in the legs, with small, poorly formed sensory nerve action potentials. Electromyography (EMG) shows evidence of active denervation in the lower limbs with positive sharp waves and fibrillations.

What is the most likely diagnosis?

A	Alcoholic neuropathy
B	Diabetic neuropathy
C	Paraneoplastic neuropathy
D	Multifocal motor neuropathy (MMN)
E	Chronic inflammatory demyelinating polyneuropathy (CIDP)

A 48-year-old merchant seaman presents with recent weight loss of 2 kg. On further questioning, he complains that for some time he has also noticed painful sensations in his legs at night, reduced sensation in his feet and some problems with balanitis and urinary frequency.

On examination, he has diminished proprioception at the toes, his ankle reflexes are absent and a small area of painless ulceration is seen on the ventral aspect of the big toe. His body mass index (BMI) is 28 kg/m^2.

Nerve conduction studies (NCS) demonstrate reduced motor conduction velocities (75% of normal) in the legs, with small, poorly formed sensory nerve action potentials. Electromyography (EMG) shows evidence of active denervation in the lower limbs with positive sharp waves and fibrillations.

What is the most likely diagnosis?

Your answer was incorrect

B Diabetic neuropathy

Diabetic neuropathy can present in a myriad of ways, but the clinical and electrophysiological features here are typical of the most common presentation – that of a distal symmetric sensorimotor polyneuropathy with both axonal and demyelinating features. Autonomic dysfunction may also be present. The painless ulcer and history of urinary frequency are also clues as to the underlying aetiology in this case. Duloxetine and pregabalin are both potential systemic interventions to control pain.

E Chronic inflammatory demyelinating polyneuropathy (CIDP)

CIDP can be viewed as the chronic form of Guillain–Barré syndrome. The predominant neurophysiological finding is reduction in conduction velocities (rather than the mixed picture seen here). The active

denervation seen in this case would also be unusual for CIDP as the axon usually remains intact in CIDP, and thus the muscle is not denervated. The foot ulcers and urinary frequency are clues that the underlying cause in this case is diabetes.

A Alcoholic neuropathy

Painless ulcers virtually never occur in alcoholic neuropathy, which is associated with a pure axonal sensorimotor picture on electrophysiological studies.

C Paraneoplastic neuropathy

Whilst possible, especially given the history of weight loss, the urinary frequency is a clue that this patient in fact has diabetes. Furthermore, the most common neuropathies occurring as a paraneoplastic phenomenon are usually length dependent and axonal (i.e. reduced amplitudes of action potentials, but normal conduction

A 19-year-old rugby player presents to the Emergency Department the morning after a match. He complains of severe neck pain and an occipital headache for the past few hours. He also has pain and numbness on the right-hand side of his face, and reports altered sensation to heat and pain on the left-hand side of his body. He also has nausea, vomiting and vertigo.

On examination, his BP is 155/90 mmHg and he looks unwell. There is right-sided decreased sensation on his face, with loss of pain and temperature sensation over the left-hand side of his trunk. You can also demonstrate nystagmus.

Investigations:

Hb	13.1 g/dl
WCC	7.1×10^9/l
PLT	201×10^9/l
Na^+	142 mmol/l
K^+	4.5 mmol/l
Creatinine	100 umol/l

investigations:

Hb	13.1 g/dl
WCC	7.1×10^9/l
PLT	201×10^9/l
Na^+	142 mmol/l
K^+	4.5 mmol/l
Creatinine	100 μmol/l

What is the best investigation to determine the cause of his symptoms?

A MRI spinal cord

B CT head

C MRI and MRA brain

D CT head and lumbar puncture

E Carotid ultrasound

8:58
tps://mypastest.pastest.com 14

the Emergency Department the morning after a match. He complains of severe neck pain and an occipital headache for the past few hours. He also has pain and numbness on the right-hand side of his face, and reports altered sensation to heat and pain on the left-hand side of his body. He also has nausea, vomiting and vertigo.

On examination, his BP is 155/90 mmHg and he looks unwell. There is right-sided decreased sensation on his face, with loss of pain and temperature sensation over the left-hand side of his trunk. You can also demonstrate nystagmus.

Investigations:

Hb	13.1 g/dl
WCC	7.1×10^9/l
PLT	201×10^9/l
Na^+	142 mmol/l
K^+	4.5 mmol/l

C MRI and MRA brain

MRI is the best test to demonstrate posterior circulation stroke (a lateral medullary syndrome is described). The history here is very suggestive of vertebral artery dissection, which may present a few hours after the precipitant injury, most likely a blow to the back of the neck during the course of the rugby match. MRA is the imaging modality of choice.

A MRI spinal cord

In vertebral artery dissection, MRI of the spine would not provide evidence to determine the origin of the vascular event. Whilst it is a useful investigation for other emergencies such as spinal cord compression, it is of limited use here.

B CT head

A CT head may well be used in acute management here, primarily to exclude

management here, primarily to exclude a sub-arachnoid haemorrhage. However, it would not accurately demonstrate a posterior circulation stroke or identify the stroke's cause.

D	CT head and lumbar puncture

As discussed above, CT head may be used in an acute scenario but it is not the diagnostic imaging modality of choice. A lumbar puncture would only be used if sub-arachnoid was suspected. Vertebral artery dissection is the most likely diagnosis and therefore CT + LP is not the best answer.

E	Carotid ultrasound

Carotid ultrasound is used in post-TIA and -stroke management, when investigating anterior circulation events. This patient has had a posterior circulation event so this test is not helpful.

The history here is very suggestive of

circulation event so this test is not helpful.

The history here is very suggestive of vertebral artery dissection which may present a few hours after the precipitant injury, most likely a blow to the back of the neck during the course of the rugby match. MRI brain, the results of which are not given here, would be urgently required to show the nature and extent of the ischaemic lesion and to exclude other causes. (While urgent CT might well be performed as an initial step if out of hours MRI is not available, this would exclude a haemorrhagic lesion but would not explain the origin of the vascular event.) MRA is the diagnostic modality of choice; if negative and suspicion is still high, 4 vessel cerebral angiography can be arranged. Where there is no evidence of sub-arachnoid haemorrhage, anti-coagulation is the management of choice to prevent thromboembolic sequelae as a result of the dissection.

21459

Rate this question:

A 42-year-old man with a history of human immunodeficiency virus (HIV) infection presents with headache, neck stiffness and problems with his vision. His partner says that he has suffered from a cough and lost weight over the past 3 or 4 months.

On examination, he is pyrexial (37.6 °C) and his BP is 145/91 mmHg with a pulse of 85 bpm. He has bilateral papilloedema and bilateral 6th nerve palsy.

Investigations:

Hb	10.5 g/dl
WCC	9.7×10^9/l
PLT	175×10^9/l
Na^+	134 mmol/l
K^+	4.5 mmol/l
Creatinine	130 µmol/l
Tuberculin test	Negative
	Hydrocephalus, basilar

CT head	Hydrocephalus, basilar meningeal thickening, nodular enhancing lesion with a hypo-dense central portion
Lumbar puncture CSF	Normal protein, reduced glucose, no cells visualised, opening pressure slightly increased

Which of the following is the most likely diagnosis?

A	Meningococcal meningitis
B	Herpes simplex encephalitis
C	Cryptococcal meningitis
D	Tuberculous (TB) meningitis
E	Cytomegalovirus (CMV) encephalitis

His partner says that he has suffered from a cough and lost weight over the past 3 or 4 months.

On examination, he is pyrexial (37.6 °C) and his BP is 145/91 mmHg with a pulse of 85 bpm. He has bilateral papilloedema and bilateral 6th nerve palsy.

Investigations:

Hb	10.5 g/dl
WCC	9.7×10^9/l
PLT	175×10^9/l
Na^+	134 mmol/l
K^+	4.5 mmol/l
Creatinine	130 µmol/l
Tuberculin test	Negative
CT head	Hydrocephalus, basilar meningeal thickening, nodular enhancing lesion with a hypo-dense central portion

D	Tuberculous (TB) meningitis

The key points from the history are the subacute onset, with weight loss and cough, which hints at the possibility of TB. The findings on CT head are entirely consistent with this. A negative tuberculin test does not exclude the possibility of TB, particularly in patients who are immunocompromised. Up to 16% of patients with HIV may have acellular cerebrospinal fluid (CSF), and nearly half may have a normal CSF protein level. Around 80% of CSF samples are positive for TB after culture, although PCR is now allowing for more rapid diagnosis.

A	Meningococcal meningitis

The subacute nature of this patient's symptoms is inconsistent with a diagnosis of meningococcal meningitis. A more rapid deterioration with bacterial septicaemia would be expected. The CT head is also very consistent with TB meningitis.

B Herpes simplex encephalitis

In herpes simplex encephalitis temporal lobe changes are usually seen, and the deterioration is more rapid than that observed here.

C Cryptococcal meningitis

Cryptococcal meningitis displays leptomeningeal enhancement on MRI, and is commonly associated with hydrocephalus. A more marked increase in CSF opening pressure would be expected.

E Cytomegalovirus (CMV) encephalitis

The position of changes on the CT here are more consistent with TB meningitis than CMV encephalitis, and in CMV infection ventricular enlargement with ependymal enhancement is usually seen.

A 56-year-old woman attends the Chest Clinic following chemotherapy for a localised small cell lung carcinoma. She complains of gradual-onset limb weakness and muscle tenderness, associated with intermittent diplopia.

On examination, she has a right-sided ptosis, proximal myopathy and reduced tendon reflexes.

Which neuroimmunological test would most help in diagnosis?

A	Anti-Yo
B	Anti-AChR (acetylcholine receptor)
C	Anti-Hu
D	Anti-Purkinje cell
E	Anti-VGCC (voltage-gated calcium channel)

9:12
tps://mypastest.pastest.com 14

A 56-year-old woman attends the Chest Clinic following chemotherapy for a localised small cell lung carcinoma. She complains of gradual-onset limb weakness and muscle tenderness, associated with intermittent diplopia.

On examination, she has a right-sided ptosis, proximal myopathy and reduced tendon reflexes.

Which neuroimmunological test would most help in diagnosis?

Your answer was correct

A	Anti-Yo
B	Anti-AChR (acetylcholine receptor)
C	Anti-Hu

E	Anti-VGCC (voltage-gated calcium channel)

The clinical picture is Lambert–Eaton myasthenic syndrome (LEMS). This is an autoimmune paraneoplastic phenomenon most often associated with small cell lung cancer (SCLC). LEMS can present up to 2 years before a primary is discovered, and in a minority of cases no primary is ever found. Clinical features of LEMS are weakness and pain especially in limb girdle muscle groups. Ocular-bulbar features are usually less severe than in myasthenia gravis. The underlying pathophysiology involves production of auto-antibodies against voltage-gated calcium channels (VGCC) at the neuromuscular junction.

A	Anti-Yo

Anti-Yo antibodies are associated with cerebellar degeneration and are especially seen in lung and gynaecological malignancy.

especially seen in lung and gynaecological malignancy.

B	Anti-AChR (acetylcholine receptor)

These are associated with thymoma and occur in myasthenia gravis.

C	Anti-Hu

Anti-Hu antibodies are associated with small cell lung cancer and lead to encephalomyositis or sensory neuropathy associated with small cell lung cancer.

D	Anti-Purkinje cell

These are associated with small cell lung cancer and lead to cerebellar degeneration.

7338

Rate this question:

A 48-year-old woman presents to the Neurology Clinic for review. She suffers 8–10 paroxysms of pain affecting the left side of her face each day. These feel like a severe, stabbing pain in her left cheek and last from a few seconds to 1–2 minutes. She denies eye-watering, conjunctival injection and nasal stuffiness. Cleaning her teeth with an electric toothbrush brings on the attacks, as can drinking a cold drink containing ice cubes. There is a past history of reflux oesophagitis for which she takes pantoprazole, but nil else of note.

Clinical examination is entirely normal, as are basic haematological and biochemical investigations.

Which of the following is the most appropriate initial therapy?

A	Amitriptyline
B	Carbamazepine
C	Gabapentin

watering, conjunctival injection and nasal stuffiness. Cleaning her teeth with an electric toothbrush brings on the attacks, as can drinking a cold drink containing ice cubes. There is a past history of reflux oesophagitis for which she takes pantoprazole, but nil else of note.

Clinical examination is entirely normal, as are basic haematological and biochemical investigations.

Which of the following is the most appropriate initial therapy?

A	Amitriptyline
B	Carbamazepine
C	Gabapentin
D	Propranolol
E	Sodium valproate

9:16
tps://mypastest.pastest.com 14

A 48-year-old woman presents to the Neurology Clinic for review. She suffers 8–10 paroxysms of pain affecting the left side of her face each day. These feel like a severe, stabbing pain in her left cheek and last from a few seconds to 1–2 minutes. She denies eye-watering, conjunctival injection and nasal stuffiness. Cleaning her teeth with an electric toothbrush brings on the attacks, as can drinking a cold drink containing ice cubes. There is a past history of reflux oesophagitis for which she takes pantoprazole, but nil else of note.

Clinical examination is entirely normal, as are basic haematological and biochemical investigations.

Which of the following is the most appropriate initial therapy?

Your answer was correct

B Carbamazepine

This patient presents with classic trigeminal neuralgia, the IHS diagnostic criteria for which are shown below.

A) At least three attacks of unilateral facial pain fulfilling criteria B and C

B) Occurring in one or more divisions of the trigeminal nerve, with no radiation beyond the trigeminal distribution

C) Pain has at least three of the following four characteristics:

- Recurring in paroxysmal attacks lasting from a fraction of a second to two minutes
- Severe intensity
- Electric shock-like, shooting, stabbing or sharp in quality
- At least three attacks precipitated by innocuous stimuli to the affected side of the face (some attacks may be, or appear to be, spontaneous)

D) No clinically evident neurologic deficit

There are significant mimics of TN which should be excluded on a first presentation; these include acute herpes zoster (or post-herpetic pain); trauma to the trigeminal nerve; demyelination; and vascular compression or space-occupying lesion causing trigeminal neuropathy. Therefore a careful history, neurological examination and MRI brain scan should be undertaken. Other primary headache disorders that should be considered include short-lasting unilateral neuralgiform headache attacks with conjunctival injection and tearing (SUNCT); short-lasting unilateral neuralgiform headache attacks with autonomic symptoms (SUNA); and primary stabbing headache. Pharmacological therapy is the initial treatment in most patients with trigeminal neuralgia, and carbamazepine has the most evidence base. Other options include oxcarbazepine, baclofen, lamotrigine,

oxcarbazepine, baclofen, lamotrigine, topical lidocaine and pimozide. Surgical options in refractory cases include microvascular decompression and ablative procedures such as rhizotomy, radiosurgery and peripheral neurectomy.

A Amitriptyline

Amitriptyline is commonly used in the prevention of migraine. This patient does not fulfil the criteria for migraine.

C Gabapentin

Gabapentin is sometimes used in the prevention of migraine. This patient does not fulfil the criteria for migraine.

D Propranolol

It is commonly used in the prevention of migraine. This patient does not fulfil the criteria for migraine.

A 55-year-old man presents to the General Medical Clinic with a 6-month history of hand weakness, cramping leg pain and neck pain. He has had difficulty working as a gardener because he has been dropping his tools. His wife feels that he has also been forgetful and his behaviour has become increasingly unpredictable. He has no significant past medical history and does not take any medication regularly.

On examination, there is no muscle wasting, but occasional fasciculations are visible in the lower limbs. There is mild spasticity of all four limbs with brisk reflexes throughout, and down-going plantar responses bilaterally. There is grade 3/5 weakness in the muscles of both hands, with reduced speed and accuracy of movements. There are no sensory findings. Cardiovascular, respiratory and abdominal examinations are unremarkable. There is a mild deficit on bedside cognitive testing (MMT 26/30) and he appears to respond inappropriately to some questions.

muscles of both hands, with reduced speed and accuracy of movements. There are no sensory findings. Cardiovascular, respiratory and abdominal examinations are unremarkable. There is a mild deficit on bedside cognitive testing (MMT 26/30) and he appears to respond inappropriately to some questions.

Which one of the following investigations would be the most useful for establishing the diagnosis in this case?

A	MRI brain and cervical spine
B	Auto-antibody screen
C	Serum B_{12}
D	Nerve conduction studies and electromyography
E	Myelography

D	Nerve conduction studies and electromyography

The examination findings of mixed upper and lower motor neurone pattern signs with no sensory impairment in this case are suggestive of a diagnosis of motor neurone disease (MND). This can occur with symptoms of frontotemporal dementia, which would explain this patient's reduced cognition and abnormal behaviour. Nerve conduction studies and electromyography (EMG) can be helpful to confirm the presence of a lower motor neuron lesion pattern, with acute and chronic denervation, which would support the diagnosis of motor neurone disease.

A	MRI brain and cervical spine

It is common practice to perform structural imaging when investigating MND. The purpose of this is to exclude other conditions rather than to make a positive diagnosis of MND.

B Auto-antibody screen

This investigation would not help make a diagnosis of MND. Vasculitis and SLE are both conditions that can affect the neurological system and may be identified by this investigation. However, a connective tissue disease would not produce this pure motor disorder and there would likely be other features in the history in keeping with systemic disease.

C Serum B_{12}

This investigation would not help make a diagnosis of MND. B_{12} deficiency may result in sensory and motor deficits and symptoms of dementia. It is associated with subacute combined degeneration of the cord, which presents with spastic paraparesis, sensory loss, absent ankle jerks and up-going plantar responses.

E Myelography

C	Serum B_{12}

This investigation would not help make a diagnosis of MND. B_{12} deficiency may result in sensory and motor deficits and symptoms of dementia. It is associated with subacute combined degeneration of the cord, which presents with spastic paraparesis, sensory loss, absent ankle jerks and up-going plantar responses.

E	Myelography

This investigation would not help make a diagnosis of MND. It would help identify pathology of the spinal cord, including syringomyelia and spinal cord compression. These conditions would present with upper motor neurone signs, and sensory symptoms would also be expected.

32705

Rate this question:

You review a 26-year-old woman who presents with transient disturbances of vision and frequent headaches. She also reports dizziness and diplopia on a number of occasions. She has a body mass index (BMI) of 32. On examination there is bilateral papilloedema. A computed tomography (CT) scan reveals no mass lesion and lumbar puncture reveals a raised opening pressure. You suspect idiopathic intracranial hypertension (IIH).

Which of the following risk factors is related to increased incidence of idiopathic intracranial hypertension?

A	Atenolol
B	Bendroflumethiazide
C	Vitamin A excess
D	Vitamin B excess
E	Vitamin C excess

C Vitamin A excess

Idiopathic intracranial hypertension has a female predominance, with estimates of the female to male sex ratio ranging between 2:1 and 10:1, presenting most commonly in the third decade. (The term 'idiopathic' is now preferred to 'benign', as the clinical course may have significant morbidity). Incidence is increased in patients who have a markedly raised BMI. Drug causes include contraceptive hormones, vitamin A excess, dopamine agonists, antibiotics, phenytoin and a number of other agents. However, the underlying pathophysiology is poorly understood. Diagnosis is via CT or magnetic resonance imaging (MRI) scans to rule out a space-occupying lesion, MR venography to exclude venous thrombosis and lumbar puncture with opening pressure measurement. Weight management is the cornerstone of treatment, coupled with withdrawal of any precipitating pharmacological agent. Diuretics

(acetazolamide) may also be used to good effect and therapeutic lumbar puncture is also of value.

A Atenolol

Atenolol, which is a beta blocker, is useful for treatment of angina and hypertension but has no role in idiopathic intracranial hypertension.

B Bendroflumethiazide

Acetazolamide, and not bendroflumethiazide, is useful for treatment of idiopathic intracranial hypertension.

D Vitamin B excess

People almost never get too much vitamin B from food, but taking high levels of certain B vitamins (such as B_6) from supplements can cause severe peripheral neuropathy.

A 58-year-old obese man (body mass index 38) continues to have transient ischaemic attacks despite being on aspirin 75 mg. Four years earlier, he suffered a minor stroke which left him with permanent loss of balance.

Blood pressure is relatively well controlled on ramipril, at 145/82 mmHg, and fasting blood glucose is 5.0 mmol/l. He remained in sinus rhythm throughout a 48 h electrocardiogram (ECG) Holter monitor.

Which of the following represents the optimal treatment for this man according to the National Institute for Health and Care Excellence (NICE) clinical guidelines for stroke?

A	Aspirin 150 mg
B	Clopidogrel 75 mg
C	Aspirin 75 mg and dipyridamole 100 mg

Blood pressure is relatively well controlled on ramipril, at 145/82 mmHg, and fasting blood glucose is 5.0 mmol/l. He remained in sinus rhythm throughout a 48 h electrocardiogram (ECG) Holter monitor.

Which of the following represents the optimal treatment for this man according to the National Institute for Health and Care Excellence (NICE) clinical guidelines for stroke?

A	Aspirin 150 mg
B	Clopidogrel 75 mg
C	Aspirin 75 mg and dipyridamole 100 mg
D	Warfarin
E	Aspirin 300 mg

B Clopidogrel 75 mg

NICE guidelines have now been harmonised such that clopidogrel 75 mg is recommended as the secondary prevention anti-platelet agent of choice for patients who are in sinus rhythm and do not fit the criteria for carotid endarterectomy.

A Aspirin 150 mg

Aspirin 150 mg is not significantly more effective compared to 75 mg daily dosing, and may increase the risk of upper gastrointestinal haemorrhage versus the lower dose regimen.

C Aspirin 75 mg and dipyridamole 100 mg

Aspirin and dipyridamole in combination was recommended as standard secondary prevention therapy after the ESPS2 study confirmed its effectiveness against further strokes, although it has now

C	Aspirin 75 mg and dipyridamole 100 mg

Aspirin and dipyridamole in combination was recommended as standard secondary prevention therapy after the ESPS2 study confirmed its effectiveness against further strokes, although it has now been superseded by clopidogrel.

D	Warfarin

In the presence of sinus rhythm, formal anticoagulation doesn't offer any advantage above anti-platelet therapy.

E	Aspirin 300 mg

High-dose aspirin significantly increases the chance of upper GI haemorrhage when used chronically versus the 75 mg dose, and is therefore not an appropriate option for secondary prevention.

6616

Rate this question:

You are asked to see a patient on the Rehabilitation Ward who has just been transferred from the Stroke Unit; you perform a neurological examination on the patient to assess the effects of the stroke.

The positive findings from this neurological examination include nystagmus and involvement of the right fifth cranial nerve. The patient has an impaired gag reflex and sluggish palatal movement, with obvious dysphagia. Limb examination reveals altered sensation in the left arm and leg with ataxia in the right arm and leg.

Infarction of which vessel is most likely to have caused this patient's stroke and subsequent neurological symptoms?

A	Anterior cerebral artery
B	Middle cerebral artery
C	Posterior cerebral artery

The positive findings from this neurological examination include nystagmus and involvement of the right fifth cranial nerve. The patient has an impaired gag reflex and sluggish palatal movement, with obvious dysphagia. Limb examination reveals altered sensation in the left arm and leg with ataxia in the right arm and leg.

Infarction of which vessel is most likely to have caused this patient's stroke and subsequent neurological symptoms?

A	Anterior cerebral artery
B	Middle cerebral artery
C	Posterior cerebral artery
D	Anterior superior cerebellar artery
E	Posterior inferior cerebellar artery

E	Posterior inferior cerebellar artery

Lateral medullary syndrome (Wallenberg syndrome) results from infarction of the lateral medulla and the inferior surface of the cerebellum. The deficits are due to involvement of one side of the nucleus ambiguous, trigeminal nucleus, vestibular nuclei, cerebellar peduncle, spinothalamic tract and autonomic fibres. These deficits consist of nystagmus, ipsilateral involvement of the V and VIII cranial nerves, ipsilateral Horner syndrome, ipsilateral ataxia and a crossed pattern of sensory loss (pain and temperature sensory loss on ipsilateral face and contralateral trunk and limbs). Any one of the five following arteries can be occluded: posterior inferior cerebellar, vertebral, superior, middle or inferior lateral medullary.

A	Anterior cerebral artery

The signs in this case clearly suggest a posterior circulation stroke, so this cannot be correct. Anterior cerebral artery strokes present with contralateral lower limb weakness.

B Middle cerebral artery

The signs in this case clearly suggest a posterior circulation stroke, so this cannot be correct. Middle cerebral artery strokes present with contralateral hemiparesis and aphasia (if dominant hemisphere) or neglect (if non-dominant).

C Posterior cerebral artery

An occlusion of this artery would typically cause a macular-sparing homonymous hemianopia.

D Anterior superior cerebellar artery

Occlusion of this vessel results in contralateral ataxia, but no brainstem

A 24-year-old legal secretary is referred by her general practitioner (GP) complaining of tremulousness of both hands. Her symptoms have deteriorated over the past 6 months leading to difficulties with typing at work. She has been increasingly distressed by her symptoms, and drinks alcohol on most evenings.

In her past medical history, she reports a miscarriage three years ago. She is currently taking the oral contraceptive pill and is on no other regular medications. She reports that her mother experiences similar tremors and that her aunt had a tremor affecting her head. Both drink alcohol heavily.

On examination, she has a prominent rhythmic tremor of both hands and forearms, much worse when she tries to perform basic tasks like drinking a cup of tea. The remainder of the examination is otherwise unremarkable.

Investigation results are as follows:

Hb	142 g/l

Hb	142 g/l
WCC	6.7×10^9/l
PLT	224×10^9/l
Na+	143 mmol/l
K+	4.2 mmol/l
Creatinine	118 µmol/l
Haematocritt	0.503 l/l
Urea	5.6 mmol/l
Bilirubin	10 mmol/l
ALT	50 U/l
ALP	125 U/l
Albumin	48 U/l

What is the best management option for this patient?

A	Referral to alcohol cessation services
B	Trial of diazepam

Haematocritt	0.503 l/l
Urea	5.6 mmol/l
Bilirubin	10 mmol/l
ALT	50 U/l
ALP	125 U/l
Albumin	48 U/l

What is the best management option for this patient?

A	Referral to alcohol cessation services
B	Trial of diazepam
C	Trial of propranolol
D	Trial of levodopa
E	Referral for relaxation therapy

C Trial of propranolol

Tremor is one of the most common neurological disorders and essential tremor (ET) is the most common form of tremor. It is a rhythmic and oscillatory movement, most commonly of the hands, with a relatively constant frequency and variable amplitude. It can also be seen in the head, voice and face.

The tremor often gets worse with age and it is common to have other family members that are similarly affected with essential tremor. The tremor gets worse with movements, such as writing or drinking tea, whereas parkinsonism often improves on these tasks. Alcohol has been reported to help the tremor.

Treatment should be offered to patients with ET who have intermittent or persistent disability caused by tremor. First-line treatments include propranolol and primidone, both of which have been shown to significantly reduce tremor. They are not effective in about 30% of cases where both treatments are tried together.

A	Referral to alcohol cessation services

This may be helpful for this lady to receive, but is highly unlikely to help her tremor in itself. She should definitely be advised to cut down her alcohol intake and may benefit from support in doing so.

B	Trial of diazepam

This will lead to muscle relaxation, which may help her tremor slightly but it is not recommended for essential tremor and has unpleasant side effects including drowsiness and addiction.

D	Trial of levodopa

This would be a treatment option for Parkinson's disease, another neurological disorder that has symptoms that include a tremor. However, one would expect to see evidence of asymmetric upper limb rigidity, bradykinesia and rest tremor in

A 43-year-old African-Caribbean woman presented with a 12-month history of progressive dysphagia and change in voice character. She also described a 2-year history of dry cough.

On examination, she had nasal speech, a decreased gag reflex on the left, palatal weakness, atrophy of the left side of the tongue with deviation to the left, but otherwise normal cranial nerves. Limb examination was normal.

What is the most likely diagnosis?

A	Systemic lupus erythematosus (SLE)
B	Multiple sclerosis (MS)
C	Motor neurone disease (MND)
D	Myasthenia gravis
E	Sarcoidosis

9:44
tps://mypastest.pastest.com 14

A 43-year-old African-Caribbean woman presented with a 12-month history of progressive dysphagia and change in voice character. She also described a 2-year history of dry cough.

On examination, she had nasal speech, a decreased gag reflex on the left, palatal weakness, atrophy of the left side of the tongue with deviation to the left, but otherwise normal cranial nerves. Limb examination was normal.

What is the most likely diagnosis?

Your answer was correct

A	Systemic lupus erythematosus (SLE)
B	Multiple sclerosis (MS)
C	Motor neurone disease (MND)

E	Sarcoidosis

Sarcoidosis can cause a basal meningitis and therefore lower cranial nerve palsies, and can also cause a dry cough. The annual incidence of sarcoidosis in Europe is somewhere between 10 and 40 per 100 000, although there is large geographical variation. Around 5% of patients with sarcoidosis will have neurological complications – in addition to cranial nerve palsies, these may include: optic neuritis, mononeuritis multiplex, myelopathy, seizures, granulomas causing mass effect and neuropsychiatric manifestations.

A	Systemic lupus erythematosus (SLE)

The lack of the typical photosensitive malar rash of SLE would make this diagnosis unlikely. An extraordinarily wide variety of neurological and neuropsychiatric manifestations of SLE are said to occur. However, selective palsies of the lower cranial nerves are

B	Multiple sclerosis (MS)

MS is very unlikely here. First, the progressive nature of the described syndrome would be unusual for MS, which usually presents as a 'relapsing-remitting' phenomenon. Second, MS is a disease purely of the central nervous system. Thus, whilst cranial nerve signs can be found in patients with MS, these are caused by inflammation within the brain or brainstem. It would be quite unusual to have inflammation in these locations without any signs evident in the limbs. This case also describes a left-sided hypoglossal nerve palsy. The cause of this is much more likely to be a lesion along the course of the hypoglossal nerve rather than a lesion within the brainstem.

C	Motor neurone disease (MND)

MND might be considered, especially if the bulbar signs are viewed in isolation. However, the associated dry cough (indicating pulmonary disease) and lack of signs in the limbs makes

a lesion along the course of the hypoglossal nerve rather than a lesion within the brainstem.

C	Motor neurone disease (MND)

MND might be considered, especially if the bulbar signs are viewed in isolation. However, the associated dry cough (indicating pulmonary disease) and lack of signs in the limbs makes this possibility less likely.

D	Myasthenia gravis

Bulbar failure is a common feature of generalised myasthenia gravis, but rarely occurs in isolation; there is no history of fatigable limb weakness or ophthalmoplegia described in this case, making this option unlikely. In addition, atrophy of muscles is not seen in myasthenia gravis.

6959

Rate this question:

A 34-year-old man complained of a 6-month history of feeling depressed and a feeling of people following him wherever he goes. He had previously been well and been taking no prescription medication, although he admits to smoking cannabis intermittently since being a teenager and more frequently in the last 6 months. The onset of the illness was not long after hearing that his father had committed suicide 10 months ago.

On neurological examination, he had infrequent facial grimacing and writhing limb movements. Tone, power and reflexes were all normal. Cranial nerve examination was normal, apart from slowed saccadic eye movements and difficulty in maintaining tongue protrusion.

Which of the following is the best way to confirm the likely diagnosis?

A	Blood film
B	Urine toxicology screen

and more frequently in the last 6 months. The onset of the illness was not long after hearing that his father had committed suicide 10 months ago.

On neurological examination, he had infrequent facial grimacing and writhing limb movements. Tone, power and reflexes were all normal. Cranial nerve examination was normal, apart from slowed saccadic eye movements and difficulty in maintaining tongue protrusion.

Which of the following is the best way to confirm the likely diagnosis?

A	Blood film
B	Urine toxicology screen
C	Genetic testing
D	Brain MRI
E	Copper studies

been well and been taking no prescription medication, although he admits to smoking cannabis intermittently since being a teenager and more frequently in the last 6 months. The onset of the illness was not long after hearing that his father had committed suicide 10 months ago.

On neurological examination, he had infrequent facial grimacing and writhing limb movements. Tone, power and reflexes were all normal. Cranial nerve examination was normal, apart from slowed saccadic eye movements and difficulty in maintaining tongue protrusion.

Which of the following is the best way to confirm the likely diagnosis?

Your answer was correct

A Blood film

B Urine toxicology screen

C Genetic testing

C Genetic testing

The most likely diagnosis here is Huntington's disease, which would be confirmed with genetic testing. This is an autosomal dominant disorder with 100% penetrance: his father is likely also to have had Huntington's in this example – the suicide rate is five times that of the general population. It is a trinucleotide repeat disorder and shows anticipation, i.e. it presents earlier and with increased severity in successive generations. The disease is characterised by the triad of movement disorders, behavioural disturbance and cognitive impairment. The movement disorder most commonly seen is that of chorea, although dystonia and myoclonus are also seen. Eye movement disorders, such as slow saccades, are also found. The most frequent behavioural disturbance seen is affective in nature, with depression in up to 50% of patients. Psychosis and particularly paranoid delusions are also common. Cognitive impairment is probably inevitable in all cases. There is no

inevitable in all cases. There is no curative treatment.

A Blood film

A blood film may be of value in the investigation of chorea-acanthocytosis, which can present with clinical features similar to Huntington's disease. It does, however, carry an autosomal recessive pattern of inheritance. It would be expected therefore that his father would be unaffected by the condition.

B Urine toxicology screen

Although drug abuse is a possible cause of movement disorder (dystonia, chorea, tics and myoclonus have all been described in patients with MDMA (3,4-methylenedioxy-methamphetamine) abuse), it seems unlikely here.

D Brain MRI

A 42-year-old homeless man is brought to the Emergency Department by the police. He was asked to move on from a shop doorway when he claimed he was ill, with a headache, vomiting and neck and arm stiffness.

On examination, he is pyrexial (37.8 °C). He has signs of mild meningism. Ophthalmoscopy reveals a small, grey-white choroidal nodule on the right-hand side. Bilateral lateral rectus palsies are observed. Following neuroimaging, lumbar puncture is performed.

Investigations:

Hb	13.2 g/dl
WCC	10.1×10^9/l
PLT	205×10^9/l
Na^+	129 mmol/l
K^+	4.0 mmol/l
Creatinine	95 μmol/l
Glucose	5.7 mmol/l
	Small nodular enhancing

MRI brain	Small nodular enhancing lesion
Chest X-ray	Left upper lobe fibrosis/consolidation

CSF analysis:

Protein	0.95 g/dl
Cell count	56/mm^3 (lymphocytes)
Glucose	2.0 mmol/l

Which of the following is the most likely diagnosis?

A	Herpes simplex encephalitis
B	Neurosyphillis
C	Primary brain tumour
D	Tuberculous meningitis
E	Neurosarcoidosis

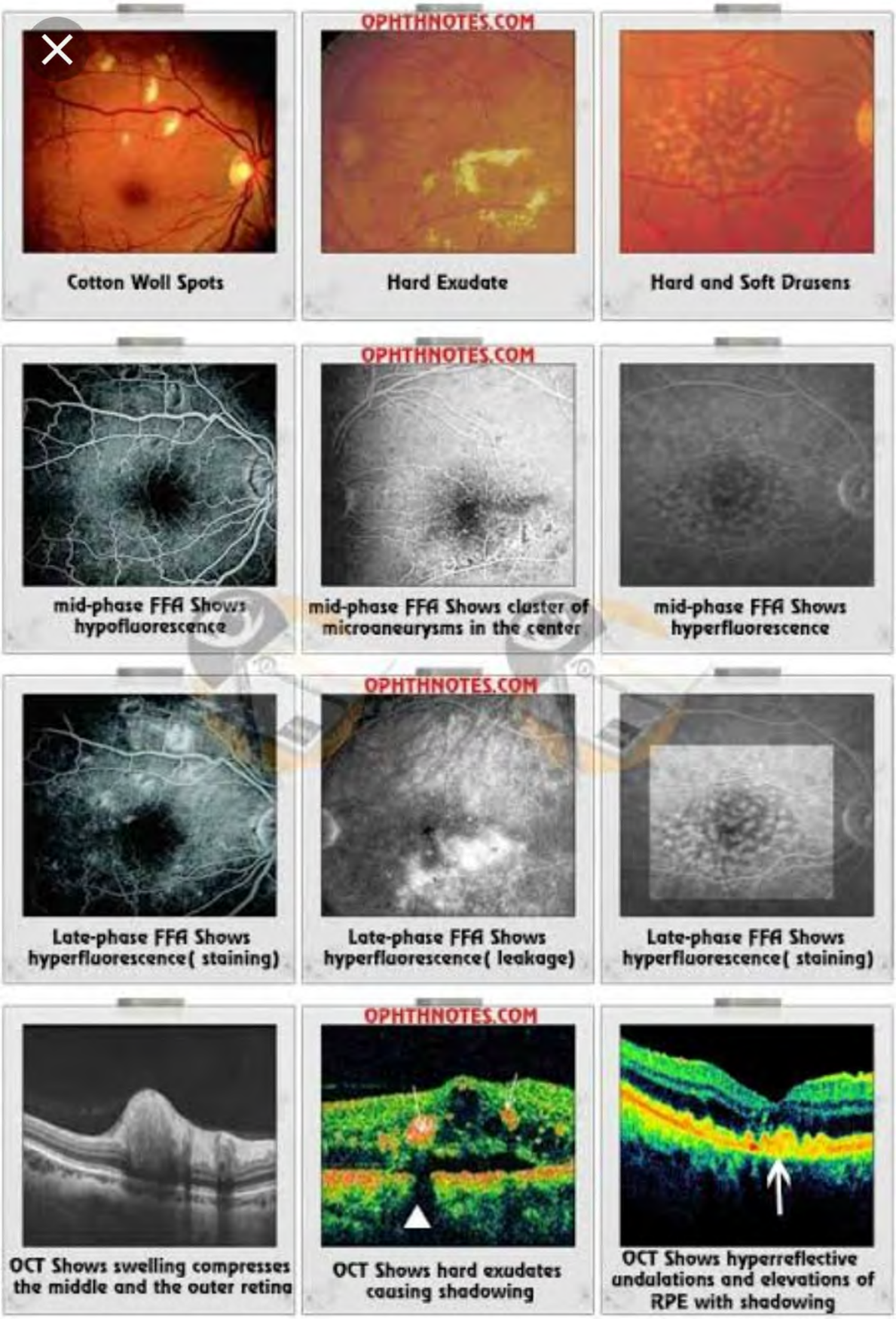

Ophthalmology Notes

Yellow White Retinal Lesion Differential Diagnosis

Images may be subject to copyright. Learn More

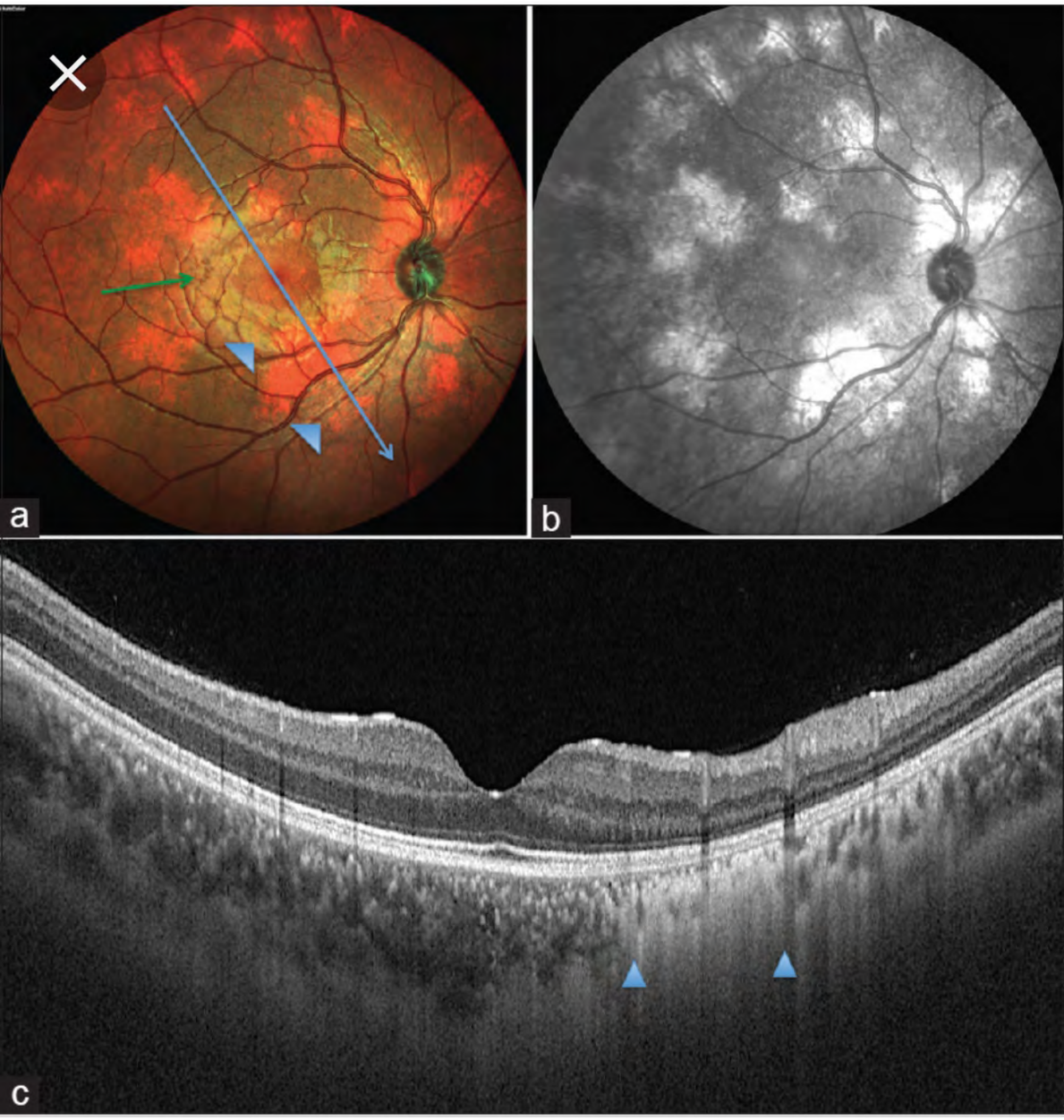

www.ijo.in

Multimodal imaging of choroidal nodules in neurofibromatosis ty...

Images may be subject to copyright. Learn More

RELATED IMAGES

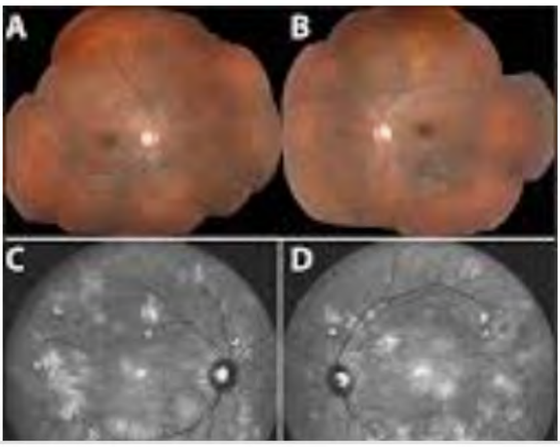

10:00
https://www.google.com/search?
14

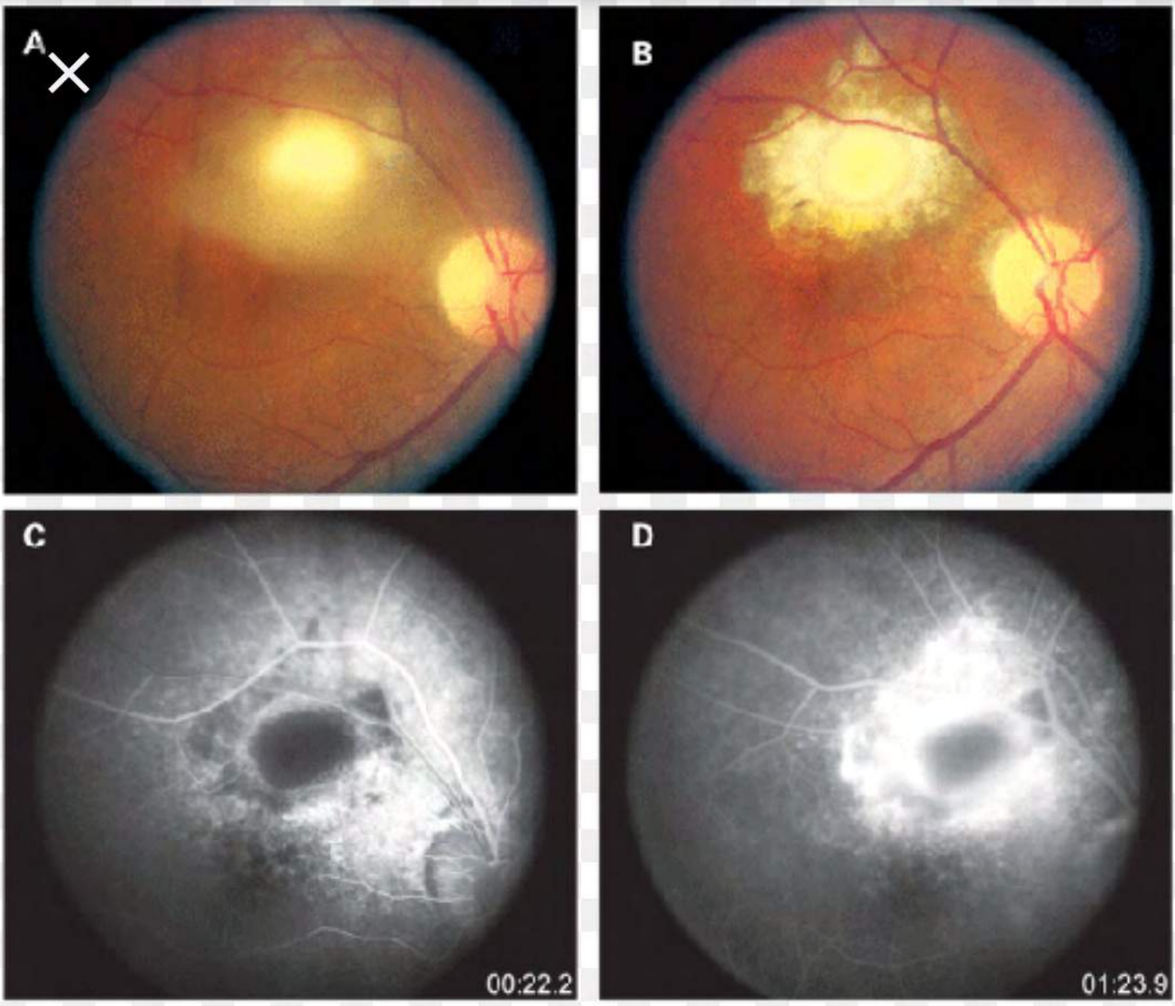

www.reviewofophthalmol...

Tuberculosis: Intraocular Involvement

Images may be subject to copyright. Learn More

RELATED IMAGES

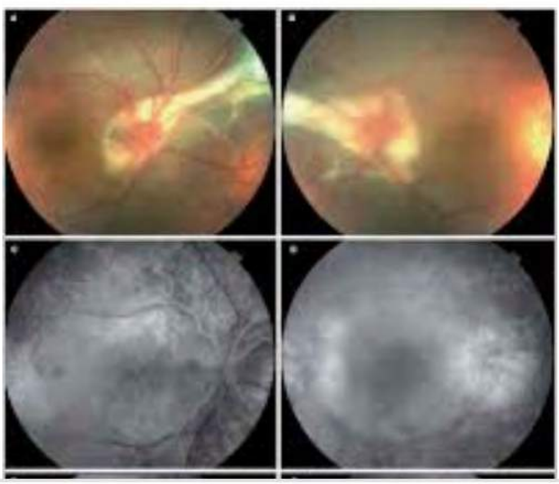

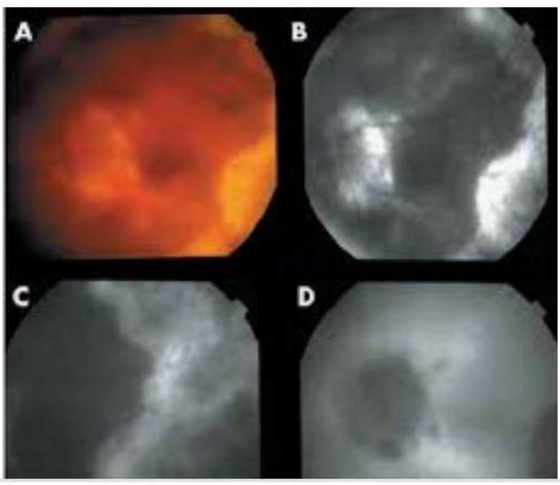

10:01
www.ijmr.org.in/viewimage.a
14
Close
Indian Journal of Medical Research

Figure 4: Chest radiograph (postero-anterior view) (A) and chest CT (lung window) (B) showing classical miliary pattern, tree-in-bud appearance (B) (arrow). The patient also had cerebral tuberculomas (arrows) and TB meningitis (C) . Choroid tubercles, located in the posterior pole of the orbit (D) (arrows) offered an early valuable clue to the diagnosis. The present case illustrates the importance of documenting the presence of neurological involvement, particularly, TB meningitis in patients with miliary TB and thereby ensuring adequate duration of anti-tuberculosis treatment and need for corticosteroid treatment.

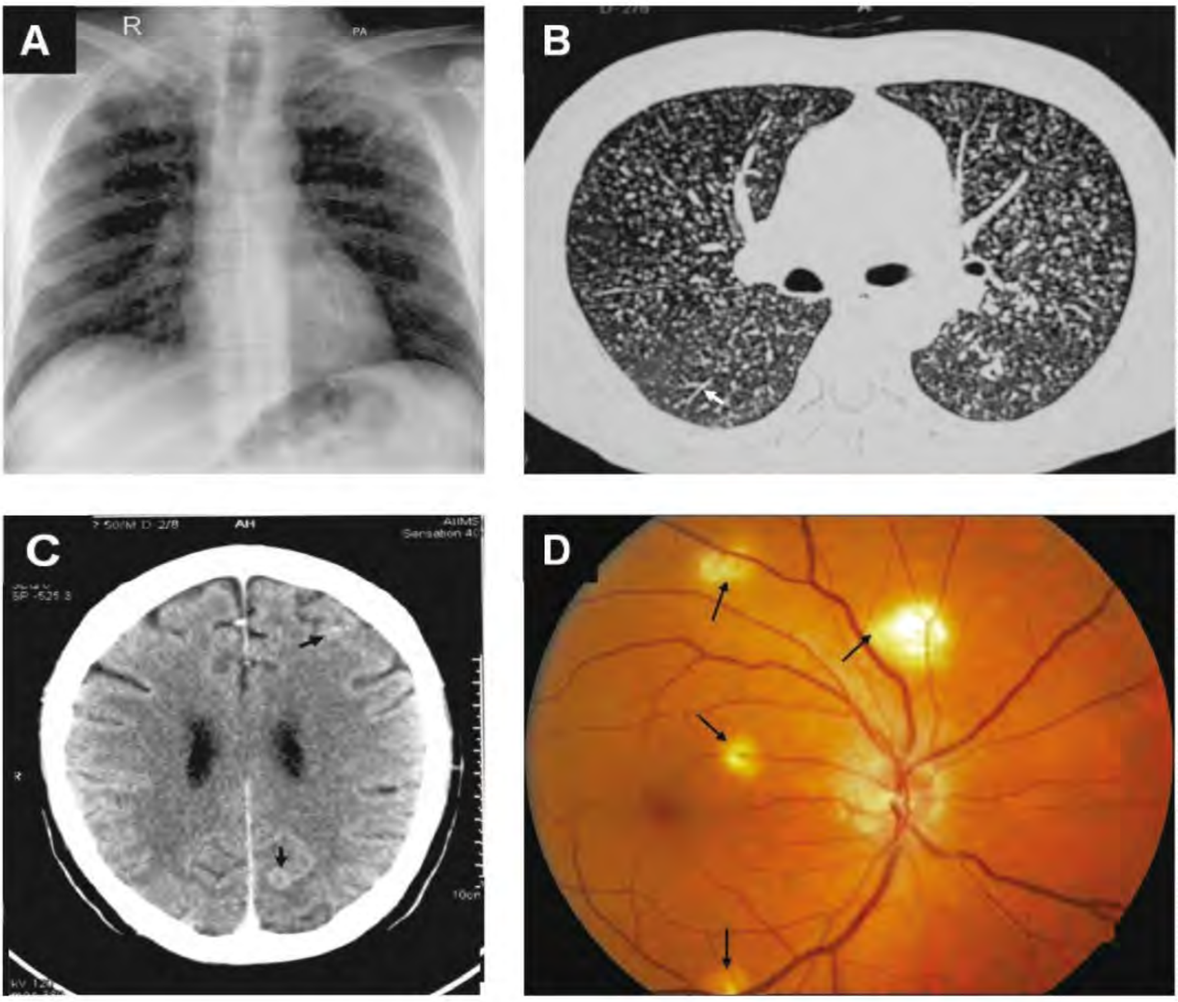

D Tuberculous meningitis

The clinical picture of a homeless man, with CXR changes suggestive of tuberculosis infection and a lymphocytic meningitis, supports the diagnosis of tuberculous meningitis. VI nerve palsies and SIADH are common findings. The onset of meningitis may be acute or chronic. Culture for TB is positive in 50–80% of meningitis patients with the condition. At least 12 months of combination antibacterial therapy, plus initial dexamethasone, is recommended.

A Herpes simplex encephalitis

Herpes simplex encephalitis is associated with predominantly temporal lobe changes more likely to be seen on an MRI scan. The most common presentation seen is one of increasing confusion and short-term memory loss, usually with seizures and headache, coming on over a few days.

B Neurosyphillis

Neurosyphilis is associated with chronic neurological deterioration including ataxia, personality changes and dementia, and microvascular strokes.

C Primary brain tumour

A nodular enhancing lesion, coupled with left upper zone fibrosis on the CXR, is much more likely to be due to infection. A primary brain tumour would also not explain the CSF findings seen here.

E Neurosarcoidosis

Other signs of sarcoidosis would be expected to support a diagnosis of CNS disease. These might include bilateral hilar lymphadenopathy, not seen here on the chest X-ray, and leptomeningeal enhancement on MRI scanning.

You are the CMT doctor on call for neurology. You are called to the general medical ward to assess a 44-year-old man. He was admitted with pneumonia secondary to rib fractures and has been an inpatient for 2 days. Past history is unremarkable other than an admission 6 years ago with head injury.

Staff initially became concerned when he complained of insomnia and nausea. Since then he has become increasingly confused, complaining of visual hallucinations, and has vomited once.

On examination, his temperature is 38 °C and he is sweating profusely. There is no neck stiffness. His pulse is 110 bpm and regular. Pupils are dilated but reactive.

Physical examination is difficult as he is agitated and picking at the bedclothes. You note fine postural tremor, palmar erythema, poor dentition and generalised muscle thinning, but no fasciculations. He has bronchial breathing at the right base. Plantar response is withdrawal.

bpm and regular. Pupils are dilated but reactive.

Physical examination is difficult as he is agitated and picking at the bedclothes. You note fine postural tremor, palmar erythema, poor dentition and generalised muscle thinning, but no fasciculations. He has bronchial breathing at the right base. Plantar response is withdrawal.

Which of the following treatments is most likely to be successful in relieving his symptoms?

A	Intravenous aciclovir
B	Intravenous cefotaxime
C	Oral benzodiazepine
D	Intramuscular haloperidol
E	Intravenous atenolol

Past history is unremarkable other than an admission 6 years ago with head injury.

Staff initially became concerned when he complained of insomnia and nausea. Since then he has become increasingly confused, complaining of visual hallucinations, and has vomited once.

On examination, his temperature is 38 °C and he is sweating profusely. There is no neck stiffness. His pulse is 110 bpm and regular. Pupils are dilated but reactive.

Physical examination is difficult as he is agitated and picking at the bedclothes. You note fine postural tremor, palmar erythema, poor dentition and generalised muscle thinning, but no fasciculations. He has bronchial breathing at the right base. Plantar response is withdrawal.

Which of the following treatments is most likely to be successful in relieving his symptoms?

Your answer was incorrect

C Oral benzodiazepine

This patient is displaying classical features of severe alcohol withdrawal. Although no history of alcohol excess is given, there is sufficient peripheral information to raise suspicion – admissions with trauma, palmar erythema and poor dentition are all pointers to towards alcoholism. Alcohol withdrawal occurs after cessation or reduction in alcohol consumption. Hospital admission is a common precipitant. Features develop within 10 h of alcohol cessation and are maximal at 48 h. Common features are hyper-arousal, nausea, autonomic instability and visual hallucinations. Severe withdrawal is a medical emergency with a mortality of 5–10%. Optimal treatment is with benzodiazepines, preferably given according to an individualised treatment schedule. Meta-analysis has shown the superiority of benzodiazepine over anticonvulsants and major tranquillisers in managing the symptoms of withdrawal. Although

not a given answer option, intravenous B vitamins are also essential in this patient, and he should also be adequately hydrated with IV fluids. CT head is important to rule out the possibility of subdural haematoma.

D Intramuscular haloperidol

Benzodiazepines are more effective in managing alcohol withdrawal than antipsychotics.

A Intravenous aciclovir

It is worth considering viral encephalitis in patients with confusion and a fever. However, some of the features here are more in keeping with delirium tremens (acute alcohol withdrawal); visual hallucinosis, tremor and autonomic disturbance are less likely to be seen in viral encephalitis.

B Intravenous cefotaxime

There are no features to support the

A Intravenous aciclovir

It is worth considering viral encephalitis in patients with confusion and a fever. However, some of the features here are more in keeping with delirium tremens (acute alcohol withdrawal); visual hallucinosis, tremor and autonomic disturbance are less likely to be seen in viral encephalitis.

B Intravenous cefotaxime

There are no features to support the diagnosis of bacterial meningitis, for which this is first-line treatment.

E Intravenous atenolol

There are no indications in this case for intravenous beta-blockers.

32715

Rate this question:

Next Question

A 25-year-old man presents to the Emergency Department with a first episode of generalised tonic-clonic seizure. He is accompanied by his girlfriend, who says he collapsed after coming home from a night out at the cinema and suffered 5 minutes of generalised limb jerking, some foaming at the mouth and incontinence of urine.

Further collateral history revealed that he had been vacant on a number of occasions for a few minutes. This also involved lip-smacking. He describes a feeling of déjà vu and a feeling of anxiety in his abdomen and chest area immediately prior to these episodes. On a number of these occasions, he seemed to lose track of where he was for some minutes.

Past medical history includes febrile convulsions as a baby. There is no family history of note. Neurological examination in the clinic is unremarkable.

Investigations:

Investigations:

Hb	13.1 g/dl
WCC	6.7×10^9/l
PLT	210×10^9/l
Na^+	139 mmol/l
K^+	4.9 mmol/l
Creatinine	102 µmol/l
CT Head	Normal

What is the most likely diagnosis?

A Juvenile myoclonic epilepsy

B Temporal lobe epilepsy

C Frontal lobe epilepsy

D Parietal lobe epilepsy

E Juvenile absence epilepsy

Emergency Department with a first episode of generalised tonic-clonic seizure. He is accompanied by his girlfriend, who says he collapsed after coming home from a night out at the cinema and suffered 5 minutes of generalised limb jerking, some foaming at the mouth and incontinence of urine.

Further collateral history revealed that he had been vacant on a number of occasions for a few minutes. This also involved lip-smacking. He describes a feeling of déjà vu and a feeling of anxiety in his abdomen and chest area immediately prior to these episodes. On a number of these occasions, he seemed to lose track of where he was for some minutes.

Past medical history includes febrile convulsions as a baby. There is no family history of note. Neurological examination in the clinic is unremarkable.

Investigations:

Hb	13.1 g/dl

B	Temporal lobe epilepsy

The presence of the symptoms of déjà vu and epigastric sensation followed by loss of consciousness and oral automatisms (lip-smacking) is very suggestive of a temporal lobe origin of seizures. A past history of febrile convulsions may be associated with hippocampal sclerosis, a relatively common cause of medial temporal lobe epilepsy. This pathology should be looked for on brain MRI with specific hippocampal views. Brain imaging should also be performed to exclude malignancy. The patient should inform the DVLA of his diagnosis and would normally be expected not to drive until he has been seizure-free for a year.

A	Juvenile myoclonic epilepsy

The likelihood of a primary generalised epilepsy syndrome (such as juvenile myoclonic epilepsy or absence epilepsy) is much less here given the description of seizures with the déjà

description of seizures with the deja vu, epigastric sensation and oral automatisms. These features all suggest a focal onset (probably temporal lobe) epilepsy syndrome.

C	Frontal lobe epilepsy

This causes other semiologies of partial seizures. The symptoms described in the question would best support temporal lobe epilepsy.

D	Parietal lobe epilepsy

This type of partial seizure may present with altered or abnormal sensations. However the key pieces of evidence to support temporal lobe epilepsy are the déjà vu and automatisms.

E	Juvenile absence epilepsy

The blank spells described here are complex partial seizures, not absence seizures. In absence seizures one does

10:29

https://www.google.com/sea 14

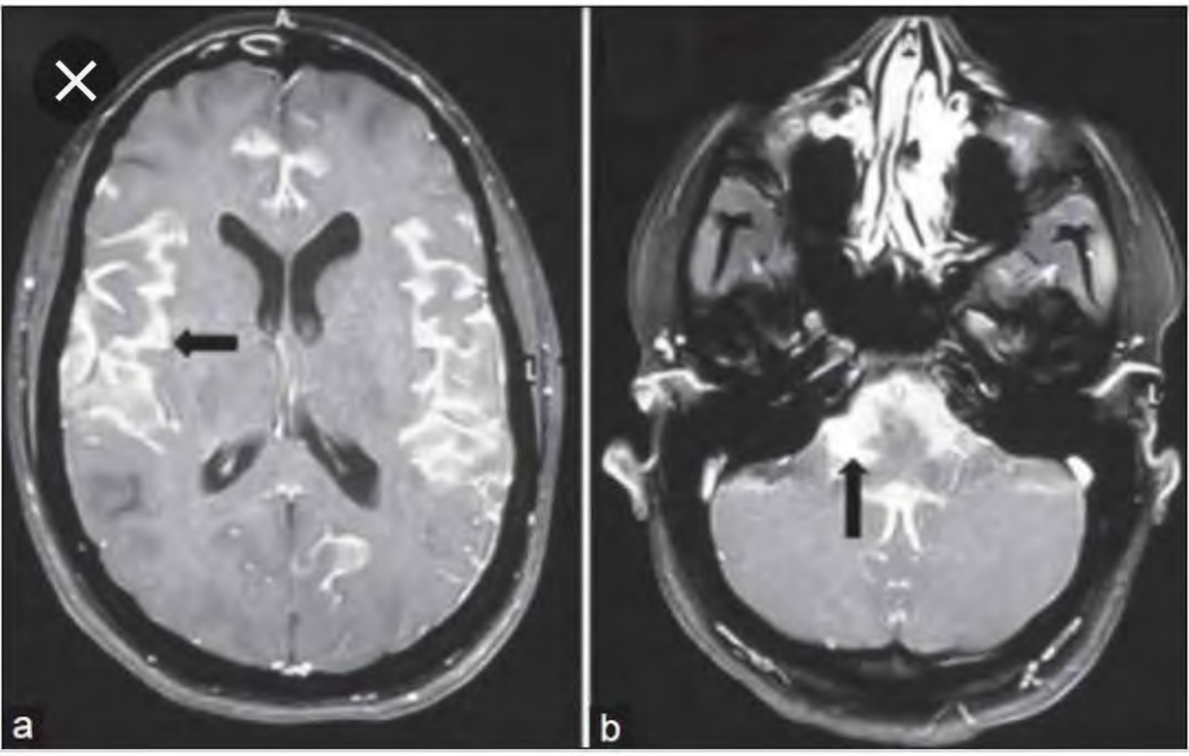

Ann Indian Acad Neurol

Primary diffuse leptomeningeal gliomatosis: An autopsy case r...

Primary diffuse leptomeningeal gliomatosis: An autopsy case report Jabeen SA, Chowdary AH, Kandadai RM, Uppin MS, Meena AK, Borgohain R, Sundaram C - Ann ...

Images may be subject to copyright. Learn More

RELATED IMAGES

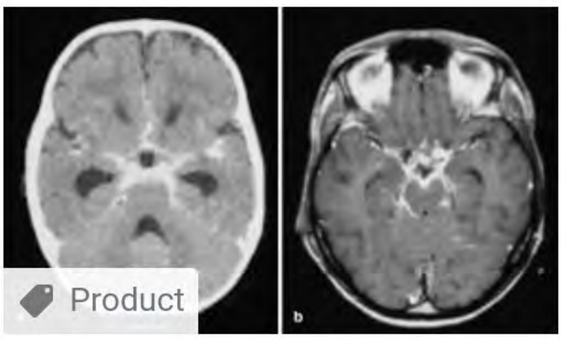

a, b Basal exudative tubercul...
researchgate.net

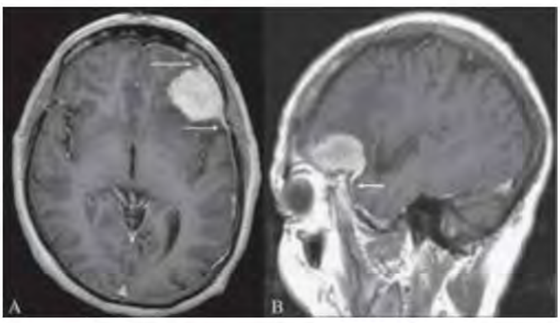

Dural tail sign. Axial (A) and s...
openi.nlm.nih.gov

10:29

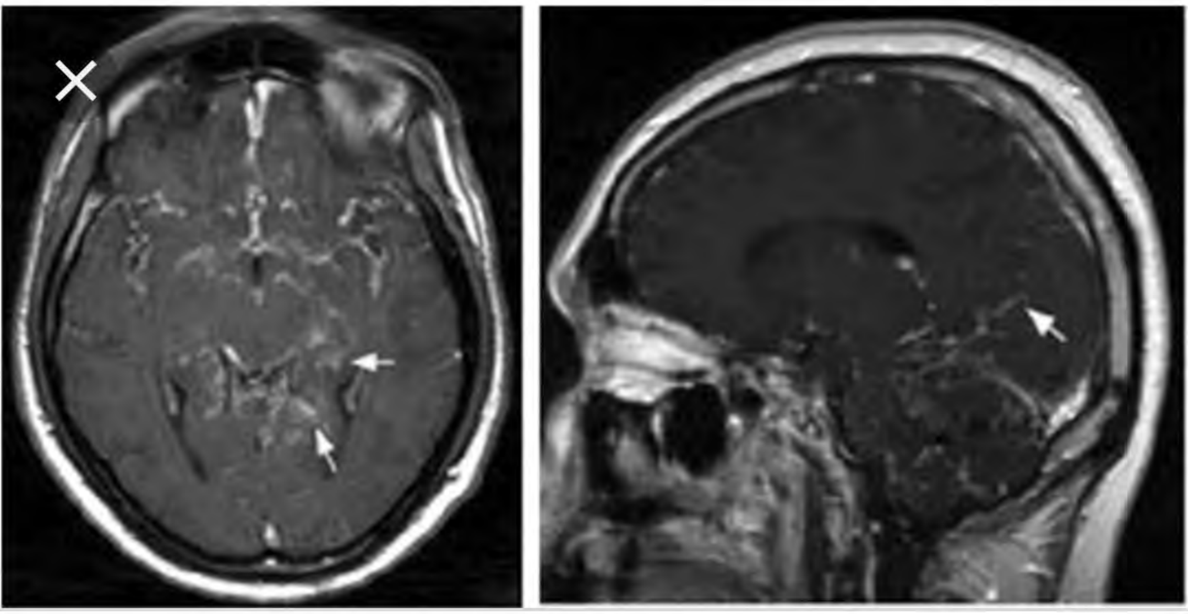

ResearchGate

Leptomeningeal sarcoidosis. (a) A gadolinium-enhanced axial T...

Leptomeningeal sarcoidosis. (a) A gadolinium-enhanced axial T1-weighted image in a 27-year-old male and (b) a gadolinium-enhanced sagittal T1-weighted image ...

Images may be subject to copyright. Learn More

RELATED IMAGES

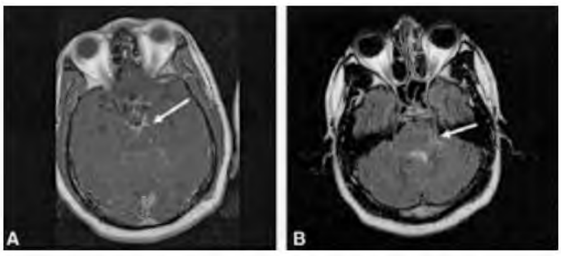

Head MRI in a 38-year-old Afr...
researchgate.net

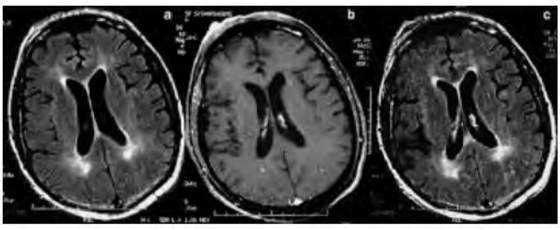

Meningitis only visible on a g...
researchgate.net

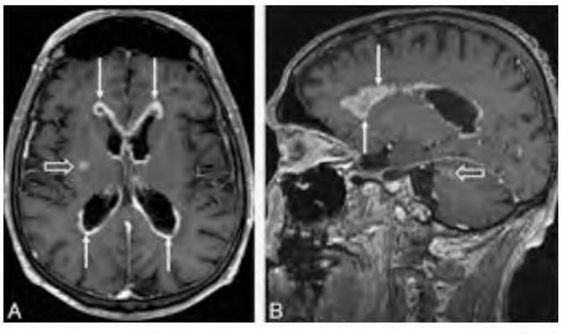

Fig 1 | Central Nervous Syste

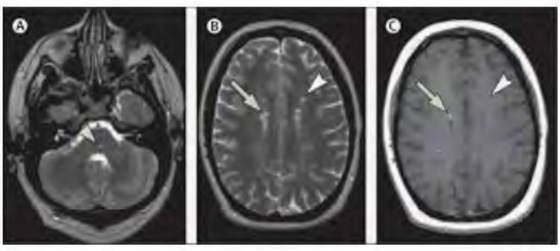

Clinically isolated syndromes...
thelancet.com

10:30

https://www.google.com/search?

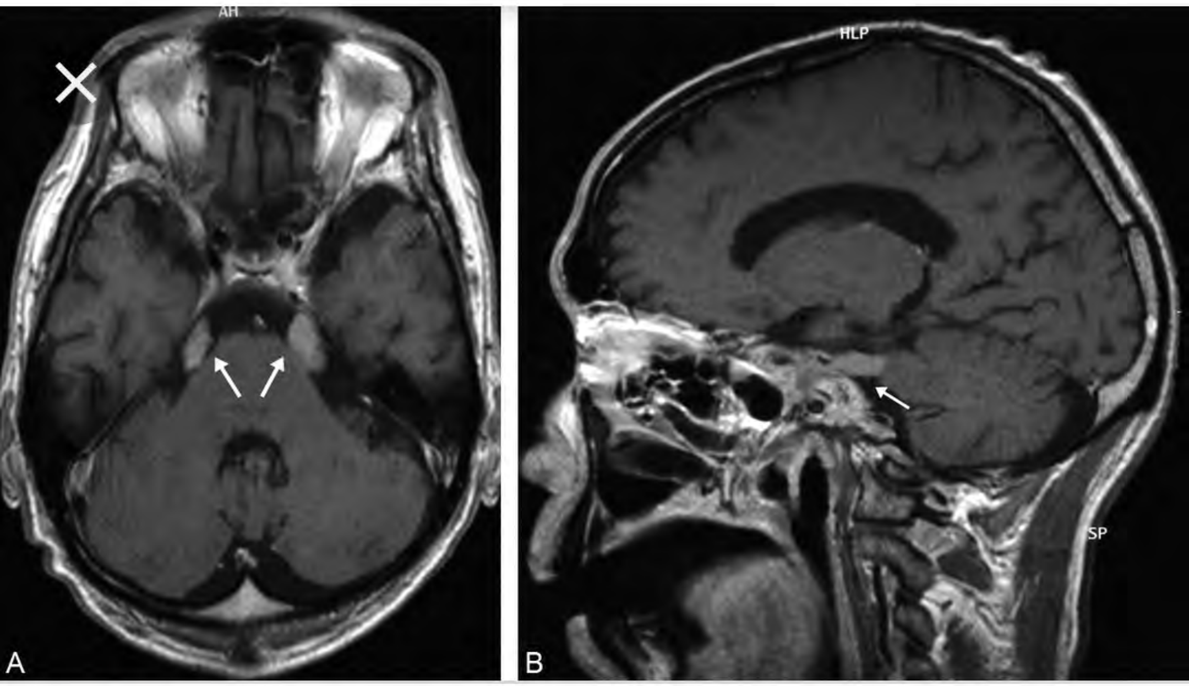

n.neurology.org

Hypertrophic cranial nerve roots in CIDP | Neurology

A 61-year-old man presented with painful dysesthesia/dysarthria (3 months) and sensorimotor impairment (13 years). Chronic inflammatory demyelinating polyradiculoneuritis (CIDP) was confirmed...

Images may be subject to copyright. Learn More

RELATED IMAGES

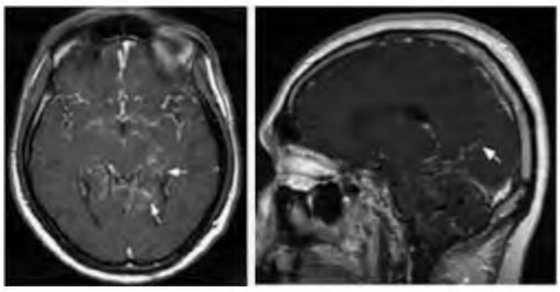

Leptomeningeal sarcoidosis. ...
researchgate.net

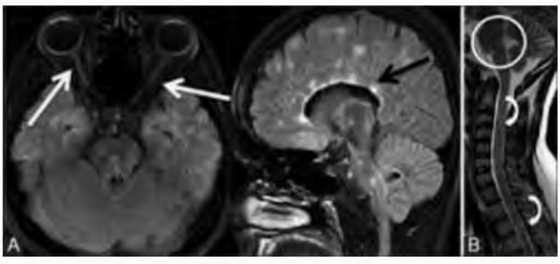

Demyelination: Multiple scler...
openi.nlm.nih.gov

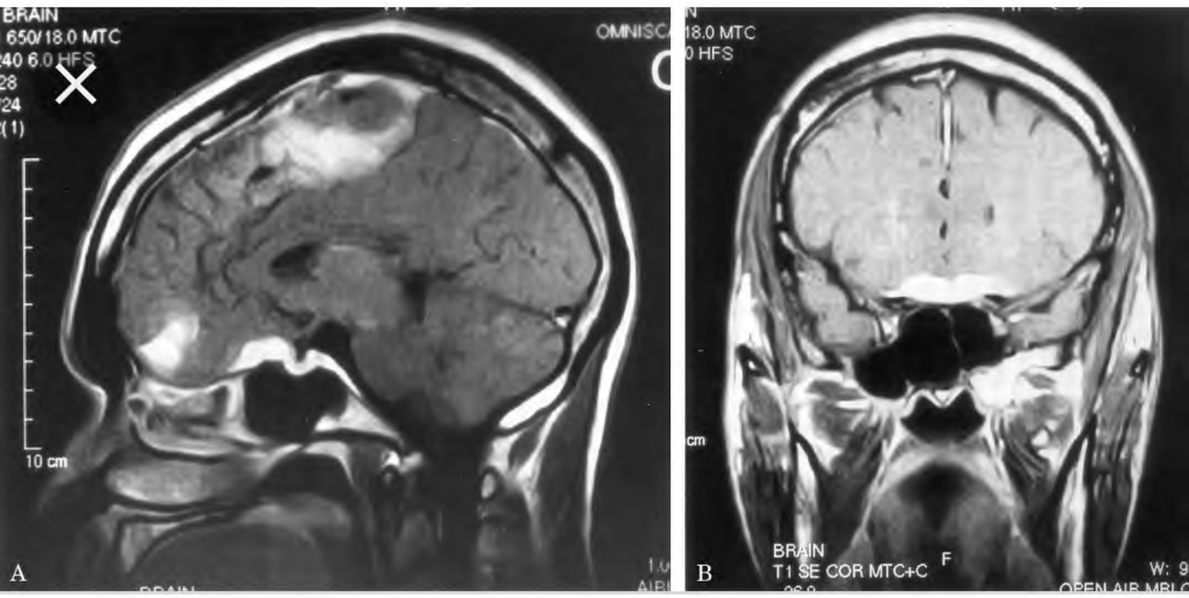

n.neurology.org

Neurosarcoidosis | Neurology

A 41-year-old black man with biopsy-confirmed pulmonary sarcoidosis presented with headache, blurred vision, and generalized tonic–clonic seizures of new onset. Neurological examination was...

Images may be subject to copyright. Learn More

RELATED IMAGES

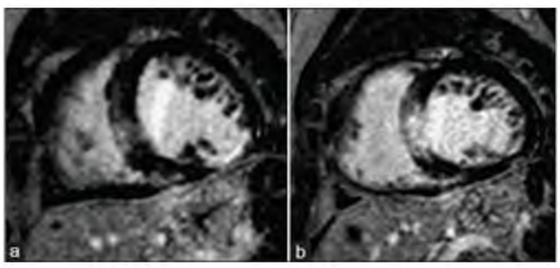

View Image
thoracicmedicine.org

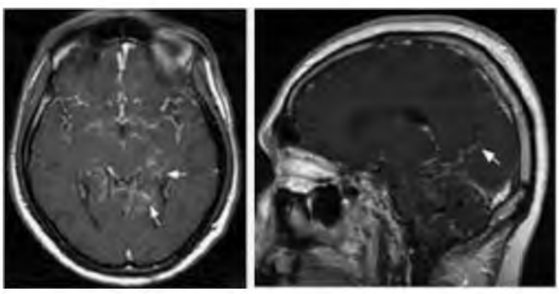

Leptomeningeal sarcoidosis. ...
researchgate.net

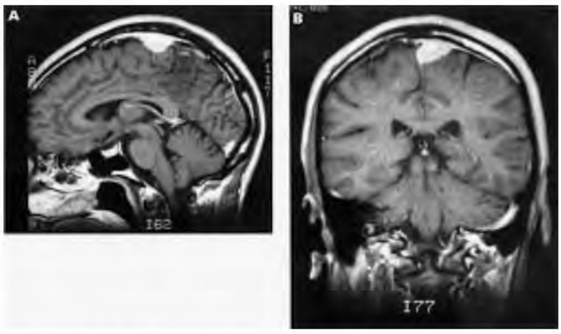

Sarcoid tumour: continuing di...
jnnp.bmj.com

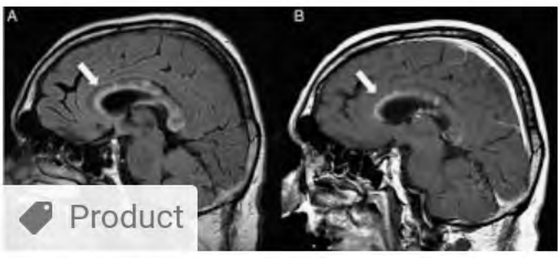

The corpus callosum in the di...
jnnp.bmj.com

A 48-year-old man is brought to the clinic for evaluation. He lives alone and his girlfriend said that for the past 3 weeks he has been behaving very abnormally, although in practice he has not been quite right, with odd mood changes and memory lapses for the past 4 months.

He had been treated at the Oncology Centre for a year and a half for chronic lymphocytic leukaemia, for which he received combination chemo- and immunotherapy. There is no history of fever or seizures.

On examination, he is drowsy and his visual acuity is 6/60 on both sides with intact pupillary reflexes. Right-sided weakness is evident, with mild spasticity and an extensor plantar response on the right. The left plantar shows a flexor response. Magnetic resonance imaging (MRI) of the brain reveals multiple non-enhancing white matter lesions in the left hemisphere. Routine blood testing shows a raised white count with lymphocytosis, but nil else of note.

weakness is evident, with mild spasticity and an extensor plantar response on the right. The left plantar shows a flexor response. Magnetic resonance imaging (MRI) of the brain reveals multiple non-enhancing white matter lesions in the left hemisphere. Routine blood testing shows a raised white count with lymphocytosis, but nil else of note.

What is the most likely diagnosis?

A	Small vessel vasculitis
B	Embolic stroke
C	Acute disseminated encephalomyelitis (ADEM)
D	Progressive multi-focal leukoencephalopathy (PML)
E	Leucodystrophy

abnormally, although in practice he has not been quite right, with odd mood changes and memory lapses for the past 4 months.

He had been treated at the Oncology Centre for a year and a half for chronic lymphocytic leukaemia, for which he received combination chemo- and immunotherapy. There is no history of fever or seizures.

On examination, he is drowsy and his visual acuity is 6/60 on both sides with intact pupillary reflexes. Right-sided weakness is evident, with mild spasticity and an extensor plantar response on the right. The left plantar shows a flexor response. Magnetic resonance imaging (MRI) of the brain reveals multiple non-enhancing white matter lesions in the left hemisphere. Routine blood testing shows a raised white count with lymphocytosis, but nil else of note.

What is the most likely diagnosis?

D Progressive multi-focal leukoencephalopathy (PML)

This uncommon disease usually develops in patients with a neoplasm or a chronic immunodeficiency state. It may also occur in patients receiving immunosuppressive drugs. Personality changes and intellectual impairment are the initial features that evolve over several days or weeks, followed by focal neurological signs, cortical blindness and seizures. This is followed by coma and death over 3–6 months. Cerebrospinal fluid (CSF) has normal constituents and MRI reveals non-enhancing white matter lesions. JC virus is a human polyomavirus that has been isolated from infected oligodendrocytes and has been confirmed as the causative agent.

A Small vessel vasculitis

Although small vessel disease is possible in this patient, lateralising disease would be unlikely and the MRI

appearance is more typical of PML.

B	Embolic stroke

Embolic stroke is more likely to present with a single lesion seen on MRI scan, and there is little evidence of increased risk of arterial embolism here.

C	Acute disseminated encephalomyelitis (ADEM)

ADEM is a disease of childhood and has specific onset in association with either an acute febrile illness or vaccination. Corticosteroids and immunoglobulin infusion are both potential interventions.

E	Leucodystrophy

This is a rare, progressive, inherited neurological condition which leads to both PNS and CNS dysfunction; the onset post-CLL doesn't fit with this as the underlying diagnosis.

A 35-year-old builder presented with a 7-month history of progressive left hand weakness and a 3-month history of similar progressive weakness in his right hand. He had been otherwise well, apart from being involved in a car crash 3 years previously.

On examination, he had fasciculations in both deltoid muscles with increased tone in both arms, weakness of intrinsic hand muscles bilaterally and all upper limb reflexes were brisk. Coordination and sensory examinations were normal.

What is the most likely diagnosis?

A	Chronic inflammatory demyelinating polyneuropathy (CIDP)
B	Multiple sclerosis (MS)
C	Cervical myelopathy
D	Syringomyelia

of similar progressive weakness in his right hand. He had been otherwise well, apart from being involved in a car crash 3 years previously.

On examination, he had fasciculations in both deltoid muscles with increased tone in both arms, weakness of intrinsic hand muscles bilaterally and all upper limb reflexes were brisk. Coordination and sensory examinations were normal.

What is the most likely diagnosis?

A	Chronic inflammatory demyelinating polyneuropathy (CIDP)
B	Multiple sclerosis (MS)
C	Cervical myelopathy
D	Syringomyelia
E	Motor neurone disease (MND)

Well, apart from being involved in a car crash 3 years previously.

On examination, he had fasciculations in both deltoid muscles with increased tone in both arms, weakness of intrinsic hand muscles bilaterally and all upper limb reflexes were brisk. Coordination and sensory examinations were normal.

What is the most likely diagnosis?

Your answer was correct

A	Chronic inflammatory demyelinating polyneuropathy (CIDP)
B	Multiple sclerosis (MS)
C	Cervical myelopathy
D	Syringomyelia
E	Motor neurone disease (MND)

E Motor neurone disease (MND)

The most common form of MND is amyotrophic lateral sclerosis. This presents with progressive upper and lower motor neurone signs. The sensory nerves are unaffected. MND has a range of onset from 20 to 90 years of age, with the mean age being around 60 years. It is more common in men than women. In most patients, symptoms start in the limbs with a smaller group (about 25%) presenting with bulbar symptoms (e.g. tongue fasciculations and wasting, dysphagia, dysarthria). There is no curative treatment and death is usually due to respiratory failure. Riluzole is used to slow progression, generally prolonging life by around six months. The main differential diagnosis to consider in patients with suspected MND is multifocal motor neuropathy with conduction block. This is a treatable inflammatory motor neuropathy associated with anti-GM1 autoantibodies, usually presenting with distal upper limb weakness and lower

A	Chronic inflammatory demyelinating polyneuropathy (CIDP)

CIDP, the chronic form of Guillain–Barré syndrome, is a disease of the peripheral nervous system. Thus, upper motor neurone signs (e.g. brisk reflexes) would not be seen. It would also be unusual for the sensory examination to be normal in a patient with CIDP, as both motor and sensory nerves are usually affected. Fasciculations are also rare in CIDP, as the predominant pathological process is demyelination of peripheral nerves, rather than axonal loss. Therefore, the muscle does not become denervated.

B	Multiple sclerosis (MS)

MS is purely a central nervous system disease. Lower motor neurone signs, such as fasciculations, are not seen. In addition, MS usually presents with a relapsing remitting pattern, and sensory symptoms and signs are very common

11:22
On ...
594-042-7551
Leave

A 40-year-old man presents to the acute medical take with a sudden-onset, severe, occipital headache. It started 13 h ago and is still extremely painful.

He has a past medical history of migraines, of which he gets about two a year. He is otherwise fit and well.

On examination, he has no focal neurology and his computerised tomography (CT) head scan shows no pathology and is reported as normal. He receives a lumbar puncture (LP), which is difficult to do and the SHO needs a few attempts. The cerebral spinal fluid (CSF) is colourless and three bottles are taken in numerical order:

Bottle 1	298 RBCs/μl
Bottle 2	356 RBCs/μl
Bottle 3	346 RBCs/μl

What is the next best step in this patient's management?

A	Admit the patient and monitor him for a further 24 h
B	Discharge the patient
C	Request an MRA of the intracranial vessels
D	Request a xanthochromia test on the CSF
E	Refer to Neurology for surgical intervention

Submit

Audio Video Share Participants More

11:24
On ...
594-042-7551
Leave

What is the next best step in this patient's management?

Your answer was correct

A	Admit the patient and monitor him for a further 24 h
B	Discharge the patient
C	Request an MRA of the intracranial vessels
D	Request a xanthochromia test on the CSF
E	Refer to Neurology for surgical intervention

Explanation

D Request a xanthochromia test on the CSF

Sudden-onset headache, regardless of severity or prior headache history, should raise the clinical suspicion for subarachnoid haemorrhage (SAH) and compel a diagnostic evaluation; 97% of SAH cases present with a sudden-onset severe headache and can be fatal in certain cases.

The first line investigation is a non-contrast CT head. This has a high sensitivity, particularly in the first 6-12 h, but becomes progressively less sensitive after that. A normal CT head does not rule out a SAH.

LP is the next investigation of choice. This should ideally be done 12 h after onset of the headache. One would look for blood clearing in the samples, with decreasing number of red cells seen from samples 1 to 3. If they remain elevated this would suggest SAH, but a decreasing level can be seen in SAH also. The diagnostic test is whether xanthochromia, a breakdown product of bilirubin, is seen. This is a

Audio Video Share Participants More

11:24
On ...
594-042-7551
Leave

D Request a xanthochromia test on the CSF

Sudden-onset headache, regardless of severity or prior headache history, should raise the clinical suspicion for subarachnoid haemorrhage (SAH) and compel a diagnostic evaluation; 97% of SAH cases present with a sudden-onset severe headache and can be fatal in certain cases.

The first line investigation is a non-contrast CT head. This has a high sensitivity, particularly in the first 6-12 h, but becomes progressively less sensitive after that. A normal CT head does not rule out a SAH.

LP is the next investigation of choice. This should ideally be done 12 h after onset of the headache. One would look for blood clearing in the samples, with decreasing number of red cells seen from samples 1 to 3. If they remain elevated this would suggest SAH, but a decreasing level can be seen in SAH also. The diagnostic test is whether xanthochromia, a breakdown product of bilirubin, is seen. This is a breakdown product of blood and indicates a significant bleed of >12 h. This would not be seen if a LP had been traumatic but there had been no SAH. Spectrophotometry is a more sophisticated version of this test, where the sample is analysed for peaks in bilirubin and oxyhaemoglobin, characteristic of blood breakdown.

A Admit the patient and monitor him for a further 24 h

This is not an appropriate management for this patient as SAH can be fatal in some cases, and this history is consistent with a SAH. This must therefore be actively ruled out before the patient can be discharged.

B Discharge the patient

This is not an appropriate management for this patient as SAH can be fatal in some cases, and this history is

Audio Video Share Participants More

This is not an appropriate management for this patient as SAH can be fatal in some cases, and this history is consistent with a SAH. This must therefore be actively ruled out before the patient can be discharged.

B Discharge the patient

This is not an appropriate management for this patient as SAH can be fatal in some cases, and this history is consistent with a SAH. This must therefore be actively ruled out before the patient can be discharged.

C Request an MRA of the intracranial vessels

This is a useful test to locate the site of a bleed, should one be diagnosed. However, the priority here is to establish whether a subarachnoid haemorrhage has occurred.

E Refer to Neurology for surgical intervention

This would be an appropriate action if a SAH had occurred, but a diagnosis must be reached first.

Rate this question:

Next Question

Previous Q... Tag Questi... Feedback End Session

© Pastest 2019

A 20-year-old undergraduate complains of regular painful muscle cramps and stiffness while playing cricket for his university. His symptoms have been present for at least 6 years, but the frequency of attacks has now become much worse, impairing his bowling. Cramps last up to 10 min and are relieved by rest. Recently, he has noticed that his urine is often 'tea-coloured'.

Examination revealed no rashes with normal tone, power, reflexes and co-ordination and sensation in the limbs.

Initial investigations are as follows:

Hb	12.4 g/dl
WCC	6.8×10^9/l
PLT	230×10^9/l
MCV	88 fl
Na^+	140 mmol/l
K^+	4.2 mmol/l
Urea	3.8 mmol/l
Creatinine	70 μmol/l
Bilirubin	8 mmol/l
ALT	18 U/l
Albumin	43 U/l
ALP	28 U/l
Lactate	1.1 mmol/l
Creatinine phosphokinase	880 IU/l

Which of the following non invasive investigations will be of most diagnostic interest?

A Tensilon test

11:27

MyPastest
https://mypastest.pastest.com

K^+	4.2 mmol/l
Urea	3.8 mmol/l
Creatinine	70 µmol/l
Bilirubin	8 mmol/l
ALT	18 U/l
Albumin	43 U/l
ALP	28 U/l
Lactate	1.1 mmol/l
Creatinine phosphokinase	880 IU/l

Which of the following non invasive investigations will be of most diagnostic interest?

A Tensilon test

B Electromyography (EMG)

C Ultrasound of the quadriceps

D Muscle MRI

E Serum lactate post exercise

32729

Submit

E Serum lactate post exercise

The history is suggestive of a metabolic myopathy, in this case McArdle syndrome (a type-V glycogen-storage disorder). This disorder is characterised by muscle phosphorylase deficiency. Symptoms include exercise-induced muscle pain and stiffness with contractures that subside at rest. Myoglobinuria can occur. In normal patients there is a sustained increase in serum lactate after exertion, but this does not occur in patients with McArdle. The diagnosis is confirmed by muscle biopsy, which demonstrates subsarcolemmal glycogen deposition and central migration of muscle nuclei. No specific therapy is recommended for the treatment of McArdle, but patients are usually instructed to avoid strenuous exercise once the diagnosis is made.

A Tensilon test

This is a test sometimes used in the investigation of myasthenia, although it has been largely superseded by antibody testing and neurophysiology.

B Electromyography (EMG)

Unlike many muscle diseases, the EMG in McArdle syndrome is frequently normal.

C Ultrasound of the quadriceps

This test has no value in the assessment of muscle disease.

D Muscle MRI

This test is becoming more common practice in the assessment of muscle disease, as some conditions tend to pick out specific muscle groups. It can also help to guide

A 26-year-old woman complained of a 6-month history of blurring of vision on bending forward. For the last 4 months she had also been suffering from headaches, which were worse first thing in the morning. She had been otherwise well.

On examination, she has a body mass index of 32, but general examination was otherwise normal. Neurological examination reveals bilateral papilloedema but nothing else. You arrange an MR venogram, which is normal.

Which of the following is the next most appropriate investigation?

A	Cerebral angiogram
B	Electroencephalography (EEG)
C	Goldmann perimetry
D	Lumbar puncture
E	Serum cortisol

71065

Submit

A 26-year-old woman complained of a 6-month history of blurring of vision on bending forward. For the last 4 months she had also been suffering from headaches, which were worse first thing in the morning. She had been otherwise well.

On examination, she has a body mass index of 32, but general examination was otherwise normal. Neurological examination reveals bilateral papilloedema but nothing else. You arrange an MR venogram, which is normal.

Which of the following is the next most appropriate investigation?

Your answer was correct

A	Cerebral angiogram
B	Electroencephalography (EEG)
C	Goldmann perimetry
D	Lumbar puncture
E	Serum cortisol

Explanation

D Lumbar puncture

The most likely diagnosis is idiopathic intracranial hypertension (IIH, formerly known as benign intracranial hypertension or BIH), which most commonly occurs in young women who are overweight. Magnetic resonance

D Lumbar puncture

The most likely diagnosis is idiopathic intracranial hypertension (IIH, formerly known as benign intracranial hypertension or BIH), which most commonly occurs in young women who are overweight. Magnetic resonance imaging of the brain, including venography if possible, is required to exclude other causes of raised intracranial pressure. A lumbar puncture can then be performed, where a raised pressure but normal contents of the cerebrospinal fluid (CSF) would be expected. Management options include weight loss, diuretics, therapeutic lumbar punctures and, if severe, either optic nerve fenestration or a shunt from the CSF to the peritoneum. Visual field assessments would also be useful to follow the response to therapeutic measures (although their importance falls below LP in terms of the correct responses here).

A Cerebral angiogram

A magnetic resonance venogram would be the investigation of choice for excluding cerebral venous thrombosis. A cerebral angiogram would be useful in identifying arterial aneurysms, but would not be useful in this situation.

B Electroencephalography (EEG)

Electroencephalography can be useful in looking for any abnormal seizure activity, but would not be helpful in this situation.

C Goldmann perimetry

Goldmann perimetry is a form of kinetic perimetry: a stimulus is moved from beyond the edge of the visual field into the field. The location at which the stimulus is first

11:33
On ...
594-042-7551
Leave

A 69-year-old woman who lives alone, and who apparently has a history of previous seizures, presents to the Medical Outpatients Department. She describes progressive difficulty walking over the last three weeks, and frequent falls.

On examination, you note that she is thin, slightly unkempt and has some bruises on her lower limbs. The Mini Mental Score is 18/30. She says that she looks after herself very well and that she is in the process of redecorating her house, and had just recently met her son for coffee. He denies this when the hospital calls him as next of kin. She has poor sitting balance and a wide-based, hesitant gait. There is bilateral gaze-evoked nystagmus and mild failure of abduction of the left eye. Speech is slightly slurred. All reflexes are present but difficult to elicit, with flexor plantar responses.

What is the most likely cause of her presentation?

A	Phenytoin toxicity
B	Chronic subdural haematoma
C	Wernicke's encephalopathy
D	Paraneoplastic cerebellar degeneration
E	Hypothyroidism

7363

Submit

Audio Video Share Participants More

11:35
On ...
594-042-7551
Leave

On examination, you note that she is thin, slightly unkempt and has some bruises on her lower limbs. The Mini Mental Score is 18/30. She says that she looks after herself very well and that she is in the process of redecorating her house, and had just recently met her son for coffee. He denies this when the hospital calls him as next of kin. She has poor sitting balance and a wide-based, hesitant gait. There is bilateral gaze-evoked nystagmus and mild failure of abduction of the left eye. Speech is slightly slurred. All reflexes are present but difficult to elicit, with flexor plantar responses.

What is the most likely cause of her presentation?

Your answer was incorrect

- A Phenytoin toxicity
- B Chronic subdural haematoma
- C Wernicke's encephalopathy
- D Paraneoplastic cerebellar degeneration
- E Hypothyroidism

Explanation

C Wernicke's encephalopathy

This is most likely to be Wernicke's syndrome caused by chronic alcohol excess, probably combined with poor nutrition. She presents the typical combination of ataxia, eye movement abnormalities and (acutely) impaired cognition. There is also the notion here of confabulation/denial of her symptoms. More history is of course needed in her case as there is no direct history of

Audio Video Share Participants More

11:35
On ...
594-042-7551
Leave

C Wernicke's encephalopathy

This is most likely to be Wernicke's syndrome caused by chronic alcohol excess, probably combined with poor nutrition. She presents the typical combination of ataxia, eye movement abnormalities and (acutely) impaired cognition. There is also the notion here of confabulation/denial of her symptoms. More history is of course needed in her case as there is no direct history of alcohol misuse, but the thinness, unkempt state and bruising could be clues to this. Biochemical and haematological tests may also provide evidence of liver dysfunction and/or undernutrition. A deficiency of thiamine (vitamin B_1) is responsible for the symptom complex manifested in Wernicke–Korsakoff syndrome, and any condition resulting in a poor nutritional state places patients at risk. Heavy, long-term alcohol use is the most common association. Treatment should be started immediately with IV B vitamins as soon as the diagnosis is suspected, as Wernicke's encephalopathy is a medical emergency; early treatment can rapidly reverse the ophthalmoplegia and improve ataxia and early mental confusion, as well as prevent development of the amnestic state. In advanced cases, where severe prolonged deficiency has led to permanent structural damage, permanent deficits most often are manifested as the amnestic state and severe ataxia.

A Phenytoin toxicity

Although phenytoin toxicity can present with nystagmus and cerebellar signs, it is not usually associated with gaze palsy.

B Chronic subdural haematoma

Chronic subdural haematoma is more likely to be associated with a history of fall, fluctuating consciousness

Audio Video Share Participants More

11:39
On ...
594-042-7551
Leave

A 28-year-old man is admitted as an emergency through casualty. He has had a 'thunderclap' headache associated with nausea. He volunteers that this is the worst headache he has suffered in his life and rates it '11 out of 10' on a scale. He has no significant medical history and is on no regular medications.

His pulse, blood pressure and temperature are all normal. He is difficult to examine because he is restless and uncooperative due to the pain. However, he does not appear to have significant neck stiffness. There are no haemorrhages seen on fundoscopy.

After you have examined him, his girlfriend approaches you. She appears embarrassed but eventually tells you that the headache happened as they were having sexual intercourse and the pain began immediately after her boyfriend had an orgasm.

A computed tomography (CT) of the brain is performed which does not demonstrate any evidence of haemorrhage. Lumbar puncture is performed (16 h after the onset of the headache) and this too is normal, including spectrophotometry analysis.

What is the most likely diagnosis?

A	Trigeminal neuralgia
B	Cluster headache
C	Cerebral venous sinus thrombosis (CVST)
D	Subarachnoid haemorrhage
E	Benign coital headache

Audio Video Share Participants More

Explanation

E Benign coital headache

This presentation of acute severe headache associated with orgasm is seen with benign coital headache. This is a form of exertion-related headache triggered by autonomic changes associated with orgasm. The differential is always one of subarachnoid haemorrhage, and it is safest to assume that this life-threatening condition is the diagnosis in the acute situation until proved otherwise. If individuals have a history of similar coital headaches, then this is reassuring. Remember that subarachnoid haemorrhage can also occur during intercourse. Remember too that lack of meningism and a normal computed tomography (CT) scan do not exclude a small 'herald' bleed and that subsequent larger bleeds can be devastating. Although CT is the most sensitive test for SAH in the first 24 h after symptom onset, this test can be negative in 5-10% of SAH cases. CSF examination, looking for haemoglobin breakdown products, has the highest reliability from 12 h to 2 weeks after the bleed.

A Trigeminal neuralgia

TN presents with paroxysms of sharp unilateral facial pain and therefore doesn't fit the description given here.

B Cluster headache

Cluster presents with severe, often nocturnal, unilateral pain associated with autonomic features (red eye, watery eye, runny nose). As the name suggests, a cluster of attacks occur overs a few weeks and then there is a remission.

C Cerebral venous sinus thrombosis (CVST)

sensitive test for SAH in the first 24 h after symptom onset, this test can be negative in 5-10% of SAH cases. CSF examination, looking for haemoglobin breakdown products, has the highest reliability from 12 h to 2 weeks after the bleed.

A Trigeminal neuralgia

TN presents with paroxysms of sharp unilateral facial pain and therefore doesn't fit the description given here.

B Cluster headache

Cluster presents with severe, often nocturnal, unilateral pain associated with autonomic features (red eye, watery eye, runny nose). As the name suggests, a cluster of attacks occur overs a few weeks and then there is a remission.

C Cerebral venous sinus thrombosis (CVST)

Although CVST may rarely present with a thunderclap headache, the information given in the case is more supportive of coital headache.

D Subarachnoid haemorrhage

The investigations performed here (entirely appropriately) have excluded this diagnosis.

7065

Rate this question:

Rana Alnasser's screen

11:43

A 45-year-old painter is admitted from his place of work after collapsing in the afternoon. He is a smoker of 20 cigarettes per day but is otherwise well.

On rousing at the building site, he was noted to have slurred speech, dizziness and some transient symptoms affecting the right side of the body. This had recovered by the time he reached the Emergency Department. Angiography revealed a proximal stenosis of the left subclavian and carotid arteries.

EEG showed no evidence of spike activity.

Which of the following diagnoses fits best with this clinical picture?

A	Transient Ischaemic attack
B	Migraine attack
C	Subclavian steal syndrome
D	Complex partial seizure
E	Generalised epilepsy

9273

Submit

Previous Q... Skip Questi...

Rana Alnasser's screen

11:44
On
594-042-7551
Leave
MyPastest
https://mypastest.pastest.com

A 45-year-old painter is admitted from his place of work after collapsing in the afternoon. He is a smoker of 20 cigarettes per day but is otherwise well.

On rousing at the building site, he was noted to have slurred speech, dizziness and some transient symptoms affecting the right side of the body. This had recovered by the time he reached the Emergency Department. Angiography revealed a proximal stenosis of the left subclavian and carotid arteries.

EEG showed no evidence of spike activity.

Which of the following diagnoses fits best with this clinical picture?

Your answer was correct

A Transient Ischaemic attack

B Migraine attack

C Subclavian steal syndrome

D Complex partial seizure

E Generalised epilepsy

Explanation

C Subclavian steal syndrome

Audio
Video
Share
Participants
More

11:44
On 594-042-7551 Leave

E Generalised epilepsy

Explanation

C Subclavian steal syndrome

Subclavian steal syndrome is associated with retrograde flow in the vertebral artery due to a proximal subclavian artery stenosis. Neurological symptoms are precipitated by vigorous use of the arm on the side of the stenosed subclavian artery, e.g. painting a wall. Rather than being related to embolic phenomena, they are in fact related to reduced blood flow, demonstrated by a difference in blood pressure between the affected and unaffected arms.

The diagnosis is often confused with transient ischaemic attacks or epilepsy. Duplex ultrasound and magnetic resonance angiography are the investigations of choice. The syndrome is associated with diseases that cause the lumen of the artery to be diminished: Takayasu's arteritis (a type of vasculitis), thoracic outlet compression or post-surgical repair of aortic abnormalities.

Medical management is similar to that of peripheral arterial disease: smoking cessation, lipid and blood pressure control and anti-platelet agents. Endarterectomy and stenting are common surgical methods involved in relieving symptoms associated with this condition.

A Transient Ischaemic attack

Transient ischaemic attacks (TIAs) might be a plausible answer given he has focal symptoms such as hemi-sensory disturbance and slurred speech. However, loss of consciousness is uncharacteristic of a TIA. Moreover, we are told that there is a proximal stenosis in the left subclavian and carotid arteries, whereas a TIA would usually be caused by stenosis in the mid- to distal carotids, with the subclavians being unaffected.

Audio Video Share Participants More

B Migraine attack

Migraines can come on at work, at times of stress, but there is usually an aura with wave-like lines moving across the affected visual field, followed by a unilateral or global thumping headache that gets better with rest. Loss of consciousness is not a feature of migraine. Therefore, this is not the correct answer.

D Complex partial seizure

Complex partial seizures cause loss of awareness without loss of consciousness, along with the other, well-known features such as a prodrome of fluttering sensation in the abdomen, and automatisms like lip-smacking. This patient has had loss of consciousness, and no history of prior lip-smacking or prodrome. Therefore, this is not a complex-partial seizure.

E Generalised epilepsy

There are no features to suggest this man has had a seizure, such as a prodrome, a history of witnessed limb rigidity or jerking, or post-ictal confusion or fatigue. Even if there were features of seizure activity in the history, generalised epilepsy (a tendency to have seizures) cannot be diagnosed from a history of a single seizure without supportive evidence from an EEG.

A 77-year-old woman presents to her general practitioner having a history of progressive unsteadiness on her feet, resulting in a number of falls. More recently she has noticed difficulty in reading and frequently loses her place while scanning the text. Her husband, who accompanied her, says that he has noticed she is much slower at doing things such as making a meal or walking to the shops, and now needs accompanying for most tasks because of unsteadiness.

Her past medical history includes hypertension, hypothyroidism and osteoarthritis. Her regular medication includes bendrofluazide 2.5 mg/day and thyroxine 75 µg/day.

On examination, her blood pressure is 100/65 mmHg (lying) and 80/55 mmHg (standing), pulse 67/min. She has marked dysarthria. Examining eye movements shows normal smooth pursuit, but hypometric vertical saccades and evidence of square-wave jerks. She also has slow spastic tongue movements. There is marked neck rigidity with retrocollis and evidence of symmetrically mild increased upper limb tone and bradykinesia. On examination of the lower limb, there is symmetrically increased tone, bradykinesia and gait instability.

Investigations:

Na^+	131 mmol/l
K^+	3.5 mmol/l
Urea	6.4 mmol/l
Creatinine	110 micromol/l
Thyroxine	59 nmol/l (58–178)
TSH	6.7 mU/l (0.4–5)

Choose the most likely cause for this patient's symptoms and signs.

Rana Alnasser's screen

On examination, her blood pressure is 100/65 mmHg (lying) and 80/55 mmHg (standing), pulse 67/min. She has marked dysarthria. Examining eye movements shows normal smooth pursuit, but hypometric vertical saccades and evidence of square-wave jerks. She also has slow spastic tongue movements. There is marked neck rigidity with retrocollis and evidence of symmetrically mild increased upper limb tone and bradykinesia. On examination of the lower limb, there is symmetrically increased tone, bradykinesia and gait instability.

Investigations:

Na^+	131 mmol/l
K^+	3.5 mmol/l
Urea	6.4 mmol/l
Creatinine	110 micromol/l
Thyroxine	59 nmol/l (58–178)
TSH	6.7 mU/l (0.4–5)

Choose the most likely cause for this patient's symptoms and signs.

A Progressive supranuclear palsy

B Multiple systems atrophy (MSA)

C Parkinson's disease

D Motor neuron disease (MND)

E Cerebrovascular disease

Explanation

A	Progressive supranuclear palsy

This patient presents with a 'Parkinson's plus' syndrome characterised by symmetrical parkinsonism, postural instability and early vertical supranuclear gaze palsy. In addition she also has a pseudobulbar palsy as evidenced by dysarthria and spastic tongue movements. These findings would be consistent with progressive supranuclear palsy.

B	Multiple systems atrophy (MSA)

Patients with MSA tend to be younger and are more likely to present with dysautonomia and cerebellar signs, which are absent in this patient. Other features of MSA include laryngeal dystonia, stridor and poly-mini myoclonus.

C	Parkinson's disease

Parkinson's disease does not usually present with falls - these are a later stage aspect of the disease. In most patients, Parkinson's disease causes an asymmetric, upper limb-onset syndrome characterised by tremor, rigidity and bradykinesia.

D	Motor neuron disease (MND)

Although the patient does have signs of a pseudobulbar palsy, which may be seen in MND, the other signs are of an extrapyramidal disorder (rigidity, bradykinesia). There is no evidence of wasting, weakness or fasciculations, which one would expect with MND.

E	Cerebrovascular disease

Patients with MSA tend to be younger and are more likely to present with dysautonomia and cerebellar signs, which are absent in this patient. Other features of MSA include laryngeal dystonia, stridor and poly-mini myoclonus.

C Parkinson's disease

Parkinson's disease does not usually present with falls - these are a later stage aspect of the disease. In most patients, Parkinson's disease causes an asymmetric, upper limb-onset syndrome characterised by tremor, rigidity and bradykinesia.

D Motor neuron disease (MND)

Although the patient does have signs of a pseudobulbar palsy, which may be seen in MND, the other signs are of an extrapyramidal disorder (rigidity, bradykinesia). There is no evidence of wasting, weakness or fasciculations, which one would expect with MND.

E Cerebrovascular disease

The small-vessel disease would need to be extensive and involve the cortex, striatum, substantia nigra and brainstem to cause these signs and symptoms. Given that, one would expect evidence of diffuse brain involvement with pyramidal signs present, as well as the observed extrapyramidal features.

Rate this question:

Next Question

Previous Q... Tag Questi... Feedback End Session

A 23-year-old man who had a road traffic accident on his motorbike 1 month ago, resulting in a fixed femoral fracture, now presents complaining of dizziness that is worse on moving his head. He finds it difficult to mobilise and finds himself needing to lie down for much of the time because he feels nauseated.

On examination, his BP is 123/78 mmHg. He has fatiguable horizontal nystagmus.

Which of the following is the most likely cause?

A	Meniere's disease
B	Benign positional vertigo
C	Vestibulocochlear nerve injury
D	Oculomotor nerve injury
E	Vestibular neuronitis

20971

Submit

11:50
On
594-042-7551
Leave

On examination, his BP is 123/78 mmHg. He has fatiguable horizontal nystagmus.

Which of the following is the most likely cause?

Your answer was correct

A Meniere's disease

B Benign positional vertigo

C Vestibulocochlear nerve injury

D Oculomotor nerve injury

E Vestibular neuronitis

Explanation

B Benign positional vertigo

Benign positional vertigo (BPV) may occur in patients who have a history of head injury, such as this man. It is thought to occur due to the presence of displaced otolithic debris, which leads to abnormal sensations of movement, dizziness and nausea. Medications to treat BPV are generally much less effective than manoeuvres such as the Epley manoeuvre to reposition any debris, and it is these exercises, rather than medication, which form the mainstay of therapy.

A Meniere's disease

Meniere's is associated with progressive tinnitus, hearing loss and vertigo

Audio Video Share Participants More

11:50
On
594-042-7551
Leave

B Benign positional vertigo

Benign positional vertigo (BPV) may occur in patients who have a history of head injury, such as this man. It is thought to occur due to the presence of displaced otolithic debris, which leads to abnormal sensations of movement, dizziness and nausea. Medications to treat BPV are generally much less effective than manoeuvres such as the Epley manoeuvre to reposition any debris, and it is these exercises, rather than medication, which form the mainstay of therapy.

A Meniere's disease

Menière's is associated with progressive tinnitus, hearing loss and vertigo.

C Vestibulocochlear nerve injury

Vestibulocochlear nerve injury would be associated with permanent hearing loss and vertigo rather than the intermittent symptoms seen here.

D Oculomotor nerve injury

Third nerve palsy is associated with ophthalmoplegia rather than the picture of dizziness with horizontal nystagmus seen here.

E Vestibular neuronitis

This is associated with nausea, vomiting and vertigo, but would occur in the context of a viral illness rather than the acute injury seen here.

Rate this question:
Audio
Video
Share
Participants
More

11:50

A 36-year-old man is admitted with headache, pyrexia, neck stiffness and photophobia developing over 48 h. The headache is throbbing, frontal and worse if he flexes his neck, and during the last few hours he has had multiple episodes of violent vomiting. His wife, who accompanies him to the Emergency Department, says he has become agitated and inattentive in the last 24 h and is concerned that the headache is not relieved by simple analgesia.

In the last week, he had been to see his general practitioner (GP) with a sinus infection, and had been given a 5-day course of amoxicillin that he has completed the previous day.

He is drowsy, with a Glasgow coma score of 13/15. His temperature is 39ºC and he appears flushed. His blood pressure is 115/75 mmHg, with pulse 90/min and regular. There is marked neck stiffness. Fundoscopy is normal as is the rest of the cranial nerve examination, although he complains of tenderness over the brow.

On examination of the peripheral nervous system, tone, power and reflexes appear normal, but there is continuous twitching of the right hand and fingers.

The patient is commenced on IV cefotaxime 2 g. An urgent computerised tomography (CT) scan shows bone erosion and evidence of chronic frontal sinus infection, but otherwise no haemorrhage or cerebral abscess.

Lumbar puncture reveals:

Opening pressure	20 cm H_2O (5–18)
Protein	0.85 g/l (0.15–0.45)
WCC	120 cells/ml (90% lymphocytes) (≤ 5)
RCC	3 cells/ml (≤ 5)
Glucose	3.4 mmol/l (3.3–4.4)

Blood tests reveal:

Rana Alnasser's screen

Opening pressure	20 cm H_2O (5–18)
Protein	0.85 g/l (0.15–0.45)
WCC	120 cells/ml (90% lymphocytes) (≤ 5)
RCC	3 cells/ml (≤ 5)
Glucose	3.4 mmol/l (3.3–4.4)

Blood tests reveal:

Hb	135 g/l
WCC	18.0×10^9/l
PLT	232×10^9/l
CRP	34 mg/l (< 10)
Glucose	5.5 mmol/l

What is the likely diagnosis?

A	Viral meningitis
B	Treated subacute bacterial meningitis
C	Herpes simplex encephalitis
D	Subdural empyema
E	Cerebral thrombophlebitis

32746

Submit

11:55
On 594-042-7551 Leave

D Subdural empyema

This patient presents with a history in keeping with subdural empyema, most likely emanating from a frontal sinus infection. This would explain the symptoms of inattention and repeated partial seizures affecting the right hand and fingers, and meningeal irritation.

The cerebrospinal fluid (CSF) analysis reflects partially treated bacterial meningitis from a prior course of antibiotics; however, the developing focal neurological signs and reduced consciousness level imply an expanding focus of infection.
Subdural empyema originates from an infection in the frontal or ethmoid sinuses, less commonly from middle ear infection. Streptococci (*viridans* and non-haemolytic) are the most common organisms, followed by *Staphylococcus aureus*, *E. coli*, *Proteus* and *Pseudomonas*.

Magnetic resonance scanning is more sensitive than CT in demonstrating a collection of pus and meningeal enhancement, and should be arranged urgently. In the meantime, high-dose IV antibiotics and IV lorazepam should be given to treat infection and simple partial seizures. A commonly used antibiotic regime would include a beta-lactamase-stable penicillin, metronidazole and a cephalosporin. Cerebral thrombophlebitis can develop in these cases, but is not the primary diagnosis in this case.

B Treated subacute bacterial meningitis

The CSF picture is consistent with this, although the antecedent sinus infection means that a subdural empyema is the more likely diagnosis.

A Viral meningitis

Although there is CSF lymphocytosis, this is as a result of the course of oral antibiotics leading to a partially treated

Audio Video Share Participants More

11:56
On 594-042-7551 Leave

meantime, high-dose IV antibiotics and IV lorazepam should be given to treat infection and simple partial seizures. A commonly used antibiotic regime would include a beta-lactamase-stable penicillin, metronidazole and a cephalosporin. Cerebral thrombophlebitis can develop in these cases, but is not the primary diagnosis in this case.

B Treated subacute bacterial meningitis

The CSF picture is consistent with this, although the antecedent sinus infection means that a subdural empyema is the more likely diagnosis.

A Viral meningitis

Although there is CSF lymphocytosis, this is as a result of the course of oral antibiotics leading to a partially treated bacterial meningitis picture, rather than a primary viral origin to the infection.

C Herpes simplex encephalitis

Herpes simplex encephalitis is associated with temporal lobe changes on scanning, with gradual deterioration in memory and consciousness.

E Cerebral thrombophlebitis

This develops as a result of subdural empyema rather than being the primary diagnosis.

Rate this question:

Next Question

Audio Video Share Participants More

11:56
On 594-042-7551 Leave
MyPastest
https://mypastest.pastest.com

that the headache is not relieved by simple analgesia.

In the last week, he had been to see his general practitioner (GP) with a sinus infection, and had been given a 5-day course of amoxicillin that he has completed the previous day.

He is drowsy, with a Glasgow coma score of 13/15. His temperature is 39°C and he appears flushed. His blood pressure is 115/75 mmHg, with pulse 90/min and regular. There is marked neck stiffness. Fundoscopy is normal as is the rest of the cranial nerve examination, although he complains of tenderness over the brow.

On examination of the peripheral nervous system, tone, power and reflexes appear normal, but there is continuous twitching of the right hand and fingers.

The patient is commenced on IV cefotaxime 2 g. An urgent computerised tomography (CT) scan shows bone erosion and evidence of chronic frontal sinus infection, but otherwise no haemorrhage or cerebral abscess.

Lumbar puncture reveals:

Opening pressure	20 cm H_2O (5–18)
Protein	0.85 g/l (0.15–0.45)
WCC	120 cells/ml (90% lymphocytes) (≤ 5)
RCC	3 cells/ml (≤ 5)
Glucose	3.4 mmol/l (3.3–4.4)

Blood tests reveal:

Hb	135 g/l
WCC	18.0×10^9/l
PLT	232×10^9/l

C
D
E
0
10
Sessi
Responses
Responses
Responses
Responses
Audio Video Share Participants More

11:57
On 594-042-7551 Leave

A 31-year-old woman is brought to the Emergency Department by her husband. She has been ill recently with 'stomach flu' and now is increasingly drowsy, and has complained of double vision.

On examination, she has ophthalmoplegia, with absent reflexes and an ataxic gait. Bloods reveal an elevated C-reactive protein (CRP) of 85 mg/l, although white count is normal.

What diagnosis fits best with this clinical picture?

A	Miller-Fisher syndrome
B	Multiple sclerosis
C	Viral encephalitis
D	Bacterial meningitis
E	Myasthenia gravis

6619

Submit

Previous Q... Skip Questi...

© Pastest 2019

Audio Video Share Participants More

11:58
On 594-042-7551 Leave

A 31-year-old woman is brought to the Emergency Department by her husband. She has been ill recently with 'stomach flu' and now is increasingly drowsy, and has complained of double vision.

On examination, she has ophthalmoplegia, with absent reflexes and an ataxic gait. Bloods reveal an elevated C-reactive protein (CRP) of 85 mg/l, although white count is normal.

What diagnosis fits best with this clinical picture?

Your answer was correct

A	Miller-Fisher syndrome
B	Multiple sclerosis
C	Viral encephalitis
D	Bacterial meningitis
E	Myasthenia gravis

Difficu

Peer R

A
B
C
D
E
0 20

Sessi

Responses
Responses
Responses
Responses

Explanation

A	Miller-Fisher syndrome

This is the Miller-Fisher variant of Guillain-Barré syndrome (GBS), characterised by ophthalmoplegia, absent reflexes and an ataxic gait. Infections associated with the onset of GBS include *Campylobacter* infection, cytomegalovirus, Epstein-Barr virus, hepatitis B virus and herpes simplex virus. The current favoured treatment is intravenous (IV)

Audio Video Share Participants More

11:58
On 594-042-7551 Leave

A Miller-Fisher syndrome

This is the Miller-Fisher variant of Guillain-Barré syndrome (GBS), characterised by ophthalmoplegia, absent reflexes and an ataxic gait. Infections associated with the onset of GBS include *Campylobacter* infection, cytomegalovirus, Epstein-Barr virus, hepatitis B virus and herpes simplex virus. The current favoured treatment is intravenous (IV) immunoglobulin infusion. Prognosis is related to speed of onset, age and requirement for ventilation. Forced vital capacity (FVC) is regularly monitored in patients presenting with GBS, and drives admission to the High-dependency Unit for ventilatory support.

B Multiple sclerosis

The features of ophthalmoplegia and gait dysfunction so soon after a bout of gastroenteritis fit much more closely with a diagnosis of Miller-Fisher syndrome.

C Viral encephalitis

Viral encephalitis is associated with decreased consciousness, but confusion rather than motor weakness is usually more prominent.

D Bacterial meningitis

Although listeria meningitis may present with a subacute picture, including symptoms of confusion, it is commoner in pregnant women and the elderly. The picture here is therefore more consistent with the Miller-Fisher syndrome.

E Myasthenia gravis

Myasthenia gravis is associated with central muscle weakness, although it follows a slowly progressive course

Audio Video Share Participants More

11:58

soon after a bout of gastroenteritis fit much more closely with a diagnosis of Miller-Fisher syndrome.

C Viral encephalitis

Viral encephalitis is associated with decreased consciousness, but confusion rather than motor weakness is usually more prominent.

D Bacterial meningitis

Although listeria meningitis may present with a subacute picture, including symptoms of confusion, it is commoner in pregnant women and the elderly. The picture here is therefore more consistent with the Miller-Fisher syndrome.

E Myasthenia gravis

Myasthenia gravis is associated with central muscle weakness, although it follows a slowly progressive course and doesn't occur in relation to acute gastrointestinal (GI) illness.

Rate this question:

Next Question

Previous Q... Tag Questi... Feedback End Session

© Pastest 2019

Rana Alnasser's screen

4G 11:58

A 20-year-old obese woman presents to the Emergency Department with a 5-day history of progressively worsening generalised headache. In last few days, she has noticed some blurring of her vision and has started to feel nauseated, particularly early in the morning.

She has a history of severe acne treated with long-term oral doxycycline, and smokes 20 cigarettes a day.

On examination, she is orientated with a Glasgow Coma Score of 15/15. Fundoscopy reveals marked papilloedema and reduced visual acuity of 6/18 in both eyes. There is reduction in temporal visual fields bilaterally, and enlargement of the blind spot bilaterally. The remainder of the neurological examination is entirely normal.

Magnetic resonance (MR) brain scan is entirely normal.

Lumbar puncture reveals:

Opening pressure	32 cm H_2O (5–18)
Protein	0.43 g/l (0.15–0.45 g/l)
WCC	3 cells/ml (=5)
RCC	4 cells/ml (=5)

Regarding the management of this patient, which of the following is the most important next step to consider?

A Request an MR venogram

B Commence on acetazolamide

C Commence on steroids

D Advice about weight loss and smoking cessation

E Refer to the neurosurgeons for a

Rana Alnasser's screen

A Request an MR venogram

This patient presents with a history in keeping with raised intracranial pressure. She has risk factors for idiopathic intracranial hypertension (IIH), which typically occurs in obese females. Other risk factors include smoking, the oral contraceptive pill and other medications including tetracyclines, oral retinoids, amiodarone, cimetidine and minocycline. However, the history is short and secondary causes of raised ICP should be sought; therefore MR venogram is the correct answer.

B Commence on acetazolamide

This is a medical treatment used in IIH, but in this case secondary causes of raised pressure need to be sought first.

C Commence on steroids

There are no features in this case to suggest that steroids will be helpful. In cases of raised ICP due to tumour, steroids may be used to temporarily reduce oedema around the lesion, thus reducing pressure.

D Advice about weight loss and smoking cessation

This is important advice in the long-term management of IIH, but in this situation the priority is to investigate for secondary causes.

E Refer to the neurosurgeons for a ventriculoperitoneal shunt

This may be necessary in severe cases of IIH where vision is threatened, but secondary causes of raised pressure (such

Rana Alnasser's screen

first.

C Commence on steroids

There are no features in this case to suggest that steroids will be helpful. In cases of raised ICP due to tumour, steroids may be used to temporarily reduce oedema around the lesion, thus reducing pressure.

D Advice about weight loss and smoking cessation

This is important advice in the long-term management of IIH, but in this situation the priority is to investigate for secondary causes.

E Refer to the neurosurgeons for a ventriculoperitoneal shunt

This may be necessary in severe cases of IIH where vision is threatened, but secondary causes of raised pressure (such as venous sinus thrombosis) need to be excluded as a priority.

Rate this question:

Next Question

© Pastest 2019

12:01
On
594-042-7551
Leave

A 21-year-old man presented with a 7-month history of difficulty gripping things. He complained of finding it particularly difficult in the cold weather. He had lost contact with his father but he remembered him having similar problems in later life.

On examination, he had a bilateral ptosis with weakness of the facial muscles. He also had difficulty opening his eyes quickly. Limb examination revealed distal weakness in both hands with difficulty opening and closing both hands quickly.

What is the most likely diagnosis?

A	Mitochondrial encephalomyopathy, lactic acidosis and stroke-like episodes (MELAS)
B	Becker's muscular dystrophy
C	Myotonic dystrophy type 1
D	Myasthenia gravis
E	Duchenne's muscular dystrophy

Submit

Audio
Video
Share
Participants
More

12:01
On
594-042-7551
Leave

Ptosis and ophthalmoplegia can be seen in mitochondrial diseases. However, this patient does not have any of the clinical features that make up the MELAS acronym.

B Becker's muscular dystrophy

First, the age onset is rather late (although late onset cases are described). Second, pure upper limb disease is not seen in Becker's. Third, Becker's is an X-linked condition, male-to-male transmission being impossible. Finally, myotonia (in this case, the inability to release grip or open the eyes quickly) is not a feature.

D Myasthenia gravis

The key clinical features of myasthenia are variability and fatigability of symptoms. For example, patients with myasthenia gravis develop increasingly severe ptosis the longer they try to keep their eyes open. Additionally, cold improves neuromuscular junction transmission. Thus, patients with myasthenia get better, not worse, in the cold (this is the basis for the 'ice-pack test').

E Duchenne's muscular dystrophy

Duchenne's is an X-linked condition (hence male-to-male transmission is impossible) with a median age at diagnosis of 4 years. Myotonia is not a feature.

Rate this question:

Next Question

Previous Q... Tag Questi... Feedback End Session
Audio Video Share Participants More

contact with his father but he remembered him having similar problems in later life.

On examination, he had a bilateral ptosis with weakness of the facial muscles. He also had difficulty opening his eyes quickly. Limb examination revealed distal weakness in both hands with difficulty opening and closing both hands quickly.

What is the most likely diagnosis?

Your answer was correct

A Mitochondrial encephalomyopathy, lactic acidosis and stroke-like episodes (MELAS)

B Becker's muscular dystrophy

C Myotonic dystrophy type 1

D Myasthenia gravis

E Duchenne's muscular dystrophy

Explanation

C Myotonic dystrophy type 1

This patient has myotonia manifesting as problems opening the eyes and releasing the grip quickly. There is a suggestion of autosomal dominant inheritance with anticipation (the reduction in age of onset as the disease passes down the generations, caused by expansion of the trinucleotide repeat in the *DMPK* gene). There is distal limb involvement, which is relatively rare in other myopathies; myotonic dystrophy type 1 is a key exception. Myotonia is [illegible] described in this case.

Rana Alnasser's screen

A 78-year-old right-handed woman is referred to the Emergency Department with sudden onset left hemiparesis. Her Glasgow Coma Scale fluctuates between 15/15 and 14/15; blood pressure is 129/96 mmHg.

Emergency computerised tomography (CT) shows a moderate-sized haematoma in the basal ganglia with minimal mass effect.

What is the initial management?

A	Admission to the stroke unit
B	Neurosurgical intervention
C	Intravenous dexamethasone
D	Oral nimodipine
E	Intravenous vitamin K

7315

Submit

Previous Q... Skip Questi...

© Pastest 2019

A 78-year-old right-handed woman is referred to the Emergency Department with sudden onset left hemiparesis. Her Glasgow Coma Scale fluctuates between 15/15 and 14/15; blood pressure is 129/96 mmHg.

Emergency computerised tomography (CT) shows a moderate-sized haematoma in the basal ganglia with minimal mass effect.

What is the initial management?

Your answer was correct

A Admission to the stroke unit

B Neurosurgical intervention

C Intravenous dexamethasone

D Oral nimodipine

E Intravenous vitamin K

Explanation

A Admission to the stroke unit

The most important management step is observation of the Glasgow coma scale, preferably in a dedicated stroke unit.

B Neurosurgical intervention

B Neurosurgical intervention

Most haemorrhagic strokes do not require surgical intervention. The main reason for surgery is the presence of hydrocephalus. For this reason patients should be closely monitored on a stroke or neurosurgical unit.

C Intravenous dexamethasone

Corticosteroids have not been found to be of benefit in haemorrhagic stroke.

D Oral nimodipine

This is used in subarachnoid haemorrhage to decrease the risk of secondary vasospasm.

E Intravenous vitamin K

Vitamin K would have no role to play in a patient not known to be taking warfarin.

7315

Rate this question:

Next Question

© Pastest 2019

A 78-year-old gentleman with known angina presents complaining of difficulty in walking, which has got worse throughout the day. He does not complain of back or leg pain and there is no history of trauma.

During his stay in the Accident and Emergency Department, his condition deteriorates and after 4 h he is unable to stand and complains of being unable to pass water.

On examination, he is found to have developed a flaccid paralysis with hyperaesthesia in the T_{12} dermatome, and reduced sensation below this point. Vibration sensation and proprioception remain intact. There is a palpable bladder.

What is the most likely diagnosis?

A Anterior spinal artery syndrome

B Malignant spinal cord compression

C Transverse myelitis

D Thoracic disc prolapse

E Epidural abscess

Submit

Explanation

A Anterior spinal artery syndrome

Anterior spinal artery syndrome results from ischaemia or infarction of the spinal cord in the distribution of the anterior spinal artery, which supplies the ventral two-thirds of the spinal cord. This condition is usually associated with atherosclerosis of the aorta and may result from dissection of an aortic aneurysm or, rarely, dissection of the anterior spinal artery. The onset is either acute or subacute and stuttering (as in this case). Clinical features include weakness and loss of pain and temperature sensation below the level of injury, with relative sparing of position and vibratory sensation.

B Malignant spinal cord compression

One would expect a slower onset of symptoms with compressive lesions due to a tumour. In addition, such cases are usually accompanied by back pain. Sparing of posterior column function would not be expected.

C Transverse myelitis

This is an inflammatory lesion that can affect the cord at any level. In this age group it is an unusual cause of a spinal cord syndrome, with compression or ischaemia both being more probable.

D Thoracic disc prolapse

This is a reasonable differential diagnosis. However, such cases are usually accompanied by back pain. Sparing of posterior column function would not be expected.

E Epidural abscess

Rana Alnasser's screen

12:05
On
594-042-7551
Leave

spinal artery. The onset is either acute or subacute and stuttering (as in this case). Clinical features include weakness and loss of pain and temperature sensation below the level of injury, with relative sparing of position and vibratory sensation.

B Malignant spinal cord compression

One would expect a slower onset of symptoms with compressive lesions due to a tumour. In addition, such cases are usually accompanied by back pain. Sparing of posterior column function would not be expected.

C Transverse myelitis

This is an inflammatory lesion that can affect the cord at any level. In this age group it is an unusual cause of a spinal cord syndrome, with compression or ischaemia both being more probable.

D Thoracic disc prolapse

This is a reasonable differential diagnosis. However, such cases are usually accompanied by back pain. Sparing of posterior column function would not be expected.

E Epidural abscess

In this syndrome one would expect back pain, fever and tenderness around the affected area.

Rate this question:

Next Question

Audio Video Share Participants More

12:05

A 20-year-old man went to see his GP because of recent onset of difficulty in breathing on mild exertion. He gave a 6-year history of weakness of his limbs, such that he was never able to pursue athletic activities in his school. His father and mother are cousins. Neither of his parents has any medical problem and he has two normal younger siblings. There was no history of muscle cramps and no discoloration of his urine.

On examination, he had weakness of the shoulder and pelvic girdle muscles. Truncal muscles were also weak. On deep inspiration, the anterior abdominals had a tendency to retract. Tendon reflexes were reduced in all four limbs. There were no sensory signs.

What is the most likely diagnosis?

A	Amyotrophic lateral sclerosis
B	Polymyositis
C	Familial hypokalaemic periodic paralysis
D	Tarui disease
E	Acid maltase deficiency

Submit

Rana Alnasser's screen

A 20-year-old man went to see his GP because of recent onset of difficulty in breathing on mild exertion. He gave a 6-year history of weakness of his limbs, such that he was never able to pursue athletic activities in his school. His father and mother are cousins. Neither of his parents has any medical problem and he has two normal younger siblings. There was no history of muscle cramps and no discoloration of his urine.

On examination, he had weakness of the shoulder and pelvic girdle muscles. Truncal muscles were also weak. On deep inspiration, the anterior abdominals had a tendency to retract. Tendon reflexes were reduced in all four limbs. There were no sensory signs.

What is the most likely diagnosis?

Your answer was correct

A Amyotrophic lateral sclerosis

B Polymyositis

C Familial hypokalaemic periodic paralysis

D Tarui disease

E Acid maltase deficiency

Explanation

E Acid maltase deficiency

Acid maltase deficiency (glycogen storage myopathy type

Explanation

E	Acid maltase deficiency

Acid maltase deficiency (glycogen storage myopathy type 2) has three clinical forms. The adult form that is depicted in this scenario is a slowly progressive weakness of the shoulder, pelvic girdle and truncal muscles. At times the diaphragmatic weakness is the prime difficulty, which brings the patient to the Accident and Emergency Department, and so the differential diagnosis would include motor neurone disease, myasthenia gravis and nemaline rod myopathy. Diagnosis is confirmed by muscle biopsy.

The sarcoplasm of affected cells is vacuolated and the vacuoles contain Periodic acid–Schiff (PAS)-positive diastase digestible material. The glycogen particles lie in aggregates. Electron microscopy shows some of these to occupy lysosomal vesicles (i.e. this is a lysosomal disease), and others to lie free. Positive ischaemic forearm tests may occur in patients with other forms of glycogen storage disorder (namely, Cori disease, McArdle disease and Tarui disease). However, a normal test result would be expected in acid maltase deficiency. Acid maltase deficiency presenting in adulthood carries a better prognosis than the infantile form, and patients are known to survive until the 6th or 7th decade.

A	Amyotrophic lateral sclerosis

Classical amyotrophic lateral sclerosis is associated with bulbar palsy, and the long duration of symptoms, including difficulty performing sports at school, counts against ALS as the diagnosis.

B	Polymyositis

Polymyositis is associated with muscle weakness, although

STC 55% 7:24 AM
https://mypastest.paste

A 30-year old woman is seen in the Emergency Department with an excruciating, throbbing left-sided headache which is mainly orbital and temporal in location. She complains of photophobia, and is curling up into a ball to try to stop it getting worse. Her left eye is red and tearful. She also has a runny nose.

She has no past medical history of note, but has been experiencing recurrent episodes of this headache. Each episode lasts between 5 and 25 min, and may come on at any time. She has been experiencing at least 12 episodes each day.

What treatment is most likely to be effective for this patient?

Audio Video Stop Share Participants More

STC 55% 7:25 AM
https://mypastest.paste

What treatment is most likely to be effective for this patient?

A High-flow oxygen

B Metoclopramide

C Indomethacin

D Amitriptyline

E Codeine phosphate

7594

Audio Video Stop Share Participants More

STC 55% 7:26 AM
https://mypastest.paste

Explanation

C Indomethacin

This patient has chronic paroxysmal hemicrania (CPH), which is characterised by unilateral pain which is generally oculo-fronto-temporal in location. It can occur at any time, and patients often describe a throbbing, boring, pulsating or claw-like pain. Frequency of attacks is usually 10–20 per day. Episodes usually last 2–25 min, but may last as long as 60 min. Patients may also complain of ipsilateral conjunctival injection, ptosis and lid swelling, lacrimation and rhinorrhoea. Occasionally photophobia

Audio Video Stop Share Participants More

STC 55% 7:27 AM
https://mypastest.paste

Patients may also complain of ipsilateral conjunctival injection, ptosis and lid swelling, lacrimation and rhinorrhoea. Occasionally photophobia may be present. The most effective treatment is with indomethacin.

A High-flow oxygen

High-flow oxygen is the intervention of choice for cluster headache, which is more likely to be the diagnosis in a patient with more prolonged, less frequent headaches.

B Metoclopramide

Audio Video Stop Share Participants More

STC 55% 7:27 AM
https://mypastest.paste

B Metoclopramide

Metoclopramide is a potential short-term option to relieve nausea associated with acute episodes of migraine.

D Amitriptyline

Amitriptyline is a potential first-line therapy for migraine prophylaxis, rather than for paroxysmal hemicrania.

E Codeine phosphate

Codeine is unlikely to be effective in this case and can potentially drive issues around both opiate-related

Audio Video Stop Share Participants More

STC 55% 7:28 AM
https://mypastest.paste

As the medical registrar, you are called to see an 83-year-old male patient on the surgical wards who is recovering from a total hip replacement operation and who has gradually become increasingly confused over the last 24 h. His past medical history is significant for type II diabetes and hypertension, and he told the nursing staff that he likes to drink brandy each evening.

You are not able to hold a conversation with him, since he appears to be disorientated in time and place with perseveration of speech. He keeps complaining that he can see ants crawling over his body and that the nursing staff have put them there.

Audio Video Stop Share Participants More

STC 54% 7:29 AM
https://mypastest.paste

with him, since he appears to be disorientated in time and place with perseveration of speech. He keeps complaining that he can see ants crawling over his body and that the nursing staff have put them there.

Examination of his chest reveals no signs of infection, His blood pressure is raised at 142/82, pulse is 88 and regular and he is sweating. Routine blood tests are performed and an electrocardiogram (ECG) is requested. He is apyrexial.

Which one of the following would you consider the most likely cause of his symptoms?

Audio Video Stop Share Participants More

STC 54% 7:29 AM
https://mypastest.paste

Which one of the following would you consider the most likely cause of his symptoms?

A Hypoglycaemia

B Opiate analgesia

C Transient ischaemic attack

D Alcohol withdrawal

E Urinary tract infection

6658

Audio Video Stop Share Participants More

STC 54% 7:29 AM
https://mypastest.paste

Explanation

D Alcohol withdrawal

An acute confusional state is common in hospitalised patients, especially the elderly, and characteristically takes place over hours or days and is usually accompanied by signs of physical ill health such as infection or drug toxicity. It has a fluctuating course, being worse at night with lucid spells during the day. The person is often disorientated for time and place, but not for people. The patient is usually fearful, irritable and may be aggressive: paranoid ideas and visual and auditory hallucinations are

Audio Video Stop Share Participants More

STC 54% 7:30 AM
https://mypastest.paste

admission), coupled with the tactile hallucinations and signs of sympathetic activation, in the absence of other features to suggest infection, points us towards a diagnosis of alcohol withdrawal. B1 vitamin replacement and a reducing course of chlordiazepoxide are important interventions.

A Hypoglycaemia

Hypoglycaemia is associated with confusion and aggression, but these features are usually rapidly progressive as blood glucose level falls, rather than the subacute picture of symptoms seen here.

Audio Video Stop Share Participants More

STC 54% 7:30 AM
https://mypastest.paste

B Opiate analgesia

Opiate analgesia is more likely to lead to drowsiness and hypoventilation rather than the symptoms/signs of activation and aggression seen here.

C Transient ischaemic attack

Transient ischaemic attacks rarely produce symptoms of global confusion, and are much more likely to be associated with focal neurological signs.

E Urinary tract infection

Audio Video Stop Share Participants More

STC 54% 7:30 AM
https://mypastest.paste

be associated with focal neurological signs.

E	Urinary tract infection

There are no urinary symptoms or signs of infection to suggest a UTI in this case.

6658

Rate this question:

Next Question

Audio Video Stop Share Participants More

STC 54% 7:31 AM
https://mypastest.paste

An 84-year-old man with a history of atrial fibrillation and a previous transient ischaemic attack (TIA) attends the Emergency Department with a large haematoma of the right hip due to a fall where he tripped over a loose carpet tile. He lives independently, and this is his only fall during the course of the last 3 years. Medication includes ramipril, atorvastatin and warfarin.

On examination, his BP is 142/77 mmHg, pulse 77/min, atrial fibrillation. You notice bilateral carotid bruits on cardiovascular system examination.

Investigations:

Hb	10.9 g/dl

Audio Video Stop Share Participants More

STC 54% 7:32 AM
https://mypastest.paste

On examination, his BP is 142/77 mmHg, pulse 77/min, atrial fibrillation. You notice bilateral carotid bruits on cardiovascular system examination.

Investigations:

Hb	10.9 g/dl
WCC	6.8×10^9/l
PLT	183×10^9/l
Na^+	141 mmol/l
K^+	4.4 mmol/l
Creatinine	149 µmol/l
INR	2.1

Audio Video Stop Share Participants More

STC 54% 7:32 AM
https://mypastest.paste

Which of the following is the most appropriate way to manage his thromboembolism prophylaxis long-term?

A Withdraw warfarin

B Change warfarin to aspirin

C Change warfarin to dipyridamole

D Change warfarin to clopidogrel

E Continue warfarin

Audio Video Stop Share Participants More

STC 54% 7:34 AM
https://mypastest.paste

Explanation

E Continue warfarin

In a situation like this, the debate is between continuing warfarin and running the risk of further bleeding episodes, and stopping warfarin and running the consequent increased risk of further TIAs or a completed stroke. In this case, with persistent atrial fibrillation (AF) and evidence of bilateral carotid stenoses, the risk of further TIAs or a stroke is considerable; as such, it is best to continue warfarin.

A Withdraw warfarin

Audio Video Stop Share Participants More

STC 53% 7:34 AM
https://mypastest.paste

A Withdraw warfarin

Withdrawing warfarin is not appropriate given this patient's high risk of a stroke, and the fact that the fall is explained by a fall over a carpet tile.

B Change warfarin to aspirin

The Birmingham Atrial Fibrillation Treatment of the Aged (BAFTA) *study* (amongst others) suggests a 50% reduction in stroke risk for warfarin versus aspirin in an elderly population.

C Change warfarin to

Audio Video Stop Share Participants More

STC 53% 7:34 AM
https://mypastest.paste

C Change warfarin to dipyridamole

Although dipyridamole was utilised in conjunction with aspirin for stroke prevention in the ESPS-2 study, here it is inferior to warfarin because of the presence of AF.

D Change warfarin to clopidogrel

Clopidogrel is superior to aspirin for stroke prevention in the absence of AF, but the presence of AF drives us to utilise warfarin here.

Audio Video Stop Share Participants More

STC 53% 7:36 AM
https://mypastest.paste

A 34-year-old woman was on a camping holiday in Spain. She awoke at three o'clock one morning with severe neck pain radiating down into her left shoulder and down to her forearm. The next day it spread to the dorsal aspect of the forearm. She was otherwise well. Her symptoms resolved after 24 hours. She noticed that after a week she was unable to wind down the car window with her left arm, and now presents to the Emergency Department. On examination of the left arm there is wasting of brachioradialis, shoulder and biceps and winging of the left scapula.

Weakness of which muscle is most likely to have caused winging of the scapula?

Audio Video Stop Share Participants More

STC 53% 7:36 AM
https://mypastest.paste

Weakness of which muscle is most likely to have caused winging of the scapula?

A Serratus anterior

B Infraspinatus

C Rhomboids

D Trapezius

E Deltoid

32744

Audio Video Stop Share Participants More

STC 53% 7:37 AM
https://mypastest.paste

Explanation

A Serratus anterior

This woman has pain in her left shoulder radiating down her forearm, which has progressed rapidly (over <24 h). There is no evidence of systemic illness and onset of left-arm weakness is apparent around a week later. The serratus anterior is supplied by the long thoracic nerve (C5, C6, C7), weakness of which leads to winging of the scapula. Amyotrophic neuralgia characteristically affects these nerve routes and is associated with sudden onset of pain, followed by muscle wasting over the next few days.

Audio Video Stop Share Participants More

STC 53% 7:38 AM
https://mypastest.paste

with sudden onset of pain, followed by muscle wasting over the next few days. The condition improves spontaneously over a prolonged period. Aetiology is unknown, but may be a post-infective phenomenon. Physiotherapy aimed at preserving full movement of the shoulder, accompanied by adequate analgesia, is the mainstay of therapy.

B	Infraspinatus

The infraspinatus is the major muscle responsible for external rotation of the shoulder, and when the arm is fixed it abducts the inferior angle of the scapula.

Audio Video Stop Share Participants More

STC 53% 7:38 AM
https://mypastest.paste

C Rhomboids

The rhomboids work in tandem with the levator scapulae muscles to elevate the medial border of the scapula, downwardly rotating the scapula with respect to the glenohumeral joint.

D Trapezius

The upper and lower fibres tend to rotate the scapula around the sternoclavicular articulation so that the acromion and inferior angles move up and the medial border moves down. This rotation is in the opposite direction to that produced by the levator scapulae and the rhomboids.

Audio Video Stop Share Participants More

STC 53% 7:38 AM
https://mypastest.paste

The middle fibres retract the scapula, but it is the function of the serratus anterior to prevents winging.

E	Deltoid

The main action of the deltoid muscle in its entirety is shoulder abduction. Intact deltoid function is also essential to prevent subluxation of the shoulder joint.

32744

Rate this question:

Next Question

Audio Video Stop Share Participants More

STC 53% 7:38 AM
https://mypastest.paste

A 56-year-old man presented with a 3-year history of progressive leg weakness, with particular problems walking up the stairs. This was associated with intermittent pains in his thighs anteriorly. In the previous year he had also noticed problems unscrewing lids from jars, which he felt was due to his grip being generally weaker. He had been well otherwise with no recent weight loss or other symptoms.

Examination revealed wasting of the forearms and the quadriceps, with distal weakness in the upper limb and proximal weakness in the lower limb. Reflexes were present with flexor plantar responses. Sensation and

Audio Video Stop Share Participants More

STC 53% 7:40 AM
https://mypastest.paste

plantar responses. Sensation and coordination were normal.

What is the most likely diagnosis?

A Myotonic dystrophy

B Motor neurone disease

C Addison's disease

D Inclusion body myositis (IBM)

E Polymyositis

6948

Audio Video Stop Share Participants More

STC 53% 7:42 AM
https://mypastest.paste

Explanation

D Inclusion body myositis (IBM)

Inclusion body myositis (IBM) is the most common acquired myopathy in those aged over 50 years, being more common in men than women. There is often fairly selective muscle involvement, with wasting and weakness of the quadriceps and the long finger flexors being the most common. Muscles can also be affected asymmetrically. The pattern of muscle involvement is thus different to polymyositis (PM) or dermatomyositis (DM), and the rate of progression is generally slower than with these

Audio Video Stop Share Participants More

STC 52% 7:43 AM
https://mypastest.paste

(around 1000 IU/l) but generally not as high as in PM or DM.
Electromyography (EMG) and sometimes muscle biopsy will help in the diagnosis. IBM is much less responsive to immunosuppressive treatment than PM or DM.

A	Myotonic dystrophy

Symptoms of myotonic dystrophy generally present during the third decade with muscle weakness and myotonia (failure of muscles to relax for a prolonged period after use). Other features include infertility/subfertility and frontal balding in men.

Audio Video Stop Share Participants More

STC 52% 7:43 AM
https://mypastest.paste

B Motor neurone disease

The selective muscle involvement seen here is much more consistent with inclusion body myositis than motor neurone disease.

C Addison's disease

Although adrenal insufficiency is associated with proximal muscle weakness, other features that would suggest a diagnosis of adrenal insufficiency are absent here.

E Polymyositis

Audio Video Stop Share Participants More

STC 52% 7:43 AM
https://mypastest.paste

E Polymyositis

The selective muscle weakness seen here is inconsistent with polymyositis, with wasting of the quadriceps being the only proximal symptom seen here.

6948

Rate this question:

Next Question

Previous Question
Tag Question
Feedback
End Session

Audio
Video
Stop Share
Participants
More

STC 52% 7:44 AM
https://mypastest.paste

A 23-year-old woman is referred to the Neurology Clinic with a 6-month history of diffuse headache. This initially began as occasional pain occurring only at certain times during the week. It has increased, however, to the point where it is continuous. She notices that the pain is worse in the morning and she has had some mild nausea. She also describes some greying of her vision on exertion or on bending down to pick something up from the floor. She has a past medical history of depression and is taking fluoxetine for this. She also takes the oral contraceptive pill and tetracycline for acne vulgaris.

On examination, she has gross

Audio Video Stop Share Participants More

STC 52% 7:45 AM
https://mypastest.paste

On examination, she has gross papilloedema affecting both eyes. There is enlargement of the blind spot with some diplopia on left lateral gaze. Her body mass index is 32. There are no other neurological signs.

A magnetic resonance (MR) brain scan is performed, which shows no space-occupying lesion.

Cerebrospinal fluid analysis demonstrates an opening pressure of 33 cm of water. CSF analysis is shown below.

WCC	< 1
RCC	< 1

Audio Video Stop Share Participants More

STC 52% 7:46 AM
https://mypastest.paste

WCC	< 1
RCC	< 1
Glucose	4.1/6.5 mmol/l (serum 6.4)
Protein	0.3 g/dl

What is the most likely diagnosis?

A Tuberculous meningitis

B Idiopathic intracranial hypertension

C Caroto-cavernous fistula

Audio Video Stop Share Participants More

STC 52% 7:46 AM
https://mypastest.paste

Protein	0.3 g/dl

What is the most likely diagnosis?

A Tuberculous meningitis

B Idiopathic intracranial hypertension

C Caroto-cavernous fistula

D Primary intracerebral lymphoma

E Bilateral optic nerve glioma

Audio Video Stop Share Participants 1 More

STC 52% 7:46 AM
https://mypastest.paste

Explanation

B	Idiopathic intracranial hypertension

This young woman has multiple risk factors for idiopathic intracranial hypertension (IIH) including obesity and oral contraceptive and tetracycline use. This condition was previously called 'benign' intracranial hypertension. However, many neurologists feel that it is better described as idiopathic, partly to highlight the sometimes not benign prognosis (particularly when it comes to ophthalmological complications and visual loss) but also to highlight the extent to which this is a diagnosis of

Audio Video Stop Share Participants More

STC 52% 7:46 AM
https://mypastest.paste

hypertension. However, many neurologists feel that it is better described as idiopathic, partly to highlight the sometimes not benign prognosis (particularly when it comes to ophthalmological complications and visual loss) but also to highlight the extent to which this is a diagnosis of exclusion of other causes of intracranial hypertension. This patient would usually also have a CT or MR venogram to exclude cerebral venous sinus thrombosis as the cause for her raised ICP.

A. Tuberculous meningitis

The normal CSF constituents

Audio Video Stop Share Participants More

STC 52% 7:46 AM
https://mypastest.paste

A Tuberculous meningitis

The normal CSF constituents essentially exclude this diagnosis.

C Caroto-cavernous fistula

The normal brain imaging essentially excludes this diagnosis.

D Primary intracerebral lymphoma

One would expect either abnormal brain imaging or CSF (or likely both) with this condition.

Audio Video Stop Share Participants More

STC 51% 7:46 AM
https://mypastest.paste

E Bilateral optic nerve glioma

This would likely present with visual failure, rather that headache, and would be expected to show up on MRI (although subtle optic nerve lesions can be missed on routine scans with no contrast).

32709

Rate this question:

Next Question

Audio Video Stop Share Participants More

STC 51% 7:48 AM
https://mypastest.paste

Sedation and muscle relaxants were tapered off, and repeated attempts to wean him from the ventilator failed.

On examination, he was conscious and alert. Cranial nerve examination was unremarkable. His shoulder girdle muscles were grade 2 power and pelvic girdle muscles were grade 1. Tendon reflexes were preserved. The remainder of the examination was normal.

Choose the most likely diagnosis:

A Guillain–Barré syndrome

B Critical illness myopathy

Audio Video Stop Share Participants More

STC 51% 7:48 AM
https://mypastest.paste

remainder of the examination was normal.

Choose the most likely diagnosis:

A	Guillain–Barré syndrome
B	Critical illness myopathy
C	Myasthenia gravis
D	Inclusion body myositis
E	Corticosteroid myopathy

Audio Video Stop Share Participants 1 More

STC 51% 7:51 AM
https://mypastest.paste

Explanation

B Critical illness myopathy

This acute myopathy occurs in critical systemic disease, usually with multi-organ failure in the context of treatment with inotropes, muscle relaxants and corticosteroids. Serum creatine phosphokinase (CPK) is elevated and electromyography (EMG) reveals myopathic motor unit potentials and fibrillations. Muscle biopsy reveals loss of myosin filaments. Most patients recover after several weeks. In some patients the picture is one of neuromyopathy, so reduced reflexes and sensory loss can be seen.

Audio Video Stop Share Participants More

STC 50% 7:54 AM
https://mypastest.paste

reveals myopathic motor unit potentials and fibrillations. Muscle biopsy reveals loss of myosin filaments. Most patients recover after several weeks. In some patients the picture is one of neuromyopathy, so reduced reflexes and sensory loss can be seen.

A Guillain–Barré syndrome

GBS is an acute, immune-mediated neuropathy where one would expect areflexia and sensory loss in addition to weakness.

C Myasthenia gravis

Whilst this can cause proximal limb

Audio Video Stop Share Participants More

STC 50% 7:54 AM
https://mypastest.paste

C Myasthenia gravis

Whilst this can cause proximal limb weakness, it would be unusual to have no ocular or bulbar involvement.

D Inclusion body myositis

This is a chronic, progressive muscle disease that characteristically causes weakness in the forearm flexors and quadriceps. It does not present acutely.

E Corticosteroid myopathy

Audio Video Stop Share Participants More

STC 50% 7:54 AM
https://mypastest.paste

This is a chronic, progressive muscle disease that characteristically causes weakness in the forearm flexors and quadriceps. It does not present acutely.

E	Corticosteroid myopathy

This is a side effect from chronic steroid use, and usually presents with mild proximal lower limb weakness.

727

Rate this question:

Next Question

Audio Video Stop Share Participants More

STC 44% 5:36 PM
https://mypastest.paste

A 64-year-old man is brought by his wife to the Accident and Emergency Department as he developed sudden memory impairment some 4 h earlier. According to his wife, he stepped out of a cold shower and was subsequently unable to describe his whereabouts, and was complaining of a mild global headache.

On examination, his temperature is 37 °C, blood pressure is 140/90 mmHg and pulse is 78 bpm and regular.

On further questioning, he is alert but disorientated in place and time, and can describe who he is. Whilse he can repeat back the names of three objects, he is unable to recall them after 3 min. There is retrograde

Audio Video Stop Share Participants More

STC 44% 5:37 PM
https://mypastest.paste

repeat back the names of three objects, he is unable to recall them after 3 min. There is retrograde amnesia for several hours. Visuospatial discrimination is normal and there are no other neurological deficits.

The next morning, he has completely recovered. Haematological and biochemical investigations are entirely normal.

What is the most likely diagnosis?

A Transient ischaemic attack

B Complex partial seizure

Audio Video Stop Share Participants More

STC 44% 5:37 PM
https://mypastest.paste

normal.

What is the most likely diagnosis?

A	Transient ischaemic attack
B	Complex partial seizure
C	Migraine
D	Transient Global Amnesia
E	Frontotemporal dementia

32766

Audio Video Stop Share Participants More

STC 44% 5:37 PM
https://mypastest.paste

D Transient Global Amnesia

Transient global amnesia is characterised by an episode of amnesia and bewilderment in middle-aged and elderly people, lasting for several hours. During the attack there is no impairment of consciousness or signs of confusion. Personal identity is intact. The patient behaves normally except for repeated questioning about his immediate circumstances or whereabouts. A typical scenario is sketched in the above question. The pathogenesis is not settled. Recurrence rate is approximately 5%, and some case series appear to show an increased risk of cerebrovascular

Audio Video Stop Share Participants More

STC 44% 5:38 PM
https://mypastest.paste

pathogenesis is not settled. Recurrence rate is approximately 5%, and some case series appear to show an increased risk of cerebrovascular disease over the longer term.

A Transient ischaemic attack

The lack of vascular risk factors in this patient, coupled with the absence of focal neurology, counts against a diagnosis of TIA.

B Complex partial seizure

Complex partial seizures are usually characterised by repeated episodes of

Audio Video Stop Share Participants More

STC 44% 5:38 PM
https://mypastest.paste

insight, rather than the picture seen here.

C	Migraine

Migraine is classically associated with a frontal headache, nausea and vomiting, preceded by an auro which hasn't been seen here.

E	Frontotemporal dementia

This is associated with inappropriate activity including sexualised and aggressive behaviour over a period before significant memory deficits become apparent.

Audio Video Stop Share Participants More

STC 44% 5:39 PM
https://mypastest.paste

A 22-year-old woman visits her GP, feeling very distressed. She woke up that morning with a sensation that her left cheek was feeling heavy. She immediately saw herself in the mirror and was horrified to find that her face was twisted. She could not close her left eye. Saliva drooled from the angle of her mouth on the left side. She was extremely distressed to note that when she tried to smile her mouth deviated to the right side. There is some sense of giddiness and hearing is muffled on the left side. Her grandmother had had a stroke 4 weeks ago. The only medication of note is the oral contraceptive pill.

On examination, her blood pressure is

Audio Video Stop Share Participants More

STC 43% 5:40 PM
https://mypastest.paste

contraceptive pill.

On examination, her blood pressure is 142/72 mmHg, her pulse is 90/min and she is anxious. Examination of her left ear reveals a few tense vesicles in her left ear and there is left-sided facial nerve palsy.

What is the most likely diagnosis?

A	Infection of the left-side gasserian ganglion
B	Herpes simplex infection
C	Left-sided acoustic neuroma

Audio Video Stop Share Participants More

STC 43% 5:40 PM
https://mypastest.paste

What is the most likely diagnosis?

A Infection of the left-side gasserian ganglion

B Herpes simplex infection

C Left-sided acoustic neuroma

D Atypical migraine

E Herpes zoster infection

32775

Audio Video Stop Share Participants More

STC 43% 5:44 PM
https://mypastest.paste

E Herpes zoster infection

This is Ramsay Hunt syndrome, a lower motor neurone facial palsy on the left side, and due presumably to herpes zoster of the geniculate ganglion. Vesicular eruption in the external auditory canal, other parts of the cranial integument and the mucous membrane of the oropharynx is usually seen, but it may not be apparent for days or may never appear. Often the eighth cranial nerve is affected as well, causing deafness and vertigo. The virus can be detected by collecting exudates from the skin of the pinna on a Schirmer strip and applying PCR. Treatment with prednisolone and acyclovir in combination is of value

Audio Video Stop Share Participants More

STC 43% 5:44 PM
https://mypastest.paste

acyclovir in combination is of value providing it is commenced within 7 days of onset of symptoms.

A Infection of the left-side gasserian ganglion

This is the alternative name for the trigeminal ganglion. Herpes zoster can lie dormant in the trigeminal ganglion and lead to areas of shingles on the face and altered sensation later in life.

B Herpes simplex infection

Herpes simplex infection leads to the development of cold sores, rather than the VIIth nerve palsy seen here.

Audio Video Stop Share Participants More

STC 43% 5:44 PM
https://mypastest.paste

B Herpes simplex infection

Herpes simplex infection leads to the development of cold sores, rather than the VIIth nerve palsy seen here.

C Left-sided acoustic neuroma

The absence of hearing loss and tinnitus over the longer term counts against acoustic neuroma as the diagnosis.

D Atypical migraine

Although atypical migraine is associated with paralysis, other symptoms such as headache are

Audio Video Stop Share Participants More

STC 42% 5:44 PM
https://mypastest.paste

A 30-year-old man presents with a short history of increasing headaches, clumsiness and unsteadiness, drowsiness and lethargy over the past 2–4 weeks.

An urgent computed tomography (CT) scan arranged by his general practitioner (GP) is sent for reporting and reveals a dilated fourth ventricle and evidence of hydrocephalus.

Where is the most likely site for the obstructing lesion?

A Cerebellum

B Amygdala

Audio Video Stop Share Participants More

STC 42% 5:45 PM
https://mypastest.paste

Where is the most likely site for the obstructing lesion?

A Cerebellum

B Amygdala

C Hippocampus

D Pituitary fossa

E Corpus callosum

32760

Audio Video Stop Share Participants More

STC 42% 5:47 PM
https://mypastest.paste

Explanation

A	Cerebellum

The correct answer is Cerebellum (Option A).

A haemangioblastoma is said to commonly present in patients from the age of 30 years, with a male to female ratio of 2 : 1. Often, patients have a history of a number of minor symptoms but present with sudden deterioration, as in this case. Cerebellar lesions may produce symptoms of ataxia or lead to obstruction and hydrocephalus, as seen here. Surgery is the treatment of choice for this condition, as it is potentially curative

Audio Video Stop Share Participants More

STC 42% 5:48 PM
https://mypastest.paste

as these are benign lesions.
Preoperative embolisation may reduce mortality and morbidity associated with surgery, and recurrence associated with modern surgical techniques for excision is put at < 25%.

B Amygdala

Amygdala (Option B) is incorrect.

The two amygdalae form part of the limbic system and are involved in decision-making, emotional response and memory.

C Hippocampus

Hippocampus (Option C) is incorrect

Audio Video Stop Share Participants More

STC 42% 5:49 PM
https://mypastest.paste

C	Hippocampus

Hippocampus (Option C) is incorrect.

The hippocampus is another part of the limbic system that plays a critical role in saving memories. It is one of the first areas to be affected by Alzheimer's disease.

D	Pituitary fossa

Pituitary fossa (Option D) is incorrect.

Tumours smaller than 10 mm are called microadenomas and often secrete anterior pituitary hormones. These smaller, functional adenomas are usually detected earlier because the

Audio Video Stop Share Participants More

STC 42% 5:49 PM
https://mypastest.paste

E Corpus callosum

Corpus callosum (Option E) is incorrect.

The corpus callosum connects, and enables communication between, the two brain hemispheres. Tumours here can lead to 'split-brain syndrome', which may cause loss of the ability to read or understand written words (word blindness) and difficulty with recognition or the ability to carry out intended actions and movements.

32780
Rate this question:
Audio Video Stop Share Participants More

STC 40% 6:21 PM
https://mypastest.paste

A 48-year-old man is brought to the clinic for evaluation. He lives alone and his girlfriend said that for the past 3 weeks he has been behaving very abnormally, although in practice he has not been quite right, with odd mood changes and memory lapses for the past 4 months.

He had been treated at the Oncology Centre for a year and a half for chronic lymphocytic leukaemia, for which he received combination chemo- and immunotherapy. There is no history of fever or seizures.

On examination, he is drowsy and his visual acuity is 6/60 on both sides with intact pupillary reflexes. Right-sided

Audio Video Stop Share Participants More

https://mypastest.paste

level of seizures.

On examination, he is drowsy and his visual acuity is 6/60 on both sides with intact pupillary reflexes. Right-sided weakness is evident, with mild spasticity and an extensor plantar response on the right. The left plantar shows a flexor response. Magnetic resonance imaging (MRI) of the brain reveals multiple non-enhancing white matter lesions in the left hemisphere. Routine blood testing shows a raised white count with lymphocytosis, but nil else of note.

What is the most likely diagnosis?

A Small vessel vasculitis

Audio Video Stop Share Participants More

https://mypastest.paste

case of note.

What is the most likely diagnosis?

A Small vessel vasculitis

B Embolic stroke

C Acute disseminated encephalomyelitis (ADEM)

D Progressive multi-focal leukoencephalopathy (PML)

E Leucodystrophy

32769

Audio Video Stop Share Participants More

STC 60% 1:07 PM

69% 10:07

E Acid maltase deficiency

Acid maltase deficiency (glycogen storage myopathy type 2) has three clinical forms. The adult form that is depicted in this scenario is a slowly progressive weakness of the shoulder, pelvic girdle and truncal muscles. At times the diaphragmatic weakness is the prime difficulty, which brings the patient to the Accident and Emergency Department, and so the differential diagnosis would include motor neurone disease, myasthenia gravis and nemaline rod myopathy. Diagnosis is confirmed by muscle biopsy.

The sarcoplasm of affected cells is vacuolated and the vacuoles contain Periodic acid–Schiff (PAS)-positive diastase digestible material. The glycogen particles lie in aggregates. Electron microscopy shows some of these to occupy lysosomal vesicles (i.e. this is a lysosomal disease), and others to lie free. Positive ischaemic forearm tests may occur in patients with other forms of glycogen storage disorder (namely, Cori disease, McArdle disease and Tarui disease). However, a normal test result would be expected in acid maltase deficiency. Acid maltase deficiency presenting in adulthood carries a better prognosis than the infantile form, and patients are known to survive until the 6th or 7th decade.

A Amyotrophic lateral sclerosis

Classical amyotrophic lateral sclerosis is associated with bulbar palsy, and the long duration of symptoms, including difficulty performing sports at school, counts against ALS as the diagnosis.

B Polymyositis

Polymyositis is associated with muscle weakness, although a shorter disease course accompanied by muscle pain and other signs of connective tissue disease would be

Annotation Stop Share

Rana Alnasser's screen

STC 25% 8:24 AM
https://mypastest.paste

You review a 41-year-old man who plays Sunday league rugby for his local club. He complains of numbness over the middle, ring and index finger of left hand.

Examination reveals weakness of finger extensors and an absent triceps reflex.

Which of the following stems best describes the likely site of the lesion?

A C6, 7 disc prolapse

B C5, 6 disc prolapse

C Radial nerve

Audio Video Stop Share Participants More

STC 24% 8:24 AM
https://mypastest.paste

Which of the following stems best describes the likely site of the lesion?

A	C6, 7 disc prolapse
B	C5, 6 disc prolapse
C	Radial nerve
D	C8, T1 disc prolapse
E	Posterior interosseous nerve

6629
Audio Video Stop Share Participants More

STC 24% 8:27 AM
https://mypastest.paste

Explanation

A C6, 7 disc prolapse

A C7 lateral disc protrusion is one of the commonest sites of disc prolapse affecting the cervical region. There is often root pain, which radiates into the C7 myotome, and sensory disturbance, tingling and numbness affecting the C7 dermatome. Weakness or wasting of the triceps, wrist and finger extensors is seen and there is loss of the triceps jerk. Many cases recover with rest and analgesics; when recovery is delayed, patients are considered for surgical root decompression.

Audio Video Stop Share Participants More

STC 24% 8:28 AM
https://mypastest.paste

B C5, 6 disc prolapse

This would cause altered sensation in the lateral border of the hand and arm and result in a suppressed supinator reflex; the biceps reflex may also be affected.

C Radial nerve

This would produce a wrist drop but not the pattern of sensory alteration seen here, or the loss of triceps reflex.

D C8, T1 disc prolapse

Audio Video Stop Share Participants More

STC 24% 8:28 AM
https://mypastest.paste

D C8, T1 disc prolapse

This would result in hand weakness and altered sensation in the medial hand and forearm.

E Posterior interosseous nerve

This would produce a finger drop, but not the pattern of sensory alteration seen here nor the loss of triceps reflex.

6620

Rate this question:

Next Question

Audio Video Stop Share Participants More

STC 24% 8:29 AM
https://mypastest.paste

A 27-year-old woman comes to the Genetics Clinic for review. She suffers from muscle weakness, bilateral ptosis and cataracts.

Her first child was born blue and required assistance with breathing during the first few minutes after birth. The child's father has a history of cataracts, but is otherwise well.

What disease does the mother suffer from?

A Galactosaemia

B Myotonic dystrophy

Audio Video Stop Share Participants More

STC 24% 8:29 AM
https://mypastest.paste

cataracts, but is otherwise well.

What disease does the mother suffer from?

A Galactosaemia

B Myotonic dystrophy

C Myasthenia gravis

D Hypothyroidism

E Becker's muscular dystrophy

Audio Video Stop Share Participants More

STC 24% 8:30 AM
https://mypastest.paste

Explanation

B Myotonic dystrophy

The mother suffers from congenital myotonic dystrophy, which is associated with cataracts, mild intellectual impairment, cardiomyopathy and conduction defects, glucose intolerance and low serum IgG. Myotonic dystrophy is a single gene disorder which results in increased 'triplet repeats', where the CTG nucleotide triplet may be repeated up to 35 times. It appears that the number of repeats increases in offspring and, as such, offspring of parents with myotonic dystrophy may

Audio Video Stop Share Participants More

STC 24% 8:31 AM
https://mypastest.paste

offspring and, as such, offspring of parents with myotonic dystrophy may actually suffer a worse phenotype.

A Galactosaemia

Congenital galactosaemia presents with convulsions and irritability in infancy; there is poor feeding and weight gain. Jaundice and vomiting are also noted in the first few days of life. It is inherited in an autosomal recessive fashion.

C Myasthenia gravis

Myasthenia gravis is a cause of ptosis and proximal muscle weakness

Audio Video Stop Share Participants More

STC 23% 8:31 AM
https://mypastest.paste

C Myasthenia gravis

Myasthenia gravis is a cause of ptosis and proximal muscle weakness, although it is an autoimmune rather than a genetic condition.

D Hypothyroidism

Hypothyroidism is associated with proximal muscle weakness, although it is not associated with cataracts; in addition, congenital hypothyroidism is a rare condition.

E Becker's muscular dystrophy

Audio Video Stop Share Participants More

STC 23% 8:31 AM
https://mypastest.paste

E Becker's muscular dystrophy

Becker's and Duchenne's muscular dystrophy are X-linked causes of proximal myopathy, although women may rarely present with muscle weakness.

6612

Rate this question:

Next Question

Previous Question Tag Question

Feedback End Session

Audio Video Stop Share Participants More

STC 23% 8:32 AM
https://mypastest.paste

You are helping at a busy Neurology Outpatient Clinic. You are pleased to see a 38-year-old woman you had managed on the wards. She was admitted 2 months previously with intracerebral haemorrhage. Non-contrast computerised tomography (CT) brain at that time revealed a discrete lobar bleed involving the right frontal cortex. She was managed conservatively and made good progress with ward-based rehabilitation.

She is well today, complaining only of mild headache and minor leg weakness. Blood pressure is 160/100 mmHg, but she attributes this to 'feeling stressed'. You organise repeat

Audio Video Stop Share Participants More

STC 23% 8:33 AM
https://mypastest.paste

frontal cortex. She was managed conservatively and made good progress with ward-based rehabilitation.

She is well today, complaining only of mild headache and minor leg weakness. Blood pressure is 160/100 mmHg, but she attributes this to 'feeling stressed'. You organise repeat CT brain and titrate her antihypertensive dose.

Which of the following is the most useful strategy with respect to determining her future management?

A ApoE genotyping

Audio Video Stop Share Participants More

STC 23% 8:33 AM
https://mypastest.paste

Which of the following is the most useful strategy with respect to determining her future management?

A ApoE genotyping

B Electroencephalogram

C Magnetic resonance angiogram

D Renal ultrasound

E Thrombophilia screen

Audio Video Stop Share Participants More

STC 23% 8:35 AM
https://mypastest.paste

determining her future management?

Your answer was incorrect

A	ApoE genotyping
B	Electroencephalogram
C	Magnetic resonance angiogram
D	Renal ultrasound
E	Thrombophilia screen

Audio Video Stop Share Participants More

STC 23% 8:36 AM
https://mypastest.paste

amyloid angiopathy is common and can result in multiple bleeding episodes. In younger patients the possibility of underlying tumour or vascular malformation needs to be considered. Many such patients will eventually have a formal angiogram; in the first instance a magnetic resonance angiogram is useful.

D	Renal ultrasound

A renal ultrasound would not be useful in this immediate situation, although it may be used to investigate the cause for the hypertension in such a young person.

Audio Video Stop Share Participants More

STC 23% 8:36 AM
https://mypastest.paste

A ApoE genotyping

Intracerebral haemorrhage (ICH) is associated with ApoE4 genotype, but screening is not used in clinical practice.

B Electroencephalogram

Electroencephalogram may be useful in some situations for detection of seizure activity, but not for diagnostic and prognostic management for intracerebral bleeds.

E Thrombophilia screen

Audio Video Stop Share Participants More

STC 23% 8:36 AM
https://mypastest.paste

E Thrombophilia screen

This patient had a lobar bleed rather than a thrombosis, and therefore a thrombophilia screen would not be useful.

71054

Rate this question:

Next Question

Previous Question | Tag Question

Feedback | End Session

Difficulty: Average

Audio Video Stop Share Participants More

STC 22% 8:38 AM
https://mypastest.paste

A 78-year-old man with a history of alcohol excess is referred to the Acute Stroke Service by his care worker. He was recently discharged from the orthopaedic wards following a fracture of his left leg and still has an above-knee cast *in situ*. He defaulted from Fracture Clinic follow-up and should have had his cast removed last week.

He was found today lying on the floor of his flat having been incontinent of urine and unable to walk. The orthopaedic team has reviewed plain films and is happy that the fracture has healed. The cast is removed.

On examination of gait, you note ankle and toe extension are weak. He is unable to evert his foot, but inversion

Audio Video Stop Share Participants More

STC 22% 8:39 AM
https://mypastest.paste

He was found today lying on the floor of his flat having been incontinent of urine and unable to walk. The orthopaedic team has reviewed plain films and is happy that the fracture has healed. The cast is removed.

On examination of gait, you note ankle and toe extension are weak. He is unable to evert his foot, but inversion is normal. There is an area of sensory loss over the lateral shin and dorsum of the foot.

What would be the most appropriate investigation?

A Magnetic resonance image (MRI) lumbar spine

Audio Video Stop Share Participants More

STC 22% 8:39 AM
https://mypastest.paste

What would be the most appropriate investigation?

A Magnetic resonance image (MRI) lumbar spine

B Serum anti-GM1 antibodies

C MRI brain

D MRI left ankle

E Nerve conduction studies

32724

Audio Video Stop Share Participants More

STC 22% 8:41 AM
https://mypastest.paste

investigation?

Your answer was incorrect

A Magnetic resonance image (MRI) lumbar spine

B Serum anti-GM1 antibodies

C MRI brain

D MRI left ankle

Nerve conduction studies

Audio Video Stop Share Participants More

STC 22% 8:42 AM
https://mypastest.paste

E Nerve conduction studies

The clinical findings are classical of common peroneal nerve palsy. This is one of the more common entrapment neuropathies. Differentiation from a L5–S1 lesion is made by examining foot inversion and eversion. Risk factors for common peroneal nerve palsy are any cause of sustained pressure at the fibular head, with plaster casts and general immobility being frequent culprits. Diagnosis can be confirmed by nerve conduction study. Prognosis is good. The other important laboratory test in a patient with a history of prolonged immobility is

Audio Video Stop Share Participants More

STC 21% 8:42 AM
https://mypastest.paste

common peroneal nerve palsy are any cause of sustained pressure at the fibular head, with plaster casts and general immobility being frequent culprits. Diagnosis can be confirmed by nerve conduction study. Prognosis is good. The other important laboratory test in a patient with a history of prolonged immobility is serum creatine kinase. Levels are likely to be raised from the trauma of lying on the floor; very high levels will alert the clinician to the possibility of rhabdomyolysis and the need for fluid resuscitation and monitoring of renal function. Urine dipstick is also of value in suspected rhabdomyolysis as it will be positive for blood.

Audio Video Stop Share Participants More

STC 21% 8:44 AM
https://mypastest.paste

A Magnetic resonance image (MRI) lumbar spine

There are no clear features to suggest a lumbar radiculopathy (back pain radiating to the leg, L5 dermatomal sensory loss) over common peroneal nerve palsy.

B Serum anti-GM1 antibodies

This test can be performed when looking for evidence of multifocal motor neuropathy with conduction block, but the case here is far more likely to represent simple nerve compression.

Audio Video Stop Share Participants More

STC 21% 8:44 AM
https://mypastest.paste

C	MRI brain

The features here suggest a common peroneal nerve palsy with no signs to suggest stroke or other brain pathology.

D	MRI left ankle

The features here suggest a common peroneal nerve palsy with no signs to suggest local pathology in the ankle.

32724

Rate this question:

Next Question

Audio Video Stop Share Participants More

STC 21% 8:45 AM
https://mypastest.paste

A 42-year-old bus driver with diet-controlled diabetes complains of generalised weakness which appears to be worse in the evenings. She often complains of double vision and her husband and friends report that her eyelids sometimes appear to be drooping. Her symptoms are generally worse after a few hours of working. She reports smoking 10 cigarettes a day for the past 25 years and drinks three to four pints of beer most weekends.

On examination, there is subtle ptosis of the left eye. Following upward gaze for 45 s, there is complete ptosis of the left eye and partial ptosis of the right eye. There is no diplopia in the primary

Audio Video Stop Share Participants More

STC 21% 8:45 AM
https://mypastest.paste

On examination, there is subtle ptosis of the left eye. Following upward gaze for 45 s, there is complete ptosis of the left eye and partial ptosis of the right eye. There is no diplopia in the primary position. Examination of eye movements demonstrates incomplete abduction of the both eyes, with variable diplopia reported on horizontal and vertical pursuit. Examination of the limbs demonstrates generalised weakness, which is greater proximally. Reflexes are symmetrical with flexor plantar responses. There is no sensory deficit.

Which of the following investigations will be of most use diagnostically?

Audio Video Stop Share Participants More

STC 21% 8:46 AM
https://mypastest.paste

Which of the following investigations will be of most use diagnostically?

A Serum anti-voltage-gated potassium channel antibody titres

B Serum anti-muscle-specific tyrosine kinase (MUSK) antibody titres

C Serum anti-striated muscle antibody titres

D Electromyography and single fibre electromyography

Audio Video Stop Share Participants More

STC 21% 8:46 AM
https://mypastest.paste

tyrosine kinase (MUSK) antibody titres

C Serum anti-striated muscle antibody titres

D Electromyography and single fibre electromyography

E Thyroid function tests

9390

Submit

Audio Video Stop Share Participants More

STC 21% 8:47 AM
https://mypastest.paste

Explanation

D	Electromyography and single fibre electromyography

This patient's fluctuating weakness with a complex ophthalmoplegia is typical of myasthenia gravis. Ocular and bulbar muscles are prone to weakness, with a propensity for symptoms to deteriorate after exercise or as the day progresses. Females are more commonly affected than males.

Diagnosis is made on clinical grounds, with confirmation by the following investigations:

Audio Video Stop Share Participants More

STC 21% 8:48 AM
https://mypastest.paste

- Serum acetylcholine receptor antibody titres (positive in up to 85%).
- Single-fibre electromyogram (EMG). This demonstrates abnormal jitter (delay in signal between two muscle fibres that are both innervated by the same nerve cell, demonstrating variation in neuromuscular junction transmission). It is positive in 95–99% of patients with generalised myasthenia. Routine nerve conduction studies and EMG are normal in

Audio Video Stop Share Participants More

STC 21% 8:49 AM
https://mypastest.paste

positive in 95-99% of patients with generalised myasthenia. Routine nerve conduction studies and EMG are normal in myasthenic syndromes, which help to differentiate it from peripheral neuropathy and myopathy.

- Using another technique called repetitive nerve stimulation (RNS), a reduced motor signal can be observed in response to slow repetitive stimulation – this mimics the fatiguable weakness seen in myasthenia.

Audio Video Stop Share Participants More

STC 21% 8:49 AM
https://mypastest.paste

As the single-fibre EMG is most likely to demonstrate a myasthenic syndrome and therefore to be useful diagnostically, this is the correct option.

Other useful investigations are chest X-ray and computerised tomography (CT) of the chest to evaluate for a thymoma. Other serological tests to investigate for the presence of autoimmune disease may also be useful.

A Serum anti-voltage-gated potassium channel antibody titres

Audio Video Stop Share Participants More

STC 21% 8:50 AM
https://mypastest.paste

A Serum anti-voltage-gated potassium channel antibody titres

Anti-voltage-gated-potassium-channel (VGKC) antibodies are seen in a specific type of autoimmune limbic encephalitis, confusion and facio-brachial seizures. They are also found in a form of neuromyotonia, a disorder characterised by delayed muscle relaxation and muscle twitching. This patient has neither of these syndromes, and therefore this is not the correct choice.

B Serum anti-muscle-specific tyrosine kinase (MUSK)

Audio Video Stop Share Participants More

Phone Manager
Low battery power
20% remaining
TURN ON POWER SAVING MODE

B Serum anti-muscle-specific tyrosine kinase (MUSK) antibody titres

This antibody is tested for in patients in whom there is a suspicion of myasthenia gravis but in whom the more commonly found antibody – anti-Acetylcholine-receptor (AChR) antibody – is negative. Around 85% of people with suspected generalized myasthenia gravis are positive for anti-AChR antibodies; a further 7-10% are positive for anti-MUSK antibodies; the remainder have 'seronegative' myasthenia gravis.

This option is incorrect because testing

Audio Video Stop Share Participants More

STC 20% 8:50 AM
https://mypastest.paste

This option is incorrect because testing for anti-MUSK antibodies is not first line, and will not be indicated unless anti-AChR antibodies are negative.

C	Serum anti-striated muscle antibody titres

This antibody is found in some people with myasthenia gravis and who also have a thymoma (there is an association between the two). They are not useful in the diagnosis of myasthenia gravis, and therefore this is not the correct option.

E	Thyroid function tests

Audio Video Stop Share Participants More

STC 20% 8:50 AM
https://mypastest.paste

myasthenia gravis, and therefore this is not the correct option.

E	Thyroid function tests

While proximal weakness and fatigue may be seen in hypothyroidism, this patient has clear signs of fatiguable ptosis and complex ophthalmoplegia, which is not seen in thyroid disorders. It is useful to check thyroid function due to the proximal weakness, but it is not likely to be helpful diagnostically. Therefore, this option is incorrect.

9390

Rate this question:

Next Question

Audio Video Stop Share Participants More

STC 20% 8:51 AM
https://mypastest.paste

A 50-year-old woman presents to her general practitioner (GP), complaining of severe problems with central obesity.

Her past medical history includes manic depression, hypertension and chronic alcohol abuse. Medication includes sodium valproate, ramipril, indapamide and amlodipine.

On examination, her blood pressure (BP) is 165/90 mmHg and her body mass index (BMI) is 38. She has moon-like facial features, buffalo hump and abdominal striae.

Investigations:

Haemoglobin	12.2 g/dl

Audio Video Stop Share Participants More

STC 21% 8:52 AM
https://mypastest.paste

investigations:

Haemoglobin (Hb)	12.2 g/dl
White cell count (WCC)	5.6×10^9/l
Platelet (PLT)	230×10^9/l
Sodium (Na)	141 mmol/l
Potassium (K)	4.8 mmol/l
Creatinine	123 μmol/l
Alanine transaminase (ALT)	105 U/l
Fasting glucose	8.2 mmol/l

Audio Video Stop Share Participants More

STC 21% 8:52 AM
https://mypastest.paste

Which of the following is the most likely diagnosis?

A Cushing's disease

B Cushing syndrome

C Pseudo Cushing's disease

D Impaired glucose tolerance

E Simple obesity

Audio Video Stop Share Participants More

STC 22% 8:57 AM
https://mypastest.paste

Explanation

C	Pseudo Cushing's disease

The answer is Pseudo-Cushing's disease (Option C).

It can be challenging to distinguish Cushing's disease from pseudo-Cushing's disease as the clinical presentation is similar. The main clinical clues to pseudo-Cushing's disease in this case are the chronic alcohol abuse and depression. The key biochemical evidence is that there remains diurnal variation in the cortisol level, which would not be seen in Cushing's disease. Often, treating the underlying cause will result in

Audio Video Stop Share Participants More

STC 22% 8:58 AM
https://mypastest.paste

remains diurnal variation in the cortisol level, which would not be seen in Cushing's disease. Often, treating the underlying cause will result in resolution of the symptoms and biochemical disturbances.

A	Cushing's disease

Cushing's disease (Option A) is incorrect.

In a patient with Cushing's disease, the plasma cortisol level would not show diurnal variation, ie the midnight plasma level would not be < 50% of the morning level; this patient's biochemistry clearly shows a drop of > 50%. With her background of chronic

Audio Video Stop Share Participants More

STC 22% 8:59 AM
https://mypastest.paste

B Cushing syndrome

Cushing syndrome (Option B) is incorrect.

In a patient with Cushing syndrome, the plasma cortisol level would not show diurnal variation, ie the midnight plasma level would not be < 50% of the morning level; this patient's biochemistry clearly shows a drop of > 50%. With her background of chronic alcohol abuse and depression, the best answer would therefore be pseudo-Cushing's disease.

D Impaired glucose tolerance

Audio Video Stop Share Participants More

STC 22% 8:59 AM
https://mypastest.paste

D	Impaired glucose tolerance

Impaired glucose tolerance (Option D) is incorrect.

A raised glucose level is expected as a result of raised cortisol levels. Diagnosing impaired glucose tolerance requires a fasting blood glucose level of < 7 mmol/l and an oral glucose tolerance test level of 7.8–11.0 mmol/l, which is not the case here.

E	Simple obesity

Simple obesity (Option E) is incorrect.

The patient clearly presents with an abnormal picture and abnormal

Audio Video Stop Share Participants More

STC 22% 9:00 AM
https://mypastest.paste

tolerance test level of 7.8–11.0 mmol/l, which is not the case here.

E	Simple obesity

Simple obesity (Option E) is incorrect.

The patient clearly presents with an abnormal picture and abnormal biochemistry, which simple obesity alone would not satisfactorily explain. There is no doubt that this patient should lose weight.

21205

Rate this question:

Next Question

Audio Video Stop Share Participants More

STC 22% 9:00 AM
https://mypastest.paste

A travelling salesman attends the Accident and Emergency Department with headache. He describes frequent bouts of headache with stereotyped features. Attacks are of 1 h duration occurring three or four times a day. A series of attacks can occur for 3 weeks, and then he has a symptom-free period of several months.

He has had to attend various hospitals for analgesia in the past. The attack he experienced today was similar to previous with intense pain and eye watering centering on his left eye. He was first assessed by your junior house officer. The patient seemed so distressed the house officer ordered multiple interventions including high-

Audio Video Stop Share Participants More

STC 23% 9:01 AM
https://mypastest.paste

He has had to attend various hospitals for analgesia in the past. The attack he experienced today was similar to previous with intense pain and eye watering centering on his left eye. He was first assessed by your junior house officer. The patient seemed so distressed the house officer ordered multiple interventions including high-flow oxygen, intravenous fluids, sublingual glycerine trinitrate, and oral morphine.

Which is likely to have helped his symptoms the most?

A High-flow oxygen

B IV saline

Audio Video Stop Share Participants More

STC 23% 9:01 AM
https://mypastest.paste

Which is likely to have helped his symptoms the most?

A High-flow oxygen

B IV saline

C Nitrates

D Oral opiates

E Indomethacin

7555

Audio Video Stop Share Participants More

STC 23% 9:01 AM
https://mypastest.paste

Explanation

A	High-flow oxygen

Doctors should be wary of patients who attend multiple hospitals requiring analgesia. In this case, however, the diagnosis of cluster headache is clear. As the name suggests, this condition occurs in recurrent bouts (clusters) with symptom-free periods in-between. Unilateral periorbital pain and autonomic activation with lacrimation, ptosis, nasal congestion and conjunctival injection are common. The pain is so bad that patients have been known to commit suicide. Duration of symptoms is from 15 min

Audio Video Stop Share Participants More

STC 23% 9:03 AM
https://mypastest.paste

been known to commit suicide. Duration of symptoms is from 15 min to 2 h. Clusters can last from weeks to months, with long, symptom-free periods. The pathophysiology remains poorly understood. Treatment options for the acute attack include high-flow oxygen, triptans and ergotamine (the latter now rarely used). Verapamil can be used for long-term prophylaxis.

B IV saline

In cluster headache there is no evidence to support IV fluids as a treatment.

C Nitrates

Audio Video Stop Share Participants More

STC 23% 9:03 AM
https://mypastest.paste

C Nitrates

Nitrates do not help with the pain of cluster headache. Indeed, nitrates tend to cause headache as a side effect.

D Oral opiates

These drugs are not efficacious in managing cluster headache, and in general terms are best avoided in all the primary headache disorders.

E Indomethacin

Some headache disorders such as paroxysmal hemicranias are exquisitely sensitive to indomethacin, but cluster

Audio Video Stop Share Participants More

STC 23% 9:05 AM
https://mypastest.paste

A 68-year-old woman presents with fatigue and diplopia that is interfering with her evening job as a barmaid. She is a lifelong smoker but has no past medical history of note.

On examination, she has a bilateral ptosis and nasal speech. There is no pupillary abnormality. Power is normal in all muscle groups tested, and reflexes are generally quite brisk; plantar responses are flexors. You admit her for further investigation.

The following results are obtained:

Magnetic resonance image (MRI) brain and brain stem	No abnormality

Audio Video Stop Share Participants More

STC 23% 9:05 AM
https://mypastest.paste

The following results are obtained:

Magnetic resonance image (MRI) brain and brain stem	No abnormality
Erythrocyte sedimentation rate (ESR)	12mm (0-20)
Creatine kinase	130 U/l (24-170)
Anti-AchR (acetylcholine receptor) antibodies	Negative
Thyroid-stimulating hormone	Normal

Audio Video Stop Share Participants More

STC 23% 9:06 AM
https://mypastest.paste

Thyroid-stimulating hormone	Normal
Computerised tomography (CT) chest	Normal thymus
Electromyography (EMG)	Decrement in evoked action potential following continued stimulation

What further immunological test is most likely to give a definitive diagnosis?

Audio Video Stop Share Participants More

STC 23% 9:06 AM
https://mypastest.paste

What further immunological test is most likely to give a definitive diagnosis?

A Anti-voltage-gated calcium channel (anti-VGCC) antibodies

B Anti-skeletal muscle (anti-SM) antibodies

C Anti-Yo (anti-PCA1) antibodies

D Anti-muscle-specific kinase (anti-MuSK) antibodies

Audio Video Stop Share Participants More

STC 23% 9:06 AM
https://mypastest.paste

antibodies

B Anti-skeletal muscle (anti-SM) antibodies

C Anti-Yo (anti-PCA1) antibodies

D Anti-muscle-specific kinase (anti-MuSK) antibodies

E HLA typing (looking for HLA DR1 halotype)

Audio Video Stop Share Participants More

STC 24% 9:07 AM
https://mypastest.paste

Explanation

D	Anti-muscle-specific kinase (anti-MuSK) antibodies

The clinical features and EMG result suggest the diagnosis of Myasthenia Gravis. In the majority (around 90%) of patients with generalised disease, antibodies to nicotinic acetylcholine receptors (anti-AChR) are found. This auto-antibody is pathognomonic for the disease.

Antibodies to the post-synaptic muscle-specific receptor tyrosine kinase (anti-MuSK) have been found in (40-70%) patients who do not have anti-AChR antibodies. These patients

Audio Video Stop Share Participants More

STC 24% 9:08 AM
https://mypastest.paste

the disease.

Antibodies to the post-synaptic muscle-specific receptor tyrosine kinase (anti-MuSK) have been found in (40-70%) patients who do not have anti-AChR antibodies. These patients are more often female, have an oculobulbar form (diplopia, ptosis, dysarthria) and are less likely to have thymoma or respond to acetylcholinesterase inhibitors.

Seronegative Myasthenia Gravis refers to the 6-12% of patients who do not have either anti-AChR or anti-MuSK antibodies. It is likely that as the molecular biology of myasthenia is better understood, antibodies to other components of the post-synaptic

Audio Video Stop Share Participants More

STC 24% 9:09 AM
https://mypastest.paste

Seronegative Myasthenia Gravis refers to the 6-12% of patients who do not have either anti-AChR or anti-MuSK antibodies. It is likely that as the molecular biology of myasthenia is better understood, antibodies to other components of the post-synaptic neuromuscular junction will be characterised in seronegative patients.

B	Anti-skeletal muscle (anti-SM) antibodies

Anti-SM antibodies are associated with thymoma in Myasthenia Gravis; although the EMG is consistent with Myasthenia Gravis, the CT chest result has ruled out a thymoma.

Audio Video Stop Share Participants More

STC 24% 9:10 AM
https://mypastest.paste

A	Anti-voltage-gated calcium channel (anti-VGCC) antibodies

Anti-VGCC antibodies are highly specific for Lambert–Eaton Myasthenic Syndrome (LEMS). Despite its strong association with small-cell lung cancer (a red herring from the smoking history of this patient) the clinical features of predominant ocular disease and associated electromyographic (EMG) findings do not support this diagnosis. LEMS characteristically presents with proximal limb weakness and recovery of lost deep tendon reflexes/ improvement in strength with intense brief muscle activation; this is reflected by the characteristic EMG

Audio Video Stop Share Participants More

STC 24% 9:10 AM
https://mypastest.paste

C	Anti-Yo (anti-PCA1) antibodies

These antibodies are associated with gynaecological and breast cancers, and cause paraneoplastic cerebellar degeneration.

E	HLA typing (looking for HLA DR1 halotype)

In this context, the HLA DR1 halotype is associated with Penicillamine-induced myasthenia.

7345

Rate this question:

Audio Video Stop Share Participants More

STC 24% 9:11 AM
https://mypastest.paste

A 33-year-old man is referred to the Headache Clinic. He was diagnosed with simple migraine 3 years previously.

In the last 18 months, attacks have increased in frequency and changed in character. He now describes a daily headache that 'presses on his temples'. The pain worsens as the day progresses. There is no relation to movement or posture and there are no other associated neurological symptoms. The pain is such that he has increased his use of analgesics considerably. At the time of consultation, he is taking daily paracetamol, diclofenac and dihydrocodeine.

Audio Video Stop Share Participants More

STC 25% 9:12 AM
https://mypastest.paste

On examination, his BP is 135/85 mmHg, with pulse 70 bpm and regular. Neurological examination is unremarkable.

Choose the most appropriate management step

A Oral propranolol

B Subcutaneous triptan

C Withdraw regular analgesics

D Amitriptyline

Audio Video Stop Share Participants More

STC 25% 9:13 AM
https://mypastest.paste

management step

A	Oral propranolol
B	Subcutaneous triptan
C	Withdraw regular analgesics
D	Amitriptyline
E	Arrange urgent MRI brain

32723

Submit

Audio Video Stop Share Participants More

STC 25% 9:13 AM
https://mypastest.paste

Explanation

C Withdraw regular analgesics

An increasingly recognised pattern among patients with headache is development of a chronic daily headache syndrome. Patients often first present with migraine, but with time develop a diffuse daily pain that can significantly interfere with daily functioning. The syndrome is thought to be exacerbated by analgesic overuse, and some classification systems recognise an 'analgesic-overuse headache'. Treatments include reassurance and gradual withdrawal of opiate analgesic agents (with the

Audio Video Stop Share Participants More

STC 25% 9:14 AM
https://mypastest.paste

overuse headache'. Treatments include reassurance and gradual withdrawal of opiate analgesic agents (with the warning that pain may worsen before it improves). Non-opiate analgesics can be withdrawn abruptly. In patients with clear ongoing migrainous features, the use of a migraine suppressant (propranolol, topirimate) can be helpful, but the regular analgesics must be stopped as well. Note there are no features here suggestive of raised intracranial pressure. This, along with the chronic onset and lack of other red flags, would suggest that urgent imaging is not required.

Audio Video Stop Share Participants More

STC 25% 9:14 AM
https://mypastest.paste

A Oral propranolol

This patient must withdraw from regular analgesics. If migrainous features continue then a drug such as propranolol may also be helpful.

B Subcutaneous triptan

This is a treatment for acute migraine, so will not help here. Indeed, regular use of triptans can give rise to analgesia-overuse headache.

D Amitriptyline

Audio Video Stop Share Participants More

STC 25% 9:14 AM
https://mypastest.paste

D Amitriptyline

This patient must withdraw from regular analgesics. If migrainous features continue, then a drug such as this may also be helpful.

E Arrange urgent MRI brain

There are no features here suggestive of raised intracranial pressure. This, along with the chronic onset and lack of other red flags, would suggest that urgent imaging is not required.

32723
Rate this question:
Audio Video Stop Share Participants More

STC 25% 9:14 AM
https://mypastest.paste

A 48-year-old woman is seen in the neurology clinic with a progressive history over many months of unsteadiness and numbness affecting both feet. She has been steadily losing weight for quite some time and has become increasingly tired and lethargic within the last few months.

She has a past medical history of irritable bowel syndrome, hypothyroidism and has attended dermatology clinics in the past for a vesicular skin rash on her arms.

On examination she is pale and thin. Examination of the cranial nerves reveals no abnormalities. Upper limb examination reveals normal tone,

Audio Video Stop Share Participants More

STC 26% 9:15 AM
https://mypastest.paste

On examination she is pale and thin. Examination of the cranial nerves reveals no abnormalities. Upper limb examination reveals normal tone, power and reflexes. Lower limb examination reveals wasting over both anterior compartments of the lower leg, with atrophic skin changes. Tone is bilaterally reduced at the ankle and knee and both plantar responses are mute. Reflexes are diminished at the ankle and knee bilaterally. There is some weakness of dorsiflexion and plantar flexion and her gait is markedly ataxic. Romberg's test is positive. Sensory examination reveals reduced sensation to all modalities extending to both knees.

Audio Video Stop Share Participants More

STC 26% 9:16 AM
https://mypastest.paste

Nerve conduction studies reveal a sensorimotor axonal neuropathy.

Investigations:

Hb	9.8 g/dl
MCV	102 fl (80-96)
WCC	4.8 x 10^9/l
Plt	237 x 10^9/l
Na^+	134 mmol/l
K^+	3.4 mmol/l
Urea	6.2 mmol/l
Creatinine	108 micromol/l
Cholesterol	2.6 mmol/l

Audio Video Stop Share Participants More

STC 26% 9:17 AM
https://mypastest.paste

TSH	4.0 mU/l (0.4-5.0)
Thyroxine	160 nmol/l (58-174)
Glucose	4.5 mmol/l
ESR	5 mm/1st hour (0-20)

What is the underlying diagnosis in this patient?

A Subacute combined degeneration of the cord

B Multiple systems atrophy

C Paraneoplastic syndrome

Audio Video Stop Share Participants More

STC 26% 9:17 AM
https://mypastest.paste

this patient?

A Subacute combined degeneration of the cord

B Multiple systems atrophy

C Paraneoplastic syndrome

D Coeliac disease

E Sjögren's syndrome

7200

Submit

Audio Video Stop Share Participants More

STC 26% 9:19 AM
https://mypastest.paste

Explanation

D	Coeliac disease

This patient's history is consistent with coeliac-associated neuropathy. She also has evidence of osteomalacia and a macrocytic anaemia. She has a previous history of 'irritable bowel syndrome', which may have been misdiagnosed, and history of vesicular rash, which in the context of the other findings may represent dermatitis herpetiformis. The neurological signs seen here are consistent with B12 deficiency as a result of malabsorption.

Audio Video Stop Share Participants More

STC 26% 9:19 AM
https://mypastest.paste

A Subacute combined degeneration of the cord

She has a macrocytic anaemia, so checking B12 is necessary (however, folate deficiency is more likely in this case). Her clinical signs are not typical of subacute combined degeneration. In this syndrome one expects pyramidal signs (such as increased tone, up-going plantars) in addition to dorsal column signs (markedly impaired joint position sense) and evidence of peripheral neuropathy.

B Multiple systems atrophy

Audio Video Stop Share Participants More

STC 26% 9:20 AM
https://mypastest.paste

B Multiple systems atrophy

Her ataxia is sensory, not cerebellar, and there are no autonomic or extrapyramidal features to suggest the cerebellar variant of multiple systems atrophy.

C Paraneoplastic syndrome

The gradual weight loss is not suggestive of malignancy, and there are no features in the examination to suggest an underlying malignancy and subsequent paraneoplastic syndrome. Paraneoplastic syndromes tend to come on quicker than the symptoms in this case, which have gradually

Audio Video Stop Share Participants More

STC 26% 9:20 AM
https://mypastest.paste

this case, which have gradually worsened over months.

E	Sjögren's syndrome

This presents with dryness of mucous membranes and salivary gland enlargement; however, patients can develop a sensory ataxic problem due to dorsal root ganglionopathy. The motor involvement and lack of sicca symptoms make this less likely in this case.

7200

Rate this question:

Next Question

Audio Video Stop Share Participants More

STC 27% 9:20 AM
https://mypastest.paste

A 66-year-old man presented with a one-year history of difficulty walking, finding it particularly difficult to turn around. He had also been complaining that his right arm seemed stiffer, with worsening of his handwriting in recent months, and his wife commented that his right arm appeared to move uncontrollably at times. His wife had also noticed he had been having difficulty over the same period with getting his words out and occasionally pronounced words incorrectly.

On examination his higher mental function was normal apart from difficulties with speech – he had some word-finding difficulties and his speech was at times effortful with the occasional wrong word. Cranial nerve

Audio Video Stop Share Participants More

STC 27% 9:22 AM
https://mypastest.paste

On examination his higher mental function was normal apart from difficulties with speech – he had some word-finding difficulties and his speech was at times effortful with the occasional wrong word. Cranial nerve examination was normal. However, limb examination revealed increased tone in his right arm and leg with difficulty of fine finger movements on the right. Power was normal throughout as were his reflexes, coordination and sensation.

What is the most likely diagnosis?

A Corticobasal degeneration

Audio Video Stop Share Participants More

STC 27% 9:23 AM
https://mypastest.paste

coordination and sensation.

What is the most likely diagnosis?

A Corticobasal degeneration

B Progressive supranuclear palsy

C Wilson's disease

D Dementia with Lewy bodies

E Multiple system atrophy

6945
Audio Video Stop Share Participants More

STC 28% 9:24 AM
https://mypastest.paste

Explanation

A	Corticobasal degeneration

Corticobasal degeneration (CBD) is a cause of adult-onset parkinsonism, often being classified amongst the 'Parkinson-plus' syndromes. Symptoms are usually unilateral initially but can progress to affect both sides. As well as rigidity and bradykinesia, there may also be myoclonus, apraxia or dystonia of a limb. A particularly characteristic feature of CBD is the development of an 'alien limb' phenomenon, where a limb, usually an arm, appears to move on its own. Some patients will develop cognitive impairment that may include

Audio Video Stop Share Participants More

STC 28% 9:25 AM
https://mypastest.paste

an 'alien limb' phenomenon, where a limb, usually an arm, appears to move on its own. Some patients will develop cognitive impairment that may include a progressive, non-fluent aphasia. There is no curative treatment.

B	Progressive supranuclear palsy

Although PSP is also a Parkinson-plus syndrome, gaze palsy, pathognomonic of the condition, is absent here.

C	Wilson's disease

Wilson's disease presents with neuropsychiatric symptoms or

Audio Video Stop Share Participants More

STC 28% 9:25 AM
https://mypastest.paste

asymptomatic rise in transaminases in the late teenage/early twenties time frame.

D	Dementia with Lewy bodies

This is characterised by features of parkinsonism accompanied by memory impairment, confusion and visual hallucinations.

E	Multiple system atrophy

Multiple system atrophy is associated with features of autonomic dysfunction such as postural hypotension, fainting episodes and with signs of parkinsonism.

Audio Video Stop Share Participants More

STC 28% 9:26 AM
https://mypastest.paste

A 50-year-old unemployed man presented with a 7-month history of progressive speech difficulty. He had appeared depressed over the same period after losing two jobs in the last year. His wife commented that he had lost all motivation and spent most of the day at home. His appetite had changed and he had become very fond of sweet foods, with his weight increasing by 2 stones in the last year. Higher mental function testing revealed problems with naming and in tasks requiring planning.

Examination of the cranial nerves and limbs was normal.

What is the most likely diagnosis?

Audio Video Stop Share Participants More

STC 29% 9:27 AM
https://mypastest.paste

limbs was normal.

What is the most likely diagnosis?

A Dementia with Lewy bodies

B Frontotemporal dementia

C Alzheimer's disease

D Creutzfeldt-Jakob disease

E Huntington's disease

6241

Audio Video Stop Share Participants More

STC 30% 9:29 AM
https://mypastest.paste

Explanation

B	Frontotemporal dementia

The diagnosis is most likely to be frontotemporal dementia, a collection of disorders affecting the frontal and temporal lobes. The age of onset is normally between 45 and 60 years of age, with a positive family history in up to 40% of patients. There are three cardinal syndromes: behavioural variant frontotemporal dementia, which presents mainly with behavioural disturbance (decreased motivation, impulsiveness, disinhibition and loss of social skills are all seen); semantic dementia, which presents

Audio Video Stop Share Participants More

STC 30% 9:31 AM
https://mypastest.paste

behavioural disturbance (decreased motivation, impulsiveness, disinhibition and loss of social skills are all seen); semantic dementia, which presents with a fluent aphasia and difficulty naming objects due to a loss of semantic knowledge; and progressive non-fluent aphasia, which presents with speech production difficulties. Overlap between the syndromes is seen. Patients often develop a sweet tooth or other changes in appetite. Problems with planning and judgement may cause them to lose their job. There is currently no treatment for these dementias.

A Dementia with Lewy bodies

Audio Video Stop Share Participants More

STC 30% 9:32 AM
https://mypastest.paste

A Dementia with Lewy bodies

This is predominantly a disease affecting the over-65s. It presents with fluctuating cognitive impairment (memory, language and visuospatial function) and well-formed visual hallucinations. Motor signs of parkinsonism are frequently seen.

C Alzheimer's disease

This common disease usually affects people over the age of 65, but is also the most frequently seen neurodegenerative dementia in the under-65s. Typical symptoms include memory loss, word finding problems

Audio Video Stop Share Participants More

STC 30% 9:32 AM
https://mypastest.paste

and visuospatial dysfunction. Significant behavioural change is uncommon during the early stages.

D	Creutzfeldt–Jakob disease

The sporadic form of CJD is a rapidly progressive dementia with ataxia and myoclonus. The majority of patients die from the illness within 1 year of diagnosis.

E	Huntington's disease

This illness is characterised by a slowly progressing chorea, sometimes with parkinsonism. Neuropsychiatric

Audio Video Stop Share Participants More

STC 30% 9:32 AM
https://mypastest.paste

D Creutzfeldt–Jakob disease

The sporadic form of CJD is a rapidly progressive dementia with ataxia and myoclonus. The majority of patients die from the illness within 1 year of diagnosis.

E Huntington's disease

This illness is characterised by a slowly progressing chorea, sometimes with parkinsonism. Neuropsychiatric disturbance and cognitive impairment are well recognised.

6241

Audio Video Stop Share Participants More

STC 31% 9:33 AM
https://mypastest.paste

She has no significant past medical history and her only regular medication is the oral contraceptive pill. She is currently studying for her A-level exams at college. Her BMI is 22 and her blood pressure is 110/70 mmHg. Neurological examination is normal.

Which anti-epileptic drug would be most suitable for this patient, given the likely epilepsy syndrome?

A Gabapentin

B Lorazepam

C Oxcarbazepine

Audio Video Stop Share Participants More

STC 31% 9:33 AM
https://mypastest.paste

Which anti-epileptic drug would be most suitable for this patient, given the likely epilepsy syndrome?

A Gabapentin

B Lorazepam

C Oxcarbazepine

D Sodium valproate

E Lamotrigine

70917

Audio Video Stop Share Participants More

STC 32% 9:35 AM
https://mypastest.paste

Explanation

E	Lamotrigine

The patient in this case most likely has juvenile myoclonic epilepsy (JME), which is the most common of the generalised epilepsy syndromes to present in mid- to late childhood. Seizure types include generalised tonic–clonic, myoclonic jerks that usually affect the upper limbs, and absence seizures. Sleep deprivation, anxiety, alcohol use and menses can precipitate seizures. Seizures typically occur in the mornings, particularly on waking. There is a strong genetic predisposition to this condition and

Audio Video Stop Share Participants More

STC 32% 9:37 AM
https://mypastest.paste

waking. There is a strong genetic predisposition to this condition and around half of patients will have an affected relative. EEG typically shows bursts of generalised polyspike-wave complexes. Sodium valproate used to be recommended as first-line therapy in JME, although it is now avoided in females of child-bearing age as it is very teratogenic and children born to mothers taking it are more likely to have learning disabilities. Lamotrigine and levetiracetam may be considered as alternatives, although the former is generally considered to be the best option. Carbamazepine and phenobarbitone may worsen the seizures and should be avoided.

Audio Video Stop Share Participants More

STC 32% 9:38 AM
https://mypastest.paste

A Gabapentin

This is not recommended in the treatment of JME. Gabapentin may be useful as an adjunctive treatment in patients with refractory focal seizures.

B Lorazepam

This drug is not recommended in the long-term treatment of JME. It is useful in the emergency setting for patients presenting with prolonged or repeated generalised seizures.

C Oxcarbazepine

Audio Video Stop Share Participants More

STC 32% 9:38 AM
https://mypastest.paste

C Oxcarbazepine

This drug is not recommended in the treatment of JME. It may be useful on the management of young people with focal seizures if first-line treatments (lamotrigine and carbamazepine) are not tolerated or ineffective.

D Sodium valproate

Due to high rates of teratogenicity and long-term developmental problems in children born to mothers taking valproate, this drug is now avoided whenever possible in women of child-bearing age.

Audio Video Stop Share Participants More

STC 33% 9:40 AM
https://mypastest.paste

lower limb clinical signs would you be most likely to detect on examination?

A Extensor plantar reflex

B Hyper-reflexia

C Loss of vibration sense

D Loss of temperature sensation

E Loss of proprioception

71068

Audio Video Stop Share Participants More

STC 33% 9:41 AM
https://mypastest.paste

Explanation

D Loss of temperature sensation

Brown-Séquard syndrome is associated with loss of, vibration and proprioception senses on the side ipsilateral to the spinal cord lesion. This is accompanied by ipsilateral weakness, hypertonia, hyper-reflexia and extensor plantar reflex, with segmental anaesthesia at the level of the lesion. Loss of pain and temperature sensation occurs, affecting the contralateral side. A complete syndrome picture is rare and many patients may only exhibit some features of the syndrome. Trauma is a common cause; demyelination due to

Audio Video Stop Share Participants More

STC 33% 9:42 AM
https://mypastest.paste

features of the syndrome. Trauma is a common cause; demyelination due to multiple sclerosis is another common cause, but any lateral cord lesion (haemorrhage, granuloma, tumour, etc.) may give this picture.

A	Extensor plantar reflex

The plantar reflex is a reflex elicited when the sole of the foot is stimulated with a blunt instrument. The reflex can take one of two forms. In normal adults, the plantar reflex causes a downward response of the hallux (flexion). An upward response (extension) of the hallux is known as the Babinski response or Babinski sign.

Audio Video Stop Share Participants More

STC 34% 9:42 AM
https://mypastest.paste

Séquard syndrome.

B Hyper-reflexia

Hyper-reflexia is on the ipsilateral side.

C Loss of vibration sense

This tends to occur on the ipsilateral side.

E Loss of proprioception

Loss of proprioception tends to occur on the ipsilateral side.

71068

Audio Video Stop Share Participants More

STC 34% 9:43 AM
https://mypastest.paste

A 25-year-old man presents with stereotyped episodes of facial pain. He describes 'electric shocks' to the lower half of his right face. Attacks last a second only, but he can experience multiple attacks in an hour, often with a residual ache. He identifies a number of triggers to attacks including laughing and shaving. There is no past medical history.

On examination, you note normal pupils and full range of ocular movement. There is reduced corneal reflex and reduced sensation in the mandibular and maxillary division of the trigeminal. The remainder of examination is unremarkable.

What is the next management step?

Audio Video Stop Share Participants More

STC 34% 9:45 AM
https://mypastest.paste

mandibular and maxillary division of the trigeminal. The remainder of examination is unremarkable.

What is the next management step?

A Carbamazepine

B Amitriptyline

C Reassurance

D Peripheral nerve block with phenol

E MRI of the brain

Audio Video Stop Share Participants More

STC 35% 9:46 AM
https://mypastest.paste

Explanation

E	MRI of the brain

The history given is characteristic of trigeminal neuralgia, with paroxysms of pain in the distribution of the trigeminal nerve. However, two features in the history should alert the clinician that this is unlikely to be 'classic' trigeminal neuralgia. Trigeminal neuralgia should not be associated with any physical signs: note the cranial nerve signs in this patient. Furthermore, trigeminal neuralgia is a disease of middle-to-late age, most often affecting women. Thus in this young male patient, imaging to exclude a structural lesion – for

Audio Video Stop Share Participants More

STC 35% 9:46 AM
https://mypastest.paste

associated with any physical signs: note the cranial nerve signs in this patient. Furthermore, trigeminal neuralgia is a disease of middle-to-late age, most often affecting women. Thus in this young male patient, imaging to exclude a structural lesion – for instance an area of demyelination related to multiple sclerosis – should be performed before therapy is instituted. Usual treatment for trigeminal neuralgia would be a titrated dose of carbamazepine. A number of surgical procedures are available for intractable pain but are associated with significant potential side effects.

Audio Video Stop Share Participants More

STC 35% 9:48 AM
https://mypastest.paste

A Carbamazepine

Carbamazepine is an initial first-line option for trigeminal neuralgia, but a structural cause for the patient's symptoms should be excluded first.

B Amitriptyline

There is little evidence to support use of tricyclic antidepressants in the management of trigeminal neuralgia, although they are often added as a second-line therapy.

C Reassurance

Audio Video Stop Share Participants More

STC 35% 9:48 AM
https://mypastest.paste

C Reassurance

The pain associated with trigeminal neuralgia is significant, and may itself drive depression because of its severity. As such, reassurance alone isn't an appropriate option.

D Peripheral nerve block with phenol

Nerve blockade may be considered in patients who fail to respond to medical therapy alone.

7337
Rate this question:
Audio Video Stop Share Participants More

STC 35% 9:48 AM
https://mypastest.paste

A 42-year-old right-handed migraneur is admitted to hospital having developed paraesthesia affecting her left arm. This came on suddenly during a migrainous attack while out shopping. The paraesthesia appeared to affect the entire left arm and in the last few hours had spread to involve the left side of the face. She had had a similar episode several months ago whereby she developed some right-sided leg and arm weakness while at work. The weakness lasted several minutes and subsequently abated. At the time she was also having one of her migraines. She has a long-standing history of migraines, which typically start with a prolonged aura and

Audio Video Stop Share Participants More

STC 36% 9:49 AM
https://mypastest.paste

history of migraines, which typically start with a prolonged aura and fortification spectra. Other than migraines, for which she has been taking pizotifen, she has no other past medical history. Her sister also suffers from migraines, and her father has a history of dementia in his 50s. She is a non-smoker and drinks minimal alcohol.

On examination she was orientated but apathetic. Her blood pressure was 130/65 mmHg, pulse 62/min and temperature 36.2ºC. There were no carotid bruits and heart sounds were entirely normal. There was reduced sensation to all modalities over the left side of the face, extending to the

Audio Video Stop Share Participants More

STC 36% 9:50 AM
https://mypastest.paste

sensation to all modalities over the left side of the face, extending to the vertex and the entire left arm. Tone and reflexes appeared intact; however, handgrip was reduced on the left due to numbness. The lower limb appeared entirely normal.

Magnetic resonance (MR) scan showed bilateral, multifocal, T_2/FLAIR (fluid-attenuated inversion recovery) hyperintensities in the deep white matter of the temporal lobes.

Lumbar puncture (CSF):

Opening pressure	14 cmH_2O (5–18)
Protein	0.40 g/l (0.15–0.45)

Audio Video Stop Share Participants More

STC 37% 9:51 AM
https://mypastest.paste

Lumbar puncture (CSF):

Opening pressure	14 cmH_2O (5–18)
Protein	0.40 g/l (0.15–0.45)
WCC	4 cells/ml (≤ 5)
RCC	2 cells/ml (≤ 5)
Glucose	3.3 mmol/l (3.3–4.4)
Lactate	1.5 mmol/l (1–2)

In view of the above findings, choose the likely diagnosis for this patient

Audio Video Stop Share Participants More

STC 37% 9:51 AM
https://mypastest.paste

In view of the above findings, choose the likely diagnosis for this patient

A	Systemic lupus erythematosis (SLE)
B	CADASIL (cerebral autosomal dominant arteriopathy with subcortical infarcts and leucoencephalopathy)
C	Migraine with aura
D	Multiple sclerosis
E	Mitochondrial disease (MELAS)

Audio Video Stop Share Participants More

STC 37% 9:53 AM
https://mypastest.paste

B CADASIL (cerebral autosomal dominant arteriopathy with subcortical infarcts and leucoencephalopathy)

This patient gives a history of migraine with aura, stroke-like episodes and has a positive family history for migraine and early dementia. In the absence of vascular risk factors such as hypertension, diabetes or hypercholesterolaemia, this patient has cerebral autosomal dominant arteriopathy with subcortical infarcts and leucoencephalopathy (CADASIL). MRI changes involving the temporal lobes are typical. CADASIL is an

Audio Video Stop Share Participants More

STC 37% 9:53 AM
https://mypastest.paste

lobes are typical. CADASIL is an arteriopathy characterised by thickening of the media and loss of smooth muscle. Notch 3, which is expressed in smooth muscle, is mutated in these patients.

A Systemic lupus erythematosis (SLE)

Migraine and stroke are more common in SLE, but there are no systemic features to suggest SLE in the history or examination. In addition, one would expect active CSF with lupus affecting the CNS.

C Migraine with aura

Audio Video Stop Share Participants More

STC 37% 9:54 AM
https://mypastest.paste

C Migraine with aura

Her neurological symptoms are relatively severe and long-lasting to be considered typical of aura. In addition, the MRI changes and family history suggest something else is going on.

D Multiple sclerosis

MS is typically associated with relapses and remissions. An MS relapse comes on over days and then lasts for several weeks; these are not usually associated with headache. Therefore MS seems unlikely on clinical grounds.

Audio Video Stop Share Participants More

STC 38% 9:54 AM
https://mypastest.paste

unlikely on clinical grounds.

E	Mitochondrial disease (MELAS)

Mitochondrial disorders such as MELAS can present with migraine and stroke-like episodes but are also characterised by elevated blood and CSF lactate. There are no other features in the history, such as short stature, diabetes and heart disease or optic nerve problems, to suggest this diagnosis. In addition, the mode of inheritance in this case looks autosomal dominant whereas MELAS is maternally inherited.

Audio Video Stop Share Participants More

STC 38% 9:55 AM
https://mypastest.paste

A 25-year-old African–Caribbean woman presented with progressively deteriorating mobility over the last five years. She had been in the UK for the last 3 years, having previously lived in Jamaica. She originally complained of back pain and then started to drag her feet while she was walking, which resulted in a number of falls. In the last 2 years, she had a regular urge to pass urine and had been incontinent twice. She was also constipated over the same period. She said that her partner, who is also from the Caribbean, had also been suffering from similar problems.

On examination, her cranial nerves and upper limbs were normal. Lower limb examination revealed increased tone

Audio Video Stop Share Participants More

STC 39% 9:56 AM
https://mypastest.paste

On examination, her cranial nerves and upper limbs were normal. Lower limb examination revealed increased tone bilaterally, pyramidal distribution weakness of both limbs and increased reflexes throughout with upgoing plantar reflexes. Coordination was normal but there was a sensory level at T10. Generalised lymphadenopathy was also noted.

What is the most likely diagnosis?

A Neurosyphilis

B Tropical spastic paraparesis

Audio Video Stop Share Participants More

STC 39% 9:56 AM
https://mypastest.paste

was also noted.

What is the most likely diagnosis?

A Neurosyphilis

B Tropical spastic paraparesis

C Multiple sclerosis

D Hereditary spastic paraparesis

E Systemic lupus erythematosus (SLE)

6947

Audio Video Stop Share Participants More

STC 39% 9:58 AM
https://mypastest.paste

Explanation

B	Tropical spastic paraparesis

This patient has a spastic paraparesis of which there are many causes. The clue in this question comes from the fact that her husband also has similar problems (i.e. a presumed spastic paraparesis) and the cause is therefore likely to be a transmissible one.
Tropical spastic paraparesis (HTLV-1-associated myelopathy) is common in areas where HTLV-1 is endemic (the Caribbean, equatorial Africa and South America in particular). HTLV-1 is a retrovirus which is passed through blood and sexual contact. However, it

Audio Video Stop Share Participants More

STC 39% 9:59 AM
https://mypastest.paste

areas where HTLV-1 is endemic (the Caribbean, equatorial Africa and South America in particular). HTLV-1 is a retrovirus which is passed through blood and sexual contact. However, it is important to note that only around 5% of people who are HTLV-1 seropositive will develop tropical spastic paraparesis. There is no curative treatment and most interventions are designed to relieve symptoms.

A Neurosyphilis

Neurosyphilis is a feature of tertiary disease and is unlikely to present in a 25-year-old.

Audio Video Stop Share Participants More

STC 39% 9:59 AM
https://mypastest.paste

C Multiple sclerosis

Multiple sclerosis would be unlikely to present with lower limb symptoms only; the absence of upper limb signs or cranial nerve involvement would be highly unusual.

D Hereditary spastic paraparesis

There is no evidence of hereditary neurological disease in this patient, and presentation with severe symptoms in the third decade would be unusual.

E Systemic lupus

Audio Video Stop Share Participants More

STC 39% 9:59 AM
https://mypastest.paste

There is no evidence of hereditary neurological disease in this patient, and presentation with severe symptoms in the third decade would be unusual.

E	Systemic lupus erythematosus (SLE)

Other features to suggest lupus are not seen here, and transverse myelitis is a rare presenting feature in SLE.

6947

Rate this question:

Next Question

Audio Video Stop Share Participants More

STC 40% 10:00 AM
https://mypastest.paste

A 65-year-old man was seen by a psychiatrist as he had developed apprehensiveness, fretfulness and irritability. He was thought to have agitated depression and a selective serotonin reuptake inhibitor (SSRI) was initiated.

However, over the next 8 months he developed falls, which would occur abruptly, and intermittent sudden involuntary closure of the eyes. He was noticed to have difficulty in swallowing and his speech had become slurred. He fell abruptly again, resulting in bruises over his knees and face and hence he was brought to the Accident and Emergency Department.

On examination, his BP was noted to

Audio Video Stop Share Participants More

STC 40% 10:00 AM
https://mypastest.paste

On examination, his BP was noted to be 145/82 mmHg, with a postural drop of 25 mmHg on standing. His pulse rate also increased by 10 bpm. There were no heart murmurs on auscultation and his chest was clear. Neurological examination revealed a Parkinsonian gait and paralysis of downward gaze. Although there is rigidity, tremor is not particularly marked.

What is the most likely diagnosis?

A Drug-induced parkinsonism

B Idiopathic Parkinson's disease

Audio Video Stop Share Participants More

STC 40% 10:01 AM
https://mypastest.paste

What is the most likely diagnosis?

A Drug-induced parkinsonism

B Idiopathic Parkinson's disease

C Narcolepsy

D Tertiary syphilis

E Progressive supranuclear palsy

32756

Audio Video Stop Share Participants More

STC 41% 10:02 AM
https://mypastest.paste

E Progressive supranuclear palsy

Progressive supranuclear palsy (PSP, also originally known as Steel Richardson and Olszewski syndrome) is a neurodegenerative disease which characteristically has its onset in the sixth decade of life. Initially there are vague changes in personality such as apprehensiveness and fretfulness, which suggests an agitated depression as in the present patient. Patients develop supranuclear ophthalmoplegia, pseudo-bulbar palsy and an axial dystonia. Blepharospasm and involuntary eye closure is prominent in some cases. Repeated

Audio Video Stop Share Participants More

STC 41% 10:03 AM
https://mypastest.paste

and an axial dystonia. Blepharospasm and involuntary eye closure is prominent in some cases. Repeated abrupt falling without any evidence of ataxia is characteristic. There is no resting tremor and patients respond poorly to levodopa.

A Drug-induced parkinsonism

SSRIs do not lead to drug-induced parkinsonism; symptoms of movement disorder may be seen when patients are prescribed neuroleptics.

B Idiopathic Parkinson's disease

The autonomic and gaze features seen

Audio Video Stop Share Participants More

STC 41% 10:03 AM
https://mypastest.paste

B Idiopathic Parkinson's disease

The autonomic and gaze features seen here count more towards a Parkinson's 'plus' disorder, as does the lack of significant tremor.

C Narcolepsy

Narcolepsy is associated with sleep disruption, but not with the other neurological and autonomic features seen here.

D Tertiary syphilis

The hallmark of tertiary syphilis is

Audio Video Stop Share Participants More

STC 41% 10:03 AM
https://mypastest.paste

C Narcolepsy

Narcolepsy is associated with sleep disruption, but not with the other neurological and autonomic features seen here.

D Tertiary syphilis

The hallmark of tertiary syphilis is dorsal column loss (loss of fine touch and proprioception), rather than the symptoms seen here.

52756

Rate this question:

Next Question

Audio Video Stop Share Participants More

STC 41% 10:04 AM
https://mypastest.paste

A 41-year-old woman presents with severe dizziness, vertigo and nausea. She has suffered a number of attacks over the past two months. The attacks come on at their worst when she lies down in bed, with her head turned to the right-hand side, and last for around 20 s to a minute. There is no tinnitus.

Examination reveals no focal localising neurological signs. You move her rapidly from a sitting position to a supine one with her head tilted at 45 degrees. After waiting for 30 s, you return her to the sitting position having noted obvious nystagmus.

Given the likeliest origin of her symptoms, which of the following would be the most appropriate

Audio Video Stop Share Participants More

STC 41% 10:05 AM
https://mypastest.paste

Given the likeliest origin of her symptoms, which of the following would be the most appropriate treatment in this case?

A Prochlorperazine

B Diazepam

C Hall-pike manoeuvre

D Epley manoeuvre

E Betahistine

Audio Video Stop Share Participants More

STC 42% 10:06 AM
https://mypastest.paste

Explanation

D Epley manoeuvre

This patient gives the classical history of benign positional vertigo (BPPV) and the absence of focal neurological signs gives credence to this as the most likely diagnosis.

The onset of BPPV is typically sudden, with frequent attacks occurring for days to weeks, occasionally for months or years afterwards. The symptoms often resolve spontaneously until the next episode and occur in a spectrum of severity. In patients with extreme cases, the slightest head movement

Audio Video Stop Share Participants More

STC 42% 10:07 AM
https://mypastest.paste

of severity. In patients with extreme cases, the slightest head movement may be associated with nausea and vomiting.

The Epley manoeuvre looks to reposition any free-floating particles within the semi-circular canals and resolve positional vertigo.

A	Prochlorperazine

In most cases of medical treatments are not indicated. The treatment of choice is the Epley manoeuvre. In acute severe exacerbations which are not responsive to the Eply manoeuvre or similar, anti-histamine and anti-cholinergic drugs may be considered

Audio Video Stop Share Participants More

STC 43% 10:08 AM
https://mypastest.paste

A Prochlorperazine

In most cases of medical treatments are not indicated. The treatment of choice is the Epley manoeuvre. In acute severe exacerbations which are not responsive to the Eply manoeuvre or similar, anti-histamine and anti-cholinergic drugs may be considered.

B Diazepam

Long-term medical therapy, such as diazepam, is not the treatment of choice as the Epley manoeuvre carries a high chance of relieving symptoms. This manoeuvre is well documented

Audio Video Stop Share Participants More

STC 43% 10:08 AM
https://mypastest.paste

particles which exist in the semi-circular canals, with a series of planned movements of the head.

C	Hall-pike manoeuvre

The Hall-pike manoeuvre, which is described in the question, is the standard clinical test for BPPV. It is used for diagnosis, not treatment and is therefore an incorrect option. The finding of classic rotatory nystagmus with latency and limited duration is considered pathognomonic. A negative test result does not exclude the diagnosis.

Audio Video Stop Share Participants More

STC 43% 10:09 AM
https://mypastest.paste

E Betahistine

Long-term medical therapy, such as bitahistine, is not the treatment of choice. This patient's signs and symptoms are suggestive of benign positional vertigo (BPPV). The treatment of choice is the Epley manoeuvre.

18524

Rate this question:

Next Question

Audio Video Stop Share Participants More

STC 43% 10:10 AM
https://mypastest.paste

A 62-year-old right-handed man is seen in the clinic with a history of three episodes of sudden-onset left arm and leg weakness and numbness. Two of these episodes have been within the preceding week. Although they are associated with a headache, there are no speech or swallowing difficulties. The episodes of weakness last approximately 20-30 min.

He has a past history of left anterior circulation stroke with partial recovery, and is taking aspirin 75 mg/day.

On examination he is alert and oriented. His blood pressure is 165/92 mmHg (two previous readings were 143/85 mmHg and 155/84 mmHg), pulse is 72 bpm and regular and

Audio Video Stop Share Participants More

STC 44% 10:10 AM
https://mypastest.paste

On examination he is alert and oriented. His blood pressure is 165/92 mmHg (two previous readings were 143/85 mmHg and 155/84 mmHg), pulse is 72 bpm and regular and temperature is 36.5 °C. The temporal arteries are pulsatile and non-tender; there are no carotid bruits and hearts sounds appear normal. Cranial nerve examination is normal.

On examination of the peripheral nervous system, there is some slight pyramidal weakness of 4/5 affecting the right arm and leg, with brisk reflexes and a right extensor plantar response. No left-sided weakness or sensory disturbance is noted.

Blood tests reveal:

Audio Video Stop Share Participants More

STC 44% 10:11 AM
https://mypastest.paste

sensory disturbance is noted.

Blood tests reveal:

Hb	134 g/l
WCC	7.0×10^9/l
PLT	180×10^9/l
Na^+	135 mmol/l
K^+	3.5 mmol/l
Creatinine	98 μmol/l
Urea	4.2 μmol/l
Glucose	5.6 mmol/l
ESR	< 5 mm/h
Cholesterol	3.4 mmol/l

Audio Video Stop Share Participants More

STC 44% 10:12 AM
https://mypastest.paste

Cholesterol	3.4 mmol/l
CT scan	Evidence of previous left anterior circulation infarct
Carotid Doppler	100% stenosis of right internal carotid artery and 60% left internal carotid artery
Echocardiogram	Normal
ECG	Flattened T-waves in lateral leads

Given the above history and investigations, how should this patient

Audio Video Stop Share Participants More

STC 44% 10:12 AM
https://mypastest.paste

be managed?

A Referral for right carotid endarterectomy

B Add pizotifen to his present medication

C Change the aspirin for clopidogrel

D Commence on warfarin and stop aspirin

E Add clopidogrel to aspirin

Audio Video Stop Share Participants More

STC 45% 10:15 AM
https://mypastest.paste

Explanation

C	Change the aspirin for clopidogrel

This patient presents with a history compatible with recurrent transient ischaemic attacks (TIAs) within the right anterior cerebral artery circulation. He has a previous history of cerebrovascular accident (previous left hemisphere infarct), borderline hypertension and may have ischaemic heart disease. His carotid Doppler shows complete occlusion of the right internal carotid artery ipsilateral to the side of the cerebral lesion (consistent with his current symptoms of recurrent left arm and leg weakness). This is not

Audio Video Stop Share Participants More

STC 46% 10:16 AM
https://mypastest.paste

internal carotid artery ipsilateral to the side of the cerebral lesion (consistent with his current symptoms of recurrent left arm and leg weakness). This is not amenable to carotid endarterectomy. Several factors need to be addressed. Although his blood pressure (BP) is not above the treatable 160/95 mmHg in all readings, he has high risk for further recurrent TIAs. The PROGRESS (Perindopril Protection Against Recurrent Stroke Study) trial showed that BP reduction (using perindopril and indapamide) after ischaemic stroke reduces the risk of further events, even in patients with 'normal' blood pressure. Therefore this patient should be commenced on an ACE inhibitor.

Audio Video Stop Share Participants More

STC 46% 10:18 AM
https://mypastest.paste

blood pressure. Therefore this patient should be commenced on an ACE inhibitor.
The Heart Protection Study showed that treatment with simvastatin 40 mg reduces the risk of stroke and other vascular events in high-risk patients (previous ischaemic stroke, coronary or peripheral vascular disease, diabetes) even if the cholesterol level is 'normal' - <3.5mmol/l, and therefore he should be commenced on simvastatin.
Current guidelines suggest this patient should be given clopidogrel instead of aspirin.

Referral for right carotid endarterectomy

Audio Video Stop Share Participants More

STC 47% 10:19 AM
https://mypastest.paste

A Referral for right carotid endarterectomy

The vessel is completely occluded so surgery is not an option.

B Add pizotifen to his present medication

The symptoms are more suggestive of TIA than migraine.

D Commence on warfarin and stop aspirin

Anticoagulation in patients with

Audio Video Stop Share Participants More

STC 47% 10:19 AM
https://mypastest.paste

D Commence on warfarin and stop aspirin

Anticoagulation in patients with previous stroke and sinus rhythm showed no additional benefit over aspirin in the WARSS (Warfarin-Aspirin Recurrent Stroke Study) trial.

E Add clopidogrel to aspirin

The MATCH trial (Management of Atherothrombosis with Clopidogrel in High-risk patients) has not shown any added benefit of combining clopidogrel with aspirin versus clopidogrel alone.

32712
Audio Video Stop Share Participants More

STC 47% 10:20 AM
https://mypastest.paste

A 45-year-old woman is admitted comatose to the resuscitation room. Her husband describes a few days of increasing confusion.

Past medical history is of diabetes, primary biliary cirrhosis and one episode of variceal haemorrhage. Drug therapy includes ursodeoxycholic acid, metformin and aspirin. She does not consume alcohol or any illicit drugs.

On examination, she is drowsy and unable to converse. There is no meningism, and pupils are equal and reactive. She has assumed a decorticate position, plantars are upgoing. Bedside blood glucose is 6.1 mmol/l. The remainder of systemic examination is unremarkable. As well

Audio Video Stop Share Participants More

STC 48% 10:21 AM
https://mypastest.paste

		Values
Hb	8.9 g/dl	11.5–16.5 g/dl
WCC	13 × 10^9/l	4–11 × 10^9
PLT	60 × 10^9/l	150–400 × 10^9
Na^+	137 mmol/l	
K^+	3.2 mmol/l	
Creatinine	66 µmol/l	
PT	19 s	11.5–15.5 s

Audio Video Stop Share Participants More

STC 48% 10:21 AM
https://mypastest.paste

CRP	45 mg/l	< 10 mg/l
Bilirubin	12 µmol/l	1–22 µmol/l
ALP	10 IU/l	45–105 IU/l
AST	36 IU/l	1–31 IU/l
ALT	38 IU/l	5–35 IU/l
Albumin	28 g/l	37–49 g/l
CT brain	Mild atrophy	
	Diffuse	

Audio Video Stop Share Participants More

STC 48% 10:22 AM
https://mypastest.paste

CT brain	Mild atrophy	
EEG	Diffuse symmetrical triphasic sharp waves	

How should this patient be further managed?

A Lorazepam boluses intravenously

B Intravenous aciclovir

C Magnetic resonance image (MRI) brain

Audio Video Stop Share Participants More

STC 48% 10:22 AM
https://mypastest.paste

managed?

A Lorazepam boluses intravenously

B Intravenous aciclovir

C Magnetic resonance image (MRI) brain

D Upper gastrointestinal endoscopy

E Plasma exchange

Audio Video Stop Share Participants More

STC 50% 10:25 AM
https://mypastest.paste

D Upper gastrointestinal endoscopy

Although the patient has relatively normal transaminases (aminotransferases), we know from the history of varices that she has cirrhotic liver disease. We can also deduce from her low albumin and prolonged prothrombin time that her synthetic liver function is severely compromised. Thus a likely diagnosis of grade III–IV hepatic encephalopathy can be made. The electroencephalogram (EEG) picture is classical for hepatic encephalopathy. Her serum ammonia ought to be measured. The next stage of management is to identify any

Audio Video Stop Share Participants More

STC 50% 10:26 AM
https://mypastest.paste

In this patient, the likely precipitants are sepsis and gastrointestinal bleed; note the raised inflammatory markers, anaemia and disproportionate rise in urea. Therefore, an upper GI endoscopy is the best option presented here. Although commonly used, interventions such as non-absorbable disaccharides (lactulose), antibiotics and protein restriction have little evidence base.

E	Plasma exchange

Plasma exchange is not helpful in treating hepatic encephalopathy.

Audio Video Stop Share Participants More

STC 50% 10:26 AM
https://mypastest.paste

A Lorazepam boluses intravenously

The diagnosis is hepatic encephalopathy, and drugs such as benzodiazepines ought to be avoided where possible.

B Intravenous aciclovir

It is sensible to consider viral encephalitis in patients with confusion, but in this case the features suggest hepatic encephalopathy and serum ammonia should be checked to confirm this.

Audio Video Stop Share Participants More

STC 50% 10:27 AM
https://mypastest.paste

C Magnetic resonance image (MRI) brain

Obtaining an MRI brain is likely only to delay treating the underlying problem – a probable upper GI bleed. In hepatic encephalopathy, basal ganglia high signal on T1-weighted images can be seen. In severe hepatic encephalopathy such as this, diffuse brain swelling may be seen.

52718

Rate this question:

Next Question

Audio Video Stop Share Participants More

STC 61% 7:38 AM
https://mypastest.paste

A 52-year-old man presented 3 days ago having fallen while intoxicated with alcohol. He had a depressed skull fracture with overlying scalp laceration and worries that he may have been hit with a blunt instrument. You are asked to review him as he is becoming increasingly drowsy and complaining of worsening headache.

On examination, he is pyrexial (38.2 °C).

Investigations:

Hb	13.2 g/dl
WCC	$13.1 \times 10^9/l$
PLT	$201 \times 10^9/l$

Audio Video Stop Share Participants More

STC 60% 7:39 AM
https://mypastest.paste

Investigations:

Hb	13.2 g/dl
WCC	13.1×10^9/l
PLT	201×10^9/l
Na^+	139 mmol/l
K^+	5.0 mmol/l
Creatinine	124 μmol/l

Which of the following is the most likely causative organism?

A *Streptococcus viridans*

B *Staphylococcus aureus*

Audio Video Stop Share Participants More

STC 60% 7:39 AM
https://mypastest.paste

Which of the following is the most likely causative organism?

A *Streptococcus viridans*

B *Staphylococcus aureus*

C *Pseudomonas aeruginosa*

D *Clostridium perfringens*

E *Aspergillus fumigatus*

20970

Audio Video Stop Share Participants More

STC 60% 7:40 AM
https://mypastest.paste

Explanation

B	*Staphylococcus aureus*

Staphylococcus aureus is the commonest cause of intracerebral infection due to penetrating/direct skull injury. Other potential causes may include *Staph. epidermidis*, *Clostridium*, soil anaerobes and fungi such as *Aspergillus* or *Candida*. Typical treatment for suspected staphylococcal intracerebral abscess includes gentamicin and flucloxacillin. Data on the brain penetration of linezolid are variable.

Audio Video Stop Share Participants More

STC 60% 7:41 AM
https://mypastest.paste

A *Streptococcus viridans*

S. viridans is associated with dental infection and is a recognised cause of subacute bacterial endocarditis. It isn't usually seen after skin/scalp laceration.

C *Pseudomonas aeruginosa*

Pseudomonas aeruginosa is an environmental pathogen and is often found in wounds that are heavily contaminated, for example with soil.

D *Clostridium perfringens*

Clostridium perfringens is responsible

Audio Video Stop Share Participants More

STC 60% 7:41 AM
https://mypastest.paste

D *Clostridium perfringens*

Clostridium perfringens is responsible for gas gangrene and results in subcutaneous emphysema. It is therefore inconsistent with the picture seen here.

E *Aspergillus fumigatus*

Fungal infection is usually diagnosed after failure to respond to antibacterials, and is more often a cause of pulmonary infection.

20970
Rate this question:
Audio Video Stop Share Participants More

STC 60% 7:41 AM
https://mypastest.paste

An 82-year-old man known to have prostatic carcinoma presents to the Emergency Department complaining of back pain, acute onset of leg weakness and loss of sensation.

On examination, he is found to have percussion tenderness of his spine, loss of sensation to the level of the umbilicus, a distended bladder and reduced anal tone. He has markedly reduced power of the lower legs, with hyperreflexia and up-going plantar responses.

Which of the following is the most useful investigation in confirming the diagnosis for this patient?

Audio Video Stop Share Participants More

STC 60% 7:42 AM
https://mypastest.paste

Which of the following is the most useful investigation in confirming the diagnosis for this patient?

A Chest X-rays

B X-ray of the whole spine X-ray

C MRI of the whole spine

D CT of the whole spine

E Myelography

32698

Audio Video Stop Share Participants More

STC 60% 7:42 AM
https://mypastest.paste

Explanation

C	MRI of the whole spine

The diagnosis in this case is acute spinal cord compression as evidenced by the upper motor neurone pattern weakness and sensory symptoms described, along with bladder and bowel dysfunction. Signs of cord compression include percussion tenderness over the spine, which is especially prominent with metastatic carcinoma, paraparesis, a sensory level and corticospinal reflex changes with increased tone, hyper-reflexia and clonus below the level of the lesion. This is a medical emergency and

Audio Video Stop Share Participants More

STC 60% 7:43 AM
https://mypastest.paste

This is a medical emergency and diagnosis should not be delayed. In patients with a history of carcinoma, bony metastases are the most common cause of cord compression and as prostate carcinoma commonly metastasises to bone this is the most likely cause in this case. Timely administration of dexamethasone is important, and discussion with Oncology regarding consideration of radiotherapy would be vital in the management of this patient.

A Chest X-rays

This investigation would not be useful in making the diagnosis of spinal cord compression. Lung is the second most

Audio Video Stop Share Participants More

STC 60% 7:43 AM
https://mypastest.paste

common site for metastatic disease in prostate cancer after bone, and so chest X-ray may aid confirmation of metastatic disease in this case.

B X-ray of the whole spine X-ray

This investigation would not be able to diagnose spinal cord compression. Spinal X-ray could show evidence of vertebral collapse, lytic lesions or sclerosis, but would not be able to confirm cord compression.

D CT of the whole spine

This investigation cannot be used to

Audio Video Stop Share Participants More

STC 60% 7:43 AM
https://mypastest.paste

D	CT of the whole spine

This investigation cannot be used to confirm spinal cord compression. CT imaging can offer detailed imaging of bony injury or disruption, but it is not useful in characterising the spinal cord and so is not the most useful modality to confirm cord compression.

E	Myelography

This investigation is less useful than MRI in the diagnosis of spinal cord compression. While it can image the spinal canal effectively, it is less useful in characterising the neural tissue.

Audio Video Stop Share Participants More

STC 59% 7:45 AM
https://mypastest.paste

A 72-year-old man presents to the Emergency Department with severe flinging movements of his right arm.

Where is the causative lesion?

A Right cerebellum

B Left subthalamic nucleus

C Medial longitudinal fasciculus (MLF)

D Right brachial plexus

E Left thalamus

Audio Video Stop Share Participants More

STC 57% 7:55 AM

A 72-year-old man presents to the Emergency Department with severe flinging movements of his right arm.

Where is the causative lesion?

Your answer was correct

A Right cerebellum

B Left subthalamic nucleus

C Medial longitudinal fasciculus (MLF)

D Right brachial plexus

E Left thalamus

Explanation

Audio Video Share Participants More

STC 57% 7:55 AM

A 72-year-old man presents to the Emergency Department with severe flinging movements of his right arm.

Where is the causative lesion?

Your answer was correct

A Right cerebellum

B Left subthalamic nucleus

C Medial longitudinal fasciculus (MLF)

D Right brachial plexus

E Left thalamus

Explanation

Shymaa Fathy's screen

STC 57% 7:55 AM

B Left subthalamic nucleus

Hemiballismus is a movement disorder which manifests as unilateral involuntary flinging movements of the proximal upper limbs. The lesion is in the contralateral subthalamic nucleus of Luys. In the elderly, the usual cause is a vascular event such as a stroke, whereas in younger patients, the aetiology may be infectious or inflammatory. Hemiballismus patients require treatment, both for the underlying aetiology and for the movements themselves. There are no large controlled clinical trials to guide anti-ballismus therapy. Dopamine receptor-blocking agents have been shown to suppress choreic and ballistic movements. Standard neuroleptic drugs, such as haloperidol, are started at low doses and titrated, as tolerated, until the movements are controlled.

Shymaa Fathy's screen

STC 57% 7:55 AM

The MLF is a heavily myelinated tract connecting the paramedian pontine reticular formation abducens complex to the oculomotor nucleus on the contralateral side. Lesions results in internuclear ophthalmoplegia, in which conjugate gaze is impaired in induction. It can occur most commonly with multiple sclerosis or, in more elderly patients, stroke.

D	Right brachial plexus

A right brachial plexus injury would result in lower motor neurone weakness and sensory loss of part of C5–C8 and T1. Clinically, this can present as Erb's palsy; the arm hangs in medial rotation, with an extended and pronated forearm, or Klumpke's paralysis – weakness of the forearm with an ulnar clawed hand. Common

Shymaa Fathy's screen

STC 56% 7:59 AM

A 69-year-old man presented with a history of progressive weakness of his lower limbs for the past four months. It was difficult for him to get up from his armchair and to walk. He has noticed that he tires very easily in any activity. There was some aching pain in his thighs. He was concerned that for the past several months he had a dry mouth and he needed laxatives to move his bowels effectively; sometimes this was very painful and he felt that he had not completely emptied. His GP has identified a positive faecal occult blood sample and he has lost 3 kg in weight over the past 2 months.

On examination, his blood pressure was 180/90 mmHg, heart rate 102/min. There was no clubbing or skin rash. His BMI was 24.

He was alert and cognition was normal. Pupils were 2.5 mm on each side and

Shymaa Fathy's screen

STC 56% 8:00 AM

Pupils were 2.5 mm on each side and were non-reactive to light. He also had slight bilateral ptosis. Other cranial nerves were normal. Hip flexors were 4/5. His grip strength also appeared weak bilaterally, but improved with reinforcement. Tendon reflexes were symmetrical and hypoactive. Planters were flexors. No muscle tenderness was present.

What is the most likely diagnosis?

A	Polymyositis
B	Lumbosacral disc disease
C	Cauda equina syndrome
D	Lambert-Eaton myasthenic syndrome

Shymaa Fathy's screen

STC 55% 8:01 AM

were non reactive to light. He also had slight bilateral ptosis. Other cranial nerves were normal. Hip flexors were 4/5. His grip strength also appeared weak bilaterally, but improved with reinforcement. Tendon reflexes were symmetrical and hypoactive. Planters were flexors. No muscle tenderness was present.

What is the most likely diagnosis?

A	Polymyositis
B	Lumbosacral disc disease
C	Cauda equina syndrome
D	Lambert–Eaton myasthenic syndrome
E	Spinal-muscular atrophy

Shymaa Fathy's screen

STC 55% 8:01 AM

B Lumbosacral disc disease

C Cauda equina syndrome

D Lambert–Eaton myasthenic syndrome

E Spinal-muscular atrophy

Explanation

D Lambert–Eaton myasthenic syndrome

LEMS is a particular form of myasthenia, typically occurring in the context of a paraneoplastic syndrome, observed more often in patients with oat cell carcinoma of the lung (60%) or carcinomas of the breast, prostate,

Shymaa Fathy's screen

STC 55% 8:02 AM

D Lambert-Eaton myasthenic syndrome

LEMS is a particular form of myasthenia, typically occurring in the context of a paraneoplastic syndrome, observed more often in patients with oat cell carcinoma of the lung (60%) or carcinomas of the breast, prostate, stomach, rectum and lymphoma. It is characterised by temporary increase in muscle power during the first few contractions, followed by increasing weakness after exertion.
Unlike in myasthenia gravis, the muscles of the pelvic and shoulder girdles and trunk are the ones that become fatiguable and weak. Tendon reflexes are often diminished.
Autonomic disturbances are usually seen, such as dry mouth, impotence, constipation, difficulty in micturition and non-reactive pupils. Cranial nerves may be involved, with ptosis occurring

Shymaa Fathy's screen

STC 55% 8:02 AM

become fatiguable and weak. Tendon reflexes are often diminished. Autonomic disturbances are usually seen, such as dry mouth, impotence, constipation, difficulty in micturition and non-reactive pupils. Cranial nerves may be involved, with ptosis occurring in around half of patients. Given the positive faecal occult blood sample and sensation of incomplete emptying, it is possible that he has an underlying rectal tumour.

Repetitive nerve stimulation reveals an incremental response (marked increase in the amplitude of action potentials).

Most patients benefit from 3,4-diaminopyridine 20 mg, five times daily. It may be combined with pyridostigmine. Intravenous immunoglobulin, plasmapheresis and corticosteroids have all been used with variable responses. Excision of the primary tumour is also known to positively affect symptom control.

Shymaa Fathy's screen

STC 55% 8:03 AM

A 23-year-old man presented to the Outpatient Clinic complaining of difficulty with his memory over the last few years. He had been unable to hold down a regular job because of this. He had found it very difficult to concentrate at work, feeling extremely tired most of the time and occasionally falling asleep at his desk.

He suffered from recurrent headaches, which happened on most days of the week for 1–4 h and were bi-frontal and throbbing in nature. He had recently had a few episodes where he had fallen to the ground without warning.

On further questioning, he complained of problems with sleeping at night, occasionally waking up in the middle of the night with a feeling that he could not move.

What would be the best treatment for this condition?

Shymaa Fathy's screen

STC 55% 8:05 AM

could not move.

What would be the best treatment for this condition?

A Sodium valproate

B Paroxetine

C Amitriptyline

D Carbamazepine

E Modafinil

6952

Submit

Shymaa Fathy's screen

STC 55% 8:05 AM

Explanation

E	Modafinil

The most likely diagnosis is narcolepsy. This is a condition that presents in the teens or 20s and consists of a tetrad of excessive daytime sleepiness, cataplexy (a sudden loss of voluntary muscle tone, often triggered by emotional stimuli), sleep paralysis (feeling that you are awake but cannot move) and hypnagogic/hypnopompic hallucinations (hallucinations on going to sleep/waking). However, not all of these have to be present to make a diagnosis. There is a human leucocyte antigen (HLA) association in a number of patients: DR2 and DQB1*0602 are both associated with narcolepsy with cataplexy (around 90% of patients). Diagnosis can be confirmed with a multiple sleep latency test. Excessive

Shymaa Fathy's screen

STC 55% 8:05 AM

E Modafinil

The most likely diagnosis is narcolepsy. This is a condition that presents in the teens or 20s and consists of a tetrad of excessive daytime sleepiness, cataplexy (a sudden loss of voluntary muscle tone, often triggered by emotional stimuli), sleep paralysis (feeling that you are awake but cannot move) and hypnagogic/hypnopompic hallucinations (hallucinations on going to sleep/waking). However, not all of these have to be present to make a diagnosis. There is a human leucocyte antigen (HLA) association in a number of patients: DR2 and DQB1*0602 are both associated with narcolepsy with cataplexy (around 90% of patients). Diagnosis can be confirmed with a multiple sleep latency test. Excessive sleepiness can be alleviated by use of modafinil.

Shymaa Fathy's screen

STC 55% 8:06 AM

A Sodium valproate

Sodium valproate is of most value in the treatment of epilepsy or as an alternative therapy for bipolar disorder. Neither seems likely given the history described here.

B Paroxetine

Although memory loss is a feature of depression, there are no other symptoms of depression reported to suggest that paroxetine would be of value.

C Amitriptyline

Amitriptyline may improve nocturnal sleep, but in the case of narcolepsy it may also exacerbate daytime sleepiness. As such, it is not of

Shymaa Fathy's screen

STC 54% 8:06 AM

An 18-year-old man is referred to the neurologist for the evaluation of sudden, shock-like contractions of his limbs, occurring particularly in the early morning for the past 4 years. These contractions may be precipitated by touch or even just a loud noise. He is unsteady on his feet and clumsy with his hands, and academically he's failing to achieve and has been recognised in class as hard of hearing.

One week before the appointment, he lost consciousness with a tonic-clonic seizure. His father is entirely normal. All of his three siblings have deafness and are diabetic, taking insulin.

On examination, he has mild cognitive impairment. His height is 140 cm. Both optic discs are pale. A grade 1 horizontal gaze-evoked nystagmus is evident. Incoordination is seen in all limbs. Shoulder girdle and pelvic girdle

Shymaa Fathy's screen

STC 54% 8:08 AM

muscles are weak, with power 4/5. Tendon reflexes are reduced in the upper limbs and absent in the lower limbs. You cannot evoke a plantar response and vibration sense is diminished to mid-shin.

What is the most likely diagnosis?

A	Bassen–Kornzweig syndrome
B	Mitochondrial myopathic syndrome
C	Paraneoplastic cerebellar degeneration
D	Spinocerebellar ataxia
E	Lafora body disease

Shymaa Fathy's screen

STC 54% 8:10 AM

B Mitochondrial myopathic syndrome

When a young adult develops myoclonus elicited by startle, with other types of seizures and then is found to have ataxia, mental decline, optic atrophy, deafness, short stature or peripheral neuropathy, a mitochondrial disease should be suspected. A family history of diabetes mellitus, unexplained deafness, unexplained neonatal deaths and seizure disorders with progressive neurological deficits, and a pattern which suggests a maternal inheritance, further complements this thought process. A mild proximal myopathy may be associated. Around 80% of such patients (with myoclonic epilepsy and ragged-red fibre disease (MERRF)) have a point mutation of the mitochondrial genome at locus 8344. Resting and post-exercise serum

Shymaa Fathy's screen

STC 53% 8:11 AM

Resting and post-exercise serum lactate and pyruvate determination are helpful. Cerebrospinal fluid (CSF) lactic acid and CSF pyruvic acid should be measured – for example, lactic acid levels may be normal in blood but elevated in CSF. EEG may also be useful here, especially given the presentation with myoclonic jerks.

A	Bassen–Kornzweig syndrome

Bassen–Kornzweig syndrome is the most well-known form of neuroacanthosis, which results in acanthosis of red blood cells and progressive ataxia. It doesn't therefore fit with the clinical picture seen here.

C	Paraneoplastic cerebellar degeneration

Shymaa Fathy's screen

The presence of underlying

STC 53% 8:12 AM

A Bassen-Kornzweig syndrome

Bassen-Kornzweig syndrome is the most well-known form of neuroacanthosis, which results in acanthosis of red blood cells and progressive ataxia. It doesn't therefore fit with the clinical picture seen here.

C Paraneoplastic cerebellar degeneration

There is no evidence of underlying malignancy (PCD is usually associated with lung or breast cancer), and the predominant symptoms seen here are muscle weakness rather than cerebellar symptoms.

D Spinocerebellar ataxia

Twenty-nine autosomal recessive

Shymaa Fathy's screen

STC 53% 8:13 AM

with lung or breast cancer), and the predominant symptoms seen here are muscle weakness rather than cerebellar symptoms.

D	Spinocerebellar ataxia

Twenty-nine autosomal recessive spinocerebellar ataxias are now identified. The absence of cerebellar signs clearly counts against this as the underlying diagnosis.

E	Lafora body disease

Lafora body disease is a benign myoclonic epilepsy of infancy, and therefore doesn't fit with the clinical presentation seen here. Sodium valproate is the mainstay of therapy.

32770

Rate this question:

Shymaa Fathy's screen

STC 53% 8:14 AM

A 19-year-old student comes to the Neurology Clinic. He is falling behind in his university studies. He is having disturbed nights of sleep and falls asleep suddenly during class in the daytime. This is hugely embarrassing and tends to occur in stressful situations or during a particularly animated conversation. In an attempt to sleep well at night, he has been drinking large amounts of alcohol in the evening.

Further questioning reveals that he has also been suffering from hypnagogic hallucinations. A friend recommended he try amphetamines to try and stay awake in the day.

Neurological examination is unremarkable.

Investigations:

Hb	12.3 g/dl

Shymaa Fathy's screen

STC 53% 8:14 AM

Neurological examination is unremarkable.

Investigations:

Hb	12.3 g/dl
WCC	5.6×10^9/l
PLT	209×10^9/l
Na^+	140 mmol/l
K^+	4.8 mmol/l
Creatinine	100 µmol/l
Urine toxicology screen	Amphetamines+

Which of the following is the most likely diagnosis?

A Narcolepsy

Shymaa Fathy's screen

STC 53% 8:15 AM

Your answer was correct

A	Narcolepsy
B	Rapid eye movement (REM) sleep disorder
C	Restless legs syndrome
D	Alcohol dependency
E	3,4-Methylenedioxymethamphetami (MDMA)-related sleep disorder

Explanation

A. Narcolepsy

Shymaa Fathy's screen

STC 53% 8:15 AM

Narcolepsy is characterised by excessive daytime sleepiness, cataplexy, hypnagogic hallucinations and sleep paralysis. Patients frequently use alcohol and other sedatives aiming to enhance their sleep at night, and try amphetamines in the day to keep them from suddenly falling asleep. The condition is most common in the Japanese population, and the prevalence in Caucasian populations is around 5:10,000. Encouraging good sleep hygiene is the mainstay of therapy, coupled with the use of either amphetamine-related agents or modafinil.

B	Rapid eye movement (REM) sleep disorder

REM sleep disorder is identified as an early feature of idiopathic Parkinson's disease and patients may be seen to

Shymaa Fathy's screen

STC 53% 8:15 AM

You are asked to see a 19-year-old woman who has been admitted following multiple seizures. She has had several seizures on the ward that have either terminated spontaneously after a few minutes or following the administration of intravenous lorazepam. The nurses suspect the seizures are not epileptic in origin and ask you to review the patient during her next seizure. On examination her BP is 135/72 mmHg, her pulse is 80/min and regular and BMI is 29. There are deliberate self-harm scars on both of her forearms. Neurological examination appears normal and she is not confused following the attack.

Which of the following features is most suggestive that this is a non-epileptic seizure?

A Friction burns on the legs

Shymaa Fathy's screen

STC 53% 8:16 AM

There are deliberate self-harm scars on both of her forearms. Neurological examination appears normal and she is not confused following the attack.

Which of the following features is most suggestive that this is a non-epileptic seizure?

A Friction burns on the legs

B Resistance to eyelid opening

C Turning the head consistently to the right

D Lack of tongue biting

E Absent pupillary light reflex

Shymaa Fathy's screen

STC 53% 8:16 AM

B Resistance to eyelid opening

Functional (or non-epileptic) seizures are common and occur in at least 10–20% of patients referred to specialist epilepsy clinics with intractable seizures. The history and description of the attacks is usually suggestive, but may not always be diagnostic of their functional nature. Non-epileptic attacks are broadly divided into: (1) hyperkinetic/thrashing attacks and (2) akinetic/motionless attacks. The 'strangeness' of an attack should in itself not imply a diagnosis of non-epileptic attack. Features that may help to distinguish functional from epileptic seizures include: asynchronous limb movements, undulating motor activity, purposeful movements, rhythmic pelvic movements, side-to-side head shaking, biting the tip of the tongue (as opposed to the side), ictal crying,

Shymaa Fathy's screen

STC 52% 8:17 AM

epileptic seizures include: asynchronous limb movements, undulating motor activity, purposeful movements, rhythmic pelvic movements, side-to-side head shaking, biting the tip of the tongue (as opposed to the side), ictal crying, vocalisation during the 'tonic–clonic' phase, closed eyelids, resistance to eyelid opening, lack of cyanosis and rapid post-ictal reorientation. Video telemetry is the gold standard investigation for possible functional seizures. Prolactin is often elevated 15–20 min after a tonic–clonic seizure, but due to several problems with this test (may rise in syncope, may remain normal in partial seizures) it is not recommended outside specialist centres.

A Friction burns on the legs

Shymaa Fathy's screen

These may be associated with either

STC 52% 8:18 AM

A 21-year-old man has recently been diagnosed with Becker's muscular dystrophy (BMD). Appropriate genetic counselling is arranged for the patient.

What would you advise him clinically about his condition?

A	It would affect any male and female offspring of his equally
B	He is likely to suffer from heart rhythm problems as he gets older
C	Any children he has with the condition are unlikely to live into their third decade due to increased penetrance
D	Any children he has will suffer symptoms in the first few

Shymaa Fathy's screen

STC 52% 8:19 AM

A It would affect any male and female offspring of his equally

B He is likely to suffer from heart rhythm problems as he gets older

C Any children he has with the condition are unlikely to live into their third decade due to increased penetrance

D Any children he has will suffer symptoms in the first few years of life

E Hypertrophy of his calf muscles and contractures over time will definitely be seen

Shymaa Fathy's screen

STC 52% 8:20 AM

B He is likely to suffer from heart rhythm problems as he gets older

While cardiomyopathy is less frequent in patients with BMD than in those with Duchenne's muscular dystrophy, conduction abnormalities may dominate and even necessitate the implantation of a defibrillator. Some rhythm disturbance over time is likely.

A It would affect any male and female offspring of his equally

BMD is X-linked, and hence any male offspring of his will be free of the condition. Any female children will carry the BMD gene.

C Any children he has with the condition are unlikely to live [illegible] third decade due to

Shymaa Fathy's screen

STC 52% 8:21 AM

D Any children he has will suffer symptoms in the first few years of life

Although Duchenne's presents by age 7, BMD follows a much more variable course, with symptoms manifest at any age from 3 years to middle age.

E Hypertrophy of his calf muscles and contractures over time will definitely be seen

Calf muscle hypertrophy and contractures are not an invariable feature of BMD compared to other forms of muscular dystrophy.

6661

Rate this question:

Next Question

Shymaa Fathy's screen

STC 51% 8:21 AM

A 28-year-old woman presents to Casualty with progressive difficulty in swallowing, which has developed over the last 6 weeks. This has become worse acutely and she has been unable to drink for the last two days. In addition to the swallowing problems, she has slurring of her speech. She reports that her symptoms seem to be worst in the evenings. She denies any arm or leg weakness; there are no sensory symptoms, no recent infections and no urinary symptoms.

On examination, her observations are within normal limits and oxygen saturations are 97% on air. She has bilateral ptosis with a complex ophthalmoplegia that is worst on up-gaze. She reports that these symptoms get worse as the day goes on. The pupillary responses are normal. The remainder of the cranial nerve examination is unremarkable, except for dysarthria. The gag reflex is

Shymaa Fathy's screen

STC 51% 8:25 AM

addition to the swallowing problems, she has slurring of her speech. She reports that her symptoms seem to be worst in the evenings. She denies any arm or leg weakness; there are no sensory symptoms, no recent infections and no urinary symptoms.

On examination, her observations are within normal limits and oxygen saturations are 97% on air. She has bilateral ptosis with a complex ophthalmoplegia that is worst on up-gaze. She reports that these symptoms get worse as the day goes on. The pupillary responses are normal. The remainder of the cranial nerve examination is unremarkable, except for dysarthria. The gag reflex is preserved. Limb examination reveals normal tone, power, preserved reflexes and normal sensory responses.

What would be the most useful investigation in confirming the

Shymaa Fathy's screen

STC 51% 8:26 AM
820-068-1014
Question 10 of 184
Leave

electromyography

The most likely diagnosis in this case is myasthenia gravis, and the patient has a typical history for this. The lack of sensory or peripheral signs, along with preserved reflexes and the more prolonged time course of symptoms, makes Guillain–Barré syndrome (GBS) (or its cranial nerve variant, Miller Fisher syndrome) unlikely. Myasthenia gravis is diagnosed by completing an assay for anti-acetylcholine receptor antibodies, electromyography (repetitive nerve stimulation and single-fibre EMG) and the so-called 'Tensilon® test'.

Remember that MG is associated in some cases with thymoma and, for this reason, chest imaging is indicated to look for this lesion. However, this in itself is clearly not a diagnostic test.

Although she has predominantly bulbar symptoms, she is very likely to

Audio Video Share Participants More

STC 51% 8:26 AM
820-068-1014
Leave

Although she has predominantly bulbar symptoms, she is very likely to have widespread subclinical involvement of other muscle groups, which should therefore be diagnostically useful if tested with EMG.

The condition is treated with acetyl cholinesterase inhibitors (pyridostigmine, neostigmine) and immunomodulators (steroids and azathioprine). Plasmapheresis and intravenous immunoglobulin infusions (IVIG) are also used. Thymectomy may be carried out and can improve symptoms and prognosis. Given the rare nature of this condition there are only a few randomised controlled studies, but they do support thymectomy as a treatment option.

Regular spirometry is essential in the context of acute myasthenic deterioration in order to detect incipient respiratory failure early and

Audio Video Share Participants More

STC 51% 8:27 AM

may be useful in the diagnosis of Guillain–Barré syndrome (GBS). The lack of sensory or peripheral signs, along with preserved reflexes and the more prolonged time course of symptoms in this case, makes GBS (or its cranial nerve variant, Miller Fisher syndrome) unlikely. It should be remembered, however, that the presentation of GBS is variable and can be almost pure motor and quite limited in its extent in some cases.

C	Nerve conduction studies

This investigation is not the most useful test in the diagnosis of myasthenia gravis. As there is no abnormality of the nerves themselves in myasthenia, nerve conduction is often normal. Specific testing with repetitive nerve stimulation and preferably single-fibre EMG is needed.

Audio Video Share Participants More

STC 51% 8:27 AM

A 66-year-old man is seen in the Emergency Department with a history of increasing confusion. His wife reports that since he retired two years ago, he had become increasingly apathetic and had lost interest in activities. He had worked as a local councillor for years, and his wife thought that he might have become depressed since his retirement.

She had taken him to see his general practitioner (GP) who started him on fluoxetine. However, he started becoming more forgetful, with his wife having to take over management of their finances. His wife also reports that his mobility had been gradually deteriorating, and she had eventually bought him a Zimmer frame, but he could no longer use this properly. For the past few weeks, his clothes would be frequently soaked with urine.

Shymaa Fathy's screen

What treatment should be considered

STC 50% 8:28 AM

becoming more forgetful, with his wife having to take over management of their finances. His wife also reports that his mobility had been gradually deteriorating, and she had eventually bought him a Zimmer frame, but he could no longer use this properly. For the past few weeks, his clothes would be frequently soaked with urine.

What treatment should be considered for this patient?

A Trimethoprim

B Trial of levodopa

C Thiamine

D Ventriculoperitoneal shunt

E Donepezil (Aricept)

Shymaa Fathy's screen

STC 50% 8:28 AM

their finances. His wife also reports that his mobility had been gradually deteriorating, and she had eventually bought him a Zimmer frame, but he could no longer use this properly. For the past few weeks, his clothes would be frequently soaked with urine.

What treatment should be considered for this patient?

A Trimethoprim

B Trial of levodopa

C Thiamine

D Ventriculoperitoneal shunt

E Donepezil (Aricept)

Shymaa Fathy's screen

STC 50% 8:30 AM

D Ventriculoperitoneal shunt

This patient has normal pressure hydrocephalus (NPH) as evidenced by the triad of gait apraxia, cognitive impairment and urinary incontinence. The usual sequence is of gait disturbance, followed by cognitive decline, and then urinary incontinence.

Diagnosis is by computed tomography (CT) of the brain which demonstrates enlarged ventricles in the presence of normal sulci (i.e. without significant superficial cortical atrophy).

Ventriculoperitoneal shunt is correct as patients with NPH may experience improvement in symptoms with drainage of excess cerebrospinal fluid. Predicting response to shunting requires a large-volume lumbar puncture: neuropsychological testing and timed walking test are performed before and after removal of 20-50 ml

Shymaa Fathy's screen

STC 50% 8:31 AM

superficial cortical atrophy).

Ventriculoperitoneal shunt is correct as patients with NPH may experience improvement in symptoms with drainage of excess cerebrospinal fluid. Predicting response to shunting requires a large-volume lumbar puncture: neuropsychological testing and timed walking test are performed before and after removal of 20-50 ml of CSF via lumbar puncture. There is wide variability in patient response to cerebrospinal fluid (CSF) diversion.

A	Trimethoprim

Trimethoprim is incorrect as this is used in the management of urinary tract infection and would not improve symptoms of normal pressure hydrocephalus (NPH). The existence of gait disturbance, followed by cognitive decline, and then urinary incontinence

Shymaa Fathy's screen

STC 50% 8:31 AM

hydrocephalus (NPH). The existence of gait disturbance, followed by cognitive decline, and then urinary incontinence makes the diagnosis of NPH much more likely than a urinary tract infection – although this should routinely be excluded.

B Trial of levodopa

Trial of levodopa is incorrect as this is used in the management of Parkinson's. This patient has normal pressure hydrocephalus (NPH) as evidenced by the triad of gait apraxia, cognitive impairment and urinary incontinence. Early stage Parkinson's disease would be less likely to present with cognitive impairment or incontinence.

C Thiamine

Shymaa Fathy's screen

STC 50% 8:32 AM

A 52-year-old electrician is referred to the Outpatient Clinic complaining of pain in his feet and difficulty in walking. On more detailed questioning, he reports noticing numbness over the soles of his feet for the past 10 months. He has been troubled by a 'pins and needles' sensation and, more recently, burning pains in both his feet. He also reports that his legs 'seem weaker' and that his walking has become increasingly unsteady such that he has recently given up work.

He takes no regular prescription medications, although he has been purchasing increasing quantities of painkillers from the supermarket for symptom relief. He has smoked 20 cigarettes a day for the past 35 years and admits to spending more time in the pub since giving up work.

Examination reveals symmetrical distal sensory loss in the lower limbs. Ankle reflexes are absent even with

Shymaa Fathy's screen

STC 50% 8:33 AM

Examination reveals symmetrical distal sensory loss in the lower limbs. Ankle reflexes are absent even with reinforcement. There is no significant postural drop in his blood pressure.

Investigations:

Haemoglobin (Hb)	11.8 g/dl
White cell count (WCC)	6.4×10^9/l
Haematocrit (Hct)	0.465
Mean corpuscular volume (MCV)	101.6 fl
Platelets	287×10^9/l
Sodium	137 mmol/l
Potassium	4.4 mmol/l
Urea	4.1 mmol/l
Creatinine	71 μmol/l

Shymaa Fathy's screen

STC 50% 8:34 AM

Bilirubin	30 mmol/l
Alanine aminotransferase	82 U/l
Albumin	43 U/l
Alkaline phosphatase	44 U/l
Gamma-glutamyl transpeptidase	110 IU/l
Calcium	2.15 mmol/l
Thyroid-stimulating hormone	2.25 mU/l
Thyroxine (T_4)	14.5 nmol/l
B_{12}	185 ng/l
Folate	10.9 µg/l
Random glucose	7.8 mmol/l
Fasting glucose	4.2 mmol/l
Erythrocyte	8

Shymaa Fathy's screen

STC 49% 8:34 AM

B_{12}	185 ng/l
Folate	10.9 µg/l
Random glucose	7.8 mmol/l
Fasting glucose	4.2 mmol/l
Erythrocyte sedimentation rate	8
C-reactive protein	4
Serum protein electrophoresis	Normal
Rheumatoid factor	Negative
Random cholesterol	8
Chest X-ray	Unremarkable

Which one of the following is the most appropriate next course of action?

Shymaa Fathy's screen

A. Magnetic resonance imaging

STC 49% 8:35 AM

Which one of the following is the most appropriate next course of action?

A Magnetic resonance imaging of the thoraco-lumbar spine

B Obtaining an accurate history of alcohol intake and recommending a detox programme

C Oral supplementation of all B vitamins

D Recommending cessation of all non-prescription analgesia and initiating a trial of amitriptyline

E Sural nerve biopsy

Shymaa Fathy's screen

STC 49% 8:37 AM

B Obtaining an accurate history of alcohol intake and recommending a detox programme

This case highlights alcoholic neuropathy. Sensory symptoms, which are usually distal and symmetrical, include early numbness, followed by dysaesthesias, particularly at night. Progression to severe pain that is described as burning or lancinating may occur. Motor manifestations tend to be mild. Autonomic disturbances are less common than in other neuropathies. The diagnosis is based on an accurate history of prolonged and excessive alcohol intake, clinical signs and symptoms, and electrophysiological testing. Management is directed at limiting degeneration of peripheral nerves and promoting restoration of normal function, primarily through abstinence

Shymaa Fathy's screen

STC 49% 8:38 AM

electrophysiological testing. Management is directed at limiting degeneration of peripheral nerves and promoting restoration of normal function, primarily through abstinence of alcohol. Nutritional support via a balanced diet and B vitamin supplementation are adjuncts to therapy, along with active rehabilitation. The prognosis of alcoholic neuropathy is generally good, provided that alcohol intake is discontinued and other causes of neuropathy (such as malignancy and diabetes) are carefully excluded. Clinical and electrophysiological examinations are reported to improve, independent of age.

C Oral supplementation of all B vitamins

It would be important to give vitamin B supplementation in conjunction with

Shymaa Fathy's screen

STC 48% 8:40 AM

A 25-year-old man presented to the Outpatient Clinic with a history of intermittent headaches for the last 5 months. These occur up to three times per day and last 30–50 min each time. He described two periods during these 5 months, one lasting 4 weeks and the other lasting 6 weeks, when the headaches occurred and that he had been headache free in between these times. He described experiencing severe right-sided pain behind the eye and he often noticed that the right eye became red and teary.

On examination, his BP is 122/72 mmHg, pulse is 70 bpm and regular and his BMI is 21. Physical examination, including full neurological exam, is entirely normal.

Which one of the following drugs is likely to be most effective in preventing further headaches?

Audio Video Share Participants More

STC 48% 8:41 AM

became red and teary.

On examination, his BP is 122/72 mmHg, pulse is 70 bpm and regular and his BMI is 21. Physical examination, including full neurological exam, is entirely normal.

Which one of the following drugs is likely to be most effective in preventing further headaches?

A Sumatriptan

B Propranolol

C Indomethacin

D Enalapril

E Verapamil

Shymaa Fathy's screen

STC 48% 8:41 AM

E Verapamil

The most likely diagnosis in this case is cluster headache, as supported by the description of severe, unilateral, periorbital headache associated with the autonomic feature of eye watering. Cluster headaches also characteristically last 15–180 min and occur 1–8 times per day in clusters lasting between 7 and 365 days, with intervening periods of at least 4 weeks where there are no headaches. Men are more commonly affected by cluster headaches than women. Autonomic features that may be experienced in association with these headaches include: conjunctival injection, lacrimation, nasal congestion, rhinorrhoea, sweating, miosis, ptosis and eyelid oedema. High-flow oxygen and triptans may be useful in terminating an acute attack but verapamil is the first-line option for

Shymaa Fathy's screen

STC 48% 8:42 AM

features that may be experienced in association with these headaches include: conjunctival injection, lacrimation, nasal congestion, rhinorrhoea, sweating, miosis, ptosis and eyelid oedema. High-flow oxygen and triptans may be useful in terminating an acute attack but verapamil is the first-line option for prophylaxis of cluster headaches, which is why it is the correct answer in this case.

A	Sumatriptan

While this medication is useful in the termination of an acute attack of cluster headache, it does not act to prevent future attacks. Sumatriptan can also be used to terminate headache due to migraine in an acute attack.

Shymaa Fathy's screen

STC 48% 8:42 AM

A 36-year-old painter and decorator presents with sudden-onset back pain. He was sitting on the floor painting a fence when he realised after some time that he was unable to get up.

On examination, he has bilateral leg weakness with lower limb hyporeflexia. He has pinprick sensory loss to the level of the umbilicus. Vibration sense is mildly impaired at the ankles and clearly present at the knee. He is in urinary retention.

Past medical history of note includes hypertension, for which he takes ramipril 10 mg daily.

Which of the following represents the most likely diagnosis?

A Anterior spinal cord syndrome

Shymaa Fathy's screen

B Cervical cord compression

STC 48% 8:43 AM

He has pinprick sensory loss to the level of the umbilicus. Vibration sense is mildly impaired at the ankles and clearly present at the knee. He is in urinary retention.

Past medical history of note includes hypertension, for which he takes ramipril 10 mg daily.

Which of the following represents the most likely diagnosis?

A	Anterior spinal cord syndrome
B	Cervical cord compression
C	Transverse myelitis
D	Guillain–Barré syndrome
E	Miller Fisher syndrome

Shymaa Fathy's screen

STC 47% 8:45 AM

A Anterior spinal cord syndrome

This artery supplies the anterior two-thirds of the spinal cord. Symptoms occur because there is complete motor paralysis below the level of the lesion due to interruption of the corticospinal tract. There is loss of pain sensation below the level of the lesion due to interruption of the spinothalamic tract. There is, however, relatively good preservation of vibration sense due to intact dorsal column function.

B Cervical cord compression

Cervical cord compression is essentially ruled out because of the sensory level at the umbilicus.

C Transverse myelitis

Shymaa Fathy's screen

STC 47% 8:47 AM

A 45-year old woman presented with 4-month history of an erythematous rash over her cheeks, her anterior upper chest and the backs of her hands. Over the same period she had become short of breath on exertion. In the last month, she had also complained of difficulty walking up the stairs at home.

General examination revealed a rash as noted above and dilated capillaries at the base of some of the fingernails.

On examination of the chest, there were a few bibasal crepitations. Neurological examination revealed mild weakness of hip flexion but it was an otherwise normal exam.

What is the most likely diagnosis?

A Dermatomyositis

B Eosinophilic granulomatosis

Shymaa Fathy's screen

STC 47% 8:47 AM

A 45-year old woman presented with 4-month history of an erythematous rash over her cheeks, her anterior upper chest and the backs of her hands. Over the same period she had become short of breath on exertion. In the last month, she had also complained of difficulty walking up the stairs at home.

General examination revealed a rash as noted above and dilated capillaries at the base of some of the fingernails.

On examination of the chest, there were a few bibasal crepitations. Neurological examination revealed mild weakness of hip flexion but it was an otherwise normal exam.

What is the most likely diagnosis?

A Dermatomyositis

Shymaa Fathy's screen

STC 47% 8:48 AM

A 45-year old woman presented with 4-month history of an erythematous rash over her cheeks, her anterior upper chest and the backs of her hands. Over the same period she had become short of breath on exertion. In the last month, she had also complained of difficulty walking up the stairs at home.

General examination revealed a rash as noted above and dilated capillaries at the base of some of the fingernails.

On examination of the chest, there were a few bibasal crepitations. Neurological examination revealed mild weakness of hip flexion but it was an otherwise normal exam.

What is the most likely diagnosis?

Your answer was correct

A Dermatomyositis

Shymaa Fathy's screen

STC 47% 8:48 AM

A	Dermatomyositis

This patient has a rash which is typical for dermatomyositis. The rash over the chest probably represents the 'V-sign' and the rash on the back of the hands is likely to be Gottron's papules. Proximal weakness is manifest as difficulty walking upstairs. The shortness of breath and bi-basal crepitation are likely to represent complicating interstitial lung disease.

B	Eosinophilic granulomatosis with polyangiitis (E-GPA)

E-GPA is a systemic vasculitis of small vessels and is associated with p-ANCA. It usually occurs in persons with a history of airway allergic hypersensitivity. Eosinophilia occurs in association with systemic features such as weight loss and night sweats. Vasculitis particularly of the peritoneal

Shymaa Fathy's screen

STC 47% 8:49 AM

A 19-year-old secretary presents with a 1-year history of progressive slowness of walking and tremor in his arms. He was sacked from his job after his line manager complained of an increasing number of mistakes at work, a general lack of motivation and irritable nature. In his family history, his mother is alive and well, his father committed suicide in his early forties and he has one younger sister who is alive and well.

On examination, he is noted to be in an unkempt state with decreased facial expression. His Mini-Mental State Examination score was 22 out of 30. Eye examination was normal. Tone was increased in the limbs, with decreased speed and amplitude of repetitive fine finger movements. An action tremor was also noted.

Which one of the following tests is most likely to establish the diagnosis in this case?

Shymaa Fathy's screen

STC 46% 8:50 AM

Which one of the following tests is most likely to establish the diagnosis in this case?

A	Levodopa challenge test
B	Free serum copper, total serum copper and serum caeruloplasmin
C	Molecular genetic analysis for CAG repeats in Huntingtin gene
D	Molecular genetic analysis in the gene coding for superoxide dismutase 1
E	Molecular genetic analysis to identify a mutation in the gene coding for dystrophin

Shymaa Fathy's screen

STC 46% 8:52 AM

C Molecular genetic analysis for CAG repeats in Huntingtin gene

This patient presents with the Westphal variant of Huntington's disease (HD), which manifests as presentation in youth with associated parkinsonian symptoms. The family history of suicide is of relevance and may be associated with behavioural features of the disease or retained insight during emergence of neurological symptoms. HD is inherited in an autosomal dominant pattern with complete penetrance. The gene for HD is on the short arm of chromosome 4, which contains CAG repeats (coding for glutamine). Healthy subjects have 11–34 repeats, while patients with HD have more than 40. Paternal inheritance is associated with anticipation (increasingly earlier age of onset in subsequent generations).

Shymaa Fathy's screen

STC 55% 7:24 AM
https://mypastest.paste

A 30-year old woman is seen in the Emergency Department with an excruciating, throbbing left-sided headache which is mainly orbital and temporal in location. She complains of photophobia, and is curling up into a ball to try to stop it getting worse. Her left eye is red and tearful. She also has a runny nose.

She has no past medical history of note, but has been experiencing recurrent episodes of this headache. Each episode lasts between 5 and 25 min, and may come on at any time. She has been experiencing at least 12 episodes each day.

What treatment is most likely to be effective for this patient?

Audio Video Stop Share Participants More

STC 55% 7:25 AM
https://mypastest.paste

What treatment is most likely to be effective for this patient?

A High-flow oxygen

B Metoclopramide

C Indomethacin

D Amitriptyline

E Codeine phosphate

7594

Audio Video Stop Share Participants More

STC 55% 7:26 AM
https://mypastest.paste

Explanation

C Indomethacin

This patient has chronic paroxysmal hemicrania (CPH), which is characterised by unilateral pain which is generally oculo-fronto-temporal in location. It can occur at any time, and patients often describe a throbbing, boring, pulsating or claw-like pain. Frequency of attacks is usually 10–20 per day. Episodes usually last 2–25 min, but may last as long as 60 min. Patients may also complain of ipsilateral conjunctival injection, ptosis and lid swelling, lacrimation and rhinorrhoea. Occasionally photophobia

Audio Video Stop Share Participants More

STC 55% 7:27 AM
https://mypastest.paste

Patients may also complain of ipsilateral conjunctival injection, ptosis and lid swelling, lacrimation and rhinorrhoea. Occasionally photophobia may be present. The most effective treatment is with indomethacin.

A High-flow oxygen

High-flow oxygen is the intervention of choice for cluster headache, which is more likely to be the diagnosis in a patient with more prolonged, less frequent headaches.

B Metoclopramide

Audio Video Stop Share Participants More

STC 55% 7:27 AM
https://mypastest.paste

B Metoclopramide

Metoclopramide is a potential short-term option to relieve nausea associated with acute episodes of migraine.

D Amitriptyline

Amitriptyline is a potential first-line therapy for migraine prophylaxis, rather than for paroxysmal hemicrania.

E Codeine phosphate

Codeine is unlikely to be effective in this case and can potentially drive issues around both opiate-related

Audio Video Stop Share Participants More

STC 55% 7:28 AM
https://mypastest.paste

As the medical registrar, you are called to see an 83-year-old male patient on the surgical wards who is recovering from a total hip replacement operation and who has gradually become increasingly confused over the last 24 h. His past medical history is significant for type II diabetes and hypertension, and he told the nursing staff that he likes to drink brandy each evening.

You are not able to hold a conversation with him, since he appears to be disorientated in time and place with perseveration of speech. He keeps complaining that he can see ants crawling over his body and that the nursing staff have put them there.

Audio Video Stop Share Participants More

STC 54% 7:29 AM
https://mypastest.paste

with him, since he appears to be disorientated in time and place with perseveration of speech. He keeps complaining that he can see ants crawling over his body and that the nursing staff have put them there.

Examination of his chest reveals no signs of infection, His blood pressure is raised at 142/82, pulse is 88 and regular and he is sweating. Routine blood tests are performed and an electrocardiogram (ECG) is requested. He is apyrexial.

Which one of the following would you consider the most likely cause of his symptoms?

Audio Video Stop Share Participants More

STC 54% 7:29 AM
https://mypastest.paste

Which one of the following would you consider the most likely cause of his symptoms?

A Hypoglycaemia

B Opiate analgesia

C Transient ischaemic attack

D Alcohol withdrawal

E Urinary tract infection

6658

Audio Video Stop Share Participants More

STC 54% 7:29 AM
https://mypastest.paste

Explanation

D Alcohol withdrawal

An acute confusional state is common in hospitalised patients, especially the elderly, and characteristically takes place over hours or days and is usually accompanied by signs of physical ill health such as infection or drug toxicity. It has a fluctuating course, being worse at night with lucid spells during the day. The person is often disorientated for time and place, but not for people. The patient is usually fearful, irritable and may be aggressive: paranoid ideas and visual and auditory hallucinations are

Audio Video Stop Share Participants More

STC 54% 7:30 AM
https://mypastest.paste

admission), coupled with the tactile hallucinations and signs of sympathetic activation, in the absence of other features to suggest infection, points us towards a diagnosis of alcohol withdrawal. B1 vitamin replacement and a reducing course of chlordiazepoxide are important interventions.

A Hypoglycaemia

Hypoglycaemia is associated with confusion and aggression, but these features are usually rapidly progressive as blood glucose level falls, rather than the subacute picture of symptoms seen here.

Audio Video Stop Share Participants More

STC 54% 7:30 AM
https://mypastest.paste

B Opiate analgesia

Opiate analgesia is more likely to lead to drowsiness and hypoventilation rather than the symptoms/signs of activation and aggression seen here.

C Transient ischaemic attack

Transient ischaemic attacks rarely produce symptoms of global confusion, and are much more likely to be associated with focal neurological signs.

E Urinary tract infection

Audio Video Stop Share Participants More

STC 54% 7:30 AM
https://mypastest.paste

be associated with focal neurological signs.

E	Urinary tract infection

There are no urinary symptoms or signs of infection to suggest a UTI in this case.

6658

Rate this question:

Next Question

Audio Video Stop Share Participants More

STC 54% 7:31 AM
https://mypastest.paste

An 84-year-old man with a history of atrial fibrillation and a previous transient ischaemic attack (TIA) attends the Emergency Department with a large haematoma of the right hip due to a fall where he tripped over a loose carpet tile. He lives independently, and this is his only fall during the course of the last 3 years. Medication includes ramipril, atorvastatin and warfarin.

On examination, his BP is 142/77 mmHg, pulse 77/min, atrial fibrillation. You notice bilateral carotid bruits on cardiovascular system examination.

Investigations:

Hb	10.9 g/dl

Audio Video Stop Share Participants More

STC 54% 7:32 AM
https://mypastest.paste

On examination, his BP is 142/77 mmHg, pulse 77/min, atrial fibrillation. You notice bilateral carotid bruits on cardiovascular system examination.

Investigations:

Hb	10.9 g/dl
WCC	6.8×10^9/l
PLT	183×10^9/l
Na^+	141 mmol/l
K^+	4.4 mmol/l
Creatinine	149 µmol/l
INR	2.1

Audio Video Stop Share Participants More

STC 54% 7:32 AM
https://mypastest.paste

Which of the following is the most appropriate way to manage his thromboembolism prophylaxis long-term?

A Withdraw warfarin

B Change warfarin to aspirin

C Change warfarin to dipyridamole

D Change warfarin to clopidogrel

E Continue warfarin

Audio Video Stop Share Participants More

STC 54% 7:34 AM
https://mypastest.paste

Explanation

E Continue warfarin

In a situation like this, the debate is between continuing warfarin and running the risk of further bleeding episodes, and stopping warfarin and running the consequent increased risk of further TIAs or a completed stroke. In this case, with persistent atrial fibrillation (AF) and evidence of bilateral carotid stenoses, the risk of further TIAs or a stroke is considerable; as such, it is best to continue warfarin.

A Withdraw warfarin

Audio Video Stop Share Participants More

STC 53% 7:34 AM
https://mypastest.paste

A Withdraw warfarin

Withdrawing warfarin is not appropriate given this patient's high risk of a stroke, and the fact that the fall is explained by a fall over a carpet tile.

B Change warfarin to aspirin

The Birmingham Atrial Fibrillation Treatment of the Aged (BAFTA) *study* (amongst others) suggests a 50% reduction in stroke risk for warfarin versus aspirin in an elderly population.

C Change warfarin to

Audio Video Stop Share Participants More

STC 53% 7:34 AM
https://mypastest.paste

C Change warfarin to dipyridamole

Although dipyridamole was utilised in conjunction with aspirin for stroke prevention in the ESPS-2 study, here it is inferior to warfarin because of the presence of AF.

D Change warfarin to clopidogrel

Clopidogrel is superior to aspirin for stroke prevention in the absence of AF, but the presence of AF drives us to utilise warfarin here.

Audio Video Stop Share Participants More

STC 53% 7:36 AM
https://mypastest.paste

A 34-year-old woman was on a camping holiday in Spain. She awoke at three o'clock one morning with severe neck pain radiating down into her left shoulder and down to her forearm. The next day it spread to the dorsal aspect of the forearm. She was otherwise well. Her symptoms resolved after 24 hours. She noticed that after a week she was unable to wind down the car window with her left arm, and now presents to the Emergency Department. On examination of the left arm there is wasting of brachioradialis, shoulder and biceps and winging of the left scapula.

Weakness of which muscle is most likely to have caused winging of the scapula?

Audio Video Stop Share Participants More

STC 53% 7:36 AM
https://mypastest.paste

Weakness of which muscle is most likely to have caused winging of the scapula?

A Serratus anterior

B Infraspinatus

C Rhomboids

D Trapezius

E Deltoid

32744

Audio Video Stop Share Participants More

STC 53% 7:37 AM
https://mypastest.paste

Explanation

A Serratus anterior

This woman has pain in her left shoulder radiating down her forearm, which has progressed rapidly (over <24 h). There is no evidence of systemic illness and onset of left-arm weakness is apparent around a week later. The serratus anterior is supplied by the long thoracic nerve (C5, C6, C7), weakness of which leads to winging of the scapula. Amyotrophic neuralgia characteristically affects these nerve routes and is associated with sudden onset of pain, followed by muscle wasting over the next few days.

Audio Video Stop Share Participants More

STC 53% 7:38 AM
https://mypastest.paste

with sudden onset of pain, followed by muscle wasting over the next few days. The condition improves spontaneously over a prolonged period. Aetiology is unknown, but may be a post-infective phenomenon. Physiotherapy aimed at preserving full movement of the shoulder, accompanied by adequate analgesia, is the mainstay of therapy.

B	Infraspinatus

The infraspinatus is the major muscle responsible for external rotation of the shoulder, and when the arm is fixed it abducts the inferior angle of the scapula.

Audio Video Stop Share Participants More

STC 53% 7:38 AM
https://mypastest.paste

C Rhomboids

The rhomboids work in tandem with the levator scapulae muscles to elevate the medial border of the scapula, downwardly rotating the scapula with respect to the glenohumeral joint.

D Trapezius

The upper and lower fibres tend to rotate the scapula around the sternoclavicular articulation so that the acromion and inferior angles move up and the medial border moves down. This rotation is in the opposite direction to that produced by the levator scapulae and the rhomboids.

Audio Video Stop Share Participants More

STC 53% 7:38 AM
https://mypastest.paste

The middle fibres retract the scapula, but it is the function of the serratus anterior to prevents winging.

E	Deltoid

The main action of the deltoid muscle in its entirety is shoulder abduction. Intact deltoid function is also essential to prevent subluxation of the shoulder joint.

32744

Rate this question:

Next Question

Audio Video Stop Share Participants More

STC 53% 7:38 AM
https://mypastest.paste

A 56-year-old man presented with a 3-year history of progressive leg weakness, with particular problems walking up the stairs. This was associated with intermittent pains in his thighs anteriorly. In the previous year he had also noticed problems unscrewing lids from jars, which he felt was due to his grip being generally weaker. He had been well otherwise with no recent weight loss or other symptoms.

Examination revealed wasting of the forearms and the quadriceps, with distal weakness in the upper limb and proximal weakness in the lower limb. Reflexes were present with flexor plantar responses. Sensation and

Audio Video Stop Share Participants More

STC 53% 7:40 AM
https://mypastest.paste

plantar responses. Sensation and coordination were normal.

What is the most likely diagnosis?

A Myotonic dystrophy

B Motor neurone disease

C Addison's disease

D Inclusion body myositis (IBM)

E Polymyositis

6948

Audio Video Stop Share Participants More

STC 53% 7:42 AM
https://mypastest.paste

Explanation

D Inclusion body myositis (IBM)

Inclusion body myositis (IBM) is the most common acquired myopathy in those aged over 50 years, being more common in men than women. There is often fairly selective muscle involvement, with wasting and weakness of the quadriceps and the long finger flexors being the most common. Muscles can also be affected asymmetrically. The pattern of muscle involvement is thus different to polymyositis (PM) or dermatomyositis (DM), and the rate of progression is generally slower than with these

Audio Video Stop Share Participants More

STC 52% 7:43 AM
https://mypastest.paste

(around 1000 IU/l) but generally not as high as in PM or DM.
Electromyography (EMG) and sometimes muscle biopsy will help in the diagnosis. IBM is much less responsive to immunosuppressive treatment than PM or DM.

A	Myotonic dystrophy

Symptoms of myotonic dystrophy generally present during the third decade with muscle weakness and myotonia (failure of muscles to relax for a prolonged period after use). Other features include infertility/subfertility and frontal balding in men.

Audio Video Stop Share Participants More

STC 52% 7:43 AM
https://mypastest.paste

B Motor neurone disease

The selective muscle involvement seen here is much more consistent with inclusion body myositis than motor neurone disease.

C Addison's disease

Although adrenal insufficiency is associated with proximal muscle weakness, other features that would suggest a diagnosis of adrenal insufficiency are absent here.

E Polymyositis

Audio Video Stop Share Participants More

STC 52% 7:43 AM
https://mypastest.paste

E Polymyositis

The selective muscle weakness seen here is inconsistent with polymyositis, with wasting of the quadriceps being the only proximal symptom seen here.

6948

Rate this question:

Next Question

Previous Question
Tag Question
Feedback
End Session

Audio
Video
Stop Share
Participants
More

STC 52% 7:44 AM
https://mypastest.paste

A 23-year-old woman is referred to the Neurology Clinic with a 6-month history of diffuse headache. This initially began as occasional pain occurring only at certain times during the week. It has increased, however, to the point where it is continuous. She notices that the pain is worse in the morning and she has had some mild nausea. She also describes some greying of her vision on exertion or on bending down to pick something up from the floor. She has a past medical history of depression and is taking fluoxetine for this. She also takes the oral contraceptive pill and tetracycline for acne vulgaris.

On examination, she has gross

Audio Video Stop Share Participants More

STC 52% 7:45 AM
https://mypastest.paste

On examination, she has gross papilloedema affecting both eyes. There is enlargement of the blind spot with some diplopia on left lateral gaze. Her body mass index is 32. There are no other neurological signs.

A magnetic resonance (MR) brain scan is performed, which shows no space-occupying lesion.

Cerebrospinal fluid analysis demonstrates an opening pressure of 33 cm of water. CSF analysis is shown below.

WCC	< 1
RCC	< 1

Audio Video Stop Share Participants More

STC 52% 7:46 AM
https://mypastest.paste

WCC	< 1
RCC	< 1
Glucose	4.1/6.5 mmol/l (serum 6.4)
Protein	0.3 g/dl

What is the most likely diagnosis?

A Tuberculous meningitis

B Idiopathic intracranial hypertension

C Caroto-cavernous fistula

Audio Video Stop Share Participants More

STC 52% 7:46 AM
https://mypastest.paste

Protein	0.3 g/dl

What is the most likely diagnosis?

A Tuberculous meningitis

B Idiopathic intracranial hypertension

C Caroto-cavernous fistula

D Primary intracerebral lymphoma

E Bilateral optic nerve glioma

Audio Video Stop Share Participants 1 More

STC 52% 7:46 AM
https://mypastest.paste

Explanation

B	Idiopathic intracranial hypertension

This young woman has multiple risk factors for idiopathic intracranial hypertension (IIH) including obesity and oral contraceptive and tetracycline use. This condition was previously called 'benign' intracranial hypertension. However, many neurologists feel that it is better described as idiopathic, partly to highlight the sometimes not benign prognosis (particularly when it comes to ophthalmological complications and visual loss) but also to highlight the extent to which this is a diagnosis of

Audio Video Stop Share Participants More

STC 52% 7:46 AM
https://mypastest.paste

hypertension. However, many neurologists feel that it is better described as idiopathic, partly to highlight the sometimes not benign prognosis (particularly when it comes to ophthalmological complications and visual loss) but also to highlight the extent to which this is a diagnosis of exclusion of other causes of intracranial hypertension. This patient would usually also have a CT or MR venogram to exclude cerebral venous sinus thrombosis as the cause for her raised ICP.

A. Tuberculous meningitis

The normal CSF constituents

Audio Video Stop Share Participants More

STC 52% 7:46 AM
https://mypastest.paste

A Tuberculous meningitis

The normal CSF constituents essentially exclude this diagnosis.

C Caroto-cavernous fistula

The normal brain imaging essentially excludes this diagnosis.

D Primary intracerebral lymphoma

One would expect either abnormal brain imaging or CSF (or likely both) with this condition.

Audio Video Stop Share Participants More

STC 51% 7:46 AM
https://mypastest.paste

E Bilateral optic nerve glioma

This would likely present with visual failure, rather that headache, and would be expected to show up on MRI (although subtle optic nerve lesions can be missed on routine scans with no contrast).

32709

Rate this question:

Next Question

Audio Video Stop Share Participants More

STC 51% 7:48 AM
https://mypastest.paste

Sedation and muscle relaxants were tapered off, and repeated attempts to wean him from the ventilator failed.

On examination, he was conscious and alert. Cranial nerve examination was unremarkable. His shoulder girdle muscles were grade 2 power and pelvic girdle muscles were grade 1. Tendon reflexes were preserved. The remainder of the examination was normal.

Choose the most likely diagnosis:

A Guillain–Barré syndrome

B Critical illness myopathy

Audio Video Stop Share Participants More

STC 51% 7:48 AM
https://mypastest.paste

remainder of the examination was normal.

Choose the most likely diagnosis:

A	Guillain–Barré syndrome
B	Critical illness myopathy
C	Myasthenia gravis
D	Inclusion body myositis
E	Corticosteroid myopathy

Audio Video Stop Share Participants 1 More

STC 51% 7:51 AM
https://mypastest.paste

Explanation

B Critical illness myopathy

This acute myopathy occurs in critical systemic disease, usually with multi-organ failure in the context of treatment with inotropes, muscle relaxants and corticosteroids. Serum creatine phosphokinase (CPK) is elevated and electromyography (EMG) reveals myopathic motor unit potentials and fibrillations. Muscle biopsy reveals loss of myosin filaments. Most patients recover after several weeks. In some patients the picture is one of neuromyopathy, so reduced reflexes and sensory loss can be seen.

Audio Video Stop Share Participants More

STC 50% 7:54 AM
https://mypastest.paste

reveals myopathic motor unit potentials and fibrillations. Muscle biopsy reveals loss of myosin filaments. Most patients recover after several weeks. In some patients the picture is one of neuromyopathy, so reduced reflexes and sensory loss can be seen.

A Guillain–Barré syndrome

GBS is an acute, immune-mediated neuropathy where one would expect areflexia and sensory loss in addition to weakness.

C Myasthenia gravis

Whilst this can cause proximal limb

Audio Video Stop Share Participants More

STC 50% 7:54 AM
https://mypastest.paste

C Myasthenia gravis

Whilst this can cause proximal limb weakness, it would be unusual to have no ocular or bulbar involvement.

D Inclusion body myositis

This is a chronic, progressive muscle disease that characteristically causes weakness in the forearm flexors and quadriceps. It does not present acutely.

E Corticosteroid myopathy

Audio Video Stop Share Participants More

STC 50% 7:54 AM
https://mypastest.paste

This is a chronic, progressive muscle disease that characteristically causes weakness in the forearm flexors and quadriceps. It does not present acutely.

E	Corticosteroid myopathy

This is a side effect from chronic steroid use, and usually presents with mild proximal lower limb weakness.

727

Rate this question:

Next Question

Audio Video Stop Share Participants More

3G 9:36

A 38-year-old man presented with a 2-week history of a firm, painless ulcer on the glans penis. He had recently returned from a 3-month trip to Thailand, China, Hong Kong and Australia. He was otherwise well.

Examination revealed an ulcer as described by the patient, with no associated lymphadenopathy.

What is the most likely diagnosis?

Calculator

Normal Values

A	Chancroid
B	Genital herpes
C	Gonorrhoea
D	Non-gonococcal urethritis
E	Syphilis

Submit

Rana Alnasser's screen

A 38-year-old man presented with a 2-week history of a firm, painless ulcer on the glans penis. He had recently returned from a 3-month trip to Thailand, China, Hong Kong and Australia. He was otherwise well.

Examination revealed an ulcer as described by the patient, with no associated lymphadenopathy.

What is the most likely diagnosis?

Your answer was correct

A	Chancroid
B	Genital herpes
C	Gonorrhoea
D	Non-gonococcal urethritis
E	Syphilis

Explanation

Difficulty: Average

Peer Responses %

Session Progress

Responses Correct:	1
Responses Incorrect:	0
Responses Total:	1
Responses - % Correct:	100%

Painless ulcers, developing 10–90 days after exposure, are typical of syphilis. However, it is worth noting that syphilitic ulcers can be painful and herpetic ulcers can be painless, and therefore this ulcer should be swabbed, and bloods should be taken for an immunoassay to confirm the diagnosis. This patient has presented with primary syphilis; secondary syphilis, which can develop roughly 6 weeks after the skin lesions have appeared, typically consists of constitutional flu-like symptoms and a non-pruritic rash which classically affects the face, palms and soles. This patient should be treated with benzathine penicillin as a single intramuscular dose. Oral azithromycin as a single dose is an acceptable second-line treatment. Fifty per cent of patients with primary syphilis will develop the Jarisch–Herxheimer reaction after treatment: flu-like symptoms and rigors which typically self-resolve within 24 h.

A	Chancroid

Chancroid is a sexually transmitted infection caused by a Gram-negative bacterium, *Haemophilus ducreyi*. It does cause penile ulceration, but you would expect the ulcer to be painful and to have associated lymphadenopathy. There is also typically a purulent exudate. The ulcer described in this patient is much more consistent with a diagnosis of syphilis: classically syphilitic ulcers are shallow and painless. They may or may not be associated with lymphadenopathy. These ulcers should be swabbed, as it is unreliable to make a clinical diagnosis in cases of genital ulcers. However, the patient should be treated for syphilis.

Calculator

Normal Values

A 34-year-old man presented with intermittent sore throat, fever, joint pain and general malaise for 3 months. He also complained of decreasing exercise tolerance.

Over the past 6 weeks, he had developed raised, red, tender lesions on his shins. He was diagnosed with human immunodeficiency virus (HIV) 8 years ago but had had a number of problems with medications because of their side-effects.

Investigations:

		Normal values
White cell count (WCC)	4×10^9/l	4.0–11.0
Neutrophils	0.2×10^9/l	1.5–7.0
Haemoglobin	131 g/l	130–180
Platelets	120×10^9/l	150–400
CD4+ count	100×10^6/l	430–1690
Chest X-ray	Two cavitating lesions in the right lung field	

Which organism is the most likely culprit?

Haemoglobin	131 g/l	130–180
Platelets	120×10^9/l	150–400
CD4+ count	100×10^6/l	430–1690
Chest X-ray	Two cavitating lesions in the right lung field	

Which organism is the most likely culprit?

A *Histoplasma capsulatum*

B *Legionella* species

C *Mycoplasma pneumoniae*

D *Pneumocystis jiroveci*

E *Staphylococcus aureus*

Submit

Rana Alnasser's screen

Explanation

A *Histoplasma capsulatum*

This patient has a low CD4+ count, but importantly he is also neutropenic. Any neutropenic patient is at significant risk of opportunistic infections, including fungal infections such as *Histoplasma capsulatum*. In this case, the patient has a cavitating pneumonia; the only two organisms in this list that cause cavitating pneumonia are *Staphylococcus aureus* and *H. capsulatum*. Typically, *S. aureus* cavitating pneumonia would present as an acute, severe pneumonia, not as an indolent course as seen in this patient. Therefore, *H. capsulatum* is the most likely diagnosis; it is associated with erythema nodosum, as seen in this patient. Other infectious causes of erythema nodosum which can affect the respiratory system are *Streptococcus*, *Mycoplasma pneumoniae*, tuberculosis, coccidioidomycosis and blastomycosis.

B *Legionella* species

This patient is immunocompromised with neutropenia and a low CD4+ count; this makes him vulnerable to any infection, including *Legionella* species. However, *Legionella* species do not cause cavitating pneumonia, as

Scroll capture Draw Crop Share

pneumonia, not as an indolent course as seen in this patient. Therefore, *H.*

organisms in this list that cause cavitating pneumonia are *S. aureus* and *H. capsulatum*. Typically, *S. aureus* cavitating pneumonia would present as an acute, severe pneumonia, not as an indolent course as seen in this patient. Therefore, *H. capsulatum* is the most likely diagnosis; it is associated with erythema nodosum, as seen in this patient.

D *Pneumocystis jiroveci*

Although *Pneumocystis jiroveci* is an important cause of pneumonia in the immunocompromised, and particularly HIV-positive patients with low CD4+ counts, it causes an indolent, dry cough, with bilateral infiltrates on chest X-ray. It does **not** cause cavitating lung lesions. The only two organisms in this list that cause cavitating pneumonia are *S. aureus* and *H. capsulatum*. Typically, *S. aureus* cavitating pneumonia would present as an acute, severe pneumonia, as not an indolent course as seen in this patient. Therefore, *H. capsulatum* is the most likely diagnosis; it is associated with erythema nodosum, as seen in this patient.

E *Staphylococcus aureus*

S. aureus does cause cavitating pneumonia, as seen on this patient's chest X-ray, but it would present as an acute, severe pneumonia, typically following a viral infection. This patient has a subacute course of illness. Any immunocompromised patient is vulnerable to fungal infection; this patient not only has a low CD4+ count but is also neutropenic. *H. capsulatum* is a fungal infection that can cause cavitating lung lesions and is the correct answer in this case.

Calculator

Normal Values

A 22-year-old female is referred to your Neurology Outpatients Clinic by the general practitioner (GP) as she is not able to smile. She has been generally unwell for about a month and has had malaise, a runny nose and muscle ache. She also noticed a rash on her arm about a month ago, but this has now cleared up. She is studying for her masters at Yale in Connecticut and does not drink, smoke or take drugs.

On examination, her pulse is 48 bpm in sinus rhythm. She has no lymphadenopathy and her chest is clear. Heart sounds are normal. There is evidence of a bilateral VIIth nerve palsy, but the remainder of the neurological examination is normal. You also notice that her right knee is swollen, but she feels she must have fallen on it.

Investigations:

Hb	13.8 g/dl
WCC	11.2×10^9/l
Lymphocytes	5.6×10^9/l
PLT	335×10^9/l
ECG	Sinus bradycardia
CXR	Normal

What is the most appropriate treatment?

Hb	13.8 g/dl
WCC	$11.2 \times 10^9/l$
Lymphocytes	$5.6 \times 10^9/l$
PLT	$335 \times 10^9/l$
ECG	Sinus bradycardia
CXR	Normal

What is the most appropriate treatment?

A	Oral prednisolone
B	Intravenous hydrocortisone
C	Doxycycline
D	Aspirin
E	Aciclovir and prednisolone

Annotation Stop Share

E Aciclovir and prednisolone

Explanation

C Doxycycline

This patient has early disseminated Lyme disease with evidence of peripheral nerve and musculoskeletal involvement. The treatment of choice would be a 2–3-week course of oral doxycycline (amoxicillin may be used instead in children and pregnant women for whom doxycycline is contraindicated).

A Oral prednisolone

This patient has Lyme disease, and there is no evidence that steroid therapy is of benefit in treating Lyme disease. If this patient had presented with an idiopathic VIIth nerve palsy alone (Bell's palsy), then the treatment of choice would be high-dose oral steroid.

B Intravenous hydrocortisone

This patient has Lyme disease, and there is no evidence that intravenous steroid therapy is of benefit in the treatment of this condition.

D Aspirin

This patient has Lyme disease and there is no role for aspirin in the treatment.

E	Aciclovir and prednisolone

This patient has Lyme disease. Valacyclovir and prednisolone would be the treatment of choice for Ramsay Hunt syndrome (reactivation of varicella zoster in the geniculate ganglion of the facial nerve). Typically patients would present with a unilateral facial nerve palsy, ear pain and a vesicular rash within the ear canal.

This patient has Lyme disease. Lyme disease is an infectious illness caused by the bacterium *Borrelia burgdorferi*. It is transmitted mainly through tick bites. It is very common in Connecticut, where it was given its name when it infected a large group of children in Lyme.

It initially presents with a slowly expanding skin lesion around the tick bite, erythemamigrans, malaise and joint aches. If not treated, neurological, cardiological and joint involvement can occur. The treatment of choice in those aged over 8 years and non-pregnant females is a 2–3-week course of doxycycline.

Bilateral facial weakness can occur with Lyme disease, myasthenia gravis, sarcoidosis and bilateral Bell's palsy.

Rate this question:

A 20-year-old man presents complaining of diarrhoea for the past 2 days. It is watery and he has opened his bowels three times already today. He feels concerned as he thinks there was a small amount of blood mixed in with the stool on the most recent occasion. He does not feel too unwell and has been drinking plenty of fluids.

He has not eaten anything unusual or been travelling abroad in the last 6 months. He had an infected boil on his back, for which he received flucloxicillin 2 weeks ago. No one else in the household feels unwell.

He has no past medical history and takes no medications. BP is 105/80 mmHg with a postural drop of 20 mmHg on standing.

What would be the most appropriate next management step?

Calculator

Normal Values

Annotation Stop Share

A	Oral antibiotics
B	IV antibiotics
C	Loperamide
D	Sigmoidoscopy
E	Oral rehydration salts

NICE suggest that acute diarrhoea should be assessed for cause and the severity of dehydration should be established. The Table below is based on NICE guidelines to help divide the different features.

Mild dehydration	Moderate dehydration	Severe dehydration
Lassitude	Apathy/tiredness	Profound apathy
Anorexia/nausea	Dizziness	Weakness
Light-headedness	Muscle cramps	Confusion
Postural hypotension	Pinched face	Shock
	Dry tongue or sunken eyes	Tachycarida
	Reduced skin elasticity	Peripheral vasoconstriction
	Postural hypotension	Hypotension
	Tachycardia	Oliguria or anuria
	Oliguria	

As his only feature dehydration is postural hypotension he can be managed for mild dehydration with oral rehydration.

A Oral antibiotics

According to guidance, antibiotics should be reserved for when a patient has a positive stool culture or is extremely unwell. This patient is very stable. He has noticed a small amount of blood on passing stool so it is definitely worth sending a stool culture. His short course of flucloxicillin is very unlikely to have precipitated Clostridium difficile infection in an otherwise healthy young man.

B IV antibiotics

As with the previous option there is no indication to treat with antibiotics, IV or oral, unless there is a specific pathogen identified or there is evidence of severe infection. This patient is well and no samples suggesting infection have yet been returned.

C Loperamide

Whilst infection has not been proven, it is suspected, especially as there is an element of PR bleeding. Loperamide should be avoided if infective diarrhoea is suspected.

D Sigmoidoscopy

Endoscopic examination would be necessary if inflammatory bowel disease was suspected to be the underlying cause. There is not very much in the history or examination to support such a suspicion: absence of fever, chronic

594-042-7551

Leave

or oral, unless there is a specific pathogen identified or there is evidence of severe infection. This patient is well and no samples suggesting infection have yet been returned.

C Loperamide

Whilst infection has not been proven, it is suspected, especially as there is an element of PR bleeding. Loperamide should be avoided if infective diarrhoea is suspected.

D Sigmoidoscopy

Endoscopic examination would be necessary if inflammatory bowel disease was suspected to be the underlying cause. There is not very much in the history or examination to support such a suspicion; absence of fever, chronic history, abdominal pain and systemic features. Should such features develop or his diarrhoea not settle then this could be a reasonable choice.

Rate this question:

Next Question

Audio Video Share Participants More

Calculator

Normal Values

A 26-year-old man presented with a 1-week history of headache and 2-day history of confusion. Three days ago, he had returned from a 6-month trip to rural Kenya.

On examination, his temperature was 39 °C, blood pressure 125/85 mmHg and pulse 88 bpm. Saturation on air was normal. Physical examination of all systems was unremarkable except for bilateral upgoing plantars.

Investigations:

Hb	100 g/dl (130–180)
WCC	9×10^9/l (4.0–11.0)
Neutrophils	3.1×10^9/l (1.5–4.0)
PLT	110×10^9/l (150–400)
Glucose	4.0 mmol/l
Thick and thin blood film	No malarial parasites in one sample
CXR	Normal
CT head	Normal
CSF	WCC 3/µl Protein 0.5 g/dl (0.15–0.45) Glucose 3.8 mmol/l (3.3–4.4)

Which drug is most appropriate in his immediate management?

Rana Alnasser's screen

Thick and thin blood film	No malarial parasites in one sample
CXR	Normal
CT head	Normal
CSF	WCC 3/µl Protein 0.5 g/dl (0.15–0.45) Glucose 3.8 mmol/l (3.3–4.4)

Which drug is most appropriate in his immediate management?

A Intravenous aciclovir

B Intravenous cefotaxime

C Intravenous methylprednisolone

D Intravenous quinine

E Oral antiretroviral therapy

Submit

D Intravenous quinine

This patient's travel history, anaemia, mild thrombocytopenia and hypoglycaemia, and their symptoms, fit with malaria. Typically, three films are required to rule out malaria, this patient had just one negative film. Intravenous quinine or artesunate would be the most appropriate treatment.

A Intravenous aciclovir

Intravenous aciclovir is used in the treatment of herpes simplex encephalitis. Although this patient could have herpes simplex encephalitis, it is not the most likely diagnosis in this case. The travel history, combined with anaemia, mild thrombocytopenia and mild hypoglycaemia, is suggestive of malaria, which is the most likely diagnosis here. If there is a strong clinical suspicion of malaria, blood films should be repeated; three or more negative blood films are needed to completely rule out malaria. Therefore the most appropriate treatment is intravenous quinine, to treat malaria.

B Intravenous cefotaxime

Intravenous cefotaxime would be an appropriate treatment for bacterial meningitis; however, this patient does not have any signs of meningism. Given his travel history, anaemia, mild hypoglycaemia and mild thrombocytopenia, malaria would be a much more likely explanation. Films can be false negatives, and three or more negative films are required to rule out a diagnosis of malaria. To treat malaria, intravenous quinine would be the most appropriate option.

C Intravenous methylprednisolone

There is debate over the use of steroids in bacterial meningitis, and even in malaria. Steroids would certainly not be the one most appropriate medication in this case. Although steroids can be useful in reducing cerebral oedema, their administration can also suppress host immune response and therefore risk overwhelming sepsis. In this case, the most likely diagnosis is malaria, given the patient's travel history, mild anaemia, thrombocytopenia and mild hypoglycaemia. Blood films can be negative, and three or more negative films would be required before a diagnosis of malaria could be excluded. The most appropriate treatment would therefore be intravenous quinine.

E Oral antiretroviral therapy

Oral antiretroviral therapy would be a treatment for HIV; this patient does not have a history, examination or investigations consistent with HIV. The most likely diagnosis in this case is malaria; it fits with his travel history, and would explain his anaemia, mild thrombocytopenia and hypoglycaemia.

Rate this question:

Next Question

A 22-year-old man presented with a 4-week history of offensive-smelling, pale diarrhoea and abdominal cramps. He reported opening his bowels up to four times a day. He had returned from travelling in South America, New Zealand and Nepal 2 weeks previously. He had been mostly well during his trip, apart from two episodes of diarrhoea or vomiting which had self-resolved.

On examination, he is afebrile. Abdominal examination reveals mild tenderness. Rectal examination reveals soft brown stool and no masses.

He was given a single dose of 2 g of tinidazole empirically. Two weeks later, he presented with ongoing diarrhoea and was referred for further investigation.

Investigations:

		Normal values
Haemoglobin (Hb)	118 g/l	130–180
Mean corpuscular volume (MCV)	78 fl	80–96
White cell count (WCC)	8.7×10^9/l	4.0–11.0
Neutrophil count	5.1×10^9/l	1.5–7.0
Lymphocyte count	3.5×10^9/l	1.5–4.0

Calculator

Normal Values

Rana Alnasser's screen

Lymphocyte count	3.5 × 10^9/l	1.5–4.0
Eosinophil count	0.3 × 10^9/l	0.04–0.4
Basophil count	0.08 × 10^9/l	< 0.1
Platelets (PLT)	390 × 10^9/l	150–400
Alanine aminotransferase (ALT)	25 u/l	
Bilirubin	14 μmol/l	
Albumin	32 g/l	
Alkaline phosphatase	54 u/l	
Stool culture	No growth	
Stool microscopy	No trophozoites, no ova or parasites seen	
Endoscopy	Duodenal villous atrophy; normal colonoscopy	

What is the most likely diagnosis?

A Coeliac disease

B *Cryptosporidium*

Stool microscopy	No trophozoites, no ova or parasites seen	
Endoscopy	Duodenal villous atrophy; normal colonoscopy	

What is the most likely diagnosis?

A Coeliac disease

B *Cryptosporidium*

C Giardiasis

D Inflammatory bowel disease

E Strongyloidiasis

Submit

Audio
Video
Share
Participants
More
End

Explanation

A Coeliac disease

This patient has iron deficiency anaemia, ongoing steatorrhoea and villous atrophy on endoscopy. This could be tropical sprue, which is not provided as an option in this list, or coeliac disease.

C Giardiasis

Giardiasis is an extremely common cause of diarrhoea and/or vomiting in the returning traveller, typically causing bloating and steatorrhoea. Although this patient has steatorrhoea, he also has an iron deficiency anaemia and villous atrophy, which cannot be explained by *Giardia lamblia*. In addition, he has been treated with tinidazole, which would usually be sufficient to successfully treat giardiasis.

B *Cryptosporidium*

Cryptosporidium is a cause of prolonged non-bloody diarrhoea in the returning traveller; however, it does not cause villous atrophy or iron deficiency anaemia. The most likely diagnosis in this patient is tropical sprue or coeliac disease.

D Inflammatory bowel disease

likely diagnosis in this patient is tropical sprue or coeliac disease.

D Inflammatory bowel disease

You would expect him to have bloody diarrhoea, not steatorrhoea (which is indicative of a small, not a large, bowel problem), and you might expect typical findings of either ulcerative colitis or Crohn's disease on endoscopy. Villous atrophy is not typical of inflammatory bowel disease; this, combined with iron deficiency anaemia and steatorrhoea, is suggestive of tropical sprue or coeliac disease.

E Strongyloidiasis

Strongyloides is a parasitic roundworm. It would be very unusual to have strongyloidiasis without eosinophilia; furthermore, you might expect larvae to be seen in the stool (though often serial analysis is required). This patient has iron deficiency anaemia and villous atrophy on his endoscopy; the most likely diagnoses are tropical sprue or coeliac disease.

Rate this question:

© Pastest 2019

10:11

A 32-year-old woman presented with a 2-week history of fever and a sore throat. She had returned from Kenya 5 weeks previously. While in Kenya she swam in freshwater lakes and had had a number of mosquito bites on her legs after a week trekking in the jungle. She admits to unprotected sexual intercourse with a family friend during her trip.

On examination, she had a temperature of 37.7 °C. There was evidence of pharyngitis and a diffuse erythematous rash on the trunk. There was widespread lymphadenopathy.

Investigations:

Hb	13.0 g/dl (11.5–16.5)
WCC	4.3×10^9/l (4.0–11.0)
Neutrophils	3.2×10^9/l (1.5–7.0)
Lymphocytes	1.1×10^9/l (1.5–4.0)
PLT	200×10^9/l (150–400)
Thin blood film	No malarial parasites
Blood cultures	Negative after 48 h in two samples
Throat swab culture	No growth

What is the most likely diagnosis?

A Dengue fever

B Falciparum malaria

C HIV infection

Rana Alnasser's screen

weeks previously. While in Kenya she swam in freshwater lakes and had had a number of mosquito bites on her legs after a week trekking in the jungle. She admits to unprotected sexual intercourse with a family friend during her trip.

On examination, she had a temperature of 37.7 °C. There was evidence of pharyngitis and a diffuse erythematous rash on the trunk. There was widespread lymphadenopathy.

Investigations:

Hb	13.0 g/dl (11.5–16.5)
WCC	4.3×10^9/l (4.0–11.0)
Neutrophils	3.2×10^9/l (1.5–7.0)
Lymphocytes	1.1×10^9/l (1.5–4.0)
PLT	200×10^9/l (150–400)
Thin blood film	No malarial parasites
Blood cultures	Negative after 48 h in two samples
Throat swab culture	No growth

What is the most likely diagnosis?

A Dengue fever

B Falciparum malaria

C HIV infection

D Schistosomiasis

E *Toxoplasma gondii*

C HIV infection

This patient has returned from an endemic area and just over a month later, has developed widespread lymphadenopathy, pharyngitis and a rash. This is typical of HIV seroconversion. This incubation period can be from 2–3 weeks to 3 months.

A Dengue fever

Typically dengue presents with a headache, myalgia and fever, and sometimes haemorrhagic manifestations (such as petechial rashes). It would be very unusual for dengue to cause a prolonged fever presenting more than 2 weeks after a patient's return from an endemic area. A more likely explanation for this patient's widespread lymphadenopathy, rash and pharyngitis is HIV seroconversion.

B Falciparum malaria

Although malaria is an important differential for fever in the returning traveller, this patient has had two negative films for malaria. Malaria is unlikely to explain the patient's rash or widespread lymphadenopathy; a much more likely explanation is HIV seroconversion.

D Schistosomiasis

Although the patient has been exposed to fresh water, and schistosomiasis

Rana Alnasser's screen

D Schistosomiasis

Although the patient has been exposed to fresh water, and schistosomiasis could explain a rash, it does not explain the pharyngitis or widespread lymphadenopathy. This patient has a clinical presentation consistent with HIV seroconversion.

E *Toxoplasma gondii*

Although toxoplasmosis could explain this patient's lymphadenopathy and pharyngitis, dermatological manifestations of toxoplasmosis are extremely rare. A much more likely explanation is HIV seroconversion, which could explain the pharyngitis, rash, and lymphadenopathy.

Rate this question:

Next Question

Rana Alnasser's screen

End

Rana Alnasser's screen

83% 20:15

Pastes+ Question 8 of 191 LOG OUT

Calculator

Normal Values

A 19-year-old student is brought to the Emergency Department by ambulance after his flat-mates called 999. They had been back at university for approximately 10 days since the summer break. He complained initially of flu like symptoms, but over the past 24 h has taken to his bed complaining of a severe headache and neck stiffness. He is now drowsy and confused.

On examination, he is pyrexial (38.9 °C), his BP is 95/50 mmHg and pulse is 95/min and regular. He has cold peripheries and a purpuric rash which appears to be extending even as you examine him. By the time you finish examining him he is unresponsive to commands. The paramedics have started a normal saline IV which is running through stat. An intubation tray is prepared.

Which of the following is the most important next step?

A	Further IV fluid loading
B	IV hydrocortisone
C	IV ceftriaxone
D	IV FFP
E	IV benzylpenicillin

Annotation Stop Share

Calculator

Normal Values

A 19-year-old student is brought to the Emergency Department by ambulance after his flat-mates called 999. They had been back at university for approximately 10 days since the summer break. He complained initially of flu like symptoms, but over the past 24 h has taken to his bed complaining of a severe headache and neck stiffness. He is now drowsy and confused.

On examination, he is pyrexial (38.9 °C), his BP is 95/50 mmHg and pulse is 95/min and regular. He has cold peripheries and a purpuric rash which appears to be extending even as you examine him. By the time you finish examining him he is unresponsive to commands. The paramedics have started a normal saline IV which is running through stat. An intubation tray is prepared.

Which of the following is the most important next step?

A	Further IV fluid loading
B	IV hydrocortisone
C	IV ceftriaxone
D	IV FFP
E	IV benzylpenicillin

C IV ceftriaxone

Early antibiotic therapy is crucial with respect to successful management of meningococcal meningitis. As such, IV ceftriaxone is the most important next step. Ceftriaxone covers meningococci, pneumococci, *H. influenzae* type B and streptococci, and is therefore a very prudent empirical choice. In the community, IM or IV benzylpenicillin should be given.

A Further IV fluid loading

Although this patient may require further circulatory support / fluid loading, at this stage time to antibiotics is the most important factor in his survival.

B IV hydrocortisone

IV steroids may reduce neurological sequelae, and as such are an important addition to therapy, although not initially.

D IV FFP

DIC is a potential complication that can be noted on the coagulation screen, but treating the underlying cause is more appropriate.

E IV benzylpenicillin

Calculator

Normal Values

A 29-year-old woman is referred by her general practitioner (GP) to the medical on-call team. She gives a 3-day history of frontal headaches and backache. She was seen 2 days previously and given a course of amoxicillin for a presumed chest infection. She is now complaining of anorexia and has vomited twice.

In her past medical history, she has had a right cerebello-pontine angle tumour removed a year ago. Six months ago, a ventriculoperitoneal shunt was inserted for hydrocephalus.

On examination, her temperature is 38 °C. Fundoscopy is normal. Pupils are reactive and equal to light. There is a right lower motor neurone VII nerve palsy. Kernig's sign is positive. She does not complain of photophobia or neck stiffness. The rest of the physical examination is unremarkable.

Which investigation is the most useful next step?

A	Magnetic resonance image (MRI) of the brain
B	Computerised tomography (CT) of the brain
C	Blood cultures
D	Chest X-ray
E	Erythrocyte sedimentation rate (ESR) and C-reactive protein level

Rana Alnasser's screen

A 29-year-old woman is referred by her general practitioner (GP) to the medical on-call team. She gives a 3-day history of frontal headaches and backache. She was seen 2 days previously and given a course of amoxicillin for a presumed chest infection. She is now complaining of anorexia and has vomited twice.

In her past medical history, she has had a right cerebello-pontine angle tumour removed a year ago. Six months ago, a ventriculoperitoneal shunt was inserted for hydrocephalus.

On examination, her temperature is 38 °C. Fundoscopy is normal. Pupils are reactive and equal to light. There is a right lower motor neurone VII nerve palsy. Kernig's sign is positive. She does not complain of photophobia or neck stiffness. The rest of the physical examination is unremarkable.

Which investigation is the most useful next step?

Your answer was incorrect

A Magnetic resonance image (MRI) of the brain

B Computerised tomography (CT) of the brain

Difficulty: Average

Peer Responses %

Session Progress

Responses Correct:	7
Responses Incorrect:	2
Responses Total:	9
Responses - % Correct:	78%

Explanation

A Magnetic resonance image (MRI) of the brain

In a patient who has had a neurological procedure and has a ventriculo-peritoneal shunt in situ, the diagnosis of bacterial meningitis is the most likely possibility. Obstruction of the shunt also needs to be excluded by magnetic resonance imaging (MRI) scan. The histology of the original tumour is unknown and recurrence of tumour with malignant meningitis is also a differential to be considered. As the patient has had antibiotics for a few days, the likely diagnosis is partially treated meningitis. Cerebrospinal fluid (CSF) Gram stain is therefore unlikely to reveal any organisms; even so a lumbar puncture is the next logical step after imaging.

Ultimate eradication of the infection would involve removal and replacement of the shunt

B Computerised tomography (CT) of the brain

CT brain scan might show hydrocephalus but provides much poorer views of the posterior fossa than MRI, making MRI the clear preference in this case

C Blood cultures

Whilst cultures should be taken as the patient is febrile, it is less likely to provide useful information especially since the patient has already been taking antibiotics, lowering the yield further.

the posterior fossa than MRI, making MRI the clear preference in this case

C Blood cultures

Whilst cultures should be taken as the patient is febrile, it is less likely to provide useful information especially since the patient has already been taking antibiotics, lowering the yield further.

D Chest X-ray

Whilst a chest X-ray should be done, it is not the most important investigation as the source of infection is unlikely to be from her lungs. The patient has no respiratory symptoms or signs but does have evidence of focal neurology indicating an infection of the central nervous system.

E Erythrocyte sedimentation rate (ESR) and C-reactive protein level

Testing for the above inflammatory markers is unlikely to help in early stages as they are very non-specific. However, inflammatory markers should be requested to help monitor response to antibiotic treatment.

Rate this question:

Next Question

Calculator

Normal Values

A 49-year-old man is seen in the Emergency Department with a two-week history of general malaise, anorexia and fever. He has lost 6 kg in weight. He had a sore throat a week before and his general practitioner (GP) had told him that it was a viral infection.

On examination, he has a temperature of 37.6 °C and three splinter haemorrhages on his right index finger. On cardiac auscultation he has a pansystolic murmur, loudest at the apex and radiating to the axilla.

Blood cultures are taken from three peripheral sites and the patient is started on intravenous benzylpenicillin and gentamicin.

Transthoracic echocardiogram demonstrates a 0.3 × 0.7 cm vegetation attached to the posterior surface of the mitral valve.

The cultures are all negative for growth at 5 days and at day 10 the patient still has a fever. You decide to speak to the cardiac surgeon.

Which of the following is a definite indication for surgical intervention?

A	Persistent unexplained fever for 5 days in culture-negative prosthetic valve endocarditis
B	Persistent fever for 10 days if the valve was a native one
C	Murantic endocarditis
D	Development of mild heart failure as a result of valve dysfunction

Rana Alnasser's screen

Blood cultures are taken from three peripheral sites and the patient is started on intravenous benzylpenicillin and gentamicin.

Transthoracic echocardiogram demonstrates a 0.3 × 0.7 cm vegetation attached to the posterior surface of the mitral valve.

The cultures are all negative for growth at 5 days and at day 10 the patient still has a fever. You decide to speak to the cardiac surgeon.

Which of the following is a definite indication for surgical intervention?

A	Persistent unexplained fever for 5 days in culture-negative prosthetic valve endocarditis
B	Persistent fever for 10 days if the valve was a native one
C	Murantic endocarditis
D	Development of mild heart failure as a result of valve dysfunction
E	*Staphylococcus aureus* infection in a prosthetic valve

33190

Submit

E *Staphylococcus aureus* infection in a prosthetic valve

Infectious endocarditis results from microbial infection of the endothelial surface of the heart. Blood cultures are positive in >95% of cases of infectious endocarditis. Three sets of cultures should be taken with 10 ml of blood in each bottle. These should be incubated for up to three weeks to grow fastidious organisms. Transthoracic echocardiogram (TTE) is specific in 91–98% of cases at detecting vegetations, but the sensitivity is only 45–60%. Suboptimal views are seen with prosthetic valves and transoesophageal echocardiography should be undertaken if vegetations are not seen on TTE.
There are several indications where cardiac surgery is or may be indicated for optimal outcome:

- Development of moderate to severe heart failure as a result of valve dysfunction
- Partial dehiscence of a prosthetic valve
- Persistent bacteraemia despite optimal antibiotics
- *aureus* prosthetic valve endocarditis
- Fungal infectious endocarditis
- Persistent fever for 10 days in culture-negative prosthetic valve endocarditis with no other explanation for fever
- Absence of effective antibiotics
- Relapse of endocarditis after optimal antibiotics in a prosthetic valve.

Indications where surgery may be required for optimal outcome in order of

- Development of moderate to severe heart failure as a result of valve dysfunction
- Partial dehiscence of a prosthetic valve
- Persistent bacteraemia despite optimal antibiotics
- *aureus* prosthetic valve endocarditis
- Fungal infectious endocarditis
- Persistent fever for 10 days in culture-negative prosthetic valve endocarditis with no other explanation for fever
- Absence of effective antibiotics
- Relapse of endocarditis after optimal antibiotics in a prosthetic valve.

Indications where surgery may be required for optimal outcome in order of strength of recommendation include:

- Perivalvular extension of infection (myocardial. annular, septal abscess or intracardiac fistula)
- Poorly responsive *aureus* endocarditis involving the aortic/mitral valve
- Infectious endocarditis caused by highly resistant organisms
- Persistent fever for 10 days in culture-negative native-valve endocarditis with no other explanation
- Relapse of native-valve endocarditis after optimal antibiotics
- Large (>1 cm diameter) hypermobile vegetations.

D Development of mild heart failure as a result of valve dysfunction

(TTE) is specific in 91-98% of cases at detecting vegetations, but the sensitivity is only 45–60%. Suboptimal views are seen with prosthetic valves and transoesophageal echocardiography should be undertaken if vegetations are not seen on TTE.
There are several indications where cardiac surgery is or may be indicated for optimal outcome:

- Development of moderate to severe heart failure as a result of valve dysfunction
- Partial dehiscence of a prosthetic valve
- Persistent bacteraemia despite optimal antibiotics
- *aureus* prosthetic valve endocarditis
- Fungal infectious endocarditis
- Persistent fever for 10 days in culture-negative prosthetic valve endocarditis with no other explanation for fever
- Absence of effective antibiotics
- Relapse of endocarditis after optimal antibiotics in a prosthetic valve.

Indications where surgery may be required for optimal outcome in order of strength of recommendation include:

- Perivalvular extension of infection (myocardial. annular, septal abscess or intracardiac fistula)
- Poorly responsive *aureus* endocarditis involving the aortic/mitral valve
- Infectious endocarditis caused by highly resistant organisms
- Persistent fever for 10 days in culture-negative native-valve endocarditis with no other explanation
- Relapse of native-valve endocarditis after optimal antibiotics
- Large (>1 cm diameter) hypermobile vegetations.

Rana Alnasser's screen

10:33
820-068-1014
End

A 32-year-old man presented with extensive burns over the forearms after attending a blaze as part of his work as a firefighter. Three days later the burns on his forearms deteriorated.

On examination, his temperature was 38.1 °C. The burns had developed a violaceous/black discolouration, bullae and sweet-smelling green pus.

Wound culture and microscopy revealed Gram-positive rods. The wounds were surgically debrided.

What is the most appropriate antibiotic therapy?

A	Benzylpenicillin
B	Chloramphenicol
C	Flucloxacillin
D	Gentamicin
E	Vancomycin

Submit

Previous Q... Skip Questi...

© Pastest 2019
Audio Video Share Participants More

10:37

C Flucloxacillin

D Gentamicin

E Vancomycin

Explanation

A Benzylpenicillin

This patient has signs consistent with gas gangrene, which is caused by *Clostridium perfringens*. This is further supported by microscopy, as *Cl. perfringens* is a Gram-positive rod. Benzylpenicillin has good activity against *Cl. perfringens*, and may be used alone or in combination with clindamycin.

B Chloramphenicol

The sweet-smelling pus and multiple bullae seen in this patient are suggestive of superinfection with *Clostridium perfringens*, which causes gas gangrene. *Cl. perfringens* is a Gram-positive rod, as seen on microscopy here. Chloramphenicol covers some Gram-positive rods, including *Bacillus anthracis* (anthrax) and *Listeria monocytogenes*, but it does not give adequate coverage of *Cl. perfringens* to treat this infection. A better choice would be benzylpenicillin, which is either used alone or in combination with clindamycin.

C Flucloxacillin

Flucloxacillin is a good empirical choice for the treatment of cellulitis as it gives excellent coverage of *Staphylococcus*, a common cause of cellulitis and wound super-infection. However, microscopy has revealed Gram-positive rods in this patient (*Staphylococcus* would appear

Rana Alnasser's screen

10:38

MyPastest
https://mypastest.pastest.com

A 32-year-old man presented with extensive burns over the forearms after attending a blaze as part of his work as a firefighter. Three days later the burns on his forearms deteriorated.

On examination, his temperature was 38.1 °C. The burns had developed a violaceous/black discolouration, bullae and sweet-smelling green pus.

Wound culture and microscopy revealed Gram-positive rods. The wounds were surgically debrided.

What is the most appropriate antibiotic therapy?

Your answer was incorrect

A	Benzylpenicillin
B	Chloramphenicol
C	Flucloxacillin
D	Gentamicin
E	Vancomycin

Explanation

A	Benzylpenicillin

This patient has signs consistent with gas gangrene, which is caused by *Clostridium perfringens*. This is further

Rana Alnasser's screen

Staphylococcus, a common cause of cellulitis and wound super-infection. However, microscopy has revealed Gram-positive rods in this patient (*Staphylococcus* would appear as Gram-positive cocci). This, combined with the sweet-smelling pus and multiple bullae, is suggestive of gas gangrene, caused by *Clostridium perfringens*. This organism is not covered by flucloxacillin. A more appropriate antibiotic would be benzylpenicillin, which is either used alone or with clindamycin.

D Gentamicin

Gentamicin provides excellent cover for Gram-negative organisms, and can work synergistically to treat some Gram-positive infections. This patient has an infection with a Gram-positive rod: combined with his presentation (sweet-smelling pus, multiple bullae), this is suggestive of gas gangrene caused by *Clostridium perfringens*. Gentamicin would not cover *Cl. perfringens*. A better choice would be benzylpenicillin, either alone or in combination with clindamycin.

E Vancomycin

Vancomycin gives excellent coverage of Gram-positive cocci and some Gram-negative cocci. It is often used in addition to other antibiotics in the treatment of resistant Gram-positive cocci – for example, methicillin-resistant *Staphylococcus aureus*. This patient, however, has a super-infection with Gram-positive rods. Having presented with sweet-smelling pus and multiple bullae, this is consistent with gas gangrene, caused by *Clostridium perfringens*. Vancomycin is not bactericidal for *Cl. perfringens*, and therefore would not be an appropriate choice here. A better choice would be benzylpenicillin, which can be used alone or with clindamycin.

Rate this question:

Rana Alnasser's screen

10:39

A 41-year-old Ugandan woman is seen in the HIV Clinic. She has a CD4 count of 140 × 10^6/L and was started on prophylactic co-trimoxazole 2 weeks previously. Unfortunately, this resulted in a severe rash and deranged liver function tests and was discontinued.

She has glucose-6-phosphate dehydrogenase (G6PD) deficiency and is a type 2 diabetic. Her only current medication is metformin 500 mg bd.

What is the most appropriate Pneumocystis jirovecii pneumonia (PCP) prophylaxis?

A	Co-trimoxazole nebuliser
B	Oral dapsone
C	Oral pentamidine
D	Oral clindamycin
E	Pentamidine nebuliser

7645

Submit

Previous Q... Skip Questi...

Rana Alnasser's screen

D Oral clindamycin

E Pentamidine nebuliser

Explanation

E Pentamidine nebuliser

This is a patient with a low CD4 count. If a patient has a CD4 count below 200 × 10^6/l then they should be offered prophylaxis against PCP. First-line treatment is oral co-trimoxazole. If this cannot be tolerated then the second-line treatment is oral dapsone. However, this is inappropriate in a patient with G6PD deficiency. Third-line prophylaxis is with nebulsed pentamidine.

A Co-trimoxazole nebuliser

The drug cannot be administered by nebuliser.

B Oral dapsone

It can cause haemolysis in patients with G6PD deficiency. Other drugs that have a definite risk include primaquine, methylthioninium chloride, nitrofurantoin, quinolones (including ciprofloxacin, moxifloxacin, nalidixic acid, norfloxacin and ofloxacin) and sulfonamides.

C Oral pentamidine

Pentamidine is only effective in nebulised form.

D Oral clindamycin

Clindamycin can be used in the treatment of *Pneumocystis jirovecii* pneumonia (PCP) but not the prophylaxis

A Co-trimoxazole nebuliser

The drug cannot be administered by nebuliser.

B Oral dapsone

It can cause haemolysis in patients with G6PD deficiency. Other drugs that have a definite risk include primaquine, methylthioninium chloride, nitrofurantoin, quinolones (including ciprofloxacin, moxifloxacin, nalidixic acid, norfloxacin and ofloxacin) and sulfonamides.

C Oral pentamidine

Pentamidine is only effective in nebulised form.

D Oral clindamycin

Clindamycin can be used in the treatment of *Pneumocystis jirovecii* pneumonia (PCP) but not the prophylaxis.

Rate this question:

© Pastest 2019

A 32-year-old man, who spent 3 months on a school building project in Nepal, visits the clinic for review. He suffered a severe episode of diarrhoea with associated blood while in the country, and now complains of intermittent sweats and pain in his right lower chest.

On examination, his temperature is 37.7 °C, and he has hepatic tenderness.

Investigations:

Hb	10.2 g/dl
WCC	11.1×10^9/l
PLT	145×10^9/l
Na^+	142 mmol/l
K^+	4.9 mmol/l
Creatinine	130 µmol/l
Bilirubin	45 µmol/l
ALT	72 U/l
ALP	342 U/l
CT thorax & upper abdomen	Single homogenous abscess in the right liver lobe, measuring 5 cm in diameter

You ask for an opinion from an interventional radiologist.

Which of the following is the most appropriate initial medical treatment for him?

A Metronidazole

B Doxycycline

WCC	11.1×10^9/l
PLT	145×10^9/l
Na^+	142 mmol/l
K^+	4.9 mmol/l
Creatinine	130 µmol/l
Bilirubin	45 µmol/l
ALT	72 U/l
ALP	342 U/l
CT thorax & upper abdomen	Single homogenous abscess in the right liver lobe, measuring 5 cm in diameter

You ask for an opinion from an interventional radiologist.

Which of the following is the most appropriate initial medical treatment for him?

A Metronidazole

B Doxycycline

C Chloroquine

D Cefotaxime

E Quinine

Submit

WCC	11.1×10^9/l
PLT	145×10^9/l
Na^+	142 mmol/l
K^+	4.9 mmol/l
Creatinine	130 µmol/l
Bilirubin	45 µmol/l
ALT	72 U/l
ALP	342 U/l
CT thorax & upper abdomen	Single homogenous abscess in the right liver lobe, measuring 5 cm in diameter

You ask for an opinion from an interventional radiologist.

Which of the following is the most appropriate initial medical treatment for him?

Your answer was correct

A Metronidazole

B Doxycycline

C Chloroquine

D Cefotaxime

E Quinine

Explanation

C Chloroquine

Chloroquine is an antimalarial drug used in the treatment of non-falciparum malaria. Its use in malaria prophylaxis and the treatment of falciparum malaria has ceased due to widespread resistance. Chloroquine can be used second line to treat amoebic liver abscess (as suggested in this case), but there is a better option.

D Cefotaxime

Cefotaxime is a third-generation cephalosporin with a broad spectrum of activity against both Gram-positive and -negative bacteria. The history and findings in this case are more suggestive of an amoebic liver abscess than a pyogenic abscess. In practice it would be appropriate to cover for both pyogenic infection and amoeba until the diagnosis is serologically confirmed.

E Quinine

Quinine is an antimalarial drug used in the treatment of falciparum malaria, though its use has been superseded by artesunate/artermisinine combination therapy where available. It is not a treatment for amoebic infection.

A 23-year-old woman presented with a 3-day history of painful genital ulceration. The pain was worse on passing urine. She also complained of flu-like symptoms with myalgia and mild fever.

On examination, there were multiple small, white painful ulcers all over the genitals. She had tender lymphadenopathy in the inguinal region.

A swab was taken of the ulcers.

What is the most appropriate next step whilst the results are pending?

A	Give 7 days of treatment-dose aciclovir; no further investigations required
B	Take blood for herpes simplex-1 antibodies
C	Take blood for herpes simplex-2 antibodies
D	Take blood for herpes simplex-1 antibodies and give 7 days of treatment-dose acyclovir
E	Take blood for herpes simplex-2 antibodies and give 7 days of treatment-dose aciclovir

71048

Submit

A 23-year-old woman presented with a 3-day history of painful genital ulceration. The pain was worse on passing urine. She also complained of flu-like symptoms with myalgia and mild fever.

On examination, there were multiple small, white painful ulcers all over the genitals. She had tender lymphadenopathy in the inguinal region.

A swab was taken of the ulcers.

What is the most appropriate next step whilst the results are pending?

Your answer was correct

A	Give 7 days of treatment-dose aciclovir; no further investigations required
B	Take blood for herpes simplex-1 antibodies
C	Take blood for herpes simplex-2 antibodies
D	Take blood for herpes simplex-1 antibodies and give 7 days of treatment-dose acyclovir
E	Take blood for herpes simplex-2 antibodies and give 7 days of treatment-dose aciclovir

Explanation

A	Give 7 days of treatment-dose aciclovir; no further investigations required

give 7 days of treatment-dose acyclovir

E Take blood for herpes simplex-2 antibodies and give 7 days of treatment-dose aciclovir

Explanation

A Give 7 days of treatment-dose aciclovir; no further investigations required

This patient has a history and examination consistent with primary genital herpes infection; as such, she should be treated with aciclovir whilst results of swabs to confirm the diagnosis are pending. No blood tests are necessary for the diagnosis: PCR on the viral swabs is sufficient. Treatment is thought to be most effective if initiated in the first 72 hours as complication rates and disease length are both reduced.

B Take blood for herpes simplex-1 antibodies

This patient has a history and examination consistent with genital herpes, and should be treated for it whilst confirmation is awaited from PCR on the ulcer swabs. Furthermore, it is herpes simplex-2 that is the most common cause of genital ulceration: herpes simplex-1 typically causes oral ulceration (cold sores). Serology is unhelpful in the diagnosis of herpes virus infections. The correct action would be to give this patient 7 days of treatment-dose aciclovir, and there is no need for further investigation whilst the results of swabs are awaited.

C Take blood for herpes simplex-2 antibodies

Serology is of very little value in herpes simplex-2 infections: it can take 12 weeks for it to become positive in primary infection, and has a low positive predictive value in low-prevalence populations. The correct course of action

diagnosis: PCR on the viral swabs is sufficient. Treatment is thought to be most effective if initiated in the first 72 hours as complication rates and disease length are both reduced.

B	Take blood for herpes simplex-1 antibodies

This patient has a history and examination consistent with genital herpes, and should be treated for it whilst confirmation is awaited from PCR on the ulcer swabs. Furthermore, it is herpes simplex-2 that is the most common cause of genital ulceration: herpes simplex-1 typically causes oral ulceration (cold sores). Serology is unhelpful in the diagnosis of herpes virus infections. The correct action would be to give this patient 7 days of treatment-dose aciclovir, and there is no need for further investigation whilst the results of swabs are awaited.

C	Take blood for herpes simplex-2 antibodies

Serology is of very little value in herpes simplex-2 infections: it can take 12 weeks for it to become positive in primary infection, and has a low positive predictive value in low-prevalence populations. The correct course of action would be to give this patient 7 days of treatment-dose aciclovir and await the results of PCR from the viral swabs that have already been taken; there is no need for any further tests.

D	Take blood for herpes simplex-1 antibodies and give 7 days of treatment-dose acyclovir

It is correct to treat this patient immediately with aciclovir as there is sufficient clinical evidence of genital herpes. However, the PCR from the viral ulcer swabs that have already been taken is sufficient to confirm the diagnosis. There is no need to undertake serological testing, and furthermore genital herpes is caused by herpes simplex-2, not 1. Serological testing has a poor positive predictive value.

10:49

A 32-year-old man presented with a 2-week history of severe, worsening headache, vomiting and double vision. He was HIV-positive and had refused antiretroviral treatment or prophylactic medications. He has a CD4 count of 120 × 106/l (normal range 300–1400).

On examination, his temperature was 37.5°C. There was a right-sided facial nerve palsy.

Investigations:

CD4 count	120 × 10^6/l (430–1690)
CT head	Two large ring-enhancing lesions, with midline shift

Based on the likeliest diagnosis, what treatment should be started?

A	Aciclovir
B	Amphotericin
C	Ceftazidime
D	Chemotherapy
E	Sulfadiazine and pyrimethamine, plus folinic acid

71052

Submit

Annotation Stop Share

D Chemotherapy

E Sulfadiazine and pyrimethamine, plus folinic acid

Explanation

E Sulfadiazine and pyrimethamine, plus folinic acid

This patient has untreated HIV and, as such, is extremely vulnerable to opportunistic infection. One such infection is toxoplasmosis, which can infect the CNS causing focal neurology due to mass lesions, visible on imaging as ring-enhancing lesions. Toxoplasmosis is a parasitic infection contracted from infected raw meat or from handling cat faeces or soil contaminated with cat faeces. First-line therapy is with sulfadiazine and pyrimethamine with folinic acid. The patient should also probably receive dexamethasone given the presence of midline shift.

A Aciclovir

This patient has untreated HIV and is severely immunocompromised. As a result he has contracted cerebral toxoplasmosis, as evidenced by the focal neurological signs and ring-enhancing lesions on CT head. An antiviral such as aciclovir will not treat cerebral toxoplasmosis, as this is caused by a parasite. The correct treatment is sulfadiazine and pyrimethamine with folinic acid.

B Amphotericin

This patient has untreated HIV, and consequently he is severely immunocompromised. This renders him vulnerable to opportunistic infection: in this case, he has contracted cerebral toxoplasmosis. This causes focal neurological signs

immunocompromised and vulnerable to opportunistic infection. In this case he has symptoms, signs and investigations consistent with cerebral toxoplasmosis: focal neurology with signs of raised intracranial pressure, and ring-enhancing lesions on brain imaging. As toxoplasmosis is caused by a parasite, antibiotics such as ceftazidime will not be an effective treatment. The correct therapy would be sulfadiazine and pyrimethamine with folinic acid.

D	Chemotherapy

This patient has untreated HIV; although HIV, and especially poorly controlled disease, is associated with malignancy (particularly with primary CNS lymphoma), the presentation and appearance of this patient's central nervous system lesions are not quite consistent with cerebral malignancy. The time course is quite rapid for metastases in the brain, and he does not have any other symptoms of primary malignancy elsewhere in the body. Ring-enhancing lesions would be an atypical appearance for primary CNS lymphoma. It is much more likely that this patient, in his immunocompromised state, has contracted cerebral toxoplasmosis. This should be treated with sulfadiazine and pyrimethamine with folinic acid.

Rate this question:

Next Question

Previous Q... Tag Questi... Feedback End Session

© Pastest

10:51

A 33-year-old Somalian woman with a 2-week history of confusion was brought to the Emergency Department by her husband. Over the preceding year, she had lost weight and had had intermittent fevers and night sweats and recurrent chest infections.

In the 3 months before her presentation, she became withdrawn and irritable, then unsteady on her feet, before becoming confused and requiring help with daily activities. She had lived in the United Kingdom for 6 months.

On examination, her temperature was 36.6 °C. There was widespread lymphadenopathy and mild hepatosplenomegaly. There was no neck stiffness or photophobia. She had dysarthria and an ataxic gait. There was left-sided hypertonia and mild weakness.

Investigations:

Blood glucose	7.8 mmol/l	Normal value 5.0–10.0
Cerebrospinal fluid (CSF)		**Normal values**
Appearance of CSF	Clear	
Opening pressure	18 mmH_2O	12–25
Glucose	4.1 mmol/l	3.3–4.4
Protein	0.7 g/l	0.15–0.45
White cell count (WCC)	4/µl	< 5

Computed tomography (CT) head with contrast	Multifocal hypodense non-enhancing periventricular lesions

Her chest X-ray is shown below:

Rana Alnasser's screen

10:54

By Mikael Häggström [CC0], from Wikimedia Commons

What is the most likely diagnosis?

A	Bacterial meningitis
B	Cryptococcal meningitis
C	Progressive multifocal leukoencephalopathy
D	Multiple sclerosis
E	Tuberculosis

2306

Submit

dissociated focal neurological signs, the CSF findings and the CT imaging (though patchy widespread lesions are more common). Personality change is sometimes seen but is a less common presenting feature of multiple sclerosis. However, multiple sclerosis could not explain her constitutional symptoms of weight loss, night sweats and fevers, or the lymphadenopathy and hepatosplenomegaly. Combined with her recent emigration from an area of high prevalence, it is more likely that these symptoms and signs are due to untreated HIV infection, and consequent PML.

E	Tuberculosis

Tuberculous meningitis can present with an insidious course of personality change, cranial nerve signs and confusion, as seen here. It is also far more common in first-generation immigrants from countries with a high tuberculosis rate, like Somalia. However, it would be very unusual for a patient to have a normal chest X-ray in the context of tuberculosis meningitis – you would expect to see apical abnormalities consistent with active or previous infection. If this were tuberculous meningitis, you would also expect the patient to have meningism, but there is no photophobia or neck stiffness here. Typically, a lumbar puncture in tuberculous meningitis reveals CSF with a spidery blood clot (here it is clear) and a low glucose level (normal in this case). Finally, CT imaging would show tuberculomas (which do enhance on CT imaging), whereas in this case there are multiple non-enhancing periventricular lesions, typical of PML.

2306

Rate this question:

10:59

MyPastest
https://mypastest.pastest.com

Pastest+

C Progressive multifocal leukoencephalopathy

This is a progressive demyelinating condition caused by the JC virus. It is very rare in immunocompetent individuals. However, this patient has a year's history of weight loss, fever and night sweats; combined with lymphadenopathy and recent emigration from an area of high prevalence, it is possible that she has human immunodeficiency virus (HIV). The indolent history of personality change, confusion and ataxia are typical for PML. The CSF is usually unremarkable, besides a raised protein level, as in this case. CT findings of hypodense periventricular lesions are typical. This patient's need for HIV treatment needs to be addressed rapidly, as, without it, the mean survival of a patient with PML due to untreated HIV is < 3 months.

A Bacterial meningitis

Bacterial meningitis would not present with such an indolent course of confusion and personality change and would not explain her constitutional symptoms. You would also expect fever, neck stiffness or photophobia, which are not present in this case. Lumbar puncture would show a high WCC (polymorphs) and low glucose level, but in this case, there is a normal WCC and glucose level in the CSF. The subacute course, personality changes, ataxia and CT findings here are typical of progressive multifocal leukoencephalopathy (PML).

B Cryptococcal meningitis

Cryptococcal meningitis would present acutely, not indolently as in this case. You would expect the patient to be febrile and have meningism (neck stiffness or photophobia). The CSF typically demonstrates a very low

11:03

A 29-year-old woman presented to clinic for follow-up. She had presented to hospital 6 weeks previously with a 5-day history of mild fever, increasing shortness of breath and right-sided pleuritic chest pain. She was treated with oral doxycycline and regular bronchodilators.

Since hospital, she had been well, but had noticed streaks of blood in her mucoid sputum. She had a history of mild asthma, and over the preceding 2 years she had had several asthma flares following upper respiratory tract infections.

Investigations:

Hb	12.9 g/dl (11.5–16.5)
WCC	14×10^9/l (4.0–11.0)
Neutrophils	8.0×10^9/l (1.5–4.0)
Eosinophils	0.6×10^9/l (0.04–0.4)
PLT	350 – 10^9/l (150–400)
ESR	35 mm/1st h
CRP	180 g/l (< 10)
CXR (at initial presentation)	Shadowing at left lower lobe

A chest X-ray was performed at clinic, and is shown below.

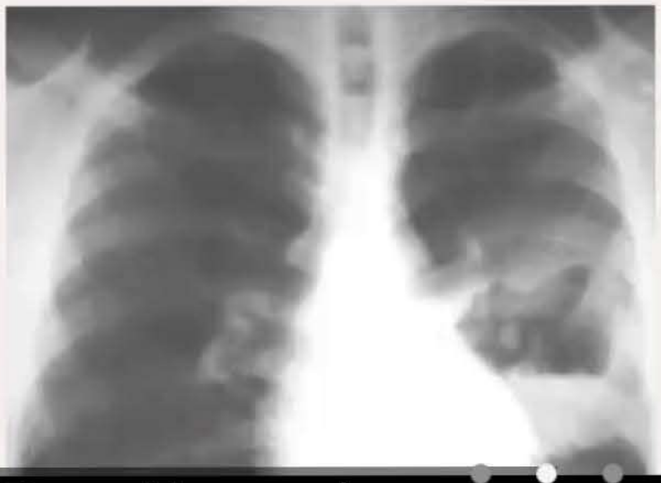

Rana Alnasser's screen

ESR	35 mm/1st h
CRP	180 g/l (< 10)
CXR (at initial presentation)	Shadowing at left lower lobe

A chest X-ray was performed at clinic, and is shown below.

What is the most likely diagnosis?

A	Allergic bronchopulmonary aspergillosis
B	Churg–Strauss syndrome
C	Cystic fibrosis
D	*Mycoplasma* pneumonia
E	Sarcoidosis

Submit

11:12

MyPastest
https://mypastest.pastest.com

Pastest+

A Allergic bronchopulmonary aspergillosis

The eosinophilia, transient pulmonary shadowing and raised CRP are suggestive of allergic bronchopulmonary aspergillosis, which is common in asthmatics. The transient pulmonary shadowing is caused by intermittent airway obstruction (which over time can lead to bronchiectasis).

B Churg–Strauss syndrome

Many of this patient's symptoms, signs and investigations do fit with Churg–Strauss syndrome: the eosinophilia, asthma, upper respiratory tract symptoms and transient opacities on the chest X-ray. Churg–Strauss also causes renal, cardiac and skin complications. However, Churg–Strauss is a very rare condition whereas allergic bronchopulmonary aspergillosis, which could also explain all these symptoms, is common in asthmatics like this patient. This means that allergic bronchopulmonary aspergillosis is the most likely diagnosis here.

C Cystic fibrosis

Cystic fibrosis causes bronchiectasis, which is not consistent with this patient's presentation. You would expect more marked changes on the chest X-ray (tramlining, coarsened lung markers) rather than isolated areas of transient opacity. You would also expect the patient to complain of thick sputum that was difficult to expectorate. Instead, this asthmatic patient is likely to have allergic bronchopulmonary aspergillosis, which is common amongst asthmatic patients and causes transient airway obstruction (leading to fleeting chest X-ray changes) and eosinophilia.

C Cystic fibrosis

Cystic fibrosis causes bronchiectasis, which is not consistent with this patient's presentation. You would expect more marked changes on the chest X-ray (tramlining, coarsened lung markers) rather than isolated areas of transient opacity. You would also expect the patient to complain of thick sputum that was difficult to expectorate. Instead, this asthmatic patient is likely to have allergic bronchopulmonary aspergillosis, which is common amongst asthmatic patients and causes transient airway obstruction (leading to fleeting chest X-ray changes) and eosinophilia.

D *Mycoplasma* pneumonia

Mycoplasma causes an 'atypical' pneumonia with a prodrome of headache, myalgia and dry cough. This patient instead has a history of asthma, upon which she developed an acute febrile illness with transient chest X-ray changes. She has a background eosinophilia and raised CRP and ESR. These findings are consistent with allergic bronchopulmonary aspergillosis, which is quite common amongst asthmatics.

E Sarcoidosis

Sarcoidosis is a vasculitic condition typically affecting African and Caribbean women. It causes progressive shortness of breath, hypercalcaemia and widespread lymphadenopathy. Typical X-ray changes are hilar lymphadenopathy and bilateral infiltrates or fibrotic changes, not transient opacities as seen in this case. This patient's presentation, with a background of asthma and eosinophilia with fleeting chest X-ray appearances, is typical of allergic bronchopulmonary aspergillosis, which is common in asthmatics.

A 24-year-old man from central Africa presents to his brother's general practitioner while visiting from overseas. He complains of painful groin lymphadenopathy and has a large hydrocoele. In addition, there are changes consistent with severe chronic lymphoedema affecting both lower limbs.

Past medical history of note includes epilepsy, for which he takes carbamazepine. He also suffers from indigestion. Elephantiasis is suspected as the underlying reason for his leg swelling.

You commence albendazole.

Which of the following other interventions is most appropriate in this case?

A	Sodium stibogluconate intramuscular (IM)
B	Paromomycin IM
C	Substitute carbamazepine with another anti-epileptic medication
D	Surgical drainage of lymph nodes
E	Immobilise the worst affected limb where possible

11:16

A 24-year-old man from central Africa presents to his brother's general practitioner while visiting from overseas. He complains of painful groin lymphadenopathy and has a large hydrocoele. In addition, there are changes consistent with severe chronic lymphoedema affecting both lower limbs.

Past medical history of note includes epilepsy, for which he takes carbamazepine. He also suffers from indigestion. Elephantiasis is suspected as the underlying reason for his leg swelling.

You commence albendazole.

Which of the following other interventions is most appropriate in this case?

Your answer was correct

A	Sodium stibogluconate intramuscular (IM)
B	Paromomycin IM
C	Substitute carbamazepine with another anti-epileptic medication
D	Surgical drainage of lymph nodes
E	Immobilise the worst affected limb where possible

Explanation

C Substitute carbamazepine with another anti-epileptic medication

Rana Alnasser's screen

4G 11:18

Explanation

C	Substitute carbamazepine with another anti-epileptic medication

This man has lymphatic filariasis. Filariae resulting in lymphatic obstruction include *Wuchereria bancrofti*, *Brugia malayi* and *Brugia timori*. Obstruction of lymphatic drainage is caused by the presence of adult worms. One treatment of choice includes albendazole, a broad-spectrum anthelminthic agent, which decreases the availability of ATP as the energy source for the worms, and results eventually in their immobilisation and death. Carbamazepine reduces the efficacy of albendazole and, if possible, should be substituted by another anti-epileptic. Dexamethasone, praziquantel and cimetidine are recognised to increase the risk of albendazole toxicity.

A	Sodium stibogluconate intramuscular (IM)

Sodium stibogluconate is used as treatment for leishmaniasis and is of therefore little use in this case. *Leishmania* are protozoa spread by sandflies in Africa, Asia, India, the Middle East, the Mediterranean and Latin America, causing granulomata. Cutaneous leishmaniasis lesions develop at the site of the bite, starting as an itchy papule which crusts to form an ulcer healing over 2-15 months. Visceral leishmaniasis, also known as kala-azar, has an incubation period of months to years. It spreads to the lymphatic system and multiplies in macrophages, presenting with dry, warty, hyper-pigmented lesions whilst the patient complains of fever, burning feet, arthralgia, cough and epistaxis. Splenomegaly occurs in 96% and hepatomegaly in 63%. Diagnosis is with microscopy of lymph nodes, spleen or bone marrow, or antibody detection. Treatment is with amphotericin, but sodium stibogluconate can also be used.

Rana Alnasser's screen

cough and epistaxis. Splenomegaly occurs in 96% and hepatomegaly in 63%. Diagnosis is with microscopy of lymph nodes, spleen or bone marrow, or antibody detection. Treatment is with amphotericin, but sodium stibogluconate can also be used.

B Paromomycin IM

Paromomycin is an antibiotic used to amoebiasis, giardiasis, leishmaniasis and tapeworm infections.

D Surgical drainage of lymph nodes

The swelling is likely to respond to medical management as the treatment is effective, and therefore there is no need for surgery.

E Immobilise the worst affected limb where possible

Immobilisation is likely to make symptoms worse, as lymphatics would collect in the limb and accumulate to cause greater swelling.

Rate this question:

© Pastest 2019

Rana Alnasser's screen

A 23-year-old man presents to the Emergency Department. He has come straight from the airport on returning from his holiday to the Democratic Republic of Congo.

He was bitten by a stray dog 1 week ago and while he washed the bite immediately, he is concerned about risk for rabies. He had all recommended vaccinations before travelling, including rabies vaccine. His bite has remained clean and the skin was punctured, but not deeply. He has no past medical history and takes no regular medications.

On examination, all of his observations are normal and the wound is nearly healed.

What is the most appropriate way to manage his risk of rabies?

A	No further action needed
B	Vaccination today and on days 7, 28 and in 2-3years
C	Vaccination today and on day 3
D	Vaccination today and on days 3, 7, 14, 30
E	Vaccination today and on days 3, 7, 14, 30 and also give immediate IV immunoglobulin

Submit

11:20

A 23-year-old man presents to the Emergency Department. He has come straight from the airport on returning from his holiday to the Democratic Republic of Congo.

He was bitten by a stray dog 1 week ago and while he washed the bite immediately, he is concerned about risk for rabies. He had all recommended vaccinations before travelling, including rabies vaccine. His bite has remained clean and the skin was punctured, but not deeply. He has no past medical history and takes no regular medications.

On examination, all of his observations are normal and the wound is nearly healed.

What is the most appropriate way to manage his risk of rabies?

A
B
C
D
E
0

Your answer was correct

A	No further action needed
B	Vaccination today and on days 7, 28 and in 2–3years
C	Vaccination today and on day 3
D	Vaccination today and on days 3, 7, 14, 30
E	Vaccination today and on days 3, 7, 14, 30 and also give immediate IV immunoglobulin

Explanation

C Vaccination today and on day 3

Rana Alnasser's screen

3years

C Vaccination today and on day 3

D Vaccination today and on days 3, 7, 14, 30

E Vaccination today and on days 3, 7, 14, 30 and also give immediate IV immunoglobulin

Explanation

C Vaccination today and on day 3

This is a patient who has been previously vaccinated against rabies presenting with a potentially dangerous bite. Rabies is a rhabdovirus spread by infected mammals with an incubation period of 9-90 days. It can present with a prodrome of malaise, agitation, pruritis surrounding the bite leading to infection, as well as headaches, before proceeding to spasms and hydrophobia. Since this patient has presented with a bite which may be at risk he should be treated. Since he had a previous vaccination he will only need a vaccination today and in 3 days to establish immunity.

A No further action needed

He is at risk of infection as he has had a skin-penetrating mammal bite in a region in which rabies is endemic.

B Vaccination today and on days 7, 28 and in 2-3years

This dosing regimen would be appropriate as pre-exposure prophylaxis in patients at increased risk.

proceeding to spasms and hydrophobia. Since this patient has presented with a bite which may be at risk he should be treated. Since he had a previous vaccination he will only need a vaccination today and in 3 days to establish immunity.

A No further action needed

He is at risk of infection as he has had a skin-penetrating mammal bite in a region in which rabies is endemic.

B Vaccination today and on days 7, 28 and in 2-3years

This dosing regimen would be appropriate as pre-exposure prophylaxis in patients at increased risk.

D Vaccination today and on days 3, 7, 14, 30

This vaccination schedule would be an appropriate option if he had never been vaccinated before and if it was used in conjunction with IV immunoglobulins.

E Vaccination today and on days 3, 7, 14, 30 and also give immediate IV immunoglobulin

This would be the full treatment if the patient had not had any vaccination to rabies before and presented within a week. IV immunoglobulins are not thought to be effective if given after 1 week, as by that time the patient should have established their own antibody response.

7617

Rate this question:

Next Question

Rana Alnasser's screen

11:22

A 21-year-old man presented with a 4-week history of white patches on the lateral borders of his tongue. The area affected changed every few days, and he had some generalised oral soreness. He had returned one month ago from Thailand and Laos, and had used intravenous heroin whilst travelling.

On examination, he was thin. He had axillary and cervical lymphadenopathy. He had white plaques on the lateral edges of his tongue: on scraping, the white material was removed revealing an erythematous under layer.

What is the most likely cause of the tongue lesions?

A	Geographic tongue
B	Herpes simplex
C	Herpes zoster
D	Oral candidiasis
E	Oral hairy leukoplakia

Submit

Previous Q... Skip Questi...

Rana Alnasser's screen

A 21-year-old man presented with a 4-week history of white patches on the lateral borders of his tongue. The area affected changed every few days, and he had some generalised oral soreness. He had returned one month ago from Thailand and Laos, and had used intravenous heroin whilst travelling.

On examination, he was thin. He had axillary and cervical lymphadenopathy. He had white plaques on the lateral edges of his tongue: on scraping, the white material was removed revealing an erythematous under layer.

What is the most likely cause of the tongue lesions?

Your answer was correct

A	Geographic tongue
B	Herpes simplex
C	Herpes zoster
D	Oral candidiasis
E	Oral hairy leukoplakia

Explanation

D	Oral candidiasis

The description of white patches that are non-adherent, and oral soreness, is typical of oral candidiasis. With his lymphadenopathy and weight loss on a background of intravenous drug use and travel to South East Asia, this

11:23

A Geographic tongue

B Herpes simplex

C Herpes zoster

D Oral candidiasis

E Oral hairy leukoplakia

Explanation

D Oral candidiasis

The description of white patches that are non-adherent, and oral soreness, is typical of oral candidiasis. With his lymphadenopathy and weight loss on a background of intravenous drug use and travel to South East Asia, this patient may have undiagnosed HIV. He should be tested and treated if he is positive. Oral candidiasis is a clinical diagnosis and can be treated topically with nystatin suspension, or with oral fluconazole in more severe cases or in immunosuppressed individuals.

A Geographic tongue

Geographic tongue is in fact caused by the loss of normal tongue papillae. This leads to the appearance of pale plaques on the tongue, when in fact the abnormality is the smooth, erythematous regions in-between (the pale plaques are islands of normal papillated tongue). This patient has mouth signs consistent with oral candidiasis: mucosal soreness with non-adherent white plaques. On a background of lymphadenopathy, weight loss, travel to South East Asia and intravenous drug use, this is suggestive of underlying immunosuppression due to HIV

Rana Alnasser's screen

plaques are islands of normal papillated tongue). This patient has mouth signs consistent with oral candidiasis: mucosal soreness with non-adherent white plaques. On a background of lymphadenopathy, weight loss, travel to South East Asia and intravenous drug use, this is suggestive of underlying immunosuppression due to HIV infection. The patient should be tested for HIV.

B Herpes simplex

Herpes simplex causes cold sores and mucosal ulceration. While mucosal ulceration could explain his generalised mouth soreness, no ulcers were seen on examination, and herpes simplex could not explain his non-adherent white patches. This patient has signs consistent with oral candidiasis, and underlying HIV infection (lymphadenopathy, weight loss and a background of intravenous drug use and travel to South East Asia). He should be tested for HIV.

C Herpes zoster

Herpes zoster causes shingles, a blistering skin rash that normally manifests in a dermatomal distribution. This patient has white, sore patches in the mouth that would be more consistent with oral candidiasis. On a background of lymphadenopathy, weight loss, intravenous drug use and travel to South East Asia, this is suggestive of an undiagnosed HIV infection, for which he should be tested.

E Oral hairy leukoplakia

This is a condition caused by the reactivation of Epstein-Barr virus in immunocompromised individuals. It does cause white patches, typically on the lateral aspects of the tongue, but these are classically rough and adherent; they do not scrape off to reveal erythematous sore patches, as in this case. This patient's signs are more consistent with

Rana Alnasser's screen

11:24
594-042-7551 Leave

C Herpes zoster

Herpes zoster causes shingles, a blistering skin rash that normally manifests in a dermatomal distribution. This patient has white, sore patches in the mouth that would be more consistent with oral candidiasis. On a background of lymphadenopathy, weight loss, intravenous drug use and travel to South East Asia, this is suggestive of an undiagnosed HIV infection, for which he should be tested.

E Oral hairy leukoplakia

This is a condition caused by the reactivation of Epstein–Barr virus in immunocompromised individuals. It does cause white patches, typically on the lateral aspects of the tongue, but these are classically rough and adherent; they do not scrape off to reveal erythematous sore patches, as in this case. This patient's signs are more consistent with oral candidiasis. On a background of weight loss and lymphadenopathy, with intravenous drug use and travel to South East Asia, the concern is that this patient might have undiagnosed HIV, for which he should be tested.

21507

Rate this question:

Next Question

Previous Q... Tag Questi... Feedback End Session

Blog About Pastest Contact Us Help
Audio Video Share Participants More

11:24

MyPastest
https://mypastest.pastest.com

Pastest+

A 40-year-old builder presents with a 5-h history of increasingly severe headache and myalgia. Two weeks ago, he was seen in the Emergency Department following a fall from the scaffolding of a building on which he was working. At that time, he had a skull X-ray that was reported as being normal. As he had no specific symptoms or signs at that time, he was not admitted.

He smokes 20 cigarettes a day and drinks 21 units of alcohol a week. He has no other past medical history.

On examination, he looks unwell. He is wearing his sunglasses. His temperature is 38 °C. His blood pressure is 130/85 mmHg, pulse 88 bpm, oxygen saturation ($Sp(O_2)$) is 98% on air. He appears to have mild neck stiffness on examination. He is orientated in time, place and person but seems alternately sleepy and slightly aggressive towards staff. GCS is graded as 14/15 by the examining doctor. Blood cultures have been taken and a CT and lumbar puncture are arranged.

Which other step should be taken in the immediate management of this man?

A	IV ceftriaxone
B	IV dexamethasone
C	IV mannitol
D	Antituberculous therapy
E	IV aciclover

Rana Alnasser's screen

11:27

Explanation

A	IV ceftriaxone

This patient has a history of a head injury and presents with what sounds like meningitis. In this particular case the fact that the patient has sustained a head injury means that CT is mandatory. That the previous skull X-ray was reported as normal is not 100% reliable as some fractures may be missed, particularly those of the temporal bones.

In general, CSF examination allowing confirmation of the diagnosis and identification of the organism is preferable prior to starting antibiotics. In most cases it is preferable to perform CT first, and this is absolutely required in the context of reduced conscious level, history of head injury or presence of focal neurological signs.
However, in a very unwell patient with a typical clinical picture of bacterial meningitis, for whom waiting for such investigations would risk undue delay in starting treatment, antibiotics may be commenced simply after blood cultures and CT/LP performed afterwards. Starting antibiotics, however, usually alters the CSF obtained and the likelihood of identifying an organism becomes less the longer the delay after the first dose of antibiotics.

B	IV dexamethasone

Dexamethasone should be used in the case of a space-occupying lesion with mass effect, such as an abscess. This could help alleviate confusion in the acute setting, and if the scan demonstrated mass effect then it could be the correct option. Dexamethasone is also be used in HIV-associated CNS infections such as *Cryptotoccus* with raised intracranial pressure. In cryptococcal meningitis, the presentation is often with focal neurology which improves rapidly with treatment, but if there is evidence of midline shift or a high number of ring-enhancing lesions then dexamethasone should be used in addition to antifungal treatment. In the absence of signs of raised intracranial

Rana Alnasser's screen

11:31
594-042-7551 Leave

could help alleviate confusion in the acute setting, and if the scan demonstrated mass effect then it could be the correct option. Dexamethasone is also be used in HIV-associated CNS infections such as *Cryptotoccus* with raised intracranial pressure. In cryptococcal meningitis, the presentation is often with focal neurology which improves rapidly with treatment, but if there is evidence of midline shift or a high number of ring-enhancing lesions then dexamethasone should be used in addition to antifungal treatment. In the absence of signs of raised intracranial pressure, positive CT or MRI findings and HIV, dexamethasone is likely to be of little use.

C IV mannitol

It is a treatment option for cerebral oedema. However, the high temperature suggests an infective aetiology to this patient's confusion.

D Antituberculous therapy

TB can cause meningitis which can be identified from CSF results. However, this patient has no described exposure to anyone with TB nor is there any mention of travel to TB endemic countries. Also, the acute onset makes this less likely.

E IV aciclover

Aciclovir is treatment for viral meningitis and encephalitis. Viral infection is possible but would be unrelated to trauma, making a bacterial infection more likely.

Rate this question:

Next Question

Annotation Stop Share
Audio Video Share Participants More

11:31

An 18-year-old man returns from a trip helping a school project in the remote Thai jungle. Soon after returning home he began suffering from a severe fever accompanied by facial flushing and a severe headache with retro-orbital pain. There is also myalgia and joint pains; most recently he has noticed bleeding from around his gums.

On examination he has a pyrexia of 41 °C, a blood pressure of 100/70 mmHg and a pulse of 100 bpm. There is a maculopapular rash, and you also notice some petechiae and bleeding from the site where you took blood.

Blood test results:

Hb	10.5 g/dl
WCC	9.1×10^9/l (lymphocytosis)
PLT	40×10^9/l
Na^+	133 mmol/l
K^+	5.5 mmol/l
Creatinine	185 µmol/l
Alanine aminotransferase (ALT)	209 U/l
Prothrombin time	25.2 s
Thick and thin film	Negative

Choose the most appropriate diagnosis from those given above?

A Typhoid fever

B D fever

Annotation Stop Share

Rana Alnasser's screen

11:33
594-042-7551 Leave

Hb	10.5 g/dl
WCC	9.1×10^9/l (lymphocytosis)
PLT	40×10^9/l
Na^+	133 mmol/l
K^+	5.5 mmol/l
Creatinine	185 µmol/l
Alanine aminotransferase (ALT)	209 U/l
Prothrombin time	25.2 s
Thick and thin film	Negative

Choose the most appropriate diagnosis from those given above?

A Typhoid fever

B Dengue fever

C Malaria

D Weil's disease

E Japanese encephalitis

Submit

Annotation Stop Share
Audio Video Share Participants More

B Dengue fever

C Malaria

D Weil's disease

E Japanese encephalitis

Explanation

B Dengue fever

Dengue fever is endemic in tropical South-East Asia, and outbreaks have also occurred in the tropical regions of Australia. The illness is a haemorrhagic fever, carried by the *Aedes* mosquito and is caused by the dengue virus. It is characterised by fever, severe headache and facial flushing. In the early stages there is a lymphocytosis, with later lymphopenia, thrombocytopenia and bleeding. Treatment is supportive.

A Typhoid fever

Typhoid fever is caused by *Salmonella* subspecies, typically 10–20 days following exposure. It causes a high fever, dry cough, malaise, abdominal pain following by green diarrhoea and hepatosplenomegaly and in the final stages it can cause complications in multiple organs. There can be associated bradycardia as well. Diagnosis is by culture, and treatment is usually with azithromycin, but if severe then IV ceftriaxone is used. This patient's tachycardia, renal injury and thrombocytopenia make this a less likely diagnosis.

C M

Annotation Stop Share

Malaria is a protozoal disease caused by species of the

Weil's disease is a severe form of leptospirosis. The organisms are spirochaetes which are spread from rat urine into aquatic areas and then contact with abraded skin or mucosa leads to infection. Water activities increase risk. Following an incubation of 1–3 weeks, there is an abrupt onset of fever, headache, myalgia, dry cough and lethargy. This phase may resolve without treatment but can lead to an immune phase with jaundice, abdominal pain, diarrhoea, rash, meningitis and organ failure. It can cause kidney disease but is unlikely to explain the thrombocytopenia. There is also no mention of at-risk behaviour such as swimming in possibly contaminated water sources.

E	Japanese encephalitis

This infection is caused by a mosquito-borne flavivirus endemic across Asia. It presents after 5–15 days with fever, headache, diarrhoea and myalgia leading to neurological disease ranging from confusion to coma and commonly seizures. It is associated with leukocytosis and neuroimaging can show bilateral thalamic lesions with haemorrhage. The abnormal liver, renal and haemaglobin tests and severe fever make this an unlikely diagnosis.

Rate this question:

Previous Q... Tag Questi... Feedback End Session

Blog About Pastest Contact Us Help

Annotation Stop Share

11:35

MyPastest
https://mypastest.pastest.com

An elderly woman is admitted to the Care Of The Elderly Ward. She presented with mild confusion and a fever. She has a past medical history of diverticular disease, for which she has been most recently admitted two years ago. Otherwise, she is in good health. In Accident and Emergency, urinalysis reveals nitrites in the urine and treatment with co-amoxiclav is commenced.

The next day, urine culture confirms an E. coli urinary tract infection (UTI). She continues the treatment for a further three days. Both the fever and confusion resolve and she is able to mobilise around the ward.

On the fourth day of her admission, she develops some diarrhoea. She has five episodes of watery diarrhoea. That evening she develops a fever of 38 °C. She is seen by the on-call SHO who examines her and arranges for routine blood tests, blood cultures and stool culture.

You arrive back on the ward the next morning to find the patient very unwell. She is tachycardic, pulse 120 bpm; BP 120/65 mmHg; temperature 38 °C. The nurses report several more episodes of profuse, green, watery diarrhoea overnight.

On examination, the patient has a diffusely tender abdomen with active bowel sounds. There is no evidence of peritonism. Chest and cardiovascular examination are unremarkable. You obtain IV access and commence IV fluids.

Blood tests from last night are as follows:

Hb	16.1 g/l
WCC	32 × 10^9/l
PLT	220 × 10^9/l
Urea	mmol/l
Creatinine	110 µmol/l

Annotation Stop Share

Rana Alnasser's screen

unremarkable. You obtain IV access and commence IV fluids.

Blood tests from last night are as follows:

Hb	16.1 g/l
WCC	32×10^9/l
PLT	220×10^9/l
Urea	9.0 mmol/l
Creatinine	110 μmol/l
Na^+	136 mmol/l
K^+	3.4 mmol/l
Bilirubin	18 μmol/l
ALT	47 U/l
ALP	87 U/l
Albumin	28 g/l

You stop the co-amoxiclav.

Of the following, which is the most urgent next step?

A Send stool for C. difficile toxin a

B Send stool for C. difficile toxin b

C Commence oral ciprofloxacin

D Commence oral vancomycin

E Abdominal X- ray

Annotation Stop Share

4G 11:38

D Commence oral vancomycin

Clinically there is ample evidence that this is Clostridium difficile infection. This patient is clearly extremely unwell, and the most important steps are to stop the co-amoxiclav which will have been the main precipitant of the C. difficile infection in the first place and to commence the appropriate treatment, which is oral **vancomycin**

A Send stool for C. difficile toxin a

Whilst testing for toxins is the correct way to diagnose C. difficile infection, it is not the most urgent action as this patient needs treatment prior to confirmation of the likely diagnosis.

B Send stool for C. difficile toxin b

Whilst testing for toxins is the correct way to diagnose C. difficile infection, it is not the most urgent action as this patient needs treatment prior to confirmation of the likely diagnosis.

C Commence oral ciprofloxacin

This would be a very dangerous option as ciprofloxacin can precipitate *C. difficile* infection and worsen current infection

E Abdominal X- ray

Both AXR and CT would be useful if there was evidence of peritonitis or obstruction. A possible complication with C. difficile is toxic megacolon which can be seen with abdominal X-ray if suspected. The presence of bowel sounds a[illegible]ence of signs of peritonism makes this a less urge[illegible]

Annotation Stop Share

11:39

MyPastest
https://mypastest.pastest.com

A 23-year-old Burmese man presents to Gastroenterology Clinic. He has lived in the UK for 8 months and works in a nightclub. He is complaining of severe persistent diarrhoea for the past month, ever since he took a trip back home to Burma where his family live in a small village. He has lost 15 kg; he denies fever or night sweats. The diarrhoea is watery with no blood or mucus. There is some associated abdominal discomfort and he feels nauseated but has not vomited. He has noticed a rash over his trunk which seems to be more obvious at some times more than others.

On examination, he is slim but looks well, pulse 90 bpm; BP 135/72 mmHg; afebrile. Abdominal examination is unremarkable with no organomegaly; the rest of the clinical examination is unremarkable.

The GP has performed some tests:

FBC	
Hb	12.2 g/dl
MCV	75 fl
WCC	6.5×10^9/l
Eosinophils	2.5×10^9/l
Lymphocytes	1.0×10^9/l
Neutrophils	2.6×10^9/l

Renal function:	
Na^+	134 mmol/l
K^+	3.2 mmol/l

Annotation Stop Share

Lymphocytes	1.0×10^9/l
Neutrophils	2.6×10^9/l

Renal function:	
Na^+	134 mmol/l
K^+	3.2 mmol/l
Urea	4.1 mmol/l
Creatinine	80 μmol/l

LFTs:	
Bilirubin	22 μmol/l
ALT	32 U/l
ALP	101 U/l
Albumin	30 g/l
Amylase	95 U/l
CRP	35 U/l

Stool microscopy & culture - No growth.

The GP had previously prescribed a week's course of ciprofloxacin which has made very little difference to the patient's symptoms. On further testing, he is found to be both HIV positive and have positive serology for strongyloides.

Which of the following is the most appropriate initial treatment?

A Metronidazole

B Albendazole

Annotation Stop Share

LFTs:	
Bilirubin	22 µmol/l
ALT	32 U/l
ALP	101 U/l
Albumin	30 g/l
Amylase	95 U/l
CRP	35 U/l

Stool microscopy & culture – No growth.

The GP had previously prescribed a week's course of ciprofloxacin which has made very little difference to the patient's symptoms. On further testing, he is found to be both HIV positive and have positive serology for strongyloides.

Which of the following is the most appropriate initial treatment?

A Metronidazole

B Albendazole

C Ivermectin

D Antiretroviral therapy

E IV gentamicin

33166

Annotation Stop Share Submit

B Albendazole

C Ivermectin

D Antiretroviral therapy

E IV gentamicin

Explanation

C Ivermectin

Strongyloides is a nematode endemic in the sub-tropics. Transmission occurs via direct skin exposure followed by cutaneous larva migrans seen as migrating urticarial on the legs and trunk. It can cause enteritis, malabsorption and pneumonitis. In the wake of the nematodes, bacteria can following which can cause septicaemia and meningitis. Treatment is usually with ivermectin for 48 hours.

B Albendazole

This antiprotozoal can be considered in patients with AIDS and strongyloides hyperinfestation. Whilst there is positive HIV serology, there is no CD4 count or AIDS-defining illnesses at this point and therefore there is no clear diagnosis of AIDS. It is the standard second line agent in the UK.

A Metronidazole

Metronidazole would be the correct threadworm or whipworm but these infections do not cause this level of infection

Annotation Stop Share

11:46
594-042-7551 Leave

A 40-year-old man presented to clinic with a 2-week history of fever, myalgia and lethargy. He also complained of mouth ulcers. Two months ago he had visited friends and relatives in South Africa. He had no medical conditions.

On examination, his temperature was 37.6ºC. He had cervical lymphadenopathy but no hepatosplenomegaly. There were aphthous ulcers on the buccal mucosa.

Investigations:

Hb	13.6 g/dl (13.0–18.0)
WCC	4.1×10^9/l (4.0–11.0)
Neutrophils	2.2×10^9/l (1.5–7.0)
Lymphocytes	0.9×10^9/l (1.5–4.0)
PLT	96×10^9/l (150–400)
Bilirubin	26 mmol/l (1–22)
ALT	72 U/l (5–35)
Blood film	Atypical reactive lymphocytes
HIV antibodies	-

What is the most likely diagnosis?

A Cytomegalovirus infection

B Hepatitis B

C Hepatitis C

D H tion

Annotation Stop Share
Audio Video Share Participants More

11:46
594-042-7551 Leave

of mouth ulcers. Two months ago he had visited friends and relatives in South Africa. He had no medical conditions.

On examination, his temperature was 37.6ºC. He had cervical lymphadenopathy but no hepatosplenomegaly. There were aphthous ulcers on the buccal mucosa.

Investigations:

Hb	13.6 g/dl (13.0–18.0)
WCC	4.1×10^9/l (4.0–11.0)
Neutrophils	2.2×10^9/l (1.5–7.0)
Lymphocytes	0.9×10^9/l (1.5–4.0)
PLT	96×10^9/l (150–400)
Bilirubin	26 mmol/l (1–22)
ALT	72 U/l (5–35)
Blood film	Atypical reactive lymphocytes
HIV antibodies	-

What is the most likely diagnosis?

A Cytomegalovirus infection

B Hepatitis B

C Hepatitis C

D HIV infection

E Malaria

Annotation Stop Share
Audio Video Share Participants More

C Hepatitis C

D HIV infection

E Malaria

Explanation

D HIV infection

This patient has recently returned from travelling in an area with a high HIV prevalence, and has a flu-like illness with lymphadenopathy, atypical lymphocytes on a blood film, a mild transaminitis and fever. HIV antibodies can be negative if the patient is currently seroconverting; a better diagnostic test would be either HIV RNA PCR or p24 antigen.

A Cytomegalovirus infection

In the immunocompetent, cytomegalovirus infection is typically asymptomatic or may cause a mild, flu-like illness. In the immunosuppressed, cytomegalovirus can cause pneumonia, retinitis or, most commonly, diarrhoea or colitis. This patient's fever, lymphadenopathy and liver dysfunction are best explained by HIV seroconversion. HIV antibodies may be negative during seroconversion: a p24 antigen test or HIV RNA PCR would be better suited to diagnosis.

B Hepatitis B

Hepatitis B could cause malaise and liver dysfunction, but you might expect liver function tests to be more markedly abnormal if were hepatitis B. Furthermore, hepatitis B would not explain the lymphadenopathy or atypical

negative during seroconversion. A better diagnostic test would be either a p24 antigen test or HIV RNA PCR.

C Hepatitis C

Hepatitis C may cause malaise, fever and liver dysfunction. However, liver function tests would likely be more markedly abnormal in symptomatic hepatitis C, and hepatitis C would not explain the lymphadenopathy or atypical lymphocytes seen in this patient. Instead, this patient is more likely to be in HIV seroconversion. HIV antibodies can be negative during seroconversion, and therefore a better diagnostic test would be either p24 antigen or HIV RNA PCR.

E Malaria

Malaria is an important cause of fever in the returning traveller and should always be a differential diagnosis; however, malaria does not explain the lymphadenopathy or atypical lymphocytes seen in this case. This picture of malaise, a relative lymphopenia, transaminitis and lymphadenopathy is more suggestive of HIV. As the patient is seroconverting, HIV antibodies can be negative. A better test would have been either p24 antigen or HIV RNA PCR.

71140

Rate this question:

Next Question

Previous Q... Tag Questi... Feedback End Session

A 72-year-old woman presented with a 5-day history of profuse diarrhoea. She passed watery stool flecked with blood up to 10 times per day. She also complained of cramping abdominal pain, a low-grade fever and increased lethargy. She had recently completed a course of clindamycin for a dental abscess.

On examination, her temperature was 37.8 °C. Her abdomen was soft but the lower portion was generally tender.

Investigations:

Hb	12.1 g/dl (11.5–16.5)
WCC	18.3×10^9/l (4.0–11.0)
Urea	13.4 mmol/l (2.5–7.0)
Na^+	142 mmol/l (137–144)
K^+	4.9 mmol/l (3.5–4.9)
Creatinine	165 µmol/l (60–110)
Rigid sigmoidoscopy	Raised, yellowish white plaques throughout sigmoid

Given the likely diagnosis, which of the following is the most appropriate treatment?

A Intravenous ciprofloxacin

B Intravenous vancomycin

C Oral ciprofloxacin

D Oral vancomycin

E Rectal budesonide

11:50
594-042-7551 Leave

Explanation

D Oral vancomycin

This patient has *Clostridium difficile* infection, as evidenced by her profuse, offensive diarrhoea, pseudomembranous colitis on rigid sigmoidoscopy and high white cell count. This was probably caused by taking clindamycin, which increases the risk of *C. difficile* infection. Oral vancomycin is the first-line treatment for *C. difficile*; other options include oral metronidazole and oral and intravenous fidaxomycin.

A Intravenous ciprofloxacin

This patient has developed pseudomembranous colitis on sigmoidoscopy, and her symptoms and high white cell count are consistent with *C. difficile* infection. Clindamycin, which this patient had received for a dental infection, is known to be associated with *C. difficile* infection. Unfortunately ciprofloxacin is also associated with the development of *C. difficile* infection, and therefore would not be an appropriate choice of treatment. Also, please note that bioavailability for intravenous and oral ciprofloxacin is virtually identical, therefore treating with intravenous ciprofloxacin provides no advantage unless the patient is unable to take oral ciprofloxacin. First-line treatment of *C. difficile* is usually oral vancomycin or oral metronidazole, but sometimes oral fidaxomycin is used.

B Intravenous vancomycin

This patient has *Clostridium difficile* infection, as evidenced by the profuse diarrhoea, pseudomembranous colitis on sigmoidoscopy and high white cell count. Clindamycin, which this patient has recently taken, is known to be associated with *C. difficile* infection. Whilst vancomycin is an appropriate choice of antibiotic, it should be given

Audio Video Share Participants More

11:51
594-042-7551 Leave

precipitated by the clindamycin she was prescribed for her dental infection. Both clindamycin and ciprofloxacin are strongly associated with increased risk of *C. difficile* infection; consequently ciprofloxacin would not be a good choice of antibiotic for treatment of this patient. First-line treatments would be oral vancomycin or oral metronidazole; second-line therapies include oral fidaxomycin.

E Rectal budesonide

Budesonide is a steroid, and rectal budesonide is used in the treatment of inflammatory bowel disease and gut graft-versus-host disease in order to tackle inflammation. However, this patient has *Clostridium difficile* infection, as evidence by her profuse, offensive diarrhoea and high white cell count after taking a course of clindamycin, an antibiotic known to be associated with *C. difficile*. The rigid sigmoidoscopy confirms a pseudomembranous colitis. Treating this with steroids would be highly inappropriate; she requires antibiotic therapy with oral vancomycin. Other appropriate options would be oral metronidazole or fidaxomycin.

Rate this question:

Next Question

Previous Q... Tag Questi... Feedback End Session

Blog About Pastest Contact Us Help

© Pastest 2019

Audio Video Share Participants More

A 29-year-old man presented to the Emergency Department with a 2-day history of abdominal pains and bloody diarrhoea. He had returned from Uganda 1 week previously. He had been relatively well during his trip but reported blood in his stool over the preceding 4 weeks.

On examination, his temperature was 37.5°C. His abdomen was generally tender to touch but no masses could be felt, and he had active bowel sounds.

Investigations:

Hb	13.1 g/dl (13.0–18.0)
WCC	12.0×10^9/l (4.0–11.0)
PLT	330×10^9/l (150–400)
Na^+	137 mmol/l (135–145)
K^+	5.1 mmol/l (3.5–5.0)
Urea	8.5 mmol/l (2.5–7.0)
Creatinine	80 µmol/l (60–110)

What is the most likely diagnosis?

A Amoebic dysentery

B *Campylobacter* enterocolitis

C Ischaemic colitis

D Giardasis

E Pseudomembranous colitis

C Ischaemic colitis

D Giardasis

E Pseudomembranous colitis

Explanation

A Amoebic dysentery

Amoebic dysentery is caused by *Entamoeba histolytica*, which is most often acquired in the tropics. The organism invades the mucosa of the colon, creating shallow ulcers with undermined edges. Although infection may be asymptomatic, the symptoms can include fever, chills, diarrhoea and abdominal pain. The stool may contain blood and/or mucus. The organism may rarely invade the liver to form an abscess, and other complications include inflammation of the intestine or rarely perforation. Diagnosis is usually made by microscopic examination of the patient's stool for the organism's trophozoites and/or cysts, and PCR stool testing.

B *Campylobacter* enterocolitis

Although *Campylobacter* is the most common cause of bloody diarrhoea in the UK, it typically causes high fever and constitutional upset. This patient is quite well and has only a low-grade fever. This, combined with his travel history, makes amoebic dysentery much more likely.

C Ischaemic colitis

Ischaemic colitis causes severe abdominal pain, which this patient does not complain of. You might expect him to be

11:54

C Ischaemic colitis

Ischaemic colitis causes severe abdominal pain, which this patient does not complain of. You might expect him to be more unwell, possibly in shock, if he had significant ischaemic colitis. The patient does not appear to have any risk factors for ischaemic colitis: he is young, without vascular disease or atrial fibrillation. This patient's travel history and presentation are more consistent with amoebic dysentery.

D Giardasis

Although a common cause of diarrhoea in the returning traveller, giardiasis does not cause bloody diarrhoea, as seen here. Instead it causes steatorrhoea, belching and flatulence, and sometimes nausea. This patient's presentation is more consistent with amoebic dysentery.

E Pseudomembranous colitis

Pseudomembranous colitis is caused by *Clostridium difficile* overgrowth, and is associated with institutionalisation or the use of antibiotics, neither of which are the case for this patient. *C. difficile* causes an offensive diarrhoea, but not a bloody diarrhoea. This patient's travel history and presentation are more consistent with amoebic dysentery.

Rate this question:

Rana Alnasser's screen

A 27-year-old man presented to clinic for review. He had been diagnosed with HIV 2 weeks previously and was due to be started on antiretroviral therapy at this clinic visit. He complained of some fatigue and headache but was otherwise well. He had no past medical history.

On examination he had a low-grade fever at 37.7°C. He had some purpuric lesions on his lower limbs. The remainder of the examination was normal.

Investigations:

Hb	9.5 g/dl (130–180)
WCC	4.6×10^9/l (4.0–11.0)
Neutrophils	3.0×10^9/l (1.5–7.0)
PLT	11×10^9/l (150–400)

What is the most important test to do next?

A Bone marrow aspiration

B CD4 count

C Liver function

D Renal function

E Ultrasound abdomen

71047

Submit

11:57

B CD4 count

C Liver function

D Renal function

E Ultrasound abdomen

Explanation

D Renal function

This patient's anaemia and thrombocytopenia could be caused by thrombotic thrombocytopenic purpura (TTP), which is associated with HIV. However, immune thrombocytopenic purpura (ITP) is also associated with HIV: this tends to improve either over time or with treatment of the HIV. In contrast, TTP requires immediate management and can be life-threatening. In order to decide whether this is HIV-associated ITP or TTP, evidence of clinical features of TTP must be sought: there is a pentad of associated features. This pentad includes thrombocytopenia, fever, neurological symptoms, haemolytic anaemia and renal impairment. Thus renal function would be the most appropriate test in this case. If this were TTP, treatment would be by plasmapheresis and steroids.

A Bone marrow aspiration

A bone marrow aspirate can sometimes be appropriate in the context of pancytopenia; however, this patient has a normal white cell count and therefore is not pancytopenic. This patient is anaemic, but also severely thrombocytopenic in the context of a new diagnosis of HIV. HIV can be associated with both thrombotic

Rana Alnasser's screen

haemolytic anaemia and renal impairment. Thus renal function would be the most appropriate test in this case. If this were TTP, treatment would be by plasmapheresis and steroids.

A Bone marrow aspiration

A bone marrow aspirate can sometimes be appropriate in the context of pancytopenia; however, this patient has a normal white cell count and therefore is not pancytopenic. This patient is anaemic, but also severely thrombocytopenic in the context of a new diagnosis of HIV. HIV can be associated with both thrombotic thrombocytopenic purpura (TTP) and immune thrombocytopenic purpura (ITP): ITP typically improves as the disease progresses and with treatment, whereas TTP needs specific intervention. TTP is characterised by a pentad of fever, thrombocytopenia, neurological symptoms, haemolytic anaemia and reduced renal function: therefore the most appropriate investigation would be renal function.

B CD4 count

The CD4 count can be useful as a marker of the level of disease control in HIV, but the problem here is that the patient has an anaemia and thrombocytopenia: the CD4 count will not help to determine the cause or management of this. In fact, HIV can be associated with both thrombotic thrombocytopenic purpura (TTP) and immune thrombocytopenic purpura (ITP). TTP is a serious condition requiring immediate treatment, whereas the ITP associated with HIV tends to improve with treatment of HIV. TTP is associated with a pentad of symptoms which includes impaired renal function: hence renal function would be the most appropriate investigation in this case.

C Liver function

thrombocytopenic purpura (TTP) and immune thrombocytopenic purpura (ITP). TTP is a serious condition requiring immediate treatment, whereas the ITP associated with HIV tends to improve with treatment of HIV. TTP is associated with a pentad of symptoms which includes impaired renal function: hence renal function would be the most appropriate investigation in this case.

C Liver function

This patient has an anaemia and thrombocytopenia: liver function tests cannot aid in diagnosing the cause or deciding management. HIV is associated with both thrombotic thrombocytopenic purpura (TTP) and immune thrombocytopenic purpura (ITP). Whilst TTP requires immediate definitive management, ITP in HIV tends to improve over time and with treatment of the HIV. To distinguish between the two, one must look for evidence of clinical features of TTP. One of these is renal impairment, and hence renal function would be the most appropriate investigation in this case.

E Ultrasound abdomen

This patient has an anaemia and thrombocytopenia; an ultrasound of the abdomen will not help to diagnose the cause or decide management. The concern is whether this could be HIV-associated thrombotic thrombocytopenic purpura (TTP). TTP is characterised by a pentad of fever, haemolytic anaemia, thrombocytopenia, neurological symptoms and renal impairment: hence renal function would be the most appropriate test in this case.

Rate this question:

Next Question

A 27-year-old homosexual man attended clinic with a 3-day history of painful and itchy penile ulcers. He also had flu-like symptoms over the preceding week, dysuria and a white urethral discharge. Ten days ago, he had unprotected penetrative anal intercourse with a casual partner.

On examination, there were three shallow, tender, sloughing ulcers under the foreskin, as well as generalised erythema of the surrounding skin. Urine dipstick was normal.

Investigations:

Urethral swab microscopy	Pus cells ++

Which investigation is most likely to provide the diagnosis?

A Culture for herpes simplex

B Culture for *Treponema pallidum*

C Human immunodeficiency virus (HIV) serology

D Polymerase chain reaction (PCR) test for herpes simplex

E Syphilis serology

Submit

E Syphilis serology

Explanation

D Polymerase chain reaction (PCR) test for herpes simplex

This is a typical presentation of herpes simplex with multiple painful ulcers following unprotected sex. The prodromal flu-like symptoms are also a classic feature, though not all patients will experience a prodrome. PCR is the most sensitive test for herpes simplex. In clinical practice, this patient would also be tested for syphilis, as co-infection can occur and sometimes it is difficult to differentiate the two conditions clinically; typically, however, syphilitic ulcers are single and painless; hence, herpes simplex is a more likely diagnosis here.

A Culture for herpes simplex

The most likely diagnosis here is herpes simplex (given that the ulcers are painful and multiple), but polymerase chain reaction (PCR) is more sensitive than culture in diagnosing herpes simplex, and therefore is the correct answer here. However, it is important to note that, in clinical practice, it is difficult to tell syphilis and herpes apart from the history and clinical examination alone, and you would test for both at the same time.

B Culture for *Treponema pallidum*

T. pallidum is syphilis; this patient has multiple painful ulcers, whereas syphilitic ulcers are typically single and painless. This patient's presentation is more consistent with herpes simplex, for which PCR is the most sensitive test. However, it is important to note that, in clinical practice, it

12:03
594-042-7551 Leave

C Human immunodeficiency virus (HIV) serology

Rashes can be a presenting feature of HIV seroconversion, but HIV does not typically cause painful penile ulcers. This presentation is more consistent with herpes simplex (multiple painful ulcers), for which the most sensitive test is PCR; PCR for herpes simplex is the correct answer here. In clinical practice, this patient would be screened for HIV (though it is likely too early at this point, and the patient would need to be screened after 3 months to rule out HIV infection), chlamydia, syphilis and herpes simplex.

E Syphilis serology

Syphilis is a reasonable differential diagnosis for this patient's presentation; however, syphilitic ulcers are typically single and painless. This patient's multiple painful ulcers are more typical of herpes simplex, for which the most sensitive diagnostic test is PCR. In clinical practice, it can be difficult to differentiate the two conditions, and therefore you would likely test for both.

Rate this question:

© Pastest 2019

Audio Video Share Participants More

A 19-year-old woman presented to the Emergency Department with a 10-day history of fevers. She had returned from a 1-month holiday in Peru 1 week previously.

Before travelling to Peru, she had received hepatitis A and typhoid vaccinations. She took malaria prophylaxis regularly while on holiday but had stopped it 5 days before returning, as she lost her tablets.

On examination, her temperature was 39 °C, with a pulse of 56 bpm. There was an erythematous, salmon-coloured maculopapular rash on her trunk. There was also cervical lymphadenopathy. Urine dipstick was positive for leukocytes.

Investigations:

		Normal values
Haemoglobin (Hb)	124 g/l	115–165
White cell count (WCC)	10.4×10^9/l	4.0–11.0
Platelets (PLT)	340×10^9/l	150–400
Sodium (Na)	139 mmol/l	135–145
Potassium (K)	4.1 mmol/l	3.5–5.0
C-reactive protein (CRP)	440 mg/l	<10
Creatinine (Cr)	97 µmol/l	60–110
Urea	6.2 mmol/l	2.5–7.0
Blood cultures	Gram-negative rods in two out of three bottles	

Rana Alnasser's screen

White cell count (WCC)	10.4×10^9/l	4.0–11.0
Platelets (PLT)	340×10^9/l	150–400
Sodium (Na)	139 mmol/l	135–145
Potassium (K)	4.1 mmol/l	3.5–5.0
C-reactive protein (CRP)	440 mg/l	<10
Creatinine (Cr)	97 µmol/l	60–110
Urea	6.2 mmol/l	2.5–7.0
Blood cultures	Gram-negative rods in two out of three bottles	
Thin malaria films	Two separate samples are negative	
Chest X-ray	Normal	

What is the most likely diagnosis?

A Cytomegalovirus (CMV) infection

B Epstein–Barr virus (EBV) infection

C *Plasmodium falciparum* malaria

D *Salmonella typhi* infection

E Schistosomiasis

Submit

12:06

MyPastest
https://mypastest.pastest.com

D *Salmonella typhi* infection

A high fever in a returning traveller should prompt you to think of two conditions: malaria and typhoid. *S. typhi* causes typhoid fever, which is a major differential diagnosis in a returning traveller with high fever. Typically, *S. typhi* has an incubation period of 10–14 days, followed by a prodrome of flu-like symptoms. In the first week, patients have a high fever, with a relative bradycardia (as seen here). Next, they develop a salmon-pink maculopapular rash that blanches on pressure, lymphadenopathy and hepatosplenomegaly; following this, complications may develop (pneumonia, endocarditis, haemolytic anaemia, meningitis, acute cholecystitis, osteomyelitis). Although the patient had been vaccinated, vaccines are unfortunately only between 30% and 70% effective. Treatment is with fluoroquinolones such as ciprofloxacin. Relapse is common, and the organism can persist in the gall bladder.

A Cytomegalovirus (CMV) infection

In immunocompetent individuals, CMV infection is usually asymptomatic. It can cause a flu-like illness, which may be complicated by Guillain–Barré syndrome or Bell's palsy. By the age of 60, around 80% of patients have been exposed to CMV, and it can be problematic if a patient later becomes immunosuppressed, for example, after transplantation or in human immunodeficiency virus (HIV)-infected patients. In such patients, it can cause colitis, severe retinitis, oesophagitis and central nervous system (CNS) disease. Treatment would be with ganciclovir. As this patient is not immunocompromised, the presentation does not fit with CMV, since it does not cause prolonged fevers or rashes in the immunocompetent.

B Epstein–Barr virus (EBV) infection

Rana Alnasser's screen

associated with Burkitt's lymphoma, nasopharyngeal carcinoma and oral hair leukoplakia.

C	*Plasmodium falciparum* malaria

Malaria is among the top important differential diagnoses in the returning traveller with prolonged fever; however, this patient has had three negative films, which rules out malaria. The incubation period of malaria does vary between species but tends to be at least 12 days, which would make it highly unlikely, given her prophylaxis covered this period.

E	Schistosomiasis

Schistosomiasis is a trematode infection, particularly associated with freshwater lakes in Africa and the Middle East. Acute infection is usually with cercarial dermatitis (swimmer's itch), which causes a self-limiting, itchy papular rash within 24 hours of exposure. Katayama fever (acute schistosomiasis) is less common and develops 4–8 weeks post-exposure and presents with fever, urticaria, eosinophilia and wheeze. This patient's presentation does not fit with the incubation period of swimmer's itch and does not have the features of acute schistosomiasis. Treatment of acute schistosomiasis would be with praziquantel and steroids.

Rate this question:

Next Question

Previous Q... Tag Questi... Feedback End Session

Rana Alnasser's screen

Calculator

Normal Values

A 42-year-old man comes to the Emergency Department with his male partner. He has had a headache for the past few days and now complains of worsening left arm weakness. His partner is also concerned that he is becoming increasingly confused.

On examination, he is pyrexial (37.8 °C) and his BP is 138/72 mmHg. There is 4/5 weakness of his left arm.

Investigations:

Hb	11.0 g/dl
WCC	4.4×10^9/l
PLT	201×10^9/l
Na^+	138 mmol/l
K^+	4.4 mmol/l
Creatinine	130 µmol/l
CSF	Elevated protein, mononuclear leucocytosis, opening pressure 18 cm H_2O
MRI head	Evidence of ventricular enlargement, possible developing right-sided infarct

owing is the most likely diagnosis?

Rana Alnasser's screen

PLT	201×10^9/l
Na^+	138 mmol/l
K^+	4.4 mmol/l
Creatinine	130 µmol/l
CSF	Elevated protein, mononuclear leucocytosis, opening pressure 18 cm H_2O
MRI head	Evidence of ventricular enlargement, possible developing right-sided infarct

Which of the following is the most likely diagnosis?

A	Toxoplasmosis
B	CMV encephalitis
C	Acute cerebral infarct
D	Cerebral vasculitis
E	Cryptococcal meningitis

Explanation

B CMV encephalitis

This man almost certainly has HIV and has developed a clinical picture consistent with CMV encephalitis. A mononuclear leukocytosis and raised CSF protein are typical. MRI findings are often non-specific, with evidence of ventricular enlargement, cerebral atrophy and, as in this case, a developing cerebral infarct. IV ganciclovir is the mainstay of therapy for CMV encephalitis, with long-term prophylaxis post-infection likely to be required. The diagnosis of HIV should also be confirmed, and he should start appropriate anti-retroviral therapy.

D Cerebral vasculitis

Cerebral vasculitis is inflammation of the blood vessels supplying the brain and spinal cord. It may be associated with a systemic vasculitis or occur in isolation. In our patient there is no history of vasculitis or other autoimmune disease and, although cerebral vasculitis should be in the differential diagnosis, an alternative option is more likely.

A Toxoplasmosis

Rana Alnasser's screen

A Toxoplasmosis

Toxoplasmosis is an infection caused by the protozoa *Toxoplasma gondii*, with primary infection resulting in a glandular fever syndrome. Reactivation in the immunocompromised can cause CNS disease with multiple ring enhancing lesions on MRI. In this case the MRI findings are not typical of toxoplasmosis, and an alternative diagnosis is more likely.

C Acute cerebral infarct

Acute cerebral infarct presents with sudden-onset neurological deficit associated with one single vascular territory, in contrast to the progressive and evolving neurology in our patient. In addition, the patient described has no apparent vascular risk factors. An alternative diagnosis is more likely.

E Cryptococcal meningitis

Cryptococcal meningitis is caused by the yeast *Cryptococcus neoformans*. In the immunocompromised it causes a meningitis. Typically CSF opening pressure is markedly elevated and examination reveals a lymphocytosis with low glucose. India Ink stain or the cyptococcal antigen test (CRAG) can be used on CSF to aid diagnosis.

Rate this question:

Rana Alnasser's screen

A 32-year-old single man presents to the clinic with his male flatmate. He complains of a rash on the left upper chest and has trouble with extensive papillary warts. He admits to weight loss of 2 stone over the course of the past year.

On examination, he has erythematous blistering rash in a dermatomal distribution, a number of pink macular lesions and extensive papillary warts. He is emaciated and there is evidence of cervical lymphadenopathy.

Which of the following is the most likely underlying diagnosis?

Calculator

Normal Values

A	HIV infection
B	Chronic myeloid leukaemia
C	Hodgkin's lymphoma
D	Acute lymphoblastic leukaemia
E	Herpes zoster infection

Explanation

A HIV infection

With this picture of weight loss, extensive papillary warts, pink macular lesions which may be Kaposi's sarcoma and herpes zoster infection, confirmatory HIV antibody testing is recommended, and measurement of CD4+ lymphocyte levels is useful in assessing risk of opportunistic infections. The overlying picture is that of several opportunistic infections without a known cause. Aciclovir is the treatment of choice for herpes zoster infection, and a number of topical treatments for viral warts are available. Retinoid gels may be of value in the management of Kaposi's sarcoma.

B Chronic myeloid leukaemia

Chronic myeloid leukaemia (CML) is a myeloproliferative disorder affecting one or all cell lines. Progression is characterised into a chronic phase, an accelerated phase, and finally blast crisis. Most patients present in the chronic phase with insidious symptoms of fatigue, weight loss and night sweats. Examination can reveal features of cell line disruption such as anaemia and bruising, but while lymphoadenopathy can occur it is not a major feature. It is not associated with immunodeficiency and would therefore not explain this patient's infections, and the age of presentation of CML is usually around 65 years old.

Rana Alnasser's screen

A 29-year-old woman was admitted with a 3-week history of oedema and intermittent paraesthesiae of her left leg. Two months earlier, she had had painful muscle cramps, first in her legs and later in her abdomen, and she had noticed her left leg was swelling and was intermittently numb and tingling. While working in Gabon 9 months previously, she had had extensive exposure to fresh water.

Calculator

Normal Values

On examination, she had 3-cm, non-tender hepatomegaly, without splenomegaly. Papular erythematous lesions were present on both legs, with pitting oedema of her left lower leg. Sensation to light touch over the left lower leg was reduced.

Investigations:

		Normal values
White cell count (WCC)	16.1×10^9/l	4.0–11.0
Lymphocytes	4.9×10^9/l	1.5–4.0
Neutrophils	5.9×10^9/l	1.5–7.0
Eosinophils	5.4×10^9/l	0.04–0.4
Haemoglobin (Hb)	13.4 g/dl	115–160
Platelets (PLT)	364×10^9/l	150–400

What is the most likely diagnosis?

Neutrophils	5.9×10^9/l	1.5–7.0
Eosinophils	5.4×10^9/l	0.04–0.4
Haemoglobin (Hb)	13.4 g/dl	115–160
Platelets (PLT)	364×10^9/l	150–400

What is the most likely diagnosis?

A Loiasis

B Malaria

C Schistosomiasis

D *Taenia solium*

E *Trichinella spiralis*

Submit

A 29-year-old woman was admitted with a 3-week history of oedema and intermittent paraesthesiae of her left leg. Two months earlier, she had had painful muscle cramps, first in her legs and later in her abdomen, and she had noticed her left leg was swelling and was intermittently numb and tingling. While working in Gabon 9 months previously, she had had extensive exposure to fresh water.

On examination, she had 3-cm, non-tender hepatomegaly, without splenomegaly. Papular erythematous lesions were present on both legs, with pitting oedema of her left lower leg. Sensation to light touch over the left lower leg was reduced.

Investigations:

		Normal values
White cell count (WCC)	16.1×10^9/l	4.0–11.0
Lymphocytes	4.9×10^9/l	1.5–4.0
Neutrophils	5.9×10^9/l	1.5–7.0
Eosinophils	5.4×10^9/l	0.04–0.4
Haemoglobin (Hb)	13.4 g/dl	115–160
Platelets (PLT)	364×10^9/l	150–400

Difficulty: Easy

Peer Responses %

Session Progress

Responses Correct:	2
Responses Incorrect:	2
Responses Total:	4

Responses -

Loa loa is a nematode causing filariasis. Classically it causes Calabar swellings – these are the erythematous papules visible across the patient's legs. Several months after the infection, it can cause temporary swelling of a limb due to blockage of lymphatic drainage. There can be numbness in the affected limb, as seen here. The hypereosinophilia found in this patient (> 1×10^9/l would be a significant eosinophilia) strongly suggests parasitic, and particularly filarial, infection.

E *Trichinella spiralis*

It is a nematode acquired by eating poorly cooked pork products. You would see eosinophilia, as found here, but clinically significant trichinellosis causes vomiting, diarrhoea and abdominal pain, then subsequently facial and peri-orbital oedema, malaise and fever. You would not expect it to cause leg swelling. These symptoms, signs and investigations could be better explained by loiasis.

B Malaria

Malaria does not cause unilateral leg swelling. A rash may be visible if there is disseminated intravascular coagulation in severe malaria, but it does not cause a maculopapular rash. You would not expect such a chronic, indolent course of illness if this were malaria, and these symptoms are not typical of a [illegible] Eosinophilia is uncommon in malaria. These symptoms, [illegible]

Rana Alnasser's screen

Touch to return to your call 01:14 9:47

not expect it to cause leg oedema and a widespread papular rash over the lower limbs, as seen here. These symptoms, signs and investigations could be better explained by loiasis.

D	*Taenia solium*

T. solium, also known as tapeworm, is usually transmitted through eating poorly cooked pork. Infection may be symptomatic or may cause diarrhoea, vomiting and abdominal pain. Occasionally, it can lead to cysticercosis where larvae travel to the brain, lung or eyes and can lead to neurological problems or sight impairment. However, it does not cause rashes or leg swelling; loiasis could explain this patient's symptoms and signs.

714 × 4

Rate this question:

Next Question

Previous Questi... Tag Question Feedback End Session

Blog About Pastest Contact Us Help

© Pastest 2019

Calculator

Normal Values

A 23-year-old man presents to Accident and Emergency Department. He is known to be HIV positive. His last outpatient appointment was several months ago and at that time his CD4 cell count was 210×10^6/l.

He did not attend his most recent scheduled appointment. He is on no regular medication and has no other medical problems. He presents with a 3-week history of increasing shortness of breath and dry cough.

On examination: T38.5, RR30/min, Sats 89% on air, heart rate 110 bpm. His chest is clear to auscultation. A chest X-ray reveals diffusely increased shadowing bilaterally. Arterial blood gas on air reveals a $p_a(O_2)$ 8.8 kPa, $p_a(CO_2)$ 3.5 kPa, bicarbonate 22 mmol/l, Sats 88%.

Which of the following is the most appropriate initial treatment?

A	Co-trimoxazole IV
B	Co-trimoxazole IV and antiretroviral therapy
C	Co-trimoxazole IV and methylprednisolone IV
D	Clindamycin and primaquine
E	Low molecular weight heparin

Annotation Stop Share

C Co-trimoxazole IV and methylprednisolone IV

The diagnosis is *Pneumocystis carinii* pneumonia (PCP) pneumonia caused by *Pneumocystis jirovecii* (previously called *carinii*). BHIVA guidelines recommend addition of methylprednisolone to IV co-trimoxazole when $p_a(O_2)$ <9.3 kPa (or <70 mmHg), as this is an indicator of severe disease. The BHIVA guidelines have provided criteria for further clarification of severity of PCP.

Table 3.2 Stratification of disease severity in PCP [149]

	Mild	Moderate*	Severe
Symptoms and signs	Dyspnoea on exertion with or without cough and sweats	Dyspnoea on minimal exertion and occasionally at rest; cough and fever with or without sweats	Dyspnoea and tachypnoea at rest; fever and cough
Oxygen PaO_2 room air, at rest in kPa (mmHg)	> 11.0 (>83)	8.1–11.0 (61–83)	≤ 8.0 (≤ 60)
SaO_2 at rest on air	>96	91–96	<91
Chest radiograph	Normal or minor perihilar shadowing	Diffuse interstitial shadowing	Extensive interstitial shadowing with or without diffuse alveolar shadowing

*Note: for treatment purposes moderate severity is grouped with severe disease if $PaO_2 \leq 9.3$kPa or mild disease if $PaO_2 > 9.3$kPa.

A Co-trimoxazole IV

This would be the correct answer if the patient did not have hypoxia as steroids are needed to acutely help relieve breathlessness. In mild disease oral treatment can be considered.

B Co-trimoxazole IV and antiretroviral therapy

$p_a(O_2)$ <9.3 kPa (or <70 mmHg), as this is an indicator of severe disease. BHIVA guidelines have provided criteria for further clarification of severit PCP.

Table 3.2 Stratification of disease severity in PCP [149]

	Mild	Moderate*	Severe
Symptoms and signs	Dyspnoea on exertion with or without cough and sweats	Dyspnoea on minimal exertion and occasionally at rest; cough and fever with or without sweats	Dyspnoea and tachypnoea at rest; fever and cough
Oxygen PaO_2 room air, at rest in kPa (mmHg)	>11.0 (>83)	8.1–11.0 (61–83)	≤8.0 (≤60)
SaO_2 at rest on air	>96	91–96	<91
Chest radiograph	Normal or minor perihilar shadowing	Diffuse interstitial shadowing	Extensive interstitial shadowing with o without diffuse alveolar shadowing

*Note: for treatment purposes moderate severity is grouped with severe disease if $PaO_2 \leq 9.3$kPa or mild disease if $PaO_2 > 9.3$kPa.

A Co-trimoxazole IV

This would be the correct answer if the patient did not have hypoxia as steroids are needed to acutely help relieve breathlessness. In mild diseas

Rana Alnasser's screen

Antiretroviral treatment will be needed and should be offered once the acute illness is treated.

D Clindamycin and primaquine

This combination is an option as second line treatment when co-trimoxazole fails.

E Low molecular weight heparin

PEs occur with a much higher incidence within the HIV-positive population and should always be considered in the differential diagnosis. However, in view of the high fever and chest X-ray changes, this is less likely.

8516

Rate this question:

Next Question

Rana Alnasser's screen

A 31-year-old male is admitted with behavioural changes. One month before admission, he was on holiday in North Tanzania. He was exposed to multiple bites from insects and he developed an erythematous swelling on his left ankle. He then developed intermittent fever, myalgia and headache and was given quinine by a local doctor, with little effect.

Over the last week, he has been sleeping most of the day and been up all night and has developed episodes of mania with rapid bursts of speech, followed by generalised apathy. He also complains of generalised headache with no blurred vision or change with posture, sneezing or coughing. He smokes 20 cigarettes/day and drinks alcohol at weekends, he has tried cannabis in the past and admits to occasional crack use, but his partner is not sure whether he has taken any recently.

On examination, he is agitated but afebrile. His pulse is 120/min and blood pressure 102/65 mmHg. His chest is clear and abdomen soft although there is generalised tenderness. On examination of his peripheral nerves there is a fine tremor in his upper limbs and increased tone throughout. He has generalised decreased power but reflexes are normal.

Investigations:

WC	$9.8 \times 10^9/l$

Investigations:

WCC	9.8×10^9/l
Hb	9.5 g/dl
MCV	82.1 fl
PLT	67×10^9/l
Total protein	84 g/l
Albumin	29 g/l
ALT	35 U/l
ALP	68 U/l
Bilirubin	9 μmol/l
Chest X-ray	normal
ECG	sinus tachycardia
Thick and thin films for malaria parasites	negative

Which investigation would be most appropriate as the next step, given the suspected diagnosis?

Rana Alnasser's screen

Thick and thin films for malaria parasites	negative

Which investigation would be most appropriate as the next step, given the suspected diagnosis?

A	Urgent computerised tomography (CT) of the brain
B	Blood culture
C	Psychiatry consultation
D	Serology
E	Serum electrophoresis

33189

Rana Alnasser's screen

A Urgent computerised tomography (CT) of the brain

This patient has *Trypanosoma brucei rhodesiense* (East African or Rhodesian African trypanosomiasis) infection. A number of tourists to game parks in northern Tanzania recently acquired East African trypanosomiasis, which is transmitted through the bite of the tsetse fly. This illness manifests as an erythematous swelling or chancre at the site of the fly bite 5–15 days later, fever, headache and myalgia, before it progresses to meningoencephalitis. The second phase often occurs after a few weeks or a month in East African trypanosomiasis, but can take longer than one year in the West African disease. It is manifested by persistent headaches, daytime somnolence followed by night-time insomnia and behavioural changes, mood swings and, in some patients, depression. In late disease the patient becomes comatose (i.e. sleeping sickness) and it can be fatal.

A computerised tomography (CT) of the head is required in order for a LP (lumbar puncture) to be performed. CT and magnetic resonance imaging (MRI) of the brain in late disease reveal cerebral oedema and white matter enhancement. Cerebrospinal fluid (CSF) investigations should always be performed in patients with parasitaemia or lymphadenopathy. The double centrifugation technique is the most sensitive method to detect trypanosomes. Other CSF findings include a high white cell count (WCC), elevated IgM and elevated protein levels.

The treatment of choice is suramin or eflornithine in stage 1 (chancre/fever/myalgia) disease and melarsoprol or eflornithine in stage 2

(central nervous system (CNS)/meningoencephalitic) stage.

D	Serology

There is no current serological test for East African trypanosomiasis, but there is serological testing for *T. gambiense*, which occurs in West and Central Africa. There is also serological testing for *T. cruzi*, American trypanosomiasis.

B	Blood culture

During the acute phase of the disease, trypanosomes are often detectable on smears of peripheral blood, but blood cultures would not be able to demonstrate any parasites.

C	Psychiatry consultation

There is plenty of evidence for organic disease such as low platelet count, high white cell count and abnormalities on physical examination that would require a physical cause to be sought before seeking a psychiatric explanation.

E	Serum electrophoresis

Rana Alnasser's screen

During the acute phase of the disease, trypanosomes are often detectable on smears of peripheral blood, but blood cultures would not be able to demonstrate any parasites.

C Psychiatry consultation

There is plenty of evidence for organic disease such as low platelet count, high white cell count and abnormalities on physical examination that would require a physical cause to be sought before seeking a psychiatric explanation.

E Serum electrophoresis

There is unlikely to be monoclonal expansion, this is unlikely to be a helpful investigation.

Rate this question:

Previous Questi... Tag Question Feedback End Session

A 39-year-old woman presented with a 10-day history of progressive pain on swallowing, such that she was unable to drink liquids. She had asthma for which she took corticosteroid inhaler therapy only.

On examination of her mouth, diffuse erythema was seen associated with white patches on the throat, soft palate and the posterior tongue.

What is the likely underlying diagnosis?

Calculator

Normal Values

A	Aphthous ulcers
B	Cytomegalovirus oesophagitis
C	Oropharyngeal candidiasis
D	Quinsy
E	Vincent's angina

6819

Submit

Annotation

Stop Share

Explanation

C	Oropharyngeal candidiasis

This patient is taking daily corticosteroid inhalers, which are a significant risk factor for developing oropharyngeal candidiasis. The oral appearance is typical, and it can be very painful and interfere with fluid intake. Oral fluconazole is the intervention of choice.

A	Aphthous ulcers

Aphthous ulcers can cause pain in the mouth, but should not extend to the oesophagus and cause pain on swallowing. Furthermore, aphthous ulcers do not appear as white plaques. This patient is more likely to have oropharyngeal candidiasis, likely as a consequence of inhaled steroids.

B	Cytomegalovirus oesophagitis

Oesophagitis is the second most common complication of CMV infection, after colitis; however it is extremely unlikely in an immunocompetent patient. This patient is much more likely to have oropharyngeal candidiasis as a consequence of using inhaled steroids.

D	Quinsy

A Aphthous ulcers

Aphthous ulcers can cause pain in the mouth, but should not extend to the oesophagus and cause pain on swallowing. Furthermore, aphthous ulcers do not appear as white plaques. This patient is more likely to have oropharyngeal candidiasis, likely as a consequence of inhaled steroids.

B Cytomegalovirus oesophagitis

Oesophagitis is the second most common complication of CMV infection, after colitis; however it is extremely unlikely in an immunocompetent patient. This patient is much more likely to have oropharyngeal candidiasis as a consequence of using inhaled steroids.

D Quinsy

A quinsy is a tonsillar abscess, which is not how this patient has presented. Classically patients with quinsy have severe throat pain and difficulty swallowing, with trismus. Quinsy could not explain the white patches in this patient's mouth; this patient has oropharyngeal candidiasis caused by

swallowing, with trismus. Quinsy could not explain the white patches in this patient's mouth; this patient has oropharyngeal candidiasis caused by inhaled corticosteroids.

E	Vincent's angina

Vincent's angina is a pharyngeal infection with an ulcerative gingivitis from *Borrelia vincentii* and *Fusiformis fusiformis*. It was common in the First World War when it was known as 'trench mouth'. This patient does not have gingivitis or necrotising lesions – she has white plaques that are consistent with oropharyngeal candidiasis, which is probably caused by her inhaled corticosteroids.

Rate this question:

Previous Questi... Tag Question Feedback End Session

© Pastest 2019

A 32-year-old woman attends the Genito-urinary Medicine (GUM) Clinic. She is concerned about vaginal discharge with an unpleasant smell. She has noticed these symptoms for the past 3 weeks and has been washing her genitals regularly with soap and shower gel. She sometimes puts Dettol in her bath. She is married and has had no other sexual partners for 5 years.

On examination, she has a normal vulva, vagina and cervix. There is a thin, white discharge with a fishy smell.

Which is the most likely diagnosis?

A	*Candida*
B	Bacterial vaginosis
C	*Trichomonas*
D	*Chlamydia*
E	HIV +ve

Calculator

Normal Values

Rana Alnasser's screen

Annotation Stop Share

A 32-year-old woman attends the Genito-urinary Medicine (GUM) Clinic. She is concerned about vaginal discharge with an unpleasant smell. She has noticed these symptoms for the past 3 weeks and has been washing her genitals regularly with soap and shower gel. She sometimes puts Dettol in her bath. She is married and has had no other sexual partners for 5 years.

On examination, she has a normal vulva, vagina and cervix. There is a thin, white discharge with a fishy smell.

Which is the most likely diagnosis?

Your answer was correct

A *Candida*

B Bacterial vaginosis

C *Trichomonas*

D *Chlamydia*

Difficulty: Easy

Peer Responses %

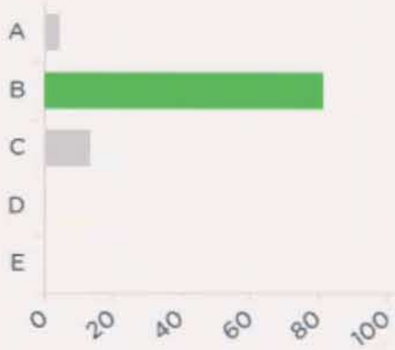

Session Progress

Responses Correct:	4
Responses Incorrect:	4
Responses Total:	8
Responses - % Correct:	50%

Rana Alnasser's screen

B Bacterial vaginosis

Bacterial vaginosis (BV) is caused by replacement of the usual vaginal lactobacilli with anaerobic bacteria, genital mycoplasmas and others. Douching, washing with scented soaps and gels have been implicated and the patient should be advised to stop these practices. Treatment is with metronidazole. BV is not sexually transmitted. BV is the commonest cause of abnormal vaginal discharge in women of childbearing age. It is twice as common as vaginal candidiasis. The prevalence of BV has varied from 5% in asymptomatic college students, 12% in pregnant women and 30% in women undergoing termination of pregnancy.

A *Candida*

Candida causes a severe itch and white lumpy discharge, which would commonly be seen on examination. Vulvovaginal candidiasis is the second most common cause of vaginitis and vaginal discharge after BV: the lifetime incidence of vulvovaginal candidiasis is estimated at 50–75%. The prevalence of vulvovaginal candidiasis is not known, but the disease is diagnosed in 5–15% of women who attend sexually transmitted disease and family planning clinics

C *Trichomonas*

clinics

C *Trichomonas*

Trichomonas gives an itch, offensive green discharge and is sexually transmitted. In 1997, GUM clinics in the UK reported over 5600 cases of trichomoniasis in women and 250 cases in men.

D *Chlamydia*

Women present with dysuria, abdominal pain, intermenstrual or postcoital bleeding and vaginal discharge. Men can have urethritis with dysuria and discharge and sometimes epididymo-orchitis.

E HIV +ve

This is very unlikely given the lack of exposure and HIV does not cause vaginal discharge.

Rate this question:

Next Question

A 32-year-old, HIV-positive man is brought to the Emergency Department by his partner, who has noticed increasing confusion over the past four weeks. The patient has been non-compliant with his antiretroviral therapy and has not attended outpatient clinic for over six months. The patient denies any headache or neurological symptoms but scores 0/10 on the Mental Test Score.

Calculator

Normal Values

Neurological examination reveals some past pointing and dysdiadochokinesis on the left but nil else. The patient is afebrile. Computed tomography (CT) of the head with contrast demonstrates no focal lesions.

Cerebrospinal fluid (CSF) results:

Protein	0.8 g/l
Glucose (plasma)	4.8 (5.2) mmol/l
Cryptococcal antigen (CRAG)	Negative
WCC	2 cell/mm^3
Red blood cells (RBC)	4 cell/mm^3
Microscopy	No organisms seen

Which treatment is most likely to improve the symptoms?

A. Sulfadiazine and pyrimethamine

Rana Alnasser's screen

Protein	0.8 g/l
Glucose (plasma)	4.8 (5.2) mmol/l
Cryptococcal antigen (CRAG)	Negative
WCC	2 cell/mm^3
Red blood cells (RBC)	4 cell/mm^3
Microscopy	No organisms seen

Which treatment is most likely to improve the symptoms?

A Sulphadiazine and pyrimethamine

B Highly active antiretroviral therapy (HAART)

C IV ganciclovir

D IV aciclovir

E High-dose fluconazole

Rana Alnasser's screen

B Highly active antiretroviral therapy (HAART)

The most likely diagnosis is progressive multifocal leukoencephalopathy (PML). PML is a unique demyelinating disease which usually occurs in a person with abnormal immune responses resulting from serious disease, treatment with cytotoxic drugs or irradiation, or long-term immunosuppression. The pathology of PML is distinctive and consists of multiple foci of demyelination of varying size from pinpoint lesions to areas of several centimetres. The lesions may occur anywhere but are usually in the cerebral hemispheres, less often in the cerebellum and brainstem and rarely in the spinal cord. Typically, PML evolves gradually, with impairment of mental function and disturbance of speech and vision. Movement may also be affected. The disease then progresses rapidly and the patient is severely disabled, eventually becoming demented, blind and paralysed, and finally there is coma and death. Almost any neurological sign can be part of the clinical spectrum, motor sensory or cerebellar signs depending on the white matter areas affected. Often nothing is seen on CT, and magnetic resonance imaging (MRI) is a much more useful modality in this condition.

PML generally occurs only at low CD4 counts and there is no specific therapy. PCR for JC virus, a polyomavirus and the causative organism, should be performed. Commencing HAART can improve symptoms in some patients, although some can deteriorate. It is inevitably progressive. Another possibility is HIV-associated encephalopathy, where the HIV virus itself is responsible for the pathology. HAART is also the treatment of choice for this.

treatment with cytotoxic drugs or irradiation, or long-term immunosuppression. The pathology of PML is distinctive and consists of multiple foci of demyelination of varying size from pinpoint lesions to areas of several centimetres. The lesions may occur anywhere but are usually in the cerebral hemispheres, less often in the cerebellum and brainstem and rarely in the spinal cord. Typically, PML evolves gradually, with impairment of mental function and disturbance of speech and vision. Movement may also be affected. The disease then progresses rapidly and the patient is severely disabled, eventually becoming demented, blind and paralysed, and finally there is coma and death. Almost any neurological sign can be part of the clinical spectrum, motor sensory or cerebellar signs depending on the white matter areas affected. Often nothing is seen on CT, and magnetic resonance imaging (MRI) is a much more useful modality in this condition.

PML generally occurs only at low CD4 counts and there is no specific therapy. PCR for JC virus, a polyomavirus and the causative organism, should be performed. Commencing HAART can improve symptoms in some patients, although some can deteriorate. It is inevitably progressive. Another possibility is HIV-associated encephalopathy, where the HIV virus itself is responsible for the pathology. HAART is also the treatment of choice for this. The clinical details do not suggest neurological toxoplasmosis, cytomegalovirus (CMV), herpes simplex virus (HSV) or cryptococcal meningitis, so the other answers are incorrect.

A Sulphadiazine and pyrimethamine

A 36-year-old man with known HIV is admitted with increasing shortness of breath. He is on antiretroviral medications.

On examination, he has raised jugular venous pressure (JVP), bilateral lower limb oedema and crackles on both bases. BP is 105/60 mmHg, pulse 95/min.

Calculator

Normal Values

Investigations:

Hb	11.4 g/dl
WCC	5.4×10^9/l
PLT	156×10^9/l
Na^+	138 mmol/l
K^+	4.3 mmol/l
Creatinine	140 µmol/l
CD4 count	235 cells/mm^3
Chest X-ray	Evidence of left ventricular failure
Echocardiography	Severe dilated cardiomyopathy
Ejection fraction	24%

Rana Alnasser's screen

Annotation

Stop Share

CD4 count	235 cells/mm^3
Chest X-ray	Evidence of left ventricular failure
Echocardiography	Severe dilated cardiomyopathy
Ejection fraction	24%

What is the most likely cause of his problem?

A	Cytomegalovirus
B	Toxoplasmosis
C	Influenza
D	Zidovudine
E	Ritonavir

Annotation Stop Share

Explanation

D	Zidovudine

Zidovudine (AZT) is a nucleoside reverse transcriptase inhibitor and was the first drug licensed for treatment of HIV. It has significant mitochondrial toxicity and is known to be associated with dilated cardiomyopathy. In patients such as this, myocardial biopsy usually reveals mitochondria full of myelin, a sign of mitochondrial dysfunction. Withdrawal of zidovudine and substitution with an agent associated with less mitochondrial toxicity, coupled with appropriate treatment for heart failure with diuretics and ACE inhibition, usually resolves the problem, although HIV itself is decreasingly recognised as a cause of cardiomyopathy.

A	Cytomegalovirus

Cytomegalovirus (CMV) is a member of the herpes virus family (HHV 5). It typically causes a glandular fever syndrome, but presentation is varied and in the immunocompromised host disease can be severe. CMV can cause a cardiomyopathy, but this is rare and an alternative explanation is more probable in our patient.

Rana Alnasser's screen

Annotation Stop Share

may result in a flu-like illness, but is more commonly asymptomatic. In the immunocompromised it may cause an encephalitis. The presentation described does not fit with toxoplasmosis.

C	Influenza

Influenza is a virus responsible for flu. Infection is characterised by upper respiratory symptoms, as well as fever and muscle aches. Myocarditis is a possible but uncommon sequalae of influenza infection. In the patient described above, an alternative diagnosis is more likely.

E	Ritonavir

Ritonavir is a protease inhibitor now used at low dose in combination with other protease inhibitors to boost their potency. Serious side effects include hepatitis, pancreatitis and arrhythmia. Its use is not associated with myocarditis.

Rate this question:

Next Question

Annotation Stop Share

A 32-year-old man presented with a 6-month history of general malaise, lethargy and difficulty swallowing with some occasional regurgitation of undigested food. He had been living in Bolivia for 6 years as a relief worker.

On examination, his blood pressure was 110/70 mmHg, his pulse was 95 bpm and his jugular venous pulse was elevated. He had bilateral basal inspiratory crackles on auscultation of the chest, and bilateral pitting leg oedema.

Barium swallow revealed a dilated oesophagus.

Which of the following is the most likely causative organism?

A	*Borrelia burgdorferi*
B	*Entamoeba histolytica*
C	*Leishmania donovani*
D	*Rickettsia rickettsi*
E	*Trypanosoma cruzi*

Calculator

Normal Values

Annotation

Stop Share

71033

Explanation

E	*Trypanosoma cruzi*

This parasite is spread via the faeces of the reduviid bug, which is left on the skin after the bug feeds and can enter the bloodstream after scratching or rubbing the skin in response to the insect bite. *Trypanosoma cruzi* causes Chagas' disease. The acute phase of Chagas' disease manifests as constitutional symptoms and facial or generalised oedema, and there may be diarrhoea and vomiting, or ECG changes. This is followed by a latent phase and then a chronic phase; this patient has presented in the chronic phase with mega-oesophagus, which is characteristic of Chagas' disease. Patients may also have megacolon, congestive heart failure and arrhythmias. Diagnosis is by serology, and the patient should have an ECG and echocardiogram to check for cardiac complications. Patients in the chronic phase can be treated with nitroheterocycles if they have been infected for less than 10 years, as in this case.

A	*Borrelia burgdorferi*

Borrelia burgdorferi is the causative bacterium of Lyme disease. It is not found in tropical climates, and therefore is unlikely to be the cause of this patient's symptoms. Furthermore, Lyme disease has a variety of stages and

Annotation Stop Share

A *Borrelia burgdorferi*

Borrelia burgdorferi is the causative bacterium of Lyme disease. It is not found in tropical climates, and therefore is unlikely to be the cause of this patient's symptoms. Furthermore, Lyme disease has a variety of stages and manifestations, but it does not cause mega-oesophagus, as seen in this patient. Instead, this patient's travel history and presentation is more consistent with Chagas' disease, which is caused by infection with the parasite *Trypanosoma cruzi*, transmitted by the faeces of the kissing bug, left on the skin after the insect has fed.

B *Entamoeba histolytica*

Entamoeba histolytica is very common in South America where it causes amoebic dysentery, and can also affect the liver. It does not cause mega-oesophagus, as seen in this patient. This patient's travel history, combined with his signs and symptoms, would be consistent with a diagnosis of Chagas' disease, which is caused by *Trypanosoma cruzi* infection.

C *Leishmania donovani*

This organism causes visceral leishmaniasis and is found in India and Africa, but it is not native to South America. Furthermore, visceral leishmaniasis has

Annotation Stop Share

Calculator

Normal Values

A 21-year-old man presented with a 1-week history of malaise and arthralgia, and a non-itchy red rash all over his body, particularly his lower legs. Two days before he presented, his right knee became increasingly red, swollen and painful with extreme limitation of movement. He had no other past medical history.

On examination he had a temperature of 38.5 °C, and pulse rate was 105 bpm. He had an erythematous maculopapular rash formed of small (< 5 mm) lesions in the distribution mentioned above. His right knee was swollen, erythematous and exquisitely painful with a large effusion. On examination of the other joints, there was some evidence of tenosynovitis at the wrists.

His right knee joint was aspirated and a turbid yellow fluid was removed.

What is most likely to be seen on microscopy?

A	High numbers of neutrophils
B	Gram-negative diplococcic
C	Gram-positive cocci
D	Negatively birefringent needle-shaped crystals
E	Positively birefringent needle-shaped crystals

Rana Alnasser's screen

Explanation

A High numbers of neutrophils

This patient clearly has a septic arthritis of the right knee. The history is classic for gonococcal septic arthritis, with malaise caused by disseminated gonococcal infection and a triad of tenosynovitis, arthritis and dermatitis. This is followed by a localised phase where the arthritis can either resolve spontaneously (as in 40–60% of cases) or develop into a septic arthritis. However, organisms are seen in the joint aspirate in less than 25% of cases: it is far more common simply to find turbid fluid and a large number of neutrophils. The aspirate and blood should be cultured. Clearly, intravenous antibiotics are needed for this degree of sepsis and joint involvement. There is significant resistance of gonorrhoea to penicillin and ciprofloxacin, and therefore ceftriaxone is the treatment of choice. Examination of the joint and wash-out under anaesthetic is also indicated.

B Gram-negative diplococcic

You may have identified that this patient has a history consistent with gonococcal septic arthritis: however, organisms are seen in joint aspirates in less than 25% of cases and it is far more likely that the aspirate will be turbid and reveal neutrophils alone. The malaise and triad of tenosynovitis, arthritis and dermatitis (as seen in this patient) is caused by a bacteraemic phase. There is then a localised phase where either the arthritis resolves spontaneously or patients develop a septic arthritis, as seen here.

Annotation Stop Share

Calculator

Normal Values

A 24-year-old man with type 1 diabetes comes to the Emergency Department with severe earache and discharge. He has recently returned from a holiday in the Dominican Republic where he regularly swam in the hotel pool.

He saw his general practitioner (GP) 1 week early and was prescribed co-amoxiclav, but his girlfriend thinks that the problem is getting worse and she can now see the infection around his ear.

On examination, he appears to have a severe otitis externa with a discharge, and evidence of spreading superficial skin infection.

Which of the following represents the most likely infectious agent?

A	Staphylococcus aureus
B	Staphylococcus epidermidis
C	Pseudomonas aeruginosa
D	Streptococcus pneumoniae
E	Streptococcus pyogenes

Rana Alnasser's screen

Explanation

C Pseudomonas aeruginosa

This man has presented with so called "Swimmer's Ear" due to pseudomonas infection which may have occurred via the swimming pool at the hotel where he was staying. Pseudomonas is the cause of swimmer's ear and is not responsive to co-amoxiclav therapy. Severe spreading infections occur more commonly in patients who also suffer from diabetes mellitus, as in this case. Therapy may involve a combination of systemic and locally delivered antibiotic therapy, and in this case an ENT surgical opinion should sought.

A Staphylococcus aureus

S. aureus is a gram-positive commensal pathogen which can cause infection of skin, eyelids and wounds. In severe infections can cause pneumonia, osteomyelitis, endocarditis and septic arthritis. The toxins can cause food poisoning and toxic shock syndrome. *S. aureus* is unlikely to cause infection, and unlikely to be acquired by swimming in a swimming pool.

B Staphylococcus epidermidis

S. epidermidis is a coagulase negative species of Staphylococcus. These species are only pathogenic if associated with immunosuppression or insertion of foreign objects such as following hip replacements. These bacteria are likely to cause otitis externa in an immunosuppressed individual.

A Staphylococcus aureus

S. aureus is a gram-positive commensal pathogen which can cause infection of skin, eyelids and wounds. In severe infections can cause pneumonia, osteomyelitis, endocarditis and septic arthritis. The toxins can cause food poisoning and toxic shock syndrome. *S. aureus* is unlikely to cause infection, and unlikely to be acquired by swimming in a swimming pool.

B Staphylococcus epidermidis

S. epidermidis is a coagulase negative species of Staphylococcus. These species are only pathogenic if associated with immunosuppression or insertion of foreign objects such as following hip replacements. These bacteria are likely to cause otitis externa in an immunosuppressed individual.

D Streptococcus pneumoniae

Streptococci are gram-positive diplococci, of which *S. pneumoniae* cases pneumonia, meningitis and otitis media. The clinical finding of otitis externa makes this a less likely pathogen.

E Streptococcus pyogenes

S. pyogenes is s group A Streptococcus, referring to the Lancefield classification by degree of heamolysis. These species cause wound and skin infections, including impetigo and erysipelas, and are also associated with tonsillitis, scarlet fever and rheumatic fever.

Calculator

Normal Values

A 19-year-old student who has been travelling in Thailand presents for review with symptoms of severe influenza. He has made a point of visiting street markets and staying in small local Thai hostels during his visit. You understand that a father and son who work in the poultry market near to where he has been staying recently died of H5N1 influenza. Both were treated with oseltamivir.

On examination, his blood pressure is 105/70 mmHg, pulse is 100 bpmn. He is pyrexial at 38.5 °C. He has severe shortness of breath and there are scattered crackles throughout both lung fields.

Investigations:

Hb	14.0 g/dl
WCC	10.1×10^9/l
PLT	295×10^9/l
Na^+	140 mmol/l
K^+	5.0 mmol/l
Creatinine	130 µmol/l
Chest X-ray	Patchy consolidation through both lung fields

Which of the following represents the most appropriate treatment?

A IV Cefotaxime

Investigations:

Hb	14.0 g/dl
WCC	10.1×10^9/l
PLT	295×10^9/l
Na^+	140 mmol/l
K^+	5.0 mmol/l
Creatinine	130 µmol/l
Chest X-ray	Patchy consolidation through both lung fields

Which of the following represents the most appropriate treatment?

A	IV Cefotaxime
B	Inhaled zanamivir
C	Oral amantadine
D	Oral co-amoxiclav
E	Oral oseltamivir

B Inhaled zanamivir

Zanamavir is a neuraminidase inhibitor shown to reduce the associated morbidity in severe influenza. It can be delivered by inhalation or intravenously. In this case the patient is at high risk of avian influenza (H5N1) and we have been told that two other patients died despite treatment with oseltamivir. There is less known resistance to zanamavir and therefore this should be the treatment of choice.

E Oral oseltamivir

Oseltamivir is a neuraminidase inhibitor shown to reduce the morbidity associated with severe influenza. However there is recognised resistance to oseltamivir and we are told that two patients have died despite its use. Zanamivir would therefore be a more appropriate choice as resistance is less likely.

A IV Cefotaxime

Cefotaxime is a broad spectrum third- generation cephalosporin with activity against both Gram-positive and Gram-negative bacteria. Although in this scenario it would be prudent to cover for potential bacterial pneumonia, this patient is at very high risk of avian influenza and the blood picture would be more typical of a viral infection; therefore the definitive treatment of choice should be an antiviral with activity against influenza.

C Oral amantadine

69% 20:27
MyPastest
https://mypastest.pastest.com

A 22-year-old woman presented with a 12-h history of fever, vomiting, diarrhoea and severe myalgia. Three days ago she had completed a 3-day course of oral trimethoprim for a urinary tract infection. She took the oral contraceptive pill, and her last menstrual period had ended the previous day.

On examination, her temperature was 39.5 °C, pulse rate 130 bpm and blood pressure 72/40 mmHg. There was no nuchal rigidity or photophobia. There was a diffuse macular erythrodermic rash on the trunk and lower limbs, and marked tenderness of the thigh muscles. She had diffuse abdominal tenderness. Neurological examination was normal.

Calculator

Normal Values

Investigations:

Blood cultures	No growth in two samples after 48 h
Urine cultures	No growth

What is the most likely diagnosis?

A Bacterial meningitis

B Gastroenteritis

nal abscess

Rana Alnasser's screen

course of oral trimethoprim for a urinary tract infection. She took the oral contraceptive pill, and her last menstrual period had ended the previous day.

Normal Values

On examination, her temperature was 39.5 °C, pulse rate 130 bpm and blood pressure 72/40 mmHg. There was no nuchal rigidity or photophobia. There was a diffuse macular erythrodermic rash on the trunk and lower limbs, and marked tenderness of the thigh muscles. She had diffuse abdominal tenderness. Neurological examination was normal.

Investigations:

Blood cultures	No growth in two samples after 48 h
Urine cultures	No growth

What is the most likely diagnosis?

A Bacterial meningitis

B Gastroenteritis

C Renal abscess

D Toxic shock syndrome

E Ulcerative colitis

A 22-year-old woman presented with a 12-h history of fever, vomiting, diarrhoea and severe myalgia. Three days ago she had completed a 3-day course of oral trimethoprim for a urinary tract infection. She took the oral contraceptive pill, and her last menstrual period had ended the previous day.

On examination, her temperature was 39.5 °C, pulse rate 130 bpm and blood pressure 72/40 mmHg. There was no nuchal rigidity or photophobia. There was a diffuse macular erythrodermic rash on the trunk and lower limbs, and marked tenderness of the thigh muscles. She had diffuse abdominal tenderness. Neurological examination was normal.

Investigations:

Blood cultures	No growth in two samples after 48 h
Urine cultures	No growth

What is the most likely diagnosis?

Your answer was correct

A Bacterial meningitis

Difficulty: Average

Peer Responses %

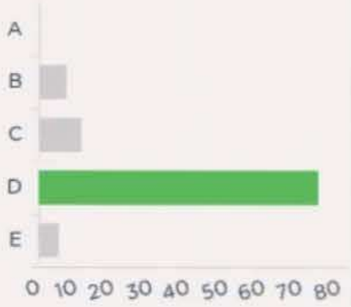

Session Progress

Responses Correct:	9
Responses Incorrect:	6
Responses Total:	15
Responses % Correct:	60%

D Toxic shock syndrome

This is a typical presentation of toxic shock syndrome, in this case, most probably caused by a retained tampon. The patient is in shock, with a high fever, myalgia and erythroderma. The profound hypotension is due to direct inhibition of myocardial contractility by the exotoxin. It is common for blood cultures to be negative in toxic shock syndrome; high vaginal swabs may be positive for *Staphylococcus*.

A Bacterial meningitis

The patient does not have any signs of meningism, does not complain of headache, and meningitis could not explain this rash. Instead, this patient's presentation is more suggestive of toxic shock syndrome, caused by a retained tampon, leading to release of staphylococcal exotoxin (TSST-1). This would explain the high fever, myalgia and rash in the presence of sterile blood and urine cultures.

B Gastroenteritis

This patient is in shock, with high fever, myalgia and a rash; this picture does not fit with a gastroenteritis. This would be more typical for toxic shock syndrome caused by staphylococcal exotoxin (TSST-1), as a result of a retained tampon.

cultures to be negative in toxic shock syndrome; high vaginal swabs may be positive for *Staphylococcus*.

A Bacterial meningitis

The patient does not have any signs of meningism, does not complain of headache, and meningitis could not explain this rash. Instead, this patient's presentation is more suggestive of toxic shock syndrome, caused by a retained tampon, leading to release of staphylococcal exotoxin (TSST-1). This would explain the high fever, myalgia and rash in the presence of sterile blood and urine cultures.

B Gastroenteritis

This patient is in shock, with high fever, myalgia and a rash; this picture does not fit with a gastroenteritis. This would be more typical for toxic shock syndrome caused by staphylococcal exotoxin (TSST-1), as a result of a retained tampon.

C Renal abscess

You might expect specific flank tenderness, and a ballotable kidney, if there was a renal abscess. Instead this patient has diffuse abdominal tenderness, erythroderma, high fever and myalgia. This is more fitting with toxic shock syndrome, caused by the release of staphylococcal exotoxin (TSST-1) as a result of a retained tampon.

A 36-year-old Ghanaian man presents to a sexual health clinic for a routine screen. He moved from Ghana 2 months ago and has no previous medical problems. He is found to be HIV positive with a CD4 count of 40 × 10^6/l, viral load 25 000, toxoplasma immunoglobulin G (IgG) positive, IgM negative, cryptococcal antigen negative.

He is referred to the HIV Clinic where he is commenced on antiretroviral therapy with tenofovir, 3TC and efavirenz. Three weeks later, he presents extremely unwell with 5 kg weight loss, drenching night sweats and malaise.

What is the most likely diagnosis?

Calculator

Normal Values

A	Adverse reaction to co-trimoxazole
B	Immune reconstitution syndrome
C	Drug side-effect of HAART
D	Disseminated cryptococcosis
E	Non-Hodgkin's lymphoma

Annotation Stop Share

Explanation

B	Immune reconstitution syndrome

The answer is Immune reconstitution syndrome -

Some patients after starting antiretroviral therapy will develop an exacerbation of symptoms, signs, or radiological manifestations of tuberculosis. This has been well described in patients without HIV infection who have a period of depressed immunity, but it appears to occur more commonly in HIV-positive patients. The aetiology of these reactions is unknown, but it is presumed in HIV disease that they occur at least in part as a consequence of antiretroviral therapy related reconstitution of immunity leading to an abnormal immune response to tubercle antigens released by dead or dying bacilli. These reactions do not have a widely accepted definition. They are characterised by worsening or appearance of new signs, symptoms, or radiographic manifestations of tuberculosis that occur after initiation of antiretroviral therapy, and are not the direct result of TB treatment failure or another disease process. Immune reconstitution syndromes (IRIS) can also occur with other infections such as cytomegalovirus (CMV) and toxoplasmosis.

A	Adverse reaction to co-trimoxazole

Co-trimoxazole is incorrect, it can cause nausea, vomiting, diarrhoea, abdominal pain, urticaria and general weakness. However, side-effects would be expected much sooner when starting treatment and would not explain the fevers or night sweats.

A 36-year-old Ghanaian man presents to a sexual health clinic for a routine screen. He moved from Ghana 2 months ago and has no previous medical problems. He is found to be HIV positive with a CD4 count of 40 × 10^6/l, viral load 25 000, toxoplasma immunoglobulin G (IgG) positive, IgM negative, cryptococcal antigen negative.

He is referred to the HIV Clinic where he is commenced on antiretroviral therapy with tenofovir, 3TC and efavirenz. Three weeks later, he presents extremely unwell with 5 kg weight loss, drenching night sweats and malaise.

What is the most likely diagnosis?

Your answer was correct

A	Adverse reaction to co-trimoxazole
B	Immune reconstitution syndrome
C	Drug side-effect of HAART
D	Disseminated cryptococcosis
E	Hodgkin's lymphoma

Difficulty: Easy

Peer Responses %

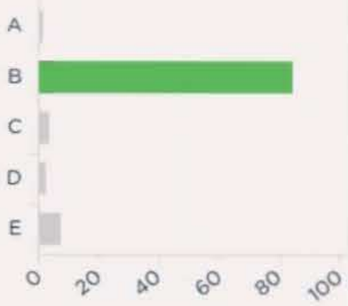

Session Progress

Responses Correct:	10
Responses Incorrect:	6
Responses Total:	16
Responses - % Correct:	63%

Rana Alnasser's screen

Calculator

Normal Values

A 31-year-old intravenous drug user attends the Genitourinary Clinic for an asymptomatic screen. His syphilis serology reveals positive TPHA (*Treponema pallidum* haemagglutination test), negative RPR (rapid plasma reagin). He denies having been previously treated for syphilis and is prescribed a course of intramuscular (IM) procaine penicillin which is administered by a nurse in clinic.

Within 1 minute of receiving the injection, the patient becomes acutely agitated, leaping off the couch and throwing the trolley across the room. He is not amenable to reasoning and is crying out, apparently experiencing visual hallucinations. Eventually, he is restrained by the security staff.

What is the explanation for this behaviour?

A	Jarisch–Herxheimer reaction
B	Procaine reaction
C	Acute opiate withdrawal
D	Anaphylaxis
E	Paranoid schizophrenia

administered by a nurse in clinic.

Within 1 minute of receiving the injection, the patient becomes acutely agitated, leaping off the couch and throwing the trolley across the room. He is not amenable to reasoning and is crying out, apparently experiencing visual hallucinations. Eventually, he is restrained by the security staff.

What is the explanation for this behaviour?

Your answer was incorrect

A	Jarisch–Herxheimer reaction
B	Procaine reaction
C	Acute opiate withdrawal
D	Anaphylaxis
E	Paranoid schizophrenia

Session Progress

Responses Correct:	10
Responses Incorrect:	7
Responses Total:	17
Responses - % Correct:	59%

Explanation

B	Procaine reaction

E Paranoid schizophrenia

Explanation

B Procaine reaction

The procaine reaction occurs when procaine penicillin is accidentally given intravenous (IV) rather than intramuscular (IM). It results in an instantaneous feeling of impending doom with delusions and hallucinations. Patients often need restraining. The process is self-limiting within 20 minutes. Occasionally the patient may have a seizure, which should be terminated with IV or PR diazepam.

A Jarisch-Herxheimer reaction

A Jarisch-Herxheimer reaction is a systemic reaction to endotoxin-like products that are released when bacteria are destroyed during antibiotic treatment. It has been documented to occur with treatment of syphilis, Lyme disease, leptospirosis and relapsing fever. It occurs 1-12 hours following the first antibiotic dose and is not seen with subsequent treatment. It causes malaise, pyrexia, flushing and tachycardia. This can be followed by hypotension due to peripheral vasodilatation. While this reaction is most commonly associated with syphilis, the timing is too early and the clinical picture does not match.

C Acute opiate withdrawal

Calculator

Normal Values

A 29-year-old man presented with a 5-day history of increasing shortness of breath, cough and wheeze. He also complained of a rash, which appeared over the preceding 7 days. He had been travelling extensively in Cambodia.

On examination, he was pyrexial at 37.8 °C and had a linear erythematous rash over his groin and buttocks. He had an audible wheeze on auscultation of his chest.

Investigations:

Hb	124 g/dl (130–180)
WCC	10.0×10^9/l (4.0–11.0)
Eosinophils	1.9×10^9/l (0.04–0.4)
CXR	Diffuse pulmonary infiltrates

What is the most appropriate treatment?

A Artesunate

B Hydrocortisone

C Ivermectin

D Metronidazole

Rana Alnasser's screen

Explanation

C	Ivermectin

This patient has strongyloidiasis, a common infection in South East Asian countries such as Cambodia, and is caught by contact between bare skin and contaminated soil. *Strongyloides* is a parasitic roundworm that causes a linear skin rash, larva currens, which advances as the parasites move under the skin. The wheeze described here is Loeffler syndrome, caused by the migration of the filarial larvae towards the lungs. It can also cause gastrointestinal upset. Strongyloidiasis explains the significant eosinophilia seen in this patient. Diagnosis can be challenging and is usually achieved by finding larvae in the stool. Ivermectin is the appropriate treatment, and albendazole can be used as a second-line agent. All patients should be treated to avoid the risk of hyper-infection syndrome, where huge numbers of larvae cause pulmonary haemorrhage and migrate to organs that are not usually involved, such as the brain and liver.

A	Artesunate

Artesunate is a treatment for malaria: there is nothing in the history or investigations here to suggest this patient has malaria. His wheeze and linear rash, after travel to Cambodia, is typical for strongylodiasis. This is a parasitic roundworm (hence the high eosinophil count) which causes larva currens (a linear rash caused by the entry and migration of the worm) and Loeffler syndrome: wheeze and breathless as the larvae migrate to the lungs.

A 50-year-old woman presented with severe vomiting, non-bloody diarrhoea and abdominal cramps. These began 6 h after eating a meat pie which she had bought the day before and left out on the counter in her kitchen.

On examination, her blood pressure was 110/70 mmHg, pulse was 92 bpm and she appeared dehydrated.

Calculator

Normal Values

Investigations:

Hb	13.3 g/dl (11.5–16.5)
WCC	11.0×10^9/l (4.0–11.0)
PLT	299×10^9/l (150–400)
Na^+	141 mmol/l (137–144)
K^+	3.7 mmol/l (3.5–4.9)
Creatinine	172 μmol/l (60–110)

Which is the most likely causative organism?

A	*Bacillus cereus*
B	*Bacteroides fragilis*

Na^+	141 mmol/l (137–144)
K^+	3.7 mmol/l (3.5–4.9)
Creatinine	172 μmol/l (60–110)

Which is the most likely causative organism?

A *Bacillus cereus*

B *Bacteroides fragilis*

C *Staphylococcus aureus*

D *Campylobacter jejuni*

E *Escherichia coli*

Submit

Explanation

C *Staphylococcus aureus*

The speed at which this patient developed symptoms following ingestion of the meat pie suggests an organism that produces an enterotoxin. Of the organisms above, only *Bacillus cereus* and *S. aureus* produce enterotoxins; *Bacillus cereus* is associated with stored cooked rice, which this patient has not eaten. *S. aureus*, however, is associated with poorly stored high-salt foods, such as the meat pie that this patient had left at room temperature. *S. aureus* typically causes a severe but self-limiting watery diarrhoea, resolving within 48 h. No specific treatment is required; simple advice regarding adequate fluid and electrolyte replacement with oral rehydration salts is sufficient.

A *Bacillus cereus*

Although *Bacillus cereus* does cause a severe watery diarrhoea, food poisoning from this organism occurs after eating cooked rice that has been stored; this is not consistent with the patient's food history. The more likely causative organism here is *S. aureus*. This patient's history is consistent with gastroenteritis caused by an organism producing an enterotoxin, such as *S. aureus*. *S. aureus* food poisoning is typically caused by foods with a high salt content that have been improperly left at room temperature, such as a meat pie. It causes a severe diarrhoea that is typically self-resolving within 48 h.

Rana Alnasser's screen

E *Escherichia coli*

Escherichia coli is the most common cause of traveller's diarrhoea and can cause food poisoning, typically through eating contaminated beef or drinking unpasteurised milk. However, the incubation period is usually at least 24 h – this patient's symptoms developed 6 h after eating the meat pie, suggesting infection with an enterotoxin-producing bacterium such as *B. cereus* or *S. aureus*. *B. cereus* is found in rice, which this patient has not eaten, whereas *S. aureus* is associated with high-salt foods such as the meat pie that this patient had left at room temperature. Consequently in this case *S. aureus* is the most likely causative organism.

Rate this question:

Next Question

© Pastest 2019

Calculator

Normal Values

A 62-year-old man presented with a 2-week history of fever, shortness of breath and a cough with haemoptysis. He had returned from Mississippi 3 weeks previously, where he was studying bats. He had no other medical conditions.

On examination, his temperature was 37.6 °C, and oxygen saturation was 97% on room air. He appeared well and comfortable at rest. There was bilateral wheeze on auscultation of the chest.

Investigations:

Hb	11.2 g/dl
WCC	9.1×10^9/l
PLT	120×10^9/l
Na^+	140 mmol/l
K^+	4.9 mmol/l
Creatinine	130 µmol/l
CXR	Hilar lymphadenopathy
ESR	35 mm/1st h (<20)
Sputum culture	Yeast forms

What is the most appropriate treatment?

Creatinine	130 µmol/l
CXR	Hilar lymphadenopathy
ESR	35 mm/1st h (<20)
Sputum culture	Yeast forms

What is the most appropriate treatment?

A Itraconazole

B Amphotericin

C Doxycycline

D Ganciclovir

E Prednisolone

Submit

Explanation

A Itraconazole

This patient has symptoms, signs and investigations consistent with a diagnosis of histoplasmosis. This would also fit with his travel history as it is endemic to areas with large bat and bird populations, such as Mississippi, Ohio and Missouri. In severe cases amphotericin is used, but in this relatively mild case, a prolonged course of itraconazole would be most appropriate.

B Amphotericin

This patient has symptoms, signs and investigations consistent with histoplasmosis, a yeast infection that is endemic in Mississippi, Ohio and Missouri. It occurs particularly in areas that house large bat and bird populations. In severe disease, amphotericin would be the correct treatment, but here in relatively mild disease, a prolonged course of itraconazole would be more appropriate.

C Doxycycline

Doxycycline is an antibiotic used in the management of community-acquired pneumonia in patients with pre-existing respiratory conditions, and in the management of rickettsial illness (e.g. Rocky Mountain spotted fever). It would not be appropriate for the treatment of a fungal or yeast infection, as

Rana Alnasser's screen

Calculator

Normal Values

A 54-year-old sheep farmer comes to the Hepatology Clinic complaining of dull right upper quadrant pain and intermittent shortness of breath which has steadily worsened over the past 3-6 months. He has no past medical history of note, takes no regular medication, and is usually well.

On examination, his blood pressure is 125/82 mmHg, with pulse 67/min and regular. Breath sounds are slightly reduced at the right lung base on auscultation. Abdomen is soft, and he is mildly tender in the right upper quadrant with two finger-breadth hepatomegaly.

Investigations:

Hb	110 g/l
WCC	9.9 x 10^9/l (elevated eosinophils)
PLT	212 x 10^9/l
ESR	45 mm / 1st hour
CRP	82 mg/l
Na	139 mmol/l
K	4.5 mmol/l
Creatinine	95 micromol/l
AST	192 U/l
ALP	245 U/l
[illegible]	23 µmol/l

Rana Alnasser's screen

AST	152 U/l
ALP	245 U/l
Bilirubin	23 µmol/l
USS liver	Multiple cysts in the right lobe of the liver with internal septae
CXR	Small right pleural effusion

Which of the following is the most appropriate next step in diagnosis?

A Albendazole trial of therapy

B CT guided cyst aspiration

C CT guided pleural fluid aspiration

D ELISA testing for Echinococcus

E Surgical cyst excision

Submit

D ELISA testing for Echinococcus

This man's profession, coupled with steadily worsening symptoms, elevated ESR, eosinophilia, abnormal LFTS, multiple cysts and a right pleural effusion, suggests liver hydatid disease. Serological testing is most likely to be positive (90%+ in most series) for patients with liver cysts, and this therefore represents the most appropriate next step in diagnosis.

A Albendazole trial of therapy

Intervention depends on the size of the cyst, smaller cysts responding well to medical therapy alone although larger cysts usually require albendazole combined with surgical excision. It is important of course to confirm the diagnosis first.

B CT guided cyst aspiration

CT-guided aspiration without drug cover runs the risk of anaphylaxis or seeding of *Echinococcus* along the track.

C CT guided pleural fluid aspiration

The pleural fluid may be reactive or due to seeding of *Echinococcus* because of cyst rupture. Aspiration may risk further spreading, and other measures to confirm the diagnosis should be attempted first.

CT-guided aspiration without drug cover runs the risk of anaphylaxis or seeding of *Echinococcus* along the track.

C CT guided pleural fluid aspiration

The pleural fluid may be reactive or due to seeding of *Echinococcus* because of cyst rupture. Aspiration may risk further spreading, and other measures to confirm the diagnosis should be attempted first.

E Surgical cyst excision

Surgical cyst excision was formerly the only treatment for *Echinococcus*, but is now considered an intervention either in combination with drug therapy or after a period of drug therapy, rather than as a diagnostic tool.

Rate this question:

Next Question

A 76-year-old woman presents with pain over her upper left chest. She has suffered a weeping vesicular rash over the area for the past 4 days associated with burning intense pain. There is a history of chicken pox infection as a child.

On examination, there is a well-demarcated rash consisting of dried-up crusted and healing vesicles, corresponding to one dermatome.

Which of the following options represents the most appropriate treatment in this patient?

Calculator

Normal Values

A	Aciclovir ointment
B	Oral aciclovir
C	Oral valciclovir
D	Gabapentin
E	IV aciclovir

53185

Submit

Rana Alnasser's screen

63% 20:48
MyPastest
https://mypastest.pastest.com

A 76-year-old woman presents with pain over her upper left chest. She has suffered a weeping vesicular rash over the area for the past 4 days associated with burning intense pain. There is a history of chicken pox infection as a child.

On examination, there is a well-demarcated rash consisting of dried-up crusted and healing vesicles, corresponding to one dermatome.

Which of the following options represents the most appropriate treatment in this patient?

Your answer was incorrect

A Aciclovir ointment

B Oral aciclovir

C Oral valciclovir

D Gabapentin

Difficulty: Average

Peer Responses %

Session

Responses Correct:	13
Responses Incorrect:	9
Responses Total:	22
Responses - % Correct:	59%

D Gabapentin

E IV aciclovir

Explanation

D Gabapentin

It is clear that this patient has suffered an unpleasant attack of Herpes zoster reactivation, also known as shingles. At this stage though, with crusting, dried-up and healing lesions there is no value in antiviral therapy. Gabapentin is a useful oral agent to block the pain associated with post-herpetic neuralgia; 300 mg daily is the most appropriate starting dose, with effective doses being from 900 mg upwards, and it can be increased up to 3.6 g/day. Alternatives include tricyclic anti-depressants and topical capsaicin cream.

B Oral aciclovir

Oral aciclovir is a good treatment option for Herpes simplex genital infections. These are sexually transmitted infections characterised by painful irritation and itching.

A Aciclovir ointment

This is mostly useful against conjunctival varicella zoster, where there is dermatomal distribution within the trigeminal nerve and including the eye.

It is clear that this patient has suffered an unpleasant attack of Herpes zoster reactivation, also known as shingles. At this stage though, with crusting, dried-up and healing lesions there is no value in antiviral therapy. Gabapentin is a useful oral agent to block the pain associated with post-herpetic neuralgia; 300 mg daily is the most appropriate starting dose, with effective doses being from 900 mg upwards, and it can be increased up to 3.6 g/day. Alternatives include tricyclic anti-depressants and topical capsaicin cream.

B Oral aciclovir

Oral aciclovir is a good treatment option for Herpes simplex genital infections. These are sexually transmitted infections characterised by painful irritation and itching.

A Aciclovir ointment

This is mostly useful against conjunctival varicella zoster, where there is dermatomal distribution within the trigeminal nerve and including the eye.

C Oral valciclovir

Valciclovir is an alternative option to acyclovir, with good cover against herpes viruses.

E IV aciclovir

This is most appropriate for HSV encephalitis. In HSV encephalitis there is

Calculator

Normal Values

An 18-year-old man was admitted to the Emergency Unit with a headache and neck stiffness.

On examination, he was pyrexial 38.8 °C, with a BP of 95/60 mmHg and a pulse of 105/min and had a purpuric rash. There was significant neck stiffness with signs of meningism. Apparently three other cases of meningococcal group C meningitis have been reported in the past two weeks at his university.

Investigations:

Hb	13.1 g/dl
WCC	13.9×10^9/l
PLT	140×10^9/l
Na^+	138 mmol/l
K^+	5.3 mmol/l
Creatinine	157 µmol/l
Lumbar puncture	Gram negative diplococci identified

His girlfriend uses the oral contraceptive pill and refuses to use other forms of contraception.

Which of the following would be the most appropriate prophylaxis against infection for his girlfriend?

A Rifampicin PO for 2 days

PLT	140 × 10^9/l
Na^+	138 mmol/l
K^+	5.3 mmol/l
Creatinine	157 µmol/l
Lumbar puncture	Gram negative diplococci identified

His girlfriend uses the oral contraceptive pill and refuses to use other forms of contraception.

Which of the following would be the most appropriate prophylaxis against infection for his girlfriend?

A	Rifampicin PO for 2 days
B	Meningococcal group C vaccination
C	Penicillin V PO for 7 days
D	Single dose oral ciprofloxacin
E	IV Immunoglobulin

Explanation

D Single dose oral ciprofloxacin

Ciprofloxacin as a single dose, rifampicin PO (4 doses over 2 days), and ceftriaxone (single dose IM) have been used as prophylaxis for contacts of patients with meningococcal infection. Data suggests that ciprofloxacin is the preferred first line option, and is now recommended by the HPA.

A Rifampicin PO for 2 days

Although rifampicin is the second line option, in this case it may also act as an enzyme inducer, reducing the effectiveness of the oral contraceptive pill and risking potential pregnancy, and is therefore best avoided.

B Meningococcal group C vaccination

Whilst strategies for mass vaccination of populations where cases of meningococcus group C have proved effective in reducing new cases, antibiotic prophylaxis is the key step for close contacts.

C Penicillin V PO for 7 days

Penicillin V is the treatment for streptococcal throat infection and would not [illegible] adequate prophylaxis against meningococcal group C species.

Rana Alnasser's screen

A Rifampicin PO for 2 days

Although rifampicin is the second line option, in this case it may also act as an enzyme inducer, reducing the effectiveness of the oral contraceptive pill and risking potential pregnancy, and is therefore best avoided.

B Meningococcal group C vaccination

Whilst strategies for mass vaccination of populations where cases of meningococcus group C have proved effective in reducing new cases, antibiotic prophylaxis is the key step for close contacts.

C Penicillin V PO for 7 days

Penicillin V is the treatment for streptococcal throat infection and would not provide adequate prophylaxis against meningococcal group C species.

E IV Immunoglobulin

IV immunoglobulin treatment can be used in some exposure to viral pathogens such as rabies, but has no role in meningococcal meningitis.

Rate this question:

Next Question

Rana Alnasser's screen

Calculator

Normal Values

A 35-year-old woman presented with a 6-week history of lower abdominal pain. This had not limited her activities, but the pain was persistent and on occasion she had felt feverish. She did not have dysuria or an abnormal discharge. She had had multiple urinary tract infections in her twenties.

On examination, the temperature was 37.3 °C. There was mild lower abdominal tenderness, and bowel sounds were present and normal. Urine dipstick was normal.

Investigations:

		Normal values
Haemoglobin (Hb)	13.2 g/dl	
White cell count (WCC)	7.6×10^9/l	4.0–11.0
Platelets (PLT)	255×10^9/l	
Sodium (Na)	137 mmol/l	
Potassium (K)	4.4 mmol/l	
Creatinine (Cr)	72 µmol/l	
Urea	4.9 mmol/l	
C-reactive protein (CRP)	45 mg/l	< 10

What is the most likely cause for her symptoms?

A Chlamydial infection

Platelets (PLT)	255 × 10^9/l	
Sodium (Na)	137 mmol/l	
Potassium (K)	4.4 mmol/l	
Creatinine (Cr)	72 µmol/l	
Urea	4.9 mmol/l	
C-reactive protein (CRP)	45 mg/l	< 10

What is the most likely cause for her symptoms?

A Chlamydial infection

B Gonococcal sepsis

C Pyelonephritis

D Renal stones

E Urinary tract infection

Submit

Explanation

A	Chlamydial infection

This is a classic description of pelvic inflammatory disease. This patient complains of subacute or long-term pelvic pain; patients may also experience mucopurulent discharge, dyspareunia or abnormal vaginal bleeding. The 'urinary tract infections' this patient reports may have included sexually transmitted chlamydial infections causing dysuria. Typically, patients have lower abdominal pain on examination and may have cervical motion or adnexal tenderness on bimanual examination. Fever and raised inflammatory markers are common findings. As this patient is clinically stable, oral treatment, as opposed to admission for intravenous treatment, is appropriate. Current British Association for Sexual Health and HIV guidelines recommend oral doxycycline or oral metronidazole.

B	Gonococcal sepsis

This patient is not septic; although she has raised inflammatory markers, she is not systemically unwell. If this were acute gonococcal infection, you would expect purulent vaginal discharge, which this patient does not have. This patient has pelvic inflammatory disease – long-standing non-specific pelvic pain with mildly raised inflammatory markers on a background of recurrent episodes of dysuria. Pelvic inflammatory disease can be caused by gonococcal infection; however, *Chlamydia* is the most common cause in the United Kingdom and therefore is the most likely cause in this case.

have lower abdominal pain on examination and may have cervical motion or adnexal tenderness on bimanual examination. Fever and raised inflammatory markers are common findings. As this patient is clinically stable, oral treatment, as opposed to admission for intravenous treatment, is appropriate. Current British Association for Sexual Health and HIV guidelines recommend oral doxycycline or oral metronidazole.

B Gonococcal sepsis

This patient is not septic; although she has raised inflammatory markers, she is not systemically unwell. If this were acute gonococcal infection, you would expect purulent vaginal discharge, which this patient does not have. This patient has pelvic inflammatory disease – long-standing non-specific pelvic pain with mildly raised inflammatory markers on a background of recurrent episodes of dysuria. Pelvic inflammatory disease can be caused by gonococcal infection; however, *Chlamydia* is the most common cause in the United Kingdom and therefore is the most likely cause in this case.

C Pyelonephritis

If this were pyelonephritis, you would expect a history of dysuria and a positive urine dipstick; you would also expect the patient to be more systemically unwell with a higher temperature. This patient has pelvic inflammatory disease, with long-standing non-specific pelvic pain and mildly raised inflammatory markers on a background of recurrent episodes of dysuria. The most common cause of pelvic inflammatory disease in the UK is *Chlamydia*, and therefore this is the most likely cause of this patient's symptoms.

common cause of pelvic inflammatory disease in the UK is chlamydial infection, and therefore this is the most likely cause of this patient's symptoms.

E Urinary tract infection

You would not expect such a long history for a patient with a urinary tract infection. If this were a urinary tract infection, you would expect the patient to complain of dysuria and the urine dipstick to be positive. Instead, this patient has a history typical of pelvic inflammatory disease – subacute non-specific bilateral pelvic pain, with intermittent fevers and mildly raised inflammatory markers. The background of recurrent dysuria may, in fact, have included sexually transmitted infections, not simply urinary tract infections. The most common cause of pelvic inflammatory disease in the UK is chlamydial infection; therefore, this is the correct answer.

Rate this question:

Rana Alnasser's screen

Calculator

Normal Values

A 21-year-old woman was brought by ambulance after as a 'red alert'. Her brother accompanied her and reported that she was very lethargic the previous evening and had complained of a sore throat and muscle aches. The following morning, he subsequently found her vomiting and complaining of a headache.

On examination, her blood pressure was 90/60 mmHg, temperature 38.7 °C and pulse rate 110 bpm. There was a purpuric skin rash and evidence of subconjunctival haemorrhage. With the thigh flexed at the hip and the knee at 90 degrees, the patient found further extension of the leg painful.

Investigations:

White cell count (WCC)	14.2×10^9/l (4.0–11)
Neutrophils	11.4×10^9/l (1.5–7.0)
Activated partial thromboplastin time (APTT)	51 s (30–40)
Urea	10.1 mmol/l (2.5–7.0)
Creatinine	148 mmol/l (60–110
Random plasma glucose	4.1 mmol/l

What is the most appropriate initial treatment?

A Ceftriaxone

B Ciprofloxacin

Rana Alnasser's screen

at 90 degrees, the patient found further extension of the leg painful.

Investigations:

White cell count (WCC)	14.2 × 10^9/l (4.0–11)
Neutrophils	11.4 × 10^9/l (1.5–7.0)
Activated partial thromboplastin time (APTT)	51 s (30–40)
Urea	10.1 mmol/l (2.5–7.0)
Creatinine	148 mmol/l (60–110
Random plasma glucose	4.1 mmol/l

What is the most appropriate initial treatment?

A Ceftriaxone

B Ciprofloxacin

C Glucose

D Hydrocortisone

E Naloxone

Explanation

A	Ceftriaxone

The answer is Ceftriaxone (Option A).

This patient has signs, including a positive Kernig's sign, and symptoms consistent with meningitis, probably meningococcal meningitis, given the evidence of disseminated intravascular coagulation. The most appropriate treatment is intravenous ceftriaxone, which should be given immediately. This patient will need to be transferred to intensive care. A computerised tomography (CT) scan is required before progressing to lumbar puncture, to rule out cerebral oedema and therefore the risk of coning on lumbar puncture. Cerebral herniation occurs in about 5% of patients with acute bacterial meningitis, accounting for about 30% of mortality. Bacterial meningitis would give a typically turbid or purulent cerebrospinal fluid (CSF), 200–300 polymorphs/mm^3, 0.5–2.0 g/l of protein and CSF glucose levels of < 50% of the blood value. It is important to treat contacts of patients with meningococcal disease with prophylaxis against infection with oral ciprofloxacin. A single dose of ceftriaxone is appropriate for prophylaxis in pregnant women.

B	Ciprofloxacin

Ciprofloxacin (Option B) is incorrect.

This patient has symptoms and signs consistent with bacterial meningitis, likely meningococcal. She is extremely unwell, with signs of disseminated

hypoglycaemic agents, who can present with reduced consciousness, hunger, irritability or confusion. In such cases, oral glucose treatment, intramuscular glucagon and intravenous dextrose can be used. Had the hypoglycaemia been more severe, then correction would have been warranted, but the highest priority should be ceftriaxone to treat the underlying cause.

D Hydrocortisone

Hydrocortisone (Option D) is incorrect.

This patient has bacterial meningitis, most likely meningococcal, and will require transfer to intensive care. Steroids have been shown to reduce the risk of hearing loss in bacterial meningitis, but there is no evidence that they reduce overall mortality. If steroids were given, dexamethasone would be the agent used, rather than hydrocortisone. Hydrocortisone would have been the correct answer to the management of an Addisonian crisis, which can present with vomiting and hypotension, but the fever, rash and headache make that a less likely diagnosis.

E Naloxone

Naloxone (Option E) is incorrect.

Naloxone is an opioid antagonist, used in overdose situations. There is no evidence that this patient has overdosed on opioids; instead, she has a purpuric rash, neurological signs and fever. This should be treated as bacterial meningitis, until proven otherwise. Evidence of an opiate overdose would be a low respiratory rate, pinpoint pupils and evidence of intravenous

hunger, irritability or confusion. In such cases, oral glucose treatment, intramuscular glucagon and intravenous dextrose can be used. Had the hypoglycaemia been more severe, then correction would have been warranted, but the highest priority should be ceftriaxone to treat the underlying cause.

D	Hydrocortisone

Hydrocortisone (Option D) is incorrect.

This patient has bacterial meningitis, most likely meningococcal, and will require transfer to intensive care. Steroids have been shown to reduce the risk of hearing loss in bacterial meningitis, but there is no evidence that they reduce overall mortality. If steroids were given, dexamethasone would be the agent used, rather than hydrocortisone. Hydrocortisone would have been the correct answer to the management of an Addisonian crisis, which can present with vomiting and hypotension, but the fever, rash and headache make that a less likely diagnosis.

E	Naloxone

Naloxone (Option E) is incorrect.

Naloxone is an opioid antagonist, used in overdose situations. There is no evidence that this patient has overdosed on opioids; instead, she has a purpuric rash, neurological signs and fever. This should be treated as bacterial meningitis, until proven otherwise. Evidence of an opiate overdose would be a low respiratory rate, pinpoint pupils and evidence of intravenous drug abuse such as track-marks.

Calculator

Normal Values

A 26-year-old man presents to the Accident and Emergency Unit with groin pain that has come on over the past few hours, which is severe in intensity and leaves him unable to walk. He denies dysuria, haematuria or penile discharge. There is no history of trauma.

On examination, he has a fever of 38.3 °C, with severe tenderness on palpation of the left testis, which is also warm and swollen. A firm, tender mass is noted at the posterior aspect of the testes. The cremasteric reflex is present. There is no change in pain noticed with elevation of scrotum. Urine dipstick showed leukocytes. Radionucleotide scan shows increased blood flow to the left testicle.

What is the most likely diagnosis?

A	Mumps orchitis
B	Testicular malignancy
C	Epididymitis
D	Urinary tract infection
E	Testicular torsion

On examination, he has a fever of 38.3 °C, with severe tenderness on palpation of the left testis, which is also warm and swollen. A firm, tender mass is noted at the posterior aspect of the testes. The cremasteric reflex is present. There is no change in pain noticed with elevation of scrotum. Urine dipstick showed leukocytes. Radionucleotide scan shows increased blood flow to the left testicle.

What is the most likely diagnosis?

Your answer was correct

A Mumps orchitis

B Testicular malignancy

C Epididymitis

D Urinary tract infection

E Testicular torsion

Session Progress

Responses Correct:	17
Responses Incorrect:	9
Responses Total:	26
Responses - % Correct:	65%

Explanation

C Epididymitis

B Testicular malignancy

It would not explain the acute onset, high temperature, leukocytes in the urine or tenderness.

D Urinary tract infection

This would present with dysuria and not with testicular tenderness.

E Testicular torsion

In testicular torsion, the pain is usually worse with elevation of scrotum, and the cremasteric reflex is usually absent. It would also not explain the leukocytes in the urine dip or the increased rather than decreased blood flow. Colour flow Doppler, in the hands of a skilled scanning technician, will demonstrate reduced blood flow in testicular torsion, and may be more available than radionucleotide scanning in the acute setting.

Rate this question:

Next Question

A 63-year-old Sri Lankan man presented with a 4-week history of cough, intermittent fever, night sweats and malaise. Six weeks previously, he had travelled to Sri Lanka for 2 months to visit his family. He denied haemoptysis or any contacts with tuberculosis.

On examination, his temperature was 38.3 °C and pulse rate was 94 bpm. There was reduced chest expansion on the right, and the right base was dull to percussion, with bronchial breathing above. There was 2-cm, tender hepatomegaly, with an irregular border.

Investigations:

		Normal values
Bilirubin	29 µmol/l	1–22
Alanine aminotransferase	27 u/l	1–31
Alkaline phosphatase	146 u/l	45–105
Blood cultures	No growth	
Sputum cultures	No growth	
CT chest, abdomen, pelvis	Multi-loculated, right-sided pleural effusion, 10 × 6 cm hepatic collection	
Pleural biopsy	No acid-fast bacilli	

Sputum cultures	No growth	
CT chest, abdomen, pelvis	Multi-loculated, right-sided pleural effusion, 10 × 6 cm hepatic collection	
Pleural biopsy	No acid-fast bacilli	

The pleural effusion was drained.

Which is the best choice of further treatment?

A	Co-amoxiclav
B	Co-amoxiclav and clarithromycin
C	Co-amoxiclav, clarithromycin and metronidazole
D	Peginterferon alpha
E	Rifampicin, isoniazid and ethambutol

Submit

Rana Alnasser's screen

C Co-amoxiclav, clarithromycin and metronidazole

This patient has signs and symptoms suggestive of amoebiasis. *Entamoeba histolytica* is common in South East Asia, and hepatic amoebiasis typically causes constitutional symptoms, as seen here. There is usually tender hepatomegaly and pleural effusions. Empyemas are a common complication. It is common for liver function tests to be normal, or there may be an obstructive picture with raised alkaline phosphatase and bilirubin levels (mildly raised here, but the alanine aminotransferase level is normal). The patient should be treated with metronidazole, and this can be given as a monotherapy. However, until the diagnosis is confirmed by serology or aspirate polymerase chain reaction (PCR), it would be appropriate to prescribe broad-spectrum antibiotic therapy by adding co-amoxiclav and clarithromycin.

E Rifampicin, isoniazid and ethambutol

These are treatments for tuberculosis. This patient's malaise and night sweats could be explained by tuberculosis, but tuberculosis does not normally cause a swinging fever (this is more associated with abscesses). Tuberculosis can seed into the liver, but it is uncommon. You would also expect to see acid-fast bacilli on pleural biopsy if this were tuberculosis. A more likely explanation for this patient's symptoms and investigation findings would be amoebiasis, which is common in Sri Lanka. Amoebiasis explains the liver abscess, and pleural effusions are a common complication. The correct treatment would be metronidazole (though it is reasonable to continue additional broad-spectrum antibiotics until the diagnosis is

Calculator

Normal Values

A 63-year-old man is seen in the Emergency Department with a 2-week history of increasing fatigue, fever and rigors. The fever appears to come on every few days. He has recently come back from Long Island, where he stayed with family. He remembers being bitten by a tick, which he subsequently removed. He has a history of hypertension and he had his spleen removed following a road traffic accident 12 years ago. He is taking aspirin, an angiotensin-converting enzyme (ACE) inhibitor and penicillin V. He is a non-smoker.

On examination he is jaundiced, looks unwell, is slightly confused and has a temperature of 38.7 °C. He has no lymphadenopathy. His pulse is 120 bpm and regular and blood pressure 95/60 mmHg. His chest is clear and his abdomen is soft but non-specifically tender. He has no neurological abnormality.

Investigations:

Hb	7.1 g/dl
WCC	11.3×10^9/l
PLT	97×10^9/l
Na^+	132 mmol/l
K^+	5.1 mmol/l
Creatinine	189 µmol/l
MCV	80.2 fl
LDH	213 µg/l

Rana Alnasser's screen

Creatinine	189 µmol/l
MCV	80.2 fl
CRP	213 µg/l
Serum electrophoresis	Polyclonal hypergammaglobulinaemia
Chest X-ray	Clear
Urinalysis	Haemoglobinuria

What is the most likely diagnosis?

A Babesiosis

B Perforated duodenal ulcer

C Lyme Disease

D Malaria

E Nocardiosis

Submit

Explanation

A Babesiosis

This is a tick-borne malaria-like illness caused by species of the intra-erythrocytic protozoan *Babesia*. Patients present with similar symptoms to malaria, i.e. fever, chills and rigors. The intra-erythrocytic *Babesia* destroy the red blood cells, causing haemolytic anaemia and haemoglobinuria. Symptoms are greater with a higher percentage of parasitism. A B-lymphocyte response is elicited with a secondary reactive polyclonal hypergammaglobulinemia Babesiosis is frequent in endemic areas of the USA, particularly Long Island, New York and Nantucket and Martha's Vineyard, Massachusetts.

Patients without a spleen have a more fulminant and prolonged clinical course and may have overwhelming infection and a fatal outcome.

Babesiosis is often a clinical diagnosis, and the history of a recent trip to Long Island and being bitten should differentiate this from malaria. In addition, patients with malaria often have a more pronounced headache. Lyme disease does not cause haemolytic anaemia, and nocardiosis is only fulminant in the immunocompromised.

D Malaria

Scroll capture Draw Crop Share

Rana Alnasser's screen

C Lyme Disease

Lyme disease is an infectious illness caused by the bacterium *Borrelia burgdorferi*. It is transmitted through tick bites. It initially presents with a slowly expanding skin lesion around the tick bite, erythema migrans, malaise and joint aches. If not treated, neurological, cardiac and joint involvement can occur. The patient described here is profoundly unwell and does not have erythema migrans; this would not be typical of acute Lyme disease.

E Nocardiosis

Nocardiosis is an uncommon infection caused by Gram-positive bacteria of the genus *Nocardia*. It may present as a localised (most commonly pulmonary or central nervous system) or systemic infection. The majority of patients affected have underlying immunodeficiency (HIV, immunosuppressive therapy, malignancy), which makes nocardiosis unlikely in our patient.

Rate this question:

Next Question

Rana Alnasser's screen

Calculator

Normal Values

A 27-year-old man presented with a 3-day history of flu-like symptoms and fatigue. Six weeks previously he had had unprotected receptive anal sexual intercourse with a male partner.

On examination, he had low-volume cervical lymphadenopathy; the remainder of the examination was unremarkable.

Investigations:

WCC	5.1×10^9/l (4.0–11.0)
Neutrophils	3.9×10^9/l (1.5–7.0)
Lymphocytes	0.9×10^9/l (1.5–4.0)
PLT	40×10^9/l (150–400)
Hepatitis B surface antigen	-
Hepatitis B core antibody	+
HIV antibody	-
Epstein–Barr virus IgM	-
Epstein–Barr virus IgG	+

Which of the following diagnoses fits best with this clinical picture?

A Early Epstein–Barr virus

B Hepatitis B

Rana Alnasser's screen

Lymphocytes	0.9×10^9/l (1.5–4.0)
PLT	40×10^9/l (150–400)
Hepatitis B surface antigen	-
Hepatitis B core antibody	+
HIV antibody	-
Epstein–Barr virus IgM	-
Epstein–Barr virus IgG	+

Which of the following diagnoses fits best with this clinical picture?

A Early Epstein–Barr virus

B Hepatitis B

C Herpes

D HIV

E Influenza

Rana Alnasser's screen

Explanation

D HIV

This would explain the patient's flu-like illness and lymphadenopathy, and the timing would fit with his exposure through unprotected sexual intercourse: seroconversion is typically at 6 weeks after exposure. The lymphopenia and thrombocytopenia are common features of seroconversion. It is quite common for HIV antibodies to be negative during seroconversion: a p24 antigen test should also be carried out, and testing should be repeated as suspicion is high. If investigations confirm the diagnosis, guidance suggests that the patient should be started on antiretroviral therapy straight away.

A Early Epstein-Barr virus

This patient has serology consistent with a previous, but not a recent, infection. After Epstein-Barr infection, IgG remains positive at a variable titre for life; IgM is only positive 4-8 weeks after an acute infection, and remains positive for up to a year. This patient has a positive IgG, indicating previous infection, but with a negative IgM it is unlikely that this is acute Epstein-Barr virus infection. Instead, this patient is more likely to be in HIV seroconversion - HIV antibody can be negative before seroconversion is complete. This would explain the flu-like illness and lymphadenopathy; the timing would also fit with a possible exposure through unprotected sexual intercourse.

B Hepatitis B

Calculator

Normal Values

A 47-year-old man, who recently emigrated from Swaziland, presented to Accident and Emergency with fatigue.

On further questioning, he also described a chronic productive cough. He was found to be human immunodeficiency virus (HIV)-positive. He was taking no regular medications and had not sought medical treatment in many years.

Investigations:

Haemoglobin (Hb)	107 g/l
White cell count (WCC)	3.1×10^9/l
Platelets (PLT)	131×10^9/l
Sodium (Na)	143 mmol/l
Potassium (K)	4.2 mmol/l
Urea	6.7 mmol/l
Creatinine (Cr)	82 µmol/l
CD4+ count	40×10^6/l (430–1690)
High-resolution computed tomography (HRCT) chest	Hilar lymphadenopathy with multiple nodules and multifocal bronchiectatic changes

Which is the most likely causative organism?

Potassium (K)	4.2 mmol/l
Urea	6.7 mmol/l
Creatinine (Cr)	82 µmol/l
CD4+ count	40×10^6/l (430–1690)
High-resolution computed tomography (HRCT) chest	Hilar lymphadenopathy with multiple nodules and multifocal bronchiectatic changes

Which is the most likely causative organism?

A *Cryptococcus*

B Cytomegalovirus

C *Mycobacterium avium intracellulare*

D *Pneumocystis jiroveci*

E *Toxoplasma gondii*

Submit

Explanation

C	*Mycobacterium avium intracellulare*

This patient has a productive cough, a CD4 count of < 50 and widespread lymphadenopathy within his chest. These findings are most in keeping with MAI. MAI is a non-tuberculous *Mycobacterium. It is spread though inhalation and ingestion, as MAI is ubiquitous in the environment. Presentation is* typically in two separate ways. In individuals with known lung disease, the presentation is similar to that of tuberculosis, with cough, weight loss, upper lobe infiltrates and cavitations. In patients with no known lung disease, it typically presents with a persistent cough and purulent sputum, but without weight loss, fever and haemoptysis.

Radiographic changes in this presentation are as described in the case, with signs of bronchiectasis coupled with multiple nodules. This infection usually affects those with a CD4 count of < 50 cells/mm^3; therefore, patients who fall into this group should receive MAI prophylaxis, usually with azithromycin. It is thought that transmission is not via person-to-person spread, but from waterborne sources. Patients are treated with a combination of antimycobacterial drugs, and in this case, antiretroviral treatment needs to be started.

A	*Cryptococcus*

Cryptococcus is a yeast, and although it can cause pulmonary disease (ranging from pneumonia to adult respiratory distress syndrome) in the immunocompromised, it is more commonly associated with meningitis or

Calculator

Normal Values

A 23-year-old woman presented with a 9-day history of lower abdominal pain which worsened during intercourse. She also reported two episodes of post-coital per vaginam bleeding. Her sexual history included unprotected intercourse with two male partners in the preceding 2 weeks.

On examination, she was pyrexial at 37.6 °C, and there was bilateral pain on bimanual palpation.

Investigations:

HB	126 g/l (115–160)
WCC	9.5×10^9/l (4.0–11.0)
Cervical smear	Neutrophils +

What is the most likely diagnosis?

A Bacterial vaginosis

B Candidiasis

C Chlamydia

D Gonorrhoea

E Trichomonas

Rana Alnasser's screen

Normal Values

intercourse with two male partners in the preceding 2 weeks.

On examination, she was pyrexial at 37.6 °C, and there was bilateral pain on bimanual palpation.

Investigations:

HB	126 g/l (115–160)
WCC	9.5×10^9/l (4.0–11.0)
Cervical smear	Neutrophils +

What is the most likely diagnosis?

A Bacterial vaginosis

B Candidiasis

C Chlamydia

D Gonorrhoea

E Trichomonas

Rana Alnasser's screen

C Chlamydia

Chlamydia is the most common sexually transmitted infection in the UK, with a prevalence of around 8% in the under 20s and 5% in those aged 20–24. This patient's symptoms of bilateral pelvic pain and intermittent fever, and deep dyspareunia, are suggestive of pelvic inflammatory disease, of which chlamydia is the most common cause. The neutrophils on microscopy without any visible bacterial is typical of chlamydia: however, the preferred method of diagnosis now is nucleic acid amplification testing (NAAT) from a high vulvo-vaginal swab, rather than endocervical swabs. Men can be tested via first-catch urine samples or urethral swabs. First-line antibiotics would be either doxycycline or a single dose of azithromycin, and contact tracing should be undertaken.

A Bacterial vaginosis

Bacterial vaginosis does not cause dyspareunia, pelvic pain or fever. Instead, patients typically complain of a change in vaginal discharge: an increased amount of thin, whitish malodourous discharge. A cervical smear would typically show 'clue cells' – these are vaginal epithelial cells covered with bacteria. Instead, this patient's dyspareunia, pelvic pain and intermittent fever, combined with a history of unprotected sex, are more suggestive of chlamydia, causing pelvic inflammatory disease.

B Candidiasis

Candidiasis, or thrush, causes soreness, itching, erythema and a thick, white

A 42-year-old man presented to the Emergency Department with a 2 h history of sudden loss of vision in his left eye. He had a past history of hypertension but was otherwise well. A sexual history revealed that he had had unprotected intercourse with multiple male partners over the preceding 2 years. He had not been screened for sexually transmitted infections for 5 years.

On fundoscopy, extensive haemorrhages and exudates were visible.

A rapid HIV test is positive.

What would be the best initial treatment?

A	Aciclovir
B	Aspirin
C	Ganciclovir
D	Low-molecular weight heparin
E	Warfarin

D Low-molecular weight heparin

E Warfarin

Explanation

C Ganciclovir

This patient is likely to have HIV (the diagnosis would need to be confirmed with laboratory testing) and consequent cytomegalovirus retinitis, an AIDs-defining illness. It is the most common cause of eye disease and blindness in HIV patients. CMV retinitis is a slowly progressive disorder; visual loss may occur suddenly as a result of haemorrhage or retinal detachment, or more slowly due to progressive involvement of the macula and optic nerve. He would need treatment with intravenous ganciclovir.

A Aciclovir

This patient likely has a diagnosis of HIV (this would need to be confirmed with full laboratory testing) and has had a sudden loss of vision. Combined with the fundoscopy findings, his presentation is suggestive of cytomegalovirus retinitis. Aciclovir is simply not potent enough to treat this; ganciclovir is the appropriate choice and is administered intravenously.

B Aspirin

Calculator

Normal Values

A 34-year-old man presented with a 2-week history of extreme fatigue and increasing generalised abdominal pain. He reports a 3-day history of vomiting, diarrhoea and dizziness. He was recently diagnosed with HIV and was started on antiretroviral therapy 3 weeks previously.

On examination his pulse rate was 120 beats/min and blood pressure was 100/50 mmHg. His cardiovascular, neurological and abdominal examinations were normal.

Investigations:

Na^+	128 mmol/l (135–145)
K^+	5.6 mmol/l (3.5–5.5)
Creatinine	100 µmol/l (60–110)
Random glucose	3.0 mmol/l
Urea	8.5 mmol/l (2.0–7.5)

Virology at the time of HIV diagnosis:

Cytomegalovirus IgG	+
HbsAb	+
HbsAg	-

Previously his electrolytes had been within the normal range.

What is the most useful bedside test to aid in diagnosis?

Random glucose	3.0 mmol/l
Urea	8.5 mmol/l (2.0–7.5)

Virology at the time of HIV diagnosis:

Cytomegalovirus IgG	+
HbsAb	+
HbsAg	-

Previously his electrolytes had been within the normal range.

What is the most useful bedside test to aid in diagnosis?

A Blood pressure in each arm

B ECG

C Exercise oxygen saturations

D Postural blood pressures

E Urinalysis

Explanation

D	Postural blood pressures

This patient is suffering from an Addisonian crisis, as evidenced by the low sodium and raised potassium, low blood pressure and dizziness, abdominal pain and vomiting. This is probably due to an immune reconstitution syndrome after starting antiretroviral therapy for HIV. In this patient's case, he is CMV IgG positive and therefore the cause may be CMV adrenalitis. If this was felt to be the case, ganciclovir should be used in treatment. Postural blood pressures will demonstrate a significant drop. He should be treated with IV hydrocortisone and fludrocortisone.

A	Blood pressure in each arm

This patient has developed an Addisonian crisis, as evidenced by the low sodium, raised potassium, abdominal pain, vomiting and diarrhoea, and low blood pressure. This can occur as part of an immune reconstitution syndrome once antiretroviral therapy is started in HIV; it may have been caused by CMV adrenalitis, as this patient has previously been exposed to CMV (hence he is IgG positive in serology). The most appropriate bedside test would be postural blood pressures: you would expect to see a significant postural drop in an Addisonian crisis.

B	ECG

an immune reconstitution syndrome after antiretroviral therapy is started, in this case, the patient is CMV IgG positive and therefore this may be as a result of CMV adrenalitis.

E	Urinalysis

This patient has developed an Addisonian crisis: he has a low blood pressure, tachycardia, hypoglycaemia, dizziness, abdominal pain and vomiting, and bloods show a low sodium and a high potassium. This is probably due to an immune reconstitution syndrome as a result of starting antiretroviral therapy for HIV; in this patient's case, he is also CMV IgG positive and therefore it is possible that this has been caused by CMV adrenalitis.

Rate this question:

Next Question

© Pastest 2019

A 42-year-old man attends the clinic complaining of diarrhoea, fatigue, fevers and right upper quadrant pain.

On examination, he looks very thin and has tender hepatosplenomegaly and lymphadenopathy. He attends with his male partner who is very concerned about him.

Investigations:

Hb	10.9 g/dl
WCC	3.9×10^9/l
PLT	90×10^9/l
Na^+	139 mmol/l
K^+	4.6 mmol/l
Creatinine	100 µmol/l
Alanine aminotransferase (ALT)	184 U/l
Alkaline phosphatase	282 U/l
CT abdomen	Retroperitoneal, para-aortic lymphadenopathy and hepatosplenomagaly
Small bowel biopsy	Acid-fast bacteria (AFB) seen, MTB PCR negative

Alanine aminotransferase (ALT)	184 U/l
Alkaline phosphatase	282 U/l
CT abdomen	Retroperitoneal, para-aortic lymphadenopathy and hepatosplenomagaly
Small bowel biopsy	Acid-fast bacteria (AFB) seen, MTB PCR negative

Which of the following is the most likely diagnosis?

A Cytomegalovirus (CMV) infection

B *Cryptosporidium*

C *Mycobacterium avium*

D *Myocbacterium tuberculosis*

E Tropical sprue

Explanation

C *Mycobacterium avium*

This patient is anaemic, with low platelets and a low white cell count giving evidence of infection, evidence of lymphadenopathy on CT scan, and non-TB AFBs identified on biopsy. The additional abnormalities seen in LFTs point towards the possibility of *Mycobacterium avium* as being the most likely cause of this presentation. We note that he has a male partner, and this raises the possibility of HIV infection and immunocompromise. Triple antibiotic therapy is usually required in HIV-infected patients; one possible combination suggested is clarithromycin, ethambutol and rifabutin.

A Cytomegalovirus (CMV) infection

Primary CMV infection causes a glandular fever syndrome typified by fever, lethargy and lymphadenopathy. Although CMV reactivation in the immunocompromised host can present with colitis, the small bowel biopsy results point to an alternative diagnosis.

B *Cryptosporidium*

Cryptosporidium parvum is a protozoan which causes a self-limiting diarrhoeal illness. In the context of immunosuppression it may cause a severe diarrhoeal illness or disseminated infection affecting multiple organ systems

Cryptosporidium parvum is a protozoan which causes a self-limiting diarrhoeal illness. In the context of immunosuppression it may cause a severe diarrhoeal illness or disseminated infection affecting multiple organ systems which may prove fatal. Treatment is primarily supportive in the immunocompetent host while treatment of the underlying immunosuppression (eg HAART in HIV-positive patients) is key in the immunocompromised. Here the small bowel biopsy results point to an alternative diagnosis.

D *Myocbacterium tuberculosis*

Tuberculosis (TB) is a chronic bacterial infection caused by *M. tuberculosis*. Primary TB most commonly affects the lungs, however almost all organ systems may be infected. A similar syndrome to that described may be present in patients with GI or miliary (disseminated TB); however we are told in the vignette that the MTB PCR is negative, this makes *Mycobacterium* TB infection much less likely.

E Tropical sprue

Tropoical sprue is a gastrointestinal condition in which inflammation and subsequent flattening of small bowel villi leads to malabsorption. The underlying aetiology is not well understood but there may be an infectious cause. The presentation is with signs and symptoms associated with malabsorption (particularly of vitamin B12 and folic acid).

Rate this question:

A 24-year-old man who has recently returned from India presents with bloody diarrhoea and mucus. More recently, he has also developed some abdominal pain and vomiting which has increased over the past few days. His blood pressure 95/70 mmHg and his pulse is 100 bpm and regular.

Calculator

Normal Values

Investigations:

Hb	11.2 g/dl
WCC	16.3×10^9/l
PLT	756×10^9/l
Urea	11.5 mmol/l
ESR	56 mm/h
Na^+	143 mmol/l
K^+	2.7 mmol/l
Creatinine	90 µmol/l
C-reactive protein (CRP)	72 mg/l

What is the most appropriate initial treatment?

A Oral metronidazole

B Discharge with advice on rehydration and outpatient appointment

PLT	756 × 10^9/l
Urea	11.5 mmol/l
ESR	56 mm/h
Na^+	143 mmol/l
K^+	2.7 mmol/l
Creatinine	90 µmol/l
C-reactive protein (CRP)	72 mg/l

What is the most appropriate initial treatment?

A Oral metronidazole

B Discharge with advice on rehydration and outpatient appointment

C IV ceftriaxone

D IV Fluid and electrolyte replacement

E Oral ciprofloxacin

E Oral ciprofloxacin

Explanation

D IV Fluid and electrolyte replacement

The two most likely diagnoses are infective diarrhoea and ulcerative colitis. The clinical history and laboratory results would be consistent with both. However, given his recent history of abdominal pain and vomiting, the most important diagnosis to exclude is toxic megacolon. He therefore requires fluid and electrolyte replacement, and an abdominal X-ray.

A Oral metronidazole

Antibiotics are seldom needed for gastroenteritis. If the patient is systemically unwell, immunosuppressed or elderly. Metronidazole would be a useful treatment for protozoal gastrointestinal infection.

B Discharge with advice on rehydration and outpatient appointment

The extent of his abnormalities of biochemistry, especially hypokalaemia, indicates that he has had severe diarrhoea from his infection and needs inpatient electrolyte correction and fluid support.

C IV ceftriaxone

A 17-year-old woman presented to the Emergency Department with a 3-week history of malaise, fever, abdominal pain and reduced appetite, with associated weight loss. She also reported nausea and vomiting. Although she suffered from diarrhoea at the beginning of the illness, this seems to have settled now. She did not have any respiratory symptoms. One month previously, she had noticed a rash on the front of her shins associated with lumps in her groin area, which had settled but which had been followed by the onset of her current symptoms.

On examination, her temperature was 37.1 °C. Her abdomen was generally tender, especially in the right lower quadrant. There was no hepatosplenomegaly. There were several small ulcers on her pharynx. There were no rashes, and she had a BCG scar on her upper arm.

Investigations:

Hb	11.0 g/dl (11.5-16.5)
WCC	7.1 × 10^9/l (4.0-11.0)
PLT	202 × 10^9/l (150-400)
Na^+	137 mmol/l (135-145)
K^+	3.6 mmol/l (3.5-5.0)
Bilirubin	9.0 µmol/l (1-22)
[illegible]	19 U/l (5-35)

Calculator

Normal Values

Rana Alnasser's screen

WCC	7.1×10^9/l (4.0–11.0)
PLT	202×10^9/l (150–400)
Na^+	137 mmol/l (135–145)
K^+	3.6 mmol/l (3.5–5.0)
Bilirubin	9.0 µmol/l (1–22)
ALT	19 U/l (5–35)
ALP	61 U/l (45–105)
Chest X-ray	Normal

What is the most likely diagnosis?

A *Campylobacter* infection

B *Mycobacterium tuberculosis* infection

C *Salmonella* infection

D Sarcoidosis

E *Yersinia enterocolitica* infection

E *Yersinia enterocolitica* infection

Explanation

E *Yersinia enterocolitica* infection

The patient has mesenteric adenitis, characterised by fever, abdominal pain and tenderness of the right lower quadrant of the abdomen. In association, the patient may also experience nausea, vomiting and aphthous ulcers of the mouth, all of which are present in this case. The symptoms may be preceded by the appearance of erythema nodosum – painful, raised red/purple lesion on the front of the shin – which is the fleeting rash described by the patient in this case. *Yersinia enterocolitica* can also cause a reactive asymmetrical polyarthritis, enteritis, uveitis, appendicitis, and glomerulonephritis amongst other complications.

A *Campylobacter* infection

Campylobacter typically causes a bloody diarrhoea; it would be unusual to have an infection without diarrhoea. It is also usually an acute illness, whereas this patient has three weeks of symptoms. This patient's fever, abdominal pain (particularly in the right lower quadrant) and lack of diarrhoea, combined with the preceding rash of erythema nodosum, and then mouth ulcers, are suggestive of *Yersinia enterocolitica* infection. It causes a mesenteric adenitis, which accounts for her abdominal symptoms, and can also cause mouth ulcers, polyarthritis, uveitis, glomerulonephritis and other complications.

A 32-year-old man returns from a trip across the Mediterranean, North and sub-Saharan Africa. He reports feeling generally unwell for the past few days with a fever.

On examination, you notice a tick bite eschar and a surrounding rash on the left mid-thigh.

Which is the most likely causative organism?

Calculator

Normal Values

A	*Rhiphicephalus sanguineus*
B	*Rickettsia rickettsii*
C	*Rickettsia conorii*
D	*Rickettsia prowzekii*
E	*Orientia tsutsugamushi*

Submit

Rana Alnasser's screen

Explanation

C *Rickettsia conorii*

This patient has infection with *R. conorii*, the hallmark of which is the tick bite eschar. Common presenting features include fever, rash, malaise, nausea, vomiting, diarrhoea and joint and muscle pain. Diagnosis is usually made on clinical history and serological testing. The most appropriate choice for antibiotic therapy is doxycycline; other effective choices include ciprofloxacin and levofloxacin. Although fatalities occur, they are rare. Complications may include neuropathy, Guillain–Barré syndrome, acute kidney disease, hepatomegaly and thrombocytopenia.

D *Rickettsia prowzekii*

Epidemic typhus is caused by *Rickettsia prowazekii*, which is transmitted by the body louse (*Pediculus humanus corporis*).This causes headaches, fever, muscle and joint pain as well as nausea and vomiting, with a discrete rash six days after onset. The absence of this constellation makes this diagnosis unlikely.

A *Rhiphicephalus sanguineus*

The vector for infection with R. conorii is commonly *R. sanguineus* or dog tick and is not an infectious organism of humans.

A 32-year-old man was admitted after a motorcycle accident in which he suffered extensive soft tissue injury to his right lower leg.

Prior to the accident, he had been fit and well. He was reviewed on the ward 5 days later and was complaining of thoracic back pain.

On examination, his temperature was 37.8 °C. He was tender over the T8 vertebra.

Investigations:

X-ray whole spine	Normal
MRI whole spine (T2)	High signal in disc space; high signal in adjacent endplates, signifying bone marrow oedema: likely discitis

Which of the following organisms is most likely to be responsible for his back pain?

Which of the following organisms is most likely to be responsible for his back pain?

Your answer was correct

A	*Clostridium perfringens*
B	*Mycobacterium tuberculosis*
C	*Staphylococcus aureus*
D	*Staphylococcus epidermidis*
E	Viridans streptococci

Explanation

C	*Staphylococcus aureus*

This patient has symptoms and signs of discitis, which is confirmed on MRI. It is common for X-rays to appear

C	*Staphylococcus aureus*

This patient has symptoms and signs of discitis, which is confirmed on MRI. It is common for X-rays to appear normal in the early stages of disease. *Staphylococcus aureus* is the most common cause of discitis in immunocompetent patients and patients who do not use intravenous drugs. Given this patient's extensive soft tissue injury, it is especially likely that *Staph. aureus* was able to enter his bloodstream and cause his discitis. He should have multiple sets of blood cultures to confirm the organism and its sensitivities. Sometimes needle aspiration of the disc space under imaging guidance is required for identification. Once the organism and sensitivities are confirmed, he should be treated with 6–8 weeks of intravenous antibiotics.

A	*Clostridium perfringens*

Cl. perfringens causes gastroenteritis

C. perfringens causes gastroenteritis and gas gangrene, but would be a very uncommon cause of discitis. This patient has thoracic back pain and MRI findings consistent with infective discitis. It is common for the X-ray to appear normal in the early stages. The most likely causative organism, given his extensive soft tissue injury, is *Staphylococcus aureus.* This is the most common cause of discitis in the immunocompetent.

B	*Mycobacterium tuberculosis*

This patient has symptoms, signs and investigations consistent with infective discitis. It is common for the X-ray to appear normal in the early stages of infection. Tuberculosis is an important cause of discitis and spinal abscesses (also known as Pott's disease), but this patient was well before his accident with no symptoms of tuberculosis. He is not immunocompromised. The most common causative organism in discitis is *Staphylococcus aureus*: given his extensive soft tissue injury, this is particularly likely to be the causative

A 40-year-old homosexual man presents to the GP some 6 weeks after returning from a holiday to Thailand with a maculopapular rash. He denies sexual intercourse during the course of his holiday.

During his holiday, he went trekking through the jungle. The only thing he remembers is a very odd single lesion that looked like a large, warty lump on his arm which formed during his holiday and then healed up.

Investigations:

Hb	12.0 g/dl
WCC	5.9×10^9/l
PLT	234×10^9/l
Na^+	140 mmol/l
K^+	5.0 mmol/l
Creatinine	100 μmol/l
P24	Negative
TPHA	Positive

Which of the following is the most likely diagnosis?

Your answer was incorrect

A	HIV infection
B	Syphillis infection
C	Yaws infection
D	Tungiasis
E	Leishmaniasis

Explanation

C	Yaws infection

Yaws is endemic in tropical areas of America, Asia, Africa and Oceania and is caused by Treponema pertenue. Early lesions may almost look papillomatous, and as well as direct

papillomatous, and as well as direct skin to skin contact, the organism may be carried by biting insects. The TPHA is positive for both yaws and syphilis. Penicillin is the drug of choice for treatment.

E Leishmaniasis

Leishmania are protozoa spread by sandflies in Africa, Asia, India, Middle East, the Mediterranean and Latin America causing granulomata. Cutaneous leishmaniasis lesions develop at the site of the bite starting as an itchy papule which crusts to form an ulcer healing over 2-15 months. Visceral leishmaniasis, also known as kala-azar, has an incubation period of months to years. It spreads to the lymphatic system and multiply in macrophages, presenting with dry, warty, hyperpigmented lesiosn whilst the patient complains of fever, burning feet, arthralgia, cough, epistaxis. Splenomegaly occurs in 96% and hepatomegaly in 63%. Diagnosis with microscopy of lymph nodes, spleen or

microscopy of lymph nodes, spleen or bone marrow, or antibody detection. Treatment is with amphotericin. This patient does have a warty lesions but the fact that it healed rather than forming an ulcer makes cutaneous leishmanisasis unlikely and the absence of systemic features makes visceral leishmaniasis unlikely as well.

A	HIV infection

This patient, whilst being in a high risk group, does not have any direct history of possible exposure nor does he have any evidence of multiple opportunistic infection. The negative P24 test excludes HIV infection as well.

B	Syphillis infection

The warty lesion described does not correspond to a syphilitic lesion. There is also no history corresponding to primary syphilis with non-painful ulcerating genital or anal lesions. The TPHA is positive in any Treponema species, meaning that it lacks

correspond to a syphilitic lesion. There is also no history corresponding to primary syphilis with non-painful ulcerating genital or anal lesions. The TPHA is positive in any Treponema species, meaning that it lacks specificity for syphilis. In addition, TPHA remains positive for life following infection at any point.

D	Tungiasis

Tungiasis is a skin condition caused by *Tunga penetrans*, also called sand flea. It is endemic in Africa, India, and South and Central America. It causes a black dot at the site of infection with a swollen red lesions surrounded by a white halo. It is very painful and itchy. It is always associated with desquamation. The absence of this and the fact that the patient has not travelled to an endemic area makes this diagnosis unlikely.

20509

Rate this question:

Next Question

6:44

https://www.google.com/search?

16

www.jotscroll.com

Yaws Disease: Yaws Ulcer, Symptoms, Causes, Treatment, ...

Yaws is a contagious disease caused by Treponema pertenue and it is the most common endemic treponemal disease worldwide. Yaws are also called

Images may be subject to copyright. Learn More

RELATED IMAGES

SEE MORE

Yaws
who.int

6:45

https://www.google.com/sea 16

Prime Health Channel

Leishmaniasis - Pictures, Symptoms, Diagnosis and Treat...

Image 4 – Leishmaniasis Picture Source – ispub

Images may be subject to copyright. Learn More

RELATED IMAGES SEE MORE

Internet Scientific Publications
ispub.com

View Image
idoj.in

6:52
https://www.google.com/sea
16

Semantic Scholar

Figure 2 from Tungiasis (sand flea disease): a parasitic diseas...

Fig. 2 Maximally developed sand flea at the nail rim of the fifth toe.

Images may be subject to copyright. Learn More

RELATED IMAGES SEE MORE

Fig. 2 Right foot of another patient: edema and erythema at first and

Fig. 4 - Ectopic lesion on the finger of an 8-year-old girl.

Christopher Columbus and C...

A 32-year-old man, whose main hobby is fishing in local freshwater lakes, comes to the Emergency Room feeling extremely unwell. Over the past few days, he has suffered from a flu-like illness but, during the past 24 h, has deteriorated further with a cough productive of blood-stained sputum, a severe headache, fevers and jaundice.

On examination, he is pyrexial (37.9 °C). His BP is 100/60 mmHg, his pulse is 95 bpm and regular. He has a non-specific skin rash and tenderness in the right upper quadrant on abdominal examination.

Investigations:

Hb	11.1 g/dl
WCC	13.2×10^9/l
PLT	95×10^9/l
Na^+	138 mmol/l
K^+	4.9 mmol/l
Creatinine	201 μmol/l
CK	980 U/l

K	4.9 mmol/l
Creatinine	201 μmol/l
CK	980 U/l
ALT	152 U/l
Bilirubin	280 μmol/l

Given the likeliest diagnosis, which of the following is the most appropriate antimicrobial therapy for him?

Your answer was incorrect

A Ciprofloxacin

B Doxycycline

C Erythromycin

D Chloramphenicol

E Benzylpenicillin

Explanation

E Benzylpenicillin

This man has symptoms consistent with severe leptospirosis, or Weil's disease. It is likely he acquired it through exposure to rats' urine associated with his fishing trips. Erythromycin and doxycycline may be considered in patients who are unsuitable for penicillin therapy, or in those with very mild symptoms of infection, but IV penicillin is the primary treatment for severe disease. The peak in incidence of cases of leptospirosis appears to be in the late summer/early autumn in temperate climates, where it may be that moist, humid conditions allow the bacteria to persist for longer.

B Doxycycline

Doxycycline is a tetracycline antibiotic with activity against Gram-positive and atypical organisms. The patient's presentation is consistent with severe leptospirosis, and although doxycycline is the treatment of choice for milder

presentation is consistent with severe leptospirosis, and although doxycycline is the treatment of choice for milder forms of the disease, this patient warrants admission and parenteral therapy.

A Ciprofloxacin

Ciprofloxacin is a fluoroquinolone antibiotic with a wide spectrum of activity against Gram-negative and some Gram-positive bacteria. The patient's presentation is suggestive of leptospirosis, and so ciprofloxacin would not be an effective treatment.

C Erythromycin

Erythromycin is a macrolide antibiotic with activity against Gram-positive and atypical organisms. This patient's presentation is highly suggestive of leptospirosis, and although erythromycin has some activity, there is a better option available.

6:57
tps://mypastest.pastest.com
16

with activity against Gram-positive and atypical organisms. This patient's presentation is highly suggestive of leptospirosis, and although erythromycin has some activity, there is a better option available.

D	Chloramphenicol

Chloramphenicol is a long-established antibiotic with a broad spectrum of activity against Gram-positive, -negative and atypical organisms. Its use has been limited due to severe potential adverse effects. The presentation described is highly suspicious for leptospirosis, and thus chloramphenicol is not an appropriate treatment for this condition.

21242

Rate this question:

The Medical Journal of Australia

Henoch–Schönlein purpura following Yersinia enterocolitica ...

Discover Updates Search Recent More

Patchy Rash - Plague Sepsis

Medcoi

Yersinia Pestis Disease – Plague

Discover Updates Search Recent More

11:42

MyPastest
https://mypastest.pastest.com

A 28-year-old man is diagnosed with HIV. He is treated with an abacavir containing HAART regimen. He attends his regular clinic appointment some 6 months later and complains of increased shortness of breath, with difficulty walking up stairs, and the fact that he wakes short of breath at night.

On examination, his blood pressure is 110/70 mmHg, pulse is 85 bpm. He has bilateral crackles on auscultation of the lungs.

Investigations:

Hb	10.2 g/dl
WCC	4.9×10^9/l
PLT	102×10^9/l
Na^+	139 mmol/l
K^+	4.9 mmol/l
Creatinine	102 µmol/l
Echo	Cardiomyopathy

Which of the following is the most likely diagnosis?

A Abacavir hypersensitivity

B Autoimmune cardiomyopathy

C Viral myocarditis

D Nucleoside reverse transcriptase inhibitor related cardiomyopathy

Annotation Stop Share

Rana Alnasser's screen

complains of increased shortness of breath, with difficulty walking up stairs, and the fact that he wakes short of breath at night.

On examination, his blood pressure is 110/70 mmHg, pulse is 85 bpm. He has bilateral crackles on auscultation of the lungs.

Investigations:

Hb	10.2 g/dl
WCC	4.9×10^9/l
PLT	102×10^9/l
Na^+	139 mmol/l
K^+	4.9 mmol/l
Creatinine	102 µmol/l
Echo	Cardiomyopathy

Which of the following is the most likely diagnosis?

A Abacavir hypersensitivity

B Autoimmune cardiomyopathy

C Viral myocarditis

D Nucleoside reverse transcriptase inhibitor related cardiomyopathy

E Ischaemic cardiomyopathy

20979

Annotation Stop Share

Submit

11:45
On
625-262-0256
Leave

Explanation

D	Nucleoside reverse transcriptase inhibitor related cardiomyopathy

Nucleoside reverse transcriptase inhibitor (NRTI) therapy is thought to reduce vascular responsiveness to acetylcholine, and hence lead to endothelial dysfunction. Mitochondrial dysfunction induced by HAART may also lead to decreased myocardial contractility. This is because cardiac myocytes can utilise energy less well, leading to decreased ejection fraction and dilative cardiomyopathy.

A	Abacavir hypersensitivity

Abacavir is a nucleoside reverse transcriptase inhibitor (NRTI). It is recommended by the British HIV Association (BHIVA) in association with lamivudine as an alternative to Truvada as part of a HAART regime. Abacavir causes a hypersensitivity reaction in patients who are HLA-B5701 positive. However this would occur within 1-2 months of starting treatment and in the UK all patients would be tested prior to initiation. It is typified by nausea, vomiting, malaise and fever, with or without a rash.

B	Autoimmune cardiomyopathy

Cardiomyopathy may be associated with autoimmune disease (eg lupus, sarcoid, vasculitis). However you might expect the patient to have a history of autoimmune disease and in this case an alternative explanation is more likely.

C	Viral myocarditis

Viral infection is a common cause of myocarditis and is

Stop Share
Audio Video Share Participants More

Nucleoside reverse transcriptase inhibitor (NRTI) therapy is thought to reduce vascular responsiveness to acetylcholine, and hence lead to endothelial dysfunction. Mitochondrial dysfunction induced by HAART may also lead to decreased myocardial contractility. This is because cardiac myocytes can utilise energy less well, leading to decreased ejection fraction and dilative cardiomyopathy.

A Abacavir hypersensitivity

Abacavir is a nucleoside reverse transcriptase inhibitor (NRTI). It is recommended by the British HIV Association (BHIVA) in association with lamivudine as an alternative to Truvada as part of a HAART regime. Abacavir causes a hypersensitivity reaction in patients who are HLA-B5701 positive. However this would occur within 1-2 months of starting treatment and in the UK all patients would be tested prior to initiation. It is typified by nausea, vomiting, malaise and fever, with or without a rash.

B Autoimmune cardiomyopathy

Cardiomyopathy may be associated with autoimmune disease (eg lupus, sarcoid, vasculitis). However you might expect the patient to have a history of autoimmune disease and in this case an alternative explanation is more likely.

C Viral myocarditis

Viral infection is a common cause of myocarditis and is certainly possible in this case. However you would typically expect to have a history of fever and possible recent viral symptoms (eg coryza, myalgia). In this case an alternative aetiology is more likely.

E Ischaemic cardiomyopathy

Although ischaemic heart disease is the most common

11:48

Highly Active Anti Retr
Therapy(HAART)

N(t)RTIs	NNRTIs	PIs	Entry inhib
Zidovudine (AZT) Stavudine (d4T) Lamivudine (3TC) Abacavir (ABC) Didanosine (ddI) Tenofovir (TDF) Fixed dose TDF/Emtricitabine (FTC) Dideoxycytidine (ddC)	Nevirapine (NVP) Efavirenz (EFV) Etravirine (ETV) Delavirdine (DLV) Rilpivirine (RPV)	Saquinavir (SQV) Indinavir (IDV) Ritonavir (RTV) Nelfinavir (NFV) Lopinavir (LPV/r) Atazanavir (ATV) Darunavir (DRV) Fos-Amprenavir (f-APV) Tipranavir (TPV)	Enfurvirtide Maraviroc (M

Green: available in India

SlideShare

HIV/AIDS RECENT ADVANCES

... 29.

Images may be subject to copyright. Learn more

RELATED IMAGES

NATIONAL AIDS CONTROL PROGRAMME IN ...
slideshare.net

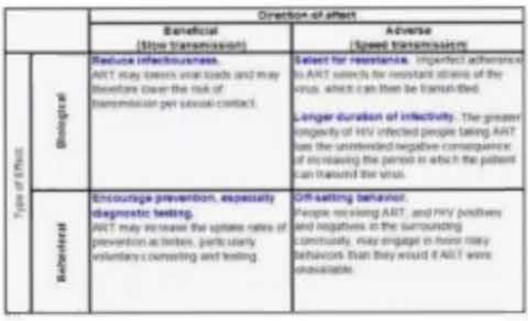

Antiretroviral Medication in Prevention
cabsa.org.za

Discover Updates Search Recent

A 37-year-old woman attended clinic with a 6-month history of breathlessness, wheeze and general fatigue. She had returned to the United Kingdom 2 weeks previously after an 8-month mission in Zanzibar, mainly spent in rural areas. She swam in the lakes and walked around barefoot. She had been well during her trip, apart from a 2-month period during which she experienced vague abdominal discomfort, which disappeared after taking a tablet prescribed by her doctor.

On examination, her pulse was 80 bpm and respiratory rate was 20 breaths/min at rest, increasing to 28 breaths/min on walking 40 m. Her body mass index (BMI) was 24, and she appeared pale. Auscultation of the chest demonstrated scattered wheeze.

Investigations:

		Normal values
Haemoglobin (Hb)	88 g/l	115–165
Mean corpuscular volume (MCV)	72.1 fl	80–96
White cell count (WCC)	8.4×10^9/l	4.0–11.0
Platelets (PLT)	460×10^9/l	150–400
Bilirubin	21 μmol/l	1–22
Alanine aminotransferase (ALT)	45 u/l	5–35
Alkaline phosphatase (ALP)	84 u/l	45–105
Albumin	32 g/l	37–49
Chest X-ray	Normal	

What is the most likely diagnosis?

Investigations:

		Normal values
Haemoglobin (Hb)	88 g/l	115–165
Mean corpuscular volume (MCV)	72.1 fl	80–96
White cell count (WCC)	8.4×10^9/l	4.0–11.0
Platelets (PLT)	460×10^9/l	150–400
Bilirubin	21 µmol/l	1–22
Alanine aminotransferase (ALT)	45 u/l	5–35
Alkaline phosphatase (ALP)	84 u/l	45–105
Albumin	32 g/l	37–49
Chest X-ray	Normal	

What is the most likely diagnosis?

A Duodenal ulcer

B Hookworm infection

C Left ventricular failure

D Pulmonary embolism

E Schistosomiasis

C Left ventricular failure

D Pulmonary embolism

E Schistosomiasis

Explanation

B Hookworm infection

The patient mentions that she has been walking around barefoot, a classic risk factor for infection by hookworm. In the early stages of the infection, the hookworms are found in the small intestine (explaining her non-specific abdominal pain). They then migrate to the lungs and can cause wheeze and a dry cough and breathlessness. This can lead to poor exercise tolerance, as demonstrated in this case. Typically, patients present with iron deficiency anaemia from ongoing gastrointestinal blood loss, as seen here.

A Duodenal ulcer

A duodenal ulcer would cause central abdominal pain, worse at night and relieved by eating. A duodenal ulcer could explain her abdominal pain. However, the duodenal ulcer cannot explain her wheeze or breathlessness (if a duodenal ulcer was causing her to be anaemic, you would not expect the symptoms to have resolved after receiving a medication from her doctor). These symptoms could be better explained by hookworm infection.

C Left ventricular failure

Left ventricular failure would explain her progressive breathlessness. However, there is no underlying pathology to explain the development of heart failure in this patient.

here.

A Duodenal ulcer

A duodenal ulcer would cause central abdominal pain, worse at night and relieved by eating. A duodenal ulcer could explain her abdominal pain. However, the duodenal ulcer cannot explain her wheeze or breathlessness (if a duodenal ulcer was causing her to be anaemic, you would not expect the symptoms to have resolved after receiving a medication from her doctor). These symptoms could be better explained by hookworm infection.

C Left ventricular failure

Left ventricular failure would explain her progressive breathlessness. However, there is no underlying pathology to explain the development of heart failure in this patient. She does have anaemia; however, it is unlikely that this level of anaemia could have caused left ventricular failure. It also does not explain her vague abdominal pain. Left ventricular failure does not explain why she has developed anaemia. This patient's presentation could be better explained by hookworm infection.

D Pulmonary embolism

The time course is too long for an acute pulmonary embolism, and you would expect pleuritic chest pain accompanying sudden-onset breathlessness. Chronic pulmonary thromboembolic disease can cause breathlessness, but this patient is young and of normal weight; there are no identified risk factors for venous thromboembolism. It is unlikely that she would have chronic thromboembolic disease, and it does not explain the anaemia or the history of vague abdominal pain. This patient's presentation could be better explained by hookworm infection. Treatment is highly successful with

A 25-year-old woman presented with a 2-day history increased urinary frequency and dysuria. She had no other medical conditions.

On examination, her temperature was 37.7 °C, pulse was 80 beats/min and blood pressure was 135/75 mmHg. There was mild supra-pubic tenderness and no loin tenderness. Urine dipstick revealed leucocytes 2+, nitrites +, blood +. She was not pregnant.

What is the most appropriate next step?

A	Admit for intravenous ciprofloxacin
B	Prescribe 3 days of ciprofloxacin
C	Prescribe 3 days of co-amoxiclav
D	Prescribe 3 days of trimethoprim
E	Send a midstream urine for microscopy and culture before treating

Submit

© Pastest 2019

11:55

A 25-year-old woman presented with a 2-day history increased urinary frequency and dysuria. She had no other medical conditions.

On examination, her temperature was 37.7 °C, pulse was 80 beats/min and blood pressure was 135/75 mmHg. There was mild supra-pubic tenderness and no loin tenderness. Urine dipstick revealed leucocytes 2+, nitrites +, blood +. She was not pregnant.

What is the most appropriate next step?

Your answer was incorrect

A	Admit for intravenous ciprofloxacin
B	Prescribe 3 days of ciprofloxacin
C	Prescribe 3 days of co-amoxiclav
D	Prescribe 3 days of trimethoprim
E	Send a midstream urine for microscopy and culture before treating

A
B
C
D
E
0

Resp
Resp
Resp
Resp

Explanation

D	Prescribe 3 days of trimethoprim

This patient has a mild urinary tract infection without any evidence of upper renal tract involvement or sepsis. She is not pregnant or catheterised, and this is a first presentation with a urinary tract infection (as opposed to a refractory or recurrent infection). As such, there is no need to send the urine for culture and the patient can have a 3-day course of oral antibiotics as an outpatient. Trimethoprim is an appropriate choice according to likely sensitivities

Rana Alnasser's screen

11:56

E Send a midstream urine for microscopy and culture before treating

Explanation

D Prescribe 3 days of trimethoprim

This patient has a mild urinary tract infection without any evidence of upper renal tract involvement or sepsis. She is not pregnant or catheterised, and this is a first presentation with a urinary tract infection (as opposed to a refractory or recurrent infection). As such, there is no need to send the urine for culture and the patient can have a 3-day course of oral antibiotics as an outpatient. Trimethoprim is an appropriate choice according to likely sensitivities.

E Send a midstream urine for microscopy and culture before treating

According to guidance, there is no requirement to send urine for culture in uncomplicated cases of non-recurrent urinary tract infection in non-pregnant women, as is the case here. Furthermore, there is no need to delay treatment: this patient should be given a 3-day course of an appropriate antibiotic such as trimethoprim.

A Admit for intravenous ciprofloxacin

This patient has symptoms and signs of a mild urinary tract infection. She is well, and does not require admission for intravenous antibiotics. There is no evidence of upper renal tract infection (no loin tenderness). Intravenous ciprofloxacin is necessary only where patients are unable to take oral medication, as the bioavailability is almost identical when taken orally. The most appropriate management of this patient would be to give a 3-day course of trimethoprim; there is no need to send urine for culture.

Rana Alnasser's screen

course of trimethoprim; there is no need to send urine for culture.

B Prescribe 3 days of ciprofloxacin

It is appropriate to give this patient, with a mild urinary tract infection, a 3-day course of oral antibiotics, but ciprofloxacin is not the best choice as it is associated with *C. difficile* infection, and it does not provide the best coverage or lowest risk of resistance. Instead trimethoprim is the most appropriate agent in this case (though local guidelines will vary according to local resistance patterns).

C Prescribe 3 days of co-amoxiclav

It is appropriate to give this patient, with a mild urinary tract infection, a 3-day course of oral antibiotics, and there is no need to send urine for culture. However, co-amoxiclav is broad spectrum and is unnecessary for this patient – it will simply develop resistance in local bacterial populations. A more appropriate choice would be trimethoprim (though local guidelines will vary).

Rate this question:

Next Question

© Pastest 2019

11:59

You are the medical senior house officer (SHO) on call. A 40-year-old man has presented to the Emergency Department with jaundice. He gives a week-long history of worsening jaundice with associated nausea and malaise. He has had mild diarrhoea, although there is no history of abdominal pain. He has felt unwell for the past 3 weeks but initially his symptoms were more 'flu-like' with muscle aches and fever. He is a man who has sex with other men and reports multiple sexual partners in the past 3 months. He often has unprotected anal intercourse, both passive and active. He uses ecstasy and cocaine as recreational drugs. He used to occasionally inject drugs but has not done so for over 10 years. He regularly attends the Genitourinary Clinic for sexual health screens and his last HIV test was negative 6 months ago.

On examination, he is afebrile, pulse 95 bpm. He is deeply jaundiced and his abdomen is soft with very mild tenderness in the right upper quadrant. There is no organomegaly.

The Emergency Department SHO has performed some blood tests:

Hb	13.2 g/dl
WCC	8.9×10^9/l
PLT	360×10^9/l
Bilirubin	154 μmol/l
Alanine aminotransferase (ALT)	872 U/l
Alkaline phosphatase (ALP)	300 U/l
Albumin	30 g/dl
Hepatitis B S antibody (Ab)	Positive
Hep B S antigen (Ag)	Negative
Renal function	Normal ranges

Rana Alnasser's screen

jaundiced and his abdomen is soft with very mild tenderness in the right upper quadrant. There is no organomegaly.

The Emergency Department SHO has performed some blood tests:

Hb	13.2 g/dl
WCC	8.9×10^9/l
PLT	360×10^9/l
Bilirubin	154 µmol/l
Alanine aminotransferase (ALT)	872 U/l
Alkaline phosphatase (ALP)	300 U/l
Albumin	30 g/dl
Hepatitis B S antibody (Ab)	Positive
Hep B S antigen (Ag)	Negative
Renal function	Normal ranges

Which test is most likely to give you the diagnosis?

A Liver ultrasound

B Anti-hepatitis A Ab

C Anti-hepatitis C Ab

D Anti-hepatitis D Ab

E HIV antibody test

12:04

MyPastest
https://mypastest.pastest.com

You are the medical senior house officer (SHO) on call. A 40-year-old man has presented to the Emergency Department with jaundice. He gives a week-long history of worsening jaundice with associated nausea and malaise. He has had mild diarrhoea, although there is no history of abdominal pain. He has felt unwell for the past 3 weeks but initially his symptoms were more 'flu-like' with muscle aches and fever. He is a man who has sex with other men and reports multiple sexual partners in the past 3 months. He often has unprotected anal intercourse, both passive and active. He uses ecstasy and cocaine as recreational drugs. He used to occasionally inject drugs but has not done so for over 10 years. He regularly attends the Genitourinary Clinic for sexual health screens and his last HIV test was negative 6 months ago.

On examination, he is afebrile, pulse 95 bpm. He is deeply jaundiced and his abdomen is soft with very mild tenderness in the right upper quadrant. There is no organomegaly.

The Emergency Department SHO has performed some blood tests:

Hb	13.2 g/dl
WCC	8.9×10^9/l
PLT	360×10^9/l
Bilirubin	154 µmol/l
Alanine aminotransferase (ALT)	872 U/l
Alkaline phosphatase (ALP)	300 U/l
Albumin	30 g/dl

A
B
C
D
E
0

Resp
Resp
Resp
Resp

D Anti-hepatitis D Ab

E HIV antibody test

Explanation

B Anti-hepatitis A Ab

This patient has symptoms suggestive of hepatitis A infection, a flu-like prodromal illness followed by an icteric illness. He is at risk as he has had unprotected anal sex with many partners; male homosexuality is a recognised risk factor for hepatitis A infection, and anal intercourse is a likely route for enteral transmission. Parenteral transmission can also occur.

A Liver ultrasound

A liver ultrasound may be useful if, for example, the patient does have chronic hepatitis C and has now developed a hepatoma. However, in this case, the symptoms are highly suggestive of an acute viral infection.

C Anti-hepatitis C Ab

It would be correct when hepatitis C is the most likely diagnosis. Hepatitis C is almost always asymptomatic during the acute infection; furthermore he has not been at high risk of contracting hepatitis C virus (HCV) for over 10 years – sexual transmission is rare compared with blood transmission. Chronic HCV would present as chronic liver disease which does not fit with this clinical picture.

D Anti-hepatitis D Ab

It would be correct when hepatitis D is the most likely

This patient has symptoms suggestive of hepatitis A infection, a flu-like prodromal illness followed by an icteric illness. He is at risk as he has had unprotected anal sex with many partners; male homosexuality is a recognised risk factor for hepatitis A infection, and anal intercourse is a likely route for enteral transmission. Parenteral transmission can also occur.

A Liver ultrasound

A liver ultrasound may be useful if, for example, the patient does have chronic hepatitis C and has now developed a hepatoma. However, in this case, the symptoms are highly suggestive of an acute viral infection.

C Anti-hepatitis C Ab

It would be correct when hepatitis C is the most likely diagnosis. Hepatitis C is almost always asymptomatic during the acute infection; furthermore he has not been at high risk of contracting hepatitis C virus (HCV) for over 10 years – sexual transmission is rare compared with blood transmission. Chronic HCV would present as chronic liver disease which does not fit with this clinical picture.

D Anti-hepatitis D Ab

It would be correct when hepatitis D is the most likely diagnosis. Hepatitis D only causes this picture when superinfection occurs in patients who are already hepatitis B positive. His results show that he has already been vaccinated against hepatitis B, or that he has had previous (now inactive) infection.

E HIV antibody test

The patient may well be HIV positive but the HIV antibody titre will not give you the diagnosis on this occasion.

A 35-year-old man presented with a 2-week history of pus and blood mixed in his stool with severe rectal pain, especially on defaecation. He was HIV positive and was on antiretroviral therapy. He had several episodes of unprotected receptive anal sex with new partners in the preceding 6 months.

On examination his temperature was 37.8 °C, and pulse rate was 95 beats/min. The abdomen was soft with some mild lower abdominal discomfort. Per rectal examination was very painful and revealed some blood mixed in with stool. There were large, tender inguinal lymph nodes. Proctoscopy was attempted but was too painful.

Investigations:

CD4 count	410×10^6/l (430–1690)
HIV viral load	Undetectable (lower detection limit 40 copies/ml)

What is the most likely diagnosis?

A *Campylobacter* gastroenteritis

B Cytomegalovirus colitis

C Lymphogranuloma venereum

D Rectal gonorrhoea

E Visceral Kaposi's sarcoma

lower abdominal discomfort. Per rectal examination was very painful and revealed some blood mixed in with stool. There were large, tender inguinal lymph nodes. Proctoscopy was attempted but was too painful.

Investigations:

CD4 count	410 × 10^6/l (430–1690)
HIV viral load	Undetectable (lower detection limit 40 copies/ml)

What is the most likely diagnosis?

Your answer was incorrect

A *Campylobacter* gastroenteritis

B Cytomegalovirus colitis

C Lymphogranuloma venereum

D Rectal gonorrhoea

E Visceral Kaposi's sarcoma

Explanation

C Lymphogranuloma venereum

This is a sexually transmitted disease caused by *Chlamydia*. Lymphogranuloma venereum has increased in incidence in developed countries with the major risk factors being men who have sex with men and HIV co-infection. This patient has a background of multiple episodes of unprotected receptive anal sex, and is therefore at risk of sexually

C Lymphogranuloma venereum

This is a sexually transmitted disease caused by *Chlamydia*. Lymphogranuloma venereum has increased in incidence in developed countries with the major risk factors being men who have sex with men and HIV co-infection. This patient has a background of multiple episodes of unprotected receptive anal sex, and is therefore at risk of sexually transmitted rectal disease. The large-volume, tender lymph nodes are typical of lymphogranuloma venereum, and tenesmus and pain on defaecation with bloody or mucopurulent discharge are also typical features. Diagnosis is via nucleic acid amplification testing (NAAT) on swabs, or by PCR. Treatment is with 21 days of oral doxycycline.

D Rectal gonorrhoea

Rectal gonorrhoea can cause some discomfort and mucopurulent discharge, but would be unlikely to cause frank pain or rectal bleeding. Although there may be associated lymphadenopathy, it would be unlikely to cause buboes as described here. This presentation is more consistent with lymphogranuloma venereum, caused by *Chlamydia*.

A *Campylobacter* gastroenteritis

Campylobacter does cause bloody diarrhoea, but it would typically have a shorter clinical course and would not cause rectal ulceration (leading to the pain on defaecation reported here). It would also be unusual to find large-volume, tender lymphadenopathy in *Campylobacter* gastroenteritis. This presentation is more typical of lymphogranuloma venereum, a sexually transmitted disease caused by *Chlamydia*. It is particularly common amongst men who have sex with men, and can present with rectal ulceration, tenesmus and bloody discharge, as seen here.

seen here.

B Cytomegalovirus colitis

This can occur as an opportunistic infection in HIV, and is an AIDs-defining illness. However, this patient has a good CD4 count and undetectable viral load. He is on antiretroviral therapy, and therefore there is no reason why he should develop an opportunistic infection such as this. Instead, given his history of unprotected receptive anal sex, large-volume tender lymphadenopathy and rectal pain, this is more likely to be lymphogranuloma venereum, caused by *Chlamydia*.

E Visceral Kaposi's sarcoma

Visceral Kaposi's sarcoma can affect the rectum, in which case it presents with rectal pain and bleeding. However, it would be extremely uncommon for Kaposi's sarcoma to present without any skin involvement at all, and therefore it is not the most likely cause of this patient's symptoms, especially as his HIV is well controlled and he is on antiretroviral therapy. The combination of rectal pain, bleeding, tenesmus and bloody discharge with large lymph nodes is much more typical for lymphogranuloma venereum, a sexually transmitted infection caused by *Chlamydia*.

Rate this question:

Next Question

Previous Q... Tag Questi... Feedback End Session

A 35-year-old man from Nigeria presents to the Emergency Department with fevers, night sweats and 10 kg weight loss over the past 2 months. There is no cough or shortness of breath. He says that he was diagnosed HIV positive 6 months previously in Africa but does not know any further details.

On examination, he is febrile at 38 °C and cachectic. He has a 4 cm lymph node in his left axilla, and his chest is clear. On examination, he has 2 cm hepatomegaly. Chest X-ray is unremarkable.

Bloods tests reveal:

Hb	8.6 g/dl
WCC	2.9×10^9/l
PLT	311×10^9/l
Urea and electrolytes	Within normal range
Alkaline phosphatase	330 U/l
Alkaline transferase	75 U/l
Bilirubin	9 µmol/l
Albumin	25 g/l
Lactate dehydrogenase	1500 U/l

An ultrasound of the liver reveals diffuse hepatomegaly with no duct dilatation.

What is the most appropriate next step?

A Sputum culture

B Bone marrow trephine

C Lymph node biopsy

details.

On examination, he is febrile at 38 °C and cachectic. He has a 4 cm lymph node in his left axilla, and his chest is clear. On examination, he has 2 cm hepatomegaly. Chest X-ray is unremarkable.

Bloods tests reveal:

Hb	8.6 g/dl
WCC	2.9×10^9/l
PLT	311×10^9/l
Urea and electrolytes	Within normal range
Alkaline phosphatase	330 U/l
Alkaline transferase	75 U/l
Bilirubin	9 μmol/l
Albumin	25 g/l
Lactate dehydrogenase	1500 U/l

An ultrasound of the liver reveals diffuse hepatomegaly with no duct dilatation.

What is the most appropriate next step?

A Sputum culture

B Bone marrow trephine

C Lymph node biopsy

D CT of the abdomen

E Liver biopsy

D CT of the abdomen

E Liver biopsy

Explanation

C Lymph node biopsy

This is a young, HIV-positive patient with fevers, night sweats, weight loss and enlarged .The most likely diagnoses are tuberculosis and lymphoma; histoplasmosis and atypical mycobacteria are also a possibility. A tissue sample is needed to differentiate between these diagnoses and a lymph node biopsy is the least invasive method of obtain histology. Further microscopy and staining will be able to provide a definitive diagnosis.

A Sputum culture

There are two main differential diagnoses: tuberculosis and lymphoma. Sputum culture is unlikely to show any bacilli as the patient is not coughing, and even if they were the sensitivity would be low.

B Bone marrow trephine

This is a very invasive investigation to obtain a tissue sample and would be a secondary investigation following established diagnosis of lymphoma.

D CT of the abdomen

A computed tomography (CT) of the abdomen will add little; a tissue sample is needed to look for lymphoma, granulomas or acid-fast bacilli.

A Sputum culture

There are two main differential diagnoses: tuberculosis and lymphoma. Sputum culture is unlikely to show any bacilli as the patient is not coughing, and even if they were the sensitivity would be low.

B Bone marrow trephine

This is a very invasive investigation to obtain a tissue sample and would be a secondary investigation following established diagnosis of lymphoma.

D CT of the abdomen

A computed tomography (CT) of the abdomen will add little; a tissue sample is needed to look for lymphoma, granulomas or acid-fast bacilli.

E Liver biopsy

The patient does have hepatomegaly, but investigating for underlying causes would be more appropriate.

Rate this question:

Next Question

Previous Q... Tag Questi... Feedback End Session

Blog About Pastest Contact Us Help

12:15

A 31-year-old man is seen in the Emergency Department with right upper quadrant tenderness and bloody diarrhoea. He has been unwell since returning from a period supervising a 1-year Operation Raleigh expedition to Brazil. This was one of a number of trips to South America. While there, he took part in watersports and went fresh-water swimming. He visited the jungles and was bitten by the occasional insect. He was always careful however with what he ate and drank. He had night sweats and fever for 1 week, with headache, a non-productive cough and arthralgia. He smokes 40 cigarettes/day and drinks heavily on the weekend. He admitted to having casual unprotected sex with some of the local women.

On examination, his temperature is 38.1 °C and his pulse 110 bpm. He has cervical and inguinal lymphadenopathy. His chest is clear but he has a large liver, which measures 10 cm below the right costal margin, and a spleen which is 8 cm below the left costal margin.

Blood results are as follows:

WCC	15.2×10^9/l
Neutrophils	9.3×10^9/l
Lymphocytes	3.2×10^9/l
Eosinophils	2.1×10^9/l
Hb	10.1 g/dl
MCV	84 fl
PLT	140×10^9/l
Alanine aminotransferase (ALT)	36 U/l
Alkaline phosphatase	134 U/l
Gamma glutamyl transferase	157 U/l
Bilirubin	21 μmol/l
Albumin	34 g/l

Rana Alnasser's screen

Neutrophils	9.3×10^9/l
Lymphocytes	3.2×10^9/l
Eosinophils	2.1×10^9/l
Hb	10.1 g/dl
MCV	84 fl
PLT	140×10^9/l
Alanine aminotransferase (ALT)	36 U/l
Alkaline phosphatase	134 U/l
Gamma glutamyl transferase	157 U/l
Bilirubin	21 μmol/l
Albumin	34 g/l
Chest X-ray	normal

Abdominal ultrasound scan shows an enlarged liver 15 cm, enlarged spleen 10 cm, kidneys and pancreas normal, two gallstones in the gallbladder, no common bile duct (CBD) dilatation.

What is the most likely diagnosis?

A HIV

B Crohn's disease

C Giardiasis

D Schistosomiasis

E Leishmaniasis

A 31-year-old man is seen in the Emergency Department with right upper quadrant tenderness and bloody diarrhoea. He has been unwell since returning from a period supervising a 1-year Operation Raleigh expedition to Brazil. This was one of a number of trips to South America. While there, he took part in watersports and went fresh-water swimming. He visited the jungles and was bitten by the occasional insect. He was always careful however with what he ate and drank. He had night sweats and fever for 1 week, with headache, a non-productive cough and arthralgia. He smokes 40 cigarettes/day and drinks heavily on the weekend. He admitted to having casual unprotected sex with some of the local women.

On examination, his temperature is 38.1 °C and his pulse 110 bpm. He has cervical and inguinal lymphadenopathy. His chest is clear but he has a large liver, which measures 10 cm below the right costal margin, and a spleen which is 8 cm below the left costal margin.

Blood results are as follows:

WCC	15.2×10^9/l
Neutrophils	9.3×10^9/l
Lymphocytes	3.2×10^9/l
Eosinophils	2.1×10^9/l
Hb	10.1 g/dl
MCV	84 fl
PLT	140×10^9/l
Alanine aminotransferase (ALT)	36 U/l
Alkaline phosphatase	134 U/l
Gamma glutamyl transferase	157 U/l
Bilirubin	21 µmol/l

12:18

MyPastest
https://mypastest.pastest.com

Pastest+

D Schistosomiasis

This patient has an exposure to fresh-water immersion and jungle activity in a country where schistosomiasis is endemic. The key findings from his history and investigation are fever, hepatosplenomegaly and bloody diarrhoea in the returning traveller. The disease is caused by one of several species of parasitic trematodes of the genus *Schistosoma*. Schistosomes infect particular species of susceptible freshwater snails, which release cercariae, which are fork-tailed 1-mm-long free-swimming larvae. These survive in freshwater for up to 48 hours, during which time they must attach to human skin/susceptible host mammal or die. Once attached, they migrate through intact skin to dermal veins and, over the next several days, to the pulmonary vasculature. The worms then migrate through the pulmonary capillaries to the systemic circulation, which carries them to the portal veins where they mature. In the portal circulation the males and females pair off and produce eggs.

Diagnosis is based on a good travel history with the risk of exposure clarified. Patients in the acute stage can present with an urticarial illness as they react to the antigenic eggs produced. Symptoms are those of serum sickness and hepatosplenomegaly is often present. Diagnosis can be made by observing eggs in the stool or urine depending on which species of *Schistosoma* has caused infection. Treatment is primarily with praziquantel and supportive therapy.

A HIV

It does not explain the bloody diarrhoea or hepatosplenomegaly. Acute HIV seroconversion is more likely to present with fever and general malaise. However, it would be worthwhile to test for HIV due to the potential

also explain the arthralgia as an extra-intestinal symptom, but the cough is difficult to explain.

C Giardiasis

It would not explain the bloody diarrhoea or hepatosplenomegaly. The patient could be exposed to *Giardia lamblia*, the causative pathogen, through unprotected sex or swimming and it would cause diarrhoea, but the additional features of the history and examination makes it less likely. Giardiasis typically presents as explosive diarrhoea and malabsorption.

E Leishmaniasis

Visceral leishmaniasis is a cause of fevers, night sweats and hepatosplenomegaly but would not present with bloody diarrhoea and does not cause arthralgia. Leishmaniasis is endemic to east Africa and India and more commonly presents in a cutaneous form, but visceral leishmaniasis is an important cause of hepatosplenomegaly as untreated it is often fatal.

Rate this question:

Next Question

Previous Q... Tag Questi... Feedback End Session

Blog About Pastest Contact Us Help

© Pastest 2019

A 28-year-old woman attended clinic. She was planning to move to South America and was 12 weeks' pregnant. She wanted to review her vaccination status prior to travelling.

Which one of the following vaccines is considered safe in pregnancy?

A	BCG
B	Rubella
C	Tetanus
D	Varicella zoster
E	Yellow fever

71038

Submit

Previous Q...

Skip Questi...

© Pastest 2019

12:22
On
625-262-0256
Leave

Explanation

C	Tetanus

Tetanus is a toxoid-based vaccine and therefore is considered safe in pregnancy. All the other examples are live attenuated vaccines, and therefore should not be given in pregnancy due to the potential risk of fetal infection. Other examples of vaccines considered safe in pregnancy are whooping cough, hepatitis B and influenza.

A	BCG

The BCG vaccination affords some protection against tuberculosis infection. However, it is a live attenuated vaccine, and as such is not recommended in pregnancy as there is a theoretical risk of infection of the fetus. Only toxoid-based or killed vaccines are considered safe in pregnancy if the risk of infection outweighs the risk of vaccination: common examples are influenza, hepatitis B, whooping cough and tetanus.

B	Rubella

Women who are planning to conceive are advised to have the rubella vaccine (as part of the measles, mumps and rubella vaccine – MMR) at least a month before conceiving. It is a live attenuated vaccine, and therefore should not be administered in pregnancy due to a theoretical risk that the fetus could become infected. Only killed or toxoid-based vaccines are considered safe in pregnancy, though it is always important to weigh the risks and benefits of any medication in pregnancy. Examples of safe vaccines include influenza, hepatitis B, whooping cough and tetanus.

D	Varicella zoster

Audio
Video
Share
Participants
More

12:23
On
625-262-0256
Leave

A 37-year-old Mexican is seen in the Emergency Department with a 1-month history of dizziness and unsteady gait. He was visiting his family, who were concerned, and so he came to the Emergency Department. They tell you that he has been slightly strange since he came to visit and seems depressed and tired. He has been complaining about back pain and constipation. He is a non-smoker and does not take drugs. He works on a cattle ranch in Mexico.

On examination, he is febrile at 38.1 °C, his pulse is 85 bpm and blood pressure 90/50 mmHg. He is fully alert but he appears confused. On abdominal palpation, you find hepatosplenomegaly and on neurological examination he has an unsteady gait and generalised hypotonia, but no neck stiffness or photophobia.

Investigations:

WCC	3.6×10^9/l
Neutrophils	1.9×10^9/l
PLT	48×10^9/l
LDH	1250 U/l (10–250)
TSH	1.2 mU/l (0.4–5)
Thyroxine (fT_4)	16.3 pmol/l (10–22)
ALT	61 U/l
ALP	165 U/l
Bilirubin	18 µmol/l
ESR	102 mm/h
Blood cultures at 5 days	No growth
Chest X-ray	Normal
CT brain	Normal

Audio
Video
Share
Participants
More

Investigations:

WCC	3.6×10^9/l
Neutrophils	1.9×10^9/l
PLT	48×10^9/l
LDH	1250 U/l (10–250)
TSH	1.2 mU/l (0.4–5)
Thyroxine (fT_4)	16.3 pmol/l (10–22)
ALT	61 U/l
ALP	165 U/l
Bilirubin	18 μmol/l
ESR	102 mm/h
Blood cultures at 5 days	No growth
Chest X-ray	Normal
CT brain	Normal
HIV test	-

What is the most likely diagnosis?

A Tuberculosis

B Nocardiosis

C Meliodosis

D Brucellosis

E Histoplasmosis

E Histoplasmosis

Explanation

D Brucellosis

Brucellosis is a zoonotic bacterial infection which causes a chronic granulomatous disease. The presentation is varied but includes bone pain, neuropsychiatric symptoms and a pyrexia of unknown origin (PUO). Blood test abnormalities are often non-specific but may include cytopenias and mildly deranged liver function. Negative cultures do not exclude brucellosis, and laboratories should be informed if the diagnosis is suspected because *Brucella* is a category three pathogen. The diagnostic test of choice is bone marrow aspiration and culture. Treatment includes 6 weeks of doxycycline with streptomycin or rifampicin. Quinolones are now also used. Treatment failure due to inadequate duration of therapy often leaves patients with chronic disease. The additional clue in this case is the history of cattle exposure in Mexico, where the infection is endemic.

A Tuberculosis

Tuberculosis (TB) is a chronic bacterial infection caused by *Mycobacterium tuberculosis*. Primary TB most commonly affects the lungs, although almost any organ system may be infected. Although TB should be considered in all patients with an undifferentiated febrile illness, it is not the most likely diagnosis in this case. In primary infection the patient would most likely have respiratory symptoms, while in reactivation the majority of patients have chest radiograph changes. In addition, as this patient has neurological signs, you would expect clinical evidence of meningism or abnormalities on the CT brain. Finally, neutropenia and thrombocytopenia are not typical of TB (though may be present in the context of bone marrow involvement).

affected have underlying immunodeficiency (HIV, immunosuppressive therapy, malignancy), which makes nocardiosis unlikely in our patient.

C Meliodosis

Meliodosis is an infection caused by the Gram-negative bacterium *Burkholderia pseudomallei*. Most patients have subclinical disease, but infection can present with pneumonia, skin abscess formation or sepsis. While sporadic cases have been reported worldwide, the disease is endemic to South and South East Asia.

E Histoplasmosis

Histoplasmosis in an infection caused by the dimorphic fungus *Histoplasma capsulatum*. Infection usually presents as a pneumonia, and associated changes on the chest radiograph would be expected such as hilar lymphadenopathy, lung nodules or lung cavities. Histoplasmosis is present worldwide but is most common in North America.

Rate this question:

Next Question

Previous Q... Tag Questi... Feedback End Session

Blog About Pastest Contact Us Help

© Pastest 2019

A 26-year-old who is taking long-term oral prednisolone (10 mg/day) therapy comes to the Emergency Department because he is worried, as his brother has been admitted to the hospital with acute chicken pox infection and he had seen him two days earlier. He is certain that he has never suffered from chicken pox.

What is the most appropriate course of action?

A	Check varicella antibody status
B	Start prophylactic acyclovir
C	Start prophylactic valacyclovir
D	Observe for signs of infection
E	Give varicella immunoglobulin

21200

Submit

© Pastest 2019

A 26-year-old who is taking long-term oral prednisolone (10 mg/day) therapy comes to the Emergency Department because he is worried, as his brother has been admitted to the hospital with acute chicken pox infection and he had seen him two days earlier. He is certain that he has never suffered from chicken pox.

What is the most appropriate course of action?

Your answer was correct

A	Check varicella antibody status
B	Start prophylactic acyclovir
C	Start prophylactic valacyclovir
D	Observe for signs of infection
E	Give varicella immunoglobulin

A
B
C
D
E
0

Resp
Resp
Resp
Resp

Explanation

A	Check varicella antibody status

Steroid use within 3 months of chicken pox exposure increases the risk of severe infection in patients who are non-immune. Guidance supports the use of varicella zoster virus (VZV) immunoglobulin within 3 days of exposure if possible, and not later than 10 days after exposure. Given that IV immunoglobulin is not without risk, antibody status should of course be assessed first. Confirmed chicken pox infection should be managed aggressively with anti-viral

A Check varicella antibody status

Steroid use within 3 months of chicken pox exposure increases the risk of severe infection in patients who are non-immune. Guidance supports the use of varicella zoster virus (VZV) immunoglobulin within 3 days of exposure if possible, and not later than 10 days after exposure. Given that IV immunoglobulin is not without risk, antibody status should of course be assessed first. Confirmed chicken pox infection should be managed aggressively with anti-viral therapy, and specialist opinion from an infectious disease consultant is advised. Complications of infection in this population include pneumonitis, hepatitis, encephalitis and disseminated intravascular coagulation (DIC).

B Start prophylactic acyclovir

This patient has had a significant chicken pox exposure and is immunocompromised. It is important to determine immune status to plan further management. All cases should be discussed with an infectious diseases specialist. There is no role for prophylactic acyclovir in this setting.

C Start prophylactic valacyclovir

This patient has had a significant chicken pox exposure and is immunocompromised. It is important to determine immune status to plan further management. All cases should be discussed with an infectious diseases specialist. There is no role for prophylactic valacyclovir in this setting.

D Observe for signs of infection

This patient has had a significant chicken pox exposure and is known to be immunosuppressed, and as such is at risk of severe disease. In this setting, if he has no immunity to varicella it would be necessary to give varicella

A 21-year-old man is brought in with fever, rash and headache. He returned from a rodeo in North Texas one week ago and admits that he had probably been bitten by many different bugs when he was out there, despite using repellent. He noticed feeling hot and cold the day before leaving Texas, but put it down to a flu-like illness as he had a headache, rhinorrhoea, dry cough and intermittent severe muscle pain in his lower back and legs. His fever and headache had, however, persisted and he was now concerned as he had developed a rash on his wrists and ankles which had now started to spread up his body.

On examination, he is febrile with a temperature of 38.1 °C and appears slightly agitated. He has a maculopapular eruption over his arms and legs, including a rash over the palms of his hands and soles of his feet. His pulse is 60/min and heart sounds are normal. His chest is clear but he is tender in the right upper quadrant. There is no meningism and neurology is normal.

Investigations:

Hb	12.1 g/dl
WCC	3.4×10^9/l
PLT	75×10^9/l
Na^+	131 mmol/l
K^+	3.9 mmol/l
Creatinine	105 µmol/l
Albumin	34 g/l
Urea	5.6 mmol/l
ALT	101 U/l
Bilirubin	34 µmol/l
Chest X-ray	Normal

What is the most likely diagnosis?

and heart sounds are normal. His chest is clear but he is tender in the right upper quadrant. There is no meningism and neurology is normal.

Investigations:

Hb	12.1 g/dl
WCC	3.4×10^9/l
PLT	75×10^9/l
Na^+	131 mmol/l
K^+	3.9 mmol/l
Creatinine	105 µmol/l
Albumin	34 g/l
Urea	5.6 mmol/l
ALT	101 U/l
Bilirubin	34 µmol/l
Chest X-ray	Normal

What is the most likely diagnosis?

A Dengue fever

B Ehrlichiosis

C Lyme disease

D Rocky Mountain spotted fever

E Syphilis

E Syphilis

Explanation

D Rocky Mountain spotted fever

This is a tick-borne disease caused by the organism *Rickettsia rickettsii*. RMSF can be lethal. Physicians must maintain a high index of suspicion for RMSF in patients who are febrile, as it is essentially a clinical diagnosis. Key aspects include history of potential tick exposure, travel to an endemic area and presentation in the spring or autumn.

Patients with unexplained febrile illness, even if they have no history of a tick bite or travel to an endemic area but have rash and myalgia, should be suspected to have RMSF. Rash is a major diagnostic sign. The maculopapular rash usually appears 2–6 days after the onset of fever and progresses through stages and distribution that are never pathognomonic. The rash begins as a maculopapular eruption on the wrists and ankles, and spreads centripetally to involve the trunk and extremities. The rash involves the palms of the hands and soles of the feet. Later in the illness, the rash becomes petechial in 50% of patients.

For adults, the preferred drug of choice is doxycycline. Chloramphenicol is an alternative.

A Dengue fever

Dengue is caused by an arbovirus transmitted by the aedes mosquito. The incubation period is one to two weeks and the typical symptoms are fever, frontal headache, musculoskeletal pains and a widespread maculopapular rash. Laboratory findings commonly show a rising haematocrit, falling platelets and a transamenitis. The clue here is the travel; cases of dengue arising in the United States are sporadic and usually associated with travel to Central and South America. An outbreak has been seen in

Rana Alnasser's screen

C Lyme disease

Lyme disease is an infectious illness caused by the bacterium *Borrelia burgdorferi*. It is transmitted through tick bites. It initially presents with a slowly expanding skin lesion around the tick bite, erythema migrans, malaise and joint aches. If not treated, neurological, cardiac and joint involvement can occur. The rash described is not consistent with acute Lyme disease.

E Syphilis

Syphilis is an infection caused by the bacterium *Treponema pallidum*, and it is most commonly acquired through sexual intercourse. Primary syphilis presents as a local painless ulcer (chancre) at the inoculation site. Secondary syphilis occurs weeks to months after the primary chancre and is typified by a widespread rash, fever, lethargy and lymphadenopathy. You might expect a question to describe risk factors for syphilis and an antecedent chancre, but in practice it may be prudent to check syphilis serology in this patient.

Rate this question:

Next Question

Previous Q... Tag Questi... Feedback End Session

Blog About Pastest Contact Us Help

© Pastest 2019

A 19-year-old Thai woman presents to the Emergency Department complaining of malaise and shortness of breath.

On examination, she has multiple enlarged cervical and axillary nodes and mild hepatosplenomegaly.

Preliminary blood tests reveal:

Hb	6.1 g/dl
WCC	3.5×10^9/l
Neutrophils	2.9×10^9/l
PLT	31×10^9/l
Urea and electrolytes	NAD
Alkaline phosphatase	205 U/l
Aspartate transferase	80 U/l
Bilirubin	6 μmol/l
Albumin	21 g/l

She is admitted and transfused three units of blood. As part of her investigation an HIV test is done, which is positive. After the transfusion, her breathlessness is much improved and she remains stable. A bone marrow trephine and lymph node biopsy are requested.

On the ward round, she mentions in passing that the vision in her right eye has been steadily deteriorating for the past 3 weeks. You perform dilated fundoscopy and note widespread haemorrhages and exudates in the right fundus. The left fundus reveals more limited exudates.

What is the best treatment for this patient?

A IV aciclovir

12:33

Neutrophils	2.9×10^9/l
PLT	31×10^9/l
Urea and electrolytes	NAD
Alkaline phosphatase	205 U/l
Aspartate transferase	80 U/l
Bilirubin	6 μmol/l
Albumin	21 g/l

She is admitted and transfused three units of blood. As part of her investigation an HIV test is done, which is positive. After the transfusion, her breathlessness is much improved and she remains stable. A bone marrow trephine and lymph node biopsy are requested.

On the ward round, she mentions in passing that the vision in her right eye has been steadily deteriorating for the past 3 weeks. You perform dilated fundoscopy and note widespread haemorrhages and exudates in the right fundus. The left fundus reveals more limited exudates.

What is the best treatment for this patient?

A IV aciclovir

B IV foscarnet

C IV ganciclovir

D IV cidofovir

E IV ribavirin

7650

Rana Alnasser's screen

D IV cidofovir

E IV ribavirin

Explanation

C IV ganciclovir

The cause of her impaired vision is cytomegalovirus (CMV) retinitis. CMV retinitis is a common cause of blurred vision in immunodeficiency which can lead to blindness. It can be asymptomatic as well. Fundoscopy can show haemorrhagic necrosis, granular lesions or frosted branch angiitis around retinal vessels.

A IV aciclovir

IV aciclovir is incorrect. Aciclovir would not be effective against CMV but could be used against herpes simplex virus infection.

B IV foscarnet

IV foscarnet is incorrect. Either IV ganciclovir or foscarnet could be used and although trial evidence suggests marginally more rapid clearance with foscarnet versus ganciclovir, ganciclovir is still preferred under UK Guidelines as the first treatment of choice. Foscarnet is generally the second-line therapy of choice in patients who fail to gain an adequate response to ganciclovir.

D IV cidofovir

IV cidofovir is incorrect. Cidofovir can be used if both ganciclovir and foscarnet are contraindicated or there is a

marginally more rapid clearance with foscarnet versus ganciclovir, ganciclovir is still preferred under UK Guidelines as the first treatment of choice. Foscarnet is generally the second-line therapy of choice in patients who fail to gain an adequate response to ganciclovir.

D IV cidofovir

IV cidofovir is incorrect. Cidofovir can be used if both ganciclovir and foscarnet are contraindicated or there is a failure to respond to one of these therapies. It is, however, the drug of choice for varicella zoster retinitis. There are very limited data comparing cidofovir with ganciclovir and foscarnet, but ganciclovir efficacy is well established. Cidofovir may have a greater role in future treatment as it can be dosed less frequently with its longer half-life.

E IV ribavirin

IV ribavirin is incorrect. Ribavirin is an antiviral agent used to treat respiratory syncytial virus, hepatitis C virus and viral haemorrhagic fever.

Rate this question:

Next Question

Previous Q... Tag Questi... Feedback End Session

Blog About Pastest Contact Us Help

© Pastest 2019

A 33-year-old man presented to the Emergency Department with a 1-day history of frontal headache, nausea and vomiting. He was prescribed cefalexin by his general practitioner (GP) earlier in the day.

Eleven months ago, he had had a left cerebellopontine angle tumour removed, and 1 week before this presentation, a ventriculoperitoneal shunt had been inserted for hydrocephalus.

On examination, the temperature is 37.9 °C. Pupils are reactive and equal to light, and fundoscopy is normal. There is a left facial nerve palsy, without sparing of the upper face. Kernig's sign is positive.

Initial investigations are as follows:

		Normal values
Haemoglobin (Hb)	109 g/l	130–180
White cell count (WCC)	12×10^9/l	4.0–11.0
Platelets (PLT)	310×10^9/l	150–400
C-reactive protein	180 mg/l	< 10
Serum glucose	5.1 mmol	
Erythrocyte sedimentation rate (ESR)	35 mm/first hour	< 15
Blood cultures	No growth after 48 h	
Cerebrospinal fluid		
Glucose	2.7 mmol	3.3–4.4
WCC	1400 /µl	< 5
Protein	0.68 g/l	0.15–0.45

White cell count (WCC)	12×10^9/l	4.0–11.0
Platelets (PLT)	310×10^9/l	150–400
C-reactive protein	180 mg/l	< 10
Serum glucose	5.1 mmol	
Erythrocyte sedimentation rate (ESR)	35 mm/first hour	< 15
Blood cultures	No growth after 48 h	
Cerebrospinal fluid		
Glucose	2.7 mmol	3.3–4.4
WCC	1400 /µl	< 5
Protein	0.68 g/l	0.15–0.45
Culture	No growth after 48 h	

Which is the most likely causative organism?

A *Escherichia coli*

B *Haemophilus influenzae* type B

C *Neisseria meningitidis*

D *Staphylococcus epidermidis*

E *Streptococcus pneumoniae*

71449

D *Staphylococcus epidermidis*

E *Streptococcus pneumoniae*

Explanation

D *Staphylococcus epidermidis*

This is a coagulase-negative *Staphylococcus* species and it is the most common cause of meningitis after neurosurgical procedures; this patient has just had a ventriculoperitoneal shunt placed. Therefore, it is the most likely culprit in this case. The consideration of coagulase-negative *Staphylococcus* species is important, and these organisms are typically penicillin-resistant. Treatment would need to be given in line with local guidelines but is likely to include vancomycin.

A *Escherichia coli*

Although *E. coli* is one of the causes of meningitis in patients following neurosurgical procedures (such as ventriculoperitoneal shunt insertion), it is not the most common. The most common organism implicated in these infections is the coagulase-negative *Staphylococcus epidermidis*, which is the correct answer in this case.

B *Haemophilus influenzae* type B

Before routine vaccination against *Haemophilus*, this was a common cause of meningitis in 'normal' patients. However, a different group of organisms are implicated in post-surgical meningitis, the most common of which is the coagulase-negative *S. epidermidis* (which is the correct answer in this case).

12:39
On ...
625-262-0256
Leave

surgical meningitis, the most common of which is the coagulase-negative *S. epidermidis* (which is the correct answer in this case).

C *Neisseria meningitidis*

N. meningitidis is one of the most common causes of meningitis in the United Kingdom. However, this patient has had a neurosurgical procedure; meningitis in these patients is caused by a different group of organisms. The most common cause of post-procedure meningitis is *S. epidermidis*, a coagulase-negative *Staphylococcus* species, and this is the answer in this case.

E *Streptococcus pneumoniae*

This is one of the most common causes of meningitis in adults in the UK; however, this patient has recently had a neurosurgical procedure which has a different epidemiology. The most common cause of meningitis post-procedure is coagulase-negative *S. epidermidis*, and therefore this is the correct answer.

© Pastest 2019

Audio Video Share Participants More

12:39

A 71-year-old white man is admitted to your ward with a 3-day history of pleuritic right-sided chest pain, cough productive of green sputum, shortness of breath and a fever. He has smoked 20 cigarettes a day for 50 years and is usually fit and well. He has no penicillin allergy.

On examination, he is alert, has a fever of 38.1 °C and a respiratory rate of 40/min. He is tachycardic, pulse 120/min and his blood pressure is 86/61 mmHg. On chest auscultation, he has coarse inspiratory breath sounds and bronchial breathing in the right lower lobe.

Investigations:

Na^+	131 mmol/l
K^+	4.2 mmol/l
Urea	14.2 mmol/l
Creatinine	137 µmol/l
C-reactive protein (CRP)	314 µg/l
WCC	16.8×10^9/l
Hb	11.3 g/dl
PLT	534×10^9/l

Chest X-ray shows shadowing in the right lower zone and blunting of the right heart border.

You want to start this patient on medication for his pneumonia.

Which of the following antibiotics/antibiotic combinations would be a reasonable choice for treatment?

A	IV cefuroxime 1.5 g tds
B	Oral co-amoxiclav 625 mg tds + oral clarithromycin 500 mg bd

Rana Alnasser's screen

Investigations:

Na^+	131 mmol/l
K^+	4.2 mmol/l
Urea	14.2 mmol/l
Creatinine	137 μmol/l
C-reactive protein (CRP)	314 μg/l
WCC	16.8×10^9/l
Hb	11.3 g/dl
PLT	534×10^9/l

Chest X-ray shows shadowing in the right lower zone and blunting of the right heart border.

You want to start this patient on medication for his pneumonia.

Which of the following antibiotics/antibiotic combinations would be a reasonable choice for treatment?

A	IV cefuroxime 1.5 g tds
B	Oral co-amoxiclav 625 mg tds + oral clarithromycin 500 mg bd
C	IV levofloxacin 500 mg od and oral rifampicin 600 mg od
D	IV co-amoxiclav 1.2 g tds and IV clarithromycin 500mg BD
E	IV ciprofloxacin 400 mg bd

Explanation

D	IV co-amoxiclav 1.2 g tds and IV clarithromycin 500mg BD

This patient has severe community-acquired pneumonia (CAP) as defined by a CURB 65 score of 4. British Thoracic Society (BTS) guidelines have recommended that all patients with pneumonia are assessed using CURB 65.

Patients get 1 point each for

- confusion
- urea >7 mmol/l
- respiratory rate >30/min
- blood pressure <90 mmHg systolic and 60 mmHg diastolic and
- patient older than 65.

Scores 3+ indicate high mortality.

Treatment for severe CAP is of course driven by local antibiotic protocols but an acceptable choice of antibiotics would be the combination of co-amoxiclav and clarithromycin delivered IV as a first-line option.

A	IV cefuroxime 1.5 g tds

IV cefuroxime can be used for severe sepsis with oral clarithromycin if the patient is penicillin allergic.

B	Oral co-amoxiclav 625 mg tds + oral clarithromycin 500 mg bd

This treatment option could be considered for mild to moderate community-acquired pneumonia if amoxicillin had recently been used and shown to be ineffective.

12:42
On ...
625-262-0256
Leave

A IV cefuroxime 1.5 g tds

IV cefuroxime can be used for severe sepsis with oral clarithromycin if the patient is penicillin allergic.

B Oral co-amoxiclav 625 mg tds + oral clarithromycin 500 mg bd

This treatment option could be considered for mild to moderate community-acquired pneumonia if amoxicillin had recently been used and shown to be ineffective.

C IV levofloxacin 500 mg od and oral rifampicin 600 mg od

Rifampicin can be added if a staphylococcal cause of pneumonia is suspected.

E IV ciprofloxacin 400 mg bd

Ciprofloxacin is a good choice against *Pseudomonas* but has little use in the empirical treatment of CAP.

Rate this question:

Next Question

Previous Q... Tag Questi... Feedback End Session

Blog About Pastest Contact Us Help

© Pastest 2019

Audio Video Share Participants More

12:42

A 31-year-old man presents with his male partner for review. For the past few days he has had worsening diarrhoea with voluminous fluid loss.

On further questioning, he admits to weight loss over the past 6 months. Modified acid-fast staining of stool culture reveals red-stained round oocysts against a blue-green background. Investigations reveal a reduced CD4/CD8 ratio.

Which one of the following would be the most appropriate initial management in this case?

A	Oral ciprofloxacin
B	Oral metronidazole
C	IV cefotaxime
D	HIV testing
E	Oral co-amoxiclav

33186

Submit

Rana Alnasser's screen

A 31-year-old man presents with his male partner for review. For the past few days he has had worsening diarrhoea with voluminous fluid loss.

On further questioning, he admits to weight loss over the past 6 months. Modified acid-fast staining of stool culture reveals red-stained round oocysts against a blue-green background. Investigations reveal a reduced CD4/CD8 ratio.

Which one of the following would be the most appropriate initial management in this case?

Your answer was correct

A	Oral ciprofloxacin
B	Oral metronidazole
C	IV cefotaxime
D	HIV testing
E	Oral co-amoxiclav

Explanation

D HIV testing

This patient has diarrhoea with a stool sample that suggests oocysts consistent with *Cryptosporidium* infection. The reduced CD4/CD8 ratio raises the possibility of HIV infection, and screening for HIV is clearly required. In patients with a CD4 count of less than 200 cells/mm^3 blood, chronic diarrhoea is common once *Cryptosporidium*

Resp

C IV cefotaxime

D HIV testing

E Oral co-amoxiclav

Explanation

D HIV testing

This patient has diarrhoea with a stool sample that suggests oocysts consistent with *Cryptosporidium* infection. The reduced CD4/CD8 ratio raises the possibility of HIV infection, and screening for HIV is clearly required. In patients with a CD4 count of less than 200 cells/mm^3 blood, chronic diarrhoea is common once *Cryptosporidium* infection is established. Antibiotic trials for *Cryptosporidium* have been disappointing, and at present there is not enough evidence to recommend any particular regime, but some patients do appear to respond to nitzoxanide. In patients who are HIV-negative, the infection tends to be self-limiting and patients recover after only a few days.

A Oral ciprofloxacin

Ciprofloxacin is a good treatment option for gastrointestinal infection with *Salmonella*, *Shigella* and *Campylobacter*. The abnormal staining of acid-fast pathogens makes this unlikely. In addition, the partner is not unwell and there is no history of ingestion of contaminated food.

B Oral metronidazole

Metronidazole would be a good antibiotic choice if

blood, chronic diarrhoea is common once *Cryptosporidium* infection is established. Antibiotic trials for *Cryptosporidium* have been disappointing, and at present there is not enough evidence to recommend any particular regime, but some patients do appear to respond to nitzoxanide. In patients who are HIV-negative, the infection tends to be self-limiting and patients recover after only a few days.

A Oral ciprofloxacin

Ciprofloxacin is a good treatment option for gastrointestinal infection with *Salmonella*, *Shigella* and *Campylobacter*. The abnormal staining of acid-fast pathogens makes this unlikely. In addition, the partner is not unwell and there is no history of ingestion of contaminated food.

B Oral metronidazole

Metronidazole would be a good antibiotic choice if anaerobes such as *Gardnerella*, *Entamoeba*, *Giardia* or Clostridium were suspected. This might be suspected with bloody diarrhoea or, for *C. difficile*, recent antibiotic use.

C IV cefotaxime

Cefotaxime provides good broad-spectrum cover and is useful in meningitis and pneumonia rather than for gastrointestinal infections.

E Oral co-amoxiclav

Co-amoxiclav provides far better cover for respiratory and urinary infections and would be of little use for this patient.

Rate this question:

A 61-year-old TV executive was evaluated in clinic with a history of increasing forgetfulness over the last 3 months. His family tells you that he has been more agitated and that the police brought him home last week as he was found wandering in the street. He does not drink alcohol or take any illicit drugs.

On examination, he has a broad-based gait with an intention tremor and past-pointing. You note several myoclonic jerks, brisk reflexes and bilateral upgoing plantars.

Cerebrospinal fluid (CSF) shows:

CSF fluid	1 white cell/ml (<5)
CSF fluid	2 red cells/ml (<5)
Protein	0.48g/l (0.15–0.45)
Glucose	5.2 mmol/l (3.3–4.4)

T_2-weighted magnetic resonance imaging (MRI) shows high signal in the caudate and putamen.

What is the most likely diagnosis?

A Vascular lymphoma

B Sporadic Creutzfeld–Jakob disease

C Subacute sclerosing panencephalitis

D Familial Alzheimer's dementia

E Paraneoplastic encephalopathy

Explanation

B Sporadic Creutzfeld-Jakob disease

Sporadic Creutzfeld-Jakob disease (CJD) is a prion disease. Normal prion proteins are found on cell surfaces all over the body mainly in an α-helix structure. The disease form is mainly in a β-sheet structure.

Peak incidence is in the seventh decade of life and characteristically involves a rapidly progressive dementia from a few weeks' duration to less than 2 years. Commonly accompanying features include cerebellar ataxia, pyramidal and extrapyramidal signs and myoclonus. A definitive diagnosis can only be made on postmortem. The other diagnoses are less likely.

A Vascular lymphoma

Vascular lymphoma is a rare subtype of large B-cell lymphoma. In this disease, there is proliferation of clonal lymphocytes within small vessels without infiltration of surrounding tissue. Presentation is often with focal neurological symptoms and signs and MRI can show multiple hyperintense lesions. The absence of such lesions on the MRI makes this a less likely diagnosis.

C Subacute sclerosing panencephalitis

This is a rare form of persistent measles infection causing a progressive encephalitis. It is characterised by a history of primary measles infection followed by progressive psychoneurological deterioration. The absence of measles and the patient's age make this unlikely.

D Familial Alzheimer's dementia

The rapid onset of his symptoms and the neurological findings makes this diagnosis unlikely.

neurological symptoms and signs and MRI can show multiple hyperintense lesions. The absence of such lesions on the MRI makes this a less likely diagnosis.

C Subacute sclerosing panencephalitis

This is a rare form of persistent measles infection causing a progressive encephalitis. It is characterised by a history of primary measles infection followed by progressive psychoneurological deterioration. The absence of measles and the patient's age make this unlikely.

D Familial Alzheimer's dementia

The rapid onset of his symptoms and the neurological findings makes this diagnosis unlikely.

E Paraneoplastic encephalopathy

The absence of known neoplasia makes this unlikely. The level of CSF protein would also be expected to be much higher.

Rate this question:

Next Question

© Pastest 2019

A 78-year-old lady presented to the Emergency Department with a 1-day history of a vesicular rash affecting her right shoulder and right upper chest. It was intensely painful and she had been taking maximal paracetamol and ibuprofen tablets to no avail. There are no other areas of rash apart from this.

What would be the best management?

A	Oral aciclovir
B	Oral opiates
C	Topical aciclovir
D	Topical clotrimazole
E	Topical hydrocortisone

Submit

Previous Q... Skip Questi...

© Pastest 2019

A 78-year-old lady presented to the Emergency Department with a 1-day history of a vesicular rash affecting her right shoulder and right upper chest. It was intensely painful and she had been taking maximal paracetamol and ibuprofen tablets to no avail. There are no other areas of rash apart from this.

What would be the best management?

Your answer was correct

A	Oral aciclovir
B	Oral opiates
C	Topical aciclovir
D	Topical clotrimazole
E	Topical hydrocortisone

Explanation

A Oral aciclovir

The history and position of the rash is suggestive of shingles (herpes zoster). Due to her early presentation, oral aciclovir may help shorten the duration and severity of the episode. Initiation of antiviral therapy as early as possible in the course of acute zoster, and definitely within 72 h of onset, has been shown to be effective in alleviating acute pain and preventing post-herpetic neuralgia (PHN) in most patients.

E Topical hydrocortisone

Explanation

A Oral aciclovir

The history and position of the rash is suggestive of shingles (herpes zoster). Due to her early presentation, oral aciclovir may help shorten the duration and severity of the episode. Initiation of antiviral therapy as early as possible in the course of acute zoster, and definitely within 72 h of onset, has been shown to be effective in alleviating acute pain and preventing post-herpetic neuralgia (PHN) in most patients.

B Oral opiates

This patient has signs and symptoms suggestive of shingles (herpes zoster). Opioid analgesia is unlikely to help with her pain, but treatment of the underlying condition with oral aciclovir can be effective in alleviating acute pain and it may prevent PHN.

C Topical aciclovir

This patient does have shingles (herpes zoster), but oral, not topical, aciclovir is the appropriate treatment. Early treatment with oral aciclovir has been shown to reduce acute pain and help prevent post-herpetic neuralgia.

D Topical clotrimazole

Clotrimazole is an anti-fungal agent; there is nothing in this patient's presentation to suggest that she has a fungal infection. Instead, her symptoms and signs are more consistent with shingles (herpes zoster) for which the appropriate treatment is oral aciclovir. Oral aciclovir has

12:48

A 42-year-old man presented with a 1-week history of general malaise, fever up to 38.5°C and night sweats. For the past 2 days he has had painful mouth ulcers. He returned to the UK 3 weeks previously from Nigeria, where he had been living for several months. On direct questioning, he reported having unprotected sexual intercourse with two local women over the past two months.

On examination he had widespread lymphadenopathy. There was no rash. Examination of all other systems was unremarkable.

Hb	14.2 g/dl (13.0–18.0)
WCC	8.5×10^9/l (4.0–11.0)
Lymphocytes	1.9×10^9/l (1.5–4.0)
PLT	190×10^9/l (150–400)
HIV antibodies	-
Blood cultures	No growth in 48 h from 2 samples
Thick and thin blood film	Negative in 2 samples
CXR	Normal

What is the most likely diagnosis?

A Dengue fever

B Falciparum malaria

C HIV infection

D Lyme disease

Rana Alnasser's screen

returned to the UK 3 weeks previously from Nigeria, where he had been living for several months. On direct questioning, he reported having unprotected sexual intercourse with two local women over the past two months.

On examination he had widespread lymphadenopathy. There was no rash. Examination of all other systems was unremarkable.

Hb	14.2 g/dl (13.0–18.0)
WCC	8.5×10^9/l (4.0–11.0)
Lymphocytes	1.9×10^9/l (1.5–4.0)
PLT	190×10^9/l (150–400)
HIV antibodies	-
Blood cultures	No growth in 48 h from 2 samples
Thick and thin blood film	Negative in 2 samples
CXR	Normal

What is the most likely diagnosis?

A Dengue fever

B Falciparum malaria

C HIV infection

D Lyme disease

E Typhoid infection

This patient has a prolonged fever, night sweats and widespread lymphadenopathy after unprotected sex; the most likely diagnosis is HIV. HIV antibody can be negative during seroconversion; a p24 antigen or HIV RNA PCR test would be a much better diagnostic test for this patient.

A Dengue fever

Typically dengue causes headache and fever in the returning traveller, and sometimes haemorrhagic rashes. However, it is unusual for dengue to cause night sweats, and very unusual for it to cause illness more than 2 weeks after returning from an endemic area. You might expect a higher fever than 38.5°C if this were dengue. This patient's symptoms and signs are better explained by HIV seroconversion; this would explain the lymphadenopathy and night sweats. HIV antibody can be negative in seroconversion: p24 antigen or HIV RNA PCR would be a better test for this patient.

B Falciparum malaria

This patient has returned from a malaria-endemic area and does have a fever, but he has had two negative blood films for malaria which makes this diagnosis less likely. Malaria does not explain his widespread lymphadenopathy or mouth ulcers. A much more likely diagnosis is HIV seroconversion. HIV antibody can be negative in seroconversion; a much better test would be either p24 antigen or HIV RNA PCR.

D Lyme disease

Lyme disease is not endemic in Nigeria. Widespread lymphadenopathy is uncommon in Lyme disease, and this patient does not have any rash. A much better explanation

D Lyme disease

Lyme disease is not endemic in Nigeria. Widespread lymphadenopathy is uncommon in Lyme disease, and this patient does not have any rash. A much better explanation for his symptoms and signs is HIV seroconversion, especially given that he has recently had unprotected sex. HIV antibody can be negative in seroconversion; a much better test would be p24 antigen or HIV RNA PCR.

E Typhoid infection

Typhoid results in prolonged high fever in the returning traveller and is caused by *Salmonella* infection. Classically patients have headache, constipation, high fever and a salmon-pink maculopapular rash. Typhoid would not explain this patient's widespread lymphadenopathy or mouth ulcers. You might expect a higher fever than 38.5°C if this were typhoid. This patient's presentation is much better explained by HIV seroconversion. HIV antibody can be negative during seroconversion; a much better test would be p24 antigen or HIV RNA PCR.

Rate this question:

Next Question

Previous Q... Tag Questi... Feedback End Session

Blog About Pastest Contact Us Help

© Pastest 2019

You are a senior house officer on the ward. An HIV-positive man is on treatment for TB with isoniazid, rifampicin, pyrazinamide and ethambutol. His treatment was commenced 1 week ago. He has a CD4 count of 100×10^6/l and the plan is to start him on antiretroviral therapy as an inpatient.

On the ward, he has a seizure which is self-terminating. Neurological examination reveals right-sided weakness affecting the arm and leg.

Further investigations reveal:

Glucose	5.1 mmol/l
Hb	10.2 g/dl
PLT	320×10^9/l
WCC	2.0×10^9/l
Urea and electrolytes	NAD

An urgent computed tomography (CT) of the head is requested, which reveals a solitary focal lesion in the left internal capsule with some surrounding oedema and mild effacement of the posterior horn of the lateral ventricle.

What is the most urgent next step?

A Add in a sixth antituberculous drug

B Urgent toxoplasma serology

C Lumbar puncture

D Commence sulphadiazine and pyrimethamine

E Magnetic resonance imaging (MRI) of the brain

12:57
On 625-262-0256 Leave

Explanation

D Commence sulphadiazine and pyrimethamine

Possible causes for a solitary focal lesion in this patient include cerebral toxoplasma, lymphoma and a tuberculoma (although solitary lesions are only seen in about 15% of toxoplasma cases). In an immunocompromised patient, always have a low index of suspicion for multiple pathologies.

E Magnetic resonance imaging (MRI) of the brain

Again, MRI may show additional features and aid the primary diagnosis while helping to exclude alternatives, such as meningitic TB, but it is not the most urgent step to be taken for this patient.

A Add in a sixth antituberculous drug

The presence of unilateral weakness following a seizure is not in keeping with central nervous system TB which is more likely to present with meningitic symptoms.

B Urgent toxoplasma serology

This would be a useful test to confirm the most likely diagnosis but is not urgent and treatment should not be delayed to await confirmation.

C Lumbar puncture

This would be dangerous given the features of increased intracerebral pressure evidenced on the CT scan.

Annotation Stop Share
Rate this question:
Audio Video Share Participants 1 More

A 29-year-old woman who received a cadaveric renal transplant two years ago comes to the Emergency Department complaining of watery diarrhoea that began three days ago. She has just returned from a holiday to Tunisia. Medication includes immunosuppression and ramipril for control of blood pressure.

On examination, her temperature is 38.4 °C, her blood pressure (BP) is 120/68 mmHg with a 20 mmHg postural drop and her pulse is 92/min and regular. She looks dehydrated and has a soft, diffusely tender abdomen.

Investigations:

Hb	13.1 g/dl
WCC	10.2×10^9/l
PLT	200×10^9/l
Na^+	140 mmol/l
K^+	3.5 mmol/l
Creatinine	185 µmol/l (142 at last clinic visit)
Stool sample	Oocysts identified

Which of the following is the most appropriate management?

A Supportive therapy with oral rehydration salts only

B Supportive therapy and oral ciprofloxacin

C Supportive therapy and oral loperamide

D Supportive therapy and oral nitazoxanide

E Supportive therapy and oral metronidazole

three days ago. She has just returned from a holiday to Tunisia. Medication includes immunosuppression and ramipril for control of blood pressure.

On examination, her temperature is 38.4 °C, her blood pressure (BP) is 120/68 mmHg with a 20 mmHg postural drop and her pulse is 92/min and regular. She looks dehydrated and has a soft, diffusely tender abdomen.

Investigations:

Hb	13.1 g/dl
WCC	10.2×10^9/l
PLT	200×10^9/l
Na^+	140 mmol/l
K^+	3.5 mmol/l
Creatinine	185 µmol/l (142 at last clinic visit)
Stool sample	Oocysts identified

Which of the following is the most appropriate management?

A Supportive therapy with oral rehydration salts only

B Supportive therapy and oral ciprofloxacin

C Supportive therapy and oral loperamide

D Supportive therapy and oral nitazoxanide

E Supportive therapy and oral metronidazole

1:02
On 625-262-0256 Leave

B Supportive therapy and oral ciprofloxacin

C Supportive therapy and oral loperamide

D Supportive therapy and oral nitazoxanide

E Supportive therapy and oral metronidazole

Explanation

D Supportive therapy and oral nitazoxanide

This woman almost certainly has *Cryptosporidium* acquired through the water supply at her Tunisian hotel. Given that she is significantly dehydrated, as evidenced by her postural drop and elevated creatinine, it is appropriate to treat her with anti-microbial therapy. Nitazoxanide interferes with the ability of the parasite to generate energy, by blocking the pyruvate ferredoxin oxidoreductase reaction. Supportive therapy with oral rehydration salts is of course also an essential part of therapy.

A Supportive therapy with oral rehydration salts only

This patient's clinical presentation and stool microscopy results are highly suggestive of *Cryptosporidium*. Supportive therapy with oral rehydration salts is an important part of her treatment; however, in the context of immunosuppression and significant dehydration, antimicrobial treatment would also be indicated.

B Supportive therapy and oral ciprofloxacin

Audio Video Share Participants 1 More

1:04
On 625-262-0256 Leave

immunosuppression and significant dehydration, antimicrobial treatment would also be indicated.

B Supportive therapy and oral ciprofloxacin

This patient's presentation is suggestive of *Cryptosporidium* diarrhoea. Supportive therapy is important, but ciprofloxacin is not a recognised treatment.

C Supportive therapy and oral loperamide

Given that this patient has significant dehydration associated with diarrhoea, supportive therapy is an important aspect of treatment. However, the history is suggestive of an underlying infectious aetiology and in this context loperamide would be contraindicated.

E Supportive therapy and oral metronidazole

This patient's presentation is suggestive of *Cryptosporidium* diarrhoea. Supportive therapy is important, but metronidazole is not an effective treatment.

Rate this question:

Next Question

Previous Q... Tag Questi... Feedback End Session

© Pastest 2019

Audio Video Share Participants More

1:04
On 625-262-0256 Leave

A 67-year-old man presents to the general practitioner (GP). He is from Southern India and is visiting the UK to see his son. His family has brought him to the doctor as he is unable to extend his wrist and has clawing of his fingers.

On examination, there is a dry scaling rash above the elbow on the affected side. The skin rash itself is painless and non-itchy, and there is evidence of sensory loss distal to the lesion.

Which of the following is the most likely diagnosis in this case?

A	Herpes zoster infection
B	Rickettsial infection
C	Lepromatous leprosy
D	Tuberculoid leprosy
E	Syphillis infection

9268

Submit

Previous Q... Skip Questi...

Audio Video Share Participants More

A 67-year-old man presents to the general practitioner (GP). He is from Southern India and is visiting the UK to see his son. His family has brought him to the doctor as he is unable to extend his wrist and has clawing of his fingers.

On examination, there is a dry scaling rash above the elbow on the affected side. The skin rash itself is painless and non-itchy, and there is evidence of sensory loss distal to the lesion.

Which of the following is the most likely diagnosis in this case?

Your answer was correct

A	Herpes zoster infection
B	Rickettsial infection
C	Lepromatous leprosy
D	Tuberculoid leprosy
E	Syphillis infection

Explanation

D Tuberculoid leprosy

This man comes from a region where leprosy infection is endemic and this clinical picture is highly suggestive of a tuberculoid leprosy picture. Serological testing can be employed to confirm the diagnosis and a number of PCR-based techniques are growing in popularity. Nerve

employed to confirm the diagnosis and a number of PCR based techniques are growing in popularity. Nerve conduction studies may show segmental slowing at the site of nerve entrapment. Skin biopsy may also be useful in confirming the diagnosis. Combination treatment with dapsone and rifampicin is usually employed for 6 months for paucibacillary leprosy; in the UK a 2-year course is recommended for multibacillary disease. While further nerve damage may be arrested by treatment, recovery of nerve function already lost is very unlikely.

Clinical leprosy lies between two extremes: tuberculoid (TT) and lepromatous (LL). Between the two ends of the spectrum lies a broad group designated as borderline, and subclassified as borderline tuberculoid (BT), midborderline (BB) and borderline lepromatous (BL). The disease does not remain static but evolves spontaneously or in response to therapy. Transition toward the TT pole is referred to as upgrading (and may lead to a reversal or type I reaction) and transition toward the LL pole as downgrading (leading to type II reaction or erythema nodosum leprosum [ENL]). The reactions reflect abrupt changes in the host-parasite immunological balance and are associated with acute clinical exacerbations.

A Herpes zoster infection

Herpes zoster virus causes varicella (chickenpox) in childhood and shingles during immunosuppression or old age. Shingles is characterised first by a pre-eruptive phase causing burning, itching or paraesthesia in one dermatome, leading to an eruptive phase with erythematous swollen plaques with clusters of small vesicles which are limited by dermatomal distribution. The absence of pain and the presence of weakness make this diagnosis unlikely.

B Rickettsial infection

Rickettsia organisms are Gram-negative coccobacilli which are obligate intracellular parasites found primarily in rats

Rana Alnasser's screen

not explain the neurological features.

C Lepromatous leprosy

This form of leprosy is systemic with symmetrical distribution and associated symptoms and signs. It is far more severe with reddish or hypopigmented patches with reduced sensation. There is also ocular involvement and systemic disease affecting the respiratory tract, kidneys and lymph nodes.

E Syphillis infection

While secondary syphilis can have a painless and asymptomatic limb rash, and tertiary syphilis can be associated with focal neurological lesions, the absence of any other features makes this an unlikely diagnosis. Primary syphilis causes a single painless ulcer at the site of infection with lymphoadenopathy. Secondary syphilis can occur 6 weeks later in 25% of untreated patients; it features a polymorphic rash of the palms and soles, but other organs can be affected. Over time, tertiary syphilis can develop with neurological syphilis and cardiovascular syphilis.

Rate this question:

Next Question

Previous Q... Tag Questi... Feedback End Session

© Pastest 2019

Rana Alnasser's screen

3G 1:09

A 42-year-old farmer is brought to the Emergency Department by his wife. She is very worried about him, as he has been unable to leave the house and get to work because of a fever and feeling completely washed out. He has been working particularly hard as they have some concerns about finance. They tell you that he was clearing some drainage ditches on the edge of one of his fields a few days ago.

On examination, he is pyrexial 38.2 °C and looks jaundiced. There is a bandage on his right leg from where he cut himself on some brambles. He has abdominal tenderness, particularly over his liver.

Investigations:

Hb	11.4 g/dl
WCC	13.3×10^9/l
PLT	56×10^9/l
Na^+	139 mmol/l
K^+	6.1 mmol/l
Creatinine	235 µmol/l
ALT	320 U/l
Bilirubin	290 µmol/l
CK	780 U/l

Which of the following is the most appropriate therapy for him?

A	N-acetylcysteine
B	Erythromycin
C	Benzylpenicillin

Rana Alnasser's screen

has been working particularly hard as they have some concerns about finance. They tell you that he was clearing some drainage ditches on the edge of one of his fields a few days ago.

On examination, he is pyrexial 38.2 °C and looks jaundiced. There is a bandage on his right leg from where he cut himself on some brambles. He has abdominal tenderness, particularly over his liver.

Investigations:

Hb	11.4 g/dl
WCC	13.3×10^9/l
PLT	56×10^9/l
Na^+	139 mmol/l
K^+	6.1 mmol/l
Creatinine	235 µmol/l
ALT	320 U/l
Bilirubin	290 µmol/l
CK	780 U/l

Which of the following is the most appropriate therapy for him?

A N-acetylcysteine

B Erythromycin

C Benzylpenicillin

D Fresh frozen plasma

E Ciprofloxacin

1:11

MyPastest
https://mypastest.pastest.com

Pastest+

Department by his wife. She is very worried about him, as he has been unable to leave the house and get to work because of a fever and feeling completely washed out. He has been working particularly hard as they have some concerns about finance. They tell you that he was clearing some drainage ditches on the edge of one of his fields a few days ago.

On examination, he is pyrexial 38.2 °C and looks jaundiced. There is a bandage on his right leg from where he cut himself on some brambles. He has abdominal tenderness, particularly over his liver.

Investigations:

Hb	11.4 g/dl
WCC	13.3 × 10^9/l
PLT	56 × 10^9/l
Na^+	139 mmol/l
K^+	6.1 mmol/l
Creatinine	235 µmol/l
ALT	320 U/l
Bilirubin	290 µmol/l
CK	780 U/l

Which of the following is the most appropriate therapy for him?

Your answer was correct

A N-acetylcysteine

Pee
A
B
C
D
E
0 10
Ses
Respons
Respons
Respons
Respons

D Fresh frozen plasma

E Ciprofloxacin

Explanation

C Benzylpenicillin

This unfortunate man has the severe form of leptospirosis known as Weil's disease, spread via rats' urine. It is likely that the cut on his leg, and wading through his drainage ditches, provided the route for infection. Infection leads to thrombocytopenia, jaundice with only a modest rise in transaminases, kidney disease and increased CK. Benzylpenicillin or IV cephalosporins are drugs of choice for severe infection, with doxycycline a possible alternative in patients who are penicillin allergic. Thankfully most patients with leptospirosis suffer from a relatively mild infection and recover. Mortality from Weil's disease is particularly high, however, in patients who are elderly or in those with pre-existing pathology.

A N-acetylcysteine

N-acetylcysteine is the treatment of choice for significant paracetamol overdose. This patient's presentation is highly suggestive of leptospirosis, and as we are not given any suggestion of paracetamol exposure, targeted antimicrobial treatment is the treatment of choice.

B Erythromycin

Erythromycin is a macrolide antibiotic with activity against Gram-positive and atypical organisms. This patient's presentation is highly suggestive of leptospirosis, and although erythromycin has some activity there is a better option available.

particularly high, however, in patients who are elderly or in those with pre-existing pathology.

A N-acetylcysteine

N-acetylcysteine is the treatment of choice for significant paracetamol overdose. This patient's presentation is highly suggestive of leptospirosis, and as we are not given any suggestion of paracetamol exposure, targeted antimicrobial treatment is the treatment of choice.

B Erythromycin

Erythromycin is a macrolide antibiotic with activity against Gram-positive and atypical organisms. This patient's presentation is highly suggestive of leptospirosis, and although erythromycin has some activity there is a better option available.

D Fresh frozen plasma

Fresh frozen plasma may be used to correct specific clotting factor deficiencies or to reverse the effect of warfarin (although its use is superseded by prothrombin complex concentrate). This patient's presentation is suggestive of leptospirosis and therefore targeted antimicrobial therapy is the treatment of choice.

E Ciprofloxacin

Ciprofloxacin is a fluoroquinolone antibiotic with a wide spectrum of activity against Gram-negative and some Gram-positive bacteria. Because the patient's presentation is suggestive of leptospirosis, ciprofloxacin would not be an effective treatment.

Rate this question:

1:13
On 625-262-0256 Leave

A 28-year-old patient currently on FLAG-IDA chemotherapy for acute myeloid leukaemia (AML) presents with fever. Bloods on admission show that he is flat neutropenic and he is therefore started on pipercillin/tazobactam (tazocin) and gentamicin for febrile neutropenia. His fevers continue, and on day 3 his antibiotics are changed to meropenem and vancomycin.

Unfortunately, his fevers persist and no clear source of infection has been identified. As part of a full work-up, you repeat all cultures and arrange a high-resolution CT chest, which is reported as consistent with invasive aspergillosis.

Which of the following would be an appropriate treatment choice?

A	Co-amoxiclav
B	Ciprofloxacin
C	Voriconazole
D	Fluconazole
E	Gentamicin

Submit

Audio Video Share Participants More

1:14

MyPastest
https://mypastest.pastest.com

repeat all cultures and arrange a high resolution CT chest, which is reported as consistent with invasive aspergillosis.

Which of the following would be an appropriate treatment choice?

Your answer was correct

A	Co-amoxiclav
B	Ciprofloxacin
C	Voriconazole
D	Fluconazole
E	Gentamicin

Explanation

C Voriconazole

Voriconazole is an antifungal drug with a broad spectrum of activity against both yeasts and moulds. In this patient, with neutropenia and CT findings suggestive of invasive aspergillosis, voriconazole would be an appropriate addition to his antimicrobial therapy. Compared to amphotericin B, it is associated with a reduced incidence of renal impairment and decreased morbidity.

A Co-amoxiclav

Co-amoxiclav is a combination of amoxicillin and clavulanic

B Ciprofloxacin

Ciprofloxacin is a fluoroquinolone antibiotic with a broad spectrum of activity against Gram-negative and some Gram-positive bacteria. However, it adds no additional cover for our patient, who is already receiving broad-spectrum antibiotics.

D Fluconazole

Fluconazole is a triazole antifungal with activity against many yeasts, but no activity against moulds such as *Aspergillus*, which is the concern in this patient.

E Gentamicin

Gentamicin is an aminoglycoside antibiotic with activity against resistant Gram-negative organisms, including extended-spectrum beta-lactamase (ESBL) producers and *Pseudomonas*. However, it is unlikely to add any additional cover for our patient, who is already receiving broad-spectrum antibiotics.

Rate this question:

Next Question

© Pastest 2019

An 18-year-old man presents to the Genitourinary Medicine Clinic complaining of dysuria for the past week. He is systemically well. In his sexual history, he has had unprotected sexual intercourse with three partners in the past 6 months. The patient is allergic to tetracycline based antibiotics.

On examination, there is no penile discharge, testicular masses or tenderness. The abdomen is soft and non-tender. Urethral swab reveals 33 neutrophils per high-power field, no organisms are seen.

What is the most appropriate treatment for this patient?

A	No treatment needed
B	Nitrofurantoin
C	Ceftriaxone
D	Azithromycin
E	Metronidazole

Submit

Clinic complaining of dysuria for the past week. He is systemically well. In his sexual history, he has had unprotected sexual intercourse with three partners in the past 6 months. The patient is allergic to tetracycline based antibiotics.

On examination, there is no penile discharge, testicular masses or tenderness. The abdomen is soft and non-tender. Urethral swab reveals 33 neutrophils per high-power field, no organisms are seen.

What is the most appropriate treatment for this patient?

Your answer was correct

A	No treatment needed
B	Nitrofurantoin
C	Ceftriaxone
D	Azithromycin
E	Metronidazole

Explanation

D	Azithromycin

The patient has non-specific or non-gonococcal urethritis (NGU) as there were no gonococci seen on microscopy but presence of neutrophils on the penile swab. NGU is caused by chlamydia in 60% of cases. It can be caused by other bacteria such as *Ureaplasma urealyticum* and *Mycoplasma genitalium*. These organisms are rarely detected but are well covered by azithromycin and doxycycline which are both commonly used for NGU and recommended as first-

E Metronidazole

Explanation

D Azithromycin

The patient has non-specific or non-gonococcal urethritis (NGU) as there were no gonococci seen on microscopy but presence of neutrophils on the penile swab. NGU is caused by chlamydia in 60% of cases. It can be caused by other bacteria such as *Ureaplasma urealyticum* and *Mycoplasma genitalium*. These organisms are rarely detected but are well covered by azithromycin and doxycycline which are both commonly used for NGU and recommended as first-line treatment by the British Association for Sexual Health and HIV (BASHH). Alternative treatments include ofloxacin.

A No treatment needed

The patient most likely has a significant infection as is evidenced by the neutrophils on the penile swab and will need treatment. If the swab is negative then no treatment should be offered.

B Nitrofurantoin

This would be a possible treatment for urinary tract infection but this is unlikely to be the correct diagnosis as dysuria is a common presentation for NGU as well as UTI, especially in a male patient with a history of unprotected sexual encounters.

C Ceftriaxone

This would be the treatment for gonorrhoea. For this diagnosis microscopy would reveal Gram-negative

1:17

A 33-year-old woman who has completed her family comes to the Sexually Transmitted Diseases Clinic complaining of a grey-white fishing smelling vaginal discharge. She is married with one regular partner, has completed her family, and had an intra-uterine contraceptive device inserted some 10 weeks earlier. She tells you that she is washing herself 3-4 times per day, but the problem has not improved.

Examination reveals a grey-white malodourous vaginal discharge. Microscopy reveals the presence of clue cells.

Which one of the following is the most appropriate intervention?

A	Oral cephalexin
B	Oral clarithromycin
C	Oral coamoxiclav
D	Oral doxycycline
E	Oral metronidazole

70595

Submit

Previous Q... Skip Questi...

Rana Alnasser's screen

A 33-year-old woman who has completed her family comes to the Sexually Transmitted Diseases Clinic complaining of a grey-white fishing smelling vaginal discharge. She is married with one regular partner, has completed her family, and had an intra-uterine contraceptive device inserted some 10 weeks earlier. She tells you that she is washing herself 3-4 times per day, but the problem has not improved.

Examination reveals a grey-white malodourous vaginal discharge. Microscopy reveals the presence of clue cells.

Which one of the following is the most appropriate intervention?

Your answer was correct

A	Oral cephalexin
B	Oral clarithromycin
C	Oral coamoxiclav
D	Oral doxycycline
E	Oral metronidazole

Explanation

E	Oral metronidazole

This patient's symptoms, coupled with the presence of clue cells on microscopy, are consistent with a diagnosis of bacterial vaginosis. Oral metronidazole at a standard dose can be given for 5–7 days, one 2 g dose can be given stat,

E Oral metronidazole

Explanation

E Oral metronidazole

This patient's symptoms, coupled with the presence of clue cells on microscopy, are consistent with a diagnosis of bacterial vaginosis. Oral metronidazole at a standard dose can be given for 5–7 days, one 2 g dose can be given stat, or metronidazole vaginal gel can also be used. Clindamycin or tinidazole are alternatives to metronidazole.

A Oral cephalexin

Cephalosporins are not as effective as metronidazole in clearance of *Gardnerella*, although some limited data do suggest they clear the bacteria.

B Oral clarithromycin

Macrolides are ineffective in clearing *Gardnerella*.

C Oral coamoxiclav

Co-amoxiclav is ineffective in this setting and may increase the risk of *Candida* infection.

D Oral doxycycline

Doxycycline is a first-line therapy for treatment of chlamydia, not for the treatment of bacterial vaginosis.

70595

Rate this question:

A 28-year-old HIV-positive woman presents to clinic complaining of shortness of breath. She has a CD4 count of 120×10^6/l and has recently been started on antiretroviral therapy (ART). She admits that she quite often forgets to take her medication, including her prophylactic co-trimoxazole.

She describes a 1-week history of worsening shortness of breath on exertion and of retrosternal chest pain. She has a dry cough and has not produced any sputum.

On examination, she is febrile at 38.5 °C, respiratory rate is 28/min, O_2 saturations 97% on air, pulse 100 beats/min. The chest is clear on auscultation, cardiovascular examination is normal. A chest X-ray shows only fluffy shadowing around both hilae.

Which investigation is the most useful pointer to the underlying diagnosis?

A	Electrocardiogram (ECG)
B	Lateral chest film
C	Exercise oximetry
D	Bedside spirometry
E	D-dimer

Submit

A 28-year-old HIV-positive woman presents to clinic complaining of shortness of breath. She has a CD4 count of 120 × 10^6/l and has recently been started on antiretroviral therapy (ART). She admits that she quite often forgets to take her medication, including her prophylactic co-trimoxazole.

She describes a 1-week history of worsening shortness of breath on exertion and of retrosternal chest pain. She has a dry cough and has not produced any sputum.

On examination, she is febrile at 38.5 °C, respiratory rate is 28/min, O_2 saturations 97% on air, pulse 100 beats/min. The chest is clear on auscultation, cardiovascular examination is normal. A chest X-ray shows only fluffy shadowing around both hilae.

Which investigation is the most useful pointer to the underlying diagnosis?

Your answer was correct

A	Electrocardiogram (ECG)
B	Lateral chest film
C	Exercise oximetry
D	Bedside spirometry
E	D-dimer

Explanation

E D-dimer

Explanation

C Exercise oximetry

The most likely diagnosis is obviously *Pneumocystis jirovecii* pneumonia (PCP) Exercise oximetry is an extremely useful test in this setting, as patients who are oxygenated well at rest may desaturate dramatically on exercise. An arterial blood gas is also important as it will influence the treatment given. If $p(O_2)$ <9.3 kPa, then high-dose methyprednisolone should also be prescribed in addition to IV co-trimoxazole.
The main differential here is of pulmonary embolus. Being HIV-positive is an independent risk factor for thromboembolic disease. However, the history is inconsistent, with a progressive course and a dry cough and a very immunocompromised patient. Retrosternal chest pain is commonly seen in PCP.
The next investigation would probably be an electrocardiogram (ECG), but exercise oximetry and an arterial blood gas are even more pressing.

A Electrocardiogram (ECG)

Whilst an ECG should definitively be done for this patient, the question asked is what investigation would most likely lead to a diagnosis. As the clinical history is suggestive of PCP, an ECG is unlikely to guide to that diagnosis and is therefore not the correct option.

B Lateral chest film

A lateral X-ray would give a good view of the retrosternal space and would also help demonstrate a subtle

Whilst an ECG should definitively be done for this patient, the question asked is what investigation would most likely lead to a diagnosis. As the clinical history is suggestive of PCP, an ECG is unlikely to guide to that diagnosis and is therefore not the correct option.

B Lateral chest film

A lateral X-ray would give a good view of the retrosternal space and would also help demonstrate a subtle pneumothorax, but would not help diagnose PCP.

D Bedside spirometry

Bedside spirometry is helpful in the diagnosis of obstructive airway illness, such as asthma and COPD, as well as restrictive airway disease such as idiopathic pulmonary fibrosis, but is unlikely to be useful in this patient. Had there been a history or examination findings of wheeze, diurnal variation or heavy smoking history this would have been more relevant.

E D-dimer

D-dimer is a biochemical test which can help exclude pulmonary embolism and deep vein thrombosis and is very unlikely to lead to diagnosis even under those circumstances, due to low specificity. It should be requested in the case of a moderate suspicion of DVT or PE as determined by Wells score.

Rate this question:

Next Question

Previous Q... Tag Questi... Feedback End Session

A 58-year-old man presented to clinic with a 10-day history of malaise, headache, fever, night sweats, back pain and myalgia. He was a sheep farmer, and had no other medical conditions.

On examination, he appeared unwell. His temperature was 37.9ºC, and there was widespread lymphadenopathy and hepatosplenomegaly. There was mild tenderness on palpation of the sacroiliac joints.

Investigations:

Hb	13.8 g/dl (13.0–18.0)
WCC	6.4×10^9/l (4.0–11.0)
Neutrophils	3.4×10^9/l (1.5–4.0)
Basophils	0.08×10^9/l (<0.1)
Eosinophils	0.1×10^9/l (0.04–0.4)
PLT	100×10^9/l (150–400)
Bilirubin	35 µmol/l (1–22)
ALT	102 U/l (5–35)
AST	51 U/l (1–31)
Blood film	Leukoerythroblastic
X-ray lumbar spine	Lumbar degenerative changes with osteophyte formation

What is the most likely diagnosis?

A Acute myeloid leukaemia

B Brucellosis

C Chronic myeloid leukaemia

palpation of the sacroiliac joints.

Investigations:

Hb	13.8 g/dl (13.0–18.0)
WCC	6.4×10^9/l (4.0–11.0)
Neutrophils	3.4×10^9/l (1.5–4.0)
Basophils	0.08×10^9/l (<0.1)
Eosinophils	0.1×10^9/l (0.04–0.4)
PLT	100×10^9/l (150–400)
Bilirubin	35 µmol/l (1–22)
ALT	102 U/l (5–35)
AST	51 U/l (1–31)
Blood film	Leukoerythroblastic
X-ray lumbar spine	Lumbar degenerative changes with osteophyte formation

What is the most likely diagnosis?

A Acute myeloid leukaemia

B Brucellosis

C Chronic myeloid leukaemia

D Hydatid disease

E Organophosphate poisoning

ALT	102 U/l (5-35)
AST	51 U/l (1-31)
Blood film	Leukoerythroblastic
X-ray lumbar spine	Lumbar degenerative changes with osteophyte formation

What is the most likely diagnosis?

Your answer was correct

A Acute myeloid leukaemia

B Brucellosis

C Chronic myeloid leukaemia

D Hydatid disease

E Organophosphate poisoning

Explanation

B Brucellosis

It is caused by a Gram-negative bacterium that is transmitted by contact with infected livestock. The typical incubation period is 1-3 weeks with an insidious onset. This patient's symptoms of malaise, fever, back pain and night sweats are typical. Back pain is common, occurring in around 50% of patients. The findings of a leucoerythroblastic blood film and raised transaminases fit with the diagnosis. Diagnosis is via bone marrow culture or serum agglutination testing.

E Organophosphate poisoning

Explanation

B Brucellosis

It is caused by a Gram-negative bacterium that is transmitted by contact with infected livestock. The typical incubation period is 1–3 weeks with an insidious onset. This patient's symptoms of malaise, fever, back pain and night sweats are typical. Back pain is common, occurring in around 50% of patients. The findings of a leucoerythroblastic blood film and raised transaminases fit with the diagnosis. Diagnosis is via bone marrow culture or serum agglutination testing.

A Acute myeloid leukaemia

Typically a patient with acute myeloid leukaemia would either have a very high white cell count or very low, but it would be unusual to have a normal white cell count. Furthermore, you might expect bone marrow failure, with bleeding and bruising, and pancytopenia. Lymphadenopathy is possible but not common. Instead, this patient's symptoms, signs and investigations would be consistent with brucellosis through exposure to sheep.

C Chronic myeloid leukaemia

You would expect a patient with chronic myeloid leukaemia to have a raised basophil and eosinophil count, but these are normal here. You might also expect a leucocytosis and teardrop poikilocytes on the blood film. This patient's signs and symptoms are more consistent with brucellosis through exposure to infected sheep.

D Hydatid disease

4G 1:24
https://mypastest.pastest.com

A 60-year-old woman presents to the casualty department following a seizure witnessed by her daughter. The daughter reports that her mother is normally fit and well but had been complaining of headaches recently. The patient is on no known medications and is a non-smoker. She had recently returned from a trip to China. Physical examination findings are normal but the patient is in a postictal state. An urgent CT scan of the head is arranged and this shows a periventricular cystic lesion in the parietal lobe with surrounding oedema. The radiologist says that the appearance is compatible with neurocysticercosis.

Which of the following investigations would be most sensitive and specific for neurocysticercosis?

A	Fundoscopic examination to directly visualise subretinal parasites
B	Serum anticysticercal antibodies demonstrated by immunoblot assay
C	CSF enzyme-linked immunosorbent assay for detection of cysticercal antigens
D	Resolution of intracranial cystic lesions after therapy with albendazole
E	Single stool examination for ova and parasites of *Taenia solium*

Submit

1:27

Explanation

A Fundoscopic examination to directly visualise subretinal parasites

The pork tapeworm, *Taenia solium*, is the causative organism in cysticercosis, which can affect either the intestine, causing an intestinal tapeworm infection, or the central nervous system, causing neurocysticercosis. The infection is acquired through the ingestion of undercooked pork containing cysticerci of *T. solium*. It is important to elicit a history of exposure to an area in which the parasite is endemic. Since the signs and symptoms can be non-specific, certain criteria are required to diagnose the infection [1]. Diagnosis can be difficult as radiological signs are often non-specific and immunological tests are often non-specific. However, direct visualisation of parasites has a very high diagnostic yield and is considered an absolute criterion. The mainstay of treatment is symptomatic relief, eg anticonvulsants for seizures, corticosteroids for cerebral oedema. Antiparasitic drugs (albendazole) are used if viable cysticerci are suspected and should be given under expert supervision.

E Single stool examination for ova and parasites of *Taenia solium*

It is worth noting that since the eggs are shed intermittently, a single stool examination looking for ova and parasites may not be enough to identify the tapeworm carriers. While a positive result would be very specific, the sensitivity of the test is low.

B Serum anticysticercal antibodies demonstrated by immunoblot assay

Antibody studies are frustratingly non-specific for neurocysticercosis. It is still considered a major criterion

Rana Alnasser's screen

It is worth noting that since the eggs are shed intermittently, a single stool examination looking for ova and parasites may not be enough to identify the tapeworm carriers. While a positive result would be very specific, the sensitivity of the test is low.

B Serum anticysticercal antibodies demonstrated by immunoblot assay

Antibody studies are frustratingly non-specific for neurocysticercosis. It is still considered a major criterion but is not as specific as direct parasite visualisation.

C CSF enzyme-linked immunosorbent assay for detection of cysticercal antigens

This is because while neurocysticercosis often involves high parasite counts within the ventricles and basal cisterns there is not always evidence of antibodies within the CSF. If positive, it is considered a major rather than absolute criterion. CSF could also show an elevated eosinophil count and the presence of parasite antigens.

D Resolution of intracranial cystic lesions after therapy with albendazole

Albendazole is not always necessary for lesion resolution as has been documented in many cases.

Reference

Del Brutto OH, Rajshekhar V, White AC Jr, Tsang VC, Nash TE, Takayanagui OM, et al. Proposed diagnostic criteria for neurocysticercosis. Neurology, 2001, 57, 177-183.

Rate this question:

Next Question

1:31
On 625-262-0256 Leave

A 26-year-old woman attends the Sexually Transmitted Disease Clinic. She has noticed postcoital pain on a few occasions and some left-sided pelvic pain. There is a history of unprotected sexual intercourse with three different partners in the last 6 months.

Pelvic examination reveals adnexal tenderness. She takes the combined oral contraceptive pill.

Investigations:

Hb	13.4 g/dl
WCC	5.4×10^9/l
PLT	301×10^9/l
K^+	5.0 mmol/l
Na^+	139 mmol/l
Creatinine	90 µmol/l
Chlamydia serology	Positive

Select the most appropriate therapy from those given below?

A Ciprofloxacin

B Penicillin V

C Amoxicillin

D Doxycycline

E Clarithromycin

Audio Video Share Participants More

1:32

B Penicillin V

C Amoxicillin

D Doxycycline

E Clarithromycin

Explanation

D Doxycycline

Doxycycline given at a dose of 100 mg bd is an appropriate therapy for chlamydia infection. An alternative is azithromycin, which is an attractive alternative as it can be given as a single dose. Sexual contacts should also be traced and treated if possible. A significant number of female patients infected with chlamydia may go on to develop pelvic inflammatory disease. One case series unfortunately estimated that the diagnosis is missed in nearly 50% of Emergency Room attendees.

A Ciprofloxacin

Ciprofloxacin is a second-generation fluoroquinolone which selectively inhibit type II topoisomerases, causing DNA unwinding in bacterial cells. It is used for respiratory tract infections, cellulitis, urinary tract infections, prostatitis, endocarditis, gastroenteritis and otitis externa.

B Penicillin V

Penicillin V, or phenoyxymethylpenicillin, is a β-lactam bactericidal antibiotic indicated in streptococcal throat infections, otitis media and cellulitis and can be used prophylactically following splenectomy.

Rana Alnasser's screen

4G 1:32
On 625-262-0256 Leave

Ciprofloxacin is a second-generation fluoroquinolone which selectively inhibit type II topoisomerases, causing DNA unwinding in bacterial cells. It is used for respiratory tract infections, cellulitis, urinary tract infections, prostatitis, endocarditis, gastroenteritis and otitis externa.

B Penicillin V

Penicillin V, or phenoyxymethylpenicillin, is a β-lactam bactericidal antibiotic indicated in streptococcal throat infections, otitis media and cellulitis and can be used prophylactically following splenectomy.

C Amoxicillin

It is a β-lactam antibiotic used for the treatment of streptococcal throat infections, lower respiratory tract infections, cellulitis and urinary tract infections.

E Clarithromycin

It binds to 23S rRNA in the bacterial ribosome preventing translation of peptides and is used for the treatment of streptococcal throat infection, lower respiratory tract infection, *Helicobacter pylori* infection and Lyme disease.

Rate this question:

Next Question

Previous Q... Tag Questi... Feedback End Session

Audio Video Share Participants More

1:32

A 46-year-old intravenous drug user comes to the Accident and Emergency Unit with a purplish rash on his arms and feet. He states that the rash has been present for nearly 2 weeks and is progressively worsening. It is not pruritic or painful.

On examination, he is not in any acute distress. There is mild jaundice present. Heart and lung examination is within normal limits. Abdominal examination shows right upper quadrant tenderness with liver edge palpable 5 cm below the right costal margin. Skin examination reveals palpable purpura on both arms and his left foot. His right lower limb shows some erythematous nodules as well as livedo reticularis. CNS examination shows decreased strength in plantar flexion as well as decreased sensation of the left foot.

Some laboratory results are shown below:

HIV test	Negative
Hepatitis B surface antigen	Positive

Urine microscopy:

RBCs	+++
Protein	++
WBC	-ve

What is the most likely cause of his rash?

A	Idiopathic thrombocytopenic purpura
B	Henoch-Schönlein purpura (HSP)
C	Polyarteritis nodosa (PAN)

Rana Alnasser's screen

1:33

feet. He states that the rash has been present for nearly 2 weeks and is progressively worsening. It is not pruritic or painful.

On examination, he is not in any acute distress. There is mild jaundice present. Heart and lung examination is within normal limits. Abdominal examination shows right upper quadrant tenderness with liver edge palpable 5 cm below the right costal margin. Skin examination reveals palpable purpura on both arms and his left foot. His right lower limb shows some erythematous nodules as well as livedo reticularis. CNS examination shows decreased strength in plantar flexion as well as decreased sensation of the left foot.

Some laboratory results are shown below:

HIV test	Negative
Hepatitis B surface antigen	Positive

Urine microscopy:

RBCs	+++
Protein	++
WBC	-ve

What is the most likely cause of his rash?

A Idiopathic thrombocytopenic purpura

B Henoch-Schönlein purpura (HSP)

C Polyarteritis nodosa (PAN)

D Kaposi's sarcoma

E Impaired coagulation secondary to liver cirrhosis

Rana Alnasser's screen

1:34

C Polyarteritis nodosa (PAN)

D Kaposi's sarcoma

E Impaired coagulation secondary to liver cirrhosis

Explanation

C Polyarteritis nodosa (PAN)

The findings such as erythematous nodules, livedo reticularis, mononeuritis multiplex and kidney involvement are all suggestive of PAN, which also occurs in patients with hepatitis B. The presence of hepatitis B surface antigen demonstrates hepatitis B infection.

A Idiopathic thrombocytopenic purpura

This diagnosis most often presents with bruising, petechiae and epistaxis and is usually seen in children. It would not explain the proteinuria as well.

B Henoch-Schönlein purpura (HSP)

The purpuric rash of Henoch-Schönlein is usually present in lower extremities and buttocks. Renal involvement can be seen in HSP, but not the signs of mononeuritis multiplex.

D Kaposi's sarcoma

This diagnosis is extremely unlikely without HIV and would not explain the neurological features.

E Impaired coagulation secondary to liver cirrhosis

Rana Alnasser's screen

reticularis, mononeuritis multiplex and kidney involvement are all suggestive of PAN, which also occurs in patients with hepatitis B. The presence of hepatitis B surface antigen demonstrates hepatitis B infection.

A Idiopathic thrombocytopenic purpura

This diagnosis most often presents with bruising, petechiae and epistaxis and is usually seen in children. It would not explain the proteinuria as well.

B Henoch–Schönlein purpura (HSP)

The purpuric rash of Henoch–Schönlein is usually present in lower extremities and buttocks. Renal involvement can be seen in HSP, but not the signs of mononeuritis multiplex.

D Kaposi's sarcoma

This diagnosis is extremely unlikely without HIV and would not explain the neurological features.

E Impaired coagulation secondary to liver cirrhosis

The absence of features of chronic liver disease makes this an unlikely diagnosis and it also would not explain neurological features.

Rate this question:

Next Question

Previous Q... Tag Questi... Feedback End Session

A 62-year-old man presented with a 5-day history of shortness of breath and a cough productive of green sputum. He was able to give a clear and focused history.

On examination, his respiratory rate was 32 breaths per minute and his heart rate was 120 beats per minute. Blood pressure was 110/65 mmHg. On chest auscultation there were coarse crackles at the left lung base.

Investigations

Hb	126 g/l (130–180)
WCC	14.5×10^6/l (4.0–11.0)
Neutrophils	10×10^6/l (1.5–7.0
Urea	6.5 mmol/l (2.5–7.0)
Creatinine	130 µmol/l (60–110
CXR	Left lower lobe consolidation

He is diagnosed with community-acquired pneumonia.

Which factor is most indicative of severity?

A Blood pressure of 110/65 mmHg

B Evidence of focal consolidation

C Neutrophilia

D Pulse rate of 120 beats/min

E Respiratory rate of 32 breaths/min

E Respiratory rate of 32 breaths/min

Explanation

E Respiratory rate of 32 breaths/min

This forms part of the CURB-65 criteria, an evidence-based scoring system used to estimate the severity and guide the management of patients with community-acquired pneumonia. The components of CURB-65 are: confusion (not present in this patient); urea greater than 7 mmol/l (urea here is <7.0 mmol/l); respiratory rate greater than or equal to 30 breaths/min (this patient meets this criteria as his respiratory rate is 32 breaths/min); systolic blood pressure less than 90 mmHg (not met in this patient, who has a systolic blood pressure of 110 mmHg); diastolic BP less than 60 mmHg, and age over 65 years (this patient is 62 years old). A score of 0 in CURB-65 corresponds to a 0.7% risk of mortality, whereas a score of 5 corresponds to a 57% risk. With a score of 1, this patient's risk is 3.2%. He would be suitable for outpatient management. If he had scored 2 or more, he should be managed as an inpatient.

A Blood pressure of 110/65 mmHg

This question relates to the CURB-65 criteria: these clinical criteria provide evidence-based guidance on the severity of a community-acquired pneumonia and can be used to determine the appropriate management of a patient (admission vs. outpatient care, and antibiotic therapy). Blood pressure does form part of the CURB-65 criteria, but patients score a point if their systolic blood pressure is less than 90 mmHg or diastolic is less than 60 mmHg. This patient has a systolic blood pressure of 110 mmHg, and therefore this is not the correct answer. The only criterion on which this patient scores against the CURB-65 is for his respiratory rate, which is ≥ 30.

1:36
On 625-262-0256 Leave

on which this patient scores against the CURB-65 is for his respiratory rate, which is ≥ 30.

B Evidence of focal consolidation

Patients with community-acquired pneumonia can be scored against the CURB-65 criteria, an evidence-based scoring system that allows estimation of severity and therefore planning of appropriate management. Chest X-ray findings and evidence of focal consolidation do not feature in this scoring system. The only CURB-65 criterion met by this patient is for his respiratory rate, which is ≥32 breaths/min.

C Neutrophilia

This question is asking about CURB-65, an evidence-based scoring system used to determine the severity and appropriate management of community-acquired pneumonia. Neutrophilia is not one of the features of CURB-65; the only criterion in CURB-65 met by this patient is for his respiratory rate, as it is ≥32 breaths/min.

D Pulse rate of 120 beats/min

All patients with community-acquired pneumonia should be scored using CURB-65, an evidence-based system that estimates disease severity and guides appropriate management. Pulse rate is not one of the components of CURB-65: the only component met by this patient is respiratory rate, as his respiratory rate is ≥32 breaths/min.

Rate this question:

Scroll capture Draw Crop
Audio Video Share Participants More

1:36
On 625-262-0256 Leave

A 32-year-old woman presents to the Emergency Department some 18 h after eating tinned salmon. She complains of nausea, vomiting, dysphagia, diplopia and an extreme thirst that is unquenchable.

Over the few hours in the Observation Ward, she develops worsening double vision and ptosis. Mini-mental State Examination is normal. She has complex restriction with eye movements, with restriction of abduction and adduction bilaterally. She is also dysarthric.

Although progressive incoordination and diminished reflexes are noted, there is no sensory loss. Her blood pressure is 110/72 mmHg, with a pulse of 85/min and temperature is 37.2 °C.

Which one of the following interventions would be most appropriate given this clinical picture?

A	Urgent anaesthetic review
B	IV immunoglobulin
C	IV Ciprofloxacin
D	IV Metronidazole
E	Computed tomography (CT) of the brain

Submit
Scroll capture Draw Crop
Audio Video Share Participants More

1:37
MyPastest
https://mypastest.pastest.com

A 32-year-old woman presents to the Emergency Department some 18 h after eating tinned salmon. She complains of nausea, vomiting, dysphagia, diplopia and an extreme thirst that is unquenchable.

Over the few hours in the Observation Ward, she develops worsening double vision and ptosis. Mini-mental State Examination is normal. She has complex restriction with eye movements, with restriction of abduction and adduction bilaterally. She is also dysarthric.

Although progressive incoordination and diminished reflexes are noted, there is no sensory loss. Her blood pressure is 110/72 mmHg, with a pulse of 85/min and temperature is 37.2 °C.

Which one of the following interventions would be most appropriate given this clinical picture?

Your answer was incorrect

A	Urgent anaesthetic review
B	IV immunoglobulin
C	IV Ciprofloxacin
D	IV Metronidazole
E	Computed tomography (CT) of the brain

Explanation

A	Urgent anaesthetic review

Diff
Pee
A
B
C
D
E
0 10
Ses
Respons
Respons
Respons
Respons

1:38

A Urgent anaesthetic review

This clinical picture is highly suggestive of botulism, infection having occurred due to defective canning of the fish. Sporadic outbreaks of the disease, although rare, do still occur. Laboratory tests and imaging studies are not generally helpful in the diagnosis of the condition. The neurotoxin produced leads to CNS and autonomic nervous system paralysis, and later respiratory muscle weakness and hypoventilation can occur. For this reason the patient should be managed in an ITU setting. Supportive therapy with intubation and ventilation, respiratory physiotherapy, nasogastric tube placement and catheterisation is the treatment of choice for severe disease. Recovery occurs on average between 30 and 100 days after infection; severe cases may require ventilation for many months.

B IV immunoglobulin

IV immunoglobulin in the form of botulinum antitoxin can be useful, but only if given very early in presentation and in those who have ingested toxin but are as yet asymptomatic. This patient has presented with severe symptoms following several hours of illness, and it is too late to be of value.

C IV Ciprofloxacin

Ciprofloxacin is not useful for botulism, which is the most likely clinical diagnosis.

D IV Metronidazole

The antibiotics which can potentially be used in botulism against *Clostridium botulinum* include benzylpenicillin and metronidazole. However, whilst metronidazole can be used as treatment, the most important management is to stabilise the patient's airway as the paralysis can lead to

Rana Alnasser's screen

treatment of choice for severe disease. Recovery occurs on average between 30 and 100 days after infection; severe cases may require ventilation for many months.

B IV immunoglobulin

IV immunoglobulin in the form of botulinum antitoxin can be useful, but only if given very early in presentation and in those who have ingested toxin but are as yet asymptomatic. This patient has presented with severe symptoms following several hours of illness, and it is too late to be of value.

C IV Ciprofloxacin

Ciprofloxacin is not useful for botulism, which is the most likely clinical diagnosis.

D IV Metronidazole

The antibiotics which can potentially be used in botulism against *Clostridium botulinum* include benzylpenicillin and metronidazole. However, whilst metronidazole can be used as treatment, the most important management is to stabilise the patient's airway as the paralysis can lead to respiratory arrest and she may need ventilation.

E Computed tomography (CT) of the brain

The likely clinical diagnosis is botulism, and a CT brain is likely to delay reaching definitive airway management before respiratory paralysis occurs.

Rate this question:

Next Question

A 58-year-old woman presented with a 2-week history of fever and headache. She had returned 2 weeks previously from a 1-month safari holiday in South Africa. She took malarial prophylaxis while away and on her return, in accordance with her general practitioner (GP)'s instructions.

On examination, her temperature was 37.7 °C. She had a 1 cm-diameter black scab on her right forearm, surrounded by erythema and mild swelling. There was right axillary lymphadenopathy. She had a non-blanching petechial rash over her trunk. Her abdomen was mildly tender on examination, with no hepatosplenomegaly.

Investigations:

Thin films for malaria	Negative in two separate samples
Chest X-ray	Normal

Which is the management of choice?

A Artesunate

B Ciprofloxacin

C Conservative measures only

D Doxycycline

E Praziquantel

Submit

D Doxycycline

This patient has classic symptoms and signs of tick typhus, or *Rickettsia*, which is a common condition caused by a tick bite while walking in grassland in South Africa. The black lesion on her forearm is an eschar that forms at the site of the tick bite. The eschar, along with regional lymphadenopathy, vasculitic rash and flu-like symptoms, are features of a typical presentation. Doxycycline is the treatment of choice, as there is a risk of complications (end-organ damage, peripheral gangrene or secondary infections) and mortality.

A Artesunate

Artesunate is an anti-malarial treatment, but this patient does not have typical symptoms for malaria and has had two negative blood films. Although, strictly speaking, three malarial blood films are required to rule out malaria, this patient's symptoms and signs are not typical for malaria and she took appropriate prophylaxis, making the diagnosis even less likely.

B Ciprofloxacin

This patient's symptoms and signs are typical for tick typhus, or *Rickettsia*: the eschar at the site of the tick bite, with regional lymphadenopathy, a vasculitic rash and flu-like symptoms. It is a common condition contracted when walking in grassland in South Africa and other game parks. Doxycycline is the correct treatment for tick typhus; although ciprofloxacin has been used, it has been associated with treatment failures.

C Conservative measures only

This patient has tick typhus, caused by infection with

This patient has tick typhus, caused by infection with *Rickettsia* through a tick bite; this is common in travellers who have been walking through long grass whilet on safari. The black lesion on her arm is an eschar at the site of the tick bite, and regional lymphadenopathy, petechial rash, fever and flu-like symptoms are typical. This condition is easily treated with doxycycline; without treatment, the risk of complications (end-organ damage, peripheral gangrene or secondary infections) is much higher, and untreated, the condition has significant mortality.

E Praziquantel

Praziquantel is used in the treatment of schistosomiasis and other fluke infections. Schistosomiasis presents acutely in two ways. The most common is with swimmer's itch, which causes a self-limiting, itchy papular rash within 24 hours of exposure. Less commonly, katayama fever (acute schistosomiasis) develops 4–8 weeks post-exposure and presents with fever, urticaria, eosinophilia and wheeze. This patient's lesion is not characteristic with either of these presentations.

Rate this question:

Next Question

Previous Q... Tag Questi... Feedback End Session

Blog About Pastest Contact Us Help

© Pastest 2019

1:43

A 25-year-old woman presented with fever 1 week after returning from India. Her fevers followed a specific pattern, rising over the course of the day and then dropping by the next morning. She also had non-specific abdominal pain, malaise and a dry cough. She had noticed a rash on her trunk.

On examination, her temperature was 38.1 °C and she appeared dehydrated. She had diffuse abdominal tenderness and a pink maculopapular rash over her trunk.

Investigations:

Hb	11.9 g/dl (11.5–16.0)
WCC	11.1×10^9/l (4.0–11.0)
PLT	201×10^9/l (150–400)
Na^+	136 mmol/l (137–144)
K^+	4.4 mmol/l (3.5–4.9)
Creatinine	130 μmol/l (60–110)
Stool culture	Isolates of *Salmonella paratyphi*

The patient is keen not to be admitted to hospital.

Which of the following is the most appropriate treatment?

A Ciprafloxacin

B Doxycycline

C Erythromycin

D Azithromycin

E Flucloxacillin

Rana Alnasser's screen

A 25-year-old woman presented with fever 1 week after returning from India. Her fevers followed a specific pattern, rising over the course of the day and then dropping by the next morning. She also had non-specific abdominal pain, malaise and a dry cough. She had noticed a rash on her trunk.

On examination, her temperature was 38.1 °C and she appeared dehydrated. She had diffuse abdominal tenderness and a pink maculopapular rash over her trunk.

Investigations:

Hb	11.9 g/dl (11.5–16.0)
WCC	11.1 × 10^9/l (4.0–11.0)
PLT	201 × 10^9/l (150–400)
Na^+	136 mmol/l (137–144)
K^+	4.4 mmol/l (3.5–4.9)
Creatinine	130 µmol/l (60–110)
Stool culture	Isolates of *Salmonella paratyphi*

The patient is keen not to be admitted to hospital.

Which of the following is the most appropriate treatment?

Your answer was incorrect

A Ciprafloxacin

B Doxycycline

C Erythromycin

D Azithromycin

Difficulty: Average

Peer Responses %

Session Progress

Responses Correct:

Responses Incorrect:

Responses Total:

Responses - % Correct

1:46
On ...
625-262-0256
Leave

Explanation

D Azithromycin

This patient has typhoid fever, which can be caused by *Salmonella typhi* or *Salmonella paratyphi* subtypes. Her presentation with high intermittent fever, dry cough, malaise and abdominal pain is typical. Patients classically have constipation rather than diarrhoea. Typhoid fever can be treated with fluoroquinolones; however, given that this patient has contracted typhoid fever after travelling to India, there is a high chance that the organism is fluoroquinolone resistant, and azithromycin would be a safer choice of treatment.

A Ciprafloxacin

This patient has symptoms, signs and investigations consistent with typhoid fever: the high intermittent fever, dry cough, lack of diarrhoea and non-specific abdominal pain, and stool culture has confirmed the presence of *S. paratyphi*. Typhoid fever can be treated with fluoroquinolones such as ciprofloxacin; however, there is widespread resistance amongst typhoid organisms to fluoroquinolones, especially in India. Consequently, azithromycin would be a safer choice of treatment for this patient.

B Doxycycline

This patient has typhoid fever, caused by *S. paratyphi* and indicated by her intermittent high fevers, dry cough, lack of diarrhoea and non-specific abdominal pain, in combination with the findings on stool culture. Although doxycyline provides some coverage of *Salmonella*, there is widespread resistance amongst *typhi* and *paratyphi* species. A better and safer choice of antibiotic in this case would be azithromycin.

Audio Video Share Participants More

1:48

After working on a relief effort after a natural disaster during wet season in Thailand, a 29-year-old male presents 5 days after returning home with a 10-day history of fever, rigors, night sweats, myalgia and headache. He has a cough productive of green sputum with occasional flecks of fresh red blood, and right-sided pleuritic chest pain. He had suffered several minor wounds to both shins whilst working which did not appear to be healing. He admitted that he had been wading through water at times to help affected victims and may have even swallowed some at one point. He is a type 1 diabetic on insulin.

On examination, he is febrile, with a temperature of 39.2 °C and has a pulse of 110 bpm. His blood pressure is 90/58 mmHg and respiratory rate 24/min. His saturation on room air is 93%. He has a pustular eruption over both shins and cervical and inguinal lymphadenopathy. On chest percussion, there is a stony dullness over the right base, and on chest auscultation he has bronchial breathing over the right mid-zone and no air entry at the right base.

Chest X-ray shows a pleural effusion at the right base, with consolidation and a lung cavity in the right mid-zone. There is diffuse shadowing at the left base.

Investigations:

Hb	10.2 g/dl
WCC	13.3×10^9/l
PLT	536×10^9/l
Urea	10.1 mmol/l
Bilirubin	34 µmol/l
Creatinine	141 µmol/l
ALT	124 U/l
ALP	158 U/l
Albumin	33 g/l

Rana Alnasser's screen

is diffuse shadowing at the left base.

Investigations:

Hb	10.2 g/dl
WCC	13.3×10^9/l
PLT	536×10^9/l
Urea	10.1 mmol/l
Bilirubin	34 µmol/l
Creatinine	141 µmol/l
ALT	124 U/l
ALP	158 U/l
Albumin	33 g/l
CRP	287 µg/l

Blood cultures are negative at 5 days.

What is the most likely diagnosis?

A Mycoplasma pneumonia

B Actinomycosis

C Tuberculosis

D Melioidosis

E Streptococcal pneumonia

Submit

1:53

Explanation

D Melioidosis

Burkholderia pseudomallei, the organism that causes melioidosis, is endemic in Thailand, especially in wet season, and Northern Australia. When bacteria are aerosolised and enter the respiratory tract via inhalation or haematogenous spread, pulmonary infections occur presenting with pneumonia, pulmonary abscesses and pleural effusions resulting in septic shock. The incubation period is 1-21 days with a mean of 9 days. Risk factors are diabetes, alcohol use, chronic renal disease and prior respiratory disease.

During a natural disaster, ingestion of contaminated water from soil and inhalation of dust contaminated with the organism can occur. The history is similar to that of other cavitating lung lesions, and the diagnosis should be thought about primarily because of the location and public events prior to the presentation.

Culture of any available source (blood, sputum etc.) is usually the diagnostic method of choice. Treatment for pulmonary melioidosis includes intravenous ceftazidime or meropenem for 2 weeks, along with co-trimoxazole for 2 weeks. Recurrences have been known.

A Mycoplasma pneumonia

Mycoplasma pneumonia is a bacterial pneumonic illness. It does not cause lung cavitation, nor could it explain the non-healing leg wounds or inguinal lymphadenopathy. In addition, his water exposure in Thailand point to an alternative diagnosis.

B Actinomycosis

Rana Alnasser's screen

1:56
On
625-262-0256
Leave

READING LESIONS

ections
the primary
e skin.

o lungs,
Liver and

with
systemic

Annotation
Stop Share

LESIONS• ...

earn more

Updates
Search
Recent
More
Audio
Video
Share
Participants
More

1:57

A 53-year-old woman presented to clinic concerned about her exposure to chickenpox. She had a background of systemic lupus erythematosus and was taking high-dose prednisolone and hydroxychloroquine. She had no personal history of chickenpox. She had been exposed to chickenpox 2 days ago whilst looking after her 4-year-old granddaughter, who had become symptomatic with chickenpox. IgG varicella antibody proved positive.

What is the most appropriate management?

A	Aciclovir
B	Ganciclovir
C	Reassurance
D	Varicella immunisation
E	Varicella zoster immunoglobulin

Submit

Previous Q... Skip Questi...

Rana Alnasser's screen

1:58

MyPastest
https://mypastest.pastest.com

A 53-year-old woman presented to clinic concerned about her exposure to chickenpox. She had a background of systemic lupus erythematosus and was taking high-dose prednisolone and hydroxychloroquine. She had no personal history of chickenpox. She had been exposed to chickenpox 2 days ago whilst looking after her 4-year-old granddaughter, who had become symptomatic with chickenpox. IgG varicella antibody proved positive.

What is the most appropriate management?

Your answer was correct

A	Aciclovir
B	Ganciclovir
C	Reassurance
D	Varicella immunisation
E	Varicella zoster immunoglobulin

Explanation

C Reassurance

This patient is IgG positive for varicella, and therefore she has previously had chickenpox and is immune to her granddaughter's infection. She may have been so young, or

A 31-year-old female is seen in Neurology Outpatients with a 4-month history of poor concentration, memory loss and increasing clumsiness. Her partner tells you she has fallen three times in the last few weeks and that she now needs help doing up her laces. She has been incontinent of urine over the last 2 weeks. She is originally from Somalia and came to the UK 5 years ago.

On examination, she is cachectic and appears agitated. She has an ataxic gait. She has generalised motor weakness, hyper-reflexia and has upgoing plantars bilaterally. There appear to be a number of small skin tumours present on general inspection.

Cerebrospinal fluid (CSF) results:

Protein	0.35 g/l (0.15–0.45)
WCC	1/ml (<5)
RBC	0/ml (<5)
Glucose	5.3 mmol/l (3.3–4.4)

Computerised tomography (CT) of the brain shows cerebral atrophy with wide sulci. Magnetic resonance imaging (MRI) of the brain shows gross white matter abnormalities, particularly in the periventricular area.

What is the most likely diagnosis?

A Herpes simplex encephalitis

B HIV encephalopathy

C West Nile encephalitis

D Progressive multifocal leucoencephalopathy

a 4-month history of poor concentration, memory loss and increasing clumsiness. Her partner tells you she has fallen three times in the last few weeks and that she now needs help doing up her laces. She has been incontinent of urine over the last 2 weeks. She is originally from Somalia and came to the UK 5 years ago.

On examination, she is cachectic and appears agitated. She has an ataxic gait. She has generalised motor weakness, hyper-reflexia and has upgoing plantars bilaterally. There appear to be a number of small skin tumours present on general inspection.

Cerebrospinal fluid (CSF) results:

Protein	0.35 g/l (0.15–0.45)
WCC	1/ml (<5)
RBC	0/ml (<5)
Glucose	5.3 mmol/l (3.3–4.4)

Computerised tomography (CT) of the brain shows cerebral atrophy with wide sulci. Magnetic resonance imaging (MRI) of the brain shows gross white matter abnormalities, particularly in the periventricular area.

What is the most likely diagnosis?

A Herpes simplex encephalitis

B HIV encephalopathy

C West Nile encephalitis

D Progressive multifocal leucoencephalopathy

E Normal-pressure hydrocephalus

D Progressive multifocal leucoencephalopathy

E Normal-pressure hydrocephalus

Explanation

B HIV encephalopathy

This lady, who has come from Somalia, is likely to have undiagnosed AIDS. HIV encephalopathy (also called AIDS–dementia complex) comes on over a period of months with cognitive dysfunction and behavioural and motor abnormalities. Typically the presentation is of diffuse subcortical dementia, and poor balance, poor coordination, an ataxic gait and generalised motor weakness, and diffuse hyper-reflexia are often found. Patients become incontinent and develop seizures.

HIV encephalopathy can be prevented by successful highly active antiretroviral therapy (HAART). Once the encephalopathy occurs, however, reversibility with HAART is variable. Normal-pressure hydrocephalus occurs almost exclusively in elderly patients; in addition, the clinical course is very slowly progressive over many months and years. It would therefore be highly unlikely here.

A Herpes simplex encephalitis

Herpes simplex encephalitis is a viral infection of the brain parenchyma, typically caused by HSV-1 (but less commonly by HSV-2). Patients present with an acute history of fever and clouding of consciousness, with or without meningism. Typical CSF findings are of a lymphocytosis.

C West Nile encephalitis

hyper-reflexia are often found. Patients become incontinent and develop seizures.

HIV encephalopathy can be prevented by successful highly active antiretroviral therapy (HAART). Once the encephalopathy occurs, however, reversibility with HAART is variable. Normal-pressure hydrocephalus occurs almost exclusively in elderly patients; in addition, the clinical course is very slowly progressive over many months and years. It would therefore be highly unlikely here.

A Herpes simplex encephalitis

Herpes simplex encephalitis is a viral infection of the brain parenchyma, typically caused by HSV-1 (but less commonly by HSV-2). Patients present with an acute history of fever and clouding of consciousness, with or without meningism. Typical CSF findings are of a lymphocytosis.

C West Nile encephalitis

West Nile encephalitis is caused by the West Nile virus (WNV), which is transmitted by *Culex* mosquitoes. Birds are the natural host. Presentation ranges from asymptomatic (most common) to a severe meningoencephalitis. CSF findings would typically show a raised protein and moderate lymphocytosis. WNV has not been reported in patients who have not travelled outside the UK.

D Progressive multifocal leucoencephalopathy

Presentation typically includes a much more focal neurological presentation (e.g. hemiparesis, aphasia or ataxia), and magnetic resonance imaging (MRI) shows multiple non-enhancing white matter lesions, typically at the grey-white matter interface, without mass effect. The

2:01

A 38-year-old HIV-positive patient presents to the clinic complaining of increasing shortness of breath, dry cough and wheezing.

On examination, you can hear a left-sided monophonic wheeze. He has cutaneous Kaposi's and is a lifelong non-smoker.

Investigations:

Hb	10.3 g/dl
WCC	5.6×10^9/l
PLT	130×10^9/l
CD4	92 cells/mm^3
Na^+	140 mmol/l
K^+	5.0 mmol/l
Creatinine	120 µmol/l
Chest X-ray	Limited left lower zone collapse

Which of the following is the most likely diagnosis?

A Bronchial carcinoma

B Bronchial carcinoid

C Endobronchial Kaposi's sarcoma

D Bacterial pneumonia

E Tuberculosis

Rana Alnasser's screen

A Bronchial carcinoma

B Bronchial carcinoid

C Endobronchial Kaposi's sarcoma

D Bacterial pneumonia

E Tuberculosis

Explanation

C Endobronchial Kaposi's sarcoma

Pulmonary Kaposi's sarcoma is found in between 6% and 30% of patients with HIV, and is the most common tumour seen. In patients who have cutaneous Kaposi's, up to 75% have demonstrable pulmonary tumours on endobronchial biopsy. Unfortunately use of HAART does not significantly appear to affect the prognosis in patients with pulmonary Kaposi's, with a mean prognosis of only 1.6 years from the point of diagnosis.

A Bronchial carcinoma

Bronchial carcinoma would be on the differential diagnosis for a patient presenting with these symptoms and lobar collapse. However we are told he is a non-smoker and in the context of his profound immunosuppression and cutaneous Kaposi's, an alternative diagnosis is more probable.

B Bronchial carcinoid

2:03
On ...
625-262-0256
Leave

B Bronchial carcinoid

Carcinoid is a paraneoplastic syndrome characterised by facial flushing, diarrhoea and bronchial constriction. Pulmonary carcinoid syndrome occurs when the primary neuroendocrine tumour occurs in the lung. In our patient with profound immunosuppression and cutaneous Kaposi's, an alternative diagnosis is more likely.

D Bacterial pneumonia

Bacterial pneumonia typically presents with a history of fevers and a productive cough. Blood tests would classically show a neutrophilia. However in practice it may be difficult to exclude infection in this case and further imaging and possible bronchoscopy would be indicated.

E Tuberculosis

Pulmonary tuberculosis most commonly causes upper-lobe consolidation and cavitation. Presentation would be with fever, a productive cough and weight loss. However clinically it may be difficult to exclude tuberculosis in this case and further investigation such as a bronchoscopy would be indicated.

Rate this question:

Next Question

Previous Q... Tag Questi... Feedback End Session

Audio Video Share Participants More

2:03

A 32-year-old woman attends the hepatology clinic for review. She is 14 weeks' pregnant and was found to have abnormal hepatitis serology at her booking visit. She has no past medical history of note, although admits to intermittent IV drug abuse during her teenage years.

On examination, her blood pressure is 105/70 mmHg, with pulse 65/min and regular. Her BMI is 22 and there are no signs of chronic liver disease.

Investigations:

Hb	12.5 g/dl
WCC	7.0×10^9/l
PLT	203×10^9/l
Na^+	137 mmol/l
K^+	4.5 mmol/l
Creatinine	85 µmol/l
ALT	32 U/l
Bilirubin	12 µmol/l
ALP	182 U/l
Hep B surface antibody	Positive
Hep B core antibody	Positive
Hep Be antigen	Negative
Hep Bs antigen	Negative

Which of the following is the most likely diagnosis?

A Autoiummune hepatitis

B Chronic hepatitis B

Rana Alnasser's screen

signs of chronic liver disease.

Investigations:

Hb	12.5 g/dl
WCC	7.0×10^9/l
PLT	203×10^9/l
Na^+	137 mmol/l
K^+	4.5 mmol/l
Creatinine	85 µmol/l
ALT	32 U/l
Bilirubin	12 µmol/l
ALP	182 U/l
Hep B surface antibody	Positive
Hep B core antibody	Positive
Hep Be antigen	Negative
Hep Bs antigen	Negative

Which of the following is the most likely diagnosis?

A Autoiummune hepatitis

B Chronic hepatitis B

C Cleared hepatitis B

D Non-A non-B hepatitis

E Vaccination for hepatitis B

Na^+	137 mmol/l
K^+	4.5 mmol/l
Creatinine	85 µmol/l
ALT	32 U/l
Bilirubin	12 µmol/l
ALP	182 U/l
Hep B surface antibody	Positive
Hep B core antibody	Positive
Hep Be antigen	Negative
Hep Bs antigen	Negative

Resp
Resp
Resp
Resp

Which of the following is the most likely diagnosis?

Your answer was correct

A Autoiummune hepatitis

B Chronic hepatitis B

C Cleared hepatitis B

D Non-A non-B hepatitis

E Vaccination for hepatitis B

Explanation

C Cleared hepatitis B

Autoimmune hepatitis is an idiopathic cause of hepatitis and cirrhosis. There is association with autoimmune diseases and with anti-smooth muscle (ASMA) and anti-LKM-1 antibodies, as well as ASMA. Presentation is variable and can range from asymptomatic to fulminant, with associated features of liver disease on examination. This patient's liver function tests are normal for her, given that the ALP is likely raised from pregnancy.

B Chronic hepatitis B

The absence of hepatitis B antigens and normal liver function tests makes this unlikely.

D Non-A non-B hepatitis

Hepatitis C is another viral infection transmitted via blood and is relatively common in IV drug users.

E Vaccination for hepatitis B

Vaccination for hepatitis B is associated with the presence of surface antibodies but not core antibodies.

Rate this question:

© Pastest 2019

A 26-year-old man presented with a 1-week history of severe and worsening headache. He also complained of nausea, worse in the morning. He did not have photophobia. He was born in Nigeria but had moved to the UK 1 year previously.

On examination, his temperature was 38°C, pulse rate was 110 beats/min and blood pressure was 130/70 mmHg. His oral mucosa and tongue were coated with white patches which scraped away to reveal erythematous and sore mucosa. He had cervical, axillary and inguinal lymphadenopathy and appeared thin. There was no meningism, but there was a right-sided weakness with associated brisk reflexes. There was a right homonymous hemianopia.

Investigations:

Hb	118 g/l (130–180)
WCC	2.8×10^9/l (4–11)
Lymphocytes	0.8×10^9/l (1.5–4.0)
PLT	270×10^9/l (150–400)

What is the most likely diagnosis?

A Cerebral toxoplasmosis

B Cryptococcal meningitis

C Lyme disease

D Meningococcal meningitis

E Middle cerebral artery thrombosis

lymphadenopathy and appeared thin. There was no meningism, but there was a right-sided weakness with associated brisk reflexes. There was a right homonymous hemianopia.

Investigations:

Hb	118 g/l (130–180)
WCC	2.8×10^9/l (4–11)
Lymphocytes	0.8×10^9/l (1.5–4.0)
PLT	270×10^9/l (150–400)

What is the most likely diagnosis?

Your answer was correct

A Cerebral toxoplasmosis

B Cryptococcal meningitis

C Lyme disease

D Meningococcal meningitis

E Middle cerebral artery thrombosis

Explanation

A Cerebral toxoplasmosis

There are symptoms and signs suggestive of HIV in this patient: he appears to have lost weight, has widespread lymphadenopathy, has oral candidiasis and a marked lymphopenia. This immunocompromise would render him

Rana Alnasser's screen

D Meningococcal meningitis

E Middle cerebral artery thrombosis

Explanation

A Cerebral toxoplasmosis

There are symptoms and signs suggestive of HIV in this patient: he appears to have lost weight, has widespread lymphadenopathy, has oral candidiasis and a marked lymphopenia. This immunocompromise would render him vulnerable to infections such as toxoplasmosis. Headache with vomiting, no meningism and focal neurological signs is suggestive of raised intracranial pressure, and on a background of potential HIV cerebral toxoplasmosis should be the top differential. The patient should have an MRI head which will show ring-enhancing lesions. Treatment requires combination therapy with septrin or pyrimethamine/sulfadiazine and folinic acid. He should also be tested for HIV and started on retroviral therapy if he is found to be positive.

B Cryptococcal meningitis

Indeed, this patient appears to have signs and symptoms suggestive of undiagnosed HIV – weight loss, widespread lymphadenopathy, oral candidiasis and a marked lymphopenia – but you would expect cryptococcal meningitis to cause meningism and photophobia. Although focal neurology can be seen with cryptococcal meningitis, the combination of headache with vomiting and focal neurology is suggestive of a mass lesion causing raised intracranial pressure: this patient is more likely to have cerebral toxoplasmosis.

A 27-year-old man has returned home from a holiday in Kenya with flu-like symptoms. Within a few days he suffers a marked deterioration and is barely rousable when brought to the Emergency Department by ambulance.

On examination, he has pyrexia of 38.8 °C, is very drowsy and has neck stiffness.

Blood test results:

Hb	10.5 g/dl
WCC	10.2×10^9/l
PLT	122×10^9/l
Na^+	137 mmol/l
K^+	4.8 mmol/l
Creatinine	156 µmol/l
Parasitaemia	2.5%

You suspect cerebral malaria and begin treatment with quinine and doxycycline. The next morning the parasitaemia has risen to 3.2% and his platelet count is 77×10^9/l. He is stable, and there has been no further deterioration in his neurological status.

Which of the following is the most appropriate next step in therapy?

A Continue quinine and doxycycline and reassess response in 24 hours

B Add clindamycin

C Add fansidar

D Exchange transfusion

2:08

Hb	10.5 g/dl
WCC	10.2 × 10^9/l
PLT	122 × 10^9/l
Na^+	137 mmol/l
K^+	4.8 mmol/l
Creatinine	156 µmol/l
Parasitaemia	2.5%

D
E
O

Resp
Resp
Resp
Resp

You suspect cerebral malaria and begin treatment with quinine and doxycycline. The next morning the parasitaemia has risen to 3.2% and his platelet count is 77 × 10^9/l. He is stable, and there has been no further deterioration in his neurological status.

Which of the following is the most appropriate next step in therapy?

Your answer was incorrect

A Continue quinine and doxycycline and reassess response in 24 hours

B Add clindamycin

C Add fansidar

D Exchange transfusion

E Change to mefloquine

Explanation

Rana Alnasser's screen

A Continue quinine and doxycycline and reassess response in 24 hours

B Add clindamycin

C Add fansidar

D Exchange transfusion

E Change to mefloquine

Explanation

A Continue quinine and doxycycline and reassess response in 24 hours

Guidelines suggest allowing a period of 48 hours before assessing the response in terms of change in parasitaemia. This patient already fits the criteria for management on an intensive care unit; in patients with parasitaemia breaching the 10% level, exchange transfusion was formerly recommended, although modern data do not suggest it improves outcomes. It can also be considered for complications such as cerebral malaria (as here), acute respiratory distress syndrome, or significant renal dysfunction. While artesunate is recommended under WHO guidelines, it is only available in the UK on a named patient basis.

D Exchange transfusion

Exchange transfusion is the process by which a portion of blood is removed and replaced with transfused blood. This is no longer recommended as a treatment option for malaria.

uncomplicated malaria, but adding clindamycin when doxycycline is already given is of no additional benefit.

C Add fansidar

Fansidar is a combination of sulfadoxine and purimethamine which can be used for chloroquine-resistant falciparum malaria, but has severe side-effects such as Steven–Johnson syndrome.

E Change to mefloquine

Mefloquine can be used in combination as part of artesinin-combination treatment for uncomplicated falciparum malaria or on its own for two doses, but would not be recommended for cerebral malaria.

Rate this question:

Next Question

Previous Questi... Tag Question Feedback End Session

You are asked to review a 35-year-old African man with a history of HIV who has been admitted to the Cardiology Ward after a myocardial infarction. He has not brought his anti-viral medications into the hospital with him as he collapsed at a restaurant.

Calculator

Normal Values

On examination, he has peripheral fat loss and increased abdominal obesity.

Investigations:

Hb	11.4 g/dl
WCC	5.6×10^9/l
PLT	204×10^9/l
Na^+	139 mmol/l
K^+	5.3 mmol/l
Creatinine	130 µmol/l
Triglcerides	3.1 mmol/l
HDL	0.7 mmol/l
LDL	3.4 mmol/l
Glucose	8.7 mmol/l

K^+	5.3 mmol/l
Creatinine	130 µmol/l
Triglcerides	3.1 mmol/l
HDL	0.7 mmol/l
LDL	3.4 mmol/l
Glucose	8.7 mmol/l

Which of the following HIV medications is most likely to be associated with the above blood picture?

A	Fosamprenavir
B	Zidovudine
C	Indinavir
D	Maraviroc
E	Abacavir

Annotation Stop Share

Rana Alnasser's screen

E Abacavir

Explanation

B Zidovudine

Zidovudine is a nucleoside reverse-transcriptase inhibitor and was the first medication developed against HIV. Zidovudine is associated with fat redistribution and biochemical changes consistent with the insulin resistant phenotype seen here; this HIV lipodystrophy picture tends to be worse with zidovudine compared with newer agents. Fosamprenavir, indinavir and abacavir are also associated with insulin resistance but to a lesser extent.

C Indinavir

Indinavir is a protease inhibitor which is no longer recommended for routine use by the British HIV Association (BHIVA) and has been associated with increased risk of cardiovascular disease. Although indinavir is associated with insulin resistance, an alternative drug is more likely to have caused the described lipoatrophy.

A Fosamprenavir

Annotation Stop Share

Rana Alnasser's screen

protease inhibitor most commonly used in combination

D	Maraviroc

Maraviroc is a CCR5 inhibitor (entry inhibitor). It is only effective in people infected with CCR5 trophic HIV (ie not CXCR4) and therefore testing is required prior to its use. Insulin resistance and lipoatrophy are not commonly associated with maraviroc use.

E	Abacavir

Abacavir is a nucleoside reverse transcriptase inhibitor (NRTI). It is recommended by the British HIV Association (BHIVA) in association with lamivudine as an alternative to Truvada as part of a HAART regime. Abacavir cannot be used in patients who are HLA-B5701 positive due to a high risk of hypersensitivity. Abacavir may be associated with insulin resistance and lipodystrophy, but to a lesser extent that zidovudine.

20626

Rate this question:

Next Question

Previous Questi... Tag Question Feedback End Session

Annotation Stop Share

A 79-year-old woman has become drowsy and confused and is exhibiting signs of a left-sided weakness. She has been brought to the hospital by her home help. Apparently she has been unwell for a few days with diarrhoea after eating some French soft cheese.

Calculator

Normal Values

On examination, she is drowsy with a blood pressure of 124/77 mmHg, pulse of 95 bpm and a temperature of 38.5 °C. She is neglecting her left side with a 3/5 power weakness on examination.

Investigations:

Hb	12.1 g/dl
WCC	15.2×10^9/l
PLT	120×10^9/l
Na^+	139 mmol/l
K^+	4.9 mmol/l
Creatinine	120 μmol/l
CT head	No focal lesion identified
Lumbar puncture	Gram positive rods, low CSF glucose

Which of the following is the most likely causative organism?

Annotation

Stop Share

A Meningococcus

Rana Alnasser's screen

Creatinine	120 µmol/l
CT head	No focal lesion identified
Lumbar puncture	Gram positive rods, low CSF glucose

Which of the following is the most likely causative organism?

A Meningococcus

B *Listeria*

C *Klebsiella*

D *Pseudomonas*

E *Mycoplasma*

Submit

Annotation Stop Share

Rana Alnasser's screen

E *Mycoplasma*

Explanation

B *Listeria*

The clear clue here is the consumption of soft cheese, which may be unpasteurised and is not recommended for the elderly or for people who are pregnant. *Listeria* is a motile non-spore-forming Gram-positive bacillus. CNS infection can manifest as meningitis, meningoencephalitis or even with symptoms of hemiparesis, mimicking a stroke. Amoxicillin is the treatment of choice for *Listeria* CNS infection. It is worth noting that cephalosporins such as ceftriaxone commonly used empirically to treat meningitis have no activity against *Listeria* and therefore if the diagnosis is suspected (eg in the elderly), amoxicillin should be included in the treatment regime.

A Meningococcus

Neisseria meningitidis (meningococcus) is a Gram-negative diplococcus which is the most common cause of bacterial meningitis in the UK. Symptoms are typically fever, headache, neck stiffness, photophobia and vomiting with or without a non-blanching rash. Treatment is with IV ceftriaxone. In this case the risk factors, presentation and CSF findings point to an alternative diagnosis.

Annotation Stop Share

Rana Alnasser's screen

Symptoms are typically fever, headache, neck stiffness, photophobia and vomiting with or without a non-blanching rash. Treatment is with IV ceftriaxone. In this case the risk factors, presentation and CSF findings point to an alternative diagnosis.

C	*Klebsiella*

Klebsiella is a genus of Gram-negative bacteria. It is a commensal of the human gut and most commonly causes intra-abdominal or urinary infections. CNS infection is very uncommon outside of neonates and neurosurgery patients.

D	*Pseudomonas*

Pseudomonas is a Gram-negative bacterium which is intrinsically quite antibiotic resistant. CNS infection is very uncommon.

E	*Mycoplasma*

Mycoplasma is an atypical bacterium lacking a cell wall. Infection most commonly presents with a community-acquired pneumonia; however extrapulmonary disease including an encephalitis is possible (although more common in children). In this case we are told the Gram stain shows Gram positive rods, which excludes *Mycoplasma* as a possible cause.

A 28-year-old man presented with a 2-day history of severe headache and neck stiffness. He also had a 4-day history of non-bloody diarrhoea.

On examination, his temperature was 37.9 °C, blood pressure was 128/72 mmHg and pulse rate was 88 beats/min. He had meningism and mild photophobia. There were no neurological signs.

Calculator

Normal Values

Investigations:

Random plasma glucose	6.1 mmol/l
CT head	Normal

Lumbar puncture:

Opening pressure	22 cmHg
Appearance	Clear fluid
Appearance	No organisms seen
Cell count	80 cells/mm^3 (lymphocytes)
CSF protein	0.8 mmol/l (0.15–0.45)
CSF glucose	4.2 mmol/l (3.4 –4.4)

Annotation Stop Share

What is the most important next investigation?

Appearance	Clear fluid
Appearance	No organisms seen
Cell count	80 cells/mm^3 (lymphocytes)
CSF protein	0.8 mmol/l (0.15–0.45)
CSF glucose	4.2 mmol/l (3.4 –4.4)

What is the most important next investigation?

A	Blood cultures
B	CSF culture
C	CSF polymerase chain reaction (PCR)
D	CSF spectrophotometry
E	MRI head

Annotation Stop Share

Submit

Explanation

C	CSF polymerase chain reaction (PCR)

This patient has symptoms and signs consistent with meningitis (headache, fever, meningism). Investigations are suggestive of a viral cause (lymphocytic CSF, normal glucose, no organisms on CSF microscopy). It is likely that this patient's meningitis was caused by an enterovirus, given his preceding diarrhoea. However, it is important to rule out herpes simplex meningoencephalitis, as this would require specific treatment with aciclovir. If this is simply enterovirus, he can be treated with supportive therapy only.

A	Blood cultures

This patient has symptoms and signs consistent with meningitis (fever, headache, meningism) and the investigations are suggestive of a viral meningitis (lymphocytosis in CSF, normal glucose, no organisms seen). The most important investigation is CSF polymerase chain reaction (PCR) to identify whether this is herpes simplex meningoencephalitis. Given this patient's preceding diarrhoea, however, it is likely that this meningitis has been caused by an enterovirus. Blood cultures should be taken in addition to other investigations, as he is febrile, but it is not the most important investigation.

B	CSF culture

caused by blood breakdown products in the CSF. However, the CSF was not bloody and this patient does not describe a sudden-onset headache. This patient's fever, headache and meningism are more suggestive of an infective meningitis: this is most likely viral given the CSF lymphocytosis and lack of organisms on microscopy. Herpes simplex meningoencephalitis should be ruled out with CSF polymerase chain reaction (PCR).

E	MRI head

This patient likely has viral meningitis: he has a fever, headache and meningism, and investigations demonstrate a clear, lymphocytic CSF with no visible organisms. His preceding diarrhoea suggests enterovirus as a cause. CSF polymerase chain reaction (PCR) should be carried out to rule out herpes simplex meningoencephalitis: this can produce suggestive features on MRI, but MRI is not the diagnostic tool of choice.

Rate this question:

Next Question

Previous Questi... Tag Question Feedback End Session

Annotation Stop Share

A 32-year-old immigrant from the Indian subcontinent presents to the Emergency Department. He is known to be HIV positive but has been non-compliant with his antiretroviral therapy and his CD4 count is 80×10^6/l. He complains of a 3-week history of a worsening headache, and malaise, with 3 kg weight loss. He has also been suffering from a chronic cough, although he smokes 10 cigarettes per day and attributes this to be the likely cause.

On examination, he is unwell, temperature 38.8 °C, pulse 120 bpm, blood pressure 100/50 mmHg, O_2 saturation 98% on air. There are some moderately enlarged lymph nodes in his neck and axillae and evidence of oral candida, there are scattered crackles on auscultation of the chest, cardiovascular examination NAD.

On neurological examination, there is no focal neurology but marked neck stiffness and photophobia. Computed tomography (CT) of the head reveals no focal lesions.

Cerebrospinal fluid (CSF):

Opening pressure	24 cm H_2O
Protein	4.5 g/l
Glucose	1.8 mmol/l (plasma 4.5)
WCC	45×10^9/l of which 43×10^9/l are lymphocytes, 2×10^9/l are polymorphs, acellular preparation

Calculator

Normal Values

Annotation

Stop Share

Rana Alnasser's screen

Opening pressure	24 cm H_2O
Protein	4.5 g/l
Glucose	1.8 mmol/l (plasma 4.5)
WCC	45×10^9/l of which 43×10^9/l are lymphocytes, 2×10^9/l are polymorphs, acellular preparation

Which is the best treatment for this condition?

A	IV amphotericin
B	Sulphadiazine and pyrimethamine
C	Isoniazid, rifampicin, pyrazinamide, ethambutol, pyridoxine, corticosteroids
D	IV ceftriaxone
E	Antiretroviral therapy

Annotation Stop Share

Explanation

C	Isoniazid, rifampicin, pyrazinamide, ethambutol, pyridoxine, corticosteroids

The diagnosis is TB meningitis as evidenced by a lymphocytic meningitis with a subacute presentation. In cases where the CSF pressure is elevated, corticosteroids should also be considered. CSF shows high protein and very low glucose as you would expect. The treatment should start with an induction phase of 2 months of all of the above drugs followed by a continuation phase. The duration this second phase, the only antibiotics needed are isoniazid and rifampicin. The duration of the continuation phase would be 4 months in normal pulmonary TB but should be extended to 7 months in the case of CNS involvement, for a total treatment duration of 9 months.

A	IV amphotericin

It would be correct for a most likely diagnosis of cryptococcal meningitis. However, the history of travel from the Indian subcontinent, and history of a chronic cough are better pointers towards tuberculosis.

B	Sulphadiazine and pyrimethamine

It would be the correct treatment for toxoplasmosis. However, the normal CT scan is not in keeping with this diagnosis as it usually shows ring-enhancing

diagnosis less likely, and the presence of lymphocytes rather than neutrophils in the CSF is definitively not in keeping with bacterial meningitis.

E	Antiretroviral therapy

It would be the most appropriate treatment option for primary CNS lymphoma. This would be the best treatment for such patients as there is little response to chemotherapy; however the prognosis would remain extremely poor. In this case, no malignant cells were seen in the CSF and you would start by 'treating the treatable', in this case TB. Also, the presence of fever and the absence of any lesions on the CT scan make CNS lymphoma far less likely.

Rate this question:

Next Question

A 23-year-old medical student has returned from a six-week holiday travelling in Kenya. Prior to leaving he took all the relevant immunisations and was taking malaria prophylaxis up until the day he returned.

Over the last 12 days, he has since been experiencing intermittent fevers and rigors. For the last two days he has also been complaining of drenching night sweats and vomiting.

On examination, he appears drowsy but orientated. There is no lymphadenopathy or rash. Cardiovascular and respiratory examinations are unremarkable. Abdominal examination reveals hepatosplenomegaly. Neurological examination is unremarkable

Thin malaria film	Negative
Blood cultures	No growth in 24 h
Haemoglobin (Hb)	10.9 g/l
White cell count (WCC)	9.5×10^9/l
Platelets	100×10^9/l
Na^+	129 mmol/l
K^+	3.8 mmol/l
Glucose	3.7 mmol/l
Urea	15.6 mmol/l
Creatinine	118 μmol/l

Calculator

Normal Values

Annotation

Stop Share

Rana Alnasser's screen

Platelets	100×10^9/l
Na^+	129 mmol/l
K^+	3.8 mmol/l
Glucose	3.7 mmol/l
Urea	15.6 mmol/l
Creatinine	118 µmol/l

What is the most likely diagnosis?

A	Plasmodium falciparum
B	Typhoid fever
C	Plasmodium malariae
D	Paratyphoid fever
E	Dengue fever

Annotation Stop Share

A Plasmodium falciparum

Plasmodium falciparum malaria is the most likely diagnosis, (given the geographical distribution of falciparum and the fact he has symptoms of cerebral disease). It is important to remember that serial films are required to exclude the diagnosis. Prophylaxis does not give full protection and in addition this patient stopped taking his prophylactic treatment too early, whatever his treatment regime (Atovaquone/proguanil combination should be continued seven days after return, other drugs such as mefloquine for 4 weeks after return). The incubation period is 1-2 weeks. Patients often give a history of prodromal symptoms of headache, myalgia and anorexia. Signs include anaemia, jaundice and hepatosplenomegaly but without lymphadenopathy. Complications include cerebral malaria, which has a mortality of 20%. Hypoglycaemia occurs in patients who are taking quinine but also is a poor prognostic indicator. Acute kidney disease and pulmonary oedema are other less common complications.

C Plasmodium malariae

This is a cause of malaria but is less likely than falciparum because the patient took prophylaxis against malaria and resistance rates are low in malariae. Also, falciparum is far more likely to cause cerebral symptoms than malariae.

B Typhoid fever

D	Paratyphoid fever

Paratyphoid fever is very similar to typhoid fever except being caused by S. paratyphi. The absence of a rash, lymphopenia and diarrhoea makes this diagnosis unlikely as well.

E	Dengue fever

Dengue fever is endemic in tropical South-East Asia, and outbreaks have also occurred in the tropical regions of Australia. The illness is a haemorrhagic fever, carried by the Aedes mosquito and is caused by the Dengue virus. It is characterised by fever, severe headache and facial flushing. Dengue fever usually presents with a morbilliform rash in the trunk area and widespread lymphadenopathy, coupled with severe muscle pains. In the early stages there is a lymphocytosis, with later lymphopenia, thrombocytopenia and bleeding. On examination there may be hepatosplenomegaly. Treatment is supportive. The absence of myalgic features, headache and a rash makes this a less likely diagnosis, and the duration of fever for two weeks is long for dengue and makes it less likely.

Rate this question:

Next Question

Rana Alnasser's screen

Calculator

Normal Values

A 24-year-old woman presented to the Emergency Department with a 2-day history of blurred vision and a 3-hour history of increasing shortness of breath. She was a user of intravenous heroin and had previously been admitted with groin abscesses.

On examination, her temperature was 36.7 °C, respiratory rate 32 breaths/min and saturations 95% on air. There was no rash or neck stiffness. Her chest was clear. She had dysarthria and an ataxic gait. Her pupils were normal in diameter but were fixed and did not accommodate. There was bilateral ptosis and facial weakness.

Investigations:

Chest X-ray	Normal

Blood gas		Normal values
pH	7.36	7.35–7.45
$p(O_2)$	7.2 kPa	11.3–12.6
$p(CO_2)$	3.2 kPa	4.7–6.0
HCO_3	25 mmol/l	21–29

What is the most likely diagnosis?

Annotation

Stop Share

Rana Alnasser's screen

Investigations:

Chest X-ray	Normal

Blood gas		Normal values
pH	7.36	7.35–7.45
$p(O_2)$	7.2 kPa	11.3–12.6
$p(CO_2)$	3.2 kPa	4.7–6.0
HCO_3	25 mmol/l	21–29

What is the most likely diagnosis?

A	Botulism
B	Heroin overdose
C	Guillain–Barré syndrome
D	Meningococcal sepsis
E	Myasthenia gravis

Annotation Stop Share

This is a rare condition, but the patient's presentation is typical. This patient is an intravenous drug user, which is the most common route of exposure to botulinum toxin. Initially (within 1–8 days of contact with the toxin), the patient develops bilateral cranial nerve signs; here the patient has developed the typical blurred vision resulting from diplopia, and slurred speech from bulbar involvement. She has no impairment of consciousness, and the pupils are fixed but of normal diameter – again, this is a classical presentation of botulism. The patient is afebrile – fever is unusual in botulism. Her type 1 respiratory failure is due to paralysis of the respiratory muscles; she is likely to progress to type 2 respiratory failure rapidly without appropriate treatment.

B	Heroin overdose

Patients with a heroin overdose would not present with blurred vision and shortness of breath; instead patients are usually brought to the Emergency Department with severely impaired consciousness. In milder cases, patients have drowsiness, nausea and vomiting and constipation. You would also expect the patient to have pinpoint pupils in opiate overdose, which are not seen here. Finally, opiates are respiratory depressants and therefore in overdose can cause hypoxaemia (as in this patient's case), but through a reduced respiratory rate; here the patient's respiratory rate is raised. This patient's presentation is classic of botulism.

C	Guillain–Barré syndrome

Typically, Guillain–Barré syndrome presents with ascending weakness and

On
625-262-0256
Leave

sensory disturbance (ie beginning in the legs and progressing towards the arms and finally the face). It does not cause a tr[illegible]cular involvement is exceedingly uncommon. Therefore, although Guillain–Barré syndrome could explain her respiratory failure, it would not explain her presentation with blurred vision without any leg weakness or sensory disturbance. It also could not explain her fixed pupils. Instead, this constellation of symptoms and signs is typical of botulism.

D	Meningococcal sepsis

Although a raised respiratory rate is common in sepsis, meningococcal sepsis without pulmonary disease (her chest X-ray is normal) cannot explain the type 1 respiratory failure seen in her blood gas. If this were meningococcal meningitis, you would expect the patient to report a headache or you would expect to find fever, photophobia or neck stiffness on examination. None of these features are present. Cerebellar and bulbar signs (as seen here) have been reported in meningococcal meningitis, but it is an extremely uncommon presentation. Therefore, although the patient has neurological signs, these are unlikely to be explained by meningococcal meningitis. In fact, bilateral involvement of multiple cranial nerves and fixed pupils are typical of botulism; botulism can also explain her rapid-onset respiratory failure caused by paralysis of the intercostal muscles (hence type 1 respiratory failure on the blood gas).

Annotation
Stop Share

E	Myasthenia gravis

Rana Alnasser's screen
Audio
Video
Share
Participants
More

Calculator

Normal Values

A 40-year-old Dutch man presents to Accident and Emergency. He is complaining of worsening breathlessness. It has been progressive for the last month and he is also experiencing a persistent dry cough. His only past medical history is of infective endocarditis 7 years ago which developed as a consequence of injecting drugs intravenously. He admits that he last injected heroin 'the day before yesterday' but is unsure how much. He is on no medication and has no drug allergies. He has been staying at a homeless persons' hostel.

On examination, he has a temperature of 39 °C. pulse 120 bpm, BP 140/70 mmHg. Oxygen saturations 93% RA (on room air); RR 26/min. On exertion, he desaturates to 82% breathing room air. He has 2 × 2 cm lymph nodes in his right groin but otherwise no lymphadenopathy. Chest is clear with no evidence of consolidation. He has 2 cm hepatomegaly and a spleen tip is palpable. Cardiovascular examination reveals a pansystolic murmur at the lower left sternal edge.

A chest X-ray reveals diffuse shadowing throughout both lung fields. An arterial blood gas is as follows; p(O_2) 10.0 kPa, p(CO_2) 3.2 kPa, Sats 91% , Bic 19 mmol/l. Routine blood tests and blood cultures are taken.

What is the immediate management?

A IV naloxone

Rana Alnasser's screen

persons hostel.

On examination, he has a temperature of 39 °C. pulse 120 bpm, BP 140/70 mmHg. Oxygen saturations 93% RA (on room air); RR 26/min. On exertion, he desaturates to 82% breathing room air. He has 2 × 2 cm lymph nodes in his right groin but otherwise no lymphadenopathy. Chest is clear with no evidence of consolidation. He has 2 cm hepatomegaly and a spleen tip is palpable. Cardiovascular examination reveals a pansystolic murmur at the lower left sternal edge.

A chest X-ray reveals diffuse shadowing throughout both lung fields. An arterial blood gas is as follows; p(O_2) 10.0 kPa, p(CO_2) 3.2 kPa, Sats 91% , Bic 19 mmol/l. Routine blood tests and blood cultures are taken.

What is the immediate management?

A	IV naloxone
B	IV co-trimoxazole
C	IV benzylpenicillin and gentamicin
D	Isoniazid, rifampicin, ethambutol, pyrazinamide
E	Nebulised salbutamol

Annotation Stop Share

Rana Alnasser's screen

Explanation

B	IV co-trimoxazole

Pneumocystis jirovecii, previously known as Pneumocystis carinii, is the organism responsible for Pneumocystis carinii pneumonia (PCP); the most common opportunistic infection in HIV-infected patients. A bronchoscopy will help confirm whether this is Pneumocystis jirovecii or TB, although at the moment the clinical suggestion is more likely Pneumocystis jirovecii pneumonia.

A	IV naloxone

There is no evidence of opiate toxicity as he is tachypnoeic, not showing respiratory depression, and there is no mention of pin-point pupils.

C	IV benzylpenicillin and gentamicin

This could be a considered management plan if the primary diagnosis was infective endocarditis. However, the murmur is most likely to be chronic following the first episode of endocarditis and there are several features, such as the severe hypoxia and lung shadowing that infective endocarditis cannot explain.

Rana Alnasser's screen

A 33-year-old man presented with a 3-month history of skin lesions. The lesions had increased in number and size over preceding months. He did not have any medical conditions or take any medications.

On examination, he had a number of purple-red scaly patches, predominantly on both lower limbs. He also had oral candidiasis and widespread low-volume lymphadenopathy.

Investigations:

Hb	11.9 g/dl (13.0–18.0)
WCC	5.1×10^9/l (4.0–11.0)
Lymphocytes	0.9×10^9/l (1.5–4.0)

What is the most appropriate initial investigation?

A	HHV-6 testing
B	HIV testing
C	HPV testing
D	Lymph node biopsy
E	Skin prick allergy testing

Calculator

Normal Values

Annotation

Stop Share

Rana Alnasser's screen

B HIV testing

This rash is consistent with Kaposi's sarcoma, an AIDS-defining illness: in the context of oral candidiasis (in the absence of a background of inhaled steroids or other immunosuppression), lymphopenia and widespread lymphadenopathy, this is highly suggestive of undiagnosed HIV infection.

A HHV-6 testing

Human herpes virus 6 causes roseola infantum, and can also reactivate in the immunosuppressed or transplant recipient, causing bone marrow suppression or pneumonitis. This patient has a lymphopenia, widespread lymphadenopathy and oral candidiasis without any background of inhaled steroids or other immunosuppression. In the context of his rash, which would be consistent with Kaposi's sarcoma, this patient is likely to have undiagnosed HIV infection, not HHV-6, and so he should be tested for HIV positivity. Human herpes virus 8 (HHV-8) is the herpesvirus associated with Kaposi's sarcoma.

C HPV testing

Human papilloma virus causes warts, and is associated with various malignancies including cervical carcinoma. This patient has a rash consistent with Kaposi's sarcoma, which is not associated with HPV infection. Kaposi's sarcoma is an AIDS-defining illness, and this patient should be tested for HIV, especially given that he has widespread lymphadenopathy, a lymphopenia and oral candidiasis without any history of inhaled steroids or other

Rana Alnasser's screen

D	Lymph node biopsy

This patient has Kaposi's sarcoma, and combined with his oral candidiasis without a background of inhaled steroids, this is strongly suggestive of underlying immunosuppression, particularly of HIV. HIV would explain his lymphadenopathy and lymphopenia, and hence the most appropriate next investigation would be an HIV test.

E	Skin prick allergy testing

This patient's rash is not consistent with allergy; the description is suggestive of Kaposi's sarcoma. He has no history of allergy symptoms (itch, wheeze, swelling), but instead has oral candidiasis which cannot be explained by inhaled steroids or other immunosuppression. When combined with his widespread lymphadenopathy and lymphopenia, this patient's presentation is highly suggestive of undiagnosed HIV, and he should be HIV tested.

Rate this question:

Previous Questi... Tag Question Feedback End Session

Annotation Stop Share

Rana Alnasser's screen

A 43-year-old, sexually active, homosexual man was admitted 'off legs'. His illness started with a sore throat.

On examination, he had a temperature of 38.6 °C. There were multiple diffuse areas of exudate on his pharynx with cervical lymphadenopathy. The medical house officer on-call had noticed a swollen neck. He had recently been on holiday to Eastern Europe.

What is the most likely diagnosis?

A	Glandular fever
B	Acute myeloid leukaemia
C	Oesophageal candida
D	Streptococcal tonsillitis
E	Diphtheria

Calculator

Normal Values

Annotation

Stop Share

Submit

diffuse areas of exudate on his pharynx with cervical lymphadenopathy. The medical house officer on-call had noticed a swollen neck. He had recently been on holiday to Eastern Europe.

What is the most likely diagnosis?

Your answer was incorrect

A	Glandular fever
B	Acute myeloid leukaemia
C	Oesophageal candida
D	Streptococcal tonsillitis
E	Diphtheria

Session Progress

Responses Correct:	37
Responses Incorrect:	13
Responses Total:	50
Responses - % Correct:	74%

Explanation

E	Diphtheria

The history of travel to Eastern Europe associated with an exudative pharyngitis coupled with a swollen neck (bull neck) is highly suggestive of

Rana Alnasser's screen

E Diphtheria

Explanation

E Diphtheria

The history of travel to Eastern Europe associated with an exudative pharyngitis coupled with a swollen neck (bull neck) is highly suggestive of diphtheria. Diphtheria is derived from the Greek meaning 'leather hide' and was first described in the 5th century by Hippocrates. It is caused by *Corynebacterium diphtheriae*, which is an aerobic Gram-positive bacillus. In this question, it is of paramount importance not to assume that the patient is HIV positive and has an AIDS-defining illness as there is no history of how chaotic his lifestyle is. Diphtheria is an acute bacterial disease that usually affects the tonsils, throat, nose and/or skin. It is passed from person to person by droplet transmission, usually by breathing in *Corynebacterium diphtheriae* after an infected person has coughed, sneezed or even laughed. Symptoms usually appear 2–4 days after infection, with a range of 1–6 days. An epidemic of diphtheria in Eastern Europe and the states of the former Soviet Union resulted in over 5000 deaths between 1990 and 1995.

A Glandular fever

Glandular fever, or infective mononucleosis, is a self-limiting infection usually caused by Epstein–Barr Virus (EBV). It presents with low-grade fever,

this question, it is of paramount importance not to assume that the patient is HIV positive and has an AIDS-defining illness as there is no history of how chaotic his lifestyle is. Diphtheria is an acute bacterial disease that usually affects the tonsils, throat, nose and/or skin. It is passed from person to person by droplet transmission, usually by breathing in *Corynebacterium diphtheriae* after an infected person has coughed, sneezed or even laughed. Symptoms usually appear 2–4 days after infection, with a range of 1–6 days. An epidemic of diphtheria in Eastern Europe and the states of the former Soviet Union resulted in over 5000 deaths between 1990 and 1995.

A	Glandular fever

Glandular fever, or infective mononucleosis, is a self-limiting infection usually caused by Epstein–Barr Virus (EBV). It presents with low-grade fever, malaise and a sore throat with exudate. However, this is more typical of children and adolescents, and adults present with few throat symptoms or signs and have often no lymphoadenopathy.

B	Acute myeloid leukaemia

This diagnosis would not explain the exudate and is associated with hepatomegaly and splenomegaly, and lymphoadenopathy is less common than for other leukaemia.

C	Oesophageal candida

Rana Alnasser's screen

9:23
625-262-0256 Leave

A 19-year-old woman returns home with diarrhoea, having worked on a gap year project in Africa. She also complains of abdominal bloating, that her stools are difficult to flush away and of excessive flatulence. She has lost her appetite over the past couple of weeks and has lost 3 kg in weight.

On examination, she has a mild pyrexia (37.6 °C) and looks bloated.

Investigations:

Hb	12.1 g/dl
WCC	9.2×10^9/l
PLT	260×10^9/l
Na^+	141 mmol/l
K^+	4.8 mmol/l
Creatinine	100 µmol/l
Albumin	39 g/l
Stool sample	No cysts or ovae seen

Which of the following is the most appropriate therapy for her?

A Ciprofloxacin

B Doxycycline

C Albendazole

D Metronidazole

E Artemesin

Audio Video Share Participants More

D Metronidazole

The history and exposure described are typical for giardiasis, infection with the protozoan parasite *Giardia*. First-line treatment of choice is with metronidazole or tinidazole.

A Ciprofloxacin

Ciprofloxacin is a fluoroquinolone antibiotic with activity against many Gram negative, and some Gram-positive, bacteria. It is sometimes used to treat traveller's diarrhoea. However, in this case the history and exposure are typical for *Giardia* and therefore ciprofloxacin would not be appropriate treatment.

B Doxycycline

Doxycycline is a tetracycline antibiotic with a broad spectrum of activity. It is used to treat Gram-positive and atypical bacterial infections, as well as malaria. In this case the history and exposure are typical for *Giardia*, and therefore doxycycline would not be appropriate treatment.

C Albendazole

Albendazole is a parasitic drug with activity against a range of helminths and some protozoa. It is used second line to treat *Giardia* refractory to metronidazole.

E Artemesin

Artemisinins are a group of drugs with activity against all species of malarial parasites. Artemisinin-based drugs are now first line for the treatment of severe and complicated falciparum malaria and non-falciparum disease. The case

A Ciprofloxacin

Ciprofloxacin is a fluoroquinolone antibiotic with activity against many Gram negative, and some Gram-positive, bacteria. It is sometimes used to treat traveller's diarrhoea. However, in this case the history and exposure are typical for *Giardia* and therefore ciprofloxacin would not be appropriate treatment.

B Doxycycline

Doxycycline is a tetracycline antibiotic with a broad spectrum of activity. It is used to treat Gram-positive and atypical bacterial infections, as well as malaria. In this case the history and exposure are typical for *Giardia*, and therefore doxycycline would not be appropriate treatment.

C Albendazole

Albendazole is a parasitic drug with activity against a range of helminths and some protozoa. It is used second line to treat *Giardia* refractory to metronidazole.

E Artemesin

Artemisinins are a group of drugs with activity against all species of malarial parasites. Artemisinin-based drugs are now first line for the treatment of severe and complicated falciparum malaria and non-falciparum disease. The case described is typical of giardiasis, and artemisinin would not be the treatment of choice.

Rate this question:

Next Question

9:31
625-262-0256
Leave

A 23-year-old, homosexual man attends because of a painful mouth. He has a past history of asthma for which he takes a fluticasone/salmeterol combination inhaler This was recently changed from using a beclomethasone inhaler alone.

On examination, he looks well but has evidence of extensive oral candidiasis.

Which is the most likely cause?

A	Steroid-related candida infection
B	HIV infection
C	Chronic myeloid leukaemia
D	Chronic lymphoblastic leukaemia
E	Hodgkin's lymphoma

Submit

Audio
Video
Share
Participants
More

9:32

MyPastest
https://mypastest.pastest.com

A 23-year-old, homosexual man attends because of a painful mouth. He has a past history of asthma for which he takes a fluticasone/salmeterol combination inhaler This was recently changed from using a beclomethasone inhaler alone.

On examination, he looks well but has evidence of extensive oral candidiasis.

Which is the most likely cause?

Your answer was correct

A	Steroid-related candida infection
B	HIV infection
C	Chronic myeloid leukaemia
D	Chronic lymphoblastic leukaemia
E	Hodgkin's lymphoma

Explanation

A	Steroid-related candida infection

Given the history of use of inhaled corticosteroids for asthma, this is the most likely cause of this man's candida infection. Steroids cause immunosuppression by glucocorticoid action, and inhaled steroids can lead to

9:33
625-262-0256 Leave

Explanation

A Steroid-related candida infection

Given the history of use of inhaled corticosteroids for asthma, this is the most likely cause of this man's candida infection. Steroids cause immunosuppression by glucocorticoid action, and inhaled steroids can lead to localised immunosuppression and opportunistic infection with poor inhaler technique. Patients should be advised on good inhaler technique, with the use of a spacer device when they are prescribed a metered dose inhaler for steroid delivery, rinsing of the mouth with water after use of the inhaler or teeth cleaning, and adequate oral hygiene when taking their night-time dose.

B HIV infection

HIV with a low CD4+ count could be an explanation for oral candidiasis, but in the absence of any mentioned risk factors and without evidence of systemic features and other opportunistic disease this is a less likely diagnosis.

C Chronic myeloid leukaemia

Chronic myeloid leukaemia (CML) is a myeloproliferative disorder affecting one or all cell lines. Progression is characterised into a chronic phase, an accelerated phase and finally blast crisis. Most patients present in the chronic phase with insidious symptoms of fatigue, weight loss and night sweats. Examination can reveal features of cell line disruption such as anaemia and bruising, but while lymphadenopathy can occur it is not a major feature. It is not associated with immunodeficiency and would therefore not explain this patient's oral candidiasis, and the age of presentation of CML is usually around 65 years old.

D Chronic lymphoblastic leukaemia

Audio Video Share Participants More

9:36
625-262-0256 Leave

disorder affecting one or all cell lines. Progression is characterised into a chronic phase, an accelerated phase and finally blast crisis. Most patients present in the chronic phase with insidious symptoms of fatigue, weight loss and night sweats. Examination can reveal features of cell line disruption such as anaemia and bruising, but while lymphadenopathy can occur it is not a major feature. It is not associated with immunodeficiency and would therefore not explain this patient's oral candidiasis, and the age of presentation of CML is usually around 65 years old.

D Chronic lymphoblastic leukaemia

Chronic lymphoblastic leukaemia (CLL) is a malignant monoclonal expansion of B lymphocytes. CLL occurs at a median age of 72 years and presents insidiously with susceptibility of infection, symmetrically enlarged lymph nodes, abdominal pain from splenomegaly, bleeding from thrombocytopenia and fatigue from anaemia. Signs include lymphadenopathy, hepatomegaly and splenomegaly. The absence of systemic features and organomegaly makes this an unlikely diagnosis.

E Hodgkin's lymphoma

Hodgkin's lymphoma is a malignant disease of lymphatic system with multinucleated giant (Reed–Sternberg) cells. Presentation usually occurs in early adulthood, and again is insidious with asymptomatic lymph node enlargement, weight loss, night sweats and unexplained fever. Some patients have chest symptoms and alcohol-induced pain.

Rate this question:

Next Question

Audio Video Share Participants More

9:36
625-262-0256
Leave

A 32-year-old homeless man presents to the Emergency Department with severe headaches, behavioural changes and pyrexia. He has been admitted to the unit on two previous occasions with heroin overdoses.

On examination, he is emaciated and has a number of needle marks consistent with drug abuse, his temperature is 38.6 °C. You also notice that he has finger clubbing and nail bed haemorrhages. There is an ejection systolic murmur. Neurological examination reveals evidence of mild papilloedema.

Investigations:

Hb	10.1 g/dl
WCC	11.2 x 10^9/l
PLT	120 x 10^9/l
ESR	87 mm/hr
Na^+	139 mmol/l
K^+	4.5 mmol/l
Creatinine	155 µmol/l
CT head	Frontal lobe abscess

He is to be urgently reviewed by the neurosurgical team.

Which of the following would be the most appropriate initial antibiotic choice pending culture results?

A IV penicillin

B IV cefotaxime

C IV co-amoxiclav

D IV vancomycin

Audio Video Share Participants More

needle marks consistent with drug abuse, his temperature is 38.6 °C. You also notice that he has finger clubbing and nail bed haemorrhages. There is an ejection systolic murmur. Neurological examination reveals evidence of mild papilloedema.

Investigations:

Hb	10.1 g/dl
WCC	11.2 x 10^9/l
PLT	120 x 10^9/l
ESR	87 mm/hr
Na^+	139 mmol/l
K^+	4.5 mmol/l
Creatinine	155 µmol/l
CT head	Frontal lobe abscess

He is to be urgently reviewed by the neurosurgical team.

Which of the following would be the most appropriate initial antibiotic choice pending culture results?

A	IV penicillin
B	IV cefotaxime
C	IV co-amoxiclav
D	IV vancomycin
E	IV flucloxacillin

E IV flucloxacillin

Explanation

E IV flucloxacillin

In intravenous drug abusers (IVDAs), a methicillin-susceptible S. aureus (MSSA) is the causative organism in about 60-70% of cases with haematogenous spread of the bacteria resulting in the frontal lobe abscess seen here. As such, flucloxacillin is the initial empiric therapy of choice. If MRSA is suspected then the penicillin can be substituted with vancomycin. Trans-oesophageal echocardiography is the investigation to confirm the diagnosis of bacterial endocarditis.

A IV penicillin

This could be the treatment for a streptococcal cause of infection but this organism is unlikely to be the cause of this patient's abscess.

B IV cefotaxime

This is the treatment for meningitis rather than cerebral abscess. If the picture was of a meningism and no evidence of raised intracranial pressure and a normal CT scan this would be a better treatment option.

C IV co-amoxiclav

This could be a useful broad-spectrum treatment if the patient was not known to be a IVDA.

D IV vancomycin

This would be correct if MRSA was suspected to be the

9:43
625-262-0256 Leave

A IV penicillin

This could be the treatment for a streptococcal cause of infection but this organism is unlikely to be the cause of this patient's abscess.

B IV cefotaxime

This is the treatment for meningitis rather than cerebral abscess. If the picture was of a meningism and no evidence of raised intracranial pressure and a normal CT scan this would be a better treatment option.

C IV co-amoxiclav

This could be a useful broad-spectrum treatment if the patient was not known to be a IVDA.

D IV vancomycin

This would be correct if MRSA was suspected to be the cause of his infection, such as if he had previous positive microbiology results for MRSA.

Rate this question:

Next Question

Audio Video Share Participants More

9:43
625-262-0256 Leave

A 22-year-old man presented to clinic with a 2-week history of intense itching, predominantly affecting the web spaces on his hands and his groin area.

On examination, there were excoriations and evidence of inflammatory papules.

Which of the following would be first-line treatment for this condition?

A	Oral antihistamine
B	Oral permethrin
C	Topical hydrocortisone
D	Topical permethrin, applied to the hands and groin area
E	Topical permethrin, applied to the whole body below the neck

6576

Submit

Previous Q... Skip Questi...

© Pastest 2019

Audio Video Share Participants More

9:43
625-262-0256
Leave

A 22-year-old man presented to clinic with a 2-week history of intense itching, predominantly affecting the web spaces on his hands and his groin area.

On examination, there were excoriations and evidence of inflammatory papules.

Which of the following would be first-line treatment for this condition?

Your answer was correct

A	Oral antihistamine
B	Oral permethrin
C	Topical hydrocortisone
D	Topical permethrin, applied to the hands and groin area
E	Topical permethrin, applied to the whole body below the neck



Explanation

E	Topical permethrin, applied to the whole body below the neck

This patient has scabies, caused by mites which burrow into the stratum corneum to lay eggs. Standard treatment includes washing of all clothing and towels used in the 48 h before therapy, a bath and then the application of permethrin lotion to all skin areas below the neck. It should

Audio
Video
Share
Participants
More

9:43
625-262-0256 Leave

Responses

D Topical permethrin, applied to the hands and groin area

E Topical permethrin, applied to the whole body below the neck

Explanation

E Topical permethrin, applied to the whole body below the neck

This patient has scabies, caused by mites which burrow into the stratum corneum to lay eggs. Standard treatment includes washing of all clothing and towels used in the 48 h before therapy, a bath and then the application of permethrin lotion to all skin areas below the neck. It should remain on the body for 8–12 h and then be repeated 1 week later.

A Oral antihistamine

This patient has scabies. Oral antihistamines can be useful for the associated pruritus, but they are not a first-line treatment for the condition. The most appropriate treatment would be topical permethrin, applied everywhere on the body below the neck.

B Oral permethrin

Permethrin is a treatment for scabies but it is not taken orally. It is applied topically, everywhere below the neck. Oral ivermectin can be used in cases of resistant scabies.

C Topical hydrocortisone

This patient has scabies. Although topical hydrocortisone

Audio Video Share Participants More

9:44
625-262-0256 Leave

A Oral antihistamine

This patient has scabies. Oral antihistamines can be useful for the associated pruritus, but they are not a first-line treatment for the condition. The most appropriate treatment would be topical permethrin, applied everywhere on the body below the neck.

B Oral permethrin

Permethrin is a treatment for scabies but it is not taken orally. It is applied topically, everywhere below the neck. Oral ivermectin can be used in cases of resistant scabies.

C Topical hydrocortisone

This patient has scabies. Although topical hydrocortisone may be somewhat useful in preventing itch, it does not treat the condition. The most appropriate first-line treatment would be topical permethrin, applied everywhere below the neck.

D Topical permethrin, applied to the hands and groin area

This patient has scabies, and topical permethrin is the correct therapy; however, it should be applied everywhere below the neck, not simply to the affected areas.

Rate this question:

Next Question

Previous Q... Tag Questi... Feedback End Session

Audio Video Share Participants More

9:44
625-262-0256 Leave

A 28-year-old man presented with warts around the anal margin and on the shaft and subpreputial space on the penis. He was distressed by their appearance.

Examination confirmed the presence of multiple soft, non-keratinised papillomas.

What is the most appropriate treatment?

A	Aciclovir ointment
B	Cryotherapy
C	No treatment
D	Oral doxycycline
E	Podophyllotoxin ointment

Submit

Previous Q... Skip Questi...

© Pastest 2019

Audio Video Share Participants More

9:45
625-262-0256
Leave

A 28-year-old man presented with warts around the anal margin and on the shaft and subpreputial space on the penis. He was distressed by their appearance.

Examination confirmed the presence of multiple soft, non-keratinised papillomas.

What is the most appropriate treatment?

Your answer was correct

A	Aciclovir ointment
B	Cryotherapy
C	No treatment
D	Oral doxycycline
E	Podophyllotoxin ointment

Explanation

E Podophyllotoxin ointment

This patient is distressed by the genital warts, and therefore it is appropriate to treat him. First-line therapy for non-keratinised warts is podophyllotoxin ointment, applied directly to the warts twice a day for three days. This is followed by four rest days, and can be repeated weekly until the lesions resolve. If this is ineffective, cryotherapy is an appropriate second line treatment.

Audio
Video
Share
Participants
More

9:45
625-262-0256
Leave

A Aciclovir ointment

B Cryotherapy

C No treatment

D Oral doxycycline

E Podophyllotoxin ointment

0 10 20
Sessi
Responses
Responses
Responses
Responses

Explanation

E Podophyllotoxin ointment

This patient is distressed by the genital warts, and therefore it is appropriate to treat him. First-line therapy for non-keratinised warts is podophyllotoxin ointment, applied directly to the warts twice a day for three days. This is followed by four rest days, and can be repeated weekly until the lesions resolve. If this is ineffective, cryotherapy is an appropriate second line treatment.

A Aciclovir ointment

Although genital warts are caused by a virus (human papilloma virus), antiviral therapies are ineffective, especially if given topically. Instead, topical podophyllotoxin can be applied directly to the warts by the patient. If the warts are particularly refractory, cryotherapy can be used.

B Cryotherapy

Cryotherapy can be used to treat genital warts, but it is usually reserved for extensive or refractory cases. First-line

Audio Video Share Participants More

9:45
625-262-0256 Leave

Cryotherapy can be used to treat genital warts, but it is usually reserved for extensive or refractory cases. First-line treatment would be podophyllotoxin ointment. The patient should also be advised to use condoms, or if the warts are not covered by a condom, refrain from sexual activity until the lesions have resolved.

C No treatment

This patient is distressed by the warts and therefore should have treatment to remove them. It can be acceptable not to treat warts, as up to one third will regress spontaneously within 6 months. If warts are treated, first-line treatment for non-keratinised warts is podophyllotoxin ointment, administered by the patient.

D Oral doxycycline

This patient has genital warts, caused by the human papilloma virus. An antibiotic will be ineffective against genital warts. The most appropriate treatment in this case would be podophyllotoxin ointment, applied by the patient.

Rate this question:

Next Question

Previous Q... Tag Questi... Feedback End Session

© Pastest 2019

Audio Video Share Participants More

9:45
625-262-0256 Leave

A 25-year-old woman presented to the Emergency Department with a 1-day history of lower abdominal pain and vomiting. Her bowel movements were normal.

On examination, her temperature was 37.9°C and her blood pressure was 140/80 mmHg. Her abdomen was soft but tender in both iliac fossae. There was anterior tenderness on digital rectal examination. On speculum examination there was profuse white-yellow vaginal discharge and tenderness. A urine pregnancy test was negative.

What is the most likely diagnosis?

A	Acute appendicitis
B	Acute salpingitis
C	Bacterial vaginosis
D	Ectopic pregnancy
E	Ruptured ovarian cyst

Submit

Audio Video Share Participants More

9:47
625-262-0256
Leave

A 25-year-old woman presented to the Emergency Department with a 1-day history of lower abdominal pain and vomiting. Her bowel movements were normal.

On examination, her temperature was 37.9°C and her blood pressure was 140/80 mmHg. Her abdomen was soft but tender in both iliac fossae. There was anterior tenderness on digital rectal examination. On speculum examination there was profuse white-yellow vaginal discharge and tenderness. A urine pregnancy test was negative.

What is the most likely diagnosis?

Your answer was correct

A	Acute appendicitis
B	Acute salpingitis
C	Bacterial vaginosis
D	Ectopic pregnancy
E	Ruptured ovarian cyst

Difficu

Peer R

Sessi

Responses
Responses
Responses
Responses

Explanation

B Acute salpingitis

Most cases are associated with sexually transmitted infection. Patients present with lower abdominal pain, a fever and vaginal discharge. The Fitz-Hughes-Curtis syndrome associated with *Chlamydia* infection is caused by infection tracking up the right paracolic gutter to cause a

Audio
Video
Share
Participants
More

9:48
625-262-0256 Leave

syndrome associated with *Chlamydia* infection is caused by infection tracking up the right paracolic gutter to cause a peri-hepatitis. These patients may also have right hypochondrial pain, fever and mild elevations in liver biochemistry.

A Acute appendicitis

Acute appendicitis is an important differential diagnosis in any patient presenting with right iliac fossa pain; however, this patient is opening her bowels normally, does not have any signs of peritonism and has vaginal discharge. Acute salpingitis would be a better explanation of her presentation.

C Bacterial vaginosis

Bacterial vaginosis does cause vaginal discharge, but does not cause abdominal pain or fever. It is most commonly caused by *Gardnerella vaginalis*. This patient's abdominal pain, fever and vaginal discharge are suggestive of acute salpingitis, which is typically caused by a sexually transmitted infection such as *Chlamydia*. *Gardnerella* is not a sexually transmitted infection.

D Ectopic pregnancy

This patient has a negative pregnancy test, which would make an ectopic pregnancy very unlikely. Ectopic pregnancies typically cause a unilateral lower abdominal pain, and may be accompanied by vaginal bleeding. It would not cause vaginal discharge of the type seen here. This constellation of abdominal pain, fever and vaginal discharge is more suggestive of acute salpingitis.

E Ruptured ovarian cyst

A ruptured ovarian cyst can cause abdominal pain, but it

Audio Video Share Participants More

9:48
625-262-0256 Leave
MyPastest
https://mypastest.pastest.com

A woman who is 35 weeks pregnant presents feeling unwell with frequency and pain on urination.

On examination, she is pyrexial 37.9 °C and has suprapubic tenderness.

Investigations:

Hb	11.1 g/dl
WCC	13.1×10^9/l
PLT	145×10^9/l
Na^+	139 mmol/l
K^+	4.9 mmol/l
Creatinine	90 µmol/l
Urine	Nitrites, blood and protein ++

Which of the following is the most likely infective organism?

A *Escherichia coli*

B *Klebsiella*

C *Proteus*

D *Enterobacter*

E *Streptococcus agalactiae*

Audio Video Share Participants More

9:48
625-262-0256 Leave

D *Enterobacter*

E *Streptococcus agalactiae*

Explanation

A *Escherichia coli*

E. coli is a Gram-negative bacterium which colonises the human gut. It is the most common cause of urinary tract infections. In the non-pregnant patient, empirical treatment for an uncomplicated lower urinary tract infection is usually nitrofurantoin (contraindicated if eGFR <45 ml/min) or trimethroprim. Trimethoprim is contraindicated in the first trimester, however its use is considered safe in the second and third trimesters. Oral cephalexin is a commonly used alternative in the pregnant patient.

B *Klebsiella*

Klebsiella is a Gram-negative bacterium which colonises the human gut. Although this is a recognised cause of urinary tract infections, it is not the most common of the options presented.

C *Proteus*

Proteus is a Gram-negative bacterium which colonises the human gut. Although this is a recognised cause of urinary tract infections, it is not the most common of the options presented. Of note, *Proteus* is associated with renal calculi and is intrinsically nitrofurantoin resistant.

D *Enterobacter*

Enterobacter is a Gram-negative bacterium which colonises

Audio Video Share Participants More

9:49
625-262-0256 Leave

alternative in the pregnant patient.

B *Klebsiella*

Klebsiella is a Gram-negative bacterium which colonises the human gut. Although this is a recognised cause of urinary tract infections, it is not the most common of the options presented.

C *Proteus*

Proteus is a Gram-negative bacterium which colonises the human gut. Although this is a recognised cause of urinary tract infections, it is not the most common of the options presented. Of note, *Proteus* is associated with renal calculi and is intrinsically nitrofurantoin resistant.

D *Enterobacter*

Enterobacter is a Gram-negative bacterium which colonises the human gut. Although it is a recognised cause of urinary tract infections, it is much less common than the alternatives. Of note *Enterobacter* spp. are intrinsically resistant to penicillins and cephalosporins (AmpC mechanism).

E *Streptococcus agalactiae*

S. agalactiae (group B strep) is a Gram-positive streptococcus which may colonise the human gut and genitourinary system. It is a recognised cause of urinary tract infection but is less common that the other listed organisms.

Rate this question:

Audio Video Share Participants More

9:49
625-262-0256 Leave

A 22-year-old woman presents to the Emergency Department with a history of white, curdy vaginal discharge and of vulval irritation. She admits to a history of unprotected sexual intercourse during the previous week.

A past medical history, including type 1 diabetes, is noted. Medication includes the combined oral contraceptive pill.

Examination of the genital area reveals a red and inflamed vulval area, with an adherent white discharge. Recent glycated haemoglobin (HbA1c) on the hospital computer system was 88 mmol/mol.

Which one of the following interventions would be most appropriate in this case?

A	Screening for gonorrhoea
B	Fluconazole 150 mg oral stat
C	Clotrimazole cream to the labial area
D	Oxytetracycline 100 mg oral twice daily for 7 days
E	Amoxicillin 500 mg oral three times daily for 7 days

Submit

Previous Q... Skip Questi...

Audio Video Share Participants More

9:50
625-262-0256 Leave

department with a history of white, scaly vaginal discharge and of vulval irritation. She admits to a history of unprotected sexual intercourse during the previous week.

A past medical history, including type 1 diabetes, is noted. Medication includes the combined oral contraceptive pill.

Examination of the genital area reveals a red and inflamed vulval area, with an adherent white discharge. Recent glycated haemoglobin (HbA1c) on the hospital computer system was 88 mmol/mol.

Which one of the following interventions would be most appropriate in this case?

Peer

Sessi

Responses
Responses
Responses
Responses

Your answer was correct

A	Screening for gonorrhoea
B	Fluconazole 150 mg oral stat
C	Clotrimazole cream to the labial area
D	Oxytetracycline 100 mg oral twice daily for 7 days
E	Amoxicillin 500 mg oral three times daily for 7 days

Explanation

B Fluconazole 150 mg oral stat

The answer is Fluconazole 150 mg oral stat (Option B).

This woman has symptoms of vaginal *Candida* infection, almost certainly the cause of her presentation. Her diabetic control is suboptimal, and hence the high circulating glucose is likely to have contributed to the risk of thrush infection. Treatment regimens may include a single 150-mg

Audio Video Share Participants More

9:51
625-262-0256 Leave

Explanation

B	Fluconazole 150 mg oral stat

The answer is Fluconazole 150 mg oral stat (Option B).

This woman has symptoms of vaginal *Candida* infection, almost certainly the cause of her presentation. Her diabetic control is suboptimal, and hence the high circulating glucose is likely to have contributed to the risk of thrush infection. Treatment regimens may include a single 150-mg dose of fluconazole or insertion of a clotrimazole vaginal pessary. While high-oestrogen contraceptives do contribute to a risk for thrush, stopping them in this case would be inappropriate. Poor diabetic control means that this lady should not get pregnant at the present time, and she should be encouraged to consult her diabetologist to see what can be done with respect to optimising her regime.

A	Screening for gonorrhoea

Screening for gonorrhoea (Option A) is incorrect.

Gonorrhoea is asymptomatic in the majority of women but can present with a mucopurulent discharge. The description of a white discharge, pruritus and an inflamed vulva makes *Candida* far more likely.

C	Clotrimazole cream to the labial area

Clotrimazole cream to the labial area (Option C) is incorrect.

This is the correct treatment in that it is an antifungal effective against *Candida* infection. An external cream to the vulva is unlikely to eradicate the infection and therefore is not the most appropriate treatment option.

Audio Video Share Participants More

9:51
625-262-0256 Leave

the vulva is unlikely to eradicate the infection and therefore is not the most appropriate treatment option.

D	Oxytetracycline 100 mg oral twice daily for 7 days

Oxytetracycline 100 mg oral twice daily for 7 days (Option D) is incorrect.

This is a broad-spectrum antibiotic that can be used as treatment for *Chlamydia*. The presentation of genital ulceration makes *Chlamydia* an unlikely cause, and therefore oxytetracycline an inappropriate treatment. *Chlamydia* normally presents in men with dysuria or discharge.

E	Amoxicillin 500 mg oral three times daily for 7 days

Amoxicillin 500 mg oral three times daily for 7 days (Option E) is incorrect.

This is a potential treatment option for urinary tract infection. The presence of a white discharge makes this an unlikely diagnosis.

Rate this question:

Next Question

Previous Q... Tag Questi... Feedback End Session

Blog About Pastest Contact Us Help

© Pastest 2019

Audio Video Share Participants More

9:51
625-262-0256 Leave

A 24-year-old man returned from a 3-week holiday in India 10 days ago. He presents with a 48-h history of fever, generalised myalgia, headache, dry cough and diarrhoea.

On examination, he is pyrexial and has hepatosplenomegaly but no other significant findings.

His blood results are as follows:

Hb	10.2 g/dl
PLT	160×10^9/l
WCC	3.0×10^9/l
Alanine aminotransferase (ALT)	140 U/l
Gamma-GT	140 U/l
Alkaline phosphatase	290 U/l
Bilirubin	20 µmol/l
Albumin	28 g/l

A malarial film is negative. Blood cultures show Gram-negative rods.

What is the most likely causative agent?

A *Legionella pneumophila*

B *Salmonella enteritis*

C *Coxiella burnetii*

D *Salmonella typhi*

E *Leptospira interrogans*

Audio Video Share Participants More

9:54
625-262-0256 Leave

Explanation

D *Salmonella typhi*

Salmonella typhi is the causative organism of typhoid fever. Typhoid fever is seen in travellers returning from countries in the developing world. The presence of Gram-negative rods on the microscopy image confirms the underlying cause. The incubation period is 1–3 weeks. The illness is characterised by fever, myalgia and headache. Diarrhoea or constipation can occur. Rose spots are characteristic findings, usually on the trunk: they are faint, salmon-coloured, maculopapular, blanching lesions.

It is often difficult to differentiate typhoid from malaria clinically. Blood cultures are the diagnostic method of choice. *S. typhi* appears as a Gram-negative bacillus on Gram film. Serology (the Widal test) is not performed routinely in the UK.

Ceftriaxone is the treatment of choice due to problems with fluoroquinolone resistance.

A *Legionella pneumophila*

L. pneumophila is the causative organism of Legionnaire's disease (LD). LD is an atypical pneumonia which is difficult to distinguish from typical pneumonia clinically. It is heavily related to foreign travel as the organism is prevalent in stagnant water and usually contracted via poorly regulated air conditioning units. LD presents after 2–10 days with headache and myalgia followed by fever, rigors and cough. A third of patients have gastrointestinal symptoms. While *L. pneumophila* is a Gram-negative rod and the patient has possible symptoms, this diagnosis would not explain the noted hepatosplenomegaly.

B *Salmonella enteritis*

Audio Video Share Participants More

9:55
625-262-0256 Leave

incubation of 6–72 hours, the patient experiences fever, diarrhoea (which can be bloody) and abdominal cramps usually lasting 4–7 days before recovery. This diagnosis would not explain the headache, cough or oraganomegaly. *S. enteritis* is a Gram-negative rod.

C *Coxiella burnetii*

C. burnetii is the cause for Q fever, a zoonosis acquired from farm animals. The organism is a Gram-negative coccobacillus. Symptoms of Q fever can be variable in onset, presenting with myalgia, headache and dry cough, and can occur with hepatitis and hepatomegaly. However, it would not explain splenomegaly and there is no history of exposure to farm animals.

E *Leptospira interrogans*

L. interrogans is a spirochaete causing leptospirosis which is spread from rat urine into aquatic areas and then contact with abraded skin or mucosa leads to infection. Water activities increase risk. Following an incubation of 1–3 weeks, there is an abrupt onset of fever, headache, myalgia, dry cough and lethargy. This phase may resolve without treatment but can lead to an immune phase with jaundice, abdominal pain, diarrhoea, rash, meningitis and organ failure. It would explain the high LFTs and low haemoglobin, and would also explain hepatomegaly but not splenomegaly.

Rate this question:

Next Question

Previous Q... Tag Questi... Feedback End Session

Audio Video Share Participants More

9:55
625-262-0256 Leave

A 28-year-old man presented with a 2-month history of swelling and pain affecting his lower limbs, worse on the right than on the left. He also felt generally unwell and had had intermittent fevers. He had returned from Sri Lanka 2 days previously, where he had been working as an aid worker in rural areas surrounded by paddy fields.

On examination, both legs were swollen with non-pitting oedema to the knee, unchanged by elevation of the legs. There was painful bilateral inguinal lymphadenopathy.

Investigations:

Hb	12.1 g/dl (13.0–18.0)
WCC	8.9×10^9/l (4.0–11.0)
Eosinophils	1.2×10^9/l (0.04–0.4)
Chest X-ray	Bilateral pulmonary infiltrates
Ultrasound of the groin	Bilateral inguinal lymphadenopathy with lymphatic obstruction

What is the most appropriate treatment for this patient's condition?

A Ivermectin

B Chloroquine

C Ciprofloxacin

D Itraconazole

E Metronidazole

Audio Video Share Participants More

9:56
625-262-0256 Leave

WCC	8.9 × 10^9/l (4.0–11.0)	Sessi
Eosinophils	1.2 × 10^9/l (0.04–0.4)	Responses
Chest X-ray	Bilateral pulmonary infiltrates	Responses
Ultrasound of the groin	Bilateral inguinal lymphadenopathy with lymphatic obstruction	Responses
		Responses

What is the most appropriate treatment for this patient's condition?

Your answer was correct

A Ivermectin

B Chloroquine

C Ciprofloxacin

D Itraconazole

E Metronidazole

Explanation

A Ivermectin

This patient has filiariasis. He has travelled to an endemic area, surrounded by paddy fields which provide the perfect breeding ground for the parasitic vector (mosquitoes). The parasitic worms block the lymphatics, leading to limb swelling and lymphadenopathy. Filiariasis also explains his general malaise and intermittent fevers, and the marked eosinophilia and bilateral pulmonary infiltrates. First-line treatment is with diethylcarbamazine (DEC), but if there is

Audio Video Share Participants More

Explanation

A Ivermectin

This patient has filiariasis. He has travelled to an endemic area, surrounded by paddy fields which provide the perfect breeding ground for the parasitic vector (mosquitoes). The parasitic worms block the lymphatics, leading to limb swelling and lymphadenopathy. Filiariasis also explains his general malaise and intermittent fevers, and the marked eosinophilia and bilateral pulmonary infiltrates. First-line treatment is with diethylcarbamazine (DEC), but if there is any suggestion of a high parasitic load or concomitant onchocerciasis, ivermectin is an appropriate second-line treatment.

B Chloroquine

This patient has filiariasis: this is infection with microscopic worms, causing blockage of lymphatics and hence lymphadenopathy and limb swelling. It is contracted through bites from mosquitoes carrying the parasite. This patient has been working near paddy fields: these watery environments provide perfect breeding grounds for mosquitoes. Filiariasis would explain his limb swelling and painful lymphadenopathy; the nematodes can also migrate to the lungs causing bilateral pulmonary infiltrates. Finally this patient has a significant eosinophilia – an eosinophilia of this level is most likely to be caused by a significant parasitic infection. Filiariasis can be treated with diethylcarbamazine (DEC), albendazole or ivermectin. Ivermectin is the most appropriate choice if there is any risk of concomitant onchocerciasis. Chloroquine would not be appropriate as it is an antimalarial agent; this patient's symptoms and signs are not consistent with malaria.

C Ciprofloxacin

This patient's leg swelling, intermittent fevers, bilateral

infection contracted after being bitten by an infected mosquito; rural paddy fields are typical breeding grounds for mosquitos. The filarial nematodes cause blockage of lymphatics, leading to lymphadenopathy and limb swelling. Ciprofloxacin is an antibiotic and will not treat this patient's parasitic infection. Diethylcarbamazine (DEC) is first line but should not be used if there is suggestion of a high filarial load or concomitant onchocerciasis. The most appropriate treatment for this patient would be ivermectin.

D Itraconazole

This patient has filiariasis: this explains his intermittent fevers, leg swelling, painful lymphadenopathy and the findings on chest X-ray and ultrasound. The marked eosinophilia is highly suggestive of a parasitic infection. Filiariasis is caused by tiny parasitic worms which are contracted through vector transmission, by infected mosquitoes; paddy fields provide perfect breeding grounds for mosquitoes. The nematodes block the lymphatics, which leads to limb swelling and lymphadenopathy. Itraconazole is an antifungal medication, and therefore would not be appropriate to treat this patient. Diethylcarbamazine (DEC) would be first line, but should not be used if there is any suggestion of high parasite load or concomitant onchocerciasis. The most appropriate treatment for this patient would be ivermectin.

E Metronidazole

The intermittent fevers, malaise, limb swelling, lymphadenopathy and marked eosinophilia, against the background of this patient's travel history, suggest filiariasis. This is a parasitic worm transmitted through mosquitoes (for which rural paddy fields provide the perfect breeding ground). The worms block the lymphatics, leading to limb swelling and lymphadenopathy. They can also cause bilateral pulmonary infiltrates. As metronidazole is an antibiotic, it is not effective against a parasite such as filarial worms. Diethylcarbamazine (DEC) is first line

A schoolgirl returns from trip to France with 4-day history of headache, vomiting and fever.

On examination, she is alert with neck stiffness and no focal neurology signs. Magnetic resonance imaging (MRI) brain demonstrates no obvious lesions.

Investigations of cerebrospinal fluid (CSF):

Opening pressure	24 cm water (5–18cm)
Protein	0.8 g/l
WCC	110/ml (99% lymphocytes) (<5/ml)
Glucose	3.2 mmol/l (serum glucose 4.0 mmol/l)

What is the most likely diagnosis?

A Viral meningitis

B Cryptococcal meningitis

C Pneumococcal meningitis

D Meningococcal meningitis

E TB meningitis

Submit

10:00

A schoolgirl returns from trip to France with 4-day history of headache, vomiting and fever.

On examination, she is alert with neck stiffness and no focal neurology signs. Magnetic resonance imaging (MRI) brain demonstrates no obvious lesions.

Investigations of cerebrospinal fluid (CSF):

Opening pressure	24 cm water (5-18cm)
Protein	0.8 g/l
WCC	110/ml (99% lymphocytes) (<5/ml)
Glucose	3.2 mmol/l (serum glucose 4.0 mmol/l)

What is the most likely diagnosis?

Your answer was correct

A Viral meningitis

B Cryptococcal meningitis

C Pneumococcal meningitis

D Meningococcal meningitis

E TB meningitis

Diffic

Peer

A B C D E

0 10 20 3

Sessi

Responses

Responses

Responses

Responses

Explanation

Rana Alnasser's screen

10:01
625-262-0256 Leave

A 41-year-old woman is seen in the Emergency Department with a 3-week history of increasing breathlessness. She has a non-productive cough and has been feeling hot and cold. She feels fine at rest, but after walking 10 yards she becomes dyspnoeic. She has suffered from rheumatoid arthritis for 10 years and is currently taking methotrexate, folic acid and prednisolone. She had a flare 4 months ago which required a course of etanercept. She is a non-smoker.

On examination, she is afebrile and comfortable at rest. She has candida of the tongue. Her respiratory rate is 20/min at rest, but on transferring from a chair to bed increases to 28/min. Saturations on room air are 92%. You ask her to take a few steps across the room and her saturation drops. Her heart sounds are normal and chest is clear.

Chest X-ray shows bilateral, peri-hilar interstitial infiltrates.

Investigations:

Hb	9.8 g/dl
WCC	3.2×10^9/l
PLT	142×10^9/l
MCV	85.6 fl

What is the most likely diagnosis?

A Tuberculosis

B Sarcoidosis

C *Pneumocystis jirovecii*

D *Histoplasma capsulatum*

E Rheumatoid lung disease

Audio Video Share Participants More

E Rheumatoid lung disease

Explanation

C *Pneumocystis jirovecii*

Given this patient's recent treatment with etanercept and now the use of methotrexate and prednisolone, she is immunosuppressed. She has a classic history, and X-ray changes are consistent with *Pneumocystis jirovecii*. Diagnosis is usually confirmed with cytological examination of broncheoalveolar lavage fluid, although this is not always necessary. First-line treatment includes high-dose co-trimoxazole.

A Tuberculosis

Tuberculosis (TB) is a chronic bacterial infection caused by *Mycobacterium tuberculosis*. Primary TB most commonly affects the lungs, but almost all organ systems may be infected. A productive cough and history of previous TB exposure would be expected. Typical chest radiograph findings include apical cavitation, lobar consolidation and hilar adenopathy.

B Sarcoidosis

Sarcoidosis is a multi-system, inflammatory condition characterised by non-caseating granuloma formation. Typical presentation (Lofgren syndrome) is with bilateral hilar adenopathy, arthritis and erythema nodosum. The chest radiograph would most likely show hilar adenopathy.

D *Histoplasma capsulatum*

Histoplasmosis in an infection caused by the dimorphic

hilar adenopathy, arthritis and erythema nodosum. The chest radiograph would most likely show hilar adenopathy.

D *Histoplasma capsulatum*

Histoplasmosis in an infection caused by the dimorphic fungus *Histoplasma capsulatum*. Infection usually presents as a pneumonia, and associated changes on the chest radiograph would be expected such as hilar lymphadenopathy, lung nodules and lung cavities. Histoplasmosis is present worldwide but is most common in North America.

E Rheumatoid lung disease

Rheumatoid lung disease can take many forms, but most commonly it presents with interstitial lung disease or pleural disease. The typical presentation of rheumatoid-associated interstitial lung disease is with gradually progressive shortness of breath, reduced exercise tolerance and interstitial shadowing (lower zones) on chest radiography. In this case the rapidity of symptom onset and the associated candidiasis point to an alternative diagnosis.

7238

Rate this question:

Next Question

Previous Q... Tag Questi... Feedback End Session

Blog About Pastest Contact Us Help

© Pastest 2019

A 50-year-old Italian man presents to the gastroenterology clinic. He has a 6-month history of worsening abdominal pain. Over the past month, he has become noticeably jaundiced and has noticed dark urine and pale stools. He has also had two episodes in the past 2 weeks where he suddenly felt hot and dizzy. When this happened he noticed an itchy rash appear over all of his body, which only lasted for 24 hours.

He has a past history of angina and is awaiting an angiogram. He takes aspirin, simvastatin and isosorbide dinitrate. He has no drug allergies. He moved to the UK from Italy 20 years ago and has not left the UK in the past 6 years. He has retired.

On examination, the only finding is marked tenderness in the RUQ.

His blood tests are as follows:

Hb	12.7 g/dl
WCC	9.9×10^9/l
Lymphocytes	3.6×10^9/l
Neutrophils	3.1×10^9/l
Eosinophils	3.1×10^9/l
PLT	170×10^9/l
Urea	5.0 mmol/l
Creatinine	95 µmol/l
Na^+	142 mmol/l
K^+	4.0 mmol/l
Bilirubin	89 µmol/l
AST	60 U/l
ALP	430 U/l

Neutrophils	3.1×10^9/l
Eosinophils	3.1×10^9/l
PLT	170×10^9/l
Urea	5.0 mmol/l
Creatinine	95 µmol/l
Na^+	142 mmol/l
K^+	4.0 mmol/l
Bilirubin	89 µmol/l
AST	60 U/l
ALP	430 U/l
Albumin	30 g/l

An abdominal US reveals a large 5-cm cyst within the liver that is pressing on the common bile duct.

What is the most important investigation to arrange?

A Blood cultures

B Amoeba serology

C Aspiration of the cyst under US guidance

D Stool microscopy for ova cysts and parasites

E CT abdomen

Submit

Urea	5.0 mmol/l
Creatinine	95 µmol/l
Na^+	142 mmol/l
K^+	4.0 mmol/l
Bilirubin	89 µmol/l
AST	60 U/l
ALP	430 U/l
Albumin	30 g/l

An abdominal US reveals a large 5-cm cyst within the liver that is pressing on the common bile duct.

What is the most important investigation to arrange?

Your answer was correct

A Blood cultures

B Amoeba serology

C Aspiration of the cyst under US guidance

D Stool microscopy for ova cysts and parasites

E CT abdomen

Explanation

E CT abdomen

The history is highly suggestive of hydatid cyst disease, which is due to infection with the helminth Echinococcus

The history is highly suggestive of hydatid cyst disease, which is due to infection with the helminth Echinococcus granulosa. The adult worm is found normally in the dog and sheep intestine and man is an accidental intermediate host. The infection is seen in Mediterranean areas, parts of East Africa, Australia and South America and the liver is the commonest organ involved. The cysts grow slowly, and a cyst is rarely diagnosed during childhood or adolescence unless the brain is affected. In the liver, the pressure effect of the cyst can produce symptoms of obstructive jaundice and abdominal pain. Minor leaks lead to increased pain and a mild allergic reaction characterised by flushing and urticaria. Major rupture can lead to a full-blown anaphylactic reaction in some cases.

CT scan has an accuracy of 98% and the sensitivity to demonstrate the daughter cysts. It is the best test for the differentiation of hydatid from amoebic and pyogenic cysts in the liver.

A Blood cultures

Blood cultures could be useful in investigation of pyogenic liver abscesses but are only positive in 30% of patients.

B Amoeba serology

Serology of amoeba is rarely available due to expenses and poor sensitivity.

C Aspiration of the cyst under US guidance

Aspiration may cause rupture of the cyst. Since the history is suggestive of hydatid disease, this could be very dangerous due to the risk of major rupture and anaphylaxis.

D Stool microscopy for ova cysts and parasites

B Amoeba serology

Serology of amoeba is rarely available due to expenses and poor sensitivity.

C Aspiration of the cyst under US guidance

Aspiration may cause rupture of the cyst. Since the history is suggestive of hydatid disease, this could be very dangerous due to the risk of major rupture and anaphylaxis.

D Stool microscopy for ova cysts and parasites

If amoebic liver abscess was suspected; Latex agglutination assay is positive in more than 90% and stool microscopy may identify the organism (but unlikely with no symptoms of dysentery). Amoebic liver abscess is unlikely in this patient who has not been abroad in 6 years, and the history of urticaria and flushing combined with an eosinophilia are highly suggestive of hydatid disease.

Rate this question:

Next Question

© Pastest 2019

A 28-year-old man was admitted after collapsing with a severe headache at the airport. He had a 3-day history of fever and flu-like symptoms. He had returned from Kenya the previous day after a 3-week visit, including time spent visiting the national parks. He was prescribed doxycycline before his trip, but admitted that he had been poorly compliant.

On examination, his temperature was 39.2 °C, blood pressure 100/60 mmHg, pulse 105 bpm and regular and a fingertip glucose was 5.7 mmol/l.

Investigations:

		Normal values
Haemoglobin (Hb)	11.4 g/dl	130–180
White cell count (WCC)	15.6×10^9/l	4.0–11.0
Platelets (PLT)	44×10^9/l	150–400

Blood gases		Normal values
pH	7.21	7.35–7.45
$p(O_2)$	12.4 kPa	11.3–12.6
$p(CO_2)$	2.4 kPa	4.7–6.0
HCO_3	14 mmol/l	21–29
Blood film with Giemsa stain	*Plasmodium falciparum* parasitaemia 1.0%	

Which clinical feature leads to a diagnosis of severe malaria?

A Glucose 5.7 mmol/l

10:09
625-262-0256 Leave

		Normal values
Haemoglobin (Hb)	11.4 g/dl	130–180
White cell count (WCC)	15.6 × 10^9/l	4.0–11.0
Platelets (PLT)	44 × 10^9/l	150–400

Blood gases		Normal values
pH	7.21	7.35–7.45
$p(O_2)$	12.4 kPa	11.3–12.6
$p(CO_2)$	2.4 kPa	4.7–6.0
HCO_3	14 mmol/l	21–29
Blood film with Giemsa stain	*Plasmodium falciparum* parasitaemia 1.0%	

Which clinical feature leads to a diagnosis of severe malaria?

A Glucose 5.7 mmol/l

B Metabolic acidosis

C Platelets 44 × 10^9/l

D Parasitaemia of 1%

E Temperature of 39.2 °C

Audio Video Share Participants More

10:10
625-262-0256 Leave

Explanation

B Metabolic acidosis

According to the World Health Organization, the presence of severe metabolic acidosis (a base deficit of > 8 mmol/l, a bicarbonate level of < 15 mmol/l or a plasma lactate level of > 5 mmol/l) qualifies as severe malaria. As this patient has a bicarbonate level of 14 mmol/l, he has severe metabolic acidosis.

A Glucose 5.7 mmol/l

Hypoglycaemia is a criterion for the diagnosis of severe falciparum malaria (as per the World Health Organization's guidelines), but this patient is not hypoglycaemic. A glucose level of < 2.2 mmol/l would qualify as hypoglycaemia and lead to a diagnosis of severe falciparum malaria. This patient has severe metabolic acidosis (defined as a base deficit of > 8 mmol/l, a bicarbonate level of < 15 mmol/l or a plasma lactate level of > 5 mmol/l), which qualifies this case as severe malaria.

C Platelets 44 × 10^9/l

Thrombocytopenia is almost invariable in significant malarial infection and, in itself, is not sufficient for a diagnosis of severe malaria. This patient has severe metabolic acidosis (defined as a base deficit of > 8 mmol/l, a bicarbonate level of < 15 mmol/l or a plasma lactate level of > 5 mmol/l), which qualifies this case as severe malaria.

D Parasitaemia of 1%

According to the World Health Organization, parasitaemia of 10% or more is a criterion for the diagnosis of severe falciparum malaria. This patient has severe metabolic

Audio Video Share Participants More

10:12
625-262-0256 Leave

of > 5 mmol/l), which qualifies this case as severe malaria.

D	Parasitaemia of 1%

According to the World Health Organization, parasitaemia of 10% or more is a criterion for the diagnosis of severe falciparum malaria. This patient has severe metabolic acidosis (defined as a base deficit of > 8 mmol/l, a bicarbonate level of < 15 mmol/l or a plasma lactate level of > 5 mmol/l), which qualifies this case as severe malaria.

E	Temperature of 39.2 °C

It is common for patients with malaria to have high fever, regardless of whether they have severe falciparum malaria or not. The World Health Organization has defined criteria for severe falciparum malaria, and the temperature of the patient is not a criterion for the diagnosis. This patient has severe metabolic acidosis (defined as a base deficit of > 8 mmol/l, a bicarbonate level of < 15 mmol/l or a plasma lactate level of > 5 mmol/l), which qualifies this case as severe malaria.

Rate this question:

Next Question

Previous Q... Tag Questi... Feedback End Session

© Pastest 2019

Audio Video Share Participants More

10:13

A 22-year-old man presented with a 1-week history of haematuria and haematospermia. He did not have dysuria, frequency or suprapubic pain. He was a medical student and had recently returned from an elective in East Africa. He had sexual intercourse with two fellow students while abroad and took trips into the countryside, including swimming in Lake Malawi. He took malarial prophylaxis throughout the trip and had continued to do so since his return. He had no other complaints.

There were no findings on examination. Routine bloods showed a mildly raised eosinophil count.

What is the most likely diagnosis?

Your answer was correct

A	Blackwater fever (malaria)
B	*Chlamydia trachomatis* infection
C	*Neisseria gonococcus*
D	*Schistosoma haematobium*
E	Urinary tract infection

Explanation

D	*Schistosoma haematobium*

It is a parasitic fluke and is found in Lake Malawi; it can be contracted by swimming in the waters and typically cause an itchy rash shortly after exposure ('swimmer's itch').

Rana Alnasser's screen

10:14
625-262-0256 Leave

D *Schistosoma haematobium*

It is a parasitic fluke and is found in Lake Malawi; it can be contracted by swimming in the waters and typically cause an itchy rash shortly after exposure ('swimmer's itch'), though the patient may be asymptomatic. Acute schistosomiasis typically occurs 3–8 weeks after infection. Bladder infection by *S. haematobium* causes haematuria, and schistosomiasis can also cause haematospermia. It must be treated, as chronic schistosomiasis significantly increases the risk of squamous cell bladder cancer.

Treatment with praziquantel should be given 4–6 weeks following initial exposure, but only once the diagnosis has been confirmed by serology or microscopy. A reducing course of corticosteroids, such as prednisolone, can be administered while awaiting confirmation, and should continue concurrently with praziquantel.

A Blackwater fever (malaria)

Blackwater fever is a term for severe malaria where intravascular haemolysis causes urine to turn dark in colour. This patient has taken sufficient malarial prophylaxis; in addition, blackwater fever or malaria could not explain haematospermia. The most likely cause for this patient's symptoms is schistosomiasis as a result of swimming in Lake Malawi. Schistosomiasis is caused by a parasitic fluke and is also known as bilharzia; common manifestations of *Schistosoma haematobium* infection are haematuria and haematospermia.

B *Chlamydia trachomatis* infection

Chlamydia trachomatis is a sexually transmitted infection, and while uncommonly it could cause haematuria, you

Scroll capture Draw Crop
Audio Video Share Participants More

10:14
625-262-0256 Leave

C *Neisseria gonococcus*

N. gonococcus is a sexually transmitted infection that typically causes dysuria and mucopurulent penile discharge. It would not typically cause haematuria or haematospermia. A much more likely explanation for this student's symptoms is schistosomiasis as a result of swimming in Lake Malawi. Schistosomiasis is caused by a parasitic fluke and is also known as bilharzia; common manifestations of *S. haematobium* infection are haematuria and haematospermia.

E Urinary tract infection

Although a urinary tract infection could certainly cause haematuria, it could not cause haematospermia. You would also expect the patient to complain of dysuria and frequency, or suprapubic pain. Urinary tract infections are uncommon in healthy young men. A much more likely explanation is schistosomiasis, a parasitic fluke contracted through swimming in Lake Malawi. *S. haematobium* could explain the haematuria and the haematospermia and is the correct answer in this case.

Rate this question:

© Pastest 2019

Audio Video Share Participants More

10:14
625-262-0256 Leave

A 34-year-old man presented to clinic with a 3-month history of a skin lesion on his left leg. He explained that when the lesion first appeared, it had been a small, red, painless raised lump, which had gradually enlarged. He was a sailor who worked on ships in the Middle East, India and Pakistan.

On examination there was a 6 cm lesion on the left leg with a raised edge and central ulceration which had crusted over with a dry scab.

What is the most likely diagnosis?

A	Basal cell carcinoma
B	Chronic venous ulceration
C	Cutaneous leishmaniasis
D	Leprosy
E	Squamous cell carcinoma

Submit

Previous Q... Skip Questi...

Audio Video Share Participants More

10:17
625-262-0256 Leave

C Cutaneous leishmaniasis

Cutaneous leishmaniasis is caused by a parasite conveyed in a sandfly bite, and 'Old Word cutaneous leishmaniasis' can be contracted whilst travelling in Asia and the Middle East. The description of an enlarging red, painless papule which develops central ulceration is typical. Many lesions will spontaneously resolve within a year of forming.

A Basal cell carcinoma

Although the current appearance of the lesion could be consistent with a basal cell carcinoma, the progression of the lesion from a red papule to a lesion with central, dry ulceration is not typical. Instead, combined with the patient's travel history, this is more likely to be cutaneous leishmaniasis. It is caused by a parasite conveyed in a sandfly bite and typically progresses from a red papule, which enlarges and develops either wet or dry central ulceration. These lesions often spontaneously resolve within a year.

B Chronic venous ulceration

Chronic venous ulceration causes background skin changes, which are not reported here, and you would expect a venous ulcer to be shallow with exudate. Furthermore, a venous ulcer would not develop as a papule and then progress to a lesion with central ulceration. This description, combined with the patient's travel history, would be more typical of cutaneous leishmaniasis.

D Leprosy

Leprosy classically causes hypopigmented patches of anaesthetised skin; it may cause irregular red plaques, or skin thickening, but the progression of the lesion described

Audio Video Share Participants More

10:17

expect a venous ulcer to be shallow with exudate. Furthermore, a venous ulcer would not develop as a papule and then progress to a lesion with central ulceration. This description, combined with the patient's travel history, would be more typical of cutaneous leishmaniasis.

D Leprosy

Leprosy classically causes hypopigmented patches of anaesthetised skin; it may cause irregular red plaques, or skin thickening, but the progression of the lesion described in this case would not fit with leprosy. It is much more likely to be caused by cutaneous leishmaniasis, caused by a parasite conveyed in a sandfly bite, which would also fit with this patient's travel history.

E Squamous cell carcinoma

Squamous cell carcinoma would typically cause an enlarging scaly or crusted lump; it would not progress from a red papule as seen here. Instead, this patient's presentation combined with his travel history is more suggestive of cutaneous leishmaniasis, caused by a parasite conveyed in a sandfly bite.

Rate this question:

Next Question

Previous Q... Tag Questi... Feedback End Session

Blog About Pastest Contact Us Help

© Pastest 2019

Rana Alnasser's screen

10:17

A 40-year-old Indian man presented to the Emergency Department after a generalised tonic-clonic seizure, which self-resolved. He had had two other generalised seizures in the preceding 2 months. He had a 4-month history of low-grade fever, malaise, weight loss and intermittent confusion. He also had a 1-year history of asthma which was poorly responsive to treatment, and an intermittent urticarial rash.

Investigations:

Hb	111 g/l (130–180)
WCC	8.9×10^9/l (4.0–11.0)
Neutrophils	4.3×10^9/l (1.5–7.0)
Lymphocytes	3.4×10^9/l (1.5–4.0)
Eosinophils	1.1×10^9/l (0.04–0.4)
MRI brain	Discrete wavy, linear lesions seen bilaterally

Which of the following is the most likely diagnosis?

A Cysticercosis

B Eosinophilic granulomatosis with polyangiitis

C Systemic lupus erythematosus

D Tuberculous meningitis

E Variant Creutzfeldt-Jakob disease

Rana Alnasser's screen

10:20
625-262-0256 Leave

Explanation

B Eosinophilic granulomatosis with polyangiitis

This was previously known as Churg–Strauss syndrome. This patient's asthma, resistant to treatment, and urticarial rash are typical. Another key feature is his marked eosinophilia, and a mild anaemia is typical. The episodes of confusion and generalised seizures are a product of cerebral vasculitis; this is consistent with the MRI findings. There is no one diagnostic investigation, but up to 40% of patients will be p-ANCA positive. If he had pulmonary or dermatological disease, biopsy of affected areas will be strongly suggestive of the condition. It is treated with high-dose corticosteroids; if these are unsuccessful, then immunosuppression with agents such as azathioprine, methotrexate or even cyclophosphamide may be used.

A Cysticercosis

This is caused by the larvae of *Taenia solium*, a tapeworm. Neurocysticercosis can cause seizures and psychiatric disturbances, but typically it would be visible on MRI as calcified cysts, which is not the case here. Although patients may have an eosinophilia, it is not common unless a cyst is leaking. Cysticercosis would also not explain the patient's urticarial rash or asthma. Instead, this constellation of symptoms and investigations would be more typical for eosinophilic granulomatosis with polyangiitis; the MRI findings represent typical vasculitic central nervous system disease.

C Systemic lupus erythematosus

This patient does have features consistent with cerebral vasculitis (including his MRI findings), of which one of the causes is systemic lupus erythematosus. However, it could not explain his resistant asthma or eosinophilia; these are

Audio Video Share Participants More

10:22

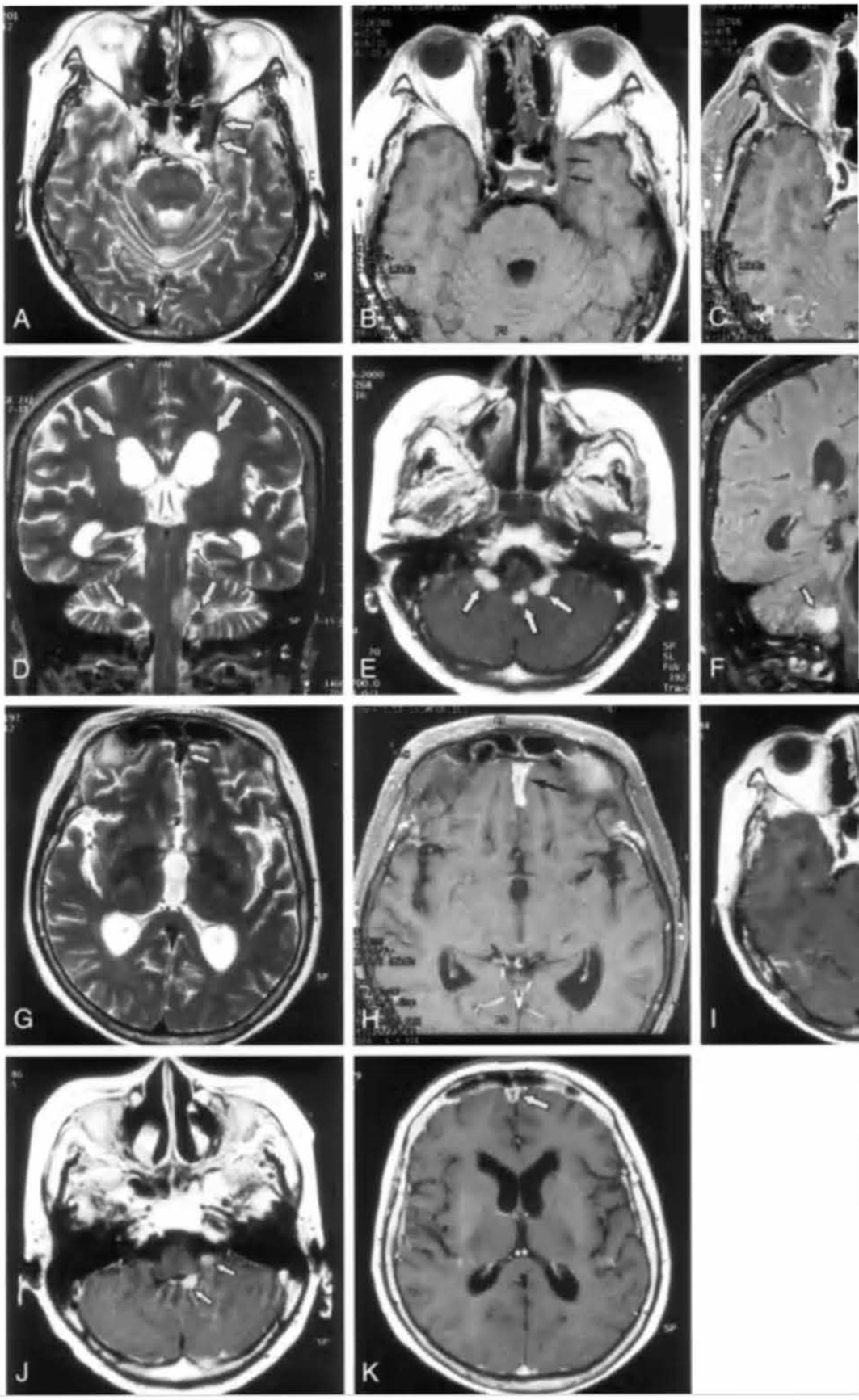

American Journal of Neuroradiology

Intracranial Meningeal Involvement in Churg-Strauss Syndrome ...

Discover
Updates
Search
Recent

10:23
625-262-0256 Leave

A 17-year-old girl presents with a 10-day history of feeling unwell. She describes fever, a rash on her body that has now cleared, and currently has pain in her left knee. She tells you that she has had a few eye infections in the past that cleared up and often gets swollen joints, as she is a keen gymnast. She takes no regular medications and has no allergies. She has not been abroad recently.

She has previously had similar episodes in the past affecting both her knees and has felt that other joints were involved too. These have been episodic in nature over the last 2 years. She had seen her GP at the time who wanted to investigate with blood tests, but she declined due to needle-phobia and managed her pain with over the counter ibuprofen.

On examination she is thin. Her temperature is 38.7 °C. She has cervical lymphadenopathy. Her blood pressure is 110/80 mm/Hg; pulse 106 bpm regular.

Heart sounds are normal with no murmurs.

Auscultation of the chest is unremarkable.

There is a splenic tip palpable on abdominal examination. Her left knee is swollen and tender and there is evidence of a small effusion.

Investigations are as follows:

Hb	11.8 g/l
WCC	13×10^9/l
Platelets	190×10^9/l
ESR	90 mm/h
Blood film	NAD
Joint aspirate Microscopy, Culture & Sensitivity	No growth after 48 h
Urine microscopy and culture	No abnormality detected

Audio Video Share Participants More

10:25
625-262-0256 Leave

Platelets	190 × 10^9/l
ESR	90 mm/h
Blood film	NAD
Joint aspirate Microscopy, Culture & Sensitivity	No growth after 48 h
Urine microscopy and culture	No abnormality detected
Paul-Bunnell test	Negative

Three days later, while in hospital, she develops painful wrists and pain on neck movement. Cardiovascular examination reveals a new friction rub but no evidence of cardiac failure.

Which diagnosis should be considered?

A Lyme's Disease

B Rubella

C Juvenile idiopathic arthritis

D Systemic lupus erythematosus

E Infectious mononucleosis

Submit

Previous Q... Skip Questi...

Audio Video Share Participants More

10:29
625-262-0256 Leave
MyPastest
https://mypastest.pastest.com

C Juvenile idiopathic arthritis

The initial presentation with fever, pain and swelling of the left knee with a prodromal history makes a diagnosis of infective arthritis important to exclude. Occasionally acute leukaemia can cause a pyogenic arthritis but the normal blood film excludes this. The progression of symptoms suggests a systemic disease. The most important differentials to consider are therefore rheumatic fever, juvenile idiopathic arthritis (JIA) and rheumatoid arthritis. The history of similar joint problems with a chronic relapsing course starting before the age of 16 makes missed JIA a strong possibility. Cervical spine involvement is more common in JIA.

A Lyme's Disease

Lyme disease is a tick-borne infection of *Borrelia burgdorferi* causing erythema migrans at the site of infection, which expands. It causes systemic features as well, including fatigue, myalgia, myocarditis, arthralgia and fever. The absence of a tick bite and erythema migrans makes this diagnosis unlikely, and it would also not explain the joint effusion.

B Rubella

This is a very unlikely diagnosis in general due to vaccination, and also does not explain the presence of pericarditis or joint effusion.

D Systemic lupus erythematosus

SLE is a multisystem autoimmune disease working in multiple immunological ways including immune complex

Audio Video Share Participants More

10:29
625-262-0256 Leave

D Systemic lupus erythematosus

SLE is a multisystem autoimmune disease working in multiple immunological ways including immune complex formation and deposition and complement activation. It is relapsing-remitting with variable symptoms including fatigue, malaise, fever with lymphadenopathy, weight loss Raynaud's and migraine. It is often associated with a malar rash and a discoid rash, as well as non-erosive arthritis of peripheral joints. However, the presentation is very early for this diagnosis and the joint involvement is far more likely to be of small joints and symmetrical.

E Infectious mononucleosis

Mononucleosis is caused by Epstein-Barr virus (EBV) and following 4-5 weeks incubation causes symptoms in adolescents. It is commonly contracted in early childhood and causes no symptoms there. It can a cause fever, sore throat and lymphadenopathy, as well as splenomegaly. A negative Paul-Bunnell test makes infectious mononucleosis unlikely. It would also not explain cardiac or arthritic involvement.

Rate this question:

Next Question

Previous Q... Tag Questi... Feedback End Session

© Pastest 2019

Audio Video Share Participants More

10:29
625-262-0256
Leave

A 68-year-old man presented to clinic with a 3-week history of fever, malaise and a dry cough. He was a dairy farmer who specialised in unpasteurised milk and cheeses. He had no other medical conditions and was otherwise well.

On examination his temperature was 38.4°C. There was an ejection systolic murmur and hepatomegaly.

Investigations:

Bilirubin	27 mmol/l (1–22)
ALT	89 U/l (5–35)
AST	67 U/l (1–31)
Blood cultures	Negative in serial samples separated by time and site
Trans-oesophageal echocardiogram	Vegetations visible on the aortic valve

What is the most likely diagnosis?

A *Coxiella* endocarditis

B Fungal endocarditis

C Libman–Sacks endocarditis

D Staphylococcal endocarditis

E Streptococcal endocarditis

Submit

Audio Video Share Participants More

10:29
625-262-0256 Leave

ALT	89 U/l (5–35)
AST	67 U/l (1–31)
Blood cultures	Negative in serial samples separated by time and site
Trans-oesophageal echocardiogram	Vegetations visible on the aortic valve

0 10 20 3

Sessi

Responses

Responses

Responses

Responses

What is the most likely diagnosis?

Your answer was correct

A *Coxiella* endocarditis

B Fungal endocarditis

C Libman–Sacks endocarditis

D Staphylococcal endocarditis

E Streptococcal endocarditis

Explanation

A *Coxiella* endocarditis

Coxiella infection is widespread in domestic and farm animals. It usually spreads between animals by ticks, which act as reservoirs of infection. Infection may be also be spread via unpasteurised milk. It causes fever and malaise, which may progress to pneumonia, hepatitis or, in rare cases, to culture-negative endocarditis, as seen here. *Coxiella* is usually diagnosed via complement fixation.

Audio Video Share Participants More

10:29
625-262-0256 Leave

Explanation

A *Coxiella* endocarditis

Coxiella infection is widespread in domestic and farm animals. It usually spreads between animals by ticks, which act as reservoirs of infection. Infection may be also be spread via unpasteurised milk. It causes fever and malaise, which may progress to pneumonia, hepatitis or. in rare cases, to culture-negative endocarditis, as seen here. *Coxiella* is usually diagnosed via complement fixation.

B Fungal endocarditis

Fungal endocarditis is a cause of culture-negative endocarditis, but it is extremely uncommon, especially in immunocompetent individuals. In most cases it is associated with cardiac surgery or healthcare settings. This patient is more likely to have *Coxiella* endocarditis; *Coxiella* is common in domestic and farm animals and causes a culture-negative endocarditis as seen in this case.

C Libman-Sacks endocarditis

Libman-Sacks endocarditis is a non-infective vegetative endocarditis seen in systemic lupus erythematosus. Therefore although it is a cause of culture-negative endocarditis, it is an unlikely diagnosis in this case as the patient has no history of, or symptoms and signs suggestive of, systemic lupus erythematosus. This patient is most likely to have *Coxiella* endocarditis as a result of contact with livestock; *Coxiella* causes a culture-negative endocarditis.

D Staphylococcal endocarditis

Audio Video Share Participants More

10:30
625-262-0256 Leave

suggestive of, systemic lupus erythematosus. This patient is most likely to have *Coxiella* endocarditis as a result of contact with livestock; *Coxiella* causes a culture-negative endocarditis.

D	Staphylococcal endocarditis

It would be unusual not to identify *Staphylococcus* spp. in serial blood cultures in a patient with vegetative endocarditis, but this patient has culture-negative endocarditis. *Coxiella* causes a culture-negative endocarditis, and is common amongst farm livestock; this is the most likely diagnosis.

E	Streptococcal endocarditis

If a patient had vegetative streptococcal endocarditis, it would be unusual for serial blood cultures to be negative. Instead, it is more likely that this patient has *Coxiella* endocarditis, which is also consistent with his prodromal illness. *Coxiella* is a common infection in livestock and can be carried by ticks.

Rate this question:

Next Question

Previous Q... Tag Questi... Feedback End Session

© Pastest 2019

Audio Video Share Participants More

10:30
625-262-0256 Leave

A 31-year-old woman who is 22 weeks pregnant attends the Emergency Department. She is very worried as her 3-year-old son has been sent home from nursery with 'slapped cheek' disease.

Which of the following is the most likely complication associated with fetal slapped cheek infection?

A	Congenital deafness
B	Hydrops fetalis
C	Fetal clotting disorder
D	Fetal polycythaemia
E	Congenital blindness

Submit

Previous Q... Skip Questi...

© Pastest 2019

Audio Video Share Participants More

10:31
625-262-0256 Leave

C	Fetal clotting disorder	Responses
D	Fetal polycythaemia	Responses
E	Congenital blindness	Responses

Explanation

B	Hydrops fetalis

Slapped cheek disease is caused by parvovirus B19 infection. It is known to cause fetal anaemia, hydrops fetalis in 1-3% (2nd trimester), and intrauterine fetal death. Infections peak in spring and autumn. Incubation period is usually around 12-14 days, meaning that this lady is likely to have been already exposed via contact with her son. In total, B19 infection may account for up to 20% of non-immune cases of hydrops. Autopsy studies indicate that highest viral concentrations are found in bone marrow and myocardium. Infection can be confirmed either with IgM serology or PCR where it is available. IV immunoglobulin may be of value in some patients.

A	Congenital deafness

This could be caused by antenatal rubella. Rubella is a viral infection causing a pink rash and lymphadenopathy behind the ears. Infection in the first 11 weeks of pregnancy can cause fetal rubella syndrome if the mother is not vaccinated. Fetal rubella syndrome causes deafness, cataracts, learning disability, growth restriction and heart defects. Diagnosis during pregnancy is via serology. Other causes include antenatal cytomegalovirus.

C	Fetal clotting disorder

Audio Video Share Participants More

10:32
625-262-0256 Leave

C Fetal clotting disorder

This could be caused be antenatal toxoplasmosis through cat exposure. Systemic neonatal infection can include thrombocytopenic pupura, hepatosplenomegaly, pneumonia, rash and jaundice. There can also be significant neurological disease.

D Fetal polycythaemia

This can be caused by increased fetal erythropoiesis related to hypoxia which can be secondary due to placental insufficiency, endocrine disorders, delayed cord clamping, twin-twin transfusion and intrapartum asphyxia.

E Congenital blindness

This can be caused by several pathologies, including antenatal rubella, antenatal varicella and antenatal cytomegalovirus. Other diseases can cause other eye problems which can lead to blindness if not treated.

Rate this question:

Next Question

Previous Q... Tag Questi... Feedback End Session

© Pastest 2019

Audio Video Share Participants More

10:32

A 19-year-old woman is brought by her partner to the Emergency Department. She has been complaining of worsening headache and neck stiffness over the past few days and is now drowsy and disorientated.

On examination, she has signs of meningism, a pyrexia 39 °C, blood pressure 100/60 mmHg and pulse 105 bpm. There is a purpuric rash.

Investigations:

Hb	12.1 g/dl
WCC	15.1×10^9/l
Na^+	140 mmol/l
K^+	5.0 mmol/l
Creatinine	140 µmol/l
Lumbar puncture	Decreased CSF glucose, increased protein, neutrophils, gram negative diplococci

You commence IV benzylpenicillin and there is initial improvement. 72 h later, however, she spikes a new fever of 39 °C, with increased eosinophil count in the peripheral blood.

What is the most important management step?

A	Stop penicillin and substitute an alternative antibiotic
B	Commence prednisolone
C	Commence aciclovir
D	Commence amphotericin
E	Commence chlorpheniramine

Rana Alnasser's screen

10:39
625-262-0256 Leave

WCC	15.1 × 10^9/l
Na^+	140 mmol/l
K^+	5.0 mmol/l
Creatinine	140 µmol/l
Lumbar puncture	Decreased CSF glucose, increased protein, neutrophils, gram negative diplococci

0 10 2
Sessi
Responses
Responses
Responses
Responses

You commence IV benzylpenicillin and there is initial improvement. 72 h later, however, she spikes a new fever of 39 °C, with increased eosinophil count in the peripheral blood.

What is the most important management step?

Your answer was correct

- A Stop penicillin and substitute an alternative antibiotic
- B Commence prednisolone
- C Commence aciclovir
- D Commence amphotericin
- E Commence chlorpheniramine

Explanation

A Stop penicillin and substitute an alternative antibiotic

Penicillin is one of a number of agents which may cause an

Audio Video Share Participants More

meloxicam, l-tryptophan, dantrolene and ethambutol.
Clearly this woman does have meningococcal meningitis given that she presented with fever and menigisms and found to have diplococci in her CSF. As such it is important to continue antibiotic therapy. Alternatives to penicillin include cephalosporins such as ceftriaxone or cefotaxime at high dose. Indeed, most centres use a cephalosporin as first line therapy because of the small risk of meningococcal resistance to penicillin.

B Commence prednisolone

This is a very tempting option as the patient likely has suffered a drug reaction. However, removing the offending drug is a far more sensible option than using prednisolone to mitigate the drug reaction.

C Commence aciclovir

This would be the correct treatment option for viral meningitis but the presence of diplococci in the blood film and purpuric rash on presentation makes this an unlikely diagnosis and therefore makes acyclovir an inappropriate treatment option.

D Commence amphotericin

Amphotericin is a potent antifungal medication which can be used against systemic aspergillus which can be a cause of eosinophilia. However, there is very strong evidence for bacterial, not fungal, infection, and this is a very unlikely diagnosis given the original presentation of meningism, purpuric rash and fever.

E Commence chlorpheniramine

Chlorphenamine is an antipruritic medication which would only provide symptomatic relief against itch and therefore

meningococcal resistance to penicillin.

B Commence prednisolone

This is a very tempting option as the patient likely has suffered a drug reaction. However, removing the offending drug is a far more sensible option than using prednisolone to mitigate the drug reaction.

C Commence aciclovir

This would be the correct treatment option for viral meningitis but the presence of diplococci in the blood film and purpuric rash on presentation makes this an unlikely diagnosis and therefore makes acyclovir an inappropriate treatment option.

D Commence amphotericin

Amphotericin is a potent antifungal medication which can be used against systemic aspergillus which can be a cause of eosinophilia. However, there is very strong evidence for bacterial, not fungal, infection, and this is a very unlikely diagnosis given the original presentation of meningism, purpuric rash and fever.

E Commence chlorpheniramine

Chlorphenamine is an antipruritic medication which would only provide symptomatic relief against itch and therefore not address the underlying problem. Given that there is a fever and haematological evidence of eosinophilia an underlying cause should be saught and addressed.

Rate this question:

Next Question

An HIV-positive man has a CD4 count of 220 × 10^6/l. He is generally asymptomatic but has noticed white patches in his mouth. They are quite unsightly and he is keen for treatment.

On examination, you observe irregular white patches, with a corrugated appearance along the side of his tongue. On probing with a swab, they cannot be dislodged.

What is the best way to eradicate these patches?

A	Oral fluconazole
B	Nystatin lozenges
C	Antiretroviral therapy
D	Aciclovir 200 mg 5× daily
E	Improve oral hygiene

Submit

Previous Q... Skip Questi...

© Pastest 2019

An HIV-positive man has a CD4 count of 220 × 10^6/l. He is generally asymptomatic but has noticed white patches in his mouth. They are quite unsightly and he is keen for treatment.

On examination, you observe irregular white patches, with a corrugated appearance along the side of his tongue. On probing with a swab, they cannot be dislodged.

What is the best way to eradicate these patches?

Your answer was correct

A	Oral fluconazole
B	Nystatin lozenges
C	Antiretroviral therapy
D	Aciclovir 200 mg 5× daily
E	Improve oral hygiene

Explanation

C Antiretroviral therapy

The diagnosis is oral hairy leukoplakia, which is an AIDs-defining illness but can occur in other cases or immunosuppression. The clinical picture is described above and it is often mistaken for oral candida, the only difference being that plaques of leucoplakia cannot be dislodged. The condition is caused by Epstein-Barr virus (EBV) and it only needs to be treated if it is causing symptoms such as pain

Explanation

C Antiretroviral therapy

The diagnosis is oral hairy leukoplakia, which is an AIDs-defining illness but can occur in other cases or immunosuppression. The clinical picture is described above and it is often mistaken for oral candida, the only difference being that plaques of leucoplakia cannot be dislodged. The condition is caused by Epstein–Barr virus (EBV) and it only needs to be treated if it is causing symptoms such as pain or dysphagia. The best treatment is to commence antiretroviral therapy, as the CD4 count rises, it will resolve. Other treatment options are high-dose aciclovir (3 g/day) and it may respond to other antivirals. Surgery is also an option.

A Oral fluconazole

It would be a treatment option if the history and examination suggested oral candida. The clinical picture would be very similar except that oral candida can be rubbed off while leukoplakia cannot.

B Nystatin lozenges

This is another treatment option for oral candida, which is not the most likely diagnosis.

D Aciclovir 200 mg 5× daily

This would be the correct treatment for herpes simplex viral sores. Oral lesions can appear as ulcers filled with yellow slough or cold sores. These are typically painful as well. As the clinical description does not match, this is not the right treatment option.

E Improve oral hygiene

defining illness but can occur in other cases or immunosuppression. The clinical picture is described above and it is often mistaken for oral candida, the only difference being that plaques of leucoplakia cannot be dislodged. The condition is caused by Epstein–Barr virus (EBV) and it only needs to be treated if it is causing symptoms such as pain or dysphagia. The best treatment is to commence antiretroviral therapy, as the CD4 count rises, it will resolve. Other treatment options are high-dose aciclovir (3 g/day) and it may respond to other antivirals. Surgery is also an option.

A Oral fluconazole

It would be a treatment option if the history and examination suggested oral candida. The clinical picture would be very similar except that oral candida can be rubbed off while leukoplakia cannot.

B Nystatin lozenges

This is another treatment option for oral candida, which is not the most likely diagnosis.

D Aciclovir 200 mg 5× daily

This would be the correct treatment for herpes simplex viral sores. Oral lesions can appear as ulcers filled with yellow slough or cold sores. These are typically painful as well. As the clinical description does not match, this is not the right treatment option.

E Improve oral hygiene

This would be the correct treatment for gingivitis. Gingivitis is inflammation of the gum and usually presents with gums that bleed easily.

An 18-year-old student is referred by his general practitioner to the Emergency Department, suffering from pharyngitis, shortness of breath with wheeze and a morbilliform skin rash.

Examination reveals generalised lymphadenopathy; wheeze in the lower zones is confirmed, and some skeletal muscle tenderness to palpation is noted. A chest X-ray is carried out and shows marked lower zone consolidation, which seems much worse than the findings noted on examination.

Investigations reveal a slightly elevated white blood cell count, with normal urea and electrolytes. The presence of cold agglutinins is noted.

Given the likely diagnosis, which one of the following would be the appropriate antibiotic choice in this case?

A	Clarithromycin
B	Penicillin V
C	Amoxicillin
D	Co-amoxiclav
E	Ciprofloxacin

Submit

An 18-year-old student is referred by his general practitioner to the Emergency Department, suffering from pharyngitis, shortness of breath with wheeze and a morbilliform skin rash.

Examination reveals generalised lymphadenopathy; wheeze in the lower zones is confirmed, and some skeletal muscle tenderness to palpation is noted. A chest X-ray is carried out and shows marked lower zone consolidation, which seems much worse than the findings noted on examination.

Investigations reveal a slightly elevated white blood cell count, with normal urea and electrolytes. The presence of cold agglutinins is noted.

Given the likely diagnosis, which one of the following would be the appropriate antibiotic choice in this case?

Your answer was correct

A	Clarithromycin
B	Penicillin V
C	Amoxicillin
D	Co-amoxiclav
E	Ciprofloxacin

Explanation

A	Clarithromycin

The answer is Clarithromycin (Option A).

Diffic

Peer

A
B
C
D
E
0 20

Sessi

Responses
Responses
Responses
Responses

A Clarithromycin

The answer is Clarithromycin (Option A).

This patient has *Mycoplasma* pneumonia, which is primarily said to affect school-aged children and young adults. Symptoms include non-exudative pharyngitis, bullous myringitis, skin rashes and wheeze on respiratory examination. Other symptoms and signs may include muscle tenderness, nerve palsies, lymphadenopathy, splenomegaly and conjunctivitis. Hints as to the diagnosis come from the fact that the chest X-ray findings are much worse than the clinical findings and that cold agglutinins are positive. Macrolide antibiotics, such as erythromycin and clarithromycin, are generally the treatment of choice for this condition.

Community-acquired pneumonia (CAP) is managed empirically generally, based on severity and suspicion of the cause, before an organism can be cultured. Mild and previously untreated CAP is caused by *Streptococcus pneumoniae* and *Haemophilus influenzae*, and typical treatment could be oral amoxicillin. Moderate CAP is caused by the above organisms, as well as *Mycoplasma pneumoniae*, and can be managed with oral amoxicillin and clarithromycin. Severe CAP should usually be treated in higher care areas with broad-spectrum antibiotics such as intravenous co-amoxiclav and oral clarithromycin. Clarithromycin has very good oral bioavailability and causes thrombophlebitis if given intravenously and therefore should be given orally, even in severe infections. Atypical CAP can be caused by *Legionella pneumophila*, *Chlamydophila* species and *Pneumocystis jiroveci*. Local guidelines may differ in the progression of antimicrobial choices, due to differences in the prevalence of different infectious organisms. Also, if culture results become available, then these should be used to guide further antibiotic choice.

B Penicillin V

10:48
625-262-0256 Leave

D	Co-amoxiclav

Co-amoxiclav (Option D) is incorrect.

Co-amoxiclav may be given to this patient with CAP, depending on the severity, as described above. It provides good antimicrobial effect against the main Gram-positive pathogens. Co-amoxiclav is a combination of amoxicillin and clavulanic acid. Clavulanic acid prevents the breakdown of amoxicillin in some resistant organisms.

E	Ciprofloxacin

Ciprofloxacin (Option E) is incorrect.

Ciprofloxacin provides good antimicrobial activity against *Pseudomonas* species – important pathogens in exacerbations of bronchiectasis and in the immunosuppressed patient – but has little value in treating chest infections without evidence of an underlying chronic lung disease such as bronchiectasis or a previous *Pseudomonas* infection.

Rate this question:

Next Question

Previous Q... Tag Questi... Feedback End Session

Blog About Pastest Contact Us Help

© Pastest 2019

Audio Video Share Participants More

10:48
625-262-0256
Leave

You are the senior house officer in the Genitourinary Medicine Clinic. A patient presents requesting post-exposure prophylaxis (PEP) following an unprotected sexual encounter.

Under which circumstances would you most recommend PEP be given?

A	A man having insertive anal sex with an HIV-positive man 4 weeks ago
B	A woman having receptive vaginal sex with a heterosexual British man of unknown HIV status 2 days ago
C	A woman performing fellatio with an HIV-positive man without ejaculation 1 day ago
D	A man having insertive anal sex with a British woman 1 day ago
E	A man having receptive anal sex with a British man 2 days ago

Submit

Previous Q...

Skip Questi...

Audio
Video
Share
Participants
More

10:52
625-262-0256
Leave

E A man having receptive anal sex with a British man 2 days ago

As the prevalence of HIV in the population of men who have sex with men is >12% in some areas, any man who has sex with other men must be considered to be in a high-risk group. Guidelines have been published by BASHH on PEP in 2015. The table from the guidelines which demonstrates the risk of HIV in each situation is detailed below.

Table 3: Summary table of PEPSE prescribing recommendations

	Source HIV status			
	HIV positive		Unknown HIV status	
	HIV VL unknown / detectable (>200copies/ml)	HIV VL undetectable (<200copies/ml)	From high prevalence country / risk-group (e.g. MSM) *	From low prevalence country / group
Receptive anal sex	Recommend	Not recommended[&] Provided source has confirmed HIV VL<200c/ml for >6 months	Recommend	Not recommended
Insertive anal sex	Recommend	Not recommended	Consider[†]	Not recommended
Receptive vaginal sex	Recommend	Not recommended	Consider[†]	Not recommended
Insertive vaginal sex	Consider[&]	Not recommended	Consider[†]	Not recommended
Fellatio with ejaculation[‡]	Not recommended	Not recommended	Not recommended	Not recommended
Fellatio without ejaculation[‡]	Not recommended	Not recommended	Not recommended	Not recommended
Splash of semen into eye	Not recommended	Not recommended	Not recommended	Not recommended
Cunnilingus	Not recommended	Not recommended	Not recommended	Not recommended
Sharing of injecting equipment**	Recommended	Not recommended	Consider	Not recommended
Human bite[§]	Not recommended	Not recommended	Not recommended	Not recommended
Needlestick from a discarded needle in the community			Not recommended	Not recommended

* High prevalence countries or risk-groups are those where there is a significant likelihood of the source individual being HIV-positive. Within the UK at present, this is likely to be MSM, IDUs from high-risk countries (see ** below) and individuals who have immigrated to the UK from areas of high HIV prevalence, particularly sub-Saharan Africa (high prevalence is >1%). HIV prevalence Country specific HIV prevalence can be found in UNAIDS Gap Report: http://www.unaids.org/en/resources/campaigns/2014/2014gapreport/gapreport

& The source's viral load must be confirmed with the source's clinic as <200c/ml for >6 months. Where there is any uncertainty about results or adherence to ART then PEP should be given after unprotected anal intercourse with an HIV-positive person

† More detailed knowledge of local prevalence of HIV within communities may change these recommendations from consider to recommended in areas of particularly high HIV prevalence. Co-factors in Box 1 that influence the likelihood of transmission should be considered

& Co-factors in Box 1 that influence the likelihood of transmission should be considered

‡ PEP is not recommended for individuals receiving fellatio i.e. inserting their penis into another's oral cavity. For individuals giving fellatio PEP is not recommended unless co-factors 1 & 2 in Box 1 are present e.g HIV seroconversion and oropharyngeal trauma / ulceration, see notes in guideline above

**HIV prevalence amongst IDUs varies considerably depending on country of origin and is particularly high in IDUs from Eastern Europe and central Asia. Region-specific estimates can be found in the UNAIDS Gap Report http://www.unaids.org/sites/default/files/media_asset/05_Peoplewhoinjectdrugs.pdf

§ A bite is assumed to constitute breakage of the skin with passage of blood. See notes in guideline above about extreme circumstances where PEP could be considered after discussion with a specialist

Ideally according to guidelines, it should be started within 72 hours of exposure.

Audio Video Share Participants More

10:53
625-262-0256
Leave

83% 20:53

Table 3: Summary table of PEPSE prescribing recommendations

	Source HIV status			
	HIV positive		Unknown HIV status	
	HIV VL unknown / detectable (>200copies/ml)	HIV VL undetectable (<200copies/ml)	From high prevalence country / risk-group (e.g. MSM) *	From low prevalence country / group
Receptive anal sex	Recommend	Not recommended[a] *Provided source has confirmed HIV VL<200c/ml for >6 months*	Recommend	Not recommended
Insertive anal sex	Recommend	Not recommended	Consider[†]	Not recommended
Receptive vaginal sex	Recommend	Not recommended	Consider[†]	Not recommended
Insertive vaginal sex	Consider[&]	Not recommended	Consider[†]	Not recommended
Fellatio with ejaculation[‡]	Not recommended	Not recommended	Not recommended	Not recommended
Fellatio without ejaculation[‡]	Not recommended	Not recommended	Not recommended	Not recommended
Splash of semen into eye	Not recommended	Not recommended	Not recommended	Not recommended
Cunnilingus	Not recommended	Not recommended	Not recommended	Not recommended
Sharing of injecting equipment**	Recommended	Not recommended	Consider	Not recommended
Human bite[§]	Not recommended	Not recommended	Not recommended	Not recommended
Needlestick from a discarded needle in the community			Not recommended	Not recommended

* High prevalence countries or risk-groups are those where there is a significant likelihood of the source individual being HIV-positive. Within the UK at present, this is likely to be MSM, IDUs from high-risk countries (see ** below) and individuals who have immigrated to the UK from areas of high HIV prevalence, particularly sub-Saharan Africa (high prevalence is >1%). HIV prevalence Country specific HIV prevalence can be found in UNAIDS Gap Report: http://www.unaids.org/en/resources/campaigns/2014/2014gapreport/gapreport

[a] The source's viral load must be confirmed with the source's clinic as <200c/ml for >6 months. Where there is any uncertainty about results or adherence to ART then PEP should be given after unprotected anal intercourse with an HIV-positive person

[†] More detailed knowledge of local prevalence of HIV within communities may change these recommendations from consider to recommended in areas of particularly high HIV prevalence. Co-factors in Box 1 that influence the likelihood of transmission should be considered

[&] Co-factors in Box 1 that influence the likelihood of transmission should be considered

[‡] PEP is not recommended for individuals receiving fellatio i.e. inserting their penis into another's oral cavity. For individuals giving fellatio PEP is not recommended unless co-factors 1 & 2 in Box 1 are present e.g HIV seroconversion and oropharyngeal trauma / ulceration, see notes in guideline above

**HIV prevalence amongst IDUs varies considerably depending on country of origin and is particularly high in IDUs from Eastern Europe and central Asia. Region-specific estimates can be found in the UNAIDS Gap Report http://www.unaids.org/sites/default/files/media_asset/05_Peoplewhoinjectdrugs.pdf

[§] A bite is assumed to constitute breakage of the skin with passage of blood. See notes in guideline above about extreme circumstances where PEP could be considered after discussion with a specialist

Ideally according to guidelines, it should be started within 72 hours of exposure.

A A man having insertive anal sex with an HIV-

Annotation Stop Share
Audio Video Share Participants More

10:53

A A man having insertive anal sex with an HIV-positive man 4 weeks ago

While this is very high-risk behaviour, the presentation is far too late for PEP. PEP should be started ideally within 24 hours but can be considered within 72 hours of exposure.

B A woman having receptive vaginal sex with a heterosexual British man of unknown HIV status 2 days ago

A British heterosexual man is considered to be of a low prevalence group and therefore PEP is not recommended.

C A woman performing fellatio with an HIV-positive man without ejaculation 1 day ago

The rate of transmission is considered to be of low risk even if ejaculation occurred.

D A man having insertive anal sex with a British woman 1 day ago

While the behaviour is considered to be of high risk of transmission, a British woman is considered to be of a low prevalence group and therefore no PEP should be recommended.

Rate this question:

Next Question

Previous Q... Tag Questi... Feedback End Session

Rana Alnasser's screen

10:53

A 50-year-old Jamaican woman, who migrated to the UK at around 20 years of age, presented with lethargy and breathlessness. She has never been out of UK since, has no history of recent travel, no previous medical history. Occasionally, she suffers abdominal pain, diarrhoea and intermittent abdominal bloating.

Investigations:

Hb	10.5 g/dl
WCC	8.1×10^9/l, (eosinophil 1.5)
PLT	210×10^9/l
Na^+	140 mmol/l
K^+	5.0 mmol/l
Creatinine	130 µmol/l
Chest X-ray	No cysts seen

Which of the following is the most likely underlying cause for her presentation?

A Ascaris

B Enterobius

C Strongyloides

D Echinococcus

E Schistosomiasis

Rana Alnasser's screen

Explanation

C Strongyloides

This woman has evidence of a parasitic infection, consistent with the likely anaemia of chronic disease seen here and hypereosinophilia. Strongyloides is characterised by pulmonary infiltration, perhaps accounting for the shortness of breath seen here. Ivermectin and thiobendazole are the treatments of choice for strongyloides. Although she has not travelled abroad for many years it is highly likely she may have undergone a repeat cycle of subclinical infection.

A Ascaris

Ascaris is caused by the nematode *Ascaris lumbricoides*. Transmitted through a faecal-oral route it migrates through the liver and lungs before settling in the small bowel. Often asymptomatic but can obstruct small bowels, bile ducts and pancreatic duct. Therefore, complications can include acute bowel obstruction, pancreatitis and cholangitis. Eosinophilia occurs as well. The patient's symptoms makes this a less likely diagnosis.

B Enterobius

Enterobius vermicularis are commonly known as threadworms causing anal itch as they lay eggs on the perineum. Diagnosis can be made using sticky tape to demonstrate eggs. This diagnosis does not match the symptoms described at all.

D Echinococcus

Echinococcus species cause cystic hydatid diseases as

B Enterobius

Enterobius vermicularis are commonly known as threadworms causing anal itch as they lay eggs on the perineum. Diagnosis can be made using sticky tape to demonstrate eggs. This diagnosis does not match the symptoms described at all.

D Echinococcus

Echinococcus species cause cystic hydatid diseases as zoonosis, commonly in rural areas, especially in sheep-farming regions. Cysts may be present in multiple organs and can present with symptoms related to where they are present. Hepatic cysts can cause obstructive jaundice, lung cysts can cause dyspnoea, chest pain and haemoptysis, CNS cysts can cause space-occupying signs. Other cysts are likely to be asymptomatic. The absence of any cysts on the CXR makes this an unlikely diagnosis.

E Schistosomiasis

This is a type of trematodes which are released from their snail hosts into water where they can cause itchy popular rashes. They then migrate to the liver via the lungs over two weeks to cause fever, urticarial, diarrhoea, cough, wheeze and hepatosplenomegaly. The latter is also called Katayama fever. Alternatively, migration can occur into bladder causing frequency, dysuria, haematuria and incontinence. The absence of the type of symptoms described above and the absence to fresh-water exposure in endemic areas makes this a less likely diagnosis.

Rate this question:

Next Question

A 21-year-old man has recently returned from a trip to north-eastern Australia where he visited the Queensland rainforest on a motor tour. He stayed in rangers' lodges on each overnight stop. He returned via Singapore but did not leave the airport.

He has been brought to the Emergency Department by his girlfriend who says he has been suffering drenching fevers and sweats for five days since returning. He also has a severe, unremitting headache and muscle aches which he says make him feel bone weary.

On examination, there is a maculopapular rash, conjunctival and pharyngeal injection lymphadenopathy affecting neck lymph nodes. He has a fever of 39.5 °C.

Investigations:

White cell count (WCC)	Low
Sodium (Na^+)	129 mmol/l
Alanine transaminase (ALT)	150 U/l

Which one of the following would be the most appropriate initial intervention in this man?

A Oral quinine

B IV quinine

C A thick and thin film

D Paracetamol

E IV broad-spectrum antibiotics

Explanation

D Paracetamol

The correct diagnosis is dengue fever, which does occur in eastern Australia. Dengue fever is caused by infection with one of four subtypes of the dengue virus and was first described in Chinese writings as early as AD 265. It typically produces severe fever, headache, rash and arthralgia, and in many cases is a self-limiting illness lasting 5–7 days. The fever may only disappear for one day and then reappear, the so-called 'saddleback' pattern. A more severe form, dengue haemorrhagic fever, occasionally presents and requires more intensive supportive therapy including correction of clotting abnormalities. Uncomplicated dengue, as in this case, should be managed with intravenous fluid rehydration and paracetamol for pain relief and as an antipyretic.

E IV broad-spectrum antibiotics

If this patient had signs of sepsis or meningitis this would be an appropriate answer, but there is no evidence of this.

A Oral quinine

Oral quinine is a treatment option for malaria. As the patient has not travelled to a malaria-endemic country this is a very unlikely diagnosis, and therefore quinine is an incorrect treatment option. Also the clinical history of rash and severe headache with myalgia is more clinically consistent with dengue than malaria, but malaria could have been considered if there had been the matching travel history for it, as cerebral malaria does occur.

B IV quinine

be an appropriate answer, but there is no evidence of this.

A Oral quinine

Oral quinine is a treatment option for malaria. As the patient has not travelled to a malaria-endemic country this is a very unlikely diagnosis, and therefore quinine is an incorrect treatment option. Also the clinical history of rash and severe headache with myalgia is more clinically consistent with dengue than malaria, but malaria could have been considered if there had been the matching travel history for it, as cerebral malaria does occur.

B IV quinine

IV quinine is incorrect as it is a treatment option for severe malaria.

C A thick and thin film

This is the standard investigation which can help identify malaria and the species involved.

Rate this question:

Next Question

© Pastest 2019

You see a patient in the HIV Outpatients Clinic. He was diagnosed HIV-positive 6 weeks ago and was found to have a CD4 count of 12×10^6/l. He was commenced on prophylactic co-trimoxazole, but developed a rash and derangement of his liver function tests and it was stopped.

He feels well now. He is planning to go mountain trekking in the Himalayas for the next three weeks. You try and dissuade him on the basis that he needs to be more immunocompetent before he goes but he will not be moved, as the trip was organised months ago and is for charity.

The patient wants to reduce his risk of catching a range of infections and would like some information about vaccinations. He wants to know what vaccinations he should have, both routine and for travelling purposes.

Which of the following groups of vaccines would you recommend as being safe in HIV-positive patients?

A	Hep A, Hep B, mumps
B	Hep A, Hep B, BCG, flu jab
C	Hep A, Hep B, flu jab, pneumococcal vaccine
D	BCG, Ty21a typhoid, pneumococcal vaccine
E	Flu jab, pneumococcal vaccine, typhoid 21a, Hep B

Submit

Explanation

C Hep A, Hep B, flu jab, pneumococcal vaccine

In general, non-replicating vaccines, including whole inactivated, polysaccharide, conjugated and subunit vaccines, can be safely used in HIV infected people. Live replicating vacines have traditionally been seen as contraindicated, but with immunorestoration following antiretroviral therapy some vaccines are recommended including MMR, varicella-zoster virus and yellow fever. For the latter three, a CD4 count >200 is advised.

Most clinics will routinely vaccinate all HIV-positive patients against hepatitis A and B. Every traveller with HIV should be sure they are vaccinated against hepatitis A and B. Pneumovax and flu vaccine are recommended. Countries have different vaccination requirements for entry. If polio vaccine is required, it should be the inactivated version, not the live oral version.

A Hep A, Hep B, mumps

Mumps is part of the MMR vaccine and is a live attenuated vaccine. As the patient is immunocompromised with a low CD4 count this is not recommended.

B Hep A, Hep B, BCG, flu jab

BCG is a live vaccine and is therefore contraindicated.

D BCG, Ty21a typhoid, pneumococcal vaccine

BCG is a live vaccine and is therefore contraindicated.

E Flu jab, pneumococcal vaccine, typhoid 21a, Hep B

contraindicated, but with immunorestoration following antiretroviral therapy some vaccines are recommended including MMR, varicella-zoster virus and yellow fever. For the latter three, a CD4 count >200 is advised.

Most clinics will routinely vaccinate all HIV-positive patients against hepatitis A and B. Every traveller with HIV should be sure they are vaccinated against hepatitis A and B. Pneumovax and flu vaccine are recommended.
Countries have different vaccination requirements for entry. If polio vaccine is required, it should be the inactivated version, not the live oral version.

A Hep A, Hep B, mumps

Mumps is part of the MMR vaccine and is a live attenuated vaccine. As the patient is immunocompromised with a low CD4 count this is not recommended.

B Hep A, Hep B, BCG, flu jab

BCG is a live vaccine and is therefore contraindicated.

D BCG, Ty21a typhoid, pneumococcal vaccine

BCG is a live vaccine and is therefore contraindicated.

E Flu jab, pneumococcal vaccine, typhoid 21a, Hep B

Typhoid is a live vaccine and is therefore contraindicated.

32165

Rate this question:

A 23-year-old immigrant from Zimbabwe presents to the clinic with headache, neck stiffness, malaise and photophobia which has been worsening over the past few days. He came to the UK 2 years ago and since then has been at university.

Over the past few months, his partner tells you that he has lost weight and seems to suffer from night sweats.

On examination, he is pyrexial 37.8 °C, has neck stiffness and photophobia. There is axillary and inguinal lymphadenopathy. He appears to have isolated 6th nerve palsy.

Investigations:

Hb	11.0 g/dl
WCC	10.9×10^9/l
PLT	120×10^9/l
Na^+	140 mmol/l
K^+	4.9 mmol/l
Creatinine	130 µmol/l
Lumbar puncture	Turbid appearance, 22 cm water opening pressure, elevated CSF protein, lymphocytes ++, neutrophils +
India ink test	Positive

Which of the following is the most likely diagnosis?

A Herpes simplex encephalitis

B Cytomegalovirus (CMV) meningoencephalitis

Over the past few months, his partner tells you that he has lost weight and seems to suffer from night sweats.

On examination, he is pyrexial 37.8 °C, has neck stiffness and photophobia. There is axillary and inguinal lymphadenopathy. He appears to have isolated 6th nerve palsy.

Investigations:

Hb	11.0 g/dl
WCC	10.9×10^9/l
PLT	120×10^9/l
Na^+	140 mmol/l
K^+	4.9 mmol/l
Creatinine	130 µmol/l
Lumbar puncture	Turbid appearance, 22 cm water opening pressure, elevated CSF protein, lymphocytes ++, neutrophils +
India ink test	Positive

Which of the following is the most likely diagnosis?

A Herpes simplex encephalitis

B Cytomegalovirus (CMV) meningoencephalitis

C Cryptococcal meningitis

D Meningococcal meningitis

E Tuberculous meningitis

K^+	4.9 mmol/l
Creatinine	130 µmol/l
Lumbar puncture	Turbid appearance, 22 cm water opening pressure, elevated CSF protein, lymphocytes ++, neutrophils +
India ink test	Positive

Which of the following is the most likely diagnosis?

Your answer was correct

A Herpes simplex encephalitis

B Cytomegalovirus (CMV) meningoencephalitis

C Cryptococcal meningitis

D Meningococcal meningitis

E Tuberculous meningitis

Explanation

C Cryptococcal meningitis

Cryptococcus neoformans is a yeast (fungus) which can cause a meningitis in the immunocompromised. The India ink test is used to diagnose cryptococcal meningitis, and the raised opening pressure, turbid appearance to the CSF, raised protein and mixed lymphocytic/neutrophil picture are relatively typical of the diagnosis. From his history there is a strong suspicion that he may be HIV positive, accounting for the underlying cryptococcal infection.

Explanation

C Cryptococcal meningitis

Cryptococcus neoformans is a yeast (fungus) which can cause a meningitis in the immunocompromised. The India ink test is used to diagnose cryptococcal meningitis, and the raised opening pressure, turbid appearance to the CSF, raised protein and mixed lymphocytic/neutrophil picture are relatively typical of the diagnosis. From his history there is a strong suspicion that he may be HIV positive, accounting for the underlying cryptococcal infection. Management of the condition involves the use of amphotericin B, which is typically given as IV combination therapy with flucytosine for a period of 2 weeks. Raised CSF opening pressure is associated with a poor prognosis in this condition.

A Herpes simplex encephalitis

Herpes simplex encephalitis is most commonly caused by HSV-1. Presentation is typically with fever and altered mentation, there may also be a recent history of cold sores. Onset is typical over a few hours to days and immunocompetent patients may be affected. In this case the tempo of presentation, as well as the CSF finding, excludes herpes simplex encephalitis.

B Cytomegalovirus (CMV) meningoencephalitis

CMV meningoencephalitis is rare but possible in the immunocompetent host. In the immunocompromised (eg HIV positive, transplant recipient) the risk is increased. Presentation would typically be with acute-onset fever, meningism and altered mentation. In this case the tempo of presentation, as well as the CSF findings, exclude CMV meningoencephalitis.

11:12
625-262-0256 Leave

D Meningococcal meningitis

Meningococcal meningitis is the most common bacterial meningitis in the UK and is caused by *Neisseria meningitidis*. Presentation is with acute-onset fever, headache, neck stiffness, photophobia and vomiting. Prompt treatment with IV antibiotics (ceftriaxone) is essential as the disease is rapidly fatal. CSF typically shows a neutrophilia, low glucose, raised protein and Gram-negative diplococci on the Gram stain.

E Tuberculous meningitis

Tuberculous meningitis may result from primary infection with *Mycobacterium tuberculosis* or reactivation of latent infection. It is more common in the immunocompromised. Presentation is often subacute with fever, neck stiffness, headache and altered mentation. Typical MRI changes are of a basal meningitis. CSF findings are typically a lymphocytosis with low glucose and raised protein. In this case we are told that the India ink stain is positive which points to an alternative explanation for the patient's symptoms.

Rate this question:

Next Question

Previous Q... Tag Questi... Feedback End Session

Blog About Pastest Contact Us Help

© Pastest 2019

Audio Video Share Participants More

11:12
625-262-0256 Leave

A 37-year-old woman presents with a 2-week history of increasing breathlessness, dry cough and joint swelling. She has a painful left ear and when she breathes in she has sharp stabbing pains on the right side of her chest. She is also concerned about a rash that has started on both her arms and legs which burns her, but is not itchy. She smokes 20 cigarettes a day and her mother died of lung cancer at the age of 43 years.

On examination, she is febrile, with a temperature of 38.2 °C, respiration rate 20/min on exertion and her saturation is 94% on room air. She has symmetrical, mucocutaneous lesions, with concentric colour changes in most lesions. She has an erythematous left ear and occipital lymphadenopathy. She has coarse inspiratory crackles in the right lung mid-zone.

Investigations:

Hb	9.3 g/dl
WCC	16.2×10^9/l
MCV	84.6 fl
Na^+	131 mmol/l
Urea	6.3 mmol/l
Creatinine	93 µmol/l
ALT	135 U/l

What is the most likely diagnosis?

A Influenza A

B Small cell lung cancer

C Tuberculosis

Audio Video Share Participants More

20 cigarettes a day and her mother died of lung cancer at the age of 43 years.

On examination, she is febrile, with a temperature of 38.2 °C, respiration rate 20/min on exertion and her saturation is 94% on room air. She has symmetrical, mucocutaneous lesions, with concentric colour changes in most lesions. She has an erythematous left ear and occipital lymphadenopathy. She has coarse inspiratory crackles in the right lung mid-zone.

Investigations:

Hb	9.3 g/dl
WCC	16.2×10^9/l
MCV	84.6 fl
Na^+	131 mmol/l
Urea	6.3 mmol/l
Creatinine	93 µmol/l
ALT	135 U/l

What is the most likely diagnosis?

A Influenza A

B Small cell lung cancer

C Tuberculosis

D Sarcoidosis

E Mycoplasma pneumonia

Rana Alnasser's screen

E Mycoplasma pneumonia

Explanation

E Mycoplasma pneumonia

This lady has a typical history for mycoplasma pneumonia, the onset of which occurs over 1–3 weeks, often with a dry cough and fever. It is associated with bullous myringitis and erythema multiforme. She has a low haemoglobin, which points to mycoplasma pneumonia as it is associated with an autoimmune haemolytic anaemia due to the presence of anti-I antibody. The treatment of choice is a macrolide antibiotic.

A Influenza A

Influenza is an RNA virus and the cause of pandemic flu. Presentation is typically with fever, myalgia, shortness of breath and a non-productive cough. The extrapulmonary symptoms described in this patient, such as erythema multiforme and myringitis, as well as the duration of illness, are not typical of influenza A.

B Small cell lung cancer

The rapidity of symptom onset and the associated fevers point towards an infectious aetiology for this patient's symptoms. Typical extrapulmonary manifestations of small cell lung cancer include a syndrome of inappropriate antidiuretic hormone hypersecretion (SIADH) and Lambert–Eaton myasthenic syndrome (LEMS), but not erythema multiforme, myringitis or arthritis.

C Tuberculosis

Tuberculosis (TB) is a chronic bacterial infection caused by

11:16

MyPastest
https://mypastest.pastest.com

A 37-year-old woman presents with a 2-week history of increasing breathlessness, dry cough and joint swelling. She has a painful left ear and when she breathes in she has sharp stabbing pains on the right side of her chest. She is also concerned about a rash that has started on both her arms and legs which burns her, but is not itchy. She smokes 20 cigarettes a day and her mother died of lung cancer at the age of 43 years.

On examination, she is febrile, with a temperature of 38.2 °C, respiration rate 20/min on exertion and her saturation is 94% on room air. She has symmetrical, mucocutaneous lesions, with concentric colour changes in most lesions. She has an erythematous left ear and occipital lymphadenopathy. She has coarse inspiratory crackles in the right lung mid-zone.

Investigations:

Hb	9.3 g/dl
WCC	16.2 × 10^9/l
MCV	84.6 fl
Na^+	131 mmol/l
Urea	6.3 mmol/l
Creatinine	93 µmol/l
ALT	135 U/l

What is the most likely diagnosis?

Your answer was correct

Diffic
Peer
A
B
C
D
E
0
20
Sess
Responses
Responses
Responses
Responses

An 85-year-old Jamaican man, who is visiting his son, is admitted to the Emergency Department with a left pneumonia. He has a number of large, painless subcutaneous nodules which he says have been developing over a number of years; these are particularly marked over his shins. Some of these have ulcerated but have a well-defined edge with granulation tissue and yellowish slough. There is hyperkeratosis of the soles of the feet and the palms of the hands.

Investigations:

Hb	10.5 g/dl
WCC	9.2×10^9/l
PLT	150×10^9/l
Na^+	139 mmol/l
K^+	4.9 mmol/l
Creatinine	141 µmol/l
VDRL	+
TPHA	+
FTA-ABS	+

He tells you he has been with the same partner for the past 65 years.

Which of the following represents the most likely diagnosis of his skin lesions?

A HIV

B Pinta

C Sarcoidosis

palms of the hands.

Investigations:

Hb	10.5 g/dl
WCC	9.2×10^9/l
PLT	150×10^9/l
Na^+	139 mmol/l
K^+	4.9 mmol/l
Creatinine	141 µmol/l
VDRL	+
TPHA	+
FTA-ABS	+

He tells you he has been with the same partner for the past 65 years.

Which of the following represents the most likely diagnosis of his skin lesions?

A HIV

B Pinta

C Sarcoidosis

D Tertiary syphilis

E Yaws

Explanation

E Yaws

Yaws is caused by *Treponema pertenue*, a non-venereal treponemal disease which, similar to syphilis, may persist for many years. Serological testing is indistinguishable from that seen for syphilis, and differentiation is made on history and clinical features. Presentation is with one or multiple skin lesions which may ulcerate. Transmission is via skin-to-skin contact. Like syphilis, penicillin remains the drug of choice for treatment of yaws, with erythromycin, tetracycline or doxycycline being possible alternatives. Patients with yaws, particularly where the infection is chronic, may require re-treatment every few years. Pinta is caused by *Treponema carateum* and is characterised mainly by chronic pigmentary skin lesions which occur predominantly in a young adult population.

A HIV

The skin lesions described would not be typical of HIV or associated complications.

B Pinta

Pinta is one of the endemic treponeal diseases. It is endemic to central and south America. Presentation is with flat hyperkeratotic skin lesions with lymphadenopathy which resolve over time. Pinta is serologically indistinguishable from syphilis hence the positive result. In this case epidemiology makes an alternative diagnosis more likely.

C Sarcoidosis

Sarcoidosis is a multisystem, inflammatory condition,

4G 11:22

Google

pinta infection

ALL IMAGES SHOPPING NEWS VIDEOS MAPS BOOKS FLIGHTS

Latest GIF HD Product

syphilis yaws carateum treponema bejel treponema pallidum

Pinta
visualdx.com

Nonvenereal) Treponematoses ...
accessmedicine.mhmedical.com

Pinta in Austr
jamanetwork.c

Pinta, Yaws and Bejel (ICDs 103, 102 ...
brianaltonenmph.com

Pinta Clinical Presentation: History ...
emedicine.medscape.com

dermaamin.co

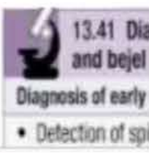

Scroll capture Draw Crop

Discover Updates Search Recent

flat hyperkeratotic skin lesions with lymphadenopathy which resolve over time. Pinta is serologically indistinguishable from syphilis hence the positive result. In this case epidemiology makes an alternative diagnosis more likely.

C Sarcoidosis

Sarcoidosis is a multisystem, inflammatory condition, characterised by non-caseating granuloma formation. Typical presentation (Lofgren syndrome) is with bilateral hilar adenopathy, arthritis and erythema nodosum.

D Tertiary syphilis

Tertial syphilis occurs approximately 10–15 years after initial infection. Presentation can be divided in to three forms: gummatous syphilis, neurosyphilis and cardiovascular syphilis. Gummatous syphilis is characterised by rubbery subcutaneous growths. The presentation descried does not fit with tertiary syphilis and the positive syphilis serology can be explained by endemic treponematoses.

Rate this question:

Next Question

Previous Q... Tag Questi... Feedback End Session

Blog About Pastest Contact Us Help

© Pastest 2019

11:24

MyPastest
https://mypastest.pastest.com

Pastest+

A 22-year-old student teacher presents to the emergency general practitioner with severe, unremitting vomiting that has lasted for the past 13 h. There is associated fever, headache, diarrhoea and myalgia. He is unable even to keep water down.

History of note is that six members of his class were absent today due to gastroenteritis, and it is currently November. Both the diarrhoea and vomiting were profuse and watery, with no sign of blood.

Which one of the following is the most likely cause for this presentation?

A	*Campylobacter* infection
B	*Salmonella* infection
C	Norovirus
D	*Cryptosporidium* infection
E	*Shigella* infection

Submit

Previous Q...

Skip Questi...

general practitioner with severe, unremitting vomiting that has lasted for the past 13 h. There is associated fever, headache, diarrhoea and myalgia. He is unable even to keep water down.

History of note is that six members of his class were absent today due to gastroenteritis, and it is currently November. Both the diarrhoea and vomiting were profuse and watery, with no sign of blood.

Which one of the following is the most likely cause for this presentation?

Your answer was correct

A	*Campylobacter* infection
B	*Salmonella* infection
C	Norovirus
D	*Cryptosporidium* infection
E	*Shigella* infection

Explanation

C Norovirus

The rapid presentation, coupled with a number of virtually simultaneous cases in his class of students, suggests a viral aetiology in this case. Norovirus belongs to the Calicivirus family, members of which may be responsible for a number of outbreaks of viral gastroenteritis, often during the winter months. Rotavirus is a member of the Reoviridae family and causes diarrhoea that may be dramatic in onset. Intravenous fluid replacement is rarely required in adults

Explanation

C Norovirus

The rapid presentation, coupled with a number of virtually simultaneous cases in his class of students, suggests a viral aetiology in this case. Norovirus belongs to the Calicivirus family, members of which may be responsible for a number of outbreaks of viral gastroenteritis, often during the winter months. Rotavirus is a member of the Reoviridae family and causes diarrhoea that may be dramatic in onset. Intravenous fluid replacement is rarely required in adults presenting with these infections, and the majority can be managed as outpatients with oral rehydration therapy.

A *Campylobacter* infection

Campylobacter gastroenteritis occurs following ingestion of contaminated milk, poultry or water. Following an incubation period of 2-5 days, there is bloody diarrhoea, abdominal pain, fever and sometimes peritonism. The absence of the above symptoms and rapid onset makes this an unlikely diagnosis.

B *Salmonella* infection

Salmonella gastroenteritis occurs following ingestion of contaminated poultry or eggs. Eggs are routinely screened in the UK, making this unusual infection. Infection occurs 12-48 h following exposure and presents with diarrhoea, vomiting, abdominal pain, fever and can progress to sepsis. Again the presentation does not match.

D *Cryptosporidium* infection

Cryptosporidium causes gastroenteritis in immunocompromised patients only after ingestion of water

aetiology in this case. Norovirus belongs to the Calicivirus family, members of which may be responsible for a number of outbreaks of viral gastroenteritis, often during the winter months. Rotavirus is a member of the Reoviridae family and causes diarrhoea that may be dramatic in onset. Intravenous fluid replacement is rarely required in adults presenting with these infections, and the majority can be managed as outpatients with oral rehydration therapy.

A *Campylobacter* infection

Campylobacter gastroenteritis occurs following ingestion of contaminated milk, poultry or water. Following an incubation period of 2-5 days, there is bloody diarrhoea, abdominal pain, fever and sometimes peritonism. The absence of the above symptoms and rapid onset makes this an unlikely diagnosis.

B *Salmonella* infection

Salmonella gastroenteritis occurs following ingestion of contaminated poultry or eggs. Eggs are routinely screened in the UK, making this unusual infection. Infection occurs 12-48 h following exposure and presents with diarrhoea, vomiting, abdominal pain, fever and can progress to sepsis. Again the presentation does not match.

D *Cryptosporidium* infection

Cryptosporidium causes gastroenteritis in immunocompromised patients only after ingestion of water contaminated by cows. The absence of evidence of immunocompromise makes this less likely.

E *Shigella* infection

Shigella gastroenteritis can occur with any food and is spread by the faecal-oral route. It occurs after an

A general practitioner (GP) refers a 21-year-old man, who had been previously fit and well, for a second opinion. He had presented with a 6-week history of flitting arthralgia and myalgia. Prior to the onset of this problem, he had been on holiday in the Far East where he had unprotected sexual intercourse with a heterosexual on one occasion only.

On general examination, there was no evidence of arthritis but it was noted that the patient had bilateral cervical lymphadenopathy. Investigations showed a white cell count at the lower end of normal, mild anaemia, normal urea and electrolytes, and abnormal liver function tests with all the liver enzymes elevated. Urethral swabs for chlamydia and gonococcus were negative.

Which is the most likely diagnosis?

A	Acute HIV infection
B	Brucellosis
C	Reiter's syndrome
D	Adult-onset Still's disease
E	Relapsing polychondritis

Submit

11:29
625-262-0256 Leave

sexual intercourse with a heterosexual on one occasion only.

On general examination, there was no evidence of arthritis but it was noted that the patient had bilateral cervical lymphadenopathy. Investigations showed a white cell count at the lower end of normal, mild anaemia, normal urea and electrolytes, and abnormal liver function tests with all the liver enzymes elevated. Urethral swabs for chlamydia and gonococcus were negative.

Which is the most likely diagnosis?

Your answer was correct

A	Acute HIV infection
B	Brucellosis
C	Reiter's syndrome
D	Adult-onset Still's disease
E	Relapsing polychondritis

Sess

Responses
Responses
Responses
Responses

Explanation

A	Acute HIV infection

Acute HIV infection can affect any number of organ systems, including the lymphatics, skin, gastrointestinal system, genitourinary system, bone marrow and nervous system, with the clinical findings being related to the organ system affected. These signs include persistent generalised lymphadenopathy, oral thrush, oral hairy leukoplakia, shingles (especially in a patient under the age of 40), anaemia, thrombocytopenia and secondary opportunistic

Audio Video Share Participants More

11:29
625-262-0256 Leave

Explanation

A Acute HIV infection

Acute HIV infection can affect any number of organ systems, including the lymphatics, skin, gastrointestinal system, genitourinary system, bone marrow and nervous system, with the clinical findings being related to the organ system affected. These signs include persistent generalised lymphadenopathy, oral thrush, oral hairy leukoplakia, shingles (especially in a patient under the age of 40), anaemia, thrombocytopenia and secondary opportunistic infections, eg *Mycobacterium tuberculosis*. The work-up of the patient varies depending on the initial presenting complaint but it is important to exclude all other treatable causes. Acute infection may be detected by the presence of P24 antigen or HIV RNA, both of which precede the development of IgM or IgG antibodies.

B Brucellosis

The lack of direct exposure and travel to an endemic area makes it a less likely diagnosis. It is a zoonosis endemic in the Middle and Far East, as well as Bosnia, which is spread via the contact with animals, their exhalations or some animal products, such as unpasteurised goat's milk. It is therefore common in veterinarians and farmers. Presentation of brucellosis is highly varied, but generally includes fever and malaise.

C Reiter's syndrome

It is a triad urethritis, conjunctivitis and seronegative arthritis secondary to infection in another part of the boy. There is not enough evidence to make this diagnosis likely, and there is also no evidence of a sexually transmitted

Audio Video Share Participants More

11:30
625-262-0256 Leave

D Brucellosis

The lack of direct exposure and travel to an endemic area makes it a less likely diagnosis. It is a zoonosis endemic in the Middle and Far East, as well as Bosnia, which is spread via the contact with animals, their exhalations or some animal products, such as unpasteurised goat's milk. It is therefore common in veterinarians and farmers. Presentation of brucellosis is highly varied, but generally includes fever and malaise.

C Reiter's syndrome

It is a triad urethritis, conjunctivitis and seronegative arthritis secondary to infection in another part of the boy. There is not enough evidence to make this diagnosis likely, and there is also no evidence of a sexually transmitted infection, the most likely cause. In addition, this diagnosis would not explain the abnormalities in the blood tests.

D Adult-onset Still's disease

The presentation makes it unlikely. Adult-onset Still's disease is characterised by a triad of persistent and high fevers, arthralgia and a salmon-coloured rash. There is no evidence of a rash and this diagnosis would not explain the abnormal liver function tests.

E Relapsing polychondritis

The clinical picture does not match relapsing polychondritis, which is characterised by nasal and auricular chondritis and usual onset is between 40 and 50 years. It can have greater systemic involvement and can even be fatal with airway involvement. It would explain the arthralgia but little else in the history.

Rate this question:

Audio Video Share Participants More

11:30
625-262-0256
Leave

A 32-year-old patient presented with a 2-day history of progressive deterioration in his visual acuity and loss of colour vision. He had no ocular pain. Six weeks previously, he was diagnosed with pulmonary tuberculosis and HIV. He was taking quadruple anti-tuberculous therapy and antiretroviral therapy.

On examination, bilateral fundoscopy was unremarkable.

Investigations:

CD4 count at diagnosis	146×10^6/l (430–1690)
CD4 count at presentation	302×10^6/l (430–1690)

Which of the following is the most likely diagnosis?

A Cytomegalovirus retinitis

B Ethambutol toxicity

C Retinal vein thrombosis

D Rifampicin toxicity

E Toxoplasmosis

Submit

Audio
Video
Share
Participants
More

11:31
625-262-0256 Leave

Explanation

B Ethambutol toxicity

This patient will be receiving ethambutol as standard first-line treatment for tuberculosis, and optic neuropathy is a known side effect of this medication. It should be stopped immediately, and the patient should be referred to ophthalmology as an emergency. It is common for fundoscopy to be normal in the early stages of neuropathy.

A Cytomegalovirus retinitis

Although this can present with loss of visual acuity, it would be unusual for it to affect colour vision so early in its presentation. Furthermore, you might expect to see signs of retinal inflammation on fundoscopy, which is normal here. Lastly, this patient's CD4 count is improving and he is on effective retroviral treatment, and therefore opportunistic infection with cytomegalovirus is less likely. Instead, this patient's symptoms are much more likely to be caused by optic nerve toxicity, a known side effect of ethambutol: ethambutol is standard first-line therapy for tuberculosis.

C Retinal vein thrombosis

This typically presents with unilateral blurred vision, but loss of colour vision would be unusual: this implies optic nerve pathology. Furthermore, if this were retinal vein occlusion, you would expect to see signs on fundoscopy, which is normal here. Instead, this patient is likely to be suffering from ethambutol toxicity. Ethambutol is standard first-line therapy for tuberculosis, and optic neuropathy is a known side effect.

D Rifampicin toxicity

Audio Video Share Participants More

11:32
625-262-0256 Leave

This patient will probably be taking rifampicin for tuberculosis, but his signs and symptoms are consistent with an optic neuropathy, which is not a side effect of rifampicin (major side effects of rifampicin are turning secretions orange and acting as an enzyme inducer). Instead ethambutol is the likely culprit: he will be taking this as part of first-line therapy for tuberculosis, and optic neuropathy is a known side effect.

E Toxoplasmosis

Ocular toxoplasmosis typically presents as a blurring of the vision; however, it would be unusual for it to cause loss of colour vision as this implies involvement of the optic nerve. Furthermore, you might expect to see retinal scarring if this were toxoplasmosis. This patient may be immunosuppressed, but not significantly so: his CD4 count has improved and he is on effective antiretroviral medication. Instead, this patient's optic neuropathy is much more likely to be caused by ethambutol toxicity. He will be taking ethambutol as a first-line therapy for tuberculosis, and optic neuropathy is a known side effect.

Rate this question:

Blog About Pastest Contact Us Help
© Pastest 2019

Audio Video Share Participants More

11:32
625-262-0256 Leave

A 24-year-old man known to be HIV positive presents with a 3-day history of worsening shortness of breath, fevers and a cough productive of green sputum. His last CD4 count 2 months ago was 220 × 10^6/l and he is on no treatment, despite it having been strongly recommended on several appointments.

On examination, O_2 saturation is 91% on breathing room air, temperature 38.8°C, pulse 120 beats/min, crackles are heard in both midzones. Chest X-ray shows diffuse interstitial shadowing bilaterally. Arterial blood gas (on air) $p(O_2)$ 10.5 kPa, $p(CO_2)$ 3.7 kPa, bicarbonate 22 mmol/l, O_2 saturation 90%.

What is the most appropriate initial treatment?

A	Intravenous (IV) co-trimoxazole
B	Amoxicillin and clarithromycin
C	Clindamycin and primaquine
D	Liposomal amphotericin
E	Metronidazole

Submit

Previous Q... Skip Questi...

Audio Video Share Participants More

11:34
625-262-0256 Leave

A 24-year-old man known to be HIV positive presents with a 3-day history of worsening shortness of breath, fevers and a cough productive of green sputum. His last CD4 count 2 months ago was 220 × 10^6/l and he is on no treatment, despite it having been strongly recommended on several appointments.

On examination, O_2 saturation is 91% on breathing room air, temperature 38.8°C, pulse 120 beats/min, crackles are heard in both midzones. Chest X-ray shows diffuse interstitial shadowing bilaterally. Arterial blood gas (on air) $p(O_2)$ 10.5 kPa, $p(CO_2)$ 3.7 kPa, bicarbonate 22 mmol/l, O_2 saturation 90%.

What is the most appropriate initial treatment?

Your answer was incorrect

A	Intravenous (IV) co-trimoxazole
B	Amoxicillin and clarithromycin
C	Clindamycin and primaquine
D	Liposomal amphotericin
E	Metronidazole

Diffic

Peer

Sess

Responses
Responses
Responses
Responses

Explanation

B Amoxicillin and clarithromycin

Audio Video Share Participants More

Explanation

B Amoxicillin and clarithromycin

The history is classical of a community-acquired pneumonia and does not suggest *Pneumocystis jirovecii pneumonia* (PCP), which generally has a more subacute time course with a dry cough. The X-ray would support a diagnosis of an atypical pneumonia. As well as opportunistic infections, HIV-positive patients are also more susceptible to common bacterial infections than non-immunocompromised patients. The treatment for community-acquired pneumonia is amoxicillin plus a macrolide, according to British Thoracic Society guidelines.

A Intravenous (IV) co-trimoxazole

This would be the first-line treatment for PCP, which is not the most likely diagnosis. PCP is characterised by a more indulent course of a dry cough, commonly a normal chest X-ray and severe hypoxia. It is also associated with pneumothorax. The clinical picture is more in keeping with an atypical chest infection rather than PCP.

C Clindamycin and primaquine

This is the second-line treatment for PCP. If the patient could not tolerate co-trimoxazole and the diagnosis was PCP then this would be an appropriate choice.

D Liposomal amphotericin

This is the treatment for severe fungal infection or leishmaniasis. Since the patient has a low CD4 count he is at risk of fungal infections, especially invasive aspergillosis, but this is an unlikely diagnosis given the duration of illness and the bilateral signs.

pneumonia (PCP), which generally has a more subacute time course with a dry cough. The X-ray would support a diagnosis of an atypical pneumonia. As well as opportunistic infections, HIV-positive patients are also more susceptible to common bacterial infections than non-immunocompromised patients. The treatment for community-acquired pneumonia is amoxicillin plus a macrolide, according to British Thoracic Society guidelines.

A Intravenous (IV) co-trimoxazole

This would be the first-line treatment for PCP, which is not the most likely diagnosis. PCP is characterised by a more indulent course of a dry cough, commonly a normal chest X-ray and severe hypoxia. It is also associated with pneumothorax. The clinical picture is more in keeping with an atypical chest infection rather than PCP.

C Clindamycin and primaquine

This is the second-line treatment for PCP. If the patient could not tolerate co-trimoxazole and the diagnosis was PCP then this would be an appropriate choice.

D Liposomal amphotericin

This is the treatment for severe fungal infection or leishmaniasis. Since the patient has a low CD4 count he is at risk of fungal infections, especially invasive aspergillosis, but this is an unlikely diagnosis given the duration of illness and the bilateral signs.

E Metronidazole

It would be the treatment for an intra-abdominal cause of infection rather than respiratory infection. Vericonazole can be used for invasive aspergillosis.

A 27-year-old man is admitted to the Emergency Department with severe shortness of breath, and lethargy such that he is only able to walk a few yards. He admits feeling generally unwell with fevers, weight loss and a dry cough over the past few months. He is a former IV drug abuser who moved to the UK from southern Italy a few years earlier.

Examination reveals blood pressure of 105/80 mmHg, with pulse is 86/min and regular. He looks pale. There is generalised lymphadenopathy and his BMI is 20.

Investigations:

Hb	7.6 g/l (reticulocyte count not elevated)
WCC	4.2×10^9/l
PLT	197×10^9/l
Na^+	137 mmol/l
K^+	4.4 mmol/l
Creatinine	110 µmol/l
ESR	65 mm/1st h
Bone marrow aspirate	Pure red cell aplasia

Which of the following is the most likely diagnosis?

A Autoimmune haemolytic anaemia

B Cytomegalovirus infection

C Myelodysplasia

D Myelofibrosis

pulse is 86/min and regular. He looks pale. There is generalised lymphadenopathy and his BMI is 20.

Investigations:

Hb	7.6 g/l (reticulocyte count not elevated)
WCC	4.2×10^9/l
PLT	197×10^9/l
Na^+	137 mmol/l
K^+	4.4 mmol/l
Creatinine	110 μmol/l
ESR	65 mm/1st h
Bone marrow aspirate	Pure red cell aplasia

Which of the following is the most likely diagnosis?

A Autoimmune haemolytic anaemia

B Cytomegalovirus infection

C Myelodysplasia

D Myelofibrosis

E Parvovirus infection

Submit

The general deterioration over the past few months, coupled with a previous history of intravenous drug abuse, raises the possibility of underlying HIV. Parvovirus B19-related red cell aplasia is associated with HIV infection and accounts for the picture seen here: anaemia without reticulocytosis and red cell aplasia on bone marrow aspiration. B19 DNA can be identified by PCR to confirm the underlying cause. IV immunoglobulin is the intervention of choice.

A Autoimmune haemolytic anaemia

Autoimmune haemolytic anaemia is destruction of red blood cells through an antibody-mediated process. There are multiple causes split into three categories: warm antibody types (e.g. SLE, Evans syndrome, CLL), cold antibody type (viral infection, *Mycoplasma pneumoniae* infection) or drug related. The history may that of anaemia with the suggestion of an underlying cause, and there may also be evidence of increased bilirubin such as gallstones or jaundice. The lack of evidence of raised bilirubin does not exclude autoimmune haemolytic anaemia in this patient, but the evidence of aplasia of red blood cells does, as does the normal reticulocyte count, of which the latter should be raised during haemolysis.

B Cytomegalovirus infection

Cytomegalovirus is a common herpesvirus which can cause gastrointestinal disease, pneumonia, retinitis and encephalitis during immunosuppression. In the immunosuppressed patient complications include haemolytic anaemia via an antibody-mediated process. As with the above explanation, the absence of a raised reticulocyte count and the presence of aplasia make this a less likely diagnosis.

A 21-year-old ma, who immigrated from Peru 2 months ago, comes to the Emergency Department with left-sided hip pain. He fell one week ago and claims that since then he has had difficulty walking, secondary to pain. He has had occasional headaches recently. He tells you that his appetite has been poor for three months and he has lost 4 stones in weight. He is a non-smoker and is currently a student.

On examination, he is cachectic and febrile with a temperature of 37.7 °C. Pulse is 54/min, blood pressure (BP) 130/78 mmHg and you feel an enlarged spleen of 10 cm. His hip is generally tender but there is a full range of movement. He has an unsteady gait and has generalised weakness with normal tone.

Investigations:

Hb	12.8 g/dl
PLT	32×10^9/l
WCC	3.1×10^9/l
Neutrophils	1.4×10^9/l

Chest X-ray of the left spine and left hip AP (anteroposterior) and lateral were all normal.

Given the suspected diagnosis, which of the following investigations would be the gold standard to confirm the underlying pathology?

A	Ultrasound scan (U/S) of the left hip
B	Computerised tomography (CT) of the left hip
C	U/S of the abdomen
D	Bone marrow aspiration and culture

On examination, he is cachectic and febrile with a temperature of 37.7 °C. Pulse is 54/min, blood pressure (BP) 130/78 mmHg and you feel an enlarged spleen of 10 cm. His hip is generally tender but there is a full range of movement. He has an unsteady gait and has generalised weakness with normal tone.

Investigations:

Hb	12.8 g/dl
PLT	32×10^9/l
WCC	3.1×10^9/l
Neutrophils	1.4×10^9/l

Chest X-ray of the left spine and left hip AP (anteroposterior) and lateral were all normal.

Given the suspected diagnosis, which of the following investigations would be the gold standard to confirm the underlying pathology?

A	Ultrasound scan (U/S) of the left hip
B	Computerised tomography (CT) of the left hip
C	U/S of the abdomen
D	Bone marrow aspiration and culture
E	Oesophageo-gastro-duodenoscopy (OGD) and biopsy

Submit

D Bone marrow aspiration and culture

E Oesophageo-gastro-duodenoscopy (OGD) and biopsy

Explanation

D Bone marrow aspiration and culture

This patient has brucellosis. Brucellosis is a chronic granulomatous disease caused by intracellular slow-growing bacteria. Transmission to humans occurs after occupational exposure or through ingestion of contaminated food products, especially unpasteurised milk products. It remains a significant health problem in many developing countries.
This patient has a three-month history of weight loss, bone pain, splenomegaly and paradoxical bradycardia. Bone symptoms occur in 55% of patients with brucellosis, which often presents as pyrexia of unknown origin (PUO). Neutropenia and thrombocytopaenia are relatively common. Bone marrow aspiration and culture is the gold standard for diagnosis. Blood culture is positive in 15–70% of patients, but a high clinical suspicion is required as subculture often takes four weeks; sensitivity is less than that for bone marrow aspiration and culture and, as such, bone marrow tissue culture is preferred.

Treatment guidelines as issued by the World Health Organization (WHO) include doxycycline in combination with streptomycin or rifampicin for 6 weeks. Quinolones have also been tried.

A Ultrasound scan (U/S) of the left hip

If there was a suspicion of septic arthritis with acute fever, isolated joint pain and reduced range of movement, then

11:46

A 21-year-old ma, who immigrated from Peru 2 months ago, comes to the Emergency Department with left-sided hip pain. He fell one week ago and claims that since then he has had difficulty walking, secondary to pain. He has had occasional headaches recently. He tells you that his appetite has been poor for three months and he has lost 4 stones in weight. He is a non-smoker and is currently a student.

On examination, he is cachectic and febrile with a temperature of 37.7 °C. Pulse is 54/min, blood pressure (BP) 130/78 mmHg and you feel an enlarged spleen of 10 cm. His hip is generally tender but there is a full range of movement. He has an unsteady gait and has generalised weakness with normal tone.

Investigations:

Hb	12.8 g/dl
PLT	32×10^9/l
WCC	3.1×10^9/l
Neutrophils	1.4×10^9/l

Chest X-ray of the left spine and left hip AP (anteroposterior) and lateral were all normal.

Given the suspected diagnosis, which of the following investigations would be the gold standard to confirm the underlying pathology?

Your answer was correct

A Ultrasound scan (U/S) of the left hip

A Ultrasound scan (U/S) of the left hip

Difficu

Peer R

Sessio

Responses

Responses

Responses

Responses

11:46

MyPastest
https://mypastest.pastest.com

Pastest+

occupational exposure or through ingestion of contaminated food products, especially unpasteurised milk products. It remains a significant health problem in many developing countries.

This patient has a three-month history of weight loss, bone pain, splenomegaly and paradoxical bradycardia. Bone symptoms occur in 55% of patients with brucellosis, which often presents as pyrexia of unknown origin (PUO). Neutropenia and thrombocytopaenia are relatively common. Bone marrow aspiration and culture is the gold standard for diagnosis. Blood culture is positive in 15–70% of patients, but a high clinical suspicion is required as subculture often takes four weeks; sensitivity is less than that for bone marrow aspiration and culture and, as such, bone marrow tissue culture is preferred.

Treatment guidelines as issued by the World Health Organization (WHO) include doxycycline in combination with streptomycin or rifampicin for 6 weeks. Quinolones have also been tried.

A	Ultrasound scan (U/S) of the left hip

If there was a suspicion of septic arthritis with acute fever, isolated joint pain and reduced range of movement, then joint ultrasound and aspiration would have been diagnostic.

B	Computerised tomography (CT) of the left hip

If an underlying malignancy or abscess was suspected, then this would have been an appropriate investigation. An abscess might have been suggested by a swinging temperature and tenderness, but would not explain many features of the history such as the bradycardia and splenomegaly.

11:53

MyPastest
https://mypastest.pastest.com

Pastest+

A 26-year-old man is admitted to the Emergency Department from the airport, having just returned on a flight from Bangladesh. Around 1 h before landing he collapsed after severe vomiting and diarrhoea on the plane.

His travelling partner reports that he became ill one day before leaving Bangladesh, with high-volume, painless, watery diarrhoea. Blood pressure is 95/60 mmHg and his pulse is 100/min and regular. Dark-field microscopy of a fresh stool specimen reveals Gram-negative bacilli.

Given the likeliest diagnosis, which one of the following antibiotic choices would be most appropriate in the treatment of this patient?

A	Ciprofloxacin
B	Metronidazole
C	Amoxicillin
D	Co-trimoxazole
E	Penicillin V

33195

Submit

Previous Q...

Skip Questi...

11:54
On
625-262-0256
Leave
MyPastest
https://mypastest.pastest.com

A Ciprofloxacin

This patient has cholera, a comma-shaped Gram-negative bacillus. It causes clinical disease by releasing an enterotoxin that affects the small bowel, leading to secretion of huge amounts of fluid and electrolytes into the intestinal lumen. Diagnosis is via dark-ground microscopy of a fresh stool specimen. While rehydration is the primary therapy for cholera, use of antibiotics is proven to shorten the duration and severity of the illness. Antibiotic choices may include quinolones such as ciprofloxacin, tetracyclines, erythromycin and co-trimoxazole, but there are problems with resistance to tetracyclines emerging in patients from the Indian subcontinent in particular. For this reason, ciprofloxacin and erythromycin are the correct answers given here. With appropriate rehydration and antibiotic therapy where required, patients usually show signs of recovery over a few days.

B Metronidazole

Metronidazole would be a good antibiotic choice if anaerobes such as *Gardnerella*, *Entamoeba*, *Giardia* or *Clostridium* were suspected. This might be suspected with bloody diarrhoea or, for *C. difficile*, recent antibiotic use.

C Amoxicillin

Amoxicillin is a good antimicrobial choice for chest infections and can be useful in the treatment of urine and skin infections, but is of limited used in gastrointestinal problems.

D Co-trimoxazole

Audio Video Share Participants More

11:55

A 26-year-old man is admitted to the Emergency Department from the airport, having just returned on a flight from Bangladesh. Around 1 h before landing he collapsed after severe vomiting and diarrhoea on the plane.

His travelling partner reports that he became ill one day before leaving Bangladesh, with high-volume, painless, watery diarrhoea. Blood pressure is 95/60 mmHg and his pulse is 100/min and regular. Dark-field microscopy of a fresh stool specimen reveals Gram-negative bacilli.

Given the likeliest diagnosis, which one of the following antibiotic choices would be most appropriate in the treatment of this patient?

Your answer was correct

A Ciprofloxacin

B Metronidazole

C Amoxicillin

D Co-trimoxazole

E Penicillin V

Explanation

A Ciprofloxacin

Rana Alnasser's screen

A 44-year-old man presented with a 3-month history of rough, white, painless patches on the sides of the tongue. These lesions tended to change in appearance over the course of a few days. He travelled extensively in East Asia for work. He had no other medical conditions.

On examination, he appeared underweight. He had painless cervical and axillary lymphadenopathy, and the lesions on his tongue were as described.

Investigations:

Hb	115 g/l (130–180)
WCC	4.9×10^9/l (4–11)
PLT	167×10^9/l (150–140)

Which of the following is the most likely diagnosis?

A Geographic tongue

B Herpes simplex infection

C Lichen planus

D Oral candidiasis

E Oral hairy leukoplakia

Submit

Explanation

E Oral hairy leukoplakia

The description of rough, white, painless patches on the lateral aspects of the tongue is classic for this condition. The disease is caused by reactivation of Epstein–Barr virus, which occurs in patients who are immunosuppressed. This patient has weight loss and widespread lymphadenopathy, on a background of travel in East Asia: the implication is that he may have undiagnosed HIV. In most cases, the diagnosis of oral hairy leukoplakia is clinical, but EBV can be demonstrated in epithelial cells with immunohistochemical staining. Specific treatment for this condition is not usually required, but he should be encouraged to have HIV testing and be managed with appropriate anti-retroviral therapy.

D Oral candidiasis

You may have correctly surmised that this patient has signs and symptoms consistent with an undiagnosed HIV infection – specifically, widespread lymphadenopathy and weight loss, on a background of travel to East Asia. Oral candidiasis is a common complication of immunosuppression, and is seen in undiagnosed HIV relatively often. However, oral candidiasis causes smooth white patches and soreness of the oral mucosa – it is not painless, and the lesions are not rough. This description is more consistent with oral hairy leukoplakia, a dermatological manifestation of Epstein–Barr virus reactivation, which can happen as a consequence of immunosuppression (as seen in undiagnosed HIV infection).

A Geographic tongue

Geographic tongue is in fact caused by the loss of areas of

11:59

A 21-year-old woman presented with a history of an abrupt onset of high fever, headache, cough and abdominal pain. About 2 days later, she developed a maculopapular rash that began on the extremities and there was associated swelling of the hands and feet. She works as a kindergarten teacher.

She has no past medical history that she is aware of, but is unsure of her vaccination history as her parents divorced when she was young and there may have been missed vaccinations during the divorce proceedings. She denies any IV drug use and does not take any regular tablets. She a tattoo on her right ankle that she had done 3 months ago while on holiday in the USA. Apart from that trip, during which she was camping with friends, she has not had any other journeys outside of the UK.

On examination, there is a rash as described affecting the hands and feet, but no other lesions. Her chest is clear on auscultation and she has no meningisms.

What is the most likely diagnosis?

A	Rocky Mountain spotted fever
B	Atypical measles syndrome
C	Atypical pneumonia
D	Leptospirosis
E	Meningococcal meningitis

Rana Alnasser's screen

12:01

MyPastest
https://mypastest.pastest.com

Pastest+

A 21-year-old woman presented with a history of an abrupt onset of high fever, headache, cough and abdominal pain. About 2 days later, she developed a maculopapular rash that began on the extremities and there was associated swelling of the hands and feet. She works as a kindergarten teacher.

She has no past medical history that she is aware of, but is unsure of her vaccination history as her parents divorced when she was young and there may have been missed vaccinations during the divorce proceedings. She denies any IV drug use and does not take any regular tablets. She a tattoo on her right ankle that she had done 3 months ago while on holiday in the USA. Apart from that trip, during which she was camping with friends, she has not had any other journeys outside of the UK.

On examination, there is a rash as described affecting the hands and feet, but no other lesions. Her chest is clear on auscultation and she has no meningisms.

What is the most likely diagnosis?

Your answer was incorrect

A Rocky Mountain spotted fever

B Atypical measles syndrome

C Atypical pneumonia

D Leptospirosis

E Meningococcal meningitis

Explanation

B Atypical measles syndrome

Atypical measles syndrome (AMS) occurs in persons who were incompletely immunised against measles. This may occur either because they were given the old killed-virus measles vaccine (no longer available) or they were given the attenuated (weakened) live measles vaccine which had been inactivated due to improper storage. The latter does not prevent measles but causes an alteration in its expression, resulting in AMS. The presentation of the patient above is typical of AMS: fever, headache, cough, headache and abdominal pain followed by a rash with oedema of hands and feet 1–2 days afterwards. Key to the diagnosis is also an immunisation history suggestive of incomplete immunity and contact with children, who are more likely to have measles. Virus isolation, serological studies, or both, may be necessary to confirm the diagnosis.

A Rocky Mountain spotted fever

This condition is caused by infection with *Rickettsiae rickettsii*, a tick-borne pathogen endemic to the Rocky Mountains and the south-eastern USA, after an incubation period of days to up to 2 weeks. There is typically headache, high fever and muscle ache with abdominal ache and vomiting. This is followed by a macular rash of the hands and feet 2–5 days later which can then spread and become haemorrhagic. While the clinical description is similar, the fact that the trip was 3 months ago to a possible endemic area makes this diagnosis very unlikely.

C Atypical pneumonia

While she has a cough, fever, and systemic symptoms, her hand and foot oedema, clear chest and abdominal pain

This condition is caused by infection with *Rickettsiae rickettsii*, a tick-borne pathogen endemic to the Rocky Mountains and the south-eastern USA, after an incubation period of days to up to 2 weeks. There is typically headache, high fever and muscle ache with abdominal ache and vomiting. This is followed by a macular rash of the hands and feet 2–5 days later which can then spread and become haemorrhagic. While the clinical description is similar, the fact that the trip was 3 months ago to a possible endemic area makes this diagnosis very unlikely.

C Atypical pneumonia

While she has a cough, fever and systemic symptoms, her hand and foot oedema, clear chest and abdominal pain make this a less likely diagnosis. Rashes with atypical pneumonia can occur, such as erythema multiforme.

D Leptospirosis

Leptospirosis is caused by *Leptospira interrogans* and is spread via rat urine. Contact can occur with activities associated with exposure to water, such as canoeing, cycling through puddles or swimming outdoors. Following an incubation period of 20 days there is fever, myalgia, chest pain and there can be haemoptysis. There is no clear exposure within the range of the incubation period and this would not explain her rash, abdominal pain or oedema.

E Meningococcal meningitis

While the patient does have a headache, fever and rash, it is not in keeping with a description of meningism such as neck stiffness and photophobia and the rash is not petechial or non-blanching. Being in contact with children would increase the risk of meningitis.

A 25-year-old man who has recently returned from a trip to Africa attends the clinic because he is feeling unwell. You understand that he had been swimming in a local river each day, while helping out on a school building project. After swimming, he noticed an itchy rash on his skin. Around a week later, he returned to the UK.

Another 4 weeks passed, and symptoms of a viral illness have now developed including fever, myalgia, headache and lethargy. He is pyrexial 38.5 °C.

Investigations:

Hb	11.9 g/l
WCC	8.0×10^9/l (Increased eosinophil count)
PLT	290×10^9/l
Na^+	139 mmol/l
K^+	4.8 mmol/l
Creatinine	120 µmol/l
ALT	62 U/l
CXR	General increase in vascular and interstitial marking
ESR	46 mm/h

Which of the following is the most appropriate treatment for this condition?

A Quinine sulphate

B Paracetamol

C Praziquantel

D Primaquine

have now developed including fever, myalgia, headache and lethargy. He is pyrexial 38.5 °C.

Investigations:

Hb	11.9 g/l
WCC	8.0×10^9/l (Increased eosinophil count)
PLT	290×10^9/l
Na^+	139 mmol/l
K^+	4.8 mmol/l
Creatinine	120 µmol/l
ALT	62 U/l
CXR	General increase in vascular and interstitial marking
ESR	46 mm/h

Which of the following is the most appropriate treatment for this condition?

A Quinine sulphate

B Paracetamol

C Praziquantel

D Primaquine

E Ciprofloxacin

20544

Submit

12:06

MyPastest
https://mypastest.pastest.com

Pastest+

ESR	46 mm/h

Which of the following is the most appropriate treatment for this condition?

Your answer was correct

A Quinine sulphate

B Paracetamol

C Praziquantel

D Primaquine

E Ciprofloxacin

Explanation

C Praziquantel

This man has Katayama fever, which has developed some 4-6 weeks after infection with Schistosomes. It is usually caused by either schistosoma japonicum or mansonii infection. The high egg and worm antigen load is thought to lead to a serum sickness type syndrome. Management involves treatment with Praziquantel, an anti-heminthic agent which leads to a cure in around 85% of patients. In those who are not cured, the egg load is normally markedly reduced.

A Quinine sulphate

A 34-year-old man presented to clinic with an 18-month history of an intensely pruritic rash. He was diagnosed with HIV infection 6 years ago and is currently not taking antiretroviral therapy or other medications.

On examination there are many excoriated papules and pustules on the chest, back and extensor surfaces of the arms.

Investigations:

CD4+ count	270×10^6/l (430–1690)

Which is the most likely diagnosis?

A Acne rosacea

B Acne vulgaris

C Eosinophilic folliculitis

D Seborrhoeic dermatitis

E Urticaria

Submit

E Urticaria

Explanation

C Eosinophilic folliculitis

This is a relatively common dermatological manifestation of HIV, and this patient has a classic history and signs of the condition. It typically occurs in patients with CD4+ counts less than 300, as seen here, and improves when antiretroviral therapy is started. Other agents that can be used are topical steroids or antihistamines. It can also occur in the absence of HIV infection, and can be associated with malignancy.

A Acne rosacea

Acne rosacea causes predominantly flushing or redness of the face. It can cause papules, but it would be very unusual for acne rosacea to be intensely itchy, and it does not have any particular association with HIV infection. This patient has typical eosinophilic folliculitis, which is associated with HIV infection. As described here, it manifests as intensely itchy papules over the face, trunk and limbs. It typically occurs in patients with CD4+ counts less than 300, as seen here.

B Acne vulgaris

This patient has eosinophilic folliculitis, which can look similar to acne vulgaris; however, acne vulgaris is not intensely itchy and does not have any specific association with HIV. This is a typical description of eosinophilic folliculitis, which typically occurs in patients with a CD4+ count of less than 300, as in this case.

12:10

eosinophilic folliculitis

Eosinophilic Folliculitis: Background ...
emedicine.medscape.com

Eosinophilic Folliculitis: Before and ...
jamanetwork.com

Figure 1 from Eosinophilic pustular ...
semanticscholar.org

How long Does Eosinophilic Folliculitis ...
health.onehowto.com

RELATED SEARCHES

- groin area eosinophilic folliculitis
- eosinophilic folliculitis histology
- arm eosinophilic folliculitis
- leg eosinophilic folliculitis

Folliculitis - Symptoms and causes ...
mayoclinic.org

Eosinophilic pustular dermatosis with ...
labome.org

Discover
Updates
Search

12:10

Health - oneHOWTO

How long Does Eosinophilic Folliculitis last? The Answer

Images may be subject to copyright. Learn more

RELATED IMAGES

Rana Alnasser's screen

Search

any particular association with HIV infection. This patient has typical eosinophilic folliculitis, which is associated with HIV infection. As described here, it manifests as intensely itchy papules over the face, trunk and limbs. It typically occurs in patients with CD4+ counts less than 300, as seen here.

B Acne vulgaris

This patient has eosinophilic folliculitis, which can look similar to acne vulgaris; however, acne vulgaris is not intensely itchy and does not have any specific association with HIV. This is a typical description of eosinophilic folliculitis, which typically occurs in patients with a CD4+ count of less than 300, as in this case.

D Seborrhoeic dermatitis

Seborrhoeic dermatitis can be itchy but is usually not intensely itchy, as seen here. It is flaky and scaly, not papular and pustular as seen here. This patient's history and signs are most consistent with eosinophilic folliculitis, which is associated with HIV infection (especially where the CD4+ count is less than 300).

E Urticaria

Urticaria manifests as wheals and large, raised lesions that are migratory. It does not cause papules and pustules, and although itchy is not intensely itchy as described here. This patient is more likely to have eosinophilic folliculitis, which is associated with HIV infection, particularly in patients with CD4+ counts less than 300, as seen here.

Rate this question:

Next Question

Rana Alnasser's screen

You are asked to see a 71-year-old man who is on the Cardiovascular Surgery Ward, having undergone aortic valve surgery. He had an initial period of intubation and ventilation, and 3 days later, he has begun to deteriorate with signs of a lower respiratory tract infection.

On examination, he is pyrexial (38.8 °C), with a pulse of 90 bpm and regular. He has signs of right-sided consolidation.

Investigations:

Haemoglobin (Hb)	124 g/l
White cell count (WCC)	15.5×10^9/l
Platelets (PLT)	203×10^9/l
Sodium (Na)	137 mmol/l
Potassium (K)	4.6 mmol/l
Creatinine (Cr)	110 µmol/l
Albumin	28 g/l
Alanine transaminase (ALT)	56 u/l
Chest X-ray	Right lower lobe shadowing

Which micro-organism is the most likely cause of this presentation?

A *Streptococcus pneumoniae*

B Meticillin-resistant *Staphylococcus aureus* (MRSA)

C *Leginonella pneumophila*

D *Pseudomonas aeruginosa*

E *Klebsiella*

White cell count (WCC)	15.5×10^9/l
Platelets (PLT)	203×10^9/l
Sodium (Na)	137 mmol/l
Potassium (K)	4.6 mmol/l
Creatinine (Cr)	110 µmol/l
Albumin	28 g/l
Alanine transaminase (ALT)	56 u/l
Chest X-ray	Right lower lobe shadowing

Which micro-organism is the most likely cause of this presentation?

Your answer was correct

A *Streptococcus pneumoniae*

B Meticillin-resistant *Staphylococcus aureus* (MRSA)

C *Leginonella pneumophila*

D *Pseudomonas aeruginosa*

E *Klebsiella*

Explanation

D *Pseudomonas aeruginosa*

The answer is *Pseudomonas aeruginosa* (Option D).

Hospital-acquired pneumonia (HAP) should be considered in patients who develop new pneumonia after 48 hours

Rana Alnasser's screen

D *Pseudomonas aeruginosa*

The answer is *Pseudomonas aeruginosa* (Option D).

Hospital-acquired pneumonia (HAP) should be considered in patients who develop new pneumonia after 48 hours from hospital admission. *P. aeruginosa* is a common and serious pathogen, responsible for many cases of HAP. There is great regional variation to the most common organism responsible, and therefore, antibiotic guidelines vary.

A *Streptococcus pneumoniae*

Streptococcus pneumoniae (Option A) is incorrect.

S. penumoniae is a Gram-positive diplococcus capable of causing community-acquired pneumonia and meningitis. It is one of the most common causes of community-acquired pneumonia. Normally, it is treated with penicillins, such as amoxicillin, but it can have resistance.

B Meticillin-resistant *Staphylococcus aureus* (MRSA)

Meticillin-resistant *Staphylococcus aureus* (MRSA) (Option B) is incorrect.

MRSA is a Gram-positive bacterium associated with pneumonia, osteomyelitis, septic arthritis and endocarditis. It produces a beta-lactamase which breaks down penicillins. It is particularly associated with skin infection and post-operative surgical infections, and is less common as a cause of pneumonia. Pneumonia with *S. aureus* is associated with a recent infection with influenza. Treatment is usually with vancomycin.

C *Leginonella pneumophila*

Leginonella pneumophila (Option C) is incorrect

and post-operative surgical infections, and is less common as a cause of pneumonia. Pneumonia with *S. aureus* is associated with a recent infection with influenza. Treatment is usually with vancomycin.

C	*Leginonella pneumophila*

Leginonella pneumophila (Option C) is incorrect.

L. pneumophila causes legionnaires' disease. It colonises water tanks and causes outbreaks, characterised by flu-like symptoms, followed by a dry cough and dyspnoea. Chest X-ray typically demonstrates bi-basal consolidation. While hospital outbreaks have been observed, this is more commonly seen in people who have stayed in hotels, and the unilateral consolidation makes this less likely.

E	*Klebsiella*

Klebsiella (Option E) is incorrect.

Klebsiella causes pneumonia, particularly in the elderly and in people with alcoholism or diabetes. It is rare. The pneumonia tends to be cavitating and in the upper lobes.

Rate this question:

Next Question

Previous Q... Tag Questi... Feedback End Session

© Pastest 2019

A 24-year-old man attends the Sexually Transmitted Diseases Clinic after a recent trip to visit his grandparents in Barbados. He admits to having had unprotected sex during his 2-week holiday.

On examination, he has an extremely painful, deep ulcer with soft, ragged margins on the coronal sulcus of his penis. He has painful inguinal lymphadenopathy.

Which one of the following treatments would be the most appropriate choice in this case?

A	Metronidazole
B	Azithromycin
C	Valiciclovir
D	Aciclovir
E	Oxytetracycline

33180

Submit

Previous Q... Skip Questi...

© Pastest 2019

C Valiciclovir

D Aciclovir

E Oxytetracycline

Explanation

B Azithromycin

This clinical picture is suggestive of chancroid infection, caused by *Haemophilus ducreyi*. Chancroid is endemic in parts of the Caribbean basin, Africa and south-west Asia and is commoner in non-white, uncircumcised populations. Patients may present with single or multiple genital ulcers, and painful lymphadenopathy occurs in 30–60% of patients. Gram-staining of ulcer exudates may demonstrate a 'school of fish' collection of short, thick Gram-negative rods. Definitive diagnosis is based on culture using enriched chocolate agar. Patients should be screened for other sexually transmitted diseases to rule out co-infection with other organisms. Suitable antibiotic treatments for *H. ducreyi* include macrolides and quinolones.

A Metronidazole

Metronidazole could have been used for a painful oral ulcer associated with gingivitis or with bacterial vaginosis. It can also be used for some protozoal infections, but this patient is unlikely to have any of the above.

C Valiciclovir

This is an antiviral option for herpes simplex infection. Herpes causes painful genital ulcers following sexual

C Valiciclovir

This is an antiviral option for herpes simplex infection. Herpes causes painful genital ulcers following sexual transmission, but the ragged margin and inguinal lymphadenopathy make chancroid a more likely diagnosis.

D Aciclovir

This is another antiviral treatment option for herpes simplex and, as described above, this is not the most likely diagnosis.

E Oxytetracycline

This is a broad-spectrum antibiotic that can be used for treatment for *Chlamydia*. The presentation of genital ulceration makes *Chlamydia* an unlikely cause, and therefore oxytetracycline an inappropriate treatment. *Chlamydia* normally presents in men with dysuria or discharge.

Rate this question:

Next Question

Previous Q... Tag Questi... Feedback End Session

Blog About Pastest Contact Us Help

© Pastest 2019

12:17

MyPastest
https://mypastest.pastest.com

E Oxytetracycline

Explanation

B Azithromycin

This clinical picture is suggestive of chancroid infection, caused by *Haemophilus ducreyi*. Chancroid is endemic in parts of the Caribbean basin, Africa and south-west Asia and is commoner in non-white, uncircumcised populations. Patients may present with single or multiple genital ulcers, and painful lymphadenopathy occurs in 30–60% of patients. Gram-staining of ulcer exudates may demonstrate a 'school of fish' collection of short, thick Gram-negative rods. Definitive diagnosis is based on culture using enriched chocolate agar. Patients should be screened for other sexually transmitted diseases to rule out co-infection with other organisms. Suitable antibiotic treatments for *H. ducreyi* include macrolides and quinolones.

A Metronidazole

Metronidazole could have been used for a painful oral ulcer associated with gingivitis or with bacterial vaginosis. It can also be used for some protozoal infections, but this patient is unlikely to have any of the above.

C Valiciclovir

This is an antiviral option for herpes simplex infection. Herpes causes painful genital ulcers following sexual transmission, but the ragged margin and inguinal lymphadenopathy make chancroid a more likely diagnosis.

Rana Alnasser's screen

a "school of fish" collection of short, thick Gram-negative rods. Definitive diagnosis is based on culture using enriched chocolate agar. Patients should be screened for other sexually transmitted diseases to rule out co-infection with other organisms. Suitable antibiotic treatments for *H. ducreyi* include macrolides and quinolones.

A Metronidazole

Metronidazole could have been used for a painful oral ulcer associated with gingivitis or with bacterial vaginosis. It can also be used for some protozoal infections, but this patient is unlikely to have any of the above.

C Valiciclovir

This is an antiviral option for herpes simplex infection. Herpes causes painful genital ulcers following sexual transmission, but the ragged margin and inguinal lymphadenopathy make chancroid a more likely diagnosis.

D Aciclovir

This is another antiviral treatment option for herpes simplex and, as described above, this is not the most likely diagnosis.

E Oxytetracycline

This is a broad-spectrum antibiotic that can be used for treatment for *Chlamydia*. The presentation of genital ulceration makes *Chlamydia* an unlikely cause, and therefore oxytetracycline an inappropriate treatment. *Chlamydia* normally presents in men with dysuria or discharge.

Rate this question:

Rana Alnasser's screen

12:17

A 24-year-old man is referred to the Respiratory Clinic for review. He has begun HAART for the treatment of HIV a few months earlier and has recently returned from a holiday to Pakistan.

Whilse there, he visited his uncle who has just been diagnosed with tuberculosis. He has a normal chest X-ray and a positve quantiferon gamma test. He did not receive the BCG vaccination as a child.

Which of the following is the most appropriate next step?

A	Four-drug anti-TB therapy for 6 months
B	Four-drug anti-TB therapy for 12 months
C	BCG vaccination
D	Isoniazid / Rifampicin for 3 months
E	Observe

37187

Submit

Previous Q... Skip Questi...

Rana Alnasser's screen

12:19

A 24-year-old man is referred to the Respiratory Clinic for review. He has begun HAART for the treatment of HIV a few months earlier and has recently returned from a holiday to Pakistan.

Whilse there, he visited his uncle who has just been diagnosed with tuberculosis. He has a normal chest X-ray and a positve quantiferon gamma test. He did not receive the BCG vaccination as a child.

Which of the following is the most appropriate next step?

Your answer was correct

A	Four-drug anti-TB therapy for 6 months
B	Four-drug anti-TB therapy for 12 months
C	BCG vaccination
D	Isoniazid / Rifampicin for 3 months
E	Observe

Explanation

D	Isoniazid / Rifampicin for 3 months

With no symptoms of TB, a normal CXR and a positive quantiferon test, this patient fits the criteria for diagnosis of latent TB. As such, the BHIVA guidelines recommend either 6 months' treatment with Isoniazid or 3 months' combination therapy. For non-CNS TB, BHIVA guidelines recommend treatment with 4 drugs for 2 months, then 2

Rana Alnasser's screen

12:19

D Isoniazid / Rifampicin for 3 months

E Observe

Explanation

D Isoniazid / Rifampicin for 3 months

With no symptoms of TB, a normal CXR and a positive quantiferon test, this patient fits the criteria for diagnosis of latent TB. As such, the BHIVA guidelines recommend either 6 months' treatment with Isoniazid or 3 months' combination therapy. For non-CNS TB, BHIVA guidelines recommend treatment with 4 drugs for 2 months, then 2 drugs for a further 4 months. Where there is CNS TB, a 9-month treatment period is recommended.

A Four-drug anti-TB therapy for 6 months

This duration is for drugs in total. Four drugs are needed for two months, and then a further four months of two drugs.

B Four-drug anti-TB therapy for 12 months

Again, this duration is not usually needed for four-drug TB therapy.

C BCG vaccination

BCG is a live vaccination and, as such, it may be potentially harmful in this situation and is therefore not recommended.

E Observe

Rana Alnasser's screen

This duration is for drugs in total. Four drugs are needed for two months, and then a further four months of two drugs.

B	Four-drug anti-TB therapy for 12 months

Again, this duration is not usually needed for four-drug TB therapy.

C	BCG vaccination

BCG is a live vaccination and, as such, it may be potentially harmful in this situation and is therefore not recommended.

E	Observe

The positive quantiferon test means that latent TB is likely to be present, despite the absence of clinical evidence and X-ray findings. Patients with HIV have a much greater risk of progression to active TB from the latent state; for this reason, observation only is not appropriate.

Rate this question:

© Pastest 2019

Rana Alnasser's screen

12:19

A 37-year-old Ghanaian woman was referred with fatigue. She has been followed for the past year with bizarre behaviour and psychotic symptoms and is treated with amisulpiride. She was diagnosed five years ago with HIV-1 infection but was lost to follow-up.

The physical examination was unremarkable. CD4 count was 16×10^6/l and HIV viral load > 500 000 copies/ml. Treatment with antiretroviral medications was commenced and the patient was discharged.

One month later the patient presents to you with confusion. She is afebrile on admission. She is disorientated in time and place but not in person.

On this occasion, the CD4 count is 414×10^6/l and HIV viral load 503 copies/ml.

Investigations:

Hb	10 g/dl
WCC	4.5×10^9/l
Neutrophils	72%
Lymphocytes	18%
PLT	435×10^9/l
C-reactive protein (CRP)	8 mg/l

Computerised tomography (CT) of the brain reveals multiple low-density lesions in the left hemisphere

Cerebrospinal fluid (CSF) WCC count	120/ml (<5)
CSF glucose	3.4 mmol/l (3.3–4.4)
CSF protein	0.56 g/l (0.15–0.45)
CSF culture	No growth in 48 h

Rana Alnasser's screen

Cerebrospinal fluid (CSF) WCC count	120/ml (<5)
CSF glucose	3.4 mmol/l (3.3–4.4)
CSF protein	0.56 g/l (0.15–0.45)
CSF culture	No growth in 48 h
CSF cryptococcal antigen	Negative
CSF toxoplasmosis PCR	Negative
India ink stain	Negative

Four days later, in hospital, she develops right-sided weakness.

Magnetic resonance of the brain with contrast diffusely enhances the lesions.

Which one of the following diagnoses is most likely?

A Toxoplasmosis

B Progressive multifocal leukoencephalopathy

C Cryptococcal meningitis

D Cytomegalovirus encephalitis

E Tuberculous meningitis

33196

Submit

Rana Alnasser's screen

C Cryptococcal meningitis

D Cytomegalovirus encephalitis

E Tuberculous meningitis

Explanation

B Progressive multifocal leukoencephalopathy

The history and investigations are consistent with cerebral lymphoma or progressive multifocal leukoencephalopathy (PML). PML is characterised by hemiparesis, disturbances of speech and vision and progressive dementia. The lesions in the brain comprise multiple areas of demyelination, abnormal oligodendrocytes and later pronounced astrocytosis. Lesions may enhance with gadolinium contrast. However, they do not usually have the characteristic ring-enhancing appearance seen in the cerebral lesions of toxoplasmosis. PML is associated with the 'JC' virus named after the patient in whom the polyoma virus was first isolated.

A Toxoplasmosis

Typically, presentation can occur with neurological signs developing over days to weeks and then can cause seizures. In addition, raised intracranial pressure can cause headaches and vomiting. Some present with diffuse encephalitis causing confusion, seizures and reduced consciousness. Normally toxoplasmosis would show ring-enhancing lesions on a CT scan. Also, the negative PCR makes this unlikely.

C Cryptococcal meningitis

Crytococcal infection is a common cause of meningitis and

Typically, presentation can occur with neurological signs developing over days to weeks and then can cause seizures. In addition, raised intracranial pressure can cause headaches and vomiting. Some present with diffuse encephalitis causing confusion, seizures and reduced consciousness. Normally toxoplasmosis would show ring-enhancing lesions on a CT scan. Also, the negative PCR makes this unlikely.

C Cryptococcal meningitis

Crytococcal infection is a common cause of meningitis and meningo-encephalitis in HIV-infected patients. It can present with headache, confusion, altered mental status, seizures and can have focal neurological signs present. The absence of antigens makes this less likely.

D Cytomegalovirus encephalitis

CMV establishes latent infection which reactivates as immunosuppression in HIV progresses. CMV can affect the central nervous system, retina, GI tract, lungs and biliary tract. In CNS infection there is usually progressive disorientation, withdrawal and apathy. On examination cranial nerve palsies and nystagmus are typical signs. Typically ring-enhancing lesions are seen on CT, but MRI is the best mode of imaging and diagnosis is confirmed on CSF PCR and treatment is with ganciclovir. The imaging findings in this patient makes CMV an unlikely but ideally should be excluded on PCR.

E Tuberculous meningitis

With this condition there would likely be meningeal enhancement on imaging studies, detectable AFB in the CSF and low glucose in the CSF as well.

A 31-year-old man visits the doctor some 4-5 weeks after returning from a photography trip to mainland China. He admits to having swum in local water on particularly hot days. He has a history of fever, lethargy, myalgia, lack of appetite with vague abdominal pain.

On examination, you find evidence of an urticarial rash and he has a temperature of 38.1 °C. There is generalised lymphadenopathy and evidence of hepatosplenomegaly.

Bloods:

Hb	11.8 g/dl
WCC	7.2×10^9/l (marked eosinophilia)
PLT	195×10^9/l
Na^+	139 mmol/l
K^+	4.9 mmol/l
Creatinine	130 µmol/l
ALT	135 U/l
Chest X-ray	Generalised increase in vascular / interstitial markings, lymphadenopathy

Which of the following represents the most likely diagnosis?

A Weil's disease

B Dengue fever

C Katayama fever

D Typhoid fever

E Visceral leishmaniasis

On examination, you find evidence of an urticarial rash and he has a temperature of 38.1 °C. There is generalised lymphadenopathy and evidence of hepatosplenomegaly.

Bloods:

Hb	11.8 g/dl
WCC	7.2 × 10^9/l (marked eosinophilia)
PLT	195 ×10^9/l
Na^+	139 mmol/l
K^+	4.9 mmol/l
Creatinine	130 µmol/l
ALT	135 U/l
Chest X-ray	Generalised increase in vascular / interstitial markings, lymphadenopathy

Which of the following represents the most likely diagnosis?

Your answer was correct

A Weil's disease

B Dengue fever

C Katayama fever

D Typhoid fever

E Visceral leishmaniasis

Explanation

12:28

MyPastest
https://mypastest.pastest.com

Pastes+

Explanation

C Katayama fever

Katayama fever occurs some 4-6 weeks after infection and is thought to coincide with initial egg release. High worm and egg stimuli are thought to lead to immune complex formation and a serum sickness type illness. Schistosomiasis may be diagnosed via a stool sample although it is not particularly sensitive, serology may be more useful but does not differentiate between acute and previous illness. Standard therapy for shistosomiasis is with praziquantel. Adjunctive corticosteroids are controversial, with some commentators recommending use in severe disease, although randomised controlled trial evidence is not easily accessible.

A Weil's disease

Weil's disease is a severe form of leptospirosis. The organism are spirochaetes which are spread from rat urine into aquatic areas and then contact with abraded skin or mucosa leads to infection. Water activities, such as swimming outdoors as this patient has, can cause exposure. Following an incubation of one to three weeks, there is an abrupt onset of fever, headache, myalgia, dry cough and lethargy. This phase may resolve without treatment but can lead to an immune phase with jaundice, abdominal pain, diarrhoea, rash, meningitis and organ failure. It is unlikely to explain the hepatosplenomegaly and severe lymphoadenopathy. Weil's disease is also primarily associated with hepatic dysfunction and acute renal impairment not seen here.

12:28

MyPastest
https://mypastest.pastest.com

Pastest+

In the early stages there is a lymphocytosis, with later lymphopenia, thrombocytopenia and bleeding. Treatment is supportive.

D Typhoid fever

Typhoid fever is caused by *Salmonella* subspecies following typically 10-20 days. It causes a high fever, dry cough, malaise, abdominal pain following by green diarrhoea and hepatosplenomegaly and in the final stages can causes complications in multiple organs. There can be associated bradycardia as well. Diagnosis is by culture and treatment is usually with azithromycin but if severe then IV ceftriaxone. Typhoid fever is associated with neurological features including headache and confusion, accompanied by vague abdominal symptoms including constipation. The absence of diarrhoea and the presentation over the incubation period makes this a less likely diagnosis.

E Visceral leishmaniasis

Leishmaniasis is endemic to east Africa and India and more commonly presents in a cutaneous form, but visceral leismaniasis is an important cause of hepatosplenomegaly as untreated it is often fatal. Visceral leishmaniasis is a potential alternative diagnosis but the respiratory features seen here would be unusual.

Rate this question:

Next Question

Previous Q... Tag Queti... Feedback End Se

disease, although randomised controlled trial evidence is not easily accessible.

A Weil's disease

Weil's disease is a severe form of leptospirosis. The organism are spirochaetes which are spread from rat urine into aquatic areas and then contact with abraded skin or mucosa leads to infection. Water activities, such as swimming outdoors as this patient has, can cause exposure. Following an incubation of one to three weeks, there is an abrupt onset of fever, headache, myalgia, dry cough and lethargy. This phase may resolve without treatment but can lead to an immune phase with jaundice, abdominal pain, diarrhoea, rash, meningitis and organ failure. It is unlikely to explain the hepatosplenomegaly and severe lymphoadenopathy. Weil's disease is also primarily associated with hepatic dysfunction and acute renal impairment not seen here.

B Dengue fever

Dengue fever is endemic in tropical South-East Asia, and outbreaks have also occurred in the tropical regions of Australia. The illness is a haemorrhagic fever, carried by the Aedes mosquito and is caused by the Dengue virus. It is characterised by fever, severe headache and facial flushing. In the early stages there is a lymphocytosis, with later lymphopenia, thrombocytopenia and bleeding. Treatment is supportive.

D Typhoid fever

Typhoid fever is caused by *Salmonella* subspecies fo
typically 10-20 days. It causes a high fever, dry coug
malaise, abdominal pain following by green diarrhoe

12:29

A 32-year-old man who suffered a motorbike accident 4 years ago is admitted from the airport after a trip to Asia. He is in shock on admission to the Emergency Department, you understand from the paramedics that he appears to have been travelling alone. They found a stock of penicillin V tablets in his bag, which imply that he has kept up with post-splenectomy antibiotic prophylaxis. He also has documentation to suggest he is up-to-date with his vaccinations. He has no history of foreign travel prior to this trip.

On examination, he is hypotensive at 85/50 mmHg, pulse 110 bpm, with areas of bruising and petechial haemorrhage. He is pyrexial at 38.8 °C.

Investigations:

Hb	9.5 g/dl, Howell Jolly bodies seen on smear
WCC	12.5×10^9/l
PLT	40×10^9/l
Haptoglobins	Decreased
Na^+	136 mmol/l
K^+	4.4 mmol/l
Creatinine	180 µmol/l
Glucose	4.8 mmol/l
Alanine aminotransferase (ALT)	35 U/l
Urine specimen	haematuria +++

Which of the following is the most likely diagnosis?

A. Falciparum malaria

Rana Alnasser's screen

12:31
On 625-262-0256 Leave

Investigations:

Hb	9.5 g/dl, Howell Jolly bodies seen on smear
WCC	12.5×10^9/l
PLT	40×10^9/l
Haptoglobins	Decreased
Na^+	136 mmol/l
K^+	4.4 mmol/l
Creatinine	180 µmol/l
Glucose	4.8 mmol/l
Alanine aminotransferase (ALT)	35 U/l
Urine specimen	haematuria +++

Which of the following is the most likely diagnosis?

A Falciparum malaria

B Meningococcus

C Pneumococcus

D *Haemophilus influenzae*

E Dengue Fever

Audio Video Share Participants More

A Falciparum malaria

The history of the RTA and presence of Howell–Jolly bodies on the blood smear implies that this patient has undergone a splenectomy. Pyrexia, haemolysis, raised white count and low platelets are suggestive of the possibility of malaria. It is as yet unclear exactly the role that the spleen plays in malaria parasite clearance, but case series suggest that splenectomy may be associated with reduced parasite clearance despite optimal antimalarial therapy.

B Meningococcus

Sepsis caused by meningococcus may present in a similar fashion to that described. However the history of travel makes an alternative diagnosis more likely. In addition, good compliance with penicillin prophylaxis is likely to reduce the risk of meningococcal sepsis (even now the majority of *Neisseria meningitidis* bacteria remain penicillin sensitive) and furthermore this patient is likely to have been vaccinated against the main meningococcus strains.

C Pneumococcus

Patients without a spleen are at increased risk of pneumococcal sepsis. However the travel history as well as thrombocytopenia and evidence of haemolysis in the full blood count point to an alternative diagnosis. In addition our patient is likely to have received the pneumococcal vaccine.

D *Haemophilus influenzae*

Patients without a spleen are at increased risk of *H. influenzae* infection. However the travel history as well as thrombocytopenia and evidence of haemolysis in the full blood count point to an alternative diagnosis.

12:32
On 625-262-0256 Leave

pneumococcal sepsis. However the travel history as well as thrombocytopenia and evidence of haemolysis in the full blood count point to an alternative diagnosis. In addition our patient is likely to have received the pneumococcal vaccine.

D	*Haemophilus influenzae*

Patients without a spleen are at increased risk of *H. influenzae* infection. However the travel history as well as thrombocytopenia and evidence of haemolysis in the full blood count point to an alternative diagnosis.

E	Dengue Fever

Dengue fever is infection caused by the dengue arbovirus. Presentation is with a febrile illness, commonly associated with a rash and frontal headache. DIC resulting in haemorrhage may also be present, particularly in the case of re-finfection with an alternative serotype. In this case the normal ALT as well as the severity of illness (in the absence of prior dengue exposure) point to an alternative diagnosis.

Rate this question:

© Pastest 2019

Audio Video Share Participants More

12:32
On
625-262-0256
Leave

A 30-year-old Ugandan woman presented to the genito-urinary medicine (GUM) clinic for a sexual health screen on her GP's advice. She has been with the same partner for 8 years and has not had other sexual partners in that time frame. Before coming to the UK 10 years ago, she had previously been a sex worker in Africa. She is asymptomatic and consents to tests for chlamydia, gonorrhoea, HIV and syphilis.

Her syphilis serology is as follows:

- TPHA +ve
- RPR –ve.

She has never heard of syphilis and does not think she has been tested before. She does not recall ever having had symptoms of genital ulceration or rash.

Which one of the following statements is most correct regarding this patient?

A	She does not require any treatment for syphilis
B	This is early latent syphilis
C	This is late latent syphilis
D	This is neurosyphilis
E	She needs an urgent lumbar puncture

Audio
Video
Share
Participants
More

previously been a sex worker in Africa. She is asymptomatic and consents to tests for chlamydia, gonorrhoea, HIV and syphilis.

Her syphilis serology is as follows:

- TPHA +ve
- RPR –ve.

She has never heard of syphilis and does not think she has been tested before. She does not recall ever having had symptoms of genital ulceration or rash.

Which one of the following statements is most correct regarding this patient?

Your answer was incorrect

A	She does not require any treatment for syphilis
B	This is early latent syphilis
C	This is late latent syphilis
D	This is neurosyphilis
E	She needs an urgent lumbar puncture

Explanation

C	This is late latent syphilis

Syphilis is caused by *Treponema pallidum*, a spirochete, which spreads as a sexually transmitted infection to form a hard ulcer, termed chancre in primary syphilis. In a time from six weeks to six months secondary syphilis can occur.

Syphilis is caused by *Treponema pallidum*, a spirochete, which spreads as a sexually transmitted infection to form a hard ulcer, termed chancre in primary syphilis. In a time from six weeks to six months secondary syphilis can occur. This can cause malaise, fever, tonsillitis and a rash with flat papules as well as other complications. Tertiary syphilis, or latent syphilis, occurs two years following infection with granuloma formation. *T. pallidum* heamagglutination assay (TPHA), is a *Treponema*-specific test which stays positive following infection permanently, while rapid plasma regain (RPR) is a cardiolipin antibody test which, whilst non-specific, becomes negative following successful treatment.

Late latent syphilis is no longer infectious, and the diagnosis is supported by the fact that RPR has become negative although TPHA is positive.

A She does not require any treatment for syphilis

As she has never been treated for syphilis, she needs to be treated now and the treatment of choice is three doses of IM benzathine penicillin.

B This is early latent syphilis

Early latent syphilis can only be diagnosed if there had been a definitive negative result within the last two years.

D This is neurosyphilis

Neurosyphilis is associated with both positive RPR and positive TPHA. Neurosyphilis can cause cranial nerve palsy, dementia, psychosis, ataxia and tabes dorsalis.

E She needs an urgent lumbar puncture

The absence of any features of neurosyphilis makes this unnecessary, and a negative RPR also excludes

12:36
On
625-262-0256
Leave

The absence of any features of neurosyphilis makes this unnecessary, and a negative RPR also excludes neurosyphilis.

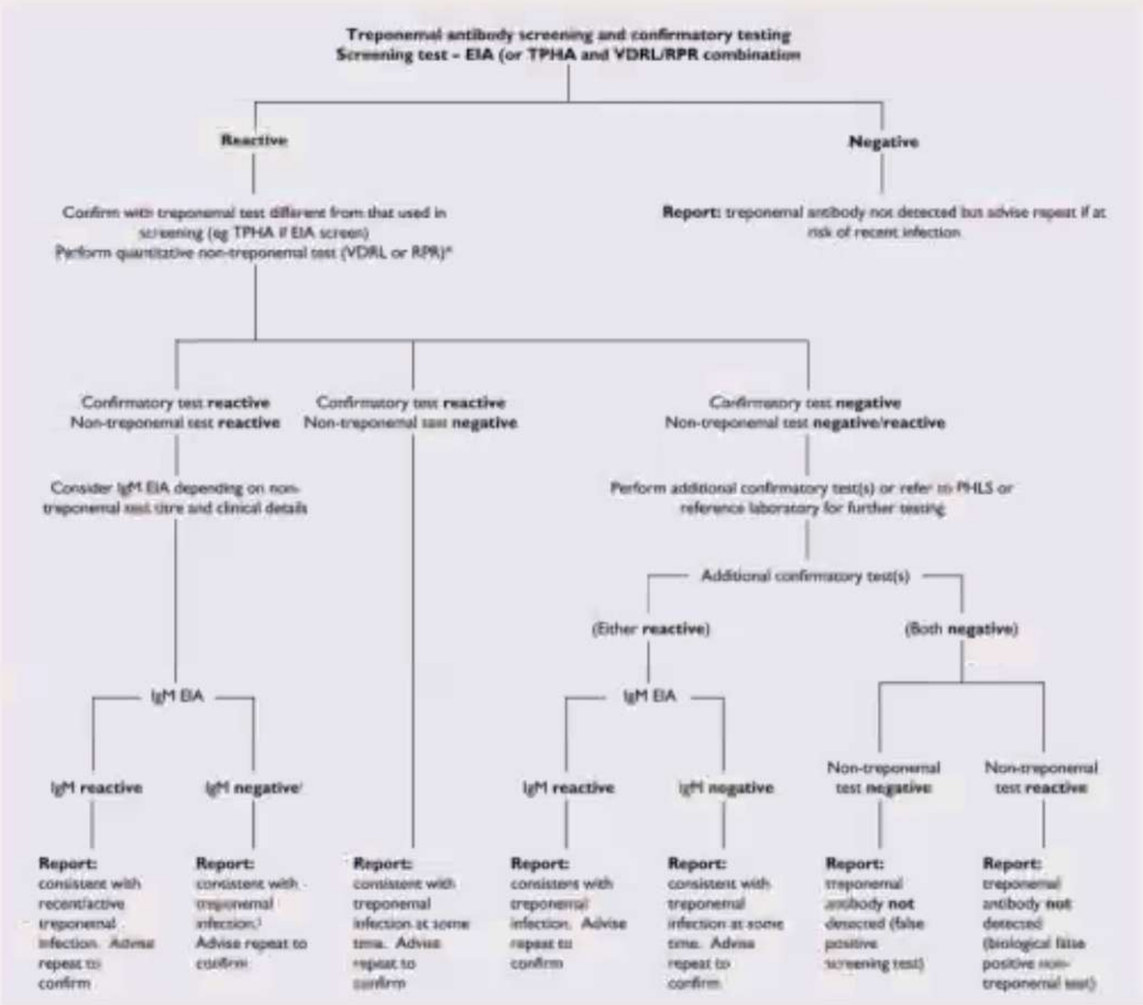

Rate this question:

Next Question

Previous Q... Tag Questi... Feedback End Session

Blog About Pastest Contact Us Help
© Pastest 2019
Audio Video Share Participants More

12:37
On
625-262-0256
Leave

A 32-year-old man presented with a 2-day history of facial weakness. He also reported a 1-month history of joint pain and stiffness, particularly affecting his elbows and knees. Three months previously, he had had a flu-like illness with a red rash, fever and malaise. In the preceding 6 months he had travelled to Kenya and Massachusetts, USA for cross-country running competitions.

On examination, he was afebrile, and there were no skin rashes. He had bilateral lower motor neurone facial nerve palsies. There was no evidence of active synovitis in his joints though his elbows appeared stiff and painful.

What is the most likely diagnosis?

A	Cerebral toxoplasmosis
B	Leprosy
C	Lyme disease
D	Reiter syndrome
E	Secondary syphilis

33162

Submit

Audio
Video
Share
Participants
More

E Secondary syphilis

Explanation

C Lyme disease

Lyme disease is caused by the bacterium *Borrelia burgdorferi*, transmitted through tick bites. This patient has travelled to Massachusetts, an area known to harbour Lyme disease, and has been running in the countryside and therefore could have been bitten by a tick. The description of a rash consistent with erythema migrans, malaise and joint pain is classical. Weeks or months later the arthritis and neurological complications develop. Diagnosis is via serology for antibodies to *B. burgdorferi*. Treatment should be with 2-3 weeks of oral doxycycline.

A Cerebral toxoplasmosis

There is no suggestion that this patient is immunocompromised, and therefore cerebral toxoplasmosis is extremely unlikely. Furthermore, cerebral toxoplasmosis would not explain his history of rash, malaise and joint pain. This presentation is more typical of Lyme disease, to which the patient was presumably exposed whilst in the countryside of Massachusetts, via a tick bite. This would explain the rash (erythema migrans), general malaise, joint pains and bilateral facial palsies.

B Leprosy

It would be very unusual for leprosy to cause facial nerve palsies without any sensory involvement, which is not reported in this case. Given the patient's travel history and history of a rash, myalgia, malaise and joint pain, a diagnosis of Lyme disease is more likely. He is likely to have contracted this after a tick bite whilst running in

Rana Alnasser's screen

Although this patient has arthritis and flu-like symptoms, he does not have urethritis or conjunctivitis/uveitis. Reiter syndrome would also not explain the rash, or his bilateral facial palsies. Bilateral lower motor neurone facial palsies are extremely uncommon. This patient's constellation of symptoms and signs would be better explained by Lyme disease, caused by a tick bite. He may have contracted it whilst running in Massachusetts. The rash would be erythema migrans, and Lyme disease would explain his malaise, arthritis and bilateral facial palsies.

E	Secondary syphilis

Although syphilis can cause a rash and cranial nerve palsies, it would be extremely uncommon for it to cause bilateral facial palsies. It would also not explain the arthritis experienced by this patient. A much better explanation would be Lyme disease, contracted from a tick bite whilst running in Massachusetts. The rash could have been erythema migrans, and Lyme would also explain the myalgia, fever, malaise and arthritis. It is a known cause of bilateral facial palsies.

Rate this question:

© Pastest 2019

A 27-year-old woman is brought to the Emergency Department with severe headache, photophobia and neck stiffness. Her brother tells you that she has been having fevers, tiredness, a sore throat and lower body muscle ache for a week, but in the last three days has felt better. She has a regular boyfriend and only drinks at the weekends. He tells you that two weeks ago they were out clubbing and she was so drunk she fell in the city river when two of her friends had to jump in and get her out. She was seen in hospital after this and was given the all-clear.

On examination, she exhibits meningism and photophobia. She is jaundiced and is pyrexial with a temperature of 38.7 °C. She has no rash but has bilateral subconjunctival haemorrhage and has pharyngeal injection and enlarged tonsillar lymph nodes. Her heart rate is 120/min, blood pressure 90/62 mmHg. She has hepatosplenomegaly on abdominal examination. Computerised tomography (CT) of the head is normal.

Cerebrospinal fluid (CSF) results are as follows:

WCC	42/µl (<5) (PMN leucocytes 36)
Protein	0.54 g/l (0.15–0.45)
Glucose	3.8mml/l (3.3–4.4)

Blood results:

Urea	16.3 mmol/l
Creatinine	215 µmol/l
ALT	198 U/l
ALP	168 U/l
Bilirubin	98 µmol/l
Glucose	5.6 mmol/l
WCC	20.3×10^9/l

WCC	42/µl (<5) (PMN leucocytes 36)
Protein	0.54 g/l (0.15–0.45)
Glucose	3.8mml/l (3.3–4.4)

Blood results:

Urea	16.3 mmol/l
Creatinine	215 µmol/l
ALT	198 U/l
ALP	168 U/l
Bilirubin	98 µmol/l
Glucose	5.6 mmol/l
WCC	20.3×10^9/l

Urine dipstick shows protein 3+, blood 3+.

What is the most likely diagnosis?

A	Meningococcal septicaemia
B	Mollaret's meningitis
C	Streptococcal meningitis
D	Leptospirosis
E	Meliodosis

7232

Submit

Rana Alnasser's screen

D Leptospirosis

E Meliodosis

Explanation

D Leptospirosis

Leptospirosis is caused by pathogenic spiral bacteria belonging to the genus *Leptospira*. The disease is more prevalent in tropical climates and those with a heavy rainfall. In the developed world it has become associated with recreational watersports and those exposed to raw sewage.

The disease incubates for 7–12 days and many patients never present with clinical features. The first phase is known as the septicaemic or leptospiraemic phase, as the bacteria can be cultured in the blood and cerebrospinal fluid (CSF). In this phase, patients often have flu-like symptoms. The patient usually then feels better for three days before developing the immune or leptospiruric stage because circulating antibodies may be detected or the organism may be isolated from urine. However, it may not be cultured from blood or CSF. In this phase, patients often present with aseptic meningitis, haemorrhagic shock or kidney disease.

Treatment includes supportive management. Doxycycline and penicillin are both reasonable choices for antimicrobial therapy.

A Meningococcal septicaemia

Meningococcal septicaemia is an infection caused by the Gram-negative coccus *Neisseria meningitides*. Patients present with sepsis and typically a non-blanching petechial rash. Meningitis can occur, but typical CSF findings would be of a much higher white cell count (>100/microlitre) with

B Mollaret's meningitis

This is a recurrent benign meningitis, most commonly associated with HSV-2. Patients present with recurrent episodes of meningism lasting several days which are then self-resolving. CSF analysis shows a lymphocytic CSF as seen in the question, but the rest of the clinical history is not consistent.

C Streptococcal meningitis

This is meningitis caused by the Gram-positive bacterium *Streptococcus pneumoniae*, a commensal of the human oropharynx. Presentation is usually with a rapid-onset meningism and sepsis. Typical CSF findings would be of a much higher white cell count (>100/μl) with neutrophil predominance, and a reduced glucose (<0.5 × serum level).

E Meliodosis

Meliodosis is an infection caused by the Gram-negative bacterium *Burkholderia pseudomallei*. Most patients have subclinical disease, but infection can present with pneumonia, skin abscess formation and sepsis. While sporadic cases have been reported worldwide, the disease is endemic to South and South East Asia.

7232

Rate this question:

Next Question

Previous Q... Tag Questi... Feedback End Session

A 70-year-old man presented with a 10-day history of severe, watery diarrhoea. He was originally from Namibia, but had not left the UK for 45 years. He had had a similar episode of diarrhoea 15 years ago, but was otherwise well. He admits to losing around 10 kg in weight over the past year.

On examination, he was afebrile, and he appeared thin. There was non-specific abdominal tenderness. The remainder of the physical examination was unremarkable.

Investigations:

Hb	13.2 g/dl (13.0–18.0)
WCC	8.9×10^9/l (4.0–11.0)
PLT	192×10^9/l (150–400)
Na^+	139 mmol/l (137–144)
K^+	3.8 mmol/l (3.5–4.9)
Creatinine	159 µmol/l (60–110)
Eosinophils	0.7×10^9/l (0.04–0.4)

Which of the following is the most likely cause for his symptoms?

A *Campylobacter jejuni*

B *Cryptosporidium* spp.

C *Escherichia coli*

D *Strongyloides stercoralis*

E *Vibrio parahaemolyticus*

Your answer was incorrect

A *Campylobacter jejuni*

B *Cryptosporidium* spp.

C *Escherichia coli*

D *Strongyloides stercoralis*

E *Vibrio parahaemolyticus*

Explanation

D *Strongyloides stercoralis*

This patient's presentation with non-bloody, watery diarrhoea and no significant systemic upset would be typical, especially when combined with a chronic disease course (suggested by the previous episode of diarrhoea and the weight loss) and a mild eosinophilia. Strongyloidiosis is endemic to Namibia and chronic infection can last for many years with only the mildest of symptoms. It can be diagnosed through microscopic examination of the stool for larvae. Despite only minor symptoms, all strongyloidiosis should be treated in order to avoid a hyper-infection syndrome: treatment is with ivermectin for two days.

B *Cryptosporidium* spp.

Cryptosporidium spp. are parasites causing diarrhoea that typically affect young children and the immunocompromised. Typically the diarrhoea is green,

Explanation

D *Strongyloides stercoralis*

This patient's presentation with non-bloody, watery diarrhoea and no significant systemic upset would be typical, especially when combined with a chronic disease course (suggested by the previous episode of diarrhoea and the weight loss) and a mild eosinophilia. Strongyloidiosis is endemic to Namibia and chronic infection can last for many years with only the mildest of symptoms. It can be diagnosed through microscopic examination of the stool for larvae. Despite only minor symptoms, all strongyloidiosis should be treated in order to avoid a hyper-infection syndrome: treatment is with ivermectin for two days.

B *Cryptosporidium* spp.

Cryptosporidium spp. are parasites causing diarrhoea that typically affect young children and the immunocompromised. Typically the diarrhoea is green, offensive smelling and bloody, not watery. Patients generally have mild malaise and a low-grade fever; high fevers are not seen in cryptosporidiosis. If this was an acute presentation of cryptosporidiosis, you would not expect to see weight loss. This patient is afebrile and systemically well. He has a background of a previous episode of diarrhoea and is thin, suggesting a long-term cause of malabsorption that could not be explained by a single episode of cryptosporidiosis. Instead, given this patient's presentation, history and Namibian background, infection with *Strongyloides* spp. is the most likely cause. Strongyloidosis is endemic in Namibia. This would also explain the patient's eosinophilia.

A *Campylobacter jejuni*

Campylobacter is the most common cause of infectious

also could not explain his chronic weight loss. These features point towards a parasitic intestinal infection, causing a low-grade inflammatory response and prolonged malabsorption. In this case, with the patient's presentation and Namibian background, *Strongyloides* spp. is the most likely cause. This parasitic infection is endemic in Namibia and chronic infection can persist for many years with the most minor of symptoms.

E	*Vibrio parahaemolyticus*

This is a bacterial cause of infectious gastroenteritis, causing severe watery diarrhoea. It is typically contracted through eating raw or undercooked seafood. Although this patient has severe watery diarrhoea, he also has weight loss and has had a previous similar episode, which suggests a chronic disease course with malabsorption. More importantly, he has an eosinophilia which cannot be explained by a bacterial gastroenteritis. This, combined with his Namibian background, makes *Strongyloides stercoralis* the most likely cause of his symptoms. This is a parasitic intestinal infection endemic to Namibia, which can cause a chronic disease with episodes of mild abdominal pain and severe watery diarrhoea, and malabsorption leading to weight loss.

12:45

MyPastest
https://mypastest.pastest.com

Pastest+

A 38-year-old homosexual man presents with diarrhoea, which also contains blood and pus. He admits to unprotected anal sex some 2–3 weeks earlier.

On examination, he is apyrexial, and there are no abnormal findings apart from tenderness on rectal examination.

Investigations:

Hb	13.1 g/dl
WCC	8.9×10^9/l
PLT	210×10^9/l
Na^+	139 mmol/l
K^+	4.5 mmol/l
Creatinine	130 μmol/l

Which of the following is the most important next step?

A	Rectal biopsy
B	Colonoscopy
C	Nucleic acid amplification test (NAAT) swab
D	Stool culture
E	Trial of antibiotics

Explanation

C	Nucleic acid amplification test (NAAT) swab

The suspicion here is that this patient has developed rectal gonococcus infection due to his unprotected anal sex. The investigation of choice when collecting rectal specimens is a NAAT swab, which is useful if gonococcus or chlamydia is suspected. Prior to treatment he should be screened for other sexually transmitted infections including HIV, and if he knows the partner with whom he had anal intercourse, that individual should also be screened.

A	Rectal biopsy

This patient presents with a short history of bloody diarrhoea. Given his risk factors, it is likely that a less invasive test will yield the diagnosis. Of course should his symptoms persist without explanation, a rectal biopsy may be warranted at a later stage.

B	Colonoscopy

This patient presents with a short history of bloody diarrhoea. Given his risk factors, it is likely that a less invasive test will yield the diagnosis. Of course should his symptoms persist without explanation, a colonoscopy may be warranted at a later stage.

D	Stool culture

The patient presents with a short history of diarrhoea with blood. Given his risk factors, there is a high suspicion of gonococcal proctitis. Gonococcus is notoriously difficult to culture in the laboratory, requiring specific set-up, and therefore would not be identified on standard culture.

B Colonoscopy

This patient presents with a short history of bloody diarrhoea. Given his risk factors, it is likely that a less invasive test will yield the diagnosis. Of course should his symptoms persist without explanation, a colonoscopy may be warranted at a later stage.

D Stool culture

The patient presents with a short history of diarrhoea with blood. Given his risk factors, there is a high suspicion of gonococcal proctitis. Gonococcus is notoriously difficult to culture in the laboratory, requiring specific set-up, and therefore would not be identified on standard culture.

E Trial of antibiotics

In this patient it would not be appropriate to give empirical antibiotics, as treatment choices are dependent on the underlying diagnosis.

Rate this question:

Next Question

Previous Q... Tag Questi... Feedback End Session

Blog About Pastest Contact Us Help

© Pastest 2019

12:47

A 25-year-old man was referred with a 4-day history of gradual-onset headache, abdominal pain, constipation and high fevers. He had returned from a holiday in Thailand 10 days previously. He had not gone swimming in any fresh water while he was away. He had had intercourse with a prostitute, but used barrier methods.

On examination, his temperature is 39.7 °C, pulse 76 bpm and regular and blood pressure 98/60 mmHg. He appeared flushed and lethargic. There was no rash, or axillary or neck lymphadenopathy. His abdomen was mildly tender in the left iliac fossa.

Investigations:

		Normal values
Haemoglobin (Hb)	107 g/l	115–165
Mean corpuscular volume (MCV)	83.2 fl	80–96
White cell count (WCC)	6.5×10^9/l	4.0–11.0
Platelets (PLT)	83×10^9/l	150–400
Bilirubin	34 µmol/l	1–22
Alanine aminotransferase (ALT)	154 u/l	5–35
Alkaline phosphatase (ALP)	221 u/l	45–105
g-glutamyl transferase	264 u/l	4–35
C-reactive protein (CRP)	298 µg/l	< 10
Sodium (Na)	138 mmol/l	
Potassium (K)	4.4 mmol/l	
[illegible]	5.9 [illegible]	

Rana Alnasser's screen

Platelets (PLT)	83 × 10^9/l	150–400
Bilirubin	34 µmol/l	1–22
Alanine aminotransferase (ALT)	154 u/l	5–35
Alkaline phosphatase (ALP)	221 u/l	45–105
g-glutamyl transferase	264 u/l	4–35
C-reactive protein (CRP)	298 µg/l	< 10
Sodium (Na)	138 mmol/l	
Potassium (K)	4.4 mmol/l	
Urea	5.9 mmol/l	
Creatinine (Cr)	64 µmol/l	

What is the most likely diagnosis?

A *Escherichia coli* gastroenteritis

B Human immunodeficiency virus (HIV)

C Influenza

D Schistosomiasis

E Typhoid fever

Submit

12:50

Your answer was correct

A	*Escherichia coli* gastroenteritis
B	Human immunodeficiency virus (HIV)
C	Influenza
D	Schistosomiasis
E	Typhoid fever

Explanation

E	Typhoid fever

This is an uncommon bacterial infection (*Salmonella typhii*) and typically causes high fevers, abdominal pain, constipation and headache, as seen in this patient. Classically, patients demonstrate Faget's sign – a relative bradycardia. Note that despite a temperature of 39.7 °C, this patient has a pulse of 76 bpm, perhaps lower than expected, given the high temperature. Treatment is classically with fluoroquinolones – ciprofloxacin or ofloxacin.

A	*Escherichia coli* gastroenteritis

E. coli is the most common cause of diarrhoea in the returning traveller; however, instead, this patient has constipation. This is not a feature of *E. coli* infection. Although *E. coli* can cause diarrhoea, leading to dehydration and subsequently headache, you would not expect headache to be an early symptom. It is uncommon [illegible] cause such a high fever and

Rana Alnasser's screen

constipation and headache, as seen in this patient. Classically, patients demonstrate Faget's sign – a relative bradycardia. Note that despite a temperature of 39.7 °C, this patient has a pulse of 76 bpm, perhaps lower than expected, given the high temperature. Treatment is classically with fluoroquinolones – ciprofloxacin or ofloxacin.

A *Escherichia coli* gastroenteritis

E. coli is the most common cause of diarrhoea in the returning traveller; however, instead, this patient has constipation. This is not a feature of *E. coli* infection. Although *E. coli* can cause diarrhoea, leading to dehydration and subsequently headache, you would not expect headache to be an early symptom. It is uncommon for *E. coli* gastroenteritis to cause such a high fever and high CRP. Instead, this patient's symptoms and signs would be more consistent with typhoid fever.

B Human immunodeficiency virus (HIV)

Although this patient did have sexual intercourse during his trip, he used barrier protection, which dramatically reduces the risk of sexually transmitted infections. HIV seroconversion can cause malaise, low-grade fever, diarrhoea and rash; however, instead this patient has constipation and a high fever, which would not be typically for seroconversion. This patient's symptoms and signs would be more consistent with typhoid fever.

C Influenza

The patient does not complain of any coryzal symptoms, and abdominal pain would be atypical for influenza infection. As influenza is a viral infection, you would not expect such a high CRP, as seen in this case, unless there was a secondary pneumonia (of which there is no

Rana Alnasser's screen

12:51

A man presents to the Genitourinary Medicine Clinic. He is a 22-year-old American man and has never attended your clinic before. He is a man who has sex with men and feels that he needs a full sexual health screen. He has had six partners in his life and has had unprotected anal sex with three of them.

Currently, he has no symptoms and feels well. He agrees to an HIV test and tests for Chlamydia and gonorrhoea. You ask him about hepatitis vaccinations and he is not sure. He thinks he may have been vaccinated against something whilst in America but knows no details.

You request hepatitis serology is reported asHep A IgG + ve, Hep B core ag –ve, Hep B s ag –ve, Hep B core ab + ve (titre 120), Hep B surface ab +

What is the most appropriate course of action?

A	Offer hepatitis B vaccination
B	Offer hepatitis A vaccination
C	Start antiviral treatment
D	Offer no vaccination or treatment
E	Repeat tests in six weeks

Submit

Rana Alnasser's screen

A man presents to the Genitourinary Medicine Clinic. He is a 22-year-old American man and has never attended your clinic before. He is a man who has sex with men and feels that he needs a full sexual health screen. He has had six partners in his life and has had unprotected anal sex with three of them.

Currently, he has no symptoms and feels well. He agrees to an HIV test and tests for Chlamydia and gonorrhoea. You ask him about hepatitis vaccinations and he is not sure. He thinks he may have been vaccinated against something whilst in America but knows no details.

You request hepatitis serology is reported asHep A IgG + ve, Hep B core ag –ve, Hep B s ag –ve, Hep B core ab + ve (titre 120), Hep B surface ab +

What is the most appropriate course of action?

Your answer was correct

A Offer hepatitis B vaccination

B Offer hepatitis A vaccination

C Start antiviral treatment

D Offer no vaccination or treatment

E Repeat tests in six weeks

Explanation

D Offer no vaccination or treatment

This question is about interpreting hepatitis serology. Hepatitis A IgG is detectable for life and is no marker of

Explanation

D Offer no vaccination or treatment

This question is about interpreting hepatitis serology. Hepatitis A IgG is detectable for life and is no marker of acute infection. HBsAg is present for 1-6 months in acute infection. HBeAg persists for up to three months and signifies highly infectious patients. Antibodies against HBcAg coupled with the negative antigen results imply past infection, whilst antibodies against HBsAg only implies vaccination. The presence of Hep B core ab implies previous infection and immunity and therefore no vaccination should be offered.

A Offer hepatitis B vaccination

The patient is immune as he has been previously infected with hepatitis B and has already established immunity.

B Offer hepatitis A vaccination

The presence of Hep A IgG without acute hepatitis implies previous infection and established immunity and therefore vaccination is not necessary.

C Start antiviral treatment

There is no evidence of acute infection and the patient is well. No active treatment is needed.

E Repeat tests in six weeks

The serology is unlikely to change and therefore would not need retesting unless the patient became unwell with hepatitis.

A 26-year-old woman was brought to the Emergency Department by ambulance with a 2-day history of headache and nausea, and a 6 h history of increasing drowsiness and confusion. She has no past medical history.

On examination, her temperature was 37.9 °C. She was drowsy and confused. There was no nuchal rigidity or photophobia.

Investigations:

CSF	Opening pressure 160 mm H_2O (50–18) Protein 0.33 g/l (0.15–0.45) Glucose 3.7 mmol/l WCC 16/ml (lymphocytes) (< 3)
Serum glucose	4.9 mmol/l
Chest X-ray	Normal
MRI head	Shown below

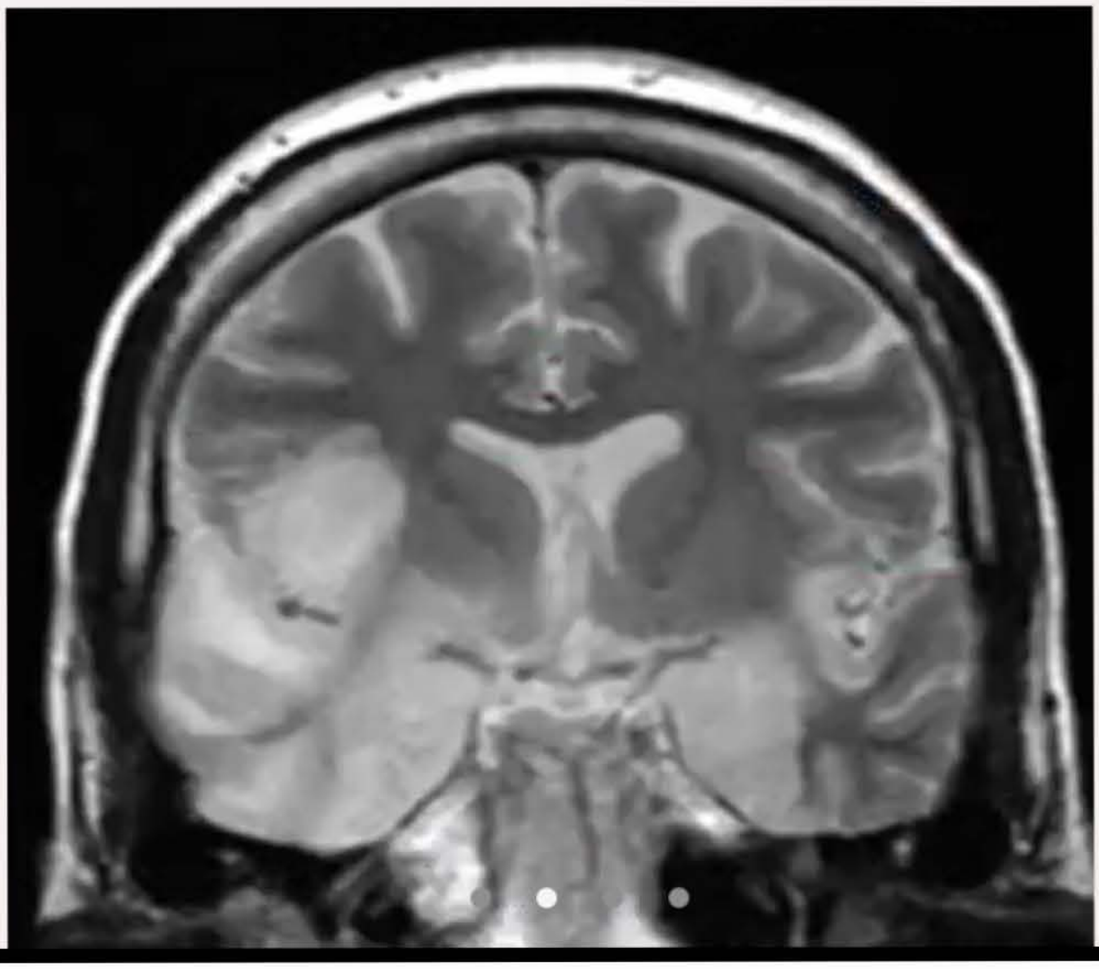

12:54

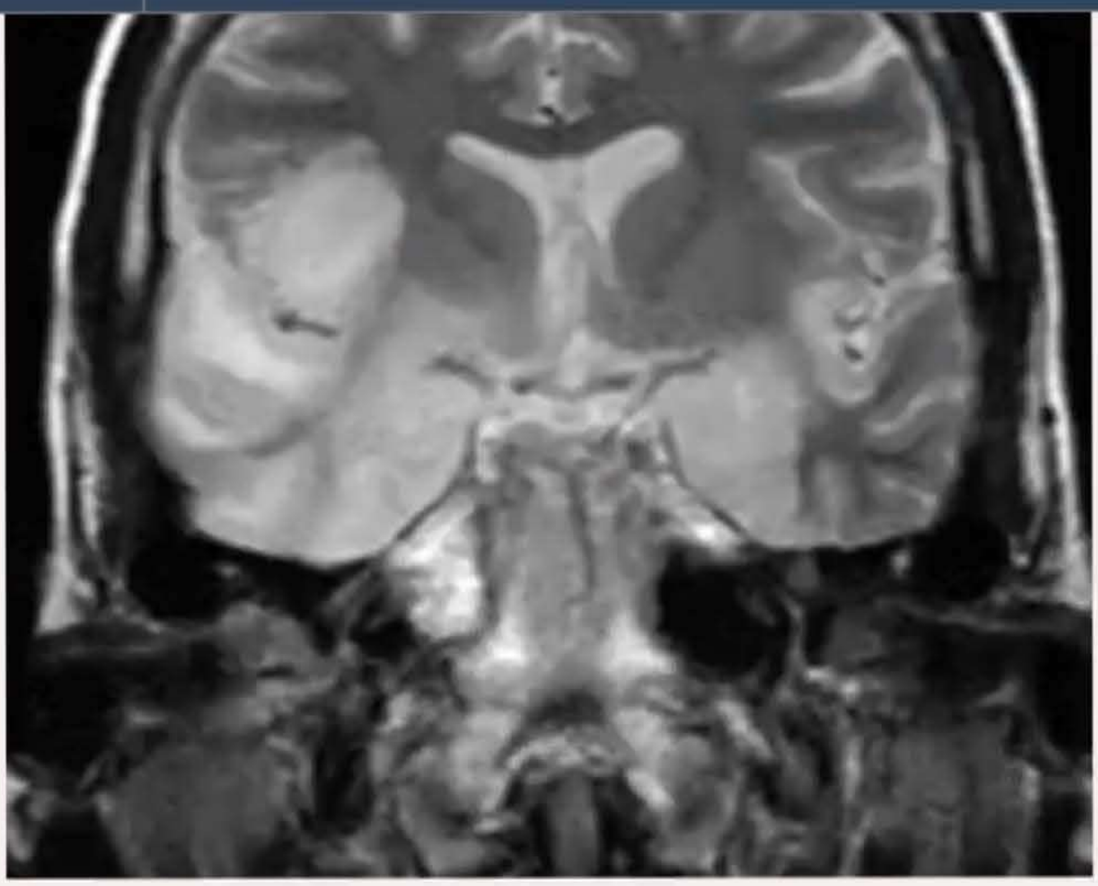

By Dr Laughlin Dawes [CC BY 3.0 (https://creativecommons.org/licenses/by/3.0)], via Wikimedia Commons

What is the most likely diagnosis?

A	Cerebral lymphoma
B	Cryptococcal meningitis
C	Herpes simplex encephalitis
D	Pneumococcal meningitis
E	Tuberculous meningitis

Submit

Wikimedia Commons

What is the most likely diagnosis?

Your answer was correct

A	Cerebral lymphoma
B	Cryptococcal meningitis
C	Herpes simplex encephalitis
D	Pneumococcal meningitis
E	Tuberculous meningitis

Explanation

C	Herpes simplex encephalitis

This short history of increasing confusion and drowsiness is typical, and she has the characteristic MRI findings of signal increase in the temporal lobes. Seizures and a prodrome of headache and nausea are common. Treatment with intravenous aciclovir should be started.

A	Cerebral lymphoma

This is highly unlikely given the acute nature of the patient's presentation and her fever. Cerebral lymphoma would typically present insidiously as confusion or focal neurological signs, or it could present suddenly with a stroke-like picture. Instead, this short history of fever, confusion and drowsiness is more typical of herpes simplex encephalitis.

neurological signs, or it could present suddenly with a stroke-like picture. Instead, this short history of fever, confusion and drowsiness is more typical of herpes simplex encephalitis.

B Cryptococcal meningitis

Cryptococcal meningitis would be extremely unlikely in an immunocompetent patient. This presentation, with a short history of increasing confusion, drowsiness and mild fever, would be more consistent with herpes simplex encephalitis.

D Pneumococcal meningitis

This presentation does not fit with bacterial meningitis – she has a low-grade fever and there are no signs of meningism. The MRI findings are typical for herpes simplex encephalitis, which would also explain her presentation.

E Tuberculous meningitis

Tuberculous meningitis typically has an insidious onset; this patient has become unwell acutely. TB meningitis can cause confusion but may also cause cranial neuropathies, as it can affect the basal skull. It would be unusual to have TB meningitis with a normal chest X-ray. This patient is more likely to have herpes simplex encephalitis; this would fit with her presentation and would also explain the MRI findings.

Rate this question:

Next Question

Previous Q... Tag Questi... Feedback End Session

A 45-year-old Eastern European man is identified at an asylum assessment centre as suffering from persistent cough. On questioning, he admits to fever, night sweats and weight loss which have continued for nearly a year. Occasionally, his sputum has been blood-stained.

Past medical history includes smoking unfiltered cigarettes for the past 20 years. On examination, his body mass index is noted to be 17; he is pyrexial at 37.9°C. On examination, there is non-specific wheeze and occasional crackles.

Which of the following would be the most appropriate initial investigation in this case?

A	Computed tomography (CT) of the thorax
B	Bronchoscopy with induced sputum
C	Chest X-ray
D	HIV testing
E	*Mycobacterium* serology

Submit

A 45-year-old Eastern European man is identified at an asylum assessment centre as suffering from persistent cough. On questioning, he admits to fever, night sweats and weight loss which have continued for nearly a year. Occasionally, his sputum has been blood-stained.

Past medical history includes smoking unfiltered cigarettes for the past 20 years. On examination, his body mass index is noted to be 17; he is pyrexial at 37.9°C. On examination, there is non-specific wheeze and occasional crackles.

Which of the following would be the most appropriate initial investigation in this case?

Your answer was correct

A	Computed tomography (CT) of the thorax
B	Bronchoscopy with induced sputum
C	Chest X-ray
D	HIV testing
E	*Mycobacterium* serology

Explanation

C Chest X-ray

This history is highly suspicious for either pulmonary tuberculosis or underlying bronchial carcinoma. The most appropriate initial investigation therefore would be a chest X-ray to look for calcified nodules or hilar lymph node

B Bronchoscopy with induced sputum

C Chest X-ray

D HIV testing

E *Mycobacterium* serology

Explanation

C Chest X-ray

This history is highly suspicious for either pulmonary tuberculosis or underlying bronchial carcinoma. The most appropriate initial investigation therefore would be a chest X-ray to look for calcified nodules or hilar lymph node calcification in primary infection, or fibrosis and cavitation in the case of reactivation of the tubercle.

A Computed tomography (CT) of the thorax

Chest X-ray should be able to demonstrate pathological apical findings and a CT is seldom necessary. However, if a chest X-ray is normal then a CT can be helpful in finding further lesions.

B Bronchoscopy with induced sputum

First attempts should be to use sputum samples to test for acid-fast bacilli on Ziehl-Neelsen staining, with confirmation by growth. If no sputum can be obtained by coughing, then sputum should be induced.

D HIV testing

in the case of reactivation of the tubercle.

A Computed tomography (CT) of the thorax

Chest X-ray should be able to demonstrate pathological apical findings and a CT is seldom necessary. However, if a chest X-ray is normal then a CT can be helpful in finding further lesions.

B Bronchoscopy with induced sputum

First attempts should be to use sputum samples to test for acid-fast bacilli on Ziehl-Neelsen staining, with confirmation by growth. If no sputum can be obtained by coughing, then sputum should be induced.

D HIV testing

Clearly HIV positivity may increase the risk of tuberculosis, and testing should be considered later.

E *Mycobacterium* serology

Mycobacterium serology is not suggested as first-line investigation. T-spot testing can be used to help aid diagnosis.

Rate this question:

Next Question

Previous Q... Tag Questi... Feedback End Session

You see a previously well 56-year-old Asian gentleman referred by his general practitioner (GP) with a 5-week history of abdominal pain, weight loss, night sweats and fever. He returned 6 weeks ago from Pakistan where he spends half the year. The pain is colicky and generalised and is not associated with meals or relieved by defecation. He has no vomiting or recent change in bowel habit, nor noticed per rectum (PR) bleeding or melaena.

On examination, he is wearing loose clothes and is afebrile. His abdomen is soft but tender in the right lower quadrant.

He has an abdominal ultrasound scan, which reports the presence of a stone in the gall bladder, but otherwise a normal scan.

Oesophageo-gastro-duodenoscopy (OGD) is normal. Barium enema shows narrowing of the terminal ileum.

What is the most likely diagnosis?

A	Ulcerative colitis
B	Carcinoid syndrome
C	Crohn's disease
D	Tuberculosis
E	Caecal cancer

Submit

D Tuberculosis

E Caecal cancer

Explanation

D Tuberculosis

This man's history of being in Pakistan recently, and the rapid onset of weight loss, fever and night sweats makes it likely that he has tuberculosis (TB).

Treatment is as for pulmonary TB, but it is essential to obtain tissue for culture to confirm the diagnosis prior to initiation. In those who are not drug resistant, the standard therapy is of isoniazid, rifampicin, pyrazinamide and ethambutol for 2 months, followed by 4 months of isoniazid and rifampicin. Therapy should be guided by a TB specialist.

A Ulcerative colitis

Ulcerative colitis is an inflammatory bowel disorder of uncertain aetiology. Presentation is typically with episodes of bloody diarrhoea associated with colicky abdominal pain. Inflammation starts at the rectum and may extend proximally to involve the entire colon. In this case, the lack of diarrhoea and terminal ileum changes on imaging point away from a diagnosis of ulcerative colitis.

B Carcinoid syndrome

Carcinoid syndrome is a paraneoplastic syndrome associated with neuroendocrine tumours caused by overproduction of serotonin. Presentation is with diarrhoea and facial flushing and, less commonly, wheeze.

A 22-year-old man presents complaining of a 4-week history of joint pain since returning from his holiday in Spain with a group of male friends. He has noticed stiffness and pain in his fingers and hands, and pain in his lower back. A couple of weeks previously he had also noticed stinging when passing urine, although this has now improved a lot. His mother has commented on how red his eyes look. He has no past medical history but is concerned as his uncle has ankylosing spondylitis.

On examination, there is no swelling of the joints of the hand but there is some clear discomfort on movement. Flexion and extension of the spine is also limited by pain and there is tenderness over the sacroiliac joint. There are no skin rashes but he has clear evidence of bilateral conjunctivitis.

Which test will be most useful in making the diagnosis?

A	Urinalysis
B	Human leukocyte antigen (HLA) typing
C	Rheumatoid factor
D	Urethral swab for microscopy
E	X-ray of the sacroiliac joint

7659

Submit

A 22-year-old man presents complaining of a 4-week history of joint pain since returning from his holiday in Spain with a group of male friends. He has noticed stiffness and pain in his fingers and hands, and pain in his lower back. A couple of weeks previously he had also noticed stinging when passing urine, although this has now improved a lot. His mother has commented on how red his eyes look. He has no past medical history but is concerned as his uncle has ankylosing spondylitis.

On examination, there is no swelling of the joints of the hand but there is some clear discomfort on movement. Flexion and extension of the spine is also limited by pain and there is tenderness over the sacroiliac joint. There are no skin rashes but he has clear evidence of bilateral conjunctivitis.

Which test will be most useful in making the diagnosis?

Your answer was correct

A	Urinalysis
B	Human leukocyte antigen (HLA) typing
C	Rheumatoid factor
D	Urethral swab for microscopy
E	X-ray of the sacroiliac joint

Explanation

D Urethral swab for microscopy

1:00

MyPastest
https://mypastest.pastest.com

Explanation

D Urethral swab for microscopy

The symptoms are classical of sexually acquired reactive arthritis (SARA) with symptoms developing within 30 days of unprotected sexual intercourse and a mean lag of 14 days between the symptoms of urethritis and the joint symptoms. If the patient is found to have >5 polymorphonuclear cells/high-powered field then that will give the diagnosis. Associated conjunctivitis is a common association, more rarely, iritis can occur.

A Urinalysis

This would be the correct answer if urinary tract infection was the right diagnosis. However, this is very unlikely given the patient is a young man, and also would not explain joint pain and conjunctivitis.

B Human leukocyte antigen (HLA) typing

This option suggests a diagnosis of ankylosing spondylitis. Ankylosing spondylitis is a possibility but should not cause dysuria. However, even if typing reveals human leukocyte antigen (HLA)-B27, that will in no way prove ankylosing spondylitis as imaging of the sacroiliac joints and a close history would be far more helpful in establishing that diagnosis.

C Rheumatoid factor

It would be helpful in establishing a diagnosis of

Rana Alnasser's screen

dysuria. However, even if typing reveals human leukocyte antigen (HLA)-B27, that will in no way prove ankylosing spondylitis as imaging of the sacroiliac joints and a close history would be far more helpful in establishing that diagnosis.

C Rheumatoid factor

It would be helpful in establishing a diagnosis of rheumatoid arthritis. While rheumatoid arthritis can cause joint pain and eye symptoms, the absence of any joint swelling, erythema or tenderness on examination, as well as stiffness in the history, makes this unlikely. His demographics and the presence of dysuria further make this an unlikely diagnosis.

E X-ray of the sacroiliac joint

This would be the most appropriate investigation to establish ankylosing spondylitis and would have been the correct answer if the history did not have dysuria and there was stiffness of his back.

Rate this question:

Next Question

Previous Q... Tag Questi... Feedback End Session

Blog About Pastest Contact Us Help

© Pastest 2019

A 72-year-old man presented with a 4-day history of vague tingling over the upper right side of his face.

On waking up that morning, a vesicular rash had developed over his upper right face, including the tip of his nose, and he noticed that his right eye was watering. He had a history of lichen planus, and for the past 3 years, he had used topical tacrolimus to treat it.

What is the most appropriate next step?

A	Prescribe artificial tear solution
B	Start chloramphenicol eye drops
C	Start topical aciclovir
D	Stop tacrolimus ointment
E	Urgent ophthalmology opinion

Submit

Previous Q... Skip Questi...

© Pastest 2019

A 72-year-old man presented with a 4-day history of vague tingling over the upper right side of his face.

On waking up that morning, a vesicular rash had developed over his upper right face, including the tip of his nose, and he noticed that his right eye was watering. He had a history of lichen planus, and for the past 3 years, he had used topical tacrolimus to treat it.

What is the most appropriate next step?

Your answer was correct

A	Prescribe artificial tear solution
B	Start chloramphenicol eye drops
C	Start topical aciclovir
D	Stop tacrolimus ointment
E	Urgent ophthalmology opinion

Explanation

E	Urgent ophthalmology opinion

This patient has herpes zoster ophthalmicus; he had a prodrome of tingling in a dermatomal distribution and subsequently developed a vesicular rash. However, the key point in this case is that he has signs of impending corneal involvement – the rash involves the tip of the nose (Hutchinson's sign) and he has watering of the eye. Hutchinson's sign occurs as the nasociliary branch of the

E Urgent ophthalmology opinion

Explanation

E Urgent ophthalmology opinion

This patient has herpes zoster ophthalmicus; he had a prodrome of tingling in a dermatomal distribution and subsequently developed a vesicular rash. However, the key point in this case is that he has signs of impending corneal involvement – the rash involves the tip of the nose (Hutchinson's sign) and he has watering of the eye. Hutchinson's sign occurs as the nasociliary branch of the trigeminal nerve innervates the cornea and the lateral dorsum of the nose and tip. You would start oral high-dose aciclovir immediately, but it is vital to refer him urgently to ophthalmology for assessment the same day, as herpes zoster ophthalmicus can be sight-threatening.

A Prescribe artificial tear solution

This patient has a vesicular rash involving his upper face and the tip of his nose; this is consistent with herpes zoster ophthalmicus. The watering of his eye and the involvement of the tip of the nose are suggestive of corneal involvement. It is important to urgently refer this patient to ophthalmology, as herpes zoster can be sight-threatening. You would start high-dose oral aciclovir immediately. Artificial tear solution may reduce this patient's symptoms, but it will not treat the underlying condition and therefore does not address the risk of sight impairment.

B Start chloramphenicol eye drops

Chloramphenicol eye drops are an antibiotic eye drop used for bacterial conjunctivitis. This patient has a rash consistent with herpes zoster ophthalmicus; it is vesicular

This patient's rash is vesicular and dermatomal, and is therefore consistent with herpes zoster. Although aciclovir is the correct therapy for this condition, the patient has symptoms and signs that suggest corneal involvement (the rash affects the tip of the nose and there is eye watering). This means that high-dose oral aciclovir should be given, not topical aciclovir. You also must refer this patient urgently to ophthalmology for assessment, as ophthalmic herpes zoster can be sight-threatening.

D	Stop tacrolimus ointment

This patient has been using tacrolimus ointment for several years, and therefore this is unlikely to be a reaction to the drug. Furthermore, vesicular drug rashes are unusual. This rash is typical of herpes zoster (dermatomal, vesicular and with preceding tingling in the affected area), and in this case there are symptoms and signs to suggest corneal involvement (the rash affects the tip of the nose and there is eye watering). This case should be referred urgently to ophthalmology, as herpes zoster ophthalmicus can be sight-threatening. You would also immediately start high-dose oral aciclovir.

Rate this question:

Previous Q... Tag Questi... Feedback End Session

Blog About Pastest Contact Us Help

© Pastest 2019

A 21-year-old student presented with a 2-day history of progressive severe retro-orbital headache, myalgia, nausea and vomiting. She had returned from Northern Queensland 1 day previously.

On examination, her temperature was 39.5 °C, and blood pressure was 125/70 mmHg lying and 105/65 mmHg standing. She appeared dehydrated and had a petechial rash over her trunk and limbs.

Investigations:

Hb	14.9 g/dl (11.5–16.0)
WCC	4.1×10^9/l (4.0–11.0)
PLT	95×10^9/l (150–400)
Na^+	141 mmol/l (137–144)
K^+	4.9 mmol/l (3.5–4.9
Urea	15.0 mmol/l (2.5–7.0)
Creatinine	187 µmol/l (60–110)
ALT	280 U/l (5–35)
Blood film (thick & thin)	Negative for malarial parasites

What is the most appropriate treatment?

A Aciclovir

B Benzylpenicillin

C Paracetamol and rehydration

D Ceftriaxone

pressure was 125/75 mmHg lying and 105/65 mmHg standing. She appeared dehydrated and had a petechial rash over her trunk and limbs.

Investigations:

Hb	14.9 g/dl (11.5–16.0)
WCC	4.1×10^9/l (4.0–11.0)
PLT	95×10^9/l (150–400)
Na^+	141 mmol/l (137–144)
K^+	4.9 mmol/l (3.5–4.9
Urea	15.0 mmol/l (2.5–7.0)
Creatinine	187 µmol/l (60–110)
ALT	280 U/l (5–35)
Blood film (thick & thin)	Negative for malarial parasites

What is the most appropriate treatment?

Your answer was correct

A Aciclovir

B Benzylpenicillin

C Paracetamol and rehydration

D Ceftriaxone

E Ibuprofen

Explanation

Explanation

C Paracetamol and rehydration

This patient has dengue fever: she has travelled to an endemic area and has developed a fever with thrombocytopenia and a petechial rash, in conjunction with the classical retro-orbital headache and flu-like symptoms. No specific treatment is required: supportive therapy with paracetamol and rehydration is adequate. Occasionally in severe cases, clotting factors may be required. Diagnosis is via serology; however, due to the specialist nature of these serological tests often results will not be available for 1–2 weeks and patients must be treated according to clinical suspicion.

A Aciclovir

Aciclovir is an appropriate treatment for suspected encephalitis, which may present with severe headache. However, this patient's symptoms and signs are more suggestive of dengue fever: she has travelled to an endemic area, and retro-orbital headache, flu-like illness, fever, and thrombocytopenia with deranged liver function tests are typical. Dengue fever is caused by a mosquito-borne virus. Treatment is supportive; it is a haemorrhagic fever and in severe cases support with clotting factors may be required, but otherwise paracetamol and rehydration are the only treatments required.

B Benzylpenicillin

Intramuscular benzylpenicillin is an appropriate primary care treatment for suspected meningococcal meningitis; as this patient has a rash, fever and severe headache, this is an understandable differential diagnosis. However, given her travel history, the retro-orbital nature of the headache and

1:05

MyPastest
https://mypastest.pastest.com

Pastest+

Ceftriaxone would be an appropriate treatment for meningococcal meningitis; however, this patient has symptoms and signs that suggest dengue fever, rather than meningitis. A severe, retro-orbital headache is a classic symptom of dengue fever, and she has travelled from an area where dengue is endemic. Her thrombocytopenia, petechial rash and deranged liver function tests are also suggestive of dengue fever. The most appropriate treatment for this viral haemorrhagic fever is supportive, with paracetamol and fluids. Rarely, in severe cases, patients may require clotting factors.

E	Ibuprofen

This patient has dengue fever; she has returned from an endemic area, has a petechial rash, thrombocytopenia, deranged liver function tests and a severe retro-orbital headache with flu-like symptoms. Dengue fever is a mosquito-borne viral haemorrhagic fever: due to the risk of bleeding and relative thrombocytopenia, ibuprofen and other NSAIDs should be avoided, due to their effects on platelet function. No specific treatment is required for this patient; she should be supported with fluid replacement and paracetamol. Occasionally, in severe cases, clotting factors may be required.

Rate this question:

Next Question

Previous Q... Tag Questi... Feedback End Session

A 26-year-old woman, who is 4 weeks post-partum, comes to the Emergency Department. She had an uneventful pregnancy and spontaneous vaginal delivery requiring episiotomy. She presents now feeling extremely ill, with a purpuric rash and a fever.

On examination, she has a pyrexia of 38.5 °C, a BP of 95/60 mmHg, and a pulse of 105 bpm regular. She has lower abdominal tenderness on palpation and you notice erythema around her episiotomy site. She is wearing a pad and you notice some foul-smelling, blood stained, yellow discharge on the pad.

Investigations:

Hb	11.1 g/dl
WCC	13.2×10^9/l
PLT	132×10^9/l
Na^+	139 mmol/l
K^+	5.2 mmol/l
Creatinine	130 µmol/l

Which of the following is the most useful investigation?

A Ultrasound scan abdomen

B Blood cultures

C High vaginal swab

D Urine culture

E Wound swab

1:06
On
625-262-0256
Leave

E Wound swab

Explanation

C High vaginal swab

The patient likely has endometritis. Symptoms of endometritis include fever, foul smelling vaginal discharge, and erythema or discharge around a wound site if present. A late presentation is not unusual, given that patients may assume their feeling unwell is just a slow recovery from labour. Studies suggest that empirical treatment covering penicillin resistant anaerobes appears most effective at treating endometritis. According to Cochrane reviews, a regime containing gentamicin and clindamycin appears to be the most efficient combination. Unfortunately over the longer term, adhesions and scarring post infection may lead to problems with future fertility. A high vaginal swab would be particularly useful on this occasion in targeting appropriate antibiotic therapy.

B Blood cultures

Whilst blood cultures should be taken as the patient is septic, they are not the most important investigation as blood cultures are unlikely have as high a diagnostic sensitivity as direct swabbing.

A Ultrasound scan abdomen

Whilst an ultrasound may be helpful, it is not the most important investigation in the acute setting. If the patient does not improve with treatment or there are concerns about abscess formation or deeper infection, then an ultrasound can be helpful.

D Urine cultures

Audio Video Share Participants More

A 23-year-old woman has attended the GU Clinic for multiple (>5) episodes of painful genital ulceration. One such episode a year before caused acute urinary retention, and was treated with IV aciclovir.

According to the case notes from that admission, at that time she was noted to have 'multiple small ulcers affecting the labial and vulval area with erythema of the surrounding skin, and marked tender inguinal lymphadenopathy'. However, on examination today at the Outpatient Clinic she has no ulcers.

What treatment should you offer her?

A	5 days' aciclovir
B	3 months' aciclovir
C	3 months' valaciclovir
D	5 days' valaciclovir
E	3 months' ganciclovir

Submit

multiple (>5) episodes of painful genital ulceration. One such episode a year before caused acute urinary retention, and was treated with IV aciclovir.

According to the case notes from that admission, at that time she was noted to have 'multiple small ulcers affecting the labial and vulval area with erythema of the surrounding skin, and marked tender inguinal lymphadenopathy'. However, on examination today at the Outpatient Clinic she has no ulcers.

What treatment should you offer her?

Your answer was incorrect

A 5 days' aciclovir

B 3 months' aciclovir

C 3 months' valaciclovir

D 5 days' valaciclovir

E 3 months' ganciclovir

Explanation

B 3 months' aciclovir

This patient has frequently recurring herpes simplex virus (HSV) episodes. Usually if a patient has more than six episodes yearly they are offered prophylactic treatment, which consists of 3 months' oral aciclovir with the aim of suppressing the HSV.

D 5 days' valaciclovir

D 5 days' valaciclovir

This would be an option for treating an acute course of HSV sores.

A 5 days' aciclovir

This would be the correct option for treating acute HSV sores but none are present at this time.

C 3 months' valaciclovir

Valaciclovir is a pro-drug of aciclovir and has the advantage of needing to be taken only twice daily. This would be a treatment option, but it is generally not offered as it is considerably more expensive.

E 3 months' ganciclovir

Ganciclovir is not usually used for HSV infections but can be used for cytomegalovirus (CMV).

Rate this question:

Next Question

Previous Q... Tag Questi... Feedback End Session

Blog About Pastest Contact Us Help

© Pastest 2019

A 28-year-old woman presented to the Emergency Department 1 hour after receiving a needlestick injury whilst at work. She was a nurse in a Gastroenterology Department and her needlestick injury had been received from a hepatitis C-positive patient. The patient was taking ribavirin and pegylated alpha interferon. The nurse had been wearing gloves at the time of the needlestick, and had punctured the pad of her left index finger. She had washed the wound with running water afterwards.

Donor virology investigations:

Hepatitis C RNA	Low levels detected
HBsAg	-
Anti-HBc	-
Anti-HBs	-
HIV RNA PCR	-

What should be the next step?

A Arrange hepatitis B vaccination

B Give anti-hepatitis C immunoglobulin

C Reassure and discharge home

D Start post-exposure prophylaxis

E Take blood from the nurse for virology

D Start post-exposure prophylaxis

E Take blood from the nurse for virology

Explanation

E Take blood from the nurse for virology

It is important to take baseline samples from the nurse to determine whether she was a carrier or was infected with a blood-borne virus before her exposure to this patient (as this would have different implications for treatment). If these are negative, her blood will continue to be monitored to check whether she has contracted hepatitis C from this patient. If she has, treatment for the virus will begin at that point. Post-exposure prophylaxis is not recommended for hepatitis C.

A Arrange hepatitis B vaccination

This nurse is likely to have already had the hepatitis B vaccination, as this is a requirement for healthcare workers. Furthermore, vaccinating the patient against hepatitis B will not influence her risk of contracting hepatitis C from the donor patient. The most important step is to take virology bloods from the nurse. These bloods are used to tell whether the nurse is already a carrier or infected with a blood-borne virus, before her exposure to the patient. Her virology bloods will then be monitored to decide whether she has contracted hepatitis C from the patient.

B Give anti-hepatitis C immunoglobulin

This is not a treatment option for hepatitis C, and there is no evidence that it is effective as a vaccine or post-exposure prophylaxis. Furthermore, at this stage, it is

1:14
On
625-262-0256
Leave

C Reassure and discharge home

Although it is not appropriate to give this nurse post-exposure prophylaxis (this is not recommended for hepatitis C), it is important to take the nurse's blood for virology. This is to check whether, at baseline, she was a carrier or was infected with a blood-borne virus (i.e. before her exposure to this patient). Her virology will then be monitored to determine whether she has contracted hepatitis C from this patient.

D Start post-exposure prophylaxis

Post-exposure prophylaxis has not been shown to be effective in the prevention of contracting hepatitis C, and therefore is not recommended. Instead, the nurse's blood should be taken for virology; this is in order to have a baseline sample to check whether she was carrying or was infected with a blood-borne virus before her exposure to this patient. Her blood will then be monitored to determine whether she has contracted hepatitis C from this patient.

© Pastest 2019

Audio Video Share Participants More

1:14

A 32-year-old man presents to the Emergency Department. He is known to be HIV positive but has been non-compliant with his antiretroviral therapy and his CD4 count is 80 × 10^6/l. He complains of a 3-week history of a worsening headache, and malaise. He reported symptoms of a dry cough and breathlessness a month ago but this seemed to improve with antibiotics from the general practitioner.

On examination, he is unwell, temperature 38.8 °C, pulse 120 bpm, blood pressure 100/50 mmHg, O_2 saturation 98% on air. There is no lymphadenopathy but there is evidence of oral candida, the chest is clear, and cardiovascular examination is normal. On neurological examination, there is no focal neurology but marked neck stiffness and photophobia. Computed tomography (CT) of the head reveals no focal lesions.

Cerebrospinal fluid (CSF):

Opening pressure	40 cmH_2O
Protein	3.5 g/l
Glucose	3.1 mmol/l (plasma 4.5)
WCC	45 × 10^9/l of which 43 × 10^9/l are lymphocytes, 2 × 10^9/l are polymorphs

Which test is most likely to give the diagnosis?

A Serum toxoplasma serology

B CSF Cryptococcal antigen

C Ziehl–Neelsen stain

D CSF herpes simplex virus (HSV) polymerase chain reaction (PCR)

Rana Alnasser's screen

of oral candida, the chest is clear, and cardiovascular examination is normal. On neurological examination, there is no focal neurology but marked neck stiffness and photophobia. Computed tomography (CT) of the head reveals no focal lesions.

Cerebrospinal fluid (CSF):

Opening pressure	40 cmH_2O
Protein	3.5 g/l
Glucose	3.1 mmol/l (plasma 4.5)
WCC	45×10^9/l of which 43×10^9/l are lymphocytes, 2×10^9/l are polymorphs

Which test is most likely to give the diagnosis?

A Serum toxoplasma serology

B CSF Cryptococcal antigen

C Ziehl-Neelsen stain

D CSF herpes simplex virus (HSV) polymerase chain reaction (PCR)

E CSF Gram stain

Submit

examination is normal. On neurological examination, there is no focal neurology but marked neck stiffness and photophobia. Computed tomography (CT) of the head reveals no focal lesions.

Cerebrospinal fluid (CSF):

Opening pressure	40 cmH_2O
Protein	3.5 g/l
Glucose	3.1 mmol/l (plasma 4.5)
WCC	45×10^9/l of which 43×10^9/l are lymphocytes, 2×10^9/l are polymorphs

Which test is most likely to give the diagnosis?

Your answer was correct

A Serum toxoplasma serology

B CSF Cryptococcal antigen

C Ziehl-Neelsen stain

D CSF herpes simplex virus (HSV) polymerase chain reaction (PCR)

E CSF Gram stain

Explanation

B CSF Cryptococcal antigen

This is the most diagnostic test for cryptococcal meningitis, the most likely explanation for this presentation:

E CSF Gram stain

Explanation

B CSF Cryptococcal antigen

This is the most diagnostic test for cryptococcal meningitis, the most likely explanation for this presentation: lymphocytic meningitis with a high opening pressure. Cryptococccal meningitis is caused by *Cryptococcus* species, which are neurotropic encapsulated yeasts. They enter the body through the lungs so up to a third of patients will report a pneumonitis in the weeks preceding systemic cryptococcal infection, which could explain the dry cough for this patient. It can also cause skin lesions which closely resemble molluscum contagiosum. Once inside, they infect neutrophils leading to meningitic spread, causing signs and symptoms of meningitis, such as neck stiffness for this patient, and headache. It is also associated with raised intracranial pressure. Standard treatment is with amphotericin B and flucytosine.

A Serum toxoplasma serology

This would be correct for a suspected diagnosis of toxoplasmosis. Cerebral toxoplasma does not classically cause meningitis. Typically, presentation can occur with neurological signs developing over days to weeks and then can cause seizures. In addition, raised intracranial pressure can cause headaches and vomiting. Some present with diffuse encephalitis causing confusion, seizures and reduced consciousness. This patient does not have focal neurology and instead has a cough, and normally toxoplasmosis would show ring-enhancing lesions on a CT scan.

C Ziehl-Neelsen stain

C Ziehl-Neelsen stain

This would be the correct answer for suspected TB meningitis. In TB meningitis, you would expect to see a much lower CSF glucose in relation to the plasma glucose. It is also not associated with a high opening pressure.

D CSF herpes simplex virus (HSV) polymerase chain reaction (PCR)

It would be correct for suspected herpes simplex encephalitis. Clinical suspicion of encephalitis would be higher if there were confusion and reduced consciousness, and again the cough makes this option less likely.

E CSF Gram stain

It would be the primary method to identify bacterial meningitis. Bacterial meningitis is unlikely with a lymphocytic cerebrospinal fluid (CSF) and also would usually have a more acute clinical course.

Rate this question:

Next Question

Previous Q... Tag Questi... Feedback End Session

© Pastest 2019

A 72-year-old man was referred by his general practitioner after investigation for his 6-month history of lower limb peripheral neuropathy.

On examination, he had a mixed sensory–motor peripheral neuropathy affecting his feet. Romberg's test was positive. He had some scarring over his lower legs from sores in childhood, when he lived in Jamaica. He had been living in the UK for 40 years.

Investigations:

Fasting plasma glucose	9.1 mmol/l (3.0–6.0)
HbA1c	78 mmol/mol (20–42)
Folate	9.6 mg/l (2.0–11.0)
Vitamin B_{12}	426 ng/l (160–760)
Treponemal EIA	+
Treponema pallidum particle agglutination	+
Rapid plasma reagin (RPR)	-

What is the most likely explanation for his syphilis serology?

A False positive

B Fully treated prior syphilis infection

C Primary syphilis

D Systemic lupus erythematosus

He had some scarring over his lower legs from sores in childhood, when he lived in Jamaica. He had been living in the UK for 40 years.

Investigations:

Fasting plasma glucose	9.1 mmol/l (3.0–6.0)
HbA1c	78 mmol/mol (20–42)
Folate	9.6 mg/l (2.0–11.0)
Vitamin B_{12}	426 ng/l (160–760)
Treponemal EIA	+
Treponema pallidum particle agglutination	+
Rapid plasma reagin (RPR)	-

What is the most likely explanation for his syphilis serology?

A False positive

B Fully treated prior syphilis infection

C Primary syphilis

D Systemic lupus erythematosus

E Yaws

71050

Submit

Fasting plasma glucose	9.1 mmol/l (3.0–6.0)
HbA1c	78 mmol/mol (20–42)
Folate	9.6 mg/l (2.0–11.0)
Vitamin B_{12}	426 ng/l (160–760)
Treponemal EIA	+
Treponema pallidum particle agglutination	+
Rapid plasma reagin (RPR)	-

What is the most likely explanation for his syphilis serology?

Your answer was incorrect

A False positive

B Fully treated prior syphilis infection

C Primary syphilis

D Systemic lupus erythematosus

E Yaws

Explanation

E Yaws

Explanation

E Yaws

This is a disease caused by a bacterium related to that causing syphilis – *Treponema pallidum pertenue*. Consequently it can cause some cross-reactivity with syphilis tests, as seen here. Yaws is not usually spread through sexual contact, but instead direct contact. It causes skin lesions which eventually can scar in the primary or secondary stage. A small number of patients will go on to a tertiary stage where there is widespread bone and joint destruction. It can be diagnosed clinically, or through dark field microscopy of lesion fluid during the primary or secondary stages. It can be treated with a single intramuscular injection of penicillin. This patient's peripheral neuropathy is most likely caused by his poorly controlled diabetes: however, it would be impossible to completely rule out neurosyphilis and therefore this patient should have a lumbar puncture to check RPR on the CSF.

B Fully treated prior syphilis infection

Although TPPA would remain positive in patients with fully treated prior syphilis infection, the clinical history here is not suggestive of prior syphilis infection.

Instead, this serology, combined with the patient's Jamaican background and childhood history of lower limb sores, is suggestive of yaws. This is an infection caused by a bacterium related to the syphilitic bacterium, *Treponema pallidium pertenue*. It causes skin sores which can eventually scar.

It is likely that this patient's peripheral neuropathy is caused by his poorly controlled diabetes.

A False positive

If this were primary syphilis, you would expect the RPR to be positive, in addition to the EIA and TPPA. However, in this case it is negative. These results, in combination with the patient's Jamaican background and childhood history of leg sores, are suggestive of yaws. This is caused by a bacterium related to that causing syphilis, and hence there can be cross-reactivity with syphilis investigations. This patient's peripheral neuropathy is likely caused by his poorly controlled diabetes.

D	Systemic lupus erythematosus

This patient has no clinical features of systemic lupus erythematosus, and there is no reason why SLE would cause cross-reactivity with syphilis investigations. Instead this patient's serology, Jamaican background and childhood history of leg sores are suggestive of previous yaws. This is a disease caused by a bacterium related to that causing syphilis, and hence can cause cross-reactivity in syphilis investigations. This patient's peripheral neuropathy is likely caused by his poorly controlled diabetes.

© Pastest 2019

You are a senior house officer in The Genitourinary Medicine Clinic. A 28-year-old Eritrean woman presents to the clinic with a letter from the obstetricians. She is 15 weeks pregnant and as part of her booking appointment was found to have positive syphilis serology. She is asymptomatic, serology shows *Treponema pallidum* haemagglutination test (TPHA) positive at a titre of 1/320.

In her clinic notes, you see that she has been treated for early latent syphilis with one dose of benzathine penicillin 18 months previously. At her most recent follow-up, 6 months ago, serology shows TPHA positive, rapid plasma reagin (RPR) 1/6; 3 months prior to that, RPR was 1/6. The patient has no symptoms and her husband was treated for syphilis at the same time.

She is very concerned about the possibility of passing syphilis onto her baby. You repeat her serology which shows TPHA positive, RPR1/4.

What is the most appropriate management?

A	Further three doses of benzathine penicillin
B	Further one dose of benzathine penicillin
C	No further treatment required
D	3-monthly monitoring of RPR during pregnancy
E	2 weeks of doxycycline

Submit

the clinic with a letter from the obstetricians. She is 15 weeks pregnant and as part of her booking appointment was found to have positive syphilis serology. She is asymptomatic, serology shows *Treponema pallidum* haemagglutination test (TPHA) positive at a titre of 1/320.

In her clinic notes, you see that she has been treated for early latent syphilis with one dose of benzathine penicillin 18 months previously. At her most recent follow-up, 6 months ago, serology shows TPHA positive, rapid plasma reagin (RPR) 1/6; 3 months prior to that, RPR was 1/6. The patient has no symptoms and her husband was treated for syphilis at the same time.

She is very concerned about the possibility of passing syphilis onto her baby. You repeat her serology which shows TPHA positive, RPR1/4.

What is the most appropriate management?

Your answer was correct

A Further three doses of benzathine penicillin

B Further one dose of benzathine penicillin

C No further treatment required

D 3-monthly monitoring of RPR during pregnancy

E 2 weeks of doxycycline

Explanation

C No further treatment required

This patient has been adequately treated for early latent syphilis and her RPR is stable, but remaining positive. She

C No further treatment required

This patient has been adequately treated for early latent syphilis and her RPR is stable, but remaining positive. She is serofast and you would only be concerned at the possibility of reinfection if the RPR increased by twofold or more. In fact, it has decreased slightly since her last blood test, so there is no cause for concern. The titre of TPHA is meaningless and should not be done. TPHA will remain positive all her life and simply indicates previous syphilis infection, giving no information about treatment.

Treatment for syphilis is generally with benzathine penicillin IM with dose and need for repeat of treatment dependent on the stage of syphilis and if the patient is pregnant. For early syphilis, including primary, secondary and early latent, a single dose of 2.4 MU is needed. For latent, cardiovascular and gummatous syphilis three doses over 3 weeks are needed. Note that for cardiovascular syphilis, steroids should be given as well, starting the day before antibiotics. For neurosyphilis, procaine penicillin and probenecid is needed for 2 weeks.

In pregnancy, treatment for early syphilis is one dose up to 27 weeks of pregnancy and two doses from week 28 to term.

A Further three doses of benzathine penicillin

There is no further need for treatment as RPR is not changing. This management is not generally recommended.

B Further one dose of benzathine penicillin

There is no further need for treatment as RPR is not changing. If a patient is treated in the third trimester then a further dose is needed and she is in week 15 of pregnancy.

1:35

A 37-year-old woman is seen in clinic with a 1-month history of malaise, tiredness, chest pain and breathlessness on walking up the stairs. You establish that she has not felt well for about 6 months since returning from Puerto Rico. She went fresh-water swimming there and often walked barefoot. She boiled her water but occasionally dined out on local delicacies. She developed an itch of both feet shortly after returning and noticed a rash, which responded to cream prescribed by her doctor. A week later, she had an episode of dyspnoea and wheeze, which her general practitioner (GP) told her was asthma and she felt better with salbutamol. About 3 months ago she had abdominal pain, nausea and diarrhoea, which settled after a few weeks.

On examination, she looks pale but there is no clubbing or lymphadenopathy. She is tachycardic at 104 bpm but her heart sounds are normal. Chest exam reveals scattered wheeze. Her abdomen is soft and her per rectum (PR) examination is normal.

Chest X-ray reveals small bilateral pleural effusions.

Blood results are as follows:

WCC	6.5×10^9/l
Hb	76 g/l
PLT	532×10^9/l
Albumin	31 g/l
C-reactive protein (CRP)	6 mg/l

What is the most likely diagnosis?

A Dilated cardiomyopathy

B Polyarteritis nodosa

Rana Alnasser's screen

shortly after returning and noticed a rash, which responded to cream prescribed by her doctor. A week later, she had an episode of dyspnoea and wheeze, which her general practitioner (GP) told her was asthma and she felt better with salbutamol. About 3 months ago she had abdominal pain, nausea and diarrhoea, which settled after a few weeks.

On examination, she looks pale but there is no clubbing or lymphadenopathy. She is tachycardic at 104 bpm but her heart sounds are normal. Chest exam reveals scattered wheeze. Her abdomen is soft and her per rectum (PR) examination is normal.

Chest X-ray reveals small bilateral pleural effusions.

Blood results are as follows:

WCC	6.5×10^9/l
Hb	76 g/l
PLT	532×10^9/l
Albumin	31 g/l
C-reactive protein (CRP)	6 mg/l

What is the most likely diagnosis?

A Dilated cardiomyopathy

B Polyarteritis nodosa

C Colonic carcinoma

D Hookworm infection

E Schistosomiasis

D Hookworm infection

E Schistosomiasis

Explanation

D Hookworm infection

The most common pathogens are *Ancylostoma duodenale* and *Necator americanus*. This patient has a history consistent with hookworm infection. Hookworm is endemic in the Americas, south-east Asia, India and Africa The worms often get in through the feet and cause an intense local rash. After about a week they move through the lung causing wheezing and cough and then they migrate to the intestine where they become adults and start laying eggs. With heavy infection the patient may have an episode of abdominal pain, nausea, diarrhoea and anorexia. This patient has experienced all of these symptoms. The examination findings are consistent with pulmonary infiltration, and the pallor and tachycardia can be explained by anaemia. Hookworms cause anaemia by attachment to the upper gastrointestinal mucosa leading to chronic bleeding and iron deficiency. After 8–12 weeks the hookworm eggs are present in the faeces and the isolation of these is the investigation of choice. Anthelminthic drugs effective against hookworms include albendazole, mebendazole and thiabendazole, as well as ivermectin.

A Dilated cardiomyopathy

It can present with shortness of breath and chest pain, but it does not explain many of the respiratory or abdominal aspects of the history or examination, nor the anaemia. Also, it is commonly associated with a family history of sudden death as that may the first presentation and it is inherited in an autosomal dominant fashion.

bleeding and iron deficiency. After 8-12 weeks the hookworm eggs are present in the faeces and the isolation of these is the investigation of choice. Anthelminthic drugs effective against hookworms include albendazole, mebendazole and thiabendazole, as well as ivermectin.

A Dilated cardiomyopathy

It can present with shortness of breath and chest pain, but it does not explain many of the respiratory or abdominal aspects of the history or examination, nor the anaemia. Also, it is commonly associated with a family history of sudden death as that may the first presentation and it is inherited in an autosomal-dominant fashion.

B Polyarteritis nodosa

While polyarteritis nodosa (PAN) can start with a rash and develop into systemic features and have gastrointestinal features and also cause anaemia, one would expect a raised WCC and CRP. It is also associated with hepatitis B and twice as common in men than women.

C Colonic carcinoma

It would not explain the wheeze or pleural effusions, and her age and lack of risk factors make the diagnosis very unlikely.

E Schistosomiasis

It would not explain her respiratory symptoms or findings. Schistosomiasis in the Americas is caused by *Schistosoma mansoni* and this species causes abdominal pain, diarrhoea and vomiting, and then progresses to hepatic symptoms and findings. African causes of schistosomiasis can have pulmonary infiltration.

1:42
On
625-262-0256
Leave

A 24-year-old single woman presents with a second episode of left iliac fossa pain in the past four months. Additionally, she has noticed inter-menstrual bleeding and has suffered an intermittent mucopurulent cervical discharge, although there are no external lesions.

On examination, she has lower abdominal pain, worse on the left-hand side. The abdomen is soft and there is no rebound tenderness. Urine testing is negative, pregnancy test is negative.

Given the likely diagnosis, which of the following interventions is the most appropriate in this case?

A	Chlamydial nucleic acid amplification testing
B	Penicillin V 500 mg po qds
C	Aciclovir po
D	Admit for surgical observation
E	Arrange abdominal ultrasound

Submit

Previous Q... Skip Questi...

Audio Video Share Participants More

1:43
On
625-262-0256
Leave

A Chlamydial nucleic acid amplification testing

This patient's history is suggestive of *Chlamydia* infection, and therefore the most appropriate initial intervention is chlamydial nucleic acid amplification testing followed by a 1-week course of doxycycline. Alternative antibiotics include macrolides, quinolones or amoxicillin. Patients should refrain from intercourse for a period of seven days, and contact notification should be encouraged where possible. Long-term complications in women include the possibility of pelvic inflammatory disease, infertility and transfer to the newborn infant during childbirth.

B Penicillin V 500 mg po qds

This would be the correct treatment for tonsillitis, otitis media, erysipelas, cellulitis, group A streptococcal infection, rheumatic fever and pneumococcal infection prophylaxis. Benzathine penicillin can be used to treat syphilis.

C Aciclovir po

Aciclovir is the treatment for herpes simplex. Herpes causes painful genital ulceration without discharge. Whilst diagnosis can be confirmed by PCR viral swabs, it is generally considered a clinical diagnosis. The absence of painful ulcers and presence of discharge and abdominal pain makes this a very unlikely diagnosis and therefore makes this option incorrect.

D Admit for surgical observation

This is a patient with a soft abdomen with no signs of peritonism. She is unlikely to require acute surgical intervention and therefore surgical observation would not be necessary.

Audio Video Share Participants More

1:44
On
625-262-0256
Leave

Acyclovir is the treatment for herpes simplex. Herpes causes painful genital ulceration without discharge. Whilst diagnosis can be confirmed by PCR viral swabs, it is generally considered a clinical diagnosis. The absence of painful ulcers and presence of discharge and abdominal pain makes this a very unlikely diagnosis and therefore makes this option incorrect.

D Admit for surgical observation

This is a patient with a soft abdomen with no signs of peritonism. She is unlikely to require acute surgical intervention and therefore surgical observation would not be necessary.

E Arrange abdominal ultrasound

An abdominal ultrasound would be of minimal diagnostic value in this patient as it would be suited to evaluation of renal pathology. A transvaginal ultrasound can be considered for adnexal infection and gynaecological abscesses, but with a negative pregnancy test and a soft abdomen it is likely to be of any help.

Rate this question:

Next Question

© Pastest 2019

Audio Video Share Participants More

1:44
On
625-262-0256
Leave

A 28-year-old man presented with a 6-month history increasing fatigue and lethargy, muscle pains and headache, accompanied by symptoms of indigestion. He had lost 4 kg in weight over the preceding 4 months. He was a voluntary aid worker and had been living in Chile for the past 5 years.

Past history of note included a pulmonary embolus, for which he was taking warfarin. An ECG demonstrated right bundle branch block.

Investigations:

Barium swallow	Dilated oesophagus
Oesophageal manometry	Increased pressure

Which of the following is the most likely diagnosis?

A	Chagas' disease
B	Fasciolosis
C	Myasthenia gravis
D	Oesophageal achalasia
E	Sleeping sickness

Submit

Audio
Video
Share
Participants
More

1:45
On 625-262-0256 Leave

A 28-year-old man presented with a 6-month history increasing fatigue and lethargy, muscle pains and headache, accompanied by symptoms of indigestion. He had lost 4 kg in weight over the preceding 4 months. He was a voluntary aid worker and had been living in Chile for the past 5 years.

Past history of note included a pulmonary embolus, for which he was taking warfarin. An ECG demonstrated right bundle branch block.

Investigations:

Barium swallow	Dilated oesophagus
Oesophageal manometry	Increased pressure

Which of the following is the most likely diagnosis?

Your answer was correct

A Chagas' disease

B Fasciolosis

C Myasthenia gravis

D Oesophageal achalasia

E Sleeping sickness

Explanation

A Chagas' disease

Chagas' disease, also known as American trypanosomiasis, is caused by infection with *Trypanosoma cruzi*, carried by

Audio Video Share Participants More

1:45
On
625-262-0256
Leave

Explanation

A Chagas' disease

Chagas' disease, also known as American trypanosomiasis, is caused by infection with *Trypanosoma cruzi*, carried by the kissing bug. Initial infection typically causes no or non-specific symptoms, but chronic infection leads to gastrointestinal and cardiac complications, such as conduction defects (hence the right bundle branch block on this patient's ECG) and mega-oesophagus, as seen here. It also increases the tendency for thromboembolic disease, which may explain why he has developed a pulmonary embolism. Chagas' disease can be diagnosed via PCR. Until recently no specific treatments were advocated for Chagas' disease, and it had significant morbidity and mortality. However, more recently it has been shown that nifurtimox may clear parasites in 50–60% of patients, though it has significant side effects.

B Fasciolosis

Fasciola are liver flukes, and cause an acute condition with fever, urticaria, anaemia, jaundice and abdominal pain, progressing to chronic inflammation and obstruction of the bile ducts and gall bladder. This patient does not have hepatic symptoms or signs; instead his symptoms and signs are more consistent with Chagas' disease, caused by chronic infection with *Trypanosoma cruzi*. The dilated oesophagus is typical, and the disease also classically affects the heart, causing conduction problems as seen here.

C Myasthenia gravis

Myasthenia gravis causes difficulty with swallowing due to failure of coordinated peristalsis and muscular fatigue

Audio Video Share Participants More

1:45
On
625-262-0256
Leave

chronic infection with the parasite *Trypanosoma cruzi* and spread by the kissing bug.

D	Oesophageal achalasia

Although oesophageal achalasia could explain the findings on barium swallow and oesophageal manometry, it does not explain why this patient has conduction abnormalities on his ECG, or his other symptoms of fatigue, headache and myalgia. The combination of his travel history, conduction abnormalities, mega-oesophagus and history of thrombosis would fit with Chagas' disease, caused by the parasite *Trypanosoma cruzi*, carried by the kissing bug.

E	Sleeping sickness

Sleeping sickness, or African trypanosomiasis, causes an acute flu-like illness with headache and myalgia, facial swelling and urticaria, and may develop into late-stage illness with a progressive meningoencephalitis. It does not cause mega-oesophagus, conduction abnormalities or and thromboembolism. This patient's symptoms, signs and travel history are more consistent with Chagas' disease, or American trypanosomiasis, caused by the parasite *Trypanosoma cruzi* and carried by the kissing bug.

Rate this question:

Next Question

Previous Q... Tag Questi... Feedback End Session

©Pastest 2019

Audio Video Share Participants More

A 49-year-old man has been having peritoneal dialysis for the last 6 months while he waits for a renal transplant. He has diabetic renal disease. His current medications include insulin, ramipril, aspirin and pravastatin. He is a non-smoker and drinks alcohol socially. He lives with his wife in a bungalow.

He presents with a 2-day history of abdominal pain and fever. The pain is localised to the site of the catheter. He tells you that the dialysis fluid is cloudy.

On abdominal examination, there is mild tenderness at the site of the catheter entrance. There are no masses palpable. There is no rebound tenderness or guarding. Bowel sounds are normal. Abdominal ultrasound scan shows no abnormalities.

Which of the following antibiotic regimes should be prescribed for this gentleman?

A	IV co-amoxiclav and IV gentamicin
B	IV imipinem and oral ciprofloxacin
C	IV tazocin and oral vancomycin
D	Intraperitoneal vancomycin and oral ciprofloxacin
E	IV cefuroxime and oral vancomycin

Submit

A 49-year-old man has been having peritoneal dialysis for the last 6 months while he waits for a renal transplant. He has diabetic renal disease. His current medications include insulin, ramipril, aspirin and pravastatin. He is a non-smoker and drinks alcohol socially. He lives with his wife in a bungalow.

He presents with a 2-day history of abdominal pain and fever. The pain is localised to the site of the catheter. He tells you that the dialysis fluid is cloudy.

On abdominal examination, there is mild tenderness at the site of the catheter entrance. There are no masses palpable. There is no rebound tenderness or guarding. Bowel sounds are normal. Abdominal ultrasound scan shows no abnormalities.

Which of the following antibiotic regimes should be prescribed for this gentleman?

Your answer was correct

A IV co-amoxiclav and IV gentamicin

B IV imipinem and oral ciprofloxacin

C IV tazocin and oral vancomycin

D Intraperitoneal vancomycin and oral ciprofloxacin

E IV cefuroxime and oral vancomycin

Explanation

D Intraperitoneal vancomycin and oral ciprofloxacin

This gentleman has peritonitis, which is dialysis related. It is

palpable. There is no rebound tenderness or guarding. Bowel sounds are normal. Abdominal ultrasound scan shows no abnormalities.

Which of the following antibiotic regimes should be prescribed for this gentleman?

Your answer was correct

A IV co-amoxiclav and IV gentamicin

B IV imipinem and oral ciprofloxacin

C IV tazocin and oral vancomycin

D Intraperitoneal vancomycin and oral ciprofloxacin

E IV cefuroxime and oral vancomycin

Explanation

D Intraperitoneal vancomycin and oral ciprofloxacin

This gentleman has peritonitis, which is dialysis related. It is very common. It is important that there is adequate cover for both *Staphylococcus aureus* and Enterobacteriaceae. For peritonitis secondary to perforation, cefuroxime and metronidazole is adequate cover. In dialysis-related peritonitis, however, intraperitoneal vancomycin is necessary in moderate illness. Intravenous vancomycin would be appropriate for more severe illness. Oral ciprofloxacin is added to further broaden coverage.

A IV co-amoxiclav and IV gentamicin

These could be the antibiotics used for pyelonephritis

urinary symptoms.

B IV imipinem and oral ciprofloxacin

This combination is effective against severe *Pseudomonas* infections.

C IV tazocin and oral vancomycin

Oral vancomycin is only effective against *Cl. difficile* as it is not absorbed and therefore only works locally. It would not help against peritoneal infection. Tazocin, or pipercillin with tazobactam, would provide broad-spectrum antimicrobial cover but the patient would be more suited for oral therapy.

E IV cefuroxime and oral vancomycin

Again, oral vancomycin is not useful for peritoneal infection. Cefuroxime is a second-generation cephalosporin that crosses the blood-brain barrier, making it a very good antibiotic for meningitis.

Rate this question:

Next Question

© Pastest 2019

A 76-year-old woman presents to the Emergency Department some 8–12 h after eating a ready-made chicken meal. She complains of fever, abdominal cramps, nausea, vomiting and diarrhoea.

She has recently been taking co-amoxiclav for a respiratory tract infection, but nothing else of note. Her blood pressure (BP) is 122/72 mmHg, with a post-drop of 20 mmHg on standing with corresponding increase in pulse rate.

Investigations:

Hb	12.9 g/dl
Plt	560×10^9/l
WCC	4.5×10^9/l
Na^+	148 mmol/l
K^+	3.2 mmol/l
Urea	18.4 mmol/l
Creatinine	195 µmol/l

Which of the following diagnoses fits best with this clinical picture?

A Norovirus

B Rotavirus

C Amoebiasis

D Giardiasis

E *Salmonella*

1:50

MyPastest
https://mypastest.pastest.com

Pastest+

Your answer was correct

A Norovirus

B Rotavirus

C Amoebiasis

D Giardiasis

E *Salmonella*

Explanation

E *Salmonella*

This patient has acute bacterial gastroenteritis. She is likely to have acquired this from the ready-made chicken meal eaten some hours previously. Given this food history and the evidence of severe dehydration due to the infection, the most likely candidates are *Salmonella* or *Campylobacter* infection. The incubation period of *Campylobacter* infection can sometimes be much longer, up to 7 days, but can be as short as 24 h, as is the case here. The incubation period of *Salmonella* gastroenteritis is 6–72 h, making it the more likely diagnosis in this case. Uncomplicated infections with these agents do not require treatment, but where there is significant dehydration as in this case, oral or intravenous rehydration therapy ± quinolone antibiotics could be considered.

A Norovirus

1:52
On
625-262-0256
Leave

outbreaks of 'winter vomiting illness', with projectile vomiting, diarrhoea and fever and settles quickly. Treatment is supportive but patients will need to be strictly isolated.

B Rotavirus

Rotavirus is a cause of viral gastroenteritis up to the age of five. Following 1-5 days of incubation there is malaise, diarrhoea, vomiting and fever.

C Amoebiasis

Ameobiasis is caused by *Entamoeba histolytica*, a protozoon. Spread is via the faecal-oral route. Presentation is usually with gastrointestinal symptoms but in 1% there can be invasive liver disease. Subtle amoebic dysentery presents slowly but can lead to bloody diarrhoea and fever. Diagnosis is with stool microscopy demonstrating trophozoites, bleed and pus cells.

D Giardiasis

It is caused by *Giardia lamblia*, a flagellated protozoon, which infects the jejenum and deuodenum following faecal-oral spread. Causes explosive diarrhoea, abdominal cramps and malabsorption. Diagnosis is with stool microscopy for cysts and trophozoites or PCR. Treatment is with tindazole 2 g stat, with high levels of hygiene. May cause lactose intolerance as well.

Rate this question:

End Session

Audio Video Share Participants More

11:23

A 25-year-old woman presents to the general practitioner (GP) with tiredness, weight loss and diarrhoea. She has also been suffering from heavy periods over the past few months.

On examination she looks tanned, but is very thin and emaciated. Her blood pressure is 115/80, pulse is 84 and regular and she has a postural drop of 20 mmHg on standing.

Investigations:

Hb	9.1 g/dl (normocytic)
WCC	6.1×10^9/l
PLT	195×10^9/l
Na^+	132 mmol/l
K^+	5.8 mmol/l
Ferritin	25 µg/l
Folate	4.0 µg/l
Ca^+	2.35 mmol/l
Albumin	28 g/l
ALT	42 U/l
TSH	8.3 U/l
Glucose	8.5 mmol/l (fasting)

Which of the following is the most likely diagnosis?

A Coeliac disease

Rana Alnasser's screen

regular and she has a postural drop of 20 mmHg on standing.

Investigations:

Hb	9.1 g/dl (normocytic)
WCC	6.1×10^9/l
PLT	195×10^9/l
Na^+	132 mmol/l
K^+	5.8 mmol/l
Ferritin	25 µg/l
Folate	4.0 µg/l
Ca^+	2.35 mmol/l
Albumin	28 g/l
ALT	42 U/l
TSH	8.3 U/l
Glucose	8.5 mmol/l (fasting)

Which of the following is the most likely diagnosis?

A Coeliac disease

B Polyglandular syndrome type 1

C Polyglandular syndrome type 2

D Polyglandular syndrome type 3

E HIV infection

Explanation

C Polyglandular syndrome type 2

Type 2 polyglandular syndrome is characterised by adrenal insufficiency, hypothyroidism and type 1 diabetes; hypogonadism, coeliac disease and myasthenia gravis may also be seen. The hyponatraemia, elevated fasting glucose and elevated TSH all support this as the diagnosis.

A Coeliac disease

This may explain the diarrhoea, but it would not explain the hyponatraemia and hyperkalaemia seen here, nor the postural drop in blood pressure.

B Polyglandular syndrome type 1

This is characterised by mucocutaneous candidiasis, hypoparathyroidism and adrenal insufficiency.

D Polyglandular syndrome type 3

Type 3 polyglandular syndrome is characterised by autoimmune thyroiditis, but the other associated autoimmune diseases don't fit with a diagnosis of either type 1 or type 2 disease.

E HIV infection

Although HIV infection may present with significant weight loss and diarrhoea, the abnormalities seen on blood testing are much more consistent with autoimmune polyglandular syndrome.

11:26

A woman is 32 weeks' pregnant. She is taking propylthiouracil 150 mg daily for thyrotoxicosis.

On her check-up, she complains of heat intolerance and palpitations, and repeat thyroid function tests confirm that thyroid-stimulating hormone (TSH) is < 0.1, and T3 and T4 are also elevated.

Which of the following is the next most appropriate management step?

A	Increase propylthiouracil dose
B	Radioiodine treatment
C	Induce delivery
D	Stop propylthiouracil and start carbimazole
E	Arrange for partial thyroidectomy

71295

Submit

Previous Q... Skip Questi...

Rana Alnasser's screen

C Induce delivery

D Stop propylthiouracil and start carbimazole

E Arrange for partial thyroidectomy

Explanation

D Stop propylthiouracil and start carbimazole

In pregnancy, PTU is only recommended in guidelines for the first trimester of pregnancy. After this time, a switch to carbimazole is recommended because of the risk of maternal liver toxicity associated with PTU use. This patients should be switched to carbimazole and the PTU not up-titrated.

A Increase propylthiouracil dose

Both carbimazole, at a suggested daily dose of 10–20 mg, and propylthiouracil (PTU), at a dose of 150 mg bd, are acceptable for use in pregnancy, although PTU tends to be the more popular choice. PTU may be more protein-bound and so less is transmitted to the foetus, but compliance with carbimazole is generally better. In addition, there is evidence that PTU may be associated with maternal hepatotoxicity in late pregnancy, precipitating a change to carbimazole as the most appropriate in that case.

B Radioiodine treatment

Radioiodine treatment is contraindicated in pregnancy, since radioiodine crosses the placenta and can cause congenital hypothyroidism. Following radioactive iodine

11:30

76% 09:30

Thyrotoxic crisis ('thyroid storm') requires emergency treatment with intravenous administration of fluids, propranolol hydrochloride and hydrocortisone (as sodium succinate), as well as oral iodine solution and carbimazole or propylthiouracil which may need to be administered by nasogastric tube.

Antithyroid drugs in pregnancy

Radioactive iodine therapy is contra-indicated during pregnancy. Propylthiouracil and carbimazole can be given but the blocking-replacement regimen is **not** suitable. Rarely, carbimazole has been associated with congenital defects, including aplasia cutis of the neonate, therefore propylthiouracil remains the drug of choice during the first trimester of pregnancy. In the second trimester, consider switching to carbimazole because of the potential risk of hepatotoxicity with propylthiouracil. Both propylthiouracil and carbimazole cross the placenta and in high doses may cause fetal goitre and hypothyroidism—the lowest dose that will control the hyperthyroid state should be used (requirements in Graves' disease tend to fall during pregnancy).

Advanced Pharmacy Services

Patients with thyroid disorders may be eligible for the Medicines Use Review service provided by a community pharmacist. For further information, see *Advanced Pharmacy Services* in Guidance on prescribing.

Related drugs

- CARBIMAZOLE
- HYDROCORTISONE
- LEVOTHYROXINE SODIUM
- NADOLOL
- PROPRANOLOL HYDROCHLORIDE
- PROPYLTHIOURACIL

11:30

A 59-year-old woman presents to the clinic with tiredness. She takes no medication, and her thyroid-stimulating hormone (TSH) level is in the normal range. She has had a pituitary adenoma in the past that was found to be prolactin-secreting, and she tells you she had some benign tumours removed from her neck. She takes calcium and vitamin D supplements.

A picture of her neck is shown below.

What is she most likely to be suffering from?

A	Familial medullary thyroid cancer
B	Hyperparathyroidism-jaw tumour syndrome
C	Multiple endocrine neoplasia type 1 (MEN-1)
D	Multiple endocrine neoplasia type 2a (MEN-2a)
E	Multiple endocrine neoplasia type 2b (MEN-2b)

71650

Submit

Rana Alnasser's screen

E Multiple endocrine neoplasia type 2b (MEN-2b)

Explanation

C Multiple endocrine neoplasia type 1 (MEN-1)

MEN-1 is associated with the development of parathyroid adenomas (linked to the neck scar and vitamin D and calcium supplementation seen here). The syndrome is also linked to pituitary adenomas, particularly prolactinomas, and endocrine pancreatic tumours. The history seen here is therefore consistent with MEN-1. Around 60% of islet cell tumours do not originate from beta cells, and these are more common in the over-40 population.

A Familial medullary thyroid cancer

Medullary thyroid cancer would not explain the presentation with prolactinoma and, as part of a syndrome, is associated with MEN-2. It is not associated with parathyroid adenomas.

B Hyperparathyroidism-jaw tumour syndrome

An autosomal dominant inheritance pattern for familial hyperparathyroidism does exist, although it would not explain the presentation with a prolactinoma seen here.

D Multiple endocrine neoplasia type 2a (MEN-2a)

MEN-2 is associated with primary hyperparathyroidism, but it is also associated with phaeochromocytoma and medullary thyroid cancer, rather than the pituitary tumour reported here.

E Multiple endocrine neoplasia type 2b (MEN-2b)

11:32

MyPastest
https://mypastest.pastest.com

Pastest+

A Familial medullary thyroid cancer

Medullary thyroid cancer would not explain the presentation with prolactinoma and, as part of a syndrome, is associated with MEN-2. It is not associated with parathyroid adenomas.

B Hyperparathyroidism-jaw tumour syndrome

An autosomal dominant inheritance pattern for familial hyperparathyroidism does exist, although it would not explain the presentation with a prolactinoma seen here.

D Multiple endocrine neoplasia type 2a (MEN-2a)

MEN-2 is associated with primary hyperparathyroidism, but it is also associated with phaeochromocytoma and medullary thyroid cancer, rather than the pituitary tumour reported here.

E Multiple endocrine neoplasia type 2b (MEN-2b)

MEN-2b is associated with a marfanoid habitus, medullary thyroid cancer and phaeochromocytoma.

Rate this question:

Next Question

Previous Q... Tag Questi... Feedback End Session

An 18-year-old man with mild learning difficulties is referred to the Emergency Department for review. He has recently moved into sheltered accommodation in the area and is noted by staff to have made multiple complaints about muscular weakness and pins and needles affecting both hands. He has been noted by the GP to have hypocalcaemia and a raised level of parathyroid hormone.

On examination, there is obvious subcutaneous calcification and he has a short fifth metacarpal on each hand.

Which of the following is the treatment of choice for this patient?

A	Parathyroidectomy
B	Calcium supplementation
C	Calcium and vitamin D supplementation
D	Parathyroid hormone administration
E	Calcitonin administration

Submit

An 18-year-old man with mild learning difficulties is referred to the Emergency Department for review. He has recently moved into sheltered accommodation in the area and is noted by staff to have made multiple complaints about muscular weakness and pins and needles affecting both hands. He has been noted by the GP to have hypocalcaemia and a raised level of parathyroid hormone.

On examination, there is obvious subcutaneous calcification and he has a short fifth metacarpal on each hand.

Which of the following is the treatment of choice for this patient?

Your answer was correct

A Parathyroidectomy

B Calcium supplementation

C Calcium and vitamin D supplementation

D Parathyroid hormone administration

E Calcitonin administration

Explanation

C Calcium and vitamin D supplementation

This individual has pseudohypoparathyroidism. It is associated with short stature, short metacarpals, subcutaneous calcification and variable intellectual impairment. The G-protein-coupled receptor for

C Calcium and vitamin D supplementation

This individual has pseudohypoparathyroidism. It is associated with short stature, short metacarpals, subcutaneous calcification and variable intellectual impairment. The G-protein-coupled receptor for parathyroid hormone (PTH) becomes unresponsive to the hormone, hence patients become hypocalcaemic in the face of normal or elevated PTH levels. Variable degrees of resistance involving other G-protein-mediated receptors, such as those linked to thyroid-stimulating hormone (TSH), luteinising hormone (LH) and follicle-stimulating hormone (FSH) activity, may also be seen. Calcium and vitamin D is the intervention of choice. Calcium levels should be monitored frequently during treatment as rapid rises may occur.

A Parathyroidectomy

The hypocalcaemia seen here is consistent with parathyroid resistance rather than functional parathyroid excess; hence parathyroidectomy is not appropriate.

B Calcium supplementation

Calcium supplementation alone is inadequate to restore normal calcium levels.

D Parathyroid hormone administration

Given this is a syndrome of parathyroid hormone resistance, supplementation of PTH will not restore normal calcium metabolism.

A 48-year-old man is referred to the clinic with newly diagnosed type 2 diabetes. He also complains of excessive sweating and worries that his hands have swollen so that his wedding ring no longer fits him.

Past medical history includes hypertension, which is managed with amlodipine and indapamide.

On examination, his blood pressure is 150/90 mmHg and he has a very prominent lower jaw. There is also soft tissue swelling of his hands.

Investigations:

Hb	14.9 g/dl
WCC	5.0×10^9/l
PLT	300×10^9/l
Na^+	138 mmol/l
K^+	4.0 mmol/l
Creatinine	100 μmol/l
Random glucose	12.1 mmol/l

Which one of the following would be the most appropriate initial investigation towards confirming this man's likely underlying diagnosis?

A Fasting plasma glucose

B Random growth hormone measurement

C Prolactin measurement

D Random cortisol measurement

E IGF-1 measurement

On examination, his blood pressure is 150/90 mmHg and he has a very prominent lower jaw. There is also soft tissue swelling of his hands.

Investigations:

Hb	14.9 g/dl
WCC	5.0×10^9/l
PLT	300×10^9/l
Na^+	138 mmol/l
K^+	4.0 mmol/l
Creatinine	100 µmol/l
Random glucose	12.1 mmol/l

Which one of the following would be the most appropriate initial investigation towards confirming this man's likely underlying diagnosis?

A Fasting plasma glucose

B Random growth hormone measurement

C Prolactin measurement

D Random cortisol measurement

E IGF-1 measurement

32892

Submit

E IGF-1 measurement

Explanation

E IGF-1 measurement

This patient has a clinical picture consistent with a diagnosis of acromegaly. IGF-1 measurement varies with age and nutritional status, but reference ranges exist for comparison. IGF-1 has a long half-life and, as such, is a useful measure of growth hormone status. Failure of growth hormone to suppress in response to an oral glucose challenge is the other diagnostic method of choice for assessing patients with possible acromegaly, although this is less convenient following an initial clinic appointment.

A Fasting plasma glucose

Although an elevation in fasting plasma glucose may indicate a diagnosis of diabetes, it won't reveal the underlying cause.

B Random growth hormone measurement

Growth hormone is released in pulsatile fashion and has a short half-life; as such, random measurement is not useful in confirming a diagnosis of acromegaly.

C Prolactin measurement

Prolactin may be elevated because of local pressure effects from a pituitary adenoma, but it won't confirm elevated growth hormone.

D Random cortisol measurement

11:37

An 18-year-old man presents to the clinic with bilateral gynaecomastia. He apparently had surgery as a child to correct bilateral undescended testes. On examination he is tall, with increased arm and leg length. He does have evidence of bilateral gynaecomastia, with small testes bilaterally. Apparently there have been problems with anxiety and bullying at 6th form and he has now left to begin a job.

Which of the following would be the most appropriate investigation?

A	Oestrogen
B	GNRH
C	FSH, LH
D	Progesterone
E	Testosterone

20607

Submit

Previous Q... Skip Questi...

Rana Alnasser's screen

11:41
594-042-7551
Leave

An 18-year-old man presents to the clinic with bilateral gynaecomastia. He apparently had surgery as a child to correct bilateral undescended testes. On examination he is tall, with increased arm and leg length. He does have evidence of bilateral gynaecomastia, with small testes bilaterally. Apparently there have been problems with anxiety and bullying at 6th form and he has now left to begin a job.

Which of the following would be the most appropriate investigation?

Your answer was incorrect

A	Oestrogen
B	GNRH
C	FSH, LH
D	Progesterone
E	Testosterone

Explanation

C	FSH, LH

The suspicion here, based on history and physical appearance, is a diagnosis of Klinefelter syndrome. Both FSH and LH are raised in Klinefelter syndrome, and elevation would be a strong pointer to confirming the underlying diagnosis. Chromosomal analysis would be an

Audio Video Share Participants More

11:41
594-042-7551
Leave

Explanation

C FSH, LH

The suspicion here, based on history and physical appearance, is a diagnosis of Klinefelter syndrome. Both FSH and LH are raised in Klinefelter syndrome, and elevation would be a strong pointer to confirming the underlying diagnosis. Chromosomal analysis would be an obvious further step. Management centres on androgen replacement, cosmetic procedures and access to psychosexual counselling.

E Testosterone

Although testosterone is reduced in patients with Klinefelter syndrome, measuring this wouldn't indicate whether the defect was at the level of the pituitary or the testes and hence FSH and LH measurement is more useful.

A Oestrogen

Although oestrogen levels are elevated in patients with Klinefelter, they are less useful vs raised gonadotrophins in confirming the diagnosis.

B GNRH

GNRH levels are reduced in Kallmann syndrome; this syndrome is associated with absence of sense of smell, which isn't reported as part of the scenario here.

D Progesterone

Progesterone levels are not useful in the evaluation of Klinefelter syndrome.

Audio Video Share Participants More

11:43

You review a 28-year-old woman with Hashimoto's thyroiditis in the thyroid clinic. She has been stable on 100 µg of thyroxine for the past few years and recent TSH was measured at 1.0 mU/l some 6 months ago (normal range 0.4–5). The reason for this appointment is that she is 12 weeks pregnant.

How would you manage her thyroxine therapy during this pregnancy?

A	Increase her thyroxine dose by an average of 100 mcg
B	Increase her thyroxine dose by an average of 25-50 mcg
C	Reduce her thyroxine dose by an average of 25 mcg
D	Reduce her thyroxine dose by an average of 50 mcg
E	Keep her thyroxine dose unchanged

Submit

Previous Q... Skip Questi...

Rana Alnasser's screen

mcg

E Keep her thyroxine dose unchanged

Explanation

B Increase her thyroxine dose by an average of 25-50 mcg

In patients already on thyroxine when they become pregnant, thyroid function tests should be assessed at 6–8 weeks' gestation and then at 16–20 and 28–32 weeks. Average increase in thyroxine requirements is 25–50 μg, and the increased need for thyroxine ceases immediately after delivery. In patients with positive thyroid autoantibodies there is a twofold increased risk of spontaneous abortion. In patients who are suboptimally treated for hypothyroidism there is a 21% risk of pregnancy-induced hypertension. Maternal hypothyroidism is also associated with increased risk of pregnancy-induced anaemia and postpartum haemorrhage; for these reasons it is crucial that patients with hypothyroidism are followed up appropriately during pregnancy. TSH should be monitored, and guidelines suggest aiming to keep TSH below 3.0.

E Keep her thyroxine dose unchanged

The 30% increase in thyroid hormone requirements in pregnancy will mean this patient slips into hypothyroidism as her pregnancy progresses.

A Increase her thyroxine dose by an average of 100 mcg

This runs the risk of symptomatic hyperthyroidism in pregnancy, increasing the risk of spontaneous abortion.

after delivery. In patients with positive thyroid autoantibodies there is a twofold increased risk of spontaneous abortion. In patients who are suboptimally treated for hypothyroidism there is a 21% risk of pregnancy-induced hypertension. Maternal hypothyroidism is also associated with increased risk of pregnancy-induced anaemia and postpartum haemorrhage; for these reasons it is crucial that patients with hypothyroidism are followed up appropriately during pregnancy. TSH should be monitored, and guidelines suggest aiming to keep TSH below 3.0.

E Keep her thyroxine dose unchanged

The 30% increase in thyroid hormone requirements in pregnancy will mean this patient slips into hypothyroidism as her pregnancy progresses.

A Increase her thyroxine dose by an average of 100 mcg

This runs the risk of symptomatic hyperthyroidism in pregnancy, increasing the risk of spontaneous abortion.

C Reduce her thyroxine dose by an average of 25 mcg

Thyroid hormone requirements increase by an average of 30% in pregnancy; as such, this is not the appropriate course of action.

D Reduce her thyroxine dose by an average of 50 mcg

Even if this patient wasn't pregnant, halving her thyroxine dose risks symptomatic hypothyroidism.

Rate this question:

A 25-year-old man attends the clinic with his partner as they have difficulties with fertility, having tried for a baby for over 24 months with no success. He admits to decreased libido and some problems maintaining his erection. He has also had difficulties with his sense of smell for as long as he can remember. On examination his BP is 120/70 mmHg, with a pulse of 75/min. He has a small penis and sparse secondary sexual hair.

Investigations:

Hb	12.4 g/dl
WCC	7.1 x 10^9/l
PLT	203 x 10^9/l
Na^+	139 mmol/l
K^+	4.4 mmol/l
Creatinine	110 µmol/l
TSH	1.2 U/l (0.5-4.5 U/l)
Free T_4	12 pmol/l (10-22)
Testosterone	7.0 nmol/l (9-35)
FSH	0.4 U/l (1-7)
LH	2 U/l (1-10)

Which of the following is the most likely diagnosis?

A Kallmann syndrome

B Kleinfelter syndrome

C Mumps orchitis

Creatinine	110 μmol/l
TSH	1.2 U/l (0.5-4.5 U/l)
Free T_4	12 pmol/l (10-22)
Testosterone	7.0 nmol/l (9–35)
FSH	0.4 U/l (1-7)
LH	2 U/l (1-10)

Which of the following is the most likely diagnosis?

A Kallmann syndrome

B Kleinfelter syndrome

C Mumps orchitis

D Pituitary failure

E Androgen insensitivity syndrome

23347

Submit

Previous Q... Skip Questi...

© Pastest 2019

A 40-year-old man attends the GP surgery for review. He reports pain in his calves while walking his dog after only quite modest exercise. He is a current smoker with a 60-pack-year history. He has a family history of early cardiovascular disease. On examination he has tendon xanthomas affecting the extensor tendons of his fingers and at the elbows. You notice that he appears to have corneal arcus.

Which of the following represents the most likely diagnosis in this case?

A	Heterozygous familial hypercholesterolaemia
B	Homozygous familial hypercholesterolaemia
C	Familial hypertriglyceridaemia
D	Apo CII deficiency
E	Tangier disease

Submit

A 40-year-old man attends the GP surgery for review. He reports pain in his calves while walking his dog after only quite modest exercise. He is a current smoker with a 60-pack-year history. He has a family history of early cardiovascular disease. On examination he has tendon xanthomas affecting the extensor tendons of his fingers and at the elbows. You notice that he appears to have corneal arcus.

Which of the following represents the most likely diagnosis in this case?

Your answer was correct

A	Heterozygous familial hypercholesterolaemia
B	Homozygous familial hypercholesterolaemia
C	Familial hypertriglyceridaemia
D	Apo CII deficiency
E	Tangier disease

Explanation

A Heterozygous familial hypercholesterolaemia

Heterozygous familial hypercholesterolaemia is an autosomal dominant condition that affects around 1 in 500 people. Although the diagnosis is mainly biochemical, two physical signs may be present, in corneal arcus and tendon xanthomata. The Simon Broome criteria are used to

Explanation

A	Heterozygous familial hypercholesterolaemia

Heterozygous familial hypercholesterolaemia is an autosomal dominant condition that affects around 1 in 500 people. Although the diagnosis is mainly biochemical, two physical signs may be present, in corneal arcus and tendon xanthomata. The Simon Broome criteria are used to diagnose familial hypercholesterolaemia:

- Total cholesterol level >7.5 mmol/l and LDL >4.9 mmol/l; plus
- Tendon xanthomata or evidence of these in a 1st or 2nd degree relative; or
- DNA evidence of an LDL receptor mutation, familial defective apo-B-100 or a PCSK9 mutation.

Heterozygotes rarely present before the age of 30. In this case the patient has presented with intermittent claudication. Treatment is with aggressive lipid-lowering therapies, such as high-dose statins ± the addition of ezetimibe.

B	Homozygous familial hypercholesterolaemia

Homozygotes present with very early cardiovascular disease, sometimes as early as the 2nd decade of life.

C	Familial hypertriglyceridaemia

Patients with hypertriglyceridaemia are often asymptomatic. They may present with abdominal pain due to pancreatitis, lipaemia retinalis or eruptive xanthomas over extensor surfaces or buttocks.

Homozygotes present with very early cardiovascular disease, sometimes as early as the 2nd decade of life.

C Familial hypertriglyceridaemia

Patients with hypertriglyceridaemia are often asymptomatic. They may present with abdominal pain due to pancreatitis, lipaemia retinalis or eruptive xanthomas over extensor surfaces or buttocks.

D Apo CII deficiency

This condition causes an accumulation of chylomicrons. It tends to present with hepatosplenomegaly, abdominal pain and eruptive xanthomas.

E Tangier disease

Tangier disease is also known as familial alpha-lipoprotein deficiency. Cholesterol deposition is common in the tonsils, lymph nodes, bone marrow, liver and spleen.

Rate this question:

© Pastest 2019

Rana Alnasser's screen

11:52

A 33-year-old female auxiliary nurse presents for review. She has had difficulty with managing her hypertension and is currently taking atenolol 100 mg, amlodipine 10 mg and ramipril 10 mg, yet her blood pressure is still raised at 165/80 mmHg. She takes beclomethasone 100 mcg BD for asthma, but nil else of note.

On examination, she has a body mass index (BMI) of 29, with no obvious abdominal striae.

Fasting blood results:

Na^+	140 mmol/l
K^+	2.8 mmol/l
Creatinine	90 µmol/l
HCO_3^-	40 mmol/l
Glucose	5.0 mmol/l

What diagnosis fits best with this clinical picture?

A Fibromuscular hyperplasia

B Diabetic nephropathy

C Conn syndrome

D Cushing syndrome

E Essential hypertension

Submit

Rana Alnasser's screen

A 33-year-old female auxiliary nurse presents for review. She has had difficulty with managing her hypertension and is currently taking atenolol 100 mg, amlodipine 10 mg and ramipril 10 mg, yet her blood pressure is still raised at 165/80 mmHg. She takes beclomethasone 100 mcg BD for asthma, but nil else of note.

On examination, she has a body mass index (BMI) of 29, with no obvious abdominal striae.

Fasting blood results:

Na^+	140 mmol/l
K^+	2.8 mmol/l
Creatinine	90 µmol/l
HCO_3^-	40 mmol/l
Glucose	5.0 mmol/l

What diagnosis fits best with this clinical picture?

Your answer was correct

A Fibromuscular hyperplasia

B Diabetic nephropathy

C Conn syndrome

D Cushing syndrome

E Essential hypertension

Explanation

Explanation

C Conn syndrome

Adrenal adenomas account for around 60% of cases of hyperaldosteronism, the likely cause of the profound hypokalaemia and resistant hypertension seen here. Small aldosterone-producing adrenal adenomas are commoner in young women, whereas bilateral adrenal hyperplasia tends to occur later and is commoner in men.

The best test for Conn syndrome is to look at renin/aldosterone levels, with antihypertensive medication having been discontinued for around 3 weeks if possible. This is because the pre-existing antihypertensive medications can impact upon the renin:aldosterone ratio. Clearly the diagnosis would be supported if aldosterone levels were raised in the presence of depressed renin levels.

A Fibromuscular hyperplasia

Fibromuscular hyperplasia is a cause of hypereninaemic hyperaldosteronism. Although it does cause hypertension, the marked reduction in potassium despite angiotensin-converting enzyme (ACE) inhibition as seen here would not be expected, and a rise in creatinine associated with ACE inhibition would be likely.

B Diabetic nephropathy

This patient fits the criteria for diabetes mellitus, although this is most likely early and is a chance finding here and not the cause of her hypertension. Renal dysfunction in type 2 diabetes is more commonly seen in older individuals and is a product of both sustained hypertension and diabetic nephropathy itself.

be expected, and a rise in creatinine associated with ACE inhibition would be likely.

B Diabetic nephropathy

This patient fits the criteria for diabetes mellitus, although this is most likely early and is a chance finding here and not the cause of her hypertension. Renal dysfunction in type 2 diabetes is more commonly seen in older individuals and is a product of both sustained hypertension and diabetic nephropathy itself.

D Cushing syndrome

Her BMI of 29 and the lack of obvious serious truncal obesity both count against Cushing as the underlying diagnosis here.

E Essential hypertension

The marked hypokalaemia and metabolic alkalosis on blood picture do not fit with a diagnosis of essential hypertension.

Rana Alnasser's screen

11:54

A 60-year-old woman on long-term therapy for depression has been referred by the Psychiatric Services. She presented acutely via the community psychiatric nurse with increasing drowsiness and confusion.

According to her carer, she had complained of increasing thirst and going to the bathroom over the past few days, and appeared to have been drinking more fluids over the past few weeks.

Investigations:

Na^+	156 mmol/l
Urea	20 mmol/l
Creatinine	205 µmol/l
Cl^-	112 mmol/l
Glucose	6.1 mmol/l
Ca^{++}	2.6 mmol/l

Which of the following medications is likely to be responsible for this lady's presentation?

A Paroxetine

B Fluoxetine

C Lithium

D Amitriptyline

E Chlorpromazine

32917

Rana Alnasser's screen

Urea	20 mmol/l
Creatinine	205 μmol/l
Cl^-	112 mmol/l
Glucose	6.1 mmol/l
Ca^{++}	2.6 mmol/l

Which of the following medications is likely to be responsible for this lady's presentation?

Your answer was correct

A Paroxetine

B Fluoxetine

C Lithium

D Amitriptyline

E Chlorpromazine

Explanation

C Lithium

This lady's long history of depression is likely to be related to bipolar disorder, which has resulted in a long-term script for lithium and her presentation with nephrogenic diabetes insipidus (DI), as shown by her hypernatraemia and picture of dehydration on blood testing. Causes of nephrogenic diabetes insipidus include an X-linked inherited disorder, an autosomal recessive pattern of inheritance, lithium, demeclocycline, chronic renal disease, post-obstructive

Explanation

C Lithium

This lady's long history of depression is likely to be related to bipolar disorder, which has resulted in a long-term script for lithium and her presentation with nephrogenic diabetes insipidus (DI), as shown by her hypernatraemia and picture of dehydration on blood testing. Causes of nephrogenic diabetes insipidus include an X-linked inherited disorder, an autosomal recessive pattern of inheritance, lithium, demeclocycline, chronic renal disease, post-obstructive uropathy, hypercalcaemia and hyperglycaemia. Therapy should only be stopped with the advice of her psychiatrist, although her symptoms are highly unlikely to improve unless the lithium therapy is ceased. Bendroflumethiazide and indomethacin may be useful in nephrogenic DI due to their local action on the kidney in cases that fail to respond to cessation of lithium: because both increase lithium levels they can't be given at the same time. Desmopressin (DDAVP) is a treatment for cranial diabetes insipidus and so is of little value here.

A Paroxetine

Paroxetine is a selective serotonin uptake inhibitor (SSRI), which is rarely associated with the serotonin syndrome but is not associated with nephrogenic diabetes insipidus.

B Fluoxetine

Like paroxetine, fluoxetine is an SSRI and is not associated with nephrogenic diabetes insipidus.

D Amitriptyline

Amitriptyline is a tricyclic antidepressant which may be associated with syndrome of inappropriate anti-diuretic

A 25-year-old patient presents with palpitations, anxiety and heat intolerance. She has a small, smooth goitre on palpation of her neck. BP is 122/72, with pulse is 88 and regular. There is a fine tremor at rest and she has sweaty palms. Urea and electrolytes are unremarkable, TSH is <0.01, and T4 and T3 are both elevated. Thyroid scanning reveals a uniformly increased uptake of technetium.

What diagnosis fits best with this clinical picture?

A	Grave's disease
B	Subacute thyroiditis
C	Toxic adenoma
D	Toxic multi-nodular goitre
E	Hashimoto's thyroiditis

Submit

Previous Q... Skip Questi...

© Pastest 2019

12:00

palpation of her neck. BP is 122/72, with pulse is 88 and regular. There is a fine tremor at rest and she has sweaty palms. Urea and electrolytes are unremarkable, TSH is <0.01, and T4 and T3 are both elevated. Thyroid scanning reveals a uniformly increased uptake of technetium.

What diagnosis fits best with this clinical picture?

Your answer was correct

A Grave's disease

B Subacute thyroiditis

C Toxic adenoma

D Toxic multi-nodular goitre

E Hashimoto's thyroiditis

Explanation

A Grave's disease

Thyrotoxicosis has a female:male ratio of 10 : 1 in the UK and affects 2% of the female population. Graves' disease is the commonest cause of thyrotoxicosis. It is associated with uniformly increased uptake on thyroid scanning. Treatment involves a period of block-replace therapy with carbimazole and thyroxine; this is followed in some patients by remission. In others the condition recurs and radioiodine therapy is the treatment of choice.

B Subacute thyroiditis

Rana Alnasser's screen

E Hashimoto's thyroiditis

Explanation

A Grave's disease

Thyrotoxicosis has a female:male ratio of 10 : 1 in the UK and affects 2% of the female population. Graves' disease is the commonest cause of thyrotoxicosis. It is associated with uniformly increased uptake on thyroid scanning. Treatment involves a period of block-replace therapy with carbimazole and thyroxine; this is followed in some patients by remission. In others the condition recurs and radioiodine therapy is the treatment of choice.

B Subacute thyroiditis

Subacute thyroiditis is associated with symptoms of hyperthyroidism, although other symptoms include a tender goitre and a short, flu-like illness, neither of which are reported here. Anti-thyroid drugs are not used in therapy; non-steroidals or a short course of prednisolone may be required.

C Toxic adenoma

The fact that there is a small, smooth goitre and uniform technetium uptake rules out a toxic adenoma.

D Toxic multi-nodular goitre

Toxic multinodular goitre is associated with a non-smooth goitre, thyrotoxicosis and patchy increased uptake on the technetium scan.

E Hashimoto's thyroiditis

An elderly man has routine blood tests taken before a hernia repair. Liver function tests are repeated twice, with calcium, alanine aminotransferase (ALT) and bilirubin in the normal range, but alkaline phosphatase is raised at 380. On further questioning he admits to drinking a glass of beer and smoking 5 cigarettes per day, and also to pain in his hips and lower back. He has recently been assessed for hearing loss.

Which of the following tests represents the best investigation to further confirm the diagnosis?

A Isotope bone scan

B Skeletal survey

C Immunoglobulin electrophoresis

D Ultrasound scan (USS) liver

E Chest X-Ray

Submit

12:02
MyPastest
https://mypastest.pastest.com
594-042-7551
Leave

An elderly man has routine blood tests taken before a hernia repair. Liver function tests are repeated twice, with calcium, alanine aminotransferase (ALT) and bilirubin in the normal range, but alkaline phosphatase is raised at 380. On further questioning he admits to drinking a glass of beer and smoking 5 cigarettes per day, and also to pain in his hips and lower back. He has recently been assessed for hearing loss.

Which of the following tests represents the best investigation to further confirm the diagnosis?

Your answer was correct

A Isotope bone scan

B Skeletal survey

C Immunoglobulin electrophoresis

D Ultrasound scan (USS) liver

E Chest X-Ray

Explanation

B Skeletal survey

The history and blood results here are suggestive of a diagnosis of Paget's disease. Recent evidence has suggested that limited skeletal survey is superior to bone scan for the assessment of the disease because, when

Audio Video Share Participants More

Explanation

B Skeletal survey

The history and blood results here are suggestive of a diagnosis of Paget's disease. Recent evidence has suggested that limited skeletal survey is superior to bone scan for the assessment of the disease because, when there is significant osteoclastic resorption of bone, bone scanning underestimates the extent of disease activity and still requires plain radiography for confirmation. Paget's is present in around 2% of the population over 55 years, this prevalence increasing with age, and the disease is also more common in men (sex ratio 3:2 men:women). Deafness may be a feature in up to half of all patients with skull base Paget's. Osteogenic sarcoma is a very rare complication of the disease. The mainstay of treatment is with bisphosphosphonates.

A Isotope bone scan

Bone scanning underestimates osteoclastic disease activity in Paget's disease, meaning that limited skeletal survey is the better option.

C Immunoglobulin electrophoresis

Immunoglobulin electrophoresis is most useful in the evaluation of multiple myeloma. The lack of other abnormal blood tests apart from alkaline phosphatase, and the recent assessment for hearing loss, are stronger pointers towards a diagnosis of Paget's disease.

D Ultrasound scan (USS) liver

Rana Alnasser's screen

ormal liver function tests, the

may be a feature in up to half of all patients with skull base Paget's. Osteogenic sarcoma is a very rare complication of the disease. The mainstay of treatment is with bisphosphosphonates.

A Isotope bone scan

Bone scanning underestimates osteoclastic disease activity in Paget's disease, meaning that limited skeletal survey is the better option.

C Immunoglobulin electrophoresis

Immunoglobulin electrophoresis is most useful in the evaluation of multiple myeloma. The lack of other abnormal blood tests apart from alkaline phosphatase, and the recent assessment for hearing loss, are stronger pointers towards a diagnosis of Paget's disease.

D Ultrasound scan (USS) liver

In the absence of other abnormal liver function tests, the elevation in alkaline phosphatase is much more likely to be related to bone turnover.

E Chest X-Ray

Although this patient has a smoking history, the lack of significant respiratory symptoms makes bronchial carcinoma less likely as an underlying diagnosis.

Rate this question:

Next Question

Previous Q Tag Questi Feedback End Session

A 23-year-old man presents to the clinic complaining of a lump at the base of his neck. He has noticed that this has become particularly prominent with swallowing and has grown significantly over the past 8 weeks. There is also a problem with diarrhoea over the past few months.

Clinical examination reveals a thyroid nodule. On further questioning, it transpires that his mother died during a thyroidectomy some years ago.

Investigations:

Hb	12.1 g/dl
WCC	5.4×10^9/l
PLT	203×10^9/l
Na^+	140 mmol/l
K^+	5.2 mmol/l
Creatinine	110 µmol/l
Ca^{++}	2.85 mmol/l
Ret oncogene	positive

Which of the following is the most likely diagnosis?

A Medullary thyroid carcinoma

B Papillary thyroid carcinoma

C Follicular thyroid carcinoma

D Anaplastic thyroid carcinoma

E Thyroid adenoma

E Thyroid adenoma

Explanation

A Medullary thyroid carcinoma

Ret oncogene positivity raises the possibility of multiple endocrine neoplasia type 2 (MEN-2). Occasionally patients suffer troublesome diarrhoea in response to increased calcitonin levels that cause increased gastrointestinal secretions. We are not given the calcitonin levels here, but it is to be assumed that they are likely to be raised. The thyroid nodule is most likely to be a medullary thyroid carcinoma. Given that his mother died on the operating table, the possibility of MEN-2 with co-existent phaeochromocytoma is further raised. The most appropriate initial screening test would be 24 h urine for catecholamines. MRI with or without meta-iodobenzylguanidine (MIBG) scanning is useful at a later stage for localising the site of a potential tumour. It is crucial to rule out a phaeochromocytoma, or to manage it appropriately with maximal alpha blockade, before progressing to thyroid surgery.

B Papillary thyroid carcinoma

Papillary thyroid carcinoma may be associated with RET mutations, but is also associated with mutations in RAS, BRAF and NTRK. The hypercalcaemia here is also more suggestive of MEN-2 because of co-associated hyperparathyroidism.

C Follicular thyroid carcinoma

Only a very small proportion of cases of follicular thyroid cancer (<5%) are thought to be related to a familial cancer

suggestive of MEN-2 because of co-associated hyperparathyroidism.

C Follicular thyroid carcinoma

Only a very small proportion of cases of follicular thyroid cancer (<5%) are thought to be related to a familial cancer syndrome. Associated syndromes include (PTEN)-hamartoma tumour syndrome/Cowden syndrome, familial adenomatous polyposis/Gardner syndrome, Carney complex type 1, Werner syndrome and Pendred syndrome.

D Anaplastic thyroid carcinoma

This is undifferentiated, fast growing and occurs most commonly in an elderly population.

E Thyroid adenoma

Thyroid adenomas are not rapidly growing and would not fit with the picture seen here of a potentially cancerous lesion.

Rate this question:

Next Question

Previous Q... Tag Questi... Feedback End Session

Blog About Pastest Contact Us Help

© Pastest 2019

You are asked to see a 24-year-old woman who is 8 weeks into her first pregnancy. She has suffered vomiting and is finding it difficult to maintain weight.

On examination, she is clearly anxious. Her BP is 105/70, with pulse 75 and regular. Her BMI is 22.

Investigations:

Hb	119 g/dl
WCC	5.7×10^9/l
PLT	212×10^9/l
Na^+	144 mmol/l
K^+	3.4 mmol/l
Creatinine	100 µmol/l
Glucose	4.8 mmol/l
Total T4	185 nmol/l (58–174)
TSH	0.6 mU/l (0.4–5)

Which of the following is the most appropriate management in this case?

A Start propylthiouracil

B Start carbimazole

C Start propylthiouracil and thyroxine (block-replace)

D Start thyroxine therapy

E Observe

E Observe

Explanation

E Observe

This patient has increased total T4 with a TSH which is in the normal range. There are no clinical signs of hyperthyroidism. The weight loss and vomiting are most likely to be related to hyperemesis gravidarum. Although normal in this case, TSH itself may be suppressed in 13.5% of patients in the first trimester due to the thyrotrophic effects of beta HCG. There is a twofold increase in thyroid-binding globulin levels in pregnancy due to a combination of reduced hepatic clearance of thyroid-binding globulin and increased synthesis in response to oestrogen. The increased level of thyroid-binding globulin plateaus at 20 weeks and then gradually falls. In this case thyroid binding globulin may be useful in confirming the diagnosis.

A Start propylthiouracil

Although thyrotoxicosis may occur in early pregnancy, the lack of symptoms of thyrotoxicosis here makes that much less likely as the underlying diagnosis, as does the fact that TSH is at the lower end of the normal range rather than being completely suppressed. Propylthiouracil is the treatment of choice for thyrotoxicosis in early pregnancy.

B Start carbimazole

Carbimazole is the preferred intervention for thyrotoxicosis in late pregnancy because of the risk of maternal hepatotoxicity associated with propylthiouracil use.

C Start propylthiouracil and thyroxine (block-

A 36-year-old man presents complaining of loss of libido and impotence. He finds work and entertaining clients very stressful.

Results of blood tests from GP were prolactin 3200 mU/l (< 360), normal thyroid function tests, MCV 100 fl, testosterone low. He admits on further questioning to drinking three glasses of wine per night. There is no reported visual field disturbance.

Which of the following is the most likely cause of his impotence?

A	Craniopharyngioma
B	Microprolactinoma
C	Alcohol abuse
D	Macroprolactinoma
E	Compression of pituitary stalk

Submit

© Pastest 2019

12:09

MyPastest
https://mypastest.pastest.com

A 36-year-old man presents complaining of loss of libido and impotence. He finds work and entertaining clients very stressful.

Results of blood tests from GP were prolactin 3200 mU/l (< 360), normal thyroid function tests, MCV 100 fl, testosterone low. He admits on further questioning to drinking three glasses of wine per night. There is no reported visual field disturbance.

Which of the following is the most likely cause of his impotence?

Your answer was correct

A Craniopharyngioma

B Microprolactinoma

C Alcohol abuse

D Macroprolactinoma

E Compression of pituitary stalk

Explanation

B Microprolactinoma

This patient's prolactin results are above 3000 mU/l, which is suggestive of a prolactinoma. The diagnostic test of choice would be MRI pituitary; microprolactinomas appear

E Compression of pituitary stalk

Explanation

B Microprolactinoma

This patient's prolactin results are above 3000 mU/l, which is suggestive of a prolactinoma. The diagnostic test of choice would be MRI pituitary; microprolactinomas appear as hypo-intense lesions within the pituitary on T1-weighted scanning. Given the fact that there are no signs of optic chiasm compression, and this patient's thyroid function tests are normal, it would be reasonable to give him a trial of dopamine agonist therapy. Surgery would be kept in reserve for this man if he was resistant or intolerant to drug therapy.

A Craniopharyngioma

Craniopharyngiomas are less likely to present with hyperprolactinaemia and more likely to present with diabetes insipidus, adrenal failure or pituitary-dependent hypothyroidism. Other focal neurological deficits as a result of local compression are also more likely to be seen.

C Alcohol abuse

Although there is evidence of alcohol abuse, including the raised MCV, this is unlikely to be the main cause of his problems.

D Macroprolactinoma

Levels of prolactin are usually above 6000 mU/l in macroprolactinoma.

E Compression of pituitary stalk

Craniopharyngiomas are less likely to present with hyperprolactinaemia and more likely to present with diabetes insipidus, adrenal failure or pituitary-dependent hypothyroidism. Other focal neurological deficits as a result of local compression are also more likely to be seen.

C Alcohol abuse

Although there is evidence of alcohol abuse, including the raised MCV, this is unlikely to be the main cause of his problems.

D Macroprolactinoma

Levels of prolactin are usually above 6000 mU/l in macroprolactinoma.

E Compression of pituitary stalk

Elevation in prolactin due to compression is smaller than that seen here.

Rate this question:

Next Question

Previous Q... Tag Questi... Feedback End Session

Blog About Pastest Contact Us Help

© Pastest 2019

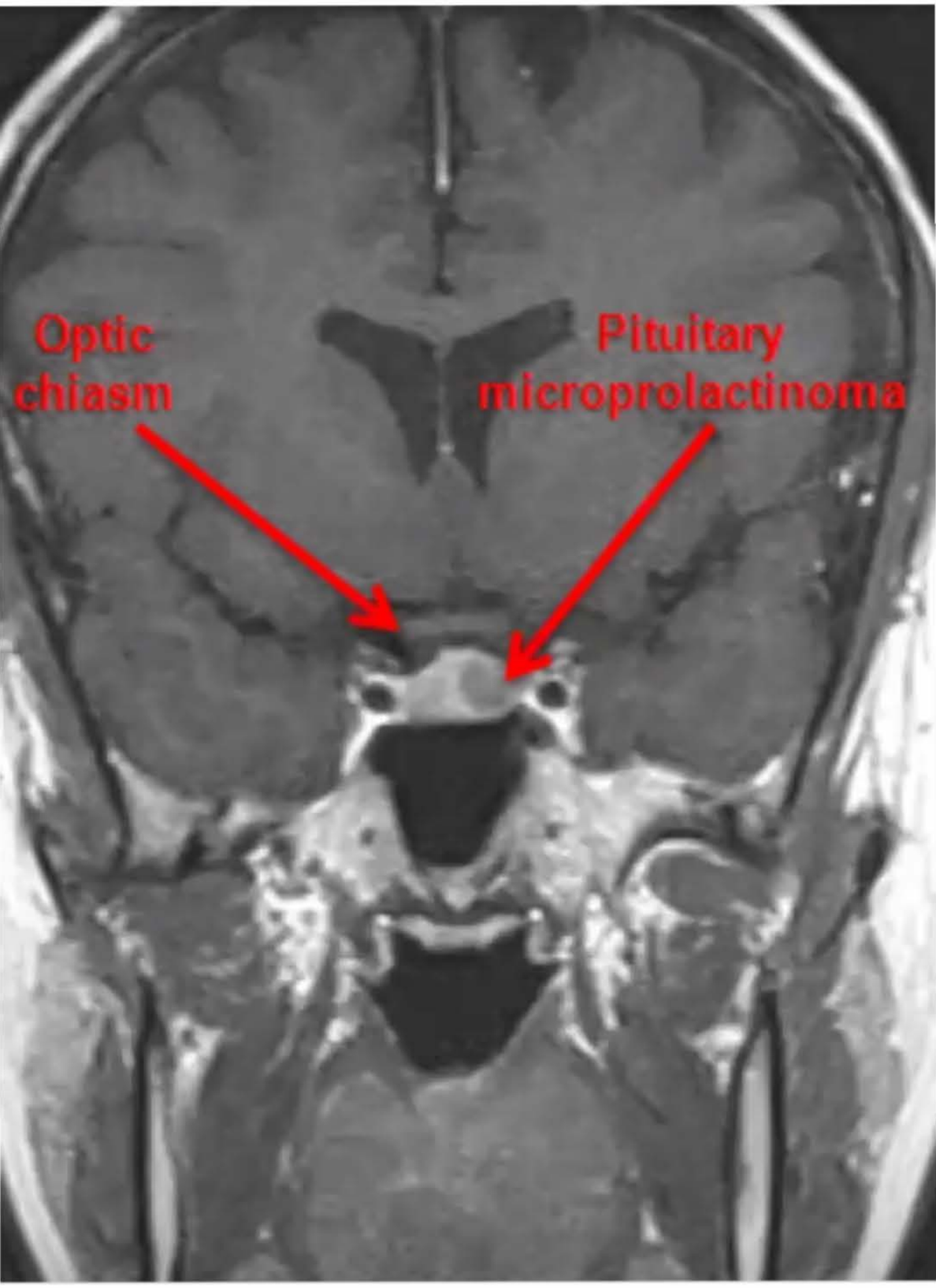

mage Library - Epocrates Online

d magnetic resonance imaging showing a left-sided 7 mm pituitary microprolactino

o copyright. Learn more

Updates Search Recent

CT/MRI

CT/MRI: Prolactinoma

Images may be subject to copyright. Learn more

RELATED IMAGES

Discover Updates Search Recent More

Rana Alnasser's screen

12:12
594-042-7551
Leave
73% 10:12

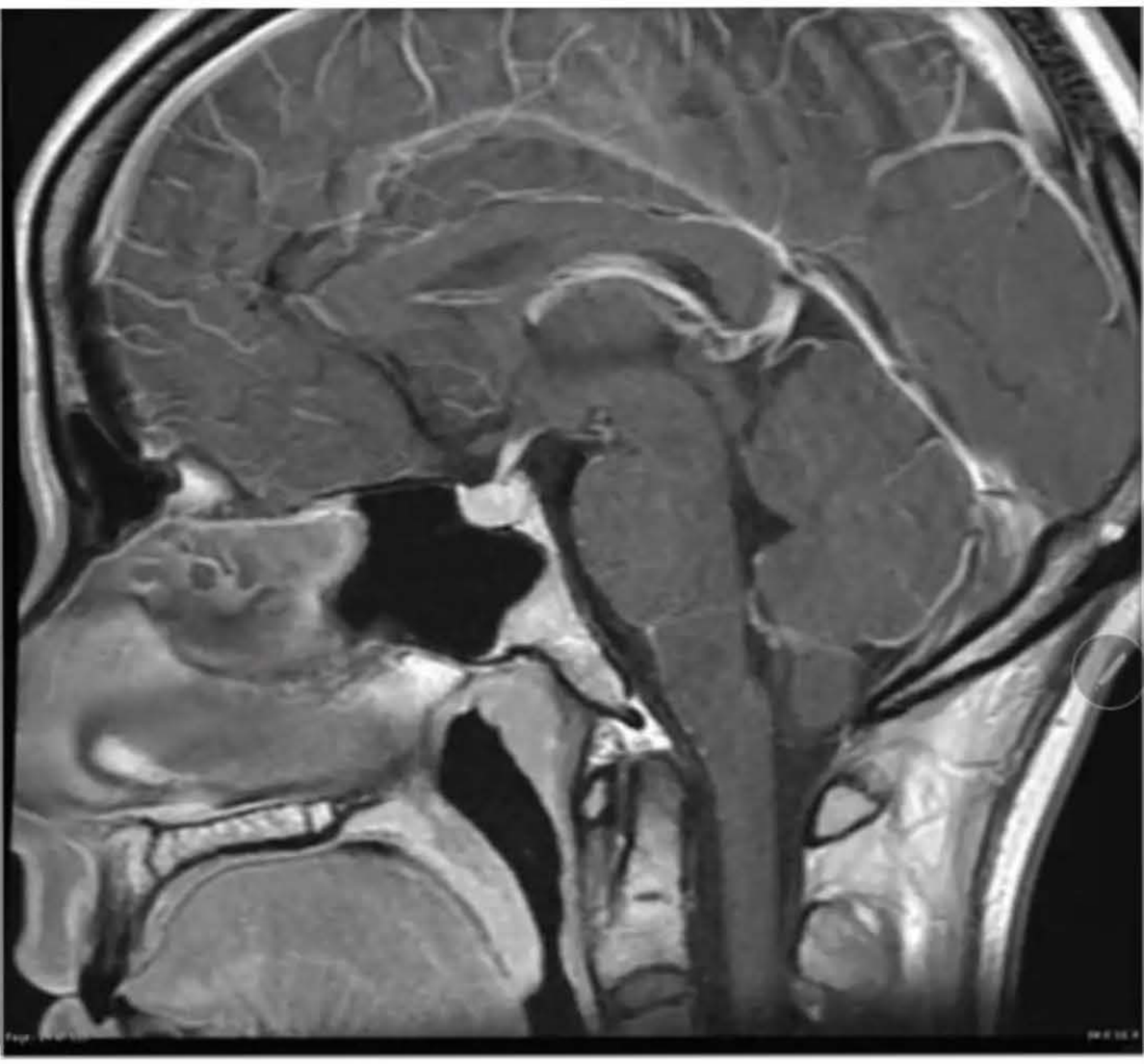

Radiopaedia
Pituitary MRI (an approach) | Radiology Reference Article ...
Pituitary MRI (an approach) | Radiology Reference Article | Radiopaedia.org
Images may be subject to copyright. Learn more
RELATED IMAGES
Discover
Updates
Search
Recent
More
Audio
Video
Share
Participants
More

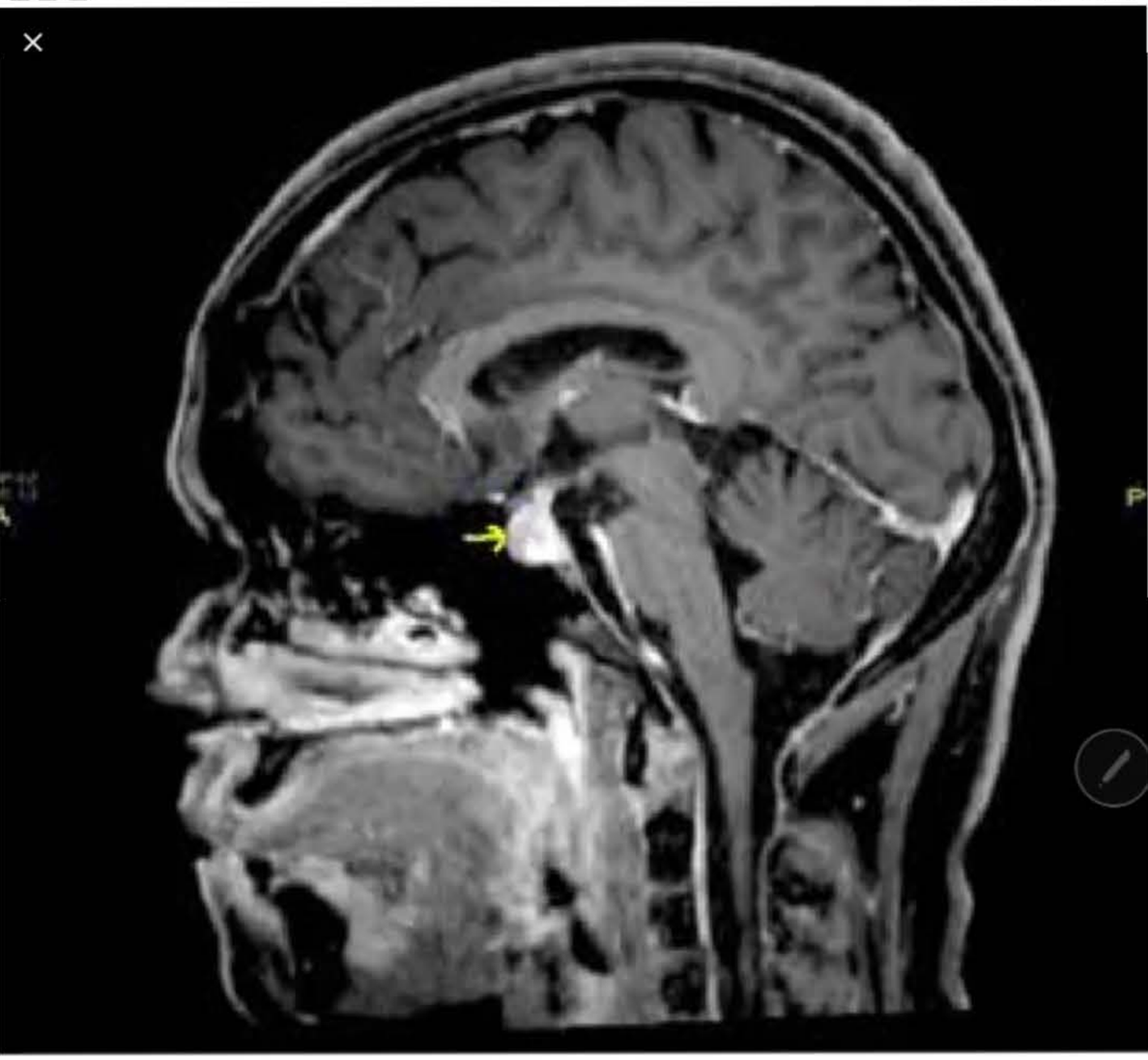

ResearchGate

MRI of the pituitary gland demonstrating homogeneous enhancement ...

MRI of the pituitary gland demonstrating homogeneous enhancement of pituitary tuberculoma with left intercavernous extension and

Images may be subject to copyright. Learn more

RELATED IMAGES

Discover Updates Search Recent More

Rana Alnasser's screen

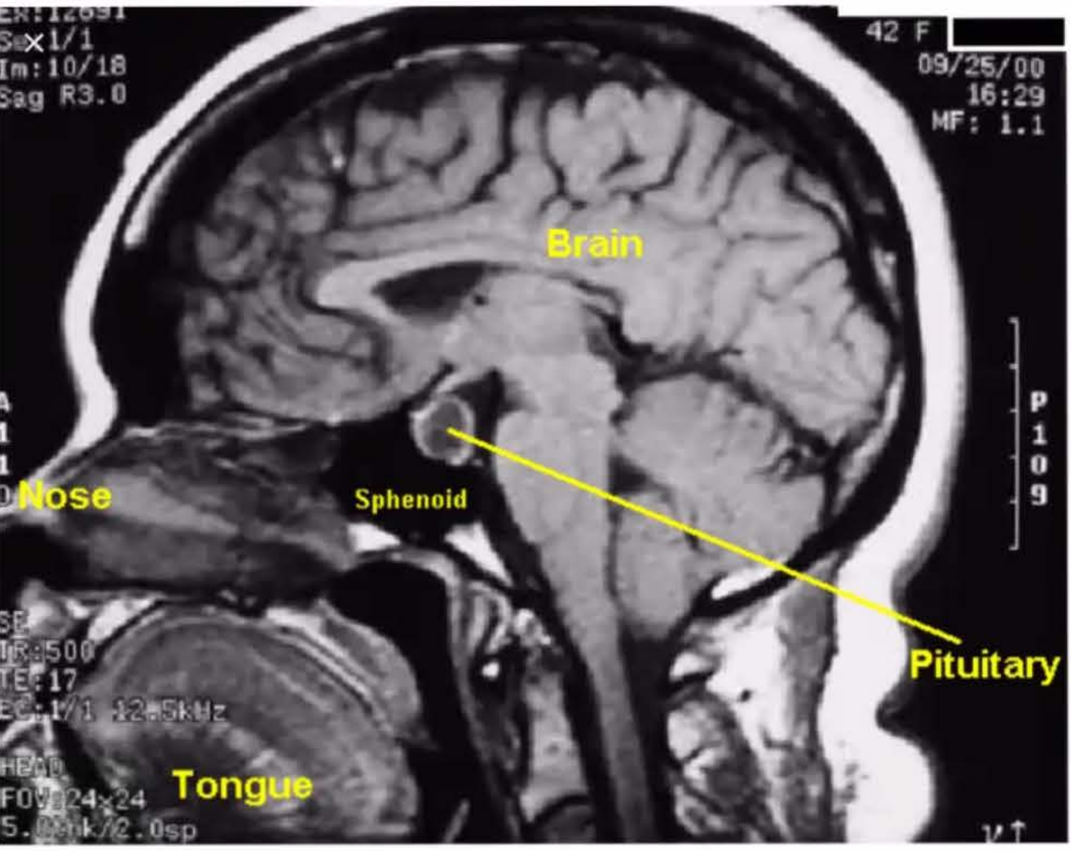

www.ghorayeb.com

Otolaryngology Houston - MRI Picture of Pituitary Adenoma

MRI Scan Showing a Pituitary Adenoma

Images may be subject to copyright. Learn more

RELATED IMAGES

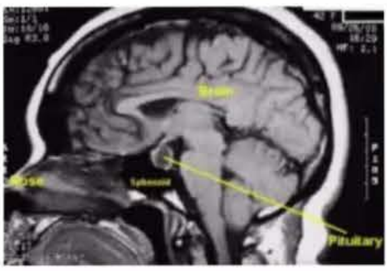

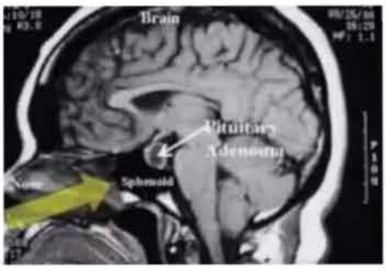

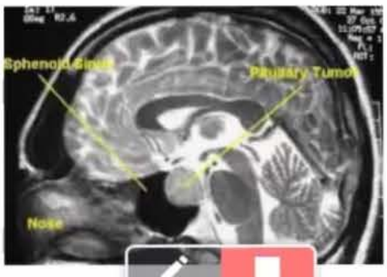

Discover Updates Search Recent More

12:14
MyPastest
https://mypastest.pastest.com

A 42-year-old woman is referred with difficult-to-treat hypertension. She is currently taking ramipril 10 mg daily and bendrofluazide 2.5 mg daily, yet recent blood pressure was 165/90 mmHg.

Past medical history in the family of subarachnoid haemorrhage was noted. She is currently being treated with amitriptyline for depression. Circulating calcitonin levels are elevated.

Examination in the clinic reveals a patient of normal body habitus, with a blood pressure of 170/90 mmHg. Abdominal ultrasound is suspicious of a left adrenal mass.

Which of the following is the most appropriate treatment for her blood pressure prior to surgery?

A	Doxazosin
B	Prazosin
C	Atenolol
D	Phenoxybenzamine
E	Propranolol

32900

Submit

Rana Alnasser's screen

A 42-year-old woman is referred with difficult-to-treat hypertension. She is currently taking ramipril 10 mg daily and bendrofluazide 2.5 mg daily, yet recent blood pressure was 165/90 mmHg.

Past medical history in the family of subarachnoid haemorrhage was noted. She is currently being treated with amitriptyline for depression. Circulating calcitonin levels are elevated.

Examination in the clinic reveals a patient of normal body habitus, with a blood pressure of 170/90 mmHg. Abdominal ultrasound is suspicious of a left adrenal mass.

Which of the following is the most appropriate treatment for her blood pressure prior to surgery?

Your answer was correct

A Doxazosin

B Prazosin

C Atenolol

D Phenoxybenzamine

E Propranolol

Explanation

D Phenoxybenzamine

This patient has difficult hypertension, a left adrenal mass

E Propranolol

Explanation

D Phenoxybenzamine

This patient has difficult hypertension, a left adrenal mass and raised calcitonin levels. The suspicion is that she has MEN-2a. Given the adrenal mass and hypertension, 24 h urinary catecholamines should be assessed to rule out phaeochromocytoma. Amitriptyline can interfere with catecholamine measurements and should be discontinued for 4 days prior to the measurements. Phenoxybenzamine is the most potent available alpha blocker, is non-selective and irreversible, and it is therefore the treatment of choice for phaeochromocytoma. Starting dose is 10 mg bd, which should be increased up to a maximum of 20 mg qds. Intravenous phenoxybenzamine is commonly used for the 3 days prior to surgery to ensure complete alpha blockade.

A Doxazosin

Conventional alpha blockers are insufficient to gain complete blood pressure control in phaeochromocytoma; as such, their use is not recommended here.

B Prazosin

Similar to doxazosin, prazosin is ineffective with respect to achieving adequate alpha blockade in phaeochromocytoma.

C Atenolol

When beta blockers are used in the absence of complete alpha blockade, a paradoxical rise in blood pressure can be seen in phaeochromocytoma; as such, they are only used

12:18
594-042-7551
Leave

A 23-year-old woman who is 10 weeks' pregnant is referred to the clinic by her GP. She is suffering from a great deal of tiredness and morning sickness. The GP is concerned about her thyroid function. She has lost 2 kg in weight over the past month. Her blood pressure is 115/82, with pulse 65 and regular.

Investigations:

TSH	0.2 U/l
Free T4	27 pmol/l (normal 10-22)

Which of the following is the most appropriate management for this patient?

A	Ask GP to repeat thyroid function tests in 2 months
B	Start propylthiouracil
C	Start carbimazole
D	Refer for partial thyroidectomy
E	Consider radioiodine

20625

Submit

Previous Q...
Skip Question
Audio
Video
Share
Participants
More

A Ask GP to repeat thyroid function tests in 2 months

Suppressed TSH with a small rise in free T4 is a normal finding in 13.5% of women in the first trimester, and 4.5% of women in the second trimester. Hyperemesis gravidarum is the most likely underlying condition. The suppressed TSH with slightly elevated levels of T4 is due to the partial thyroid-stimulating action of beta-HCG. No specific management is indicated. Thyroid function tests are likely to have returned to normal on retesting.

B Start propylthiouracil

At this stage of pregnancy, without overt symptoms of hyperthyroidism and with TSH and T4 only slightly outside the normal range, thionamides aren't indicated.

C Start carbimazole

Like propylthiouracil, carbimazole isn't indicated, because the overserved thyroid blood tests seen here are a normal physiological finding.

D Refer for partial thyroidectomy

Thyroidectomy is indicated for Graves' disease in pregnancy where medical therapy with thionamides is ineffective or contra-indicated.

E Consider radioiodine

Radioiodine is contra-indicated in pregnancy, and treatment isn't indicated because the thyroid function tests seen here are not as a result of thyrotoxicosis, but as a result of excess beta-HCG.

A 22-year-old woman with type 1 diabetes for the past 14 years presents for review. Recent Hb A_{1c} is elevated at 58mmol/mol. Her blood pressure in clinic is 125/80 mmHg. Past history of note includes a number of episodes of cystitis. She has dipstick-positive proteinuria and a timed urine sample confirms elevated urinary albumin excretion. There is no bacterial growth after incubation of a portion of the specimen. Renal ultrasound scan shows normal-sized kidneys.

Which of the following represents the most appropriate management of her proteinuria?

A	Long-term prophylactic antibiotics
B	Transition to an insulin pump
C	Angiotensin-converting enzyme (ACE) inhibition
D	Beta-blocker therapy
E	Calcium antagonist therapy

Submit

C Angiotensin-converting enzyme (ACE) inhibition

The EUCLID study looked at the effects of treating normotensive type 1 diabetes patients with microalbuminuria with lisinopril. This showed a 20% reduction in urinary albumin excretion versus placebo, but the active treatment group did also show a 3-mmHg reduction in blood pressure, which may have contributed. A similar study in normotensive type 2 diabetes patients with enalapril demonstrated a reduction in urinary albumin excretion. These two studies together are taken as evidence for ACE inhibition in normotensive microalbuminuric patients.

A Long-term prophylactic antibiotics

Prophylactic antibiotics may have a role in the management of kidney disease associated with vesicoureteric reflux, but used in the context of type 1 diabetes they may merely increase the risk of antibiotic resistance.

B Transition to an insulin pump

Although her Hb A_{1c} is mildly elevated, transition to an insulin pump to drive tighter glycaemic control will only result in a modest impact on renal disease progression.

D Beta-blocker therapy

Beta-blocker therapy is thought to be less effective than ACE inhibitors with respect to reducing proteinuria at a given blood pressure.

E Calcium antagonist therapy

Non dihydropyridine calcium channel antagonists such as diltiazem offer modest benefits in reducing proteinuria, but

A 48-year-old woman is referred to the Endocrine Clinic after routine blood testing at the GP surgery. She has no significant previous medical history; her only recent attendance at the doctor's was after fainting at a wedding when the weather was noted to be rather hot.

There was no other past history of note and examination revealed blood pressure of 112/82 mmHg. No previous history of hypertension was noted, nor any episodes of hypovolaemia.

Investigations:

Hb	12.2 g/dl
WCC	6×10^9/l
PLT	197×10^9/l
Na^+	141 mmol/l
K^+	3.0 mmol/l
Bicarbonate	32 mmol/l
Creatinine	90 μmol/l

Which of the following investigations would be most useful in pointing to the diagnosis?

A Renin and aldosterone levels

B Urinary electrolytes

C Renal ultrasound scan

D Renal biopsy

E Renal angiography

hypovolaemia.

Investigations:

Hb	12.2 g/dl
WCC	6×10^9/l
PLT	197×10^9/l
Na^+	141 mmol/l
K^+	3.0 mmol/l
Bicarbonate	32 mmol/l
Creatinine	90 μmol/l

Which of the following investigations would be most useful in pointing to the diagnosis?

Your answer was incorrect

A Renin and aldosterone levels

B Urinary electrolytes

C Renal ultrasound scan

D Renal biopsy

E Renal angiography

Explanation

A Renin and aldosterone levels

This patient has hypokalaemic alkalosis without evidence of

B Urinary electrolytes

C Renal ultrasound scan

D Renal biopsy

E Renal angiography

Explanation

A Renin and aldosterone levels

This patient has hypokalaemic alkalosis without evidence of hypovolaemia or hypertension. The presentation is typical of Gitelman syndrome presenting at older age, with no symptoms of hypovolaemia. Gitelman is caused by mutation in the thiazide-sensitive NaCl transporter, and resultant salt wasting leads to activation of the renin-angiotensin system also leading to raised aldosterone levels. It is the most common congenital renal tubular disorder in white people, with a prevalence of 1 in 40,000, and is associated with hypocalciuria and hypomagnesaemia. Treatment is with potassium and magnesium replacement. Where patients fail to respond to supplementation, potassium-sparing diuretics may be required to restore serum potassium levels.

B Urinary electrolytes

Urinary electrolytes may reveal low urinary calcium excretion, but this is less useful than renin and aldosterone levels as a pointer to the underlying diagnosis.

C Renal ultrasound scan

magnesium replacement. Where patients fail to respond to supplementation, potassium-sparing diuretics may be required to restore serum potassium levels.

B Urinary electrolytes

Urinary electrolytes may reveal low urinary calcium excretion, but this is less useful than renin and aldosterone levels as a pointer to the underlying diagnosis.

C Renal ultrasound scan

Renal ultrasound scanning is most useful in identifying kidney diameter as a pointer to the underlying cause of hypertension, rather than pointing to the cause of hypokalaemia when blood pressure is normal.

D Renal biopsy

Although not required for diagnosis, renal biopsy in Gitelman reveals hyperplasia of the juxtaglomerular apparatus and prominence of medullary interstitial cells. It is most useful in identifying the pathology underlying other causes of tubular dysfunction.

E Renal angiography

Renal angiography is considered post-renal ultrasound in the event that there is hypertension, differential kidney sizing, hypokalaemia, and hyper-reninaemic hyperaldosteronism, because of increased likelihood of renal artery stenosis as the underlying diagnosis.

Rate this question:

Next Question

A 42-year-old man with a 30-year history of type 1 diabetes comes to the clinic complaining of frequent falls. On two occasions he has fainted and knocked his head and had to be taken to the Emergency Department, and at other times he was dizzy, but a short period sitting down improved things for him. He has a history of peripheral neuropathy and erectile dysfunction. He takes a basal bolus insulin regime involving insulin glargine and meal time Novorapid™. He also takes ramipril 5 mg/day for renoprotection and indapamide 2.5 mg. On examination his BP is 145/80 mmHg with a postural drop of 35 mmHg systolic. He has signs consistent with peripheral sensory neuropathy to the mid-shin.

Investigations:

Hb	12.2 g/dl
WCC	5.4×10^9/l
PLT	201×10^9/l
Na^+	139 mmol/l
K^+	4.9 mmol/l
Creatinine	122 µmol/l
HbA1c	50 mmol/ml (6.73%)

Which of the following is the most appropriate next intervention?

A Elastic stockings

B Fludrocortisone

C Reduce prandial insulin

D Reduce background insulin

Novorapid™. He also takes ramipril 5 mg/day for renoprotection and indapamide 2.5 mg. On examination his BP is 145/80 mmHg with a postural drop of 35 mmHg systolic. He has signs consistent with peripheral sensory neuropathy to the mid-shin.

Investigations:

Hb	12.2 g/dl
WCC	5.4 x 10^9/l
PLT	201 x 10^9/l
Na^+	139 mmol/l
K^+	4.9 mmol/l
Creatinine	122 µmol/l
HbA1c	50 mmol/ml (6.73%)

Which of the following is the most appropriate next intervention?

A Elastic stockings

B Fludrocortisone

C Reduce prandial insulin

D Reduce background insulin

E Stop indapamide

Submit

E Stop indapamide

This patient has peripheral neuropathy and almost certainly has significant autonomic neuropathy, which accounts for the large postural drop in his blood pressure. A standing BP of 110 mmHg systolic is clearly acceptable, and therefore the most obvious first step is in stopping his indapamide and monitoring his blood pressure over the subsequent 2–4 weeks. If he still has significant postural hypotension then the next steps would be to add elastic stockings, followed by fludrocortisone. The history of pre-syncope is much more suggestive of changes in blood pressure rather than changes in blood glucose.

A Elastic stockings

Elastic stockings are a potential intervention for patients who have persistent postural hypotension despite discontinuing the thiazide-like diuretic.

B Fludrocortisone

Fludrocortisone is considered for patients who fail to respond to conservative measures such as elastic stockings.

C Reduce prandial insulin

The postural drop in blood pressure points to hypotension rather than hypoglycaemia as the cause of this patient's collapse.

D Reduce background insulin

Excess background insulin is primarily associated with fasting hypoglycaemia, which is not the cause of this patient's collapse given the obvious postural hypotension.

A 48-year-old woman presents with a two-week history of malaise and anterior neck pain. She tells you she has been suffering from what seems like a severe flu-like illness. On examination her pulse is 118 and regular and her blood pressure is 132/74 mmHg. She has a fine tremor and her palms are moist. She has a slightly enlarged, smooth tender thyroid.

Investigations:

T_4	40 nmol/l
TSH	<0.01 mU/l
ESR	40 mm/h

Which of the following is the most likely diagnosis?

A Toxic multinodular goitre

B Graves' disease

C Toxic solitary nodule

D Medullary carcinoma of the thyroid

E Subacute thyroiditis

Submit

Explanation

E Subacute thyroiditis

This is a description of subacute (De Quervain's) thyroiditis, which usually presents with malaise and neck pain. The neck pain can radiate to the ear or occiput. There is often tenderness and nodularity of the thyroid. ESR is often elevated. A Technetium-99m scan shows no technetium uptake by the thyroid. Mild cases can be treated with non-steroidal anti-inflammatory drugs (NSAIDs), but more severe cases associated with hyperthyroidism should be treated with prednisolone 30 mg/day. The prednisolone can be stopped when the T_4 normalises. Treatment with carbimazole is not indicated.

A Toxic multinodular goitre

A nodular enlarged thyroid gland is expected in toxic multinodular goitre, with a more prolonged period of symptoms of hyperthyroidism.

B Graves' disease

Graves' is associated with smooth enlargement of the thyroid, often with only mild tenderness. Symptoms of thyrotoxicosis also occur over a more prolonged period.

C Toxic solitary nodule

Toxic adenoma is not associated with generalised tenderness of the thyroid gland, and symptoms of thyrotoxicosis build up over a period of weeks and months.

D Medullary carcinoma of the thyroid

Medullary carcinoma of the thyroid is a C-cell (calcitonin-

A 45-year-old lady with diabetes mellitus presents with this ulcer on her foot. Her posterior tibial pulses are easily felt, but her dorsalis pedis pulses are not palpable. Pinprick and vibration perception are absent from the knee down.

Sole of the patient's left foot.

Which of the following represents the likely aetiology of this ulcer?

A	Primary infection
B	Diabetic peripheral neuropathy
C	Combined neuropathy and arterial insufficiency
D	Venous insufficiency
E	Arterial insufficiency

Explanation

B Diabetic peripheral neuropathy

This is a typical neuropathic ulcer, with callus forming the edge and a clean base. These are commonly found on the pressure points of the feet and are painless. Ten per cent of people have absent dorsalis pedis pulses; therefore, their absence does not indicate ischaemia. Off-loading is the key intervention with respect to driving successful ulcer healing, although many patients find this difficult to achieve.

C Combined neuropathy and arterial insufficiency

There are no features such as pallor, cold extremities and trophic changes including loss of hair and nail dystrophy to suggest arterial insufficiency.

A Primary infection

Around 50% of diabetic foot ulcers may become infected, although primary infection is not the usual cause of plantar lesions like this.

D Venous insufficiency

Venous insufficiency results in ulceration with slough and debris formation, primarily over the medial malleolus.

E Arterial insufficiency

Arterial insufficiency results in loss of temperature in the feet, pallor and trophic changes including loss of hair and nail dystrophy. These changes are not seen here.

Rana Alnasser's screen

www.apligraf.com

Diabetic Foot Ulcer Treatment Video

Images may be subject to copyright. Learn more

RELATED IMAGES

Diabetic Foot Ulcers — Edixomed
edixomed.com

October | 2011 | The Barefoot Weave
thebarefootweave.wordpress.com

Discover Updates Search

12:36
594-042-7551
Leave

82% 10:36

Feature	Ulcer Type			
	Venous	Arterial	Neuropathic Diabetic	Pressure
Underlying condition	Varicose veins, previous deep-vein thrombosis, obesity, pregnancy, recurrent phlebitis	Diabetes, hypertension, smoking, previous vascular disease	Diabetes, trauma, prolonged pressure	Limited mobility
Ulcer location	Area between the lower calf and the medial malleolus	Pressure points, toes and feet, lateral malleolus and tibial areas	Plantar aspect of foot, tip of the toe, lateral to fifth metatarsal	Bony prominences, heel
Ulcer characteristic	Shallow and flat margins, moderate-to-heavy exudate, slough at base with granulation tissue	Punched out and deep, irregular shape, unhealthy wound bed, presence of necrotic tissue, minimal exudate unless infected	Deep, surrounded by callus, insensate	Deep, often macerated
Condition of leg or foot	Hemosiderin staining, thickening and fibrosis, eczematous and itchy skin, limb edema, normal capillary refill	Thin shiny skin, reduced hair growth, cool skin, pallor on leg elevation, absent or weak pulses, delayed capillary refill, gangrene	Dry, cracked, insensate, calluses	Atrophic skin, loss of muscle mass
Treatment	Compression therapy, leg elevation, surgical management	Revascularization, antiplatelet medications, management of risk factors	Off-loading of pressure, topical growth factors	Off-loading of pressure; reduction of ex[illegible] moist[illegible] friction; adequate nutrition

NEJM Resident 360

Evaluation and Management of Lower-Extremity Ulcers | NEJM ...

Venous, Arterial, Neuropathic Diabetic, and Pressure Ulcers.

Images may be subject to copyright. Learn more

RELATED IMAGES

Discover Updates Search Recent More

Audio Video Share Participants More

12:39
594-042-7551
Leave

An 18-year-old presents to her GP with a chest infection. The GP takes routine blood tests and notices that her glucose is just into the range for diabetes. He refers her to the Diabetic Clinic, where you see her and take a full history. At the time of the test, she had been unwell for 1 week with a chest infection. She has no other medical history and is normally fit and well. Her grandmother, mother and sister all have diabetes, which presented when they were young. Her mother's and sister's diabetes is diet-controlled only. Her grandmother has only started to need insulin recently. She has two older brothers who do not have diabetes. Her family are all very health conscious and do not smoke, do not drink excessive alcohol and exercise regularly. They all maintain a BMI around 20.

Her fasting venous glucose is 12 mmol/l.

How would you best describe the likely diagnosis in her case?

A	Incidental hyperglycaemia
B	Type-1 diabetes mellitus
C	Type-2 diabetes mellitus
D	Syndrome X
E	Maturity-onset diabetes of the young (MODY)

Audio Video Share Participants More

regularly. They all maintain a BMI around 20.

Her fasting venous glucose is 12 mmol/l.

How would you best describe the likely diagnosis in her case?

Your answer was correct

A	Incidental hyperglycaemia
B	Type-1 diabetes mellitus
C	Type-2 diabetes mellitus
D	Syndrome X
E	Maturity-onset diabetes of the young (MODY)

Explanation

E	Maturity-onset diabetes of the young (MODY)

Maturity-onset diabetes is a genetic subgroup of diabetes characterised by autosomal-dominant inheritance, early onset, non-insulin-dependent diabetes and results from a monogenic defect leading to defects of either insulin sensing or insulin release. MODY3 is particularly important to diagnose as many patients initially treated with insulin can in fact be managed with sulphonylurea.

A	Incidental hyperglycaemia

The FPG result of 12 is well into the abnormal range. Coupled with the probable autosomal-dominant inheritance of diabetes, MODY is the more likely diagnosis.

12:42

84% 10:42

Table 1. Classification of subtypes of MODY diabetes

MODY subtype	GEN	Monogenic phenotype
MODY 1	HNF4A	Progressive and severe ß-cell dysfunction.
MODY 2	Glucokinase (GCK)	Mild to moderate and stable hyperglycaemia; glucose regulation exists, but at a higher level.
MODY 3	HNF1A (TCF1)	Progressive and severe ß-cell dysfunction.
MODY 4	IPF-1 (PDX1)	Progressive and severe ß-cell dysfunction. Pancreatic agenesis if the mutation is homozygous.
MODY 5	HNF1 B (TCF2)	Progressive and severe ß-cell dysfunction; renal and genital abnormalities.
MODY 6	Neuro D1	Progressive and moderately severe ß-cell dysfunction.
MODY 7	CEL (Carboxyl ester lipase)	Variable diabetes. Exocrine pancreatic insufficiency.

Adapted from Weedon, Frayling and Raeder[27,28]

GuíaSalud

GuíaSalud. CPG Diabetes Mellitus. English full version. Definition.

MODY diabetes is considered a monogenic disease, of autosomal dominant inheritance (presence of the mutation in heterozygosity), and currently at least ...

Images may be subject to copyright. Learn more

RELATED IMAGES

Genetic classification of autosomal dominan...
researchgate.net

MODY subtypes (4 most common in descen...
researchgate.net

Discover Updates Search Recent More

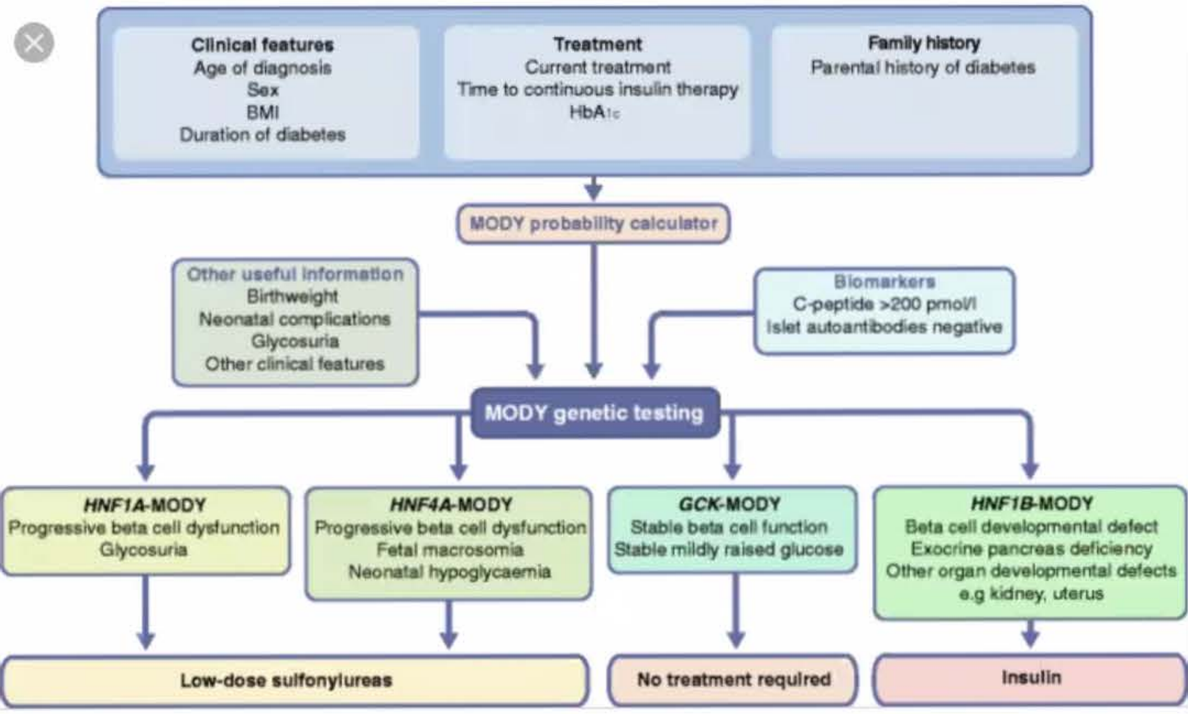

Springer Link

Precision diabetes: learning from monogenic diabetes | SpringerLink

Open image in new window ...

Images may be subject to copyright. Learn more

RELATED IMAGES

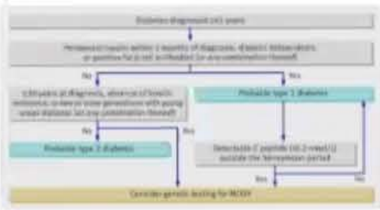

Diagnosis and management of maturity onse...
bmj.com

A UK nationwide prospective study of treatm...
link.springer.com

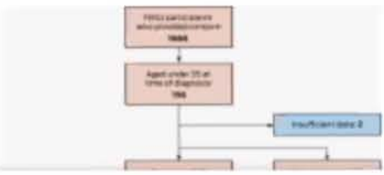

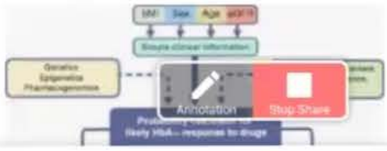

Discover Updates Search Recent More

A 16-year-old girl of Greek origin comes to the clinic with failure to maintain normal growth and development. She has Beta-thalassaemia major and receives regular blood transfusions to maintain her Hb in the range of 9-10 g/dl. You arrange some blood tests:

Investigations;

Hb	95 g/dl
WCC	7.1×10^9/l
PLT	174×10^9/l
Na^+	130 mmol/l
K^+	5.3 mmol/l
Creatinine	90 µmol/l
Free T4	6.5 nmol/l
9am cortisol	52 nmol
IGF-1	2.5 nmol/l (9.3-56)
FSH	0.2

Which of the following is the most appropriate replacement therapy to begin with?

A Growth hormone

B Hydrocortisone

C Oestrogen

D Thyroxine

E Fludrocortisone

D Thyroxine

E Fludrocortisone

Explanation

B Hydrocortisone

This patient has pituitary dysfunction, which has almost certainly been caused by iron overload. Her blood testing is consistent with a diagnosis of pan-hypopituitarism, but it is corticosteroid replacement that is essential first to avoid the possibility of precipitating an adrenal crisis.

A Growth hormone

Although chronic growth hormone deficiency is associated with tiredness, lethargy and a reduction in muscle mass, it is hydrocortisone that is the more important replacement therapy to start first.

C Oestrogen

Sex hormone replacement is important, particularly to enable this patient to maintain good bone health, but it can be commenced later.

D Thyroxine

Thyroxine replacement is essential, but should be begun shortly after hydrocortisone has commenced to avoid precipitating an adrenal crisis.

E Fludrocortisone

Rana Alnasser's screen

certainly been caused by iron overload. Her blood testing is consistent with a diagnosis of pan-hypopituitarism, but it is corticosteroid replacement that is essential first to avoid the possibility of precipitating an adrenal crisis.

A Growth hormone

Although chronic growth hormone deficiency is associated with tiredness, lethargy and a reduction in muscle mass, it is hydrocortisone that is the more important replacement therapy to start first.

C Oestrogen

Sex hormone replacement is important, particularly to enable this patient to maintain good bone health, but it can be commenced later.

D Thyroxine

Thyroxine replacement is essential, but should be begun shortly after hydrocortisone has commenced to avoid precipitating an adrenal crisis.

E Fludrocortisone

This is only necessary in patients with adrenal insufficiency who are unable to maintain normal blood pressure control.

Rate this question:

Rana Alnasser's screen

You review a 32-year-old man with a history of type 1 diabetes who is complaining of tiredness, lethargy and weight loss. He also tells you that he has fainted on three occasions over the past 2 months. He admits to nausea and vomiting. He has been working in Spain for some months.

On examination, he is very thin and you notice he is tanned. His blood pressure is 102/65 mmHg, with a postural drop of 12 mmHg on standing.

Investigations:

T4	5.7 pmol/l (10-22)
Na^+	132 mmol/l
K^+	5.2 mmol/l
Glucose	5.8 mmol/l
Urea	9.1 mmol/l

He has a normochromic, normocytic anaemia.

Which one of the following is the best way to diagnose the cause of his symptoms?

A	9 am cortisol and ACTH measurement
B	Thyroid auto-antibodies
C	CT head scan
D	Urine sodium and osmolality
E	Transferrin saturation

On examination, he is very thin and you notice he is tanned. His blood pressure is 102/65 mmHg, with a postural drop of 12 mmHg on standing.

Investigations:

T4	5.7 pmol/l (10-22)
Na^+	132 mmol/l
K^+	5.2 mmol/l
Glucose	5.8 mmol/l
Urea	9.1 mmol/l

He has a normochromic, normocytic anaemia.

Which one of the following is the best way to diagnose the cause of his symptoms?

Your answer was correct

A 9 am cortisol and ACTH measurement

B Thyroid auto-antibodies

C CT head scan

D Urine sodium and osmolality

E Transferrin saturation

Explanation

A 9 am cortisol and ACTH measurement

This man has adrenal insufficiency until proven otherwise.

A 9 am cortisol and ACTH measurement

This man has adrenal insufficiency until proven otherwise. This is illustrated by his blood picture of hyponatraemia, hyperkalaemia (levels may have been blunted by vomiting), raised urea and normochromic normocytic anaemia. Nine am cortisol and adrenocorticotrophic hormone (ACTH) levels are a very sensitive way to detect adrenal insufficiency, with inappropriately low cortisol levels compared to raised ACTH levels indicating a positive diagnosis.

Around 70% of cases of adrenal insufficiency occur due to autoimmune destruction of the adrenal glands, adrenal insufficiency occurring with increased frequency in patients with a history of type 1 diabetes or other autoimmune disease. Malignant destruction and infection by tuberculosis are other possible causes.

B Thyroid auto-antibodies

Thyroid dysfunction is likely to be as a result of the severe non-thyroidal illness, and antibody testing is therefore of no value here. Raised thyroid-stimulating hormone (TSH) and reduced T4 levels are often seen at the point of diagnosis of hypoadrenalism. Commencing thyroid hormone replacement may actually worsen the adrenal crisis, and thyroid function testing should be repeated a few weeks after stabilising glucocorticoid replacement.

C CT head scan

Given this patient has increased skin pigmentation, hypoadrenalism related to adrenal rather than pituitary failure is much more likely here, and hence CT head is not of value.

D Urine sodium and osmolality

tuberculosis are other possible causes.

B Thyroid auto-antibodies

Thyroid dysfunction is likely to be as a result of the severe non-thyroidal illness, and antibody testing is therefore of no value here. Raised thyroid-stimulating hormone (TSH) and reduced T4 levels are often seen at the point of diagnosis of hypoadrenalism. Commencing thyroid hormone replacement may actually worsen the adrenal crisis, and thyroid function testing should be repeated a few weeks after stabilising glucocorticoid replacement.

C CT head scan

Given this patient has increased skin pigmentation, hypoadrenalism related to adrenal rather than pituitary failure is much more likely here, and hence CT head is not of value.

D Urine sodium and osmolality

Relative dehydration and increased urinary sodium loss are both likely consequences of hypoadrenalism. Urine assay of sodium and osmolality won't, however, determine the underlying cause.

E Transferrin saturation

Transferrin saturation is useful in diagnosing haemochromatosis, which does present with increased skin pigmentation, although this is against a background of a type 2 diabetes-like picture with arthritis and erectile dysfunction due to low levels of testosterone.

Rate this question:

A 24-year-old woman presents to her general practitioner (GP) for a 10 week early pregnancy check. She complains of mild lethargy and he checks some thyroid function tests. Thyroid-stimulating hormone (TSH) is 0.3 mU/l (0.4–5) and free thyroxine (T_4) is 27 pmol/l (10–22). He diagnoses thyrotoxicosis and refers her to you for an opinion.

What is the best next management step for this patient?

A	Observation
B	Start carbimazole therapy
C	Start propylthiouracil therapy
D	Refer for radioiodine
E	Refer for thyroid uptake scan

6465

Submit

© Pastest 2019

A 24-year-old woman presents to her general practitioner (GP) for a 10 week early pregnancy check. She complains of mild lethargy and he checks some thyroid function tests. Thyroid-stimulating hormone (TSH) is 0.3 mU/l (0.4–5) and free thyroxine (T_4) is 27 pmol/l (10–22). He diagnoses thyrotoxicosis and refers her to you for an opinion.

What is the best next management step for this patient?

Your answer was correct

A	Observation
B	Start carbimazole therapy
C	Start propylthiouracil therapy
D	Refer for radioiodine
E	Refer for thyroid uptake scan

Explanation

A Observation

This patient has no symptoms of thyrotoxicosis, with a thyroid-stimulating hormone (TSH) level just below the normal range and a thyroxine (T_4) just above the normal range. It is a feature of normal pregnancy that triiodothyronine (T_3) and T_4 levels show a slight increase in the first trimester due to human chorionic gonadotrophin (HCG) stimulation. TSH may be mildly suppressed in up to 13.5% of pregnancies during the first trimester, and this is

D	Refer for radioiodine
E	Refer for thyroid uptake scan

Explanation

A	Observation

This patient has no symptoms of thyrotoxicosis, with a thyroid-stimulating hormone (TSH) level just below the normal range and a thyroxine (T_4) just above the normal range. It is a feature of normal pregnancy that triiodothyronine (T_3) and T_4 levels show a slight increase in the first trimester due to human chorionic gonadotrophin (HCG) stimulation. TSH may be mildly suppressed in up to 13.5% of pregnancies during the first trimester, and this is considered a normal variant. Thyroid-binding globulin has a twofold increase in concentration during pregnancy as a result of reduced hepatic clearance and increased synthesis under oestrogen stimulus. The rise plateaus out at week 20 and then begins to fall in the postpartum period. When there are TSH receptor antibodies present at high concentration they may cross the placenta.

B	Start carbimazole therapy

Carbimazole is used for treating *bona fide* thyrotoxicosis in pregnancy, and is used late in pregnancy because of potential risks of propylthiouracil and maternal hepatotoxicity.

C	Start propylthiouracil therapy

Propylthiouracil is used for treating thyrotoxicosis in early pregnancy, but in this case the abnormal TFTs are likely to be related to normal physiology.

12:58
594-042-7551
Leave

considered a normal variant. Thyroid-binding globulin has a twofold increase in concentration during pregnancy as a result of reduced hepatic clearance and increased synthesis under oestrogen stimulus. The rise plateaus out at week 20 and then begins to fall in the postpartum period. When there are TSH receptor antibodies present at high concentration they may cross the placenta.

B Start carbimazole therapy

Carbimazole is used for treating *bona fide* thyrotoxicosis in pregnancy, and is used late in pregnancy because of potential risks of propylthiouracil and maternal hepatotoxicity.

C Start propylthiouracil therapy

Propylthiouracil is used for treating thyrotoxicosis in early pregnancy, but in this case the abnormal TFTs are likely to be related to normal physiology.

D Refer for radioiodine

Radioiodine is contraindicated in pregnancy because of the risk of causing hypothyroidism in the unborn child.

E Refer for thyroid uptake scan

This won't inform management in this case, and isotope scanning is avoided if possible in pregnancy.

Rate this question:

Next Question

Audio Video Share Participants More

12:59
594-042-7551
Leave

A 42-year-old type-2 diabetic woman presents with recurrent urinary tract infections. She has been treated with a number of antibiotics including trimethoprim, ciprofloxacin and amoxicillin. She still complains of dysuria and some soreness in her groin. Her most recent Hb A_{1c} was 108 mmol/mol (12%). USS abdomen demonstrated no structural abnormalities or evidence of pyelonephritis.

What is the most likely causative agent?

A	Extended spectrum beta-lactamase-producing *coli*
B	Methicillin-resistant *Staphylococcal aureus* (MRSA)
C	*Candida albicans*
D	*Neisseria gonorrhoea*
E	*Chlamydia trachomatis*

Submit

Blog About Pastest Contact Us Help
Audio Video Share Participants More

Explanation

A	Extended spectrum beta-lactamase-producing *coli*

Data from the American Diabetes Association have shown that **9.4% of people diagnosed with type 2 diabetes** had a UTI compared to **only 5.7%** of those without. The most common pathogens isolated from the urine of diabetic patients with UTI were *E. coli* and other Enterobacteriaceae such as *Klebsiella* spp., *Proteus* spp., *Enterobacter* spp. and Enterococci.

Multiple courses of antibiotic therapy in these patients, and increased incidence of hospital-acquired and catheter-associated UTI, induce the development of antibiotic-resistant urinary pathogens.

Infection with ESBL-producing *E. coli* is an increasingly recognised cause of infection in diabetes patients and is associated with poor outcomes. ESBLs are enzymes that open the beta-lactam ring, inactivating the antibiotic and consequently conferring resistance to most beta-lactam antibiotics such as pencillins and cephalosporins. Some ESBL isolates have been shown to be resistant to antibiotics commonly used for UTI, such as trimethoprim and ciprofloxacin.

Carbapenems are generally considered the drug of choice for the treatment of ESBL/*E. coli* (ESBL-EC) infections. With a half-life of 4 h, ertapenem is commonly used as it is administered only once daily. Fosfomycin is an oral antibiotic agent that has broad activity against multi-drug-resistant pathogen, including ESBL-EC. Another oral antimicrobial agent that can be considered for the treatment of ESBL-EC cystitis is nitrofurantoin.

C	*Candida albicans*

Candida urinary tract infections (UTIs) also occur

1:05

A 48-year-old man who suffers from epilepsy presents to his general practitioner (GP) for review. His medication has recently been changed after an increase in his fit frequency, and he is now taking carbamazepine.

In the past week, he has complained of increasing headaches, tiredness and lethargy. In addition, his wife reports that he appears intermittently confused at times.

What diagnosis fits best with this clinical picture?

A	Complex partial seizures
B	Temporal lobe epilepsy
C	Drug-related hypernatraemia
D	Drug related hyponatraemia
E	Intra-cranial tumour

71145

Submit

Previous Q... Skip Questi...

© Pastest 2019

Rana Alnasser's screen

A 48-year-old man who suffers from epilepsy presents to his general practitioner (GP) for review. His medication has recently been changed after an increase in his fit frequency, and he is now taking carbamazepine.

In the past week, he has complained of increasing headaches, tiredness and lethargy. In addition, his wife reports that he appears intermittently confused at times.

What diagnosis fits best with this clinical picture?

Your answer was correct

A	Complex partial seizures
B	Temporal lobe epilepsy
C	Drug-related hypernatraemia
D	Drug related hyponatraemia
E	Intra-cranial tumour

Explanation

D Drug related hyponatraemia

We are told that this patient has recently commenced carbamazepine therapy, and we are also aware that he is complaining of symptoms that may suggest hyponatraemia. Syndrome of Inappropriate antidiuretic hormone (ADH) secretion (SIADH), is a recognised side effect of carbamazepine therapy. Other drugs that may result in SIADH include vincristine, vinblastine, cyclophosphamide, chlorpropamide, clofibrate

D Drug related hyponatraemia

E Intra-cranial tumour

Explanation

D Drug related hyponatraemia

We are told that this patient has recently commenced carbamazepine therapy, and we are also aware that he is complaining of symptoms that may suggest hyponatraemia. Syndrome of Inappropriate antidiuretic hormone (ADH) secretion (SIADH), is a recognised side effect of carbamazepine therapy. Other drugs that may result in SIADH include vincristine, vinblastine, cyclophosphamide, chlorpropamide, clofibrate, phenothiazines and monamine oxidase uptake inhibitors. Criteria for diagnosis include normal renal, adrenal and thyroid function, with hyponatraemia and hypotonic plasma (< 270 mOsmol/kg). In addition, urine osmolality should be inappropriately high and there should be excessive renal sodium loss of at least 20 mmol/l. In this case the best treatment option would be to consider switching to another suitable anti-epileptic agent.

A Complex partial seizures

A complex partial seizure, now known as a focal impaired awareness seizure according to the updated classification system from the International League Against Epilepsy (ILAE), starts focally within the brain and causes impairment of consciousness. In most patients, focal impaired awareness seizures represent underlying temporal lobe epilepsy. Focal impaired awareness seizures typically last 30–120 s. Longer seizures may occur when these become generalised with full-body convulsions or

Temporal lobe seizures often begin with a motionless stare followed by oral or manual automatisms, symptoms and signs which are not present in this scenario.

C Drug-related hypernatraemia

This is strictly defined as a hyperosmolar condition caused by a decrease in total body water relative to electrolyte content. Hypernatremia is a 'water problem', not a problem of sodium homeostasis. Patients developing hypernatremia outside of the hospital are generally elderly people who are mentally and physically impaired, often with an acute infection.

E Intra-cranial tumour

Manifestations of intra-cranial tumours nay be non-specific and include headache (new onset or different in nature), altered mental status, ataxia, nausea, vomiting, limb weakness, gait disturbance, focal seizures, fixed visual changes, speech deficits and focal sensory abnormalities.

© Pastest 2019

A 34-year-old woman presents with weight loss, palpitations and anxiety. Her periods stopped three months ago, but a pregnancy test which she took two weeks ago was negative. She tells you that she has completed her family and has two children aged 9 and 6 years.

On examination, she has a blood pressure (BP) of 126/70 mmHg, her pulse is 92/min at rest and her body mass index (BMI) is 21. She has an obvious left-sided thyroid nodule.

Investigations:

Hb	12.1 g/dl
WCC	5.7×10^9/l
PLT	190×10^9/l
Na^+	139 mmol/l
K^+	4.9 mmol/l
Creatinine	100 µmol/l
TSH	< 0.05 U/l
FNAB	Consistent with adenoma

Which of the following is the most appropriate long-term intervention?

A Subtotal thyroidectomy

B Lugol's iodine

C Carbimazole

D Radioiodine

E Propylthiouracil

1:09
594-042-7551
Leave

investigations:

Hb	12.1 g/dl
WCC	5.7×10^9/l
PLT	190×10^9/l
Na^+	139 mmol/l
K^+	4.9 mmol/l
Creatinine	100 µmol/l
TSH	< 0.05 U/l
FNAB	Consistent with adenoma

Which of the following is the most appropriate long-term intervention?

Your answer was correct

A Subtotal thyroidectomy

B Lugol's iodine

C Carbimazole

D Radioiodine

E Propylthiouracil

Explanation

D Radioiodine

Radioiodine is highly effective for the treatment of a single toxic adenoma. We use the pediatric dose taken

Audio Video Share Participants More

B Lugol's iodine

C Carbimazole

D Radioiodine

E Propylthiouracil

Explanation

D Radioiodine

Radioiodine is highly effective for the treatment of a single toxic adenoma, because the 'hot nodule' avidly takes up radioiodine. If patients are, however, concerned about the possibility of radioactive iodine treatment or there is a suspicion of malignant change within the nodule, then they may be offered subtotal thyroidectomy.

A Subtotal thyroidectomy

This isn't the preferred option because of morbidity associated with surgery.

B Lugol's iodine

This is given for short-term control of thyrotoxicosis to enable unstable patients to progress to surgery.

C Carbimazole

Although anti-thyroid drugs may manage her thyroid function, given there are two definitive alternative interventions, these are preferred.

Rana Alnasser's screen

1:10

A 72-year-old woman is referred to the Endocrine Clinic. Over the past year, she has noticed a change in her facial appearance and has been suffering from headaches. Her general practitioner (GP) has also found it difficult to control her blood pressure and has recently diagnosed her with pre-diabetes.

Her blood pressure is 155/88 mmHg; her pulse is 74 bpm and regular. Her body mass index (BMI) is 24 kg/m^2.

A picture of her face is shown below.

Which of the following is the most useful next outpatient investigation?

A	Abdominal ultrasound scan
B	Computed tomography (CT) head
C	Insulin-like growth factor 1 (IGF-1)
D	Random growth hormone
E	24-hour urinary free cortisol

Rana Alnasser's screen

B Computed tomography (CT) head

Because of the risk of brain imaging detecting an incidentaloma, a biochemical diagnosis of acromegaly is usually made before proceeding to pituitary imaging. Out of the two options, magnetic resonance imaging (MRI) is preferred to CT.

D Random growth hormone

Growth hormone release is pulsatile, and growth hormone itself has a very short half-life. This means that a random growth hormone measurement can miss a diagnosis of acromegaly.

E 24-hour urinary free cortisol

Urinary free cortisol is an initial outpatient investigation for Cushing syndrome, characterised by obesity and impaired glucose tolerance, rather than the changes in facial appearance seen here.

Rate this question:

© Pastest 2019

A 40-year-old man presents to the Hypertension Clinic with difficult-to-control blood pressure. He is now taking ramipril 10 mg daily and amlodipine 10 mg, but his blood pressure is still 153/88 mmHg.

Investigations:

Na^+	145 mmol/l
K^+	3.0 mmol/l
Urea	5.2 mmol/l
Creatinine	85 µmol/l
Renal ultrasound scan	Kidneys normal size

Which of the following represents the best investigation for this patient?

A Plasma renin, aldosterone and cortisol level

B Plasma renin, aldosterone and cortisol levels after washout of antihypertensives

C Echocardiogram

D Renal angiogram

E Oral salt loading

Submit

1:13
594-042-7551
Leave
MyPastest
https://mypastest.pastest.com

Na^+	145 mmol/l
K^+	3.0 mmol/l
Urea	5.2 mmol/l
Creatinine	85 µmol/l
Renal ultrasound scan	Kidneys normal size

Which of the following represents the best investigation for this patient?

Your answer was correct

A Plasma renin, aldosterone and cortisol level

B Plasma renin, aldosterone and cortisol levels after washout of antihypertensives

C Echocardiogram

D Renal angiogram

E Oral salt loading

Explanation

B Plasma renin, aldosterone and cortisol levels after washout of antihypertensives

ACE inhibitors may increase plasma renin activity, and calcium antagonists may reduce aldosterone. Hence, renin, aldosterone and cortisol should be measured after a 2-

Audio Video Share Participants More

1:16
594-042-7551 Leave

B Plasma renin, aldosterone and cortisol levels after washout of antihypertensives

ACE inhibitors may increase plasma renin activity, and calcium antagonists may reduce aldosterone. Hence, renin, aldosterone and cortisol should be measured after a 2-week washout period to confirm primary hyperaldosteronism, the most likely diagnosis here. Resection of adenoma leads to resolution of hypertension in around 70% of patients where a discrete adenoma has been identified. Bilateral adrenal hyperplasia may be managed with spironolactone for many years; dexamethasone is the treatment of choice for those with glucocorticoid-suppressible hyperaldosteronism.

A Plasma renin, aldosterone and cortisol level

These investigations are in the context of suspected secondary hypertension (young patient requiring three antihypertensive agents). These need to be performed after washout of his medication, since ACE inhibitors may increase plasma renin activity and calcium antagonists may reduce aldosterone.

C Echocardiogram

It may reveal end organ damage (left ventricular hypertrophy) but it will not clarify the cause of the hypertension.

D Renal angiogram

In young patients with hypertension that is difficult to control, renal artery stenosis is one of the differential diagnoses. In this scenario though, normal-sized kidneys preclude this diagnosis.

Audio Video Share Participants More

D Renal angiogram

In young patients with hypertension that is difficult to control, renal artery stenosis is one of the differential diagnoses. In this scenario though, normal-sized kidneys preclude this diagnosis.

E Oral salt loading

This is one of the tests used to detect autonomous aldosterone secretion. Patients should increase their sodium intake to more than 6 g/day for 3 days with diet and sodium chloride tabs. Potassium supplementation and daily potassium measurements are required for patients with hypokalaemia. Patients perform 24 h urine collection starting on day 3 for sodium and aldosterone. A 24 h urinary aldosterone excretion of more than 12 mcg is consistent with primary aldosteronism, whereas 24 h urinary sodium of 200 mEq indicates adequate intake. This test should not be performed in patients with uncontrolled hypertension, congestive heart failure or arrhythmias.

Rate this question:

Next Question

© Pastest 2019

Rana Alnasser's screen

A 48-year-old woman is reviewed after attending for a wel woman clinic. She finds it difficult to control her weight, often feels tired, and currently has very heavy periods. Apart from this she doesn't have any particular concerns. On examination her BMI is 32 and her BP is 155/92 mmHg. Otherwise clinical examination is unremarkable.

Investigations

Hb	13.2 g/dl
WCC	4.5 $\times 10^9$/l
PLT	201 $\times 10^9$/l
Na^+	140 mmol/l
K^+	4.5 mmol/l
Creatinine	132 µmol/l
Total cholesterol	6.1 mmol/l
Fasting serum triglyceride	3.2 mmol/l (0.45-1.69)

Which of the following tests is most likely to contribute to determining the underlying diagnosis?

A HDL measurement

B HbA1c measurement

C LFTs

D Prolactin

E TFTS

Rana Alnasser's screen

E TFTS

Explanation

E TFTS

The difficulty with weight control, menorrhagia and hypertriglyceridaemia are all features consistent with hypothyroidism. TSH is likely to be elevated above the normal range, with low T3 and T4. Hashimoto's thyroiditis is the commonest cause of hypothyroidism, and the condition is managed with thyroid hormone replacement. Once thyroxine is commenced, periods improve and hypertriglyceridaemia usually begins to resolve without intervention with statin therapy.

A HDL measurement

HDL may be low but it's not contributing to the underlying diagnosis.

B HbA1c measurement

Significantly elevated blood glucose is unlikely to be seen, and even if HbA1c is abnormal it won't illustrate the reason for her weight gain and menorrhagia.

C LFTs

There may be a small elevation in transaminases, but this won't confirm the underlying cause of her symptoms.

D Prolactin

1:18
Pastest 594-042-7551 Question 33 of 200 Leave

E TFTS

Explanation

E TFTS

The difficulty with weight control, menorrhagia and hypertriglyceridaemia are all features consistent with hypothyroidism. TSH is likely to be elevated above the normal range, with low T3 and T4. Hashimoto's thyroiditis is the commonest cause of hypothyroidism, and the condition is managed with thyroid hormone replacement. Once thyroxine is commenced, periods improve and hypertriglyceridaemia usually begins to resolve without intervention with statin therapy.

A HDL measurement

HDL may be low but it's not contributing to the underlying diagnosis.

B HbA1c measurement

Significantly elevated blood glucose is unlikely to be seen, and even if HbA1c is abnormal it won't illustrate the reason for her weight gain and menorrhagia.

C LFTs

There may be a small elevation in transaminases, but this won't confirm the underlying cause of her symptoms.

D Prolactin

Audio Video Share Participants More

1:19

A couple attend for genetic counselling. They have one child with Klinefelter syndrome who was conceived when the mother was 19 years of age. She is now 35 and would like to try for a second child before she is too old.

What is the likelihood of a second male child being affected by Klinefelter?

A	1 in 2
B	1 in 4
C	1 in 8
D	1 in 25
E	1 in 500

21449

Submit

Previous Q... Skip Questi...

© Pastest 2019

Audio Video Share Participants More

1:20
Pastest 594-042-7551 Question 34 of 222 Leave

B 1 in 4

C 1 in 8

D 1 in 25

E 1 in 500

Explanation

E 1 in 500

Klinefelter, the commonest form of which is XXY, is the result of chromosomal non-dysjunction; as such, it does not follow a mendelian pattern of inheritance. Population studies suggest that the rate of occurrence in live male births is between 1 in 500 and 1 in 1000. The rate of chromosomal non-dysjunction increases with increasing maternal age and increasing paternal age, each parent contributing 50% of the risk. Around 60% of Klinefelter cases do not survive the fetal period.

D 1 in 25

1 in 25–30 represents the carrier frequency amongst Caucasians for the gene responsible for causing cystic fibrosis.

A 1 in 2

This is the risk of inheritance of an autosomal dominant condition where one parent is affected by the condition.

B 1 in 4

Audio Video Share Participants More

A 27-year-old woman presents to the clinic because of problems with the physical side of her relationship. She is concerned that her breasts leak milk after only minimal stimulation from her boyfriend, and that intercourse is difficult as she has significant problems with vaginal dryness. She also reports that she has not had a period for the past 4 months. The only other history of note is that she was given metoclopramide by a locum doctor for a recent episode of gastroenteritis. On examination her BP is 142/82 mmHg, pulse is 82/min and regular. Cardiovascular, respiratory and abdominal examination is unremarkable. You can produce milk on minimal breast stimulation. She has some peripheral field visual loss.

Investigations:

Hb	12.7 g/dl
WCC	7.6 x 10^9/l
PLT	203 x 10^9/l
Na^+	138 mmol/l
K^+	4.4 mmol/l
Creatinine	100 µmol/l
Prolactin	1005 mU/l (<360)
TSH	7.2 mU/l (0.4-5.0)
Free T4	16.2 pmol/l (10-22)
FSH	0.5 U/l
LH	2.5 U/l

Which of the following is the most likely diagnosis?

A Non-functioning pituitary adenoma

B Metoclopramide-related hyperprolactinaemia

respiratory and abdominal examination is unremarkable. You can produce milk on minimal breast stimulation. She has some peripheral field visual loss.

Investigations:

Hb	12.7 g/dl
WCC	7.6 x 10^9/l
PLT	203 x 10^9/l
Na^+	138 mmol/l
K^+	4.4 mmol/l
Creatinine	100 µmol/l
Prolactin	1005 mU/l (<360)
TSH	7.2 mU/l (0.4-5.0)
Free T4	16.2 pmol/l (10-22)
FSH	0.5 U/l
LH	2.5 U/l

Which of the following is the most likely diagnosis?

A Non-functioning pituitary adenoma

B Metoclopramide-related hyperprolactinaemia

C Microprolactinoma

D Macroprolactinoma

E Pregnancy

A Non-functioning pituitary adenoma

The prolactin isn't raised enough to be consistent with a macroprolactinoma, and the peripheral visual field loss raises the possibility of a large tumour. The low FSH and LH are consistent with this; the raised TSH may be due to either local compression or the fact that so called non-functioning adenomas may occasionally secrete small amounts of TSH. This woman should undergo a magnetic resonance imaging (MRI) scan to further characterise the tumour. However it is likely that surgery will be the mainstay of therapy as the tumour is highly unlikely to respond significantly to somatostatin or dopamine agonists.

B Metoclopramide-related hyperprolactinaemia

Drug-related hyperprolactinaemia is usually associated with a lesser rise in prolactin, to <1000.

C Microprolactinoma

Microprolactinomas are not associated with visual field loss, and a greater rise in prolactin would be expected in microprolactinoma.

D Macroprolactinoma

Macroprolactinomas are associated with the visual disturbance seen here, although a rise in prolactin to at least 5000 mU/l would be expected.

E Pregnancy

Although pregnancy is associated with a rise in prolactin, i isn't associated with the visual field defect seen here.

A 45-year-old teacher presents with a tingling sensation in the fingers of both hands, especially the thumb and index fingers, which is worse at night and disturbs his sleep. He also describes aching pain in his forearms, exacerbated by carrying heavy objects. He describes polydipsia and generalised aches and pains, and his wife has commented that he must have put on weight as his wedding ring no longer fits.

Clinical examination confirms reproducible sensory loss to pinprick in both hands, particularly over the thumb, index and middle fingers, but is otherwise unremarkable. His blood pressure is 150/96 mmHg. His general practitioner has recently performed a fasting glucose which was 8.4 mmol/l. You suspect he has carpal tunnel syndrome and arrange nerve conduction studies.

He has abnormal facial features, which are shown below.

By Philippe Chanson and Sylvie Salenave [CC BY 2.0 (https://creativecommons.org/licenses/by/2.0)], via Wikimedia Commons

Which of the following is the next most appropriate step in his management?

A	Random growth hormone (GH) level
B	Oral glucose tolerance test (OGTT) with GH measurement
C	Magnetic resonance imaging (MRI) of the pituitary fossa

and middle fingers, but is otherwise unremarkable. His blood pressure is 150/96 mmHg. His general practitioner has recently performed a fasting glucose which was 8.4 mmol/l. You suspect he has carpal tunnel syndrome and arrange nerve conduction studies.

He has abnormal facial features, which are shown below.

By Philippe Chanson and Sylvie Salenave [CC BY 2.0 (https://creativecommons.org/licenses/by/2.0)], via Wikimedia Commons

Which of the following is the next most appropriate step in his management?

A	Random growth hormone (GH) level
B	Oral glucose tolerance test (OGTT) with GH measurement
C	Magnetic resonance imaging (MRI) of the pituitary fossa
D	Pituitary function tests
E	Visual field testing

Submit

Explanation

B	Oral glucose tolerance test (OGTT) with GH measurement

This man has presented with bilateral carpal tunnel syndrome which, in association with macroglossia, prognathism, frontal bossing, enlarged hands, arthralgia, diabetes and hypertension (although a one-off measurement), strongly suggests a diagnosis of acromegaly. This is a rare disease, usually presenting at 30-50 years, and is due to hypersecretion of GH from a pituitary tumour.

Random GH measurement may show increased secretion, but levels vary diurnally and are therefore not diagnostic. The OGTT is definitive, with samples collected for glucose and GH at intervals of 30 minutes (0–150 minutes). Normally, GH is suppressed, but not in acromegaly (levels may rise).

A	Random growth hormone (GH) level

GH levels display diurnal variation, and therefore a random level may be falsely normal or low.

C	Magnetic resonance imaging (MRI) of the pituitary fossa

The first step in the management is to confirm the GH excess via OGTT. Subsequently, MRI/computed tomography (CT) of the pituitary is used to visualise the tumour and trans-sphenoidal surgery is usually the treatment of choice. Irradiation is used in older patients or following failed surgery. If the OGTT confirms the diagnosis, then MRI/CT plus surgery and investigation/management of other complications (visual fields, pituitary function, echocardiogram, etc.) is indicated

The first step in the management is to confirm the GH excess via OGTT. Subsequently, MRI/computed tomography (CT) of the pituitary is used to visualise the tumour and trans-sphenoidal surgery is usually the treatment of choice. Irradiation is used in older patients or following failed surgery. If the OGTT confirms the diagnosis, then MRI/CT plus surgery and investigation/management of other complications (visual fields, pituitary function, echocardiogram, etc.) is indicated

D Pituitary function tests

Pituitary function tests are indicated once the diagnosis of acromegaly is confirmed. A full pituitary profile would include testing the thyroid, gonadal and adrenal axis (thyroid-stimulating hormone (TSH), free thyroxine (fT4), follicle-stimulating hormone (FSH), luteinising hormone (LH), testosterone, cortisol).

E Visual field testing

Formal visual field assessment is indicated once the presence of an adenoma is confirmed on MRI pituitary.

Rate this question:

Next Question

Previous Q... Tag Questi... Feedback End Session

Blog About Pastest Contact Us Help

© Pastest 2019

A 31-year-old woman is referred by her GP as an emergency. She gives a history of malaise and weight loss. Most recently she collapsed at home and has suffered from persistent vomiting over the past 24 hours. Other past history of note includes a deep vein thrombosis in pregnancy and positive screen for anti-phospholipid antibody syndrome.

Investigations:

Na^+	128 mmol/l
K^+	6.0 mmol/l
Urea	9.1 mmol/l
Creatinine	128 micromol/l
Hb	10.1 g/dl
MCV	99 fl
ESR	41 mm/1st hr
Glucose	3.1 mmol/l

You arrange for a blood sample to be sent for cortisol and give a bolus of 20% dextrose.

Which of the following is the most appropriate next step in managing this patient?

A	Arrange a short synacthen test for the following morning
B	Start prednisolone 30 mg PO OD
C	Start fludrocortisone 100 mcg PO OD
D	Start IV fluid replacement with 5% dextrose

Investigations:

Na^+	128 mmol/l
K^+	6.0 mmol/l
Urea	9.1 mmol/l
Creatinine	128 micromol/l
Hb	10.1 g/dl
MCV	99 fl
ESR	41 mm/1st hr
Glucose	3.1 mmol/l

You arrange for a blood sample to be sent for cortisol and give a bolus of 20% dextrose.

Which of the following is the most appropriate next step in managing this patient?

A Arrange a short synacthen test for the following morning

B Start prednisolone 30 mg PO OD

C Start fludrocortisone 100 mcg PO OD

D Start IV fluid replacement with 5% dextrose

E Start IV fluid replacement with 0.9% saline and give a bolus of IV hydrocortisone

E Start IV fluid replacement with 0.9% saline and give a bolus of IV hydrocortisone

This woman has anti-phospholipid antibody syndrome, which may have led to adrenal infarction, precipitating this presentation with an Addisonian crisis. Autoimmune disease is the commonest cause of Addison's in the developed world, although malignancy and infection (e.g. with tuberculosis) may also be responsible. Initial treatment is with rehydration, and several litres of normal saline may be required during the first 24 h of therapy. A bolus of hydrocortisone 100 mg IV should also be given. If the patient is able to take oral medication, this can then be given as regular oral hydrocortisone or could be given IM if needed.

C Start fludrocortisone 100 mcg PO OD

Fludrocortisone replacement is not normally required in the acute stage, but can be added once the dose of hydrocortisone is reduced after a few days.

A Arrange a short synacthen test for the following morning

This lady is presenting with an Addisonian crisis – you should not wait for a synacthen test prior to commencing therapy.

B Start prednisolone 30 mg PO OD

Hydrocortisone is the steroid of choice in the treatment of Addison's.

D Start IV fluid replacement with 5% dextrose

Hypotension should be managed with aggressive fluid

1:32

You review a 19-year-old student who presents with delayed puberty. He has so far been unable to form relationships and feels any time he meets a potential female partner everything breaks down at the physical stage. Examination reveals sparse body hair and underdeveloped penis with small testes. Blood pressure and BMI are both normal. He is also anosmic.

Investigations:

testosterone	5 nmol/l (9–35)
FSH	0.69 U/l (1–7)
LH	0.57 U/l (1–10).
TSH	1.2 U/l (0.5-4.5)

What diagnosis fits best with this clinical picture?

A Kallman syndrome

B Klinefelter syndrome

C Androgen insensitivity syndrome

D Pan-hypopituitarism

E Turner syndrome

Submit
Audio Video Share Participants More

1:33
Pastes+ 594-042-7551 Leave

stage. Examination reveals sparse body hair and underdeveloped penis with small testes. Blood pressure and BMI are both normal. He is also anosmic.

Investigations:

testosterone	5 nmol/l (9–35)
FSH	0.69 U/l (1–7)
LH	0.57 U/l (1–10).
TSH	1.2 U/l (0.5-4.5)

What diagnosis fits best with this clinical picture?

Your answer was correct

A Kallman syndrome

B Klinefelter syndrome

C Androgen insensitivity syndrome

D Pan-hypopituitarism

E Turner syndrome

Explanation

A Kallman syndrome

Kallman syndrome results from disordered migration of gonadotropin-releasing hormone (GnRH)-producing neurons into the hypothalamus. This leads to failure of episodic GnRH secretion and subsequent failure of

Audio Video Share Participants More

gonadotropin-releasing hormone (GnRH)-producing neurons into the hypothalamus. This leads to failure of episodic GnRH secretion and subsequent failure of luteinising hormone (LH), follicle-stimulating hormone (FSH) and testosterone production. Seventy-five per cent of sufferers have absent sense of smell (anosmia). It occurs in 1 in 10,000 males, being rarer in females (male:female ratio 4: 1). The syndrome is also associated with an increased risk of cleft lip and palate and sensorineural deafness.

B Klinefelter syndrome

Klinefelter syndrome is associated with small testes and low levels of testosterone, but isn't associated with loss of sense of smell.

C Androgen insensitivity syndrome

AIS is associated with female external genitalia, rather than the male phenotype seen here.

D Pan-hypopituitarism

The normal-range TSH in the absence of symptoms of hypothyroidism counts against a diagnosis of pan-hypopituitarism.

E Turner syndrome

Turner syndrome is associated with short stature, cardiovascular abnormalities and female external genitalia.

Rate this question:

Rana Alnasser's screen

which is currently managed with diet. On examination his BP is 142/82 mmHg, with pulse is 76/min and regular. He looks particularly tanned. You count a number of spider naevi on examination of his upper chest and you notice that his pubic hair seems a little sparse. His BMI is 31.

Investigations:

Hb	12.9 g/dl
WCC	8.1 x10^9/l
PLT	190 x10^9/l
Na^+	139 mmol/l
K^+	4.5 mmol/l
Creatinine	134 µmol/l
ALT	182 U/l
Bilirubin	65 µmol/l
Glucose	11.1 mmol/l
Right knee x-ray	chondrocalcinosis

Which of the following tests would you carry out next?

A Serum calcium

B Serum ferritin

C Serum copper

D Urinary copper

E Hepatitis serology

Rana Alnasser's screen

A 42-year-old man presents with chronic right knee pain. He lives and works in Italy and only returns to the UK intermittently to see his family. He has a history of type 2 diabetes mellitus diagnosed last time he was in the UK, which is currently managed with diet. On examination his BP is 142/82 mmHg, with pulse is 76/min and regular. He looks particularly tanned. You count a number of spider naevi on examination of his upper chest and you notice that his pubic hair seems a little sparse. His BMI is 31.

Investigations:

Hb	12.9 g/dl
WCC	8.1 x10^9/l
PLT	190 x10^9/l
Na^+	139 mmol/l
K^+	4.5 mmol/l
Creatinine	134 µmol/l
ALT	182 U/l
Bilirubin	65 µmol/l
Glucose	11.1 mmol/l
Right knee x-ray	chondrocalcinosis

Which of the following tests would you carry out next?

Your answer was correct

A Serum calcium

B Serum ferritin

Explanation

B Serum ferritin

The suspicion is that he has so-called bronze diabetes, or haemochromatosis, associated with chronic liver disease, diabetes mellitus and chondrocalcinosis. The condition occurs because of an inherited mutation on chromosome 6 which affects the way that the transferrin receptor binds to transferrin, and leads to iron accumulation. It is this which results in organ damage and consequent chronic liver disease and diabetes mellitus. The C282Y mutation is found in the majority of patients with haemochromatosis, and this can be screened for using a widely available genetic test. Ferritin is usually elevated in association with haemochromatosis, and is a useful initial screening test. It is not specific for haemochromatosis, however, as ferritin may be elevated in chronic liver disease *per se*. It is usually followed by transferrin saturation testing and genetic screening.

A Serum calcium

Although hypercalcaemia is associated with chondrocalcinosis, it's haemochromatosis which is more likely to be the primary cause here.

C Serum copper

Disordered copper metabolism is the cause of Wilson's disease, where patients usually present at an earlier age either with unexplained abnormal liver function, psychiatric disturbance, or chorea, more marked on one side than the other.

D Urinary copper

This is part of the work up for Wilson's disease, which

Although hypercalcaemia is associated with chondrocalcinosis, it's haemochromatosis which is more likely to be the primary cause here.

C Serum copper

Disordered copper metabolism is the cause of Wilson's disease, where patients usually present at an earlier age either with unexplained abnormal liver function, psychiatric disturbance, or chorea, more marked on one side than the other.

D Urinary copper

This is part of the work-up for Wilson's disease, which presents at an earlier age with neurological impairment or unexplained abnormal liver function tests.

E Hepatitis serology

For viral hepatitis, presentation with diabetes mellitus or chondrocalcinosis would not be expected.

Rate this question:

Next Question

Previous Q... Tag Questi... Feedback End Session

Blog About Pastest Contact Us Help

© Pastest 2019

Rana Alnasser's screen

A 62-year-old man with a known history of type 2 diabetes comes to the Emergency Department having taken an overdose of an unknown quantity of tablets some 3 hours earlier.

e refuses to discuss what he took, but his last discharge suggests he is taking a number of medications including metformin, gliclazide, ramipril, aspirin and atorvastatin.

You review his arterial blood gas results, which are shown below:

PO_2	10.4 kPa
PCO_2	3.9 kPa
Bicarbonate	16 mmol/l
pH	7.36

Which of the following is the most likely explanation for the blood gas results?

A Compensated metabolic acidosis

B Compensated respiratory alkalosis

C Compensated respiratory acidosis

D Compensated metabolic alkalosis

E Normal blood gas result

Submit

Rana Alnasser's screen

e refuses to discuss what he took, but his last discharge suggests he is taking a number of medications including metformin, gliclazide, ramipril, aspirin and atorvastatin.

You review his arterial blood gas results, which are shown below:

PO_2	10.4 kPa
PCO_2	3.9 kPa
Bicarbonate	16 mmol/l
pH	7.36

Which of the following is the most likely explanation for the blood gas results?

Your answer was correct

A Compensated metabolic acidosis

B Compensated respiratory alkalosis

C Compensated respiratory acidosis

D Compensated metabolic alkalosis

E Normal blood gas result

Explanation

A Compensated metabolic acidosis

This man's bicarbonate is below the lower limit of normal, and he is blowing off CO_2 to allow him to maintain a

Explanation

A Compensated metabolic acidosis

This man's bicarbonate is below the lower limit of normal, and he is blowing off CO_2 to allow him to maintain a normal pH. In this context, given that he is taking metformin, he may have overdosed on it leading to presentation with raised anion gap acidosis. His other results, including his chloride, could be scrutinised to confirm this suspicion.

B Compensated respiratory alkalosis

This is seen in the first few hours after aspirin overdose, and in this case is associated with vomiting and tinnitus.

C Compensated respiratory acidosis

This occurs in patients with chronic obstructive pulmonary disease (COPD), and is associated with an elevated pCO_2 and bicarbonate.

D Compensated metabolic alkalosis

This is seen in persistent vomiting, although respiratory compensation is limited by a compulsion to breathe and maintain adequate oxygenation.

E Normal blood gas result

The bicarbonate is below the lower limit of normal, as is th PCO_2.

Rana Alnasser's screen

Rate this question:

B Compensated respiratory alkalosis

This is seen in the first few hours after aspirin overdose, and in this case is associated with vomiting and tinnitus.

C Compensated respiratory acidosis

This occurs in patients with chronic obstructive pulmonary disease (COPD), and is associated with an elevated pCO_2 and bicarbonate.

D Compensated metabolic alkalosis

This is seen in persistent vomiting, although respiratory compensation is limited by a compulsion to breathe and maintain adequate oxygenation.

E Normal blood gas result

The bicarbonate is below the lower limit of normal, as is th PCO_2.

Rate this question:

Next Question

Previous Q... Tag Questi... Feedback End Session

Blog About Pastest Contact Us Help

© Pastest 2019

Rana Alnasser's screen

1:38
Pastes+ 594-042-7551 Leave

A 25-year-old gentleman is referred by his GP to the Endocrine Clinic with weight loss and polyuria. You note his blood pressure to be 125/82 mmHg with a postural drop of 20 mmHg on standing. His BMI is 23. You also note that he has vitiligo.

Investigations (by his GP):

Na^+	125 mmol/l
K^+	6.0 mmol/l
Urea	8.0 mmol/l
Creatinine	120 µmol/l
Glucose	12.5 mmol/l
Ca^+	2.15 mmol/l
T_4	8.0 pmol/l
TSH	20 mU/l

What is the most likely diagnosis?

A	Lysosomal acid lipase deficiency
B	DIDMOAD syndrome
C	Polyglandular syndrome type 1
D	Polyglandular syndrome type 2
E	Multiple endocrine neoplasia type 1

Audio Video Share Participants More

investigations (by his GP).

Na^+	125 mmol/l
K^+	6.0 mmol/l
Urea	8.0 mmol/l
Creatinine	120 µmol/l
Glucose	12.5 mmol/l
Ca^+	2.15 mmol/l
T_4	8.0 pmol/l
TSH	20 mU/l

What is the most likely diagnosis?

Your answer was correct

A Lysosomal acid lipase deficiency

B DIDMOAD syndrome

C Polyglandular syndrome type 1

D Polyglandular syndrome type 2

E Multiple endocrine neoplasia type 1

Explanation

D Polyglandular syndrome type 2

Autoimmune polyglandular syndrome type 2 is the association of primary adrenal insufficiency with primary

B DIDMOAD syndrome

C Polyglandular syndrome type 1

D Polyglandular syndrome type 2

E Multiple endocrine neoplasia type 1

Explanation

D Polyglandular syndrome type 2

Autoimmune polyglandular syndrome type 2 is the association of primary adrenal insufficiency with primary hypothyroidism and type 1 diabetes. Sometimes, primary gonadal failure is present as well. Both type 1 and type 2 polyglandular syndrome are associated with vitiligo and pernicious anaemia.

A Lysosomal acid lipase deficiency

LAL deficiency, also known as Wolman syndrome, is characterised by primary adrenal failure, hepatosplenomegaly and steatorrhoea.

B DIDMOAD syndrome

DIDMOAD syndrome is characterised by Diabetes Insipidus, Diabetes Mellitus, Optic Atrophy and Deafness and is a mitochondrial rather than an autoimmune disorder.

Scroll capture Draw Crop

D Polyglandular syndrome type 2

Autoimmune polyglandular syndrome type 2 is the association of primary adrenal insufficiency with primary hypothyroidism and type 1 diabetes. Sometimes, primary gonadal failure is present as well. Both type 1 and type 2 polyglandular syndrome are associated with vitiligo and pernicious anaemia.

A Lysosomal acid lipase deficiency

LAL deficiency, also known as Wolman syndrome, is characterised by primary adrenal failure, hepatosplenomegaly and steatorrhoea.

B DIDMOAD syndrome

DIDMOAD syndrome is characterised by Diabetes Insipidus, Diabetes Mellitus, Optic Atrophy and Deafness and is a mitochondrial rather than an autoimmune disorder.

C Polyglandular syndrome type 1

Type 1 polyglandular syndrome is characterised by two or more of the following: hypoparathyroidism (90%), primary adrenal insufficiency (60%), chronic mucocutaneous candidiasis, primary gonadal failure and primary hypothyroidism.

E Multiple endocrine neoplasia type 1

MEN1 is associated with pancreatic tumours, including insulinomas and glucagonomas, rather than the development of adrenal insufficiency and diabetes seen here.

A 65-year-old woman presents with vomiting, anorexia, and polyuria. She is a non-smoker. Her GP has been treating her for anaemia with iron supplements, although she tells you this has had little or no effect on feelings of increasing lethargy over the past few months.

On examination, her BP is 122/82, pulse is 88 and regular. She looks pale.

Investigations:

Na^+	141 mmol/l
K^+	3.6 mmol/l
Bilirubin	20 µmol/l
Urea	12 mmol/l
ALT	30 U/l
ALP	280 U/l
Creatinine	154 µmol/l
Albumin	30 g/l
Total protein	85 g/l
Corrected Ca^{++}	3.0 mmol/l
Phosphate	1.3 mmol/l

You start her on IV normal saline.

Which one of the following would be the best initial investigation to contribute to the underlying diagnosis?

A Sesta MIBI scan of the neck

B CT chest

C Abdominal X-ray

Na^+	141 mmol/l
K^+	3.6 mmol/l
Bilirubin	20 μmol/l
Urea	12 mmol/l
ALT	30 U/l
ALP	280 U/l
Creatinine	154 μmol/l
Albumin	30 g/l
Total protein	85 g/l
Corrected Ca^{++}	3.0 mmol/l
Phosphate	1.3 mmol/l

You start her on IV normal saline.

Which one of the following would be the best initial investigation to contribute to the underlying diagnosis?

A Sesta MIBI scan of the neck

B CT chest

C Abdominal X-ray

D Ultrasound of the neck

E Skeletal survey

Explanation

E Skeletal survey

This woman has hypercalcaemia without hypophosphataemia. Therefore, malignancy must be considered. The LFTs show increased globulin fraction (TP-ALB) indicating the possibility of myeloma. Therefore, the most appropriate management in this case is IV saline and a skeletal survey. Treatment of myeloma-induced hypercalcaemia is IV saline rehydration. Furosemide therapy with IV saline can be used as an adjunct to increase calcium excretion. IV pamidronate is also useful in reducing the calcium. In myeloma, hypercalcaemia is primarily due to increased osteolysis and high-dose steroids - e.g. prednisolone 40 mg od can rapidly reduce the calcium level. IV pamidronate is also useful in reducing the calcium in resistant cases. The emphasis should be on treating the myeloma with chemotherapy, which will in turn lead to a reduction in the calcium.

A Sesta MIBI scan of the neck

This is most useful if a parathyroid adenoma is suspected. Given the phosphate is in the normal range. this is much less likely versus malignancy as the underlying cause of her hypercalcaemia.

B CT chest

CT chest is most useful in patients with suspected bronchial carcinoma; the absence of a history of smoking and any reports of a cough counts against this as the underlying diagnosis.

C Abdominal X-ray

Rana Alnasser's screen

A 61-year-old man with type 2 diabetes and a recent HbA1c of 83.61 mmol/mol (9.8%) asks for urgent clinic review. He complains of a hot, swollen left foot, which has gradually got worse over the past month.

On examination, there is increased heat over the tarsal-metatarsal joint and the foot is swollen. Dorsalis pedis and posterior tibial pulses are palpable and there is obvious neuropathy.

Investigations:

Hb	12.1 g/dl
WCC	12.1×10^9/l
PLT	204×10^9/l
Na^+	140 mmol/l
K^+	4.5 mmol/l
Creatinine	101 µmol/l
CRP	9 mg/l

Which of the following represents the investigation of choice with respect to the likely diagnosis (where available)?

A Technetium isotope scan

B Indium-labelled white cell scan

C Plain radiograph

D ESR

E Joint aspiration

On examination, there is increased heat over the tarsal-metatarsal joint and the foot is swollen. Dorsalis pedis and posterior tibial pulses are palpable and there is obvious neuropathy.

Investigations:

Hb	12.1 g/dl
WCC	12.1×10^9/l
PLT	204×10^9/l
Na^+	140 mmol/l
K^+	4.5 mmol/l
Creatinine	101 μmol/l
CRP	9 mg/l

Which of the following represents the investigation of choice with respect to the likely diagnosis (where available)?

Your answer was incorrect

A Technetium isotope scan

B Indium-labelled white cell scan

C Plain radiograph

D ESR

E Joint aspiration

Explanation

Explanation

B Indium-labelled white cell scan

Although not widely available, an indium-labelled white cel scan is the best way to differentiate between infective causes of this clinical presentation and Charcot's arthropathy. It is more stable with respect to labelling of white cells versus other techniques such as technetium, and is therefore less likely for example, to label areas of increased bone turnover.

Charcot's is thought to occur due to increased blood flow as a result of neuropathy. This results in increased osteoclast activity and bone turnover; the foot is then susceptible to often very minor trauma and destructive changes take place. Experts recommend immobilisation fo at least 3 months in an aircast-type non-weight-bearing plaster. This is to allow bone remodelling/repair to occur. Bisphosphonates are a useful adjunct to the healing process as they reduce osteoclast activity. Whilst insulin therapy is likely to improve glycaemic control and slow further progression of neuropathy, it will not affect recovery of the Charcot's joint.

C Plain radiograph

Plain X-rays may show areas of joint destruction but won't differentiate between infection and Charcot's-driven inflammation.

A Technetium isotope scan

Technetium is more likely to label areas of increased bone turnover associated with Charcot's, as well as areas of infection.

D ESR

plaster. This is to allow bone remodelling/repair to occur. Bisphosphonates are a useful adjunct to the healing process as they reduce osteoclast activity. Whilst insulin therapy is likely to improve glycaemic control and slow further progression of neuropathy, it will not affect recovery of the Charcot's joint.

C Plain radiograph

Plain X-rays may show areas of joint destruction but won't differentiate between infection and Charcot's-driven inflammation.

A Technetium isotope scan

Technetium is more likely to label areas of increased bone turnover associated with Charcot's, as well as areas of infection.

D ESR

Although ESR may be elevated, it is a non-specific marker of inflammation and therefore won't definitively confirm osteomyelitis here.

E Joint aspiration

Joint aspiration of a foot is technically difficult and painful. Whilst it may deliver a diagnosis of osteomyelitis, where indium-labelled white cell scanning is available, it's preferred.

Rate this question:

Next Question

A 75-year-old lifelong smoker was seen with a 5-day history of wheeze and ankle swelling. He was prescribed diuretics along with some other medications but continued to deteriorate. His BP is 110/60 mmHg with a postural drop of 20 mmHg, and his pulse is 90/min and regular.

Investigations:

Na^+	133 mmol/l
K^+	5.0 mmol/l
Urea	28 mmol/l
Creatinine	200 µmol/l
pH	7.11
$p(CO_2)$	7.0 kPa
$p(O_2)$	6.5 kPa
HCO_3	16 mmol/l

Which one of the following diagnoses best explains the clinical picture and these biochemical results?

A Mixed picture of COPD and cardiac failure with renal hypoperfusion

B Severe COPD

C Pre-kidney disease secondary to diuretics

D Aspirin poisoning

E Acute kidney disease and fluid overload

Explanation

A Mixed picture of COPD and cardiac failure with renal hypoperfusion

This patient has a respiratory acidosis ($p(CO_2)$ >6.5 kPa, pH <7.35 and hypoxia) and a metabolic acidosis (low bicarbonate). It's very likely that he has an element of COPD with chronic CO_2 retention and a degree of pulmonary oedema. Treatment with diuretics then leads to renal hypoperfusion, resulting in metabolic acidosis.

B Severe COPD

This would produce a respiratory acidosis with metabolic compensation, which would be reflected by raised bicarbonate level on the ABG.

C Pre-kidney disease secondary to diuretics

Pre-kidney disease on its own would not cause carbon dioxide retention and hypoxia.

D Aspirin poisoning

Symptoms of acute aspirin (acetyl salicylic acid) toxicity include nausea, vomiting, diarrhoea, tinnitus, vertigo, altered mentation, non-cardiogenic pulmonary oedema, hyperpyrexia and coma. Salicylates stimulate the medullary respiratory centre leading to increased rate (tachypnoea) and depth of respiration (hyperventilation). This leads to a fall in pCO_2 and respiratory alkalosis. Later, metabolic acidosis occurs due to accumulation of lactic and other organic acids. The most common acid–base presentation is that of mixed respiratory alkalosis–metabolic acidosis.

E Acute kidney disease and fluid overload

A young female junior doctor is concerned that she has pu on weight since she was a medical student, as she now no longer finds time to exercise. She looks in the British National Formulary for drugs that cause weight loss and decides to try some on a temporary basis. After 2 months, she is successfully losing weight but also has trouble with increased stool frequency. However, she is concerned as she has also noticed difficulty in climbing stairs. She has no problems walking on the flat, but she also has difficulty getting up out of chairs. She has difficulty in sleeping at th moment but puts that down to increased frequency of headaches for the past 2 months. She asks you, a fellow work colleague, what the cause of her weakness could be.

Which one of the following do you think is the most likely

A	She is just tired from overworking
B	She is abusing thyroxine tablets
C	She is abusing metformin
D	She is abusing insulin injections
E	She is abusing laxatives

6830

Submit

1:58

MyPastest
https://mypastest.pastest.com

A young female junior doctor is concerned that she has put on weight since she was a medical student, as she now no longer finds time to exercise. She looks in the British National Formulary for drugs that cause weight loss and decides to try some on a temporary basis. After 2 months, she is successfully losing weight but also has trouble with increased stool frequency. However, she is concerned as she has also noticed difficulty in climbing stairs. She has no problems walking on the flat, but she also has difficulty getting up out of chairs. She has difficulty in sleeping at the moment but puts that down to increased frequency of headaches for the past 2 months. She asks you, a fellow work colleague, what the cause of her weakness could be.

Which one of the following do you think is the most likely?

Your answer was incorrect

A She is just tired from overworking

B She is abusing thyroxine tablets

C She is abusing metformin

D She is abusing insulin injections

E She is abusing laxatives

Explanation

B She is abusing thyroxine tablets

Explanation

B She is abusing thyroxine tablets

Thyroxine, metformin and laxatives can all cause weight loss. Her weakness fits with a proximal muscle weakness, which can be caused by hyperthyroidism. She may also be tachycardic, but has not experienced palpitations. Excessive use not only results in proximal muscle weakness but also can cause a tachycardic cardiomyopathy, arrhythmias, palpitations, muscle cramps, diarrhoea, tremors, restlessness, sweating, headaches and insomnia.

C She is abusing metformin

Metformin can cause diarrhoea and headaches, but does not cause muscle weakness as described in this scenario.

A She is just tired from overworking

The increased stool frequency, the weight loss, the headaches and muscle weakness point towards an underlying pathology such as thyrotoxicosis rather than simply overworking.

D She is abusing insulin injections

Insulin is an anabolic hormone. It can cause weight gain and dangerous hypoglycaemia.

E She is abusing laxatives

Laxatives cause weight loss by volume depletion. Chronic use of stimulant laxatives can lead to serious medical consequences such as fluid and electrolyte imbalance, steatorrhea, protein-losing gastroenteropathy, osteomalacia and vitamin and mineral deficiencies.

A 19-year-old woman is referred to the clinic for review by her GP. She has been worried as she has suffered weight gain of 3 kg over the past 3 months and has not had a period for the past 2 months. There is also some breast tenderness and a feeling of fullness. On examination she looks well and has a normal BP of 125/75 mmHg; other features are entirely normal.

Investigations:

Hb	12.1 g/dl
WCC	5.6 $\times 10^9$/l
PLT	192 $\times 10^9$/l
Na^+	140 mmol/l
K^+	4.7 mmol/l
Creatinine	100 µmol/l
Prolactin	1600 mU/l (<360)

Which of the following is the most likely diagnosis?

A Hypothyroidism

B Pregnancy

C Microprolactinoma

D Macroprolactinoma

E Polycystic ovarian syndrome

E Polycystic ovarian syndrome

Explanation

B Pregnancy

Prolactin levels rise rapidly in pregnancy, and the symptoms of amenorrhoea, breast fullness/tenderness and weight gain fit very well with this underlying diagnosis. A urine pregnancy test is easily accessible, and should represent the investigation of choice for this patient.

A Hypothyroidism

Hypothyroidism presents with menorrhagia and weight gain rather than the picture seen here.

C Microprolactinoma

Prolactin levels in microprolactinoma are usually slightly higher than those seen here.

D Macroprolactinoma

In macroprolactinoma a much greater rise in prolactin would be expected, with symptoms of optic chiasm compression.

E Polycystic ovarian syndrome

PCOS is associated with weight gain, irregular heavy periods and symptoms of hyperandrogenism.

Rate this question:

2:01

A 53-year-old man with type 2 diabetes attends the clinic for review. He has had diabetes for 5 years and is currently managed with metformin 1 g PO BD and pioglitazone 30 mg daily. You understand that he suffered a myocardial infarction while on holiday some 5 months earlier and has suffered very minor episodes of angina since. He is treated with atorvastatin 40 mg, aspirin 75 mg, ramipril 10 mg and GTN PRN, and most recently has had trouble with increasing shortness of breath and peripheral oedema. His BP is 142/80 mmHg, his BMI is 29.

Investigations:

Hb	13.4 g/dl
WCC	5.6 $\times 10^9$/l
PLT	299 $\times 10^9$/l
Na^+	140 mmol/l
K^+	4.9 mmol/l
Creatinine	120 µmol/l
HbA1c	57.38 mmol/mol (7.4%)

Which of the following represent the most appropriate management in this case?

A Leave the diabetes therapy unchanged

B Add a sulphonylurea to the regime

C Change the pioglitazone to empagliflozin

D Switch to basal bolus insulin therapy

E Add liraglutide

Rana Alnasser's screen

2:04

MyPastest
https://mypastest.pastest.com

A 53-year-old man with type 2 diabetes attends the clinic for review. He has had diabetes for 5 years and is currently managed with metformin 1 g PO BD and pioglitazone 30 mg daily. You understand that he suffered a myocardial infarction while on holiday some 5 months earlier and has suffered very minor episodes of angina since. He is treated with atorvastatin 40 mg, aspirin 75 mg, ramipril 10 mg and GTN PRN, and most recently has had trouble with increasing shortness of breath and peripheral oedema. His BP is 142/80 mmHg, his BMI is 29.

Investigations:

Hb	13.4 g/dl
WCC	5.6 x10⁹/l
PLT	299 x10⁹/l
Na^+	140 mmol/l
K^+	4.9 mmol/l
Creatinine	120 µmol/l
HbA1c	57.38 mmol/mol (7.4%)

Which of the following represent the most appropriate management in this case?

Your answer was correct

A Leave the diabetes therapy unchanged

B Add a sulphonylurea to the regime

C Change the pioglitazone to empagliflozin

C Change the pioglitazone to empagliflozin

This man has a history of ischaemic heart disease and evidence of heart failure. As such, a glitazone is likely to be dangerous with respect to the possibility of worsening his heart failure and increasing the risk of cardiovascular events. For these reasons the pioglitazone should be discontinued. Because his HbA1c is only modestly elevated, a trial of SGLT-2 inhibitor is reasonable, which will control HbA1c and promote modest weight loss, accompanied by a mild diuresis. The class has also now been shown to reduce heart failure, with empagliflozin also having a positive impact on MACE events.

A Leave the diabetes therapy unchanged

Leaving therapy unchanged runs the risk of worsening heart failure and fluid retention because of the pioglitazone.

B Add a sulphonylurea to the regime

Adding a sulphonylurea risks increasing the risk of hypoglycaemia for this patient, driving weight gain, and it is not associated with positive cardiovascular outcomes.

D Switch to basal bolus insulin therapy

Switching to basal bolus insulin therapy may drive tighter glycaemic control, but it also drives hypoglycaemia and weight gain and may increase the risk of sudden cardiac death because of episodes of severe hypo.

E Add liraglutide

Without stopping the pioglitazone, it's inappropriate to move straight to adding a GLP-1 agonist.

2:05

A 28-year-old woman presents to the Endocrinology Clinic with tiredness and loss of libido. This is leading to problems with her relationship. She has had no periods for the past 4 months and has taken three pregnancy tests, all of which have been negative. She takes no medication and currently works as a solicitor. There is a past history of a left lower limb deep vein thrombosis (DVT) 5 years earlier after a return flight to the UK from Australia. She does not have any current plans for pregnancy.

On examination, her BP is 122/70 mmHg, with pulse 70/min and regular. Her BMI is 22. Visual fields are normal.

Investigations:

Hb	13.0 g/dl
WCC	7.0×10^9/l
PLT	201×10^9/l
Na^+	137 mmol/l
K^+	3.9 mmol/l
Creatinine	115 μmol/l
Prolactin	1500 U/l
Pituitary MRI	Micro-adenoma

Which of the following is the optimal way to manage her?

A Trans-sphenoidal resection

B Cabergoline

C Bromocriptine

D Domperidone

Rana Alnasser's screen

limb deep vein thrombosis (DVT) 5 years earlier after a return flight to the UK from Australia. She does not have any current plans for pregnancy.

On examination, her BP is 122/70 mmHg, with pulse 70/min and regular. Her BMI is 22. Visual fields are normal.

Investigations:

Hb	13.0 g/dl
WCC	7.0×10^9/l
PLT	201×10^9/l
Na^+	137 mmol/l
K^+	3.9 mmol/l
Creatinine	115 µmol/l
Prolactin	1500 U/l
Pituitary MRI	Micro-adenoma

Which of the following is the optimal way to manage her?

A Trans-sphenoidal resection

B Cabergoline

C Bromocriptine

D Domperidone

E Combined oral contraceptive pill

36029

Submit

WCC	7.0×10^9/l
PLT	201×10^9/l
Na^+	137 mmol/l
K^+	3.9 mmol/l
Creatinine	115 μmol/l
Prolactin	1500 U/l
Pituitary MRI	Micro-adenoma

Which of the following is the optimal way to manage her?

Your answer was correct

A Trans-sphenoidal resection

B Cabergoline

C Bromocriptine

D Domperidone

E Combined oral contraceptive pill

Explanation

B Cabergoline

Dopamine agonists are the intervention of choice for microprolactinoma. A meta-analysis suggested that cabergoline is more efficacious than bromocriptine in normalising prolactin, with a better side effect profile, and it is therefore the treatment of choice for this patient.

Explanation

B Cabergoline

Dopamine agonists are the intervention of choice for microprolactinoma. A meta-analysis suggested that cabergoline is more efficacious than bromocriptine in normalising prolactin, with a better side effect profile, and it is therefore the treatment of choice for this patient.

A Trans-sphenoidal resection

Surgery is not indicated for microprolactinoma unless there is a failure of symptoms to respond to medical intervention or there is significant optic chiasm compression from a macro-adenoma.

C Bromocriptine

Bromocriptine has a slightly less favourable adverse event profile versus cabergoline, but greater evidence exists for safe use in early pregnancy. It is therefore the preferred option in women who are considering starting a family.

D Domperidone

Domperidone is a dopamine antagonist, which is a cause of hyperprolactinaemia.

E Combined oral contraceptive pill

Combined oral contraceptives are an option for women with a microprolactinoma who don't require the return of fertility, although in this case they are best avoided with the previous history of deep vein thrombosis.

A 19-year-old medical student, who is excessively tall, comes to the clinic for review. Apparently his parents are also tall. On examination he is 197 cm in height, his mother is 191 cm, his father 195 cm. His limbs look long for his body, and he has mild pectus excavatum. He has hypermobility of his finger joints. There is a systolic murmur loudest in the mitral area.

Investigations:

Hb	14.1 g/dl
WCC	5.1 x10^9/l
PLT	230 x10^9/l
Na^+	139 mmol/l
K^+	4.5 mmol/l
Creatinine	120 µmol/l
Growth hormone	5 mcg/l (0-10)
Testosterone	21 nmol/l (9-35)

Which of the following is the most likely diagnosis?

A Familial tall stature

B Homocystinuria

C Gigantism

D Klinefelter's syndrome

E Marfan's syndrome

Explanation

E Marfan's syndrome

This patient has long limbs for his height, pectus excavatum, hypermobility and a systolic murmur consistent with mitral valve prolapse, all of these features being consistent with Marfan. Unfortunately DNA testing for fibrillin gene mutations, whilst helpful, cannot exclude a diagnosis of Marfan because a number of mutations exist (at least 130). Hence diagnosis is made on the major and minor features associated with the syndrome.

A Familial tall stature

Given his long limb length, pectus excavatum, hypermobility and cardiac murmur, Marfan is a much more likely diagnosis.

B Homocystinuria

Homocystinuria has similar features to Marfan, but is often also associated with developmental delay, behavioural problems and venous thromboembolism.

C Gigantism

Although growth hormone release is episodic, and a normal level therefore doesn't totally rule out gigantism, it is less likely given the other features seen here.

D Klinefelter's syndrome

Testosterone is well within the normal range, excluding Klinefelter, where testosterone is of course expected to be low.

Touc... 00:14 2:11

A 28-year-old woman presents to the Endocrinology Clinic for review. She recently suffered a fall whilst at a nightclub and was knocked out for a few minutes.

Since then, over the past few weeks, she has suffered polyuria and polydipsia. She has no past medical history of note, and her only medication is the oral contraceptive pill.

On examination, her BP is 122/72 mmHg, with pulse 85/min and regular. She has a postural drop of 15 mmHg on standing. Her BMI is 21. Neurological assessment is unremarkable.

Investigations:

Hb	13.1 g/dl
WCC	8.1×10^9/l
PLT	191×10^9/l
Na^+	143 mmol/l
K^+	4.4 mmol/l
Creatinine	142 µmol/l
Urea	9.1 mmol/l
Glucose	5.4 mmol/l
Ca^{++}	2.21 mmol/l

Which of the following is the most appropriate next investigation?

A Computerised tomography (CT) head

B Urine and plasma osmolality

C Thyroid function

Rana Alnasser's screen

9:17
594-042-7551 Leave

A 28-year-old woman presents to the Endocrinology Clinic for review. She recently suffered a fall whilst at a nightclub and was knocked out for a few minutes.

Since then, over the past few weeks, she has suffered polyuria and polydipsia. She has no past medical history of note, and her only medication is the oral contraceptive pill.

On examination, her BP is 122/72 mmHg, with pulse 85/min and regular. She has a postural drop of 15 mmHg on standing. Her BMI is 21. Neurological assessment is unremarkable.

Investigations:

Hb	13.1 g/dl
WCC	8.1×10^9/l
PLT	191×10^9/l
Na^+	143 mmol/l
K^+	4.4 mmol/l
Creatinine	142 µmol/l
Urea	9.1 mmol/l
Glucose	5.4 mmol/l
Ca^{++}	2.21 mmol/l

Which of the following is the most appropriate next investigation?

Your answer was correct

A Computerised tomography (CT) head

B Urine and plasma osmolality

Audio Video Share Participants More

B Urine and plasma osmolality

The diagnosis to exclude is diabetes insipidus (DI) due to the head injury, and urine and plasma osmolality is an appropriate non-invasive first step in excluding DI. Inappropriately low urine osmolality in the presence of a raised plasma osmolality is suggestive of the diagnosis, and a water deprivation test would be the obvious next step after this.

A Computerised tomography (CT) head

In the absence of focal neurology, a CT head isn't indicated before further biochemistry is obtained.

C Thyroid function

The lack of signs of hypo- or hyperthyroidism implies that thyroid function testing is most likely to be normal.

D Urinary sodium

Urinary sodium is more useful in the assessment of syndrome of inappropriate antidiuretic hormone secretion (SIADH) and of acute tubular necrosis.

E Water deprivation test

A water deprivation test is the default next investigation after a spot urine and plasma osmolality.

Rate this question:

Next Question

9:19
594-042-7551
Leave

A 16-year-old girl who is 1.95 m in height comes to the clinic with her parents because they are concerned that she is excessively tall. She entered puberty normally at the age of 13 years, and takes no regular medication. She is achieving at school and is on course for 10 GCSEs.

Her BP is 105/60 mmHg and she has a diastolic murmur loudest in the aortic area. She displays dolichostenomelia and arachnodactyly. Her BMI is 21. Secondary sexual development appears normal.

Which of the following is the most likely diagnosis?

A	Acromegaly
B	Ehler's Danlos syndrome
C	Homocystinuria
D	Marfan's disease
E	Turner's syndrome

Submit

Audio Video Share Participants More

9:19
594-042-7551
Leave

Explanation

D Marfan's disease

Marfan may present as a spontaneous mutation (1/3 of cases), and this occurs more commonly to offspring of older males. The body habitus is typical for Marfan, and the murmur is consistent with aortic valve disease seen in that condition. Of key importance is the control of blood pressure to prevent progression to aortic dissection, as such patients are treated with prophylactic beta blockade or ACE inhibition. Lens dislocation is common, as are periodontic disease and joint dislocations. Pregnancy is thought to be associated with a significantly increased risk of aortic rupture, and specialist input in management is therefore recommended.

A Acromegaly

Acromegaly is associated with other features such as increase in the size of the lower jaw or fingers, soft tissue swelling, hypertension and diabetes, none of which are seen here.

B Ehler's Danlos syndrome

Although Ehlers Danlos, like Marfan, is associated with hypermobility, it is also, however, associated with normal adult height.

C Homocystinuria

Although the presentation of homocystinuria is similar to that of Marfan, the condition is usually associated with learning difficulties.

Audio Video Share Participants More

9:22

A 44-year-old woman comes to the clinic complaining of shortness of breath and a choking sensation, particularly when she goes to bed. She has seen the GP, been given a diagnosis of anxiety and started on sertraline. On examination she has an obvious multinodular goitre.

Investigations:

Hb	12.7 g/dl
WCC	5.9 x10⁹/l
PLT	194 x109/l
Na^+	139 mmol/l
K^+	4.9 mmol/l
Creatinine	100 µmol/l
TSH	3.5 U/l (<0.5-4.5)
Ultrasound	Multiple thyroid nodules, very large goitre

Which of the following is the most appropriate therapy?

A Radioiodine

B Carbimazole

C Propylthiouracil

D Observation

E Sub-total thyroidectomy

21190

Rana Alnasser's screen

E Sub-total thyroidectomy

The fact this woman has symptoms of thoracic inlet obstruction when she lies flat in bed raises the possibility that she may have significant tracheal compression because of her goitre. There is some debate about whether sub-total or total thyroidectomy is the most appropriate option, with slow re-growth and the possibility of malignant change favouring the latter, but this is countered with increased potential risk of postoperative hypoparathyroidism and recurrent laryngeal nerve palsy.

A Radioiodine

Radioiodine is not warranted in a patient who is euthyroid; it is effective in patients with thyrotoxicosis where increased uptake of iodine is seen.

B Carbimazole

Anti-thyroid drugs will result in hypothyroidism without resolving the goitre seen here.

C Propylthiouracil

Like carbimazole, propylthiouracil will result in hypothyroidism without significant resolution of the goitre.

D Observation

This woman has significant symptoms of thoracic outlet obstruction and is at risk of nocturnal hypoxia.

Rate this question:

A 68-year-old woman who has been taking long term amiodarone therapy comes to the clinic complaining of palpitations at rest. On examination her BP is 135/75 mmHg, her pulse is 90/min at rest. Thyroid gland examination is normal.

Investigations;

Hb	11.9 g/dl
WCC	6.1 x10^9/l
PLT	182 x10^9/l
Na^+	138 mmol/l
K^+	4.9 mmol/l
Creatinine	130 µmol/l
TSH	<0.05 U/l (<0.5-4.5)
Thyroid autoantibodies	-ve
IL-6	Elevated

You change her amiodarone for another agent. Which of the following is the mainstay of therapy in this situation?

A Carbimazole

B Potassium perchlorate

C Thyroidectomy

D Corticosteroids

E Propylthiouracil

A 55 year old woman who has been taking long term amiodarone therapy comes to the clinic complaining of palpitations at rest. On examination her BP is 135/75 mmHg, her pulse is 90/min at rest. Thyroid gland examination is normal.

Investigations;

Hb	11.9 g/dl
WCC	6.1 x10⁹/l
PLT	182 x10⁹/l
Na^+	138 mmol/l
K^+	4.9 mmol/l
Creatinine	130 µmol/l
TSH	<0.05 U/l (<0.5-4.5)
Thyroid autoantibodies	-ve
IL-6	Elevated

You change her amiodarone for another agent. Which of the following is the mainstay of therapy in this situation?

Your answer was correct

A Carbimazole

B Potassium perchlorate

C Thyroidectomy

D Corticosteroids

E Propylthiouracil

Explanation

D	Corticosteroids

This patient has amiodarone-induced thyrotoxicosis (AIT) type 2, as evidenced by the relatively normal thyroid on clinical examination, lack of marked signs of thyrotoxicosis, elevated IL-6 and negative thyroid autoantibodies. Management of AIT type 2 is very different to the management of AIT type 1, with corticosteroids being the mainstay of therapy. This is because AIT type 2 is the result of a direct effect of amiodarone, which leads to thyroiditis.

A	Carbimazole

Anti-thyroid drugs are the mainstay of therapy for AIT type 1, which is more usually associated with positive thyroid antibodies and there is no rise in IL-6. There is no practical difference in efficacy between propylthiouracil and carbimazole.

B	Potassium perchlorate

Potassium perchlorate is utilised to gain acute control of thyroid function in patients who require urgent intervention, for example because of unstable cardiovascular disease.

C	Thyroidectomy

This is considered for patients who fail to respond to medical intervention alone, usually for AIT type 1.

E	Propylthiouracil

This is an alternative to carbimazole as a mainstay of intervention in AIT type 1.

A 27-year-old woman attends the GP 3 months after the birth of her second child. She complains of an increasing inability to cope over the past few months and frequent tearfulness.

On examination, her BP is 132/72 mmHg, her pulse is 66/min and regular, her BMI is 28 and she tells you she has gained weight over the past 2-3 weeks.

Investigations:

TSH	8.5 mU/l (0.4–5.0)
Free T4	6.5 pmol/l (10–22)
Anti TPO antibodies	+

Which of the following diagnoses fits best with this clinical picture?

A Grave's disease

B Hashimoto's thyroiditis

C Post-partum thyroiditis

D Sub-acute thyroiditis

E Riedel's thyroiditis

32697

Submit

C Post-partum thyroiditis

Postpartum thyroiditis is said to develop some 3–7 months after pregnancy and is often associated with mild symptoms such as tiredness or depression. It is said to occur to varying degrees in 5–7% of women, and in 30–52% of cases anti-TPO antibodies are positive. Permanent hypothyroidism is said to develop in around 40% of patients, with increased frequency in patients with positive anti-TPO antibodies. Standard treatment for postpartum hypothyroidism is low-dose thyroxine (around 50 µg), with a withdrawal period after 6 months to measure recovery of thyroid function.

A Grave's disease

Graves' disease is associated with thyrotoxicosis rather than the picture of hypothyroidism seen here.

B Hashimoto's thyroiditis

This is the major differential, but the timing of her symptoms means that postpartum thyroiditis is potentially more likely, and there is potential to recover from the hypothyroidism seen here.

D Sub-acute thyroiditis

Subacute thyroiditis is associated with flu-like symptoms and pain over the thyroid gland rather than the picture seen here.

E Riedel's thyroiditis

This is associated with dense fibrosis of the thyroid gland and notable changes in the anterior neck, not seen in this patient, and not associated with the post-pregnancy

A 27-year-old woman who is 22 weeks' pregnant with her second child comes to the clinic complaining of anxiety and palpitations. She is concerned as she is finding it difficult to maintain an adequate weight. On examination she has a BP of 135/70 mmHg and a resting pulse of 88/min. You palpate a nodule on the left hand side of her thyroid.

Investigations:

Hb	11.4 g/dl
WCC	5.9 x10^9/l
PLT	172 x10^9/l
Na^+	141 mmol/l
K^+	4.0 mmol/l
Creatinine	95 µmol/l
TSH	<0.05 (<0.5-4.5)
Free T4	31 pmol/l (10-22)
Ultrasound	solitary left sided thyroid nodule

FNA reveals an adenoma.

Which of the following is the most appropriate management for her?

A Subtotal thyroidectomy

B Propanolol

C Radioiodine

D Anti-thyroid medication

difficult to maintain an adequate weight. On examination she has a BP of 135/70 mmHg and a resting pulse of 88/min. You palpate a nodule on the left hand side of her thyroid.

Investigations:

Hb	11.4 g/dl
WCC	5.9 x10^9/l
PLT	172 x10^9/l
Na^+	141 mmol/l
K^+	4.0 mmol/l
Creatinine	95 µmol/l
TSH	<0.05 (<0.5-4.5)
Free T4	31 pmol/l (10-22)
Ultrasound	solitary left sided thyroid nodule

FNA reveals an adenoma.

Which of the following is the most appropriate management for her?

A Subtotal thyroidectomy

B Propanolol

C Radioiodine

D Anti-thyroid medication

E Lugol's iodine

D Anti-thyroid medication

In this scenario, options are limited to manage her thyrotoxicosis. Anti-thyroid drugs would form the mainstay of intervention until after delivery. Both propylthiouracil and carbimazole are options, although the former is not recommended in late pregnancy because of the risk of maternal liver dysfunction.

A Subtotal thyroidectomy

This is the option for patients who are unable to tolerate anti-thyroid medication.

B Propanolol

Propanolol offers symptomatic relief only, and will not reduce the risk of fetal loss due to thyrotoxicosis.

C Radioiodine

Radioiodine is contraindicated during pregnancy, and is likely to be unsuitable for this patient for a considerable period of time because of the need to avoid exposure to young children.

E Lugol's iodine

Lugol's iodine is used to acutely control thyrotoxicosis when urgent surgery is considered.

21189

Rate this question:

A 32-year-old woman is referred to the clinic by the Emergency Department. She has had three episodes of collapse over the past 5 months. There is also a history of increased hunger, which has been accompanied by gradual weight gain.

On further questioning, family history reveals no useful information. You elect to admit her for a period of fasting. The morning after admission, after some 16 h without food, she complains of feeling faint.

Investigations:

Glucose	2.1 mmol/l
Insulin	7 mU/l with increased proportion of pro-insulin
C-peptide	Elevated
Cortisol	550 nmol/l

Which of the following diagnoses fits best with this clinical picture?

A Abuse of insulin secretagogues

B Abuse of insulin

C Insulinoma

D Glucagonoma

E Addison's disease

C Insulinoma

After a 15 h fast, the cut-off normal limits for glucose are 2.5 mmol/l and 5 mU/l for insulin. As such, this patient has an inappropriately low glucose and raised insulin level. By 24 h, fasting leads to a detection rate of 78% for insulinoma. If the fast is extended to 72 h, this detection rate increases to 98%. Insulinomas have an incidence of 1-2/million/year, are commoner in women and may be associated with the MEN-1 syndrome in around 10%; 90% of them are less than 2 cm in size. More of the insulin released by an insulinoma remains as pro-insulin, so that pro-insulin levels are often raised as a proportion of total insulin levels.

A Abuse of insulin secretagogues

As she is in hospital, abuse of insulin secretagogues is unlikely.

B Abuse of insulin

Abuse of insulin would lead to raised insulin levels without a corresponding rise in c-peptide.

D Glucagonoma

A glucagonoma would lead to hyperglycaemia, rather than hypoglycaemia.

E Addison's disease

The cortisol levels in this patient are appropriately towards the upper end of the normal range, making Addison's disease very unlikely.

A 42-year-old man presents to the Emergency Department with loss of vision in his right eye. Past history of note includes recurrent episodes of acute pancreatitis. Fundoscopy reveals cotton wool spots and a number of flame haemorrhages. On wider examination there is evidence of eruptive xanthoma on extensor surfaces of upper and lower limbs. Emergency blood testing reveals normal full blood count and U&E, but the lab notes that the sample appears markedly lipaemic. Previous blood lipid results are not available.

Which of the following represents the best long-term management for this patient?

A	Warfarin
B	Clopidogrel
C	Aspirin
D	Fenofibrate
E	Simvastatin

Submit

Rana Alnasser's screen

A 42-year-old man presents to the Emergency Department with loss of vision in his right eye. Past history of note includes recurrent episodes of acute pancreatitis. Fundoscopy reveals cotton wool spots and a number of flame haemorrhages. On wider examination there is evidence of eruptive xanthoma on extensor surfaces of upper and lower limbs. Emergency blood testing reveals normal full blood count and U&E, but the lab notes that the sample appears markedly lipaemic. Previous blood lipid results are not available.

Which of the following represents the best long-term management for this patient?

Your answer was correct

A Warfarin

B Clopidogrel

C Aspirin

D Fenofibrate

E Simvastatin

Explanation

D Fenofibrate

This patient has presented with retinal vein thrombosis and has a past history of recurrent pancreatitis. Together with the clinical findings of eruptive xanthomata and the

D Fenofibrate

This patient has presented with retinal vein thrombosis and has a past history of recurrent pancreatitis. Together with the clinical findings of eruptive xanthomata and the lipaemic sample on testing in the Emergency Department, this picture is highly suggestive of familial hypertriglyceridaemia. The mainstay of management is commencement of fibrate therapy.

A Warfarin

The venous thrombosis is related to hypertriglyceridaemia and is not a result of a coagulation disorder for which antithrombotics are indicated.

B Clopidogrel

Clopidogrel is an antiplatelet agent, the primary role of which is in stroke secondary prevention, post coronary artery stenting, and in patients who are intolerant to aspirin.

C Aspirin

Aspirin is indicated for secondary prevention of coronary artery disease and in primary stroke prevention.

E Simvastatin

Statins including simvastatin have only modest effects on triglycerides and as such are not indicated here.

6550

Rate this question:

A 26-year-old dancer is referred by her dentist since he was concerned about the erosion of enamel on her teeth. The patient herself reports no health problems, and feels generally fit and well, admitting to exercising for 3 hours every day. However, examination of the patient shows her to be thin and she is found to weigh 48 kg but is 1.7 m tall. Routine laboratory investigations are performed and hypokalaemia is noted.

Which of the following would be the most appropriate investigation?

A	Bartter's syndrome genetic testing
B	Magnesium levels
C	Carry out an initial screen for eating disorders
D	24-hour urinary catecholamines
E	24-hour urinary 5HIAA

70809

Submit

9:40
594-042-7551
Leave

A 26-year-old dancer is referred by her dentist since he was concerned about the erosion of enamel on her teeth. The patient herself reports no health problems, and feels generally fit and well, admitting to exercising for 3 hours every day. However, examination of the patient shows her to be thin and she is found to weigh 48 kg but is 1.7 m tall. Routine laboratory investigations are performed and hypokalaemia is noted.

Which of the following would be the most appropriate investigation?

Your answer was correct

A Bartter's syndrome genetic testing

B Magnesium levels

C Carry out an initial screen for eating disorders

D 24-hour urinary catecholamines

E 24-hour urinary 5HIAA

Explanation

C Carry out an initial screen for eating disorders

Anorexia nervosa is an eating disorder characterised by severe weight loss leading to significant physiological consequences – affected patients starve themselves into an emaciated state yet continue to convince themselves that they are overweight. It is a condition that predominantly

Audio Video Share Participants More

9:40
MyPastest 594-042-7551 Leave
https://mypastest.pastest.com

C Carry out an initial screen for eating disorders

Anorexia nervosa is an eating disorder characterised by severe weight loss leading to significant physiological consequences – affected patients starve themselves into an emaciated state yet continue to convince themselves that they are overweight. It is a condition that predominantly affects young women (M:F ratio 1:50) especially in industrialised countries where cultural pressures encourage a woman to be thin. Use of laxatives to drive weight loss is common.

An initial screen for eating disorders, and a referral to an eating disorder service if appropriate, would be the most appropriate next step.

A Bartter's syndrome genetic testing

Although hypokalaemia is reported here, the more likely cause is purgative abuse rather than Bartter's syndrome.

B Magnesium levels

Hypomagnesaemia may be present as a result of purgative abuse, although it does not reveal the likely underlying cause.

D 24-hour urinary catecholamines

24-hour urinary catecholamines are used as the screen for phaeochromocytoma, and apart from hypokalaemia there are no other pointers to a phaeochromocytoma.

Audio Video Share Participants More

A 40-year-old solicitor who is attending the Hypertension Clinic describes a 3-month-history of episodes of headaches and dizziness. In addition he often experiences vague central abdominal discomfort. He feels that he has lost some weight recently, though this may be related to a low-fat diet he has been trying. Examination shows a standing BP of 152/90 mmHg. In addition there appears to be a thyroid swelling which has not previously been noted. His bone profile revealed a corrected calcium of 2.74 mmol/l. He also had an oral glucose tolerance test with his GP, who was concerned about the weight loss, which was normal, hence excluding the diagnosis of diabetes.

Which one of the following is most likely to be the cause of his hypertension?

A Cushing's syndrome

B Addison's disease

C Abuse of growth hormone

D Phaeochromocytoma

E Graves' disease

Submit

Rana Alnasser's screen

A 40-year-old solicitor who is attending the Hypertension Clinic describes a 3-month-history of episodes of headaches and dizziness. In addition he often experiences vague central abdominal discomfort. He feels that he has lost some weight recently, though this may be related to a low-fat diet he has been trying. Examination shows a standing BP of 152/90 mmHg. In addition there appears to be a thyroid swelling which has not previously been noted. His bone profile revealed a corrected calcium of 2.74 mmol/l. He also had an oral glucose tolerance test with his GP, who was concerned about the weight loss, which was normal, hence excluding the diagnosis of diabetes.

Which one of the following is most likely to be the cause of his hypertension?

Your answer was correct

A	Cushing's syndrome
B	Addison's disease
C	Abuse of growth hormone
D	Phaeochromocytoma
E	Graves' disease

Explanation

D	Phaeochromocytoma

The episodic symptoms of headache and dizziness, the hypertension, the hypercalacaemia and the thyroid mass fit better with a phaeochromocytoma in the context of MEN 2A. MEN 2 presents with medullary thyroid carcinoma and

D Phaeochromocytoma

The episodic symptoms of headache and dizziness, the hypertension, the hypercalacaemia and the thyroid mass fit better with a phaeochromocytoma in the context of MEN 2A. MEN 2 presents with medullary thyroid carcinoma and phaechromocytoma. The third component could be parathyroid hyperplasia (MEN 2A) or mucutaneous neuromas and marfanoid habitus (MEN 2B).

A Cushing's syndrome

Cushing syndrome is a cause of secondary hypertension but would not cause weight loss. The typical feature is weight gain with central distribution.

B Addison's disease

Addison's could be considered in the context of dizziness and abdominal pain, but hypertension would be unusual in this condition. It mainly resents with postural hypotension, nausea, abdominal pain and hyperpigmentation.

C Abuse of growth hormone

Abuse of growth hormone is another cause for secondary hypertension. It may also lead to weight gain, insulin resistance and impaired glucose tolerance, which is not the case in this scenario.

E Graves' disease

Graves' disease can cause a diffusely enlarged, non-tender goitre and also mild hypercalcaemia in the acute phase (thyrotoxicosis). However, dizziness, abdominal pain and hypertension are not features of the condition.

An 63-year-old visitor from Saudi Arabia attends the clinic with her son after referral from her general practitioner (GP). He has noticed that she has symptoms of hypercalcaemia, and is worried about hyperparathyroidism.

On further questioning, you find out she has been taking Rennie anti-indigestion tablets three or four times per day, and has increased these as she has felt progressively more nauseous. Additionally, she is taking a calcium supplement to guard against bone fracture as her mother suffered from fractures late in life. Additional symptoms include fatigue, and apparently while in Saudi Arabia she was started on sertraline for depression.

Investigations:

Hb	12.9 g/dl
WCC	5.6×10^9/l
PLT	145×10^9/l
ESR	18 mm/hr
Na^+	140 mmol/l
K^+	5.0 mmol/l
Creatinine	185 µmol/l
Ca^{++}	2.85 mmol/l
PTH	low
CXR	No focal lesion seen

Which of the following is the most likely diagnosis?

A Familial hypercalcaemic hypocalciuria

B Hypoparathyroidism

fractures late in life. Additional symptoms include fatigue, and apparently while in Saudi Arabia she was started on sertraline for depression.

Investigations:

Hb	12.9 g/dl
WCC	5.6×10^9/l
PLT	145×10^9/l
ESR	18 mm/hr
Na^+	140 mmol/l
K^+	5.0 mmol/l
Creatinine	185 µmol/l
Ca^{++}	2.85 mmol/l
PTH	low
CXR	No focal lesion seen

Which of the following is the most likely diagnosis?

A Familial hypercalcaemic hypocalciuria

B Hypoparathyroidism

C Primary hyperparathyroidism

D Hypercalcaemia of malignancy

E Milk-alkali syndrome

Explanation

E	Milk-alkali syndrome

This patient has a markedly elevated oral calcium intake, as illustrated by her propensity to take both calcium-containing indigestion medications (Rennies is a mixture of calcium and magnesium carbonate) and calcium supplementation to reduce the risk of bone fracture. Additionally, she has various symptoms of hypercalcaemia including the nausea, lethargy and depression reported here. The condition can lead to mild renal impairment, as we've seen with her elevated serum creatinine, but this may well return to normal once calcium intake is reduced.

A	Familial hypercalcaemic hypocalciuria

FHH is usually asymptomatic, although some patients may present with renal stones, or very rarely with acute pancreatitis.

B	Hypoparathyroidism

Hypoparathyroidism is associated with hypocalcaemia rather than the elevated calcium seen here.

C	Primary hyperparathyroidism

In the absence of the strong history of excess calcium and alkali ingestion here, primary hyperparathyroidism would be considered the main differential, although a normal or slightly elevated PTH, rather than the low value seen here would be expected.

D	Hypercalcaemia of malignancy

Hypercalcaemia of malignancy is a possibility given the patient's age, but the lack of other symptoms, apart from

present with renal stones, or very rarely with acute pancreatitis.

B Hypoparathyroidism

Hypoparathyroidism is associated with hypocalcaemia rather than the elevated calcium seen here.

C Primary hyperparathyroidism

In the absence of the strong history of excess calcium and alkali ingestion here, primary hyperparathyroidism would be considered the main differential, although a normal or slightly elevated PTH, rather than the low value seen here would be expected.

D Hypercalcaemia of malignancy

Hypercalcaemia of malignancy is a possibility given the patient's age, but the lack of other symptoms, apart from indigestion, and relatively normal blood picture including ESR and haemoglobin, count against this.

Rate this question:

© Pastest 2019

A 42-year-old woman is admitted to hospital with central chest pain suspicious of angina. She has a history of resistant hypertension, currently managed by her GP with Ramipril, amlodipine and indapamide. She tells you that her mother suffered from Conn syndrome and she is concerned she may have the same problem. Her BP is 155/95, pulse is 84 and regular. Her BMI is 22.

What abnormality would you expect to find in the patient's workup if she was suffering from Conn syndrome?

A	Hyponatraemia
B	Elevated serum creatinine
C	Metabolic acidosis
D	Hypokalaemia
E	Hypernatraemia

Submit

B Elevated serum creatinine

C Metabolic acidosis

D Hypokalaemia

E Hypernatraemia

Explanation

D Hypokalaemia

Conn syndrome, a cause of secondary hypertension, is usually due to an aldosterone-secreting adenoma which leads to hyporeninaemic hyperaldosteronism. The rule of thumb is that in patients prescribed an ACE inhibitor, hypokalaemia is highly suggestive of the condition. It was previously thought that adrenal adenomas were responsible for the majority of cases of hyporeninaemic hyperaldosteronism, but it's now realised that the split is much more 50:50. Aldosterone has an action on the distal tubule of the kidney to increase sodium resorption and enhance potassium and hydrogen ion loss. Renin levels are suppressed and do not rise with an upright posture. Medical treatment includes a low-sodium diet with an aldosterone receptor antagonist (spironolactone). Surgical therapy is usually indicated after localisation of adenoma.

A Hyponatraemia

Hyponatraemia is associated with adrenal insufficiency, not with hyporeninaemic hyperaldosteronism.

B Elevated serum creatinine

This patient may yet develop intrinsic renal damage as a result of chronic hypertension, and thus creatinine values

Explanation

D Hypokalaemia

Conn syndrome, a cause of secondary hypertension, is usually due to an aldosterone-secreting adenoma which leads to hyporeninaemic hyperaldosteronism. The rule of thumb is that in patients prescribed an ACE inhibitor, hypokalaemia is highly suggestive of the condition. It was previously thought that adrenal adenomas were responsible for the majority of cases of hyporeninaemic hyperaldosteronism, but it's now realised that the split is much more 50:50. Aldosterone has an action on the distal tubule of the kidney to increase sodium resorption and enhance potassium and hydrogen ion loss. Renin levels are suppressed and do not rise with an upright posture. Medical treatment includes a low-sodium diet with an aldosterone receptor antagonist (spironolactone). Surgical therapy is usually indicated after localisation of adenoma.

A Hyponatraemia

Hyponatraemia is associated with adrenal insufficiency, not with hyporeninaemic hyperaldosteronism.

B Elevated serum creatinine

This patient may yet develop intrinsic renal damage as a result of chronic hypertension, and thus creatinine values may well be normal.

C Metabolic acidosis

Mineralocorticoid excess leads to presentation with elevated bicarbonate and a metabolic alkalosis, not acidosis.

E Hypernatraemia

responsible for the majority of cases of hyporeninaemic hyperaldosteronism, but it's now realised that the split is much more 50:50. Aldosterone has an action on the distal tubule of the kidney to increase sodium resorption and enhance potassium and hydrogen ion loss. Renin levels are suppressed and do not rise with an upright posture. Medical treatment includes a low-sodium diet with an aldosterone receptor antagonist (spironolactone). Surgical therapy is usually indicated after localisation of adenoma.

A Hyponatraemia

Hyponatraemia is associated with adrenal insufficiency, not with hyporeninaemic hyperaldosteronism.

B Elevated serum creatinine

This patient may yet develop intrinsic renal damage as a result of chronic hypertension, and thus creatinine values may well be normal.

C Metabolic acidosis

Mineralocorticoid excess leads to presentation with elevated bicarbonate and a metabolic alkalosis, not acidosis.

E Hypernatraemia

Although serum sodium may well be at the upper end of the normal range, frank hypernatraemia is often not seen in patients with Conn syndrome.

Rate this question:

Next Question

A 38-year-old woman presents with decreased libido, vaginal dryness and absence of periods for the past 4 months.

Most recently, she has begun to suffer embarrassing milk leakage from her breasts on only minor nipple stimulation. Medication history includes use of the oral contraceptive pill. Prolactin level is 1300 IU and she maintains that she could not possibly be pregnant as she has bought a home test, which is negative.

Her BP is normal at 132/72 mmHg, pulse is 74/min and regular and her BMI is 23.

Which of the following is most likely to yield the diagnosis?

A	Magnetic resonance imaging (MRI) scan of the pituitary fossa
B	Laboratory pregnancy test
C	Thyroid function testing
D	Abdominal ultrasound scan
E	Gonadotropin-releasing hormone (GnRH) testing

Submit

9:52

MyPastest
https://mypastest.pastest.com

A 38-year-old woman presents with decreased libido, vaginal dryness and absence of periods for the past 4 months.

Most recently, she has begun to suffer embarrassing milk leakage from her breasts on only minor nipple stimulation. Medication history includes use of the oral contraceptive pill. Prolactin level is 1300 IU and she maintains that she could not possibly be pregnant as she has bought a home test, which is negative.

Her BP is normal at 132/72 mmHg, pulse is 74/min and regular and her BMI is 23.

Which of the following is most likely to yield the diagnosis?

Your answer was correct

A Magnetic resonance imaging (MRI) scan of the pituitary fossa

B Laboratory pregnancy test

C Thyroid function testing

D Abdominal ultrasound scan

E Gonadotropin-releasing hormone (GnRH) testing

Explanation

A Magnetic resonance imaging (MRI) scan of the pituitary fossa

A Magnetic resonance imaging (MRI) scan of the pituitary fossa

Prolactin levels are too elevated to be due to the oral contraceptive pill; with this symptomatic picture it is important to rule out a prolactinoma or other pituitary tumour leading to raised prolactin levels due to pressure effects. MRI scanning is needed to determine tumour size and location. Given her prolactin level, the most likely diagnosis is a micro-adenoma producing prolactin; as such, the management of choice is with a dopamine agonist such as bromocriptine or cabergoline in the first instance.

B Laboratory pregnancy test

Shop-bought pregnancy tests have an accuracy of above 95%, so pregnancy is unlikely; however, it would be reasonable to perform a re-test to make absolutely sure that it is negative.

C Thyroid function testing

Given that there has been no weight loss or other symptoms of thyrotoxicosis, hyperthyroidism as a cause of her amenorrhoea is unlikely. Additionally, it is hypothyroidism rather than thyrotoxicosis that is associated with elevated prolactin levels.

D Abdominal ultrasound scan

Elevated prolactin levels are noted in some ovarian and endometrial cancers and with pregnancy, although these are unlikely diagnoses given the absence of abdominal symptoms and negative pregnancy test.

reasonable to perform a re-test to make absolutely sure that it is negative.

C Thyroid function testing

Given that there has been no weight loss or other symptoms of thyrotoxicosis, hyperthyroidism as a cause of her amenorrhoea is unlikely. Additionally, it is hypothyroidism rather than thyrotoxicosis that is associated with elevated prolactin levels.

D Abdominal ultrasound scan

Elevated prolactin levels are noted in some ovarian and endometrial cancers and with pregnancy, although these are unlikely diagnoses given the absence of abdominal symptoms and negative pregnancy test.

E Gonadotropin-releasing hormone (GnRH) testing

This is used in the work-up primarily of precocious and delayed puberty associated with low LH and FSH levels.

Rate this question:

© Pastest 2019

Rana Alnasser's screen

A 45-year-old woman was referred by her general practitioner (GP) for the management of her type 2 diabetes mellitus and persistent hypertension. In addition to insulin and metformin for her diabetes, she was also on sertraline and lorazepam for her depression, and carbamazepine for her agonizing post-herpetic neuralgia.

On examination, she was obese with a round face and moderate facial acne. She was a heavy drinker. An overnight dexamethasone suppression test showed failure of suppression of cortisol. A provisional diagnosis of Cushing syndrome was made. However, computed tomography (CT) of the chest and abdomen revealed normal adrenal glands and no evidence of malignancy, and the serum cortisol measurement showed normal daily variation. Further investigations including a midnight cortisol later excluded Cushing syndrome.

What was the reason for her failed initial dexamethasone suppression test?

A	Interference of metformin with the cortisol radioimmunoassay
B	Variance of baseline cortisol due to fluctuating glycaemic control
C	The induction of the cytochrome p450 system by alcohol and carbamazepine
D	Fluctuating level of adrenocorticotropic hormone (ACTH) and cortisol due to non-compliance with insulin treatment
E	Ectopic ACTH production

Rana Alnasser's screen

C The induction of the cytochrome p450 system by alcohol and carbamazepine

The overnight dexamethasone suppression test is usually used as a screening test for Cushing syndrome. This test has a false-positive rate of up to 2–12% (meaning that a diagnosis of Cushing is suggested incorrectly). Dexamethasone is primarily metabolised by the cytochrome p450 system, specifically by the CYP3A4 isoenzyme. Several drugs such as phenobarbital, carbamazepine and rifampicin are enzyme inducers, and therefore lead to increased activity of CYP3A4 enzyme, and can thus result in false-positive dexamethasone suppression tests. Considerable increases in cytochrome 450 enzyme activity can be seen in smokers and people who drink alcohol regularly.

D Fluctuating level of adrenocorticotropic hormone (ACTH) and cortisol due to non-compliance with insulin treatment

Non-compliance with insulin treatment is likely to lead to poor glycaemic control, but there is not known to be a link between this and levels of ACTH or cortisol.

A Interference of metformin with the cortisol radioimmunoassay

Patients need to be off all oestrogen-containing medication for six weeks prior to any measurements of serum cortisol, but metformin is not known to effect cortisol.

B Variance of baseline cortisol due to fluctuating glycaemic control

Whilst patients with diabetes often have slightly higher [illegible] there is no link between raised

Rana Alnasser's screen

tumour, and we are given no suggestion in the history of one here. Very high ACTH levels are highly suggestive of an ectopic source of ACTH.

A high-dose dexamethasone suppression test is used by some units to help differentiate between pituitary and ectopic sources of ACTH in difficult to diagnose Cushing syndrome, where ACTH fails to suppress when the production is ectopic.

References

1. Privitera MR, Greden JF, Gardner RW, Ritchie JC, Carroll BJ. Interference by carbamazepine with the dexamethasone suppression test. *Biol Psychiatry* 1982; 17: 611–20.
2. Meikle AW, Stanchfield JB, West CD, Tyler FH. Hydrocortisone suppression test for Cushing syndrome: therapy with anticonvulsants. *Arch Intern Med* 1974; 134: 1068–71.

Useful mnemonic

Enzyme inducers = SCRAP GP (sulphonylureas, carbamazepine, rifampicin, alcohol, phenytoin, griseofulvin, phenobartbitol)

Rate this question:

Next Question

Previous Q... Tag Questi... Feedback End Session

Blog About Pastest Contact Us Help

© Pastest 2019

A 34-year-old woman presents to the Emergency Department with increasing nausea and vomiting over the past 72 h. She has a history of autoimmune hypothyroidism controlled with thyroxine replacement, but has no other significant past medical illnesses.

On further questioning, it transpires that she has lost weight and been feeling increasingly lethargic, having passed out twice at work, in the last three months.

Examination reveals a BP of 100/80 mmHg, which falls to 85/65 mmHg on standing; her pulse is 80/min and regular. She is slim and tanned with a BMI of 20.

Investigations:

Hb	11.9 g/dl
WCC	7.1×10^9/l
PLT	188×10^9/l
Na^+	130 mmol/l
K^+	4.9 mmol/l
Creatinine	110 μmol/l
Urea	10.2 mmol/l
Glucose	4.1 mmol/l
TSH	2.1 U/l

Which of the following is the most important step?

A IV hydrocortisone

B IV normal saline

C Oral fludrocortisone

D Synacthen test the following day

Na^+	130 mmol/l
K^+	4.9 mmol/l
Creatinine	110 µmol/l
Urea	10.2 mmol/l
Glucose	4.1 mmol/l
TSH	2.1 U/l

Which of the following is the most important step?

A IV hydrocortisone

B IV normal saline

C Oral fludrocortisone

D Synacthen test the following day

E Abdominal ultrasound scan (USS)

40246

Submit

© Pastest 2019

significant past medical illnesses.

On further questioning, it transpires that she has lost weight and been feeling increasingly lethargic, having passed out twice at work, in the last three months.

Examination reveals a BP of 100/80 mmHg, which falls to 85/65 mmHg on standing; her pulse is 80/min and regular. She is slim and tanned with a BMI of 20.

Investigations:

Hb	11.9 g/dl
WCC	7.1×10^9/l
PLT	188×10^9/l
Na^+	130 mmol/l
K^+	4.9 mmol/l
Creatinine	110 µmol/l
Urea	10.2 mmol/l
Glucose	4.1 mmol/l
TSH	2.1 U/l

Which of the following is the most important step?

A IV hydrocortisone

B IV normal saline

C Oral fludrocortisone

D Synacthen test the following day

E Abdominal ultrasound scan (USS)

A IV hydrocortisone

The presentation here is consistent with Addison's disease. Given the significantly abnormal clinical chemistry, coupled with worsening nausea and vomiting, there is no opportunity to delay initiation of therapy whilst awaiting a Synacthen test. Commencing IV hydrocortisone is therefore the initial intervention of choice. In this case, given the previous history of autoimmune thyroid disease, autoimmune adrenal failure is the most likely cause here. Adrenal insufficiency is excluded in the Synacthen test by an incremental rise in cortisol of > 200 nmol/L and a 30 min value > 600 nmol/L. One dose of hydrocortisone the previous evening is unlikely to affect interpretation of the test.

B IV normal saline

Although IV normal saline may temporarily improve blood pressure, it won't impact on the underlying cause, in this case adrenal insufficiency.

C Oral fludrocortisone

Oral fludrocortisone is used in patients who fail to maintain postural blood pressure despite adequate corticosteroid replacement.

D Synacthen test the following day

Delaying intervention until after a Synacthen test is inappropriate given the significant hypotension and

E Abdominal ultrasound scan (USS)

This may reveal adrenal atrophy or calcification, but it won't provide an estimation of adrenal function.

B IV normal saline

Although IV normal saline may temporarily improve blood pressure, it won't impact on the underlying cause, in this case adrenal insufficiency.

C Oral fludrocortisone

Oral fludrocortisone is used in patients who fail to maintain postural blood pressure despite adequate corticosteroid replacement.

D Synacthen test the following day

Delaying intervention until after a Synacthen test is inappropriate given the significant hypotension and

E Abdominal ultrasound scan (USS)

This may reveal adrenal atrophy or calcification, but it won't provide an estimation of adrenal function.

© Pastest 2019

A 51-year-old woman is brought in to the Emergency Department severely unwell, with a 3 h history of severe shortness of breath and weakness. On admission she is tachycardic and hypotensive, with a blood pressure (BP) of 80/60 mmHg. She is afebrile, and examination of her chest reveals bilateral fine crackles up to her mid-zones. During initial assessment her BP falls to 60 mmHg systolic and she is treated with inotropes. She makes a gradual recovery and an echocardiogram performed that day reveals severe cardiomyopathy with a left ventricular ejection fraction of 30%. Initial blood tests including full blood count, urea and electrolytes, troponin and liver function tests are within normal limits. On further questioning the patient admits to having had recurrent episodes of headache over the past month. She has no other significant medical or family history. During a work-up for the cause of her presentation, a computerised tomography scan (CT) of the abdomen is performed which shows a 5 cm, enhancing intra-abdominal mass close to the origin of the inferior mesenteric artery.

What is the most appropriate next step in investigation?

A	CT-guided biopsy of the abdominal lesion
B	^{131}I-metaiodobenzylguanidine (MIBG)) scan
C	24 h urinary catecholamines
D	Drug screen
E	Exercise stress test

C 24 h urinary catecholamines

Phaeochromocytoma is a rare, catecholamine-secreting tumour most commonly found in the adrenal medulla. Although the typical presentation is that of hypertension with paroxysms of headache, palpitations and sweating, it can also present with severe hypotension from catecholamine-induced cardiomyopathy, as in this case. Approximately 10% of tumours are extra-adrenal (sometimes called paragangliomas), 10% are bilateral and 10% are malignant. Phaeochromocytomas are associated with a number of syndromes, including multiple endocrine neoplasia (MEN) 2A and MEN 2B.

Diagnosis is made by demonstrating elevated catecholamine levels in a 24 h urine sample. Treatment is by surgical excision of the tumour after pharmacological alpha- and beta-adrenergic blockade.

B ^{131}I-metaiodobenzylguanidine (MIBG)) scan

A scan with ^{131}iodine-labelled metaiodobenzylguanidine (MIBG) is used in cases where a tumour is confirmed biochemically but cannot be identified on computerised tomography (CT) or magnetic resonance imaging (MRI) scanning.

A CT-guided biopsy of the abdominal lesion

The aim of the first line of investigations for an adrenal tumour is to determine whether it is functioning or not; therefore, a full hormonal profile

(adrenal androgens, renin:aldosterone ratio, urinary cathecholamines) is the first line of treatment. If the tumour proves to be functioning, then surgical resection needs to be considered. If it is a non-functioning adenoma, surveillance depending on radiological criteria (size of the tumour, consistency) is recommended

cathecholamines) is the first line of treatment. If the tumour proves to be functioning, then surgical resection needs to be considered. If it is a non-functioning adenoma, surveillance depending on radiological criteria (size of the tumour, consistency) is recommended.

D Drug screen

In the context of the history and clinical presentation (pulmonary oedema with left ventricular failure), drug screen is not appropriate. Drug screen could be considered when cocaine ingestion may be considered in the differential – for instance, when a relatively young patient presents acutely with symptoms of heart failure that may be secondary to myocardial infarction.

E Exercise stress test

This lady has clinically symptoms and signs of heart failure confirmed by ECHO, and the priority is to treat the underlying cause (phaeochromocytoma). An exercise stress test would not add much in terms of diagnosis.

Rate this question:

Next Question

Previous Q... Tag Questi... Feedback End Session

Blog About Pastest Contact Us Help

© Pastest 2019

A 72-year-old woman presents with severe vomiting and dehydration. There has been a history of tiredness, weakness, malaise and weight loss which has increased over the past few months.

Other past medical history of note involves a left breast lumpectomy 6 years previously and increasing bone and joint pain over the past few years.

On examination, she looks dehydrated. Her BP is 100/60 mmHg, with a pulse of 96/min. Her BMI is 21. There is a scar over her left breast and she is tender over the lower part of her back and over her left hip.

Investigations:

Corrected Ca^+	3.6 mmol/l
Urea	15.2 mmol/l
Creatinine	286 µmol/l
Albumin	28 g/l
Hb	10.8 g/dl
Viscosity	2.8 mPa/s (1.5-1.72)
Urinalysis	Proteinuria

Which of the following is the initial management of choice in this case?

A IV normal saline

B IV 5% dextrose

C Furosemide (frusemide)

D Bendroflumethiazide

Explanation

A IV normal saline

Initial management of choice would be fluid rehydration with normal saline, aiming for 3–6 l in 24 h depending on fluid and cardiovascular status. Rehydration can significantly reduce calcium, allowing for the impact of other interventions to take effect. Although the history of lumpectomy may be a pointer towards carcinoma of the breast, the raised viscosity and anaemia are suggestive of myeloma. It is likely that the development of renal amyloidosis secondary to the myeloma has precipitated the proteinuria seen here. Bisphosphonates are the mainstay of therapy for malignant hypercalcaemia.

B IV 5% dextrose

Hypercalcaemia is associated with relative salt and water depletion, and therefore normal saline is the default choice for initial fluid replacement.

C Furosemide (frusemide)

IV furosemide without rehydration first can drive a further increase in creatinine, and worsening pre-kidney disease.

D Bendroflumethiazide

Thiazide diuretics promote calcium retention and should therefore be avoided here.

E IV calcitonin

Although IV calcitonin is used as a treatment for acute

Explanation

A IV normal saline

Initial management of choice would be fluid rehydration with normal saline, aiming for 3–6 l in 24 h depending on fluid and cardiovascular status. Rehydration can significantly reduce calcium, allowing for the impact of other interventions to take effect. Although the history of lumpectomy may be a pointer towards carcinoma of the breast, the raised viscosity and anaemia are suggestive of myeloma. It is likely that the development of renal amyloidosis secondary to the myeloma has precipitated the proteinuria seen here. Bisphosphonates are the mainstay of therapy for malignant hypercalcaemia.

B IV 5% dextrose

Hypercalcaemia is associated with relative salt and water depletion, and therefore normal saline is the default choice for initial fluid replacement.

C Furosemide (frusemide)

IV furosemide without rehydration first can drive a further increase in creatinine, and worsening pre-kidney disease.

D Bendroflumethiazide

Thiazide diuretics promote calcium retention and should therefore be avoided here.

E IV calcitonin

Although IV calcitonin is used as a treatment for acute hypercalcaemia, IV normal saline is the initial step given that the majority of patients are significantly fluid depleted at presentation.

A 49-year-old woman with a history of type 2 diabetes comes to the Diabetes Clinic for review. She has been taking metformin for the last 3 years but is gradually losing control of her blood sugars.

Her current metformin dose is 1g BD. She has a history of hypertension which is currently managed with ramipril and indapamide.

On examination, her BP is 155/85 mmHg and pulse is 67/min and regular. Her BMI is 36.

Investigations:

Hb	124 g/l
WCC	6.1×10^9 /l
PLT	203×10^9 /l
Na	138 mmol/l
K	4.5 mmol/l
Creatinine	102 µmol/l
HbA1c	62 mmol/mol (7.8%)

Which of the following is the most appropriate next step?

A Dapagliflozin

B Glimepiride

C Liraglutide

D Pioglitazone

E Saxagliptin

A Dapagliflozin

This patient is obese and is outside the guidance for good HbA1c control set by NICE at 58mmol/mol for HbA1c; as such she requires therapy intensification. Out of the options given, the SGLT-2 inhibitor is the most appropriate option because it results in modest calorie spillage into the urine, and has positive effects on blood pressure control. Patients on average see around 2% weight loss over 6 months, although in some much greater weight reduction is seen. Evidence from cardiovascular outcomes amongst the class, (the Empa-Reg study for empagliflozin), suggests a positive impact on cardiovascular outcomes.

B Glimepiride

Sulphonylureas promote weight gain and increase the risk of hypoglycaemia, glimepiride is therefore suboptimal as a therapy option for this patient.

C Liraglutide

Although liraglutide is likely to drive greater weight loss versus SGLT-2, it is not recommended by NICE guidelines to introduce a GLP-1 at this stage.

D Pioglitazone

Glitazones promote weight gain, fluid retention and over the longer term have a negative impact on bone mineral density. They are therefore best avoided in a relatively young, obese woman.

E Saxagliptin

DPPIV inhibitors are a possible option after metformin, and do not increase the risk of hypoglycaemia. SGLT-2

Rana Alnasser's screen

C Liraglutide

Although liraglutide is likely to drive greater weight loss versus SGLT-2, it is not recommended by NICE guidelines to introduce a GLP-1 at this stage.

D Pioglitazone

Glitazones promote weight gain, fluid retention and over the longer term have a negative impact on bone mineral density. They are therefore best avoided in a relatively young, obese woman.

E Saxagliptin

DPPIV inhibitors are a possible option after metformin, and do not increase the risk of hypoglycaemia. SGLT-2 inhibition is however preferred because it promotes greater weight loss and may be associated with positive cardiovascular outcomes, whereas DPPIV inhibitors have a neutral effect on CV outcomes in reported studies.

Rate this question:

Next Question

Previous Q... Tag Questi... Feedback End Session

Blog About Pastest Contact Us Help

© Pastest 2019

A 39-year-old woman presents to the clinic with polyuria, polydipsia and lethargy. She had undergone a total thyroidectomy some 2 years previously. On examination her BP is 148/89 mmHg, her pulse 80/min and regular. She has a neck scar consistent with thyroidectomy.

Investigations:

Hb	12.1 g/dl
WCC	7.3 $\times 10^9$/l
PLT	201 $\times 10^9$/l
Na^+	139 mmol/l
K^+	4.3 mmol/l
Creatinine	155 µmol/l
Ca^{++}	2.9 mmol/l
PTH	10.1 pmol/l (0.9-5.4)
Glucose	8.1 mmol/l

Which of the following is the most likely overarching diagnosis in this patient?

A Thyroid carcinoma with new recurrence

B Secondary hyperparathyroidism

C MEN-1

D MEN-2b

E MEN-2a

her BP is 148/89 mmHg, her pulse 80/min and regular. She has a neck scar consistent with thyroidectomy.

Investigations:

Hb	12.1 g/dl
WCC	7.3 x10^9/l
PLT	201 x10^9/l
Na^+	139 mmol/l
K^+	4.3 mmol/l
Creatinine	155 µmol/l
Ca^{++}	2.9 mmol/l
PTH	10.1 pmol/l (0.9-5.4)
Glucose	8.1 mmol/l

Which of the following is the most likely overarching diagnosis in this patient?

Your answer was correct

A Thyroid carcinoma with new recurrence

B Secondary hyperparathyroidism

C MEN-1

D MEN-2b

E MEN-2a

Explanation

E MEN-2a

MEN-2 is associated with the development of medullary thyroid carcinoma, hyperparathyroidism and phaeochromocytoma. It is likely that the previous thyroidectomy was due to medullary carcinoma of the thyroid. Given that medullary thyroid carcinoma in MEN-2a tends to be less aggressive than in 2b, the presence of hypercalcaemia and the fact that the PTH is inappropriately elevated, the most likely diagnosis is one of hyperparathyroidism. The raised blood pressure and evidence of glucose intolerance also raises the possibility of co-existent phaeochromocytoma. Prior to any surgical intervention for hyperparathyroidism it is crucial to rule out phaeochromocytoma as a co-existent diagnosis.

A Thyroid carcinoma with new recurrence

This would not account for the elevated serum calcium seen here.

B Secondary hyperparathyroidism

This is essentially ruled out by the patient's renal function, which is only mildly abnormal, probably as a result of dehydration.

C MEN-1

MEN-1 is associated with parathyroid adenomas, pituitary adenomas and pancreatic endocrine tumours, but not with phaeochromocytoma. It is not associated with medullary thyroid cancer.

D MEN-2b

MEN-2b is associated with a marfanoid habitus, not

A 40-year-old man presents to the clinic for advice. He works as a solicitor, keeps fit, is of normal weight and is a non-smoker. He is worried as his father and brother both died of myocardial infarction during their early forties. On examination he is of normal weight with a BMI of 24 and has a blood pressure of 135/78 mmHg.

Fasting bloods reveal:

LDL cholesterol	6.0 mmol/l
Triglycerides	3.3 mmol/l
HDL cholesterol	0.8 mmol/l
Glucose	4.1 mmol/l
TSH	0.5mU/l (0.4-5)

What is the most appropriate action in this case?

A Commence fenofibrate therapy

B Reassure this gentleman that his cardiovascular risk is low and discharge him

C Advise him to diet and reduce his fat intake

D Start atorvastatin

E Start ezetimibe

Submit

A 40-year-old man presents to the clinic for advice. He works as a solicitor, keeps fit, is of normal weight and is a non-smoker. He is worried as his father and brother both died of myocardial infarction during their early forties. On examination he is of normal weight with a BMI of 24 and has a blood pressure of 135/78 mmHg.

Fasting bloods reveal:

LDL cholesterol	6.0 mmol/l
Triglycerides	3.3 mmol/l
HDL cholesterol	0.8 mmol/l
Glucose	4.1 mmol/l
TSH	0.5mU/l (0.4-5)

What is the most appropriate action in this case?

Your answer was correct

A Commence fenofibrate therapy

B Reassure this gentleman that his cardiovascular risk is low and discharge him

C Advise him to diet and reduce his fat intake

D Start atorvastatin

E Start ezetimibe

Explanation

D Start atorvastatin

D Start atorvastatin

This man is likely to have familial combined hyperlipidaemia, present in around 1/250 individuals and associated with premature cardiovascular disease. The most common type of familial dyslipidaemia, it may be responsible for up to 10% of cases of premature cardiovascular disease. It is characterised by increased LDL and triglyceride levels, often accompanied by low HDL levels. A statin will reduce the risk of cardiovascular disease events and is the first-choice drug for primary and secondary prevention of cardiovascular disease.

A Commence fenofibrate therapy

Fenofibrate may be added to statin therapy if triglycerides remain high even after the LDL cholesterol concentration has been reduced adequately.

B Reassure this gentleman that his cardiovascular risk is low and discharge him

His blood tests show evidence of increased LDL and triglyeride levels, which puts him at increased risk of cardiovascular events.

C Advise him to diet and reduce his fat intake

Given that he already lives a healthy lifestyle, dietary modification is unlikely to significantly impact on his lipid parameters.

E Start ezetimibe

Ezetimibe as a monotherapy is recommended as an option for the treatment of primary hypercholesterolaemia in adults in whom initial statin therapy is contraindicated or

10:25

MyPastest
https://mypastest.pastest.com

Pastest+

A 40-year-old man presents to the clinic for advice. He works as a solicitor, keeps fit, is of normal weight and is a non-smoker. He is worried as his father and brother both died of myocardial infarction during their early forties. On examination he is of normal weight with a BMI of 24 and has a blood pressure of 135/78 mmHg.

Fasting bloods reveal:

LDL cholesterol	6.0 mmol/l
Triglycerides	3.3 mmol/l
HDL cholesterol	0.8 mmol/l
Glucose	4.1 mmol/l
TSH	0.5mU/l (0.4-5)

What is the most appropriate action in this case?

Your answer was correct

A Commence fenofibrate therapy

B Reassure this gentleman that his cardiovascular risk is low and discharge him

C Advise him to diet and reduce his fat intake

D Start atorvastatin

E Start ezetimibe

A 72-year-old obese man with type 2 diabetes comes to the clinic for review. He is managed with metformin 1 g BD and pioglitazone 30 mg. On examination, he has a large necrotic, malodorous ulcer over the right medial malleolus. You notice that he has bilateral peripheral oedema and varicose veins. Peripheral pulses are easily palpable and capillary return is normal. Dopplers done by the chiropody team in the clinic are also within acceptable limits. His pioglitazone is discontinued and a transition to insulin therapy is planned.

Investigations:

Hb	10.9 g/dl
WCC	5.4×10^9/l
PLT	200×10^9/l
Na^+	139 mmol/l
K^+	5.0 mmol/l
Creatinine	182 µmol/l
CRP	27 mg/l (<10 mg/l)
Wound swab	scanty faecal flora

Which of the following treatments is likely to be the most effective?

A Surgical debridement under GA

B Multi-layer compression bandaging

C Oral metronidazole

D Varicose vein stripping

and pioglitazone 30 mg. On examination, he has a large necrotic, malodorous ulcer over the right medial malleolus. You notice that he has bilateral peripheral oedema and varicose veins. Peripheral pulses are easily palpable and capillary return is normal. Dopplers done by the chiropody team in the clinic are also within acceptable limits. His pioglitazone is discontinued and a transition to insulin therapy is planned.

Investigations:

Hb	10.9 g/dl
WCC	5.4×10^9/l
PLT	200×10^9/l
Na^+	139 mmol/l
K^+	5.0 mmol/l
Creatinine	182 µmol/l
CRP	27 mg/l (<10 mg/l)
Wound swab	scanty faecal flora

Which of the following treatments is likely to be the most effective?

A Surgical debridement under GA

B Multi-layer compression bandaging

C Oral metronidazole

D Varicose vein stripping

E Mobilisation

pioglitazone is discontinued and a transition to insulin therapy is planned.

Investigations:

Hb	10.9 g/dl
WCC	5.4 x 10^9/l
PLT	200 x 10^9/l
Na^+	139 mmol/l
K^+	5.0 mmol/l
Creatinine	182 µmol/l
CRP	27 mg/l (<10 mg/l)
Wound swab	scanty faecal flora

Which of the following treatments is likely to be the most effective?

Your answer was correct

A Surgical debridement under GA

B Multi-layer compression bandaging

C Oral metronidazole

D Varicose vein stripping

E Mobilisation

Explanation

B Multi-layer compression bandaging

Explanation

B Multi-layer compression bandaging

The fact that peripheral arteries are palpable and the normal Dopplers exclude the ischaemic origin of the ulcer. The location strongly suggests that this man's ulcer is venous. As such, the optimal management is compression bandaging. His white count is normal and the CRP is only just above normal, and thus infection is not likely to be the primary cause of his ulcer. Dressings may be employed that encourage de-sloughing, rather than progressing to definitive surgical debridement.

A Surgical debridement under GA

Surgical debridement is usually performed on diabetic foot ulcers that are infected and neuropathic, ischaemic or mixed in origin.

C Oral metronidazole

Depending upon sensitivities, an antibiotic with broad-spectrum activity, such as co-amoxiclav, may also be required. Metronidazole is reserved for ulcers where anaerobic infection is strongly suspected.

D Varicose vein stripping

This procedure is done under general or local anaesthetic to aid in the treatment of varicose veins and other manifestations of chronic venous disease. It is mainly performed when the symptoms are quite severe (pain/discomfort).

E Mobilisation

Rather than mobilisation, elevation of the leg above the

encourage de-sloughing, rather than progressing to definitive surgical debridement.

A Surgical debridement under GA

Surgical debridement is usually performed on diabetic foot ulcers that are infected and neuropathic, ischaemic or mixed in origin.

C Oral metronidazole

Depending upon sensitivities, an antibiotic with broad-spectrum activity, such as co-amoxiclav, may also be required. Metronidazole is reserved for ulcers where anaerobic infection is strongly suspected.

D Varicose vein stripping

This procedure is done under general or local anaesthetic to aid in the treatment of varicose veins and other manifestations of chronic venous disease. It is mainly performed when the symptoms are quite severe (pain/discomfort).

E Mobilisation

Rather than mobilisation, elevation of the leg above the level of the heart and rest, to reduce peripheral oedema, is the recommended course of action.

A 42-year-old woman is referred to the clinic with palpitations. Approximately 3 weeks ago she had suffered with flu and since then she has been getting occasional palpitations, anxiety attacks and loose bowel motions. Her weight has remained stable and she has previously been fit and well.

Examination reveals a tender thyroid, but no enlargement or focal masses. Her pulse rate is 110/min and regular.

Thyroid function tests:

TSH	0.3 mU/l (0.4–5)
T4	190 nmol/l (58–174)
T3	3.21 nmol/l (1.07–3.18)
ESR	45 mm/1st h (< 20)

What is the next most appropriate management step?

A Carbimazole

B Propylthiouracil

C Ibuprofen

D Radioiodine

E Subtotal thyroidectomy

52860

Submit

Rana Alnasser's screen

A 42-year-old woman is referred to the clinic with palpitations. Approximately 3 weeks ago she had suffered with flu and since then she has been getting occasional palpitations, anxiety attacks and loose bowel motions. Her weight has remained stable and she has previously been fit and well.

Examination reveals a tender thyroid, but no enlargement or focal masses. Her pulse rate is 110/min and regular.

Thyroid function tests:

TSH	0.3 mU/l (0.4–5)
T4	190 nmol/l (58–174)
T3	3.21 nmol/l (1.07–3.18)
ESR	45 mm/1st h (< 20)

What is the next most appropriate management step?

Your answer was correct

A Carbimazole

B Propylthiouracil

C Ibuprofen

D Radioiodine

E Subtotal thyroidectomy

Explanation

C Ibuprofen

Explanation

C Ibuprofen

Subacute thyroiditis is transient inflammation of the thyroid, which typically occurs in females in the fourth and fifth decade. Patients can have a preceding viral infection followed by mild symptoms of hyperthyroidism. The thyroid gland is usually tender by this time. If bloods are taken early, the patient can display a low thyroid-stimulating hormone (TSH) and raised thyroxine (T4)/tri-iodothyronine (T3). The mainstay of treatment is management of pain over the thyroid with NSAIDs. Prednisolone can be used if NSAIDS are ineffective. The symptoms should resolve but can take weeks to a few months to do so, and the patient's thyroid status should be monitored. Some patients are left hypothyroid after the inflammation has settled. Propranolol may be considered if palpitations or anxiety are particularly severe.

A Carbimazole

Carbimazole is used for Graves' thyrotoxicosis. It is a pro-drug which, after absorption, is converted to the active form, methimazole. Methimazole prevents thyroid peroxidase enzyme (TPO) from coupling and iodinating the tyrosine residues on thyroglobulin, hence reducing the production of the thyroid hormones (T3 and T4). In De Quervain's thyroiditis, the transient rise of T3 and T4 is self-limiting and doesn't require anti-thyroid medication.

B Propylthiouracil

This is used in Graves' thyrotoxicosis. It shares the same mechanism of action as carbimazole, but moreover inhibits the enzyme 5'-deiodinase which converts T4 to the more active form T3.

10:29
594-042-7551
Leave

production of the thyroid hormones (T3 and T4). In De Quervain's thyroiditis, the transient rise of T3 and T4 is self-limiting and doesn't require anti-thyroid medication.

B Propylthiouracil

This is used in Graves' thyrotoxicosis. It shares the same mechanism of action as carbimazole, but moreover inhibits the enzyme 5'-deiodinase which converts T4 to the more active form T3.

D Radioiodine

This is used in Graves' thyrotoxicosis when not complicated by thyroid eye disease, as there is a chance that it may aggravate its course.

E Subtotal thyroidectomy

This is considered in the case of a toxic adenoma or when the cytology results following fine-needle aspiration (FNA) of a nodule raise the suspicion of malignancy.

Rate this question:

Next Question

© Pastest 2019

Audio Video Share Participants More

10:29

A 67-year-old man with a history of type 2 diabetes and hypertension comes to the Emergency Department with weakness of the right-hand side of his face and his right arm of 30 min duration. The weakness came on suddenly and shortly after its onset his wife called an ambulance.

On examination, his BP is 185/100 mmHg, pulse is 82/min and regular. You note weakness of the right-hand side of his face and right arm, there are no other neurological deficits. Routine bloods reveal a glucose of 8.9 mmol/l, but are otherwise normal.

Which of the following is the most likely diagnosis?

A	Inflammatory neuropathy
B	Lacunar syndrome stroke (LACS)
C	Partial anterior circulation syndrome stroke (PACS)
D	Posterior circulation syndrome stroke (POCS)
E	Total anterior circulation syndrome stroke (TACS)

70488

Submit

Rana Alnasser's screen

A 67-year-old man with a history of type 2 diabetes and hypertension comes to the Emergency Department with weakness of the right-hand side of his face and his right arm of 30 min duration. The weakness came on suddenly and shortly after its onset his wife called an ambulance.

On examination, his BP is 185/100 mmHg, pulse is 82/min and regular. You note weakness of the right-hand side of his face and right arm, there are no other neurological deficits. Routine bloods reveal a glucose of 8.9 mmol/l, but are otherwise normal.

Which of the following is the most likely diagnosis?

Your answer was correct

A	Inflammatory neuropathy
B	Lacunar syndrome stroke (LACS)
C	Partial anterior circulation syndrome stroke (PACS)
D	Posterior circulation syndrome stroke (POCS)
E	Total anterior circulation syndrome stroke (TACS)

Explanation

B Lacunar syndrome stroke (LACS)

LACS is defined by one of the following:

- Unilateral weakness (and/or sensory deficit) of face and arm, arm and leg or all three.

Explanation

B	Lacunar syndrome stroke (LACS)

LACS is defined by one of the following:

- Unilateral weakness (and/or sensory deficit) of face and arm, arm and leg or all three.
- Pure sensory stroke.
- Ataxic hemiparesis

The pattern of both face and arm weakness is unlikely to be due to an underlying inflammatory neuropathy.

A	Inflammatory neuropathy

The pattern of both face and arm weakness is unlikely to be due to an underlying inflammatory neuropathy.

C	Partial anterior circulation syndrome stroke (PACS)

PACS is defined by two of the following:

- Unilateral weakness (and/or sensory deficit) of face, arm and leg
- Homonymous hemianopia
- Higher cerebral dysfunction (dysphasia, visuospatial disorder)

D	Posterior circulation syndrome stroke (POCS)

POCS is defined by one of the following:

- Cerebellar or brainstem syndromes
- Loss of consciousness

disorder)

D	Posterior circulation syndrome stroke (POCS)

POCS is defined by one of the following:

- Cerebellar or brainstem syndromes
- Loss of consciousness
- Isolated homonymous hemianopia

E	Total anterior circulation syndrome stroke (TACS)

TACS is defined by all three of the following:

- Unilateral weakness (and/or sensory deficit) of face, arm and leg
- Homonymous hemianopia
- Higher cerebral dysfunction (dysphasia, visuospatial disorder)

Rate this question:

Next Question

Previous Q... Tag Questi... Feedback End Session

Blog About Pastest Contact Us Help

© Pastest 2019

A 51-year-old obese woman with type 2 diabetes comes to the clinic for review. She has completed a period of diet and exercise since her diagnosis 3 months ago. There is also a history of hypertension and dyslipidaemia, which is managed with ramipril and atorvastatin. On examination her BMI is 33, and her BP is 145/82 mmHg. You review her home blood glucose monitoring and find average fasting sugars of around 8.8 mmol/l, with postprandial excursions up to 15.5 mmol/l.

Investigations:

Hb	14.1 g/dl
WCC	4.5 $\times 10^9$/l
PLT	142 $\times 10^9$/l
Na^+	141 mmol/l
K^+	4.8 mmol/l
Creatinine	100 µmol/l
HbA1c	68.31 mmol/mol (8.4%)

Which of the following is the most appropriate next management step for her?

A Sitagliptin

B Metformin

C Pioglitazone

D Dapagliflozin

E Gliclazide

A 51-year-old obese woman with type 2 diabetes comes to the clinic for review. She has completed a period of diet and exercise since her diagnosis 3 months ago. There is also a history of hypertension and dyslipidaemia, which is managed with ramipril and atorvastatin. On examination her BMI is 33, and her BP is 145/82 mmHg. You review her home blood glucose monitoring and find average fasting sugars of around 8.8 mmol/l, with postprandial excursions up to 15.5 mmol/l.

Investigations:

Hb	14.1 g/dl
WCC	4.5 $\times 10^9$/l
PLT	142 $\times 10^9$/l
Na^+	141 mmol/l
K^+	4.8 mmol/l
Creatinine	100 μmol/l
HbA1c	68.31 mmol/mol (8.4%)

K^+	4.8 mmol/l
Creatinine	100 µmol/l
HbA1c	68.31 mmol/mol (8.4%)

Which of the following is the most appropriate next management step for her?

Your answer was correct

A Sitagliptin

B Metformin

C Pioglitazone

D Dapagliflozin

E Gliclazide

Explanation

B Metformin

B Metformin

Guidelines from the ADA/EASD, and those from NICE recommend metformin as the initial management step for patients with type 2 diabetes who have not achieved adequate blood glucose control. This is based on evidence from UKPDS supporting a cardiovascular outcomes benefit, the fact that metformin use is associated with modest weight loss, and the fact that it is a generic cost-effective option.

A Sitagliptin

Sitagliptin is s DPPIV inhibitor which is weight neutral, but is not associated with positive cardiovascular outcomes. As such, it as a consideration as a potential alternative to metformin in patients who cannot tolerate it.

C Pioglitazone

In an obese woman, use of

A 58-year-old patient who has a history of hypertension is operated on by the neurosurgeons for an intracranial haemorrhage. Over the next few days his serum sodium level progressively declines and by the third day has fallen to 118 mmol/l despite fluid restriction to 1 litre per day. His blood pressure has maintained steady at 145/85 mmHg. Examination reveals no signs of left ventricular failure or peripheral oedema. Urine osmolality ~700 mosmol/l, urinary sodium is raised at 80 mmol/l. Serum potassium is 4.3 mmol/l.

Which of the following fits best with the diagnosis in this patient?

Your answer was correct

A Addisonian crisis

B Secretion of inappropriate antidiuretic hormone (SIADH)

C Cranial diabetes insipidus

raised at 80 mmol/l. Serum potassium is 4.3 mmol/l.

Which of the following fits best with the diagnosis in this patient?

Your answer was correct

A	Addisonian crisis
B	Secretion of inappropriate antidiuretic hormone (SIADH)
C	Cranial diabetes insipidus
D	Hypovolaemia
E	Fluid overload

Explanation

B	Secretion of inappropriate antidiuretic hormone (SIADH)

SIADH is well known to occur after

B Secretion of inappropriate antidiuretic hormone (SIADH)

SIADH is well known to occur after head injury, central nervous system (CNS) infection or intracranial haemorrhage. It is associated with hyponatraemia and hypotonic plasma, raised urine osmolality and excessive urinary sodium excretion (often >50 mmol/l). SIADH is often a transient phenomenon and resolves after a few days; in patients who fail to respond to fluid restriction, demeclocycline, which induces partial diabetes insipidus, may be a treatment option.

A Addisonian crisis

Addisonian crisis is associated with significant salt wasting and consequent hypotension, not present here, making Addison's less likely as the underlying cause of his hyponatraemia.

C Cranial diabetes insipidus

C Cranial diabetes insipidus

Cranial diabetes insipidus is associated with hypernatraemia and hypotension, rather than the picture seen here.

D Hypovolaemia

The steady maintenance of blood pressure above 140 mmHg systolic effectively rules out significant hypovolaemia.

E Fluid overload

Fluid overload is both associated with hyponatraemia and signs of heart failure or peripheral oedema, neither of which is seen in the scenario here.

6552

Rate this question:

Next Question

A 21-year-old man presents for review with concerns about his sexual function. He has recently begun a relationship with a woman and is unable to become sexually aroused. Past history of note includes repair of cleft lip and palate.

On examination, he is normal height and is thin. He has failure of development of secondary sexual characteristics.

Other history of note includes a lack of sense of smell, which he puts down to an accident as a toddler. He wishes to settle down with this woman and may start a family soon.

Investigations:

TSH	Normal
LH	Low
FSH	Low
Testosterone	Low

Which of the following is the most appropriate treatment?

LH	Low
FSH	Low
Testosterone	Low

Which of the following is the most appropriate treatment?

Your answer was correct

A Testosterone supplementation

B Continuous GnRH therapy

C Pulsed GnRH therapy

D FSH therapy

E LH therapy

Explanation

C Pulsed GnRH therapy

C Pulsed GnRH therapy

This patient is thought to have Kallmann syndrome and a failure of GnRH, and hence LH, FSH secretion. The history of cleft palate defect and lack of sense of smell both fit best with this as the most likely diagnosis. It is due to disordered migration of GnRH-producing neurones to the hypothalamus. It has an incidence of 1 in 10,000 males, with a male to female ratio of 4:1. Anosmia is present in 75% and there is an increased association with cleft lip and palate.

Pulsed GnRH treatment is needed to restore LH and FSH release. It needs to be continued for as long as fertility is required. Once his family is complete, switching to testosterone therapy may be more convenient for him.

A Testosterone supplementation

Although this restores secondary sexual characteristics, it doesn't restore fertility and is therefore not

appropriate here.

B Continuous GnRH therapy

As natural GnRH release is pulsatile, continuous therapy fails to lead to LH and FSH release.

D FSH therapy

FSH can be used to induce fertility, but it is thought to be potentially less effective than pulsed GnRH therapy. Long-acting preparations of FSH do exist, though, which may be more convenient with respect to administration.

E LH therapy

LH can be used in conjunction with FSH to induce fertility in women with Kallmann syndrome.

32908

Rate this question:

A 29-year-old woman who is 30 weeks' pregnant comes to the Endocrine Clinic for review. She has found it increasingly difficult to maintain her weight during the past few weeks, and has been suffering from palpitations and anxiety. She has no past medical history of note.

Examination reveals a BP of 122/72 mmHg, with pulse 88/min and regular. She has a fine resting tremor and a smooth, non-tender goitre.

Investigations:

Hb	11.9 g/dl
WCC	7.1×10^9/l
PLT	181×10^9/l
Na^+	137 mmol/l
K^+	4.3 mmol/l
Creatinine	84 μmol/l
Glucose	4.8 mmol/l
TSH	< 0.05 U/l
[illegible]	[illegible]

Glucose	4.8 mmol/l
TSH	< 0.05 U/l
Free T4	40 pmol/l
Anti-thyroid antibody	+

Which of the following is the most appropriate intervention?

Your answer was correct

A	Carbimazole
B	Carbimazole and thyroxine (block-replace)
C	Radioiodine
D	Propylthiouracil
E	Propylthiouracil and thyroxine (block-replace)

A Carbimazole

This patient has thyrotoxicosis, potentially due to underlying Graves' disease. The recommended treatment approach is to give enough anti-thyroid drug therapy to maintain thyroid hormone levels in the upper third of the normal range. Carbimazole is the recommended option in late pregnancy because of reports of hepatotoxicity associated with propylthiouracil.

B Carbimazole and thyroxine (block-replace)

Thyroxine does not cross the placenta to any appreciable degree, and therefore block-replace is not recommended in pregnancy.

C Radioiodine

Radioiodine is contraindicated in pregnancy because administration

Radioiodine is contraindicated in pregnancy because administration would lead to uptake in the fetal thyroid.

D	Propylthiouracil

Propylthiouracil may be used in early pregnancy, but in late pregnancy it is not recommended because of risk of hepatotoxicity.

E	Propylthiouracil and thyroxine (block-replace)

Block-replace is not indicated because of thyroxine not crossing the placental barrier.

39026

Rate this question:

End Session

A 24-year-old woman who is 24 weeks' pregnant is referred to the clinic complaining of increasing tiredness, emotional lability, tiredness particularly in the evenings, and episodes of palpitations. Her GP has put this down to the normal stresses and strains associated with a first pregnancy. On examination she looks tired, her BP is 125/78 mmHg and her pulse is 90/min at rest. You notice that she has sweaty palms. There is a small, smooth goitre on palpation.

Investigations:

Hb	11.0 g/dl
WCC	5.4 $\times 10^9$/l
PLT	182 $\times 10^9$/l
Na^+	139 mmol/l
K^+	4.1 mmol/l
Creatinine	100 µmol/l
TSH	<0.05 U/l (<0.5-4.5)

Which of the following is the most likely diagnosis?

A Hyperemesis gravidarum

B Anxiety

C Hashimoto's thyroiditis

D Graves' disease

E Toxic adenoma

Rana Alnasser's screen

Explanation

D Graves' disease

Thyrotoxicosis, of which 85% of cases are due to Graves' disease, occurs in 0.1-0.4% of all pregnancies. Whilst her reported symptoms may be reflective of the anxiety experienced by many pregnant women, they seem particularly severe, and the presence of a suppressed TSH points towards the diagnosis.

A Hyperemesis gravidarum

This may be associated with TSH suppression, but it isn't usually suppressed below the lower limit of quantification, and is not usually associated with frank symptoms of thyrotoxicosis.

B Anxiety

The goitre, signs of thyrotoxicosis and suppressed TSH effectively rule out anxiety as the cause of symptoms here.

C Hashimoto's thyroiditis

Hashimoto's thyroiditis is of course associated with hypothyroidism rather than the picture of thyrotoxicosis seen here.

E Toxic adenoma

A toxic adenoma isn't associated with a goitre, but with a discrete nodule. The suppressed TSH would, however, fit with a toxic adenoma.

Rate this question:

A 42-year-old Portuguese woman presents to her GP with increasing lethargy. He had seen her twice in the past few months and commenced antidepressants at her last appointment. Most recently, she had been complaining of increasing nausea and vomiting and had lost a considerable amount of weight.

On examination, her blood pressure was 105/65 mmHg and her BMI was 21. There was a postural drop of 20 mmHg in her blood pressure on standing, with a corresponding increase in her pulse rate.

Investigations:

Na^+	126 mmol/l
K^+	4.8 mmol/l
TSH	7 mU/l (0.4–5)
Free T4	7 pmol/l (10–22)
Urea	10.1 mmol/l
Hb	10.1 g/dl (normochromic, normocytic), eosinophil count raised

Which of the following is the initial treatment of choice in this patient?

A Thyroxine

B Fludrocortisone

C Hydrocortisone

D IV 5% dextrose

E Fluid restriction

Explanation

C	Hydrocortisone

This patient has the clinical features of adrenal insufficiency, with hyponatraemia, a raised urea, normochromic normocytic anaemia with eosinophilia and a relatively high potassium level despite repeated episodes of vomiting. She should not be treated with thyroxine at this stage: thyroid function testing should be repeated after treatment with corticosteroids. She should be rehydrated, but with N saline. Autoimmune adrenalitis is the commonest cause of primary adrenal insufficiency. Metastatic carcinoma from lung, breast or kidney primaries is also known to result in adrenal failure. Infiltration due to amyloid, infection due to tuberculosis, vascular haemorrhage or infarction are other documented causes.

A	Thyroxine

Mild biochemical hypothyroidism often accompanies adrenal insufficiency, but early treatment of abnormal thyroid numbers, particularly before corticosteroid stabilisation, may further decompensate the adrenal insufficiency.

B	Fludrocortisone

This is used for mineralocorticoid insufficiency leading to postural hypotension. In Addison's disease, because corticosteroid replacement therapy usually exerts a mineralocorticoid effect, fludrocortisone is not first-line treatment.

D	IV 5% dextrose

Adrenal insufficiency manifesting with adrenal crisis is associated with volume depletion, and therefore normal

A 32-year-old woman who is known to have autoimmune hypothyroidism presents with nausea, vomiting and lethargy. Medication of note includes thyroxine and the oral contraceptive pill. On examination her BP is 110/70 mmHg, with a pulse of 70/min; she has a postural drop of 20 mmHg on standing and her pulse increases by 10/min. She has areas of vitiligo on skin examination.

Investigations:

Hb	10.5 g/dl
WCC	7.4 $\times 10^9$/l
PLT	201 $\times 10^9$/l
Na^+	124 mmol/l
K^+	4.5 mmol/l
Creatinine	132 µmol/l

Which of the following is the most likely diagnosis?

A Autoimmune polyglandular syndrome type 1

B Autoimmune polyglandular syndrome type 2

C Gastroenteritis

D Isolated new onset Addison's disease

E Pernicious anaemia

Submit

Explanation

B Autoimmune polyglandular syndrome type 2

This is the commonest subtype, and includes autoimmune Addison's disease in combination with thyroid disease and/or type 1 diabetes mellitus. There are associations with other autoimmune conditions such as coeliac disease and pernicious anaemia, which could explain the anaemia, and primary hypogonadism and myasthenia gravis are also commonly observed.

A Autoimmune polyglandular syndrome type 1

Type 1 polyglandular syndrome is associated with mucocutaneous candidiasis, not vitiligo. It also encompasses both autoimmune hypoparathyroidism and hypoadrenalism.

C Gastroenteritis

Gastroenteritis is a self-limiting infectious illness causing diarrhoea and vomiting, and is not normally associated with anaemia or hyponatraemia.

D Isolated new onset Addison's disease

This lady possibly does have a new diagnosis of Addison's disease, but in view of her other autoimmune history this option is incorrect.

E Pernicious anaemia

A 67-year-old man has been diagnosed with type 2 diabetes coinciding with presentation to the Emergency room with an acute myocardial infarction. For the past 3 months he has been managed with diet and lifestyle advice. On examination his BMI is 34 and his BP is 145/82 mmHg; cardiovascular and respiratory examination is unremarkable.

Investigations:

Hb	12.1 g/dl
WCC	5.6 x10^9/l
PLT	190 x10^9/l
Na^+	141 mmol/l
K^+	4.8 mmol/l
Creatinine	250 µmol/l
HbA1c	73.77 mmol/mol (8.9%) (75.96 mmol/mol, 9.1% 3 months earlier)

Which of the following is the most appropriate next step?

A Insulin

B Metformin

C Gliclazide

D Pioglitazone

E Empagliflozin

Hb	12.1 g/dl
WCC	5.6 x10⁹/l
PLT	190 x10⁹/l
Na^+	141 mmol/l
K^+	4.8 mmol/l
Creatinine	250 µmol/l
HbA1c	73.77 mmol/mol (8.9%) (75.96 mmol/mol, 9.1% 3 months earlier)

Which of the following is the most appropriate next step?

Your answer was correct

A Insulin

B Metformin

C Gliclazide

D Pioglitazone

E Empagliflozin

Explanation

A Insulin

Although insulin will result in weight gain in this situation, it is the only realistic option from those listed to achieve HbA1c target given this patient also has renal impairment. Given he has suffered a previous MI, a basal bolus approach would be preferred to drive a greater chance of

A Insulin

Although insulin will result in weight gain in this situation, it is the only realistic option from those listed to achieve HbA1c target given this patient also has renal impairment. Given he has suffered a previous MI, a basal bolus approach would be preferred to drive a greater chance of achieving blood glucose control with less chance of hypoglycaemia.

B Metformin

Metformin is contraindicated in patients with a GFR <30, which would almost certainly be indicated by a creatinine of 250.

C Gliclazide

Sulphonylureas are not recommended in patients with renal impairment because of risks of accumulation and hypoglycaemia.

D Pioglitazone

Pioglitazone drives increased risk of fluid retention, which can exacerbate heart failure; it should therefore be avoided in a patient with a previous history of MI.

E Empagliflozin

Although SGLT-2 inhibitors do have modest positive effects on blood pressure and uric acid excretion, they have only a limited effect on blood glucose, and this is blunted by renal impairment.

A 61-year-old man, who has had type 2 diabetes for the past 8 years, comes to the clinic for review. He has found it increasingly difficult to maintain his HbA1c at target on metformin 1g BD, empagliflozin 25 mg and vildagliptin 100 mg per day. He has also gained 6 kg in weight over the past year.

His BP is 142/90 mmHg pulse is 78/min and regular. Respiratory examination is unremarkable. Abdomen is soft and non-tender, and his BMI is 36.

Investigations:

Hb	131 g/l
WCC	7.0×10^9/l
PLT	181×10^9/l
Na	139 mmol/l
K	4.3 mmol/l
Creatinine	100 µmol/l
Glucose	7.1 mmol/l
HbA1c	62 mmol/mol (7.8%)

Which of the following is the most appropriate next step?

A Add basal insulin

B Continue two orals and add liraglutide

C Refer for bariatric surgery

D Stop oral treatment and transition to mixed insulin

E Stop oral treatment and transition to basal bolus

B Continue two orals and add liraglutide

In this situation, with a BMI of >35, NICE guidelines allow for a trial of GLP-1 analogue. They recommend reassessment of response to therapy after 3 months, to ensure that adequate HbA1c reduction (>1%), and weight loss of 3% or more has been achieved. The vildagliptin should be discontinued as trials of DPPIV inhibitor and GLP-1 together suggest no added efficacy versus GLP-1 alone.

A Add basal insulin

This patient is significantly obese; as such although adding basal insulin may improve HbA1c, it is likely to result in significant further weight gain and adverse effects including weight gain and hypoglycaemia. In particular, in patients with long term diabetes, hypoglycaemia may risk cardiac arrhythmia.

C Refer for bariatric surgery

Although this patient would qualify for bariatric surgery, a trial of GLP-1 agonist therapy is indicated first, given the morbidity associated with a permanent surgical solution.

D Stop oral treatment and transition to mixed insulin

In Type 2 diabetes continuing medications such as metformin and SGLT-2 inhibitor can limit weight gain in patients starting insulin therapy, and mixed insulin could potentially offer suboptimal glycaemic control.

E Stop oral treatment and transition to basal bolus insulin

11:44
594-042-7551
Leave

patients with long term diabetes, hypoglycaemia may risk cardiac arrhythmia.

C Refer for bariatric surgery

Although this patient would qualify for bariatric surgery, a trial of GLP-1 agonist therapy is indicated first, given the morbidity associated with a permanent surgical solution.

D Stop oral treatment and transition to mixed insulin

In Type 2 diabetes continuing medications such as metformin and SGLT-2 inhibitor can limit weight gain in patients starting insulin therapy, and mixed insulin could potentially offer suboptimal glycaemic control.

E Stop oral treatment and transition to basal bolus insulin

Although basal bolus insulin can optimise insulin delivery, continuing metformin and SGLT-2 seems sensible in this case to limit weight gain on insulin initiation.

Rate this question:

© Pastest 2019

Audio Video Share Participants More

11:44
594-042-7551
Leave

A 58-year-old man who has both type 1 DM and chronic kidney disease managed with haemodialysis comes to the clinic for review. He was previously noted to have raised PTH and started on $CaCO_3$ and twice weekly vitamin D at the high dose. He has recently begun suffering from depression. He has suffered two previous myocardial infarctions and had a spinal anaesthetic for a hip injury in the past year.

Investigations:

Hb	11.0 g/dl
WCC	4.5 $\times 10^9$/l
PLT	199 $\times 10^9$/l
Na^+	139 mmol/l
K^+	5.2 mmol/l
Creatinine	634 µmol/l
PTH	40 pmol/l
Ca^{++}	2.2 mmol/l (2.2-2.6 mmol/l)
PO_4^{3-}	1.45 mmol/l (0.8-1.4 mmol/l)

Which of the following is the next most appropriate management step for this patient?

A Parathyroidectomy

B Increased dose of vitamin D

C Sevelamer

D Cinacalcet

Audio Video Share Participants More

clinic for review. He was previously noted to have raised PTH and started on $CaCO_3$ and twice weekly vitamin D at the high dose. He has recently begun suffering from depression. He has suffered two previous myocardial infarctions and had a spinal anaesthetic for a hip injury in the past year.

Investigations:

Hb	11.0 g/dl
WCC	4.5 x10^9/l
PLT	199 x10^9/l
Na^+	139 mmol/l
K^+	5.2 mmol/l
Creatinine	634 µmol/l
PTH	40 pmol/l
Ca^{++}	2.2 mmol/l (2.2-2.6 mmol/l)
PO_4^{3-}	1.45 mmol/l (0.8-1.4 mmol/l)

Which of the following is the next most appropriate management step for this patient?

A Parathyroidectomy

B Increased dose of vitamin D

C Sevelamer

D Cinacalcet

E Aluminium hydroxide

D Cinacalcet

This man has hyperparathyroidism, with a PTH that has failed to suppress in response to calcium and vitamin D. As such, the next most appropriate step is cinacalcet. It works as an agonist at the site of the calcium sensor on the parathyroid gland. This leads to a suppression of PTH levels. Cinacalcet may currently be used in patients on renal replacement therapy as an adjunct to vitamin D or phosphate binders.

C Sevelamer

Sevelamer is a phosphate binder, and given that phosphate is only just above the normal range, it's not going to significantly impact on the clinical picture seen here.

A Parathyroidectomy

Given this patient's history of myocardial infarctions and the fact he received a spinal anaesthetic for a hip replacement last year, he is very unlikely to be a candidate for operative intervention for hyperparathyroidism.

B Increased dose of vitamin D

PTH is in the treatment range, and calcium is in the normal range,, supplementing further with vitamin D is therefore very unlikely to drive down levels of parathyroid hormone.

E Aluminium hydroxide

Aluminium hydroxide, an alternative phosphate binder is now used less frequently because of risks of accumulation and the impact on cognitive function.

A 44-year-old man is referred to clinic with headaches and a raised fasting glucose of 7.5 mmol/l. He has also noticed a change in his facial appearance and enlargement of his hands.

Examination reveals prognathism, enlarged digits and bitemporal hemianopia. His BP is elevated at 155/90 mmHg. An oral glucose tolerance test with growth hormone levels showed a blood glucose of 11.5 mmol/l at 120 min and also failure to suppress growth hormone levels.

An MRI scan of the pituitary fossa revealed an adenoma that was abutting the optic chiasm. Treatment options were explained to the patient and he opted for medical therapy rather surgery (transphenoidal resection of the adenoma).

Which of the following is the most appropriate initial medical therapy for him?

A	Insulin
B	Glucagon
C	Bromocriptine
D	Somatostatin analogue
E	Pegvisomant

32884

Submit

11:53
MyPastest 594-042-7551 Leave
https://mypastest.pastest.com

Explanation

D Somatostatin analogue

This gentleman has acromegaly. Acromegaly is usually related to a pituitary adenoma, although it is occasionally caused by ectopic secretion of growth hormone from malignant cells. This results in coarsening of facial features, prognathism and macroglossia. Patients are at increased risk of cardiovascular disease with hypertension and diabetes. Transphenoidal removal of the adenoma would be curative and is the first-line treatment option.

A Insulin

The excess secretion of growth hormone in acromegaly results in increased insulin resistance and diabetes. Some patients require dietary intervention only, oral hypoglycaemic agents or insulin. In this case, there is insufficient information regarding the glycaemic control of the patient and whether he will require insulin or not. In any case, priority is the treatment of acromegaly since diabetes usually subsequently resolves.

B Glucagon

This is used for the treatment of severe hypoglycaemia when the patient is unconscious or unable to receive glucose orally.

C Bromocriptine

This is a dopamine agonist used for the treatment of prolactinomas as an alternative to cabergoline.

Audio Video Share Participants More

related to a pituitary adenoma, although it is occasionally caused by ectopic secretion of growth hormone from malignant cells. This results in coarsening of facial features, prognathism and macroglossia. Patients are at increased risk of cardiovascular disease with hypertension and diabetes. Transphenoidal removal of the adenoma would be curative and is the first-line treatment option.

A Insulin

The excess secretion of growth hormone in acromegaly results in increased insulin resistance and diabetes. Some patients require dietary intervention only, oral hypoglycaemic agents or insulin. In this case, there is insufficient information regarding the glycaemic control of the patient and whether he will require insulin or not. In any case, priority is the treatment of acromegaly since diabetes usually subsequently resolves.

B Glucagon

This is used for the treatment of severe hypoglycaemia when the patient is unconscious or unable to receive glucose orally.

C Bromocriptine

This is a dopamine agonist used for the treatment of prolactinomas as an alternative to cabergoline.

E Pegvisomant

This is a growth hormone receptor antagonist and is a third-line treatment when surgery, radiotherapy and somatostatin analogues are not effective.

Rana Alnasser's screen

A 56-year-old man presents to his doctor for review. He has been suffering particularly from increased bony pain around his lower back and pelvic region over the past few months. Some degree of hearing loss was diagnosed two years ago. Blood testing reveals normal calcium levels but alkaline phosphatase is raised. X-rays reveal skull features consistent with Paget's disease, and increased activity on bone scanning is seen in the lumbar vertebrae and pelvis. You commence bisphosphonate treatment.

Which of the following represents the most appropriate way to monitor disease activity in this man?

A	3-monthly alkaline phosphatase levels
B	6-monthly alkaline phosphatase levels
C	6-monthly acid phosphatase levels
D	6-monthly calcium levels
E	Yearly isotope bone scan

18542

Submit

© Pastest 2019

11:56
594-042-7551
Leave

B 6-monthly alkaline phosphatase levels

The goals of therapy in Paget's disease are to normalise bone turnover and achieve an alkaline phosphatase as a marker of this, in the normal range if possible. Bisphosphonates have become the mainstay of therapy, with daily, weekly, monthly and intravenous intermittent formulations now all possibilities for treatment. It appears that the more aggressive initial therapy is, then the longer a period of remission may be achieved. Alkaline phosphatase, as a non-invasive method, appears to be the best way to monitor disease activity. Levels should be checked at 6 months, and subsequently every 6-12 months.

E Yearly isotope bone scan

It is unclear whether normalisation of appearances on isotope bone scan correlates to clinical outcome. It is therefore difficult to justify the use of serial bone scans to monitor treatment in view of the radiation dose involved.

A 3-monthly alkaline phosphatase levels

Alkaline phosphatase levels can take 3-4 months to normalise following treatment.

C 6-monthly acid phosphatase levels

Serum total acid phosphatase is an osteoclastic enzyme that may be elevated in active Paget's disease, but is not as reliable in males as it can also be raised in prostate cancer.

D 6-monthly calcium levels

Calcium is normal in Paget's disease.

Audio Video Share Participants More

11:56
594-042-7551
Leave

E Yearly isotope bone scan

It is unclear whether normalisation of appearances on isotope bone scan correlates to clinical outcome. It is therefore difficult to justify the use of serial bone scans to monitor treatment in view of the radiation dose involved.

A 3-monthly alkaline phosphatase levels

Alkaline phosphatase levels can take 3-4 months to normalise following treatment.

C 6-monthly acid phosphatase levels

Serum total acid phosphatase is an osteoclastic enzyme that may be elevated in active Paget's disease, but is not as reliable in males as it can also be raised in prostate cancer.

D 6-monthly calcium levels

Calcium is normal in Paget's disease.

Rate this question:

© Pastest 2019

Audio Video Share Participants More

11:56
594-042-7551
Leave

A 23-year-old final year medical student presents to the student health service complaining of increased hairiness and trouble with acne. Her periods are erratic and she is an intermittent user of the oral contraceptive pill.

On examination, her BMI is 31 and her blood pressure is mildly elevated at 145/89 mmHg. She has slight thinning of the hair on the front of her head, increased hair around her moustache and beard line, and hair around her nipples and lower abdomen.

Investigations:

LH/FSH ratio	Increased
Testosterone level	5 nmol/l (1–2.5 nmol/l)

Which of the following is the investigation most likely to confirm the diagnosis in this case?

A Transvaginal ultrasound scan

B Pituitary MRI

C 17-OH progesterone levels

D Adrenal ultrasound scan

E Karyotyping

Submit

Previous Q... Audio Video Share Participants Skip Questi... More

11:57
594-042-7551
Leave

A Transvaginal ultrasound scan

This patient's clinical picture is suggestive of polycystic ovarian syndrome (PCOS), and transvaginal ultrasound is said to have 91% diagnostic sensitivity for the condition in experienced hands. The presence of more than eight follicular cysts <10 mm and increased ovarian stroma is sufficient to make the diagnosis. Cyproterone acetate is useful for suppression of ovarian androgens, and electrolysis is useful for reducing hirsutism. Metformin increases insulin sensitivity, and therefore has positive effects on associated metabolic features and helps restore ovulatory function. Weight loss is, however, the gold-standard treatment for PCOS and improves ovulation, androgen levels, hirsutism and metabolic features associated with insulin resistance. A loss in weight of only 5% reduces hirsutism by up to 40%.

C 17-OH progesterone levels

This test is used as screening for congenital adrenal hyperplasia (CAH).

- Females with severe CAH due to deficiencies of 21-hydroxylase, 11-beta-hydroxylase or 3-beta-hydroxysteroid dehydrogenase have ambiguous genitalia at birth (classic virilising adrenal hyperplasia).
- Females with mild 21-hydroxylase deficiency are identified later in childhood because of precocious pubic hair, clitoromegaly or both, often accompanied by accelerated growth and skeletal maturation (simple virilising adrenal hyperplasia).
- Females with still milder deficiencies of 21-hydroxylase or 3-beta-hydroxysteroid dehydrogenase activity may present in adolescence

Audio Video Share Participants More

5% reduces hirsutism by up to 40%.

C	17-OH progesterone levels

This test is used as screening for congenital adrenal hyperplasia (CAH).

- Females with severe CAH due to deficiencies of 21-hydroxylase, 11-beta-hydroxylase or 3-beta-hydroxysteroid dehydrogenase have ambiguous genitalia at birth (classic virilising adrenal hyperplasia).
- Females with mild 21-hydroxylase deficiency are identified later in childhood because of precocious pubic hair, clitoromegaly or both, often accompanied by accelerated growth and skeletal maturation (simple virilising adrenal hyperplasia).
- Females with still milder deficiencies of 21-hydroxylase or 3-beta-hydroxysteroid dehydrogenase activity may present in adolescence or adulthood with oligomenorrhea, hirsutism and/or infertility (non-classic adrenal hyperplasia).
- Females with 17-hydroxylase deficiency appear phenotypically female at birth but do not develop breasts or menstruate in adolescence; they may present with hypertension.

Our case could phenotypically resemble non-classic adrenal hyperplasia, although the biochemical profile and the excess weight point towards PCOS.

B	Pituitary MRI

This would be the investigation of choice if a pituitary [illegible] a cause of amenorrhea. In that

Rana Alnasser's screen

A 28-year-old single woman presents to the Endocrine Clinic with recent symptoms of sweating, weight loss and palpitations. She tells you that there is a history of thyroid disease in the family and she has recently applied for a job as a nurse because she wants to help people.

On examination, she has a BMI of 20, there is no palpable goitre and a tremor is noted.

Investigations:

Hb	125 g/dl
WCC	6.5×10^9/l
PLT	203×10^9/l
Na^+	138 mmol/l
K^+	4.5 mmol/l
Creatinine	90 µmol/l
Glucose	5.7 mmol/l
TSH	< 0.05 mU/l (0.5–4)
Free T4	32.1 pmol/l (10–22)
Thyroid scintography	revealed decreased uptake

Which of the following is the most appropriate next investigation?

A Thyroid ultrasound scan

B Fine needle aspiration biopsy

C Beta HCG

D Thyroglobulin levels

Rana Alnasser's screen

Clinic with recent symptoms of sweating, weight loss and palpitations. She tells you that there is a history of thyroid disease in the family and she has recently applied for a job as a nurse because she wants to help people.

On examination, she has a BMI of 20, there is no palpable goitre and a tremor is noted.

Investigations:

Hb	125 g/dl
WCC	6.5×10^9/l
PLT	203×10^9/l
Na^+	138 mmol/l
K^+	4.5 mmol/l
Creatinine	90 µmol/l
Glucose	5.7 mmol/l
TSH	< 0.05 mU/l (0.5–4)
Free T4	32.1 pmol/l (10–22)
Thyroid scintography	revealed decreased uptake

Which of the following is the most appropriate next investigation?

A Thyroid ultrasound scan

B Fine needle aspiration biopsy

C Beta HCG

D Thyroglobulin levels

E Abdominal ultrasound scan

D Thyroglobulin levels

E Abdominal ultrasound scan

Explanation

D Thyroglobulin levels

One possible cause of recent-onset thyrotoxicosis is thyroiditis. Thyroglobulin levels can be used to differentiat thyroiditis and other causes of hyperthyroidism from thyrotoxicosis factitia. Low thyroglobulin levels are associated with a diagnosis of thyrotoxicosis factitia (inappropriate abuse of thyroid hormone), and this is also associated with absence of thyroid enlargement and suppressed TSH in the presence of elevated T4 levels. Decreased isotope uptake is seen on thyroid scanning. Expert psychiatric input is advised in cases such as this one, as presentation of the diagnosis may be met with a hostile reaction and appropriate psychological assessment is required.

A Thyroid ultrasound scan

Thyroid ultrasound scanning is most useful in identifying small thyroid masses that can't be detected on palpation alone.

B Fine needle aspiration biopsy

Fine needle aspiration biopsy is most useful in identifying the histology of cold nodules, identified on ultrasound scan.

C Beta HCG

Thyroid ultrasound scanning is most useful in identifying small thyroid masses that can't be detected on palpation alone.

B Fine needle aspiration biopsy

Fine needle aspiration biopsy is most useful in identifying the histology of cold nodules, identified on ultrasound scan.

C Beta HCG

There are no signs of pregnancy, where elevated beta HCG which suppresses TSH is seen. It doesn't normally cause symptoms of thyrotoxicosis.

E Abdominal ultrasound scan

Abdominal ultrasound scanning is useful in identifying intra-abdominal tumours producing thyroid hormone, although these are extremely rare and unlikely to be the cause of symptoms seen here.

Rate this question:

© Pastest 2019

12:12

A 21-year-old student with type 1 diabetes is brought to the Emergency Department by her flat-mates. She has been suffering from a cold for a few days.

On examination, her GCS is 12, and she has a respiratory rate of 40/min. Finger-prick blood glucose in the department is measured at 38.1 mmol/l and this is confirmed on venous sampling. Arterial blood gases reveal a pH of 7.05 and serum bicarbonate of 12 mmol/l. Electrolytes are abnormal, with potassium of 5.9 mmol/l, urea of 15.5 mmol/l and creatinine of 193 mmol/l.

Which of the following options would represent the most appropriate initial treatment for her?

A	1 litre of normal saline over 8 h
B	1 litre of normal saline stat
C	1 litre of Hartmann's over 4 h
D	1 mmol of sodium bicarbonate/kg IV over 30 min
E	Intubation and ventilation

32873

Submit

Previous Q... Skip Questi...

Rana Alnasser's screen

A 21-year-old student with type 1 diabetes is brought to the Emergency Department by her flat-mates. She has been suffering from a cold for a few days.

On examination, her GCS is 12, and she has a respiratory rate of 40/min. Finger-prick blood glucose in the department is measured at 38.1 mmol/l and this is confirmed on venous sampling. Arterial blood gases reveal a pH of 7.05 and serum bicarbonate of 12 mmol/l. Electrolytes are abnormal, with potassium of 5.9 mmol/l, urea of 15.5 mmol/l and creatinine of 193 mmol/l.

Which of the following options would represent the most appropriate initial treatment for her?

Your answer was correct

A	1 litre of normal saline over 8 h
B	1 litre of normal saline stat
C	1 litre of Hartmann's over 4 h
D	1 mmol of sodium bicarbonate/kg IV over 30 min
E	Intubation and ventilation

Explanation

B 1 litre of normal saline stat

This patient presents with diabetic ketoacidosis, the likely precipitant of which has been her recent respiratory infection. Initial investigations of choice for diabetic ketoacidosis (DKA) include blood for urea, electrolytes and

B 1 litre of normal saline stat

This patient presents with diabetic ketoacidosis, the likely precipitant of which has been her recent respiratory infection. Initial investigations of choice for diabetic ketoacidosis (DKA) include blood for urea, electrolytes and glucose, full blood count, arterial blood gases, blood and urine cultures, chest radiograph and electrocardiogram (ECG). Initial management involves 2 l of 1 M saline administered over 2 h unless the patient has cardiovascular or fluid management issues. Potassium administration is set according to serum potassium (intravenous (IV) insulin may result in rapid potassium reduction); the recommended dosage ranges from 40 mmol/l K^+ added per litre bag of 1 M/saline if serum potassium is <3 mmol/l, to no potassium added if serum potassium is 6.0 mmol/l or above. Where potassium is <3, management on the ITU where central venous access delivery of potassium can be carried out, is preferred. An IV fixed-rate insulin infusion is also started to combat hyperglycaemia.

A 1 litre of normal saline over 8 h

Patients presenting with DKA may be fluid depleted by up to 5 l. As such, delivering 1 l over 8 h is far too slow an infusion rate.

C 1 litre of Hartmann's over 4 h

It's argued that Hartmann's shouldn't be used as initial fluid replacement because it delivers a lactate load, and patients already have a high lactate/pyruvate ratio in DKA.

D 1 mmol of sodium bicarbonate/kg IV over 30 min

At this stage the initial response to aggressive fluid resuscitation and insulin delivered IV should be assessed

An 18-year-old man has been referred to the endocrinology clinic. He presents with short stature (less than the lower 3rd centile) with his weight being between the 10th and 15th centiles. On examination he has no pubic hair and pre-pubertal testes. There is no family history and he is currently well apart from a 6-month history of headaches. Appropriate investigations and imaging studies are arranged for the patient, and the result of the CT scan of the head shows the presence of a suprasellar calcified cyst with the cyst content having the same density as the CSF.

What is the diagnosis?

A	Idiopathic intracranial hypertension
B	Craniopharyngioma
C	Low-grade astrocytoma
D	Neurosarcoidosis
E	Tolosa-Hunt syndrome

Submit

An 18-year-old man has been referred to the endocrinology clinic. He presents with short stature (less than the lower 3rd centile) with his weight being between the 10th and 15th centiles. On examination he has no pubic hair and pre-pubertal testes. There is no family history and he is currently well apart from a 6-month history of headaches. Appropriate investigations and imaging studies are arranged for the patient, and the result of the CT scan of the head shows the presence of a suprasellar calcified cyst with the cyst content having the same density as the CSF.

What is the diagnosis?

Your answer was correct

A	Idiopathic intracranial hypertension
B	Craniopharyngioma
C	Low-grade astrocytoma
D	Neurosarcoidosis
E	Tolosa-Hunt syndrome

Explanation

B Craniopharyngioma

Craniopharyngioma is a slow-growing, calcified cystic tumour arising from the remnants of the craniopharyngeal duct. It compromises 4.2% of all childhood tumours and is slightly more common in males than females. The

Explanation

B Craniopharyngioma

Craniopharyngioma is a slow-growing, calcified cystic tumour arising from the remnants of the craniopharyngeal duct. It compromises 4.2% of all childhood tumours and is slightly more common in males than females. The symptoms develop very slowly and usually manifest once the tumour has attained a diameter of 3 cm. The commonest presentation in young patients is growth failure and delayed puberty. The radiological hallmark of a craniopharyngioma is the presence of a suprasellar calcified cyst, with calcification being more common in children than in adults. Using imaging studies, CT is most useful in demonstrating the calcifications whereas MRI is essential for defining the local anatomy prior to surgical intervention. Surgery is the management of choice and may attempt to resect the tumour in total, or to reduce the size followed by postoperative radiotherapy treatment.

A Idiopathic intracranial hypertension

The most common symptom of idiopathic intracranial hypertension is headache, but it should not cause developmental delay. CT of the head may show ventricles that are slightly reduced in size.

C Low-grade astrocytoma

Astrocytomas commonly present with headaches and seizures, or with other symptoms of raised intracranial pressure.

D Neurosarcoidosis

Neurosarcoidosis presents with a cranial neuropathy in 60-70%, usually involving the 7th cranial nerve. Aseptic meningitis occurs in around 20%

3G 12:18

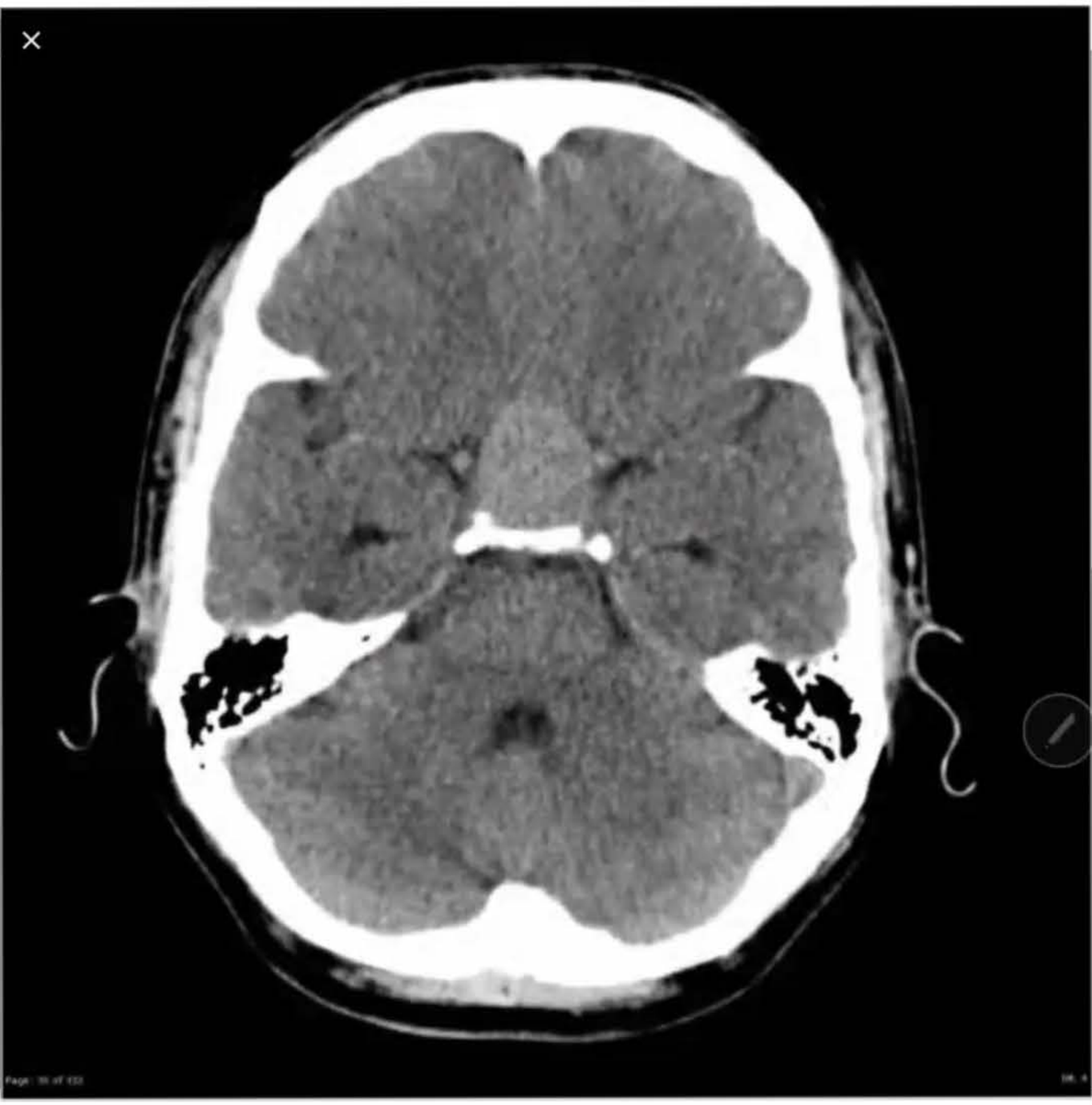

radiopaedia.org

Craniopharyngioma (papillary) | Radiology Case | Radiopaedia.org

Images may be subject to copyright. Learn more

RELATED IMAGES

Stop Annotation Spotlight Pen Highlighter Line Rectangle Oval Undo Redo Clear Color Stop Share

Discover Updates Search Recent More

Rana Alnasser's screen

12:18
594-042-7551
Leave
66% 10:18

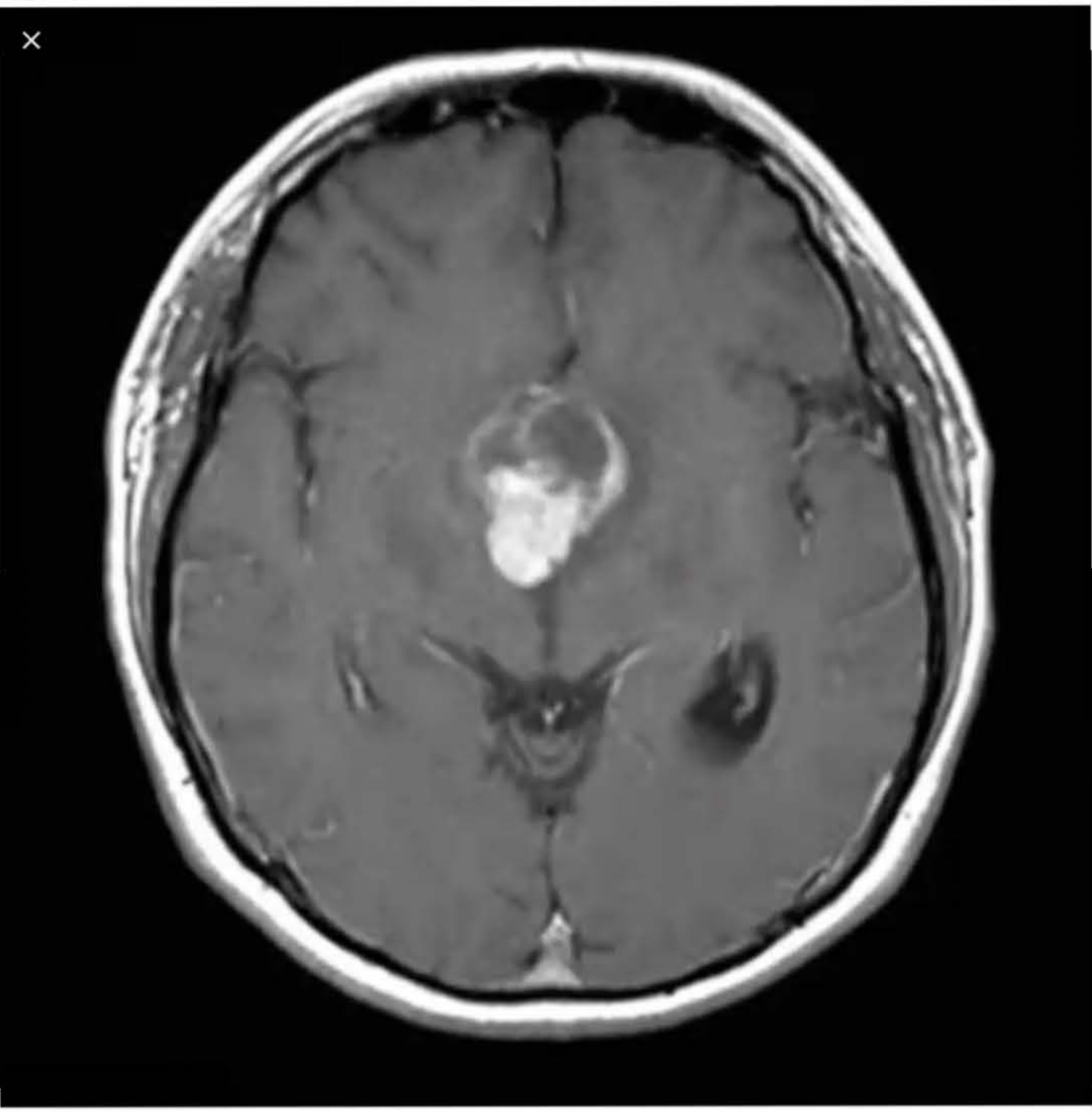

radiopaedia.org
Craniopharyngioma - papillary | Radiology Case | Radiopaedia.org
Images may be subject to copyright. Learn more
RELATED IMAGES
Discover
Updates
Search
Recent
More
Audio
Video
Share
Participants
More

12:18
594-042-7551
Leave

ResearchGate

Sagittal brain MRI of a 51 year old male with a recurrence of a ...

Sagittal brain MRI of a 51 year old male with a recurrence of a craniopharyngioma.

Images may be subject to copyright. Learn more

RELATED IMAGES

Stop Annotation Spotlight Pen Highlighter Line Rectangle Oval Undo Redo Clear Color Stop Share

Discover Updates Search Recent More

Audio Video Share Participants More

12:19

MyPastest
https://mypastest.pastest.com

Pastest+

A 54-year-old woman is referred to the Rheumatology Clinic having suffered a right Colle's fracture after slipping on ice at home. She has a history of hypertension and chronic kidney disease and is treated with ramipril, amlodipine and indapamide. A recent GFR has been measured at 32 ml/min and her DEXA scan shows a T score of -3.0.

On examination, her BP is 128/80 mmHg, pulse is 70/min and regular. Her BMI is 23. Her right wrist appears to have healed well. She is already taking calcium and vitamin D.

Which of the following is the most appropriate intervention?

A	Alendronate
B	Continue calcium and vitamin D only
C	Denosumab
D	Raloxifene
E	Teriparatide

70507

Submit

12:21

A 54-year-old woman is referred to the Rheumatology Clinic having suffered a right Colle's fracture after slipping on ice at home. She has a history of hypertension and chronic kidney disease and is treated with ramipril, amlodipine and indapamide. A recent GFR has been measured at 32 ml/min and her DEXA scan shows a T score of -3.0.

On examination, her BP is 128/80 mmHg, pulse is 70/min and regular. Her BMI is 23. Her right wrist appears to have healed well. She is already taking calcium and vitamin D.

Which of the following is the most appropriate intervention?

Your answer was incorrect

A	Alendronate
B	Continue calcium and vitamin D only
C	Denosumab
D	Raloxifene
E	Teriparatide

Explanation

C Denosumab

This is a RANK ligand inhibitor which reduces osteoclast activity and is an effective intervention for osteoporosis given as a subcutaneous injection once every six months

Dif
Pe
A
B
C
D
E
0 10
Se
Respons
Respons
Respons
Respons

Explanation

C Denosumab

This is a RANK ligand inhibitor which reduces osteoclast activity and is an effective intervention for osteoporosis given as a subcutaneous injection once every six months. Like bisphosphonates it is associated with osteonecrosis of the jaw, but not other adverse events such as reflux oesophagitis. The risk of a dynamic bone disease may be less for denosumab versus bisphosphonates because it does not accumulate in bone.

A Alendronate

Alendronate is incorrect. This is contraindicated in patients with a GFR less than 35 ml/min, as such it should not be used here.

B Continue calcium and vitamin D only

Calcium and vitamin D is incorrect. This combination is ineffective as a stand-alone intervention for patients with established osteoporosis.

D Raloxifene

Raloxifene is incorrect. This is less effective in preventing loss of bone mineral density versus bisphosphonates or denosumab. It is also associated with increased risk of venous thromboembolism.

E Teriparatide

Teriparatide is incorrect. Teriparatide, a synthetic PTH analogue, is usually reserved for patients with severe

12:22
594-042-7551 Leave

with a GFR less than 35 ml/min, as such it should not be used here.

B Continue calcium and vitamin D only

Calcium and vitamin D is incorrect. This combination is ineffective as a stand-alone intervention for patients with established osteoporosis.

D Raloxifene

Raloxifene is incorrect. This is less effective in preventing loss of bone mineral density versus bisphosphonates or denosumab. It is also associated with increased risk of venous thromboembolism.

E Teriparatide

Teriparatide is incorrect. Teriparatide, a synthetic PTH analogue, is usually reserved for patients with severe osteoporosis. Caution is also advised for patients with moderate or worse renal impairment.

Rate this question:

Next Question

© Pastest 2019

Audio Video Share Participants More

12:23

A 40-year-old female patient asks for her cholesterol to be measured. She has a past history of polycystic ovary disease and diet-controlled diabetes mellitus. She drinks a glass of wine each night and swims most days. She is currently on the oral contraceptive pill.

Investigations:

LDL cholesterol	5.5 mmol/l
Triglycerides	2.5 mmol/l
HDL cholesterol	0.8 mmol/l

Which one of the following is the most likely cause of the low HDL cholesterol levels?

A Alcohol

B Exercise

C Oral contraceptive pill

D Diet-controlled diabetes

E Female sex

6640

Submit

Rana Alnasser's screen

12:24
594-042-7551 Leave

Explanation

D Diet-controlled diabetes

Low levels of HDL are associated with an increased risk of ischaemic heart disease. Diabetes causes low HDL and raised triglycerides. HMG CoA reductase inhibitors are used in primary and secondary prevention of coronary events. Statins are particularly considered for patients with diabetes mellitus and are recommended now for all diabetics above 40 years of age in the JBS2 guidelines. They are also used in other patients with high calculated cardiovascular risk.

E Female sex

Women have naturally higher HDL levels compared to men, due to higher oestrogen levels.

A Alcohol

Mild to moderate alcohol consumption is associated with an increase in HDL.

B Exercise

Exercise is an effective way of increasing HDL cholesterol levels.

C Oral contraceptive pill

Increased oestrogen levels, as caused by the contraceptive pill, lead to higher HDL levels.

6840
Rate this question:
Audio Video Share Participants More

A 34-year-old man attends the clinic for review. He has a microprolactinoma which was diagnosed after he presented with erectile dysfunction and loss of libido. He was started on cabergoline, but suffered an episode of pericarditis.

Which of the following medications should he avoid because of the previous pericarditis?

A Aspirin

B Fluoxetine

C Pergolide

D Sumatriptan

E Ondansetron

Submit

Previous Q... Skip Questi...

© Pastest 2019

Explanation

C Pergolide

Both pergolide and cabergoline may be associated with pericarditis, cardiac valve regurgitation, pericardial effusion and pulmonary hypertension. Dopamine agonists are the treatment of choice for microprolactinoma, and ropinirole may be an appropriate alternative in this case, but otherwise surgery would be the next most appropriate step.

A Aspirin

Aspirin is recommended for treatment of pericarditis after ST-elevation myocardial infarction.

B Fluoxetine

Fluoxetine, also known by various trade names, is an antidepressant of the selective serotonin reuptake inhibitor (SSRI) class. It is used for the treatment of major depressive disorder, obsessive-compulsive disorder (OCD), bulimia nervosa, panic disorder and premenstrual dysphoric disorder.

Its use should also be avoided in those receiving other serotonergic drugs such as monoamine oxidase inhibitors, tricyclic antidepressants, methamphetamine, 3,4-methylenedioxymethamphetamine (MDMA; Ecstasy), triptans, buspirone, serotonin-norepinephrine reuptake inhibitors and other SSRIs, due to the potential for serotonin syndrome to develop as a result.

D Sumatriptan

It is used in the management of migraine or cluster headaches. Serious cardiac events, including some that have been fatal, have occurred following the use of

12:26
594-042-7551 Leave

methylenedioxymethamphetamine (MDMA; Ecstasy), triptans, buspirone, serotonin-norepinephrine reuptake inhibitors and other SSRIs, due to the potential for serotonin syndrome to develop as a result.

D Sumatriptan

It is used in the management of migraine or cluster headaches. Serious cardiac events, including some that have been fatal, have occurred following the use of sumatriptan injection or tablets. Events reported have included coronary artery vasospasm, transient myocardial ischemia, myocardial infarction, ventricular tachycardia and ventricular fibrillation (V-Fib)

E Ondansetron

Ondansetron is a medication used to prevent nausea and vomiting caused by cancer chemotherapy, radiation therapy or surgery. It is also useful in gastroenteritis. It has little effect on vomiting caused by motion sickness. It can cause QT prolongation.

Rate this question:

© Pastest 2019

Audio Video Share Participants More

12:27
594-042-7551 Leave

A 54-year-old man with type 1 diabetes presents for his annual review. Over the past couple of years, he has suffered problems with early satiety, indigestion and regurgitation of food matter but has not lost weight, and now requests investigations.

His diabetes is relatively well controlled, with a recent HbA1c of 57.38 mmol/mol (7.4%), his Hb is normal at 13.0 g/dl and his ESR is 13 mm/h. You note that he does have a postural drop of 35 mmHg on blood pressure measurement.

Which of the following actions is most useful with respect to his GI symptoms?

A	Oesophageal pH monitoring
B	Isotope gastric motility studies
C	Upper GI endoscopy
D	Trial of anti-acids
E	Trial of proton pump inhibitor therapy

Submit

Audio Video Share Participants More

regurgitation of food matter but has not lost weight, and now requests investigations.

His diabetes is relatively well controlled, with a recent HbA1c of 57.38 mmol/mol (7.4%), his Hb is normal at 13.0 g/dl and his ESR is 13 mm/h. You note that he does have a postural drop of 35 mmHg on blood pressure measurement.

Which of the following actions is most useful with respect to his GI symptoms?

Your answer was correct

A	Oesophageal pH monitoring
B	Isotope gastric motility studies
C	Upper GI endoscopy
D	Trial of anti-acids
E	Trial of proton pump inhibitor therapy

Explanation

B Isotope gastric motility studies

This patient likely has diabetic autonomic neuropathy, manifest in postural hypotension and delayed gastric emptying. Isotope gastric motility studies are the most appropriate way to assess gastric emptying, and treatments involve prokinetic agents such as domperidone, metoclopramide or erythromycin, although response to treatment is generally poor. Treatment of postural hypotension involves mechanical measures such as bedhead elevation and wearing of support stockings

Explanation

B Isotope gastric motility studies

This patient likely has diabetic autonomic neuropathy, manifest in postural hypotension and delayed gastric emptying. Isotope gastric motility studies are the most appropriate way to assess gastric emptying, and treatments involve prokinetic agents such as domperidone, metoclopramide or erythromycin, although response to treatment is generally poor. Treatment of postural hypotension involves mechanical measures such as bedhead elevation and wearing of support stockings. Intake of sodium chloride should be adequate, and fludrocortisone may be added starting at a dose of 50 µg/day, increased up to 400 µg as required. Diuretics, vasodilators and tricyclic antidepressants may exacerbate the condition and, for this reason, review of current medications that may exacerbate postural hypotension is important before commencing further therapy.

A Oesophageal pH monitoring

Oesophageal pH monitoring is most useful for evaluating symptoms of oesophageal reflux disease. Although there is a degree of reflux here, it's driven by dysmotility rather than by excess acid production.

C Upper GI endoscopy

Upper GI endoscopy is required as part of the work-up symptoms of indigestion in this patient, but won't reveal the underlying cause.

D Trial of anti-acids

Although anti-acids may offer some relief, given dysmotility is the primary problem, they are unlikely to

A 56-year-old man with a history of hypothyroidism managed with thyroxine replacement comes to the clinic for review. He has increasing tiredness. Other symptoms of note include depression and one episode of renal colic.

Investigations:

TSH	2.1 U/l (<0.5-4.5)
Hb	11.3 g/dl
WCC	4.2 x10^9/l
Na^+	139 x10^9/l
K^+	5.4 mmol/l
Creatinine	237 µmol/l
Ca^{++}	2.10 mmol/l (2.2-2.6)
1,25 dihydroxycholecalciferol	10 ng/l (20-50)
PTH	13 pmol/l (1-6)

Which of the following is the most appropriate therapy for him?

A Alphacalcidol

B Ergocalciferol

C Cinacalcet

D Sevelamer

E Parathyroidectomy

12:30
594-042-7551 Leave

WCC	4.2 x10⁹/l
Na⁺	139 x10⁹/l
K⁺	5.4 mmol/l
Creatinine	237 µmol/l
Ca⁺⁺	2.10 mmol/l (2.2-2.6)
1,25 dihydroxycholecalciferol	10 ng/l (20-50)
PTH	13 pmol/l (1-6)

E
0 10
Se
Respons
Respons
Respons
Respons

Which of the following is the most appropriate therapy for him?

Your answer was correct

A Alphacalcidol

B Ergocalciferol

C Cinacalcet

D Sevelamer

E Parathyroidectomy

Explanation

A Alphacalcidol

This man has a PTH just above twice the normal level and chronic kidney disease. Management of his secondary hyperparathyroidism involves appropriate vitamin D replacement, normally given twice per week. Surgery may be considered if parathyroidism does not respond to

Audio Video Share Participants More

12:30
594-042-7551 Leave

E Parathyroidectomy

Explanation

A Alphacalcidol

This man has a PTH just above twice the normal level and chronic kidney disease. Management of his secondary hyperparathyroidism involves appropriate vitamin D replacement, normally given twice per week. Surgery may be considered if parathyroidism does not respond to medical management.

B Ergocalciferol

This is less effective in managing hyperparathyroidism, because of defective hydroxylation of vitamin D in the kidney.

C Cinacalcet

Cinacalcet is only used for managing symptomatic hyperparathyroidism in patients with chronic kidney disease on renal replacement therapy or in those who are unable to undergo surgery.

D Sevelamer

Sevelamer is a phosphate binder used for managing hyperphosphataemia in patients with chronic renal impairment.

E Parathyroidectomy

Parathyroidectomy is the next step in patients who fail to respond to medical intervention for hyperparathyroidism.

Audio Video Share Participants More

This man has a PTH just above twice the normal level and chronic kidney disease. Management of his secondary hyperparathyroidism involves appropriate vitamin D replacement, normally given twice per week. Surgery may be considered if parathyroidism does not respond to medical management.

B Ergocalciferol

This is less effective in managing hyperparathyroidism, because of defective hydroxylation of vitamin D in the kidney.

C Cinacalcet

Cinacalcet is only used for managing symptomatic hyperparathyroidism in patients with chronic kidney disease on renal replacement therapy or in those who are unable to undergo surgery.

D Sevelamer

Sevelamer is a phosphate binder used for managing hyperphosphataemia in patients with chronic renal impairment.

E Parathyroidectomy

Parathyroidectomy is the next step in patients who fail to respond to medical intervention for hyperparathyroidism.

Rate this question:

Next Question

12:33
594-042-7551
Leave

A 58-year-old woman is admitted to the Admissions Unit. She has a long history of type 2 diabetes. Her foot is hot and swollen, and she has been suffering vague bony pains in it over the past few months. There is no history of trauma and no obvious skin break. Fundoscopy reveals diabetic retinopathy, and examination of her lower limbs reveals absent sensation to vibration and pinprick to the knees. Her blood pressure is 155/95 mmHg. HbA1c is 65 mmol/mol.

A photo and X-ray of her foot are shown below.

Audio
Video
Share
Participants
More

What is your next management step?

A	IV flucloxacillin and metronidazole
B	Lower limb venous ultrasound scan

What is your next management step?

A	IV flucloxacillin and metronidazole
B	Lower limb venous ultrasound scan
C	Below-knee cast
D	Oral clindamycin
E	Class 3 compression stockings

Explanation

C Below-knee cast

This subacute presentation, with joint swelling and chronic joint pains against a background of long-standing and poorly controlled diabetes, suggests possible Charcot's, in this case of the talo-navicular joint. Non-weight bearing in a cast is the intervention of choice. Bisphosphonates may also be of value in reducing bone turnover.

E Class 3 compression stockings

Compression stockings are used in the treatment of chronic venous insufficiency. The picture reveals no evidence of venous ulceration to suggest they are of value here.

A IV flucloxacillin and metronidazole

Co-amoxiclav is the usual preferred option for diabetic soft tissue infection, because it has wide coverage of both aerobes and anaerobes, and the subacute history is more consistent with Charcot's, especially as there is no obvious potential site of infection.

B Lower limb venous ultrasound scan

The localised swelling around the ankle joint is more consistent with bony deformity than a venous thrombosis.

D Oral clindamycin

Clindamycin is optimal oral therapy for osteomyelitis, although it is associated with high risk of development of

chronic venous insufficiency. The picture reveals no evidence of venous ulceration to suggest they are of value here.

A IV flucloxacillin and metronidazole

Co-amoxiclav is the usual preferred option for diabetic soft tissue infection, because it has wide coverage of both aerobes and anaerobes, and the subacute history is more consistent with Charcot's, especially as there is no obvious potential site of infection.

B Lower limb venous ultrasound scan

The localised swelling around the ankle joint is more consistent with bony deformity than a venous thrombosis.

D Oral clindamycin

Clindamycin is optimal oral therapy for osteomyelitis, although it is associated with high risk of development of pseudomembranous colitis.

Rate this question:

Previous Q... Tag Questi... Feedback End Session

Blog About Pastest Contact Us Help

© Pastest 2019

A 38-year-old man presents with ulcerated lesions over both shins. They are erythematous around the edges, but the centres are yellowed and atrophic with signs of ulceration. He has a history of type 1 diabetes mellitus. He has recently lost his job and has poor standards of personal care. He is on multiple daily insulin injections (insulin detemir [rDNA origin] injection as basal insulin and insulin aspart with his meals) and his diabetes control is poor (HbA1c: 79 mmol/mol).

Which of the following represents the most appropriate treatment to the non-atrophied areas?

A	Topical steroids
B	Oral prednisolone
C	Azathioprine
D	Flucloxacillin
E	Compression bandaging

7607

Submit

A 38-year-old man presents with ulcerated lesions over both shins. They are erythematous around the edges, but the centres are yellowed and atrophic with signs of ulceration. He has a history of type 1 diabetes mellitus. He has recently lost his job and has poor standards of personal care. He is on multiple daily insulin injections (insulin detemir [rDNA origin] injection as basal insulin and insulin aspart with his meals) and his diabetes control is poor (HbA1c: 79 mmol/mol).

Which of the following represents the most appropriate treatment to the non-atrophied areas?

Your answer was correct

- A Topical steroids
- B Oral prednisolone
- C Azathioprine
- D Flucloxacillin
- E Compression bandaging

Explanation

A Topical steroids

Necrobiosis lipoidica is seen in 0.3–1% of patients with diabetes and is more common in females. Around 40–60% of patients with necrobiosis lipoidica have diabetes, and the condition may predate the development of abnormal blood sugar. Treatments with topical steroids, injectable

Explanation

A Topical steroids

Necrobiosis lipoidica is seen in 0.3–1% of patients with diabetes and is more common in females. Around 40–60% of patients with necrobiosis lipoidica have diabetes, and the condition may predate the development of abnormal blood sugar. Treatments with topical steroids, injectable steroids, skin grafting and camouflage creams have been used as therapies. In practice, however, the areas of already atrophied skin respond poorly to steroid therapy.

B Oral prednisolone

Oral prednisolone would deteriorate his diabetes control even further.

C Azathioprine

Azathioprine, sold under the brand name is an immunosuppressive medication which is used in rheumatoid arthritis, Crohn's disease and ulcerative colitis, and in kidney transplants to prevent rejection. Common side effects include bone marrow suppression and vomiting. Bone marrow suppression is especially common in people with a genetic deficiency of the enzyme thiopurine S-methyltransferase. Other serious risk factors include an increased risk of lymphoma. Azathioprine is in the purine analogue and anti-metabolite family of medication. It works via 6-thioguanine to disrupt the synthesis of RNA and DNA by cells.

D Flucloxacillin

This is mainly used in cases of cellulitis which would manifest with an area of erythema accompanied usually by tenderness and increased skin temperature.

vomiting. Bone marrow suppression is especially common in people with a genetic deficiency of the enzyme thiopurine S-methyltransferase. Other serious risk factors include an increased risk of lymphoma. Azathioprine is in the purine analogue and anti-metabolite family of medication. It works via 6-thioguanine to disrupt the synthesis of RNA and DNA by cells.

D	Flucloxacillin

This is mainly used in cases of cellulitis which would manifest with an area of erythema accompanied usually by tenderness and increased skin temperature.

E	Compression bandaging

This is used for the treatment of venous ulcers. A venous ulcer tends to occur on the medial side of the leg, typically around the medial malleolus, and is usually shallow with irregular, sloping edges. Venous ulcers are typically 'wet' with a moderate to heavy exudate. The skin surrounding a venous ulcer may be oedematous, and there may be evidence of varicose veins.

Rate this question:

Previous Q... Tag Questi... Feedback End Session

Blog About Pastest Contact Us Help

© Pastest 2019

A collapsed patient is admitted to A&E. In his possession are empty prednisolone boxes, and he has a steroid user card. He has obvious rheumatoid features on examination and unilateral consolidation on his chest X-ray. He is given intravenous fluids and broad-spectrum antibiotics. His BP is 100/60 mmHg lying and 75/40 standing, with a pulse of 95/min.

Investigations:

Sodium	131 mmol/l
Potassium	5.7 mmol/l
Urea	7.8 mmol/l
Creatinine	105 umol/l

Which one of the following would be the most useful addition to the current management?

A	Thyroid function test before giving steroids
B	Oral prednisolone 40 mg
C	IV hydrocortisone 100 mg
D	Oral prednisolone 20 mg and fludrocortisone 50 µg
E	Oral prednisolone 40 mg and fludrocortisone 50 µg

Submit

C IV hydrocortisone 100 mg

The history of rheumatoid arthritis and steroid user card suggests the patient is on steroids. The fact that he has empty boxes in his possession may mean that he has run out of steroids. As he currently has a pneumonia, his need for steroids will be higher than normal. These should be given IV to ensure they are absorbed.

A Thyroid function test before giving steroids

It is important not to delay the administration of steroids as the patient is systemically unwell and may have missed a number of doses.

B Oral prednisolone 40 mg

Oral formulations of steroids are inadequately absorbed and therefore not appropriate in patients who are systemically unwell.

D Oral prednisolone 20 mg and fludrocortisone 50 µg

Fludrocortisone is often used in the treatment of Addison's disease at a dose of 50-300 µg. There is no indication that this patient has Addison's. Even in new diagnoses of Addison's, mineralocorticoid replacement is not necessary in the acute phase. This is because high-dose hydrocortisone has a mineralocorticoid effect.

E Oral prednisolone 40 mg and fludrocortisone 50 µg

Fludrocortisone is often used in the treatment of Addison's disease. There is no indication that this patient has Addison's. Even in new diagnoses of Addison's

A 55-year-old man with a 5-year history of type 2 diabetes presents for review. He currently takes metformin 2 g/day and gliclazide 160 mg/day, and a recent HbA1c was 68.31 mmol/mol (8.4%). His complaint is of weight loss, burning proximal muscle pain and weakness. On examination there is left-sided quadriceps wasting.

Which of the following treatments is most appropriate for his diabetes and associated complications?

A	Increased metformin dose
B	Increased gliclazide dose
C	Transition to insulin therapy
D	Amytriptyline
E	Tramadol

Submit

Previous Q... Skip Questi...

© Pastest 2019

Explanation

C Transition to insulin therapy

The aetiology of diabetic amyotrophy, the diagnosis here, is unknown. It affects the lumbar sacral plexus lower motor neurones. Transition to insulin therapy is recommended because it is likely to improve his glucose control, and may impact progression of neuropathy. Recovery of diabetic amyotrophy happens over 3-4 months, but only 50% achieve complete recovery. Trials of immunomodulatory agents in managing the condition have been disappointing.

A Increased metformin dose

There is little evidence that increasing metformin dose above 2 g/day has any additional impact on glycaemic control.

B Increased gliclazide dose

Like metformin, the dose response curve for gliclazide is relatively flat at high doses. The increment in glucose control between 160 and 320 mg/day is therefore small.

D Amytriptyline

Amitriptyline, although effective in treating neuropathic pain, won't impact on progression of neuropathy.

E Tramadol

Opiate-based analgesics aren't recommended for the treatment of diabetic neuropathy because they are less effective than agents such as tricyclic anti-depressants, and are addictive.

12:43

MyPastest
https://mypastest.pastest.com

Pastest+

A 73-year-old man comes to the clinic as a referral from his GP, having presented with severe headaches and ischaemic pain in his fingers and toes. The pain increases with heat, and improves if he keeps his hands and feet cold. Most striking is that just taking a few aspirin tablets seemed to improve things for a significant time period. He has a past medical history of hypertension for which he takes ramipril. On examination his BP is 142/87 mmHg and the remainder of the physical examination is unremarkable.

Investigations (sent by the GP):

Hb	12.3 g/dl
WCC	8.1 $\times 10^9$/l
PLT	821 $\times 10^9$/l
Na^+	140 mmol/l
K^+	6.2 mmol/l
Creatinine	130 µmol/l

Which of the following is the most appropriate way to deal with his hyperkalaemia?

A Stop the ramipril

B Start a small dose of furosemide

C Re-check a fresh sample at the hospital

D Reassure the biochemistry department that it is related to the high platelet count

E Start calcium resonium

Hb	12.3 g/dl
WCC	8.1 x10⁹/l
PLT	821 x10⁹/l
Na^+	140 mmol/l
K^+	6.2 mmol/l
Creatinine	130 µmol/l

Which of the following is the most appropriate way to deal with his hyperkalaemia?

Your answer was correct

A Stop the ramipril

B Start a small dose of furosemide

C Re-check a fresh sample at the hospital

D Reassure the biochemistry department that it is related to the high platelet count

E Start calcium resonium

Explanation

C Re-check a fresh sample at the hospital

Pseudohyperkalaemia is known to be associated with essential thrombocytosis, the most likely diagnosis here. It is also likely that the sample taken at the GP surgery had spent a considerable amount of time in transit, allowing for in-tube cell lysis to further increase potassium levels. As

C Re-check a fresh sample at the hospital

Pseudohyperkalaemia is known to be associated with essential thrombocytosis, the most likely diagnosis here. It is also likely that the sample taken at the GP surgery had spent a considerable amount of time in transit, allowing for in-tube cell lysis to further increase potassium levels. As such, it is sensible to re-check a sample.

A Stop the ramipril

Given that the creatinine is almost in the normal range, it's most likely the elevated potassium is due to pseudohyperkalaemia; as such, the potassium must be re-checked before considering treatment discontinuation.

B Start a small dose of furosemide

This may lead to volume depletion and actually increase the risk of a thrombotic event related to the high platelet count.

D Reassure the biochemistry department that it is related to the high platelet count

It must be re-checked at the hospital to exclude significant hyperkalaemia.

E Start calcium resonium

This should be started for hyperkalaemia either in the acute setting or where other options for reducing hyperkalaemia in the chronic setting, such as discontinuation of other therapies, have been excluded.

Rate this question:

A 46-year-old publican presents to the Emergency room with symptoms of thirst and lethargy. He had been discharged some 2 weeks earlier after his 3rd episode of acute pancreatitis in the past year. He admits to alcoholism, drinking 3 bottles of whisky and at least 30 pints of beer each week. On examination he looks dehydrated. His BP is 125/70 mmHg, and his pulse is 92/min, his BMI is 21. Respiratory, cardiovascular and abdominal examinations are unremarkable.

Investigations:

Hb	12.1 g/dl
WCC	9.1 x10^9/l
PLT	232 x10^9/l
Na^+	142 mmol/l
K^+	5.1 mmol/l
Creatinine	185 µmol/l
Glucose	26.1 mmol/l
Amylase	400U/L (60-180)
Urine ketones	-ve

He agrees to begin a detox regime.

Which of the following is the most appropriate way to manage his diabetes?

A Metformin

B Glicazide

C Acarbose

D Sitagliptin

Respiratory, cardiovascular and abdominal examinations are unremarkable.

Investigations:

Hb	12.1 g/dl
WCC	9.1 x10⁹/l
PLT	232 x10⁹/l
Na^+	142 mmol/l
K^+	5.1 mmol/l
Creatinine	185 µmol/l
Glucose	26.1 mmol/l
Amylase	400U/L (60-180)
Urine ketones	-ve

He agrees to begin a detox regime.

Which of the following is the most appropriate way to manage his diabetes?

A Metformin

B Glicazide

C Acarbose

D Sitagliptin

E Insulin

Submit

PLT	232 x10⁹/l
Na^+	142 mmol/l
K^+	5.1 mmol/l
Creatinine	185 µmol/l
Glucose	26.1 mmol/l
Amylase	400U/L (60-180)
Urine ketones	-ve

He agrees to begin a detox regime.

Which of the following is the most appropriate way to manage his diabetes?

Your answer was correct

A Metformin

B Glicazide

C Acarbose

D Sitagliptin

E Insulin

Explanation

E Insulin

Diabetes associated with pancreatitis is due to damage to the endocrine pancreas and associated lack of insulin. This

E Insulin

Diabetes associated with pancreatitis is due to damage to the endocrine pancreas and associated lack of insulin. This pathophysiology is consistent with the patient's presentation: he is thin, with symptoms of insulinopaenia. As such, exogenous insulin replacement is the only appropriate intervention here.

A Metformin

Metformin reduces hepatic glucose output and is therefore expected to have no significant impact on blood glucose levels in this patient.

B Glicazide

Although gliclazide will have a stimulatory effect on remaining endogenous insulin production, it's unlikely to achieve blood glucose control.

C Acarbose

Acarbose reduces absorption of complex carbohydrates from the gut. In this case it won't impact on glucose control and will actually worsen diarrhoea.

D Sitagliptin

Sitagliptin reduces degradation of endogenous incretins; these, however, have little effect on increasing insulin production from a failing pancreas.

Rate this question:

A 42-year-old man presents to the GP with lethargy and depression. He is in relationship difficulties, as his partner is having an affair and he admits to impotence over the last 2 years. Other past history of note includes hypertension which is managed with amlodipine 5mg daily. On examination his BP is 145/82 mmHg, he is overweight with a BMI of 29. You note that he is quite tanned but tells you he had taken the children on holiday to the beach during the previous week.

Investigations;

Hb	13.4 g/dl
WCC	7.9 x10^9/l
PLT	204 x10^9/l
Na^+	139 mmol/l
K^+	4.5 mmol/l
Creatinine	130 µmol/l
ALT	135 U/l
TSH	Low
T4	Just below limit of normal range
Glucose	8.9 mmol/l (fasting)

Which of the following investigations is most likely to confirm the diagnosis?

A Testosterone

B Morning cortisol

C Growth hormone

examination his BP is 145/82 mmHg, he is overweight with a BMI of 29. You note that he is quite tanned but tells you he had taken the children on holiday to the beach during the previous week.

Investigations;

Hb	13.4 g/dl
WCC	7.9 x10⁹/l
PLT	204 x10⁹/l
Na^+	139 mmol/l
K^+	4.5 mmol/l
Creatinine	130 µmol/l
ALT	135 U/l
TSH	Low
T4	Just below limit of normal range
Glucose	8.9 mmol/l (fasting)

Which of the following investigations is most likely to confirm the diagnosis?

A Testosterone

B Morning cortisol

C Growth hormone

D Transferrin saturation

E Ferritin

D Transferrin saturation

The constellation of diabetes, increased skin pigmentation with evidence of pituitary dysfunction as evidenced by pituitary dependent hypothyroidism, and impotence, against a background of abnormal LFTs raises the possibility of haemochromatosis. Transferrin saturation is the optimal blood test to support the diagnosis, as ferritin may also be elevated in a number of other chronic liver conditions. HFE gene analysis is the mainstay with respect to confirming the diagnosis, with liver biopsy useful in determining the degree of cirrhosis associated with haemochromatosis.

A Testosterone

Testosterone may well be reduced, but measuring it is unlikely to reveal the underlying cause.

B Morning cortisol

Morning cortisol may be low due to pituitary dysfunction and failure of ACTH production, although this is less likely given that both sodium and potassium are within the normal range.

C Growth hormone

Growth hormone may be reduced due to pituitary dysfunction, although again, measuring it is unlikely to reveal the underlying cause.

E Ferritin

Although ferritin is elevated in haemochromatosis, it is also an acute phase protein and is therefore also elevated with other causes of hepatic dysfunction.

12:50

A 20-year-old woman comes to the clinic complaining of excess facial hair and acne.

On examination, her BMI is elevated at 29 kg/m^2. Her BP is raised at 155/92 mmHg and her pulse is 80/min and regular. You notice excess hair around her beard line, upper chest and lower abdomen. There are no purple striae on abdominal examination. The examination of external genitalia is normal.

On further questioning, she tells you that her periods are irregular, only occurring every 3 months, and they are heavy when they do occur.

Which one of the following would be an appropriate initial investigation?

A	Plasma ACTH
B	MRI pituitary
C	Testosterone levels
D	High-dose dexamethasone suppression test
E	17-hydroxyprogesterone

Submit

Previous Q... Skip Questi...

Rana Alnasser's screen

C Testosterone levels

The suspected diagnosis here is polycystic ovarian syndrome (PCOS). According to the Rotterdam Consensus, two of the following three criteria are required for the diagnosis of the PCOS:

- oligo-/anovulation
- hyperandrogenism
  - clinical (hirsutism or less commonly male pattern alopecia) or
  - biochemical (raised free androgen index or free testosterone)
- polycystic ovaries on ultrasound.

A Plasma ACTH

There is no clear clinical evidence of cortisol excess in this scenario. Even if Cushing syndrome was suspected, an overnight dexamethasone suppression test or high-dose dexamethasone suppression test would be the initial investigation in order to establish the presence of hypercortisolism. If hypercortisolim was confirmed, a suppressed ACTH would point towards an adrenal cause whereas raised ACTH would indicate a pituitary cause.

B MRI pituitary

This would be useful only if Cushing syndrome was confirmed via overnight dexamethasone or high-dose dexamethasone suppression test and a central cause for hypercortisolism was suspected.

D High-dose dexamethasone suppression test

This is used when Cushing syndrome is clinically suspected

confirmed via overnight dexamethasone or high-dose dexamethasone suppression test and a central cause for hypercortisolism was suspected.

D High-dose dexamethasone suppression test

This is used when Cushing syndrome is clinically suspected and the overnight dexamethasone suppression test results are equivocal.

E 17-hydroxyprogesterone

This is usually raised (>1000 ng/dl) in cases of congenital adrenal hyperplasia (CAH) due to 21-hydroxylase deficiency. Females with severe CAH due to deficiencies of 21-hydroxylase, 11-beta-hydroxylase or 3-beta-hydroxysteroid dehydrogenase have ambiguous genitalia at birth (classic virilising adrenal hyperplasia). Females with mild 21-hydroxylase deficiency are identified later in childhood because of precocious pubic hair, clitoromegaly or both, often accompanied by accelerated growth and skeletal maturation (simple virilising adrenal hyperplasia). Females with still milder deficiencies of 21-hydroxylase or 3-beta-hydroxysteroid dehydrogenase activity may present in adolescence or adulthood with oligomenorrhoea, hirsutism and/or infertility (non-classic adrenal hyperplasia).

Rate this question:

Next Question

Previous Q... Tag Questi... Feedback End Session

12:52
594-042-7551
Leave

An 18-year-old man has been seen in the clinic for recurrent oral candida infections over the past year. He was previously fit and well. HIV antibody and polymerase chain reaction tests are negative.

In terms of his biochemical profile, the patient has a normal oral glucose tolerance test, normal urea and electrolytes and normal TSH.

His bone profile results:

Corr. Ca^{++}	2.01 mmol/l (2.2-2.6 mmol/l)
Phosphate	1.65 mmol/l (0.8-1.5 mmol/l)
PTH	1.0 pmol/l (1.5-7.6 pmol/l)
Vitamin D	23 nmol/l (< 25 nmol/l indicates deficiency)

Which of the following is the most likely pathology?

A Type 2 polyglandular syndrome

B Secondary hyperparathyroidism

C Primary hyperparathyroidism

D Type 1 polyglandular autoimmune syndrome

E Hyperthyroidism

Submit

Previous Q...
Skip Questi...
Audio
Video
Share
Participants
More

An 18-year-old man has been seen in the clinic for recurrent oral candida infections over the past year. He was previously fit and well. HIV antibody and polymerase chain reaction tests are negative.

In terms of his biochemical profile, the patient has a normal oral glucose tolerance test, normal urea and electrolytes and normal TSH.

His bone profile results:

Corr. Ca^{++}	2.01 mmol/l (2.2-2.6 mmol/l)
Phosphate	1.65 mmol/l (0.8-1.5 mmol/l)
PTH	1.0 pmol/l (1.5-7.6 pmol/l)
Vitamin D	23 nmol/l (< 25 nmol/l indicates deficiency)

Which of the following is the most likely pathology?

Your answer was correct

A Type 2 polyglandular syndrome

B Secondary hyperparathyroidism

C Primary hyperparathyroidism

D Type 1 polyglandular autoimmune syndrome

E Hyperthyroidism

Explanation

D Type 1 polyglandular autoimmune syndrome

Explanation

D	Type 1 polyglandular autoimmune syndrome

Type 1 polyglandular autoimmune syndrome comprises mucocutaneous candidiasis, chronic hypoparathyroidism and autoimmune hypoadrenalism. The three major components tend to present in the chronological order of candidiasis, followed by hypoparathyroidism, followed by adrenal insufficiency. Hypoparathyroidism chronologically follows the mucocutaneous candidiasis and presents with hypocalcaemia, hyperphosphataemia and low parathyroid hormone. Other autoimmune pathologies associated with the condition include type 1 diabetes, pernicious anaemia, hypothyroidism and vitiligo. Treatment includes antifungals, vitamin D, calcium and glucocorticoid replacement.

A	Type 2 polyglandular syndrome

Type 2 polyglandular syndrome comprises autoimmune hypoadrenalism, in combination with thyroid autoimmune disease (Hashimoto's thyroiditis or Graves' disease) and/or type 1 diabetes mellitus. Primary hypogonadism, myasthenia gravis and coeliac disease are also commonly seen in this syndrome.

B	Secondary hyperparathyroidism

The biochemical profile would have been different in this condition, with a low Vitamin D, hypocalcaemia and a high PTH.

C	Primary hyperparathyroidism

This is not part of the polygandular autoimmune syndromes and manifests with hypercalcaemia, hypophosphataemia and normal/high parathyroid hormone

An 18-year-old woman has been referred to the clinic by her GP. She attends with her mother, who is concerned that she has become irritable, depressed and withdrawn over the past few weeks after splitting with her boyfriend. She is currently studying for her A-levels. Her mother takes thyroxine.

Thyroid function tests are shown below:

TSH	2.1 mU/l (0.4–5)
Total T4	85 nmol/l (58–174)
Total T3	3.31 pmol/l (1.07–3.18)
Free T4	14 nmol/l (10–22)
Free T3	6.1 pmol/l (5–10)

Which of the following diagnoses fits best with this clinical and biochemical picture?

A T3 thyrotoxicosis

B Sick euthyroid syndrome

C Pregnancy

D Grave's disease

E Ectopic thyroid hormone administration

Submit

C Pregnancy

This woman has become irritable and depressed with a change of behaviour over the past few weeks. Excess oestrogen, clofibrate and chronic heroin abuse are known to increase thyroid hormone-binding proteins. This would result in an increase in total T3 and T4, with normal free hormone levels. For this reason, total thyroid hormone levels are often misleading and most laboratories now measure free hormone concentration. In this case the thyroid screen is of course normal with only the total T3 just above the normal range. Glucocorticoids, phenytoin, androgens and carbamazepine all result in a reduction in thyroid hormone binding proteins.

E Ectopic thyroid hormone administration

Ectopic thyroid hormone administration results in suppression of TSH and elevated free thyroid hormones, in contrast to the clinical picture seen here.

A T3 thyrotoxicosis

Although total T3 is above the upper limit of normal, free T3 lies within the normal range, suggesting an increase in thyroid-binding globulin, not T3 thyrotoxicosis.

B Sick euthyroid syndrome

Sick euthyroid syndrome occurs when thyroid hormone levels fall at the time of a severe intercurrent illness.

D Grave's disease

Graves' disease is associated with excess free thyroid hormones and suppression of TSH.

12:58
594-042-7551
Leave

A 78-year-old woman signs on with a new general practitioner (GP) and has some routine blood tests. It is after these blood tests that the GP notices a raised corrected calcium level of 2.80 mmol/l and a raised parathyroid hormone (PTH) at 9 pmol/l. There is no history of renal stones, fractures or psychiatric disturbance. Other renal and liver function testing is unremarkable, full blood count is normal and there is no suspicion of underlying malignancy. Bone mineral density is at the lower end of the normal range.

Which is likely to be the most appropriate way to manage this woman?

A	Neck exploration for parathyroidectomy
B	Hormone replacement therapy
C	Observation
D	Calcium and vitamin D therapy
E	Oral phosphate

Submit

Audio
Video
Share
Participants
More

A 78-year-old woman signs on with a new general practitioner (GP) and has some routine blood tests. It is after these blood tests that the GP notices a raised corrected calcium level of 2.80 mmol/l and a raised parathyroid hormone (PTH) at 9 pmol/l. There is no history of renal stones, fractures or psychiatric disturbance. Other renal and liver function testing is unremarkable, full blood count is normal and there is no suspicion of underlying malignancy. Bone mineral density is at the lower end of the normal range.

Which is likely to be the most appropriate way to manage this woman?

Your answer was incorrect

A Neck exploration for parathyroidectomy

B Hormone replacement therapy

C Observation

D Calcium and vitamin D therapy

E Oral phosphate

Explanation

C Observation

Definite indications for surgery in hyperparathyroidism, the most likely diagnosis here (American National Institutes of Health consensus) include markedly elevated corrected

C Observation

Definite indications for surgery in hyperparathyroidism, the most likely diagnosis here (American National Institutes of Health consensus) include markedly elevated corrected serum calcium (>3 mmol/l), previous marked hypercalcaemic episode, impaired renal function, renal stones, nephrocalcinosis, substantially elevated urinary calcium and reduced bone mineral density. Patients with hyperparathyroidism kept under observation require annual plasma calcium, renal function and blood pressure checks, repeat bone mineral density check every 2–3 years and renal ultrasound scan. Any significant deterioration in the clinical condition would be an indication for surgery. Surgery should be carried out by a surgeon who does more than 20 parathyroidectomies per year. In parathyroid adenoma the affected gland should be removed; hyperplasia may be managed with partial parathyroidectomy or complete parathyroidectomy, with medical treatment for hypoparathyroidism.

A Neck exploration for parathyroidectomy

In this scenario the patient has mild hypercalcaemia, with no symptoms and no end-organ damage (i.e. nephrocalcinosis, osteoporosis), and therefore there is no indication for surgical intervention.

B Hormone replacement therapy

Common clinical indications to commence menopausal hormone replacement therapy are:

- to relieve vasomotor symptoms
- to improve urogenital symptoms (long-term therapy is required)
- to prevent osteoporosis.

Oestrogen therapy in postmenopausal women has been shown to cause a small reduction in serum calcium (up to 0.25 mmol/l) without a change in parathyroid hormone. Oestrogen also has beneficial effects on lumbar spine and femoral neck bone mineral density. However, due to risks associated with oestrogen replacement, it should not be used for the sole purpose of treating primary hyperparathyroidism.

D Calcium and vitamin D therapy

Calcium replacement is not indicated in primary hyperparathyroidism, since it would deteriorate the hypercalcaemia. Vitamin D can be administered cautiously and at a lower dose in the context of deficiency.

E Oral phosphate

Primary hyperparathyroidism can cause mild hypophosphataemia through increased phosphaturia. Phosphate replacement therapy is not indicated.

6466

Rate this question:

Next Question

Previous Q... Tag Questi... Feedback End Session

Blog About Pastest Contact Us Help

© Pastest 2019

An 18-year-old hirsute female, obese patient is referred to your clinic with a prolactin of 850 mU/l (90–520), and no menses for the past 3 months. She has a blood pressure of 125/82 mmHg, and her pulse is 70/min and regular. Her BMI is 27.

What is the most important next step?

A	Serum 17-hydroxy-progesterone levels
B	Pituitary MRI
C	Serum testosterone levels
D	Serum FSH and LH levels
E	Pregnancy testing

6250

Submit

Previous Q... Skip Questi...

© Pastest 2019

E Pregnancy testing

The first test to do when seeing anyone with hyperprolactinaemia is to exclude pregnancy, as it is the most common cause. Obesity and hirsutism are common and may not indicate any underlying pathology. Prolactin is normally <450 mU/l, but can rise tenfold in pregnancy. A serum prolactin of >3000 mU/l is suggestive of a tumour. However, treatment with dopamine antagonists can give a prolactin of 900–3600 mU/l.

A Serum 17-hydroxy-progesterone levels

Congenital adrenal hyperplasia is associated with hirsutism, although given that the patient has had a normal menstrual cycle until 3 months earlier, pregnancy is the more likely cause of her presentation here.

B Pituitary MRI

The prolactin level seen here is not particularly elevated, making a tumour less likely as the cause of her symptoms. Large pituitary tumours can compress or interrupt the pituitary stalk, leading to prolactin in the range of 900–6000 mU/l. However, macroprolactinomas are generally defined as a prolactin of >6000 mU/l. First-line therapy for prolactinoma is with dopamine agonists such as bromocriptine or cabergoline.

C Serum testosterone levels

Given that this patients symptoms of amenorrhoea are recent, pregnancy is more likely than an alternative diagnosis such as polycystic ovarian syndrome.

D Serum FSH and LH levels

Calculation of the LH:FSH ratio is most useful in the

A 40-year-old woman is referred to the Endocrine Clinic with diabetes mellitus and hypertension. She tells you that she has gained weight by 23 kg over the past 18 months and her blood glucose is not controlled (recent HbA1c is 65 mmol/mol), despite taking metformin, liraglutide and long-acting insulin in combination. Her blood pressure is 155/95 mmHg.

She has also developed hirsutism and acne, as seen in the picture below.

Which of the following is the most useful next investigation?

A	Insulin-like growth factor 1 (IGF-1)
B	Oral glucose tolerance test with growth hormone measurement
C	Thyroid-stimulating hormone (TSH)
D	24-hour urinary metanephrines
E	24-hour urinary free cortisol

Explanation

E	24-hour urinary free cortisol

The suspicion in a patient with rapid weight gain, hirsuitism, acne, impaired glucose tolerance and hypertension is that they have developed Cushing syndrome. Adrenal causes of Cushing syndrome versus a pituitary adenoma may be associated with a greater degree of hyperandrogenism, and hence with more marked hirsutism and acne in women. The patient can be given a urine bottle when she leaves the clinic. Hence 24-hour urinary free cortisol represents an ideal initial screening test for Cushing syndrome.

A	Insulin-like growth factor 1 (IGF-1)

IGF-1 is most useful in screening for acromegaly, as it is elevated in patients with growth hormone excess. The features here fit better with Cushing syndrome, rather than a diagnosis of acromegaly.

B	Oral glucose tolerance test with growth hormone measurement

This may be used as a confirmatory test for acromegaly where growth hormone fails to be suppressed. Here the features are consistent with Cushing syndrome, rather than acromegaly.

C	Thyroid-stimulating hormone (TSH)

Hypothyroidism could account for the weight gain seen here, but it would not account for the marked deterioration in glucose tolerance, nor for the hirsutism and acne seen in this patient.

1:05

A 52-year-old woman with diabetes mellitus treated with metformin is admitted in a semi-comatose state. She is also taking ramipril, bendroflumethiazide and digoxin for atrial fibrillation and hypertension. You understand she also takes sleeping pills and codeine-based pain relief for arthritis and has recently split from her husband.

Investigations:

pH	7.41
pCO_2	3.2 kPa
pO_2	8.8 kPa
Bicarbonate	19 mmol/l
Glucose	57 mmol/l
Na^+	149 mmol/l
K^+	4.7 mmol/l
Creatinine	134 mol/l

Which of the following is the most likely diagnosis?

A Acute kidney disease

B Diabetic ketoacidosis

C Hyperosmolar non-ketotic state

D Codeine overdose

E Lactic acidosis

Rana Alnasser's screen

pO_2	6.8 kPa
Bicarbonate	19 mmol/l
Glucose	57 mmol/l
Na^+	149 mmol/l
K^+	4.7 mmol/l
Creatinine	134 mol/l

Which of the following is the most likely diagnosis?

Your answer was correct

A Acute kidney disease

B Diabetic ketoacidosis

C Hyperosmolar non-ketotic state

D Codeine overdose

E Lactic acidosis

Explanation

C Hyperosmolar non-ketotic state

This woman has markedly high blood glucose yet the pH is within the normal range, with bicarbonate of 19 mmol/l. It is likely that she is suffering from hyperosmolar hyperglycaemic state, which is characterised by profound hyperglycaemia and diuresis. Non-compliance with diet and medication may have precipitated her presentation. Treatment centres on aggressive fluid replacement with normal saline, and treatment of hyperglycaemia using a

C Hyperosmolar non-ketotic state

This woman has markedly high blood glucose yet the pH is within the normal range, with bicarbonate of 19 mmol/l. It is likely that she is suffering from hyperosmolar hyperglycaemic state, which is characterised by profound hyperglycaemia and diuresis. Non-compliance with diet and medication may have precipitated her presentation. Treatment centres on aggressive fluid replacement with normal saline, and treatment of hyperglycaemia using a fixed-rate IV insulin regimen. She may well be converted back to oral therapy once the acute metabolic disturbance is corrected.

A Acute kidney disease

The lack of significant acidosis and only mildly elevated creatinine count against acute kidney disease as the reason for her presentation here.

B Diabetic ketoacidosis

Diabetic ketoacidosis is seen in patients with type 2 diabetes but is seen very late in the disease when patients have significant insulinopaenia, and is associated with metabolic acidosis not seen here.

D Codeine overdose

Codeine overdose is associated with respiratory acidosis, not seen on the laboratory values here.

E Lactic acidosis

Although lactic acidosis is associated with metformin use, the bicarbonate of 19 effectively rules that out here.

A 48-year-old patient with type 2 diabetes has been admitted with high blood sugars and dehydration consistent with hyperosmolar hyperglycaemic state. His blood sugar has been controlled on a combination of metformin and gliclazide tablets for the last 10 years, but over the last few months his sugars have been increasingly difficult to control. He has been controlled on sliding-scale insulin during the inpatient stay. The plan is to commence twice daily 30/70 mixed insulin on discharge. He is 90 kg in weight.

He has been eating normally, and his sugars have settled down. The nurse would like you to prescribe his insulin.

Sliding scale chart. Date: (25/7, admission)

Time	Insulin U/h	Time	Insulin U/h
0100 h		0100 h	1
0200 h		0200 h	1
0300 h		0300 h	1
0400 h		0400 h	1
0500 h		0500 h	1
0600 h		0600 h	2
0700 h		0700 h	2
0800 h		0800 h	3
0900 h		0900 h	4
1000 h		1000 h	3
1100 h		1100 h	2
1200 h	2	1200 h	3
1300 h	3	1300 h	4
1400 h	4	1400 h	
1500 h	5	1500 h	

1200 h	2	1200 h	3
1300 h	3	1300 h	4
1400 h	4	1400 h	
1500 h	5	1500 h	
1600 h	3	1600 h	
1700 h	2	1700 h	
1800 h	4	1800 h	
1900 h	3	1900 h	
2000 h	4	2000 h	
2100 h	2	2100 h	
2200 h	2	2200 h	
2300 h	2	2300 h	
2400 h	1	2400 h	

What would you prescribe?

A 30/70 mix 20 units am, 10 units pm

B 30/70 mix 20 units am, 20 units pm

C 30/70 mix 20 units am, 40 units pm

D 30/70 mix 60 units am

E 30/70 mix 40 units am, 20 units pm

1:17
594-042-7551
Leave

E 30/70 mix 40 units am, 20 units pm

Explanation

B 30/70 mix 20 units am, 20 units pm

This patient has been requiring around 60 units of insulin per 24 h, and they have type 2 diabetes. After getting over his episode of hyperosmolar hyperglycaemic state, it is likely that his insulin requirement will fall. Hence as a starting insulin dose, it would be most sensible to begin with around 2/3 of the total dose required during the episode of hyperosmolar hyperglycaemic state (40 units), split morning and evening.

E 30/70 mix 40 units am, 20 units pm

Insulin requirements as an outpatient will diminish versus those in the inpatient period. Although the patient may eventually require 60 units, it would be better to start at a dose of 40 and slowly up-titrate the dose if needed.

A 30/70 mix 20 units am, 10 units pm

This is likely to underdose on insulin, being only 50% of his inpatient requirements and is only 0.33 U/kg of body weight. Significant up-titration is therefore likely to be needed.

C 30/70 mix 20 units am, 40 units pm

Although this does represent inpatient requirements, these are likely to diminish post the acute illness and dosing 2/3 of the insulin in the evening risks significant nocturnal hypoglycaemia.

D 30/70 mix 20 units a

Audio Video Share Participants More

2:00
594-042-7551
Leave

A 24-year-old woman comes to the Endocrine Clinic as she has become increasingly concerned about her weight, which has increased considerably over the past six months. She claims that her diet has remained unchanged and her physical fitness is good. She is taking topical erythromycin for her acne. A pregnancy test was negative, although she does admit to a somewhat erratic menstrual cycle. She has also noticed increased coarse, dark, hair growth on her upper lip. In the clinic, her random blood sugar measurement by finger-prick was 8.0 mmol/l.

Which investigation is most likely to point to the underlying diagnosis?

A Urinary cortisol levels

B TSH level

C Oral glucose tolerance test

D MRI brain

E USS pelvis

2348

Submit

Audio
Video
Share
Participants
More

2:01
On
594-042-7551
Leave

A 24-year-old woman comes to the Endocrine Clinic as she has become increasingly concerned about her weight, which has increased considerably over the past six months. She claims that her diet has remained unchanged and her physical fitness is good. She is taking topical erythromycin for her acne. A pregnancy test was negative, although she does admit to a somewhat erratic menstrual cycle. She has also noticed increased coarse, dark, hair growth on her upper lip. In the clinic, her random blood sugar measurement by finger-prick was 8.0 mmol/l.

Which investigation is most likely to point to the underlying diagnosis?

Your answer was correct

A	Urinary cortisol levels
B	TSH level
C	Oral glucose tolerance test
D	MRI brain
E	USS pelvis

Explanation

E	USS pelvis

The history is consistent with Cushing syndrome or polycystic ovary syndrome (PCOS). If not caused by

Audio
Video
Share
Participants
More

2:01
On
594-042-7551
Leave

E USS pelvis

The history is consistent with Cushing syndrome or polycystic ovary syndrome (PCOS). If not caused by pregnancy, weight gain is most likely in young people to be caused by increased fat. The causes are: increased caloric consumption disproportionate to energy expenditure; sedentary lifestyle, contributing significantly by TV watching and video gaming; endocrine disorders such as Cushing syndrome; PCOS; hypothyroidism; hypothalamic dysfunction; medications; environmental factors such as poor sleep; gut microbiota; and viruses.

Women with PCOS often present with hirsutism and menstrual irregularities. PCOS is also associated with insulin resistance. As per the Rotterdam 2003 criteria for PCOS, two out of the following three should be applicable for a diagnosis of PCOS.

- Oligo- and/or anovulation
- Clinical and/or biochemical signs of hyperandrogenism
- Polycystic ovaries (by ultrasound).

The ultrasound criterion for defining polycystic ovarian morphology is the presence of 12 or more follicles in each ovary measuring 2–9 mm in diameter and/or increased ovarian volume (>10 ml; calculated using the formula 0.5 × length × width × thickness). One ovary fitting this definition is sufficient to define PCOS.

A Urinary cortisol levels

The typical physical signs of Cushing syndrome, such as facial plethora, round face, abdominal striae, dorsal fat pad and easy bruising (ecchymoses), have not been described in this case. Screening tests would be one of the following:

Audio Video Share Participants More

2:01
On
594-042-7551
Leave

A 70-year-old woman presents to the Accident and Emergency Department with thirst, polyuria and constipation. Her family also feel that she has been depressed over the last few weeks, which is unusual for her. Examination is unremarkable apart from generalised abdominal tenderness and a scar noted on the left breast from a previous lumpectomy for breast carcinoma.

Investigations:

Urea	10.0 mmol/l
Creatinine	100 µmol/l
Sodium	133 mmol/l
Potassium	4.0 mmol/l
Corrected calcium	3 .84 mmol/l
Plasma parathyroid hormone (PTH) levels	0.8 pmol/l (0.9–5.4)

Which single initial management choice would be most appropriate from the list below?

A IV fluids

B Oral furosemide

C IV steroids

D IV pamidronate

E Denosumab

Audio
Video
Share
Participants
More

Explanation

A IV fluids

The initial diagnosis here is hypercalcaemia, which can cause severe gastrointestinal disturbance. Serum levels >3.5 mmol/l are associated with cardiac arrhythmias, coma and pancreatitis and urgent treatment is required. The low parathyroid hormone precludes parathyroid disease as a cause, and in this age group (particularly with a previous malignancy) metastatic bone disease would be high on a list of differential diagnoses.
Hypercalcaemia is often associated with severe dehydration that increases the risk of renal damage. The bisphosphonate pamidronate is the treatment of choice to reduce osteoclast activity and hence bone resorption of calcium, but should always be preceded by aggressive rehydration to prevent renal tubular damage. In the case described here, these would therefore be used as a next step following IV fluids.

B Oral furosemide

In cases of hypercalcaemia, furosemide is not routinely recommended in the Society for Endocrinology Guidelines, and it should only be given with fluid resuscitation if there is evidence of ventricular strain and pulmonary oedema.

C IV steroids

Prednisolone is used to treat hypercalcaemia associated with sarcoid.

D IV pamidronate

Pamindronate is a bisphosphonate used in the acute

8:32

A 38-year-old South-Asian man is referred to the outpatient clinic. He is currently undergoing treatment for tuberculosis, which is known to involve the renal tracts in this case. Only other past history of note is hypertension, for which he takes ramipril 10 mg daily. The infectious disease doctor has referred him to you because of some abnormal tests:

TSH	6.5 mU/l (0.4-5.0)
Free T4	8.4 pmol/l (10-22)
K^+	5.9 mmol/l
Na^+	131 mmol/l
CT scan	Adrenal calcification

His blood pressure in the clinic is actually low with a systolic of 100 mmHg.

Which of the following actions would be most appropriate in this case?

A Commence 50 mcg thyroxine/day

B Check anti-TPO antibodies

C Arrange a short synacthen test

D Commence fludrocortisone 100mcg/day

E Check anti-adrenal antibodies

18547

Submit

Rana Alnasser's screen

A 38-year-old South-Asian man is referred to the outpatient clinic. He is currently undergoing treatment for tuberculosis, which is known to involve the renal tracts in this case. Only other past history of note is hypertension, for which he takes ramipril 10 mg daily. The infectious disease doctor has referred him to you because of some abnormal tests:

TSH	6.5 mU/l (0.4-5.0)
Free T4	8.4 pmol/l (10-22)
K^+	5.9 mmol/l
Na^+	131 mmol/l
CT scan	Adrenal calcification

His blood pressure in the clinic is actually low with a systolic of 100 mmHg.

Which of the following actions would be most appropriate in this case?

Your answer was correct

A Commence 50 mcg thyroxine/day

B Check anti-TPO antibodies

C Arrange a short synacthen test

D Commence fludrocortisone 100mcg/day

E Check anti-adrenal antibodies

Explanation

C Arrange a short synacthen test

This man is not acutely unwell and you have time to confirm the diagnosis of hypoadrenalism with a short synacthen test. If this is positive then you would consider commencing hydrocortisone replacement. The low BP, coupled with the low sodium and raised potassium, raise the suspicion of hypoadrenalism in this case.

A Commence 50 mcg thyroxine/day

His thyroid function tests are abnormal, but you would not commence thyroid hormone replacement at this stage. Commencing thyroxine in a patient with hypoadrenalism may precipitate a rapid deterioration in their condition. It would be most important to confirm the diagnosis of adrenal insufficiency, commence steroid hormone replacement and then re-check the thyroid function testing later.

B Check anti-TPO antibodies

Autoimmune thyroid dysfunction is commonly associated with Addison's. Although the suspicion is that this patient is hypo-adrenal, this is likely to be secondary to TB rather than an autoimmune cause.

D Commence fludrocortisone 100mcg/day

Fludrocortisone replacement is not normally required in the acute stage in the treatment of hypoadrenalism, but can be added once the dose of hydrocortisone is reduced after a few days.

E Check anti-adrenal antibodies

commencing hydrocortisone replacement. The low BP, coupled with the low sodium and raised potassium, raise the suspicion of hypoadrenalism in this case.

A Commence 50 mcg thyroxine/day

His thyroid function tests are abnormal, but you would not commence thyroid hormone replacement at this stage. Commencing thyroxine in a patient with hypoadrenalism may precipitate a rapid deterioration in their condition. It would be most important to confirm the diagnosis of adrenal insufficiency, commence steroid hormone replacement and then re-check the thyroid function testing later.

B Check anti-TPO antibodies

Autoimmune thyroid dysfunction is commonly associated with Addison's. Although the suspicion is that this patient is hypo-adrenal, this is likely to be secondary to TB rather than an autoimmune cause.

D Commence fludrocortisone 100mcg/day

Fludrocortisone replacement is not normally required in the acute stage in the treatment of hypoadrenalism, but can be added once the dose of hydrocortisone is reduced after a few days.

E Check anti-adrenal antibodies

Adrenal antibody testing can be extremely helpful in elucidating the cause of suspected adrenal failure. The adrenal calcification suggests the possibility of tuberculosis infection, so that anti-adrenal antibodies are unlikely to be helpful here.

Rana Alnasser's screen

8:34

A 65-year-old woman who is known to suffer from chronic lymphocytic leukaemia is brought to the Emergency Department by her partner. For the past few weeks she has been suffering increasing proximal myopathy and bony pain, predominantly affecting the long bones of the arms and legs. Blood testing reveals profoundly low phosphate levels. Urine testing reveals the presence of glycosuria, although serum glucose is unremarkable.

What diagnosis fits best with this clinical picture?

A	X-linked hypophosphataemia
B	Tumour lysis syndrome
C	Hypoparathyroidism
D	Oncogenic osteomalacia
E	Hyperparathyroidism

Submit

Previous Q... Skip Questi...

© Pastest 2019

Rana Alnasser's screen

A 65-year-old woman who is known to suffer from chronic lymphocytic leukaemia is brought to the Emergency Department by her partner. For the past few weeks she has been suffering increasing proximal myopathy and bony pain, predominantly affecting the long bones of the arms and legs. Blood testing reveals profoundly low phosphate levels. Urine testing reveals the presence of glycosuria, although serum glucose is unremarkable.

What diagnosis fits best with this clinical picture?

Your answer was correct

A	X-linked hypophosphataemia
B	Tumour lysis syndrome
C	Hypoparathyroidism
D	Oncogenic osteomalacia
E	Hyperparathyroidism

Explanation

D	Oncogenic osteomalacia

Certain tumours, including mesenchymal tumours, adenocarcinomas (e.g. prostatic carcinoma) and haematological malignancies such as myeloma and chronic lymphocytic leukaemia, appear to produce a phosphaturic substance. Clinically, patients present with bone pain and/or fracture, profound proximal myopathy and severe hypophosphataemia, usually accompanied by a marked reduction in concentration of 1,25-OH vitamin D. Other

8:38
594-042-7551 Leave

A 62-year-old man is admitted with confusion. He has a background of chronic obstructive pulmonary disease and is on home nebulisers and oxygen. His relatives have noticed increased breathlessness and vomiting, which has meant he has been unable to keep down his rescue course of prednisolone.

General examination reveals skin bruises and dry mucous membranes. Other past history of note includes treated hypothyroidism. On chest auscultation, there are bibasal inspiratory crepitations with prolonged expiratory wheeze. His pulse is 78/min, blood pressure 85/54 mmHg, temperature 37.5 °C. Chest radiography shows chronic obstructive airways changes and an electrocardiogram (ECG) shows sinus rhythm.

Investigations:

Hb	13.2 g/dl
WCC	14×10^9/l
PLT	470×10^9/l
Na^+	125 mmol/l
K^+	5.3 mmol/l
Urea	17.2 mmol/l
Creatinine	130 µmol/l
Glucose	2.8 mmol/l

You give him a bolus of IV glucose and start IV fluid replacement with normal saline.

Which of the following is the next best immediate management step?

A IV hydrocortisone

Audio Video Share Participants More

inspiratory crepitations with prolonged expiratory wheeze. His pulse is 78/min, blood pressure 85/54 mmHg, temperature 37.5 °C. Chest radiography shows chronic obstructive airways changes and an electrocardiogram (ECG) shows sinus rhythm.

Investigations:

Hb	13.2 g/dl
WCC	14×10^9/l
PLT	470×10^9/l
Na^+	125 mmol/l
K^+	5.3 mmol/l
Urea	17.2 mmol/l
Creatinine	130 μmol/l
Glucose	2.8 mmol/l

You give him a bolus of IV glucose and start IV fluid replacement with normal saline.

Which of the following is the next best immediate management step?

A IV hydrocortisone

B IV antibiotics

C IV calcium gluconate

D Oral calcium resonium

E IV aminophylline

8:39

A IV hydrocortisone

Acute adrenal insufficiency in this patient is most likely due to a chest infection and prior suppression of the adrenocortical axis by exogenous steroids. Patients present with hypotension and confusion. Examination may reveal evidence of prior treatment with steroids. Biochemistry shows hyponatraemia, hyperkalaemia, hypoglycaemia and an increased urea. Treatment includes correction of hypoglycaemia, administration of glucocorticoids and adequate hydration.

B IV antibiotics

Whilst these may be appropriate, antibiotics should follow corticosteroids in this case in terms of urgency given the significant electrolyte disturbance and hypotension.

C IV calcium gluconate

Potassium is towards the upper end of the normal range and is likely to fall rapidly as a result of rehydration and initiation of corticosteroid therapy.

D Oral calcium resonium

Calcium resonium is unpleasant to take and is not required here, because potassium will almost certainly fall once fluid replacement and steroid therapy is initiated. Its main use is in the management of hyperkalaemia occurring as a result of acute on chronic kidney disease.

E IV aminophylline

IV aminophylline use is not encouraged in acute exacerbations of COPD because of the high risk of atrial arrhythmias; it may be used in cases where other options

Rana Alnasser's screen

8:39

A 54-year-old Asian man with a 7-year history of type 2 diabetes has been diagnosed with background diabetic retinopathy at his annual review. He was also recently admitted to hospital with an episode of cardiac failure after an anterior myocardial infarction. He is taking gliclazide 80 mg bd as he failed to tolerate metformin. His BMI is elevated at 35. Recent Hb A_{1C} was 7.1%, blood pressure (BP) 154/85, proteinuria +; and total cholesterol 5.4 mmol/l with HDL 0.7 mmol/l.

You are considering switching his blood glucose-lowering medication because of recent weight gain.

Which of the following is the most appropriate switch therapy with respect to overall cardiovascular risk in this patient?

A Insulin

B Empagliflozin

C Lixisenatid

D Saxagliptin

E Sitagliptin

6544

Submit

Previous Q... Skip Questi...

Rana Alnasser's screen

8:40
594-042-7551 Leave

A 54-year-old Asian man with a 7-year history of type 2 diabetes has been diagnosed with background diabetic retinopathy at his annual review. He was also recently admitted to hospital with an episode of cardiac failure after an anterior myocardial infarction. He is taking gliclazide 80 mg bd as he failed to tolerate metformin. His BMI is elevated at 35. Recent Hb A_{1C} was 7.1%, blood pressure (BP) 154/85, proteinuria +; and total cholesterol 5.4 mmol/l with HDL 0.7 mmol/l.

You are considering switching his blood glucose-lowering medication because of recent weight gain.

Which of the following is the most appropriate switch therapy with respect to overall cardiovascular risk in this patient?

Your answer was correct

A Insulin

B Empagliflozin

C Lixisenatid

D Saxagliptin

E Sitagliptin

Explanation

B Empagliflozin

Blood glucose-lowering medications in the GLP-1 and SGLT2 inhibitor class have been shown to reduce the risk of major adverse cardiovascular events (MACE). As such, empagliflozin, which causes glucose excretion and can

Audio Video Share Participants More

8:40
594-042-7551 Leave

Explanation

B Empagliflozin

Blood glucose-lowering medications in the GLP-1 and SGLT2 inhibitor class have been shown to reduce the risk of major adverse cardiovascular events (MACE). As such, empagliflozin, which causes glucose excretion and can have positive effects on weight, reduces cardiovascular death and incident cardiac failure, is the most appropriate choice.

A Insulin

Insulin has no effect in reducing cardiovascular risk, and indeed may increase the risk of heart failure in patients with type 2 diabetes. As such, it is best avoided here.

C Lixisenatid

Although liraglutide has shown a positive effect on MACE, lixisenatide has not shown an impact on MACE events in a secondary prevention type 2 diabetes population.

D Saxagliptin

Saxagliptin showed no positive impact on MACE events, although its use was associated with a small increase in cardiac failure episodes during the course of a cardiovascular outcome trial.

E Sitagliptin

Sitagliptin shows no positive impact on MACE events, although unlike saxagliptin the use of sitagliptin did not increase the risk of cardiac failure in the context of its cardiovascular outcome trial.

Audio Video Share Participants More

8:42

A 37-year-old man with a 30-year history of type 1 diabetes comes to the clinic for review. He takes a basal bolus insulin regime of 22 units of long-acting insulin (Insulotard®) per day and 6 units of short-acting insulin (Actrapid®) with each meal.

His main problem is unpredictable hypoglycaemic episodes, which occur during the day, normally a few hours after each meal. He has peripheral neuropathy affecting the soles of both feet, but is otherwise well.

Examination reveals a BP of 105/80 mmHg, with pulse 70/min and regular. His BMI is 21.

Investigations:

Hb	13.2 g/dl
WCC	7.1×10^9/l
PLT	199×10^9/l
Na^+	137 mmol/l
K^+	4.4 mmol/l
Creatinine	102 µmol/l
Glucose	6.1 mmol/l
HbA1c	53 mmol/mol (7.0%)

Which of the following is the most appropriate next step?

A Arrange a 72 continuous glucose monitor recording

B Change the Insulotard® to insulin glargine

C Reduce the dose of the Actrapid®

D Reduce the dose of Insulotard®

Rana Alnasser's screen

His main problem is unpredictable hypoglycaemic episodes, which occur during the day, normally a few hours after each meal. He has peripheral neuropathy affecting the soles of both feet, but is otherwise well.

Examination reveals a BP of 105/80 mmHg, with pulse 70/min and regular. His BMI is 21.

Investigations:

Hb	13.2 g/dl
WCC	7.1×10^9/l
PLT	199×10^9/l
Na^+	137 mmol/l
K^+	4.4 mmol/l
Creatinine	102 µmol/l
Glucose	6.1 mmol/l
HbA1c	53 mmol/mol (7.0%)

Which of the following is the most appropriate next step?

A	Arrange a 72 continuous glucose monitor recording
B	Change the Insulotard® to insulin glargine
C	Reduce the dose of the Actrapid®
D	Reduce the dose of Insulotard®
E	Refer for Dose Adjustment for Normal Eating (DAFNE) education.

E Refer for Dose Adjustment for Normal Eating (DAFNE) education.

In this situation it is possible that the patient has never been educated about matching short-acting insulin to the carbohydrates consumed with the meal. In the first instance he is likely to benefit from DAFNE education, teaching him to take appropriate short-acting insulin for the meal he has eaten. Reducing the dose of his insulin is likely to lead to deterioration in his glycaemic control.

B Change the Insulotard® to insulin glargine

This is more likely to impact on fasting hypoglycaemia during the overnight period, rather than daytime hypo episodes.

A Arrange a 72 continuous glucose monitor recording

Although continuous glucose monitoring may elucidate the daytime hypoglycaemia episodes, it won't initiate the change in behaviour which is driven by DAFNE education.

C Reduce the dose of the Actrapid®

A blanket reduction in the dose of Actrapid® is likely to drive hyperglycaemia; as such, it should be avoided here if possible.

D Reduce the dose of Insulotard®

This would have most impact on nocturnal rather than daytime hypoglycaemia.

Rate this question:

A 54-year-old woman presents to her general practitioner (GP) complaining of thirst and lethargy. She has been feeling unwell for some time, and is now suffering from an erythematous rash that began on her groin but has now spread to involve the buttocks, lower limbs and perineum. Her GP read in a dermatology text that the rash may be necrolytic migratory erythema (NME). There is associated glossitis and vaginitis. Fasting blood glucose is raised, at 8.1 mmol/l. On further questioning she admits to weight loss of a few kilograms over the past few months.

What would be the most useful investigation in this patient?

A Insulin level

B Glucagon level

C Somatostatin level

D Oral glucose tolerance test

E Insulin tolerance test

Submit

8:48

Explanation

B Glucagon level

This lady has diabetes mellitus, with the characteristic rash of necrolytic migratory erythema. Therefore, her diabetes may be secondary to a glucagonoma. Glucagonomas are extremely rare, with an annual incidence estimated at 1/20 million. Diagnosis is confirmed on finding raised plasma glucagon levels. Most primary tumours are >3 cm in diameter, 70% are malignant in nature and more than 50% have metastasised at the time of diagnosis. Tumour localisation is usually possible with abdominal ultrasound and/or computerised tomography (CT); where tumours are small, or metastatic spread is being assessed, octreotide scanning may be utilised. The potential for surgical cure is only 5%; octreotide is useful for controlling the rash, although its effects on associated diabetes and weight loss are more variable. Palliative chemotherapy using streptozocin and fluorouracil does produce acceptable reductions of glucagon over a 1-year period. Selective tumour embolisation via the hepatic artery may be of additional value.

A Insulin level

Insulin levels are most useful in assessment of hypoglycaemia, checked in conjunction with a c-peptide and glucose at the time of an episode. In insulinoma elevated insulin and c-peptide are seen with a low blood glucose.

C Somatostatin level

Although a somatostatinoma may be associated with the development of impaired glucose tolerance, it is not associated with the characteristic skin rash of glucagonoma seen here.

Rana Alnasser's screen

Insulin levels are most useful in assessment of hypoglycaemia, checked in conjunction with a c-peptide and glucose at the time of an episode. In insulinoma elevated insulin and c-peptide are seen with a low blood glucose.

C Somatostatin level

Although a somatostatinoma may be associated with the development of impaired glucose tolerance, it is not associated with the characteristic skin rash of glucagonoma seen here.

D Oral glucose tolerance test

This will merely confirm the diagnosis of diabetes mellitus without elucidating the underlying cause.

E Insulin tolerance test

Insulin tolerance testing is used in the evaluation of patients with growth hormone deficiency.

Rate this question:

Next Question

Previous Q... Tag Questi... Feedback End Session

Blog About Pastest Contact Us Help

© Pastest 2019

8:50

Google

necrolytic migratory erythema

ALL IMAGES NEWS VIDEOS MAPS SHOPPING BOOKS FLI

Latest GIF HD Product

glucagonoma usmle mild histology

Necrolytic Migratory Erythema | NEJM
nejm.org

Necrolytic migratory erythema | Primary ...
pcds.org.uk

Necrolytic Migratory Erythema
medscape.com

Necrolytic Migratory Erythema: The ...
jamanetwork.com

necrolytic migratory erythema ...
semanticscholar.org

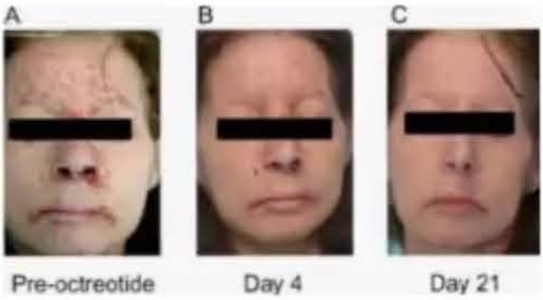

necrolytic migratory erythema ...
researchgate.net

Discover Updates Search Rece

8:50

The Primary Care Dermatology Society

Necrolytic migratory erythema | Primary Care Dermatology S

Download. Figure: 1. Necrolytic migratory erythema

Images may be subject to copyright. Learn more

RELATED IMAGES

Doctors Gates: Mucocutaneous Manifestatio...
doctorsgates.blogspot.com

Necr
nejm

Discover Updates Search Rece

8:50

MyPastest
https://mypastest.pastest.com

Pastest+

You are in a Medical Outpatients Clinic seeing a 53-year-old woman. She is hypertensive and has been treated with atenolol for the last 2 years.

While in the clinic, she asks your advice regarding the use of hormone replacement therapy (HRT). She suspects that she is menopausal due to hot flushes, mood swings and lack of periods for the last 5 months.

She has no past medical history of thromboembolism, stroke or breast cancer. However, having read conflicting results about HRT in the press, she is concerned about the risk of deep venous thrombosis (DVT) and heart disease.

Which of the following statements is correct with respect to HRT (combined oestrogen–progestin therapy)?

A	HRT reduces the risk of coronary artery disease
B	HRT has a protective effect on the risk of DVT
C	Risk of strokes is reduced by HRT
D	Risk of DVT is 2–4 times higher in women on HRT
E	HRT has no effect on the risk of DVT

2512

Submit

Rana Alnasser's screen

8:52

D Risk of DVT is 2–4 times higher in women on HRT

The WHI is the largest available clinical trial on HRT. It was stopped after 5 years – 3 years early – because it revealed increased dangers. Older age and obesity added to the risk associated with a regimen of oestrogen plus progestin. Thinner and younger women were at a low absolute risk of DVT, although their risk was still twofold higher among women taking oestrogen plus progestin, compared with women taking placebo.

A HRT reduces the risk of coronary artery disease

Clinical trial evidence from the Heart and Oestrogen/Progestin Replacement Study (HERS) and the Women's Health Initiative (WHI) have shown that oestrogen therapy, with or without progestin, is associated with an increased risk of DVT.

B HRT has a protective effect on the risk of DVT

HERS has shown no reduced risk of coronary artery disease in women taking HRT.

C Risk of strokes is reduced by HRT

The WHI has shown that the risk of having an ischaemic stroke is increased in those taking HRT due to an increased risk of blood clotting.

Scroll capture Draw Crop

4 times in those taking HRT.

Rana Alnasser's screen

8:52
594-042-7551 Leave

A 32-year-old man presents for review. He has told his general practitioner (GP) that he consumes up to 8 or 9 l of drinks per day and is constantly up during the night and day to pass urine. The GP has checked some routine bloods; a fasting blood sugar is 3.4 mmol/l. You arrange a water deprivation test:

Maximal serum osmolality after fluid deprivation	290 mOsmol/kg (278–300)
Urine osmolality after fluid deprivation	830 mOsmol/kg (>750)
Urine osmolality after desmopressin	841 mOsmol/kg (>750)

What diagnosis fits best with this clinical picture?

A Cranial diabetes insipidus (DI)

B Primary polydipsia

C Nephrogenic DI

D Partial nephrogenic DI

E Hyporeninaemic hyperaldosteronism

Submit

Audio Video Share Participants More

8:53
594-042-7551
Leave

B Primary polydipsia

Results of the fluid deprivation test are crucial in determining the correct diagnosis here. In this test, patients are deprived of fluids for a period of 8 h or until 5% of body weight is lost. Patients should be weighed hourly. Plasma osmolality is measured 4-hourly, with urine volume and osmolality measurements occurring every 2 h. The patient is then given 2 μg intramuscular (i/m) desmopressin, with urine volume and urine and serum osmolality measured over the next 4 h. Where urine osmolality reaches levels >800 mOsmol/kg without desmopressin, then the diagnosis is primary polydipsia. This patient should be offered behavioural advice about slowly reducing his fluid intake.

A Cranial diabetes insipidus (DI)

If serum osmolality rises above 305 mOsmol/kg in the water deprivation test, then the patient is said to have DI and the test is stopped. Urine osmolality <300 mOsmol/kg after fluid deprivation, rising to >800 mOsmol/kg after desmopressin, indicates cranial DI.

C Nephrogenic DI

Urine osmolality <300 mOsmol/kg in the water deprivation test, remaining at <300 mOsmol/kg after desmopressin, indicates nephrogenic DI.

D Partial nephrogenic DI

Where urine osmolality at the end of the water deprivation test is intermediate (300–800 mOsmol/kg), and fails to rise above 800 mOsmol/kg after desmopressin, the diagnosis may be partial DI or polydipsia.

Audio Video Share Participants More

8:54

A 49-year-old man with a history of diabetes mellitus and hypertension is referred to the Endocrine Clinic. Most recently, he has noticed swelling of his hands and is unable to keep his wedding ring on. His brother also visited from Australia, and thought that his appearance had changed a little.

Medication includes ramipril 10 mg daily, amlodipine 10 mg daily, metformin 1 g BD and gliclazide 160 mg BD. On examination he has soft tissue swelling of his hands and a prominent lower jaw. He is hypertensive, with a BP of 162/90 mmHg.

Investigations:

Hb	13.9 g/dl
WCC	4.6×10^9/l
PLT	200×10^9/l
Na^+	140 mmo/l
K^+	4.8 mmol/l
Creatinine	155 µmol/l
HbA1c	68.31 mmol/mol (8.4%)

You arrange for him to undergo a 75 g oral glucose tolerance test. You look at the low point reached in terms of growth hormone level during the test.

Immunoradioassay reveals a growth hormone level of 1.6 mcg/l and you diagnose a growth hormone-producing adenoma. He progresses to surgery, but he then presents 1 year later with a raised IGF-1 level. His diabetes control has worsened a little and again his blood pressure is proving difficult to control.

Which of the following would be the most appropriate option for first-line medical therapy for him?

Rana Alnasser's screen

Hb	13.9 g/dl
WCC	4.6×10^9/l
PLT	200×10^9/l
Na^+	140 mmo/l
K^+	4.8 mmol/l
Creatinine	155 µmol/l
HbA1c	68.31 mmol/mol (8.4%)

You arrange for him to undergo a 75 g oral glucose tolerance test. You look at the low point reached in terms of growth hormone level during the test.

Immunoradioassay reveals a growth hormone level of 1.6 mcg/l and you diagnose a growth hormone-producing adenoma. He progresses to surgery, but he then presents 1 year later with a raised IGF-1 level. His diabetes control has worsened a little and again his blood pressure is proving difficult to control.

Which of the following would be the most appropriate option for first-line medical therapy for him?

A Selegeline

B Bromocriptine

C Somatostatin analogue

D Pegvisomant

E Pergolide

E Pergolide

Explanation

C Somatostatin analogue

Dopamine agonists are somewhat less effective in the treatment of acromegaly than they are in the treatment of hyperprolactinaemia. For this reason, somatostatin analogues are considered first-line medical therapy. Treatment failures may be considered for pegvisomant, a growth hormone antagonist. Indeed, pegvisomant may be more suitable for patients with particularly marked features of hyperinsulinaemia, as in this gentleman, but currently it is considered a choice only for those who have failed therapy with a somatostatin analogue.

A Selegeline

Selegiline, at normal clinical doses, is a selective irreversible MAO-B inhibitor. In larger doses, it loses its specificity and also inhibits MAO-A. It is available in tablet form and is used to reduce symptoms in early-stage Parkinson's disease. A transdermal patch is used to treat depression.

B Bromocriptine

It is a dopamine agonist and the alternative to cabergoline as first-line treatment for prolactin-secreting pituitary adenomas.

D Pegvisomant

Pegvisomant is a growth hormone receptor antagonist used in the treatment of acromegaly. It is primarily used if the pituitary gland tumour causing the acromegaly cannot

Selegiline, at normal clinical doses, is a selective irreversible MAO-B inhibitor. In larger doses, it loses its specificity and also inhibits MAO-A. It is available in tablet form and is used to reduce symptoms in early-stage Parkinson's disease. A transdermal patch is used to treat depression.

B Bromocriptine

It is a dopamine agonist and the alternative to cabergoline as first-line treatment for prolactin-secreting pituitary adenomas.

D Pegvisomant

Pegvisomant is a growth hormone receptor antagonist used in the treatment of acromegaly. It is primarily used if the pituitary gland tumour causing the acromegaly cannot be controlled with surgery or radiation, and the use of somatostatin analogues is unsuccessful, but is also effective as a monotherapy.

E Pergolide

Pergolide is an ergoline-based dopamine receptor agonist used in some countries for the treatment of Parkinson's disease (PD). PD is associated with reduced dopamine activity in the substantia nigra of the brain. Pergolide acts on many of the same receptors as dopamine to increase receptor activity.

A 50-year-old gentleman with a past history of atrial fibrillation and periods of paroxysmal ventricular tachycardia on 24hr tape,is referred to the outpatient clinic with weight loss and tremor. He is clinically hyperthyroid. He takes warfarin and amiodarone.

Blood results are as follows:

Thyroxine (T_4)	100 nmol/l
Thyroid-stimulating hormone (TSH)	<0.01 mu/l

A colour flow Doppler ultrasound of his thyroid shows increased blood flow.

What would be the preferred next management step?

A	Stop amiodarone
B	Start prednisolone 30 mg OD and carbimazole 40 mg OD
C	Start carbimazole 40 mg OD
D	Arrange a thyroidectomy
E	Arrange radioiodine therapy

9393

Submit

Previous Q... Skip Questi...

A 50-year-old gentleman with a past history of atrial fibrillation and periods of paroxysmal ventricular tachycardia on 24hr tape,is referred to the outpatient clinic with weight loss and tremor. He is clinically hyperthyroid. He takes warfarin and amiodarone.

Blood results are as follows:

Thyroxine (T_4)	100 nmol/l
Thyroid-stimulating hormone (TSH)	<0.01 mu/l

A colour flow Doppler ultrasound of his thyroid shows increased blood flow.

What would be the preferred next management step?

Your answer was incorrect

A Stop amiodarone

B Start prednisolone 30 mg OD and carbimazole 40 mg OD

C Start carbimazole 40 mg OD

D Arrange a thyroidectomy

E Arrange radioiodine therapy

Explanation

C Start carbimazole 40 mg OD

This is an example of type 1 amiodarone-induced hyperthyroidism (AIT). The high iodine content of the

C Start carbimazole 40 mg OD

This is an example of type 1 amiodarone-induced hyperthyroidism (AIT). The high iodine content of the amiodarone induces release of thyroid hormone (Jod-Basedow effect) and causes hyperthyroidism. In type 2 AIT the amiodarone causes a destructive thyroiditis. Colour flow Doppler ultrasound can be used to differentiate the two: blood flow is increased in type 1 and decreased in type 2. High-dose anti-thyroid drugs are needed to treat type 1 AIT as they have less effect due to the high iodine load.

B Start prednisolone 30 mg OD and carbimazole 40 mg OD

Steroids in combination with anti-thyroid drugs help to treat type 2 AIT. However, these have no role in type 1 AIT.

A Stop amiodarone

Amiodarone should be discontinued if possible, but in this case, given the VT, this decision should be considered carefully in conjunction with a cardiologist. Withdrawal of amiodarone alone will have no immediate effect due to the long half-life of amiodarone.

D Arrange a thyroidectomy

Thyroidectomy is rarely recommended as first-line treatment for thyrotoxicosis. Thyroidectomy in a thyrotoxic patient may precipitate thyroid storm.

E Arrange radioiodine therapy

Radioiodine is not usually effective because of reduced uptake by the thyroid due to high iodine levels.

8:58

A 60-year-old woman has been referred to the Endocrine Clinic with a history of increasing shoe size and problems with her dentures fitting. She also complains of flushing and sweating.

Routine blood testing at the initial clinic appointment confirms an elevated random blood glucose and an elevated IGF-1. Because of a suspected diagnosis of acromegaly, an oral glucose tolerance test with growth hormone is performed as well as a gadolinium-enhanced magnetic resonance image (MRI) of the pituitary. She attends for review after the tests have been performed.

The results of the oral glucose tolerance test are as follows:

Time (min)	Growth hormone (GH) (mU)
0	8
30	8 (elevated)
60	7
90	8
120	9
180	9

The gadolinium-enhanced MRI of the pituitary is reported as not showing an adenoma, although the pituitary appears slightly enlarged overall.

Which step would you take next to best manage her case?

A Arginine test

B CT of the chest and abdomen

C Refer for transphenoidal hypophysectomy

Rana Alnasser's screen

magnetic resonance image (MRI) of the pituitary. She attends for review after the tests have been performed.

The results of the oral glucose tolerance test are as follows:

Time (min)	Growth hormone (GH) (mU)
0	8
30	8 (elevated)
60	7
90	8
120	9
180	9

The gadolinium-enhanced MRI of the pituitary is reported as not showing an adenoma, although the pituitary appears slightly enlarged overall.

Which step would you take next to best manage her case?

A Arginine test

B CT of the chest and abdomen

C Refer for transphenoidal hypophysectomy

D Insulin tolerance test

E Inferior petrosal vein sampling

32891

Submit

Rana Alnasser's screen

9:02
594-042-7551
Leave

A 60-year-old woman has been referred to the Endocrine Clinic with a history of increasing shoe size and problems with her dentures fitting. She also complains of flushing and sweating.

Routine blood testing at the initial clinic appointment confirms an elevated random blood glucose and an elevated IGF-1. Because of a suspected diagnosis of acromegaly, an oral glucose tolerance test with growth hormone is performed as well as a gadolinium-enhanced magnetic resonance image (MRI) of the pituitary. She attends for review after the tests have been performed.

The results of the oral glucose tolerance test are as follows:

Time (min)	Growth hormone (GH) (mU)
0	8
30	8 (elevated)
60	7
90	8
120	9
180	9

The gadolinium-enhanced MRI of the pituitary is reported as not showing an adenoma, although the pituitary appears slightly enlarged overall.

Which step would you take next to best manage her case?

Your answer was incorrect

A Arginine test

B CT of the chest and abdomen

Audio Video Share Participants More

9:02
594-042-7551 Leave

Explanation

B CT of the chest and abdomen

The oral glucose tolerance test shows non-suppression of GH secretion, with the 75 g glucose load indicating the diagnosis of acromegaly. However, the magnetic resonance image (MRI) of the pituitary shows no adenoma, which is unusual. This raises the possibility of other causes of acromegaly. The patient complains of flushing, which is a symptom of carcinoid syndrome. Carcinoid tumours can rarely produce GH-releasing hormone (GhRH), causing pituitary hyperplasia and acromegaly. CT of the chest and abdomen would be used to look for a carcinoid tumour, and chromogranin A, also known as parathyroid secretory hormone 1, is a serum marker for carcinoid tissue.

E Inferior petrosal vein sampling

Inferior petrosal vein sampling is useful to localise a source of elevated ACTH. Given the MRI shows no adenoma, this is unlikely to be a useful step.

A Arginine test

Administration of arginine promotes GH release and is therefore used in the evaluation of GH deficiency.

C Refer for transphenoidal hypophysectomy

Without a discrete adenoma, pituitary surgery is not indicated here.

D Insulin tolerance test

Like the arginine test, the insulin tolerance test is used in evaluation of growth hormone deficiency, and therefore has no role here. Its use has also fallen off in recent years

Audio Video Share Participants More

9:03
594-042-7551 Leave

C Inferior petrosal vein sampling

Inferior petrosal vein sampling is useful to localise a source of elevated ACTH. Given the MRI shows no adenoma, this is unlikely to be a useful step.

A Arginine test

Administration of arginine promotes GH release and is therefore used in the evaluation of GH deficiency.

C Refer for transphenoidal hypophysectomy

Without a discrete adenoma, pituitary surgery is not indicated here.

D Insulin tolerance test

Like the arginine test, the insulin tolerance test is used in evaluation of growth hormone deficiency, and therefore has no role here. Its use has also fallen off in recent years due to significant risk of serious hypoglycaemia.

Rate this question:

Next Question

© Pastest 2019

Audio Video Share Participants More

9:03

A 23-year-old woman is referred to the clinic by the Emergency department, having been admitted after fainting in the local supermarket. On further questioning it transpires that she has been feeling weak and washed out for quite some time. On examination, her BP is 105/60 mmHg, pulse is 75/min. Her BMI is 18. She has calluses on her knuckles, but tells you these are due to her job as a landscape gardener.

Investigations:

Hb	10.9 g/dl
WCC	5.0×10^9/l
PLT	194×10^9/l
Na^+	140 mmol/l
K^+	3.3 mmol/l
Creatinine	115 µmol/l
Urinary K^+	0.7 mmol/l (25–100/24 h)

Which of the following is the most likely diagnosis?

A Bartter syndrome

B Liddle syndrome

C Diuretic abuse

D Laxative abuse

E Conn syndrome

21453

Rana Alnasser's screen

Submit

mmHg, pulse is 75/min. Her BMI is 18. She has calluses on her knuckles, but tells you these are due to her job as a landscape gardener.

Investigations:

Hb	10.9 g/dl
WCC	5.0×10^9/l
PLT	194×10^9/l
Na^+	140 mmol/l
K^+	3.3 mmol/l
Creatinine	115 µmol/l
Urinary K^+	0.7 mmol/l (25–100/24 h)

Which of the following is the most likely diagnosis?

Your answer was correct

A Bartter syndrome

B Liddle syndrome

C Diuretic abuse

D Laxative abuse

E Conn syndrome

Explanation

D Laxative abuse

This woman is underweight and has symptoms of fatigue

D Laxative abuse

This woman is underweight and has symptoms of fatigue which are consistent with hypokalaemia. The fact that she is underweight with a BMI of 18, and has calluses on her knuckles, may point towards induced vomiting and a diagnosis of bulimia, which would fit with possible laxative abuse. Laxative abuse leads to increased GI potassium loss and renal conservation of potassium, a urinary concentration of potassium of <1 mmol/l being highly suggestive of laxative abuse. Urine screening exists for a range of possible laxatives, and the patient should be consented for a urinary laxative screen with appropriate counselling.

A Bartter syndrome

This is an autosomal recessive renal tubular disorder characterised by hypokalaemia, hypochloraemia, metabolic alkalosis and hyper-reninaemia with normal blood pressure. Urinary potassium excretion is high due to the inability of the kidneys to retain potassium.

B Liddle syndrome

This is a rare hereditary disorder involving increased activity of the epithelial sodium channel (ENaC) which causes the kidneys to excrete potassium but retain too much sodium and water, leading to hypertension. Symptoms are of hypertension, fluid retention hypokalaemia and metabolic alkalosis. The urinary potassium excretion is high.

C Diuretic abuse

The use of thiazide diuretics leads to hypokalaemia through increased potassium excretion in the urine.

B Liddle syndrome

This is a rare hereditary disorder involving increased activity of the epithelial sodium channel (ENaC) which causes the kidneys to excrete potassium but retain too much sodium and water, leading to hypertension. Symptoms are of hypertension, fluid retention hypokalaemia and metabolic alkalosis. The urinary potassium excretion is high.

C Diuretic abuse

The use of thiazide diuretics leads to hypokalaemia through increased potassium excretion in the urine.

E Conn syndrome

Conn syndrome, or primary hyperaldosteronism, occurs due to excess production of the hormone aldosterone by the adrenal glands, resulting in low renin levels. Around 66% of cases are due to enlargement of both adrenal glands and 33% are due to an adrenal adenoma that produces aldosterone. Most people have hypertension requiring treatment with more than three agents. Primary hyperaldosteronism causes hypernatraemic, hypokalaemic, metabolic alkalosis. The urinary excretion of potassium is high.

Rate this question:

A 50-year-old woman with Graves' disease attends clinic for follow-up of her thyroid status. She is currently taking propranolol and carbimazole. In the clinic she complains of sore eyes and double vision, particularly at extremes of gaze. Examination reveals marked proptosis. Her blood pressure is normal at 122/82, pulse is 60 and regular. She has tried artificial tears and eye patches with no relief.

Which of the following would be the initial treatment of choice to improve the ophthalmopathy?

A	Radioiodine
B	Ibuprofen
C	IV glucocorticoids
D	Surgical decompression
E	Orbital radiotherapy

Submit

© Pastest 2019

9:07
NC
594-042-7551
Leave

C IV glucocorticoids

Graves' disease causes ophthalmopathy with signs of lid lag, lid retraction (related to thyrotoxicosis), proptosis and diplopia (related to Graves' itself). There are usually two phases: an initial inflammatory phase followed by a fibrotic stage. If the symptoms are mild, patients can be managed with lubricants, eye patches and smoking cessation. This lady has active disease (pain, eyelid redness and swelling), which is sight-threatening (exophthalmos, diplopia and loss of colour vision). For sight-threatening dysthyroid optic neuropathy, the initial treatment option is IV glucocorticoids (methylprednisolone 500 mg once weekly and subsequently tapering down).

E Orbital radiotherapy

This is an alternative option to reduce acute orbital inflammation, but it is not recommended for dysthyroid optic

A Radioiodine

Radioiodine is a definitive treatment option for relapsed Graves' thyrotoxicosis. There is concern that radioiodine could exacerbate Graves' ophthalmopathy. Patients with active Graves' ophthalmopathy receiving radioiodine treatment should be offered steroid cover. Radioiodine treatment can safely be given to patients with inactive Graves' ophthalmopathy provided hypothyroidism is avoided.

B Ibuprofen

This is used as first-line treatment for symptom control in cases of subacute thyroiditis.

Audio Video Share Participants More

which is sight-threatening (exophthalmos, diplopia and loss of colour vision). For sight-threatening dysthyroid optic neuropathy, the initial treatment option is IV glucocorticoids (methylprednisolone 500 mg once weekly and subsequently tapering down).

E Orbital radiotherapy

This is an alternative option to reduce acute orbital inflammation, but it is not recommended for dysthyroid optic

A Radioiodine

Radioiodine is a definitive treatment option for relapsed Graves' thyrotoxicosis. There is concern that radioiodine could exacerbate Graves' ophthalmopathy. Patients with active Graves' ophthalmopathy receiving radioiodine treatment should be offered steroid cover. Radioiodine treatment can safely be given to patients with inactive Graves' ophthalmopathy provided hypothyroidism is avoided.

B Ibuprofen

This is used as first-line treatment for symptom control in cases of subacute thyroiditis.

D Surgical decompression

This may be done to decompress the orbit, improve proptosis and address strabismus, but is performed 1-2 weeks after IV glucocorticoids if the response is poor.

Rate this question:

9:11
NC ...
MyPastest
https://mypastest.pastest.com

An 18-year-old man presents to his general practitioner (GP) with recurrent episodes of penile thrush. He has no other significant symptoms indicating hyperglycaemia. A strong family history of type 2 diabetes is noted and the GP arranges to check fasting plasma glucose. Two samples are checked and the laboratory glucose results are 8.1 and 8.2 mmol/l. Urine is negative for ketones. Haemoglobin A1C, also checked by the GP, is elevated at 74 mmol.mol (8.9%). His BMI is 22 and his BP is 105/72.

Which one of the following is the most appropriate initial therapy for this patient?

A Metformin

B Gliclazide

C Sitagliptin

D Basal bolus insulin

E Acarbose

Submit

Rana Alnasser's screen

9:12
NC ...
MyPastest
https://mypastest.pastest.com

An 18-year-old man presents to his general practitioner (GP) with recurrent episodes of penile thrush. He has no other significant symptoms indicating hyperglycaemia. A strong family history of type 2 diabetes is noted and the GP arranges to check fasting plasma glucose. Two samples are checked and the laboratory glucose results are 8.1 and 8.2 mmol/l. Urine is negative for ketones. Haemoglobin A1C, also checked by the GP, is elevated at 74 mmol.mol (8.9%). His BMI is 22 and his BP is 105/72.

Which one of the following is the most appropriate initial therapy for this patient?

Your answer was correct

A Metformin

B Gliclazide

C Sitagliptin

D Basal bolus insulin

E Acarbose

Explanation

B Gliclazide

This man is most likely to have maturity onset of diabetes

Rana Alnasser's screen

9:12

B Gliclazide

This man is most likely to have maturity onset of diabetes of youth 3 (MODY3) due to HNF1-alpha mutation (hepatic nuclear factor-1). MODY3 is the cause of 1–2% of type 2 diabetes and makes up around 70% of MODY cases. It presents most commonly in early adulthood and is associated with severe hyperglycaemia in some cases and frequent microvascular complications. One-third of patients require insulin therapy and around one-third may be controlled on oral hypoglycaemic drugs. Sulphonylureas (SUs) would be the initial drug of choice because, at least for the first few years, the capacity to secrete insulin is preserved and the use of SUs restores insulin release, avoiding the need for insulin therapy. The next commonest MODY variant is MODY 2, which results from a glucokinase mutation leading to altered glucose sensing in pancreatic beta cells. In contrast, 90% of MODY2 patients are controlled on diet therapy alone.

A Metformin

Metformin primarily reduces hepatic glucose output and has minor positive effects on weight control. As such, it is the initial therapy of choice for overweight and obese patients with type 2 diabetes.

C Sitagliptin

Sitagliptin potentiates the incretin effect by preventing the breakdown of endogenous GLP-1; it is used as adjunctive therapy in type 2 diabetes.

D Basal bolus insulin

Basal bolus insulin therapy may well not be required for the majority of patients with MODY for a considerable period

Rana Alnasser's screen

You review a 42-year-old man who is referred to your private clinic after a general practitioner (GP) medical. He has a family history of premature cardiovascular disease. A trial of statin therapy was abandoned due to muscle pains at the lowest dose. Cholesterol testing reveals triglyceride levels of 4.2 mmol/l and a high-density lipoprotein (HDL) level of 0.8 mmol/l. You elect to commence him on fibrate therapy.

Which of the following options best describes the mode of action for fibrates?

A	Inhibition of hydroxymethylglutaryl-CoA (HMG-CoA) reductase activity
B	Inhibition of cholesterol ester transferase protein (CETP) activity
C	Inhibition of adipocyte lipolysis
D	Bile acid sequestration
E	Activation of lipoprotein lipase

Submit

9:14
594-042-7551
Leave

E Activation of lipoprotein lipase

The mode of action of fibrates is by enhancing lipoprotein lipase activity, increasing low-density lipoprotein (LDL) receptor-mediated clearance of LDL and increasing high-density lipoprotein (HDL) synthesis. This leads to a corresponding lowering of triglycerides, due to a fall in very low-density lipoprotein (VLDL) and a rise in HDL. In total, these reduce triglyceride levels by 20–60%, LDL by 5–25% and increase HDL by 15–30%.

B Inhibition of cholesterol ester transferase protein (CETP) activity

CETP inhibitors elevate HDL cholesterol and are thought to drive reverse cholesterol transport.

A Inhibition of hydroxymethylglutaryl-CoA (HMG-CoA) reductase activity

This is the rate-limiting step in cholesterol synthesis and is the mode of action of statins.

C Inhibition of adipocyte lipolysis

Niacin inhibits adipocyte lipolysis, but many patients don't like using niacin because of side effects, including itching.

D Bile acid sequestration

Resins, such as cholestyramine, sequester bile acids thereby leading to a reduction in LDL cholesterol.

Rate this question:
Audio Video Share Participants More

9:17

A 28-year-old woman with chronic kidney disease as a result of long-standing reflux nephropathy goes to her GP complaining of tiredness. She currently takes ramipril and indapamide for hypertension.

On examination, her BP is 142/88 mmHg and she looks pale and washed-out. Her pulse is 72 bpm and regular.

Investigations:

Hb	10.4 g/dl
WCC	5.6×10^9/l
PLT	198×10^9/l
Na^+	139 mmol/l
K^+	5.2 mmol/l
Creatinine	232 µmol/l
TSH	1.5 U/l (< 0.5-4.5)
Total T4	45 nmol/l (58-161)
Total T3	0.8 nmol/l (0.9-2.8)

Which of the following is the most likely diagnosis?

A Hashimotos's thyroiditis

B Pituitary failure

C Sick euthyroid syndrome

D Iodine deficiency

E Thyroxine-binding globulin deficiency

Rana Alnasser's screen

TSH	1.5 U/l (< 0.5-4.5)
Total T4	45 nmol/l (58-161)
Total T3	0.8 nmol/l (0.9-2.8)

Which of the following is the most likely diagnosis?

Your answer was correct

A Hashimotos's thyroiditis

B Pituitary failure

C Sick euthyroid syndrome

D Iodine deficiency

E Thyroxine-binding globulin deficiency

Explanation

E Thyroxine-binding globulin deficiency

Thyroxine-binding globulin (TBG) deficiency is a non-harmful condition that is either acquired or inherited. The thyroid hormones - thyroxine (T4) and 3,5,3'-triiodothyronine (T3) - circulate in the blood by reversibly binding to carrier proteins. Although only 0.3% or less of T3 and T4 circulates unbound, it is this free hormone fraction that is metabolically active at the tissue and cellular level. The three main proteins that carry the majority (>95%) of thyroid hormones are TBG), transthyretin (TTR, or prealbumin) and albumin.

Thyroid hormone binding to TBG is characterised by low

E Thyroxine-binding globulin deficiency

Thyroxine-binding globulin (TBG) deficiency is a non-harmful condition that is either acquired or inherited. The thyroid hormones – thyroxine (T4) and 3,5,3'-triiodothyronine (T3) – circulate in the blood by reversibly binding to carrier proteins. Although only 0.3% or less of T3 and T4 circulates unbound, it is this free hormone fraction that is metabolically active at the tissue and cellular level. The three main proteins that carry the majority (>95%) of thyroid hormones are TBG), transthyretin (TTR, or prealbumin) and albumin.

Thyroid hormone binding to TBG is characterised by low capacity but high avidity. Inherited or acquired variations in the concentration and/or affinity of these proteins may produce substantial changes in serum total thyroid hormone levels as measured by commercially available assays. Notably, these changes do not result in illness (i.e. hypothyroidism or hyperthyroidism), because the concentration of free thyroid hormones does not change.

A deficiency in thyroid hormone-binding proteins is suspected when abnormally low serum total thyroid hormone concentrations are encountered in clinically euthyroid subjects in the presence of normal serum thyroid-stimulating hormone (TSH). More specifically, low TBG is suggested because this protein carries the majority of the serum thyroid hormones.

Thyroid function tests (TFTs) in patients with TBG deficiency show normal TSH and free T4, but low total T4 and, occasionally, low total T3 serum concentrations. The most important clinical aspect of TBG deficiency states is recognition of these disorders and avoidance of unnecessary and potentially harmful thyroid hormone replacement therapy.

A Hashimotos's thyroiditis

Hashimoto's thyroiditis is an autoimmune condition causing

9:20

A 28-year-old woman attends the endocrine clinic because of inability to achieve a pregnancy. She and her husband have been trying for some 3 years for a child without success. Her general practitioner (GP) has measured a prolactin level of 2600 mU/l (normal <360). You arrange pituitary magnetic resonance imaging (MRI) that demonstrates a microprolactinoma. She elects for pharmacotherapy.

Which one of the following agents is the most appropriate treatment choice?

A Bromocriptine

B Fluphenazine

C Domperidone

D Haloperidol

E Chlorpheniramine

Submit

Rana Alnasser's screen

Explanation

A Bromocriptine

Bromocriptine is a dopamine agonist that leads to activation of D2 receptors. Side effects may include nausea and postural hypotension. Rarely, patients have been known to develop hallucinations and psychosis with therapy, but this is only at very high drug doses. It is important to warn female patients that, within a few months, menstrual cycles are likely to return and that pregnancy has a much higher probability of occurring. When patients become pregnant, they should cease dopamine agonist therapy as soon as they have a positive pregnancy test. More modern dopamine agonists such as ropinirole are also used in the management of prolactinomas, although there is less longitudinal evidence to support their safety in early pregnancy.

B Fluphenazine

This is a phenothiazine dopamine antagonist that actually increases dopamine levels. It is used as a treatment for chronic schizophrenia.

C Domperidone

Domperidone is a dopamine antagonist prokinetic anti-emetic which doesn't have a role in the treatment of prolactinoma.

D Haloperidol

Haloperidol is recommended in **NICE guidelines** for the treatment of agitation related to delirium in the elderly, where other interventions such as 1:1 nursing have failed to

and postural hypotension. Rarely, patients have been known to develop hallucinations and psychosis with therapy, but this is only at very high drug doses. It is important to warn female patients that, within a few months, menstrual cycles are likely to return and that pregnancy has a much higher probability of occurring. When patients become pregnant, they should cease dopamine agonist therapy as soon as they have a positive pregnancy test. More modern dopamine agonists such as ropinirole are also used in the management of prolactinomas, although there is less longitudinal evidence to support their safety in early pregnancy.

B Fluphenazine

This is a phenothiazine dopamine antagonist that actually increases dopamine levels. It is used as a treatment for chronic schizophrenia.

C Domperidone

Domperidone is a dopamine antagonist prokinetic anti-emetic which doesn't have a role in the treatment of prolactinoma.

D Haloperidol

Haloperidol is recommended in **NICE guidelines** for the treatment of agitation related to delirium in the elderly, where other interventions such as 1:1 nursing have failed to control the situation. It is a dopamine antagonist.

E Chlorpheniramine

Chlorpheniramine is a sedative antihistamine used in the treatment of allergic reactions, including hay fever and urticaria.

Rana Alnasser's screen

9:21

A 42-year-old woman attends her GP appointment complaining of a 3-week history of a sore throat associated with lethargy, a reduced appetite and general viral symptoms. She has also felt frequent palpitations recently and increased sweating but these appear to be settling, with the patient now complaining of occasional palpitations. Other symptoms include pain in the lower part of her neck made worse with swallowing and an occasional hoarseness of her voice. She is otherwise fit and well, is not on any medications and is a non-smoker. There is no significant family history. The only positive findings on examination were residual tenderness over her lower anterior neck to palpation and mild tachycardia associated with warm skin to touch. No lymphadenopathy was palpable.

The GP arranged for some thyroid function tests, which showed a T_4 level slightly above normal and a TSH level of <0.1 mU/l. Her GP diagnosed a viral illness and then commenced carbimazole 20 mg bd on the basis of her TFT results. Two months later, the patient again attended her GP but this time complaining of increased lethargy, weight gain and a minor discomfort in the lower part of her neck.

What would be the next most appropriate management step?

A	Adjust the dose of carbimazole to control the patient's symptoms
B	Stop carbimazole and consider replacement thyroid hormone therapy if symptoms don't recover
C	Refer the patient for an ultrasound scan of the thyroid gland
D	Refer patient for a fine needle aspiration biopsy of

Rana Alnasser's screen

of her neck made worse with swallowing and an occasional hoarseness of her voice. She is otherwise fit and well, is not on any medications and is a non-smoker. There is no significant family history. The only positive findings on examination were residual tenderness over her lower anterior neck to palpation and mild tachycardia associated with warm skin to touch. No lymphadenopathy was palpable.

The GP arranged for some thyroid function tests, which showed a T_4 level slightly above normal and a TSH level of <0.1 mU/l. Her GP diagnosed a viral illness and then commenced carbimazole 20 mg bd on the basis of her TFT results. Two months later, the patient again attended her GP but this time complaining of increased lethargy, weight gain and a minor discomfort in the lower part of her neck.

What would be the next most appropriate management step?

A	Adjust the dose of carbimazole to control the patient's symptoms
B	Stop carbimazole and consider replacement thyroid hormone therapy if symptoms don't recover
C	Refer the patient for an ultrasound scan of the thyroid gland
D	Refer patient for a fine needle aspiration biopsy of the thyroid gland
E	Change carbimazole to proplythiouracil

9:25
MyPastest
https://mypastest.pastest.com

B Stop carbimazole and consider replacement thyroid hormone therapy if symptoms don't recover

De Quervain thyroiditis is the most common cause of a painful thyroid gland and causes hyperthyroidism initially, sometimes followed by transient hypothyroidism. The underlying cause is felt to be either a viral infection or the post-viral inflammatory response. The condition is more common in females. The typical course of the disease consists of an acute phase, in which the main complaint is pain, although signs of hyperthyroidism may also be present. This is followed by a transient asymptomatic and euthyroid phase, which evolves into the hypothyroid phase. The hypothyroid state may become permanent in 5–10% of patients, but the vast majority go on to the recovery phase, characterised by normalisation of thyroid structure and function. The treatment is consequently directed towards the control of pain and thyroid symptoms. Initial symptomatic hyperthyroidism can be treated with beta-blockade. Beta-adrenergic blockers are usually the sole form of treatment indicated/required in cases of thyroiditis, although severe, persistent symptoms/signs in may require additional therapy with salicylates and/or glucocorticoids. If hypothyroidism occurs in the late stages, replacement therapy is required and is guided by the TSH levels.

A Adjust the dose of carbimazole to control the patient's symptoms

The patient's symptoms are caused by the hypothyroid phase of De Quervain's thyroiditis, rather than the carbimazole.

C Refer the patient for an ultrasound scan of the thyroid gland

Rana Alnasser's screen

carbimazole.

C	Refer the patient for an ultrasound scan of the thyroid gland

Ultrasound scanning should be performed in patients presenting with a single palpable nodule.

D	Refer patient for a fine needle aspiration biopsy of the thyroid gland

Fine needle aspiration should always be performed on solitary nodules >10 mm, those <10 mm with suspicious imaging characteristics or on dominant nodules.

E	Change carbimazole to proplythiouracil

The patient's symptoms are not due to carbimazole. Propylthiouracil and carbimazole are both associated with agranulocytosis and must be stopped if this complication is suspected, and only restarted if a blood count has confirmed that the white cell count is in fact normal.

Rate this question:

Previous Q... Tag Questi... Feedback End Session

Blog About Pastest Contact Us Help

© Pastest 2019

A 28-year-old single man with type 1 diabetes presents for review. His HbA1c is 50.82 mmol/mol (6.8%) yet he is concerned that morning sugars are occasionally as high as 24 mmol/l. He is also suffering from frequent nightmares.

He is currently managed on a basal bolus insulin regime. His blood pressure is 112/82, with pulse 67 and regular. Creatinine is normal and he has 1+ of protein on urine testing.

Which of the following is most appropriate for his further management?

A	Increase his nocturnal dose of long-acting insulin
B	Switch his nocturnal long-acting insulin to morning dosing
C	Divide his nocturnal long-acting insulin into morning and evening doses
D	Add in an extra dose of short-acting insulin with a snack at 10 pm
E	Arrange for continuous glucose monitoring

52906

Submit

A 28-year-old single man with type 1 diabetes presents for review. His HbA1c is 50.82 mmol/mol (6.8%) yet he is concerned that morning sugars are occasionally as high as 24 mmol/l. He is also suffering from frequent nightmares.

He is currently managed on a basal bolus insulin regime. His blood pressure is 112/82, with pulse 67 and regular. Creatinine is normal and he has 1+ of protein on urine testing.

Which of the following is most appropriate for his further management?

Your answer was incorrect

A Increase his nocturnal dose of long-acting insulin

B Switch his nocturnal long-acting insulin to morning dosing

C Divide his nocturnal long-acting insulin into morning and evening doses

D Add in an extra dose of short-acting insulin with a snack at 10 pm

E Arrange for continuous glucose monitoring

Explanation

E Arrange for continuous glucose monitoring

His long-term blood glucose control is excellent, and his occasional high morning sugars are suggestive of the

E Arrange for continuous glucose monitoring

His long-term blood glucose control is excellent, and his occasional high morning sugars are suggestive of the Somogyi effect, related to nocturnal hypoglycaemia, reactive release of counter-regulatory hormones such as adrenaline and rebound hyperglycaemia. Continuous glucose monitoring would be useful in producing a 72 h profile of glucose excursions to rule out nocturnal hypoglycaemia. In the event that a significant problem with morning dipping in glucose is revealed, then his long-acting insulin dose will require a reduction, as may his short-acting evening insulin dose.

See also *The Lancet* 1980, Gale *et al.*, 316(8189):279-282.

C Divide his nocturnal long-acting insulin into morning and evening doses

Steady state dosing and long-half-life insulin mean that there is only a minor impact on blood glucose levels from splitting the dose.

A Increase his nocturnal dose of long-acting insulin

Until nocturnal hypoglycaemia is excluded, increasing his nocturnal dose of long-acting insulin risks life-threatening hypoglycaemia.

B Switch his nocturnal long-acting insulin to morning dosing

Modern long-acting insulin analogues should not have a significant variance in their effect if they are dosed in the morning or the evening, because of their long half-life and ability to reach steady state. As such, there is no value in switching the timing of the dose.

You review a 62-year-old type 2 diabetic who is taking metformin 2 g per day and gliclazide 160 mg per day and ramipril for renoprotection. Recent HbA1c was 68.31 mmol/mol (8.4%) and his blood pressure was 140/75 mmHg. You review his eye photograph that reveals dot-and-blot haemorrhages, cotton wool spots and micro-aneurysms. None are within close proximity to the macula.

Which of the following treatments represents the best option for reducing the probability of further deterioration of his diabetic retinopathy over the long term?

A	Gradual transition to insulin therapy
B	Addition of valsartan to his blood pressure regime
C	Addition of amlodipine to his blood pressure regime
D	Laser therapy
E	Increasing gliclazide to 320 mg/day

32911

Submit

9:36

You review a 62-year-old type 2 diabetic who is taking metformin 2 g per day and gliclazide 160 mg per day and ramipril for renoprotection. Recent HbA1c was 68.31 mmol/mol (8.4%) and his blood pressure was 140/75 mmHg. You review his eye photograph that reveals dot-and-blot haemorrhages, cotton wool spots and micro-aneurysms. None are within close proximity to the macula.

Which of the following treatments represents the best option for reducing the probability of further deterioration of his diabetic retinopathy over the long term?

Your answer was correct

A	Gradual transition to insulin therapy
B	Addition of valsartan to his blood pressure regime
C	Addition of amlodipine to his blood pressure regime
D	Laser therapy
E	Increasing gliclazide to 320 mg/day

Explanation

A Gradual transition to insulin therapy

This patient's blood pressure is relatively well controlled, yet there is room for significant improvement in his blood glucose. Achievement of the target HbA1c of 47.54 mmol/mol (7.0%) would be associated with significantly

Rana Alnasser's screen

A Gradual transition to insulin therapy

This patient's blood pressure is relatively well controlled, yet there is room for significant improvement in his blood glucose. Achievement of the target HbA1c of 47.54 mmol/mol (7.0%) would be associated with significantly reduced progression of retinopathy.

B Addition of valsartan to his blood pressure regime

Addition of ARB to an ACE inhibitor brings little added impact on blood pressure control, with significantly increased risk of hyperkalaemia. As such, it should be avoided.

C Addition of amlodipine to his blood pressure regime

The next step in further intensification of blood pressure control is addition of a calcium antagonist such as amlodipine, although amongst the calcium antagonist class, only diltiazem has been shown to impact significantly on proteinuria.

D Laser therapy

Although laser therapy reduces progression of retinopathy, there are no high-risk features currently identified on retinal photography.

E Increasing gliclazide to 320 mg/day

The dose-response curve for gliclazide above 160 mg is fairly flat, and hence there is little value in a further increase in sulphonylurea dose.

A 52-year-old man comes to an annual check-up clinic for type 2 diabetes mellitus which is controlled by metformin. He was diagnosed with diabetes 11 years ago after an inferior myocardial infarction. In the clinic today his blood pressure (BP) is 160/95 mmHg and his body mass index (BMI) is 26. He has normal fundi and examination of his feet shows normal sensation and peripheral pulses. As well as his metformin he takes amlodipine 5 mg OD and simvastatin 40 mg ON.

Investigations:

Cholesterol	4.6 mmol/l
Urea	7.4 mmol/l
Creatinine	109 µmol/l
HbA1c	57.38 mmol/mol (7.4%)
Albumin : creatinine ratio	3.8 mg/mmol (<3.5 males/<3.5 females)

Which of the following is likely to have the greatest impact on his future risk of complications?

A	Start a sulphonylurea
B	Start insulin
C	Add an angiotensin-converting enzyme (ACE) inhibitor to his calcium channel antagonist
D	Add a thiazide diuretic to his calcium channel antagonist
E	Add a fibrate to his statin therapy

C Add an angiotensin-converting enzyme (ACE) inhibitor to his calcium channel antagonist

NICE guidelines suggest a target BP of 140/80 mmHg in type 2 diabetes. First-line antihypertensive drug treatment should be an ACE inhibitor. This patient also has microalbuminuria – a sign of diabetic nephropathy. ACE inhibitors significantly reduce the risk of all-cause mortality for patients with diabetic kidney disease.

A Start a sulphonylurea

NICE guidelines suggest a target HbA1c of <53 mmol/mol (<7%) in type 2 diabetes mellitus. Unfortunately, in late-stage patients who have a positive cardiovascular history, both the ACCORD and VADT trials showed no benefit of aiming for a HbA1c of <47.54 mmol/mol (6.5%). Recent trials have shown improved cardiac outcomes with the addition of either SGLT2 inhibitors such as empagliflozin (EMPA-REG OUTCOME) or GLP-1 agonists such as liraglutide (LEADER), with a reduction in death from cardiovascular causes and hospitalisation for heart failure.

B Start insulin

If initial drug treatment with metformin has not continued to control HbA1c to below the person's agreed threshold for intensification, consider dual therapy with metformin combined with one combining a DPP-4 inhibitor, pioglitazone or a sulfonylurea. Insulin is only normally considered if dual therapy has not achieved adequate glycaemic control.

D Add a thiazide diuretic to his calcium channel antagonist

If the person's blood pressure is not reduced to the individually agreed target with first-line therapy, a calcium

You review a 46-year-old man who complains of polydipsia and polyuria. He is careful with his weight and regularly visits the gym, but still feels that his health is deteriorating and he is actually finding it difficult to maintain his weight and muscle mass. He also complains of diarrhoea and a skin rash which seems to break down and bruise/bleed easily. He has no past medical history, apart from a recent fall from his bike after which he sustained a head injury.

On examination, his blood pressure is 135/85 mmHg, with pulse 68 bpm and regular. His BMI is 25 kg/m^2. On dipstick urine testing, there are 2+ of glucose.

Which of the following would best explain these findings?

A	Head Injury
B	Hypothyroidism
C	Hyperparathyroidism
D	Glucagonoma
E	Insulinoma

6535

Submit

9:42

visits the gym, but still feels that his health is deteriorating and he is actually finding it difficult to maintain his weight and muscle mass. He also complains of diarrhoea and a skin rash which seems to break down and bruise/bleed easily. He has no past medical history, apart from a recent fall from his bike after which he sustained a head injury.

On examination, his blood pressure is 135/85 mmHg, with pulse 68 bpm and regular. His BMI is 25 kg/m². On dipstick urine testing, there are 2+ of glucose.

Which of the following would best explain these findings?

Your answer was correct

A Head Injury

B Hypothyroidism

C Hyperparathyroidism

D Glucagonoma

E Insulinoma

Explanation

D Glucagonoma

Glucagonoma is vanishingly rare, with an annual incidence estimated at 1 in 20 million, but it fits the bill here as the only potential cause of secondary diabetes mellitus from the options listed. The fact his weight is normal and he has developed diabetes whilst still maintaining a healthy weight and lifestyle is suggestive of secondary diabetes.

Rana Alnasser's screen

D Glucagonoma

Glucagonoma is vanishingly rare, with an annual incidence estimated at 1 in 20 million, but it fits the bill here as the only potential cause of secondary diabetes mellitus from the options listed. The fact his weight is normal and he has developed diabetes whilst still maintaining a healthy weight and lifestyle is suggestive of secondary diabetes.

A Head Injury

Head injury can be a cause of transient diabetes insipidus that usually recovers slowly over the course of a few weeks.

B Hypothyroidism

Autoimmune thyroid disease is associated with type 1 diabetes, but wouldn't account for the glycosuria seen here.

C Hyperparathyroidism

Hyperparathyroidism may be associated with diuresis related to hypercalcaemia, but we are given no evidence here of elevated serum calcium.

E Insulinoma

Insulinomas present with recurrent episodes of collapse due to hypoglycaemia, and gradual weight gain because of compensatory eating.

6533

Rate this question:

Next Question

Rana Alnasser's screen

A 46-year-old Bangladeshi chef was admitted with a 3-month history of night sweats, weight loss and malaise. Examination in the clinic reveals a BP of 154/88 mmHg, with pulse 80/min and regular. Auscultation of the chest appears normal apart from occasional wheezes, and the abdomen is soft and non-tender. Abdominal examination is normal. He has been checking his temperature at home and produces a diary to confirm swinging fevers up to 39.0°C over the last 2 weeks.

Investigations are:

Hb	12.1 g/dl
WCC	4.3×10^9/l
PLT	205×10^9/l
Na^+	132 mmol/l
K^+	4.9 mmol/l
Creatinine	104 µmol/l
Urea	7.0 mmol/l
CRP	72 mg/l
Sputum microscopy	No evidence of AAFB
Abdominal CT scan	Bilaterally enlarged adrenal glands

His chest X-ray is shown below:

By Mikael Häggström [CC0], from Wikimedia Commons

Which of the following is the most useful next investigation?

A	Mantoux test
B	Groccott-stained adrenal biopsy
C	Bone marrow trephine
D	17-Hydroxyprogesterone
E	Low-dose dexamethasone suppression test

B Groccott-stained adrenal biopsy

The differential diagnosis for a pyrexia of unknown origin and bilateral adrenal swelling would be lymphoma, tuberculosis or histoplasmosis. Tuberculosis is unlikely in view of the normal chest X-ray and negative sputum cultures. Lymphoma is unlikely as the white count is normal. Histoplasmosis, which is caused by *Histoplasma capsulatum*, a dimorphic soil fungus, should therefore be excluded. A slowly progressing chronic form occurs in those who are fit and immunocompetent. Those who are weak, very young, very old or immunocompromised tend to acquire a disseminated infection. Acute infection causes malaise, fevers, anorexia and headache. It can cause a TB-like illness with dyspnoea, cough and haemoptysis, or can simply cause bilateral hilar lymphadenopathy. Disseminated infection causes bilateral adrenal enlargement in 79% of cases. It can result in adrenal insufficiency. Diagnosis made by adrenal biopsy or fine needle aspirate (FNA). The Groccott stain identifies the organism. Treatment is with itraconazole.

A Mantoux test

The Mantoux test is used as a screening test for exposure to tuberculosis, a positive test being declared according to the degree of induration identified after the skin is inoculated with tuberculin protein.

C Bone marrow trephine

Bone marrow involvement is seen in chronic disseminated histoplasmosis, although in this case adrenal biopsy is more likely to demonstrate infection.

A 31-year-old man with type 1 diabetes comes to the clinic for advice about his blood glucose control. He has suffered a number of significant hypoglycaemic episodes over the past 2 months, which have corresponded with a wish to increase his exercise. He is currently running 15 km per week in 5 km blocks. He takes BD mixed insulin and doesn't alter his dose on the days he exercises. On examination his BP is 125/78 mmHg and his BMI is 27. There are no signs of peripheral neuropathy.

Investigations:

Hb	13.1 g/dl
WCC	7.6 x 10^9/l
PLT	210 x 10^9/l
Na^+	138 mmol/l
K^+	4.4 mmol/l
Creatinine	90 µmol/l
HbA1c	50 mmol/ml (6.73%)

Which of the following is the most appropriate next step in his management with respect to glucose and weight management?

A	Reduce his BD mixed insulin dose on the days he exercises
B	Advise him to reduce his exercise
C	Advise him to transfer to a basal bolus regime
D	Advise him to maintain the same insulin dose and take a source of sugar with him when he runs

week in 5 km blocks. He takes BD mixed insulin and doesn't alter his dose on the days he exercises. On examination his BP is 125/78 mmHg and his BMI is 27. There are no signs of peripheral neuropathy.

Investigations:

Hb	13.1 g/dl
WCC	7.6 x 10^9/l
PLT	210 x 10^9/l
Na^+	138 mmol/l
K^+	4.4 mmol/l
Creatinine	90 µmol/l
HbA1c	50 mmol/ml (6.73%)

Which of the following is the most appropriate next step in his management with respect to glucose and weight management?

A	Reduce his BD mixed insulin dose on the days he exercises
B	Advise him to reduce his exercise
C	Advise him to transfer to a basal bolus regime
D	Advise him to maintain the same insulin dose and take a source of sugar with him when he runs
E	Reassure him that he will adjust to the lower blood sugar and his hypos will subside

Explanation

C	Advise him to transfer to a basal bolus regime

Whilst some patients with type 1 diabetes prefer to take a BD mixed insulin regime because of convenience and number of injections, it is not responsive to changes in routine such as taking intensive aerobic exercise. As such, he should be persuaded to change to a basal bolus regime where he can alter his short-acting insulin dose just prior to when he is planning exercise.

A	Reduce his BD mixed insulin dose on the days he exercises

Reducing his BD insulin is likely to precipitate an increase in his HbA1c because his glucose outside periods of exercise will increase significantly.

B	Advise him to reduce his exercise

Exercise is important with respect to maintaining fitness and reducing cardiovascular risk in type 1 diabetes. As such, aiming to reduce his exercise is inappropriate.

D	Advise him to maintain the same insulin dose and take a source of sugar with him when he runs

This will blunt some of the benefits of exercise in driving a calorie deficit.

E	Reassure him that he will adjust to the lower blood sugar and his hypos will subside

This runs the risk of reducing awareness of significant hypoglycaemic episodes.

9:53
594-042-7551
Leave

A 30-year-old man attends the endocrine clinic with gynaecomastia. He had mumps aged 8, and broke his arm aged 14. Otherwise, he has no past history of note. He is on no regular medications. On examination, he is tall, with sparse secondary sexual hair pattern. His testicular volume is less than 5 ml.

Investigations:

9 am testosterone	4 nmol/l
LH	Elevated
FSH	Elevated

What is the likely underlying diagnosis?

A Kallmann syndrome

B Mump's orchitis

C Pituitary adenoma

D Adrenal tumour

E Klinefelter syndrome

Submit

Audio
Video
Share
Participants
More

9:54
594-042-7551
Leave

A 30-year-old man attends the endocrine clinic with gynaecomastia. He had mumps aged 8, and broke his arm aged 14. Otherwise, he has no past history of note. He is on no regular medications. On examination, he is tall, with sparse secondary sexual hair pattern. His testicular volume is less than 5 ml.

Investigations:

9 am testosterone	4 nmol/l
LH	Elevated
FSH	Elevated

What is the likely underlying diagnosis?

Your answer was incorrect

A Kallmann syndrome

B Mump's orchitis

C Pituitary adenoma

D Adrenal tumour

E Klinefelter syndrome

Explanation

E Klinefelter syndrome

Low testosterone in the presence of raised LH and FSH suggests gonadal failure. Gynaecomastia and infertility are the two commonest presentations of Klinefelter syndrome

Audio Video Share Participants More

9:54
594-042-7551
Leave

E Klinefelter syndrome

Low testosterone in the presence of raised LH and FSH suggests gonadal failure. Gynaecomastia and infertility are the two commonest presentations of Klinefelter syndrome (47,XXY karyotype), which is often but not inevitably associated with reduced secondary sexual characteristics.

B Mump's orchitis

Testicular failure following mumps is a rare complication and only occurs following mumps orchitis when contracted after puberty.

A Kallmann syndrome

Kallmann syndrome is typified by either anosmia or severe hyposmia. It is also associated with hypogonadotrophic hypogonadism.

C Pituitary adenoma

A pituitary adenoma will cause hypogonadotrophic hypogonadism, resulting in both the LH and FSH being reduced.

D Adrenal tumour

Oestrogen-producing adrenal tumours are rare and should not result in primary hypogonadism. Adrenocortical adenomas are associated with pituitary tumours in the context of multiple endocrine neoplasia type 1, but in this case would cause hypogonadotrophic hypogonadism.

Rate this question:
Audio Video Share Participants More

A 61-year-old man is admitted having taken an overdose of unspecified medication. He is known to have type 2 diabetes, controlled with tablets, hypertension and a previous myocardial infarction.

His BP is 95/60 mmHg, with pulse 105/min and regular. His respiratory rate is 35/min.

Investigations:

Hb	12.9 g/dl
WCC	8.9×10^9/l
PLT	200×10^9/l
Na^+	143 mmol/l
K^+	4.5 mmol/l
Creatinine	132 µmol/l
Bicarbonate	15 mmol/l
Cl^-	105 mmol/l
Glucose	4.9 mmol/l

Which of the following is the most likely cause of his overdose?

A Paracetamol

B Atenolol

C Ramipril

D Metformin

E Sitagliptin

9:57

MyPastest
https://mypastest.pastest.com

This man has a raised anion gap metabolic acidosis. As such, the most likely cause of his overdose is metformin excess. Treatment is supportive, although in severe cases prolonged haemodialysis can be considered. Mortality is considerable, particularly in patients with underlying cardiovascular disease.

A Paracetamol

Metabolic acidosis in paracetamol overdose is a late presentation, associated with oliguria and acute kidney disease.

B Atenolol

Atenolol is associated with bradycardia and hypotension rather than the clinical picture seen here.

C Ramipril

Angiotensin-converting enzyme (ACE) inhibitor overdose leads to profound hypotension and acute kidney disease rather than the picture seen here.

E Sitagliptin

Experience with respect to sitagliptin overdose is minimal, although up to 800 mg was given as a regular dose in early studies without any significant adverse consequences.

Rate this question:

Rana Alnasser's screen

9:57
594-042-7551
Leave

A 65-year-old woman is brought into hospital critically ill and with a reduced level of consciousness. Her relatives state she has been increasingly lethargic over the past month and had put on weight. She had been slightly confused, with constipation, and was commenced on antibiotics for a presumed urinary tract infection. She currently takes no regular medication. Her pulse is 55/min, blood pressure 125/98 mmHg, temperature 34 °C, respiratory rate 8/min, oxygen saturations 98% on air.

Examination reveals coarse facial features with dry skin, thin hair and brittle nails.

Initial investigations:

ECG	Sinus bradycardia
Glucose	5.9 mmol/l
Urea	15.2 mmol/l
Na^+	127 mmol/l
K^+	5.8 mmol/l
Creatinine	223 µmol/l

After giving her IV hydrocortisone, which other therapy would you consider?

A Rapid intravenous fluids

B Intravenous T3

C Rapid rewarming

D Hypertonic saline

E Demeclocycline

Audio Video Share Participants More

antibiotics for a presumed urinary tract infection. She currently takes no regular medication. Her pulse is 55/min, blood pressure 125/98 mmHg, temperature 34 °C, respiratory rate 8/min, oxygen saturations 98% on air.

Examination reveals coarse facial features with dry skin, thin hair and brittle nails.

Initial investigations:

ECG	Sinus bradycardia
Glucose	5.9 mmol/l
Urea	15.2 mmol/l
Na^+	127 mmol/l
K^+	5.8 mmol/l
Creatinine	223 µmol/l

After giving her IV hydrocortisone, which other therapy would you consider?

Your answer was correct

A Rapid intravenous fluids

B Intravenous T3

C Rapid rewarming

D Hypertonic saline

E Demeclocycline

Explanation

B Intravenous T3

Myxoedema coma can be the initial presentation of hypothyroidism, but more usually occurs against a background of long-standing disease where patients are unable to comply with their thyroxine replacement. Patients will have a history of cold intolerance, weight gain, increasing lethargy and constipation. Facial features include general coarsening with periorbital oedema and hair thinning. This is an emergency, and treatment involves intravenous thyroxine and slow rewarming. It is also important to take serum for thyroid function and adrenal function. Coexisting hypoadrenalism is suggested by the hyponatraemia, the hyperkalaemia and a raised urea. Patients may also be hypoglycaemic, although that is not the case here. Treatment with hydrocortisone is recommended until Addison's disease can be excluded. It is important to provide hydrocortisone until Addison's is excluded, as just giving thyroid hormone alone may precipitate an adrenal crisis.

A Rapid intravenous fluids

The patient has a normal blood pressure with bradycardia, and therefore there is no indication for aggressive fluid resuscitation. Moreover, she is hyponatraemic, and therefore the correction of sodium levels should be gradual in order to avoid central pontine myelinolysis.

C Rapid rewarming

The patient is hypothermic and she should be rewarmed slowly in order to improve the chance of neurological recovery.

D Hypertonic saline

A 28-year-old woman consults her doctor because of lethargy. She is currently taking fluoxetine for postnatal depression, her child now being 5 months old. Other past history of note is type 1 diabetes mellitus, for which she is using a basal bolus insulin regime. Her thyroid hormone tests reveal a TSH of 7 mU/l (0.4-5.0) and a free T4 of 8.0 pmol/l (10-22). Anti-TPO antibodies are positive.

Which of the following most accurately represents her prognosis?

A	She is likely to progress rapidly to thyrotoxicosis
B	She is more likely to become euthyroid than to remain hypothyroid
C	She is more likely to remain hypothyroid than to become euthyroid
D	Corticosteroids can improve the chances of becoming euthyroid
E	Permanent thyroxine replacement therapy is likely to be needed

18541

Submit

Rana Alnasser's screen

10:02
594-042-7551
Leave
MyPastest
https://mypastest.pastest.com

A 28-year-old woman consults her doctor because of lethargy. She is currently taking fluoxetine for postnatal depression, her child now being 5 months old. Other past history of note is type 1 diabetes mellitus, for which she is using a basal bolus insulin regime. Her thyroid hormone tests reveal a TSH of 7 mU/l (0.4-5.0) and a free T4 of 8.0 pmol/l (10-22). Anti-TPO antibodies are positive.

Which of the following most accurately represents her prognosis?

Your answer was correct

A. She is likely to progress rapidly to thyrotoxicosis

B. She is more likely to become euthyroid than to remain hypothyroid

C. She is more likely to remain hypothyroid than to become euthyroid

D. Corticosteroids can improve the chances of becoming euthyroid

E. Permanent thyroxine replacement therapy is likely to be needed

Explanation

B She is more likely to become euthyroid than to remain hypothyroid

Audio Video Share Participants More

10:02
594-042-7551
Leave

B She is more likely to become euthyroid than to remain hypothyroid

Postpartum thyroid dysfunction is said to occur in 5-10% of women during the first year after the birth of a child. Hyperthyroidism is said to occur within the first 4 months of pregnancy, the only symptom of which may be tiredness, with hypothyroidism occurring later, at the 3-7-month stage. Often symptoms are mild and non-specific. Spontaneous recovery occurs in the majority of patients within 6-12 months of delivery, although around 40% eventually go on to develop permanent hypothyroidism. Risk of permanent hypothyroidism isn't closely related to the anti-TPO titre at the end of pregnancy because titres progressively fall during the course of pregnancy.

A She is likely to progress rapidly to thyrotoxicosis

The hyperthyroid phase presents with non-specific symptoms and may pass undetected. Patients either then become euthyroid or hypothyroid.

C She is more likely to remain hypothyroid than to become euthyroid

Around 40% of patients develop permanent hypothyroidism.

D Corticosteroids can improve the chances of becoming euthyroid

In patients with postpartum hypothyroidism, low-dose thyroxine (e.g. 50 µg) may be used to allow for spontaneous recovery to occur with re-checking of thyroid function off therapy after 6 months of treatment. There is no role for corticosteroids in treatment.

Audio Video Share Participants More

You are called to interpret the results of a synacthen test on the Oncology Ward. The patient is a 60-year-old woman who is in hospital for chemotherapy for breast cancer. She has tolerated her therapy poorly and is currently suffering from multiple episodes of vomiting.

On examination, pulse 120/min regular, BP 90/60 mmHg. Her JVP is not seen, her heart sounds are normal and her chest is clear. There is evidence of a right mastectomy. Abdominal and neurological examination is normal.

Short synacthen test:

Time (min)	0	30	60
cortisol (nmol/l)	90	130	145

Given the likely diagnosis, which of the following is the most important component of your immediate management?

A 1 litre IV dextrose over 6

B 1 litre IV normal saline over 12

C Hydrocortisone 100 mg IV BD

D Hydrocortisone oral 20 mg AM, 10 mg PM

E Hydrocortisone 50 mg IV OD

32670

Submit

You are called to interpret the results of a synacthen test on the Oncology Ward. The patient is a 60-year-old woman who is in hospital for chemotherapy for breast cancer. She has tolerated her therapy poorly and is currently suffering from multiple episodes of vomiting.

On examination, pulse 120/min regular, BP 90/60 mmHg. Her JVP is not seen, her heart sounds are normal and her chest is clear. There is evidence of a right mastectomy. Abdominal and neurological examination is normal.

Short synacthen test:

Time (min)	0	30	60
cortisol (nmol/l)	90	130	145

Given the likely diagnosis, which of the following is the most important component of your immediate management?

Your answer was correct

A 1 litre IV dextrose over 6

B 1 litre IV normal saline over 12

C Hydrocortisone 100 mg IV BD

D Hydrocortisone oral 20 mg AM, 10 mg PM

E Hydrocortisone 50 mg IV OD

Explanation

C Hydrocortisone 100 mg IV BD

C Hydrocortisone 100 mg IV BD

This patient's rise in cortisol demonstrates an inadequate response to synacthen. The 30 min value should rise above 550 nmol/l. Therefore, this lady has acute adrenal insufficiency. The treatment for this is intravenous saline - at least 6-hourly initially, as her blood pressure is on the low side. Hydrocortisone should be given at a dose of 100 mg IV BD. Lower doses will not be sufficient. Fludrocortisone should be started but is not necessary for emergency treatment. The aetiology of the adrenal insufficiency should be elucidated, but in this lady is likely to be due to metastatic spread, most commonly from a breast or lung primary.

A 1 litre IV dextrose over 6

IV dextrose may further exacerbate any underlying hyponatraemia, and is unlikely to represent adequate fluid replacement for this patient.

B 1 litre IV normal saline over 12

Although normal saline will contribute to total body sodium, this represents an inadequate fluid replacement regimen and won't correct underlying hypoadrenalism.

D Hydrocortisone oral 20 mg AM, 10 mg PM

This is an adequate maintenance regimen for hypoadrenalism, although it is inappropriate here due to vomiting, and because of likely greater corticosteroid requirements due to her intercurrent illness.

E Hydrocortisone 50 mg IV OD

This patient is acutely unwell with a very poor cortisol

IV dextrose may further exacerbate any underlying hyponatraemia, and is unlikely to represent adequate fluid replacement for this patient.

B	1 litre IV normal saline over 12

Although normal saline will contribute to total body sodium, this represents an inadequate fluid replacement regimen and won't correct underlying hypoadrenalism.

D	Hydrocortisone oral 20 mg AM, 10 mg PM

This is an adequate maintenance regimen for hypoadrenalism, although it is inappropriate here due to vomiting, and because of likely greater corticosteroid requirements due to her intercurrent illness.

E	Hydrocortisone 50 mg IV OD

This patient is acutely unwell with a very poor cortisol response to synacthen, and thus higher doses of corticosteroids will almost certainly be required.

Rate this question:

© Pastest 2019

Rana Alnasser's screen

A 23-year-old blonde-haired, blue-eyed, tanned lady presents to your clinic. She has had type 1 diabetes for 8 years, and until recently it has been well controlled; however, recently, she has been having numerous hypoglycaemic attacks. These hypos can be at any time of the day and follow no pattern. Her periods are regular. Her BP is 100/60 mmHg with a postural drop of 10 mmHg. She is on a basal bolus regime, taking insulin aspart 8 units three times per day and glargine insulin 15 units at night.

Investigations:

Hb	10.0 g/dl
WCC	6.3×10^9/l
PLT	193×10^9/l
Na^+	130 mmol/l
K^+	4.4 mmol/l
Creatinine	100 µmol/l
MVC	93 fl
Urea	8.0 mmol/l

Which of the following is most likely to determine the underlying diagnosis?

A Serum ferritin

B Paired serum and urine osmolality

C Continuous glucose monitoring

D Short Synacthen test

E Transferrin saturation

BP is 100/60 mmHg with a postural drop of 10 mmHg. She is on a basal bolus regime, taking insulin aspart 8 units three times per day and glargine insulin 15 units at night.

Investigations:

Hb	10.0 g/dl
WCC	6.3×10^9/l
PLT	193×10^9/l
Na^+	130 mmol/l
K^+	4.4 mmol/l
Creatinine	100 µmol/l
MVC	93 fl
Urea	8.0 mmol/l

Which of the following is most likely to determine the underlying diagnosis?

Your answer was correct

A Serum ferritin

B Paired serum and urine osmolality

C Continuous glucose monitoring

D Short Synacthen test

E Transferrin saturation

Explanation

Type 1 diabetes is associated with many autoimmune diseases, including Addison's (primary autoimmune adrenal failure). It commonly presents with weight loss and malaise. In patients with diabetes, it presents more commonly as hypoglycaemia. Hyponatraemia is present in 90% and hyperkalaemia in 65%. A normocytic normochromic anaemia is often present, sometimes with an associated eosinophilia.

A Serum ferritin

This patient has normocytic anaemia, which is much more likely to be related to adrenal failure rather than to low iron stores.

B Paired serum and urine osmolality

The presence of unexplained hypoglycaemia in the presence of a low serum sodium steers us more towards adrenal insufficiency, which must be excluded before a diagnosis of syndrome of inappropriate antidiuretic hormone (SIADH) can be considered.

C Continuous glucose monitoring

CGM will confirm a diagnosis of unpredictable hypoglycaemia, although won't contribute to elucidating the cause.

E Transferrin saturation

However, haemochromatosis does present with diabetes mellitus and can be associated with adrenal failure, due to the effect of the menstrual cycle it presents in older women, usually post-menopause.

A 25-year-old postman presents for review. He is 6 feet 4 inches tall and has signs of delayed puberty and infertility on examination, notably small testes with scanty pubic hair.

Investigations:

FSH	35 U/l (1–7)
Testosterone	5 nmol/l (9–35)

Which diagnosis fits best with this clinical picture?

A 47XXY

B Down syndrome

C Fragile-X syndrome

D Hypogonadotropic hypogonadism

E Kallmann's syndrome

32893

Submit

Previous Q... Skip Questi...

© Pastest 2019

A 25-year-old postman presents for review. He is 6 feet 4 inches tall and has signs of delayed puberty and infertility on examination, notably small testes with scanty pubic hair.

Investigations:

FSH	35 U/l (1–7)
Testosterone	5 nmol/l (9–35)

Which diagnosis fits best with this clinical picture?

Your answer was correct

A 47XXY

B Down syndrome

C Fragile-X syndrome

D Hypogonadotropic hypogonadism

E Kallmann's syndrome

Explanation

A 47XXY

This is 47XXY, or Klinefelter syndrome. Hypogonadotropic hypogonadism occurs in hypopituitarism, selective gonadotrophin deficiency (e.g. Kallmann syndrome), systemic illness or severe weight reduction. Fragile-X syndrome is associated with macro-orchidism and learning difficulties in males. Klinefelter syndrome affects 1 in 1000

Explanation

A 47XXY

This is 47XXY, or Klinefelter syndrome. Hypogonadotropic hypogonadism occurs in hypopituitarism, selective gonadotrophin deficiency (e.g. Kallmann syndrome), systemic illness or severe weight reduction. Fragile-X syndrome is associated with macro-orchidism and learning difficulties in males. Klinefelter syndrome affects 1 in 1000 males and involves the loss of Leydig cells and seminiferous tubular dysgenesis. Treatment is with androgen replacement unless testosterone levels are normal. No treatment is possible for associated infertility. Chromosomal disorders such as Klinefelter syndrome, which occur due to loss, gain or rearrangement of one or more chromosomes, have no clear pattern of inheritance and carry a low risk of inheritance in relatives.

B Down syndrome

Down syndrome is caused by trisomy 21 and is of course associated with learning difficulties, rather than the specific features of hypoandrogenism seen here.

C Fragile-X syndrome

Fragile-X syndrome is associated with learning difficulties and macro-orchidism rather than the small testes seen here.

D Hypogonadotropic hypogonadism

We can see from the blood results that FSH is significantly elevated, ruling out hypogonadotrophic hypogonadism.

E Kallmann's syndrome

Chromosomal disorders such as Klinefelter syndrome, which occur due to loss, gain or rearrangement of one or more chromosomes, have no clear pattern of inheritance and carry a low risk of inheritance in relatives.

B Down syndrome

Down syndrome is caused by trisomy 21 and is of course associated with learning difficulties, rather than the specific features of hypoandrogenism seen here.

C Fragile-X syndrome

Fragile-X syndrome is associated with learning difficulties and macro-orchidism rather than the small testes seen here.

D Hypogonadotropic hypogonadism

We can see from the blood results that FSH is significantly elevated, ruling out hypogonadotrophic hypogonadism.

E Kallmann's syndrome

Kallmann syndrome is caused by defective release of GnRH, due to failure of development of the olfactory bulb. LH and FSH are reduced, and patients suffer from anosmia.

Rate this question:

A 64-year-old woman with type II diabetes comes to the clinic for investigation of chronic diarrhoea. She is taking metformin 2.5 g / day and gliclazide 160 mg. Additional medication includes simvastatin 40 mg and aspirin 75 mg.

On examination, she has a body mass index (BMI) of 28 and looks well; abdominal examination is unremarkable. Her blood pressure (BP) is 145/82 mmHg, with no postural drop. There is no evidence of peripheral neuropathy.

Investigations:

Hb	13.9 g/dl
WCC	6.1×10^9/l
PLT	229×10^9/l
Na^+	139 mmol/l
K^+	4.6 mmol/l
Cr	130 µmol/l
Alb	40 g/l
ALT	35 U/l
ESR	13 mm/hr

Small bowel biopsy normal and colonoscopy is unremarkable.

Which of the following is the most likely diagnosis?

A Autonomic neuropathy

B Bile salt malabsorption

C Chronic pancreatitis

D Coeliac disease

On examination, she has a body mass index (BMI) of 28 and looks well; abdominal examination is unremarkable. Her blood pressure (BP) is 145/82 mmHg, with no postural drop. There is no evidence of peripheral neuropathy.

Investigations:

Hb	13.9 g/dl
WCC	6.1×10^9/l
PLT	229×10^9/l
Na^+	139 mmol/l
K^+	4.6 mmol/l
Cr	130 µmol/l
Alb	40 g/l
ALT	35 U/l
ESR	13 mm/hr

Small bowel biopsy normal and colonoscopy is unremarkable.

Which of the following is the most likely diagnosis?

A	Autonomic neuropathy
B	Bile salt malabsorption
C	Chronic pancreatitis
D	Coeliac disease
E	NSAID related colitis

Explanation

B Bile salt malabsorption

High-dose metformin is thought to interfere with the enterohepatic circulation of bile salts, leading to reduced reabsorption of bile salts from the ileum. Diarrhoea, in association with metformin therapy, can often be avoided with slow up-titration of the dose.

A Autonomic neuropathy

Given the lack of peripheral neuropathy and no postural drop in blood pressure, significant autonomic neuropathy is very unlikely.

C Chronic pancreatitis

Clinically significant chronic pancreatitis is associated with malabsorption. The albumin of 40 counts against significant malabsorption.

D Coeliac disease

Coeliac disease is associated with anaemia and evidence of malabsorption on biochemistry, neither of which is seen here. The small bowel biopsy effectively rules this out.

E NSAID related colitis

Abnormalities on colonic biopsy would be expected in patients with NSAID-related colitis.

Rate this question:

Next Question

You see a new patient in a Diabetic Clinic who was started on metformin three years ago. His weight is maintained at around 70 kg. His GP has carried out some routine blood tests, including his HbA_{1c}. The patient has a history of ischaemic heart disease and heart failure, hypertension and chronic kidney disease (serum creatinine: 180 µmol/l, eGFR: 26).

His medications are as follows:

metformin	1 g bd
ramipril	10 mg od
aspirin	75 mg od
clopidogrel	75 mg od
simvastatin	40 mg od
nifedipine	20 mg od
nicorandil	20 mg bd
furosemide	80 mg bd
isosorbide mononitrate	40 mg bd

Venous HbA_{1c} is 108mmol/mol

Which one of the following antidiabetic regimens would you institute?

A Add in glicazide and pioglitazone

B Add in glicazide alone

C Add in pioglitazone alone

D Add in nocturnal insulin

tests, including his HbA_{1c}. The patient has a history of ischaemic heart disease and heart failure, hypertension and chronic kidney disease (serum creatinine: 180 µmol/l, eGFR: 26).

His medications are as follows:

metformin	1 g bd
ramipril	10 mg od
aspirin	75 mg od
clopidogrel	75 mg od
simvastatin	40 mg od
nifedipine	20 mg od
nicorandil	20 mg bd
furosemide	80 mg bd
isosorbide mononitrate	40 mg bd

Venous HbA_{1c} is 108mmol/mol

Which one of the following antidiabetic regimens would you institute?

A Add in glicazide and pioglitazone

B Add in glicazide alone

C Add in pioglitazone alone

D Add in nocturnal insulin

E Stop his metformin and start daily insulin

E Stop his metformin and start daily insulin

Explanation

E Stop his metformin and start daily insulin

This patient has very poor diabetes control with end organ damage (ischaemic heart disease with heart failure and kidney disease). He already has renal impairment, with an eGFR <30, so metformin is contraindicated and sulfonylureas are not preferable due to the high risk of hypoglycaemia in kidney disease.

A Add in glicazide and pioglitazone

Gliclazide is not preferable since the use with an eGFR increases the risk of hypoglycaemia. Pioglitazone is contraindicated in heart failure.

B Add in glicazide alone

Gliclazide is a sulfunyluria and it is best avoided, since an eGFR of 26 increases the risk of hypoglycaemia.

C Add in pioglitazone alone

Pioglitazone is only indicated as second-line therapy if sulfonylureas are contraindicated, as in this case, but is contraindicated in heart failure.

D Add in nocturnal insulin

Nocturnal insulin would be useful as an adjunct to oral agents providing basal insulin cover; since the option of oral agents is limited due to possible adverse effects, a

A 32-year-old man who has had diabetes mellitus for 27 years comes to the clinic for review. He has bilateral lower limb sensory loss consistent with peripheral neuropathy and background diabetic retinopathy, but is otherwise well.

Current insulin regime is 8 U TDS of short-acting insulin (Actrapid®) with 20 U/ day of long-acting insulin (Insulotard®). Apart from recurrent nocturnal hypoglycaemia (4 times/week), he feels he is doing well. His BP is 135/70 mmHg, with pulse 80/min and regular. His BMI is 23. HbA1c is 66 mmol/mol (8.2%) and a recent creatinine was measured at 135 micromol/l. Morning glucoses are in the range of 6–22 mmol/l.

Which of the following is the most appropriate change in his regimen?

A	Reduce his Actrapid® by 6 units/day
B	Reduce his Insulotard® by 6 units/day
C	Change his Insulotard® to insulin glargine at 20 units/day
D	Increase his Actrapid® by 6 units/day
E	Change his regime to 12 units of Mixtard® twice/day

Submit

10:23
594-042-7551
Leave

Explanation

C	Change his Insulotard® to insulin glargine at 20 units/day

This patient is missing his HbA1c target and suffering nocturnal hypos, as evidenced by his symptoms and some of the morning glucose values (22 mmol/l being potentially reflective of a counter-regulatory response to hypoglycaemia). Because he is missing the HbA1c target, it would not really be appropriate to reduce his insulin dose. Switching to glargine is likely to reduce the risk of hypoglycaemia whilst improving target achievement, because it is a 'peak-less' insulin.

A	Reduce his Actrapid® by 6 units/day

The profile of glucose testing suggests possible episodes of hypoglycaemia at night; as such, reducing the dose of Actrapid® won't impact significantly on this patient's glucose control.

B	Reduce his Insulotard® by 6 units/day

Given that the HbA1c is above target, this is suboptimal versus switching to an insulin analogue.

D	Increase his Actrapid® by 6 units/day

This won't significantly impact on nocturnal hypoglycaemia, but may drive increased food intake and suboptimal weight control.

E	Change his regime to 12 units of Mixtard® twice/day

BD mixed insulin is not tailored as appropriately to meal times as a basal bolus regimen, and as such it isn't

Audio Video Share Participants More

10:24
594-042-7551
Leave

The profile of glucose testing suggests possible episodes of hypoglycaemia at night; as such, reducing the dose of Actrapid® won't impact significantly on this patient's glucose control.

B	Reduce his Insulotard® by 6 units/day

Given that the HbA1c is above target, this is suboptimal versus switching to an insulin analogue.

D	Increase his Actrapid® by 6 units/day

This won't significantly impact on nocturnal hypoglycaemia, but may drive increased food intake and suboptimal weight control.

E	Change his regime to 12 units of Mixtard® twice/day

BD mixed insulin is not tailored as appropriately to meal times as a basal bolus regimen, and as such it isn't recommended for patients with type 1 diabetes.

Rate this question:

Next Question

© Pastest 2019

Audio Video Share Participants More

10:24
594-042-7551
Leave

A 57-year-old non-insulin-dependent diabetic man presented to the Emergency Department with sudden onset of shortness of breath. He was commenced on insulin 4 months ago due to persistent hyperglycaemia despite being on metformin 1 g twice daily (bd) and gliclazide 160 mg bd, and the oral medications were continued.

Since being on insulin, he has noticed a weight gain of about 10 kg. He has been a heavy consumer of alcohol and has been treated on multiple occasions for withdrawal symptoms. Other medication includes ramipril, aspirin and atorvastatin.

On examination, he had bilateral pitting oedema up to the knees and facial puffiness. Auscultation revealed bilaterally decreased air entry and widespread crackles. Jugular vein pressure (JVP) was not visualised. Investigations revealed a normal renal, liver and cardiac profile. Electrocardiogram (ECG) was normal. An echocardiogram revealed a slightly reduced ejection fraction.

An admission chest X-ray is shown below.

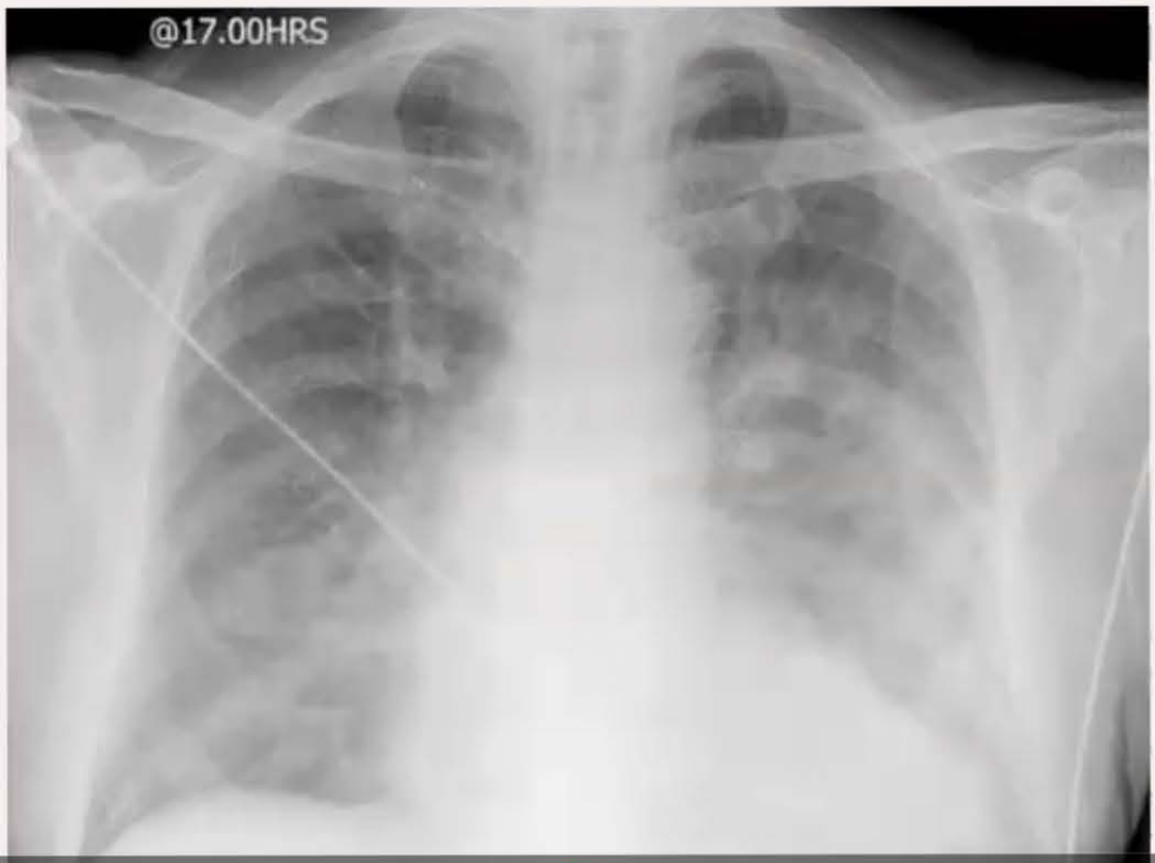

Audio
Video
Share
Participants
More

10:26
594-042-7551
Leave

sa/3.0) or GFDL (http://www.gnu.org/copyleft/fdl.html)], from Wikimedia Commons

Investigations:

Haemoglobin (Hb)	102 g/dl (mean corpuscular volume 104)
White cell count (WCC)	7.1×10^9/l
Platelets (PLT)	110×10^9/l
Sodium (Na^+)	139 mmol/l
Potassium (K^+)	4.5 mmol/l
Creatinine	90 µmol/l
HbA1c	55 mmol/mol

Which of the following would be the most appropriate management step for this patient?

A Discontinue insulin

B Reduce the insulin dosage

C Fluid restriction

D Oral furosemide and thiamine supplementation

E Trial of bisoprolol

32889

Submit

Audio Video Share Participants More

10:28
594-042-7551
Leave

D Oral furosemide and thiamine supplementation

This is a well-established but largely under-recognised clinical scenario of insulin-related worsening of heart failure and fluid overload, which occurs because insulin itself promotes salt and water retention. Thiamine deficiency may also have contributed to his heart failure symptoms. Management of choice is with furosemide to promote salt and water excretion, and thiamine in view of his excessive alcohol consumption. Once his fluid status is stable, if he still has symptoms of heart failure, addition of a cardioselective beta blocker such as bisoprolol may be of value.

A Discontinue insulin

HbA1c is virtually at target, and discontinuing insulin risks a significant negative impact on target attainment.

B Reduce the insulin dosage

Reducing the insulin dose without additional blood glucose lowering therapy runs the risk of deterioration in HbA1c.

C Fluid restriction

Fluid restriction alone won't provide sufficient impact on fluid status to reduce symptoms of heart failure.

E Trial of bisoprolol

Beta blockade may improve symptoms of heart failure, but only after fluid overload has been treated with diuretics.

Rate this question
Audio Video Share Participants More

You review a 42-year-old woman who presents with feelings of anxiety. She has lost weight over the past few months and describes palpitations. She has visited her general practitioner (GP) three times over the past six months and been prescribed a selective serotonin uptake inhibitor (SSRI), although her condition continues to worsen. Her blood pressure (BP) is 122/70 mmHg, with pulse 88/min and regular, and she has a fine tremor.

The GP has checked some thyroid function tests:

Thyroid-stimulating hormone (TSH)	0.05 mU/l (0.4–5.0)
Free thyroxine (T_4)	20.1 pmol/l (10–22)
Free triiodothyronine (T_3)	12.5 pmol/l (5–10)

What is the best treatment for this woman's underlying condition?

A Reassurance

B Propranolol

C Paroxetine

D Carbimazole

E Thyroxine

Submit

10:33
594-042-7551
Leave

D Carbimazole

This woman has triiodothyronine (T_3) thyrotoxicosis. Isolated elevation in T_3 accompanied by a thyroxine (T4) in the normal range is associated with around 5% of cases of thyrotoxicosis. Thyrotoxicosis is 10 times more common in women than men in the UK. Prevalence is approximately 2% of the female population, with an annual incidence of 3 per 1000 women. Graves' disease is the commonest cause of thyrotoxicosis; other causes include toxic multinodular goitre and toxic adenoma. Assessment of thyrotoxicosis includes thyroid function tests, thyroid autoantibodies and radionucleotide thyroid scanning, where the diagnosis is uncertain. Carbimazole is the mainstay of initial management of thyrotoxicosis, with propylthiouracil an alternative in patients who fail to tolerate carbimazole or for whom it is unsuitable.

A Reassurance

Reassurance alone is inappropriate here, since with suppressed TSH, T_4 at the upper limit of normal and elevated T_3, this patient has confirmed thyrotoxicosis.

B Propranolol

Although propranolol may be useful for relief of symptoms in the early stages of thyrotoxicosis, use as monotherapy is not appropriate in this situation.

C Paroxetine

Therapy for depression may be required, but her mood should be reassessed once thyroid equilibrium is established.

E Thyroxine

Audio Video Share Participants More

per 1000 women. Graves' disease is the commonest cause of thyrotoxicosis; other causes include toxic multinodular goitre and toxic adenoma. Assessment of thyrotoxicosis includes thyroid function tests, thyroid autoantibodies and radionucleotide thyroid scanning, where the diagnosis is uncertain. Carbimazole is the mainstay of initial management of thyrotoxicosis, with propylthiouracil an alternative in patients who fail to tolerate carbimazole or for whom it is unsuitable.

A Reassurance

Reassurance alone is inappropriate here, since with suppressed TSH, T_4 at the upper limit of normal and elevated T_3, this patient has confirmed thyrotoxicosis.

B Propranolol

Although propranolol may be useful for relief of symptoms in the early stages of thyrotoxicosis, use as monotherapy is not appropriate in this situation.

C Paroxetine

Therapy for depression may be required, but her mood should be reassessed once thyroid equilibrium is established.

E Thyroxine

Thyroxine is not indicated, given that TSH is suppressed, T_4 is at the upper end of the normal range and T_3 is elevated.

Rate this question:

Next Question

Rana Alnasser's screen

10:33
594-042-7551
Leave
MyPastest
https://mypastest.pastest.com

A 25-year-old woman is attending clinic for follow-up. She has a history of multiple previous fractures and precocious puberty.

On examination, she has café-au-lait skin pigmentation. Her pulse rate is 100 beats/min and regular and she has sweaty palms. Her thyroid function tests showed a raised fT4 at 23.4 pmol/l and a low TSH at 0.09 mIU/l. Her bone profile (calcium, phosphate, ALP, PTH and Vitamin D) is normal.

Which of the following is the most likely pathology?

A	Turner syndrome
B	Neurofibromatosis type 1
C	Paget's disease
D	McCune-Albright syndrome
E	Osteitis fibrosa cystica

Submit

Audio
Video
Share
Participants
More

10:34
594-042-7551
Leave
MyPastest
https://mypastest.pastest.com

A 25-year-old woman is attending clinic for follow-up. She has a history of multiple previous fractures and precocious puberty.

On examination, she has café-au-lait skin pigmentation. Her pulse rate is 100 beats/min and regular and she has sweaty palms. Her thyroid function tests showed a raised fT4 at 23.4 pmol/l and a low TSH at 0.09 mIU/l. Her bone profile (calcium, phosphate, ALP, PTH and Vitamin D) is normal.

Which of the following is the most likely pathology?

Your answer was correct

A Turner syndrome

B Neurofibromatosis type 1

C Paget's disease

D McCune-Albright syndrome

E Osteitis fibrosa cystica

Explanation

D McCune-Albright syndrome

McCune-Albright syndrome is due to a mutation in a G-protein. This results in variable clinical presentations:

Audio Video Share Participants More

10:34

D McCune-Albright syndrome

McCune–Albright syndrome is due to a mutation in a G-protein. This results in variable clinical presentations:

- Precocious puberty (typically gonadotropin-independent). This includes breast development, genital maturation (with or without pubic hair growth), increased height velocity and macroorchidism in males.
- Café-au-lait pigmentation. This consists of spots ranging from light brown to dark brown in colour. These often display a segmental distribution and frequently are predominant on one side of the body without crossing the midline; these spots must be differentiated from those characteristic of neurofibromatosis.
- Polyostotic fibrous dysplasia. Multiple pathological fractures may be prominent early in the history; in many cases, bony involvement is found to predominate clinically on one side; clinical manifestations include gait anomalies, visible bony deformities (including abnormal bone growths of the skull), bone pain and joint stiffness with pain.
- Hyperthyroidism, which in infants can result in failure to thrive.

There is an increased risk of osteosarcoma and other connective tissue tumours, especially if the patient has had multiple radiographs of affected areas. In relation to precocious puberty, the patient is at increased risk of developing breast carcinoma. The increased risk of osteosarcoma is in the setting of polyostotic fibrous dysplasia, although it still has an overall incidence of only around 1%.

Rana Alnasser's screen

C Paget's disease

It is a disorder of bone remodelling with increased osteoclastic activity and bone resorption followed by compensatory osteoblastic activity. The structure of the newly formed bone is disorganized, resulting in weakness and fracture susceptibility. It is more prevalent above the age of 65, and markedly raised ALP is typical with normal calcium and phosphate levels.

E Osteitis fibrosa cystica

This is a skeletal disorder resulting in loss of bone mass, which is replaced with fibrous tissue (peri-trabecular fibrosis) and the formation of cyst-like brown tumours in and around the bone. Osteitis fibrosis cystica is caused by hyperparathyroidism, which stimulates osteoclastic bone resorption. Clinical presentation is one of hyperparathyroidism with the addition of bone fractures. PTH and serum calcium will also be elevated.

© Pastest 2019

An overweight 68-year-old woman with a 5-year history of type 2 diabetes mellitus attends for her annual review. She is currently being treated with metformin (2 g total daily dose).

Investigations:

HbA1C	98.91 mmol/mol (11.2%)
eGFR	24
Creatinine	240 µmol/l
Total cholesterol	7.5 mmol/l

Which of the following represents the most appropriate therapeutic option for this patient?

A Start gliclazide instead of metformin

B Start gliclazide in addition to metformin

C Start insulin and continue metformin

D Start a statin

E Start insulin and stop metformin

Submit

An overweight 68-year-old woman with a 5-year history of type 2 diabetes mellitus attends for her annual review. She is currently being treated with metformin (2 g total daily dose).

Investigations:

HbA1C	98.91 mmol/mol (11.2%)
eGFR	24
Creatinine	240 µmol/l
Total cholesterol	7.5 mmol/l

Which of the following represents the most appropriate therapeutic option for this patient?

Your answer was correct

A Start gliclazide instead of metformin

B Start gliclazide in addition to metformin

C Start insulin and continue metformin

D Start a statin

E Start insulin and stop metformin

Explanation

E Start insulin and stop metformin

diabetes are initiated on a twice-daily mixed insulin regime, with conversion to a basal bolus regime as an option if sufficient control is not achieved.

A Start gliclazide instead of metformin

Her HbA_{1c} is very high, and therefore the initiation of insulin is more appropriate in order to achieve more rapid glycaemic control. In terms of her renal function, gliclazide could cause hypoglycaemia since its clearance will be delayed.

B Start gliclazide in addition to metformin

Metformin has to be discontinued once eGFR is <30. Gliclazide can be used, but there is the risk of hypoglycaemia

C Start insulin and continue metformin

Although metformin enhances insulin sensitivity and can be used as adjunctive therapy to insulin, it has to be discontinued in our case since eGFR is <30.

D Start a statin

The priority is to improve the glycaemic control. Once this is achieved, lipid management with a statin can be considered.

Rate this question:

Next Question

Previous Q... Tag Questi... Feedback End Session

A young woman comes to the clinic with the diagnosis of polycystic ovarian syndrome (PCOS) and decides she would like some treatment. She tells you that her facial hair and acne cause her a great deal of stress. She has a BMI of 23. She is not currently interested in having children and is currently on the oral contraceptive pill (COCP).

Which one of the following would be the most appropriate advice?

A	There is no treatment available
B	Losing weight will significantly impact on her symptoms
C	Clomifene is the most appropriate intervention
D	Metformin is effective in controlling hirsuitism and acne
E	Co-cyprindiol may be more effective than the COCP

70810

Submit

A young woman comes to the clinic with the diagnosis of polycystic ovarian syndrome (PCOS) and decides she would like some treatment. She tells you that her facial hair and acne cause her a great deal of stress. She has a BMI of 23. She is not currently interested in having children and is currently on the oral contraceptive pill (COCP).

Which one of the following would be the most appropriate advice?

Your answer was correct

A	There is no treatment available
B	Losing weight will significantly impact on her symptoms
C	Clomifene is the most appropriate intervention
D	Metformin is effective in controlling hirsuitism and acne
E	Co-cyprindiol may be more effective than the COCP

Explanation

E	Co-cyprindiol may be more effective than the COCP

Co-cyprindiol because it contains cyproterone, an anti-androgen, may be more effective than the COCP in controlling acne and hirsuitism and acne in PCOS.

COCP

Explanation

E Co-cyprindiol may be more effective than the COCP

Co-cyprindiol because it contains cyproterone, an anti-androgen, may be more effective than the COCP in controlling acne and hirsuitism and acne in PCOS.

A There is no treatment available

Co-cyprindrol may offer incremental benefit versus the COCP alone in managing symptoms of hyperandrogenism.

B Losing weight will significantly impact on her symptoms

This patient's BMI is in the normal range, hence weight loss is likely to have very little impact on her current symptoms.

C Clomifene is the most appropriate intervention

Clomifene is used to induce ovulation in PCOS; hence it is not of value here.

D Metformin is effective in controlling hirsuitism and acne

A Cochrane meta-analysis has suggested that metformin is not effective in controlling hirsuitism and acne versus other options such as the COCP or co-cyprindrol.

Rate this question:

10:40
594-042-7551
Leave
MyPastest
https://mypastest.pastest.com

A 55-year-old man presents to clinic and complains of tiredness, weakness and loss of body hair. He has recently split up with his partner and he cites loss of sexual function as one reason for this occurring. There is no past medical history of note apart from mild essential hypertension, for which he takes amlodipine.

On examination, pulse is 90/min and BP 100/50 mmHg. He is of normal appearance and has normal secondary sexual characteristics, although his body hair is fine and sparse. He also has bitemporal hemianopia. Routine bloods reveal mildly elevated potassium of 5.5 mmol/l. TSH is in the normal range.

What test would be most useful from those listed?

A	High-dose dexamethasone suppression test
B	Insulin tolerance test
C	Serum prolactin
D	Random serum cortisol
E	Serum glucose

32867

Submit

Audio
Video
Share
Participants
More

10:42

MyPastest
https://mypastest.pastest.com

A 55-year-old man presents to clinic and complains of tiredness, weakness and loss of body hair. He has recently split up with his partner and he cites loss of sexual function as one reason for this occurring. There is no past medical history of note apart from mild essential hypertension, for which he takes amlodipine.

On examination, pulse is 90/min and BP 100/50 mmHg. He is of normal appearance and has normal secondary sexual characteristics, although his body hair is fine and sparse. He also has bitemporal hemianopia. Routine bloods reveal mildly elevated potassium of 5.5 mmol/l. TSH is in the normal range.

What test would be most useful from those listed?

A	High-dose dexamethasone suppression test
B	Insulin tolerance test
C	Serum prolactin
D	Random serum cortisol
E	Serum glucose

Explanation

C	Serum prolactin

This clinical history is highly suggestive of a pituitary

Explanation

C	Serum prolactin

This clinical history is highly suggestive of a pituitary macroadenoma. As the patient is of normal appearance, the differential diagnosis is that of prolactinoma or a non-functioning pituitary adenoma. Therefore, serum prolactin is therefore of great importance. A Synacthen™ test is an adequate measure of cortisol reserve and would be the next most important test. MRI pituitary is important to document the size and invasion of the pituitary tumour, but would be done after a Synacthen™ test and serum prolactin to confirm the diagnosis and evaluate the most appropriate surgical approach.

A	High-dose dexamethasone suppression test

A high-dose dexamethasone suppression test is used in the diagnostic workup for Cushing syndrome, which is effectively ruled out here by the normal appearance and normal blood pressure.

B	Insulin tolerance test

Insulin tolerance testing is used in the work-up for growth hormone deficiency, which at this stage isn't appropriate until an MRI has taken place and other pituitary hormones have been profiled.

D	Random serum cortisol

Cortisol is subject to pulsatile release, and therefore random measurement is not useful in the work-up for possible pituitary tumour.

10:29

MyPastest
https://mypastest.pastest.com

A 58-year-old woman with a previous psychiatric history presents to the Emergency Department for review with severe left loin pain.

Medication of note includes paroxetine, which was started some 6 months earlier by her GP.

On examination, her BP is elevated at 155/80 mmHg, pulse is 95/min and regular and she is in pain. Examination of the abdomen reveals severe left loin pain.

Investigations:

Hb	13.2 g/dl
WCC	9.9×10^9/l
PLT	188×10^9/l
Na^+	137 mmol/l
K^+	4.2 mmol/l
Creatinine	124 µmol/l
Ca^{++}	3.2 mmol/l
Phosphate	0.7 mmol/l
KUB	Evidence of left renal stones

Which of the following is the most likely diagnosis in this case?

A Hypoparathyroidism

B Primary hyperparathyroidism

C Secondary hyperparathyroidism

Rana Alnasser's screen

Medication of note includes paroxetine, which was started some 6 months earlier by her GP.

On examination, her BP is elevated at 155/80 mmHg, pulse is 95/min and regular and she is in pain. Examination of the abdomen reveals severe left loin pain.

Investigations:

Hb	13.2 g/dl
WCC	9.9×10^9/l
PLT	188×10^9/l
Na^+	137 mmol/l
K^+	4.2 mmol/l
Creatinine	124 µmol/l
Ca^{++}	3.2 mmol/l
Phosphate	0.7 mmol/l
KUB	Evidence of left renal stones

Which of the following is the most likely diagnosis in this case?

A Hypoparathyroidism

B Primary hyperparathyroidism

C Secondary hyperparathyroidism

D Multiple myeloma

E Paget's disease

PLT	188×10^9/l
Na^+	137 mmol/l
K^+	4.2 mmol/l
Creatinine	124 µmol/l
Ca^{++}	3.2 mmol/l
Phosphate	0.7 mmol/l
KUB	Evidence of left renal stones

Which of the following is the most likely diagnosis in this case?

Your answer was correct

A Hypoparathyroidism

B Primary hyperparathyroidism

C Secondary hyperparathyroidism

D Multiple myeloma

E Paget's disease

Explanation

B Primary hyperparathyroidism

In this case, there is confirmed nephrolithiasis and a history of previous psychiatric disorder. In the presence of hypercalcaemia and hypophosphataemia, this is highly suggestive of hyperparathyroidism. The condition occurs

Rana Alnasser's screen

B Primary hyperparathyroidism

In this case, there is confirmed nephrolithiasis and a history of previous psychiatric disorder. In the presence of hypercalcaemia and hypophosphataemia, this is highly suggestive of hyperparathyroidism. The condition occurs most frequently in postmenopausal women, and the prevalence in this group may be as high as 3%. The differential here is between parathyroid hyperplasia and a solitary parathyroid adenoma. Technetium (99mTc) sestamibi scanning has a high specificity and sensitivity for parathyroid adenoma. This patient already has symptoms of primary hyperparathyroidism, so that surgery is the definitive management. A sestamibi scan is most likely to inform on the location of any adenoma prior to a surgical approach.

A Hypoparathyroidism

This is associated with low levels of calcium and elevated phosphate because of PTH deficiency.

C Secondary hyperparathyroidism

Secondary hyperparathyroidism occurs as a result of chronic renal impairment, and creatinine here is relatively normal at 124.

D Multiple myeloma

Multiple myeloma is not associated with renal stone disease, and is rarely associated with significant hypercalcaemia.

E Paget's disease

Rana Alnasser's screen

A Hypoparathyroidism

This is associated with low levels of calcium and elevated phosphate because of PTH deficiency.

C Secondary hyperparathyroidism

Secondary hyperparathyroidism occurs as a result of chronic renal impairment, and creatinine here is relatively normal at 124.

D Multiple myeloma

Multiple myeloma is not associated with renal stone disease, and is rarely associated with significant hypercalcaemia.

E Paget's disease

Paget's disease is associated with normal calcium. Mild elevation in calcium may be seen in patients with Paget's who have prolonged bed rest.

Rate this question:

Next Question

Previous Q... Tag Questi... Feedback End Session

© Pastest 2019

Rana Alnasser's screen

10:31

You review a 19-year-old woman who has been referred by the Emergency Department after attending with a faint. She is noted, on routine blood testing in the department, to have a potassium level of 2.9 mmol/l with a serum bicarbonate of 30 mmol/l. In addition, her blood pressure on admission was elevated at 155/90 mmHg. She has no past medical history of note and is on no medications. You arrange some further blood tests, which reveal low renin and aldosterone levels. Urine diuretic screen is negative.

Which of the following represents the best treatment for her?

A	Potassium replacement
B	Ramipril
C	Spironolactone
D	Amiloride
E	Bumetanide

Submit

Rana Alnasser's screen

10:33
On
594-042-7551
Leave

D Amiloride

This woman presents with a hypokalaemic alkalosis and suppressed renin and aldosterone levels in the presence of hypertension. This is strongly suggestive of Liddle syndrome, an autosomal dominant condition thought to arise from a mutation in genes mapped to chromosome 16. This mutation leads to abnormality in the beta- or gamma-subunit of the highly selective epithelial sodium channel in the distal nephron. This results in activation of sodium/potassium exchange independent of circulating mineralocorticoid. Hypertension and hypokalaemia respond well to amiloride but not spironolactone, because amiloride acts directly on the sodium channel whereas spironolactone acts on the mineralocorticoid receptor. Hypokalaemia and alkalosis in normotensive individuals who have elevated plasma renin and aldosterone levels is suggestive of either Bartter or Gitelman syndrome.

A Potassium replacement

Potassium replacement is of value in the treatment of Bartter and Gitelman, but it isn't an option for Liddle because it doesn't improve blood pressure control.

B Ramipril

Angiotensin-converting enzyme (ACE) inhibition is of most value in the treatment of hyporeninaemic hyperaldosteronism, but it is less effective in the treatment of Liddle compared to amiloride.

C Spironolactone

Spironolactone is an intervention of choice in the treatment of hyporeninaemic hyperaldosteronism.

Audio Video Share Participants More

10:34

You review a 52-year-old farmer who rarely consults with medical services. He complains of ocular pain and loss of vision. High magnification slit lamp examination reveals neovascular tufts of capillaries at the pupillary margin. The pupil is poorly reactive. Retinal photography reveals bilateral cotton wool spots, hard exudates, aneurysms and small dot-and-blot haemorrhages. He has a past history of diabetes and hypothyroidism. You suspect rubeosis iridis and subsequent glaucoma. His blood pressure is 135/82 mmHg. The most recent HbA1c is measured at 61 mmol/mol, and his TSH is 2.5.

Which of the following is the most important preventative intervention to reduce the risk of glaucoma in this patient?

A Tighter control of blood pressure

B Tighter control of blood glucose

C Increased thyroxine dose

D Pan-retinal photocoagulation

E Oral acetazolamide

Submit

Previous Q... Skip Questi...

Rana Alnasser's screen

Explanation

D Pan-retinal photocoagulation

An important part of the work-up of rubeosis iridis is with fluorescein angiography to assess the extent of retinal ischaemia, and ultrasound. Once eye disease has progressed to rubeosis, the mainstay of therapy is pan-retinal photocoagulation to reduce the area of viable retina. Anti-VEGF agents and topical steroids may also be of value, but ultimately the prognosis is poor because of late stage at presentation.

B Tighter control of blood glucose

HbA1c, like blood pressure, is only slightly above target, hence any impact of tightening of blood glucose control on disease progression will be limited.

A Tighter control of blood pressure

There is limited scope to further improve blood pressure control here, and the patient already has advanced retinal disease, meaning any impact of improved blood pressure control on disease progression will be limited.

C Increased thyroxine dose

TSH is in the normal range, meaning there is gain to be had from increasing thyroxine.

E Oral acetazolamide

This is a potential intervention for acute glaucoma.

10:38
On
594-042-7551
Leave

rubeosis iridis

Rubeosis iridis or neovascularization ...
webeye.ophth.uiowa.edu

Rubeosis iridis or neovascularization ...
webeye.ophth.uiowa.edu

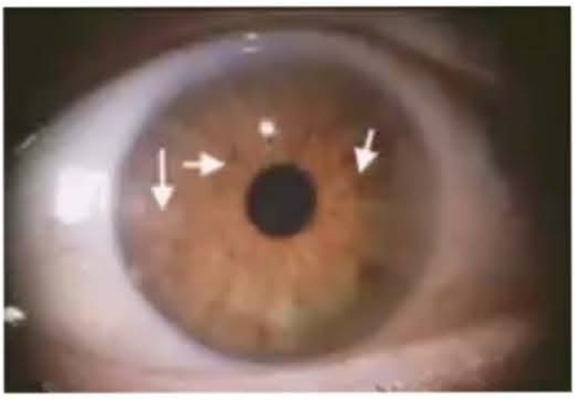

Rubeosis iridis in a case of PDR a ...
endotext.org

Rubeosis iridis or neovascularization ...
webeye.ophth.uiowa.edu

Ophthalmology spot diagnosis : Rubeosis ...
epomedicine.com

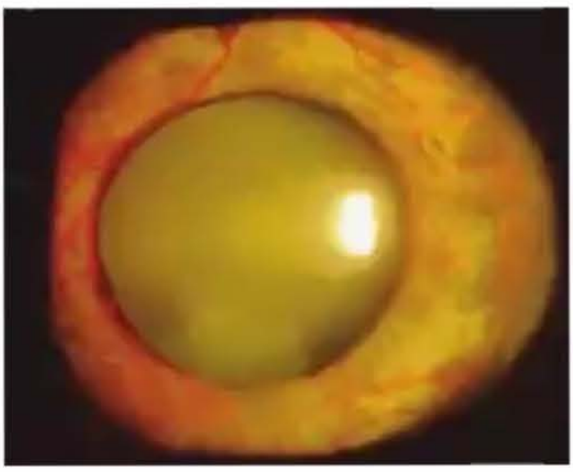

rubeosis iridis shows ...
researchgate.net

RUBEOSIS IRIDIS Stock Photo: 49181825 ...
alamy.com

Rubeosis Iridis - an overview ...
sciencedirect.com

Audio
Discover
Video
Updates
Share
Participants
Search
More

10:38
On
594-042-7551
Leave

t of Ophthalmology and Visual Sciences - The University ...

ridis or neovascularization of the iris in diabetes

ation of the iris ...

ubject to copyright. Learn more

ES

gte Rubeosis iridis bei prol...

showing superotemporal circumlinear corne...
researchgate.net

Glaucoma Managemen
pinterest.com

Audio
Video
Share
Participants
More

10:38

56% 08:38

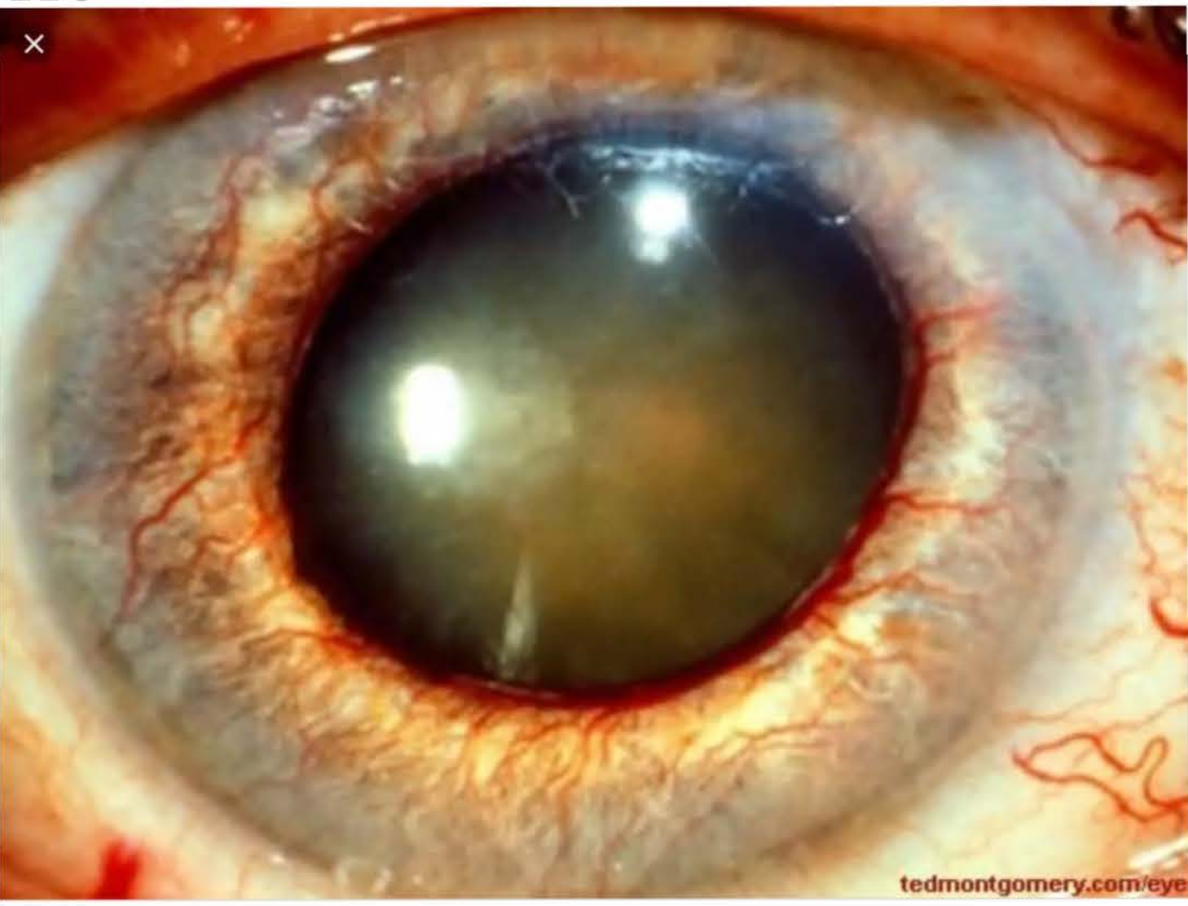

Ted Montgomery

Rubeosis Iridis

RubeosisIridis.jpg

Annotation Stop Share

Images may be subject to copyright. Learn more

RELATED IMAGES

Discover Updates Search Recent More

Rana Alnasser's screen

10:39
On
594-042-7551
Leave

A 29-year-old woman presents with tiredness and a swollen neck. You notice she is with a 6-week-old baby. She has a goitre on examination of the neck.

Investigations:

TSH	0.3 mU/l (0.4–5)
Total T4	199 nmol/l (58–174)
Total T3	3.31 pmol/l (1.07–3.18)
Free T4	46 nmol/l (10–22)
Free T3	2.1 pmol/l (5–10)

Radioiodine uptake is not increased on thyroid scanning. What diagnosis fits best with this clinical picture?

A Post-partum thyroiditis (PPT)

B Grave's disease

C Anxiety

D Riedel's thyroiditis

E Hashimoto's thyroiditis

Submit

Audio Video Share Participants More

A 29-year-old woman presents with tiredness and a swollen neck. You notice she is with a 6-week-old baby. She has a goitre on examination of the neck.

Investigations:

TSH	0.3 mU/l (0.4–5)
Total T4	199 nmol/l (58–174)
Total T3	3.31 pmol/l (1.07–3.18)
Free T4	46 nmol/l (10–22)
Free T3	2.1 pmol/l (5–10)

Radioiodine uptake is not increased on thyroid scanning. What diagnosis fits best with this clinical picture?

Your answer was incorrect

A Post-partum thyroiditis (PPT)

B Grave's disease

C Anxiety

D Riedel's thyroiditis

E Hashimoto's thyroiditis

Explanation

A Post-partum thyroiditis (PPT)

Explanation

A Post-partum thyroiditis (PPT)

PPT is a variant of chronic autoimmune thyroiditis (Hashimoto's thyroiditis), and is characterised by the presence of antimicrosomal antibodies. Histological examination of thyroid glands affected by PPT shows destructive lymphocytic thyroiditis. Hyperthyroidism may occur within 4 months of delivery, the commonest symptom being fatigue. Hypothyroidism may develop within 3–7 months of delivery; again, the commonest symptom is tiredness. Postpartum thyroid dysfunction is said to occur in up 10% of women during the first year after delivery.

E Hashimoto's thyroiditis

Hashimoto's thyroiditis is accompanied by hypothyroidism, and the thyroid function tests in our case are consistent with the opposite (hyperthyroidism).

B Grave's disease

Postpartum hyperthyroidism is differentiated from Graves' disease by a lack of increased uptake on thyroid scanning.

C Anxiety

The abnormal thyroid function tests point towards the diagnosis of thyrotoxicosis rather than simply anxiety symptoms.

D Riedel's thyroiditis

Rana Alnasser's screen

Riedel thyroiditis, or Riedel's thyroiditis (RT), is a rare,

10:45

MyPastest
https://mypastest.pastest.com

Pastest+

nephropathy, with a recent creatinine measured at 180 µmol/l, and microalbuminuria. Last year he received laser treatment to his left eye for severe retinopathy. He is currently treated with a Novomix 30 at a dose of 12 units BD. A recent HbA1c was measured at 59.56 (7.6%). You review his home glucose record and find that 2 h postprandial glucose is high, at 12 mmol/l, yet he appears to be suffering attacks of hypoglycaemia late in the afternoon before his evening meal, and occasionally before breakfast. His BMI is 22.

Which of the following represents the best advice with respect to his treatment irrespective of patient preference?

Your answer was correct

A	Reduce his portion size in an attempt to take in fewer calories
B	Alter his insulin to a basal bolus regime involving glargine and aspart
C	Increase his BD insulin to 14 units
D	Increase the proportion of short-acting insulin in his mixed insulin dose
E	Advise him to snack more in the middle of the afternoon and prior to going to bed

Explanation

glargine and aspart

This man has documented microvascular disease with proven retinopathy and nephropathy. In this population, optimal glycaemic control would be indicated by an HbA1c of 47.54 mmol/mol (<6.5%) if possible. Novorapid, as a short-acting insulin, and glargine as an insulin analogue are associated with less hypoglycaemia, would be the most appropriate choice for him.

A Reduce his portion size in an attempt to take in fewer calories

Reducing his portion size may impact on his postprandial blood glucose levels but will increase the risk of late hypoglycaemia.

C Increase his BD insulin to 14 units

Increasing his BD insulin would only exacerbate the problem of late between-dose hypoglycaemia.

D Increase the proportion of short-acting insulin in his mixed insulin dose

This may improve his postprandial blood glucose levels but may increase the risk of hypoglycaemia.

E Advise him to snack more in the middle of the afternoon and prior to going to bed

Snacking, but remaining on BD insulin, would only serve to increase his total energy intake and may worsen his glycaemic control.

16543

Rate this question:

10:45

A 38-year-old physiotherapist attended for a routine follow-up in the Diabetes Clinic. She was diagnosed with type 1 diabetes mellitus at the age of 11 and unfortunately had a history of both diabetic maculopathy and early diabetic nephropathy with microalbuminuria.

She complained of a 6-week history of raised, tender plaques over the shins (shown below) and, on further questioning, described painful wrists and ankles for the past 6 months.

Rana Alnasser's screen

By Warfieldian [CC BY-SA 3.0 (https://creativecommons.org/licenses/by-sa/3.0)], from Wikimedia Commons

Examination confirmed the presence of the plaques, over which there was clear skin thinning and telangiectasia. Her blood pressure is 147/84 mmHg. A urine dipstick revealed protein +1 and glucose +1.

What is the most useful next investigation?

A	Anti-nuclear antibody testing
B	Anti-cyclic citrullinated peptide (CCP) antibody testing
C	Serum complement measurement
D	Ankle and wrist X-ray
E	Immunoglobulin E (IgE) measurement

Submit

B Anti-cyclic citrullinated peptide (CCP) antibody testing

Anti-CCP is specific for rheumatoid arthritis, the most probable diagnosis here, and may be positive in advance of any joint destruction. It also stratifies those with rapid disease progression. It is therefore the most useful next step.

D Ankle and wrist X-ray

The plaques are probably unconnected to the wrist and ankle pain but are due to necrobiosis lipoidica diabeticorum. The condition is more common in women and presents in young adults or in early middle life. These erythematous plaques are due to small vessel damage causing partial necrosis of the dermal collagen and connective tissue, with a resulting histiocytic cellular response. The lesions are usually managed with support bandaging and use of topical steroids. The wrist and ankle pain is suggestive of possible arthritis. Both rheumatoid arthritis and type 1 diabetes may be associated with the human leukocyte antigen HLA-DR4.

Although ankle and wrist X-rays are useful in defining rheumatoid arthritis, the absence of changes should not delay treatment. Hence, CCP testing is potentially more useful at this stage of the disease.

A Anti-nuclear antibody testing

Anti-nuclear antibody testing is useful when systemic lupus erythematosus (SLE) is considered as the underlying diagnosis, although given that joint pains are limited to the wrists and ankles and there is an absence of a photosensitive rash, this is less likely vs a new diagnosis of rheumatoid arthritis.

useful at this stage of the disease.

A Anti-nuclear antibody testing

Anti-nuclear antibody testing is useful when systemic lupus erythematosus (SLE) is considered as the underlying diagnosis, although given that joint pains are limited to the wrists and ankles and there is an absence of a photosensitive rash, this is less likely vs a new diagnosis of rheumatoid arthritis.

C Serum complement measurement

Necrobiosis lipoidica is not associated with generalised complement activation, and so this parameter is likely to be normal.

E Immunoglobulin E (IgE) measurement

Necrobiosis lipoidica is associated with neither Churg-Strauss vasculitis nor generalised hypersensitivity, and thus IgE measurement has little utility here.

Rate this question:

Next Question

Previous Q... Tag Questi... Feedback End Session

Blog About Pastest Contact Us Help

© Pastest 2019

A 28-year-old woman presents to her GP complaining of tiredness and malaise, which came on after a short viral illness. She also has pain which appears to be referred to her lower jaw. On examination of the neck the GP notices that the thyroid gland appears to be generally tender and is nodular on palpation. TSH is measured at <0.05 mU/l (0.4-5.0), ESR is raised at 45 mm/h and a technetium scan reveals decreased thyroid uptake.

Which of the following is the most likely diagnosis?

A	Hashimoto's thyroiditis
B	Riedel's thyroiditis
C	Graves' disease
D	de Quervain's Thyroiditis
E	Pyogenic thyroiditis

18540

Submit

De Quervain's thyroiditis is the most common cause of a painful thyroid gland and causes hyperthyroidism initially, sometimes followed by transient hypothyroidism. The underlying cause is felt to be either a viral infection or the postviral inflammatory response. The condition is more common in females. The typical course of the disease consists of an acute phase, in which the main complaint is pain, although signs of hyperthyroidism may also be present. This is followed by a transient asymptomatic and euthyroid phase which evolves into the hypothyroid phase. The hypothyroid state may become permanent in 5–10% of patients, but the vast majority go on to the recovery phase, characterised by normalisation of thyroid structure and function. The treatment is consequently directed towards the control of pain and thyroid symptoms. Initial symptomatic hyperthyroidism can be treated with beta-blockade, but anti-thyroid drugs are of no value since the excess circulating thyroid hormone is due to the release of pre-existing thyroid hormone because of follicular damage rather than from increased synthesis. If hypothyroidism occurs in the late stages, replacement therapy is required and is guided by the TSH levels. Radionucleotide scanning reveals decreased uptake from the thyroid gland.

A Hashimoto's thyroiditis

Hashimoto's presents with symptoms of hypothyroidism. On examination there is often a hard goitre which is non-tender. Anti-thyroid peroxidise antibodies are usually raised.

B Riedel's thyroiditis

Riedel's thyroiditis is characterised by intense fibrosis of

tender. Anti-thyroid peroxidise antibodies are usually raised.

B Riedel's thyroiditis

Riedel's thyroiditis is characterised by intense fibrosis of the gland. Most patients remain euthyroid. Symptoms of tracheal compression can occur.

C Graves' disease

Radionucleotide scanning is useful in distinguishing between Graves' and other causes of thyrotoxicosis: it will show increased uptake in the whole gland in Graves' disease.

E Pyogenic thyroiditis

Pyogenic thyroiditis is rare and is associated with a pyogenic infection elsewhere. Patients can present with pain and swelling in the neck. and fever. TFTs are often normal.

Rate this question:

Next Question

Previous Q... Tag Questi... Feedback End Session

Blog About Pastest Contact Us Help

© Pastest 2019

Rana Alnasser's screen

A 17-year-old boy attends the clinic. He is worried as he has failed to enter puberty. He would like to form relationships with women but at the current time this is impossible. On examination he is 6ft 2 inches in height and has absent secondary sexual hair, a small penis and testes. On further questioning he admits to not having any sense of smell to speak of.

Investigations

Hb	12.1 g/dl
WCC	6.2×10^9/l
PLT	231×10^9/l
Na^+	139 mmol/l
K+	4.5 mmol/l
Creatinine	100 µmol/l
Testosterone	Very low
FSH	Low
LH	Low

Given the likely diagnosis, what appearance would you expect to see on cerebral magnetic resonance imaging (MRI)?

A Normal result

B Hypothalamic damage on MRI

C Empty sella

D Absent olfactory bulbs

Hb	12.1 g/dl
WCC	6.2 x 10^9/l
PLT	231 x 10^9/l
Na^+	139 mmol/l
K+	4.5 mmol/l
Creatinine	100 µmol/l
Testosterone	Very low
FSH	Low
LH	Low

Given the likely diagnosis, what appearance would you expect to see on cerebral magnetic resonance imaging (MRI)?

A Normal result

B Hypothalamic damage on MRI

C Empty sella

D Absent olfactory bulbs

E Hypertrophied olfactory bulbs

Submit

10:57
On
594-042-7551
Leave

Explanation

D Absent olfactory bulbs

Absent olfactory bulbs, correct. This boy is likely to have Kallmann syndrome, as evidenced by hypogonadotrophic hypogonadism and absent sense of smell. Absent olfactory bulbs are present on 75% of MRI scans in these patients. The syndrome results in an isolated gonadotrophin (GNRH) deficiency and, in turn, gonadal deficiencies. This causes loss of libido, loss of secondary sexual hair and amenorrhoea/erectile dysfunction.

B Hypothalamic damage on MRI

This patient should be managed with androgen replacement therapy. Fertility can be restored in the majority of patients with either pulsed GNRH or gonadotrophin therapy. Assessment of bone age and bone mineral density is also essential in these patients.

A Normal result

Although with this condition the absence of olfactory bulbs is more common. This is because Kallman syndrome is usually an x-linked mutation in the KAL-1 gene which encodes anosmin-1, causing loss of smell.

C Empty sella

This is more often associated with a defect in the diaphragm and extension into the subarachnoid space (a congenital abnormality), following a pituitary infarction or pituitary tumour treatment.

E Hypertrophied olfactory bulbs

Audio Video Share Participants More

11:00
On
594-042-7551
Leave

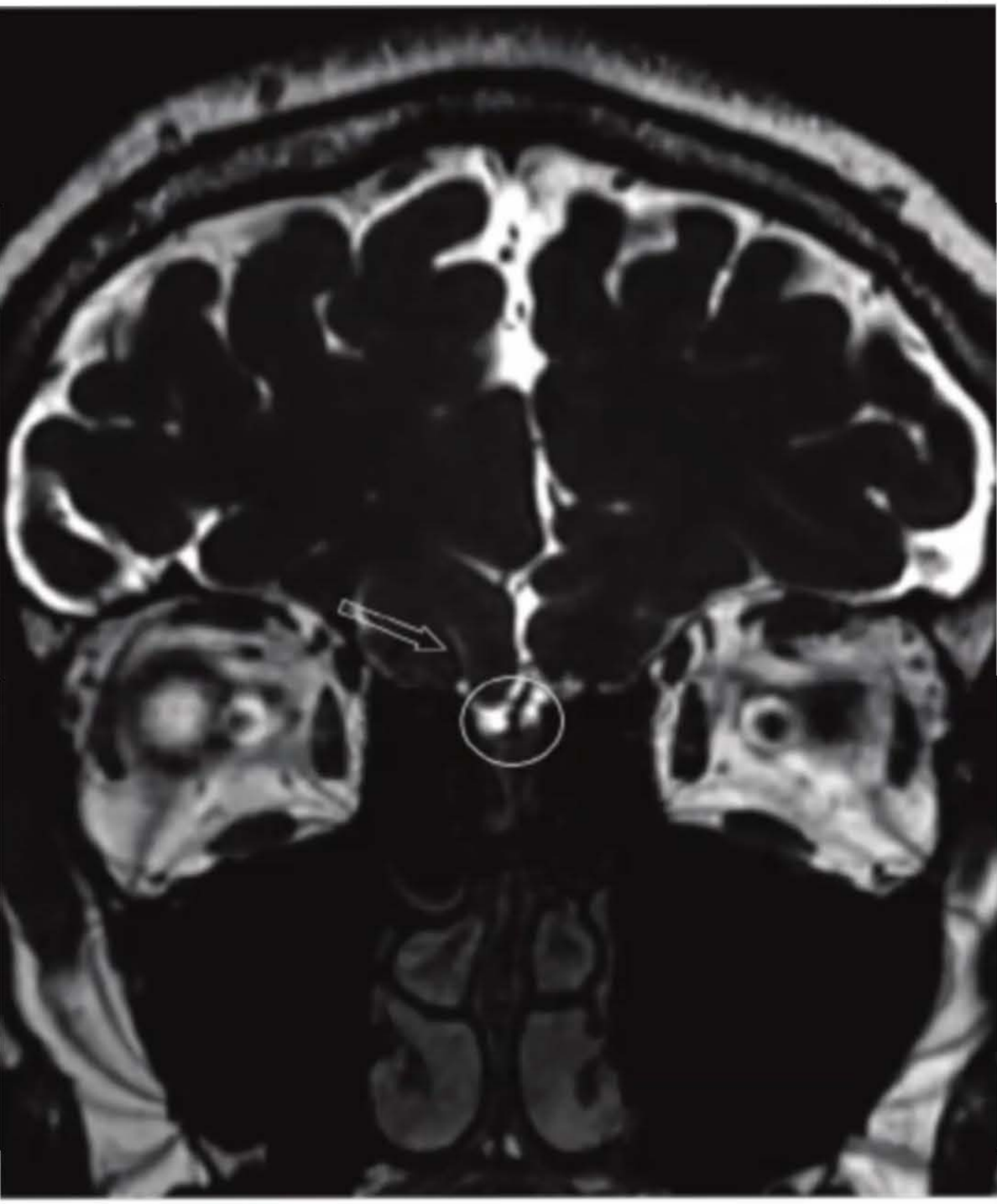

.researchgate.net

al T2 image of the case with Kallmann syndrome. Normal olfactory... |
oad Scientific Diagram

l scientific diagram | Coronal T2 image of the case with Kallmann syndrome. Normal olfactory sulcu
light arrow), olfactory sulcus was not seen on the left. Olfactory...

y be subject to copyright. Learn more
Stop Share
scover
Updates
Search
Recent
Mor
Audio
Video
Share
Participants
More

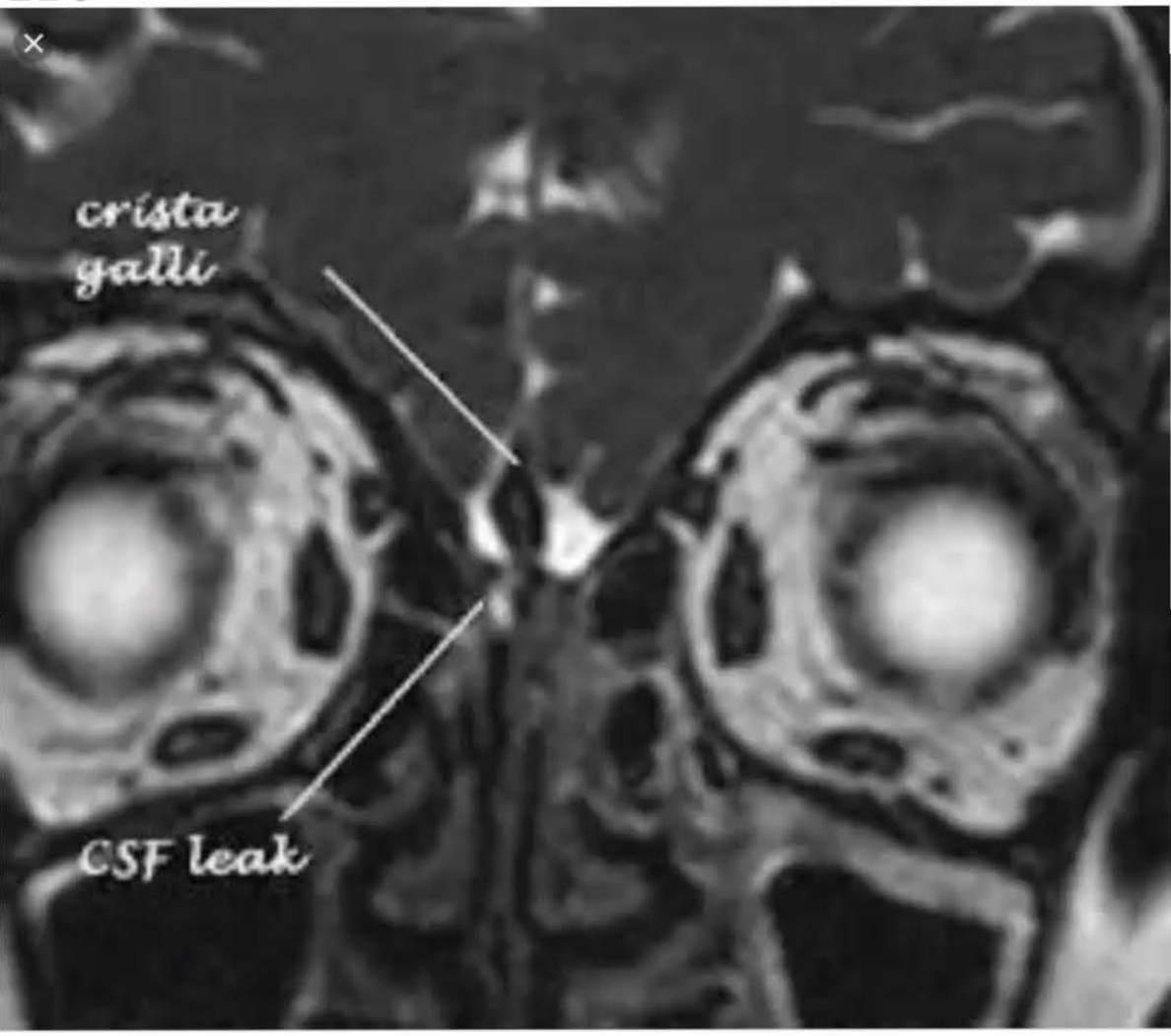

msgopalakrishnan.blogspot.com

M S Gopalakrishnan: Spontaneous CSF rhinorrhea - MRI CISS images - cribriform plate defect

25 year old lady with four months history of profuse watery discharge from right nostril. Anosmia in right nostril. No raised ICP feature...

Images may be subject to copyright. Learn more

RELATED IMAGES

Discover Updates Search Recent More

Rana Alnasser's screen

11:02

A 29-year-old woman, who has a 10-month-old baby, presents with neck and throat pain over the area of her thyroid. She tells you that she had a flu-like illness a week or so before the pain began. Her partner, who also attends the appointment, tells you she has been nervous and agitated over the past week. On examination, there is mild diffuse enlargement of the thyroid gland and it is tender to palpation. Her BP is 141/82 mmHg, and her pulse is 85/min and regular at rest. She has a slight tremor.

Investigations:

Hb	12.1 g/dl
WCC	6.1 x10^9/l
PLT	170 × 10^9/l
Na^+	139 mmol/l
K^+	4.6 mmol/l
Creatinine	100 µmol/l
TSH	<0.05 U/l
Anti-TPO	-
ESR	62 mm/hr
fT4	24.3 pmol/l

Radioiodine uptake on the isotope scan is decreased.

Which of the following forms of thyroiditis is the most likely diagnosis?

A Hashimoto's

B De Quervain's

Rana Alnasser's screen

Hb	12.1 g/dl
WCC	6.1 x10^9/l
PLT	170 × 10^9/l
Na^+	139 mmol/l
K^+	4.6 mmol/l
Creatinine	100 µmol/l
TSH	<0.05 U/l
Anti-TPO	-
ESR	62 mm/hr
fT4	24.3 pmol/l

Radioiodine uptake on the isotope scan is decreased.

Which of the following forms of thyroiditis is the most likely diagnosis?

A Hashimoto's

B De Quervain's

C Riedel's

D Graves'

E Postpartum

Submit

Rana Alnasser's screen

Explanation

B De Quervain's

De Quervain's thyroiditis, also known as subacute thyroiditis, is characterised by acute onset of thyroid tenderness after a short viral illness, with raised ESR but negative anti-thyroid antibodies. It is thought to be linked to a response to viral infection, although a range of different viruses such as influenza and Coxsackie B have been implemented in its development. The early stages are characterised by a period of thyrotoxicosis, and radioisotope scanning reveals decreased thyroid uptake. As the disease progresses, there are phases of euthyroidism and hypothyroidism, followed by a period of recovery to a euthyroid state once again. Management centres on controlling pain, with either non-steroidals or corticosteroids, and managing the symptoms of thyrotoxicosis, normally with beta blockade.

A Hashimoto's

Hashimoto's thyroiditis, also known as chronic lymphocytic thyroiditis, is an autoimmune disease in which the thyroid gland is gradually destroyed. Early on there may be no symptoms. Over time the thyroid may enlarge, forming a painless goitre. Some people eventually develop hypothyroidism with its accompanying weight gain, feeling tired, constipation, depression and general pains. The thyroid function tests in this scenario are in keeping with thyrotoxicosis. It is very unusual for Hashimoto's thyroiditis to present with negative anti-TPO antibodies. Neither is pain in the neck a feature of the disease.

C Riedel's

Riedel's thyroiditis, also known as chronic sclerosing thyroiditis, is a rare, chronic inflammatory disease of the

immunoglobulins bind to and activate thyrotropin receptors, causing the thyroid gland to grow and the thyroid follicles to increase synthesis of thyroid hormone. Graves' disease, along with Hashimoto's thyroiditis, is classified as an autoimmune thyroid disorder. In some patients, Graves' disease represents part of more extensive autoimmune processes leading to dysfunction of multiple organs (e.g. polyglandular autoimmune syndromes). Graves' disease is associated with pernicious anaemia, vitiligo, diabetes mellitus type 1, autoimmune adrenal insufficiency, systemic sclerosis, myasthenia gravis, Sjögren syndrome, rheumatoid arthritis and systemic lupus erythematosus. Painful goitre or neck pain with flu-like symptoms is not a characteristic of this condition.

E Postpartum

The peak incidence for postpartum thyroiditis is at month 6 post-delivery. There is an initial period of thyrotoxicosis, followed by hypothyroidism, then recovery, although a significant percentage – perhaps as high as 40% – eventually become permanently hypothyroid. Flu-like symptoms are not a feature.

Rate this question:

Next Question

Previous Q... Tag Questi... Feedback End Session

Blog About Pastest Contact Us Help

© Pastest 2019

A 72-year-old man presents to the endocrine clinic for review. He has been taking amiodarone for the past few months for short episodes of VT diagnosed after a myocardial infarction.

During the past 2 months, he has noticed weight loss and heat intolerance, with short runs of an irregular, fast heartbeat. In the clinic he has a BP of 112/82, pulse is 88 and regular. His BMI is 21. Thyroid function testing is abnormal, with a suppressed thyroid-stimulating hormone (TSH) suggestive of thyrotoxicosis. Radioiodine uptake scan is normal, as is serum interleukin 6 (IL-6). A most recent ECHO cardiogram is 38%.

His amiodarone is discontinued by the cardiologist after the repeat ECHO cardiogram and a 72 h tape, which shows paroxysmal AF but no episodes of VT.

Which one of the following options is the best initial therapy for him?

A	Prednisolone 40 mg/day
B	Carbimazole and potassium perchlorate therapy
C	Thyroidectomy
D	Radioiodine
E	Partial thyroidectomy

11:05
On
Pastest+
594-042-7551
Leave

A 72-year-old man presents to the endocrine clinic for review. He has been taking amiodarone for the past few months for short episodes of VT diagnosed after a myocardial infarction.

During the past 2 months, he has noticed weight loss and heat intolerance, with short runs of an irregular, fast heartbeat. In the clinic he has a BP of 112/82, pulse is 88 and regular. His BMI is 21. Thyroid function testing is abnormal, with a suppressed thyroid-stimulating hormone (TSH) suggestive of thyrotoxicosis. Radioiodine uptake scan is normal, as is serum interleukin 6 (IL-6). A most recent ECHO cardiogram is 38%.

His amiodarone is discontinued by the cardiologist after the repeat ECHO cardiogram and a 72 h tape, which shows paroxysmal AF but no episodes of VT.

Which one of the following options is the best initial therapy for him?

Your answer was correct

A Prednisolone 40 mg/day

B Carbimazole and potassium perchlorate therapy

C Thyroidectomy

D Radioiodine

E Partial thyroidectomy

Explanation

B Carbimazole and potassium perchlorate therapy

Audio Video Share Participants More

11:05
On
Pastest+
594-042-7551
Leave

B Carbimazole and potassium perchlorate therapy

This man probably has amiodarone-induced thyrotoxicosis (AIT) type 1, as exemplified by the presence of symptoms of thyrotoxicosis, normal radioiodine uptake and normal interleukin 6 (IL-6) levels. AIT type 1 results primarily from iodine excess and therefore increased hormone synthesis. Type 1 AIT is treated initially with a combination of anti-thyroid drugs and potassium perchlorate therapy.

A Prednisolone 40 mg/day

Prednisolone is a component of therapy for AIT type 2, which is thought to result from a direct toxic effect of amiodarone and is associated with thyroiditis, decreased radioiodine uptake on thyroid scan and raised IL-6 levels. Patients may eventually become hypothyroid because of the destruction of thyroid hormone-producing cells.

C Thyroidectomy

Surgery should be avoided if possible in a patient with relatively unstable cardiovascular disease; in the event that it is required, acute control of thyroid status is first achieved with perchlorate therapy. It may be considered particularly in cases where amiodarone cannot be withdrawn.

D Radioiodine

Radioiodine is ineffective at least initially in amiodarone-induced thyrotoxicosis, because of the iodine load already delivered by amiodarone therapy.

E Partial thyroidectomy

Audio Video Share Participants More

11:08
On
594-042-7551
Leave

66% 09:08

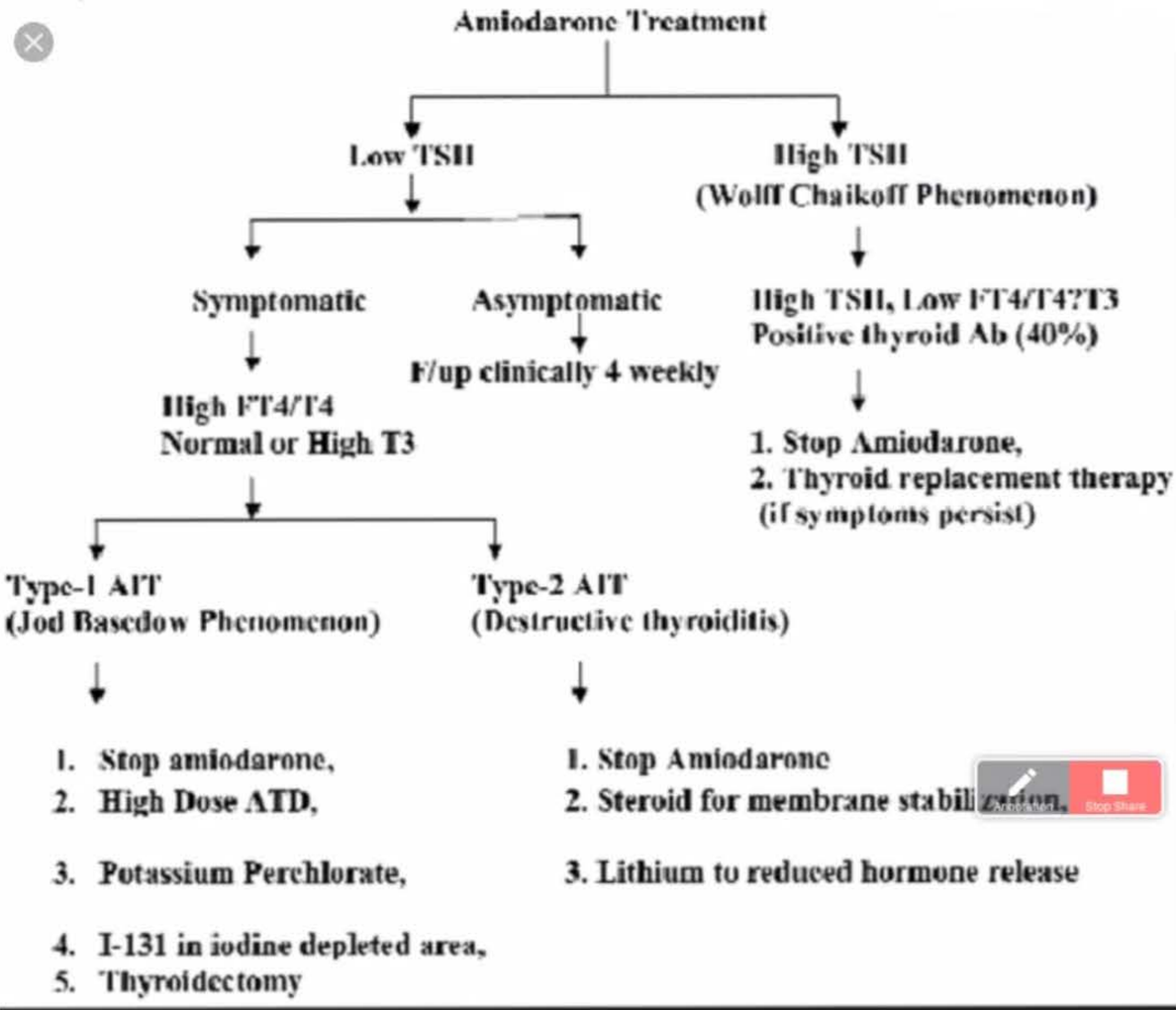

Figure: Algorithm showing management of amiodarone induced thyroid disorders.

Journal Of Pakistan Medical Association

JPMA - Journal Of Pakistan Medical Association

Normalization of thyroid function may be delayed due to prolonged elimination life of amiodarone and also due to pre-existing autoimmune thyroid disorder.

Images may be subject to copyright. Learn more

RELATED IMAGES

Medication | Side effects
Propylthiouracil/Strumazol | Hepatotoxicity, vasculitis, agranulocytosis, anaemia,

Type 1
Usually <4

Discover
Updates
Search
Recent
More

Audio
Video
Share
Participants
More

11:11
On
MyPastest
https://mypastest.pastest.com
594-042-7551
Leave

A 40-year-old woman is referred to the Endocrine Clinic complaining of an 8-month history of constant sweating and occasionally being feverish. She found her recent summer holiday to Turkey unbearable and had to return to the UK early. She has also noticed that she has lost weight over the last year, though her appetite remains fine. On examination, she was afebrile but tachycardic. Her palms were sweaty. No goitre was palpable. There was no cervical lymphadenopathy. Routine FBC, U&E and LFT are normal.

What is the most likely diagnosis?

A Hodgkin's lymphoma

B Non-Hodgkin's lymphoma

C Thyrotoxicosis

D Infection – undefined organism

E Phaeochromocytoma

Submit

Audio
Video
Share
Participants
More

11:12
On MyPastest 594-042-7551 Leave
https://mypastest.pastest.com

A 40-year-old woman is referred to the Endocrine Clinic complaining of an 8-month history of constant sweating and occasionally being feverish. She found her recent summer holiday to Turkey unbearable and had to return to the UK early. She has also noticed that she has lost weight over the last year, though her appetite remains fine. On examination, she was afebrile but tachycardic. Her palms were sweaty. No goitre was palpable. There was no cervical lymphadenopathy. Routine FBC, U&E and LFT are normal.

What is the most likely diagnosis?

Your answer was correct

A Hodgkin's lymphoma

B Non-Hodgkin's lymphoma

C Thyrotoxicosis

D Infection – undefined organism

E Phaeochromocytoma

Explanation

C Thyrotoxicosis

Episodic bouts of sweating may be due to hypoglycaemia, phaeochromocytoma or carcinoid. However, a patient

Audio Video Share Participants More

11:12
On MyPastest 594-042-7551 Leave
https://mypastest.pastest.com

Explanation

C Thyrotoxicosis

Episodic bouts of sweating may be due to hypoglycaemia, phaeochromocytoma or carcinoid. However, a patient reporting night sweats suggests a diagnosis of Hodgkin's disease or tuberculosis. Hodgkin's disease tends to feature localised lymphadenopathy, weight loss, pruritus and fever.

Patients with thyrotoxicosis report constant sweating and heat intolerance. There may be no evidence of enlargement of the thyroid gland.

Taking her age and sex into account, thyrotoxicosis is the most likely diagnosis.

A Hodgkin's lymphoma

Hodgkin's disease tends to feature localised lymphadenopathy, weight loss, pruritus and fever, splenomegaly and/or hepatomegaly. In our case, the physical examination is not in keeping with Hodgkin's lymphoma.

B Non-Hodgkin's lymphoma

Signs and symptoms of low-grade non-Hodgkin's lymphomas are:

- peripheral adenopathy: painless and slowly progressive; can spontaneously regress
- primary extra-nodal involvement and B symptoms: uncommon at presentation; however, common with

Audio Video Share Participants More

Apart from the weight loss and the sweats, there are no other symptoms which would point towards an infection. Moreover, the FBC is normal (no neutrophilia, or lymphocytosis in the case of viral infections). Also, liver function tests are normal, which precludes hepatitis or Epstein-Barr. The natural history of the disease is also too long (8 months).

E Phaeochromocytoma

Classically, pheochromocytoma manifests as spells with the following four characteristics:

- headaches
- palpitations
- diaphoresis
- severe hypertension.

In our scenario, apart from weight loss and sweating, which are non-specific, there is nothing else pointing towards a diagnosis of phaechromocytoma.

Rate this question:

Next Question

Previous Q... Tag Questi... Feedback End Session

Blog About Pastest Contact Us Help

© Pastest 2019

Rana Alnasser's screen

A 32-year-old woman presents to the GP complaining of lethargy. She works in the local pharmacy and has had to ask for increasing amounts of time off work. Apparently there is no past medical history of note, apart from some trouble due to an eating disorder as a teenager. On examination she looks normal, her blood pressure is 125/72 mmHg and BMI is 20.

Investigations:

Hb	12.1 g/dl
WCC	4.6 $\times 10^9$/l
PLT	200 $\times 10^9$/l
Na^+	134 mmol/l
K^+	3.1 mmol/l
Creatinine	90 µmol/l
Bicarbonate	34 mmol/l

Which of the following is the most likely diagnosis?

A Bartter syndrome

B Gitelman syndrome

C Conn's syndrome

D Thiazide abuse

E Liddle's syndrome

Rana Alnasser's screen

examination she looks normal, her blood pressure is 125/72 mmHg and BMI is 20.

Investigations:

Hb	12.1 g/dl
WCC	4.6 x10^9/l
PLT	200 x10^9/l
Na^+	134 mmol/l
K^+	3.1 mmol/l
Creatinine	90 µmol/l
Bicarbonate	34 mmol/l

Which of the following is the most likely diagnosis?

Your answer was correct

A Bartter syndrome

B Gitelman syndrome

C Conn's syndrome

D Thiazide abuse

E Liddle's syndrome

Explanation

D Thiazide abuse

This patient works in a pharmacy, so it is possible she has access to medicine, and we hear she has a history of an

E Liddle's syndrome

Explanation

D Thiazide abuse

This patient works in a pharmacy, so it is possible she has access to medicine, and we hear she has a history of an eating disorder as a teenager. Thiazide abuse would result in exactly this picture, with normal BP, hypokalaemia and high bicarbonate.

A Bartter syndrome

Bartter syndrome may present with a similar biochemical picture, although access to diuretics given she works in a pharmacy is much more likely to be the cause of her symptoms.

B Gitelman syndrome

Although Gitelman syndrome may also present with hypokalaemic metabolic alkalosis, it differs from Bartter in that it is associated with reduced calcium excretion.

C Conn's syndrome

Primary hyperaldosteronism is associated with hypertension, hypokalaemia and metabolic alkalosis, rather than the normal blood pressure seen here.

E Liddle's syndrome

Liddle syndrome is associated with hypertension, and hence cannot be the diagnosis here. It is caused by a

An 18-year-old woman is referred by her general practitioner to the Endocrine Clinic complaining of excessive hairiness. She is particularly concerned as this affects her face and the upper part of her chest. Her periods have been irregular ever since they began at the age of 12. Her body mass index (BMI) is 28. Testosterone level is measured at 3.2 nmol/l (0.5–3.0) and there is a raised luteinising hormone/follicle-stimulating hormone (LH/FSH) ratio.

What is the best long-term management for this lady?

A	Weight loss
B	Pioglitazone
C	Combined oral contraceptive pill
D	Metformin
E	Cyproterone acetate and ethinyloestradiol

Submit

An 18-year-old woman is referred by her general practitioner to the Endocrine Clinic complaining of excessive hairiness. She is particularly concerned as this affects her face and the upper part of her chest. Her periods have been irregular ever since they began at the age of 12. Her body mass index (BMI) is 28. Testosterone level is measured at 3.2 nmol/l (0.5–3.0) and there is a raised luteinising hormone/follicle-stimulating hormone (LH/FSH) ratio.

What is the best long-term management for this lady?

Your answer was correct

A	Weight loss
B	Pioglitazone
C	Combined oral contraceptive pill
D	Metformin
E	Cyproterone acetate and ethinyloestradiol

Explanation

A	Weight loss

This woman has evidence of polycystic ovarian syndrome (PCOS) as evidenced by her clinical presentation, moderately raised testosterone level and reversal of the LH/FSH ratio. Given that her elevated BMI is approaching the obese range, the best management is loss of weight.

Explanation

A Weight loss

This woman has evidence of polycystic ovarian syndrome (PCOS) as evidenced by her clinical presentation, moderately raised testosterone level and reversal of the LH/FSH ratio. Given that her elevated BMI is approaching the obese range, the best management is loss of weight. Loss of weight leads to decreased insulin resistance, increases in sex hormone-binding globulin (SHBG) and reduction in levels of free androgens. A 5% weight loss is said to result in a 40% improvement in hirsuitism. It will also significantly reduce the risk of developing type 2 diabetes over the longer term.

B Pioglitazone

The insulin sensitiser pioglitazone improves insulin sensitivity and restores ovulatory function in a significant number of patients with PCOS. It is, however, usually avoided over the long term because of adverse effects including weight gain, fluid retention and decreased bone mineral density.

C Combined oral contraceptive pill

Although the pill will regularise the menstrual cycle and improve hirsutism, over the longer term weight loss is more beneficial with respect to the patient's health.

D Metformin

Like pioglitazone, metformin reduces insulin resistance and has a modest effect on weight reduction in women with PCOS.

number of patients with PCOS. It is, however, usually avoided over the long term because of adverse effects including weight gain, fluid retention and decreased bone mineral density.

C Combined oral contraceptive pill

Although the pill will regularise the menstrual cycle and improve hirsutism, over the longer term weight loss is more beneficial with respect to the patient's health.

D Metformin

Like pioglitazone, metformin reduces insulin resistance and has a modest effect on weight reduction in women with PCOS.

E Cyproterone acetate and ethinyloestradiol

Cyproterone acetate and ethinyloestradiol do reduce hirsuitism, although where patients can manage to lose weight this is the preferred intervention, accompanied by electrolysis.

© Pastest 2019

A 32-year-old woman who has been diagnosed with a phaeochromocytoma by the general physicians visits you for a specialist endocrinology appointment. She is on adrenergic blockade with phenoxybenzamine and is awaiting surgery. They are concerned as her calcium is elevated, at 2.75 mmol/l. On examination her BP is elevated at 148/88 mmHg. You feel a hard mass on the right-hand side of the thyroid.

Which test is most important for confirming the diagnosis?

A	Tc-sestamibi parathyroid scan
B	Pentagastrin stimulation test
C	Ultrasound of the neck
D	Random calcitonin
E	PTH assay

Submit

© Pastest 2019

A 32-year-old woman who has been diagnosed with a phaeochromocytoma by the general physicians visits you for a specialist endocrinology appointment. She is on adrenergic blockade with phenoxybenzamine and is awaiting surgery. They are concerned as her calcium is elevated, at 2.75 mmol/l. On examination her BP is elevated at 148/88 mmHg. You feel a hard mass on the right-hand side of the thyroid.

Which test is most important for confirming the diagnosis?

Your answer was incorrect

A Tc-sestamibi parathyroid scan

B Pentagastrin stimulation test

C Ultrasound of the neck

D Random calcitonin

E PTH assay

Explanation

B Pentagastrin stimulation test

There is a high index of suspicion that this patient has MEN-2a, and she may well have both parathyroid hyperplasia and medullary thyroid carcinoma. Medullary thyroid carcinoma is the most important diagnosis to confirm, with the pentagastrin test the best way to do this. It measures calcitonin levels at 2 and 5 minutes, however, and a rise in calcitonin is suggestive of medullary thyroid carcinoma

B Pentagastrin stimulation test

There is a high index of suspicion that this patient has MEN-2a, and she may well have both parathyroid hyperplasia and medullary thyroid carcinoma. Medullary thyroid carcinoma is the most important diagnosis to confirm, with the pentagastrin test the best way to do this. It measures calcitonin levels at 2 and 5 minutes, however, and a rise in calcitonin is suggestive of medullary thyroid carcinoma.

E PTH assay

PTH may be elevated, but wouldn't confirm or refute an underlying diagnosis of medullary thyroid carcinoma.

A Tc-sestamibi parathyroid scan

Parathyroid hyperplasia is much commoner than medullary thyroid carcinoma, and it's most important to confirm or refute medullary thyroid carcinoma and hence MEN-2a.

C Ultrasound of the neck

Ultrasound of the neck is relatively insensitive with respect to identifying small neck masses, and doesn't provide a biochemical diagnosis.

D Random calcitonin

Random calcitonin is much less sensitive versus pentagastrin-stimulated calcitonin to identify medullary thyroid carcinoma.

Rate this question:

11:20

Pentagastrin stimulation test

Pentagastrin is also used as a stimulation test to elevate of several hormones, such as serotonin. It provokes flushing and is useful in evaluating patients who describe flushing, but have normal or only marginally elevated biochemical markers for carcinoid syndrome.

It has been used to stimulate ectopic gastric mucosa for the detection of Meckels diverticulum by nuclear medicine.

Calcitonin test

The **pentagastrin-stimulated calcitonin test** is a diagnostic test for medullary carcinoma of the thyroid (MTC). MTC is a malignancy of the calcitonin-secreting cells of the thyroid gland, and thus MTC is commonly associated with an elevated calcitonin level, but an elevated level may not always be obvious. The pentagastrin-stimulated calcitonin test is useful in cases of suspected MTC that are not associated with elevated calcitonin. In these patients, injecting pentagastrin will cause calcitonin levels to rise significantly above the normal or basal range.[4] After a total thyroidectomy for medullary thyroid carcinoma, the pentagastrin-stimulated calcitonin release can be used to detect

IUPAC name
N-(tert-butoxycarbony
aspartyl-L-pheny
CAS Number
PubChem CID
IUPHAR/BPS
DrugBank
ChemSpider
UNII
KEGG
ChEMBL
ECHA InfoCard
Chemi
Formula
Molar mass
3D model (JSmol)
SMILES
O=C(N)[C@@H](N
[C@@H](NC(=
H]c2)CCSC)CC
InChI
InChI=1S/C37H49
(45)41-28(19-2
2-26(15-17-54-
7(32(38)48)18
4-20H2,1-4H3,
43,51)(H,44,49
Key:NEYNJQRKHL

You review a 52-year-old man who describes having undergone pituitary surgery (and 'some treatment' after the operation), a while ago. He now complains of feelings of lethargy, reduced energy and vitality.

On examination, he has increased central abdominal adiposity and has reduced grip strength. He is already taking thyroid and cortisol replacement, and blood testing suggests these are adequate. Full blood count (FBC), urea and electrolytes (U&E) and liver function tests (LFTs) are unremarkable.

Which of the following would be the best investigation to perform next?

A	Magnetic resonance imaging (MRI) of the pituitary fossa
B	Insulin tolerance test
C	Glucose tolerance test
D	Serum prolactin
E	Serum insulin-like growth factor-1 (IGF-1)

Submit

11:23
On
594-042-7551
Leave

E Serum insulin-like growth factor-1 (IGF-1)

In light of this man's previous pituitary surgery, it is possible that he has growth hormone (GH) deficiency. Clinical features of growth hormone deficiency include impaired well-being, reduced energy and vitality, reduced muscle mass and exercise tolerance, decreased sweating, increased cardiovascular risk and increased fracture risk (osteoporosis). A serum IGF-1 concentration lower than the lower limit of normal in a patient who has pituitary disease confirms the diagnosis of GH deficiency. Even a normal value does not exclude GH deficiency; further investigations would be indicated here.

B Insulin tolerance test

Insulin tolerance testing to induce hypoglycaemia is a potential option for investigation, although this is unpleasant for the patient. Other options, such as the arginine-growth hormone-releasing hormone test, are preferred where these are available now.

A Magnetic resonance imaging (MRI) of the pituitary fossa

We know that pituitary anatomy is likely to be abnormal in relation to previous surgery, and further imaging won't inform as to abnormalities of gland function.

C Glucose tolerance test

Oral glucose tolerance testing is utilised in the evaluation of acromegaly, not growth hormone deficiency.

D Serum prolactin

Audio Video Share Participants More

possible that he has growth hormone (GH) deficiency. Clinical features of growth hormone deficiency include impaired well-being, reduced energy and vitality, reduced muscle mass and exercise tolerance, decreased sweating, increased cardiovascular risk and increased fracture risk (osteoporosis). A serum IGF-1 concentration lower than the lower limit of normal in a patient who has pituitary disease confirms the diagnosis of GH deficiency. Even a normal value does not exclude GH deficiency; further investigations would be indicated here.

B Insulin tolerance test

Insulin tolerance testing to induce hypoglycaemia is a potential option for investigation, although this is unpleasant for the patient. Other options, such as the arginine-growth hormone-releasing hormone test, are preferred where these are available now.

A Magnetic resonance imaging (MRI) of the pituitary fossa

We know that pituitary anatomy is likely to be abnormal in relation to previous surgery, and further imaging won't inform as to abnormalities of gland function.

C Glucose tolerance test

Oral glucose tolerance testing is utilised in the evaluation of acromegaly, not growth hormone deficiency.

D Serum prolactin

An elevated serum prolactin would neither confirm or refute growth hormone deficiency, and this is not therefore a preferred next investigation.

Rana Alnasser's screen

11:25

A 31-year-old woman is admitted via paramedic ambulance from the local airport, having returned on a flight from Australia. She was unable to mobilise off the flight due to pain and swelling affecting her left lower limb, and also appeared to be suffering from right sided face and arm weakness. She is usually well with no past medical history of note, and is a non-smoker.

On examination, her BP is 152/90 mmHg, pulse is 80/min and regular. There are no murmurs. Her chest is clear. You note a swollen left calf, with swelling spreading up towards the knee, consistent with a DVT. She also has a right-sided face and arm weakness consistent with a stroke.

Investigations:

Hb	125 g/l
WCC	6.5×10^9/l
PLT	189×10^9/l
NA	138 mmol/l
K	4.5 mmol/l
Creatinine	90 µmol/l
CXR	unremarkable
Left lower limb venous Doppler	extensive DVT

Which of the following is the most useful investigation to find the cause of the stroke?

A Carotid duplex

B Contrast echocardiography

C CT Head

Rana Alnasser's screen

On examination, her BP is 152/90 mmHg, pulse is 80/min and regular. There are no murmurs. Her chest is clear. You note a swollen left calf, with swelling spreading up towards the knee, consistent with a DVT. She also has a right-sided face and arm weakness consistent with a stroke.

Investigations:

Hb	125 g/l
WCC	6.5×10^9/l
PLT	189×10^9/l
NA	138 mmol/l
K	4.5 mmol/l
Creatinine	90 µmol/l
CXR	unremarkable
Left lower limb venous Doppler	extensive DVT

Which of the following is the most useful investigation to find the cause of the stroke?

A Carotid duplex

B Contrast echocardiography

C CT Head

D Thrombophilia screen

E Transcranial Doppler ultrasound

Rana Alnasser's screen

NA	138 mmol/l
K	4.5 mmol/l
Creatinine	90 µmol/l
CXR	unremarkable
Left lower limb venous Doppler	extensive DVT

Which of the following is the most useful investigation to find the cause of the stroke?

Your answer was correct

A Carotid duplex

B Contrast echocardiography

C CT Head

D Thrombophilia screen

E Transcranial Doppler ultrasound

Explanation

B Contrast echocardiography

A contrast trans-oesophageal echocardiogram using agitated saline is the optimal to visualise a patent foramen ovale (PFO), the most likely cause of this patient's stroke. It is possible that part of the deep vein thrombosis has traversed the PFO and moved from the right to the left side of the circulation, causing the stroke. If this is the case

B Contrast echocardiography

A contrast trans-oesophageal echocardiogram using agitated saline is the optimal to visualise a patent foramen ovale (PFO), the most likely cause of this patient's stroke. It is possible that part of the deep vein thrombosis has traversed the PFO and moved from the right to the left side of the circulation, causing the stroke. If this is the case, long term anti-coagulation, and potentially closure of the PFO would be considered.

A Carotid duplex

We are not given any history of cardiovascular risk factors which would point us towards significant carotid disease. Carotid duplex is most useful where there is other evidence of atherosclerosis or risk factors for its development.

C CT Head

Although CT head is useful as part of the stroke workup, it will not tell us the likely underlying cause.

D Thrombophilia screen

Although thrombophilia screen may provide information about increased risk of thromboembolic disease, it will not provide the link between the DVT and the cerebral event.

E Transcranial Doppler ultrasound

Although transcranial Doppler is useful in establishing the presence of a shunt, it cannot in this case provide information on the location of the shunt.

is possible that part of the deep vein thrombosis has traversed the PFO and moved from the right to the left side of the circulation, causing the stroke. If this is the case, long term anti-coagulation, and potentially closure of the PFO would be considered.

A Carotid duplex

We are not given any history of cardiovascular risk factors which would point us towards significant carotid disease. Carotid duplex is most useful where there is other evidence of atherosclerosis or risk factors for its development.

C CT Head

Although CT head is useful as part of the stroke workup, it will not tell us the likely underlying cause.

D Thrombophilia screen

Although thrombophilia screen may provide information about increased risk of thromboembolic disease, it will not provide the link between the DVT and the cerebral event.

E Transcranial Doppler ultrasound

Although transcranial Doppler is useful in establishing the presence of a shunt, it cannot in this case provide information on the location of the shunt.

Rate this question:

Next Question

A 71-year-old man is referred to the Rheumatology Clinic with pain over his left hip and pelvis. Previously very active, he is now limited to walking only a few hundred yards due to pain. Past medical history of note includes hypertension, which is treated with felodipine.

On examination, his BP is 135/70 mmHg, with pulse 70/min and regular. He has pain over the left hip, and flexion and external rotation are limited by pain. His GP has arranged an X-ray of the hip, which reveals evidence of osteolysis and new bone formation around both the femoral head and the pelvis.

Which of the following is most likely to be abnormal?

A	Calcium
B	Alkaline phosphatase
C	Vitamin D
D	Phosphate
E	Parathyroid hormone (PTH)

Submit

11:29
On
594-042-7551
Leave

and regular. He has pain over the left hip, and flexion and external rotation are limited by pain. His GP has arranged an X-ray of the hip, which reveals evidence of osteolysis and new bone formation around both the femoral head and the pelvis.

Which of the following is most likely to be abnormal?

Your answer was correct

A Calcium

B Alkaline phosphatase

C Vitamin D

D Phosphate

E Parathyroid hormone (PTH)

Explanation

B Alkaline phosphatase

The X-ray appearance is typical of Paget's disease. In patients with Paget's, other markers of bone turnover, apart from alkaline phosphatase, are usually in the normal range. Alkaline phosphatase is a useful marker of disease activity and of response to bisphosphonates, with a fall in alkaline phosphatase correlating with a reduction in disease activity. Over the longer term, bisphosphonates may not be completely effective; one study suggested that despite the use of etidronate, disease progression occurred in 28% of individuals.

Audio Video Share Participants More

A Calcium

Calcium in patients with Paget's remains in the normal range for the majority of patients, unless there is a prolonged period of bed rest, where minor elevations may be seen.

C Vitamin D

Vitamin D elevation is seen in patients with sarcoidosis and symptomatic hypercalcaemia, and in those who take excess exogenous vitamin D.

D Phosphate

Elevations in phosphate are seen in hypoparathyroidism and in those with renal impairment, rather than those with Paget's.

E Parathyroid hormone (PTH)

Hyperparathyroidism is not usually associated with single joint destruction, and is normal in patients with Paget's disease.

Rate this question:

Next Question

11:29

You review a 36-year-old woman who presents to the Emergency Department with anxiety and palpitations. She has an 8-month-old child. Over the past 4 months, she has lost 5 kg in weight but puts this down to all the work looking after her baby.

The admitting nurses notice that she has rather 'staring eyes' and on examination you notice she has obvious chemosis, proptosis and lid lag. Thyroid-stimulating hormone (TSH) measurement is 0.05 mU/l.

Which of the following best fits the underlying diagnosis of her systemic condition?

A Graves' disease

B Hashimoto's thyroiditis

C Riedel's thyroiditis

D Toxic thyroid adenoma

E Postpartum thyroiditis

Submit

Rana Alnasser's screen

You review a 36-year-old woman who presents to the Emergency Department with anxiety and palpitations. She has an 8-month-old child. Over the past 4 months, she has lost 5 kg in weight but puts this down to all the work looking after her baby.

The admitting nurses notice that she has rather 'staring eyes' and on examination you notice she has obvious chemosis, proptosis and lid lag. Thyroid-stimulating hormone (TSH) measurement is 0.05 mU/l.

Which of the following best fits the underlying diagnosis of her systemic condition?

Your answer was correct

A	Graves' disease
B	Hashimoto's thyroiditis
C	Riedel's thyroiditis
D	Toxic thyroid adenoma
E	Postpartum thyroiditis

Explanation

A	Graves' disease

This woman has Graves' ophthalmopathy and thyrotoxicosis. Graves' ophthalmopathy occurs due to local accumulation of glycosaminoglycans; 75% of Graves'

A Graves' disease

This woman has Graves' ophthalmopathy and thyrotoxicosis. Graves' ophthalmopathy occurs due to local accumulation of glycosaminoglycans; 75% of Graves' patients develop the disease within 1 year of ophthalmopathy occurring. The condition can be worsened by smoking and by hypothyroidism post-radioiodine treatment. If visual impairment, with blurring or visual field loss, or pain occurs, then this is a sign of optic neuropathy, and the patient should be referred to an ophthalmologist for treatment. Standard therapy involves a portfolio of treatment modalities that may include systemic corticosteroids, radiotherapy or orbital decompression, or a combination of treatments. In patients with thyroid eye disease undergoing radioiodine treatment, post-radioiodine hypothyroidism should be avoided because of the risk of worsening Graves' eye disease. For this reason, patients are stabilised on a block–replace regimen before moving to radioiodine therapy.

B Hashimoto's thyroiditis

Hashimoto's disease is associated with goitre, but not with thyroid eye disease, and leads to hypothyroidism not thyrotoxicosis.

C Riedel's thyroiditis

This leads to fibrotic disease of the thyroid gland and to hypothyroidism rather than thyrotoxicosis.

D Toxic thyroid adenoma

Toxic thyroid adenoma is associated with thyrotoxicosis, but not with the eye signs seen here which are related to

11:30
On
594-042-7551
Leave

Pastest+

A 25-year-old woman presents with palpitations which have worsened in frequency over the past week, a blood pressure of 130/80 mmHg and she is found to have atrial fibrillation on her ECG.

On examination, she has a palpable, smooth thyroid goitre. She is 3 months' postpartum and is currently breast-feeding. Her daughter is very healthy. She has no past medical history. TSH is supressed at < 0.05 mU/l and is TSH receptor and TPO antibody positive.

Which one of the following is the most likely diagnosis of her goitre?

A	Postpartum thyroiditis
B	Pregnancy
C	Graves' disease
D	Struma ovarii
E	Subacute thyroiditis

32915

Submit

Audio
Video
Share
Participants
More

11:33

A 25-year-old woman presents with palpitations which have worsened in frequency over the past week, a blood pressure of 130/80 mmHg and she is found to have atrial fibrillation on her ECG.

On examination, she has a palpable, smooth thyroid goitre. She is 3 months' postpartum and is currently breast-feeding. Her daughter is very healthy. She has no past medical history. TSH is supressed at < 0.05 mU/l and is TSH receptor and TPO antibody positive.

Which one of the following is the most likely diagnosis of her goitre?

Your answer was correct

A Postpartum thyroiditis

B Pregnancy

C Graves' disease

D Struma ovarii

E Subacute thyroiditis

Explanation

A Postpartum thyroiditis

This patient has clinical hyperthyroidism and is in the first few months after pregnancy. As such, the most likely [illegible] roiditis. In women who present

Rana Alnasser's screen

A Postpartum thyroiditis

This patient has clinical hyperthyroidism and is in the first few months after pregnancy. As such, the most likely diagnosis is postpartum thyroiditis. In women who present with postpartum thyroiditis and have symptoms of thyrotoxicosis, TSH receptor antibodies are found with increased frequency, although TPO antibodies are classically described in association with the condition. A transient period of hypothyroidism follows the episode of thyrotoxicosis, and up to 30% of patients may eventually develop permanent hypothyroidism.

B Pregnancy

Pregnancy may be associated with development of a goitre, but thyrotoxicosis is of course pathological.

C Graves' disease

Postpartum thyroiditis may be a harbinger of permanent thyroid dysfunction in some women, but the timing here points us towards postpartum disease rather than diagnosing Graves' at this stage.

D Struma ovarii

Struma ovarii is caused by ectopic thyroid tissue, so there is no goitre present.

E Subacute thyroiditis

Subacute thyroiditis is associated with symptoms of a flu-like illness, pain over the thyroid gland and thyrotoxicosis. It is not associated with pregnancy.

Rana Alnasser's screen

A 52-year-old man on a visit to his GP has been noticed to have a blood pressure of 160/90 mm Hg. He has a 7-year history of type 2 diabetes, which is currently managed with metformin 1 g twice daily and gliclazide 160 mg twice daily. His BMI in the clinic was 26.

Systemic examination otherwise was normal apart from bilateral peripheral sensory loss and loss of vibration sense up to his knees, consistent with diabetic neuropathy. He has also had laser photocoagulation treatment in both eyes. Other medication of note includes ramipril 10 mg daily, atorvastatin and aspirin, which were started approximately 5 years earlier.

Investigations:

HbA1c	70.49 mmol/mol (8.6%) g/dl
Urea	16.7 mmol/l
Phosphate	1.02 mmol/l
Na^+	138 mmol/l
K^+	4.8 mmol/l
Creatinine	225 µmol/l
Ca^{2+}	2.27 mmol/l
Albumin	38 g/l
Chloride	115 mmol/l
Bicarbonate	18 mmol/l
Urine protein	0.8 g/24 h
Urine albumin/creatinine ratio	25 mg/mmol (normal range <3 mg/mmol)
ECG	Normal

Which next step in his management would be the most

HbA1c	70.49 mmol/mol (8.6%) g/dl
Urea	16.7 mmol/l
Phosphate	1.02 mmol/l
Na^+	138 mmol/l
K^+	4.8 mmol/l
Creatinine	225 µmol/l
Ca^{2+}	2.27 mmol/l
Albumin	38 g/l
Chloride	115 mmol/l
Bicarbonate	18 mmol/l
Urine protein	0.8 g/24 h
Urine albumin/creatinine ratio	25 mg/mmol (normal range <3 mg/mmol)
ECG	Normal

Which next step in his management would be the most appropriate?

A Stop gliclazide and metformin and start a basal bolus insulin regime

B Reduce the dose of ACE inhibitor by 50%

C Stop his ACE inhibitor

D Start beta-blockers

E Start furosemide

Explanation

A Stop gliclazide and metformin and start a basal bolus insulin regime

This gentleman's renal function precludes the use of metformin. Moreover, the fact that despite being on the maximum dose of gliclazide and a high dose of metformin, his suboptimal HbA1c points towards the need for insulin initiation. A basal bolus regimen would be ideal given his poor renal function. Moreover, it will provide flexibility in terms of dose adjustment and will optimize his glycaemic control. Tight glycaemic control is crucial given that this gentleman has already diabetic nephropathy, retinopathy and peripheral neuropathy.

B Reduce the dose of ACE inhibitor by 50%

The target blood pressure for diabetics is recommended as <140/80 mmHg, or 125/75 mmHg in type 1 diabetic patients and individuals who have at least micro-albuminuria. ACE inhibitors are renoprotective in patients with a history of diabetic nephropathy, and thus continuing the ACE inhibitor at maximal tolerated dose is recommended. They also have significant effect on reducing the albuminuria.

C Stop his ACE inhibitor

It is likely that the creatinine seen here is chronically elevated in the context of diabetic nephropathy and has not been worsened by ACE inhibition.

D Start beta-blockers

This patient needs better management of his hypertension, and the use of a second agent would be necessary. Beta-blockers would not be a first choice unless there is history

recommended. They also have significant effect on reducing the albuminuria.

C Stop his ACE inhibitor

It is likely that the creatinine seen here is chronically elevated in the context of diabetic nephropathy and has not been worsened by ACE inhibition.

D Start beta-blockers

This patient needs better management of his hypertension, and the use of a second agent would be necessary. Beta-blockers would not be a first choice unless there is history of atrial fibrillation or coronary artery disease, given the potential worsening effect of some of these on glycaemic control.

E Start furosemide

There is no evidence of fluid overload that could justify its use, and it could potentially worsen the renal function.

Rate this question:

© Pastest 2019

A 56-year-old woman was admitted to the Intensive Therapy Unit (ITU) after a road traffic accident. There were multiple long bone fractures and significant bleeding, and she required a period of mechanical ventilation due to a chest injury.

Past medical history of note includes hypertension, which is managed with indapamide, and obesity with a BMI of 31. During her recovery, the orthopaedic surgeons noticed a small goitre.

Results obtained 6 days after admission:

Free thyroxine (T4)	4.1 pmol/l (10–22)
Free tri-iodothyronine (T3)	1.5 pmol/l (5–10)
Thyroid-stimulating hormone (TSH)	0.5 mU/l (0.4–5)
Random cortisol	1250nmol/l (200–700 at 0900 h)

Which of the following is the most appropriate management of her thyroid disorder?

A Thyroxine 50 mcg/day

B Thyroxine 100 mcg/day

C Carbimazole

D Propylthiouracil

E Repeat thyroid function testing in 3 months

E Repeat thyroid function testing in 3 months

This patient has a normal thyroid-stimulating hormone (TSH) level, which suggests that she is suffering from 'sick euthyroid' syndrome. This condition, characterised by low tri-iodothyronine (T3) and thyroxine (T4) and normal TSH, is associated with severe illness and frequently occurs in patients admitted to the ITU. Most physicians advise repeating thyroid function testing in a few months; there is no evidence that patients benefit from thyroid hormone replacement. This patient's level of cortisol is entirely appropriate given her admission to the ITU and road traffic accident. While she is obese, the possibility of co-existent Cushing's disease is unlikely. It might be appropriate to repeat a morning cortisol level a few more weeks into her recovery.

A Thyroxine 50 mcg/day

Resolution of the underlying illness (in this case the trauma and subsequent surgery) is enough to correct thyroid function. Replacing thyroid hormone, even at low dose, risks driving symptoms of thyrotoxicosis and potentially hindering recovery.

B Thyroxine 100 mcg/day

Thyroxine 100 mcg/day will drive suppression of TSH and symptoms of hyperthyroidism. Resolution of thyroid dysfunction, accompanied by restoration of T3 and T4 levels, occurs within a few weeks.

C Carbimazole

Thyroid hormone levels are depressed as a result of the acute illness, and thus there is no value in suppressing thyroid hormone production further.

A 24-year-old man with a history of previous injury in a motorcycle accident comes to the clinic with his mother. She looks after him as he has been left with a right arm and leg weakness after a skull fracture and intracranial haemorrhage. He also has epilepsy for which he takes carbamazepine. They complain that he is thirsty all the time and can't stop drinking litres of water and squash each day. His mother herself has significant chronic illness, suffering from chronic left ventricular failure.

Investigations:

Hb	13.4 g/dl
WCC	5.9 $\times 10^9$/l
PLT	203 $\times 10^9$/l
Na^+	149 mmol/l
K^+	4.5 mmol/l
Creatinine	143 µmol/l
Bicarbonate	22 mmol/l
Plasma osmolality	350 mosmol/kg
Urine osmolality	270 after water deprivation, rises to 810 after DDAVP

Which of the following is the most likely diagnosis?

A Nephrogenic diabetes insipidus

B SIADH

C Cranial diabetes insipidus

D Psychogenic polydipsia

haemorrhage. He also has epilepsy for which he takes carbamazepine. They complain that he is thirsty all the time and can't stop drinking litres of water and squash each day. His mother herself has significant chronic illness, suffering from chronic left ventricular failure.

Investigations:

Hb	13.4 g/dl
WCC	5.9 x10^9/l
PLT	203 x10^9/l
Na^+	149 mmol/l
K^+	4.5 mmol/l
Creatinine	143 µmol/l
Bicarbonate	22 mmol/l
Plasma osmolality	350 mosmol/kg
Urine osmolality	270 after water deprivation, rises to 810 after DDAVP

Which of the following is the most likely diagnosis?

A Nephrogenic diabetes insipidus

B SIADH

C Cranial diabetes insipidus

D Psychogenic polydipsia

E Diuretic abuse

11:41
On
594-042-7551
Leave

Explanation

C Cranial diabetes insipidus

It is highly likely that this man's head injury has led to cranial diabetes insipidus. Whilst it is possible given the clinical history that he may have psychogenic polydipsia, the osmolality results only fit with cranial DI as the diagnosis. Treatment is with intranasal vasopressin; given the possibility of overdose and consequent hyponatraemia, monitoring of U&E is recommended. Carbamazepine may exacerbate hyponatraemia with vasopressin therapy, and therefore close monitoring of U&E and symptom response versus vasopressin dose is even more essential in this case.

A Nephrogenic diabetes insipidus

Nephrogenic DI would not show a positive response to DDAVP and is therefore excluded here.

B SIADH

SIADH is associated with relative salt and water overload, accompanied by hyponatraemia rather than the elevated sodium seen here.

D Psychogenic polydipsia

This is the alternative diagnosis, although the history of head injury and strong response to DDAVP makes cranial diabetes insipidus much more likely.

E Diuretic abuse

Diuretic abuse may be associated with symptoms of dehydration, but elevated bicarbonate would be expected here.

Audio Video Share Participants More

11:41
On
594-042-7551
Leave

A Nephrogenic diabetes insipidus

Nephrogenic DI would not show a positive response to DDAVP and is therefore excluded here.

B SIADH

SIADH is associated with relative salt and water overload, accompanied by hyponatraemia rather than the elevated sodium seen here.

D Psychogenic polydipsia

This is the alternative diagnosis, although the history of head injury and strong response to DDAVP makes cranial diabetes insipidus much more likely.

E Diuretic abuse

Diuretic abuse may be associated with symptoms of dehydration, but elevated bicarbonate would be expected here.

21489
Rate this question:

© Pastest 2019

Audio Video Share Participants More

11:41
On
594-042-7551
Leave

A 40-year-old South African man presents to the Accident and Emergency Department. He is confused, but you can get a history from his wife. He is on holiday in the UK for a week.

He is normally in good health and was well when he arrived in the UK. The only past history of note is an admission some 3 years earlier with acute lower abdominal pain and agitation. He is on no regular medications but took some over-the-counter antihistamines yesterday for hay fever. Since then, he has been complaining of a weak arm, vomiting and abdominal pain. When he became confused, his wife became concerned and brought him to Accident and Emergency.

On examination, he is confused and hallucinating. He has bilateral wrist drop. Otherwise, examination of his peripheral nervous system and cranial nerves is normal. Pulse is 120/min and regular, and his BP is 175/100 mmHg. Examination of his chest is also normal. Examination of his abdomen reveals diffuse tenderness.

Investigations:

Na^+	120 mmol/l
K^+	4.3 mmol/l
Urea	6.0 mmol/l
Creatinine	120 μmol/l

He is given a bolus of IV glucose, what other measure would you take next?

A IV haem arginate

B Alcohol withdrawal regime of chlordiazepoxide

Audio Video Share Participants More

over-the-counter antihistamines yesterday for hay fever. Since then, he has been complaining of a weak arm, vomiting and abdominal pain. When he became confused, his wife became concerned and brought him to Accident and Emergency.

On examination, he is confused and hallucinating. He has bilateral wrist drop. Otherwise, examination of his peripheral nervous system and cranial nerves is normal. Pulse is 120/min and regular, and his BP is 175/100 mmHg. Examination of his chest is also normal. Examination of his abdomen reveals diffuse tenderness.

Investigations:

Na^+	120 mmol/l
K^+	4.3 mmol/l
Urea	6.0 mmol/l
Creatinine	120 µmol/l

He is given a bolus of IV glucose, what other measure would you take next?

A IV haem arginate

B Alcohol withdrawal regime of chlordiazepoxide

C Intravenous thiamine

D IV cyclizine

E Abdominal CT

32869

Rana Alnasser's screen

Submit

A IV haem arginate

This describes an attack of acute intermittent porphyria. The diagnosis requires demonstration of increased urinary excretion of the haem precursor, porphobilinogen (PBG), in the urine. All attacks of porphyria increase the activity of hepatic 5-aminolevulinate (ALA) synthase. The relation between these biochemical abnormalities and the neuronal dysfunction that underlies all the features of an acute attack is uncertain. Two procedures have been shown to decrease the activity of ALA synthase in animals - carbohydrate loading and parenteral infusion of haem arginate. Consequently, these two procedures are the mainstay of the treatment along with opiate analgesia. Provoking medication, such as the antihistamines in this case, should be withdrawn.

B Alcohol withdrawal regime of chlordiazepoxide

Chlordiazepoxide is a benzodiazepine type sedative, but it won't manage the underlying cause of this patient's agitation, an acute episode of porphyria.

C Intravenous thiamine

We aren't given a significant alcohol consumption history as part of the scenario, and the previous episode 3 years ago of abdominal pain fits with intermittent porphyria, and thus thiamine is not likely to be effective here.

D IV cyclizine

Cyclizine is an anti-emetic with some antihistamine activity; reports about its safety conflict with respect to use in porphyria, with some case reports suggesting it can be used and others raising the possibility that it can precipitate porphyria episodes.

mainstay of the treatment along with opiate analgesia. Provoking medication, such as the antihistamines in this case, should be withdrawn.

B Alcohol withdrawal regime of chlordiazepoxide

Chlordiazepoxide is a benzodiazepine type sedative, but it won't manage the underlying cause of this patient's agitation, an acute episode of porphyria.

C Intravenous thiamine

We aren't given a significant alcohol consumption history as part of the scenario, and the previous episode 3 years ago of abdominal pain fits with intermittent porphyria, and thus thiamine is not likely to be effective here.

D IV cyclizine

Cyclizine is an anti-emetic with some antihistamine activity; reports about its safety conflict with respect to use in porphyria, with some case reports suggesting it can be used and others raising the possibility that it can precipitate porphyria episodes.

E Abdominal CT

The symptoms of pseudo-obstruction with hypertension and hyponatraemia are most consistent with acute intermittent porphyria; the abdominal CT is therefore most likely to be normal.

Rate this question:

Next Question

Rana Alnasser's screen

An 18-year-old woman from a travelling family presents for review. Her mother is concerned as her periods have not started.

On examination, she is significantly shorter than would be expected given her parental height, her nipples are widely spaced and there is a suspicion of a high-arched palate. There appears to be failure of secondary sexual characteristics. Her blood pressure is elevated at 149/90 mmHg.

Investigations reveal an FSH > 40 IU/l on at least two occasions.

Which of the following is the most appropriate investigation in this case?

A	Karyotyping
B	Autoimmune screen
C	Pituitary MRI
D	Abdominal ultrasound scan
E	Oestrogen levels

32899

11:46
On
Pastest
594-042-7551
Leave

A Karyotyping

The most appropriate investigation is karyotyping. There is a strong suspicion that this patient has Turner syndrome and that access to health services has been patchy because she is from a travelling family. Features include short stature, webbing of the neck, micrognathia, low-set ears, a high-arched palate, widely spaced nipples and cubitus valgus, some of which are clearly present here. Turner occurs due to the complete or partial absence of one X chromosome and diagnosis is by lymphocyte karyotyping. Turner is associated with a number of other associated abnormalities including aortic coarctation and other left-sided congenital heart defects, osteoporosis, hypothyroidism, lymphoedema, skeletal abnormalities and congenital malformations of the renal tract. Surveillance echocardiography and renal ultrasound are recommended.

B Autoimmune screen

Autoimmune screening is a potential investigation in primary ovarian failure, which may be associated with other autoimmune diseases.

C Pituitary MRI

Pituitary MRI is most useful in secondary ovarian failure associated with elevated prolactin in an attempt to identify the presence of a pituitary adenoma.

D Abdominal ultrasound scan

Although an ultrasound scan may identify the absence of normal ovaries, karyotyping is straightforward and a sample can be taken at the initial outpatient appointment. Given she is from a travelling family, there is potential she may only have patchy attendance for further follow-up.

Audio Video Share Participants More

associated abnormalities including aortic coarctation and other left-sided congenital heart defects, osteoporosis, hypothyroidism, lymphoedema, skeletal abnormalities and congenital malformations of the renal tract. Surveillance echocardiography and renal ultrasound are recommended.

B Autoimmune screen

Autoimmune screening is a potential investigation in primary ovarian failure, which may be associated with other autoimmune diseases.

C Pituitary MRI

Pituitary MRI is most useful in secondary ovarian failure associated with elevated prolactin in an attempt to identify the presence of a pituitary adenoma.

D Abdominal ultrasound scan

Although an ultrasound scan may identify the absence of normal ovaries, karyotyping is straightforward and a sample can be taken at the initial outpatient appointment. Given she is from a travelling family, there is potential she may only have patchy attendance for further follow-up.

E Oestrogen levels

Oestrogen levels will be low, but measuring them won't determine the underlying pathophysiology.

32899

Rate this question:

Next Question

Rana Alnasser's screen

A 54-year-old housewife is referred to your clinic with a history of 'funny turns' over the last 2 years. She complains of intermittent episodes of feeling sweaty and faint and having double vision. She tells you that she often feels better after a strong cup of tea with three sugars. She has no medical history of note and is taking no tablets. Her mother had diabetes mellitus and her father had epilepsy. She smokes 10 cigarettes a day and drinks alcohol occasionally. Her examination is completely normal.

Investigations:

Urea	6.8 mmol/l
Ca^{2+}	2.93 mmol/l
PO_4	0.84 mmol/l
Na^+	136 mmol/l
K^+	5.4 mmol/l
Creatinine	84μmol/l
Glucose	5.3 mmol/l

What is the most likely diagnosis?

A Petit mal epilepsy

B Recurrent TIAs

C Multiple endocrine neoplasia type-1

D Paroxysmal atrial fibrillation

E Phaeochromocytoma

E Phaeochromocytoma

Explanation

C Multiple endocrine neoplasia type-1

An insulinoma should be suspected in this patient, given her 2-year history of 'funny turns' and the fact that she feels better after a strong cup of tea. Furthermore the blood tests reveal an elevated calcium, raising the suspicion of associated hyperparathyroidism. Multiple endocrine neoplasia (MEN)-1 should be suspected here, which may be a combination of a pituitary tumour (often a macroadenoma), hyperparathyroidism and a pancreatic islet tumour. Of course all these conditions may not necessarily occur at the same point in time.

The *MEN 1* gene has an autosomal-dominant pattern of inheritance. Any individual with a relative with *MEN 1* should be screened. Mutational analysis of the coding region has a sensitivity of about 95% in *MEN 1* patients. Relatives without the mutation can be reassured and do not require regular screening. Screening includes serum calcium and prolactin in all patients; 90% of *MEN 1* patients present with hypercalcaemia.

A Petit mal epilepsy

This is a common type of epilepsy syndrome presenting in children in the first decade. A seizure is characterised by a brief staring episode with behavioural arrest. A 3 Hz spike-and-slow-wave discharge on electroencephalogram (EEG is generally associated with this seizure.

B Recurrent TIAs

Transient ischemic attack (TIA) is defined as a transient episode of neurologic dysfunction caused by focal brain.

11:48

MyPastest
https://mypastest.pastest.com

A 54-year-old housewife is referred to your clinic with a history of 'funny turns' over the last 2 years. She complains of intermittent episodes of feeling sweaty and faint and having double vision. She tells you that she often feels better after a strong cup of tea with three sugars. She has no medical history of note and is taking no tablets. Her mother had diabetes mellitus and her father had epilepsy. She smokes 10 cigarettes a day and drinks alcohol occasionally. Her examination is completely normal.

Investigations:

Urea	6.8 mmol/l
Ca^{2+}	2.93 mmol/l
PO_4	0.84 mmol/l
Na^+	136 mmol/l
K^+	5.4 mmol/l
Creatinine	84μmol/l
Glucose	5.3 mmol/l

What is the most likely diagnosis?

Your answer was correct

A Petit mal epilepsy

B Recurrent TIAs

Rana Alnasser's screen

eoplasia type-1

is generally associated with this seizure.

B Recurrent TIAs

Transient ischemic attack (TIA) is defined as a transient episode of neurologic dysfunction caused by focal brain, spinal cord or retinal ischaemia, without acute infarction. The duration of symptom/sign is <24 h and resolution is not related to consumption of any food/beverage.

D Paroxysmal atrial fibrillation

Paroxysmal AF (PAF) is defined as an episode of AF that reverts to sinus rhythm spontaneously or with intervention within seven days. Symptoms can be irregular palpitations, shortness of breath, dyspnoea on exertion, a sensation of light-headedness or less commonly fatigue, weakness or generalised malaise. In acute presentations, heart rate is controlled by a beta blocker or calcium channel blocker. If spontaneous reversion doesn't occur and there is haemodynamic compromise, electrical cardioversion is considered or, alternatively, pharmacological conversion with flecainide or amiodarone.

E Phaeochromocytoma

Phaechromocytoma are rare catecholamine-secreting tumours occurring in <0.2% of patients with hypertension. Most (about 70%) are sporadic. Classical symptoms are headaches, sweating and tachycardia. Other symptoms include palpitations, tremor, pallor, dyspnoea, generalised weakness, and panic attack-type symptoms. Most common sign is sustained or paroxysmal hypertension. Symptoms usually resolve spontaneously without intervention.

Rate this question:

Next Question

A 37-year-old woman has been brought to the Emergency Department with a 1-day history of abdominal pain, diarrhoea and vomiting. She has a history of type 1 diabetes mellitus and pernicious anaemia.

Her partner tells you that her general practitioner (GP) has recently prescribed amoxicillin for her chest infection and that she has lost 12.5 kg (nearly 2 stone) in weight over the last few months. She does not smoke or drink alcohol.

On examination, she is flushed, disorientated, agitated and jaundiced. Her temperature is 42.1 °C, pulse 180 bpm and irregular and blood pressure (BP) 180/70 mmHg. You detect a third heart sound, her chest is clear and her abdomen generally tender. Her legs are weak proximally and all reflexes brisk. She has some pitting oedema of her lower limbs.

Investigations:

Hb	10.3 g/dl
WCC	17.2×10^9/l
PLT	9.0 /l
Na^+	131 mmol/l
K^+	2.8 mmol/l
Creatinine	165 µmol/l
Ca^{2+}	2.82 mmol/l
Bilirubin	64 µmol/l
ALT	140 U/l
ALP	210 U/l
Glucose	19.8 mmol/l
Neutrophils	12.6×10^9/l
MCV	102.4 fl

Hb	10.3 g/dl
WCC	17.2×10^9/l
PLT	9.0 /l
Na^+	131 mmol/l
K^+	2.8 mmol/l
Creatinine	165 µmol/l
Ca^{2+}	2.82 mmol/l
Bilirubin	64 µmol/l
ALT	140 U/l
ALP	210 U/l
Glucose	19.8 mmol/l
Neutrophils	12.6×10^9/l
MCV	102.4 fl

Results of an ECG show a fast AF.

What is the most likely diagnosis?

A Atypical pneumonia

B Diabetic ketoacidosis

C Thyroid storm

D Gastroenteritis

E Adverse drug reaction

C Thyroid storm

Her past history of diabetes mellitus and pernicious anaemia makes it more likely that she has a further autoimmune disorder. The history of weight loss suggests an underlying thyroid disorder, with the thyroid storm being precipitated by her chest infection. Thyroid storm is a sudden, life-threatening exacerbation of thyrotoxicosis. Some series suggest a mortality rate of between 30 and 75%. Its manifestations are due to the action of excess thyroid hormone. Fever is the most characteristic feature, with the temperature often rising above 41°C. There may be evidence of organ damage. The clinical picture is frequently clouded by a secondary infection such as pneumonia or a viral infection. Death may be caused by cardiac arrhythmia, congestive heart failure, hyperthermia or other unidentified factors. The diagnosis of thyroid storm is made entirely on clinical grounds. The results of thyroid function tests will rarely be available soon enough to make the diagnosis. Propylthiouracil followed by a stable iodine preparation (e.g. Lugol's iodine) is usually given. Propranolol, intravenous fluids, dexamethasone and cooling are also often required. Finally, one must remember to treat the precipitating cause.

A Atypical pneumonia

This is caused by 'atypical' pathogens such as *M. pneumoniae*, *Legionella* spp, C. *pneumonia* and *C. psittaci*. Absence of cough and respiratory signs on physical examination makes this diagnosis unlikely. Incubation period is usually within 10 days, and onset of illness to presentation time is usually within a week.

B Diabetic ketoacidosis

Diabetic ketoacidosis usually evolves within 24 h. It is characterised by the triad of metabolic acidosis (7.25 or

A 38-year-old man with a history of hypertension is referred to the endocrine clinic. The GP has not yet commenced anti-hypertensive therapy, but is worried as three measured BPs over the past 2 months have been >150 mmHg systolic. On examination he looks well and his BP is 157/92 mmHg. His BMI is 29.

Investigations:

Hb	12.1 g/dl	
WCC	4.1×10^9/l	
PLT	190×10^9/l	
Na^+	139 mmol/l	
K^+	3.9 mmol/l	
Creatinine	110 µmol/l	
Fasting glucose	5.2 nmol/l	
Urinary free cortisol	320 nmol/24 h (normal <280)	
Renin	Supine: 3.0 pmol/ml/h (normal 1.1-2.7)	Upright: 5.0 pmol/ml/h (normal 3.0-4.3) after 30 min
Aldosterone	Supine: 600 pmol/ml (normal 135-400) after 30 min	Upright: 1200 pmol/ml (normal 330-830) after 4 h

Which of the following is the most likely diagnosis?

A Primary hyperaldosteronism

WCC	4.1×10^9/l	
PLT	190×10^9/l	
Na^+	139 mmol/l	
K^+	3.9 mmol/l	
Creatinine	110 µmol/l	
Fasting glucose	5.2 nmol/l	
Urinary free cortisol	320 nmol/24 h (normal <280)	
Renin	Supine: 3.0 pmol/ml/h (normal 1.1-2.7)	Upright: 5.0 pmol/ml/h (normal 3.0-4.3) after 30 min
Aldosterone	Supine: 600 pmol/ml (normal 135-400) after 30 min	Upright: 1200 pmol/ml (normal 330-830) after 4 h

Which of the following is the most likely diagnosis?

A Primary hyperaldosteronism

B Cushing syndrome

C Phaeochromocytoma

D Renal artery stenosis

E Coarctation of the aorta

D Renal artery stenosis

Both this patient's renin and aldosterone levels are raised, which rules out primary hyperaldosteronism. The fact that this is secondary hyperaldosteronism raises the possibility of intrinsic renal disease, which given the options makes renal artery stenosis the most likely cause. The next diagnostic steps would be to consider a renal ultrasound scan and magnetic resonance angiogram.

A Primary hyperaldosteronism

This is effectively ruled out because of the elevation in renin levels seen here.

B Cushing syndrome

The urinary free cortisol is only slightly above the upper limit of normal and is therefore very unlikely to account for the hypertension seen here.

C Phaeochromocytoma

The raised renin and aldosterone levels are a pointer towards renal artery stenosis, and the hypertension seen with phaeochromocytoma is often episodic in nature.

E Coarctation of the aorta

Symptomatic coarctation of the aorta without other presenting features, such as shortness of breath on exercise, differential blood pressure in both arms and radio-femoral delay, is an unlikely alternative diagnosis.

Rate this question:

Rana Alnasser's screen

A 36-year-old man is admitted via the Emergency Department, having suffered a very severe headache after chasing a man who was stealing his car.

Previously fit and well and of normal stature, he was noted to be hypertensive on admission with a blood pressure (BP) of 165/90 mmHg, which later settled to 155/85 mmHg.

On further questioning, it was noted that his mother was known to have had 'thyroid cancer', and died at an early age.

What is the most likely unifying diagnosis behind his presentation?

A	Multiple endocrine neoplasia type 1 (MEN-1)
B	MEN-2b
C	MEN-2a
D	Familial medullary thyroid carcinoma syndrome
E	Von Hippel–Lindau disease

6456

Submit

Rana Alnasser's screen

Department, having suffered a very severe headache after chasing a man who was stealing his car.

Previously fit and well and of normal stature, he was noted to be hypertensive on admission with a blood pressure (BP) of 165/90 mmHg, which later settled to 155/85 mmHg.

On further questioning, it was noted that his mother was known to have had 'thyroid cancer', and died at an early age.

What is the most likely unifying diagnosis behind his presentation?

Your answer was correct

A	Multiple endocrine neoplasia type 1 (MEN-1)
B	MEN-2b
C	MEN-2a
D	Familial medullary thyroid carcinoma syndrome
E	Von Hippel–Lindau disease

Explanation

C MEN-2a

The history of marked hypertension in this gentleman, coupled with a family history of thyroid carcinoma, should raise the possibility of multiple endocrine neoplasia (MEN). MEN-2a is characterised by medullary thyroid carcinoma, phaeochromocytoma and parathyroid chief cell hyperplasia. It is likely that both this man and his mother carry the same mutation. Around 30% of carriers of an MEN-2a mutation never develop the associated clinical

Rana Alnasser's screen

C MEN-2a

The history of marked hypertension in this gentleman, coupled with a family history of thyroid carcinoma, should raise the possibility of multiple endocrine neoplasia (MEN). MEN-2a is characterised by medullary thyroid carcinoma, phaeochromocytoma and parathyroid chief cell hyperplasia. It is likely that both this man and his mother carry the same mutation. Around 30% of carriers of an MEN-2a mutation never develop the associated clinical syndrome.

The initial diagnostic investigation of choice for phaeochromocytoma is 24 h urinary catecholamine assay. Where the diagnosis is proven, it is sensible to screen for medullary thyroid carcinoma via pentagastrin testing. Conversely, where patients present with medullary thyroid carcinoma, they should be screened for phaeochromocytoma prior to consideration of surgery. Where adequate alpha blockade is not in place prior to surgery, there is a very real chance of hypertensive crisis and possible on-table myocardial infarction.

A Multiple endocrine neoplasia type 1 (MEN-1)

MEN-1 is associated with multiple parathyroid adenomas, pancreatic islet cell tumours and pituitary adenomas (prolactinomas being most commonly seen).

B MEN-2b

MEN-2b tends to occur as a sporadic mutation; additional features compared to MEN-2a include a marfanoid habitus and multiple mucosal neuromas.

D Familial medullary thyroid carcinoma syndrome

Familial medullary thyroid carcinoma syndrome is associated with the RET mutation, although presentation

Rana Alnasser's screen

MEN-1 is associated with multiple parathyroid adenomas, pancreatic islet cell tumours and pituitary adenomas (prolactinomas being most commonly seen).

B MEN-2b

MEN-2b tends to occur as a sporadic mutation; additional features compared to MEN-2a include a marfanoid habitus and multiple mucosal neuromas.

D Familial medullary thyroid carcinoma syndrome

Familial medullary thyroid carcinoma syndrome is associated with the RET mutation, although presentation with phaeochromocytoma would not be expected.

E Von Hippel–Lindau disease

VHL is associated with phaeochromocytoma, although it often presents earlier with balance disturbance due to the presence of CNS haemangioblastomas.

Rate this question:

Next Question

Previous Q... Tag Questi... Feedback End Session

Blog About Pastest Contact Us Help

© Pastest 2019

A 32-year-old bank clerk was admitted via A&E with a 2-day history of severe abdominal pain, nausea and vomiting. He had returned from a week's holiday in Crete 2 weeks ago. He says he is worried because he had numerous episodes of unprotected heterosexual intercourse. He is feeling weak, has lost his appetite and has lost 6.3 kg (1 stone) in weight. He smokes 20 cigarettes a day and often drinks a bottle of red wine for dinner. His mother has type 1 diabetes mellitus and his father has had a stroke. On examination his clothes hang loosely and he has a suntan. He is afebrile. His pulse is 60 bpm and his BP 80/40 mmHg. His heart sounds are normal and his chest is clear. His abdomen is soft but tender on palpation. Bowel sounds are present. His neurological examination is normal, as is a CXR.

Investigations:

Hb	11.0 g/dl
WCC	3.2×10^9/l
PLT	143×10^9/l
Na^+	121 mmol/l
K^+	5.0 mmol/l
Creatinine	65 µmol/l
Ca++	2.72 mmol/l
Urea	7.2 mmol/l
Albumin	34 g/l
Glucose	9.8 mmol/l
MCV	101.3 fl
Blood film	Macrocytosis

What is the most likely diagnosis?

present. His neurological examination is normal, as is a CXR.

Investigations:

Hb	11.0 g/dl
WCC	3.2×10^9/l
PLT	143×10^9/l
Na^+	121 mmol/l
K^+	5.0 mmol/l
Creatinine	65 µmol/l
Ca++	2.72 mmol/l
Urea	7.2 mmol/l
Albumin	34 g/l
Glucose	9.8 mmol/l
MCV	101.3 fl
Blood film	Macrocytosis

What is the most likely diagnosis?

A Gonococcal sepsis

B IV drug abuse

C Addison's disease

D Gastroenteritis

E Diabetic ketoacidosis

Rana Alnasser's screen

12:02
On
Pastest+
594-042-7551
Leave

C Addison's disease

Over 90% of patients diagnosed complain of weakness, hyperpigmentation, anorexia, nausea, vomiting and hypotension. In addition, the accompanying macrocytic anaemia suggests a diagnosis of pernicious anaemia. Between 70 and 90% of cases of Addison's disease in the UK are caused by autoimmune adrenalitis. The combination of a high ACTH concentration (>80 ng/l) and a poorly responsive Synacthen test is diagnostic of Addison's disease. The raised glucose raises the possibility of co-existent autoimmune diabetes, but the glucose isn't high enough to indicate ketoacidosis.

A Gonococcal sepsis

Gonococcal sepsis affects 0.5–3% patients with a sexually transmitted Gram-negative organism called *N. gonorrhoeae*. It presents as one of the two common syndromes: a triad of tenosynovitis, dermatitis and polyarthralgia without purulent arthritis (also called the 'arthritis–dermatitis syndrome'); or purulent arthritis without associated skin lesions.

B IV drug abuse

There would be signs of injection drug use, including scars at injection sites (so-called 'track marks') on the skin. When acutely unwell, patients can present with medical conditions affecting one or more system – the cardiovascular system (infective endocarditis, heart failure, cardiomyopathy, etc.); renal system (kidney failure); gastrointestinal system (pancreatitis, cirrhosis, chronic liver disease, infective hepatitis, etc.); central nervous system (dementia, memory impairment, cerebrovascular events, etc.); or respiratory system (lung abscess, pneumonia, chronic obstructive airway disease, TB, etc.).

Audio Video Share Participants More

B IV drug abuse

There would be signs of injection drug use, including scars at injection sites (so-called 'track marks') on the skin. When acutely unwell, patients can present with medical conditions affecting one or more system – the cardiovascular system (infective endocarditis, heart failure, cardiomyopathy, etc.); renal system (kidney failure); gastrointestinal system (pancreatitis, cirrhosis, chronic liver disease, infective hepatitis, etc.); central nervous system (dementia, memory impairment, cerebrovascular events, etc.); or respiratory system (lung abscess, pneumonia, chronic obstructive airway disease, TB, etc.).

D Gastroenteritis

Diarrhoea and frequent vomiting are usually present together, but the former symptom conspicuously is absent in this case making this diagnosis less likely. Vomiting can present in isolation in some cases of viral gastroenteritis, but the incubation period is usually shorter (<72 h).Weight loss in not present in the acute phase.

E Diabetic ketoacidosis

There is no weight loss as the presentation is acute, and the patient is significantly dehydrated. Laboratory investigations to confirm the diagnosis include the following: elevated plasma glucose (>13 mmol/l), arterial pH ≤7.3, serum bicarbonate ≤15 mmol/l, positive urine ketones, blood ketones ≥3 mmol/l.

Rate this question:

Next Question

A 68-year-old woman presents with an ulcer over the left medial malleolus on her left leg. She has a history of obesity and hypertension, and has been recently diagnosed with type 2 diabetes. On examination she has obvious bilateral varicose veins; there is no evidence of diabetic neuropathy.

Investigations:

Hb	14.0 g/dl
WCC	6.1 x10^9/l
PLT	310 x10^9/l
Na^+	140 mmol/l
K^+	5.0 mmol/l
Creatinine	140 µmol/l
Glucose	8.1 mmol/l
ABPI	0.9

Which of the following options offers the best chance for complete healing of the ulcer?

A Lower limb angioplasty

B Multi-layer bandaging

C Maggot therapy

D Surgical debridement

E Fucidin ointment

B Multi-layer bandaging

Multi-layer bandaging is most useful in reducing lower limb oedema and improving the chances of healing of venous ulcers. It is also crucial for patients to rest and keep the leg up where possible. An ankle brachial pressure index (ABPI) measurement is essential before beginning bandaging, as if there is significant arterial insufficiency, blood supply to the lower limb may be threatened. An ABPI of 0.8 has become a pivotal figure in the management of leg ulceration, defining the cut-off point for high-compression bandaging, and is frequently taken as indicating the presence of a so-called 'mixed ulcer'.

A Lower limb angioplasty

Lower limb angioplasty will improve arterial supply and has no significant impact on venous insufficiency.

C Maggot therapy

Although maggot therapy may be useful for debridement, it isn't the primary driver for healing of venous ulcers.

D Surgical debridement

Surgical debridement is only useful where there is significant necrotic tissue that risks extensive soft tissue infection.

E Fucidin ointment

Antibiotic ointment has not been shown to drive faster healing of venous ulcers.

Rate this question:

12:07
On
Pastest+
594-042-7551
Leave

A 31-year-old adopted man presents with acute onset central crushing chest pain. ECG confirms anterior myocardial infarction. He is a non-smoker. Cholesterol on admission was 10.5 mmol/l, with relatively normal triglycerides and a marked increase in LDL. You suspect he has familial hypercholesterolaemia. Physical findings in this man include tendon xanthomata, corneal arcus and xanthelasma.

Which of the following is the most appropriate long-term treatment for his hypercholesterolaemia?

A	Atorvastatin 10 mg OD
B	Atorvastatin 80 mg OD
C	Nicotinic acid 1.5 g OD
D	Bezafibrate 200 mg BD
E	Pravastatin 40 mg OD

32910

Submit

Blog About Pastest Contact Us Help
Audio Video Share Participants More

B Atorvastatin 80 mg OD

This patient is at serious risk of further cardiovascular events and requires maximal statin therapy to reduce his LDL cholesterol. If 80 mg of atorvastatin fails to achieve the LDL target, ezetimibe can be added. Evolocumab, a PCSK9 inhibitor, is also now available for familial hypercholesterolaemia to further drive down cholesterol levels.

A Atorvastatin 10 mg OD

This will not achieve the LDL target given the high baseline.

C Nicotinic acid 1.5 g OD

Nicotinic acid primarily targets hypertriglyceridaemia and drives a modest rise in HDL cholesterol, rather than specifically targeting LDL. Tolerability is poor in many patients due to symptoms of itching and facial flushing.

D Bezafibrate 200 mg BD

Fibrates remain the treatment of choice for hypertriglyceridaemia, although the FIELD outcome study did not indicate a significant impact on cardiovascular risk.

E Pravastatin 40 mg OD

Pravastatin 40 mg has only modest effects on LDL cholesterol and is therefore unlikely to achieve target here.

Rate this question:

Rana Alnasser's screen

12:08
On
Pastest+
594-042-7551
Leave

A 21-year-old student nurse presents with frequent episodes of collapse. One of these occurred during a placement in the Emergency Department at the same time as a cardiac arrest. Blood glucose at the time was noted to be 1.4 mmol/l. Other blood tests were unremarkable.

On examination straight after an event, her BP was 123/82 mmHg, withpulse is 95/min and regular and she was cold and sweaty. Blood taken at the time confirmed a venous blood glucose of 1.2 mmol/l, C-peptide level was low-normal and insulin levels were markedly elevated.

Which of the following is the most likely diagnosis in this case?

A	Insulinoma
B	Sulphonylurea misuse
C	Insulin misuse
D	Alcohol misuse
E	Retroperitoneal sarcoma

Submit

Audio
Video
Share
Participants
More

A 21-year-old student nurse presents with frequent episodes of collapse. One of these occurred during a placement in the Emergency Department at the same time as a cardiac arrest. Blood glucose at the time was noted to be 1.4 mmol/l. Other blood tests were unremarkable.

On examination straight after an event, her BP was 123/82 mmHg, withpulse is 95/min and regular and she was cold and sweaty. Blood taken at the time confirmed a venous blood glucose of 1.2 mmol/l, C-peptide level was low-normal and insulin levels were markedly elevated.

Which of the following is the most likely diagnosis in this case?

Your answer was correct

A	Insulinoma
B	Sulphonylurea misuse
C	Insulin misuse
D	Alcohol misuse
E	Retroperitoneal sarcoma

Explanation

C Insulin misuse

Hyperinsulinaemia in the presence of a normal or low C-peptide is suggestive of insulin misuse, which is unfortunately a more common occurrence in healthcare

D Alcohol misuse

E Retroperitoneal sarcoma

Explanation

C Insulin misuse

Hyperinsulinaemia in the presence of a normal or low C-peptide is suggestive of insulin misuse, which is unfortunately a more common occurrence in healthcare professionals who are seeking attention, as is the case here. As here, measurement of insulin, glucose and C-peptide at the time of a collapse is crucial for making the diagnosis.

A Insulinoma

Insulinoma is a rare occurrence, and is associated with elevated insulin and C-peptide. Overnight fasting, coupled with supervised exercise, is the most commonly used protocol to drive a hypoglycaemic episode.

B Sulphonylurea misuse

Elevation in both C-peptide and insulin may raise suspicion of sulphonylurea abuse. It is possible to assay levels of commonly used sulphonylureas in urine, and this should be considered.

D Alcohol misuse

Hypoglycaemia does occur in association with alcohol misuse, but this is commonly following a period of binge drinking and it's unlikely this person could work in a hospital environment whilst having consumed significant

An 18-year-old woman is admitted with diabetic ketoacidosis. She is usually managed with basal bolus insulin but has omitted a number of doses due to a row with her boyfriend. On examination her respiratory rate is 35/min, she is drowsy, confused and smells of pear drops.

Which of the following results would fit best with her arterial blood gases?

A	pH 7.4; pCO_2 3.0 mmol/l; pO_2 12.1 mmol/l
B	pH 7.5; pCO_2 3.0 mmol/l; pO_2 7.4 mmol/l
C	pH 7.25; pCO_2 6.7 mmol/l; pO_2 7.4 mmol/l
D	pH 7.1; pCO_2 3.0 mmol/l; pO_2 11.1 mmol/l
E	pH 7.4; pCO_2 6.7 mmol/l; pO_2 6.7 mmol/l

212/19

Submit

© Pastest 2019

Your answer was correct

A	pH 7.4; pCO_2 3.0 mmol/l; pO_2 12.1 mmol/l
B	pH 7.5; pCO_2 3.0 mmol/l; pO_2 7.4 mmol/l
C	pH 7.25; pCO_2 6.7 mmol/l; pO_2 7.4 mmol/l
D	pH 7.1; pCO_2 3.0 mmol/l; pO_2 11.1 mmol/l
E	pH 7.4; pCO_2 6.7 mmol/l; pO_2 6.7 mmol/l

Explanation

D	pH 7.1; pCO_2 3.0 mmol/l; pO_2 11.1 mmol/l

The characteristic picture of metabolic acidosis with hyperventilation and the smell of pear drops is typical of diabetic ketoacidosis. Hyperglycaemia with a relatively normal pH is of course seen in patients with hyperosmolar non-ketotic coma, typically found in the elderly population with type 2 diabetes who retain enough residual insulin production to avoid becoming ketotic.

A	pH 7.4; pCO_2 3.0 mmol/l; pO_2 12.1 mmol/l

Drowsiness with respiratory compensation accompanied by a pear drop smell would always imply a metabolic acidosis due to diabetic ketoacidosis until proven otherwise.

B	pH 7.5; pCO_2 3.0 mmol/l; pO_2 7.4 mmol/l

This implies an alkalosis, and with a low CO_2 this would be respiratory in origin.

A pH 7.4; pCO_2 3.0 mmol/l; pO_2 12.1 mmol/l

Drowsiness with respiratory compensation accompanied by a pear drop smell would always imply a metabolic acidosis due to diabetic ketoacidosis until proven otherwise.

B pH 7.5; pCO_2 3.0 mmol/l; pO_2 7.4 mmol/l

This implies an alkalosis, and with a low CO_2 this would be respiratory in origin.

C pH 7.25; pCO_2 6.7 mmol/l; pO_2 7.4 mmol/l

The pCO_2 here is elevated, which implies a respiratory rather than a metabolic acidosis.

E pH 7.4; pCO_2 6.7 mmol/l; pO_2 6.7 mmol/l

A normal pH is inconsistent with this presentation, and the elevated pCO_2 implies a respiratory acidosis with metabolic compensation.

Rate this question:

Next Question

Previous Q... Tag Questi... Feedback End Session

Blog About Pastest Contact Us Help

© Pastest 2019

A 69-year-old man with long-standing type 2 diabetes managed with metformin 1 g BD, liraglutide 1.8 mg daily and glargine 30 mg nocte. He complains of burning pain affecting both feet, much worse at night. Other history of note includes problems with intermittent urinary retention. On examination his BMI is 32, and his BP is 149/82 mmHg. His feet feel warm and his peripheral pulses are easily palpable.

Investigations:

Hb	11.6 g/dl
WCC	4.5 x10^9/l
PLT	244 x10^9/l
Na^+	139 mmol/l
K^+	4.8 mmol/l
Creatinine	145 µmol/l
HbA1c	57.38 mmol/mol (7.4%)

Which of the following represents the most appropriate first line treatment in this case?

A Duloxetine

B Carbamazepine

C Capsaicin

D Sodium valproate

E Amitriptyline

A Duloxetine

There is no indication of peripheral vascular disease, and the most likely diagnosis appears to be peripheral neuropathy. NICE guidelines recommend duloxetine, amitriptyline or gabapentin as potential initial therapies. Duloxetine is preferred to amitryptiline because it is associated with a lower risk of urinary retention.

B Carbamazepine

This is thought to be less effective than amitryptiline and is associated with increased risk of hyponatraemia.

C Capsaicin

It is a topical agent used for the treatment of neuropathy in addition to systemic agents, or for patients who are unable to take them.

D Sodium valproate

Sodium valproate is an alternative therapy for peripheral diabetic neuropathy, but isn't recommended as a first-line option by NICE guidelines.

E Amitriptyline

This isn't preferred here because of a higher risk of urinary retention versus duloxetine.

Rate this question:

A 25-year-old woman comes to the clinic with her 5-month-old baby. Over the past few weeks she has been feeling increasingly tired, but the GP has dismissed the problem as the usual tiredness after having a baby. She tells you she feels tired, has put on weight and is constipated all the time, feeling the cold when she goes out. On further questioning, she tells you this wasn't always the case, and that in fact during the first few months she actually felt like she had more energy and could survive on hardly any sleep at all. On examination her BP is 142/70 mmHg, with pulse is 65/min. Her BMI is 28. You notice that her hair and skin are quite dry.

Investigations:

Hb	10.9 g/dl
WCC	6.7 x10^9/l
PLT	190 x10^9/l
Na^+	140 mmol/l
K^+	4.9 mmol/l
Creatinine	100 µmol/l
Cholesterol	6.2 mmol/l
TSH	7.1 U/l
Free T4	7.1 pmol/l
Anti-thyroid antibody	+ve

Which of the following is the most likely diagnosis?

A Graves' disease

B Subacute thyroiditis

Rana Alnasser's screen

mmHg, with pulse is 65/min. Her BMI is 28. You notice that her hair and skin are quite dry.

Investigations:

Hb	10.9 g/dl
WCC	6.7 x10^9/l
PLT	190 x10^9/l
Na^+	140 mmol/l
K^+	4.9 mmol/l
Creatinine	100 µmol/l
Cholesterol	6.2 mmol/l
TSH	7.1 U/l
Free T4	7.1 pmol/l
Anti-thyroid antibody	+ve

Which of the following is the most likely diagnosis?

A Graves' disease

B Subacute thyroiditis

C Hashimoto's thyroiditis

D Post-partum thyroiditis

E Sick euthyroid syndrome

Submit

PLT	190 x10⁹/l
Na^+	140 mmol/l
K^+	4.9 mmol/l
Creatinine	100 µmol/l
Cholesterol	6.2 mmol/l
TSH	7.1 U/l
Free T4	7.1 pmol/l
Anti-thyroid antibody	+ve

Which of the following is the most likely diagnosis?

Your answer was correct

A Graves' disease

B Subacute thyroiditis

C Hashimoto's thyroiditis

D Post-partum thyroiditis

E Sick euthyroid syndrome

Explanation

D Post-partum thyroiditis

The history here suggests that an early period of possible thyrotoxicosis has now been followed with symptoms of hypothyroidism, with hypothyroidism confirmed on

Explanation

D Post-partum thyroiditis

The history here suggests that an early period of possible thyrotoxicosis has now been followed with symptoms of hypothyroidism, with hypothyroidism confirmed on biochemical testing. The timing after the birth of her child suggests this is post-partum thyroiditis. Treatment is with thyroxine replacement, although withdrawal may be possible in some patients who recover normal thyroid function. Recurrence of thyroiditis is common in subsequent pregnancies, however, and in up to 40% permanent hypothyroidism develops. The presence of anti-thyroid antibodies does put her at higher risk of permanent hypothyroidism.

A Graves' disease

Graves' disease is characterised by thyrotoxicosis rather than the picture of hypothyroidism seen here.

B Subacute thyroiditis

Subacute thyroiditis is associated with symptoms of a flu-like illness and pain over the thyroid gland. An initial period of thyrotoxicosis is followed by transient hypothyroidism and then recovery.

C Hashimoto's thyroiditis

Hashimoto's disease is the main differential here, although this patient's recent pregnancy makes post-partum thyroiditis more likely.

E Sick euthyroid syndrome

Sick euthyroid syndrome is associated with a significant

A 24-year-old woman presents to the clinic with recurrent palpitations. She continues to hold down her job as a nurse on the Cardiology Ward of the local hospital but feels increasingly tired. There is no past medical history of note and her only medication is the oral contraceptive pill.

On examination, her BP is 122/72 mmHg, with pulse 70/min and regular. Her BMI is 25. Her TSH is 0.15 mU/l (0.4–5), free T4 is 20.0 pmol/l (10–22) and free T3 is 9.3 pmol/l (5–10).

Which of the following is the most likely diagnosis?

A	Subclinical thyrotoxicosis
B	Pituitary failure
C	Sick euthyroid syndrome
D	Addison's disease
E	Thyrotoxicosis factitia

Submit

12:17

MyPastest
https://mypastest.pastest.com

Pastest+

A 24-year-old woman presents to the clinic with recurrent palpitations. She continues to hold down her job as a nurse on the Cardiology Ward of the local hospital but feels increasingly tired. There is no past medical history of note and her only medication is the oral contraceptive pill.

On examination, her BP is 122/72 mmHg, with pulse 70/min and regular. Her BMI is 25. Her TSH is 0.15 mU/l (0.4–5), free T4 is 20.0 pmol/l (10–22) and free T3 is 9.3 pmol/l (5–10).

Which of the following is the most likely diagnosis?

Your answer was correct

A	Subclinical thyrotoxicosis
B	Pituitary failure
C	Sick euthyroid syndrome
D	Addison's disease
E	Thyrotoxicosis factitia

Explanation

A	Subclinical thyrotoxicosis

The TSH is below the lower limit of normal, and the T3 and T4 are at the upper limit of the normal range. This picture fits best with a diagnosis of subclinical thyrotoxicosis. Patients with subclinical thyrotoxicosis are at increased risk of incident atrial fibrillation and coronary heart disease

A Subclinical thyrotoxicosis

The TSH is below the lower limit of normal, and the T3 and T4 are at the upper limit of the normal range. This picture fits best with a diagnosis of subclinical thyrotoxicosis. Patients with subclinical thyrotoxicosis are at increased risk of incident atrial fibrillation and coronary heart disease (although ischaemic events are very unlikely in a patient of this age). At this stage no treatment is indicated, although thyroid function tests should be repeated in another 2–3 months.

B Pituitary failure

Pituitary failure would be associated with a low TSH, and T3 and T4 below the lower limit of normal. Other features such as postural hypotension would also be expected.

C Sick euthyroid syndrome

Sick euthyroid syndrome is associated with a significant non-thyroidal illness, where T3 and T4 are reduced; recovery is spontaneous and no intervention is required.

D Addison's disease

Addison's is usually associated with a hypothyroid picture on blood testing.

E Thyrotoxicosis factitia

Although this patient having taken a small dose of thyroid hormone can't be excluded, abuse of thyroid hormone is more likely to lead to T4 outside the upper limit of the normal range.

A type-2 diabetic man presents to the diabetic clinic as a new patient referred from his GP. He has a past history of hypertension, heart failure and hypothyroidism. His BMI is 36. He is currently on metformin 500 mg bd and has excellent compliance. He was previously on gliclazide in addition to metformin, but this was stopped when he was admitted to hospital following a collapse. His $HbA1_c$ is 85.79 mmol/mol (10%).

Which one of the following treatments would be the most suitable?

A	Add in Pioglitazone
B	Add in glimepiride
C	Add in liraglutide
D	Add in nocturnal isophane insulin
E	Increase metformin to 1g bd

Submit

© Pastest 2019

A type-2 diabetic man presents to the diabetic clinic as a new patient referred from his GP. He has a past history of hypertension, heart failure and hypothyroidism. His BMI is 36. He is currently on metformin 500 mg bd and has excellent compliance. He was previously on gliclazide in addition to metformin, but this was stopped when he was admitted to hospital following a collapse. His $HbA1_c$ is 85.79 mmol/mol (10%).

Which one of the following treatments would be the most suitable?

Your answer was correct

A	Add in Pioglitazone
B	Add in glimepiride
C	Add in liraglutide
D	Add in nocturnal isophane insulin
E	Increase metformin to 1g bd

Explanation

C Add in liraglutide

Despite excellent compliance with treatment, this patient's $HbA1_c$ remains well above the target range at 85.79 mmol/mol (10%). As treatment intensification with a sulphonylurea or pioglitazone is contraindicated in this case, and the patient's BMI is greater than 35, NICE

C Add in liraglutide

Despite excellent compliance with treatment, this patient's $HbA1_c$ remains well above the target range at 85.79 mmol/mol (10%). As treatment intensification with a sulphonylurea or pioglitazone is contraindicated in this case, and the patient's BMI is greater than 35, NICE advocates the use of a GLP-1 agonist such as liraglutide. Liraglutide binds to and activates the GLP-1 receptor to increase insulin secretion, suppress glucagon secretion and slow gastric emptying. This should only be continued if a patient has a reduction in HbA1c of at least 11 mmol/mol and a weight loss of at least 3% of initial body weight in 6 months.

A Add in Pioglitazone

Pioglitazone is contraindicated in this patient due to the history of heart failure.

B Add in glimepiride

Sulphonylureas would usually be used as a second-line treatment in addition to metformin. However, the patient has already previously been on a sulphonylurea which was stopped due to an episode of collapse. It is therefore unlikely that a sulphonylurea would be trialled again due to the risk of hypoglycaemia.

D Add in nocturnal isophane insulin

The addition of insulin to the patient's current dose of metformin may be the best way to improve his $HbA1_c$. The most common way to do this is to introduce a once-daily, bedtime injection of long-acting insulin to be given in addition to the patient's current oral hypoglycaemic agents (for example, Humulin I). However, the implication in this

Sulphonylureas would usually be used as a second-line treatment in addition to metformin. However, the patient has already previously been on a sulphonylurea which was stopped due to an episode of collapse. It is therefore unlikely that a sulphonylurea would be trialled again due to the risk of hypoglycaemia.

D	Add in nocturnal isophane insulin

The addition of insulin to the patient's current dose of metformin may be the best way to improve his $HbA1_c$. The most common way to do this is to introduce a once-daily, bedtime injection of long-acting insulin to be given in addition to the patient's current oral hypoglycaemic agents (for example, Humulin I). However, the implication in this question is that the patient has previously had a problem with hypoglycaemia. Insulin should therefore be avoided unless absolutely necessary.

E	Increase metformin to 1g bd

It is very unlikely that the patient will reach the target $HbA1_c$ of 7.5% or lower through monotherapy, and increasing the dose of metformin further is more likely to result in GI side effects.

Rate this question:

Previous Q... Tag Questi... Feedback End Session

Blog About Pastest Contact Us Help

A 45-year-old man comes to the clinic for review. He has been referred by his GP for an obvious slowly enlarging mass in the left lobe of the thyroid. He is concerned he might have cancer.

Which of the following would increase the likelihood in this patient of underlying thyroid malignancy?

A	Family history of hyperthyroidism
B	Strong family history of breast cancer requiring multiple check-up mammograms
C	Abuse of thyroid tablets as a teenager
D	Family history of familial adenomatous polyposis (FAP)
E	Male sex

Submit

Previous Q... Skip Questi...

© Pastest 2019

Explanation

D Family history of familial adenomatous polyposis (FAP)

FAP is caused by an APC gene mutation on chromosome 5, and is also associated with increased risk of developing thyroid cancer.

B Strong family history of breast cancer requiring multiple check-up mammograms

A familial history of breast cancer is most closely associated with increased risk of ovarian cancer.

A Family history of hyperthyroidism

Endemic goitre, Hashimoto's thyroiditis and thyroid adenoma, not hyperthyroidism, are associated with increased risk of thyroid malignancy.

C Abuse of thyroid tablets as a teenager

Thyrotoxicosis factitia, or abuse of thyroid hormone, is not associated with increased risk of thyroid cancer.

E Male sex

Females are three times more likely to develop thyroid cancer than males.

Rate this question:

Next Question

A pregnant lady at 26 weeks of gestation has clinical evidence of hyperthyroidism. She is very anxious and complains of palpitations, heat intolerance and difficulty maintaining her weight during the pregnancy. On examination her BP is 120/70 mmHg, with pulse 95/min regular. There is no obvious goitre on neck examination.

Investigations:

Hb	11.9 g/dl
WCC	5.4 x10^9/l
PLT	190 x10^9/l
Na^+	140 mmol/l
K^+	4.5 mmol/l
Creatinine	94 µmol/l
TSH	<0.05 U/l (<0.5-4.5)
Anti-thyroid antibodies	+ve

How would you propose to manage her?

A Carbimazole

B Radioiodine

C Propylthiouracil

D Propranolol

E Prednisolone

B Radioiodine

This is contraindicated in pregnancy because of accumulation in both the fetal thyroid and the mother's thyroid gland.

C Propylthiouracil

Propylthiouracil is now rarely used in late pregnancy because of case reports of maternal hepatotoxicity.

D Propranolol

Although propranolol will treat symptoms of thyrotoxicosis, it won't significantly impact on the risk of miscarriage.

E Prednisolone

Prednisolone doesn't significantly impact on the progression of autoimmune thyrotoxicosis in pregnancy and therefore has no role here.

21474

Rate this question:

Next Question

Previous Q... Tag Questi... Feedback End Session

Blog About Pastest Contact Us Help

© Pastest 2019

A 45-year-old lady had some blood tests as part of a medical examination for life insurance. She is completely well and takes no regular medication. Apparently another member of her family is noted to have high calcium levels, but has required no intervention.

Investigations:

Corrected calcium	2.88 mmol/l

Her GP therefore added some blood tests, which were as follows:

Parathyroid hormone (PTH)	4.7 pmol/l (0.9-5.4)
Urinary calcium-to-creatinine ratio	< 0.01, indicating relative hypocalciuria
Serum ACE	30 U/l (25-82)

Which of the following is the most likely diagnosis?

A Bronchial carcinoma

B Primary hyperparathyroidism

C Familial hypocalciuric hypercalcaemia (FHH)

D Sarcoidosis

E Paget's disease

A 45-year-old lady had some blood tests as part of a medical examination for life insurance. She is completely well and takes no regular medication. Apparently another member of her family is noted to have high calcium levels, but has required no intervention.

Investigations:

Corrected calcium	2.88 mmol/l

Her GP therefore added some blood tests, which were as follows:

Parathyroid hormone (PTH)	4.7 pmol/l (0.9-5.4)
Urinary calcium-to-creatinine ratio	< 0.01, indicating relative hypocalciuria
Serum ACE	30 U/l (25–82)

Which of the following is the most likely diagnosis?

Your answer was correct

A Bronchial carcinoma

B Primary hyperparathyroidism

C Familial hypocalciuric hypercalcaemia (FHH)

D Sarcoidosis

E Paget's disease

Explanation

C Familial hypocalciuric hypercalcaemia (FHH)

This lady is well but has elevated calcium. Her parathyroid hormone and serum ACE are normal. Her calcium-to-creatinine ratio is <0.01, indicating reduced excretion of calcium. This is characteristic of FHH, which is a defect in the calcium-sensing receptor (plasma membrane G-protein coupled receptor). No treatment is usually needed. FHH is characterised by hypercalcaemia, relative hypocalciuria, slight hypermagnesaemia and inappropriately normal to high levels of PTH.

A Bronchial carcinoma

Squamous cell carcinoma of the bronchus is associated with production of parathyroid hormone-related PTH (PTHrP), which is a cause of hypercalcaemia, but should actually suppress endogenous PTH production. Other features suggestive of bronchial carcinoma, such as a cough or smoking history, are also absent in this scenario.

B Primary hyperparathyroidism

Relative hypocalciuria was previously thought to differentiate between primary hyperparathyroidism and FHH, although population analyses of patients with primary hyperparathyroidism cast doubt on this as a differentiating factor. The inheritance pattern indicating other affected family members does, however, support a diagnosis of FHH.

D Sarcoidosis

Where there is significant sarcoid disease activity, leading to a raised serum calcium, angiotensin-converting enzyme levels are usually elevated. Normal levels seen here count against sarcoidosis as the cause of hypercalcaemia.

Relative hypocalciuria was previously thought to differentiate between primary hyperparathyroidism and FHH, although population analyses of patients with primary hyperparathyroidism cast doubt on this as a differentiating factor. The inheritance pattern indicating other affected family members does, however, support a diagnosis of FHH.

D Sarcoidosis

Where there is significant sarcoid disease activity, leading to a raised serum calcium, angiotensin-converting enzyme levels are usually elevated. Normal levels seen here count against sarcoidosis as the cause of hypercalcaemia.

E Paget's disease

Paget's disease is associated with elevated alkaline phosphatase and joint pain, and is usually only associated with hypercalcaemia when patients spend a significant period of time recumbent in bed.

Rate this question:

Next Question

Previous Q... Tag Questi... Feedback End Session

Blog About Pastest Contact Us Help

© Pastest 2019

A 55-year-old man presents to his GP complaining of a cough and breathlessness that has been present for about 2 weeks. He reports that prior to the onset of these symptoms, he was fit and well and was not on any medication. He is a known smoker of 10 cigarettes per day and has been smoking for over 25 years. On examination, the GP was unable to elicit any positive clinical signs and diagnosed a mild viral chest infection and reassured the patient that the symptoms would settle of their own accord. Two weeks later, the patient then presented again to the GP, this time complaining of thirst, polyuria and generalised muscle weakness. His blood pressure was elevated at 155/95 mmHg. The GP noticed the presence of ankle oedema. A prick test confirmed the presence of hyperglycaemia and the patient was referred to the hospital for investigations where the medical registrar ordered a variety of blood tests.

Some of these results are shown below:

Na^+	144 mmol/l
K^+	2.2 mmol/l
Bicarbonate	34 mmol/l
Glucose	16 mmol/l

What is the most likely diagnosis?

A Ectopic ACTH production

B Cushing's disease

C Dermatomyositis

D Primary hyperaldosteronism

E Adrenal insufficiency

A 55-year-old man presents to his GP complaining of a cough and breathlessness that has been present for about 2 weeks. He reports that prior to the onset of these symptoms, he was fit and well and was not on any medication. He is a known smoker of 10 cigarettes per day and has been smoking for over 25 years. On examination, the GP was unable to elicit any positive clinical signs and diagnosed a mild viral chest infection and reassured the patient that the symptoms would settle of their own accord. Two weeks later, the patient then presented again to the GP, this time complaining of thirst, polyuria and generalised muscle weakness. His blood pressure was elevated at 155/95 mmHg. The GP noticed the presence of ankle oedema. A prick test confirmed the presence of hyperglycaemia and the patient was referred to the hospital for investigations where the medical registrar ordered a variety of blood tests.

Some of these results are shown below:

Na^+	144 mmol/l
K^+	2.2 mmol/l
Bicarbonate	34 mmol/l
Glucose	16 mmol/l

What is the most likely diagnosis?

Your answer was correct

A Ectopic ACTH production

B Cushing's disease

C Dermatomyositis

A

B

C

D

E

Explanation

A Ectopic ACTH production

The suspicion here is that this patient has a small (oat) cell carcinoma of the lung which is a rapidly growing aggressive tumour characterised by early spread to distant sites. Patients often present with disseminated disease. A feature of this tumour is the range of paraneoplastic syndromes that occur due to the production of a variety of peptide hormones, the most common of which are the syndrome of inappropriate secretion of antidiuretic hormone (SIADH) and the syndrome of ectopic adrenocorticotropin hormone (ACTH) production. Typical features of Cushing's syndrome are often absent in these patients but they may present with pigmentation and weight loss accompanied by hyperglycaemia, hypokalaemia, a metabolic alkalosis and increased serum and urine cortisol concentrations.

B Cushing's disease

Given this patient is a known smoker with respiratory symptoms, ectopic ACTH production is more likely than a pituitary adenoma driving Cushing's disease.

C Dermatomyositis

Dermatomyositis is associated with proximal myopathy, but not with the other features of hyperadrenalism seen here including metabolic alkalosis and raised blood glucose.

D Primary hyperaldosteronism

Although the blood pressure is elevated, the hyperglycaemia seen here is more consistent with a diagnosis of elevated cortisol.

A 45-year-old contract painter presents for review. He consulted the GP complaining of tiredness and lethargy, abdominal pain and headaches. He works regularly on renovation jobs in old houses.

Only past history of note includes atenolol for hypertension and gout, which has become a recent problem over the past few months.

On examination, his BP is 138/80 mmHg, with pulse 72 and regular. He looks pale and has a peripheral neuropathy.

Investigations:

Hb	9.1 g/dl (hypochromic, microcytic anaemia)
WCC	9.7×10^9/l
PLT	173×10^9/l
Na^+	133 mmol/l
K^+	3.4 mmol/l
Creatinine	122 µmol/l
Uric acid	680 µmol/l

What diagnosis fits best with this clinical picture?

A Acute interstitial nephritis

B Lead poisoning

C Hypertensive nephropathy

D Pseudohypoaldosteronism

E Atenolol use

and gout, which has become a recent problem over the past few months.

On examination, his BP is 138/80 mmHg, with pulse 72 and regular. He looks pale and has a peripheral neuropathy.

Investigations:

Hb	9.1 g/dl (hypochromic, microcytic anaemia)
WCC	9.7×10^9/l
PLT	173×10^9/l
Na^+	133 mmol/l
K^+	3.4 mmol/l
Creatinine	122 µmol/l
Uric acid	680 µmol/l

What diagnosis fits best with this clinical picture?

Your answer was correct

A Acute interstitial nephritis

B Lead poisoning

C Hypertensive nephropathy

D Pseudohypoaldosteronism

E Atenolol use

Explanation

Rana Alnasser's screen

B Lead poisoning

The picture here, with hypochromic, microcytic anaemia, gout and hypokalaemia, fits best with lead poisoning. Lead nephropathy leads to proximal tubular defects including phosphate, amino acid and glucose loss in the urine. Pencillamine is one effective treatment for lead poisoning, promoting increased lead excretion; other options include dimercaptosuccinic acid (DMSA) and calcium disodium edetate. Reduced lead levels over time can result in a partial reversal of aldosterone resistance.

A Acute interstitial nephritis

Typically, acute interstitial nephritis begins abruptly, manifesting as acute kidney injury. In most instances, acute interstitial nephritis occurs within days of exposure to the offending drug. In some instances (particularly with nonsteroidal anti-inflammatory drugs [NSAIDs]), acute interstitial nephritis begins after several months of exposure. Almost all acute interstitial nephritides are caused by hypersensitivity reactions to drugs and are not mediated by direct toxicity. Although any drug can potentially cause a hypersensitivity reaction involving the kidney, the following agents are the most frequently implicated:

- Antibiotics (e.g. penicillins, cephalosporins, sulfa drugs, quinolones)
- NSAIDs
- Diuretics (e.g. thiazides, furosemide)
- Allopurinol
- Phenytoin
- Rifampin
- Interferon alfa
- Proton pump inhibitors.

nephropathy tend to have disproportionately worse hyperuricaemia compared to patients with other kidney diseases, because of the unique effects of lead on urate metabolism, and, consequently, gout is common.

D	Pseudohypoaldosteronism

Pseudohypoaldosteronism comprises a heterogeneous group of disorders of electrolyte metabolism characterised by an apparent state of renal tubular unresponsiveness or resistance to the action of aldosterone. It is manifested by hyperkalaemia, metabolic acidosis and a normal glomerular filtration rate (GFR). In our case, there is mild hypokalaemia and reduced

GFR; therefore, the diagnosis of pseudohypoaldosteronism is unlikely.

E	Atenolol use

Atenolol is unlikely to have caused the kidney disease; however, dose adjustment is required according to the patient's creatinine clearance.

Rate this question:

Next Question

Previous Q... Tag Questi... Feedback End Session

© Pastest 2019

A 72-year-old woman comes to the clinic for review. She has difficult-to-control hypertension and impaired glucose tolerance. She also suffers from regular snoring and often stops breathing at night.

A blood test for insulin-like growth factor 1 (IGF-1) is markedly elevated.

Her external appearance is shown below.

A magnetic resonance imaging (MRI) scan reveals a 4-mm pituitary adenoma.

Which of the following is the most appropriate intervention?

A	Bromocriptine
B	Ketoconazole
C	Nocturnal continuous positive airway pressure (CPAP)
D	Pioglitazone
E	Pituitary adenomectomy



A magnetic resonance imaging (MRI) scan reveals a 4-mm pituitary adenoma.

Which of the following is the most appropriate intervention?

Your answer was correct

A	Bromocriptine
B	Ketoconazole
C	Nocturnal continuous positive airway pressure (CPAP)
D	Pioglitazone
E	Pituitary adenomectomy

Explanation

E	Pituitary adenomectomy

This patient has symptoms of acromegaly, with the biochemistry consistent with the diagnosis, (impaired glucose tolerance and raised IGF-1) and a positive MRI scan. Progression to surgery, usually via a trans-sphenoidal approach, is the most appropriate intervention.

Ketoconazole can be used to suppress adrenal corticosteroid production. It can be used to treat resistant symptoms of Cushing syndrome in patients with adrenal carcinoma.

C	Nocturnal continuous positive airway pressure (CPAP)

The symptoms of sleep apnoea in this case are related to acromegaly and are likely to improve significantly post-surgery. CPAP may, in some cases, still be required, but the patient should be reassessed once a biochemical cure has been achieved.

D	Pioglitazone

Pioglitazone is an insulin sensitiser; it has been shown in studies to reduce the progression of impaired glucose tolerance to diabetes, but it does not have an indication for the condition. In this case, glucose tolerance is likely to normalise after surgery and no medical intervention is required.

Rate this question:

Next Question

Previous Q... Tag Questi... Feedback End Session

Blog About Pastest Contact Us Help

© Pastest 2019

A 27-year-old woman is brought to the Emergency room by the police. She is convinced that her husband is trying to poison her. Her husband tells you that she is hardly sleeping and seems almost hyperactive at present. She has a first child who is 4 months old. On examination her BP is 150/85 mmHg, with a pulse of 100/min and atrial fibrillation.

Investigations:

Hb	12.5 g/dl
WCC	5.7 x10^9/l
PLT	282 x10^9/l
Na^+	139 mmol/l
K^+	4.8 mmol/l
Creatinine	90 µmol/l
TSH	<0.05 U/l
T4	31.2 nmol/l
Anti-microsomal antibody	+

Which of the following is the most likely diagnosis?

A Hashimoto's thyroiditis

B Graves' disease

C Post-partum thyroiditis

D Post-natal depression

E Atrophic thyroiditis

Na	139 mmol/l
K^+	4.8 mmol/l
Creatinine	90 µmol/l
TSH	<0.05 U/l
T4	31.2 nmol/l
Anti-microsomal antibody	+

Which of the following is the most likely diagnosis?

Your answer was correct

A Hashimoto's thyroiditis

B Graves' disease

C Post-partum thyroiditis

D Post-natal depression

E Atrophic thyroiditis

Explanation

C Post-partum thyroiditis

Post-partum thyroiditis presents with hyperthyroidism in around 1/3 of sufferers some 1-4 months post-pregnancy. In rare cases thyrotoxicosis may be associated with a psychotic presentation, as seen here. The period of hyperthyroidism is followed by hypothyroidism and then resolution of the condition in the majority of patients; however, 1/3 of women develop permanent hypothyroidism, in which case permanent thyroid

C Post-partum thyroiditis

Post-partum thyroiditis presents with hyperthyroidism in around 1/3 of sufferers some 1-4 months post-pregnancy. In rare cases thyrotoxicosis may be associated with a psychotic presentation, as seen here. The period of hyperthyroidism is followed by hypothyroidism and then resolution of the condition in the majority of patients; however, 1/3 of women develop permanent hypothyroidism, in which case permanent thyroid replacement is required.

A Hashimoto's thyroiditis

The time of presentation is more consistent with post-partum thyroiditis, and patients with Hashimoto's present with hypo-, not hyperthyroidism.

B Graves' disease

Graves' disease is associated with TSH receptor antibodies, not anti-microsomal antibodies.

D Post-natal depression

Post-partum psychosis can be excluded because of the abnormal thyroid function tests, suggesting that the psychological disturbance is related to thyrotoxicosis.

E Atrophic thyroiditis

Atrophic thyroiditis is rare, occurs in women aged 40-60 years and is associated with hypothyroidism.

18664

Rate this question:

A 45-year-old woman presents to her GP complaining of a progressively hoarse voice for about 6 weeks. She denies any recent upper respiratory tract infections and is a non-smoker. She has no other symptoms and is normally very fit and well. She is not on any medications. The positive findings on examination include a palpable, firm, non-tender nodule in the thyroid area that moves with swallowing. The nodule measures about 1 cm across and has a hard consistency and ill-defined borders. No lymphadenopathy is felt. The GP suspects this to be a thyroid lump and arranges further investigations for the patient.

Which of the following best describes a thyroid nodule which is suspected to be malignant?

A	Chest radiography, CT scanning and/or MRI are commonly used in the initial work-up of a thyroid nodule
B	Follicular thyroid carcinoma is the most common cancer of the thyroid gland
C	Follicular thyroid carcinoma is part of the multiple endocrine neoplasia syndrome
D	The prognosis is best for follicular cancers
E	Papillary cancers carry a good prognosis

Submit

E	Papillary cancers carry a good prognosis

Papillary carcinoma is the most common form of well-differentiated thyroid cancer, and the most common form of thyroid cancer to result from exposure to radiation. Papillary carcinoma appears as an irregular, solid or cystic mass or nodule in a normal thyroid parenchyma.

The life expectancy of patients with this cancer is related to their age. The prognosis is better for younger patients than for patients who are older than 45 years.

Fine-needle aspiration biopsy is considered the best first-line diagnostic procedure for a thyroid nodule. Surgery is the definitive management of papillary thyroid cancer. Approximately 4–6 weeks after surgical thyroid removal, patients may have radioiodine therapy to detect and destroy any metastasis and residual tissue in the thyroid.

A	Chest radiography, CT scanning and/or MRI are commonly used in the initial work-up of a thyroid nodule

CXR, CT and MRI are not usually used in the initial work-up of a patient with a thyroid nodule, except in clear cases of metastatic disease. The first imaging study that is performed in any patient with a thyroid nodule is ultrasonography, which further characterises the nodules' U grading and determines the need for biopsy.

B	Follicular thyroid carcinoma is the most common cancer of the thyroid gland

Papillary carcinoma is the most common thyroid carcinoma and, in general, the prognosis for this carcinoma is excellent.

C	Follicular thyroid carcinoma is part of the multiple

A 45-year-old Pakistani lady is referred to the Endocrine Clinic with bone pain. She has progressively become weaker, and she now finds it difficult to get up.
On examination, she has 3/5 power in shoulder abduction and adduction but 5/5 power in all other muscle groups in the arms. In the legs, she has 3/5 power in hip flexion and extension but normal power in the rest of the legs. Her plantar reflexes are flexor.

Investigations:

Hb	13.0 g/dl
WCC	8.0×10^9/l
PLT	150×10^9/l
Na^+	135 mmol/l
K^+	4.3 mmol/l
Urea	5.9 mmol/l
Creatinine	96 micromol/l
ALT	45 mmol/l
Cl^-	109 mmol/l
Bilirubin	17 µmol/l
ALP	590 U/l
Albumin	36 g/l
PO_4^{3-}	0.6 mmol/l
HCO_3^-	19.0 mmol/l
Corrected Ca^{++}	2.02 mmol/l

What is the most likely underlying cause of her clinical picture?

A Type 1 renal tubular acidosis

WCC	8.0×10^9/l
PLT	150×10^9/l
Na^+	135 mmol/l
K^+	4.3 mmol/l
Urea	5.9 mmol/l
Creatinine	96 micromol/l
ALT	45 mmol/l
Cl^-	109 mmol/l
Bilirubin	17 µmol/l
ALP	590 U/l
Albumin	36 g/l
PO_4^{3-}	0.6 mmol/l
HCO_3^-	19.0 mmol/l
Corrected Ca^{++}	2.02 mmol/l

What is the most likely underlying cause of her clinical picture?

A Type 1 renal tubular acidosis

B Hypoparathyroidism

C Osteomalacia

D Hypothyroidism

E Polymyalgia rheumatica (PMR)

12:39

MyPastest
https://mypastest.pastest.com

Pastest+

ALP	590 U/l
Albumin	36 g/l
PO_4^{3-}	0.6 mmol/l
HCO_3^-	19.0 mmol/l
Corrected Ca^{++}	2.02 mmol/l

What is the most likely underlying cause of her clinical picture?

Your answer was correct

A Type 1 renal tubular acidosis

B Hypoparathyroidism

C Osteomalacia

D Hypothyroidism

E Polymyalgia rheumatica (PMR)

Explanation

C Osteomalacia

The clinical picture is one of bone pain and proximal myopathy. The blood tests show a mild hypocalcaemia and hypophosphataemia associated with a high alkaline phosphatase, which is typical of osteomalacia. There is also an acidosis, which is caused by the inhibition of phosphate,

C Osteomalacia

The clinical picture is one of bone pain and proximal myopathy. The blood tests show a mild hypocalcaemia and hypophosphataemia associated with a high alkaline phosphatase, which is typical of osteomalacia. There is also an acidosis, which is caused by the inhibition of phosphate, bicarbonate and sodium reabsorption by parathyroid hormone (PTH). Osteomalacia is more common in ethnic groups who are dark-skinned, or in those cover themselves up so that cholesterol cannot be converted to vitamin D in the skin. Asians who eat chapattis are also at risk, as the phytic acid in the chapattis chelates vitamin D and calcium. X-rays may show Looser's zones, which are areas of decalcification.

A Type 1 renal tubular acidosis

Type 1 renal tubular acidosis is associated with hypokalaemia, which is not seen here.

B Hypoparathyroidism

Hypoparathyroidism is associated with elevated levels of phosphate, which doesn't fit the biochemical picture seen here.

D Hypothyroidism

Although hypothyroidism is associated with proximal myopathy, it is not associated with the low serum calcium and elevated alkaline phosphatase seen here.

E Polymyalgia rheumatica (PMR)

PMR is associated with proximal muscle pain and weakness, but not with the abnormalities in calcium metabolism seen here.

A 43-year-old man is referred to the clinic because of attending Emergency after a road traffic accident. He admits that he did not see the car approaching from the right which hit him, and had been bumping into things at home. On examination in the Emergency department he was noted to have bilateral peripheral visual field loss. Past history of note includes lethargy and difficulties at work, for which his GP has referred him to a counsellor, and erectile dysfunction for which he has been trialling sildenafil. On review in the clinic his BP is 110/70 mmHg, with pulse 70/min regular. There are no abnormal findings on general examination, but neurological examination confirms peripheral visual field loss.

Investigations:

Hb	12.9 g/dl
WCC	7.8 x10^9/l
PLT	192 x10^9/l
Na^+	134 mmol/l
K^+	5.5 mmol/l
Creatinine	121 µmol/l
TSH	0.4 U/l (<0.5-4.5)
Free T_4	7.8 pmol/l (10-22)
Testosterone	7 nmol/l (9-35)
Prolactin	1510 mU/l (<360)
IGF-1	5.0 nmol/l (5.6-23.3)
MRI pituitary	Macroadenoma with pressure on the optic chiasm

Which of the following is the most appropriate management?

Hb	12.9 g/dl
WCC	7.8 x10^9/l
PLT	192 x10^9/l
Na^+	134 mmol/l
K^+	5.5 mmol/l
Creatinine	121 µmol/l
TSH	0.4 U/l (<0.5-4.5)
Free T_4	7.8 pmol/l (10-22)
Testosterone	7 nmol/l (9-35)
Prolactin	1510 mU/l (<360)
IGF-1	5.0 nmol/l (5.6-23.3)
MRI pituitary	Macroadenoma with pressure on the optic chiasm

Which of the following is the most appropriate management?

A Radiotherapy

B Hypophysectomy

C Somatostatin

D Cabergoline

E Adenomectomy

Rana Alnasser's screen

12:47

E Adenomectomy

This man has a pituitary macroadenoma with significant optic chiasm compression. On reviewing his investigations his sodium is low, he has mildly elevated potassium, his TSH and T4 are low, testosterone is low and IGF-1 is below the lower end of the normal range. Probably due to pressure effects, the prolactin is elevated. Putting these results together, the most likely diagnosis is a non-functioning macroadenoma. A minority of patients respond to either dopamine agonists or somatostatin analogues, so in this situation surgery is the treatment of choice.

A Radiotherapy

Radiotherapy is used in cases of pituitary adenomas where medical or surgical therapy has failed.

B Hypophysectomy

It is usually performed in cases of cancer or tumours that resist other forms of treatment, especially craniopharyngiomas.

C Somatostatin

Somatostatin analogues are used for the management of acromegaly (growth hormone-secreting pituitary adenomas).

D Cabergoline

Cabergoline is a dopamine agonist used for the treatment of prolactin-secreting pituitary adenomas

23367

Rate this question:

Rana Alnasser's screen

A 32-year-old woman is referred to the Pregnancy Diabetes Clinic by your colleagues in Obstetrics, having failed a trial of 2 weeks' diet and exercise. Her first child was large at birth, and in retrospect it is thought that she may previously have had gestational diabetes. She is now 20 weeks' pregnant. She has no prior medical history of note.

Investigations:

Fasting plasma glucose	6.9 mmol/l
Oral glucose tolerance test at 2 h	11.4 mmol/l

What is the most appropriate next step in this case?

A Oral glibenclamide

B Diet and exercise advice only

C Oral metformin

D Basal bolus insulin therapy

E Oral acarbose

Submit

A 32-year-old woman is referred to the Pregnancy Diabetes Clinic by your colleagues in Obstetrics, having failed a trial of 2 weeks' diet and exercise. Her first child was large at birth, and in retrospect it is thought that she may previously have had gestational diabetes. She is now 20 weeks' pregnant. She has no prior medical history of note.

Investigations:

Fasting plasma glucose	6.9 mmol/l
Oral glucose tolerance test at 2 h	11.4 mmol/l

What is the most appropriate next step in this case?

Your answer was correct

A Oral glibenclamide

B Diet and exercise advice only

C Oral metformin

D Basal bolus insulin therapy

E Oral acarbose

Explanation

C Oral metformin

This woman has gestational diabetes, as evidenced by a raised fasting and 2 h blood glucose. Abnormal glucose tolerance occurs as a *de novo* event in around 2–3% of pregnant women; unfortunately their long-term risk of

Explanation

C Oral metformin

This woman has gestational diabetes, as evidenced by a raised fasting and 2 h blood glucose. Abnormal glucose tolerance occurs as a *de novo* event in around 2–3% of pregnant women; unfortunately their long-term risk of subsequent type 2 diabetes is as high as 40–50%. The aim of treatment is to keep blood glucose readings to around 7 mmol/l or below, and to allow mothers to give birth normally (although a number should deliver at 38 weeks' gestation due to excess fetal growth). Women should be offered a further glucose tolerance test at the 6-week check, to rule out the possibility of continued abnormal glucose tolerance or type 2 diabetes.

Studies have demonstrated that where metformin is instigated as initial therapy, maternal and fetal outcomes are no worse than where patients are prescribed insulin first line, and women gain less weight in pregnancy with greater overall treatment satisfaction scores.

A Oral glibenclamide

Although one trial has shown that glibenclamide is effective in controlling blood glucose in pregnancy, it is associated with weight gain and risk of hypoglycaemia, meaning that metformin is preferred.

B Diet and exercise advice only

Diet and exercise advice only runs the risk of uncontrolled hyperglycaemia and subsequent adverse fetal outcomes. This is particularly a problem as further weight gain in pregnancy will only exacerbate insulin resistance and worsen glycaemic control.

D Basal bolus insulin therapy

offered a further glucose tolerance test at the 6-week check, to rule out the possibility of continued abnormal glucose tolerance or type 2 diabetes.

Studies have demonstrated that where metformin is instigated as initial therapy, maternal and fetal outcomes are no worse than where patients are prescribed insulin first line, and women gain less weight in pregnancy with greater overall treatment satisfaction scores.

A Oral glibenclamide

Although one trial has shown that glibenclamide is effective in controlling blood glucose in pregnancy, it is associated with weight gain and risk of hypoglycaemia, meaning that metformin is preferred.

B Diet and exercise advice only

Diet and exercise advice only runs the risk of uncontrolled hyperglycaemia and subsequent adverse fetal outcomes. This is particularly a problem as further weight gain in pregnancy will only exacerbate insulin resistance and worsen glycaemic control.

D Basal bolus insulin therapy

Basal bolus insulin therapy is the next intervention when blood glucose levels escape target despite maximal tolerated oral metformin.

E Oral acarbose

Although oral acarbose does reduce GI carbohydrate absorption, no large trial of effectiveness in pregnancy has been carried out.

Rate this question:

12:49
On
594-042-7551
Leave

An 18-year-old woman with type 1 diabetes who has recently broken up with her boyfriend is brought to the Emergency room by ambulance. Her parents say that she has become increasingly drowsy and confused over the past 12 h. She is usually managed with a basal bolus insulin regime but examination of the hospital records reveals two previous admissions with DKA, and her most recent HbA1c was 80.33 mmol/mol (9.5%). On examination she is drowsy, confused and aggressive; her GCS is 14. Her BP is 95/65 mmHg, pulse 105/min and regular. She is apyrexial. Her respiratory rate is 31/min. There is vague abdominal pain on examination of the abdomen.

Investigations:

Hb	12.1 g/dl
WCC	6.7 x10^9/l
PLT	201 x10^9/l
Na^+	143 mmol/l
K^+	5.9 mmol/l
Creatinine	180 µmol/l
Glucose	34.1 mmol/l
Bicarbonate	13.0 mmol/l
pH	7.2
Urine (catheter)	Ketones +++, blood +, protein -

You begin an insulin infusion and appropriate IV fluid replacement. Which other therapy would you also instigate?

A IV sodium bicarbonate

B IV phosphate

Audio Video Share Participants More

mmHg, pulse 105/min and regular. She is apyrexial. Her respiratory rate is 31/min. There is vague abdominal pain on examination of the abdomen.

Investigations:

Hb	12.1 g/dl
WCC	6.7 x10^9/l
PLT	201 x10^9/l
Na^+	143 mmol/l
K^+	5.9 mmol/l
Creatinine	180 µmol/l
Glucose	34.1 mmol/l
Bicarbonate	13.0 mmol/l
pH	7.2
Urine (catheter)	Ketones +++, blood +, protein -

You begin an insulin infusion and appropriate IV fluid replacement. Which other therapy would you also instigate?

A IV sodium bicarbonate

B IV phosphate

C S/c low-molecular weight heparin

D IV antibiotics

E IV mannitol

WCC	6.7 x10⁹/l
PLT	201 x10⁹/l
Na^+	143 mmol/l
K^+	5.9 mmol/l
Creatinine	180 µmol/l
Glucose	34.1 mmol/l
Bicarbonate	13.0 mmol/l
pH	7.2
Urine (catheter)	Ketones +++, blood +, protein -

You begin an insulin infusion and appropriate IV fluid replacement. Which other therapy would you also instigate?

Your answer was correct

A IV sodium bicarbonate

B IV phosphate

C S/c low-molecular weight heparin

D IV antibiotics

E IV mannitol

Explanation

C S/c low-molecular weight heparin

C S/c low-molecular weight heparin

Patients with diabetic ketoacidosis (DKA) are at increased risk of venous thromboembolism because of volume depletion, hyperglycaemia and their decreased conscious level. As such, standard prophylaxis against deep vein thrombosis is an important component of management.

A IV sodium bicarbonate

Sodium bicarbonate is also not used routinely and is only recommended in severe acidosis or circulatory collapse as an adjunct to insulin and fluid resuscitation.

B IV phosphate

Although extracellular phosphate may be depleted once insulin therapy is instigated, phosphate replacement isn't considered a routine component of the management of DKA.

D IV antibiotics

The normal white count isn't consistent with signs of acute infection.

E IV mannitol

IV mannitol has a role to play in the management of acute cerebral oedema, but in this case is only likely to exacerbate volume depletion.

21170

Rate this question:

Next Question

A 32-year-old woman presents with headaches, sweating, anxiety and palpitations. She states that members of her family on her father's side have had similar symptoms and have required surgery. She is also complaining of polydipsia and constipation.

On examination, her blood pressure is elevated at 165/92. She had two 24 h urinary collections for catecholamines, which were above the upper limit of normal. Her bone profile revealed:

Corr. Ca^{2+}	2.71 mmol/l (2.2-2.6 mmol/l)
Phosphate	1.1 mmol/l (0.8-1.5 mmol/l)
PTH	19 pmol/l (1.5-7.6 pmol/l)

Her physician would like to send her for genetic testing. Which condition would he like to test her for?

A Von Hippel-Landau disease

B MEN 2A

C MEN 2B

D MEN 1

E Familial hypocalciuric hypercalcaemia

Submit

B MEN 2A

C MEN 2B

D MEN 1

E Familial hypocalciuric hypercalcaemia

Explanation

B MEN 2A

Type 2 Multiple Endocrine Neoplasia (MEN 2) is a rare familial cancer syndrome caused by mutations in the *RET* proto-oncogene. It is inherited in an autosomal dominant fashion. MEN 2A patients present with phaeochromocytoma, parathyroid hyperplasia and medullary thyroid carcinoma.

A Von Hippel-Landau disease

Clinical hallmarks of this disease include the development of retinal and central nervous system haemangioblastomas, which are absent in this case. Moreover, hyperparathyroid hyperplasia is not part of the condition.

C MEN 2B

This condition is characterised by the presence of mucosal neuromas and marfanoid habitus, along with phaechromocytoma and medullary thyroid carcinoma.

D MEN 1

A Von Hippel-Landau disease

Clinical hallmarks of this disease include the development of retinal and central nervous system haemangioblastomas, which are absent in this case. Moreover, hyperparathyroid hyperplasia is not part of the condition.

C MEN 2B

This condition is characterised by the presence of mucosal neuromas and marfanoid habitus, along with phaechromocytoma and medullary thyroid carcinoma.

D MEN 1

The main components of MEN 1 are hyperparathyroidism and pituitary and pancreatic tumours. From the pituitary tumours, 25-90% are usually prolactinomas although growth hormone or ACTH secretion has also been described. The pancreatic tumours can be non-functioning, originating from the beta-cells (insulinoma) or originating from non-beta-cells and secreting other peptides such as glucagon, pancreatic polypeptide, somatostatin, chromogranin or gastrin.

E Familial hypocalciuric hypercalcaemia

This is a genetic condition caused in the majority of cases due to loss of function mutations in the calcium-sensing receptor (CaSR) gene, expressed in parathyroid and kidney tissue. The perceived lack of calcium levels by the parathyroid leads to constitutively high levels of parathyroid hormone and therefore hypercalcaemia. Urine calcium/creatinine ratio has to be less than 0.01 in order to consider this condition as a cause for primary hyperparathyroidism.

Medullary carcinoma of the thyroid

chromogranin or gastrin.

E	Familial hypocalciuric hypercalcaemia

This is a genetic condition caused in the majority of cases due to loss of function mutations in the calcium-sensing receptor (CaSR) gene, expressed in parathyroid and kidney tissue. The perceived lack of calcium levels by the parathyroid leads to constitutively high levels of parathyroid hormone and therefore hypercalcaemia. Urine calcium/creatinine ratio has to be less than 0.01 in order to consider this condition as a cause for primary hyperparathyroidism.

Medullary carcinoma of the thyroid

• Multiple endocrine neoplasia (MEN) type 2A: medullary carcinoma of the thyroid, phaeochromocytoma, hyperparathyroidism (inherited in autosomal dominant fashion)
• MEN type 2B: the above features which are found in MEN 2A and mucosal neuromas (most likely to be sporadic, although where inherited follows an autosomal dominant pattern).

They are inherited in an autosomal dominant fashion. Phaechromocytomas are also associated with other conditions: von Hippel-Lindau disease, neurofibromatosis, and tuberous sclerosis.

32882

Rate this question:

A 62-year-old man presents to the clinic with increasing anxiety, palpitations and heat intolerance. He has lost 3 kg in weight over the past month. He is taking long-term maintenance amiodarone therapy at a dose of 200 mg daily, along with warfarin because of a low ejection fraction due to previous myocardial infarction, and two previous episodes of paroxysmal ventricular tachycardia. He has refused an ICD in the past. On examination his BP is 123/82 mmHg, with pulse 95/min. His BMI is 21. There are bilateral crackles at both lung bases consistent with mild cardiac failure.

Investigations:

Hb	12.4 g/dl
WCC	6.1 $\times 10^9$/l
PLT	199 $\times 10^9$/l
Na^+	139 mmol/l
K^+	4.5 mmol/l
Creatinine	132 µmol/l
TSH	<0.05 U/l
Thyroid uptake scan	normal
Thyroid autoantibodies	+ve

Which of the following is the most appropriate treatment for this patient?

A Carbimazole

B Subtotal thyroidectomy

C Lugol's iodine

D Radioactive iodine

12:56

MyPastest
https://mypastest.pastest.com

Pastest+

being driven by the high levels of iodine contained in amiodarone. Optimal management of AIT type 1 involves the use of high-dose thionamides and discontinuation of the amiodarone if possible. Given that this man is taking amiodarone for VT, the possibility of an ICD should be re-discussed. Without discontinuation of amiodarone, persistently high levels of iodine reduce the effectiveness of therapy.

B Subtotal thyroidectomy

Any thyroid surgery is likely to carry significant risks in this patient because of poor cardiac function, and should therefore be avoided.

C Lugol's iodine

Lugol's iodine is a short-term measure designed to treat hyperthyroidism, allowing for a window of intervention for surgery.

D Radioactive iodine

Radioactive iodine is usually ineffective in managing AIT type 1 due to the excess iodine afforded by long-term amiodarone treatment.

E Propranolol

This would impact on symptoms but may exacerbate cardiac failure. It wouldn't treat the underlying thyrotoxicosis.

Rate this question:

A 62-year-old man presents to the clinic with increasing anxiety, palpitations and heat intolerance. He has lost 3 kg in weight over the past month. He is taking long-term maintenance amiodarone therapy at a dose of 200 mg daily, along with warfarin because of a low ejection fraction due to previous myocardial infarction, and two previous episodes of paroxysmal ventricular tachycardia. He has refused an ICD in the past. On examination his BP is 123/82 mmHg, with pulse 95/min. His BMI is 21. There are bilateral crackles at both lung bases consistent with mild cardiac failure.

Investigations:

Hb	12.4 g/dl
WCC	6.1 x10^9/l
PLT	199 x10^9/l
Na^+	139 mmol/l
K^+	4.5 mmol/l
Creatinine	132 µmol/l
TSH	<0.05 U/l
Thyroid uptake scan	normal
Thyroid autoantibodies	+ve

Which of the following is the most appropriate treatment for this patient?

Your answer was correct

A Carbimazole

B Subtotal thyroidectomy

C Lugol's iodine

11:00
On
594-042-7551
Leave

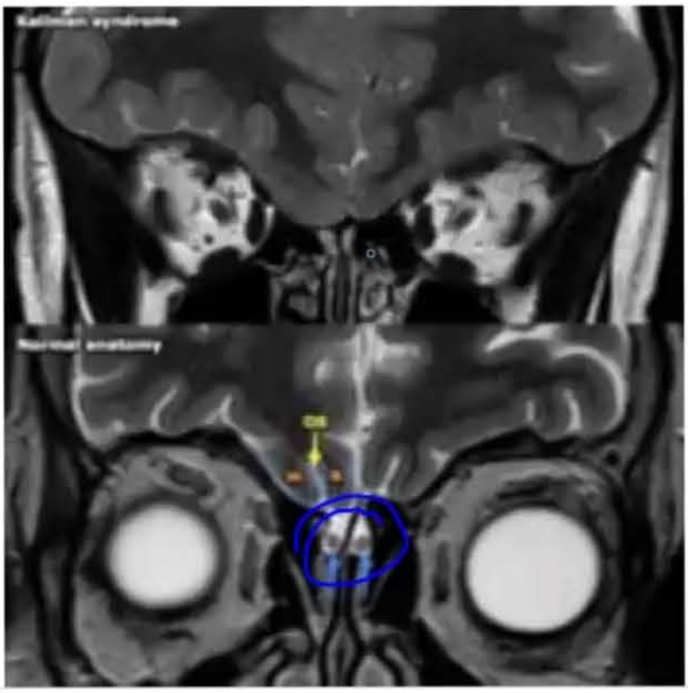

K

N

opaedia

nn syndrome | Radiology Reference Article | Radiopaedia.org

Kallman versus normal anatomyFigure 1: Kallman versus normal anatomy

y be subject to copyright. Learn more

IMAGES

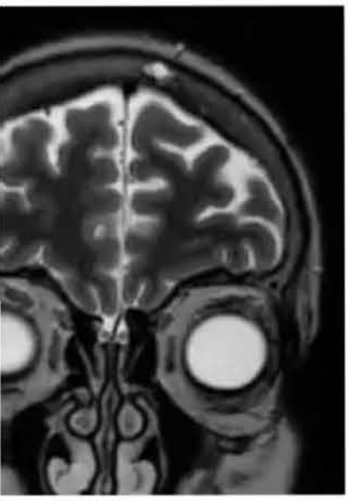

rves | Radiology Case | Radiopae...

rg

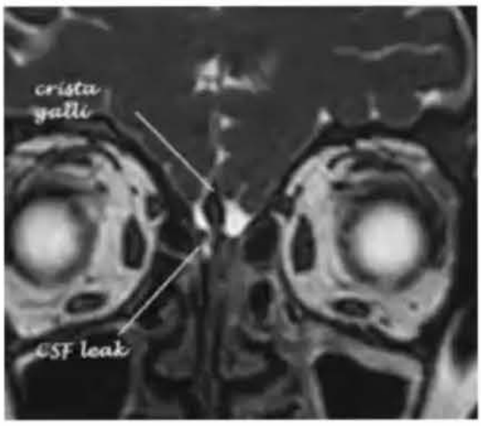

M S Gopalakrishnan: Spontaneous CSF rhino...

msgopalakrishnan.blogspot.com

Coronal T2 image of the case with

researchgate.net

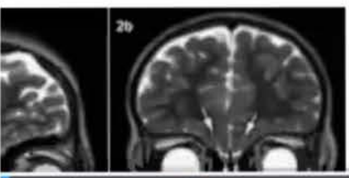

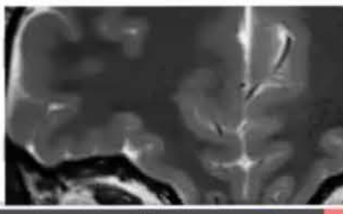

Spotlight
Pen
Highlighter
Line
Rectangle
Oval
Undo
Redo
Clear
Color
Updates
Search
Recent
Audio
Video
Share
Participants
More

Calculator

Normal Values

A 67-year-old man with a history of chronic cough with haemoptysis comes to the Emergency Room with severe vomiting and dehydration. His relatives tell you that he has suffered from the cough for over three months and has progressively lost weight. He smokes 40–50 cigarettes per day. On examination, he looks unwell and has a BMI of 18, with a BP of 95/70 mmHg and a pulse of 75/min. There are coarse crackles on auscultation of both lung fields.

Investigations:

Hb	11.9 g/dl
WCC	8.9×10^9/l
PLT	198×10^9/l
Na^+	124 mmol/l
K^+	5.3 mmol/l
Creatinine	145 µmol/l
CXR	Right hilar mass

What is the diagnosis?

A	Autoimmune adrenal failure
B	Paraneoplastic syndrome
C	Adrenal metastases
D	Severe gastroenteritis
E	Acute tubular necrosis

Rana Alnasser's screen

STC 2:23 PM 91%
On 594-042-7551 Leave
00:11

44% 11:23
MyPastest
https://mypastest.pastest.com

C Adrenal metastases

This patient has an underlying bronchial carcinoma, and whilst adrenocorticotrophic hormone (ACTH)-producing tumours are seen which lead to a Cushing-type picture, hypoadrenalism is usually related to the presence of metastases. Severe gastroenteritis with vomiting leads to hypokalaemia; in this case, given that the potassium is at the upper end of the normal range, another cause such as Addison's is more likely.

This patient has likely got a lung malignancy, as evidenced by the abnormality seen on his CXR and the history. He is hypotensive and hyponatraemic, which is suggestive of adrenal insufficiency. The most common cause in this case would be adrenal metastases, and therefore adrenal metastases is the correct answer. A staging CT will help confirm the diagnosis.

A Autoimmune adrenal failure

This diagnosis is possible but incorrect, as in the context of possible lung cancer, metastases is more likely.

B Paraneoplastic syndrome

Small cell lung cancer has an association with inappropriate secretions of anti-diuretuc hormone (ADH), but it would not explain his symptoms of vomiting and hypotension. It also does not normally present so acutely.

D Severe gastroenteritis

There are no infective symptoms to suggest that gastroenteritis is the underlying diagnosis in this case. You

Annotation Stop Share
Mute Start Video Share Content Participants More

STC 2:23 PM 91%
On 594-042-7551 Leave
00:32

Calculator

Normal Values

A 36-year-old woman who is 20 weeks' pregnant with her 2nd child is referred to you by the midwife service for glycosuria. Her first child was over 9 lb in weight and she herself is quite overweight, having had a BMI of 29 prior to becoming pregnant. On examination her BP is 139/78 mmHg. She has already followed a diabetes diet for the past 2 weeks.

Investigations:

Hb	12.1 g/dl
WCC	5.6 x10^9/l
PLT	192 x10^9/l
Na^+	139 mmol/l
K^+	4.5 mmol/l
Creatinine	100 µmol/l
Fasting glucose	6.9 mmol/l
OGTT 2hr glucose level	13.2 mmol/l

Which of the following is the most appropriate initial management?

A	Metformin
B	Diet
C	Pioglitazone
D	Gliclazide
E	Insulin

Annotation Stop Share
Unmute Start Video Share Content Participants More

A Metformin

Given that her 2 h glucose is significantly elevated at 13.2 mmol/l, she requires treatment for her diabetes. Dietary therapy alone is not sufficient to control glucose levels, although patients are recommended to eat more frequent, smaller meals to aid glucose control. Metformin has been proven in a large scale clinical trial and is recommended as initial therapy, to which insulin is then usually added. Basal bolus is the standard insulin regime, as the goal of therapy is to mimic physiological glucose control as closely as possible. Metformin has also been recommended by NICE guidelines on the treatment of gestational diabetes.

B Diet

Diet alone is inadequate to control this patient's glucose, and risks significant fetal exposure to hyperglycaemia.

C Pioglitazone

Pioglitazone is an insulin sensitiser, and it is not recommended for the treatment of diabetes in pregnancy. It's use in the treatment of type 2 diabetes is relatively limited because of weight gain and loss of bone mineral density.

D Gliclazide

Sulphonylureas are not recommended in pregnancy because they lead to weight gain and are suboptimal in achieving blood glucose control versus insulin. A small trial did indicate that glibenclamide is a safe option for reducing blood glucose in pregnancy.

Annotation Stop Share

E Insulin

44% 11:25

A 37-year-old man undergoes examination as part of a 'well man' screening at his general practitioner's surgery. The lesion over his heel, shown below, was noted on examination.

Calculator

Normal Values

What would be your next investigation?

A	Fasting lipids
B	Fasting glucose
C	Biopsy of lesion
D	Serum uric acid
E	Rheumatoid factor

Submit

Previous Q... Skip Questi...

Annotation Stop Share

Rana Alnasser's screen

Explanation

A Fasting lipids

The image shows xanthomata affecting the Achilles tendons. Xanthomata are lesions characterised by accumulations of lipid-laden macrophages, and can be a reflection of lipid metabolism alteration or a result of local cell dysfunction. Tendon xanthomata are diagnostic hallmarks of heterozygous familial hypercholesterolaemia (FH) (incidence 1 in 500). Other causes of tendon xanthomata are very rare (phytosterolaemia and cerebrotendinous xanthomata), and the presence of raised cholesterol and tendon xanthomata is therefore effectively pathognomonic of FH. The most common sites for tendon xanthomata are in the tendons overlying the Achilles tendons and the knuckles; less common sites include the extensor hallucis longus tendon and the triceps tendon, and they may also occur on the tibial tuberosity at the site of insertion of the patellar tendon (called subperiosteal xanthomata). Ultrasound can be used to look for subclinical Achilles lesions. In heterozygous FH, cholesterol is >7.5 mmol/l and coronary heart disease begins in the third decade; men are at greater risk than women and, if untreated, 50–75% will have a myocardial infarction by the age of 60 years. Homozygous FH presents with coronary disease in the teens and cholesterol levels in excess of 16 mmol/l.

B Fasting glucose

Necrobiosis lipoidica diabeticorum is a rash that occurs on the lower legs. It is more common in women, and there are usually several spots. There are also slightly raised shiny, red-brown patches. The centres are often yellowish and may develop open ulcers that are slow to heal.

C Biopsy of lesion

A patient comes to your clinic complaining for 2 months of abdominal pain. He has lost significant weight. He complains of feeling dizzy on standing. He has had a normal upper gastrointestinal (GI) endoscopy, colonoscopy and barium follow-through. His blood pressure from lying to standing dropped by 30 mmHg - from 120 mmHg systolic to 90 mmHg. He has abnormal mucosal pigmentation, which is shown below.

Calculator

Normal Values

By FlatOut [CC0], via Wikimedia Commons

Which one of the following blood test results might you most expect to see?

A	Glucose 3 mmol/l (3.5-5.5)
B	Calcium 2.1 mmol/l (2.12-2.65)
C	Lymphocytes 15% (20-45%)
D	Neutrophils 90% (40-75%)
E	Sodium 148 mmol/l (135-145)

Submit

Rana Alnasser's screen

A Glucose 3 mmol/l (3.5-5.5)

Addison's disease, the most likely diagnosis here, can present with hyperkalaemia, hyponatraemia, uraemia, hypoglycaemia, mild acidosis, hypercalcaemia, neutropenia, lymphocytosis, eosinophilia, anaemia and abnormal liver function tests. It also presents with darkening of the skin in a number of areas, including palmar creases and the buccal mucosa, as seen in this case. In the United Kingdom, non-iatrogenic Addison's disease is most commonly due to autoimmune destruction of the adrenal glands. Adrenal autoantibodies are present in about 75% of cases. The next most common cause is tuberculosis. Other causes include haemorrhage (including during pregnancy), sepsis (including Waterhouse–Friderichsen syndrome from meningococcaemia), shock, coagulopathy and metastases. Other causes are metastases in over 90% in both glands, human immunodeficiency virus (HIV) and opportunistic infections associated with acquired immune deficiency syndrome (AIDS).

B Calcium 2.1 mmol/l (2.12-2.65)

The most likely diagnosis here is Addison's disease, which can be accompanied by hypercalcaemia. The mechanism is uncertain but is thought to be a combination of increased calcium input into the extracellular space and reduced calcium removal by the kidney. Reduction in calcium removal is probably due to decreased glomerular filtration and increased tubular calcium reabsorption. Both renal factors are secondary to volume depletion. The enhanced calcium mobilization is thought to be of skeletal origin.

C Lymphocytes 15% (20-45%)

In Addison's disease, relative lymphocytosis and eosinophilia may be present, which respond to glucocorticoid replacement therapy.

45% 11:33

A 29-year-old woman with type 1 diabetes comes to the Dermatology Clinic for review. She is otherwise well, apart from lesions on each tibia and some loss of sensation in her feet.

The lesions are shown below.

By Warfieldian [CC BY-SA 3.0 (https://creativecommons.org/licenses/by-sa/3.0)], from Wikimedia Commons

Annotation Stop Share

Biopsy reveals granuloma formation, with infiltration of

Rana Alnasser's screen

By Warfieldian [CC BY-SA 3.0 (https://creativecommons.org/licenses/by-sa/3.0)], from Wikimedia Commons

Biopsy reveals granuloma formation, with infiltration of lymphocytes, plasma cells and eosinophils.

Which of the following is the most appropriate treatment?

A	Aspirin
B	Oral prednisolone
C	Oral ciclosporin
D	Topical corticosteroids
E	Hydroxychloroquine

36525

Submit

Previous Q... Skip Questi...

Rana Alnasser's screen

E Hydroxychloroquine

Explanation

D Topical corticosteroids

The appearance in the picture of these ulcerated lesions with their yellow-brown appearance, along with the history of diabetes, points towards the diagnosis of necrobiosis lipoidica diabeticorum. These erythematous plaques are due to small vessel damage causing partial necrosis of the dermal collagen and connective tissue, with a resulting histiocytic cellular response.

While topical corticosteroids can worsen atrophy, they may be of value in reducing inflammation in early lesions. As such, in this situation, they are the intervention of choice, and systemic steroids are best avoided, if possible, due to their impact on glycaemic control. Small trials support the use of both ciclosporin and hydroxychloroquine as second-line agents.

A Aspirin

Antiplatelet agents, such as aspirin, have only limited efficacy in treating necrobiosis lipoidica. A 2016 Cochrane systematic review concluded that further research is necessary before this treatment option can be confirmed to be safe and effective. Most venous ulcers respond to patient education, elevation of foot, elastic compression and evaluation.

B Oral prednisolone

Topical steroids are indicated for the management of necrobiosis lipoidica diabeticorum. Oral steroids can significantly impact on glycaemic control.

STC 2:35 PM 95%
On 594-042-7551 Leave
11:59

Calculator

Normal Values

A 27-year-old man with a history of type 1 diabetes comes to the clinic for review. He is managed with a basal bolus insulin regime comprising glargine and Novorapid™. He has had type 1 diabetes since the age of 5 and has trouble with peripheral neuropathy. On examination his BP is 115/70 mmHg with a postural drop of 10 mmHg, and his BMI is 29. There is glove-and-stocking peripheral neuropathy.

Investigations:

Hb	12.9 g/dl
WCC	7.1 x10^9/l
PLT	184 x10^9/l
Na^+	138 mmol/l
K^+	4.9 mmol/l
Creatinine	80 µmol/l
HbA1c	56 mmol/mol
Urinary ACR	7.5 mg/mmol (<3.5)

Which of the following is the next most appropriate management step with respect to reducing risk of progression of microvascular complications?

A	Amlodipine 5mg
B	Insulin pump therapy
C	Metformin 500mg BD
D	Ramipril 2.5 mg
E	Reassurance

Mute Start Video Share Content Participants More

D Ramipril 2.5 mg

Evidence suggests that even with normal blood pressure, patients with type 1 diabetes derive benefit with respect to progression of renal disease after micro-albuminuria has become established from angiotensin-converting enzyme (ACE) inhibition. As such, even though his BP is in the normal range it is appropriate to trial this patient on ramipril.

A Amlodipine 5mg

Although attaining BP target is important with respect to reducing the risk of microvascular complications, in this case with a systolic BP of 115 mmHg, ACE inhibition is the more appropriate intervention.

B Insulin pump therapy

Although HbA1c is slightly above target, a dose adjustment for normal eating (DAFNE) course is more appropriate initially versus moving to an insulin pump.

C Metformin 500mg BD

Metformin may help with weight control in patients with type 1 diabetes and have a small impact in reducing HbA1c, although studies are not powered to detect any impact on outcomes.

E Reassurance

Given that there is evidence to support use of ACE inhibitors in this situation, reassurance alone is not appropriate.

Rate this question:

46% 11:36

A 38-year-old man presents to the clinic with a left Colles' fracture after a relatively minor fall at work. He lives alone and admits that he has difficulty maintaining sexual interest in women. He holds down a normal job although he has recently had time off work with depression. On examination he has sparse secondary sexual hair and small testes. His BP is 138/88 mmHg.

Calculator

Normal Values

Investigations:

Hb	12.6 g/dl
WCC	7.1 x10^9/l
PLT	197 x10^9/l
Na^+	139 mmol/l
K^+	4.7 mmol/l
Creatinine	124 µmol/l
Ca^{++}	2.2 mmol/l
T-score	-3.1

Which of the following is the most appropriate way to manage him?

A	Weekly alendronate
B	Teriparatide
C	Calcium and Vitamin D
D	Raloxifene
E	Testosterone

Annotation Stop Share

Rana Alnasser's screen

Explanation

E	Testosterone

From the history we are given, the suspicion is that this patient has underlying hypogonadism, most probably due to Klinefelter syndrome. Small testes, sparse sexual hair, problems with depression and sexual function are all in keeping with the diagnosis. Testosterone is known to improve bone mineralization and is the treatment of choice here; it is also likely to impact on his sexual function and may consequently improve his depressive symptoms. Unfortunately, due to late diagnosis of Klinefelter, a significant number of patients begin testosterone replacement therapy far too late.

A	Weekly alendronate

This would be considered a standard intervention for post-menopausal osteoporosis, but hormone replacement is more important here.

B	Teriparatide

This synthetic PTH analogue is primarily used in the treatment of severe osteoporosis, with a T-score of below either -3.5 or – 4.0 contingent upon age, and is a daily injectable. Replacement with testosterone, usually via an intermittent implant, is more appropriate.

C	Calcium and Vitamin D

Calcium and vitamin D status isn't the primary driver of fracture risk in this patient; hormone replacement is the crucial first intervention.

D	Raloxifene

A 34-year-old gentleman presents with diplopia. He has diplopia, maximal on looking left and looking down. Examining his eyes, he has mild bilateral proptosis and the eyes look normal, looking straight ahead. There is decreased movement in the left eye looking down and to the left. However, all other eye movements appear normal. His pupils are equal and have normal direct and consensual light reflexes. He is able to look up freely, without double vision for a long period of time.

Calculator

Normal Values

Investigations:

FT_4	18 pmol/l
TSH	3.2 mU/l<

What is the diagnosis?

A Left abducens nerve palsy

B Left oculomotor nerve palsy

C Myasthenia gravis

D Graves eye disease

E Left trochlear nerve palsy

Submit

Previous Q...

Skip Questi...

D Graves eye disease

The differential diagnosis for an eye movement abnormality, which cannot be explained by a single or multiple cranial nerve palsy, is either myasthenia gravis or Graves' disease. Myasthenia is unlikely, as the patient can look up freely for long periods of time. Graves' eye disease can occur with normal thyroid function. The diagnosis can be made by looking for thyroid-stimulating receptor antibody in the serum.

A Left abducens nerve palsy

Sixth nerve palsy, or abducens nerve palsy, is a disorder associated with dysfunction of cranial nerve VI (the abducens nerve), which is responsible for causing contraction of the lateral rectus muscle to abduct the eye. The inability of an eye to turn outward results in a convergent strabismus or esotropia, of which the primary symptom is diplopia (commonly known as double vision) in which the two images appear side by side. The condition is commonly unilateral but can also occur bilaterally. The unilateral abducens nerve palsy is the most common of the isolated ocular motor nerve palsies.

B Left oculomotor nerve palsy

A complete oculomotor nerve palsy will result in a characteristic down-and-out position in the affected eye. The eye will be displaced outward and displaced downward – outward because the lateral rectus (innervated by the sixth cranial nerve) maintains muscle tone in comparison to the paralysed medial rectus. The eye will be displaced downward, because the superior oblique (innervated by the fourth cranial or trochlear nerve) is non-antagonised by the paralysed superior rectus, inferior rectus and inferior oblique. The affected individual will also have a ptosis, or drooping of the eyelid, and mydriasis

Calculator

Normal Values

A 47-year-old woman is brought to A&E after collapsing at home. She remembers walking to the dining room when she felt faint, had chest tightness and collapsed. When she woke up she called an ambulance. Over the last 2 years she had seen her GP for chest tightness, palpitations and dyspnoea, which lasted for minutes at a time. In the last few months she had developed non-specific pins and needles in her extremities and 'spots before her eyes'. She smokes 20 cigarettes a day and drinks alcohol socially. Her GP started her on a tricyclic antidepressant 2 weeks ago for depression. Her mother died of a stroke at age 48. On examination she is alert, but notably restless, afebrile and has moist palms.. Her pulse is 80 bpm and regular and her BP 180/70 mmHg. She has a 2/6 pansystolic murmur loudest at the apex. Chest (including CXR) and abdominal examinations are normal, as is the neurological examination, but the ECG shows sinus rhythm.

Urine testing reveals glucose++ and blood+.

Haematology investigations:

Hb	18.9 g/dl
WCC	6.0×10^9/l
PLT	471×10^9/l
Na^+	134 mmol/l
K^+	3.1 mmol/l
Creatinine	75 µmol/l
Urea	4.2 mmol/l
Glucose	9.5 mmol/l
Ca^{++}	2.56 mmol/l
CRP	6 mg/l

What is the most likely diagnosis?

49% 11:45
MyPastest
https://mypastest.pastest.com

loudest at the apex. Chest (including CXR) and abdominal examinations are normal, as is the neurological examination, but the ECG shows sinus rhythm.

Urine testing reveals glucose++ and blood+.

Haematology investigations:

Hb	18.9 g/dl
WCC	6.0×10^9/l
PLT	471×10^9/l
Na^+	134 mmol/l
K^+	3.1 mmol/l
Creatinine	75 µmol/l
Urea	4.2 mmol/l
Glucose	9.5 mmol/l
Ca^{++}	2.56 mmol/l
CRP	6 mg/l

What is the most likely diagnosis?

A	Cardiac arrhythmia
B	Transient ischaemic attack
C	Systemic mastocytosis
D	Phaeochromocytoma
E	Coronary vasospasm

Annotate Stop Share
Rana Alnasser's screen

Explanation

D Phaeochromocytoma

Phaeochromocytoma is a rare, catecholamine-producing tumour within the adrenal gland. (The 'rule of tens', i.e. 10% familial, 10% are bilateral, 10% are extra-adrenal, 10% are malignant, is no longer tenable, as approximately 30% of phaeochromocytomas are familial; the tumour location and malignancy risk are variable). There is an association with multiple endocrine neoplasia type 2 in familial cases, and also with the von Hippel–Lindau syndrome. Von Hippel–Lindau syndrome predisposes patients to renal cell carcinoma, phaeochromocytoma and retinal and cerebellar haemangioblastomas. As a result, patients may have a raised haemoglobin due to a secondary increase in erythropoietin production. This patient does have a raised haemoglobin and therefore needs to be screened for von Hippel–Lindau syndrome.

Patients present with a variety of symptoms including episodic hypertension, chest tightness, abdominal pain, vomiting, sweating, restlessness, anxiety, pallor and weakness. Symptoms are precipitated by sneezing, stress, surgery and by agents such as cheese, alcohol and tricyclic antidepressants. Glycosuria occurs during attacks in 30% of cases.

Tests that help in diagnosis include 24 h catecholamine measurement, meta-iodobenzylguanidine (MIBG) and CT/MRI of the adrenal glands.

C Systemic mastocytosis

Mastocytosis is a condition characterised by excessive mast cell accumulation in one or multiple tissues, and is further divided into two categories: cutaneous

Hippel–Lindau syndrome.

Patients present with a variety of symptoms including episodic hypertension, chest tightness, abdominal pain, vomiting, sweating, restlessness, anxiety, pallor and weakness. Symptoms are precipitated by sneezing, stress, surgery and by agents such as cheese, alcohol and tricyclic antidepressants. Glycosuria occurs during attacks in 30% of cases.

Tests that help in diagnosis include 24 h catecholamine measurement, meta-iodobenzylguanidine (MIBG) and CT/MRI of the adrenal glands.

C Systemic mastocytosis

Mastocytosis is a condition characterised by excessive mast cell accumulation in one or multiple tissues, and is further divided into two categories: cutaneous mastocytosis (limited to the skin) and systemic mastocytosis, which involves extra-cutaneous organs like the bone marrow and gastrointestinal tract. The most common symptoms are pruritus on exposure to heat or physical irritation and the presence of urticarial pigmentosa, which are yellowish to reddish-brown papules seen on the extremities, chest and abdomen.

A Cardiac arrhythmia

Cardiac arrhythmias mimic several medical disorders as they can present with symptoms of palpitations (due to arrhythmia per se) or may be due to the haemodynamic consequences (dizziness, syncope, chest pain, light-headedness, weakness, breathlessness, anxiety). In this case, the presence of other features suggestive of phaechromocytomas makes this answer unlikely.

B Transient ischaemic attack

Transient ischemic attack (TIA) is defined as a transient

50% 11:50

Google

urticaria pigmentosa

ALL IMAGES NEWS VIDEOS SHOPPING MAPS BOOKS FLIGHTS TABLET

Latest GIF HD Product

mastocytosis | darier sign | infant | feline | pediatric | nodula

Urticaria Pigmentosa: Symptoms ...
healthline.com

Urticaria Pigmentosa: Symptoms ...
healthline.com

Urticaria pigmentosa
aboutkidshealth.ca

Urticaria pigmentosa - Wikipedia
en.wikipedia.org

Urticaria Pigmentosa: Symptoms ...
healthline.com

Discover Updates Search Recent More

Wikipedia

Urticaria pigmentosa - Wikipedia

Discover Updates Search Recent More

STC 2:51 PM 94%

On 594-042-7551 Leave

28:21

50% 11:51

Pastes+ Question 42 of 136 LOG OUT

Calculator

Normal Values

A keen junior doctor studying for his MRCP examination shows the medical registrar an electrocardiogram (ECG) recorded on a 36-year-old woman in the Medical Clinic in the morning.

Examination of the patient reveals a normal body habitus with a body mass index (BMI) of 23 kg/m², but she is hypertensive with a blood pressure of 165/95 mmHg. She takes no medications and apparently complains of lethargy and muscle aches most of the time. The patient had been referred urgently by the general practitioner for investigation for a metabolic abnormality.

The ECG is shown below.

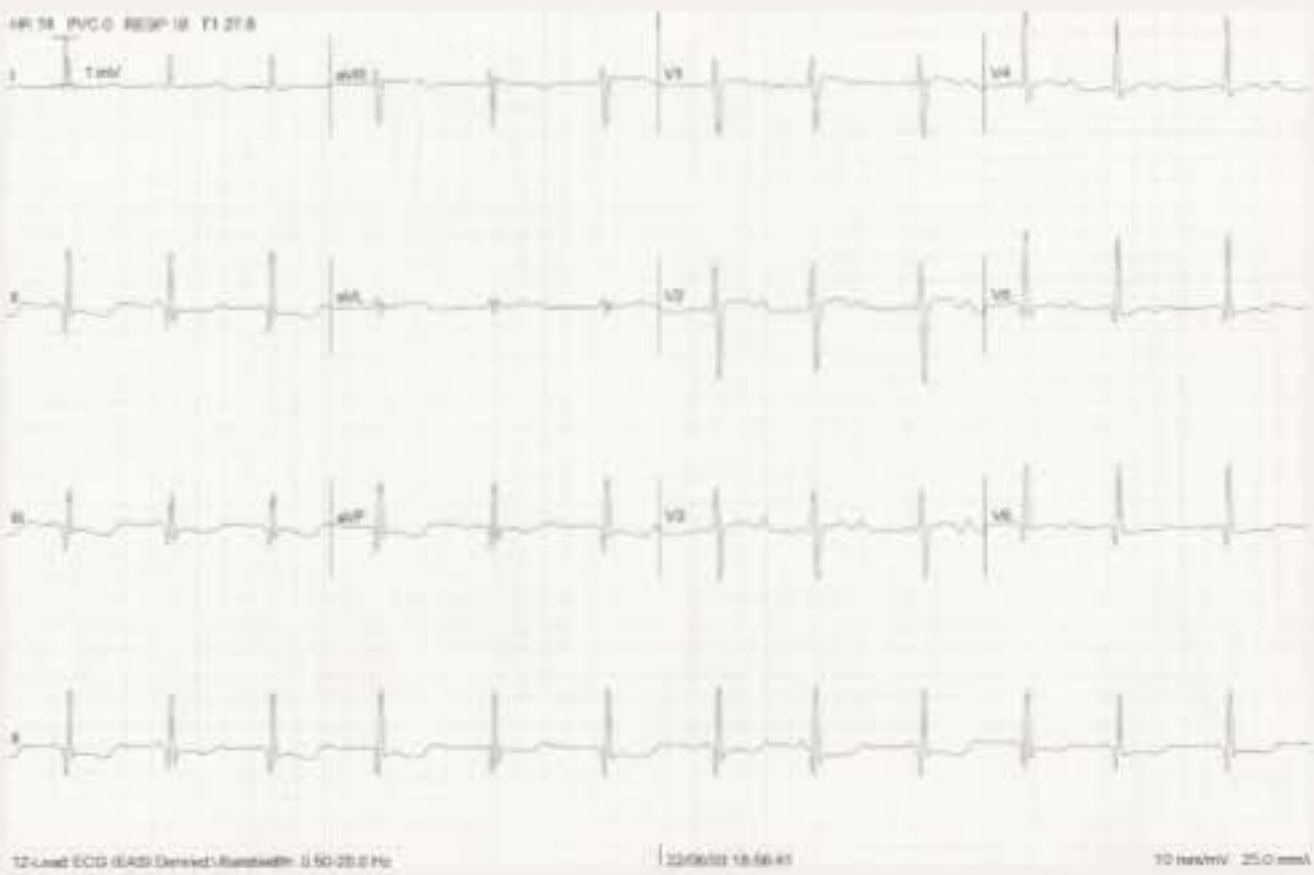

Image taken from Life In The Fast Lane

Based on the ECG, what is the most likely underlying metabolic abnormality?

A	Hyperkalaemia
B	Hypokalaemia

Annotation Stop Share

Unmute Start Video Share Content Participants More

MyPastest
https://mypastest.pastest.com

for a metabolic abnormality.

own below.

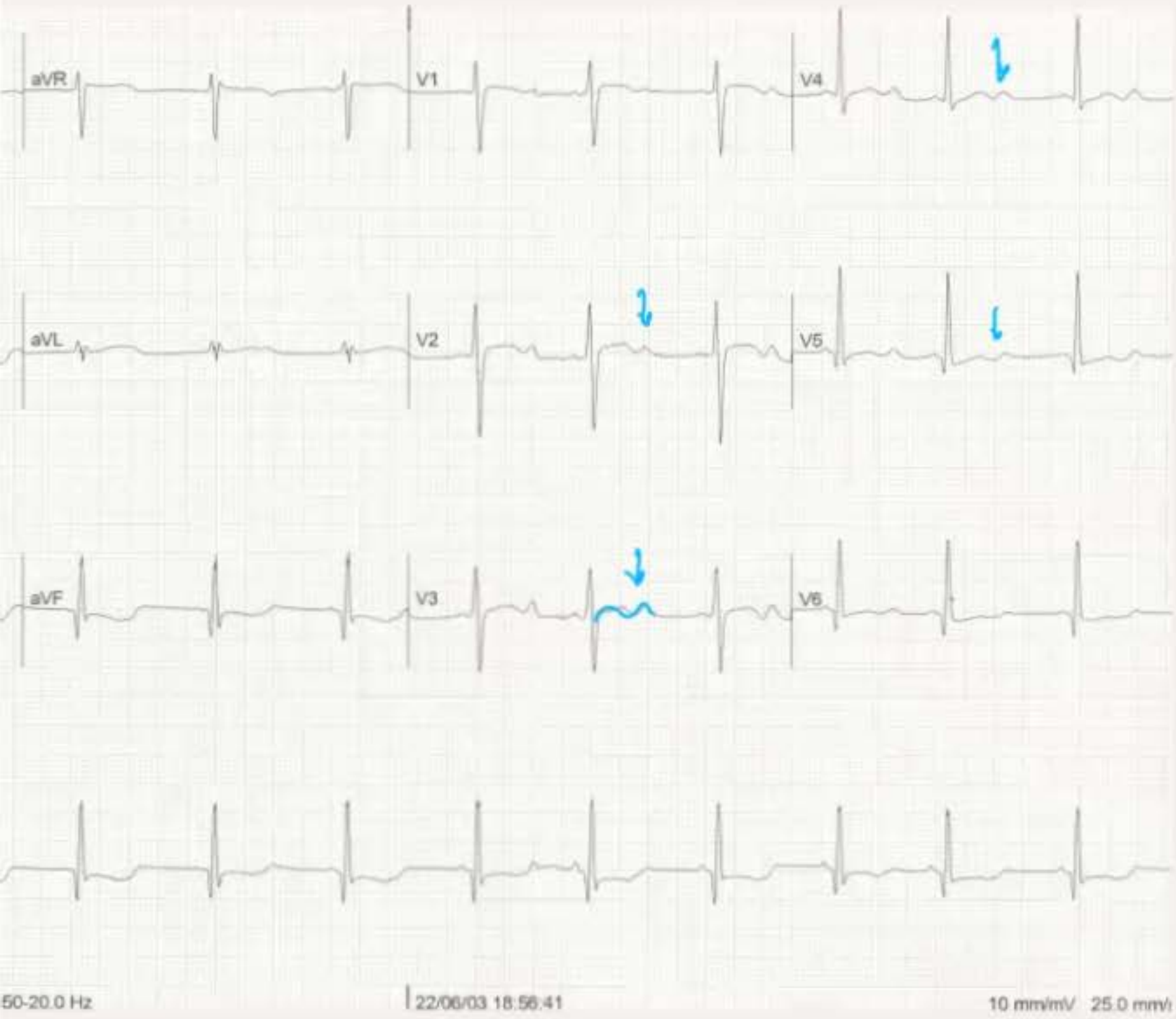

rom Life In The Fast Lane

ECG, what is the most likely underlying

nor

Stop Annotation | Spotlight | Pen | Highlighter | Line | Rectangle | Oval | Undo | Redo | Clear | Color | Stop Share

51% 11:54
MyPastest
https://mypastest.pastest.com

referred urgently by the general practitioner for investigation for a metabolic abnormality.

The ECG is shown below.

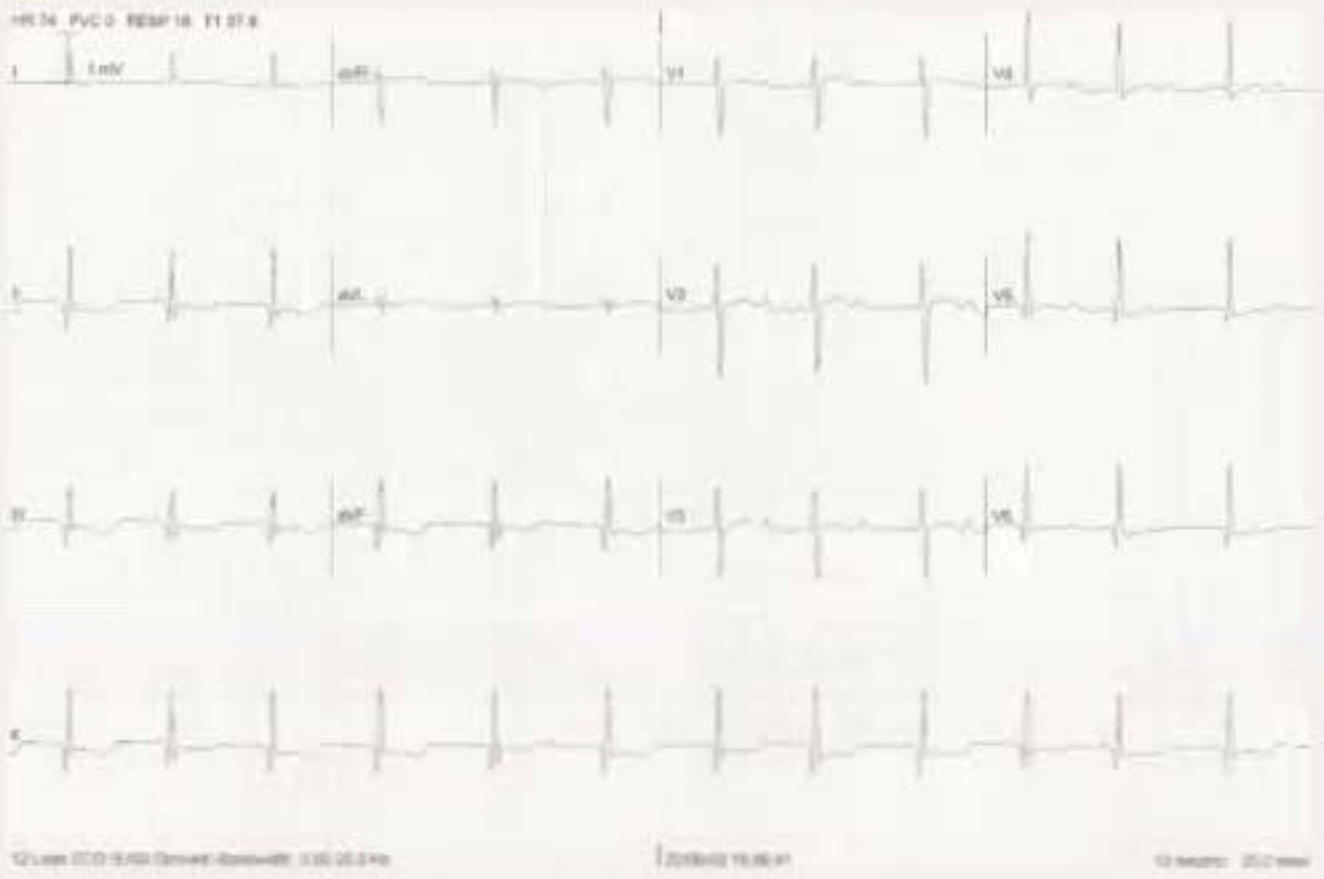

Image taken from Life In The Fast Lane

Based on the ECG, what is the most likely underlying metabolic abnormality?

A	Hyperkalaemia
B	Hypokalaemia
C	Hypercalcaemia
D	Hypocalcaemia
E	Hypomagnesaemia

Explanation

B Hypokalaemia

This ECG demonstrates the classical picture of a prominent U wave - a small deflection immediately following the T wave, usually seen in V2 and V3. A U wave on the ECG is thought to correspond with after-depolarisation events in the ventricles. A normal U wave is of the same polarity as the T wave, but one-third of the amplitude. The differential diagnosis of prominent upright U waves includes hypokalaemia, left ventricular hypertrophy, some cases of mitral valve prolapse, hyperthyroidism, and quinidine and other type 1A antiarrhythmics. Conn syndrome is characterised by increased aldosterone secretion (primary hyperaldosteronism) from the adrenal gland from a unilateral aldosterone-producing adenoma. Metabolically, this manifests as suppression of plasma renin activity, hypertension and hypokalaemia. Bartter syndrome is a cause of congenital salt wasting, which presents in childhood with failure to thrive, polyuria and polydipsia.

A Hyperkalaemia

Hyperkalaemia is associated with peaked T waves and later, as the potassium level rises further, with bizarre broadened QRS complexes.

C Hypercalcaemia

The main abnormality associated with hypercalcaemia is shortening of the QT interval. When the calcium level is very high, J waves may also be seen.

D Hypocalcaemia

Hypocalcaemia leads to QT prolongation, although arrhythmias are surprisingly rarely reported in association

Rana Alnasser's screen

A 64-year-old type 2 diabetes patient presents for review. She has poor blood glucose control and is taking maximal doses of metformin and gliclazide. You elect to substitute insulin glargine for her gliclazide.

Calculator

Normal Values

Which of the following options best describes the amino acid modifications seen in glargine insulin?

A	Glycine is at position A21, two arginines are added to the B chain
B	Aspartic acid is at position B28
C	Glycine is at position B28
D	Aspartic acid is at position A21
E	Proline is at position A21

Submit

Previous Q... Skip Questi...

© Pastest 2019

Rana Alnasser's screen

A Glycine is at position A21, two arginines are added to the B chain

The clue is in the name – 'glargine' is an amalgam of glycine and arginine. Insulin glargine is a long-acting insulin analogue. It has recently been joined by another insulin analogue, insulin detemir.. The main use for insulin analogues is in improving glycaemic control in type 1 diabetes. Some patients may be limited in haemoglobin A_{1c} (Hb_{A1c}) reductions due to post-meal hypoglycaemia or nocturnal hypoglycaemia, and the use of short- and/or long-acting insulin analogues may improve glycaemic control with reduced incidence of hypoglycaemia compared to conventional insulins. Additional studies of glargine insulin in type 2 diabetes have demonstrated a reduction in nocturnal hypoglycaemia.

C Glycine is at position B28

Insulin aspart is a short-acting insulin analogue which has an aspartic acid residue at position B28.

B Aspartic acid is at position B28

Insulin aspart is a short-acting insulin analogue which has an aspartic acid residue at position B28. It is used as prandial insulin. In our scenario, since the patient was on maximum doses of gliclazide and metformin, the next step would be to add in basal insulin such as glargine. If this doesn't work, there is the option to advance to a basal bolus regimen where basal insulin is administered once daily, and a type of fast-acting insulin as aspart is used to cover post-prandial hyperglycaemia.

D Aspartic acid is at position A21

Insulin aspart is a short-acting insulin analogue which has

52% 12:00

A 24-year-old woman comes to the Endocrine Clinic as she has become increasingly concerned about her weight, which has increased considerably over the past six months. She claims that her diet has remained unchanged and her physical fitness is good. She is taking topical erythromycin for her acne. A pregnancy test was negative, although she does admit to a somewhat erratic menstrual cycle. She has also noticed increased coarse, dark, hair growth on her upper lip. In the clinic, her random blood sugar measurement by finger-prick was 8.0 mmol/l.

Which investigation is most likely to point to the underlying diagnosis?

A	Urinary cortisol levels
B	TSH level
C	Oral glucose tolerance test
D	MRI brain
E	USS pelvis

Annotation Stop Share
Rana Alnasser's screen

Explanation

E	USS pelvis

The history is consistent with Cushing syndrome or polycystic ovary syndrome (PCOS). If not caused by pregnancy, weight gain is most likely in young people to be caused by increased fat. The causes are: increased caloric consumption disproportionate to energy expenditure; sedentary lifestyle, contributing significantly by TV watching and video gaming; endocrine disorders such as Cushing syndrome; PCOS; hypothyroidism; hypothalamic dysfunction; medications; environmental factors such as poor sleep; gut microbiota; and viruses.

Women with PCOS often present with hirsutism and menstrual irregularities. PCOS is also associated with insulin resistance. As per the Rotterdam 2003 criteria for PCOS, two out of the following three should be applicable for a diagnosis of PCOS.

- Oligo- and/or anovulation
- Clinical and/or biochemical signs of hyperandrogenism
- Polycystic ovaries (by ultrasound).

The ultrasound criterion for defining polycystic ovarian morphology is the presence of 12 or more follicles in each ovary measuring 2–9 mm in diameter and/or increased ovarian volume (>10 ml; calculated using the formula 0.5 × length × width × thickness). One ovary fitting this definition is sufficient to define PCOS.

A	Urinary cortisol levels

The typical physical signs of Cushing syndrome, such as facial plethora, round face, abdominal striae, dorsal fat pad and easy bruising (ecchymoses), have not been described in this case. Screening tests would be one of the following:

STC 3:01 PM 90%
On 594-042-7551 Leave
38:36

Calculator

Normal Values

A 70-year-old woman presents to the Accident and Emergency Department with thirst, polyuria and constipation. Her family also feel that she has been depressed over the last few weeks, which is unusual for her. Examination is unremarkable apart from generalised abdominal tenderness and a scar noted on the left breast from a previous lumpectomy for breast carcinoma.

Investigations:

Urea	10.0 mmol/l
Creatinine	100 µmol/l
Sodium	133 mmol/l
Potassium	4.0 mmol/l
Corrected calcium	3 .84 mmol/l
Plasma parathyroid hormone (PTH) levels	0.8 pmol/l (0.9–5.4)

Which single initial management choice would be most appropriate from the list below?

A	IV fluids
B	Oral furosemide
C	IV steroids
D	IV pamidronate
E	Denosumab

Mute Start Video Share Content Participants More

A IV fluids

The initial diagnosis here is hypercalcaemia, which can cause severe gastrointestinal disturbance. Serum levels >3.5 mmol/l are associated with cardiac arrhythmias, coma and pancreatitis and urgent treatment is required. The low parathyroid hormone precludes parathyroid disease as a cause, and in this age group (particularly with a previous malignancy) metastatic bone disease would be high on a list of differential diagnoses.
Hypercalcaemia is often associated with severe dehydration that increases the risk of renal damage. The bisphosphonate pamidronate is the treatment of choice to reduce osteoclast activity and hence bone resorption of calcium, but should always be preceded by aggressive rehydration to prevent renal tubular damage. In the case described here, these would therefore be used as a next step following IV fluids.

B Oral furosemide

In cases of hypercalcaemia, furosemide is not routinely recommended in the Society for Endocrinology Guidelines, and it should only be given with fluid resuscitation if there is evidence of ventricular strain and pulmonary oedema.

C IV steroids

Prednisolone is used to treat hypercalcaemia associated with sarcoid.

D IV pamidronate

Pamindronate is a bisphosphonate used in the acute management of hypercalcaemia after the initial phase of fluid resuscitation; therefore, it would be a good second-line treatment option.

is present. Disc protrusion in the thoracic spine, however, is somewhat rare because the thoracic spinal segment is attached directly to the ribcage, keeping the 12 thoracic vertebrae relatively stable and stationary. Lumbar disc protrusion (in the lower back) and cervical disc protrusion (in the neck) are much more common.

The cervical spine is constructed around the vertebrae, or the seven stacked bony building blocks in the spine. They are numbered from top to bottom as C1 to C7. The nerve that is affected by the cervical disc herniation is the one exiting the spine at that level, so at the C5–6 level it is the C6 nerve root that is affected.

33283

Rate this question:

Next Question

Previous Question | Tag Question

Feedback | End Session

Difficulty: Average

Peer Responses %

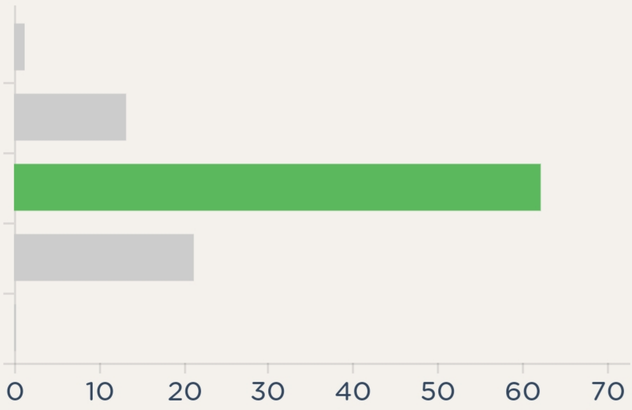

Session Progress

Responses Correct:	6
Responses Incorrect:	2
Responses Total:	8

Na^+	140 mmol/l
K^+	5.0 mmol/l
Creatinine	100 µmol/l
ESR	58 mm/h
MCV	79 fl
ANA	+ at 1:160

MRI of both knees is suggestive of synovitis; echocardiogram is suggestive of pericarditis.

Which of the following is the most likely diagnosis?

A	Systemic lupus erythematosus (SLE)
B	Juvenile idiopathic arthritis
C	Rheumatoid arthritis
D	Sarcoidosis
E	Kawasaki disease

33287

Submit

Investigations:

Hb	121 g/l (> 120 g/l)
WBC	10.5 × 10^9/l (4–11 × 10^9/l)
PLT	450 × 10^9/l (15–400 × 10^9/l)
ESR	67mm/1st hour
CRP	45 mg/l
AST	33 IU/l (6–34 IU/l)
ALK-P	313 IU/l (25–110 IU/l)

You order an autoantibody screen and X-ray of the hands and feet.

What is the most likely diagnosis?

A	Early rheumatoid arthritis (RA)
B	Recurrent symmetrical seronegative arthritis with pitting oedema (RSSPE)
C	Early scleroderma
D	Osteoarthritis
E	Reflex sympathetic dystrophy syndrome (RSDS)

A 25-year-old woman comes to the clinic for review. She has been suffering from small joint polyarthritis and an erythematous rash, which becomes more prominent over sun-exposed areas, for the past few months. She is anti-nuclear antibody positive and has reduced C3 and C4 levels. Her creatinine level is in the normal range.

An image of her facial appearance is shown below.

Which of the following is the most appropriate long-term intervention?

A	Azathioprine

An image of her facial appearance is shown below.

Which of the following is the most appropriate long-term intervention?

A	Azathioprine
B	Hydroxychloroquine
C	Methotrexate
D	Mycophenolate mofetil
E	Prednisolone

A 25-year-old woman comes to the clinic for review. She has been suffering from small joint polyarthritis and an erythematous rash, which becomes more prominent over sun-exposed areas, for the past few months. She is anti-nuclear antibody positive and has reduced C3 and C4 levels. Her creatinine level is in the normal range.

An image of her facial appearance is shown below.

Which of the following is the most appropriate long-term intervention?

Your answer was correct

A Azathioprine

B Hydroxychloroquine

This patient has active SLE, as evidenced by the rash, arthritis, anti-nuclear antibody positivity and low C3 and C4 levels. The most appropriate intervention therefore is hydroxychloroquine, which is a first-line option in SLE where there is no evidence of significant renal involvement.

A Azathioprine

Azathioprine is licensed for the treatment of systemic lupus erythematosus (SLE) but is thought to be less effective in managing patients with joint disease than anti-malarials, such as hydroxychloroquine. It is an alternative in this case if other first-line agents for lupus are unsuitable or not tolerated.

C Methotrexate

Methotrexate is a first-line agent for

C Methotrexate

Methotrexate is a first-line agent for the treatment of rheumatoid arthritis. The clinical features and antibody profile seen here are more consistent with a diagnosis of active lupus.

D Mycophenolate mofetil

Mycophenolate mofetil is a first-line agent for patients with SLE who have active renal vasculitis. The normal creatinine level seen here counts against that.

E Prednisolone

Although prednisolone may be used short-term to manage lupus flares, long-term use is avoided, if possible, because of the risk of steroid-related side-effects such as weight gain, impaired glucose tolerance and osteoporosis.

71643

Rate this question:

A 26-year-old woman known to have lupus since the age of 19 years presents in the clinic with right groin pain. This started 4 months ago and has been progressively getting worse. The pain is present all the time and increases further on weight bearing. She walks with a limp. The range of movements at both hips is painful and restricted, the right much more than the left.

Her medications include prednisolone 5 mg daily, azathioprine 125 mg daily, Adcal-D3® 1 tab twice daily and co-codamol.

Investigations:

Hb	10.2 g/dl
WBC	4.2×10^9/l
PLT	123×10^9/l
Neutrophils	2.8×10^9/l
Lymphocytes	0.9×10^9/l
ESR	4.5 mm/1st hour
CRP	4 mg/l

Neutrophils	2.3 x 10⁹/l
Lymphocytes	0.9 x 10^9/l
ESR	4.5 mm/1st hour
CRP	4 mg/l
AST	33 IU/l
Creatinine	84 mmol/l
Urine dipstick	All normal

You order an urgent X-ray of the hips.

What is the most likely diagnosis?

A	Osteoarthritis of the hips
B	Trochanteric bursitis
C	Avascular necrosis of the hips
D	Rheumatoid arthritis (RA) of the hips
E	Sacroilitis

A 26-year-old woman known to have lupus since the age of 19 years presents in the clinic with right groin pain. This started 4 months ago and has been progressively getting worse. The pain is present all the time and increases further on weight bearing. She walks with a limp. The range of movements at both hips is painful and restricted, the right much more than the left.

Her medications include prednisolone 5 mg daily, azathioprine 125 mg daily, Adcal-D3® 1 tab twice daily and co-codamol.

Investigations:

Hb	10.2 g/dl
WBC	4.2 x 10^9/l
PLT	123 x 10^9/l
Neutrophils	2.8 x 10^9/l
Lymphocytes	0.9 x 10^9/l
ESR	4.5 mm/1st hour
CRP	4 mg/l

C Avascular necrosis of the hips

Deprivation of blood supply to the cortex and medulla results in marrow cell death and causes AVN. The common causes are lupus, high-dose corticosteroid therapy, antiphospholipid antibody syndrome, sickle cell disease, alcoholism, Caisson's disease and Gaucher's disease. In lupus, femoral head involvement is the most common and in 90% of cases progresses to involve the opposite side after 12 months. The pain is often most severe and recalcitrant, with poor response to analgesic and anti-inflammatory medications. CRP and ESR may show mild/moderate elevation in this condition, or may be normal. Indeed no particular blood parameter is useful for diagnosis or assessing prognosis of this condition. Plain X-ray characteristically shows irregular contouring of the femoral head, although it may appear normal in the early phase. MRI is the most sensitive modality of imaging for AVN of the hip,

early phase. MRI is the most sensitive modality of imaging for AVN of the hip, and is the investigation of choice in patients where AVN is suspected but radiography is normal. Conservative treatment involves non-weight bearing to prevent the collapse of the femoral head and secondary osteoarthritis. Depending on the stage of the disease, surgical options include core decompression or replacement of the femoral head.

A	Osteoarthritis of the hips

He is far too young to have osteoarthritis of her hips.

B	Trochanteric bursitis

Trochanteric bursitis is characterised by lateral thigh pain and is worse on lying on the affected side.

D	Rheumatoid arthritis (RA) of the hips

A local general practitioner (GP) asks you to review a 42-year-old woman who has suffered from symptoms of oesophageal reflux disease that have only partially responded to proton-pump inhibitors. She has recently started to complain in particular about cold weather, and may have Raynaud's phenomenon. Routine blood testing has revealed a raised creatinine of 180 μmol/l, and she is hypertensive with a blood pressure of 170/85 mmHg.

Which one of the following agents is the best treatment to ameliorate further renal impairment?

A	Ramipril
B	Amlodipine
C	Bendrofluazide
D	Prednisolone
E	IV methylprednisolone

A local general practitioner (GP) asks you to review a 42-year-old woman who has suffered from symptoms of oesophageal reflux disease that have only partially responded to proton-pump inhibitors. She has recently started to complain in particular about cold weather, and may have Raynaud's phenomenon. Routine blood testing has revealed a raised creatinine of 180 μmol/l, and she is hypertensive with a blood pressure of 170/85 mmHg.

Which one of the following agents is the best treatment to ameliorate further renal impairment?

Your answer was correct

A	Ramipril
B	Amlodipine
C	Bendrofluazide
D	Prednisolone

A Ramipril

ACE inhibitors are seen as the treatment of choice for renal disease associated with systemic sclerosis (the diagnosis here). This lady should be seen in Casualty, as she may have scleroderma renal crisis. In systemic sclerosis, interlobular renal arteries are affected with intimal thickening, and fibrinoid changes occur in afferent glomerular arterioles. The pathogenesis is unknown, and neither steroids nor immunosuppressive therapy appears to have an effect on the progression of renal disease. In contrast, treatment with ACE inhibitors has positive effects on proteinuria and appears to halt or even reverse decline in renal function in some cases. Prostacyclin infusion may be of additional benefit in cases where renal function is rapidly deteriorating.

B Amlodipine

Amlodipine is a calcium channel

Amlodipine is a calcium channel blocker. ACE inhibitors are seen as the treatment of choice for renal disease associated with systemic sclerosis. Calcium channel blockers may be used in the treatment of Raynaud's, where they reduce the frequency and severity of vasospastic attacks. Calcium channel blockers can also be useful in patients who have systemic sclerosis with lung involvement.

C	Bendrofluazide

Bendrofluazide is a thiazide diuretic, and thiazides are moderately potent diuretics. Because of their negative effects on glucose tolerance, they are no longer the recommended first-line treatment for hypertension, but are useful in the treatment of mild to moderate heart failure. Thiazides are ineffective if eGFR is <30 ml/min/1.73 m^2, and have no reno-protective benefits.

D	Prednisolone

You review a 24-year-old man who has recently returned from a holiday in Spain. He complains of fever and malaise with associated myalgia and joint pain affecting his lower back, knees, ankles, and feet. He has burning and itching affecting his eyes and urethral discharge.

On examination, he has balanitis and a psoriatic-type rash affecting his feet. You prescribe a course of antibiotics and non-steroidal anti-inflammatory drugs.

Which of the following is associated with an increased risk of the arthropathy described in this scenario?

A	Female sex
B	Age >50 years
C	Coeliac disease
D	*Candida* infection

recently returned from a holiday in Spain. He complains of fever and malaise with associated myalgia and joint pain affecting his lower back, knees, ankles, and feet. He has burning and itching affecting his eyes and urethral discharge.

On examination, he has balanitis and a psoriatic-type rash affecting his feet. You prescribe a course of antibiotics and non-steroidal anti-inflammatory drugs.

Which of the following is associated with an increased risk of the arthropathy described in this scenario?

Your answer was correct

A	Female sex
B	Age >50 years
C	Coeliac disease
D	*Candida* infection

E HLA-B27-positive status

This man has the typical picture of reactive arthritis, most likely related to non-specific urethritis acquired while on holiday in Spain.

Reactive arthritis should always be considered whenever a young adult presents with acute arthritis affecting the knees, ankles or feet. Reactive arthritis is a systemic inflammatory disorder characterised by an aseptic arthritis triggered by infections arising most commonly from the genitourinary and gastrointestinal site.

Peak onset of reactive arthritis occurs in the 15–35-year-old age group. Reactive arthritis post-chlamydial infection is much more common in men, while the sex ratio of reactive arthritis post-dysentery is roughly equal between men and women. HLA-B27 patients have been described as up to 50 times more likely to develop reactive arthritis than the rest of the population (Aho K. *et al.,* HLA-B27 in reactive arthritis).

In general, symptoms last from a few weeks to around 6 months in total. However, recurrent arthritis is said to occur in 15–50% of reactive arthritis patients, and chronic persistent arthritis or sacro-iliitis occurs in 15–30%. In HLA-B27-positive patients, ankylosing spondylitis may develop in up to 50% of patients who have suffered an episode of reactive arthritis. Rarer long-term complications include urethral stricture, cataracts and aortic root necrosis. Prognosis with respect to long-term complications is better when dysenteric infection is the precipitant factor rather than chlamydial infection.

A	Female sex

Recurrent arthritis is more usually found in men, where it is approximately three times more common.

B	Age >50 years

common.

B	Age >50 years

The peak onset of reactive arthritis occurs in the 15–35-year-old age group.

C	Coeliac disease

Enteric-acquired reactive arthritis can occur up to 4 weeks after an acute episode of diarrhoea. However, there is no clear association with coeliac disease.

D	*Candida* infection

Candida infection is not linked with reactive arthritis, *Chlamydia trachomatis* is often indicated in sexually acquired cases of reactive arthritis.

6418

Rate this question:

A 72-year-old woman is reviewed in the Hand Clinic. She has suffered from arthritis for many years but is now finding it very difficult to manage at home, particularly with respect to cooking food and eating. Her hands have become progressively more disfigured.

She takes thyroxine 100 µg per day and medications for hypertension, but she is otherwise well. Routine bloods are in the normal range.

You note a scar over her neck.

A picture of her left hand is shown below.

Which of the following is the most likely diagnosis?

A picture of her left hand is shown below.

Which of the following is the most likely diagnosis?

A	Hyperparathyroidism
B	Osteoarthritis
C	Pseudohypoparathyroidism
D	Psoriatic arthritis
E	Rheumatoid arthritis

A 72-year-old woman is reviewed in the Hand Clinic. She has suffered from arthritis for many years but is now finding it very difficult to manage at home, particularly with respect to cooking food and eating. Her hands have become progressively more disfigured.

She takes thyroxine 100 μg per day and medications for hypertension, but she is otherwise well. Routine bloods are in the normal range.

You note a scar over her neck.

A picture of her left hand is shown below.

Which of the following is the most likely diagnosis?

D Psoriatic arthritis

This patient has long-standing arthritis with arthritis mutilans. Shortening, particularly of the distal interphalangeal joints, is consistent with psoriatic arthritis. It is likely that this patient's active disease has burnt out some time ago, given that the routine blood tests are in the normal range.

E Rheumatoid arthritis

Rheumatoid arthritis is associated with arthritis mutilans in advanced disease, although nail pitting and the predominantly distal features of this patient's disease count against rheumatoid arthritis vs psoriatic arthritis as the cause here.

A Hyperparathyroidism

Although hyperparathyroidism does result in shortening of the distal

6:38
:tps://mypastest.pastest.com
10

hypertension, hyperlipidaemia, recurrent joint pain and steatohepatitis. He currently takes ramipril, atorvastatin and amlodipine.

A photograph of his right ear is shown below.

What is the most appropriate plan for this patient's management?

A	Excision biopsy of lesion

A 64-year-old man presents to the General Medical Clinic. He is concerned as his wife has pointed out that his ears look different.

He has not noticed anything abnormal in terms of pain or itch. He has otherwise been feeling well, without any pain or systemic problems.

He has a past medical history of hypertension, hyperlipidaemia, recurrent joint pain and steatohepatitis. He currently takes ramipril, atorvastatin and amlodipine.

A photograph of his right ear is shown below.

What is the most appropriate plan for this patient's management?

A	Excision biopsy of lesion
B	Staging computed tomography (CT) scan of head and neck
C	Prednisolone
D	Allopurinol
E	Stop ramipril

A 64-year-old man presents to the General Medical Clinic. He is concerned as his wife has pointed out that his ears look different.

He has not noticed anything abnormal in terms of pain or itch. He has otherwise been feeling well, without any pain or systemic problems.

He has a past medical history of hypertension, hyperlipidaemia, recurrent joint pain and steatohepatitis. He currently takes ramipril, atorvastatin and amlodipine.

A photograph of his right ear is shown below.

D Allopurinol

This patient has gouty tophi on his ears. It is likely given this that he has undiagnosed recurrent gout given his history of recurrent joint pain. Gouty tophi are nodular masses of monosodium urate crystals deposited in soft tissue and are a sign of chronic hyperuricaemia. Starting urate-lowering treatment would be appropriate to prevent further attacks of gout. Measuring serum urate would be appropriate to ensure adequate response. As allopurinol is started, he should also be given treatment for acute gout as allopurinol can, in the first instance, precipitate an acute attack.

A Excision biopsy of lesion

The lesions presents are not consistent with malignancy. Squamous cell carcinoma (SCC) can arise on the ears as they are in a sun-exposed area. These lesions are hyperkeratotic

as they are in a sun-exposed area. These lesions are hyperkeratotic lesions which often develop a central ulcer which can bleed and are often itchy. There is also usually only one lesion.

B	Staging computed tomography (CT) scan of head and neck

Staging scanning is appropriate when a malignant melanoma has been confirmed. Melanomas are usually characterised by flat, irregular, multichromatic lesions with changing appearance. They are also usually pigmented. If these features were present, the initial step would still be to do a biopsy to confirm the nature of the lesion.

C	Prednisolone

Systemic steroid therapy would be an option for acute gout, not for chronic gout.

A 55-year-old woman with rheumatoid arthritis presents for review. She has recently returned from a holiday to Spain and complains of a rash on her face and upper chest.

On examination, she has a florid rash on her face, and on her upper body which follows the line of her swimsuit. Medication includes captopril for hypertension, and sulfasalazine for arthritis. Blood testing reveals positive antinuclear antibodies, positive rheumatoid factor, normal C3/C4 levels and negative anti-dsDNA antibodies.

Which of the following diagnoses fits best with this clinical picture?

A	Mixed connective tissue disease
B	Flare of rheumatoid arthritis
C	Drug-induced lupus
D	Systemic lupus erythematosis

face and upper chest.

On examination, she has a florid rash on her face, and on her upper body which follows the line of her swimsuit. Medication includes captopril for hypertension, and sulfasalazine for arthritis. Blood testing reveals positive antinuclear antibodies, positive rheumatoid factor, normal C3/C4 levels and negative anti-dsDNA antibodies.

Which of the following diagnoses fits best with this clinical picture?

A	Mixed connective tissue disease
B	Flare of rheumatoid arthritis
C	Drug-induced lupus
D	Systemic lupus erythematosis
E	Drug-induced photosensitivity

Spain and complains of a rash on her face and upper chest.

On examination, she has a florid rash on her face, and on her upper body which follows the line of her swimsuit. Medication includes captopril for hypertension, and sulfasalazine for arthritis. Blood testing reveals positive antinuclear antibodies, positive rheumatoid factor, normal C3/C4 levels and negative anti-dsDNA antibodies.

Which of the following diagnoses fits best with this clinical picture?

Your answer was correct

A	Mixed connective tissue disease
B	Flare of rheumatoid arthritis
C	Drug-induced lupus
D	Systemic lupus erythematosis

C Drug-induced lupus

Sulfasalazine is a known drug-culprit of drug-induced lupus; this lady has a photosensitive rash with normal complement and negative anti-dsDNA antibodies. Features of drug-induced lupus include an average age of onset at 50–70 years, and equal male and female sex ratio. Anti-histone antibodies are positive in more patients with drug-induced lupus than systemic lupus erythematosus (SLE), and C3/C4 levels are normal, whereas complement levels may be decreased in SLE and anti-dsDNA levels are usually normal in drug-induced SLE. The commonest drugs associated with drug-induced lupus are hydralazine, procainamide, minocycline and quinidine, although captopril, sulfasalazine and a number of other drugs may be causative agents. Treatment involves removal of the offending agent; low-dose corticosteroids may speed recovery in patients who are slow to improve.

He is concerned as he plays the piano in a local hotel and is not able to manage this at the moment. On further questioning, he admits to 2 h of morning stiffness, and pain affecting the hips, knees and elbows.

On examination, he has nodules over his elbows and pain over the PIP joints of the fingers.

Investigations:

Hb	11.9 g/dl
WCC	5.4×10^9/l
PLT	201×10^9/l
Na^+	140 mmol/l
K^+	4.8 mmol/l
Creatinine	100 μmol/l
Erythrocyte sedimentation	45

B Prednisolone 20 mg PO

This man is likely to have seropositive rheumatoid arthritis (RF positive, as he has nodules) and needs early intensive intervention to reduce joint damage and disability, to allow him to maintain function. Steroids should be started concomittently with DMARDs, such as methotrexate. Steroids have a rapid onset of action and bridge the gap before methotrexate exerts its effects (up to 12 weeks).

A Diclofenac 50 mg tds

Although he may gain some symptomatic relief from diclofenac, it does not have any disease modification and therefore does little to reduce joint damage.

C Splinting of his fingers

Although he does need to rest his fingers while the inflammation is controlled, splinting will not

Although he does need to rest his fingers while the inflammation is controlled, splinting will not significantly reduce pain or inflammation or damage.

D	Surgical tendon release

We are told that this man plays the piano, and as such surgical tendon release would be best avoided if possible due to the period of time involved in recovery.

E	Joint fusion

We are told that this man plays the piano, and as such joint fusion would be best avoided if possible due to the period of time involved in recovery.

20592

Rate this question:

Next Question

A 60-year-old woman presents with a 1-year history of progressive pain and stiffness involving the small joints of her hands and knees. She has xanthelasmas in the periorbital areas and nodules over the hands as shown below. There is tenderness over the DIP and PIP joints, with mild instability at the occasional PIP joints. Her knees are tender and crepitus is palpable bilaterally.

X-rays of the hands show preservation of the DIP joint space with erosions having clear margins.

An image of the right hand is shown below:

Which of the following is the most likely diagnosis?

below.

Which of the following is the most likely diagnosis?

A	Rheumatoid nodules
B	Methotrexate-induced nodules
C	Multicentric reticulohistiocytosis
D	Xanthomata
E	Molluscum contagiosum

1-year history of progressive pain and stiffness involving the small joints of her hands and knees. She has xanthelasmas in the periorbital areas and nodules over the hands as shown below. There is tenderness over the DIP and PIP joints, with mild instability at the occasional PIP joints. Her knees are tender and crepitus is palpable bilaterally.

X-rays of the hands show preservation of the DIP joint space with erosions having clear margins.

An image of the right hand is shown below:

Which of the following is the most likely diagnosis?

C Multicentric reticulohistiocytosis

The characteristic nail fold nodules of multicentric reticulohistiocytosis have the appearance of 'coral beads'. Nodules may be numerous, may grow to as large as 2 cm and may involve mucosal surfaces. The hand radiograph above shows erosive changes in multiple joints. Distal interphalangeal erosions are characteristic and may lead to pseudo-widening of the joint spaces.

Multicentric reticulohistiocytosis is a rare, non-Langherhans cell histiocytosis with skin and joint involvement. Nearly all organs can be involved. Association with cancer occurs in about 25% of cases. Association with autoimmune diseases has also been recorded. Microscopic examination shows a histiocytic nodular infiltrate composed of giant cells with ground-glass appearance and periodic acid-schiff (PAS)-positive cytoplasm.

A Rheumatoid nodules

Rheumatoid arthritis (RA) does not cause erosions at the DIPJs – RA usually affects MCPs and PIPs, not DIPs.

B Methotrexate-induced nodules

There is no history of her being on methotrexate. NB: Methotrexate may cause nodulosis or accelerated nodulosis.

D Xanthomata

Although this lady has xanthelasma on her eyelids, the image does not look like xanthomata, which are small, yellowish-orange to reddish-brown papules.

E Molluscum contagiosum

Molluscum lesions look like small, umbilicated, pearly iridescent papules

A 54-year-old man is admitted via the medical take. He has been seen on a number of occasions over the past few months by his general practitioner (GP) complaining of nasal stuffiness. On this occasion, he presented with worsening cough, and two episodes of haemoptysis.

Laboratory testing reveals a creatinine of 285 μmol/l, markedly raised erythrocyte sedimentation rate (ESR) and positive c-ANCA. Chest X-ray reveals diffuse shadowing.

Given the likely diagnosis, which one of the following options would you give as a component of initial therapy in this patient?

A	IV methylprednisolone
B	Prednisolone
C	Hydrocortisone
D	Methotrexate

medical take. He has been seen on a number of occasions over the past few months by his general practitioner (GP) complaining of nasal stuffiness. On this occasion, he presented with worsening cough, and two episodes of haemoptysis.

Laboratory testing reveals a creatinine of 285 μmol/l, markedly raised erythrocyte sedimentation rate (ESR) and positive c-ANCA. Chest X-ray reveals diffuse shadowing.

Given the likely diagnosis, which one of the following options would you give as a component of initial therapy in this patient?

Your answer was correct

A	IV methylprednisolone
B	Prednisolone
C	Hydrocortisone
D	Methotrexate

A IV methylprednisolone

This patient has strong evidence pointing towards a diagnosis of Wegener's granulomatosis (granulomatosis with polyangitis). This is a systemic vasculitis of mainly medium- and small-calibre vessels, and is associated with of systemic necrotising angiitis, necrotising granulomatous inflammation of the respiratory tract, and necrotising glomerulonephritis. This patient has evidence of lung involvement and established renal damage, and warrants intravenous therapy to establish remission. The gold-standard choice for intravenous induction is pulsed therapy with IV methylprednisolone and cyclophosphamide. Rituximab has been shown to be non-inferior to cyclophosphamide as the induction agent in recent clinical trials. IV steroids are later converted to oral prednisolone and a suitable steroid-sparing agent, such as methotrexate or azathioprine. It should be noted that

sparing agent, such as methotrexate or azathioprine. It should be noted that patients on high-dose prednisolone and cyclophosphamide are at increased risk of pneumocystis pneumonia, and co-trimoxazole prophylaxis should be considered. Good prognosis in Wegener's is very closely linked to early aggressive intervention, with over 90% of patients improving on cyclophosphamide and methylprednisolone in combination; remission however is only achieved in 75%.

B	Prednisolone

This patient has life- and organ-threatening vasculitis and needs steroids fast. The most effective route of administration, with the most rapid onset of action, is intravenous methylprednisolone, not oral prednisolone.

C	Hydrocortisone

This patient has life- and organ-

A 32-year-old man is referred as an emergency by his general practitioner (GP). He presents with a history of haemoptysis over the past few days, with cough, fevers, nausea and vomiting. The GP had diagnosed flu, but the patient re-presented a few days later, and routine bloods revealed Hb 9.2 g/dl and a creatinine of 385 μmol/l.

On examination, he is severely short of breath and has bilateral basal inspiratory crackles on auscultation of the lung fields. Urgent renal biopsy the day after admission reveals a necrotising glomerulonephritis with linear immunoglobulin and complement deposits on the basement membrane. While awaiting a bed on the renal ward, he suffers a large haemoptysis, (20–30 ml of blood).

Given the likeliest diagnosis, which step would be most appropriate in his initial management?

A	Plasmapheresis

necrotising glomerulonephritis with linear immunoglobulin and complement deposits on the basement membrane. While awaiting a bed on the renal ward, he suffers a large haemoptysis, (20–30 ml of blood).

Given the likeliest diagnosis, which step would be most appropriate in his initial management?

A	Plasmapheresis
B	Commence oral prednisolone
C	Commence oral cyclophosphamide
D	Commence IV methylprednisolone and cyclophosphamide
E	Commence IV furosemide therapy

vomiting. The GP had diagnosed flu, but the patient re-presented a few days later, and routine bloods revealed Hb 9.2 g/dl and a creatinine of 385 µmol/l.

On examination, he is severely short of breath and has bilateral basal inspiratory crackles on auscultation of the lung fields. Urgent renal biopsy the day after admission reveals a necrotising glomerulonephritis with linear immunoglobulin and complement deposits on the basement membrane. While awaiting a bed on the renal ward, he suffers a large haemoptysis, (20–30 ml of blood).

Given the likeliest diagnosis, which step would be most appropriate in his initial management?

Your answer was correct

A	Plasmapheresis
B	Commence oral prednisolone

D Commence IV methylprednisolone and cyclophosphamide

This patient has strong evidence of Goodpasture's syndrome. Goodpasture's syndrome is an uncommon condition with an incidence of 0.5/1 000 000 per year. There is a male predominance, and age at presentation follows a bimodal distribution: young men presenting with a pulmonary–renal picture in the 20–30-year age group, and elderly women presenting with a predominantly renal picture. The safest way to secure a diagnosis is by renal biopsy, and the typical picture demonstrated is a necrotising glomerulonephritis, with positive staining for both immunoglobulin and complement. Where there is severe haemoptysis, rapid removal of anti-GBM antibody is indicated, and the best way to do this is by plasmapheresis at a specialist centre. This is usually accompanied by pulsed therapy with IV methylprednisolone and cyclophosphamide. Prognosis is

therapy with IV methylprednisolone and cyclophosphamide. Prognosis is dependent on presenting renal function; a high percentage of patients who have lost more than 50% of their renal function at diagnosis unfortunately progress to long-term renal replacement therapy.

A	Plasmapheresis

This patient has Goodpasture's syndrome with a pulmonary–renal syndrome. The best initial management would be intravenous methylprednisolone and cyclophosphamide and then plasmapheresis, which is usually only available in specialist centres – the question says he is 'awaiting a bed on the renal ward'. Therefore while plasmapheresis is being arranged, the patient should be given IV methylprednisolone and cyclophosphamide.

B	Commence oral prednisolone

This patient has life-threatening pulmonary–renal syndrome and needs rapid induction of remission; oral prednisolone would be too slow to achieve the best possible outcome.

C	Commence oral cyclophosphamide

This patient has life-threatening pulmonary–renal syndrome and needs rapid induction of remission; Treatment is tailored according to severity and extent of disease. The level of immunosuppression should reflect the severity of vasculitis. Cyclophosphamide can be given orally daily or pulsed intravenously at 2–3-week intervals. There has been a move towards using intravenous therapy in recent times.

E	Commence IV furosemide therapy

This patient needs immunosuppression

A 74-year-old woman presents to her general practitioner (GP) complaining of poorly localised but severe pain in her shoulder. The pain started suddenly about 10 days ago and has become increasingly severe, being present at rest and at night and exacerbated by any activity. She has tried taking analgesics to relieve the pain but the pain returns. She denies any other joint pains and has no history of trauma. She does, however, require oral steroids for occasional exacerbations, which she estimates at approximately two to three times a year.

On examination, it is noted that she has a decreased range of movement and that attempts to move the joint cause obvious pain to the patient. Crepitations are also noted. An X-ray is requested and is reported as showing minimal changes, including slight flattening of the humeral head.

What is the diagnosis?

A	Subluxation of the

On examination, it is noted that she has a decreased range of movement and that attempts to move the joint cause obvious pain to the patient. Crepitations are also noted. An X-ray is requested and is reported as showing minimal changes, including slight flattening of the humeral head.

What is the diagnosis?

A	Subluxation of the glenohumeral joint
B	Fracture of the neck of the humerus
C	Avascular necrosis of the head of the humerus
D	Rotator cuff tendonitis
E	Osteoarthritis of the shoulder joint

C Avascular necrosis of the head of the humerus

Avascular necrosis is characterised by sudden-onset, severe pain. Her risk factor is long-term oral steroids. X-ray changes are usually minimal and an MRI is the diagnostic investigation of choice. Avascular necrosis is a pathological process that results from interruption of the blood supply to bone. Ultimately, the main presentation is with pain and limitation of movement, although the pain is poorly localised. Both night and rest pain are present and worsened with activity. Two forms of the condition exist – a traumatic form and an atraumatic form. The traumatic form occurs in nearly all fractures of the anatomic neck as well as in fractures or dislocations of the humeral head. There are multiple risk factors associated with the atraumatic form, including steroid use, alcohol use, haemoglobinopathies (such as sickle cell and thrombophilias) and connective tissue disorders. The mainstay of treatment is the removal

connective tissue disorders. The mainstay of treatment is the removal of the causative agent, if possible, with non-surgical options often being more successful in cases of avascular necrosis of the shoulder because the shoulder is a non-weight-bearing joint.

A	Subluxation of the glenohumeral joint

Shoulder subluxation is usually provoked by trauma or injury; other causes can include previous injury to the joint, and joint laxity. The subluxation may be evident on radiographs, particularly if an AP and lateral view are requested. MRI may be needed to confirm diagnosis. The history of no trauma does not fit with the diagnosis, and neither do the findings on the X-ray.

B	Fracture of the neck of the humerus

Fractures usually occur after trauma or injury, but may be atraumatic if the

Fractures usually occur after trauma or injury, but may be atraumatic if the bone is very osteoporotic. Fractures should be evident on radiographs. In this scenario we would expect the patient to complain of localised tenderness if a fracture was present.

D	Rotator cuff tendonitis

Rotator cuff tendonitis usually presents with a more gradual history and pain is particularly elicited on abduction.

E	Osteoarthritis of the shoulder joint

Acromoclavicular joint osteoarthritis would be visible on shoulder X-ray, and the history is more insidious than in this patient.

6801

Rate this question:

Next Question

A 67-year-old woman presents to the General Medical Clinic. She has been suffering from long-standing problems with her joints. The joints have become progressively stiffer and her hand has slowly changed shape. Both of her hands are affected.

She has not seen any doctors for the last ten years because her husband died due to medical errors. Her daughter has brought her in at this point as she is concerned about difficulty coping with manual dexterity in activities, such as cooking. There is a past medical history of appendicectomy and humeral fracture, but no regular medications.

There is palpable swelling of the joints. Her hand is shown below.

What investigation is most appropriate initial investigation to confirm the diagnosis?

A	C-reactive protein (CRP)
B	Joint aspiration and light microscopy
C	Anti-nuclear antibody (ANA)
D	Rheumatoid factor
E	Anti-cyclic citrullinated peptide (anti-CCP)

suffering from long-standing problems with her joints. The joints have become progressively stiffer and her hand has slowly changed shape. Both of her hands are affected.

She has not seen any doctors for the last ten years because her husband died due to medical errors. Her daughter has brought her in at this point as she is concerned about difficulty coping with manual dexterity in activities, such as cooking. There is a past medical history of appendicectomy and humeral fracture, but no regular medications.

There is palpable swelling of the joints. Her hand is shown below.

D Rheumatoid factor

Rheumatoid factor would be the most appropriate investigation as this patient clinically has symptoms and signs of rheumatoid arthritis (RA) including symmetrical polyarthritis with synovitis and deformity. In patients with synovitis, rheumatoid factor is the first-line investigation. It is positive in 60–70% of those with RA, but about 5% of people have a false-positive rheumatoid factor. If rheumatoid factor is negative, then anti-cyclic citrullinated peptide should be requested.

E Anti-cyclic citrullinated peptide (anti-CCP)

Anti-CCP is a useful investigation with greater sensitivity than rheumatoid factor for rheumatoid arthritis. However, the National Institute for Health and Care Excellence (NICE) advises that anti-CCP should be requested for patients where

requested for patients where rheumatoid arthritis is suspected but rheumatoid factor is negative.

A	C-reactive protein (CRP)

CRP is an acute-phase reactant which can be useful in monitoring levels of inflammation. It is a non-specific test and would not be helpful in diagnosis.

B	Joint aspiration and light microscopy

Aspiration would be a more appropriate investigation in patients with acute monoarthritis with effusion to differentiate between septic arthritis, gout and pseudogout, especially if the patient was unstable.

In this patient, joint aspiration would be unlikely to yield a diagnosis as the long, progressive, deforming and symmetrical disease seen is not consistent with an acute monoarthritis.

C	Anti-nuclear antibody (ANA)

You review a 48-year-old woman who complains of sudden visual loss affecting her left eye. She has no significant previous medical history and takes no regular medications. Her body mass index (BMI) is 27 kg/m^2.

On examination, you see flame haemorrhages and cotton wool spots in one segment of the retina. Blood testing reveals a prolonged APTT and fasting plasma glucose of 7.2 mmol/l.

Which one of the following diagnoses would you consider as the most important cause of her visual loss?

A	Wegener's granulomatosis
B	Anti-phospholipid antibody syndrome
C	Diabetes mellitus
D	Open-angle glaucoma
E	Giant cell arteritis

haemorrhages and cotton wool spots in one segment of the retina. Blood testing reveals a prolonged APTT and fasting plasma glucose of 7.2 mmol/l.

Which one of the following diagnoses would you consider as the most important cause of her visual loss?

Your answer was correct

A	Wegener's granulomatosis
B	Anti-phospholipid antibody syndrome
C	Diabetes mellitus
D	Open-angle glaucoma
E	Giant cell arteritis

Explanation

B Anti-phospholipid antibody

B Anti-phospholipid antibody syndrome

This patient has branch retinal vein occlusion (BRVO), and the prolonged APTT is suggestive of anti-phospholipid antibody syndrome. Other conditions associated with BRVO include diabetes, sarcoidosis, Lyme disease and other causes of thrombophilia. This lady should be anticoagulated once anti-phospholipid syndrome is confirmed.

A Wegener's granulomatosis

Wegener's granulomatosis (granulomatosis with polyangiitis, GPA) is not associated with a branch retinal vein occlusion. Ocular manifestations include scleritis and uveitis.

C Diabetes mellitus

The fasting plasma glucose indicative of diabetes is an incidental finding

The fasting plasma glucose indicative of diabetes is an incidental finding here, and has not significantly contributed to the risk of BRVO versus anti-phospholipid antibody syndrome. The level is only just above the fasting level for diagnosis of diabetes, and without symptoms, it is likely that her sugar has been in the diabetic range for a relatively short time.

D	Open-angle glaucoma

No link between open-angle glaucoma and branch retinal vein occlusion has been demonstrated.

E	Giant cell arteritis

Giant cell arteritis (GCA) is associated with anterior ischaemic optic neuropathy, not a BRVO. Furthermore, she is too young for giant cell arteritis and there are no other supportive features.

33282

Rate this question:

A 62-year-old woman has attended the Emergency Department with several days of bilateral shoulder weakness and pain. She smokes 10 cigarettes per day, and has suffered from a cough in the mornings over the past few months. There are no abnormalities on plain X-rays, but the Emergency Department doctor was concerned about a purplish discoloration around the eyes and prominent nail fold telangiectasia, which the patient had not really noticed before. CK is raised at 2820 U/l.

Which of the following would you do next for this patient?

A	Autoantibody profile
B	Serum erythrocyte sedimentation rate
C	Analgesia and physiotherapy
D	Weekly methotrexate

plain X-rays, but the Emergency Department doctor was concerned about a purplish discoloration around the eyes and prominent nail fold telangiectasia, which the patient had not really noticed before. CK is raised at 2820 U/l.

Which of the following would you do next for this patient?

A	Autoantibody profile
B	Serum erythrocyte sedimentation rate
C	Analgesia and physiotherapy
D	Weekly methotrexate
E	Malignancy screen

8525

Submit

A 62-year-old woman has attended the Emergency Department with several days of bilateral shoulder weakness and pain. She smokes 10 cigarettes per day, and has suffered from a cough in the mornings over the past few months. There are no abnormalities on plain X-rays, but the Emergency Department doctor was concerned about a purplish discoloration around the eyes and prominent nail fold telangiectasia, which the patient had not really noticed before. CK is raised at 2820 U/l.

Which of the following would you do next for this patient?

Your answer was incorrect

A	Autoantibody profile
B	Serum erythrocyte sedimentation rate
C	Analgesia and physiotherapy

E Malignancy screen

This lady is a smoker with a cough and has features of dermatomyositis (muscle weakness, heliotrope, dilated nail fold capillaries and raised CK), which may be paraneoplastic in 15% of cases.

Polymyositis causes a symmetrical proximal muscle weakness, and skin signs of dermatomyositis include macular 'shawl sign' rash over the back and shoulders, heliotrope rash on cheeks and eyelids, nail fold erythema and Gottron's papules. Rough papules on extensor surfaces of the phalanges are pathognomonic if there is a history of weakness and elevated creatine kinase (CK). In older patients (>40 years) there is an increased risk of malignancy, which must be extensively investigated. Thorough clinical examination should include per rectum, breasts and lymph nodes; investigations should include chest X-ray, ultrasound scan of the abdomen/pelvis, mammography and

abdomen/pelvis, mammography and prostate-specific antigen (PSA) (men).

A	Autoantibody profile

ANA can be negative (it is positive in 40–80% of cases) and only 20% have a myositis-associated antibody, of which Jo-1 is the most common.

B	Serum erythrocyte sedimentation rate

An ESR is non-specific, not diagnostic, and may be normal in dermatomyositis.

C	Analgesia and physiotherapy

Although analgesia and physiotherapy are part of the management, this patient may need prednisolone and treatment of the underlying cancer.

D	Weekly methotrexate

A 38-year-old white woman presents for review with a history of two transient ischaemic attacks in the past 24 months. In addition, she reports cramping of her arms when lifting weights at the gym. She has also been significantly tired recently.

She has smoked 20–30 cigarettes per day since the age of 34 years. Arteriography reveals diffuse stenoses of the thoracic and abdominal aortae, as well as the subclavian arteries.

Investigations:

Hb	12.7 g/dl
WCC	4.8×10^9/l
PLT	450×10^9/l
Neutrophils	2.5×10^9/l
Lymphocytes	1.8×10^9/l
ESR	58 mm/1st h
CRP	21 mg/l
AST	28 IU/l
ALP	101 IU/l

CRP	21 mg/l
AST	28 IU/l
ALP	101 IU/l
ALT	15 IU/l
ANA	-

What diagnosis fits best with this clinical picture?

A Buerger's disease

B Behçet's disease

C Takayasu's disease

D Giant-cell arteritis

E Systemic lupus erythematosis

C Takayasu's disease

Takayasu's disease (TD) is a continuous or patchy granulomatous inflammatory vasculitis that causes progressive occlusive disease of the aorta and its branches. It is rare in the Western world, with an annual incidence of between 2 and 3 per million. It more commonly affects individuals in Asia and the Far East, although may occur in Caucasian patients, such as in this case. Approximately 80% of patients are women, and the mean age of onset is 30 years. Presentation may be with constitutional symptoms such as fever, malaise and weight loss; neurological symptoms such as transient ischaemic attacks; or vascular symptoms such as claudication, including upper limb claudication. Cardiac features include angina, heart failure and aortic regurgitation. Renal manifestations may include mesangial proliferative glomerulonephritis. Blood tests may be normal, but usually there is a modest inflammatory response as in this case – raised ESR and CRP. Corticosteroids

inflammatory response as in this case raised ESR and CRP. Corticosteroids with the addition of steroid-sparing second agents such as methotrexate or azathioprine are the mainstay of therapy. With good care, 15-year survival rates approach 90%.

A	Buerger's disease

Buerger's disease (thromboangiitis obliterans) is a condition associated with progressive inflammation and thrombosis (clotting) of small and medium arteries and veins of the hands and feet, predominantly in young male smokers. Although this lady is a heavy smoker, her symptoms of transient ischaemic attacks started only two years into her smoking history, and their timing would thus not be appropriate for a diagnosis of Buerger's.

B	Behçet's disease

Behcet's disease is a rare, multi-system vasculitis, usually associated a triad of

oral ulcers, genital ulcers and uveitis. Vascular complications are usually found in men.

D	Giant-cell arteritis

Giant cell arteritis (temporal arteritis, GCA) is usually found in elderly Caucasian females (mean age of onset 70, not found in patients under 50) and is associated with headache and a risk of irreversible blindness. GCA may occur as part of a spectrum of polymyalgia rheumatic, characterised by proximal muscle pain.

E	Systemic lupus erythematosis

Although this lady is in the right demographic for SLE – a young female – she has no signs of symptoms of SLE, such as rash, photosensitivity, arthralgia, etc. and has a negative ANA.

6419

Rate this question:

7:14
tps://mypastest.pastest.com

A 45-year-old woman presents with chest pain to the Emergency Department. She has a history of asthma for which she uses occasional salbutamol, and she smokes approximately 30 cigarettes per day. There is no history of hypersensitivity to non-steroidal anti-inflammatory agents. There is pain with coughing and deep breathing, with tenderness of the 2nd to 5th costochondral junctions with the sternum.

Chest X-ray is unremarkable and electrocardiogram (ECG) shows no acute changes; saturations are 98% on air.

Which of the following would be the most appropriate intervention in this case?

A	Low-molecular weight heparin

with the sternum.

Chest X-ray is unremarkable and electrocardiogram (ECG) shows no acute changes; saturations are 98% on air.

Which of the following would be the most appropriate intervention in this case?

A	Low-molecular weight heparin
B	Aspirin 75 mg po
C	Naproxen 250 mg qds
D	Amoxicillin 500 mg po tds
E	Fluticasone 50 µg inhaler bd

33274

Submit

approximately 30 cigarettes per day. There is no history of hypersensitivity to non-steroidal anti-inflammatory agents. There is pain with coughing and deep breathing, with tenderness of the 2nd to 5th costochondral junctions with the sternum.

Chest X-ray is unremarkable and electrocardiogram (ECG) shows no acute changes; saturations are 98% on air.

Which of the following would be the most appropriate intervention in this case?

Your answer was correct

A	Low-molecular weight heparin
B	Aspirin 75 mg po
C	Naproxen 250 mg qds
D	Amoxicillin 500 mg po tds

C Naproxen 250 mg qds

This patient has costochondritis (Tietze syndrome), which has a higher prevalence in women and is commoner over the age of 40 years. It is associated with tenderness over the costochondral junctions and/or sternum, pain on coughing and deep breathing, and equal involvement with both sides of the chest. Non-steroidals would be an appropriate first-line intervention for pain relief. It is of course an ideal opportunity to reinforce advice about smoking cessation.

A Low-molecular weight heparin

A pulmonary embolism is very unlikely given the normal ECG, lack of tachycardia, normal oxygen saturations on room air and tenderness on palpation of the chest wall.

B Aspirin 75 mg qds

B Aspirin 75 mg po

Aspirin 75 mg would be inadequate to treat acute coronary syndrome, which is unlikely in any case given her lack of ECG changes and no mention of cardiac enzymes being elevated.

D Amoxicillin 500 mg po tds

This lady does not have productive cough, fever, raised CRP or crackles on examination, and therefore antibiotics in this case are inappropriate and may perpetuate antibiotic resistance.

E Fluticasone 50 µg inhaler bd

There is no suggestion that this is an exacerbation of asthma – she has no wheeze or dyspnoea, but does have pain on palpation of her chest wall at the costochondral junction.

33274

Rate this question:

E Electromyogram (EMG)/nerve conduction studies

This patient has carpal tunnel syndrome (CTS), as evident by paraesthesia in the hands especially at night. CTS occurs as a result of compression of the median nerve at the wrist and characteristically affects the thumb and lateral two fingers. It is seen commonly in rheumatoid arthritis (RA), most often due to entrapment of the median nerve by synovial swelling. Treatment includes the use of resting hand splints, local corticosteroid injections or median nerve release surgery. An electromyogram (EMG)/nerve conduction study is useful for confirming clinical diagnosis prior to actual surgery.

B Routine MR of the cervical spine

This lady has carpal tunnel syndrome, where the median nerve is usually compressed at the wrist. Cervical spine

compressed at the wrist. Cervical spine imaging is not indicated.

A	Urgent magnetic resonance (MR) scan of the cervical spine

This lady has carpal tunnel syndrome, where the median nerve is usually compressed at the wrist. Cervical spine imaging is not indicated.

C	X-ray of the hands

X-rays are not helpful in the diagnosis of carpal tunnel syndrome or assessing RA disease activity, but may be useful in detecting damage resulting from RA.

D	MR of the hands

MRI imaging of the hands may not show median nerve compression. It is very expensive and an insensitive method for detection of carpal tunnel syndrome. MR imaging may be helpful

A 52-year-old woman presents to the Respiratory Clinic with increased shortness of breath. She has suffered from Raynaud's syndrome for some time, and around 6–9 months ago began treatment for gastro-oesophageal reflux. Other past history of note includes smoking of 10 cigarettes per day.

On examination, her blood pressure is 152/92 mmHg, with a pulse of 83 bpm. Auscultation of the chest reveals fine inspiratory crackles throughout both lung fields.

Investigations:

Hb	10.9 g/dl
WCC	5.9×10^9/l
PLT	135×10^9/l
Na^+	141 mmol/l
K^+	4.9 mmol/l
Creatinine	142 μmol/l
FEV_1	2.1
FVC	2.7

K^+	4.9 mmol/l
Creatinine	142 μmol/l
FEV_1	2.1
FVC	2.3
Adjusted KCO	Low

Which of the following is the most likely diagnosis?

A	Asthma
B	Chronic obstructive pulmonary disease (COPD)
C	Systemic sclerosis
D	Systemic lupus erythematosus (SLE)
E	Idiopathic pulmonary fibrosis

shortness of breath. She has suffered from Raynaud's syndrome for some time, and around 6–9 months ago began treatment for gastro-oesophageal reflux. Other past history of note includes smoking of 10 cigarettes per day.

On examination, her blood pressure is 152/92 mmHg, with a pulse of 83 bpm. Auscultation of the chest reveals fine inspiratory crackles throughout both lung fields.

Investigations:

Hb	10.9 g/dl
WCC	5.9×10^9/l
PLT	135×10^9/l
Na^+	141 mmol/l
K^+	4.9 mmol/l
Creatinine	142 μmol/l
FEV_1	2.1
FVC	2.3
Adjusted KCO	Low

C Systemic sclerosis

The constellation of symptoms and signs seen here, with Raynaud's, gastro-oesophageal reflux disease, dyspnoea and a restrictive pattern of spirometry, is highly suggestive of systemic sclerosis with pulmonary fibrosis. Antinuclear antibody testing is usually positive, high-resolution CT scanning reveals changes characteristic of interstitial lung disease: pulmonary fibrosis. Calcium channel blockers, prostaglandins and cyclophosphamide have all been used in the treatment of systemic sclerosis related lung disease, and PDE-5 inhibitors are now used extensively for control of pulmonary hypertension.

A Asthma

One would expect an obstructive pattern of spirometry, and onset of asthma at this age would be unusual. Polyphonic wheezes are more likely to be heard, as crackles may signify

B	Chronic obstructive pulmonary disease (COPD)

An obstructive spirometry pattern would be found and the extrapulmonary features are not associated with COPD.

D	Systemic lupus erythematosus (SLE)

Although the features could be consistent with SLE, the absence of any rashes or cytopaenias make SLE less likely than systemic sclerosis.

E	Idiopathic pulmonary fibrosis

The most striking feature dissuading you from the diagnosis of idiopathic pulmonary fibrosis is Raynaud's phenomenon, which is strongly linked to connective tissue disease.

21012

Rate this question:

A 38-year-old male postgraduate student from Hong Kong presents to his general practitioner (GP) complaining of sudden-onset left ear pain, and with an inability to sleep on the affected side. He reports that he is feeling very low because he has had a number of health problems since coming to this country 6 months ago.

On further questioning, he admits to having general aches and pains, including pains in various joints over this time. He reports that both his eyes are red all the time but that anti-allergy drops bought from the chemist have had no effect. He has also had a couple of nose bleeds, which is a first for him and which he blames on the increased pollution in the air, which he also feels is responsible for the hoarseness in his voice. He denies any known medical problems and, apart from analgesics, he is not on any regular medication.

Positive findings on clinical examination include left auricular chondritis, bilateral eyelid oedema and bilateral mild episcleritis, tenderness to

from analgesics, he is not on any regular medication.

Positive findings on clinical examination include left auricular chondritis, bilateral eyelid oedema and bilateral mild episcleritis, tenderness to palpation over the anterior trachea and pain on palpation over the costochondral joints. The GP orders some blood tests and X-rays, including rheumatoid factor, which is negative.

What is the most likely diagnosis?

A	Relapsing polychondritis
B	Reiter's syndrome
C	Wegener's granulomatosis/granulomatosis with polyangitis (GPA)
D	Cogan's syndrome
E	Polyarteritis nodosa

having general aches and pains, including pains in various joints over this time. He reports that both his eyes are red all the time but that anti-allergy drops bought from the chemist have had no effect. He has also had a couple of nose bleeds, which is a first for him and which he blames on the increased pollution in the air, which he also feels is responsible for the hoarseness in his voice. He denies any known medical problems and, apart from analgesics, he is not on any regular medication.

Positive findings on clinical examination include left auricular chondritis, bilateral eyelid oedema and bilateral mild episcleritis, tenderness to palpation over the anterior trachea and pain on palpation over the costochondral joints. The GP orders some blood tests and X-rays, including rheumatoid factor, which is negative.

What is the most likely diagnosis?

Your answer was correct

A Relapsing polychondritis

A Relapsing polychondritis

This young man has inflammation of cartilaginous structures – the pinna (red, painful ear), nasal septum (epistaxis) and larynx (hoarse voice), as well as chostochondritis and the C-rings of the trachea, consistent with relapsing polychondritis (RP).

There is no gender difference in the distribution of the disease, and although it can occur at any age it is most common in the fifth decade. The patient's reported symptoms depend on the area of the body affected. General symptoms include intermittent fever and weight loss, but other more specific symptoms include sudden onset of ear pain with an inability to sleep on the affected side, diminished hearing, mono- or polyarthritis, back pain, myalgias, mild epistaxis, saddle-shaped nose, redness of the eyes indicative of conjunctivitis, episcleritis and/or scleritis, hoarseness of the voice and recurrent respiratory infections. There are no specific diagnostic laboratory findings in

infections. There are no specific diagnostic laboratory findings in patients with RP, but the non-specific indicators of inflammation (ESR, CRP) are often elevated. No specific therapy exists for RP, but the goal of treatment is to control the patient's symptoms and to preserve the integrity of the affected cartilaginous structures. The mainstay of treatment is systemic corticosteroids. It is important in these patients to investigate for the presence of other concurrent autoimmune diseases.

B	Reiter's syndrome

Ear pain, epistaxis and hoarse voice are not features of reactive arthritis (Reiter syndrome). Reactive arthritis is a systemic inflammatory disorder characterised by an aseptic oligoarthritis, triggered by infections arising most commonly from the genitourinary and gastrointestinal systems. A history of urethritis/dysuria and conjunctivitis completes the reactive arthritis triad.

D Cogan's syndrome

Cogan syndrome is a rare chronic inflammatory autoimmune-mediated disorder characterised by inflammation of the ears and eyes. The pathophysiology is poorly understood, but the immunological theory is based on the release of auto-antibodies against corneal, inner ear and endothelial antigens, and of anti-nuclear cytoplasmic auto-antibodies (ANCA). Preceding infection may also be implicated but again the exact mechanism is unclear. Cogan syndrome can lead to vision difficulty, hearing loss and dizziness. The inner ear is affected, leading to hearing loss in Cogan syndrome, whereas in this case the cartilaginous pinna is affected resulting in a red, swollen, painful ear.

E Polyarteritis nodosa

This is a rare medium-sized vessel vasculitis, usually leading to mesenteric ischaemia and mononeuritis multiplex.

You review a 52-year-old man who complains of persistent bone pain. Bone scanning indicates activity particularly affecting the femurs you discuss treatment options including bisphosphonate therapy. He has no other medical conditions and no family history of bone conditions or malignancy. The patient has been studying the condition on the Internet and is worried about possible risk of osteogenic sarcoma.

Which of the factors below is associated with increased risk of osteogenic sarcoma?

A	Bisphosphonate therapy
B	Retinoblastoma
C	Previous chemotherapy treatment
D	Osteopenia
E	Age >50 years

B Retinoblastoma

This is a rare malignancy of the eye found in children. In hereditary forms of retinoblastoma there is an increased risk of developing bone or soft tissue sarcomas. This risk is further increased if radiotherapy has been used to treat the patient.

Other conditions that increase the risk of osteosarcoma include Paget's disease of the bone, hereditary multiple ostochondromas and inherited cancer syndromes such as Li–Fraumeni syndrome.

A Bisphosphonate therapy

There is no link between bispohosphonates and osteogenic sarcoma. The mainstay of treatment for Paget's disease is bisphosphonate therapy, which is proven to relieve symptoms of pain and has been shown to reduce the risk of pathological fracture in long bones and complications of Paget's such as

deafness. Bisphosphonates may also be of benefit alongside conventional chemotherapy treatment of osteosarcoma.

C	Previous chemotherapy treatment

Chemotherapy has not been linked with osteosarcoma, but there is an increased risk of developing osteosarcoma in individuals who have had radiotherapy. In this situation the osteosarcoma arises in the area of previous treatment.

D	Osteopenia

There is no causative link between osteopenia and osteosarcoma. Bone diseases associated with increased risk of osteosarcoma include Paget's disease of the bone and hereditary multiple ostochondromas.

E	Age >50 years

A 19-year-old man was referred to the Rheumatology Clinic with a long history of pain in the back and knee joints. The initial problem started with recurrent back and wrist pain when he was 6 years old. He was treated for possible juvenile arthritis, which often responded to analgesia. Over the year the disease has been relapsing and remitting, but since last year the back pain has been constant all over the spine and has not responded to analgesia.

Several investigations in the past include X-ray of the spine and knee, rheumatoid factor, antinuclear antibody and autoimmune profile. All these investigations were reported as normal.

He had a normal childhood with no illness and there is no family history of note. He has seen the dermatologists for an abnormal dark-brown pigmentation in his ears and sclera, but no cause was found.

On examination, his knees are swollen and painful. He also has tenderness all

and painful. He also has tenderness all over his spine. Both sclera and ears show an abnormal dark brown pigmentation.

Investigations:

Hb	10.3 g/dl
WCC	9.8×10^9/l
PLT	250×10^9/l
Na^+	145 mmol/l
K^+	4.3 mmol/l
Ca^{2+}	2.6 mmol/l
Phosphate	0.9 mmol/l
Glucose	4.2 mmol/l
ALP	110 U/l
X-ray spine	Calcification of intervertebral disc
X-ray knees	Soft tissue swelling with meniscal calcification

Urinalysis:

knees	meniscal calcification

Urinalysis:

Colour	Dark
Glucose	+++
Blood	-

What is the probable underlying diagnosis?

A Osteogenesis imperfecta

B Ankylosing spondylitis

C Phenylketonuria

D Alkaptonuria

E Polyarticular Still's disease

33285

Submit

D Alkaptonuria

Alkaptonuria is a hereditary disease characterised by a deficiency of the enzyme homogentisic oxidase, which is responsible for the degradation of homogentisic acid produced from phenylalanine and tyrosine. Accumulation of homogentisic acid causes pigmentation of the urine, sclera and connective tissues. Deposition in the joints causes cartilage pigmentation (ochronosis) and degeneration. Homogentisic acid is a reducing agent, and therefore it gives an incorrect positive Glucostix test but normal Clinitest. Urine, after standing, becomes dark in colour due to oxidation of the product. The knees and spine are commonly affected. The sacroiliac joint may be spared. No curative treatment is yet available.

A Osteogenesis imperfecta

In osteogenesis imperfecta the X-rays are likely to be abnormal and blue sclerae are often observed

are likely to be abnormal and blue sclerae are often observed.

B Ankylosing spondylitis

X-rays would show changes in the sacroiliac joints (erosions, sclerosis, fusion) and there are no pigmentary problems.

C Phenylketonuria

Phenylketonuria (PKU) is an inborn error of metabolism that results in decreased metabolism of the amino acid phenylalanine. Untreated PKU can lead to intellectual disability, seizures, behavioural problems and mental disorder. It may also result in a musty smell and lighter skin.

E Polyarticular Still's disease

Still's disease is not associated with urinary problems or ocular pigmentation.

A 39-year-old man presents to his general practitioner (GP), complaining of long-standing lower back pain. He has tried multiple treatments for it, including physiotherapy and osteopathy, but they have had no effect. The pain tends to be distributed asymmetrically along the lower back, and he gets mild relief by using non-steroidal anti-inflammatory drugs (NSAIDs). He is otherwise fit and well and is not on any other medications.

He has had two episodes of redness and pain in his right eye, which he thought was an 'infection' and which resolved with appropriate treatment. He has one brother who is also known to suffer from back pain that has prevented him from working, but the patient is not aware of the exact nature of the problem since his brother is now living in Australia.

There is pain on palpation of his lower back. The positive findings found on clinical examination are pictured below.

By CopperKettle [CC BY-SA 3.0 (https://creativecommons.org/licenses/by-sa/3.0)], from Wikimedia Commons

On the basis of these findings, what is likely to be the diagnosis?

A	Reactive arthritis
B	Ankylosing spondylitis
C	Osteoarthritis
D	Psoriatic arthritis
E	Gout

general practitioner (GP), complaining of long-standing lower back pain. He has tried multiple treatments for it, including physiotherapy and osteopathy, but they have had no effect. The pain tends to be distributed asymmetrically along the lower back, and he gets mild relief by using non-steroidal anti-inflammatory drugs (NSAIDs). He is otherwise fit and well and is not on any other medications.

He has had two episodes of redness and pain in his right eye, which he thought was an 'infection' and which resolved with appropriate treatment. He has one brother who is also known to suffer from back pain that has prevented him from working, but the patient is not aware of the exact nature of the problem since his brother is now living in Australia.

There is pain on palpation of his lower back. The positive findings found on clinical examination are pictured below.

D Psoriatic arthritis

This man has psoriatic arthritis of the axial spondylitis subtype. Psoriatic arthritis is a member of the group of seronegative spondyloarthritides. It affects men and women equally, with the age of onset ranging between 35 and 55 years. The condition can present with or without associated psoriatic skin lesions or only with nail malformations. If no obvious skin lesions are visible, the clinician must look for psoriasis in hidden sites such as the scalp, intergluteal cleft and umbilicus. Nail involvement includes onycholysis, transverse ridging and nail pitting, as seen in the image. Five subsets of psoriatic arthritis have been described, based on the pattern of joint involvement, with an increased prevalence of the spondylitic form in men and the rheumatoid form in women. Extra-articular features of the condition include flexor tendon synovitis and uveitis.

B Ankylosing spondylitis

This man has axial spondylitis as part of psoriatic arthritis. The condition can be distinguished from the sacroiliitis seen in ankylosing spondylitis by the presence of the other clinical signs of cutaneous psoriasis in the nails and skin.

A	Reactive arthritis

The history is too long for reactive arthritis (which is usually acute, not chronic), and there is no gastrointestinal or genitourinary infective precipitant before the onset.

C	Osteoarthritis

This man is too young to have primary degenerative changes, and if he does have degenerative changes on X-ray, these are likely to be secondary osteoarthritis due to previous inflammation.

E	Gout

The dual X-ray bone absorptiometry (DXA) scan results of a 60-year-old man with rheumatoid arthritis (RA), being treated with prednisolone 7.5 mg per day and methotrexate 10 mg per week, show T scores of –1.6 at the spine and –1.8 at the hips.

Which of the following is the optimal therapy for this patient?

A	Calcium and vitamin D alone
B	Parathyroid hormone with calcium supplementation
C	Alendronate with calcium supplementation
D	Strontium
E	No change in therapy

The dual X-ray bone absorptiometry (DXA) scan results of a 60-year-old man with rheumatoid arthritis (RA), being treated with prednisolone 7.5 mg per day and methotrexate 10 mg per week, show T scores of −1.6 at the spine and −1.8 at the hips.

Which of the following is the optimal therapy for this patient?

Your answer was correct

A	Calcium and vitamin D alone
B	Parathyroid hormone with calcium supplementation
C	Alendronate with calcium supplementation
D	Strontium
E	No change in therapy

Explanation

C Alendronate with calcium supplementation

A T score of less than −2.5 at hip or spine is indicative of osteoporosis. However, in patients on steroid therapy, a score of −1.5 is taken as a cut-off value to start osteoporosis therapy. The use of bisphosphonates (alendronate and risedronate) has been shown to be associated with a reduced risk of fractures. Bisphosphonates are most commonly used as first-line agents in the treatment of osteoporosis.

A Calcium and vitamin D alone

Calcium and vitamin D therapy alone are not sufficient in reducing the risk of fractures in patients with osteoporosis, although they do offer some benefit. They may be given concomitantly with bisphosphonates.

B Parathyroid hormone with calcium supplementation

PTH stimulates bone formation and active remodelling and can be used in osteoporosis treatment. However, it is not first-line therapy for osteoporosis and therefore not the preferred answer.

D	Strontium

Strontium is used in cases of intolerance or lack of response to bisphosphonates, although recent labelling changes around risks of cardiovascular and thromboembolic events associated with strontium use mean that it is likely to become the treatment of last resort.

E	No change in therapy

This patient needs treatment for osteoporosis.

6884

Rate this question:

Next Question

A 59-year-old man presents with an acute pain and effusion in his right knee. He is on haemodialysis for chronic kidney disease related to type 1 diabetes and takes a number of medications including vitamin D and cinacalcet.

On examination, his blood pressure is 155/89 mmHg, his pulse is 80 bpm regular, his temperature is 37.6 °C. He does not appear to be fluid overloaded. He has psoriatic plaques on knees and elbows.

Investigations:

Hb	10.4 g/dl
WCC	6.7×10^9/l
PLT	179×10^9/l
Na^+	140 mmol/l
K^+	4.5 mmol/l
Ca^{2+}	2.15 mmol/l
Creatinine	540 µmol/l (pre-dialysis)
	Neutrophils and

Na^+	140 mmol/l
K^+	4.5 mmol/l
Ca^{2+}	2.15 mmol/l
Creatinine	540 μmol/l (pre-dialysis)
Knee effusion	Neutrophils and rhomboid crystals identified, weakly positively birefringent

Which of the following is the most likely diagnosis?

A Gout

B Hydroxyapatite arthritis

C Pseudogout

D Psoriatic arthritis

E Osteoarthritis

Creatinine	540 μmol/l (pre-dialysis)
Knee effusion	Neutrophils and rhomboid crystals identified, weakly positively birefringent

Which of the following is the most likely diagnosis?

Your answer was correct

A Gout

B Hydroxyapatite arthritis

C Pseudogout

D Psoriatic arthritis

E Osteoarthritis

Explanation

C Pseudogout

C Pseudogout

This man has end-stage kidney disease and hyperparathyroidism, as evidenced by his cinacalcet prescription, and his low normal calcium.
Hyperparathyroidism is associated with pseudogout (chondrocalcinosis) which may present acutely as an oligoarthritis, similar to gout, in shoulders, elbows or ankles or knees. Diagnosis is based on negative culture, and non- or weakly positively birefringent rhomboid or rod-shaped crystals. NSAIDs are used in patients without renal dysfunction, but may worsen salt and water retention and blood pressure in this patient, so colchicine may be a more appropriate choice.

A Gout

Gouty crystals are needle shaped and negatively birefringent.

B Hydroxyapatite arthritis

A 40-year-old woman reports intermittent joint pains affecting her wrists, ankles and knees for the last six months. She describes each episode as involving pain, swelling and erythema in one of the above joints, which usually resolves with anti-inflammatory drugs over one to two days.

Recently, the frequency of attacks has increased to two to three times per week from the previous two to three attacks every month. The last episode, involving the right knee, occurred three days ago.

Examination in clinic was unremarkable for synovitis in any of the joints.

Which one of the following is the most appropriate initial step?

A	Ask the patient to contact the rheumatologist ASAP during the next attack
B	X-ray of hands
C	Bone scan

increased to two to three times per week from the previous two to three attacks every month. The last episode, involving the right knee, occurred three days ago.

Examination in clinic was unremarkable for synovitis in any of the joints.

Which one of the following is the most appropriate initial step?

A	Ask the patient to contact the rheumatologist ASAP during the next attack
B	X-ray of hands
C	Bone scan
D	Anti-nuclear antibody (ANA) testing
E	Anti-neutrophil cytoplasmic antibody (ANCA) testing

A Ask the patient to contact the rheumatologist ASAP during the next attack

The patient is suffering from palindromic rheumatism, affecting mostly large joints. This is characterised by one or more features of inflammation, such as pain, swelling and erythema affecting an articular or periarticular site which lasts less than 72 hours before recovering completely. Any of the joints may be affected. In approximately 50% of patients, this may progress to rheumatoid arthritis (RA). The factors suggesting progression are small joint involvement, and a positive rheumatoid factor (RF) or anti-cyclic citrullinated peptide (CCP).

The most common cause of recurrent or relapsing arthritis, however, is crystal arthritis. It is therefore important to ask the patient to report to clinic in the event of a future attack for synovial fluid aspiration and examination for urate and calcium pyrophosphate dehydrate (CPPD)

pyrophosphate dehydrate (CPPD) crystals. Hyperuricaemia may be present but is not diagnostic and so testing for serum uric acid is not the correct answer here.

Other diseases, such as systemic autoinflammatory disorders (periodic fever syndromes), Whipple's disease, arthritis associated with hyperlipidaemia and intermittent hydrarthrosis, should be taken into account in the differential diagnosis of patients with recurrent arthritis.

D	Anti-nuclear antibody (ANA) testing

An ANA test is non-specific and unlikely to be helpful if positive. A far more useful test would be an anti-cyclic citrullinated peptide (CCP) antibody, which is more sensitive and more specific for a diagnosis of rheumatoid arthritis (RA) than rheumatoid factor, and can predate the clinical onset of RA.

Cryoprecipitate	73%
Vitamin K	9%
Factor VIII	7%
Factor IX	4%
No further treatment	8%

In bleeding patients with DIC with severe hypofibrinogenaemia (<1 g/l) that persists despite FFP replacement, then fibrinogen concentrate or cryoprecipitate is indicated

Important for me Less important

The patient has DIC likely secondary to malignancy. In bleeding patients with DIC and prolonged prothrombin time (PT) and activated partial thromboplastin time (aPTT), administration of fresh frozen plasma (FFP) may be useful. Notably, this patient continues to have severe hypofibrinogenaemia despite administration of FFP. In bleeding patients with DIC with severe hypofibrinogenaemia (<1 g/l) that persists despite FFP replacement, then fibrinogen concentrate or cryoprecipitate is indicated.

Vitamin K would be indicated in Vitamin K deficiency. There is nothing in the history to suggest vitamin K deficiency.

Factor VIII and factor IX are indicated for Haemophilia A and B respectively.

Discuss (2) Improve

Bleeding Disorders (ITP vs TTP vs HUS vs DIC)

Dirty USMLE - YouTube 0 0

+ Suggest media Report broken media

27 ✗
28 ✓
29 ✓
30 ✓
31 ✗
32 ✓
33 ✓
34 ✓
35 ✓

ding

4G 10:00

+880 1731-6554...
Today, 8:59 PM

Juco d
SLE

A 39-year-old man presents to Rheumatology Clinic after noticing a new swelling on the side of his finger. He has noticed that the swelling has been worsening over the past several months.

He has a past medical history of rheumatoid arthritis (RA), hypertension and hyperlipidaemia. He normally takes methotrexate, paracetamol, ramipril, atorvastatin and aspirin.

A photograph of his hand is shown below.

What is the most likely diagnosis?

A	Xanthoma

What is the most likely diagnosis?

A	Xanthoma
B	Rheumatoid nodule
C	Basal cell carcinoma (BCC)
D	Squamous cell carcinoma (SCC)
E	Keratoacanthoma

71602

Submit

B Rheumatoid nodule

This patient has developed a rheumatoid nodule. These are firm swellings in subcutaneous tissue, often occurring over bony prominences, but also in the lungs. A quarter of patients with RA develop nodules which are usually asymptomatic. They consist of fibrous layers.

Methotrexate can make nodules worse, while rituximab can make them better. Surgical removal is often successful.

A Xanthoma

Xanthomas are flat, yellow plaques appearing in the 30s or 40s, typically in women. The lesions tend to become static and do not regress. They are associated with high cholesterol-rich beta-lipoproteins (LDLs). This nodule, however, is not flat and does not have the typical yellowish colour.

C Basal cell carcinoma (BCC)

D	Squamous cell carcinoma (SCC)

SCCs are malignant tumours arising from keratinising cells of the epidermis and can be locally invasive and sometimes metastatic. Presentation is as an individual nodular keratinising or crusting lesion which can ulcerate. There is some variety in presentation, but typically it is a small nodule which progressively grows, becomes necrotic and sloughs. The absence of such features makes this an unlikely diagnosis.

E	Keratoacanthoma

Keratoacanthomas are rapidly growing squamous lesions that appear over months and spontaneously resolve. They are solitary, round and skin coloured or reddish papules which may project like a horn. The absence of a centre keratin horn-like structure makes this unlikely.

6:30
tps://mypastest.pastest.com

A 34-year-old woman complains of severe pain and aching in her fingers and toes on going out into cold weather. She reports a triad of initial whitening of the fingers resulting from vasospasm, followed by blue discoloration and then reddening and pain.

She is currently taking atenolol 50 mg po daily for hypertension and takes methysergide for intermittent migraine. She has a history of reflux nephropathy and her creatinine is 180 µg/l. Her methysergide is discontinued.

Which other intervention would be most appropriate for this patient?

A	Start isosorbide dinitrate
B	Stop atenolol and start ramipril
C	Start prednisolone 40 mg po

methysergide for intermittent migraine. She has a history of reflux nephropathy and her creatinine is 180 µg/l. Her methysergide is discontinued.

Which other intervention would be most appropriate for this patient?

A	Start isosorbide dinitrate
B	Stop atenolol and start ramipril
C	Start prednisolone 40 mg po daily
D	Start diclofenac 50 mg po tds
E	Start verapamil

33278

Submit

A 34-year-old woman complains of severe pain and aching in her fingers and toes on going out into cold weather. She reports a triad of initial whitening of the fingers resulting from vasospasm, followed by blue discoloration and then reddening and pain.

She is currently taking atenolol 50 mg po daily for hypertension and takes methysergide for intermittent migraine. She has a history of reflux nephropathy and her creatinine is 180 µg/l. Her methysergide is discontinued.

Which other intervention would be most appropriate for this patient?

Your answer was incorrect

A	Start isosorbide dinitrate
B	Stop atenolol and start ramipril

B Stop atenolol and start ramipril

Both methysergide and atenolol are possible causes of Raynaud's phenomenon, or can exacerbate existing Raynaud's as described here. Other causes include ergotamine, vinblastine, bleomycin and oral contraceptives. ACE inhibitors also have the best evidence for reno-protection where there is underlying autoimmune pathology. Calcium channel antagonists such as nifedipine may be of value in improving symptoms.

E Start verapamil

Although verapamil is a calcium channel blocker it is not used for Raynaud's, unlike nifedipine (and even amlodipine).

A Start isosorbide dinitrate

There is no evidence for nitrates in

There is no evidence for nitrates in improving Raynaud's symptoms.

C	Start prednisolone 40 mg po daily

There are no features of underlying connective tissue disease and this may well be primary Raynaud's or related to medications. Raynaud's phenomenon has many causes, including systemic sclerosis, mixed connective tissue disease, systemic lupus erythematosus (SLE), rheumatoid arthritis, polycythemia and thromboangiitis obliterans.

D	Start diclofenac 50 mg po tds

NSAIDs are contraindicated given her kidney disease and would not improve her Raynaud's symptoms in any case.

33278

Rate this question:

A 58-year-old male patient with well-controlled ankylosing spondylitis reminds you of his scheduled right knee replacement surgery in 6 weeks' time.

His medications include etanercept 50 mg subcutaneously weekly, prednisolone 5 mg per day and co-codamol tablets.

What advice regarding his medication should be given prior to surgery?

A	Stop etanercept 4–6 weeks prior to surgery
B	Stop etanercept 2–4 weeks prior to surgery
C	Stop both etanercept and prednisolone 2–4 weeks prior to surgery
D	Keep the medications unchanged

His medications include etanercept 50 mg subcutaneously weekly, prednisolone 5 mg per day and co-codamol tablets.

What advice regarding his medication should be given prior to surgery?

A	Stop etanercept 4–6 weeks prior to surgery
B	Stop etanercept 2–4 weeks prior to surgery
C	Stop both etanercept and prednisolone 2–4 weeks prior to surgery
D	Keep the medications unchanged
E	Double the dose of etanercept

B Stop etanercept 2–4 weeks prior to surgery

The British Society for Rheumatology (BSR) guidelines (January 2005) for prescribing tumour necrosis factor (TNF-α) blockers in adults with RA recommend withholding etanercept and other TNF-blockers (infliximab and adalimumab) for 2–4 weeks prior to a major surgical procedure. Stopping earlier may lead to disease flare-up and thus interfere with the surgery. Treatment may be restarted postoperatively if there is no evidence of infection and once wound healing is satisfactory. Small-dose prednisolone is safe – it doesn't increase the risk of infection or interfere with wound healing and therefore need not be stopped. However, care must be taken to administer 50–100 mg hydrocortisone perioperatively in order to meet with increased demands during the stress of major surgery.

A Stop etanercept 4–6 weeks

This may increase the risk of RA disease flare-up.

C	Stop both etanercept and prednisolone 2–4 weeks prior to surgery

This may increase the risk of an addisonian crisis.

D	Keep the medications unchanged

This may increase the risk of infection.

E	Double the dose of etanercept

This may increase the risk of infection and is not a licensed dose regimen for etanercept, which could have potentially dangerous effects.

6883

Rate this question:

A 67-year-old woman presents to the General Medical Clinic with long-standing pain in her hands. She has had progressively worsening deformity of her hands with ongoing pain and stiffness. She has no systemic symptoms. For many years, she has been taking only paracetamol and ibuprofen as this has controlled her pain, but she finds this to be no longer effective. She has a past medical history of asthma as a child, elective hip replacement due to osteoarthritis and hypertension.

On examination of her hands there is painful swelling of wrists and metacarpophalangeal (MCP) joints.

Her hands are shown below.

Blood tests have been requested.

What is the most appropriate management plan?

A	Codeine
B	Methotrexate and prednisolone
C	Biological therapy
D	Methotrexate alone
E	Topical naproxen cream

71601

Submit

B Methotrexate and prednisolone

This patient has chronic deformity due to underlying, untreated rheumatoid arthritis (RA). There is also evidence of active synovitis. The deformity in this patient includes ulnar deviation of the metacarpophalangeal (MCP) joints, radial shift of metacarpals, Boutonniere deformity of the thumb and swan-neck deformity.

While the aim of treatment is to prevent this level of deformity, the joint pain also indicates active disease. This means that treatment is needed with a disease-modifying antirheumatic drug (DMARD) to help control disease in the long term and a corticosteroid to achieve disease control in the short term.

A Codeine

Codeine is a mild opiate which can be used as analgesia. It would not help in addressing the underlying problem for

this patient.

C	Biological therapy

Biological therapy includes adalimumab and etanercept. These are monoclonal antibodies which can be used as treatment when DMARD therapy has failed in RA. It is not appropriate as first-line therapy.

D	Methotrexate alone

Methotrexate can be used as first-line treatment to control RA, but the active synovitis means that corticosteroids are necessary to induce remission as well.

E	Topical naproxen cream

Topical non-steroidal anti-inflammatory drug (NSAID) creams are useful in hand and knee osteoarthritis, but would not be useful in addressing the underlying RA in this patient and would fail to prevent further deformity.

You are called to see a 63-year-old man in the Surgical Ward, who underwent hernia repair surgery 4 days ago. He is complaining of pain and swelling in the right knee for the past 2 days. He describes the pain as being severe and similar to previous episodes affecting either the knees or toes intermittently.

He reminds you that the medication he regularly takes for joint pains has been discontinued during the present admission. You aspirate 10 ml of synovial fluid from his red, swollen and tender right knee and examine it under microscope.

What is the most likely microscopic appearance of the joint aspirate fluid?

A	Neutrophils and negatively birefringent crystals
B	Lymphocytes and negatively birefringent crystals
C	Neutrophils and positively

regularly takes for joint pains has been discontinued during the present admission. You aspirate 10 ml of synovial fluid from his red, swollen and tender right knee and examine it under microscope.

What is the most likely microscopic appearance of the joint aspirate fluid?

A	Neutrophils and negatively birefringent crystals
B	Lymphocytes and negatively birefringent crystals
C	Neutrophils and positively birefringent crystals
D	Lymphocytes and positively birefringent crystals
E	Both negatively and positively birefringent crystals

A Neutrophils and negatively birefringent crystals

The patient is having an acute attack of gout, precipitated by stopping allopurinol and the stress of surgery. The synovial fluid will show an abundance of neutrophils and negatively birefringent, needle-shaped urate crystals.

B Lymphocytes and negatively birefringent crystals

Gouty fluid shows neutrophils (not lymphocytes). Lymphocytes are more characteristic of chronic infections

C Neutrophils and positively birefringent crystals

Gouty fluid shows neutrophils and negatively (not positive) birefringent crystals. Calcium pyrophosphate dehydrogenase (CPPD) crystals seen in pseudo-gout show positive birefringence and are rhomboid-

A 66-year-old man presents with bony pain affecting his right hip and pelvis. He has a past history of prostatism, for which he received a transurethral resection of the prostate (TURP) some three years earlier.

On examination, there is pain on right hip flexion and internal and external rotation.

Investigations:

Haemoglobin (Hb)	12.1 g/dl
White cell count (WCC)	5.0×10^9/l
Platelets (PLT)	191×10^9/l
Sodium (Na^+)	139 mmol/l
Potassium (K^+)	4.6 mmol/l
Creatinine	145 μmol/l
Calcium (Ca^{2+})	2.3 mmol/l

Prostate-specific antigen (PSA)	2.0 µg/l
Alkaline phosphatase (ALP)	360 u/l

X-ray of the pelvis is shown below.

By Jmarchn [CC BY-SA 3.0 (https://creativecommons.org/licenses/by-sa/3.0) or GFDL (http://www.gnu.org/copyleft/fdl.html)], from Wikimedia Commons

Which of the following is the most likely diagnosis?

A	Metastatic prostatic carcinoma

By Jmarchn [CC BY-SA 3.0 (https://creativecommons.org/licenses/by-sa/3.0) or GFDL (http://www.gnu.org/copyleft/fdl.html)], from Wikimedia Commons

Which of the following is the most likely diagnosis?

A	Metastatic prostatic carcinoma
B	Osteoarthritis of the left hip
C	Myeloma
D	Paget's disease of bone
E	Hyperparathyroidism

33288

Submit

D Paget's disease of bone

The X-ray shows severe degenerative disease in the right hip, along with cortical thickening. As is most common in the general population, these changes are found more so in the right hip than the left. The site described is a typical one for Paget's disease, and the combination of raised alkaline phosphatase and normal calcium level also fits with this. A radionucleotide bone scan may be useful at a later stage to determine the extent of disease. Both a prolonged oral course of bisphosphonates and intermittent intravenous courses are used for the treatment of Paget's disease. These inhibit osteolysis and, as such, lead to a reduction in serum ALP levels (which can be used for serial measurements of treatment response) and reduce the pain associated with Paget's disease. For patients who fail to respond to bisphosphonates or cannot tolerate them, calcitonin may be a suitable alternative.

A Metastatic prostatic carcinoma

It is likely that his previous TURP was for benign prostatic hypertrophy. His PSA level now does not give any cause for concern and his calcium level is normal.

B Osteoarthritis of the left hip

X-rays of osteoarthritis show sclerosis, without areas of osteolysis. The isolated elevated ALP level also fits with Paget's disease.

C Myeloma

His calcium level is normal; the ALP level is elevated, and there are areas of increased bone density on the X-ray, a picture that does not fit with myeloma.

E Hyperparathyroidism

His calcium level is normal.

A 67-year-old man with a previous history of acute gout and mild renal impairment comes to the clinic complaining of an acute flare. He has hypertension for which he takes amlodipine 5 mg daily and mild renal impairment is again confirmed. His current medication for gout is allopurinol 100 mg per day and colchicine 500 μg daily.

Investigations:

Hb	11.8 g/dl
WCC	5.4×10^9/l
PLT	202×10^9/l
Na^+	139 mmol/l
K^+	5.0 mmol/l
Creatinine	157 μmol/l

Which of the following represents the most appropriate management for him?

A Increase his colchicine to

Na^+	139 mmol/l
K^+	5.0 mmol/l
Creatinine	157 µmol/l

Which of the following represents the most appropriate management for him?

A	Increase his colchicine to cope with the exacerbation
B	Halve the dose of his allopurinol
C	Give him a course of prednisolone 30mg daily for 1 week
D	Increase his allopurinol
E	Add diclofenac to his regime

A Increase his colchicine to cope with the exacerbation

Increasing his colchicine should be sufficient to get on top of his acute exacerbation.

B Halve the dose of his allopurinol

Halving his allopurinol as the only intervention is unlikely to be helpful in the short term.

C Give him a course of prednisolone 30mg daily for 1 week

A short course of corticosteroids is a possibility if he fails to respond to the increased dose of colchicine.

D Increase his allopurinol

Increasing his allopurinol may make matters worse, as allopurinol can

week

A short course of corticosteroids is a possibility if he fails to respond to the increased dose of colchicine.

D Increase his allopurinol

Increasing his allopurinol may make matters worse, as allopurinol can trigger a worsening of gout and should not be started in an acute attack, nor should the dose be increased in an acute attack.

E Add diclofenac to his regime

Adding diclofenac may worsen both his renal function and blood pressure and should be avoided in this case.

20572

Rate this question:

Next Question

A 56-year-old woman who suffered a road traffic accident some years ago presents to the clinic for review. She has been complaining of increasing pain and weakness in her right arm over the past few months and is now unable to work. Past history of note includes osteoarthritis.

On examination, there is weakness and wasting of the triceps, wrist and finger extensors, loss of the triceps jerk and sensory loss over the middle fingers of the hand.

Prolapse of which intervertebral disc is most likely to be responsible for her symptoms and signs?

A	C4–5
B	C5–6
C	C6–7
D	C7–T1

C C6–7

A lateral cervical disc protrusion at the C6–7 level (i.e. the disc between the 6th and 7th cervical vertebrae) compresses the exiting C7 nerve and thus causes pain and weakness over the C7 myotome (triceps, wrist and finger extensors), loss of the triceps jerk and loss of sensation over the C7 dermatome. Pain relief and immobilisation may be appropriate for initial management, although in those who fail to respond, MRI and assessment for surgical decompression are recommended.

A C4–5

C4–5 (C5 nerve root): A herniation at this level can cause shoulder pain and weakness in the deltoid muscle at the top of the upper arm, and does not usually cause numbness or tingling.

B C5–6

upper arms) and wrist extensor muscles. Numbness and tingling along with pain can radiate to the thumb side of the hand. This is one of the most common levels for a cervical disc herniation to occur.

D	C7–T1

C7–T1 (C8 nerve root): This level is located at the very bottom of the neck, where the cervical spine meets the thoracic, or upper, back. A herniation here can cause weakness with handgrip, along with numbness and tingling and pain that radiates down the arm to the little finger side of hand.

E	T1–2

T1–2 disc protrusion specifically refers to the deterioration of one or more of the intervertebral discs in the thoracic (middle) segment of the spine. The protrusion of a disc between any of the 12 vertebrae in the thoracic spine (T1–12) can cause severe pain and

A 35-year-old Turkish man was referred to the Emergency Department by his general practitioner (GP) with a suspected deep vein thrombosis (DVT).

He recently returned to the UK after a 1-year break in Turkey. While away, he was admitted once to hospital with diarrhoea and abdominal pain, which was accompanied by multiple painful lesions in his mouth. A few days after discharge from hospital, he presented again to the Emergency Department with an acute red and painful eye. He was sent home with eye drops for suspected conjunctivitis. A few months afterwards, the mouth lesions reappeared, but this time with similar lesions on his scrotum. At the same time, his ankle and wrist joints were swollen and painful. The lesions resolved after a few weeks as well as the joint problems. He has no past medical history.

On examination, he is pyrexial with a temperature of 38 °C. The left calf is swollen and tender and there are several painful lesions on the extensor

temperature of 38 °C. The left calf is swollen and tender and there are several painful lesions on the extensor surface of both legs. The wrists and ankles are swollen and tender and there are two well-demarcated ulcers on the roof of his mouth that are tender to touch.

Investigations:

Rheumatoid factor	Negative
Anti-nuclear antibody (ANA	Negative
Hb	8.8 g/dl
WCC	14×10^9/l
PLT	350×10^9/l
Na^+	140 mmol/l
K^+	4.8 mmol/l
Urea	8.8 mmol/l
Creatinine	98 μmol/l
Erythrocyte sedimentation	120 mm/h

Creatinine	98 μmol/l
Erythrocyte sedimentation rate (ESR)	120 mm/h
C-reactive protein (CRP)	210 g/l
Doppler ultrasound	Popliteal deep vein thrombosis (DVT)

What is the most likely underlying diagnosis?

A	Rheumatoid vasculitis
B	Sarcoidosis
C	Polyarteritis nodosa
D	Behçet's syndrome
E	Ulcerative colitis

D Behçet's syndrome

This man has orogenital ulceration, likely uveitis, inflammation in his bowels, erythema nodosum and a DVT (unprovoked as the flight to Turkey is not long haul). Behçet's syndrome is characterised predominantly by inflammation of the small blood vessels leading to recurrent ulceration, especially in the oral and genital mucosa. It persists for many years with characteristic painful oral and genital ulcers, uveitis, seronegative arthritis, thrombophlebitis, DVT and erythema nodosum.

The incidence is higher in Mediterraneans and equally affects both sexes, but men have a more severe disease course. The most common presentation is painful oral aphthous ulcers that are often accompanied by genital ulcers. Arthritis is asymmetrical affecting large joints. Recurrent thrombophlebitis and DVT are also common. The pathergy sign is a useful

thrombophlebitis and DVT are also common. The pathergy sign is a useful diagnostic sign: this is characterised by the formation of a sterile pustule at venepuncture sites. Steroids and azathioprine are useful in the management of the disease. Infliximab, anti-TNF, may be used for more severe cases.

A Rheumatoid vasculitis

This patient is seronegative and has relapsing remitting arthritis with orogential ulceration

B Sarcoidosis

Sarcoidosis is not associated with orogenital ulcers or DVT.

C Polyarteritis nodosa

Polyarteritis nodosa is not associated with orogenital ulceration or erythema nodosum. The skin rash that may occur with polyarteritis nodosa is livedo

You are intrigued by a skin lesion on the hands of a 47-year-old woman who has accompanied her daughter (who is having joint pains) to your clinic. The clinical appearance is shown below.

The woman informs you that the rash has been present for 2–3 years. She denies any other similar lesions or functional impairment due to this. Her general health remains good.

Which of the following is the most likely diagnosis?

A	Tinea infection
B	Lichen sclerosus

The woman informs you that the rash has been present for 2–3 years. She denies any other similar lesions or functional impairment due to this. Her general health remains good.

Which of the following is the most likely diagnosis?

A	Tinea infection
B	Lichen sclerosus
C	Morphea
D	Tuberculoid leprosy
E	Vitiligo

6895

Submit

C Morphea

Morphea is a form of localised scleroderma that may be circumscribed or generalised. In circumscribed morphea, there may be just one or two lesions with no generalised spread. The changes often begin with small, violaceous or erythematous skin lesions, which enlarge and progress to firm 'hidebound' skin with a variable degree of hypo- or hyperpigmentation. These lesions eventually settle into a waxy, white appearance with subsequent atrophy. Lesions vary in diameter between 1 and 10 cm. The condition generally resolves within 3–5 years, although sometimes a patch may persist for over 25 years. No therapy is usually needed for a single lesion, but emollients, low-concentration topical corticosteroids or calcipotriene may help relieve dryness and itching.

E Vitiligo

Vitiligo is caused by an autoimmune

process against melanocytes, it causes areas of depigmentation.

A Tinea infection

Tinea is associated with an annular lesion with scaling/erythema around the margin, caused by a fungal infection.

B Lichen sclerosus

Formally known as lichen sclerosus et atrophicus, this is a chronic skin disorder that most often affects the genital and perianal areas. It is ten times more common in women than men. The lesions appear like cigarette paper with dry, wrinkled skin and prominent hair follicles.

D Tuberculoid leprosy

Tuberculoid leprosy generally presents with large macular hypopigmented or erythematous anaesthetic lesions. Furthermore, there is no suggestion of

A 48-year-old woman presents with symptoms of parotid swelling, and dry eyes. She also avoids eating dry foods like cheese biscuits because her mouth is dry, and that she has recently had to have her plate from her dental implant refitted because it is rubbing on her gums. Other history of note is treatment for oral candidiasis 3 months ago.

On examination, her blood pressure is 145/82 mmHg, she has blepharitis and bilateral parotid enlargement.

Investigations:

Hb	12.1 g/dl
WCC	7.1×10^9/l
PLT	182×10^9/l
Na^+	141 mmol/l
K^+	4.3 mmol/l
Creatinine	135 μmol/l
Rheumatoid factor	weakly positive

Given the suspected diagnosis, which

Na^+	141 mmol/l
K^+	4.3 mmol/l
Creatinine	135 μmol/l
Rheumatoid factor	weakly positive

Given the suspected diagnosis, which investigation would be most likely to confirm this?

A	Antinuclear antibodies
B	Anti-Ro and Anti-La antibodies
C	Serum protein electrophoresis
D	Anti-smooth muscle antibodies
E	c-ANCA

B Anti-Ro and Anti-La antibodies

This woman has Sjögren's syndrome. This is an autoimmune exocrinopathy characterised by drying of mucus membranes such as conjunctivae, the buccal mucosa, and the vagina in women. Anti-Ro and anti-La antibodies are seen in Sjögren's, and antinuclear antibodies/rheumatoid factor are usually positive, but they are not specific for Sjögren's. Sjögren's can either be primary (on its own) or secondary to other conditions, such as rheumatoid arthritis or systemic lupus erythematosus (SLE). Schirmer's test demonstrates reduced flow of tears and involves placing a bent piece of filter paper in the corner of the eye. Management in the first instance involves replacing tears and saliva with lubricants; women may also require a suitable vaginal lubricant.

A Antinuclear antibodies

Antinuclear antibodies are non-specific

and found in many different conditions, as well as 10% of the asymptomatic healthy normal population.

C	Serum protein electrophoresis

In Sjögren's one would see a polyclonal hypergammaglobulinaemia (ie polyclonal raised IgG). The presentation does not sound like myeloma at all.

D	Anti-smooth muscle antibodies

Anti-smooth muscle antibodies are found in autoimmune hepatitis.

E	c-ANCA

cANCA is found in Wegener's granulomatosis (granulomatosis with polyangitis). This presentation in the clinical vignette does not sound like a vasculitis – with no upper respiratory tract, lower respiratory tract or renal involvement.

A 72-year-old man presents for revision of his left hip replacement some 10 years after his first prosthesis. Apart from some dull ache in the joint, he has suffered no particular problems over the past few years. He is otherwise completely well.

On examination, his blood pressure is 142/80 mmHg, he is apyrexial.

Investigations:

Hb	12.1 g/dl
WCC	5.6×10^9/l
PLT	190×10^9/l
Na^+	140 mmol/l
K^+	4.8 mmol/l
Creatinine	100 μmol/l
Joint aspirate	Gram positive bacillus

Which of the following is the most likely organism to have been aspirated from the joint?

PLT	190×10^9/l
Na^+	140 mmol/l
K^+	4.8 mmol/l
Creatinine	100 μmol/l
Joint aspirate	Gram positive bacillus

Which of the following is the most likely organism to have been aspirated from the joint?

A *Bacillus anthracis*

B *Clostridium difficile*

C *Clostridium perfringens*

D *Propionibacterium acnes*

E *Cornyebacterium striatum*

D *Propionibacterium acnes*

Propionibacterium acnes [1] is a slow growing Gram-positive bacterium which is poorly virulent. Symptoms of *P. acnes* infection may occur many years after original arthroplasty and the bacteria are only identified at the time of joint revision. Prolonged intravenous antibiotics given at the time of revision arthroplasty are said to resolve infection in around 90% of cases. *P. acnes* is known to be sensitive to penicillins, clindamycin and carbapenems.

A *Bacillus anthracis*

Bacillus anthracis is extremely rare. In humans, anthrax usually takes a cutaneous form with necrotic black lesions.

B *Clostridium difficile*

Clostridium difficile is most likely to be associated with antibiotic-associated

B	*Clostridium difficile*

Clostridium difficile is most likely to be associated with antibiotic-associated diarrhoea and pseudomembranous colitis.

C	*Clostridium perfringens*

This is associated with gas gangrene, bacteraemia, tissue necrosis, emphysematous cholecystitis

E	*Cornyebacterium striatum*

While *Cornyebacterium striatum* is an occasional cause of prosthetic joint infection, *P. acnes* is more commonly found.

Zeller V, Ghorbani A, Strady C, Leonard P, Mamoudy P, Desplaces N. *Propionibacterium acnes*: an agent of prosthetic joint infection and colonization. Journal of Infection, 55, 119–124.

A 30-year-old woman with a history of systemic lupus erythematosus presents with a 3-day history of cough and pleuritic chest pain. She feels generally lethargic and unwell. She takes hydroxychloroquine 200 mg od for her lupus and was recently started on phenytoin after two seizures.

Investigations:

Hb	11.3 g/dl
WCC	13.5×10^9/l
PLT	233×10^9/l
ESR	24 mm/1st h
CRP	63 mmol/l
Na^+	137 mmol/l
K^+	3.8 mmol/l
Creatinine	76 mmol/l
Urea	6.7 mmol/l
Anti-nuclear antibodies	+
Anti-DNA	+, low titre

K^+	3.8 mmol/l
Creatinine	76 mmol/l
Urea	6.7 mmol/l
Anti-nuclear antibodies	+
Anti-DNA	+, low titre
Anti-histone antibody	-

What is the treatment of choice?

A Stop phenytoin

B Start prednisolone 30 mg od

C Start amoxicillin 500 mg tds

D Start ibuprofen 400 mg tds

E Stop hydroxycholoroquine

C Start amoxicillin 500 mg tds

This lady has a raised CRP, indicating infection. Patients with SLE are more prone to infections as a consequence of disease-specific factors, such as low complement, cytopenia, immune dysfunction and immunosuppressive agents.

A Stop phenytoin

Phenytoin can induce a lupus-like syndrome, but this is much less common, and her anti-histone antibodies are negative.

B Start prednisolone 30 mg od

This lady does not have a lupus flare-up, because her CRP is elevated (indicating infection), lupus activity markers such as WCC and platelets are normal, and anti-dsDNA Abs are of low titre. SLE flare-ups may be associated with a raised ESR, normal CRP, cytopenia, rising anti-dsDNA titre and

This lady does not have a lupus flare-up, because her CRP is elevated (indicating infection), lupus activity markers such as WCC and platelets are normal, and anti-dsDNA Abs are of low titre. SLE flare-ups may be associated with a raised ESR, normal CRP, cytopenia, rising anti-dsDNA titre and falling complement.

D	Start ibuprofen 400 mg tds

We try to avoid NSAIDs as much as possible in SLE patients, to avoid any renal impairment.

E	Stop hydroxycholoroquine

Hydroxychloroquine does not suppress the immune system and therefore can be continued during active infection. Stopping it may increase the risk of an SLE flare-up.

8540

Rate this question:

A 66-year-old retired labourer presents to his general practitioner (GP) complaining of an acutely swollen and red ankle. The attack started the night before with swelling and pain, and despite taking various analgesics, the pain intensified. He is a known hypertensive and suffers from congestive cardiac failure and osteoarthritis. He had previous similar episodes a few years ago. His current medications include bendroflumethiazide, lisinopril and amlodipine.

On examination, the patient is apyrexial. There is a small, hard lump on his ear and he has a red, swollen and exquisitely painful right ankle, but he has full range of movement.

Based on this patient's history and clinical examination, what is the most likely diagnosis?

A	Septic arthritis
B	Reactive arthritis

On examination, the patient is apyrexial. There is a small, hard lump on his ear and he has a red, swollen and exquisitely painful right ankle, but he has full range of movement.

Based on this patient's history and clinical examination, what is the most likely diagnosis?

A	Septic arthritis
B	Reactive arthritis
C	Gout
D	Pseudo-gout
E	Fracture of the ankle

6799

Submit

osteoarthritis. He had previous similar episodes a few years ago. His current medications include bendroflumethiazide, lisinopril and amlodipine.

On examination, the patient is apyrexial. There is a small, hard lump on his ear and he has a red, swollen and exquisitely painful right ankle, but he has full range of movement.

Based on this patient's history and clinical examination, what is the most likely diagnosis?

Your answer was correct

A	Septic arthritis
B	Reactive arthritis
C	Gout
D	Pseudo-gout
E	Fracture of the ankle

C Gout

He has had previous episodes or attacks before and has risk factors for gout, e.g. diuretic use, and has a tophus on clinical examination. Given that he has tophaceous gout, he should be started on allopurinol, when the acute attack has settled. Losartan could be started, in place of one of the other antihypertensives, the former having uricosuric action. Gout and pseudo-gout are conditions caused by the accumulation of crystals in the joint space resulting in pain, redness and swelling in the affected joints. Both conditions are more prevalent in males, gout more markedly so, and usually affect patients in the age range 30–60 years. Gout is caused by the accumulation of monosodium urate monohydrate crystals, whilst pseudo-gout is caused by the accumulation of calcium pyrophosphate crystals. In gout, the first metatarsophalangeal joint of the big toe is the site most commonly affected (the condition is known as ‘podagra’), with other

commonly affected (the condition is known as 'podagra'), with other common sites being the ankle, wrist and knee. The condition results from overproduction or reduced secretion of uric acid, with thiazide diuretics and foods that are rich in purines increasing the frequency of attacks.

A	Septic arthritis

Septic arthritis should, however, always be considered in a mono-arthritis. Patients with crystal-induced arthritis may also present with fever and malaise, but he has no risk factors for septic arthritis such as recent penetrating injury or gonorrhoea, and the previous similar episodes suggest gout.

B	Reactive arthritis

There is no infective precipitant – gastrointestinal or genitourinary. Reactive arthritis is usually an oligoarthritis (2–4 joints affected).

gastrointestinal or genitourinary. Reactive arthritis is usually an oligoarthritis (2–4 joints affected).

D	Pseudo-gout

Although it is difficult to reliably distinguish gout and pseudo-gout on clinical grounds, a tendency exists for gout symptoms to develop rapidly over a few hours, whereas the onset of symptoms in pseudo-gout tends to be more insidious and may occur over a period of several days. The joints affected by pseudo-gout usually include the knee, wrist and shoulder.

E	Fracture of the ankle

A fracture without a history of trauma or injury and in the absence of osteoporosis is very unlikely.

6799

Rate this question:

A 63-year-old woman presents with a 5-year history of Raynaud's phenomenon affecting the fingers and, to a lesser extent, the toes. Recently this has become a lot worse, with attacks coming on unprovoked by temperature changes and lasting longer. She has noticed some swallowing difficulties and symptoms of acid reflux recently. Her fingers have become increasingly restricted over 5 years, but now they are more swollen and painful. She feels tired, with a recent onset of headaches and has lost 6 pounds in weight with loss of appetite.

Examination of the fingers reveals acrocyanosis of the digits with splinter haemorrhages in a warm examination room. Her blood pressure is 210/115 mmHg. The rest of the examination is unremarkable.

Which of the following is the most important initial investigation with respect to determining her outlook?

A	Double-stranded DNA

6 pounds in weight with loss of appetite.

Examination of the fingers reveals acrocyanosis of the digits with splinter haemorrhages in a warm examination room. Her blood pressure is 210/115 mmHg. The rest of the examination is unremarkable.

Which of the following is the most important initial investigation with respect to determining her outlook?

A	Double-stranded DNA antibodies
B	Liver function tests
C	Urea and electrolytes
D	Urine dipstick
E	Anti-neutrophil cytoplasmic antibodies

A 63-year-old woman presents with a 5-year history of Raynaud's phenomenon affecting the fingers and, to a lesser extent, the toes. Recently this has become a lot worse, with attacks coming on unprovoked by temperature changes and lasting longer. She has noticed some swallowing difficulties and symptoms of acid reflux recently. Her fingers have become increasingly restricted over 5 years, but now they are more swollen and painful. She feels tired, with a recent onset of headaches and has lost 6 pounds in weight with loss of appetite.

Examination of the fingers reveals acrocyanosis of the digits with splinter haemorrhages in a warm examination room. Her blood pressure is 210/115 mmHg. The rest of the examination is unremarkable.

Which of the following is the most important initial investigation with respect to determining her outlook?

Your answer was incorrect

D Urine dipstick

This lady's presentation is very suggestive of a connective tissue disease, with a recent acceleration and deterioration of severe progressive Raynaud's. The other features raise the possibility of scleroderma, but the diagnosis is secondary to determining the extent of vital organ involvement. The presence of splinter haemorrhages raises the likelihood of an immune complex vasculitis. The elevated blood pressure and headaches immediately raise the possibility of a renal component. Therefore her urine dipstick (the presence of blood and protein) and importantly her urine protein:creatinine ratio, to quantify the degree of proteinuria, are critical to determine renal involvement.

E Anti-neutrophil cytoplasmic antibodies

Although the presence of ANCA would give an indication of the diagnosis, it would not help to determine organ

give an indication of the diagnosis, it would not help to determine organ involvement and disease status.

A Double-stranded DNA antibodies

Although the presence of anti-dsDNA antibodies would give an indication of prognosis, it would not help to determine organ involvement and disease status.

B Liver function tests

Liver involvement is not particularly common in connective tissue diseases and therefore not as critical in determining renal involvement.

C Urea and electrolytes

Although increased creatinine level is a later stage, it signifies damage rather than 'involvement'. The first sign is the urine dipstick.

You make a diagnosis of rheumatoid arthritis (RA) in a 30-year-old woman. She has one 4-year-old son and informs you that she is interested in having another child. Her arthritis is very active, and she needs to have treatment started.

According to current guidelines, which one of the following agents would be the most appropriate choice?

A	Methotrexate
B	Leflunomide
C	Sulphasalazine
D	Azathioprine
E	Infliximab

C Sulphasalazine

None of the medications used in the treatment of arthritis is absolutely safe during pregnancy. Careful consideration of the risk–benefit ratio is needed, on an individual basis. Drugs that are definitely contra-indicated in pregnancy include NSAIDs (first trimester, due to risk of abortion) and methotrexate (teratogenicity). At present the recommended therapies are sulfasalazine and hydroxychloroquine, or azathioprine if the benefit–risk ratio is in favour of this. Sulfasalazine can be safely used prior to and during all stages of pregnancy. It is compatible with breastfeeding, though should be advised with caution because of the rare possibility that the mother is a slow acylator.

A Methotrexate

Methotrexate (MTX) is teratogenic and patients should not conceive while on

patients should not conceive while on MTX. Pregnancies should be planned, allowing MTX to be stopped and a wash-out period of 3–6 months before safe conception. Patients should take high-dose 5 mg daily folic acid prenatally and during pregnancy.

B	Leflunomide

Leflunomide is teratogenic and has a very long wash out period (up to 2 years). If a patient wishes to conceive, an accelerated washout may be achieved with activated charcoal or cholestyramine, and the leflunomide level can be measured post wash out to ensure it is below a safe limit to allow conception.

D	Azathioprine

Azathioprine can be safely used in pregnancy, however it is not very effective for the joints in rheumatoid arthritis, and therefore sulphasalazine is preferred. Women with severe rheumatic disease that is otherwise

rheumatic disease that is otherwise hard to control may use azathioprine during pregnancy. No apparent congenital malformations are known with doses up to 2 mg/kg/day. However in case series, the maternal use of azathioprine in pregnancy was associated with small-for-gestational-age infants, premature rupture of membranes, and intrauterine growth retardation.

E	Infliximab

No increase in pregnancy or birth complications has been shown with infliximab, etanercept or adalimumab. While data on newer biological treatments (including anti-tumour necrosis factor A inhibitors) is reassuring, so far no significant increased risk has been demonstrated and their use in pregnancy is not currently recommended.

33266

Rate this question:

A 67-year-old woman with long-standing erosive rheumatoid arthritis is referred by her general practitioner (GP) for further management. She has bilateral lower limb swelling and difficult to manage hypertension.

Current medication includes low dose corticosteroids, methotrexate, ramipril, aspirin and atorvastatin.

On examination, her blood pressure is 149/82 mmHg, pulse is 78 bpm regular. She has bilateral pitting oedema but her chest is clear. There is hepatomegaly on abdominal examination.

Investigations:

Hb	11.0 g/dl
WCC	7.8 × 10^9/l
PLT	190 × 10^9/l
Na^+	139 mmol/l

Na^+	139 mmol/l
K^+	4.9 mmol/l
Creatinine	199 µmol/l
Erythrocyte sedimentation rate (ESR)	44 mm/hr
Alanine aminotransferase (ALT)	54 U/l
Alkaline phosphatase	189 U/l
24-h urinary protein	3.1g

Which of the following is the most likely diagnosis?

A Systemic inflammatory amyloidosis

B Methotrexate toxicity

C Rheumatoid vasculitis

rate (ESR)	mm/hr
Alanine aminotransferase (ALT)	54 U/l
Alkaline phosphatase	189 U/l
24-h urinary protein	3.1g

Which of the following is the most likely diagnosis?

A	Systemic inflammatory amyloidosis
B	Methotrexate toxicity
C	Rheumatoid vasculitis
D	Minimal change disease
E	Systemic lupus erythematosus (SLE)

hepatomegaly on abdominal examination.

Investigations:

Hb	11.0 g/dl
WCC	7.8 × 10^9/l
PLT	190 × 10^9/l
Na^+	139 mmol/l
K^+	4.9 mmol/l
Creatinine	199 µmol/l
Erythrocyte sedimentation rate (ESR)	44 mm/hr
Alanine aminotransferase (ALT)	54 U/l
Alkaline phosphatase	189 U/l
24-h urinary protein	3.1g

A Systemic inflammatory amyloidosis

The hepatomegaly, heavy proteinuria with raised alkaline phosphatase is a strong indicator towards amyloid infiltration. Secondary inflammatory amyloidosis occurs due to increased circulating levels of serum amyloid A, which is an acute phase reactant. The raised ESR seen here is an indication of ongoing inflammation related to her rheumatoid disease. While colchicine is of value in reducing amyloid deposition in familial Mediterranean fever, there is no evidence it has a positive effect in amyloidosis related to underlying systemic inflammation. Treatment should focus on intensive control of the underlying cause; her rheumatoid disease.

B Methotrexate toxicity

Methotrexate toxicity can cause myelosuppression (but her FBC is fine) and hepatotoxicity (her ALT is only mildly elevated). It is not associated

mildly elevated). It is not associated with hepatomegaly or nephrotic syndrome. Rheumatoid arthritis drugs that may cause nephrotic syndrome include penicillamine and gold.

C	Rheumatoid vasculitis

Rheumatoid vasculitis very rarely affects the kidneys, but usually causes cutaneous (purpuric rashes) and neurological (mononeuritis multiplex) manifestations.

D	Minimal change disease

Although minimal change disease might explain her nephrotic syndrome, it would not explain hepatomegaly.

E	Systemic lupus erythematosus (SLE)

This lady has known rheumatoid arthritis and therefore is unlikely to then develop an entirely different

C	Rheumatoid vasculitis

Rheumatoid vasculitis very rarely affects the kidneys, but usually causes cutaneous (purpuric rashes) and neurological (mononeuritis multiplex) manifestations.

D	Minimal change disease

Although minimal change disease might explain her nephrotic syndrome, it would not explain hepatomegaly.

E	Systemic lupus erythematosus (SLE)

This lady has known rheumatoid arthritis and therefore is unlikely to then develop an entirely different disease later. The key to knowing that she did not have an arthritis as part of SLE that evolved later on, is the finding that she had erosions, which are strongly suggestive that the original diagnosis of rheumatoid arthritis was correct.

A 64-year-old man, who has a history of type 2 diabetes, ischaemic heart disease and atrial fibrillation, presents to the Emergency Room with acute gout.

Medication of note includes ramipril, furosemide, digoxin, atorvastatin and insulin. He is also warfarinised.

On examination, his blood pressure is 142/82 mmHg, his pulse is 78 bpm in atrial fibrillation. He has obvious gout affecting his right ankle.

Investigations:

Hb	11.0 g/dl
WCC	6.7 × 10^9/l
PLT	220 × 10^9/l
Na^+	138 mmol/l
K^+	4.9 mmol/l

K^+	4.9 mmol/l
Creatinine	185 µmol/l
Estimated glomerular filtration rate (eGFR)	20

Which of the following therapies for gout would be the best choice taking into account he is warfarinised, although it may not currently be licensed for all forms of acute gout?

A	Colchicine
B	Allopurinol
C	Prednisolone
D	Naproxen
E	Intrarticular steroid injection

E Intrarticular steroid injection

This is the best option, provided infection has been excluded, as a localised steroid injection into the affected joint will alleviate the symptoms from the acute attack and not upset the renal function or glycaemic control.

A Colchicine

There is some evidence that colchicine increases the INR and his eGFR is less than 30, therefore colchicine is ideally best avoided, if possible even at a 500 µg bd dosage.

B Allopurinol

Allopurinol should not be started in the acute attack of gout and can worsen the acute episode. Furthermore his renal function is very poor.

C Prednisolone

µg bd dosage.

B Allopurinol

Allopurinol should not be started in the acute attack of gout and can worsen the acute episode. Furthermore his renal function is very poor.

C Prednisolone

Although systemic steroids (prednisolone) will be effective and will not worsen his renal function directly, it might worsen his glucose control.

D Naproxen

NSAIDs should not be used with this degree of renal impairment.

21235

Rate this question:

A 50-year-old man presents with an acutely red, tender, left knee joint. He has a long history of hypertension, which has been well controlled over a number of years with bendroflumethiazide and amlodipine. There is no history of recent injury.

The pain has been severe for 2 days, and on examination, the joint is red, warm and tender. There is swelling and a small effusion. The knee joint is aspirated, and the aspirate sent to the lab for analysis.

Below is an image of the aspirate when examined under a microscope using polarised light.



By Bobjgalindo [GFDL (http://www.gnu.org/copyleft/fdl.html) or CC BY-SA 4.0 (https://creativecommons.org/licenses/by-sa/4.0)], from Wikimedia Commons

Investigations:

Haemoglobin (Hb)	14.0 g/dl
White cell count (WCC)	14.0×10^9/l
Platelets (PLT)	180×10^9/l
Sodium (Na^+)	145 mmol/l
Potassium (K^+)	3.2 mmol/l
Urea	6.0 mmol/l
Creatinine	100 µmol/l
C-reactive protein (CRP)	10×10^9/l
Erythrocyte sedimentation rate (ESR)	70 mm/h
Knee joint aspirate	White blood cells 2000/µl

C-reactive protein (CRP)	$10 \times 10^9/l$
Erythrocyte sedimentation rate (ESR)	70 mm/h
Knee joint aspirate	White blood cells 2000/μl

What is the most likely diagnosis?

A	Meniscus tear
B	Rheumatoid arthritis (RA)
C	Gout
D	Septic arthritis
E	Osteoarthritis (OA)

C Gout

This patient has risk factors for gout (middle-aged man, on a diuretic), and therefore, gout is the most likely explanation in this scenario. The low potassium level is consistent with the use of bendroflumethiazide, a drug that predisposes the patient to gout (but not pseudogout), and the inflammatory markers support this.

Bendroflumethiazide is not the first-line treatment for hypertension, but the National Institute for Health and Care Excellence guidelines recommend that patients who are already taking bendroflumethiazide with well-controlled hypertension continue this treatment.

Gout and pseudogout cannot be reliably distinguished on purely clinical grounds. The synovial fluid would be expected to show the presence of crystals. In gout, needle-shaped intracellular and extracellular crystals of monosodium urate appear. When examined with a polarising filter, these are yellow when aligned parallel to the

of monosodium urate appear. When examined with a polarising filter, these are yellow when aligned parallel to the axis of the red compensator, but they turn blue when aligned across the direction of polarisation (ie they exhibit negative birefringence), as seen in the image.

In pseudogout, calcium pyrophosphate (CPP) crystals appear, these being shorter and often rhomboidal. Under a polarising filter, CPP crystals do not change colour, according to their alignment relative to the direction of the red compensator.

In pseudogout, radiography may show chondrocalcinosis, which is useful in differentiating between the two conditions. However, of the five options provided, gout is the most likely diagnosis in this scenario.

A	Meniscus tear

A meniscal tear would cause a swollen, painful knee joint, but the patient would provide a history of recent

injury to the knee, with progressive increase in swelling over a few days. With more severe injury, the patient may experience locking of the knee. This patient has no history of knee injury, and a warm, red joint is not consistent with a meniscal tear.

B	Rheumatoid arthritis (RA)

RA is very unlikely to present as monoarthritis of the knee and is usually a small joint polyarthritis affecting the hands.

D	Septic arthritis

Whenever a patient has monoarthritis, the clinician should always consider joint sepsis, as it is very important not to miss this diagnosis. However, in this case, the relatively low number of pus cells is against a diagnosis of septic arthritis; most septic joints have a WCC of > 50 000/μl, with > 75% of polymorphonuclear leukocytes.

A 34-year-old woman is admitted via the Emergency Department after suffering acute lower back pain. X-ray in the department revealed two compression fractures suspicious of osteoporosis. Past medical history of note includes depression and anxiety.

On examination, her body mass index (BMI) is 16 kg/m^2 and her blood pressure is 125/72 mmHg, with a pulse of 55/min and regular.

Investigations:

Hb	11.2 g/dl
WCC	4.6 × 10^9/l
PLT	202 × 10^9/l
Na^+	139 mmol/l
K^+	4.5 mmol/l
Creatinine	102 μmol/l
Ca^{2+}	2.2 mmol/l
ALP	115 U/l
T-score	−3.1

Ca^{2+}	2.2 mmol/l
ALP	115 U/l
T-score	−3.1

Which of the following is likely to be the most important contributory factor to her condition?

A Low BMI leading to secondary ovarian failure

B Genetic predisposition to osteoporosis

C Hyperthyroidism

D Hypovitaminosis D

E Calcium deficiency

33289

Submit

A Low BMI leading to secondary ovarian failure

This patient has a very low BMI (and is slightly bradycardic), and further questioning may reveal that she is not currently menstruating and may not have been for some time. Given that she has significant life years ahead of her, gaining weight is the most appropriate option with respect to restarting ovulation and oestrogenisation. Given questions about the long-term efficacy of bisphosphonates, these would not be the best option here.

B Genetic predisposition to osteoporosis

Clearly a genetic predisposition to osteoporosis might also increase the risk of fracture at an early age, but BMI is almost certainly the greatest contributor to risk here.

C Hyperthyroidism

is almost certainly the greatest contributor to risk here.

C	Hyperthyroidism

Hyperthyroidism is another possibility, but we are given no information that she has symptoms or signs of this and indeed she is bradycardic, not tachycardic.

D	Hypovitaminosis D

Although a risk factor for demineralisation of bone, her biggest risk factor is low BMI.

E	Calcium deficiency

Her calcium is in the normal range.

33289

Rate this question:

Next Question

A 27-year-old woman comes to the Rheumatology Clinic for review. Over the past few months, she has developed a photosensitive rash, which is particularly prominent on her face, and small joint polyarthritis which is affecting her job as a data operator.

You note evidence of active arthritis affecting her fingers, wrists, both elbows, and her feet. Urine is positive for both blood and protein.

A picture of her face is shown below.

Which of the following is most likely to be positive?

A	Anti-CCP

Which of the following is most likely to be positive?

A	Anti-CCP
B	Anti-nuclear antibody
C	Anti-Scl 70
D	c-ANCA
E	p-ANCA

71642

Submit

B Anti-nuclear antibody

The rash seen here is suggestive of the erythematous changes seen in patients with active SLE, as is the evidence of arthritis and renal vasculitis. Anti-nuclear antibody testing has a sensitivity of 95% for SLE, but the titre is not closely related to disease activity. As such, other measures, such as complement testing, are more useful in assessing this.

A Anti-CCP

Anti-CCP antibodies are a marker of disease activity in rheumatoid arthritis. Although that may be a reasonable alternative diagnosis, the facial rash is a stronger pointer towards systemic lupus erythematosus (SLE) here.

C Anti-Scl 70

Scl 70 positivity is a marker of diffuse systemic sclerosis, which is not

suggested here because of the absence of other features such as sclerodactyly and peripheral calcinosis.

D	c-ANCA

c-ANCA positivity is most associated with granulomatosis with polyangiitis, in which pulmonary and renal vasculitis is seen, often with evidence of chronic sinusitis. There is no evidence of pulmonary vasculitis here.

E	p-ANCA

p-ANCA positivity is seen in around half of patients with eosinophilic granulomatosis with polyangiitis, which is usually associated with symptoms of poorly controlled asthma. It is also seen in patients suffering from primary sclerosing cholangitis.

71642

Rate this question:

A 54-year-old patient presents to the General Medical Clinic. He has a 6-month history of slowly worsening breathlessness and is finding it more difficult to carry out daily activities. He denies any chest pain but has an occasional cough, during which he brings up some sputum.

He is an ex-smoker with a 15 pack-year history. He has a minimal alcohol history. He travelled to the USAs last year. He has not been in contact with anyone with known tuberculosis. He has a long history of working as an electrician since he was 18 years old, but has lately struggled with his work due to breathlessness.

On examination, he has reduced air entry on the right lower lobe. There is also a slight general wheeze.

His hands are pictured below.

A chest X-ray demonstrates a small-to-moderate right-sided pleural effusion and evidence of multiple pleural plaques.

Which investigation is most appropriate to differentiate between benign and malignant disease?

A	Pleural biopsy
B	Pleural aspiration for cytology
C	Computed tomography (CT) chest with contrast
D	Liver function tests
E	Blood film

A Pleural biopsy

This patient has a long history of a profession associated with asbestos exposure and has developed breathlessness. In addition, there are pleural plaques which are highly suggestive of asbestos-related disease. The presence of a pleural effusion and clubbing raises the possibility of malignant mesothelioma.

B Pleural aspiration for cytology

Pleural aspiration can be done for this patient as he is symptomatic with a pleural effusion. However, the cytology from aspiration has a high rate of false-negative results. Therefore, it is important to send a large volume to be centrifuged to allow for a better yield. Because of this, the most definitive diagnosis is a biopsy which has a much lower rate of false-negative results.

C Computed tomography (CT)

C	Computed tomography (CT) chest with contrast

A CT will be helpful to delineate any masses, but it will still struggle to differentiate between a malignant and a benign lesion unless there is clear evidence of metastatic or invasive disease. This is unusual with mesotheliomas, and therefore a biopsy would be more appropriate. In addition, the patient is relatively young and should be able to tolerate a biopsy.

D	Liver function tests

Liver function tests can be useful and if severely deranged can indicate liver metastases; however, this is unusual for mesotheliomas and highly non-specific.

E	Blood film

A blood film would be unlikely to give any abnormal results. It would be far

A 32-year-old man presents to the Cardiology Clinic for review. He has been referred because he has had an echocardiogram showing aortic root dilatation.

He has had a history of lens dislocation and his father is known to have Marfan syndrome.

A photograph of his mouth is shown below.

He is concerned about the implications of the aortic root dilatation.

Which of the following treatments would slow the progression of aortic root dilatation?

A	Aspirin

below.

He is concerned about the implications of the aortic root dilatation.

Which of the following treatments would slow the progression of aortic root dilatation?

A	Aspirin
B	Atorvastatin
C	Azathioprine
D	Bisoprolol
E	Ramipril

A 32-year-old man presents to the Cardiology Clinic for review. He has been referred because he has had an echocardiogram showing aortic root dilatation.

He has had a history of lens dislocation and his father is known to have Marfan syndrome.

A photograph of his mouth is shown below.

He is concerned about the implications of the aortic root dilatation.

Which of the following treatments would slow the progression of aortic root dilatation?

Your answer was incorrect

D Bisoprolol

Beta blockers, such as bisoprolol, are a useful medication to slow the progression of aortic root dilatation. They slow the time to aortic root dilatation that is sufficient to need surgery by decreasing myocardial contractility and pulse pressure. Ultimately, annual echocardiograms are necessary to monitor for aortic root dilatation. When dilatation progresses to 4.5 cm, surgery can become necessary to prevent aortic dissection and rupture. Alternatives are angiotensin receptor blockers such as losartan.

E Ramipril

Ramipril is an angiotensin-converting enzyme (ACE) inhibitor and can be useful in controlling hypertension, which is an important aspect in preventing aortic root dilatation. However, this patient does not have hypertension and this treatment is not

hypertension and this treatment is not going to be helpful currently.

A Aspirin

Aspirin is an antiplatelet drug and will not affect the progression of aortic root dilatation. It would be useful in coronary artery disease and peripheral vascular disease.

B Atorvastatin

Atorvastatin is a statin and will not affect the progression of aortic root dilatation. It is useful to control elevated lipids and as secondary prevention in atherosclerotic disease.

C Azathioprine

Azathioprine is an immunomodulating drug and will not affect the progression of aortic root dilatation. It is useful as a steroid-sparing agent to control inflammatory conditions such as rheumatoid arthritis and

A 47-year-old personal assistant attends the outpatient clinic with a six-month history of malaise and joint pains. She has had to quit her job. She is also complaining of difficulty sleeping at night and urinary frequency. She complains of still being tired on waking up.

On examination, palpation of her muscles appears to cause pain in several different regions, especially around the shoulders and neck.

Investigations:

Hb	12.6 g/dl
WCC	4.0×10^9/l
PLT	198×10^9/l
Neutrophils	2.9×10^9/l
Lymphocytes	2.8×10^9/l
ESR	11 mm/1st h
CRP	2.0 mg/l
AST	28 IU/l
ALP	[illegible]

AST	28 IU/l
ALP	101 IU/l
ALT	25 IU/l
Anti-CCP	-
RF	-
ANA	-

What is the most likely diagnosis?

A Fibromyalgia

B Depression

C Rheumatoid arthritis

D Polymyalgia rheumatic

E Systemic lupus erythematosus

A Fibromyalgia

Fibromyalgia is said to occur in between 1 and 2% of the general population and has a female to male ratio of 9:1, presenting most often in the 30–50-year age group. It presents with musculoskeletal pain that often has multiple trigger points and may be poorly defined. The 1990 ACR classification criteria for FM include (1) the presence of widespread pain for more than 3 months and (2) pain, not just tenderness, that can be elicited by manual pressure of approximately 4 kg/cm^2 at 11 or more defined tender points. The number of painful tender points is correlated strongly with psychologic distress, not only in patients with FM but also in the general population. (These criteria are classification criteria for the selection of subjects for research studies, not diagnostic criteria.) At a clinical level, fibromyalgia is much more than widespread pain. Substantial overlap exists in major depressive disorder, various anxiety disorders and chronic

various anxiety disorders and chronic fatigue syndrome, and in multiple regional pain syndromes, such as headache, atypical chest pain (chest pain with normal cardiac evaluation findings), irritable bowel syndrome, chronic pelvic pain, temporomandibular joint pain (jaw pain with no underlying pathologic condition) and others.

The EULAR 2016 management guidelines suggested that initial management should involve patient education and focus on non-pharmacological therapies. In case of non-response, further therapies should be tailored to the specific needs of the individual and may involve psychological therapies (for mood disorders and unhelpful coping strategies), pharmacotherapy (for severe pain or sleep disturbance, such as tricyclic antidepressents) and/or a multi-modal rehabilitation programme, such as graded exercise programmes.

B	Depression

However, this lady may have depression as well as fibromyalgia; there is association and overlap.

C	Rheumatoid arthritis

The normal autoimmune screen and inflammatory markers make RA unlikely.

D	Polymyalgia rheumatic

This patient has a normal ESR. Patients with polymyalgia rheumatic usually have elevated inflammatory markers – ESR and CRP. Additionally she is slightly too young for PMR, which is very rare in patients under 50 years of age.

E	Systemic lupus erythematosus

The normal autoimmune screen and ESR make SLE very unlikely – 95% of patients with SLE have a positive ANA. This lady has a negative ANA.

8:39
tps://mypastest.pastest.com
10

ESR	35 mm/h
MCV	79 fl
ANA	+ at 1:160

MRI of both knees is suggestive of synovitis; echocardiogram is suggestive of pericarditis.

Which of the following is the most likely diagnosis?

A	Systemic lupus erythematosus (SLE)
B	Juvenile idiopathic arthritis
C	Rheumatoid arthritis
D	Sarcoidosis
E	Kawasaki disease

arthritis affecting his wrists, knees, ankles and some of his finger joints. He also has marked morning stiffness and a rash which affects his trunk and extremities. You understand from his mother that he has little interest in sport. You also notice a pericardial rub.

Investigations:

Hb	10.2 g/dl
WCC	5.6×10^9/l
PLT	145×10^9/l
Na^+	140 mmol/l
K^+	5.0 mmol/l
Creatinine	100 μmol/l
ESR	58 mm/h
MCV	79 fl
ANA	+ at 1:160

MRI of both knees is suggestive of synovitis; echocardiogram is suggestive of pericarditis.

Which of the following is the most

B Juvenile idiopathic arthritis

Whilst juvenile idiopathic arthritis (Still's disease) normally occurs in younger children, it may occasionally present in adolescents or young adults. Up to 25% of patients have a positive anti-nuclear antibody status. A microcytic anaemia, which tends to be resistant to iron replacement and pericarditis, is often found. Patients may also present with symptoms consistent with uveitis. Options for pharmacotherapy include NSAIDs, corticosteroids, methotrexate and anti-TNF biologicals.

A Systemic lupus erythematosus (SLE)

Multi-system rheumatologic disease may be distinguished from juvenile idiopathic arthritis (JIA) by clinical features and laboratory findings. SLE often presents in adolescence with fever, rash and non-erosive arthritis. The ANA is positive in SLE but also

fever, rash and non-erosive arthritis. The ANA is positive in SLE but also may be present in oligoarticular and polyarticular JIA. Both SLE and systemic-onset JIA may manifest as fever and serositis, but the skin findings are different. In addition, malar rash, nephritis, cytopenia, hypocomplementaemia and anti-double-stranded DNA and other autoantibodies are seen only in SLE.

C	Rheumatoid arthritis

A diagnosis of rheumatoid arthritis is reserved for adult patients, whereas this patient is an adolescent.

D	Sarcoidosis

Most of the reported cases of childhood sarcoidosis are accompanied by non-specific constitutional symptoms, such as fever, fatigue, malaise and weight loss, as well as symptoms from particular organs, such as the lungs, eyes, skin and lymph nodes. The joints tend not

D Sarcoidosis

Most of the reported cases of childhood sarcoidosis are accompanied by non-specific constitutional symptoms, such as fever, fatigue, malaise and weight loss, as well as symptoms from particular organs, such as the lungs, eyes, skin and lymph nodes. The joints tend not to be affected in children.

E Kawasaki disease

Kawasaki syndrome is a vasculitis in children, with prominent features including cervical lymphadenopathy and 'strawberry red' lips, palms and soles of feet. In some children coronary artery aneurysms may form.

33287

Rate this question:

Next Question

A 71-year-old man comes to the clinic with stiffness and limited range of movement of his right knee. He is overweight, with a body mass index (BMI) of 29, and has a history of osteoarthritis.

On examination, there is a transluminable swelling over the postero-medial aspect of the knee. Tenderness is most marked over the swelling, but extends to the upper part of the calf.

Which of the following investigations is most appropriate?

A	Knee ultrasound
B	Plain knee X-ray
C	D-dimer
D	Venogram
E	MRI of the knee

A 71-year-old man comes to the clinic with stiffness and limited range of movement of his right knee. He is overweight, with a body mass index (BMI) of 29, and has a history of osteoarthritis.

On examination, there is a transluminable swelling over the postero-medial aspect of the knee. Tenderness is most marked over the swelling, but extends to the upper part of the calf.

Which of the following investigations is most appropriate?

Your answer was correct

A	Knee ultrasound
B	Plain knee X-ray
C	D-dimer
D	Venogram

A Knee ultrasound

The picture here is more typical of that seen with a Baker's cyst, rather than with a DVT. The swelling is the result of synovial fluid distending the gastrocnemio-semimembranosus bursa, rather than being a true cyst. Whilst drainage may be attempted, recurrence is common and spontaneous resolution may itself occur over the course of 1–2 years. It can also be injected with steroids. Medical management in the meantime includes ice, NSAIDs and non-weight-bearing exercise. If the diagnosis is in doubt, MRI can be considered to confirm the origin of the cyst.

B Plain knee X-ray

A plain X-ray of his knee will probably show osteoarthritis, but the Baker's cyst will not be visible.

C D-dimer

This does not sound like a DVT, given that there is a transluminable mass in the popliteal fossa and the pain originates from behind the knee. D-dimer may be elevated due to knee injury.

D	Venogram

This does not sound like a DVT, given that there is a transluminable mass in the popliteal fossa. Venogram is only indicated if there are strong suspicions of a DVT after the ultrasound has taken place.

E	MRI of the knee

Although an MRI will confirm the diagnosis of a Baker's cyst, it is expensive and does not allow management (eg aspiration or injection), whereas an aspiration can be done under ultrasound guidance.

34967

Rate this question:

A 24-year-old woman presents with pain, swelling and stiffness in the small joints of her hands and wrists for 2 weeks.

On further questioning, she says she has been feeling more tired over the past 3 months and has given up her dance class because of aching joints in her feet. She has been previously fit and healthy. Her mother-in-law suffers from rheumatoid arthritis. She works as school teacher, smokes four cigarettes a day and drinks alcohol on occasions.

Which one of the following is the strongest risk factor for developing rheumatoid arthritis in this case?

A	Smoking
B	Alcohol
C	Exercise (dance classes)
D	Family history

has been feeling more tired over the past 3 months and has given up her dance class because of aching joints in her feet. She has been previously fit and healthy. Her mother-in-law suffers from rheumatoid arthritis. She works as school teacher, smokes four cigarettes a day and drinks alcohol on occasions.

Which one of the following is the strongest risk factor for developing rheumatoid arthritis in this case?

A	Smoking
B	Alcohol
C	Exercise (dance classes)
D	Family history
E	Occupation

has been feeling more tired over the past 3 months and has given up her dance class because of aching joints in her feet. She has been previously fit and healthy. Her mother-in-law suffers from rheumatoid arthritis. She works as school teacher, smokes four cigarettes a day and drinks alcohol on occasions.

Which one of the following is the strongest risk factor for developing rheumatoid arthritis in this case?

Your answer was correct

A	Smoking
B	Alcohol
C	Exercise (dance classes)
D	Family history
E	Occupation

A Smoking

This lady has rheumatoid arthritis (RA). RA commonly presents as a symmetrical arthritis affecting the small joints of the hands and wrists. Smoking is the strongest environmental risk factor for developing RA, especially in those that are anti- cyclic citrullinated peptide (CCP) positive. Smoking may contribute to citrullination (post-translational modification of arginine residues) in the lungs. This lady should be encouraged to stop smoking, which will help her joints, as well as her general health.

B Alcohol

Alcohol is not a risk factor for developing rheumatoid arthritis, and in fact may lower the risk.

C Exercise (dance classes)

developing rheumatoid arthritis, and in fact may lower the risk.

C	Exercise (dance classes)

Exercise is not a risk factor for rheumatoid arthritis. Overuse of a joint may increase the risk of osteoarthritis.

D	Family history

This lady's mother in law (not a blood relative) has rheumatoid arthritis, and therefore does not contribute to her genetic risk.

E	Occupation

There has been interest in occupational risk factors for rheumatoid arthritis, although nil conclusive identified. This patient as a teacher does not put her at an increased risk.

33267

Rate this question:

A 32-year-old Nigerian woman presents to the Dermatology Clinic with a 4-month history of facial rash. It started at the bridge of the nose and slowly spread to the face. She has just returned from Nigeria and the rash flared up while she was there. The rash is non-itchy and not painful. She has tried various cosmetic products, but none have worked. She also complained that her hair has started falling out. She has no past medical history and is not on any medication.

On examination, she has a well-defined erythematous scaly rash, with an area of scarring over the face, ear and scalp. She has patchy hair loss over her scalp. Other examinations are completely normal.

Investigations reveal:

Hb	13.6 g/dl
WCC	5×10^9/l
PLT	150×10^9/l
Erythrocyte	50

Investigations reveal:

Hb	13.6 g/dl
WCC	5×10^9/l
PLT	150×10^9/l
Erythrocyte sedimentation rate (ESR)	50 mm/h
Na^+	136 mmol/l
Creatinine	98 µmol/l
Calcium	2.28 mmol/l
Anti-ds DNA	Not detected
Antinuclear antigen	Not detected

What the most likely diagnosis?

A Lupus pernio

	µmol/l
Calcium	2.28 mmol/l
Anti-ds DNA	Not detected
Antinuclear antigen	Not detected

What the most likely diagnosis?

A	Lupus pernio
B	Dermatomyositis
C	Discoid lupus
D	Morphoea
E	Systemic lupus erythematosus (SLE)

C Discoid lupus

This lady has a scaly rash localised to her face with scarring alopecia, with no systemic manifestations and negative antinuclear antigen and anti-dsDNA. Discoid lupus primarily affects the skin and is characterised by a well-demarcated macular rash with erythema, scales, plaques and atrophy. It is a variant of SLE, in which skin involvement is the main feature. It is more common in African–Caribbean women. Photosensitivity is a feature as well as scarring alopecia of the scalp. Very rarely patients may develop systemic features, but these are usually mild. Diagnosis is made by biopsy of the lesion.

A Lupus pernio

Lupus pernio is a cutaneous form of sarcoidosis with dusky-purple infiltration of the nose.

sarcoidosis with dusky-purple infiltration of the nose.

B	Dermatomyositis

The facial rash of dermatomyositis is around the eyelids.

D	Morphoea

Morphoea is a localised form of scleroderma, characterised by dermal sclerosis with pigmentation. The skin appears thickened, rather than scaly.

E	Systemic lupus erythematosus (SLE)

This lady has a scaly rash localised to her face with scarring alopecia, with no systemic manifestations and negative antinuclear antigen and anti-dsDNA, making systemic lupus very unlikely.

9527

Rate this question:

A woman who was given a diagnosis of systemic sclerosis 4 years ago presents for review. She has been suffering significantly increased shortness of breath over the past few months. Respiratory function testing reveals evidence of pulmonary fibrosis, and echocardiography suggests elevated right heart pressures. You arrange for iloprost infusion treatment.

Which one of the following pharmacological interventions is most likely to provide additional benefit in reducing pulmonary artery pressure?

A	Ramipril
B	Amlodipine
C	Atenolol
D	Sildenafil
E	Prednisolone

D Sildenafil

Sildenafil has positive effects in reducing pulmonary arterial pressure. Ghofrani published evidence (in *Annals of Internal Medicine*) in 2002 from a study in 30 patients with pulmonary hypertension; six of these patients had evidence of systemic sclerosis. Severe pulmonary hypertension was defined as pulmonary artery pressure >40 mmHg. Patients were randomised to receive between 12.5 and 50 mg of sildenafil in addition to iloprost infusion. The study showed a dose-dependent benefit of sildenafil on pulmonary artery pressure. Unfortunately, pulmonary hypertension is still a significant contributor to mortality in systemic sclerosis.

A Ramipril

Although blood pressure control may reduce pulmonary artery pressure to a small degree, sildenafil is the best fit here. ACE inhibitors are the treatment

here. ACE inhibitors are the treatment of choice for renal disease associated with systemic sclerosis, in which the ACE inhibitor may halt or even reverse the decline in renal function in certain cases.

B	Amlodipine

Although blood pressure control may reduce pulmonary artery pressure by a small degree, sildenafil is the best fit here, and calcium channel blockers are not usually indicated for patients with pulmonary hypertension associated with systemic sclerosis. A small proportion of patients may benefit from a reduction in pulmonary blood pressure associated with their use, and this is indicated by acute vasoreactivity testing. Calcium channel blockers are useful in the non-urgent management of Raynaud's phenomenon that does not respond adequately to general measures, and therefore many patients with systemic sclerosis may be prescribed amlodipine for this reason.

C	Atenolol

Although blood pressure control may reduce pulmonary artery pressure by a small degree, sildenafil is the best fit here. Beta blockers are best avoided in patients with systemic sclerosis, as non-cardioselective beta blockers (and cardioselective beta blockers to a certain extent) may cause peripheral vasoconstriction and worsen the symptoms of Raynaud's.

E	Prednisolone

Steroids do not improve pulmonary artery pressure and are a risk factor for scleroderma renal crisis, and should therefore be used sparingly in patients with scleroderma. High-dose steroids may, however, be useful in patients with pleurisy, pericarditis or other severe systemic manifestations of systemic sclerosis.

6412

Rate this question:

A 63-year-old man presents with a 4-week history of painful wrists. He has smoked 60 cigarettes a day for many years. He complains of mild swelling of his hands without stiffness, predominantly affecting the phalanges and the distal end of the radius and ulna.

Examination shows tenderness just proximal to the joints without limitation of movement.

A picture of his fingers is shown below.

What would be the most likely radiological appearance?

What would be the most likely radiological appearance?

A	Periosteitis over the ulna and radius
B	Irregular bone lysis
C	Chondrocalcinosis
D	Pannus formation
E	Narrowing of the joint space

A 63-year-old man presents with a 4-week history of painful wrists. He has smoked 60 cigarettes a day for many years. He complains of mild swelling of his hands without stiffness, predominantly affecting the phalanges and the distal end of the radius and ulna.

Examination shows tenderness just proximal to the joints without limitation of movement.

A picture of his fingers is shown below.

What would be the most likely radiological appearance?

A Periosteitis over the ulna and radius

This man likely has hypertrophic pulmonary osteoathropathy (HPOA), probably caused by non-small cell lung cancer – he is a smoker and has clubbing. HPOA usually affects the wrists and/or ankles and is a paraneoplastic phenomenon characterised by periosteal reaction.

B Irregular bone lysis

Lytic lesions have a wide differential, including metastases and infection. They are very rarely found on hand (or foot) X-rays, and this is unlikely in this scenario.

C Chondrocalcinosis

Chondrocalcinosis is seen in pseudo-gout. Pseudo-gout, resulting from the formation of calcium pyrophosphate crystals and deposition into the synovial fluid, most commonly affects

be affected including the wrists, shoulders and elbows. The patient may present with warm, swollen joint or joints and acute onset. This would not be consistent with the history or examination findings in this scenario.

D	Pannus formation

Pannus is seen during fracture healing.

E	Narrowing of the joint space

In HPOA the joint space is usually unaffected. Joint space narrowing can be seen in conditions such as rheumatoid arthritis or osteoarthritis.

The presence of clubbing and tender wrists without synovitis makes pulmonary osteoarthropathy the most likely diagnosis. It is usually associated with underlying carcinoma of the lung. Regression of the pain has been reported with successful resection of the tumour and after vagotomy.

A 15-year-old boy presents with a 4-month history of fever, lethargy and a generalised macular rash, which comes and goes. Before the episode, he was well. He had no previous medical history or recent illness and there was no recent travel abroad.

On examination, temperature was 38.5 °C, blood pressure 125/75 mmHg, pulse of 100 bpm. The chest was clear and there were no heart murmurs on auscultation. A widespread non-blanching macular rash is seen over the chest and abdomen. There is swelling of the interphalangeal joints of both hands and feet with slight tenderness. Lymph nodes are palpable on the supraclavicular, axillary and inguinal regions.

Examination of the abdomen also reveals a palpable mass on both right and left hypochondrium.

Investigations reveal:

Hb	13.5 g/dl
WCC	14.0 × 10^9/l

investigations reveal:

Hb	13.5 g/dl
WCC	14.0 × 10^9/l
PLT	380 × 10^9/l
Na^+	145 mmol/l
K^+	4.8 mmol/l
Creatinine	89 μmol/l
Rheumatoid factor	Negative
Antinuclear antibody (ANA)	Negative
Anti-dsDNA	Negative
Anti-streptolysin O (ASO) titre	Not detected
Electrocardiogram (ECG)	Sinus rhythm

What is the most likely underlying diagnosis from the choices listed

(ANA)	
Anti-dsDNA	Negative
Anti-streptolysin O (ASO) titre	Not detected
Electrocardiogram (ECG)	Sinus rhythm

What is the most likely underlying diagnosis from the choices listed below?

A	Acute rheumatic fever
B	Juvenile systemic lupus erythematosus
C	Pauciarticular Still's disease
D	Reiter's syndrome
E	Systemic Still's disease

E Systemic Still's disease

Systemic Still's disease and other forms of juvenile rheumatoid arthritis (JRA) usually begin before the age of 16 years. There are different types of JRA with different presenting features. Systemic Still's is characterised by systemic features, high fever, rashes, generalised lymphadenopathy and splenomegaly with minor features of arthritis. Systemic features may precede the onset of arthritis. Rheumatoid factor and antinuclear antibodies are absent.

B Juvenile systemic lupus erythematosus

The antinuclear antibody is negative and there are significant systemic features (high fevers).

A Acute rheumatic fever

The history is too long, the ASO titre is

features (high fevers).

A	Acute rheumatic fever

The history is too long, the ASO titre is negative and there are no features of carditis with a normal ECG and PR interval.

C	Pauciarticular Still's disease

In pauciarticular Still's disease, antinuclear antibodies are present. Large joints are affected and most patients develop classic features of seronegative spondyloarthritis.

D	Reiter's syndrome

The history is too long, there is no infective precipitant and the generalised lymphadenopathy and splenomegaly does not fit with reactive arthritis.

9523

Rate this question:

A 30-year-old African woman complains that she is unable to completely straighten her right ankle and has difficulty walking. Her husband was a lorry driver in southern Africa who died of HIV, and she is visiting her sister in England. She is unable to indicate the onset of the ankle problems, and she does not remember injuring the joint. She is experiencing difficulty in walking.

Examination reveals a grossly deformed right ankle. There is gross bony swelling around the ankle but no tenderness; crepitus is felt on passive movement of the joint.

Investigations:

Hb	11.7 g/dl
WCC	4.8×10^9/l
PLT	188×10^9/l
Neutrophils	2.1×10^9/l
Lymphocytes	1.8×10^9/l
ESR	17 mm/1st h

ESR	17 mm/1st h
CRP	8.0 mg/l
AST	28 IU/l
ALP	101 IU/l
ALT	15 IU/l
Glucose	5.5 mmol/l

What is the most likely diagnosis?

Your answer was correct

A Septic arthritis

B Osteoarthritis

C Rheumatoid arthritis (RA)

D Charcot's (neuropathic) joint

E Pyrophosphate arthropathy

D Charcot's (neuropathic) joint

Individuals lacking sensation in a joint are predisposed to developing severe damage to that joint. Diagnosis is suggested by severe joint destruction with minimal symptoms and surprisingly normal joint movements. First described in 1868 by Charcot in a patient with syphilis, but also seen in syringomyelia, diabetic neuropathy, spinal cord and peripheral nerve injury, leprosy, multiple sclerosis and meningomyelocoele. Tabes dorsalis affects large joints of the lower extremities, whereas syringomyelia affects large joints of the upper extremities and diabetes affects the foot. The suspicion here is of chronic syphilis infection.

A Septic arthritis

Septic arthritis is usually characterised by sudden-onset pain and does not cause joint deformity. She has no tenderness at the ankle. A septic

existing deformity, but the normal white cell count, CRP and ESR go against this diagnosis.

B	Osteoarthritis

OA does not cause such significant bony deformity – it is a painful, degenerative arthritis.

C	Rheumatoid arthritis (RA)

RA is very unlikely to be asymmetrical, and joints are tender on palpation.

E	Pyrophosphate arthropathy

Pseudo-gout does not cause joint deformity. Pseudo-gout is caused by calcium pyrophosphate crystal deposition in the affected joint space. The onset of symptoms in pseudo-gout tends to occur over a period of several days and is more common in the older population. The joints usually affected by pseudogout include the knee, wrist and shoulder.

B Relapsing polychondritis

This lady has inflammation of the outer ear, nasal septum and relapsing remitting arthralgia/arthritis consistent with relapsing polychondritis. Relapsing polychondritis is a disorder that affects, cartilaginous and connective tissues causing episodic inflammation and destruction. Onset is typically in middle age and it occurs in equal frequency in men and women. The most common symptom is inflammation of the external ear and nasal cartilage. It is often associated with arthritis involving both small and large joints. Characteristic of the disease are bouts of inflammation that heal over weeks. Recurrent inflammation results in destruction of cartilaginous tissue resulting in floppy ears and a saddle nose. Biopsy of affected cartilaginous tissue will confirm the diagnosis.

A Wegener's granulomatosis

A Wegener's granulomatosis

This lady has outer ear inflammation, ie of the cartilaginous pinna, and relapsing arthritis which are key differentiators from Wegener's granulomatosis (granulomatosis with polyangiitis). Although we are not given an ANCA result (expecting a cANCA with Wegener's), the renal function is normal and urine dipstick is inactive.

C Mixed connective tissue disorder

The ANA is negative and she has no features of connective tissue disease.

D Systemic sclerosis

In systemic sclerosis, ear and nose involvement is not common and Raynaud's is almost universal.

E Polymyalgia rheumatica

You review a 42-year-old woman who is referred to the Rheumatology Clinic because blood tests have shown a positive CCP antibody at > 200. Her rheumatoid factor is negative. She denies any joint pains or stiffness and examination is normal, with no evidence of synovitis. The blood test was performed as part of a health check.

Her great-grandmother had rheumatoid arthritis with significant deformities at a time that unfortunately biological therapy was not available. She smokes 30 cigarettes per day.

Investigations:

Hb	13.7 g/dl
WCC	4.8×10^9/l
PLT	188×10^9/l
Neutrophils	2.1×10^9/l
Lymphocytes	1.8×10^9/l
ESR	10 mm/1st h

ESR	10 mm/1st h
CRP	2 mg/l
AST	28 IU/l
ALP	101 IU/l
ALT	15 IU/l
Glucose	5.5 mmol/l
Anti-CCP	2 > 200
RF	-
ANA	-

What is the best management plan?

A	Start methotrexate
B	Advise her to stop smoking
C	Start hydroxychloroquine
D	Nothing: reassure and discharge her from clinic

B Advise her to stop smoking

There is evidence that stopping smoking and delaying the onset of the development of arthritis in patients at risk of developing RA (such as this lady, with positive anti-CCP antibodies) can ameliorate the prognosis of patients in whom arthritic symptoms have already developed (e.g. reduce the burden of joint damage).

A Start methotrexate

This lady has anti-CCP antibodies and a family history of rheumatoid arthritis. She does have a higher risk of developing rheumatoid arthritis, although she does not have any synovitis currently and therefore the benefits of starting methotrexate do not outweigh the risk.

C Start hydroxychloroquine

Although hydroxychloroquine is the

there is no evidence that patients at risk of developing RA (asymptomatic, anti-CCP positive) have any better prognosis when treated before symptoms develop.

D	Nothing: reassure and discharge her from clinic

This lady is asymptomatic and could be discharged from the clinic. However, she should be informed about the effects of smoking on her joints, advised to stop smoking and to seek medical advice if she develops any symptoms of joint pains, stiffness, swelling etc.

E	Work her up for anti-TNF

This lady does not fulfil criteria for a diagnosis of RA, and is certainly not eligible for biologic therapy. There is no evidence that starting therapy before the onset of symptoms changes the prognosis or course of disease.

A 30-year-old woman complains of pain in the right ankle that she has experienced for the past 3 weeks. Two or three days later, she notices that the ankle is also swollen. A week later, this is followed by pain and swelling in both knees. Her general practitioner (GP) started diclofenac 50 mg three times daily, which alleviated the pain to some extent.

She further remembers having loose bowel movements for a few days about 10 days prior to the onset of joint symptoms. She informs you that she sometimes develops loose bowel movements after eating a takeaway.

Medications other than non-steroidal anti-inflammatory drugs (NSAIDs) include paracetamol, which she takes for intermittent backache, and salbutamol and beclomethasone inhalers, for bronchial asthma.

Investigations:

Hb	13.7 g/dl
WCC	$4.8 \times 10^9/l$

inhalers, for bronchial asthma.

Investigations:

Hb	13.7 g/dl
WCC	4.8×10^9/l
PLT	188×10^9/l
Neutrophils	2.1×10^9/l
Lymphocytes	1.8×10^9/l
ESR	18 mm/1st h
CRP	21 mg/l
AST	28 IU/l
ALP	101 IU/l
ALT	15 IU/l
Glucose	5.5 mmol/l

What is the most likely diagnosis?

A	Ankylosing spondylitis (AS)
B	Reactive arthritis

ESR	18 mm/1st h
CRP	21 mg/l
AST	28 IU/l
ALP	101 IU/l
ALT	15 IU/l
Glucose	5.5 mmol/l

What is the most likely diagnosis?

A Ankylosing spondylitis (AS)

B Reactive arthritis

C Septic arthritis

D Gout

E Still's disease

6877

Submit

B Reactive arthritis

This lady has an oligoarthritis following a likely gastrointestinal infection. Asymmetrical arthritis, predominantly involving large joints in lower extremities, is suggestive of the seronegative spondyloarthropathy type of arthritis. Reactive arthritis is most likely with the preceding history of diarrhoea. Her inflammatory markers are modestly elevated. Reactive arthritis is aseptic inflammatory arthritis, usually triggered by chlamydial urethritis or cervicitis or enteric infection with *Salmonella*, *Shigella*, *Campylobacter* or *Yersinia* in a genetically susceptible individual. HLA B27 is the major currently known genetic risk factor. The arthritis usually resolves in 3 months but can recur or become chronic.

A Ankylosing spondylitis (AS)

There is a clear infective precipitant and although she has back pain, we are not given any features of

C Septic arthritis

She has an oligoarthritis following a diarrhoeal illness. Septic arthritis may be a polyarthritis in 10% of cases, but usually patients are far more sick (with signs of systemic sepsis) with red, hot swollen joints and can barely move these affected joints. Blood results are not overtly helpful for differentiating causes here, but one might expect a higher CRP and white cell count with septic arthritis. NB: Gonococcal septic arthritides are usually associated with a pustular skin rash and red, linear areas of tenosynovitis.

D Gout

This lady has a spreading oligoarthritis following a diarrheal episode. Gout is usually a sudden-onset, exquisitely painful arthritis. This young female patient does not have any risk factors for gout either.

E Still's disease

You have been asked to review a 56-year-old woman who has been admitted with a history of feeling unwell for the past 2 months.

On further questioning, she admits having discoloration of the fingers and hands, loss of appetite and weight, joint pains and difficulty in mobilising.

On examination, you notice a rash affecting the hands and face hands (as shown below), tenderness over the wrists and knees, crackles over both lung bases and generalised muscle weakness.

Results of investigations are awaited.

What are the underlying features on examination of this patient's hands?

A Raynaud's phenomenon

Results of investigations are awaited.

What are the underlying features on examination of this patient's hands?

A	Raynaud's phenomenon
B	Tinea infection
C	Contact dermatitis
D	Gottron's papules
E	Scabies

6893

Submit

D	Gottron's papules

This patient has muscle weakness, Gottron's papules and likely heliotrope facial rash, polyarthralgia and Raynaud's.

The image above shows the typical appearance of dermatomyositis, with thickened patches on the dorsal surface of the knuckles. The above clinical picture with findings of Gottron's papules is suggestive of dermatomyositis (skin plus muscle involvement), rather than polymyositis – polymyositis does not have any skin features. Heliotrope rash (periorbital lilac-coloured rash) is the characteristic facial rash of dermatomyositis – the word is derived from the name of a flower. It is recommended that all adult patients with dermatomyositis should be screened for underlying malignancy.

A	Raynaud's phenomenon

Although she has symptoms of

A Raynaud's phenomenon

Although she has symptoms of Raynaud's phenomenon, this is not a cause of the features in the image.

B Tinea infection

Tinea is a fungal infection.

C Contact dermatitis

These features are characteristic of Gottron's papules.

E Scabies

These features are characteristic of Gottron's papules. Scabies is intensely itchy, and therefore, one may see excoriation marks and wheals where the scabies mites have burrowed under the skin, especially in the spaces between the fingers.

You are asked by the obstetricians to review a 28-year-old woman who has had three previous miscarriages. Each of her miscarriages occurred at around the 14th week of pregnancy. Blood testing showed positive antiphospholipid antibodies.

Further questioning into her medical history revealed a history of venous thrombosis after a plane flight. She is 8 weeks' pregnant. She is commenced on low-dose aspirin.

Which further intervention would you implement?

A	Warfarin therapy
B	Subcutaneous low-molecular-weight heparin daily
C	Prednisolone 40 mg daily
D	Azathioprine therapy
E	IV immunoglobulin therapy

B	Subcutaneous low-molecular-weight heparin daily

This patient has evidence of the antiphospholipid syndrome (APLS). This is characterised by recurrent miscarriage with three unexplained mid-trimester fetal losses and a venous thrombosis, albeit somewhat 'provoked'. She likely has antiphospholipid antibodies. Standard therapy where there is recurrent miscarriage and a diagnosis of APLS is low-molecular-weight heparin and low-dose aspirin during pregnancy and approximately 6 weeks postpartum, which is also a prothrombotic state. APLS is thought to be the cause of complications in around 45/100 000 pregnancies.

A	Warfarin therapy

Warfarin is teratogenic and contra-indicated in pregnancy, particularly in the first and third trimesters. Outside pregnancy, antiphospholipid antibody

pregnancy, antiphospholipid antibody syndrome, patients with a history of thrombosis are usually managed with warfarin therapy.

C	Prednisolone 40 mg daily

There is no indication for prednisolone, unless there are features of catastrophic antiphospholipid syndrome (multi-organ involvement), which this lady does not have.

D	Azathioprine therapy

There is no indication for immunosuppression with azathioprine. She needs vascular prophylaxis and anticoagulation.

E	IV immunoglobulin therapy

There is no indication for immunomodulation with IV immunoglobulin therapy. She needs vascular prophylaxis and anticoagulation.

A 44-year-old man presents with gout. He has a history of obesity, type 2 diabetes, a previous myocardial infarction some 4 years earlier and subsequent ischaemic cardiomyopathy. He also has congestive heart failure which is managed with ramipril and furosemide.

On examination, his blood pressure is 135/80 mmHg, his pulse is 78 bpm and regular. He has mild bibasal crackles and bilateral pitting oedema of both ankles, and gout affecting his right great toe.

Investigations:

Hb	11.5 g/dl
WCC	4.5×10^9/l
PLT	190×10^9/l
Na^+	139 mmol/l
K^+	4.5 mmol/l
Creatinine	130 μmol/l
Urate	0.64 mmol/l (0.23-0.46)

PLT	190×10^9/l
Na^+	139 mmol/l
K^+	4.5 mmol/l
Creatinine	130 μmol/l
Urate	0.64 mmol/l (0.23-0.46)

Which of the following is the most appropriate treatment for his acute gout?

A Rasburicase

B Ibuprofen

C Colchicine

D Allopurinol

E Prednisolone

C Colchicine

Colchicine is the best fit here, and could be used at a lower 'renal' dose of 500 µg bd.

A Rasburicase

While rasburicase accelerates the metabolism of uric acid and is useful in preventing and treating hyperuricaemia associated with tumour lysis syndrome, it is not currently licensed for the treatment of acute gout associated with other conditions.

B Ibuprofen

Ibuprofen is appropriate for the majority of patients with acute gout, but it may precipitate sodium and water retention and as such is not appropriate in this case, and could worsen creatinine.

conditions.

B Ibuprofen

Ibuprofen is appropriate for the majority of patients with acute gout, but it may precipitate sodium and water retention and as such is not appropriate in this case, and could worsen creatinine.

D Allopurinol

Allopurinol may worsen the acute attack.

E Prednisolone

Prednisolone is also responsible for sodium and water retention and may worsen his glucose control.

21505

Rate this question:

Next Question

A 34-year-old sales representative presents with severe pain going down her neck and right arm. She admits that this pain is worse on sitting in her car while driving for long periods. Past history includes two previous road traffic accidents, but nil else of note.

On examination, there is weakness and sensory loss over a C5/C6 nerve distribution and pain with neck movement, particularly extension. An MRI of the spinal cord is arranged.

Which other investigation would be most useful in this case?

A	Nerve conduction studies
B	Myelogram
C	Autoimmune profile
D	Arthroscopy of the right shoulder
E	Plain X-rays of the right elbow

traffic accidents, but nil else of note.

On examination, there is weakness and sensory loss over a C5/C6 nerve distribution and pain with neck movement, particularly extension. An MRI of the spinal cord is arranged.

Which other investigation would be most useful in this case?

Your answer was correct

A	Nerve conduction studies
B	Myelogram
C	Autoimmune profile
D	Arthroscopy of the right shoulder
E	Plain X-rays of the right elbow

Explanation

A Nerve conduction studies

This patient has symptoms of cervical radiculopathy, resulting from disc degeneration due either to herniation or degenerative change (spondylosis). When there are posterior osteophytes leading to anterior spinal cord compression, as is likely here, patients present with chronic radicular arm pain, numbness and tingling sensations. The investigation of choice is magnetic resonance imaging (MRI) scanning to assess spinal cord encroachment, and nerve conduction studies to assess the degree of nerve damage. Treatment is with physiotherapy and non-steroidal anti-inflammatory agents. Patients will usually improve with time, and surgical intervention is needed in less than 5% of patients.

B Myelogram

Myelography uses a real-time form of X-ray called fluoroscopy and an

X-ray called fluoroscopy and an injection of contrast material to evaluate the spinal cord, nerve roots and spinal lining (meninges). It is particularly useful for assessing the spine following surgery, and also for assessing disc abnormalities in patients who cannot undergo MRI. A myelogram is not appropriate here as it is invasive and expensive, and there are no contraindications to an MRI in this case.

C	Autoimmune profile

This lady has a likely mechanical problem, with no features to suggest an autoimmune/inflammatory cause.

D	Arthroscopy of the right shoulder

This lady has a cervical radiculopathy, i.e. nerves emanating from the cervical spine, and therefore a shoulder arthroscopy is unlikely to help.

A-40-year old man presents to the Emergency Department with digital ulceration and areas of gangrene affecting the fingers and toes. The problem started a few months back with insidious tingling, numbness and discoloration of his fingers associated with pain.

Gradually, the symptoms progressed with more severe discoloration and the appearance of ulcers on the tip of his fingers associated with a constant burning sensation. He noticed that on walking he would experience severe pain in the instep of his foot and the calves. There is no history of angina or exertional dyspnoea. He is a heavy smoker, but has no medical history.

Examination revealed cold hands and feet with extensive cyanosis, ulceration and gangrene of the fingers and toes. There are absent pulses in the radial, dorsalis pedis and posterior tibia arteries.

Investigations revealed:

Hb	12.6 g/dl

There are absent pulses in the radial, dorsalis pedis and posterior tibia arteries.

Investigations revealed:

Hb	12.6 g/dl
WCC	12×10^9/l
PLT	240×10^9/l
Na^+	135 mmol/l
Creatinine	80 µmol/l
Erythrocyte sedimentation rate (ESR)	20 mm/h
Rheumatoid factor	Negative
Antinuclear antibody	Absent

What is the underlying diagnosis?

A	Takayasu's arteritis
B	Disseminated atherosclerosis

Na^+	135 mmol/l
Creatinine	80 µmol/l
Erythrocyte sedimentation rate (ESR)	20 mm/h
Rheumatoid factor	Negative
Antinuclear antibody	Absent

What is the underlying diagnosis?

A Takayasu's arteritis

B Disseminated atherosclerosis

C Systemic sclerosis

D Buerger's disease

E Acrocyanosis

D Buerger's disease

This heavy smoker has critical digital ischaemia with absent pulses and negative autoantibodies. Thrombangiitis obliterans (Buerger's disease) is a disease of small and medium-sized arteries and veins resulting in inflammation and ulceration. There is no excessive atheroma and it does not involve the coronary arteries like atherosclerosis. The disease occurs mainly in cigarette smokers. The patient presents with symptoms of arterial ischaemia. Migratory phlebitis in the superficial vein is present in 40% of cases. The disease progresses proximally, resulting in gangrene of the digits. Diagnosis is usually clinical. Arteriogram is also of benefit and will show occlusion of distal arteries of the hands and feet. Treatment is supportive and patients should stop smoking.

A Takayasu's arteritis

There is no constitutional upset, or signs of large vessel and aortic involvement, inflammatory markers are normal and Takayasu's usually occurs in females.

B Disseminated atherosclerosis

There is no history of angina or exertional dyspnoea.

C Systemic sclerosis

The patient has negative autoantibodies and has no other features of systemic sclerosis.

E Acrocyanosis

Acrocyanosis is persistent blue or cyanotic discoloration of the extremities, most commonly occurring in the hands, although it also occurs in the feet and distal parts of face. Acrocyanosis is not painful, nor is it associated with digital ulceration.

C Immobilisation in a plaster cast

This patient has Charcot arthropathy, the clue being that he is not in any pain (it is an anaesthetic joint), the foot is grossly deformed and he likely has underlying type 2 diabetes, indicated by the prescription of gliclazide. Immobilisation in a cast for 3–6 months is the treatment of choice; this is thought to be complemented by use of bisphosphonates: the reduction in bone reabsorption associated with bisphosphonates is thought to accelerate healing. Good control of blood glucose to reduce the risk of microvascular complications is associated with a decreased incidence in Charcot arthropathy, although once established it cannot be reversed.

E Ibuprofen 400 mg po tds

A Charcot joint is anaesthetic and therefore not painful, as given to you in the question, and therefore neither analgesia nor anti-inflammatories is

analgesia nor anti-inflammatories is indicated.

A Calcium and vitamin D

Although one facet of treatment is to ensure he is vitamin D replete, the most important part of managing a Charcot joint is to immobilise it and allow healing.

B IV Flucloxacillin

While the joint is hot and swollen, the normal C-reactive protein and white blood cell count make it unlikely that this is due to osteomyelitis, and therefore antibiotics are not indicated.

D Surgical drainage

Although the joint appears 'swollen', it is actually grossly deformed due to underlying bone and the CRP is normal, making infection very unlikely, and there is no effusion to drain.

A 22-year-old woman presents with a 3-day history of right knee and left middle finger pain and swelling. She has no previous history of joint problems. On systematic enquiry, she denies any recent infection. She has recently returned from a holiday with four friends to Spain.

On examination, she is pyrexial, with a temperature of 38.7 °C, and a tachycardia of 110 beats/min. She is noted to have small pustules on the sides of some fingers, and a diffusely red, swollen, painful middle finger that she cannot flex. She also has pitting in some nails with hypertrophic plaques of scaling skin on both knees. She has a similar lesion in her scalp behind the right ear. Her right knee is red and hot and very painful, and held in slight flexion. She resists any movement of it. General medical examination is otherwise unremarkable.

What is the most likely diagnosis?

A	Psoriatic arthritis

she cannot flex. She also has pitting in some nails with hypertrophic plaques of scaling skin on both knees. She has a similar lesion in her scalp behind the right ear. Her right knee is red and hot and very painful, and held in slight flexion. She resists any movement of it. General medical examination is otherwise unremarkable.

What is the most likely diagnosis?

A	Psoriatic arthritis
B	Reactive arthritis
C	Rheumatoid arthritis
D	Gonococcal arthritis
E	Mixed connective tissue disease

A 22-year-old woman presents with a 3-day history of right knee and left middle finger pain and swelling. She has no previous history of joint problems. On systematic enquiry, she denies any recent infection. She has recently returned from a holiday with four friends to Spain.

On examination, she is pyrexial, with a temperature of 38.7 °C, and a tachycardia of 110 beats/min. She is noted to have small pustules on the sides of some fingers, and a diffusely red, swollen, painful middle finger that she cannot flex. She also has pitting in some nails with hypertrophic plaques of scaling skin on both knees. She has a similar lesion in her scalp behind the right ear. Her right knee is red and hot and very painful, and held in slight flexion. She resists any movement of it. General medical examination is otherwise unremarkable.

What is the most likely diagnosis?

A	Psoriatic arthritis

sides of some fingers, and a diffusely red, swollen, painful middle finger that she cannot flex. She also has pitting in some nails with hypertrophic plaques of scaling skin on both knees. She has a similar lesion in her scalp behind the right ear. Her right knee is red and hot and very painful, and held in slight flexion. She resists any movement of it. General medical examination is otherwise unremarkable.

What is the most likely diagnosis?

A	Psoriatic arthritis
B	Reactive arthritis
C	Rheumatoid arthritis
D	Gonococcal arthritis
E	Mixed connective tissue disease

A 22-year-old woman presents with a 3-day history of right knee and left middle finger pain and swelling. She has no previous history of joint problems. On systematic enquiry, she denies any recent infection. She has recently returned from a holiday with four friends to Spain.

On examination, she is pyrexial, with a temperature of 38.7 °C, and a tachycardia of 110 beats/min. She is noted to have small pustules on the sides of some fingers, and a diffusely red, swollen, painful middle finger that she cannot flex. She also has pitting in some nails with hypertrophic plaques of scaling skin on both knees. She has a similar lesion in her scalp behind the right ear. Her right knee is red and hot and very painful, and held in slight flexion. She resists any movement of it. General medical examination is otherwise unremarkable.

What is the most likely diagnosis?

Your answer was incorrect

D Gonococcal arthritis

Disseminated gonococcal infection is caused by the bacteraemic spread of the sexually transmitted bacterium *Neisseria gonorrhoeae*. The best-fit syndrome described in this patient is the dermatitis–polyarthritis–tenosynovitis syndrome, symptoms including fever, symmetrical polyarthralgia (small or large joints), tenosynovitis and dermatitis (painless vesiculopustular lesions). Diagnosis is made by culture of synovial fluid, skin lesions and specimens from urethral swabs. Treatment includes symptomatic relief with NSAIDs, and ceftriaxone and azithromycin.

B Reactive arthritis

Reactive arthritis would be in the differential diagnosis. Reactive arthritis also typically presents with the triad of arthritis, conjunctivitis and urethritis, and is an inflammatory response to a distant gastrointestinal or urogenital

A	Psoriatic arthritis

Some of the signs described in this patient are consistent with psoriatic arthritis (scaling skin on her knees and nail pitting), but the onset is too rapid and the single joint disease is more severe than expected.

C	Rheumatoid arthritis

The pattern of joint involvement and additional signs are not consistent with RA.

E	Mixed connective tissue disease

Mixed connective tissue disease is an overlap syndrome including features of systemic lupus erythematosus (SLE), systemic sclerosis and polymyositis. High titres of anti-U1 ribonucleoprotein (RNP) are seen. It is not consistent with this patient's history and examination.

A 32-year-old man presents to the general practitioner after returning from a 1-week holiday in Thailand. He complains of pain on passing urine, and cloudy urine that looks like pus on occasions. There is also joint pain predominantly affecting the knees and ankles, and itchy eyes.

On examination, there appears to be a psoriatic-type rash affecting the feet.

Given the likeliest diagnosis, which one of the following treatments would best fit with the management of this condition?

A	Methotrexate 2.5 mg po weekly
B	Azathioprine
C	Doxycycline 100 mg bd
D	Prednisolone 40 mg po daily
E	Coal tar skin creams

A 32-year-old man presents to the general practitioner after returning from a 1-week holiday in Thailand. He complains of pain on passing urine, and cloudy urine that looks like pus on occasions. There is also joint pain predominantly affecting the knees and ankles, and itchy eyes.

On examination, there appears to be a psoriatic-type rash affecting the feet.

Given the likeliest diagnosis, which one of the following treatments would best fit with the management of this condition?

Your answer was incorrect

A	Methotrexate 2.5 mg po weekly
B	Azathioprine
C	Doxycycline 100 mg bd
D	Prednisolone 40 mg po daily

C Doxycycline 100 mg bd

This patient has reactive arthritis, which is a form of spondyloarthritis caused by a remote gastrointestinal or urogenital infection. Pathogens include *Chlamydia trachomatis*, *Yersinia*, *Salmonella*, *Shigella*, *Campylobacter*, *E. coli*, *Clostridium difficile* and *Chlamydia pneumoniae*. The social history and suggestion of keratoderma blennorrhagica would implicate *Chlamydia* infection.

D Prednisolone 40 mg po daily

Oral glucocorticoids are not suggested in the treatment of reactive arthritis, but intra-articular steroid injections can be used in those who do not respond to oral NSAIDs.

A Methotrexate 2.5 mg po weekly

This patient has reactive arthritis, which is addressed by treating the

A	Methotrexate 2.5 mg po weekly

This patient has reactive arthritis, which is addressed by treating the underlying infection and NSAIDs for symptomatic relief.

B	Azathioprine

Explanation as for Methotrexate 2.5 mg po weekly.

E	Coal tar skin creams

The psoriatic-type rash in this patient is more likely keratoderma blennorrhagica, given the history. This can be treated with topical steroids or salicylates.

33270

Rate this question:

A 76-year-old man is brought to the Emergency Department complaining of severe headaches affecting the left-hand side of his head. He has also suffered intermittent pain in his jaw on chewing.

On further questioning, his wife reports that her husband has suffered increasing tiredness over the past few weeks. Laboratory testing reveals a markedly raised ESR of 90 mm/h.

What is the optimal next step in managing this condition?

A	Urgent CT scan of the head
B	Book temporal artery biopsy for surgical list in 5 days' time
C	Start 20 mg prednisolone per day
D	Start 60 mg prednisolone per day

suffered intermittent pain in his jaw on chewing.

On further questioning, his wife reports that her husband has suffered increasing tiredness over the past few weeks. Laboratory testing reveals a markedly raised ESR of 90 mm/h.

What is the optimal next step in managing this condition?

A	Urgent CT scan of the head
B	Book temporal artery biopsy for surgical list in 5 days' time
C	Start 20 mg prednisolone per day
D	Start 60 mg prednisolone per day
E	Arrange immunoglobulin testing

D Start 60 mg prednisolone per day

The history and markedly raised ESR are suggestive of a diagnosis of temporal arteritis. A temporal artery biopsy from the affected side is the definitive diagnostic test, though treatment with prednisolone should not be delayed while awaiting biopsy. Histological features on biopsy include intimal hypertrophy, inflammation of the intima and sub-intima, breaking up of the internal elastic lamina, and giant cell infiltration of the internal elastic lamina. Prednisolone therapy should not be delayed because involvement of the ophthalmic arteries can cause sudden unilateral visual loss. Treatment is with high-dose prednisolone therapy, and the symptom response is both dramatic and diagnostic. In total, around three-quarters of patients need between 1 and 3 years' of steroid therapy, though the remaining quarter may require continued steroids for some years.

A	Urgent CT scan of the head

The history is typical for giant cell arteritis (GCA), and investigations should not delay urgent treatment to prevent visual loss.

B	Book temporal artery biopsy for surgical list in 5 days' time

The history is typical for GCA and investigations should not delay urgent treatment to prevent visual loss. A temporal artery biopsy of at least 1–2 cm can be performed to confirm the diagnosis. The sensitivity is high, but false-negatives do occur due to the segmental nature of the arteritic involvement by GCA, the so-called 'skip areas'. Colour Doppler ultrasound is an emerging diagnostic test, but currently with limited availability.

C	Start 20 mg prednisolone per day

The diagnosis is GCA, but high-dose

A 60-year-old woman who is being treated with methotrexate for rheumatoid arthritis has misunderstood the directions for therapy and presents to the surgery with glossitis, severe mouth ulcers and megaloblastic anaemia.

On further questioning, it transpires she has been taking a dose of 40 mg per week, rather than 10 mg per week.

Investigations:

Haemoglobin (Hb)	98 g/l
Mean corpuscular volume (MCV)	107 fl
White cell count (WCC)	2.3×10^9/l
Platelets (PLT)	95×10^9/l

Which of the following is the most appropriate rescue medication?

A	Vitamin B_{12}

Mean corpuscular volume (MCV)	107 fl
White cell count (WCC)	$2.3 \times 10^9/l$
Platelets (PLT)	$95 \times 10^9/l$

Which of the following is the most appropriate rescue medication?

A Vitamin B_{12}

B Folinic acid

C Vitamin C

D Iron sulfate

E Niacin

21008

Submit

B Folinic acid

The answer is Folinic acid (Option B).

Unfortunately, medication errors with respect to rheumatoid arthritis are not uncommon. Patients occasionally find it difficult to understand that they must take their medication weekly, as opposed to daily. Calcium folinate is a potent antagonist for the effects of methotrexate on the haematopoietic system, given by intravenous (IV) infusion at doses of up to 75 mg in the first 12 hours. This can then be followed by doses of 6–12 mg every 4 hours. Blood transfusion may also be required in exceptional circumstances. Where a massive overdose of methotrexate has occurred, hydration and urinary alkalinisation may be an option. Standard dialysis is ineffective in removing methotrexate, although intermittent high-flux dialysis may be of value.

A Vitamin B_{12}

A 28-year-old white man presented with 2-week history of fever and chills followed by a widespread papular rash over his body. One week ago, he noticed that his wrist and ankle were swollen and tender. The inflammation resolved a few days later, but now his right knee is very swollen and tender and he can barely weight-bear on it. He works as a computer salesman and he was in Thailand until 2 weeks ago on a business trip.

On examination, his right knee is hot and swollen and there are a few pustular lesions on his trunk.

Investigations:

Haemoglobin (Hb)	13.6 g/dl (>13 g/dl)
White cell count (WCC)	13 × 10^9/l (4–11 × 10^9/l)
Sodium	145 mmol/l (135/145 mmol/l)
Potassium	4.5 mmol/l (3.5–5 mmol/l)

Creatinine	88 μmol/l (68–150 mmol/l)
Rheumatoid factor	Negative
Antinuclear antibody	Absent
Synovial fluid white cells	>20 000/μl

What is the probable diagnosis?

A Acute gout

B Reactive arthritis

C Gonococcal arthritis

D Tuberculous arthritis

E Pseudo-gout

C Gonococcal arthritis

Disseminated gonococcal infection is caused by the bacteraemic spread of the sexually transmitted bacterium *Neisseria gonorrhoeae*. The syndrome described in this patient is the dermatitis–polyarthritis–tenosynovitis syndrome, symptoms including fever, symmetrical polyarthralgia (small or large joints), tenosynovitis and dermatitis (painless vesiculopustular lesions). Diagnosis is made by culture of synovial fluid, skin lesions and specimens from urethral swabs. Treatment includes symptomatic relief with NSAIDs and ceftriaxone and azithromycin.

A Acute gout

The age, social history and associated signs are not typical for acute gout, which usually presents as a mono-arthritis.

B Reactive arthritis

B Reactive arthritis

Reactive arthritis would be in the differential diagnosis, but the presence of white cells in the synovial fluid indicates joint infection rather than an inflammatory response to remote infection, as is the case in reactive arthritis. Reactive arthritis also typically presents with the triad of arthritis, conjunctivitis and urethritis.

D Tuberculous arthritis

TB arthritis tends to occur in the knee and hip, which is subacute in onset. It is uncommon in developed countries and would not explain the associated signs.

E Pseudo-gout

The age, social history and associated signs are not typical for pseudo-gout, which usually presents as a mono-arthritis.

A 60-year-old woman is referred to the Rheumatology Clinic after suffering her second Colles' fracture. Dual-energy X-ray absorptiometry (DEXA) scanning reveals a T-score of -2.8, confirming osteoporosis. The patient is keen to start preventive therapy.

Investigations:

Phosphate	0.9 mmol/l
Ca^{++}	2,27 mmol/l
ALP	180 U/l
Urea	3.2 mmol/l
Creatinine	75 mmol/l
K^{+}	4.2 mmol/l
Na^{+}	140 mmol/l

What is the best choice for initial therapy in this patient?

Creatinine	75 mmol/l
K^+	4.2 mmol/l
Na^+	140 mmol/l

What is the best choice for initial therapy in this patient?

A	Hormone-replacement therapy>
B	Calcitonin therapy
C	Calcium and vitamin D supplementation
D	Raloxifene
E	Bisphosphonate therapy

E Bisphosphonate therapy

Osteoporosis is defined by a T-score of –2.5 SD or below on DXA scanning

NICE guidelines TA160/161 state that alendronate is recommended as a treatment option for the secondary prevention of osteoporotic fragility fractures in postmenopausal women (such as the patient in this scenario) who are confirmed to have osteoporosis. In women aged 75 years or older, a DXA scan may not be required if the responsible clinician considers it to be clinically inappropriate or unfeasible.

Alendronate is also recommended as a treatment option for the primary prevention of osteoporotic fragility fractures in the following groups (see links below for full guidance):

1. Women aged 70 years or older who have an independent clinical risk factor for fracture or an indicator of low BMD and who are confirmed to have osteoporosis. In women aged 75 years or older

women aged 75 years or older who have two or more independent clinical risk factors for fracture or indicators of low BMD, a DXA scan may not be required.

2. Women aged 65–69 years who have an independent clinical risk factor for fracture and who are confirmed to have osteoporosis.
3. Postmenopausal women younger than 65 years who have an independent clinical risk factor for fracture and at least one additional indicator of low BMD, and who are confirmed to have osteoporosis.

Risedronate and etidronate are recommended as alternative treatment options for the primary and secondary prevention of osteoporotic fragility fractures in postmenopausal women who are unable to comply with the special instructions for the administration of alendronate, or have a contraindication to or are intolerant of alendronate.

Oral bisphosphonates are relatively contraindicated with dyspepsia, but IV bisphosphonates are associated with a higher increased risk of avascular necrosis of the jaw and atypical femoral fractures. Another rare complication of long-term bisphosphonate therapy is the risk of long bone mid-shaft fractures, possibly due to prolonged suppression of bone turnover. The International Osteoporosis Foundation and the European Society on Clinical and Economic Aspects of Osteoporosis and Osteoarthritis (ESCEO) conclude that the risk of these rare (<1 in 1000) atypical fractures is outweighed by the benefit of prevention of other osteoporotic fractures.

A	Hormone-replacement therapy>

HRT has been proven to reduce loss of bone mineral density and fracture risk at vertebral and other sites in postmenopausal women. In recent years, however, the risks of

thrombosis, cardiovascular disease and cancers have thrown into question the risk-benefit ratio of HRT.

B	Calcitonin therapy

Calcitonin is rarely used as a treatment for osteoporosis now because of the risks of osteosarcoma associated with its use over the longer term and the availability of alternatives.lignancy.

C	Calcium and vitamin D supplementation

Calcium and vitamin D are insufficient alone, but may be used alongside bisphosphonates. NICE osteoporosis guidelines state that unless clinicians are confident that women who receive treatment for osteoporosis have an adequate calcium intake and are vitamin D replete, calcium and/or vitamin D supplementation should be considered.

D	Raloxifene

D	Raloxifene

Raloxifene is a selective oestrogen receptor modifier that appears to be associated with a reduction in the risk of oestrogen receptor-positive breast carcinomas, as well as positive effects on bone mineral density. Raloxifene is not recommended by NICE as a treatment option for the primary prevention of osteoporotic fragility fractures in postmenopausal women, but recommends that it should be considered for the secondary prevention of osteoporotic fragility fractures in postmenopausal women who:

- are unable to comply with the special instructions for the administration of alendronate and either risedronate or etidronate, or have a contraindication to or are intolerant of alendronate and either risedronate or etidronate; and

but recommends that it should be considered for the secondary prevention of osteoporotic fragility fractures in postmenopausal women who:

- are unable to comply with the special instructions for the administration of alendronate and either risedronate or etidronate, or have a contraindication to or are intolerant of alendronate and either risedronate or etidronate; and
- who also have a combination of T-score, age and number of independent clinical risk factors for fracture (see guidelines below).

6415

Rate this question:

Next Question

A 54-year-old man presents to his general practitioner (GP) complaining that he is unable to get up off his low sofa. There is also a history of pain and tenderness particularly over the thigh muscles and the shoulder girdle.

On further questioning, he admits to shortness of breath on exercise and chronic cough.

Examination reveals an obese man with obvious proximal muscle weakness and evidence of interstitial lung disease. CK level is 1050 U/l (24–195), ESR is raised and anti-Jo-1 antibodies are positive.

What diagnosis fits best with this clinical picture?

A	Polymyalgia rheumatica
B	Dermatomyositis
C	Polymyositis
D	Giant cell arteritis

9:56
:tps://mypastest.pastest.com

On further questioning, he admits to shortness of breath on exercise and chronic cough.

Examination reveals an obese man with obvious proximal muscle weakness and evidence of interstitial lung disease. CK level is 1050 U/l (24–195), ESR is raised and anti-Jo-1 antibodies are positive.

What diagnosis fits best with this clinical picture?

Your answer was correct

A	Polymyalgia rheumatica
B	Dermatomyositis
C	Polymyositis
D	Giant cell arteritis

C Polymyositis

Patients with polymyositis commonly present after 3–6 months of symptoms with painful proximal muscle weakness. CK levels may be elevated to 5–50 times the upper limit of normal. Anti-Jo-1 antibodies are associated with coexistent interstitial lung disease, Raynaud's phenomenon and peripheral arthritis. Prednisolone is the mainstay of treatment, at an initial dose of 1 mg/kg/day. In patients who fail to show improvement, disease-modifying steroid-sparing agents may be added. A high-protein diet and supervised exercise may further improve symptoms. Most patients have a favourable response to corticosteroid therapy, and 5-year survival rates approach 80%. Women are more frequently affected than men, with a female:male ratio of 3:1. There is an association with malignancy in a significant minority of patients, including adenocarcinomas of the cervix, lung, ovaries, pancreas, bladder and stomach.

A Polymyalgia rheumatica

PMR is characterised by bilateral aching and morning stiffness in at least two areas (neck or torso, shoulders or proximal arms, hips or thighs). There is elevated ESR and a prompt response to low-dose glucocorticoids. The history of pain and tenderness and the additional symptoms are not consistent with PMR.

B Dermatomyositis

Dermatomyositis and polymyositis are both idiopathic inflammatory myopathies, but the former is distinguished by the presence of cutaneous lesions such as Gottron's papules, heliotrope rash or the shawl sign.

D Giant cell arteritis

The lack of unilateral headache/scalp tenderness, jaw claudication and the rise in CK make GCA unlikely.

A 32-year-old man with rheumatoid arthritis complicated by deforming arthritis comes to the Rheumatology Clinic for review. His arthritis is very poorly controlled, and he has recently failed to gain significant benefit from methotrexate.

You elect to institute therapy with tocilizumab. The patient asks you about potential adverse events.

Which side-effect would be the most important to counsel him about?

A	Depression
B	Diabetes
C	Folate deficiency
D	Neutropenia
E	Lung fibrosis

D Neutropenia

The answer is Neutropenia (Option D).

Neutropenia and neutropenic infections may be seen with tocilizumab therapy.

A Depression

Depression (Option A) is incorrect.

Depression is not an observed side-effect of tocilizumab therapy.

B Diabetes

Diabetes (Option B) is incorrect.

Diabetes would not be expected with tocilizumab. Diabetes is a common complication of corticosteroid-based therapy and may need treatment to control blood sugars.

C Folate deficiency

Folate deficiency (Option C) is

tocilizumab. Diabetes is a common complication of corticosteroid-based therapy and may need treatment to control blood sugars.

C	Folate deficiency

Folate deficiency (Option C) is incorrect.

Folate deficiency is a common side-effect of metformin use, not tocilizumab.

E	Lung fibrosis

Lung fibrosis (Option E) is incorrect.

Lung fibrosis is a side-effect of many medications, but not tocilizumab. Possible causes include methotrexate, bleomycin, amiodarone, nitrofurantoin and cyclophosphamide.

71573

Rate this question:

A 24-year-old man presents to his general practitioner (GP) complaining of lower back pain, particularly over the lateral lower spine on bending forward. The pain is worse in the morning; he was signed off from his job as a builder 6 months earlier due to an episode of plantar fasciitis.

Investigations:

Hb	12.6 g/dl
WCC	4.8×10^9/l
PLT	198×10^9/l
Neutrophils	2.9×10^9/l
Lymphocytes	2.8×10^9/l
ESR	15 mm/1st h
CRP	7.0 mg/l
AST	28 IU/l
ALP	101 IU/l
ALT	25 IU/l
Anti-CCP	< 20

ALP	101 IU/l
ALT	25 IU/l
Anti-CCP	< 20
RF	-
ANA	-

What is the best initial therapy in this case?

A	Rest for a further 1 month
B	Non-steroidal anti-inflammatory agents
C	Non-steroidal anti-inflammatory agents and physiotherapy
D	Sulphasalazine
E	Etanercept

C Non-steroidal anti-inflammatory agents and physiotherapy

This man's presentation is highly suspicious of spondyloarthritis/ankylosing spondylitis, i.e. back pain onset <40 years, morning stiffness and associated plantar fasciitis. Adequate pain relief and physiotherapy have a crucial role to play in maintenance of function when the disease is diagnosed early.

A Rest for a further 1 month

Minimising activity, i.e. rest, is the worst thing this gentleman could do. Mobilising and exercise have a critical role in the management of spondyloarthritis/ankylosing spondylitis.

B Non-steroidal anti-inflammatory agents

NSAIDs, in combination with

B	Non steroidal anti inflammatory agents

NSAIDs, in combination with physiotherapy have been shown to have the best outcomes in ankylosing spondylitis.

D	Sulphasalazine

DMARDs, such as sulfasalazine, are used when patients have peripheral joint arthritis (e.g. a swollen knee), which this man does not.

E	Etanercept

TNF-a antagonists such as etanercept are recommended by **NICE** if disease is still active despite two NSAIDs for at least four weeks.

6423

Rate this question:

Next Question

A 42-year-old man presents to the Rheumatology Clinic for review. He complains of multiple joint pains, particularly affecting his back, wrists, ankles and feet, with clear distal interphalangeal joint involvement.

On examination, he has psoriatic patches on his elbows. There is onycholysis, transverse ridging and pitting on examination of his nails. DIP swelling, pain and restricted movement is noted. He is started on and methotrexate but on return to the clinic there is no improvement. You elect to treat him with adalimumab.

The mode of action of adalimumab is mediated through which of the following?

A	C-reactive protein (CRP)
B	Erythrocyte sedimentation rate (ESR)
C	IL-23

patches on his elbows. There is onycholysis, transverse ridging and pitting on examination of his nails. DIP swelling, pain and restricted movement is noted. He is started on and methotrexate but on return to the clinic there is no improvement. You elect to treat him with adalimumab.

The mode of action of adalimumab is mediated through which of the following?

A	C-reactive protein (CRP)
B	Erythrocyte sedimentation rate (ESR)
C	IL-23
D	TNF-α
E	IL-12

D TNF-α

Adalimumab is anti-TNF-α monoclonal antibody. Adalimumab, etanercept and infliximab are anti-TNF agents which show some degree of efficacy as second-line agents in the management of psoriasis and psoriatic arthritis. TNF-α is thought to play an important role as a cytokine leading to worsening of joint inflammation and destruction.

E IL-12

Ustekinumab has recently been approved by NICE for the treatment of psoriasis and psoriatic arthritis, and is an IL-12/23 antagonist.

A C-reactive protein (CRP)

While CRP and ESR may well fall in response to anti-TNF therapy, they are more non-specific markers of inflammation.

B Erythrocyte sedimentation

While CRP and ESR may well fall in response to anti-TNF therapy, they are more non-specific markers of inflammation.

B	Erythrocyte sedimentation rate (ESR)

While CRP and ESR may well fall in response to anti-TNF therapy, they are more non-specific markers of inflammation.

C	IL-23

Ustekinumab has recently been approved by NICE for the treatment of psoriasis and psoriatic arthritis, and is an IL-12/23 antagonist.

18520

Rate this question:

Next Question

A 40-year-old man with a history of diabetes presented to the clinic with bilateral knee pain. He works as an insurance salesman; he is a non-smoker but drinks on most weekends. He is on insulin for the diabetes and also takes sildenafil occasionally for erectile dysfunction.

On examination, he appeared suntanned with sparse body hair. The knees were swollen and tender, with limited range of movement.

Investigations:

Sodium	135 mmol/l (135–145 mmol/l)
Potassium	5.0 mmol/l (3.5–5 mmol/l)
Creatinine	110 μmol/l (68–150 μmol/l)
Albumin	35 g/l (33–49 g/l)
Bilirubin	1.75 mg/dl (0.1–1.2 mg/dl)

Bilirubin	1.75 mg/dl (0.1–1.2 mg/dl)
Serum alanine aminotransferase (ALT)	75 U/l (7–55 U/l)
Serum aspartate transaminase (AST)	65 U/l (8–48 U/l)
Gamma glutamyl transferase	160 U/l (9–48 U/l)
Glucose	14 mmol/l
Luteinising hormone (LH)	0.6 U/l (1–10 U/l)
Follicle-stimulating hormone (FSH)	0.5 U/l (1–7 U/l)
Testosterone	6.8 nmol/l (9–35nmol/l)
X-ray of the knees	Calcification present

What is the most likely cause of the joint abnormality?

Luteinising hormone (LH)	0.6 U/l (1–10 U/l)
Follicle-stimulating hormone (FSH)	0.5 U/l (1–7 U/l)
Testosterone	6.8 nmol/l (9–35nmol/l)
X-ray of the knees	Calcification present

What is the most likely cause of the joint abnormality?

A Osteomalacia

B Ochronosis

C Cystinosis

D Chondrocalcinosis

E Gout

D Chondrocalcinosis

Hereditary haemochromatosis should be suspected in patients with liver cirrhosis (liver function tests can often be normal), diabetes mellitus, hypogonadism and impotence, skin hyperpigmentation, fatigue and arthropathy. Biochemical findings include high serum iron, ferritin and transferrin saturation, and liver biopsy shows staining for excess iron. Arthropathy in hereditary haemochromatosis is due to calcium pyrophosphate crystal deposition and can include pseudo-gout, chondrocalcinosis and chronic arthropathy.

A Osteomalacia

Bilateral knee joint pain is not a common presentation of osteomalacia, which is often asymptomatic. Bone pain and tenderness, fragility fractures, waddling gait and osteopenia on X-ray may be features.

A 45-year-old Asian woman presents with 3-month history of difficulty climbing stairs. She also described non-specific pain all over her joints, the lower legs and upper arms. She has been seeing her general practitioner for her symptoms, and several analgesics have been tried, but her symptoms are not improving. She is on insulin for diabetes and bendroflumethiazide for mild hypertension. On examination there is slight tenderness on the upper arms and the lower legs. Respiratory and cardiovascular examinations are normal.

Investigations reveal:

Hb	11 g/dl
WCC	6.6×10^9/l
PLT	200×10^9/l
Na^+	135 mmol/l
K^+	3.8 mmol/l
Creatinine	102 umol/l

Creatinine	102 µmol/l
Calcium	2.08 mmol/l
Phosphate	0.69 mmol/l
Creatinine kinase (CK)	200 U/l
Alkaline phosphatase (ALP)	150 mmol/l

X-ray of the lower legs shows coarsened trabecular bone, no fracture.

What diagnosis will you consider the most likely in her case?

A Fibromyalgia

B Polymyositis

C Osteoarthritis

D Osteoporosis

coarsened trabecular bone, no fracture.

What diagnosis will you consider the most likely in her case?

Your answer was correct

A	Fibromyalgia
B	Polymyositis
C	Osteoarthritis
D	Osteoporosis
E	Osteomalacia

Explanation

E	Osteomalacia

The patient has slightly low calcium, low phosphate and high ALP. Osteomalacia results from inadequate

Osteomalacia results from inadequate mineralisation of bone due to deficiency in vitamin D. Inadequate sunlight exposure (particularly in some Asian women who wear protective long clothing), in combination with dietary deficiency is often seen as a cause. Other causes of osteomalacia are chronic kidney disease, renal osteodystrophy, malabsorption and renal tubular defects etc. Osteomalacia may result in symptoms such as skeletal pain and tenderness, proximal muscle weakness and spontaneous fractures. X-ray of long bone is often normal but may show defective mineralisation, with the characteristic 'Looser's zone' (pseudofractures). Biochemistry shows low calcium, phosphate, vitamin D levels and raised ALP.

A	Fibromyalgia

The patient has an abnormal bone profile and does not have tenderness at multiple trigger points on examination. Fibromyalgia is a

at multiple trigger points on examination. Fibromyalgia is a diagnosis of exclusion.

B Polymyositis

The patient's main symptoms are generalised bony pain, she has an abnormal bone profile and her CK is only mildly elevated. Osteomalacia can cause a proximal myopathy.

C Osteoarthritis

The patient's bone profile and her clinical features of generalised bone pain are suggestive of osteomalacia and she is too young for generalised osteoarthritis.

D Osteoporosis

Osteoporosis is associated with normal bone profile.

9526

Rate this question:

A 54-year-old woman with a long history of diabetes mellitus, which is now managed with insulin, presents for review. She has acute pain and swelling over the first metatarsophalangeal joint of her left foot and there are rounded, calcium-like deposits in her ear cartilage.

Investigations:

Haemoglobin A1c (HbA1c)	72.68 mmol/mol (8.8%)
WCC	6.8×10^9/l
Creatinine	145 μmol/l
K^+	5.8 mmol/l
Na^+	134 mmol/l

Which of the following would be the most appropriate initial management of this patient?

A	Diclofenac 50 mg po tds
B	Colchicine

Haemoglobin A1c (HbA1c)	72.68 mmol/mol (8.8%)
WCC	6.8×10^9/l
Creatinine	145 µmol/l
K^+	5.8 mmol/l
Na^+	134 mmol/l

Which of the following would be the most appropriate initial management of this patient?

A Diclofenac 50 mg po tds

B Colchicine

C Allopurinol 100 mg po daily

D Paracetamol

E Prednisolone 40 mg po daily

B Colchicine

This patient has chronic kidney disease, probably as a result of longstanding poorly controlled diabetes mellitus, and has developed gout. As such, colchicine would be the initial treatment of choice. The creatinine is a little high, although the eGFR is likely to be over 30 and therefore colchicine could be 'renally dosed' at 500 mcg bd. The incidence of renal stones is increased in patients with gout: 80% of these are uric acid stones.

A Diclofenac 50 mg po tds

Non-steroidals in this case may exacerbate salt and water retention and worsen renal function.

C Allopurinol 100 mg po daily

Allopurinol should not be started during an acute attack, but could be

during an acute attack, but could be started at least four weeks after the attack has settled. The contraindication to allopurinol in renal impairment is relative, and this drug can be used even in moderate–severe kidney disease providing dose reduction is employed, although of course it should be begun after the acute episode.

D	Paracetamol

Paracetamol is not likely to be sufficiently effective enough for the acute pain and inflammation of gout.

E	Prednisolone 40 mg po daily

Corticosteroids are reserved for those patients in whom non-steroidal anti-inflammatory agents and colchicine are either contraindicated or there is patient intolerance.

33277

Rate this question:

A 71-year-old woman who has had rheumatoid arthritis (RA) since the age of 50, being treated with 12.5 mg methotrexate per week, informs you that she has recently had three courses of antibiotics for feeling unwell and recurrent upper respiratory tract infections.

Examination reveals rheumatoid nodules over the extensor aspect of both elbows, swelling and tenderness in occasional PIP and metacarpophalangeal (MCP) joints, and bilaterally replaced knee joints. Her chest is clear and cardiovascular system examination is unremarkable. Her abdominal examination shows mild splenomegaly.

Investigations:

Hb	10.1 g/dl
WBC	3.2×10^9/l
Neutrophils	1.9×10^9/l
Lymphocytes	0.9×10^9/l
Eosinophils	0.1×10^9/l

Eosinophils	$0.1 \times 10^9/l$
Monocytes	$0.3 \times 10^9/l$
ESR	88 mm/1st hour
Rheumatoid factor (RF)	+
Antinuclear antibody (ANA)	+

The most likely diagnosis is?

A	Lymphoma
B	Felty's syndrome
C	Methotrexate-induced leucopenia
D	Rheumatoid lung
E	Systemic lupus erythematosus

B Felty's syndrome

This lady has the triad of RA, splenomegaly and neutropenia. Felty syndrome usually occurs in patients with long-standing seropositive rheumatoid arthritis (RA). Two-thirds of patients are female. The clinical features include RA, leucopenia, lymphadenopathy and splenomegaly. Leg ulcers, recurrent infections and episcleritis may also be present. Initial treatment is for the underlying rheumatoid arthritis, including disease-modifying anti-rheumatic drugs (DMARDs) and NSAIDs. More severe cases refractory to treatment may benefit from weekly injections of colony-stimulating factor to stimulate production of granulocytes. Splenectomy is also an option for certain severe cases.

A Lymphoma

This lady has the triad of RA, splenomegaly and neutropenia – Felty syndrome. There are no signs that

syndrome. There are no signs that would make lymphoma more likely, such as lymphadenopathy or systemic upset (fevers, weight loss, sweats, etc.).

C	Methotrexate-induced leucopenia

Although she is on MTX and leucopenic, the splenomegaly is not explained by this option.

D	Rheumatoid lung

This lady may well have rheumatoid lung, but the neutropenia and splenomegaly are not explained by this option.

E	Systemic lupus erythematosus

Presenting symptoms in SLE can be very variable due to the condition having multi-system effects, but the classic presentation is of fever.

You review a 62-year-old woman who has severe rheumatoid arthritis. She takes regular non-steroidal anti-inflammatory agents and you have recently had to withdraw methotrexate from her regime due to toxicity. She has previously been treated with sulphasalazine. You elect to begin a trial of adalimumab.

What is the mode of action of adalimumab?

A	It is a TNF-α antagonist
B	It is a TNF-α agonist
C	It is anti-CD20
D	It is an anti-CTLA-4
E	It is an IL-6R blocker

A It is a TNF-α antagonist

Adalimumab is a competitive inhibitor tumour necrosis factor (TNF) binding to cell surface receptors. Adalimumab can also modulate biological responses controlled by additional downstream molecules (e.g. cytokines, adhesion molecules or proteinases) that are induced or regulated by TNF. TNF is a dominant cytokine involved in the pathogenesis of both rheumatoid arthritis and plaque psoriasis. Side effects include allergic reactions and itching at the site of injection, transient fever and symptoms of upper respiratory tract infection soon after injection. Full anaphylactic-type reactions are thankfully much rarer. Adalimumab is indicated for the treatment of rheumatoid arthritis, either alone or in combination with methotrexate.

B It is a TNF-α agonist

Adalimumab is a TNF-α antagonist, not

treatment of rheumatoid arthritis, either alone or in combination with methotrexate.

B It is a TNF-α agonist

Adalimumab is a TNF-a antagonist, not an agonist.

C It is anti-CD20

Rituximab is a monoclonal antibody directed against CD20

D It is an anti-CTLA-4

Abatacept is an anti-CTLA-4 molecule (blocks T-cell co-stimulation).

E It is an IL-6R blocker

Tocilizumab is an IL-6 receptor blocker.

7604

Rate this question:

A 50-year-old Asian woman, who has been living in the United Kingdom (UK) for 5 years, presents complaining of bone pain, especially in the lower back and both legs. She also describes difficulty walking upstairs and standing from a sitting position. The patient is a lifelong vegetarian but does eat small amounts of dairy products.

On examination, there is mild proximal muscle weakness.

Investigations:

Phosphate	0.7 mmol/l
Calcium (Ca^{2+})	2.1 mmol/l
Alkaline phosphatase (ALP)	180 u/l
Urea	3.2 mmol/l
Creatinine	75 mmol/l
Potassium (K^{+})	4.2 mmol/l

Creatinine	75 mmol/l
Potassium (K^+)	4.2 mmol/l
Sodium (Na^+)	140 mmol/l

What would be the most likely radiographic finding on X-ray of this patient's hip?

A	Normal bones
B	Low-density bands extending from the cortex
C	Osteopenia
D	Subperisoteal erosions
E	Sclerotic bone

B Low-density bands extending from the cortex

This woman's ethnic origin and her history are suggestive of osteomalacia. In fact, vitamin D deficiency is very common in the UK, even in white patients, due to the climatic conditions. The diagnosis would be confirmed by blood results and X-ray findings. Looser's zones occur in this condition and are characterised by low-density bands extending from the cortex inwards. Osteomalacia is associated with vitamin D deficiency, which leads to hypocalcaemia, phosphate levels at the lower end of the normal range and elevated ALP levels. Bone pain and proximal myopathy are well-recognised sequelae.

A Normal bones

This is a possibility, even in osteomalacia, but given her symptoms, clinical findings of myopathy and abnormal biochemistry, there is likely

abnormal biochemistry, there is likely to be evidence of osteomalacia on imaging.

C	Osteopenia

Osteopenia and osteoporosis are usually associated with normal bone profiles/biochemistry. Risk factors for osteopenia include past history of smoking, early menopause, below-normal body weight and type 2 diabetes.

D	Subperisoteal erosions

Subperiosteal erosions can be seen in hyperparathyroidism, which would be associated usually with hypercalcaemia and low serum phosphate levels.

E	Sclerotic bone

Sclerotic and lytic bones may be seen in Paget's disease, in which one would see an isolated elevated ALP level and normal serum calcium levels.

A 21-year-old man has recently returned from a holiday in the Far East. He gives a history of symmetrical joint pain in his knees, ankles and feet and also complains of sore eyes.

On further questioning, the patient informs you that he did have unprotected sexual relations on several occasions whilst away, and is now experiencing some pain on urination.

His ESR is raised. A synovial fluid aspirate is sterile but with a high neutrophil count.

What is the most likely diagnosis?

A	Ankylosing spondylitis
B	Septic arthritis
C	Reactive arthropathy
D	Rheumatoid arthritis
E	Still's disease

C Reactive arthropathy

The history of recent travel to the Far East with episodes of unprotected sexual encounters raises the possibility of venereal disease. An oligoarthritis is seen more often than symmetrical arthropathy in reactive arthritis. The history of urethritis/dysuria and conjunctivitis completes the reactive arthritis triad. A penile swab should be taken and treatment should include treatment of the probable underlying STI.

A Ankylosing spondylitis

The potential exposure to venereal pathogens makes reactive arthropathy a more likely diagnosis than ankylosing spondylitis. Furthermore, there is no history of back or buttock pain.

B Septic arthritis

Septic arthritis is usually a mono-

B Septic arthritis

Septic arthritis is usually a mono-arthritis, but can be a polyarthritis in approximately 10% of cases. His synovial fluid aspirate is sterile, and the concurrent symptom of sore eyes suggests conjunctivitis associated with a reactive arthritis.

D Rheumatoid arthritis

The presence of conjunctivitis and evidence of urethritis steers us more towards reactive arthritis versus rheumatoid.

E Still's disease

Still's presents with high spiking fevers and oligoarthritis over the course of a few weeks/months, and not usually in this age group.

2330

Rate this question:

A 70-year-old woman with brittle asthma presents with left hip and groin pain. It is very painful to bear weight.

An X-ray of her hip reveals no evidence of a fracture. She is confused and cannot give a history.

On examination, she is afebrile and there is no redness or warmth around the hip. You notice that her fingers appear deformed.

What investigation will give the definitive diagnosis for her hip pain?

A	Inflammatory markers
B	MRI hip

appear deformed.

What investigation will give the definitive diagnosis for her hip pain?

A	Inflammatory markers
B	MRI hip
C	Auto-antibodies
D	Arthroscopy
E	X-ray knee

B MRI hip

The most likely diagnosis is of avascular necrosis of the hip, given the clues to oral steroid use – 'brittle' asthma as well as rheumatoid arthritis. An MRI is the diagnostic imaging technique of choice.

A Inflammatory markers

Although this lady is likely to have rheumatoid arthritis, as suggested by the Boutonniere deformity, inflammatory markers are unlikely to help – the history suggests a monoarthritis but dissuades you from a septic arthritis, with the absence of fever or erythema.

C Auto-antibodies

Auto-antibodies may help you confirm a diagnosis of rheumatoid arthritis, but would not help delineate the cause of her acute hip pain.

C Auto-antibodies

Auto-antibodies may help you confirm a diagnosis of rheumatoid arthritis, but would not help delineate the cause of her acute hip pain.

D Arthroscopy

Arthroscopy is very invasive and unnecessary in this case, to diagnose avascular necrosis.

E X-ray knee

It is always important to think of the joint below (and above if applicable), as pain may be referred. However, in this case with groin pain and likely long-term steroid use, the most likely diagnosis is avascular necrosis of the hip. The hip is a common site, as it is supplied by an end-artery.

6894

Rate this question:

A 36-year-old woman presents with pain in her right elbow on forearm extension and wrist extension. She is a keen gardener and has recently been planting spring bulbs.

On examination, the elbow is held in partial flexion, pain is reproduced on resisted wrist extension and there is pain on palpation over the lateral epicondyle.

Which of the following interventions would be most appropriate to gain short term relief for this patient?

A	Local steroid/anaesthetic injection
B	Flexion exercise programme
C	Oral prednisolone
D	Elbow immobilisation
E	Early surgical intervention for medial tendon release

A Local steroid/anaesthetic injection

This lady has a lateral epicondylitis (i.e. tennis elbow). Local steroid/anaesthetic injection and use of non-steroidal anti-inflammatory agents may both be of benefit.

B Flexion exercise programme

With a lateral epicondylitis, physiotherapy and, in particular, stretching exercises, may also be of benefit, but the benefits of physiotherapy occur over the longer term.

C Oral prednisolone

Oral prednisolone is not appropriate for a lateral epicondylitis, which is localised inflammation. Systemic steroids are likely to have side effects, despite only minimal efficacy.

Oral prednisolone is not appropriate for a lateral epicondylitis, which is localised inflammation. Systemic steroids are likely to have side effects, despite only minimal efficacy.

D	Elbow immobilisation

While restricted activity may be appropriate, it would be inappropriate for this patient to have her elbow completely immobilised because her muscles are likely to waste and therefore cause more problems later.

E	Early surgical intervention for medial tendon release

Surgical intervention for lateral tendon release may be appropriate in patients who fail to respond to medical therapy.

33275

Rate this question:

Next Question

rheumatoid arthritis (RA) comes to the clinic for review. She is currently taking methotrexate and has quiescent disease, but wants to begin trying for a family.

Examination reveals no evidence of active joint disease, and her ESR is 13 mm/1st h. Liver function testing reveals transaminases within the normal range.

Which of the following is the most appropriate way to manage her RA?

A	Continue methotrexate at the same dose
B	Halve the dose of methotrexate
C	Stop methotrexate
D	Switch methotrexate to azathioprine
E	Switch methotrexate to infliximab

D Switch methotrexate to azathioprine

Approximately 50–70% of women with RA improve during pregnancy. This usually starts in the first trimester and lasts through the duration of pregnancy, but patients will often flare in the postpartum period. Glucocorticoids are safe to use during pregnancy, but NSAIDs should be avoided in early pregnancy and the third trimester due to premature closure of the ductus arteriosus. Azathioprine, sulfasalazine and hydroxychloroquine are relatively safe to use during pregnancy. Those three medications are not cast iron safe by any means.

A Continue methotrexate at the same dose

Methotrexate is an abortifacient that can also induce congenital anomalies if taken during pregnancy. It is therefore contraindicated in pregnant women.

contraindicated in pregnant women. Contraceptive use is advised in women taking methotrexate, as well as discontinuation of therapy in both women and men at least three months prior to conception. Oligospermia and chromatid breaks have been described in men on methotrexate.

B	Halve the dose of methotrexate

This strategy would not abolish the risks to the foetus and would leave the patient with suboptimal rheumatoid arthritis (RA) control.

C	Stop methotrexate

Stopping methotrexate without a replacement agent is not advised as will likely result in flare of RA.

E	Switch methotrexate to infliximab

Evidence suggests a relatively benign

A 37-year-old woman presents with tiredness, anorexia, gradual weight loss and intermittent pleuritic chest pain. She also complains of a sunburn-type rash which affects the bridge of her nose and cheeks, particularly in the summer months and joint pains affecting the wrists, knees and ankles.

On examination, her blood pressure is 148/92 mmHg. She has a rash on her face.

Investigations:

Hb	10.3 g/dl (normochromic normocytic)
WCC	4.1 $\times 10^9$/l
PLT	92 $\times 10^9$/l
APTT	44 s
C-reactive protein (CRP)	41 mg/l
Na^+	141 mmol/l
K^+	5.0 mmol/l

C-reactive protein (CRP)	41 mg/l
Na^+	141 mmol/l
K^+	5.0 mmol/l
Creatinine	142 µmol/l
Urine	Blood +, protein ++

Which of the following is the most specific investigation to elucidate the underlying diagnosis?

A Anti-nuclear antibodies

B Anti-ds DNA antibodies

C Anti-histone antibodies

D C3 levels

E C4 levels

B Anti-ds DNA antibodies

Anti-ds DNA antibodies are 100% specific for systemic lupus erythematosus (SLE), and their level may correlate with lupus activity, however only 50–70% SLE patients have these antibodies. Anti-dsDNA antibodies also indicate a worse prognosis, with renal/neurological involvement.

A Anti-nuclear antibodies

Anti-nuclear antibodies have sensitivity of over 95% for lupus, but are not very specific. 10% of the asymptomatic healthy, normal population are positive for anti-nuclear antibodies.

C Anti-histone antibodies

Anti-histone antibodies are more consistent with drug-induced lupus.

D C3 levels

Anti-histone antibodies are more consistent with drug-induced lupus.

D C3 levels

Complement may be low in SLE; this is non-specific and this phenomenon is also observed in other conditions such as subacute bacterial endocarditis.

E C4 levels

Complement may be low in SLE; this is non-specific and this phenomenon is also observed in other conditions such as subacute bacterial endocarditis

20955

Rate this question:

Next Question

A 26-year-old man presents to Rheumatology Clinic. His new partner has noticed that the inside of his mouth appears unusual and the patient has been referred by the general practitioner (GP) to exclude any abnormal cause.

He denies any pain and has no previous medical history. He has a family history of ischaemic heart disease and breast cancer. He takes no prescribed medication.

On examination, he is a tall and thin man with mild pectus excavatum. He has long, 'spidery' fingers. When making a fist, his thumb sticks out, and when he holds his own wrist he can reach around and cover his thumb.

A photograph of his mouth is shown below.

reach around and cover his thumb.

A photograph of his mouth is shown below.

Which investigation is necessary to establish diagnosis?

A	Fundoscopy only
B	Echocardiogram
C	Genetic testing only
D	Chromosome testing
E	No further testing necessary

B Echocardiogram

This patient clinically has classic features of Marfan syndrome: a tall person with long limbs, with chest deformity and long fingers with a positive thumb and wrist signs, as well as a high-arched palate. Diagnosis is established via the 2010 Revised Ghent Nosology. In the absence of family history, it is essential to establish aortic root dilatation above a Z score of 2 for a diagnosis and for this an echocardiogram is necessary. In the absence of a family history, the presence of ectopia lentis and *FBN1* genetic mutation in the absence of aortic root dilation can be used to establish a diagnosis.

A Fundoscopy only

Fundoscopy can reveal ectopic lens dislocation. This is a criterion for Marfan syndrome in patients with a known family history of the syndrome, but as this patient does not have a

but as this patient does not have a family history, it is not sufficient to establish a diagnosis. If a patient without a family history of Marfan syndrome has ectopia lentis and *FBN1* genetic mutation, then a diagnosis can be made, but fundoscopy alone cannot confirm a diagnosis.

C	Genetic testing only

Marfan syndrome is associated with a mutation of the *FBN1* gene on chromosome 15. *FBN1* encodes fibrillin-1, a glycoprotein important for the extracellular matrix. However, as there is variable expressivity, genetic testing is not definitive. Establishing *FBN1* gene mutation does not establish a diagnosis in the absence of family history. The presence of *FBN1* gene mutation can establish a diagnosis if there is also confirmed ectopia lentis.

D	Chromosome testing

Marfan syndrome is not a

chromosome 15. *FBN1* encodes fibrillin-1, a glycoprotein important for the extracellular matrix. However, as there is variable expressivity, genetic testing is not definitive. Establishing *FBN1* gene mutation does not establish a diagnosis in the absence of family history. The presence of *FBN1* gene mutation can establish a diagnosis if there is also confirmed ectopia lentis.

D	Chromosome testing

Marfan syndrome is not a chromosomal disorder and therefore this test would be unhelpful.

E	No further testing necessary

In the absence of family history, to establish a diagnosis it is necessary to demonstrate aortic root dilatation. If there were a family history, then this would have been correct.

71613

Rate this question:

A 55-year-old man with well-controlled ulcerative colitis (on azathioprine 100 mg), hypertension (on lisinopril) and diabetes (on metformin), presents to his general practitioner (GP) with exquisite pain affecting the right big toe. He has had several attacks this year, which usually subside with regular diclofenac for a week. His GP starts him on colchicine and when the attack has settled, adds in allopurinol. He returns to the GP two months later to pick up his repeat prescriptions.

Before his GP issues the prescription, he reviews this gentleman's blood tests (below) and is alarmed. He phones the gastroenterology registrar on call, as he suspects azathioprine toxicity.

Investigations:

Hb	5.8 g/dl
WCC	1.8×10^9/l
PLT	88×10^9/l
Neutrophils	0.5×10^9/l

WCC	$1.8 \times 10^9/l$
PLT	$88 \times 10^9/l$
Neutrophils	$0.5 \times 10^9/l$
Lymphocytes	$0.4 \times 10^9/l$
ESR	20 mm/1st h
CRP	8.0 mg/l

What is the underlying cause of azathioprine toxicity?

A Gout

B Allopurinol

C Colchicine

D Diclofenac

E Metformin

B Allopurinol

This patient is pancytopenic following an interaction between allopurinol and azathioprine. The combination of xanthine oxidase inhibition (allopurinol) and azathioprine potentiates the formation of mercaptopurine metabolites, which leads to significant and life-threatening bone marrow suppression. Allopurinol should never be co-prescribed with azathioprine.

A Gout

Gout *per se* does not cause azathioprine toxicity.

C Colchicine

Very rarely colchicine may cause myelosuppression.

D Diclofenac

You review a 54-year-old man who complains of progressive palmar contracture of the little and ring fingers of the left hand that has worsened over the past 12 months or so.

On examination of the palmar surface of the hand, you can feel a number of hard nodules and longitudinal firm cords that extend to the fingers.

Which one of the following fits best with the underlying condition?

A	Alcohol abuse is present in around 20% of sufferers
B	There is an association with Ledderhose disease
C	Atenolol may be of value as medical therapy
D	Patients usually suffer associated pain

fingers of the left hand that has worsened over the past 12 months or so.

On examination of the palmar surface of the hand, you can feel a number of hard nodules and longitudinal firm cords that extend to the fingers.

Which one of the following fits best with the underlying condition?

A	Alcohol abuse is present in around 20% of sufferers
B	There is an association with Ledderhose disease
C	Atenolol may be of value as medical therapy
D	Patients usually suffer associated pain
E	Previous myocardial infarction is not an associated risk factor

B There is an association with Ledderhose disease

This patient has Dupuytren's contracture of the hands. The condition is painless and has a male:female predominance of 10:1. Ledderhose disease is involvement of the plantar fascia (in the feet) by a similar process of nodule and cord formation leading to contraction of the toes. There are marked ethnic differences in the prevalence of Dupuytren's contracture, with prevalence rates approaching 25% in elderly Scandinavians. Alcoholism is an associated factor in around 10% of cases, diabetes mellitus in around 8% of cases. Other associations include previous myocardial infarction, hand trauma, HIV infection and cigarette smoking. Surgery followed by physiotherapy to improve finger function is the recommended course of action. Collagenase therapy may be an alternative to surgery in some cases.

A Alcohol abuse is present in

10:24
https://www.google.com/sea
10

Canadian Dupuytren Society

Canadian Dupuytren Society |

smoking. Surgery followed by physiotherapy to improve finger function is the recommended course of action. Collagenase therapy may be an alternative to surgery in some cases.

A	Alcohol abuse is present in around 20% of sufferers

Alcohol excess is associated with 10% of sufferers.

C	Atenolol may be of value as medical therapy

Chronic atenolol use may be associated with Dupuytren's contracture and therefore is a potential cause, not therapy.

D	Patients usually suffer associated pain

Duputryen's contracture is usually painless.

A 62-year-old patient presents to the Respiratory Clinic. He has been complaining of progressively worsening shortness of breath and dry cough. He denies any haemoptysis or chest pain. He smoked when he was younger and has roughly a ten pack-year history of smoking cigarettes. He used to work as a welder. He has a pet dog and lives in a house with his wife. He does not recall any asbestos exposure.

His past medical history includes gastro-oesophageal reflux disease (GORD), cholecystectomy for gallstones and hypertension. He normally takes amlodipine, omeprazole and ramipril.

Auscultation demonstrates crepitations in both lung bases.

His hands are as shown below.

crepitations in both lung bases.

His hands are as shown below.

What is the most likely diagnosis?

A	Bronchiectasis
B	Pulmonary fibrosis
C	Congestive cardiac failure
D	Pulmonary arterial hypertension
E	Pulmonary embolism

B Pulmonary fibrosis

The presence of a slow-onset shortness of breath, dry cough, bibasal crepitations and clubbing makes pulmonary fibrosis the most likely diagnosis. The patient's demographics fit well with this diagnosis as most patients with pulmonary fibrosis present in their 60s. Pulmonary fibrosis is accumulation of excessive fibrous tissues in a process termed fibrosis. This causes reduced oxygenation. Many cases are idiopathic, but environmental pollutants can be involved, such as in asbestosis and silicosis. Some cases are associated with underlying connective tissue diseases, and others are medication induced, eg amiodarone, methotrexate, nitrofurantoin and bleomycin.

The first-line investigations would be spirometry, for which a restrictive pattern would be found, and a chest X-ray, which would demonstrate a reticulonodular shadowing. Furthermore, a high-resolution computed tomography (HRCT) of the

Furthermore, a high-resolution computed tomography (HRCT) of the chest would be done and, if the diagnosis remains in doubt, a biopsy may be needed.

A Bronchiectasis

Bronchiectasis is a suppurative chronic lung disease characterised by scarred and thickened airways with chronic mucous secretion. It can be idiopathic, but many cases are due to viral infection, cystic fibrosis, autoimmune disease and tuberculosis. While bronchiectasis would explain worsening shortness of breath and cough, as well as the clubbing, bronchiectasis is clinically characterised by high mucous production. The absence of mucous makes this very unlikely. One would also expect crepitations which change in character on coughing.

C Congestive cardiac failure

Heart failure can cause progressive

Heart failure can cause progressive shortness of breath, especially in patients who have a smoking history and hypertension. It can also cause cough, but this is generally productive with white or pink sputum. However, the differentiating factor is clubbing. Clubbing is not caused by heart failure.

D	Pulmonary arterial hypertension

Pulmonary arterial hypertension is a rare condition characterised by sustained elevation in pulmonary arterial pressure and pulmonary vascular resistance without any other clear cause. Presentation is with progressive dyspnoea progressing to oedema and ascites, and late stage may be complicated by angina and arrhythmia. Clinically, one can expect a right ventricular heave, loud second heart sound and raised jugular venous pressure (JVP) on examination. The absence of these findings and the presence of clubbing make this unlikely.

absence of these findings and the presence of clubbing make this unlikely.

E	Pulmonary embolism

Pulmonary embolism is an obstruction of the pulmonary artery due to thrombosis, fat, amniotic fluid or air. Presentation is with sudden dyspnoea, pleuritic chest pain, cough and haemoptysis. It is not a cause of clubbing and would be unlikely to cause the slow progression of symptoms or the presence of crepitations bilaterally. It could be considered if there was further evidence of malignancy and the symptoms were more sudden in their nature, as the clubbing could then be associated with a malignancy.

71598

Rate this question:

A 30-year-old woman complains of severe headache, mainly in the occipital region, as well as irritability, low mood and lack of energy. Her husband informs you that he has noted her to be withdrawn and short-tempered. She also gives a history of a recent increase in hair loss, and joint pains, predominantly in the wrist and knees. She has had amenorrhoea for the last 3 months. She works as a secretary, and is now finding it extremely difficult to cope with both her work and household activities. She and her husband are requesting sick leave.

On examination, she looks unwell. Her temperature is 37.5 °C, she is pale and there is an erythematous rash on her face. Joint examination is remarkable for tenderness in the wrists and knees, but no swelling. Cardiovascular, respiratory and abdominal examination are unrevealing. Neurological examination does not show focal neurological signs or neck stiffness.

Investigations:

neurological signs or neck stiffness.

Investigations:

Hb	9.7 g/dl
WCC	3.8×10^9/l
PLT	188×10^9/l
Neutrophils	2.1×10^9/l
Lymphocytes	0.8×10^9/l
ESR	88 mm/1st h
CRP	8.0 mg/l
AST	44 IU/l
ALP	156 IU/l
ALT	50 IU/l
ANA	+
DNA and ENA	Awaited
Urine dipstick	Protein trace

What is the most likely clinical problem that may explain the above?

ALP	156 IU/l
ALT	50 IU/l
ANA	+
DNA and ENA	Awaited
Urine dipstick	Protein trace

What is the most likely clinical problem that may explain the above?

A Neuropsychiatric lupus

B Viral meningitis

C Lupus glomerulonephritis

D Antiphospholipid antibody syndrome

E Bacterial meningitis

A Neuropsychiatric lupus

This young lady is in the right demographic to suspect systemic lupus erythematosus (SLE), which is suggested by polyarthralgia, hair fall, facial rash and positive ANA. However, the symptoms of headache and mood changes point towards the possibility of neuropsychiatric lupus. Features of neurological disease in lupus range from the common, relatively harmless migraine headache, to major psychotic episodes and grand mal seizures, recognised in some lupus patients. Amenorrhoea is sometimes observed with neuropsychiatric lupus, and may be due to either interference with gonadotrophin release or associated autoimmune ovarian failure.

B Viral meningitis

The history is too protracted, and the non-neurological features (facial rash, hair fall) are more suggestive of connective tissue disease and do not

fit with viral meningitis.

C	Lupus glomerulonephritis

Lupus glomerulonephritis cannot be completely excluded, but active urinary sediment with proteinuria ++ on dipstick will be more suggestive.

D	Antiphospholipid antibody syndrome

Antiphospholipid antibody syndrome (APLS) can cause headaches and migraines, but also dural sinus thrombosis. APLS should be considered, but is less likely as her platelets are normal and she has psychological features in addition to her severe headache.

E	Bacterial meningitis

The history is too protracted, her CRP is normal and there is no meningism.

A 60-year-old man presents with variable dysphagia, first to liquids, then to solids, then either intermittently. He has no other significant past medical history, but has been feeling rather fatigued over the past few months and has asked to be transferred from his manual job at the local warehouse, to a computer-based alternative.

On examination, he has a purple/red rash on his face. He finds it difficult to get up out of the chair, but says that this is because he is tired after walking to outpatients from the main hospital car park. His blood pressure is 145/82 mmHg and his BMI is 31; there are no other abnormal findings on clinical examination.

Investigations:

Hb	12.1 g/dl
WCC	7.2×10^9/l
PLT	201×10^9/l
Na^+	141 mmol/l

Na^+	141 mmol/l
K^+	4.6 mmol/l
Creatinine	130 µmol/l
Antinuclear antibody (ANA)	Positive

Which of the following is the most likely diagnosis?

A	Polymyositis
B	Oesophageal cancer
C	Scleroderma
D	Systemic lupus erythematosus (SLE)
E	Dermatomyositis

E Dermatomyositis

This patient has muscle weakness, dysphagia (due to muscle weakness) and facial rash. The ANA may be positive (40–80% of cases). Approximately 20% of patients have myositis-specific autoantibodies (such as anti-Jo 1 antibodies). The creatine kinase (CK) is usually elevated, as may alanine aminotransferase (ALT) (may be muscle not liver). Skin and muscle biopsies are diagnostic.

A Polymyositis

The facial rash makes the diagnosis derm (skin)-atomyositis. This is a very important learning point – essentially polymyositis is clinically almost identical to dermatomyositis, but there is no rash.

B Oesophageal cancer

The intermittent nature of the symptoms seen here goes against

symptoms seen here goes against oesophageal carcinoma, as does the absence of weight loss; these aspects with the initial dysphagia to liquids make the diagnosis unlikely.

C	Scleroderma

Scleroderma is unlikely because he does not have Raynaud's or skin thickening and the myopathy should make you think of dermatomyositis/polymyositis. Dysphagia in scleroderma is due to osephageal dysmotility.

D	Systemic lupus erythematosus (SLE)

The facial rash might point us towards either SLE or dermatomyositis, but the proximal myopathy seen when he tries to get out of a chair points us more towards the latter diagnosis.

21476

Rate this question:

A 41-year-old woman presents to her general practitioner (GP), complaining of dry eyes, dry mouth and vaginal dryness on sexual intercourse.

There is no significant past medical history; specifically, there is no history of rheumatoid arthritis or connective tissue disease.

Which of the following is a likely clinical feature in this case?

A	4 mm wetting per 5 minutes on Schirmer's testing
B	Hypersalivation
C	Negative anti-Ro antibodies
D	Negative antinuclear antibodies (ANA)
E	Low oestrogen levels

A	4 mm wetting per 5 minutes on Schirmer's testing

The answer is 4 mm wetting per 5 minutes on Schirmer's testing (Option A).

This woman has Sjögren syndrome, as evidenced by her symptoms of dry mouth and dry eyes and the fact that other mucosal surfaces are affected. It may be primary or secondary (related to other autoimmune conditions). There is plasma cell infiltration of salivary and lacrimal glands with positive anti-Ro and anti-La antibodies, and a definitive positive Schirmer's test is defined as <5 mm wetting per 5 minutes. Treatment involves use of artificial tears and screening for ophthalmic (corneal dryness and ulceration) and dental (caries) complications.

B	Hypersalivation

Hypersalivation (Option B) is incorrect.

You review a 62-year-old man in the Cardiology Clinic, some 6 weeks after his admission for acute myocardial infarction. He was commenced on lipid-lowering therapy with simvastatin after his myocardial infarction, in addition to other medications including ramipril 10 mg daily and aspirin 75 mg, which he has taken for several years. Since his myocardial infarction he has been increasing his exercise, but is complaining of pains in the joints and muscles, general malaise and a skin rash.

Blood testing reveals:

Anti ds-DNA antibodies	Negative
Anti-histone antibodies	Positive
C3/C4 levels	Normal

You suspect a diagnosis of lupus.

Which of the following represents the most appropriate course of action?

A	Withdraw his ramipril

Anti ds-DNA antibodies	Negative
Anti-histone antibodies	Positive
C3/C4 levels	Normal

You suspect a diagnosis of lupus.

Which of the following represents the most appropriate course of action?

A	Withdraw his ramipril
B	Withdraw his simvastatin
C	Withdraw his aspirin
D	Start prednisolone 30mg PO daily for 6 weeks
E	Observe for resolution of symptoms over time

18559

Submit

You review a 62-year-old man in the Cardiology Clinic, some 6 weeks after his admission for acute myocardial infarction. He was commenced on lipid-lowering therapy with simvastatin after his myocardial infarction, in addition to other medications including ramipril 10 mg daily and aspirin 75 mg, which he has taken for several years. Since his myocardial infarction he has been increasing his exercise, but is complaining of pains in the joints and muscles, general malaise and a skin rash.

Blood testing reveals:

Anti ds-DNA antibodies	Negative
Anti-histone antibodies	Positive
C3/C4 levels	Normal

You suspect a diagnosis of lupus.

Which of the following represents the most appropriate course of action?

B Withdraw his simvastatin

This man has just been started on many medications and has positive anti-histone antibodies. There is a suspicion that this man has drug-induced lupus. Generally symptoms are said to appear some 3 weeks to 2 years after the onset of therapy, making his simvastatin the most likely culprit in this case. Drug-induced lupus is said to affect the 50–70 year age group most commonly, has a male:female ratio of 1:1 and affects Caucasians more commonly than other populations. Skin rash is seen in around 25% of sufferers, joint pains and malaise are more common, and Raynaud's is seen in around 25%. Anti-histone antibodies are more likely to be positive in drug-induced lupus versus non-drug-induced lupus; anti-ds DNA antibodies are less likely to be positive. C3/C4 levels are usually normal. Drugs which may directly cause lupus include simvastatin, captopril, valproate, penicillamine, carbamazepine, methyldopa,

cause lupus include simvastatin, captopril, valproate, penicillamine, carbamazepine, methyldopa, procainamide, minocycline, griseofulvin and a host of other agents. Treatment is withdrawal of the offending medication, with rapid clinical resolution normally apparent.

D	Start prednisolone 30mg PO daily for 6 weeks

The patient's symptoms are likely to resolve with withdrawal of the culprit drug, without the need for such high-dose steroids.

A	Withdraw his ramipril

Ramipril does not commonly cause a drug-induced lupus.

C	Withdraw his aspirin

Aspirin is not commonly associated with drug-induced lupus.

A 40-year-old man is attending the Rheumatology Clinic because of a several months history of pain and stiffness in his hands. The patient denies any history of rash, dry mouth or dry eyes. There is also no history of unprotected intercourse. The patient does describe a tendency towards constipation recently but denies any other gastrointestinal problems.

His medications include an acute prescription of co-codamol and ramipril for his well controlled hypertension.

On examination, there is tenderness to the right wrist with most distal interphalangeal joints being affected with tenderness and mild swelling.

A photograph of the appearance is shown below:

What is the most likely diagnosis?

A	Psoriatic arthropathy
B	Rheumatoid arthritis
C	Systemic sclerosis
D	Systemic lupus erythematosus (SLE)
E	Arthritis of inflammatory bowel disease

A Psoriatic arthropathy

Psoriatic arthropathy most commonly presents as a poly- or oligoarthritis. There are five patterns of involvement: distal arthritis (DIP joint involvement), asymmetric oligoarthritis, symmetric polyarthritis, arthritis mutilans and spondyloarthritis. The nails show pitting and onycholysis (lifting of the nail from the nailbed). The function of the hands is usually good unless the joints are severely inflamed. In about 75% of patients there is a preceding history of psoriasis before the arthropathy; in 15%, the onset of the rash is synchronous and in 10% the arthritis precedes the rash.

B Rheumatoid arthritis

RA rarely affects the DIP joints, as is the case in this patient. Furthermore, there are associated nail changes which would not be consistent with RA.

C	Systemic sclerosis

Systemic sclerosis (SSc) is subcategorised into diffuse cutaneous SSc and limited cutaneous SSc. Limited cutaneous SSc is commonly associated with the CREST syndrome. Skin involvement is a defining feature of SSc, and includes variable thickening and hardening with oedematous swelling and erythema. Fatigue, arthralgia and myalgia are common as well as Raynaud phenomenon. These features are not provided with this patient.

D	Systemic lupus erythematosus (SLE)

SLE is a chronic inflammatory disease that can involve any organ. Arthritis can occur in more than 90% of patients and tends to be migratory, symmetrical and polyarticular. The nail changes seen in the picture are not characteristic.

E	Arthritis of inflammatory

You review a 67-year-old man who has previously been given a diagnosis of osteoarthritis. He presents with acute-on-chronic pain in his first metatarsophalangeal (MTP) joint. He has a past history of hypertension, for which he takes bendroflumethiazide 5 mg per day.

On examination, the joint is hot and red and has a knobbly appearance.

The X-ray is shown below.

By Hellerhoff [CC BY-SA 3.0 (https://creativecommons.org/licenses/by-sa/3.0)], from Wikimedia Commons

Which of the following is the most appropriate long-term management for this patient?

A	Start allopurinol
B	Start ibuprofen
C	Stop bendroflumethiazide and substitute a calcium antagonist
D	Start flucloxacillin
E	Advise dietary restriction of rich foods

C Stop bendroflumethiazide and substitute a calcium antagonist

The X-ray shows erosive changes in the first MTP joint, with well-maintained joint space and coexisting soft tissue swelling. This, along with the presentation, demonstrates that the patient has chronic tophaceous gout, which is usually associated with chronic renal impairment or long-term use of diuretic therapy. Deposits of sodium urate occur in the skin and around joints; larger deposits are unsightly and may ulcerate. Whenever possible, and where the condition is associated with diuretic use, the diuretics should be substituted for another medication.

A Start allopurinol

This patient has chronic tophaceous gout. If a patient is already receiving urate-lowering therapy, then there is no value in suspending it during an

acute flare, and subsequent reintroduction may precipitate an attack. There is no direct benefit to starting urate-lowering therapy in an acute flare, but it should be commenced in the future.

B Start ibuprofen

Non-steroidal anti-inflammatory drugs (NSAIDs) might be beneficial as short-term therapy in flares but should not be continued long term due to their implications in renal function. As bendroflumethiazide discontinuation is the best long-term intervention in this case, Option B is not the preferred answer.

D Start flucloxacillin

The description and radiological findings are not consistent with septic arthritis, and flucloxacillin is not an appropriate empirical antibiotic for this indication.

You are seeing a 21-year-old man with a 3-year history of inflammatory back pain. You make a presumptive diagnosis of ankylosing spondylitis (AS). You order X-rays of the lumbosacral spine, sacroiliac joints and HLA B27.

Which of the following statements is correct with regard to HLA B27?

A	It can be used as screening test for AS in the general population
B	The likelihood of a positive test depends on the racial and ethnic background of the patient
C	The test helps distinguish AS from other spondyloarthropathies
D	HLA B27 is essential for the diagnosis of AS

correct with regard to HLA B27?

A	It can be used as screening test for AS in the general population
B	The likelihood of a positive test depends on the racial and ethnic background of the patient
C	The test helps distinguish AS from other spondyloarthropathies
D	HLA B27 is essential for the diagnosis of AS
E	Acute anterior uveitis is relatively more common in B27-negative than –positive patients

B The likelihood of a positive test depends on the racial and ethnic background of the patient

The sensitivity and specificity of the test depend on the racial and ethnic background of the patient. The prevalence of HLA B27 varies among ethnic groups and races. Inuits have been shown to have the highest frequency of the gene (25–40%), with an overall prevalence of spondyloarthropathies between 2 and 4%. HLA B27 frequency is only 8–9% in people from Holland and Germany. Accordingly, the prevalence of spondyloarthropathies (2%) is lower than in Inuit.

A It can be used as screening test for AS in the general population

Although HLA B27 may be helpful in diagnosis, 10% of the asymptomatic healthy normal population may be HLA

healthy normal population may be HLA B27 positive and therefore it cannot be used as a screening test.

C	The test helps distinguish AS from other spondyloarthropathies

HLA B27 positivity does not distinguish between the axial spondyloarthropathies.

D	HLA B27 is essential for the diagnosis of AS

Most AS patients do not need HLA B 27 testing if they have certain clinical and radiological features. Patients can fulfil the criteria for AS without testing positive for HLA B27.

E	Acute anterior uveitis is relatively more common in B27-negative than –positive patients

Acute anterior uveitis is more common

A 66-year-old woman presents to the clinic with a history of arthralgia affecting the small joints of her hands, feet and wrists for the past 4 months. The pain in her fingers gets worse when she goes out in the cold without gloves. She has been feeling extremely tired. She has noticed an erythematous, non-pruritic rash over both legs.

The examination reveals early synovitis of joints of the hands and feet and raised non-blanching erythematous purpura over the extensor aspects of both legs.

Investigations:

Hb	11.4 g/dl
WCC	4.2×10^9/l
PLT	180×10^9/l
ESR	88 mm/h
CRP	6.7 mg/dl (< 10)
ANA	+
RF	+

CRP	6.7 mg/dl (< 10)
ANA	+
RF	+
C3	Normal
C4	Low

Results of the radiography of hands and feet are awaited.

Which one of the following is the most likely underlying cause of her finger symptoms?

A	Raynaud's
B	Mixed connective tissue disease
C	Cryoglobulinaemia
D	Subacute bacterial endocarditis
E	Polyarteritis nodosa

A 66-year-old woman presents to the clinic with a history of arthralgia affecting the small joints of her hands, feet and wrists for the past 4 months. The pain in her fingers gets worse when she goes out in the cold without gloves. She has been feeling extremely tired. She has noticed an erythematous, non-pruritic rash over both legs.

The examination reveals early synovitis of joints of the hands and feet and raised non-blanching erythematous purpura over the extensor aspects of both legs.

Investigations:

Hb	11.4 g/dl
WCC	4.2×10^9/l
PLT	180×10^9/l
ESR	88 mm/h
CRP	6.7 mg/dl (< 10)
ANA	+
RF	+

C Cryoglobulinaemia

This lady has a purpuric rash, Raynaud's, polyarthralgia with a positive rheumatoid factor (RF) and low C4, suggestive of cyroglobulinaemia with a likely underlying connective tissue disease.

In RA, RF is positive in 70% of patients, whereas in Sjögren syndrome and cryoglobulinaemia it is prevalent in up to 90% of cases.

A Raynaud's

Although this woman does have a colour change suggestive of Raynaud's, the underlying condition driving this condition is cryoglobulinaemia, which is therefore the best fit. Cryoglobulinaemia is also driving a polyarthralgia/polyarthritis.

B Mixed connective tissue disease

We do not know whether she has mixed connective tissue disease as we are not given her anti-RNP antibody status. Cryoglobulinaemia is usually secondary to connective tissue disease, myeloma or infection (most commonly hepatitis C).

D	Subacute bacterial endocarditis

Although some of her symptoms could be explained by a subacute bacterial endocarditis (purpuric rash and even the RF), you would expect the history to be shorter with endocarditis, and also both C3 and C4 to be low.

E	Polyarteritis nodosa

The rash associated with polyarteritis nodosa is livedo reticularis, and one would usually expect mesenteric ischaemia and mononeuritis multiplex, rather than this constellation of symptoms with arthritis.

A 25-year-old woman presents with episodic discoloration of the fingers of both hands – white followed by a bluish tinge – first noticed 2 years ago.

She has otherwise been fit and healthy and denies any previous medical problems.

Which of the following investigations would be most useful in determining whether the Raynaud's is related to vasculitis?

A	Rheumatoid factor (RF) testing
B	Antinuclear antibody testing
C	X-ray of the hands
D	X-ray of the chest
E	Nail fold capillaroscopy

E Nail fold capillaroscopy

This young woman has symptoms of Raynaud's syndrome. It will be important to differentiate between primary and Raynaud's secondary to connective tissue disease (CTD). The most useful initial assessment must include nail fold capillary loop examination, ideally by capillaroscopy or, if not available, by ophthalmoscope using magnification. Patients with CTD such as systemic sclerosis most often will show a positive ANA and dilated, distorted, missed nail fold capillary loops (i.e. with gaps – areas of drop-out).

A Rheumatoid factor (RF) testing

The RF is non-specific and is found in multiple conditions, including infections.

B Antinuclear antibody testing

multiple conditions, including infections.

B	Antinuclear antibody testing

A close second to nail fold capillaroscopy. Measurement of anti-nuclear antibodies, whilst being non-specific, may provide additional clarification for Raynauds.

C	X-ray of the hands

X-rays are likely to be completely normal, even in secondary Rayaud's associated with connective tissue disease.

D	X-ray of the chest

X-ray of the chest is useful to determine whether cervical ribs are present, as a cause of Raynauds, but not to determine any other causes.

33280

Rate this question:

100% 11:12

https://www.google.com/sea 10

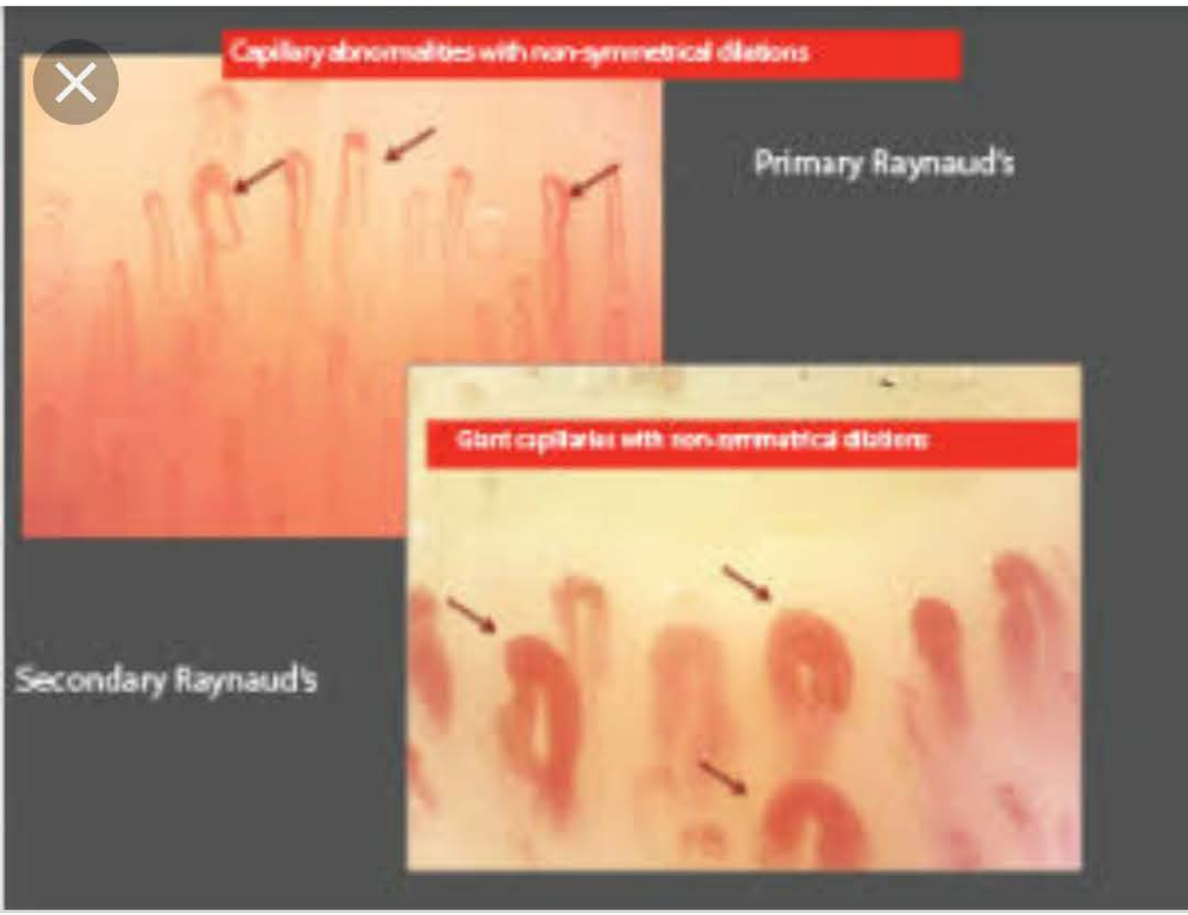

The Rheumatologist

Rheumatologists Find Nailfold Capillaroscopy an Increasingly ...

Early structural changes in a patient with Raynaud's phenomenon (left picture) that should identify

Images may be subject to copyright. Learn More

RELATED IMAGES SEE MORE

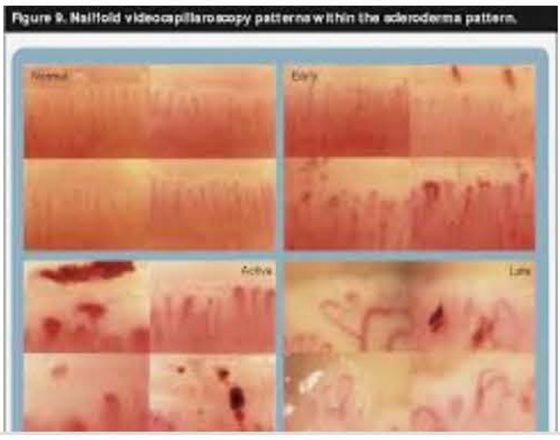

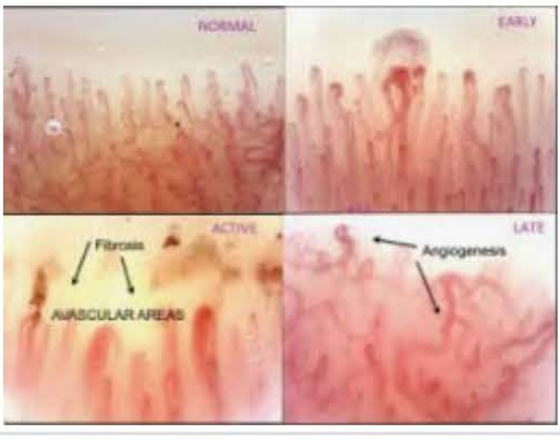

A 44-year-old woman comes to the Rheumatology Clinic complaining of pain, pins and needles and altered sensation over the antero-lateral aspect of the left thigh. The symptoms are made worse by walking or standing, and made better by a period of sitting down. She has no other past medical history of note apart from mild asthma for which she takes a seretide inhaler.

On examination, her BP is 135/80 mmHg, pulse is 62/min and regular. There is minor numbness over the anterior aspect of the left thigh, and deep palpation just below the anterior superior iliac spine reproduces her symptoms. Her BMI is 26. Routine bloods are unremarkable, apart from a fasting plasma glucose of 7.2 mmol/l.

Which of the following is the most likely diagnosis?

A	Diabetic amyotrophy
B	Femoral mononeuropathy

There is minor numbness over the anterior aspect of the left thigh, and deep palpation just below the anterior superior iliac spine reproduces her symptoms. Her BMI is 26. Routine bloods are unremarkable, apart from a fasting plasma glucose of 7.2 mmol/l.

Which of the following is the most likely diagnosis?

A	Diabetic amyotrophy
B	Femoral mononeuropathy
C	Lumbar spine radiculopathy
D	Meralgia paraesthetica
E	Spinal stenosis

70486

Submit

A 44-year-old woman comes to the Rheumatology Clinic complaining of pain, pins and needles and altered sensation over the antero-lateral aspect of the left thigh. The symptoms are made worse by walking or standing, and made better by a period of sitting down. She has no other past medical history of note apart from mild asthma for which she takes a seretide inhaler.

On examination, her BP is 135/80 mmHg, pulse is 62/min and regular. There is minor numbness over the anterior aspect of the left thigh, and deep palpation just below the anterior superior iliac spine reproduces her symptoms. Her BMI is 26. Routine bloods are unremarkable, apart from a fasting plasma glucose of 7.2 mmol/l.

Which of the following is the most likely diagnosis?

Your answer was incorrect

A	Diabetic amyotrophy

D Meralgia paraesthetica

The symptoms here fit well with a diagnosis of MP, which occurs due to entrapment of the lateral cutaneous nerve of thigh. It passes into the thigh through a tunnel formed by the lateral attachment of the inguinal ligament and the anterior superior iliac spine, and it is the crossover into the thigh where entrapment is most likely to occur. Risk factors include obesity and wearing tight, low-waisted trousers, which may compress the nerve.

E Spinal stenosis

Spinal stenosis is associated with claudication-type pain which is relieved by lying down or sitting forward.

A Diabetic amyotrophy

The glucose of 7.2 mmol/l is consistent with early diabetes, particularly as she

forward.

A Diabetic amyotrophy

The glucose of 7.2 mmol/l is consistent with early diabetes, particularly as she is not being treated with any blood glucose-lowering therapy. Diabetic amyotrophy is also associated with muscle wasting, which is not seen here.

B Femoral mononeuropathy

The symptoms are confined to the sensory distribution associated with the lateral cutaneous nerve of the thigh.

C Lumbar spine radiculopathy

This is associated with both motor and sensory symptoms and signs related to a particular nerve root, rather than a specific nerve distribution as seen here.

A 34-year-old, right-handed woman complains of pain in her right wrist which has been evident for 3 months. Recently she has also noted some pain in her left wrist, although of much less severity. She works at a till in a superstore and has been finding it difficult to continue with her job.

The examination reveals a localised swelling and tenderness over the lateral, dorsal aspect of the right wrist and mild tenderness in the left wrist, particularly over the radial aspect. The haematology and biochemistry blood test results are normal.

Which of the following is the most likely diagnosis?

A	De Quervain's tenosynovitis
B	Intersection syndrome
C	Wrist synovitis
D	Ganglion

superstore and has been finding it difficult to continue with her job.

The examination reveals a localised swelling and tenderness over the lateral, dorsal aspect of the right wrist and mild tenderness in the left wrist, particularly over the radial aspect. The haematology and biochemistry blood test results are normal.

Which of the following is the most likely diagnosis?

A	De Quervain's tenosynovitis
B	Intersection syndrome
C	Wrist synovitis
D	Ganglion
E	Trigger thumb

6879

Submit

Recently she has also noted some pain in her left wrist, although of much less severity. She works at a till in a superstore and has been finding it difficult to continue with her job.

The examination reveals a localised swelling and tenderness over the lateral, dorsal aspect of the right wrist and mild tenderness in the left wrist, particularly over the radial aspect. The haematology and biochemistry blood test results are normal.

Which of the following is the most likely diagnosis?

Your answer was incorrect

A	De Quervain's tenosynovitis
B	Intersection syndrome
C	Wrist synovitis
D	Ganglion

A De Quervain's tenosynovitis

This lady has tenderness at the thumb-sided tendons – at the radial side of the wrist and at the base of the thumb – and probably has an occupational aetiology given her job as checkout cashier.

De Quervain's tenosynovitis refers to inflammation of the abductor pollicis longus tendon at the wrist joint. It is best diagnosed by inspecting the wrist from the radial side, with the palms together. It is then seen as a unilateral swelling, extending from the first carpometacarpal joint proximally. The diagnosis is confirmed by Finkelstein's test. In this test, the patient is asked to bring the thumb across the palm and clasp the fingers around it. The examiner then pulls it in the ulnar direction, which elicits a sharp pain. This condition is commonly caused by occupational or avocational repetitive movement of the thumb, but has also been associated with RA, psoriatic arthritis, direct trauma, pregnancy and

arthritis, direct trauma, pregnancy and the post-partum period. Treatment options include splinting, steroid injections into the joint and surgical decompression of the tendon tunnel.

C	Wrist synovitis

This lady has localised swelling at the radial side (not the whole wrist). Wrist synovitis is inflammation of the wrist joint and therefore the whole wrist would be swollen diffusely.

B	Intersection syndrome

This lady has irritation at the first dorsal compartment. Intersection syndrome is a painful condition that affects the thumb side of the forearm when inflammation occurs at the intersection of the muscle bellies of the abductor pollicis longus and extensor pollicis brevis crossing over the extensor carpi radialis longus and the extensor carpi radialis brevis. These 1st and 2nd dorsal muscle compartments

abductor pollicis longus and extensor pollicis brevis crossing over the extensor carpi radialis longus and the extensor carpi radialis brevis. These 1st and 2nd dorsal muscle compartments intersect at this location, hence the name. The mechanism of injury is usually repetitive resisted extension, as with rowing, weight-lifting or pulling.

D	Ganglion

A ganglion is a discrete, palpable lump.

E	Trigger thumb

A trigger digit is a common disorder characterised by catching, snapping or locking of the involved finger flexor tendon, associated with dysfunction and pain.

6879

Rate this question:

A 20-year-old man presents with a 1-month history of intermittent fever accompanied by chest pain, which is worse on lying down. He has recently also noticed pain in the joints of his hands and feet.

He is febrile, with a temperature of 39 °C. His pulse is 98/min and his blood pressure is 110/70 mmHg. The positive findings on examination are enlarged anterior cervical lymph nodes, pericardial rub, mild hepatomegaly and synovitis of the proximal interphalangeal (PIP) and wrist joints.

Investigations:

Hb	10.5 g/dl
WBC	20 x 10 ^{9}/l
PLT	540 x 10^{9}/l
ESR	110 mm/1st hr
CRP	246 mg/l
ALT	69 IU/l
ALK-P	246 IU/l

Ferritin	4567 µg/l (normal range 14 – 200 µ/l)
CXR	Cardiomegaly
2-D echocardiogram	Pericardial effusion
MSU and blood culture	-
ANA, RF, ANCA	All -
CT abdomen	Hepatosplenomegaly

Which of the following is most likely diagnosis?

A	Systemic lupus erythematosus (SLE)
B	Mixed connective tissue disease (MCTD)
C	Undifferentiated connective tissue disease (UCTD)

MSU and blood culture	-
ANA, RF, ANCA	All -
CT abdomen	Hepatosplenomegaly

Which of the following is most likely diagnosis?

A	Systemic lupus erythematosus (SLE)
B	Mixed connective tissue disease (MCTD)
C	Undifferentiated connective tissue disease (UCTD)
D	Rheumatoid arthritis (RA)
E	Adult-onset Still's disease

6881

Submit

E Adult-onset Still's disease

This man has a long history of fever, arthritis, lymphadenopathy, serositis and hepatosplenomegaly consistent with Still's disease. Clinical features of adult-onset Still's disease include arthralgia or arthritis; a high fever (>39°C), especially in the afternoon and evening; fleeting salmon-pink maculopapular rash which is most prominent with fever; serositis; anaemia; elevated acute phase reactants; and evidence of reticuloendothelial activation. In between the febrile episodes the patient feels rather well. The laboratory investigations commonly reveal leucocytosis, thrombocytosis, markedly raised serum ferritin and an elevated erythrocyte sedimentation rate and C-reactive protein. Autoantibodies are negative.

A Systemic lupus erythematosus (SLE)

A very high fever, raised CRP, organomegaly and negative ANA make SLE very unlikely. SLE is associated with a normal CRP and an elevated ESR. The presenting symptoms in SLE can be very variable due to the condition having multi-system effects ranging from indolent to fulminant, but the classic presentation is of the triad of arthralgia, fever and malar rash in a woman of child-bearing age.

B	Mixed connective tissue disease (MCTD)

A very high fever, raised CRP, organomegaly and negative ANA make MCTD very unlikely. MCTD is a term used to describe a condition that features overlap of autoimmune connective tissue disorders with certain laboratory findings to match. It is recognised to consist of the following core features:

- Raynauds
- Sclerodactily

- Raynauds
- Sclerodactily
- Arthritis/arthralgia
- Acrosclerosis
- Myositis
- Oesophageal dysmotility
- Pulmonary hypertension
- Lung fibrosis
- Raised anti–U1-RNP antibodies
- Antibodies against U1-70 kd small nuclear ribonucleoprotein (snRNP).

C	Undifferentiated connective tissue disease (UCTD)

A very high fever, raised CRP, organomegaly and negative ANA make connective tissue disease very unlikely. The term UCTD is used to describe patients who have symptoms of autoimmune disorders or connective tissue disease with particular laboratory findings to match, but who do not meet all the diagnostic criteria

The term UCTD is used to describe patients who have symptoms of autoimmune disorders or connective tissue disease with particular laboratory findings to match, but who do not meet all the diagnostic criteria for the more well-defined conditions.

UCTD symptoms are similar to those of MCTD, but there are no antibodies to snRNP present.

D	Rheumatoid arthritis (RA)

This patient has a very high fever and his RF and CCP are negative, making RA very unlikely. Rheumatoid arthritis is a symmetrical autoimmune polyarthropathy causing pain, swelling and joint deformity. The patient may complain of morning stiffness and generalised malaise and will have raised inflammatory markers; rheumatoid factor is positive in around 70% of sufferers.

6881

Rate this question:

A 61-year-old man who has a long history of rheumatoid arthritis, currently treated with methotrexate, presents to the Emergency Department with an acute arthritis affecting his right elbow. He tells you he was pruning roses a few days earlier in the garden and wonders whether something may have got into the joint. His rheumatoid disease has been stable for some time on methotrexate, and he takes lisinopril in addition for hypertension.

His BP is 142/72 mmHg, pulse is 90/min and regular and he is pyrexial (38.6 °C). The elbow is erythematous and hot, there is a significant effusion and he is holding the joint in flexion because of pain on minimal movement.

Investigations:

Hb	11.1 g/dl
WCC	15.4×10^9/l
PLT	203×10^9/l
Na^+	137 mmol/l

PLT	203×10^9/l
Na^+	137 mmol/l
K+	4.3 mmol/l
Creatinine	115 μmol/l
CRP	205 mg/l
X-ray elbow	Changes consistent with rheumatoid arthritis

Which of the following is the most important next step?

A	Aspiration of joint
B	IV Flucloxacillin
C	Serum urate testing
D	Oral naproxen
E	IV Co-amoxiclav

stable for some time on methotrexate, and he takes lisinopril in addition for hypertension.

His BP is 142/72 mmHg, pulse is 90/min and regular and he is pyrexial (38.6 °C). The elbow is erythematous and hot, there is a significant effusion and he is holding the joint in flexion because of pain on minimal movement.

Investigations:

Hb	11.1 g/dl
WCC	15.4×10^9/l
PLT	203×10^9/l
Na^+	137 mmol/l
K+	4.3 mmol/l
Creatinine	115 μmol/l
CRP	205 mg/l
X-ray elbow	Changes consistent with rheumatoid arthritis

Which of the following is the most important next step?

A Aspiration of joint

This patient has septic arthritis until proven otherwise. As such, it is essential that the diagnosis and likely pathogen are confirmed by joint aspiration.

B IV Flucloxacillin

Blind antibiotic use in a patient taking immunosuppression is ill advised. The joint should be aspirated and then broad-spectrum antibiotics started, pending sensitivities.

C Serum urate testing

Serum urate may be elevated, but it would not divert you from joint aspiration to rule out septic arthritis.

D Oral naproxen

Of course this patient needs analgesia, but the most important part of

C Serum urate testing

Serum urate may be elevated, but it would not divert you from joint aspiration to rule out septic arthritis.

D Oral naproxen

Of course this patient needs analgesia, but the most important part of management is to aspirate the joint for a diagnosis.

E IV Co-amoxiclav

After joint aspiration, broad-spectrum antibiotics (usually benzylpenicillin and flucloxacillin) are started to cover joint sepsis.

36521

Rate this question:

Next Question

A 64-year-old patient with a long history of rheumatoid arthritis attends the clinic for review. She is managed on low-dose methotrexate, folic acid and non-steroidal anti-inflammatory agents for her disease, but has noticed a worsening in her rheumatoid nodules over the past few months and has developed dry eyes most recently.

On examination, she has splenomegaly.

Investigations reveal a low total white count of 3.4×10^9/l; she is also anaemic, with haemoglobin of 9.8 g/dl and a platelet count of 105×10^9/l.

Which of the following interventions would be most appropriate initially in this case?

A	Stop methotrexate therapy
B	Folinic acid rescue
C	Splenectomy
D	Busulphan

agents for her disease, but has noticed a worsening in her rheumatoid nodules over the past few months and has developed dry eyes most recently.

On examination, she has splenomegaly.

Investigations reveal a low total white count of 3.4×10^9/l; she is also anaemic, with haemoglobin of 9.8 g/dl and a platelet count of 105×10^9/l.

Which of the following interventions would be most appropriate initially in this case?

A	Stop methotrexate therapy
B	Folinic acid rescue
C	Splenectomy
D	Busulphan
E	Pulsed corticosteroid therapy

A 64-year-old patient with a long history of rheumatoid arthritis attends the clinic for review. She is managed on low-dose methotrexate, folic acid and non-steroidal anti-inflammatory agents for her disease, but has noticed a worsening in her rheumatoid nodules over the past few months and has developed dry eyes most recently.

On examination, she has splenomegaly.

Investigations reveal a low total white count of 3.4×10^9/l; she is also anaemic, with haemoglobin of 9.8 g/dl and a platelet count of 105×10^9/l.

Which of the following interventions would be most appropriate initially in this case?

Your answer was incorrect

A Stop methotrexate therapy

B Folinic acid rescue

E Pulsed corticosteroid therapy

This patient has Felty syndrome, as evidenced by splenomegaly and worsening of extra-articular manifestations in a patient with a long-standing history of rheumatoid arthritis. This, coupled with the low white count, is highly suggestive of Felty syndrome, which has a 60–70% female predominance and is usually recognised from the fifth decade onwards in patients who have had rheumatoid arthritis for an average of 10 years or more. Pulsed corticosteroid and/or cyclophosphamide therapy may be effective in raising neutrophil counts, as may appropriate switching/intensification of DMARD therapy for the rheumatoid.

B Folinic acid rescue

This is not methotrexate toxicity but Felty syndrome. Folinic acid rescue is the treatment for methotrexate toxicity.

toxicity.

A Stop methotrexate therapy

This is not methotrexate toxicity but Felty syndrome. The key is the worsening of RA features and splenomegaly.

C Splenectomy

Splenectomy is one option in patients with Felty syndrome who fail to respond to medical intervention.

D Busulphan

This patient does not have development of lymphoma, but rather Felty syndrome.

33276

Rate this question:

Next Question

100% 11:29
tps://mypastest.pastest.com

A 62-year-old man attends for review. He has evidence of arthritis affecting the shoulder, elbow, radiocarpal and knee joints bilaterally, with pain also in the left first metatarsophalangeal joint.

An X-ray of the knee is shown below.

By Taokinesis (Pixabay profile) (Pixabay) [CC0 or CC0], via Wikimedia Commons

Aspiration of the left knee reveals calcium pyrophosphate crystals. Serum uric acid level is slightly above the upper limit of normal. Other medical history of note is ulcerative colitis.

What is the most likely diagnosis in this case?

A	Gout
B	Pseudogout
C	Primary osteoarthritis
D	Rheumatoid arthritis
E	Septic arthritis

B Pseudogout

The clinical picture of joint involvement, coupled with X-ray evidence of chondrocalcinosis and synovial fluid pyrophosphate crystals, is strongly suggestive of a diagnosis of pseudogout. The slightly elevated uric acid level and a history of ulcerative colitis are 'red herrings' in this case. Chondrocalcinosis is the deposition of calcium pyrophosphate crystals within the hyaline and fibrous cartilage. On X-ray, this is seen as a calcific appearance within the joint line (as shown above).

Management involves use of simple painkillers and non-steroidal anti-inflammatory agents, coupled with physiotherapy where appropriate. Associated conditions include haemochromatosis and Wilson's disease where there are other symptoms and signs, and it may be worth screening for these concomitant illnesses. Pseudogout has an equal male : female ratio, with the frequency

illnesses. Pseudogout has an equal male : female ratio, with the frequency increasing with advancing age; it is said to affect around 5% of subjects above the age of 30 years.

A Gout

Gout is caused by monosodium urate crystals, which are fine, needle-like and negatively birefringent under polarised light.

C Primary osteoarthritis

Osteoarthritis has a predilection for the knees, hips, interphalangeal joints, first carpometacarpal joints, first metatarsophalangeal joints and apophyseal (facet) joints of the lower cervical and lower lumbar spine. It is not associated with calcium pyrophosphate crystals.

D Rheumatoid arthritis

There is no suggestion of morning

cervical and lower lumbar spine. It is not associated with calcium pyrophosphate crystals.

D	Rheumatoid arthritis

There is no suggestion of morning stiffness in this case history, and the distribution of affected joints and presence of calcium pyrophosphate crystals make rheumatoid arthritis unlikely.

E	Septic arthritis

Acute monoarticular gout can be indistinguishable from septic arthritis in the history and clinical examination, and in some cases, these coexist. However, the identification of calcium pyrophosphate crystals and no mention of inflammatory cells in the synovial fluid make this answer incorrect.

6420

Rate this question:

A 25-year-old woman presents to Accident and Emergency with a 1-month history of joint pains and sore, red eyes. She has no significant past medical history and is taking no medication.

Examination reveals normal cardiovascular, respiratory and abdominal systems. Joint examination reveals tenderness in her knees, but mainly her ankle joints with a reduced range of movement and swelling.

Examination of the lower limbs reveals a raised, red, tender rash on both shins. Her chest X-ray is shown below.

Investigations:

Na^+	140 mmol/l
K^+	4.5 mmol/l
Urea	5.0 mmol/l
Creatinine	60 µmol/l
Bilirubin	12 µmol/l
APL	100 U/l
ALT	35 U/l
Corr. Ca^{++}	2.70 mmol/l (2.2-2.6)
WCC	10×10^9/l
HB	13 g/dl

ALT	35 U/l
Corr. Ca^{++}	2.70 mmol/l (2.2-2.6)
WCC	10×10^9/l
HB	13 g/dl
PLT	170×10^9/l

What is the most likely diagnosis?

A	Inflammatory bowel disease
B	Sarcoidosis
C	Primary hyperparathyroidism
D	Secondary hyperparathyroidism
E	Tertiary hyperparathyroidism

2319

Submit

Examination reveals normal cardiovascular, respiratory and abdominal systems. Joint examination reveals tenderness in her knees, but mainly her ankle joints with a reduced range of movement and swelling.

Examination of the lower limbs reveals a raised, red, tender rash on both shins. Her chest X-ray is shown below.

Investigations:

Na^+	140 mmol/l
K^+	4.5 mmol/l
Urea	5.0 mmol/l

B Sarcoidosis

Sarcoidosis is correct because this lady has ankle synovitis (which is quite classical for sarcoidosis), erythema nodosum, uveitis and hypercalcaemia, and bihilar lymphadenopathy on chest X-ray. NB: Löfgren syndrome is an acute form of sarcoidosis with erythema nodosum, bihilar lymphadenopathy and polyarthralgia or polyarthritis. Serum angiotensin-converting enzyme (ACE) may be elevated, but this is non-specific for sarcoidosis. Across the range of patients with sarcoidosis, hypercalcaemia is seen in up to 20%.

A Inflammatory bowel disease

Although inflammatory bowel disease may be associated with a seronegative enteropathic arthritis and erythema nodosum, it is rare in the absence of any bowel symptoms. The serum calcium is also out of keeping with a diagnosis of inflammatory bowel disease

100% 11:33
Taking scrolling screenshot · ·
Touch scrolling area to end

PLT	450 × 10^9/l (15–400 × 10^9/l)
ESR	67mm/1st hour
CRP	45 mg/l
AST	33 IU/l (6–34 IU/l)
ALK-P	313 IU/l (25–110 IU/l)

You order an autoantibody screen and X-ray of the hands and feet.

What is the most likely diagnosis?

A	Early rheumatoid arthritis (RA)
B	Recurrent symmetrical seronegative arthritis with pitting oedema (RSSPE)
C	Early scleroderma
D	Osteoarthritis
E	Reflex sympathetic dystrophy syndrome (RSDS)

100% 11:35

tps://mypastest.pastest.com 10

A 32-year-old woman presents with a history of pain and swelling accompanied by early morning stiffness of 30 min affecting her hands and feet. She had been fit and healthy until the onset of joint symptoms 10 weeks ago.

The findings of examination of her hands are shown in the image below.

Investigations:

Hb	121 g/l (> 120 g/l)
WBC	10.5×10^9/l ($4–11 \times 10^9$/l)
PLT	450×10^9/l ($15–400 \times 10^9$/l)

PLT	450 × 10^9/l (15–400 × 10^9/l)
ESR	67mm/1st hour
CRP	45 mg/l
AST	33 IU/l (6–34 IU/l)
ALK-P	313 IU/l (25–110 IU/l)

You order an autoantibody screen and X-ray of the hands and feet.

What is the most likely diagnosis?

A Early rheumatoid arthritis (RA)

B Recurrent symmetrical seronegative arthritis with pitting oedema (RSSPE)

C Early scleroderma

D Osteoarthritis

E Reflex sympathetic dystrophy

A 32-year-old woman presents with a history of pain and swelling accompanied by early morning stiffness of 30 min affecting her hands and feet. She had been fit and healthy until the onset of joint symptoms 10 weeks ago.

The findings of examination of her hands are shown in the image below.

Investigations:

Hb	121 g/l (> 120 g/l)
WBC	10.5×10^9/l ($4–11 \times 10^9$/l)
PLT	450×10^9/l ($15–400 \times 10^9$/l)
ESR	67mm/1st hour

A Early rheumatoid arthritis (RA)

Symmetric involvement of the hands is the hallmark of RA. In early disease, there may be swelling of the wrists, MCP or PIP joints, but no deformity. The above symptoms and signs, in association with an acute phase response, are strongly suggestive of early RA in this patient. Treatment includes early aggressive DMARD therapy, analgesics and anti-inflammatories, a physiotherapy and occupational therapy assessment, and education on RA as well as on the side effects and monitoring of disease-modifying anti-rheumatic drugs (DMARDs).

B Recurrent symmetrical seronegative arthritis with pitting oedema (RSSPE)

RSSPE presents with oedema of the hands and feet, along with synovitis, and it most commonly occurs in older

and it most commonly occurs in older adults. There is coexistent malignancy in 16–30% of patients, including from haematological (leukaemia, myelodysplastic syndrome and lymphoma) and solid tumours (prostate, breast, gastrointestinal, lung, ovarian, bladder and endometrial).

C	Early scleroderma

There are no reported skin changes in keeping with scleroderma.

D	Osteoarthritis

The patient's age and degree of morning stiffness are not consistent with osteoarthritis.

E	Reflex sympathetic dystrophy syndrome (RSDS)

This syndrome usually only affects one extremity and describes a continuing (spontaneous and/or evoked) regional pain that is disproportionate in time or

C	Early scleroderma

There are no reported skin changes in keeping with scleroderma.

D	Osteoarthritis

The patient's age and degree of morning stiffness are not consistent with osteoarthritis.

E	Reflex sympathetic dystrophy syndrome (RSDS)

This syndrome usually only affects one extremity and describes a continuing (spontaneous and/or evoked) regional pain that is disproportionate in time or degree to the usual course of any known trauma or other lesion. The pain is regional (not in a specific nerve territory or dermatome) and usually has a distal predominance of abnormal sensory, motor, sudomotor, vasomotor and/or trophic findings.

6892

Rate this question:

11:38

:tps://mypastest.pastest.com

A 44-year-old woman is referred to the ENT Department with recurrent sinusitis. She also has chronic joint pain and generalised malaise.

Blood testing reveals urea of 14.2 mmol/l and creatinine of 310 μmol/l.

Which one of the following is most likely to support the suspected diagnosis of Granulomatosis with polyangiitis (Wegener's granulomatosis)?

A	Positive c-ANCA
B	Thrombocytopaenia
C	Polycythaemia
D	Micro-aneurysms on renal biopsy
E	C-reactive protein (CRP) in

A Positive c-ANCA

Wegener's granulomatosis, or granulomatosis with polyangiitis (GPA), is a systemic vasculitis identified by a triad of systemic necrotising angiitis, necrotising granulomatous inflammation of the respiratory tract and necrotising glomerulonephritis. Features include positive c-ANCA (anti-neutrophil cytoplasmic antibodies), thrombocytosis, raised erythrocyte sedimentation rate (ESR) and C-reactive protein (CRP) and granulomatous inflammation on renal or lung biopsy. Treatment is with a combination of high-dose corticosteroids and cyclophosphamide (or rituximab) to induce remission, followed by oral corticosteroids and a suitable second-line steroid-sparing agent.

B Thrombocytopaenia

In GPA one would expect a

B Thrombocytopaenia

In GPA one would expect a thrombocytosis (high platelet count), which is reactive to inflammation.

C Polycythaemia

In GPA, one would expect an anaemia, normocytic due to anaemia of chronic disease.

D Micro-aneurysms on renal biopsy

Micro-aneurysms are found in polyarteritis nodosa.

E C-reactive protein (CRP) in the normal range

In GPA, ESR and CRP are usually both elevated.

33269

Rate this question:

A 59-year-old woman with a long history of asthma comes to the clinic for review. She previously had a myocardial infarction, aged 51. She is currently taking 500 μg fluticasone inhaled bd and salbutamol prn. She complains of a further exacerbation and you prescribe her oral prednisolone. This is her eighth course of oral steroids over the past 3 years.

Other past medical history of note includes vertebral fractures diagnosed after an episode of acute pain some 3 months ago. On auscultation of her chest you can hear wheeze throughout both lung fields.

Investigations:

Hb	12.3 g/dl
WCC	5.3×10^9/l
PLT	201×10^9/l
Na^+	139 mmol/l
K^+	4.5 mmol/l
Creatinine	120 μmol/l

PLT	201×10^9/l
Na^+	139 mmol/l
K^+	4.5 mmol/l
Creatinine	120 μmol/l
eGFR	57
T score	- 2.6

Which of the following is the most appropriate therapy for her osteoporosis?

A Teriparatide

B Ibandronate

C Alendronate

D Strontium

E Calcium and vitamin D

C Alendronate

Guidelines for osteoporosis recommend prescription of a weekly generic bisphosphonate in the first instance. For patients who fail to tolerate a weekly preparation, monthly oral or more intermittent IV preparations may be appropriate. Strontium and teriparatide are reserved for patients with more severe osteoporosis. Her asthma therapy should be reviewed, with consideration of a long acting beta agonist. See also SIGN guideline on osteoporosis.

A Teriparatide

While teriparatide does have some evidence for osteoporotic vertebral fractures, current NICE guidelines recommend bisphonates first and teriparatide is reserved for more severe osteoporosis.

B Ibandronate

B	Ibandronate

Guidelines recommend a weekly oral bisphosphonate first, before an alternative of a different frequency. Ibandronate is given intravenously every 3 months.

D	Strontium

Strontium is relatively contraindicated in patients with previous myocardial infarctions, or other thromboembolic diseases (eg pulmonary emboli) as it can increase the thrombotic risk.

E	Calcium and vitamin D

This patient is on glucocorticoids and has a fragility fracture (vertebral) and is osteoporotic on her DEXA scan (T score <–2.5). She therefore does need therapy and bone protection and calcium and vitamin D is insufficient on its own.

21567

Rate this question:

A 43-year-old woman is referred to the Rheumatology Clinic for review. She is noted by her GP to have Raynaud's phenomenon, calcinosis and thickening of the skin affecting her fingers, and telangiectasiae around her mouth and over her upper body. The GP suspects systemic sclerosis. You confirm the clinical features on examination, and her BP is 155/82 mmHg.

Investigations:

Hb	13.1 g/dl
WCC	7.2×10^9/l
PLT	199×10^9/l
Na^+	137 mmol/l
K^+	4.5 mmol/l
Creatinine	122 µmol/l
ANA	+

Creatinine	122 µmol/l
ANA	+
Anti-RNA polymerase III antibody	+
Urine	Protein+

Which of the following is she at risk of developing?

A	CREST syndrome
B	Features of rheumatoid arthritis
C	Limited cutaneous disease only
D	Pulmonary fibrosis
E	Scleroderma renal crisis

telangiectasiae around her mouth and over her upper body. The GP suspects systemic sclerosis. You confirm the clinical features on examination, and her BP is 155/82 mmHg.

Investigations:

Hb	13.1 g/dl
WCC	7.2 × 10^9/l
PLT	199 × 10^9/l
Na^+	137 mmol/l
K^+	4.5 mmol/l
Creatinine	122 µmol/l
ANA	+
Anti-RNA polymerase III antibody	+
Urine	Protein+

E Scleroderma renal crisis

Different auto-antibody patterns are associated with differing patterns of disease associated with systemic sclerosis. Anti-nuclear antibody (ANA) tests positive in approximately 95% of patients with SSc, and therefore a negative test should prompt consideration of other fibrosing illnesses. Anti-RNA polymerase III antibodies are found in patients with diffuse disease, and are associated with rapidly progressive skin involvement as well as an increased risk for scleroderma renal crisis. These patients may also be at increased risk for cancer.

A CREST syndrome

CREST syndrome is a term no longer used, as not all patients fulfil the entire mnemonic. Rather, the 'limited cutaneous' terminology is preferred.

B Features of rheumatoid

B Features of rheumatoid arthritis

Even if she had a rheumatoid factor (RF), this is non-specific and does not indicate propensity to develop features of rheumatoid arthritis.

C Limited cutaneous disease only

Anti-centromere antibodies are usually associated with limited cutaneous systemic sclerosis, and these patients are more likely to have pulmonary hypertension and gastrointestinal involvement.

D Pulmonary fibrosis

Anti-Scl-70 antibody is generally associated with diffuse cutaneous systemic sclerosis and a higher risk of severe interstitial lung disease.

40119

Rate this question:

A 48-year-old woman presents to her general practitioner complaining of symptoms of pain and tingling in her hands, which is particularly worse at night. She has an unremarkable past medical history.

On examination, Tinel's sign is positive and there is some vague sensory loss over a median nerve distribution; there is also some weakness of the muscles of the thenar eminence.

Which ONE of the following conditions is most likely to be the cause of this problem?

A	Hypothyroidism
B	Anorexia nervosa
C	Hyperthyroidism
D	Addison's
E	Menopause

medical history.

On examination, Tinel's sign is positive and there is some vague sensory loss over a median nerve distribution; there is also some weakness of the muscles of the thenar eminence.

Which ONE of the following conditions is most likely to be the cause of this problem?

Your answer was correct

A	Hypothyroidism
B	Anorexia nervosa
C	Hyperthyroidism
D	Addison's
E	Menopause

Explanation

A Hypothyroidism

This patient has symptoms of carpal tunnel syndrome, with pain and tingling at night, thenar eminence wasting and positive Tinel's sign (reproduction of pain and tingling on tapping over median nerve). Associated conditions include hypothyroidism, raised oestrogen levels (oral contraceptive pill or pregnancy), Cushing syndrome and obesity, amongst a number of additional related diseases. Treatment of choice for carpal tunnel syndrome is surgery, although in patients who are surgically unfit, non-steroidal anti-inflammatory drugs, locally injected corticosteroids and nocturnal splints may be usefully employed. Even with treatment of hypothyroidism, or birth of the child, symptoms of carpal tunnel syndrome may not resolve.

B Anorexia nervosa

Obesity is associated with carpal

B Anorexia nervosa

Obesity is associated with carpal tunnel syndrome, due to compression of the median.

C Hyperthyroidism

Hypothyroidism is associated with carpal tunnel syndrome due to excessive soft tissue/collagenous deposition associated with myxoedem.

D Addison's

Cushing syndrome (i.e the 'opposite' of Addison's) is associated with carpal tunnel syndrome.

E Menopause

High oestrogen levels, such as during pregnancy or whilst taking oral contraceptives, are associated with carpal tunnel syndrome.

A 43-year-old man attends for review. His past medical history includes renal stones treated by lithotripsy, and he also has type 2 diabetes. He is taking treatment for high cholesterol. He has been attending the clinic for a number of months with long-standing pain and swelling in his fingers.

This is the clinical appearance of his hands:

Picture courtesy of Charlie Goldberg, M.D., UCSD School of Medicine and VA Medical Center, San Diego, CA

What is the most likely diagnosis?

Picture courtesy of Charlie Goldberg, M.D., UCSD School of Medicine and VA Medical Center, San Diego, CA

What is the most likely diagnosis?

A	Calcinosis
B	Gout
C	Pseudo-gout
D	Psoriatic arthropathy
E	Rheumatoid arthritis

6347

Submit

B Gout

This is chronic gout with tophi (uric acid crystals in the soft tissues), indicating long-standing hyperuricaemia. Untreated chronic tophaceous gout can develop and lead to severe joint destruction. Men are affected twice as commonly as women, and it tends to be a disease of middle to older age; as a general rule, uric acid levels are elevated for 20 years before the onset of gout. Hyperuricaemia is associated with an increase in all-cause mortality. Patients with gout are often clustered within the metabolic syndrome: diabetes, hypertension, hypertriglyceridaemia and low high-density lipoproteins, though no evidence indicates that either gout or hyperuricaemia causes any of these other disorders. The relationship between serum uric acid and cardiovascular disease remains controversial, but raised uric acid may be an independent risk factor for vascular disease in some individuals with other risk factors.

A Calcinosis

Calcinosis cutis is the deposition of insoluble calcium salts in the skin and subcutaneous tissue. White calcium deposits can be seen in nodules, unlike the picture shown here.

C Pseudo-gout

The clinical manifestations of the crystal arthropathies can be difficult to distinguish. However, pseudo-gout tends to occur in older patients and risk factors include hypothyroidism, haemochromatosis, hyperparathyroidism and Wilson's disease. Furthermore, there are risk factors for gout in this patient.

D Psoriatic arthropathy

Psoriatic arthropathy most commonly presents as a poly- or oligoarthritis. There are five patterns of involvement: distal arthritis (DIP joint involvement), asymmetric oligoarthritis, symmetric polyarthritis, arthritis mutilans and

risk factors include hypothyroidism, haemochromatosis, hyperparathyroidism and Wilson's disease. Furthermore, there are risk factors for gout in this patient.

D	Psoriatic arthropathy

Psoriatic arthropathy most commonly presents as a poly- or oligoarthritis. There are five patterns of involvement: distal arthritis (DIP joint involvement), asymmetric oligoarthritis, symmetric polyarthritis, arthritis mutilans and spondyloarthritis. This is not the description provided for this patient.

E	Rheumatoid arthritis

The swelling is more extensive than would be expected for RA, and there is no history of joint stiffness in the history, which makes RA unlikely.

6347

Rate this question:

100% 11:50
tps://mypastest.pastest.com

A 45-year-old woman presents to her general practitioner (GP) complaining of skin dryness with dry and gritty eyes. She also has diminished libido because of increasing vaginal dryness. You arrange for a Schirmer test to be carried out.

Which of the following test results would be useful in the diagnosis of Sjögren syndrome?

A	4 mm of filter strip wetting on Schirmer tear test
B	Positive ANCA
C	Negative rheumatoid factor
D	Positive anti-smooth muscle antibodies
E	Reduced oestrogen levels

A 4 mm of filter strip wetting on Schirmer tear test

The Schirmer tear test involves placement of a standard strip of filter paper on the inside of the lower eyelid. Wetting of <5 mm in 5 min indicates defective tear production. In Sjögren syndrome, Rose Bengal staining of the eyes may show punctuate or filamentary keratitis. Laboratory abnormalities include a polyclonal raised IgG and positive rheumatoid factor. Antinuclear antibodies are found in 60–70% and antimitochondrial antibodies in 10%. Anti-Ro and -La antibodies are found in 70% of patients with primary Sjögren syndrome. Treatment is with artificial tears and saliva-replacement solution.

B Positive ANCA

A positive ANCA (anti-neutrophil cytoplasmic antibody) is associated with certain types of systemic vasculitis, especially Wegener's

polyarteritis. It has no clinical relevance in the diagnosis of Sjögren.

C	Negative rheumatoid factor

Rheumatoid factor is non-specific and may be positive in numerous rheumatological conditions, including Sjögren where up to 70% of patients have a positive result. A negative result would not be helpful in the diagnosis of the condition.

D	Positive anti-smooth muscle antibodies

Positive anti-smooth muscle antibodies are associated with autoimmune hepatitis.

E	Reduced oestrogen levels

Oestrogen levels may be measured to exclude a hormonal cause for vaginal dryness, but will not be useful in the diagnosis of Sjögren. The treatment of vaginal dryness in the setting of

A 42-year-old woman presents with intensely painful fingers on going outdoors during the autumn and winter months. She reports the same problem if she washes her hands in cold water. Her fingers go pale and blue-tinged, and later become erythematous and are burning and prickly.

Examination in the clinic is unremarkable.

Investigations:

Hb	13.7 g/dl
WCC	4.8×10^9/l
PLT	188×10^9/l
Neutrophils	2.1×10^9/l
Lymphocytes	1.8×10^9/l
ESR	18 mm/1st h
CRP	21 mg/l
AST	28 IU/l
ALP	101 IU/l

AST	28 IU/l
ALP	101 IU/l
ALT	15 IU/l
Glucose	5.5 mmol/l
TSH	2.0 mU/l
CK	70 u/l
ANA	-

What is the best initial medical treatment for this lady?

A	Nifedipine MR
B	Atenolol
C	Ramipril
D	Prednisolone
E	Aspirin

A Nifedipine MR

Extensive screening has failed to establish an underlying cause for this lady's Raynaud's, so she has primary Raynaud's phenomenon or Raynaud's disease. Primary Raynaud's is not usually associated with increased mortality or morbidity, although occasionally necrosis of the affected extremity may occur. Clearly, in patients presenting with this symptom picture, it is crucial to carry out an extensive screen for underlying autoimmune or metabolic disease as in this case, as therapy should be tailored to any underlying condition. Primary Raynaud's commonly presents in the second or third decade of life, and prevalence is slightly higher in women than men – put at around 5% depending on case series. Treatment of choice is with vasodilating calcium-channel antagonists such as nifedipine modified/sustained release (MR/SR) or angiotensin II receptor blockers such as losartan.

4G 100% 11:12
https://www.google.com/sea 10

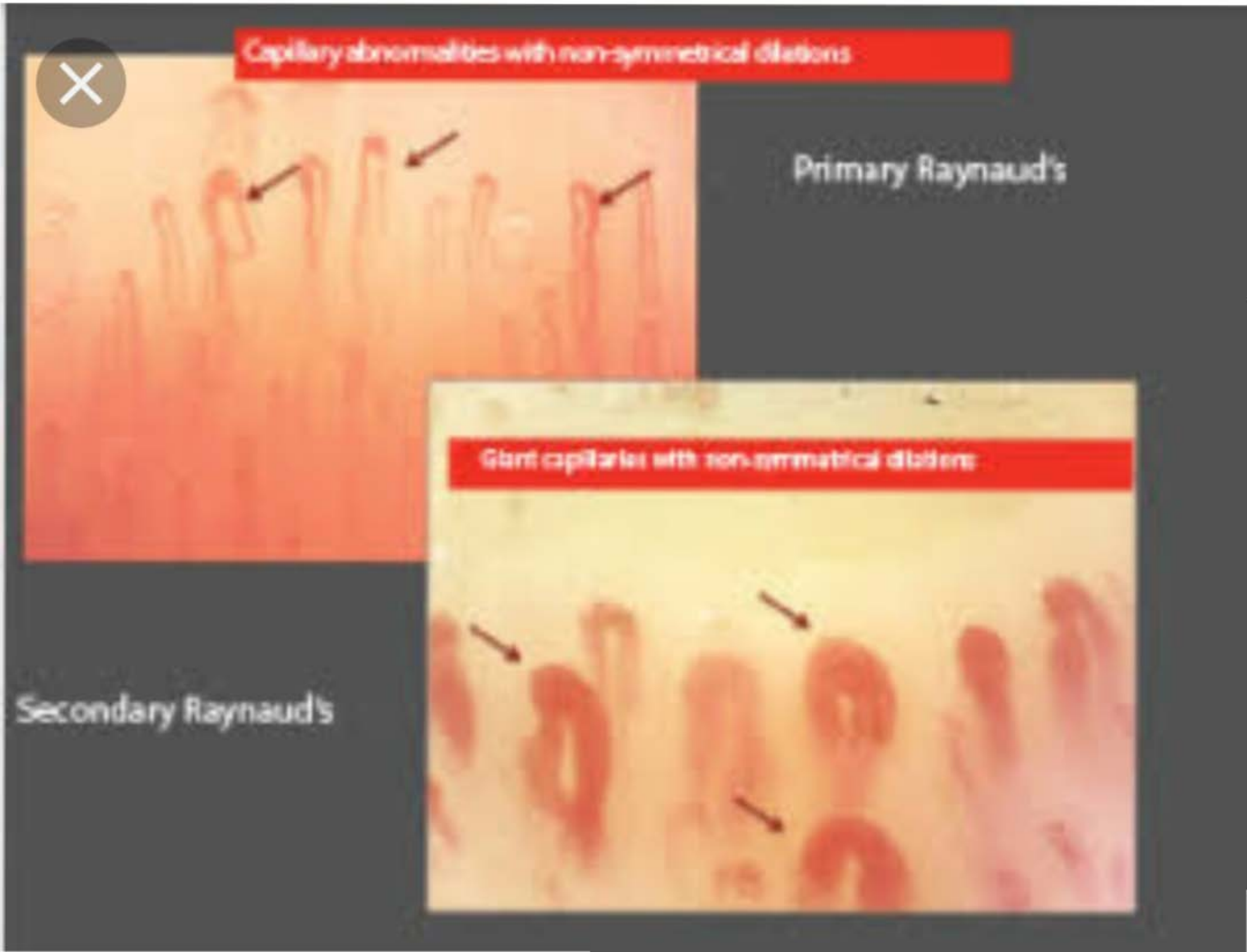

9:40

A 56-year-old woman with known chronic kidney disease (CKD) (usual creatinine 400 μmol/1), secondary to adult polycystic kidney disease, presents with a 2-day history of dysuria, left loin pain, fevers and vomiting.

On examination, she is pyrexial (temperature of 38.5 °C), with left loin tenderness and a pericardial rub. Mucosal surfaces and skin turgor look normal. Her blood pressure is elevated at 162/90 mmHg. You commence her on intravenous (iv) antibiotics.

Investigations show:

Creatinine (Cr)	1200 μmol/l
Electrocardiogram (ECG)	Left bundle branch block. No other abnormality.
Haemoglobin (Hb)	9.5 g/dl
Potassium (K^+)	5.8 mmol/l
Urea	60 mmol/l
White cell count (WCC)	25×10^9/l

Which one of the following is the most appropriate intervention with respect to her renal impairment and circulatory status?

A Blood transfusion

B Dialysis

C Fluid restriction

D Insulin and dextrose

E Rapid intravenous (iv) fluids

Rana Alnasser's screen

9:41
594-042-7551
Leave

Explanation

B Dialysis

This patient demonstrates a case of acute-on-chronic kidney disease, secondary to likely pyelonephritis/infected cyst. She needs dialysis urgently, as she has a pericardial rub, which is most likely due to uraemic pericarditis. She also has severe uraemia with urea and creatinine values as high as these. Dialysis is required for severe renal impairment and uraemic pericarditis; it will result in the lowering of the potassium level as well.

A Blood transfusion

A blood transfusion is not needed, as many patients with CRF are anaemic, secondary to erythropoietin deficiency, and this is usually worse in the setting of an acute infection. It is best to treat the kidney disease and re-assess the anaemia once the infection is treated.

C Fluid restriction

Fluid restriction will lead to further rise in urea levels and will potentially exacerbate the uraemic pericarditis. In this situation, it would be better to give fluids instead.

D Insulin and dextrose

Insulin and dextrose will lower the potassium level, but this is not dangerously elevated. Furthermore, the combination of insulin and dextrose, when used to lower the potassium level, is only temporary because it acts to push potassium into the cells. To remove total potassium, potassium needs to be removed via the gut or kidneys. So if the kidneys are not functioning, then dialysis will be required to remove potassium.

Audio Video Share Participants More

A 56-year-old woman with known chronic kidney disease (CKD) (usual creatinine 400 μmol/1), secondary to adult polycystic kidney disease, presents with a 2-day history of dysuria, left loin pain, fevers and vomiting.

On examination, she is pyrexial (temperature of 38.5 °C), with left loin tenderness and a pericardial rub. Mucosal surfaces and skin turgor look normal. Her blood pressure is elevated at 162/90 mmHg. You commence her on intravenous (iv) antibiotics.

Investigations show:

Creatinine (Cr)	1200 μmol/l
Electrocardiogram (ECG)	Left bundle branch block. No other abnormality.
Haemoglobin (Hb)	9.5 g/dl
Potassium (K^+)	5.8 mmol/l
Urea	60 mmol/l
White cell count (WCC)	25×10^9/l

Which one of the following is the most appropriate intervention with respect to her renal impairment and circulatory status?

Your answer was correct

A Blood transfusion

B Dialysis

C Fluid restriction

D Insulin and dextrose

A
B
C
D
E
O

rub, which is most likely due to uraemic pericarditis. She also has severe uraemia with urea and creatinine values as high as these. Dialysis is required for severe renal impairment and uraemic pericarditis; it will result in the lowering of the potassium level as well.

A Blood transfusion

A blood transfusion is not needed, as many patients with CRF are anaemic, secondary to erythropoietin deficiency, and this is usually worse in the setting of an acute infection. It is best to treat the kidney disease and re-assess the anaemia once the infection is treated.

C Fluid restriction

Fluid restriction will lead to further rise in urea levels and will potentially exacerbate the uraemic pericarditis. In this situation, it would be better to give fluids instead.

D Insulin and dextrose

Insulin and dextrose will lower the potassium level, but this is not dangerously elevated. Furthermore, the combination of insulin and dextrose, when used to lower the potassium level, is only temporary because it acts to push potassium into the cells. To remove total potassium, potassium needs to be removed via the gut or kidneys. So if the kidneys are not functioning, then dialysis will be required to remove potassium.

E Rapid intravenous (iv) fluids

Although cautious iv fluids would not be inappropriate, the patient is only mildly dehydrated and they will not correct this degree of kidney disease. Rapid iv fluids could result in pulmonary oedema if the kidneys are not functioning.

A 65-year-old woman presents to the Renal Clinic for review for an inherited condition. She brings with her a pedigree of her family affected by a genetic disease linked to progressive kidney disease, hearing loss and haematuria. She has progressively worsening renal impairment detected by her general practitioner (GP). Currently, she is not taking any medications.

On examination, her blood pressure is 140/80 mmHg, and her chest and abdominal examination is unremarkable.

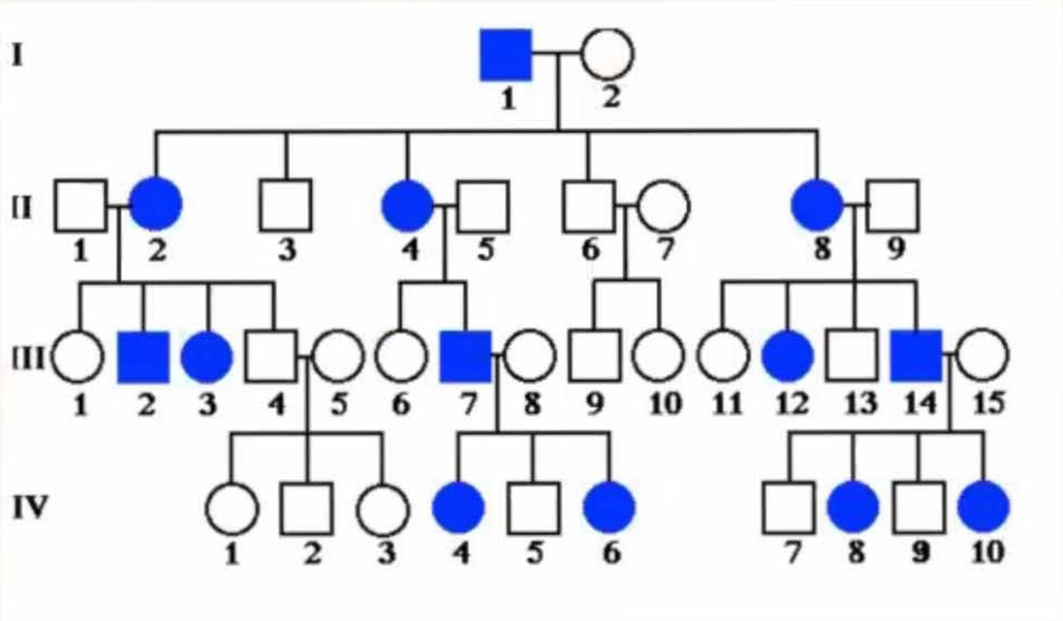

Given the suspected diagnosis, which of the following correctly reflects the inheritance pattern for this condition?

A	Autosomal dominant
B	Autosomal recessive
C	X-linked dominant
D	X-linked recessive
E	X-linked recessive plus spontaneous mutation

9:46

Explanation

C X-linked dominant

The symptoms described here are suggestive of a diagnosis of Alport's syndrome, 85% of which is inherited as an X-linked dominant condition. This accounts for the fact that both men and women are affected. With respect to Alport's, women usually present with milder, later onset disease.

A Autosomal dominant

The fact that this is a renal condition suggestive of Alport's drives us towards X-linked dominant as the likely diagnosis. If an abnormal gene is inherited from the affected parent, the offspring will get the disease in both men and women. One example of autosomal dominant inherited renal disease is polycystic kidney disease.

B Autosomal recessive

The high rates of heritability from generation to generation, (up to 50% of offspring), are much more suggestive of either X-linked dominant or autosomal dominant inheritance. Adult polycystic kidney disease may be inherited as an autosomal recessive condition.

D X-linked recessive

The fact that women are affected by the condition effectively rules out X-linked recessive inheritance. An example of X-linked recessive renal disease is nephrolithiasis (Dent disease).

E X-linked recessive plus spontaneous mutation

Rana Alnasser's screen

One example of autosomal dominant inherited renal disease is polycystic kidney disease.

B Autosomal recessive

The high rates of heritability from generation to generation, (up to 50% of offspring), are much more suggestive of either X-linked dominant or autosomal dominant inheritance. Adult polycystic kidney disease may be inherited as an autosomal recessive condition.

D X-linked recessive

The fact that women are affected by the condition effectively rules out X-linked recessive inheritance. An example of X-linked recessive renal disease is nephrolithiasis (Dent disease).

E X-linked recessive plus spontaneous mutation

This would not be consistent with the number of women affected by the condition.

Rate this question:

Next Question

Previous Q... Tag Questi... Feedback End Session

© Pastest 2019

A 39-year-old man comes to the clinic because of having had an achy low back pain for the past few weeks. He describes the pain as a dull ache that came on gradually. There are no other specific symptoms. He has been taking hydrochlorothiazide and enalapril for hypertension for the last five years. His father and younger sister also have hypertension.

On examination, his pulse rate is 65 beats/min, blood pressure 135/90 mmHg and temperature 36.6 °C. He has mild tenderness on the left flank and a mid-systolic click on cardiac examination. Urine dipstick shows microscopic haematuria.

What is the most appropriate next step?

A	Arrange a kidney biopsy
B	Computed tomography (CT) scan of the kidneys
C	Genetic linkage analysis
D	Intravenous pyelogram
E	Ultrasound scan of the kidneys

Submit

A 39-year-old man comes to the clinic because of having had an achy low back pain for the past few weeks. He describes the pain as a dull ache that came on gradually. There are no other specific symptoms. He has been taking hydrochlorothiazide and enalapril for hypertension for the last five years. His father and younger sister also have hypertension.

On examination, his pulse rate is 65 beats/min, blood pressure 135/90 mmHg and temperature 36.6 °C. He has mild tenderness on the left flank and a mid-systolic click on cardiac examination. Urine dipstick shows microscopic haematuria.

What is the most appropriate next step?

Your answer was correct

A Arrange a kidney biopsy

B Computed tomography (CT) scan of the kidneys

C Genetic linkage analysis

D Intravenous pyelogram

E Ultrasound scan of the kidneys

Explanation

E Ultrasound scan of the kidneys

This patient is most likely to have adult polycystic kidney disease (APKD). Ultrasound scan will be the most

Your answer was correct

A	Arrange a kidney biopsy
B	Computed tomography (CT) scan of the kidneys
C	Genetic linkage analysis
D	Intravenous pyelogram
E	Ultrasound scan of the kidneys

Explanation

E Ultrasound scan of the kidneys

This patient is most likely to have adult polycystic kidney disease (APKD). Ultrasound scan will be the most appropriate test as it will show multiple renal cysts. It presents with hypertension, flank pain, micro- or macroscopic haematuria and chronic kidney disease. It is associated with intracranial aneurysms, colonic diverticula, mitral valve prolapse and cysts in other organs – the liver, pancreas and spleen.

A Arrange a kidney biopsy

Renal biopsy is not indicated in the diagnosis of adult polycystic kidney disease.

B Computed tomography (CT) scan of the kidneys

Computed tomography (CT) is a sensitive test, but it is

A Arrange a kidney biopsy

Renal biopsy is not indicated in the diagnosis of adult polycystic kidney disease.

B Computed tomography (CT) scan of the kidneys

Computed tomography (CT) is a sensitive test, but it is done after the ultrasound scan.

C Genetic linkage analysis

Genetic linkage analysis will give the diagnosis in suspected cases when the radiographic imaging is negative. Genetic linkage is particularly useful in the young (<20 years), because ultrasound is frequently negative, whilst in older patients (>20 years) ultrasound are more likely to be positive. About 85% of people have an abnormality in the PKD1 gene with APKD.

D Intravenous pyelogram

Intravenous pyelogram is the least sensitive of all the tests available as an option.

Rate this question:

Next Question

Previous Q... Tag Questi... Feedback End Session

9:50

A general practitioner (GP) has referred a 20-year-old patient to the Renal Clinic with haematuria. The patient recalls having coryzal symptoms two weeks ago and then developing frank haematuria for a few days. He says the symptoms have resolved. The patient recalls his maternal grandfather had 'kidney' problems at a young age.

He has a past history of hearing difficulties and wears hearing aids, and is under the ophthalmologists for treatment of corneal ulcers.

Tests show:

Blood pressure	145/80 mmHg
Urine dipstick	++protein, ++blood
Fundoscopy	Bilateral yellow dots around the macula

Evidence of what underlying diagnosis is likely to be seen on the renal biopsy?

A Rapidly progressive glomerulonephritis

B Mesangiocapillary glomerulonephritis

C Primary focal segmental glomerulosclerosis

D Membranous glomerulonephritis

E Alport's syndrome

Submit

D Membranous glomerulonephritis

E Alport's syndrome

Explanation

E Alport's syndrome

Alport's syndrome consists of:

1. nephritis causing microscopic haematuria and progressive kidney disease with episodic frank haematuria
2. ocular pathology – corneal ulcerations, bilateral anterior lenticonus, bilateral dot-fleck marks around the fovea
3. progressive high-frequency sensorineuronal deafness.

A light microscope examination can be unremarkable and electron microscope examination is needed. Occasionally focal and segmental glomerulosclerosis, interstitial fibrosis, tubular atrophy, and infiltration of lymphocytes and plasma cells may be seen on light microscopy. The syndrome is inherited mainly as X-linked.

A Rapidly progressive glomerulonephritis

This is a syndrome consisting of a rapid loss in renal function (usually a 50% decline in glomerular filtration rate within 3 months) with glomerular crescent formation in at least 50–75% of glomeruli on renal biopsy. If left untreated it rapidly progresses into acute kidney disease.

B Mesangiocapillary glomerulonephritis

MPGN is an uncommon cause of chronic nephritis in children and young adults. There is a thickening of the

inherited mainly as X-linked.

A Rapidly progressive glomerulonephritis

This is a syndrome consisting of a rapid loss in renal function (usually a 50% decline in glomerular filtration rate within 3 months) with glomerular crescent formation in at least 50–75% of glomeruli on renal biopsy. If left untreated it rapidly progresses into acute kidney disease.

B Mesangiocapillary glomerulonephritis

MPGN is an uncommon cause of chronic nephritis in children and young adults. There is a thickening of the peripheral capillary walls by subendothelial immune deposits and or intramembranous dense deposits.

C Primary focal segmental glomerulosclerosis

FSGS is a common cause of nephrotic range proteinuria in adults. There would not be haematuria on dipstick.

D Membranous glomerulonephritis

This is the commonest cause of nephrotic syndrome (proteinuria, oedema and hypoalbuminaemia) in adults. There would not be blood in membranous glomerulonephritis on dipstick.

Rate this question:

Next Question

A 65-year-old woman is admitted as an emergency following her renal function having been assessed 1 month after starting ramipril therapy for hypertension.

Examination in the clinic reveals abdominal and carotid bruits; she is clinically euvolaemic. Her blood pressure (BP) is 156/88 mmHg. Electrocardiogram (ECG) on admission is unremarkable.

Investigations reveal:

On admission:

Sodium (Na^+)	142 mmol/l
Potassium (K^+)	6.0 mmol/l
Creatinine	340 µmol/l

One month previously:

Na^+	140 mmol/l
K+	4.2 mmol/l
Creatinine	175 µmol/l

Which one of the following represents the most appropriate initial step in the management of this patient?

A	Add bendroflumethiazide 2.5 mg po daily
B	Advise a low-potassium diet
C	Observe renal function over the next week
D	Start calcium resonium
E	Stop ramipril therapy

E Stop ramipril therapy

This clinical scenario is highly suggestive of underlying renal artery stenosis. ACE inhibitors result in a decrease in efferent renal arteriolar blood pressure and a deterioration in serum creatinine in patients with renal artery stenosis. Magnetic resonance angiography is the definitive investigation.

The key intervention for this patient is to stop the ramipril and substitute another antihypertensive drug, such as a calcium channel antagonist if required. Depending on local protocol, most physicians check renal function one week and one month after initiating ACE inhibitors or angiotensin II receptor blockade.

Her potassium is likely to fall within a day or two of stopping the ramipril therapy; given the fact that her ECG on admission is unremarkable, no acute intervention for her potassium is warranted here.

This clinical scenario is highly suggestive of underlying renal artery stenosis. ACE inhibitors result in a decrease in efferent renal arteriolar blood pressure and a deterioration in serum creatinine in patients with renal artery stenosis. Magnetic resonance angiography is the definitive investigation.

The key intervention for this patient is to stop the ramipril and substitute another antihypertensive drug, such as a calcium channel antagonist if required. Depending on local protocol, most physicians check renal function one week and one month after initiating ACE inhibitors or angiotensin II receptor blockade.

Her potassium is likely to fall within a day or two of stopping the ramipril therapy; given the fact that her ECG on admission is unremarkable, no acute intervention for her potassium is warranted here.

A Add bendroflumethiazide 2.5 mg po daily

B Advise a low-potassium diet

A low-potassium diet will not correct the underlying cause, which is deterioration in renal function due to the ACE inhibitor. A low-potassium diet will help with some control.

C Observe renal function over the next week

The renal function will stay the same or worsen if the patient is continued on the ACE inhibitor, so there is no rationale in observing the renal function. The renal function will not be altered unless the offending agent is stopped.

D Start calcium resonium

Calcium resonium acts to prevent potassium absorption by the gut. It has side-effects of constipation. Although calcium resonium may control any potassium rise, the underlying cause is not resolved; therefore, the potassium will not be entirely corrected. Calcium resonium alone will be unpredictable in the level of control of potassium and is not fast-acting.

71273

Rate this question:

© Pastest 2019

A 28-year-old Somalian woman presented to the Emergency Department with a 3-week history of generalised weakness, anorexia, decreased appetite and weight loss. She was noted to be increasingly short of breath and had intermittent headaches. She worked as a cleaner and has been in the UK for three years. She was unable to give a sexual history. There was no history of blood transfusions.

On examination, she appeared cachectic, afebrile, pulse 80/min and regular, BP 130/80 mmHg, jugular venous pressure (JVP) not seen. There was no peripheral oedema. Chest examination was normal. Fundoscopy revealed grade 2 hypertensive retinopathy. The remainder of the examination was normal.

Investigations:

Hb	9.2 g/dl
WCC	4.1×10^9/l
PLT	100×10^9/l
Blood film	Microcytosis
Na^+	138 mmol/l
K^+	3.2 mmol/l
Urea	18 mmol/l
Creatinine	205 µmol/l
Total protein	58 g/l
Albumin	18 g/l
LFTs	Normal

WCC	4.1×10^9/l
PLT	100×10^9/l
Blood film	Microcytosis
Na^+	138 mmol/l
K^+	3.2 mmol/l
Urea	18 mmol/l
Creatinine	205 μmol/l
Total protein	58 g/l
Albumin	18 g/l
LFTs	Normal
Bone profile	Normal
Urine microscopy	Intact red blood cells/granular casts, protein ++
Blood/urine culture	Negative
Chest X-ray	Normal
ECG	Normal
Renal ultrasound scan	Highly echogenic kidneys; right kidney 13.5 cm, left kidney 14 cm

She underwent a native renal biopsy, the results of which are shown below:

microscopy	protein ++
Blood/urine culture	Negative
Chest X-ray	Normal
ECG	Normal
Renal ultrasound scan	Highly echogenic kidneys; right 13.5 cm, left kidney 14 cm

She underwent a native renal biopsy, the results are shown below:

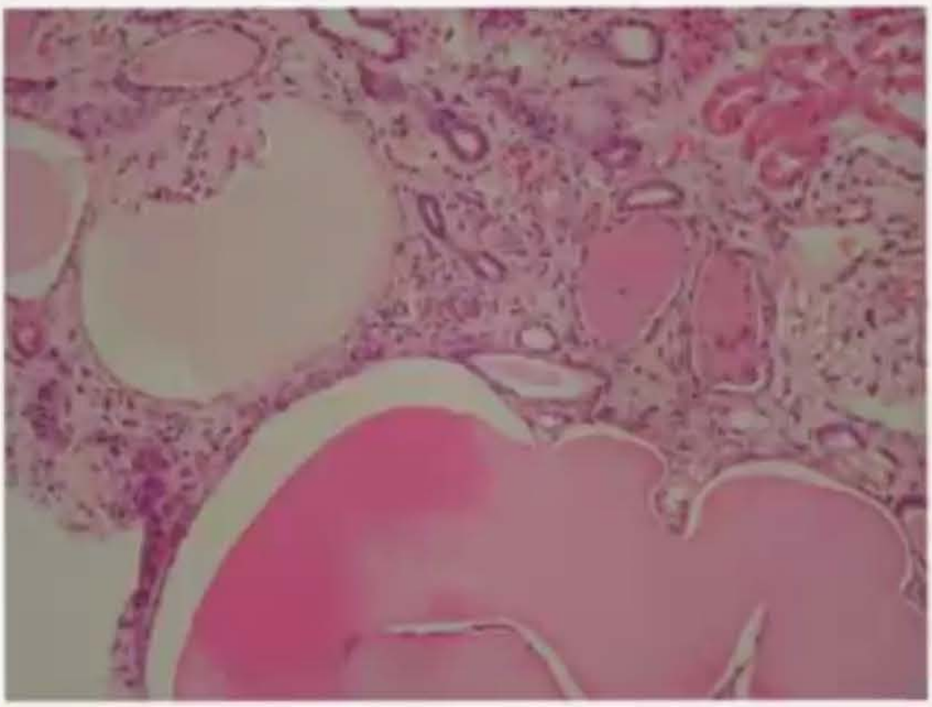

What is the most likely diagnosis?

A	Heroin-associated nephropathy

Chest X-ray	Normal
ECG	Normal
Renal ultrasound scan	Highly echogenic kidneys; right kidney 13.5 cm, left kidney 14 cm

She underwent a native renal biopsy, the results of which are shown below:

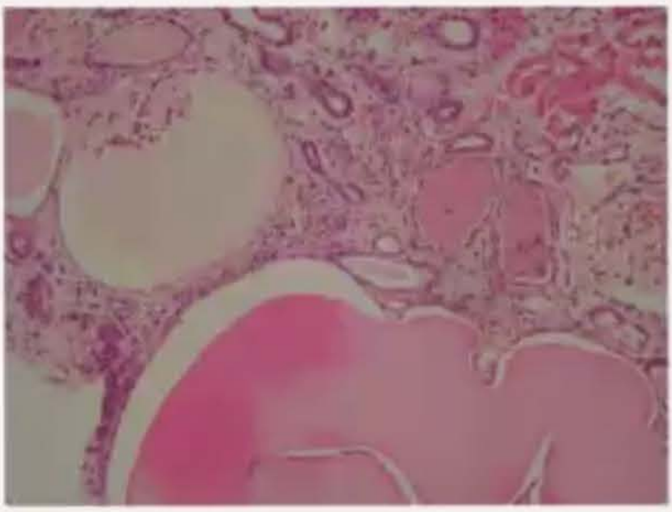

What is the most likely diagnosis?

A Heroin-associated nephropathy

B HIV-associated nephropathy

C Malignant hypertension

D Primary focal segmental glomerulosclerosis

E Schistosomiasis

10:03
594-042-7551 Leave

Explanation

B HIV-associated nephropathy

HIV-associated nephropathy (HIVAN) is associated with massive proteinuria, microscopic haematuria and kidney disease, and predominantly occurs in black patients with HIV infection. In the era prior to combination antiretroviral therapy, this led to rapid progression to end-stage kidney disease. The classic lesion on renal histology is the collapsing variant of secondary focal segmental glomerulosclerosis.

A Heroin-associated nephropathy

While the histological features may also represent heroin-associated nephropathy, there are no clinical pointers towards this, and would not explain the hypergammaglobulinaemia.

C Malignant hypertension

The blood pressure is the upper limit of normal with only grade 2 hypertensive retinopathy. Malignant hypertension is characterised by vascular fibrinoid necrosis and loss of precapillary arteriolar autoregulation. It is a medical emergency because the blood pressure rises acutely and there is risk of stroke.

D Primary focal segmental glomerulosclerosis

This would not explain the high total protein count caused by hypergammaglobulinaemia. Primary focal segmental glomerulosclerosis is a common cause of nephrotic syndrome in adults and one of the leading causes of kidney disease.

Audio Video Share Participants More

10:04

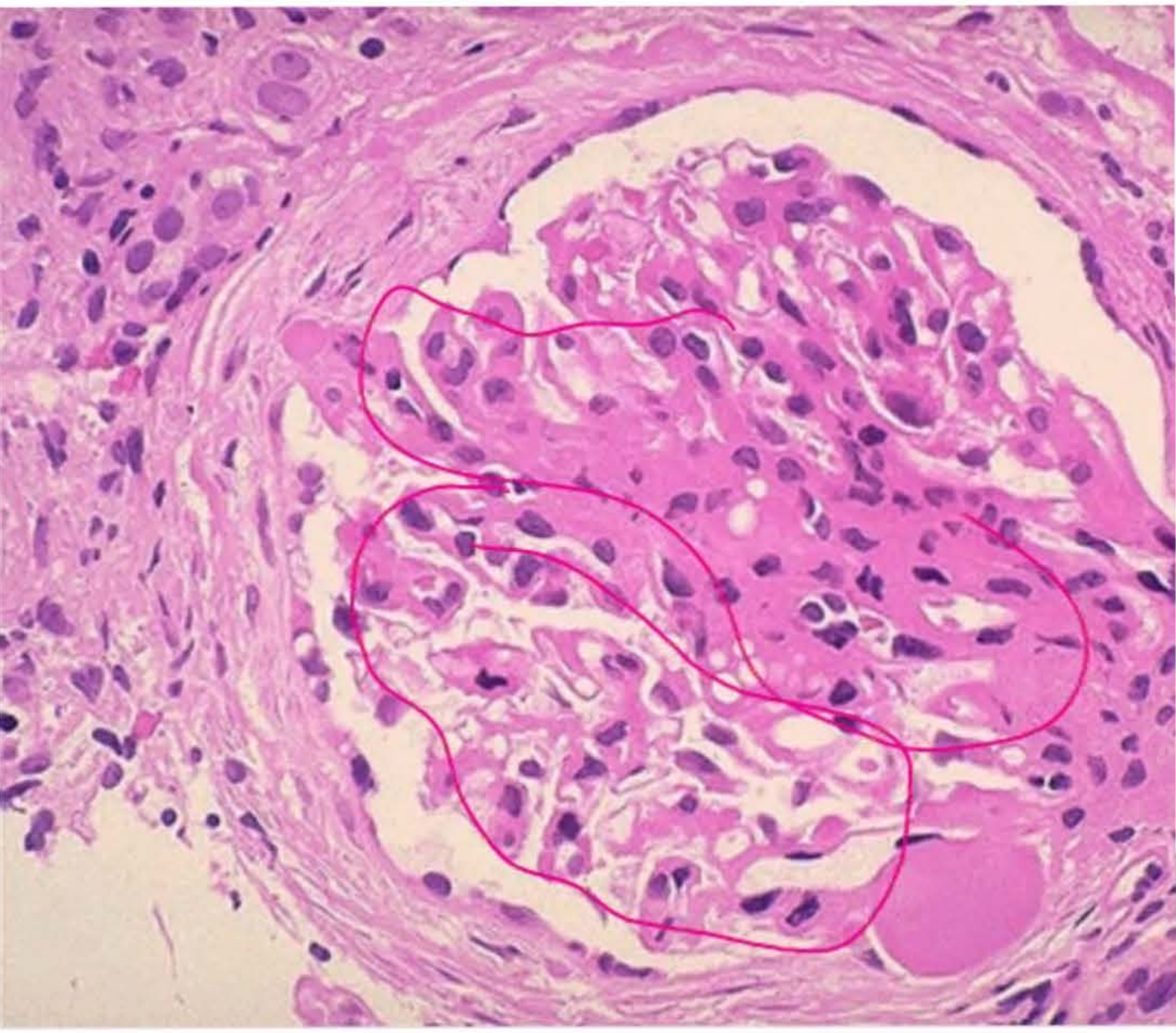

Renal Pathology

Renal Pathology

This is focal segmental glomerulosclerosis (FSGS). An area of collagenous sclerosis runs a

Images may be subject to copyright. Find out more

RELATED IMAGES

Prostatitis - Wikipedia

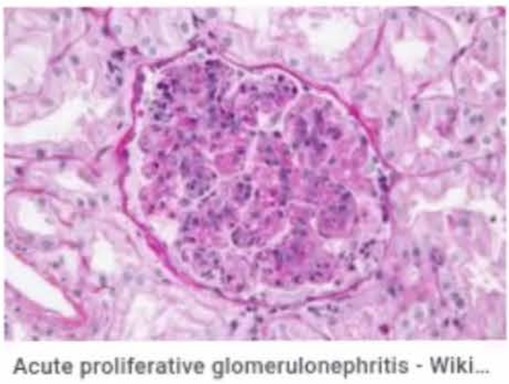

Acute proliferative glomerulonephritis - Wiki...

Ischemic Gl

Stop Annotation Spotlight Pen Highlighter Line Rectangle Oval Undo Redo

Discover Updates Search Recent

10:07

A 52-year-old man presents with several months' history of generalised swelling, fatigue, cough, dyspnoea and several episodes of haemoptysis. There is no significant past medical history and he did not take any regular medication. He smokes 20 cigarettes per day and drinks 14 units of alcohol per week.

On examination, he is grossly oedematous and has ascites. Cardiorespiratory examination is unremarkable and there are no neurological signs or rashes.

Investigation results are below:

Hb	10.2 g/dl
WCC	6.0×10^9/l
PLT	380×10^9/l
Mean corpuscular volume (MCV)	90fl
Na^+	145 mmol/l
K^+	3.7 mmol/l
Urea	8.2 mmol/l
Bilirubin	16 µmol/l
Creatinine	180 µmol/l
Albumin	22 g/l
Aspartate transaminase (AST)	32 U/l
Alkaline phosphatase	120 U/l
Urinalysis	Protein +++
24-hour urinary protein excretion	5 g
Chest X-ray	Enlarged right hilum

Rana Alnasser's screen

10:09
594-042-7551 Leave

Aspartate transaminase (AST)	32 U/l
Alkaline phosphatase	120 U/l
Urinalysis	Protein +++
24-hour urinary protein excretion	5 g
Chest X-ray	Enlarged right hilum
Echocardiogram	Mild left ventricular impairment, no valve lesion
Abdominal ultrasound scan	Normal-sized kidneys, no abnormality seen

A renal biopsy was performed.

What is it most likely to show?

A Crescent formation

B Kimmelstiel–Wilson lesions

C Fusion of podocyte foot processes on electron microscopy

D Necrotising granulomata

E Thickened glomerular basement membrane with deposits of IgG and C3

Submit

Audio Video Share Participants More

B Kimmelstiel-Wilson lesions

C Fusion of podocyte foot processes on electron microscopy

D Necrotising granulomata

E Thickened glomerular basement membrane with deposits of IgG and C3

Explanation

E Thickened glomerular basement membrane with deposits of IgG and C3

This patient has developed nephrotic syndrome as a result of membranous glomerulonephritis which is associated with an underlying bronchial carcinoma. Membranous glomerulonephritis accounts for 20–30% of adult nephrotic syndromes, and there will be underlying malignancy in 10% of cases. Other causes of membranous nephropathy are drugs (eg gold and penicillamine), autoimmune diseases (eg systemic lupus erythematosus (SLE)) and infections (eg hepatitis). Approximately one-third of patients will progress to end-stage kidney disease within 10–20 years of diagnosis. Typical renal biopsy features of membranous nephropathy is thickened glomerular basement membrane with deposits of IgG and C3. Treatment may include chlorambucil and cyclophosphamide.

A Crescent formation

Crescents are found in rapidly progressive glomerulonephritis. The presentation would be a quickly deteriorating renal function with blood and protein in the urine. Crescentric glomerulonephritis may be found in anti-glomerular basement membrane disease and lupus

10:12
594-042-7551 Leave

A Crescent formation

Crescents are found in rapidly progressive glomerulonephritis. The presentation would be a quickly deteriorating renal function with blood and protein in the urine. Crescentric glomerulonephritis may be found in anti-glomerular basement membrane disease and lupus nephritis.

B Kimmelstiel–Wilson lesions

These lesions are pathognomonic of diabetic nephropathy. In this scenario there is no mention of history of diabetes and there is no sugar in the urine. The first sign of diabetic nephropathy is microalbuminuria.

C Fusion of podocyte foot processes on electron microscopy

This feature is found in minimal change disease. Although minimal change disease can present with nephrotic syndrome, it is more common in young children. The prognosis is generally good and steroid responsive.

D Necrotising granulomata

Granulomas are an organised collection of macrophages. There are a variety of conditions which can cause necrotising granulomata, of which the most classic is tuberculosis. In this scenario there is no history that is indicative of tuberculosis such as fever, weight loss or any contact history.

Rate this question:

Next Question

Audio Video Share Participants More

10:12

A 67-year-old man is referred to the Hypertension Clinic with difficult-to-control blood pressure. He is currently taking atenolol 50 mg daily, ramipril 10 mg daily and indapamide 2.5 mg daily. There is a past history of an inferior myocardial infarction (MI) some 3 years earlier and he continues to smoke ten cigarettes per day.

On examination, his BP is 155/95 mmHg, pulse is 62/min and regular. His chest and abdominal examination is unremarkable. You note left carotid and left femoral bruits and poor capillary return in his feet.

Investigations:

Hb	13.1 g/dl
WCC	6.8×10^9/l
PLT	212×10^9/l
Na^+	138 mmol/l
K^+	3.1 mmol/l
Creatinine	110 μmol/l
Ultrasound renal tract	Differential kidney size with small left kidney

Which of the following is the most likely diagnosis?

A Essential hypertension

B Phaeochromocytoma

C Primary hyperaldosteronism

D Renal artery stenosis

E Reflux nephropathy

Rana Alnasser's screen

10:14

C Primary hyperaldosteronism

D Renal artery stenosis

E Reflux nephropathy

Explanation

D Renal artery stenosis

There are multiple clues to the fact that this patient is a significant vasculopathy, with the previous inferior MI, poor peripheral circulation and multiple bruits. This, coupled with a differential kidney size on ultrasound, is suggestive of renal artery stenosis, resultant secondary hyperaldosteronism leading to the hypokalaemia seen here. Angiography is the definitive investigation to confirm the diagnosis; although, in practice, recent large studies have suggested that medical management of hypertension is as effective as vascular intervention.

A Essential hypertension

Essential hypertension can give rise to renal impairment and difficult-to-treat hypertension. However, there would not be a differential kidney size. Both kidneys would be small in chronic hypertensive nephropathy.

B Phaeochromocytoma

Phaeochromocytoma would not have different sized kidneys. There may be other symptoms such as flushing and tachycardia. The hypertension is often episodic rather than permanent.

Rana Alnasser's screen

and tachycardia. The hypertension is often episodic rather than permanent.

C Primary hyperaldosteronism

Conn syndrome is an excess production of aldosterone and there is a low renin level. Often, there are few symptoms except high blood pressure. There may be myalgia, paraesthesiae and polyuria. There is no differential kidney size in primary hyperaldosteronism.

E Reflux nephropathy

Reflux nephropathy is due to reflux of urine from bladder back towards the kidneys – vesicoureteral reflux. Longstanding vesicoureteric reflux can result in small and scarred kidneys during the first five years in affected children. The end result is hypertension, proteinuria and may lead to end-stage kidney disease. In this scenario, there is mainly a vascular history rather than a history of recurrent urinary tract and vesicoureteric reflux; therefore, renal artery stenosis is a likely diagnosis.

Rate this question:

Next Question

Previous Q... Tag Questi... Feedback End Session

© Pastest 2019

10:15

A 24-year-old man presents with macroscopic haematuria. He is seen a few days following an upper respiratory tract infection.

Urine is positive for blood and protein, but no growth is seen after urine culture. Blood pressure is normal. Renal biopsy reveals focal proliferative glomerulonephritis with mesangial IgA deposition.

Which of the following diagnoses fits best with the clinical picture?

A	Anti-GBM disease
B	IgA nephropathy
C	Post-streptococcal glomerulonephritis
D	Granulomatosis with polyangiitis
E	Minimal-change disease

Submit

Previous Q... Skip Questi...

© Pastest 2019

10:16

A 24-year-old man presents with macroscopic haematuria. He is seen a few days following an upper respiratory tract infection.

Urine is positive for blood and protein, but no growth is seen after urine culture. Blood pressure is normal. Renal biopsy reveals focal proliferative glomerulonephritis with mesangial IgA deposition.

Which of the following diagnoses fits best with the clinical picture?

Your answer was correct

A	Anti-GBM disease
B	IgA nephropathy
C	Post-streptococcal glomerulonephritis
D	Granulomatosis with polyangiitis
E	Minimal-change disease

Diffic

Peer

Sessi

Responses
Responses
Responses
Responses

Explanation

B IgA nephropathy

IgA nephropathy is the most common form of glomerulonephritis seen worldwide, and consists of focal proliferative glomerulonephritis with mesangial deposits of

3G 10:16

E Minimal-change disease

Explanation

B IgA nephropathy

IgA nephropathy is the most common form of glomerulonephritis seen worldwide, and consists of focal proliferative glomerulonephritis with mesangial deposits of IgA. It is thought to occur due to an exaggerated immune response to viral or other antigens, and may follow respiratory or gastrointestinal infection. They may present with asymptomatic microscopic haematuria or macroscopic haematuria, proteinuria occurs and 5% may be nephrotic. Good prognosis is associated with normal blood pressure, renal function and absence of proteinuria at presentation.

A Anti-GBM disease

Anti-GBM disease would present with haemoptysis and rapidly progressive kidney disease. Anti-GBM antibodies would be present. There would be protein and blood in the urine.

C Post-streptococcal glomerulonephritis

The main distinguishing feature here from post-streptococcal glomerulonephritis is the presence of mesangial IgA. Although small amounts of IgA may be present in post-streptococcal GN, significant quantities suggest a different diagnosis.

D G natosis with polyangiitis

Annotation Stop Share

cANCA is positive in granulomatosis with polyangiitis, and

would be present. There would be protein and blood in the urine.

C Post-streptococcal glomerulonephritis

The main distinguishing feature here from post-streptococcal glomerulonephritis is the presence of mesangial IgA. Although small amounts of IgA may be present in post-streptococcal GN, significant quantities suggest a different diagnosis.

D Granulomatosis with polyangiitis

cANCA is positive in granulomatosis with polyangiitis, and there is an association with ear nose and throat symptoms in addition to rapidly progressive kidney disease.

E Minimal-change disease

Minimal-change disease is the most common cause of nephrotic syndrome in children. Haematuria is not a feature.

Rate this question:

Next Question

© Past

10:17

A 40-year-old woman with end-stage kidney disease and undergoing regular haemodialysis is due to undergo renal transplantation from her sister the following day. The primary cause of her kidney disease is hypertension and she has no other past medical history.

On examination, her blood pressure is 145/70 mmHg, chest and abdominal examination is unremarkable.

Investigations show:

Na^+	134 mmol/l
K^+	5.8 mmol/l
Urea	15 mmol/l
Creatinine	370 µmol/l
Hb	8.9 g/dl
WCC	5.1×10^9/l
PLT	243×10^9 /l

Which of the following represents the best treatment plan?

A	Give calcium resonium
B	Consider dextrose and insulin infusion
C	Do nothing
D	Arrange an extra haemodialysis session
E	Give regular salbutamol nebulisers

Annotation Stop Share

10:21

MyPastest
https://mypastest.pastest.com

A 40-year-old woman with end-stage kidney disease and undergoing regular haemodialysis is due to undergo renal transplantation from her sister the following day. The primary cause of her kidney disease is hypertension and she has no other past medical history.

On examination, her blood pressure is 145/70 mmHg, chest and abdominal examination is unremarkable.

Investigations show:

Na^+	134 mmol/l
K^+	5.8 mmol/l
Urea	15 mmol/l
Creatinine	370 µmol/l
Hb	8.9 g/dl
WCC	5.1×10^9/l
PLT	243×10^9 /l

Which of the following represents the best treatment plan?

Your answer was correct

A Give calcium resonium

B Consider dextrose and insulin infusion

ng

Annotation Stop Share

10:22

D Arrange an extra haemodialysis session

Raised serum potassium in a patient with end-stage kidney disease is an indication for delaying routine surgery. As this patient is not due to have her transplant until the following day however, there is an opportunity to intervene with an extra haemodialysis session. Serum potassium above 5.5 mmol/l is the level at which intervention should be considered. Calcium resonium, insulin and dextrose and salbutamol nebulisers are all treatments for acute hyperkalaemia.

A Give calcium resonium

Calcium resonium prevents the absorption of potassium from the gut. It is a slow treatment and would not be used acutely in this situation.

B Consider dextrose and insulin infusion

Insulin will push potassium from extracellular to intracellular compartment, but will not alter the total body potassium content. It is a temporary treatment.

C Do nothing

Hyperkalaemia pre-renal transplant will increase anaesthetic risk. The patient would be at risk of arrythmias, therefore high potassium needs to be treated.

E Give regular salbutamol nebulisers

Salbutamol forces potassium from extracellular to intracelluar compartment. It is used in the treatment of acute hyperkalaemia.

Annotation Stop Share

Rate this question:

Rana Alnasser's screen

10:23
594-042-7551 Leave

A 70-year-old man is admitted to the Emergency Department acutely unwell. He has a 2-day history of disorientation reported by a neighbour. He lives alone and was found collapsed on the floor. It is suspected that he was on the floor for many hours and probably overnight. He is now drowsy and incoherent.

His pulse is 120/min and his blood pressure 80/40 mmHg. His respiratory rate is 20/min with saturations of 95% on air. He is febrile, with a temperature of 38.5 °C. He is stabilised in the resuscitation room and given IV calcium with IV glucose and insulin to reduce his potassium over the first hour of his treatment and, in spite of catheterisation, he does not pass any urine.

Urgent investigations:

Hb	12.3 g/dl
WCC	19.0 × 10^9/l (predominantly neutrophils)
Platelets	480 × 109/l
International normalised ratio (INR)	1.1
Activated partial thromboplastin time (APTT)	44 s
Na^+	136 mmol/l
K^+	6.7 mmol/l
Urea	36 mmol/l
Creatinine	780 µmol/l
Bicarbonate	18 mmol/l
Calcium corrected	1.92 mmol/l
Phosph	1.6 mmol/l

Annotation Stop Share
Audio Video Share Participants More

International normalised ratio (INR)	1.1
Activated partial thromboplastin time (APTT)	44 s
Na^+	136 mmol/l
K^+	6.7 mmol/l
Urea	36 mmol/l
Creatinine	780 µmol/l
Bicarbonate	18 mmol/l
Calcium corrected	1.92 mmol/l
Phosphate	1.6 mmol/l
Creatine kinase	5999 IU/l

He is fluid loaded in the hope of improving his blood pressure.

In his subsequent management, which one of the following steps is most likely to improve his outcome?

A	Continuous or intermittent renal replacement therapy (haemodialysis)
B	Further intravenous calcium supplementation
C	'Renal dose' dopamine infusion
D	Loop diuretic
E	Urinary acidification

D Loop diuretic

E Urinary acidification

Explanation

A Continuous or intermittent renal replacement therapy (haemodialysis)

This man has rhabdomyolysis due to sepsis, and probably also due to prolonged lying on the floor before being discovered. The steps most likely to improve his outcome are rigorous rehydration (with caution to avoid cardiac failure), and definitive renal replacement therapy if this does not improve oliguria and hyperkalaemia.

B Further intravenous calcium supplementation

The calcium and phosphate abnormalities will probably self-correct if renal function can be maintained. Therefore there is no need for supplementation.

C 'Renal dose' dopamine infusion

There is no conclusive evidence that dopamine or atrial natriuretic peptide is of benefit in the management of oliguric renal impairment.

D Loop diuretic

There is no conclusive evidence that loop diuretics are of benefit in the management of oliguric renal impairment.

E Urinary acidification

Urinary alkalinisation is sometimes used in rhabdomyolysis.

10:27
594-042-7551 Leave

A 64-year-old man comes to the office complaining of left flank pain and gross haematuria. The pain is non-radiating, dull in nature and not associated with any fever or chills. The patient has not had any medical care in 20 years.

His vital signs and physical examination are unremarkable. A complete blood count and biochemical profile are normal. A computed tomography (CT) scan of the abdomen and pelvis reveals a contrast-enhancing 5 cm mass in the lower pole of the left kidney. A chest X-ray and ultrasound of the abdomen are unremarkable, as is a CT thorax.

What is the most appropriate way to manage this patient?

A	Order a MIBI scan
B	Order a magnetic resonance image (MRI) with gadolinium
C	Schedule chemotherapy
D	Schedule radiation therapy
E	Send him to a urologist for radical nephrectomy

Submit

Previous Q... Skip Questi...

Audio Video Share Participants More

10:29

A 64-year-old man comes to the office complaining of left flank pain and gross haematuria. The pain is non-radiating, dull in nature and not associated with any fever or chills. The patient has not had any medical care in 20 years.

His vital signs and physical examination are unremarkable. A complete blood count and biochemical profile are normal. A computed tomography (CT) scan of the abdomen and pelvis reveals a contrast-enhancing 5 cm mass in the lower pole of the left kidney. A chest X-ray and ultrasound of the abdomen are unremarkable, as is a CT thorax.

What is the most appropriate way to manage this patient?



Your answer was incorrect

A	Order a MIBI scan
B	Order a magnetic resonance image (MRI) with gadolinium
C	Schedule chemotherapy
D	Schedule radiation therapy
E	Send him to a urologist for radical nephrectomy

Explanation

E	Send him to a urologist for radical nephrectomy

This patient has renal cell carcinoma of the left kidney. A computed tomography (CT) scan with and without contrast that reveals a contrast-enhancing mass is the

10:29

MyPastest
https://mypastest.pastest.com

Responses

B	Order a magnetic resonance image (MRI) with gadolinium
C	Schedule chemotherapy
D	Schedule radiation therapy
E	Send him to a urologist for radical nephrectomy

Explanation

E	Send him to a urologist for radical nephrectomy

This patient has renal cell carcinoma of the left kidney. A computed tomography (CT) scan with and without contrast that reveals a contrast-enhancing mass is the primary radiological modality used to diagnose this disease. This patient presents with two of the three symptoms of the classic triad of renal cell carcinoma: costovertebral pain, haematuria and palpable mass. Unfortunately this triad is seen in only 10% of the patients diagnosed with renal cell carcinoma. Surgical removal remains the only potential curative therapy for renal cell carcinoma. While a variety of therapeutic modalities are available (e.g. partial nephrectomy), radical nephrectomy provides this patient with the best possible chance of cure. Prognosis for patients with T1 renal cell carcinoma (<7 cm in size) is >85% with appropriate treatment.

A	Order a MIBI scan

A MIBI scan may be used for differentiating different type of cancers, such as an oncocytoma, from a renal cell

10:30
594-042-7551 Leave

disease. This patient presents with two of the three symptoms of the classic triad of renal cell carcinoma: costovertebral pain, haematuria and palpable mass. Unfortunately this triad is seen in only 10% of the patients diagnosed with renal cell carcinoma. Surgical removal remains the only potential curative therapy for renal cell carcinoma. While a variety of therapeutic modalities are available (e.g. partial nephrectomy), radical nephrectomy provides this patient with the best possible chance of cure. Prognosis for patients with T1 renal cell carcinoma (<7 cm in size) is >85% with appropriate treatment.

A Order a MIBI scan

A MIBI scan may be used for differentiating different type of cancers, such as an oncocytoma, from a renal cell carcinoma

B Order a magnetic resonance image (MRI) with gadolinium

Although an MRI scan may identify renal carcinoma, a CT scan is more often readily available and easier to perform, so would be the investigation of choice.

C Schedule chemotherapy

Surgical removal remains the only potential curative therapy for renal cell carcinoma.

D Schedule radiation therapy

Surgical removal remains the only potential curative therapy for renal cell carcinoma.

Rate this question:

Audio Video Share Participants More

10:31
594-042-7551 Leave

A 74-year-old woman presents with lethargy on a background of depression and type 2 diabetes mellitus. She takes metformin and gliclazide. Her blood pressure is 130/70 mmHg and she is clinically euvolaemic.

Routine biochemical investigations reveal:

Na^+	120 mmol/l
K^+	3.8 mmol/l
Urea	5.6 mmol/l
Creatinine	76 μmol/l
Thyroid function test	Normal

Which biochemical test would be most useful in determining her state of water balance?

A 24-hour urinary protein and creatinine

B Erect/supine renin and aldosterone estimation

C Fractional excretion of Na^+

D Plasma ADH

E Serum and urine osmolality

Submit

Audio Video Share Participants More

10:34
594-042-7551 Leave

A 74-year-old woman presents with lethargy on a background of depression and type 2 diabetes mellitus. She takes metformin and gliclazide. Her blood pressure is 130/70 mmHg and she is clinically euvolaemic.

Routine biochemical investigations reveal:

Na^+	120 mmol/l
K^+	3.8 mmol/l
Urea	5.6 mmol/l
Creatinine	76 µmol/l
Thyroid function test	Normal

Which biochemical test would be most useful in determining her state of water balance?

A 24-hour urinary protein and creatinine

B Erect/supine renin and aldosterone estimation

C Fractional excretion of Na^+

D Plasma ADH

E Serum and urine osmolality

Explanation

E Serum and urine osmolality

Urine osmolality relative to serum osmolality gives an

Audio Video Share Participants More

10:34
594-042-7551 Leave

E Serum and urine osmolality

Urine osmolality relative to serum osmolality gives an accurate assessment of the state of the ADH axis. In the absence of other causes (eg CCF), a high urine osmolality relative to serum osmolality in the setting of hyponatraemia is inappropriate. Other tests, such as plasma ADH and detailed urine electrolyte studies, can give similar information, but at much greater expense and difficulty. Sulphonylureas are recognised as a rare cause of syndrome of inappropriate antidiuretic hormone secretion (SIADH); the condition is seen most commonly with chlorpropamide and, while this has been replaced by more modern agents such as gliclazide, it is still occasionally seen.

A 24-hour urinary protein and creatinine

This investigation is for measurement of total protein, it would be useful to diagnose nephrotic conditions. However this investigation would not give any indication of volume status.

B Erect/supine renin and aldosterone estimation

The aldosterone-to-renin ratio (ARR) (ie the ratio of plasma aldosterone to plasma renin activity) is the most sensitive means of differentiating primary from secondary causes of hyperaldosteronism. It is not useful for volume status assessment.

C Fractional excretion of Na^+

The fractional excretion of sodium is the percentage of the sodium filtered by the kidney which is excreted in the urine. It is measured in terms of plasma and urine sodium, rather than by the interpretation of urinary sodium concentration alone, as urinary sodium concentrations can vary with

Audio Video Share Participants More

B Erect/supine renin and aldosterone estimation

The aldosterone-to-renin ratio (ARR) (ie the ratio of plasma aldosterone to plasma renin activity) is the most sensitive means of differentiating primary from secondary causes of hyperaldosteronism. It is not useful for volume status assessment.

C Fractional excretion of Na^+

The fractional excretion of sodium is the percentage of the sodium filtered by the kidney which is excreted in the urine. It is measured in terms of plasma and urine sodium, rather than by the interpretation of urinary sodium concentration alone, as urinary sodium concentrations can vary with water reabsorption. Therefore, the urinary and plasma concentrations of sodium must be compared to get an accurate picture of renal clearance. In clinical use, the fractional excretion of sodium can be calculated as part of the evaluation of acute kidney failure in order to determine if hypovolaemia or decreased effective circulating plasma volume is a contributor to the kidney failure.

D Plasma ADH

Plasma ADH would be high in dehydration because it controls the amount of water that is excreted in the urine. ADH levels may be raised and low in certain pathological states such as SIADH or diabetes insipidus therefore it is not the best method to assess fluid status.

Rate this question:

Next Question

Previous Q... Tag Questi... Feedback End Session

A 39-year-old man comes to the clinic for follow-up after a short hospital admission for an episode of renal colic.

At the time of admission, the patient had an intravenous pyelogram performed that showed mid-ureteric calculi on the left side. There was delayed uptake and excretion of the contrast in the left kidney, consistent with obstruction. There was also a filling defect at the level of L5 consistent with the calcification seen on pre-contrast films.

While in the hospital, he underwent ureteroscopic stone extraction of the left mid-ureteral calculi. The calculi were sent to the laboratory for chemical analysis, and the image is shown below. He denies any history of calculi in the past or history of calculi in the family.

Image of calculi:

What will be the likely composition of the stones?

A	Calcium oxalate
B	Cysteine
C	Oxalate
D	Magnesium-ammonium-phosphate
E	Uric acid

Rana Alnasser's screen

D Magnesium-ammonium-phosphate

E Uric acid

Explanation

A Calcium oxalate

This patient has a radio-opaque calculus. Calcium oxalate-containing stones account for nearly 60% of all kidney stones. They are radio-opaque. Cysteine stones result from cysteinuria, which is due to an inherited autosomal recessive disorder of renal tubular reabsorption of four amino acids. Uric acids stones are not radio-opaque. Magnesium-ammonium-phosphate stones are infectious in aetiology. The most common organisms are *Proteus*, *Kleibsiella* and *Pseudomonas*.

B Cysteine

Cysteine stones are suspected in childhood stone formers. Mutation in the gene encoding an amino acid transporter leads to wasting of the cationic amino acids cysteine, ornithine, lysine and arginine.

C Oxalate

Hyperoxaluria can be associated with increased dietary oxalate or enhanced oxalate uptake due to ileal inflammation or resection, such as in inflammatory disease, and may lead to the formation of oxalate stones. Normally stones are in combination with calcium rather than oxalate alone.

D Magnesium-ammonium-phosphate

Rana Alnasser's screen

A 62-year-old man is admitted to hospital with a 3-day history of dyspnoea, pleuritic chest pain and several episodes of haemoptysis.

Before this, he described several months of constant rhinorrhoea, with some nasal crusting, several large epistaxes and constant pain below his eyes. More recently, he had noticed some double vision and swelling of his right eye.

On examination, he had low-grade pyrexia and was normotensive. There was some nasal mucosal ulceration and right-sided proptosis. Cardiovascular examination was unremarkable. He had localised areas of crepitations throughout both lung fields. His abdomen was soft and non-tender, with no masses. There were no focal neurological signs or skin lesions.

Investigation results are below:

Haemoglobin (Hb)	10.0 g/dl
White cell count	12.0×10^9/l
Platelets	390×10^9/l
Mean corpuscular volume (MCV)	90 fl
Erythrocyte sedimentation rate (ESR)	80 mm/h
Na^+	142 mmol/l
K^+	5.7 mmol/l
Urea	22.0 mmol/l
Creatinine	620 µmol/l
C-reactive protein	238 mg/L
Bilirubin	15 µmol/l
Alkaline	

Creatinine	820 µmol/l
C-reactive protein	238 mg/L
Bilirubin	15 µmol/l
Alkaline phosphatase	88 iu/l
Aspartate transaminase	32 iu/l
Ca^{2+}	2.42 mmol/l
Gamma-glutamyl transferase (GGT)	48 iu/l
Urinalysis	Blood +++ protein ++
Chest X-ray	Multiple large cavitating nodules throughout both lung fields
Electrocardiogram (ECG)	Normal sinus rhythm, no acute changes

What would be the most useful investigation in pointing to the diagnosis if positive?

A High-resolution computed tomography (CT) scan of the thorax

B Serum antiglomerular basement membrane antibodies

C Serum antineutrophil cytoplasmic antibodies

D Serum antinuclear antibodies

E Urine microscopy

Rana Alnasser's screen

10:41
Pastest+ 594-042-7551 Leave

Explanation

C	Serum antineutrophil cytoplasmic antibodies

This patient has the typical features of granulomatosis with polyangiitis (GPA), also known as Wegener's, which is a necrotising granulomatous arteritis of the upper and lower respiratory tract and kidney. It is rare, with an incidence of 5–10 per million. It is a multisystem disease and may affect the eyes, skin, joints, heart and nervous system. Pulmonary involvement is seen in 95% of cases, and renal involvement in 85% of cases. A positive serum antineutrophil cytoplasmic antibody (ANCA) is present in > 90% of cases of GPA and strongly supports the diagnosis. Renal biopsy is sometimes required.

Treatment is with steroids and cyclophosphamide. Untreated, 1-year mortality is 80%, but with appropriate therapy, remission can be achieved in up to 90% of patients.

A	High-resolution computed tomography (CT) scan of the thorax

This may show the cavitating lung lesions in more detail but will not aid in the diagnosis.

B	Serum antiglomerular basement membrane antibodies

This scenario is not antiglomerular basement membrane disease; therefore, these antibodies will be normal.

D	Serum antinuclear antibodies

Serum antinuclear antibodies will not aid in the diagnosis.

E	Urine microscopy

Audio Video Share Participants More

A High-resolution computed tomography (CT) scan of the thorax

This may show the cavitating lung lesions in more detail but will not aid in the diagnosis.

B Serum antiglomerular basement membrane antibodies

This scenario is not antiglomerular basement membrane disease; therefore, these antibodies will be normal.

D Serum antinuclear antibodies

Serum antinuclear antibodies will not aid in the diagnosis.

E Urine microscopy

Urine microscopy may show blood and protein; however, it is non-specific for the diagnosis.

71306

Rate this question:

Next Question

Previous Q... Tag Questi... Feedback End Session

Blog About Pastest Contact Us Help

© Pastest 2019

Rana Alnasser's screen

A 46-year-old man was admitted with 24 hours of severe pleuritic, retrosternal chest pain. He described a preceding 6-week history of malaise, fever, myalgia and 1 stone of weight loss. Over the last few days, he had also developed a rash and had noticed some loss of sensation in his feet and ankles which was causing some difficulty with walking.

On examination, his temperature was 39 °C, blood pressure was 190/108 mmHg, pulse 110 bpm regular. There was a friction rub audible at the left sternal edge. His chest was clear and his abdomen was soft and non-tender. He had paraesthesia in a stocking distribution bilaterally and purpuric skin lesions.

Investigation results are below:

Hb	8.6 g/dl
WCC	18×10^9/l
PLT	450×10^9/l
Mean corpuscular volume (MCV)	96 fl
Erythrocyte sedimentation rate (ESR)	102 mm/h
Na^+	132 mmol/l
K^+	5.8 mmol/l
Urea	26.0 mmol/l
Creatinine	860 µmol/l
Bilirubin	16 µmol/l
Aspartate transaminase (AST)	30 U/l
Alkaline phosphatase	80 U/l
Gamma-glutamyl transferase (GGT)	48 U/l
Urinalysis	Protein ++ blood +++

Urea	20.0 mmol/l
Creatinine	860 µmol/l
Bilirubin	16 µmol/l
Aspartate transaminase (AST)	30 U/l
Alkaline phosphatase	80 U/l
Gamma-glutamyl transferase (GGT)	48 U/l
Urinalysis	Protein ++ blood +++
Electrocardiogram (ECG)	Saddle-shaped ST segments across all leads
Chest X-ray	Normal
Serum pANCA and cANCA (antineutrophil cytoplasmic antibody)	Negative

What is the most likely diagnosis?

A Cryoglobulinaemia

B Goodpasture's syndrome

C Microscopic polyangitis

D Polyarteritis nodosa (PAN)

E Wegener's granulomatosis

Submit

Touc... 00:17 10:47

C Microscopic polyangitis

D Polyarteritis nodosa (PAN)

E Wegener's granulomatosis

Explanation

D Polyarteritis nodosa (PAN)

PAN is a necrotising vasculitis which causes aneurysms of medium-sized arteries with subsequent thrombosis and infarction. It occurs most commonly in middle-aged men. It is a multisystem disorder, but the most common causes of death are from renal (hypertension, kidney disease) and cardiac (coronary arteritis, myocardial infarction, pericarditis) involvement. Other features include mononeuritis multiplex, sensorimotor neuropathy, abdominal pain from infracted viscera and skin lesions (purpura, livedo reticularis). Diagnosis is made by a combination of clinical features plus renal or mesenteric angiography which will demonstrate microaneurysms. ANCA is very rarely positive in classic PAN. Treatment options include with high-dose corticosteroids, azathioprine and cyclophosphamide.

A Cryoglobulinaemia

Cryoglobulinaemia is associated with a purpuric rash on the legs (leucocytoclastic vasculitis on biopsy); it may be associated with infections such as hepatitis C. Symptoms include fatigue, weakness, weight loss, arthralgia, myalgia and mononeuritis multiplex. Other symptoms include hepatosplenomegaly and Raynaud's phenomenon. Renal manifestations include blood and protein in the urine. The proteinuria is frequently in the nephrotic range. There would be hypertension, renal impairment that is

Rana Alnasser's screen

and mononeuritis multiplex. Other symptoms include hepatosplenomegaly and Raynaud's phenomenon. Renal manifestations include blood and protein in the urine. The proteinuria is frequently in the nephrotic range. There would be hypertension, renal impairment that is progressive or even present as an acute kidney disease.

B Goodpasture's syndrome

Goodpasture's syndrome, also known as anti-GBM disease, is associated with pulmonary haemorrhage. There is pathogenic IgG anti-GBM antibodies against the α3 chain of the type IV collagen in the basement membrane of the glomerulus and alveolus. It may present gradually over months or years, or abruptly over days with fulminant pulmonary haemorrhage and kidney disease.

C Microscopic polyangitis

Microscopic polyangitis is less likely given that ANCA is negative, because it is a small-vessel vasculitis characterised by ANCA. Symptoms include weight loss, fever, malaise and flitting polyarthralgia. There is no ear, nose and throat involvement. P-ANCA (MPO) is positive with no granulomata in the kidneys. There is a low likelihood of relapse.

E Wegener's granulomatosis

Wegener's is less likely given that ANCA is negative because, similar to microscopic polyangitis, it is a small-vessel vasculitis characterised by ANCA. However, in contrast to microscopic polyangitis, there are frequently ear, nose and throat symptoms. C-ANCA (PR3) is positive with granulomata in the kidneys. There is a high likelihood of relapse.

A 22-year-old student presents with dark urine with the appearance of 'black tea', followed by swelling of the eyelids associated with malaise, anorexia and weakness.

She has no relevant medical history, although she reports having had an infection at the site of a skin piercing approximately 4 weeks previously, for which she was prescribed some antibiotics. She took these for 2 days but stopped because the infection cleared and she developed some abdominal pain while taking them.

On physical examination, her blood pressure is 125/70 mmHg, with chest and abdominal examination unremarkable.

Urinalysis:

Protein	3+
Blood	3+
Nitrites	Negative
Leukocytes	Negative

The likely diagnosis is?

A Acute intermittent porphyria

B Acute variegate porphyria

C Alkaptonuria

D Mesangioproliferative glomerulonephritis (immunoglobulin A [IgA] nephropathy)

E Post-streptococcal glomerulonephritis

Rana Alnasser's screen

(immunoglobulin A [IgA] nephropathy)

E Post-streptococcal glomerulonephritis

Explanation

E Post-streptococcal glomerulonephritis

This young woman has presented with a nephritic syndrome with frank (probably haemolysed) blood in her urine. The length of time after her skin infection makes the likely diagnosis a post-streptococcal glomerulonephritis (Option E).

A Acute intermittent porphyria

Acute intermittent porphyria can cause urinary discoloration when the urine is left to stand in sunlight, but this lady has dark urine when passed.

B Acute variegate porphyria

The clinical features in any case are not those of this form of porphyria, which typically presents with neuropathy, severe episodes of abdominal pain and neuropsychiatric disturbance. When comparing acute intermittent porphyria (AIP) and variegate porphyria, the latter rarely presents with acute episodes (unlike the former), and often the only reported symptom is excessive skin sensitivity to sunlight.

C Alkaptonuria

Alkaptonuria is an inborn error of the metabolism of tyrosine, resulting again in urine which turns black on standing due to excretion of homogentisic acid, which is oxidised on contact with air.

The clinical features in any case are not those of this form of porphyria, which typically presents with neuropathy, severe episodes of abdominal pain and neuropsychiatric disturbance. When comparing acute intermittent porphyria (AIP) and variegate porphyria, the latter rarely presents with acute episodes (unlike the former), and often the only reported symptom is excessive skin sensitivity to sunlight.

C Alkaptonuria

Alkaptonuria is an inborn error of the metabolism of tyrosine, resulting again in urine which turns black on standing due to excretion of homogentisic acid, which is oxidised on contact with air.

D Mesangioproliferative glomerulonephritis (immunoglobulin A [IgA] nephropathy)

Immunoglobulin A (IgA) nephropathy usually occurs with upper respiratory tract infections and usually either at the same time or within 2–3 days of these.

Rate this question:

Next Question

Previous Q... Tag Questi... Feedback End Session

Blog About Pastest Contact Us Help

© Pastest 2019

A 42-year-old homosexual man presents for review. He admits to unprotected sex with a number of men and has suffered a dry cough, shortness of breath and weight loss over the past few months.

His major current complaint is that has had progressive lower limb swelling which has worsened over the past few weeks. Blood pressure on examination is 135/75 mmHg and there is peripheral oedema. His BMI is 21.

Investigations reveal:

24-h urinary protein excretion	5.2 g
Haemoglobin (Hb)	10.9 g/dl
CD4 count	175/µl (> 500)
Albumin	27 g
Sodium (Na^+)	138 mmol/l
Potassium (K^+)	4.2 mmol/l
Creatinine	195 µmol/l
Urea	12.2 mmol/l

Which of the following is the initial treatment of choice for this patient's renal dysfunction?

A Antiretroviral drugs

B Corticosteroids

C Ciclosporin

D Cyclophosphamide

E Furosemide

10:57

there is peripheral oedema. His BMI is 21.

Investigations reveal:

24-h urinary protein excretion	5.2 g
Haemoglobin (Hb)	10.9 g/dl
CD4 count	175/µl (> 500)
Albumin	27 g
Sodium (Na^+)	138 mmol/l
Potassium (K^+)	4.2 mmol/l
Creatinine	195 µmol/l
Urea	12.2 mmol/l

Which of the following is the initial treatment of choice for this patient's renal dysfunction?

Your answer was correct

A Antiretroviral drugs

B Corticosteroids

C Ciclosporin

D Cyclophosphamide

E Furosemide

Explanation

A Antiretroviral drugs

Rana Alnasser's screen

10:57
NC ...
MyPastest
https://mypastest.pastest.com

A Antiretroviral drugs

B Corticosteroids

C Ciclosporin

D Cyclophosphamide

E Furosemide

Explanation

A Antiretroviral drugs

This patient has HIV-associated nephropathy (HIVAN), characterised by nephrotic range proteinuria, normal blood pressure, normal or increased kidney size on ultrasound scan and focal segmental glomerulosclerosis on renal biopsy. Treatment includes aggressive antiretroviral therapy and angiotensin-converting enzyme (ACE) inhibitor therapy for patients where this is not contraindicated due to hyperkalaemia.

B Corticosteroids

No completed randomised controlled trials exist for the use of second-line agents such as corticosteroids for HIVAN, although observational studies suggest that a benefit may exist.

C Ciclosporin

Rana Alnasser's screen

11:00

A 72-year-old woman who has undergone haemodialysis for 8 years presents with numbness and tingling in both hands, which wakes her from sleep in the early hours. In addition, she has had trouble holding items between her fingers and thumb recently. She also complains of dysphagia.

On examination, her BP is 155/82 mmHg, pulse is 75 bpm and BMI is 23. There is wasting of the thenar eminence on both hands and numbness over the palmar aspect of the thumb index and middle fingers.

Investigations:

Hb	12.4 g/dl
WCC	8.9×10^9/l
Platelets	500×10^9/l
Na^+	139 mmol/l
K^+	4.0 mmol/l
Urea	18.0 mmol/l
Creatinine	350 µmol/l
Hand X-ray	Some blood vessel calcification

Which of the following measures is most appropriate in this patient?

A Ciclosporin therapy

B Corticosteroid therapy

C Incision of the flexor retinaculae

D Non-steroidal anti-inflammatory drugs

Rana Alnasser's screen

On examination, her BP is 155/82 mmHg, pulse is 75 bpm and BMI is 23. There is wasting of the thenar eminence on both hands and numbness over the palmar aspect of the thumb index and middle fingers.

Investigations:

Hb	12.4 g/dl
WCC	8.9×10^9/l
Platelets	500×10^9/l
Na^+	139 mmol/l
K^+	4.0 mmol/l
Urea	18.0 mmol/l
Creatinine	350 μmol/l
Hand X-ray	Some blood vessel calcification

Which of the following measures is most appropriate in this patient?

A Ciclosporin therapy

B Corticosteroid therapy

C Incision of the flexor retinaculae

D Non-steroidal anti-inflammatory drugs

E Switch to low-flux dialysis membranes

32395

Submit

E Switch to low-flux dialysis membranes

Explanation

C Incision of the flexor retinaculae

This patient has dialysis amyloidosis due to excess beta-2 microglobulin. Most of the manifestations of dialysis amyloidosis are musculoskeletal and include carpal tunnel syndrome, flexor tenosynovitis, subchondral bone cysts and even pathological fractures. Treatment in this case involves surgical incision of the flexor retinaculae, as this patient has demonstrable distal nerve loss. In addition, switching to high-flux dialysis membranes consisting of polyacrylonitrile and polysulphone membranes reduces amyloid deposition. Renal transplantation halts progression of the disease. It is common for patients with kidney disease to have calcification of blood vessels due to high calcium.

A Ciclosporin therapy

Ciclosporin therapy would not be used in amyloidosis. It may be useful as an immunosuppressant in many autoimmune conditions, and for prevention of rejection in renal transplants.

B Corticosteroid therapy

There is no evidence that steroids are useful for amyloidosis, although steroid injections may be useful for some types of inflammatory rheumatoid arthritis.

D Non-steroidal anti-inflammatory drugs

Although non-steroidal anti-inflammatory drugs (NSAIDs) may help the pain in arthritic conditions, this would not

11:05
594-042-7551
Leave

A 39-year-old man, with a history of treated hypertension treated with ramipril 10 mg daily, comes to see the GP complaining of tiredness and lethargy. He runs some routine bloods, which are given below:

Investigations

Hb	12.0 g/dl
WCC	5.0×10^9/l
PLT	170×10^9/l
Na^+	133 mmol/l
K^+	5.6 mmol/l
Bicarbonate	16 mmol/l
Creatinine	180 µmol/l

Which of the following is the most likely diagnosis?

A Renal tubular acidosis type I

B Renal tubular acidosis type II

C Renal tubular acidosis type IV

D Addison's disease

E Conn syndrome

Audio
Video
Share
Participants
More

11:10
NC ...
MyPastest
https://mypastest.pastest.com

A 39-year-old man, with a history of treated hypertension treated with ramipril 10 mg daily, comes to see the GP complaining of tiredness and lethargy. He runs some routine bloods, which are given below:

Investigations

Hb	12.0 g/dl
WCC	5.0×10^9/l
PLT	170×10^9/l
Na^+	133 mmol/l
K^+	5.6 mmol/l
Bicarbonate	16 mmol/l
Creatinine	180 µmol/l

Which of the following is the most likely diagnosis?

Your answer was correct

A Renal tubular acidosis type I

B Renal tubular acidosis type II

C Renal tubular acidosis type IV

D Addison's disease

E Conn syndrome

Explanation

C Renal tubular acidosis type IV

Type IV RTA, also known as hyperkalaemic RTA occurs when the kidney fails to respond to aldosterone. This leads to hyperkalaemic metabolic acidosis. Pharmacological causes of type IV RTA include spironolactone, ACE inhibitors and ARBS, trimethoprim, heparin, pentamidine and NSAIDs. Structural kidney diseases such as SLE and amyloidosis can also affect response to aldosterone and lead to type IV RTA. Where there is a causative agent that can be discontinued, alternative therapy should be provided, otherwise patients may be offered bicarbonate supplements and agents to lower serum potassium.

A Renal tubular acidosis type I

There is disordered excretion of acid (H^+) in this condition from the collecting ducts, resulting in acidosis. Therefore the clinical picture will be a hyperchloraemic, hypokalaemic metabolic acidosis with hypophosphataemic metabolic bone disease, renal stones or diffuse nephrocalcinosis. It is rarely inherited, or it may be secondary to conditions such as chronic tubular-interstitial disease and dysproteinaemias.

B Renal tubular acidosis type II

There is impaired bicarbonate retention in the proximal tubule leading to bicarbonate wasting and a systemic acidosis. This will present with a hyperchloraemic metabolic acidosis, with other features of proximal tubular dysfunction such as phosphate wasting and reduced serum urate. There would be glycosuria and proteinuria with loss of amino acids.

of amino acids.

D Addison's disease

Patients with Addison's disease have low blood pressure rather than hypertension. There may be hyperpigmentation of the skin, even in areas that are not sun-exposed. Characteristic areas of darkening include skin creases, nipple and buccal mucosa. This is because melanocyte-stimulating hormone and ACTH share the same precursor (pro-opiomelanocortin). Investigations review a low sodium, high potassium, high calcium and low glucose.

E Conn syndrome

Conn syndrome is associated with elevated aldosterone and therefore the serum potassium would be low rather than high in this case. Patients with Conn syndrome often have few or no symptoms, but some may get occasional muscle weakness, muscle spasms, paraesthesiae or polyuria. High blood pressure and muscle cramps occur due to low serum calcium.

Rate this question:

© Pastest 2019

11:12
594-042-7551
Leave

50-year-old man presented with a 4-month history of hypertension, headaches, and impaired vision. Two weeks ago he noted blood in his urine. His medical history was significant – he had a left nephrectomy 16 years previously.

The following is the MRI scan of his abdomen and brain:

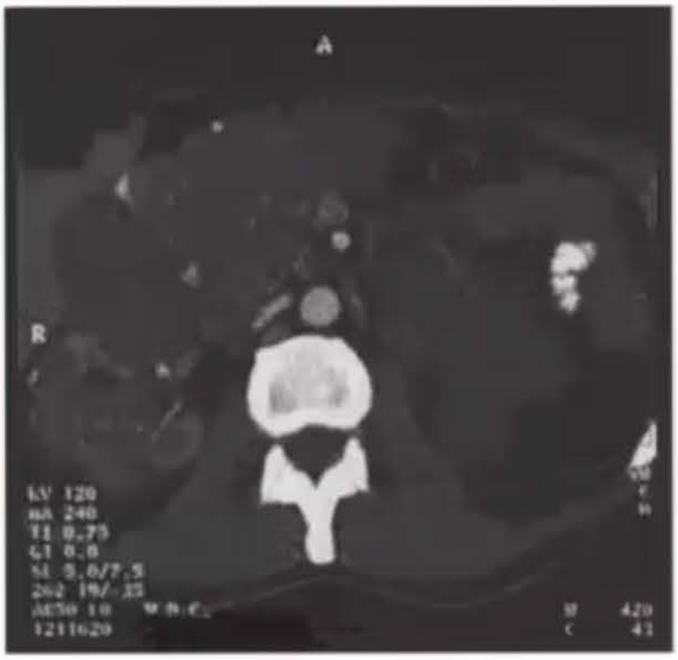

What is the diagnosis?

A Autosomal dominant polycystic kidney disease

B Autosomal recessive polycystic kidney disease

Audio Video Share Participants More

3G 11:14
NC ...

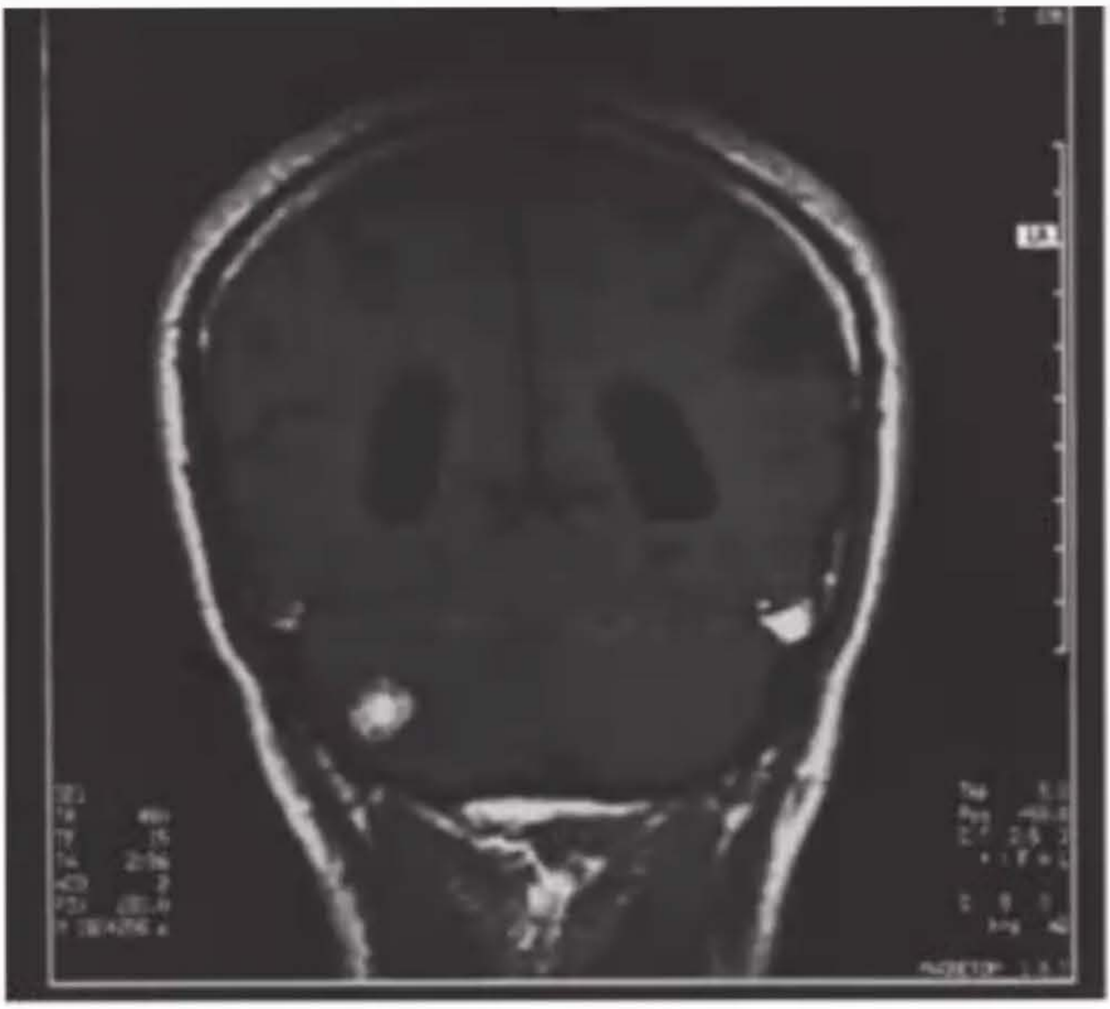

What is the diagnosis?

A	Autosomal dominant polycyst
B	Autosomal recessive polycyst
C	Tuberose sclerosis
D	von-Hippel Lindau disease
E	Histiocytosis X

11:16
594-042-7551
Leave

D von-Hippel Lindau disease

Von Hippel-Lindau disease is an autosomal dominant condition that manifests in CNS haemangioblatomas, renal and pancreatic cysts, renal carcinoma and phaeochromocytomas. Renal cysts are usually multiple and bilateral and are often associated with solid tumours. Other causes of renal cystic disease include ADPKD, ARPKD, tuberose sclerosis complex, medullary cystic disease and renal cystic dysplasia.

A Autosomal dominant polycystic kidney disease

This would not explain the MRI brain findings. ADPKD commonly presents in adulthood and may be associated with intracranial berry aneurysms.

B Autosomal recessive polycystic kidney disease

This commonly presents in either the neonatal period or up to adolescence with renal impairment.

C Tuberose sclerosis

In TSC 80% of affected individuals have seizures and manifest with angiomyolipomas in skin and visceral organs at a younger age.

E Histiocytosis X

Langerhans cell histiocytosis, which is also called Histiocytosis X is incorrect. It is a multisystem disease with predominant bone manifestations.

Rate this question:
Audio Video Share Participants More

A Autosomal dominant polycystic kidney disease

This would not explain the MRI brain findings. ADPKD commonly presents in adulthood and may be associated with intracranial berry aneurysms.

B Autosomal recessive polycystic kidney disease

This commonly presents in either the neonatal period or up to adolescence with renal impairment.

C Tuberose sclerosis

In TSC 80% of affected individuals have seizures and manifest with angiomyolipomas in skin and visceral organs at a younger age.

E Histiocytosis X

Langerhans cell histiocytosis, which is also called Histiocytosis X is incorrect. It is a multisystem disease with predominant bone manifestations.

Rate this question:

Next Question

Previous Q... Tag Questi... Feedback End Session

© Pastest 2019

Rana Alnasser's screen

11:18
594-042-7551 Leave

A 68-year-old woman is admitted with a 4-day history of profuse bloody diarrhoea, vomiting and lower abdominal pain. She had a past medical history of well-controlled hypertension and mild asthma, but her health had been good until the onset of the presenting illness. She had no recent foreign travel and did not smoke or drink.

On examination, she was drowsy, but oriented when roused. Her temperature was 39 °C, pulse 110 bpm and regular, blood pressure 102/60 mmHg, and she was clinically dehydrated.

Cardiorespiratory examination was unremarkable. Her abdomen was soft and diffusely tender with scanty bowel sounds and no palpable masses. There were no focal neurological signs or rashes.

Investigation results are below:

Hb	8.0 g/dl
WCC	26.0×10^9/l
Platelets	48×10^9/l
MCV	84 fl
Na^+	147 mmol/l
K^+	5.8 mmol/l
Urea	25 mmol/l
Creatinine	780 mmol/l
Bilirubin	32 µmol/l
AST	34 IU/l
ALP	80 IU/l
GGT	54 U/l
Urinalysis	Protein ++ blood ++

Audio Video Share Participants More

Platelets	48×10^9/l
MCV	84 fl
Na^+	147 mmol/l
K^+	5.8 mmol/l
Urea	25 mmol/l
Creatinine	780 mmol/l
Bilirubin	32 µmol/l
AST	34 IU/l
ALP	80 IU/l
GGT	54 U/l
Urinalysis	Protein ++ blood ++
Abdominal X-ray	No dilated bowel loops
Chest X-ray	Clear lung fields, no subdiaphragmatic air

What of the following is the most likely diagnosis?

A *Campylobacter* infection

B *E. coli* infection

C Norovirus infection

D Salmonellosis

E *Staphylococcus aureus* gastroenteritis

B *E. coli* infection

The diagnosis is haemolytic uraemic syndrome (HUS), which causes a microangiopathic haemolysis with thrombocytopenia. HUS is similar to thrombotic thrombocytopenic purpura (TTP), but there are a number of differences between the two conditions. HUS usually presents in childhood or old age, with acute kidney disease following a diarrhoeal illness, whereas TTP is more common in young adults with predominantly neurological features, such as fits and confusion. There is a strong association with verotoxin-producing *E. coli* 0157 and this organism should be looked for specifically in the stool culture. A normal coagulation screen will exclude disseminated intravascular coagulation which can present similarly. The blood film will show fragmented and deformed red cells. The mortality of HUS with good supportive care is less than 10%. Treatment includes fresh frozen plasma and plasma exchange, but antibiotics are not seen to positively affect prognosis.

A *Campylobacter* infection

Campylobacter is a Gram-negative bacterium that is typically comma- or s-shaped and it is mobile. The infection comes from contaminated food or coming in contact with infected animals. The organism produces diffuse, bloody, oedematous and exudative enteritis. Although rarely the infection been considered a cause of HUS and TTP, no unequivocal case reports exist. In some cases, a *Campylobacter* infection can be the underlying cause of Guillain–Barré syndrome and gastrointestinal perforation is a rare complication of ileal infection.

C Norovirus infection

Norovirus is sometimes referred to as winter vomiting bug, and it is a common cause of viral gastroenteritis. It can

weakness, muscle aches, headaches and low-grade fevers may occur. The disease is usually self-limiting, and severe illness is rare.

D Salmonellosis

Salmonellosis presents with diarrhoea, fever, vomiting and abdominal cramps 12–72 hours after the infection. In the majority of cases, the illness lasts 4–7 days and most people recover without treatment. In some cases the diarrhoea may be so severe as to lead to dehydration and the need for hospitalisation for fluid replacement. There is no association with HUS.

E *Staphylococcus aureus* gastroenteritis

Staph. aureus gastroenteritis occurs as a result of eating or drinking substances that are contaminated with the staphylococcal enterotoxin. The toxin then settles in the small intestine and causes inflammation and swelling. This in turn can cause abdominal pain, cramping, dehydration, diarrhoea and fever. It is not associated with HUS.

32475

Rate this question:

Next Question

Previous Q... Tag Questi... Feedback End Session

Blog About Pastest Contact Us Help

© Pastest 2019

A 48-year-old woman was admitted to hospital for investigation of a 2-month history of polyuria, polydipsia and increased thirst. She had bipolar affective disorder, which was well-controlled on lithium, and no other medical problems.

She smoked 5–10 cigarettes per day and did not drink alcohol. There was no relevant family history. Physical examination was unremarkable.

Investigation results are below:

Sodium (Na^+)	148 mmol/l
Potassium (K^+)	4.3 mmol/l
Urea	5.2 mmol/l
Creatinine	92 µmol/l
Calcium (Ca^{2+})	2.30 mmol/l
Glucose (fasting)	5.0 mmol/l
Plasma osmolality	340 mosmol/kg (278–305)
Urine osmolality	280 mosmol/kg (350–1000)

The patient proceeded to a water deprivation test, the results of which are below:

	Urine osmolality (mOsmol/kg)
After 8 h of fluid deprivation	200
After desmopressin administration	240

What is the diagnosis?

A Conn syndrome

Creatinine	92 μmol/l
Calcium (Ca^{2+})	2.30 mmol/l
Glucose (fasting)	5.0 mmol/l
Plasma osmolality	340 mosmol/kg (278–305)
Urine osmolality	280 mosmol/kg (350–1000)

The patient proceeded to a water deprivation test, the results of which are below:

	Urine osmolality (mOsmol/kg)
After 8 h of fluid deprivation	200
After desmopressin administration	240

What is the diagnosis?

A Conn syndrome

B Cranial diabetes insipidus (DI)

C Nephrogenic diabetes insipidus

D Psychogenic polydipsia

E Syndrome of inappropriate antidiuretic hormone (ADH) secretion

Submit

Creatinine	92 µmol/l
Calcium (Ca^{2+})	2.30 mmol/l
Glucose (fasting)	5.0 mmol/l
Plasma osmolality	340 mosmol/kg (278–305)
Urine osmolality	280 mosmol/kg (350–1000)

The patient proceeded to a water deprivation test, the results of which are below:

	Urine osmolality (mOsmol/kg)
After 8 h of fluid deprivation	200
After desmopressin administration	240

What is the diagnosis?

Your answer was correct

A Conn syndrome

B Cranial diabetes insipidus (DI)

C Nephrogenic diabetes insipidus

D Psychogenic polydipsia

E Syndrome of inappropriate antidiuretic hormone (ADH) secretion

Explanation

Explanation

C Nephrogenic diabetes insipidus

DI is due to either reduced vasopressin (ADH) secretion from the posterior pituitary gland (cranial DI) or renal resistance to its action (nephrogenic DI). It must be distinguished from psychogenic polydipsia, which is excessive fluid intake usually secondary to psychiatric disturbance.

In DI, there should be high plasma and low urine osmolality. The diagnosis is confirmed by the water deprivation test. The patient is fluid-restricted for 8 h, and the blood/urine osmolality and weight are measured hourly.

In cranial DI, the urine osmolality should rise to > 660 mOsmol/kg after desmopressin, whereas there will be little to no response in nephrogenic DI.

The causes of nephrogenic DI include drugs (eg lithium), hypokalaemia and hypercalcaemia, or it can be inherited. Management mainly involves treating or removing the cause, although bendroflumethiazide can be used. Cranial DI will respond to intranasal desmopressin.

A Conn syndrome

Conn syndrome is a cause of hypertension, but with no abnormality in urine osmolality.

B Cranial diabetes insipidus (DI)

In cranial DI, the urine osmolality should rise to > 660 mOsmol/kg after desmopressin. Cranial DI will respond to intranasal desmopressin.

D Psychogenic polydipsia

A Conn syndrome

Conn syndrome is a cause of hypertension, but with no abnormality in urine osmolality.

B Cranial diabetes insipidus (DI)

In cranial DI, the urine osmolality should rise to > 660 mOsmol/kg after desmopressin. Cranial DI will respond to intranasal desmopressin.

D Psychogenic polydipsia

Psychogenic polydipsia is excessive fluid intake, usually secondary to psychiatric disturbance. There would be an increase in urine osmolality after water deprivation.

E Syndrome of inappropriate antidiuretic hormone (ADH) secretion

Syndrome of inappropriate ADH secretion is associated with low sodium in plasma.

Rate this question:

© Pastest 2019

11:28

A 58-year-old man, previously in good health, suddenly develops severe abdominal pain radiating from the left loin to the groin and associated with nausea, perspiration and frequent urination.

There is a history of diverticular disease but nil else of note. He is restless, tossing and turning in bed.

His BP is elevated at 180/90 mmHg, his pulse is 95/min and he is in obvious pain.

What is the most likely diagnosis?

A	Herpes zoster involving the left lower rib dermatome
B	Left ureteric calculus
C	Retroperitoneal haemorrhage
D	Sigmoid diverticulitis
E	Torsion of the left testicle

71115

Submit

3G 11:30

A 58-year-old man, previously in good health, suddenly develops severe abdominal pain radiating from the left loin to the groin and associated with nausea, perspiration and frequent urination.

There is a history of diverticular disease but nil else of note. He is restless, tossing and turning in bed.

His BP is elevated at 180/90 mmHg, his pulse is 95/min and he is in obvious pain.

What is the most likely diagnosis?

Your answer was correct

A	Herpes zoster involving the left lower rib dermatome
B	Left ureteric calculus
C	Retroperitoneal haemorrhage
D	Sigmoid diverticulitis
E	Torsion of the left testicle

Explanation

B Left ureteric calculus

This is a typical case of ureteric colic. It is sudden in onset, radiating from loin to groin, and is associated with urge to urinate frequently. It is the pain radiating to the groin that points more towards ureteric colic versus diverticulitis, the

Rana Alnasser's screen

E Torsion of the left testicle

Explanation

B Left ureteric calculus

This is a typical case of ureteric colic. It is sudden in onset, radiating from loin to groin, and is associated with urge to urinate frequently. It is the pain radiating to the groin that points more towards ureteric colic versus diverticulitis, the major differential here. The usual causes are blood clots and calculi. Urine examination reveals macroscopic or microscopic haematuria.

A Herpes zoster involving the left lower rib dermatome

The left lower rib dermatome would not be radiating pain from loin to groin.

C Retroperitoneal haemorrhage

We would expect a drop in blood pressure with retroperitoneal haemorrhage and back pain.

D Sigmoid diverticulitis

Sigmoid diverticulitis would not reveal haematuria; it would present with acute abdominal pain, fever, nausea and vomiting. Frequently diagnosed on CT abdominal scan.

E Torsion of the left testicle

Torsion of the left testicle would not cause loin pain typically. Testicular torsion would present with severe

11:31

This is a typical case of ureteric colic. It is sudden in onset, radiating from loin to groin, and is associated with urge to urinate frequently. It is the pain radiating to the groin that points more towards ureteric colic versus diverticulitis, the major differential here. The usual causes are blood clots and calculi. Urine examination reveals macroscopic or microscopic haematuria.

A Herpes zoster involving the left lower rib dermatome

The left lower rib dermatome would not be radiating pain from loin to groin.

C Retroperitoneal haemorrhage

We would expect a drop in blood pressure with retroperitoneal haemorrhage and back pain.

D Sigmoid diverticulitis

Sigmoid diverticulitis would not reveal haematuria; it would present with acute abdominal pain, fever, nausea and vomiting. Frequently diagnosed on CT abdominal scan.

E Torsion of the left testicle

Torsion of the left testicle would not cause loin pain typically. Testicular torsion would present with severe testicular pain and tachycardia. There may be difficulty in passing urine due to the pain. The testicles would be swollen, red and tender.

Rate this question:

Next Question

Rana Alnasser's screen

A 19-year-old boy presents to his general practitioner (GP) complaining of macroscopic haematuria which began 48 h after he started with a recent respiratory tract infection. He has a past medical history of asthma and eczema. He takes salbutamol inhalers, as required, on occasions.

On examination, his blood pressure is 142/86 mmHg, chest and abdominal examination is unremarkable. He has no peripheral oedema.

Investigations reveal:

K^+	4.0 mmol/l
Na^+	145 mmol/l
Creatinine	155μmol/l
Urea	14.0 mmol/l
Urine	Culture negative, red cells 3+, protein 1+
Urine microscopy	Leukocytes and red cell casts
Renal biopsy	Diffuse mesangial proliferation and extracellular matrix expansion. A few necrotising lesions with crescent formation are noted.

Which is the next best treatment for his condition?

A Calcium channel antagonists

B Ciclosporin

C Low-protein diet

D Prednisolone therapy

has a past medical history of asthma and eczema. He takes salbutamol inhalers, as required, on occasions.

On examination, his blood pressure is 142/86 mmHg, chest and abdominal examination is unremarkable. He has no peripheral oedema.

Investigations reveal:

K^+	4.0 mmol/l
Na^+	145 mmol/l
Creatinine	155μmol/l
Urea	14.0 mmol/l
Urine	Culture negative, red cells 3+, protein 1+
Urine microscopy	Leukocytes and red cell casts
Renal biopsy	Diffuse mesangial proliferation and extracellular matrix expansion. A few necrotising lesions with crescent formation are noted.

Which is the next best treatment for his condition?

A Calcium channel antagonists

B Ciclosporin

C Low-protein diet

D Prednisolone therapy

E Doxazocin

11:34
NC ...
MyPastest
https://mypastest.pastest.com

Creatinine	155μmol/l
Urea	14.0 mmol/l
Urine	Culture negative, red cells 3+, protein 1+
Urine microscopy	Leukocytes and red cell casts
Renal biopsy	Diffuse mesangial proliferation and extracellular matrix expansion. A few necrotising lesions with crescent formation are noted.

Which is the next best treatment for his condition?

Your answer was correct

A Calcium channel antagonists

B Ciclosporin

C Low-protein diet

D Prednisolone therapy

E Doxazocin

Explanation

D Prednisolone therapy

This young man has immunoglobulin A (IgA) nephropathy as illustrated by the presentation with haematuria post-

Rana Alnasser's screen

11:34

B Ciclosporin

C Low-protein diet

D Prednisolone therapy

E Doxazocin

Explanation

D Prednisolone therapy

This young man has immunoglobulin A (IgA) nephropathy as illustrated by the presentation with haematuria post-respiratory tract infection and the histological findings on renal biopsy. Gross proteinuria is rare, but haematuria is the commonest form of presentation. The disease is commoner in males, and presents most often in the second and third decades. Management includes control of hypertension, with angiotensin-converting enzyme (ACE) inhibitors the preferred agent, and use of corticosteroids. Where there is crescenteric nephritis on biopsy, intravenous pulsed corticosteroids are employed, with the addition of cyclophosphamide. Thankfully, progression to end-stage renal disease is uncommon in this condition. Where end-stage renal disease does occur, renal transplantation carries a high chance of success.

A Calcium channel antagonists

Angiotensin-converting enzyme (ACE) inhibitors are the preferred agent rather than calcium channel antagonists because ACE inhibitors will help reduce proteinuria while calcium channel antagonists may even increase proteinuria.

B Ciclosporin

Rana Alnasser's screen

11:35

because ACE inhibitors will help reduce proteinuria while calcium channel antagonists may even increase proteinuria.

B Ciclosporin

It is cyclosphosphamide which would be added early to the steroid regime rather than ciclosporin. Ciclosporin may be a considered agent later on down the line for disease control.

C Low-protein diet

A low-protein diet may reduce proteinuria. However, it would not be used on its own to control symptoms. In fact, there is no evidence that low-protein diets alter disease progression.

E Doxazocin

Angiotensin-converting enzyme (ACE) inhibitors are the preferred agents rather than doxazocin to control blood pressure and proteinuria.

Rate this question:

Next Question

Previous Q... Tag Questi... Feedback End Session

© Pastest 2019

Rana Alnasser's screen

11:35

MyPastest
https://mypastest.pastest.com

Pastest+

A 49-year-old man with a history of type 1 diabetes is admitted to the Emergency Room with an epileptic seizure. He has chronic kidney disease and has been receiving dialysis for the past three months.

Medication includes ramipril, amlodipine, aspirin, calcium and vitamin D, and periodic injections of recombinant erythropoietin, which were begun recently.

On examination, his blood pressure (BP) is 145/85 mmHg, with a temperature of 37.8 °C; his Glasgow Coma Scale (GCS) score is 13.

Investigations:

Hb	11.5 g/dl
WCC	5.6 x10^9/l
PLT	295 x10^9/l
Na^+	139 mmol/l
K^+	5.0 mmol/l
Creatinine	656 µmol/l
Glucose	3.9 mmol/l
Computed tomography (CT) head	No focal lesion identified

Which of the following is the most likely cause of his seizure?

A Bacterial meningitis

B Erythropoietin-induced epilepsy

On examination, his blood pressure (BP) is 145/85 mmHg, with a temperature of 37.8 °C; his Glasgow Coma Scale (GCS) score is 13.

Investigations:

Hb	11.5 g/dl
WCC	5.6 x10^9/l
PLT	295 x10^9/l
Na^+	139 mmol/l
K^+	5.0 mmol/l
Creatinine	656 µmol/l
Glucose	3.9 mmol/l
Computed tomography (CT) head	No focal lesion identified

Which of the following is the most likely cause of his seizure?

A Bacterial meningitis

B Erythropoietin-induced epilepsy

C Ischaemic stroke

D Viral meningitis

E Uraemic encephalopathy

Submit

C Ischaemic stroke

D Viral meningitis

E Uraemic encephalopathy

Explanation

B Erythropoietin-induced epilepsy

This is erythropoietin-induced epilepsy. This rare, adverse event is seen within 90 days of erythropoietin initiation. His white blood cell count is normal, making sepsis less likely, and the elevated temperature here is just likely to be the result of his fit.

The creatinine level of 656 μmol/l is most likely due to the interval between his dialysis sessions. The exact mechanism related to the seizures is unclear but may be related to veno-occlusive disease or the rise in haemoglobin associated with erythropoietin use.

A Bacterial meningitis

This is incorrect because we would have expected the white cell count to be raised. In bacterial meningitis, there may be symptoms of fever, skin rash and meningism, such as photophobia and neck stiffness.

Lumbar puncture for bacterial meningitis usually shows an elevated opening pressure (> 25 cm of cerebrospinal fluid) and a white blood cell count of > 100 cells/μl, with > 90% of polymorphs; glucose level is low (< 40% of serum glucose) and protein level is elevated (> 50 mg/dl).

C Ischaemic stroke

Rana Alnasser's screen

The other symptoms of an

11:38

This is incorrect because we would have expected the white cell count to be raised. In bacterial meningitis, there may be symptoms of fever, skin rash and meningism, such as photophobia and neck stiffness.

Lumbar puncture for bacterial meningitis usually shows an elevated opening pressure (> 25 cm of cerebrospinal fluid) and a white blood cell count of > 100 cells/µl, with > 90% of polymorphs; glucose level is low (< 40% of serum glucose) and protein level is elevated (> 50 mg/dl).

C Ischaemic stroke

CT head shows no focal lesion. The other symptoms of an ischaemic stroke depend on the location of the stroke, but may include hemiplegia, visual disturbances and dysphasia.

D Viral meningitis

We would have expected the white cell count to be abnormal. Viral meningitis may present with symptoms of meningism, such as photophobia and neck stiffness.

Lumbar puncture for viral meningitis shows a normal or elevated opening pressure, a white blood cell count of 10–1000 cells/µl, classically lymphocytes, but there may be polymorphs early on, and glucose levels normally > 60% of serum levels, but they may be low in herpes simplex virus (HSV) infection. Protein levels are elevated (> 50 mg/dl).

The common culprits are HSV, varicella-zoster virus and adenovirus/enteroviruses. Therefore, a lumbar puncture sample should be sent for viral polymerase chain reaction (PCR).

E Uraemic encephalopathy

He has been receiving dialysis for the last three months; it would be unlikely that his urea level would be raised, [illegible] adequate dialysis

Rana Alnasser's screen

may include hemiplegia, visual disturbances and dysphasia.

D Viral meningitis

We would have expected the white cell count to be abnormal. Viral meningitis may present with symptoms of meningism, such as photophobia and neck stiffness.

Lumbar puncture for viral meningitis shows a normal or elevated opening pressure, a white blood cell count of 10–1000 cells/µl, classically lymphocytes, but there may be polymorphs early on, and glucose levels normally > 60% of serum levels, but they may be low in herpes simplex virus (HSV) infection. Protein levels are elevated (> 50 mg/dl).

The common culprits are HSV, varicella-zoster virus and adenovirus/enteroviruses. Therefore, a lumbar puncture sample should be sent for viral polymerase chain reaction (PCR).

E Uraemic encephalopathy

He has been receiving dialysis for the last three months; it would be unlikely that his urea level would be raised, providing he was getting adequate dialysis.

Rate this question:

© Pastest 2019

Rana Alnasser's screen

A 44-year-old woman presents to her GP for review. She has attended the GP on a number of occasions during the past year for sinusitis and is now concerned that the bridge of her nose has collapsed and that she may require cosmetic surgery.

Upon examination, blood pressure is 160/70 mmHg, chest is clear and abdominal examination is unremarkable.

Chest X-ray is abnormal and reveals multiple nodules. Routine blood testing reveals a creatinine of 205 μmol/l.

Renal biopsy reveals:

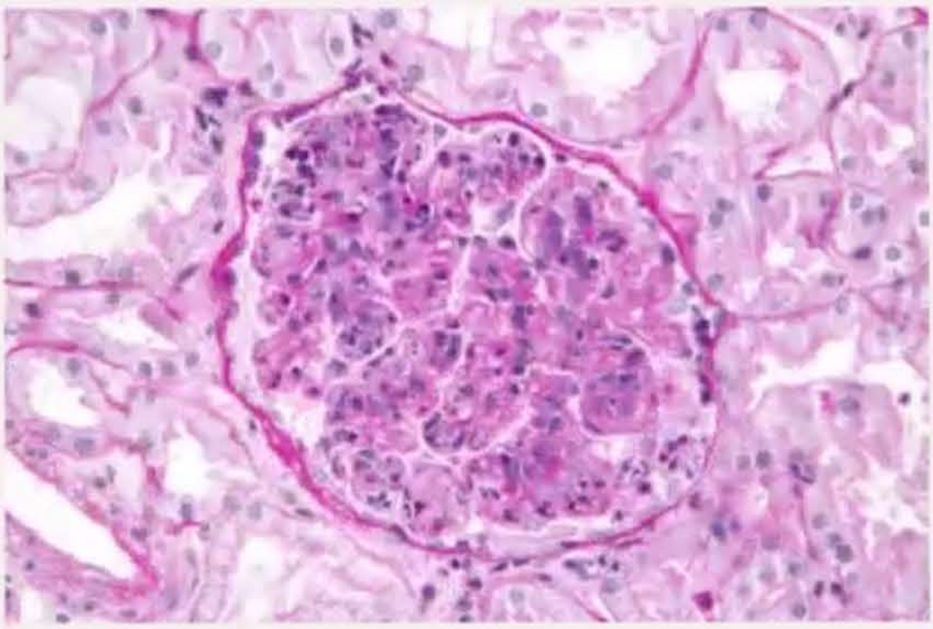

Which of the following is the best initial treatment for this condition?

A	Azathioprine
B	Corticosteroids
C	Cyclophosphamide
D	Corticosteroids and cyclophosphamide
E	Methotrexate

E Methotrexate

Explanation

D Corticosteroids and cyclophosphamide

The clinical history is highly suggestive of Wegener's granulomatosis. Often patients present with severe rhinorrhoea, complicated by nasal ulceration and later cough with haemoptysis. Chest X-ray reveals nodular changes ± pneumonic features. Renal involvement is characterised by microvascular glomerulonephritis, which is what is illustrated in the picture. Treatment is with cyclophosphamide in combination with corticosteroids in patients with severe disease.

A Azathioprine

Azathioprine may be used in the maintenance therapy for Wegener's granulomatosis when the patient is in remission

B Corticosteroids

Corticosteroids would treat the inflammation, but would not be used alone in therapy. Before the introduction of steroids, over 75% of patients who had vital organ involvement and vasculitis would die. However, after the introduction of steroids, 5-year mortality fell to 50% and further decreased to 12% with the addition of cytotoxic drugs for polyarteritis nodosa. Few data exist for the use o steroids alone for Wegener's granulomatosis, but we woul expect a similar reduction in death; therefore the addition of cytotoxic medications in addition to steroids is important.

C Cyclophosphamide

Rana Alnasser's screen

11:43

NC ··· 93% 21:43

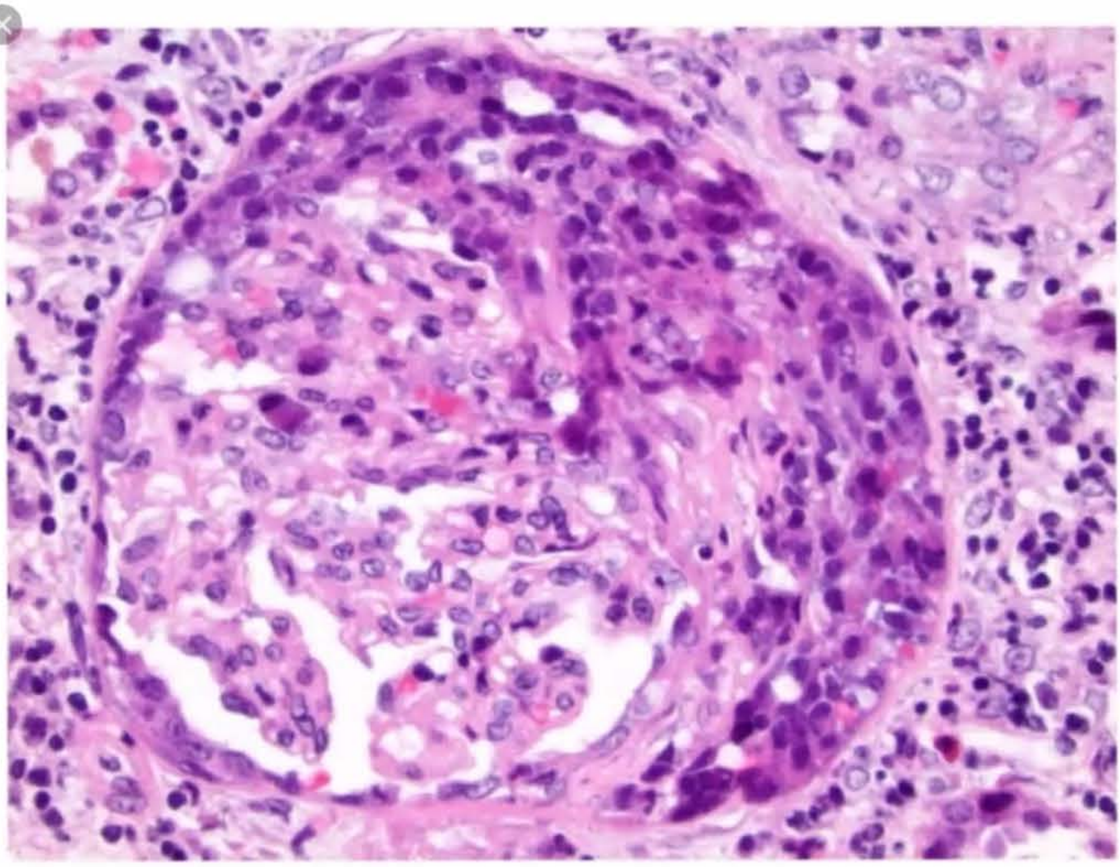

ResearchGate

H&E stains showing crescentic glomerulonephritis with moderate ...

H&E stains showing crescentic glomerulonephritis with moderate interstitial inflammation and mild fibrosi
evidence of

Annotation Stop Share

Images may be subject to copyright. Learn more

RELATED IMAGES

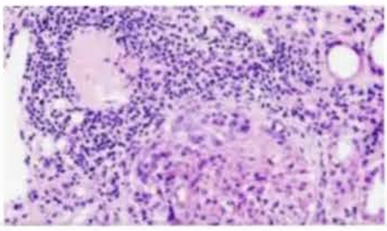

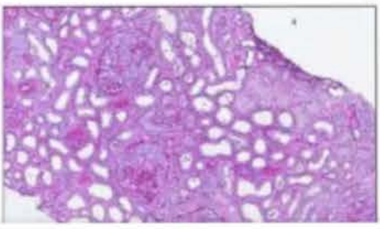

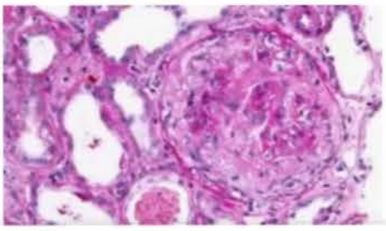

Discover Updates Search Recent More

Rana Alnasser's screen

11:43
594-042-7551
Leave
93% 21:43

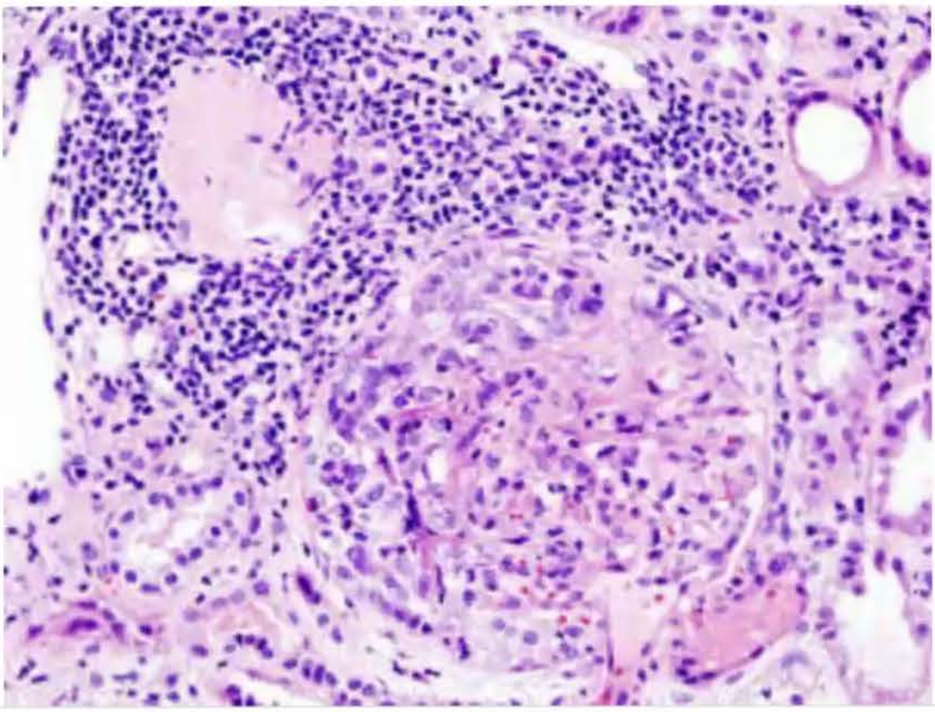

Wikipedia

Rapidly progressive glomerulonephritis - Wikipedia

Rapidly progressive glomerulonephritis

Images may be subject to copyright. Learn more

RELATED IMAGES

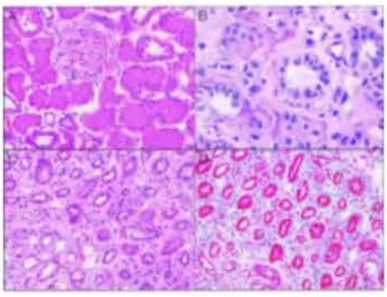

Histopathology of renal biopsy demonstratin...
researchgate.net

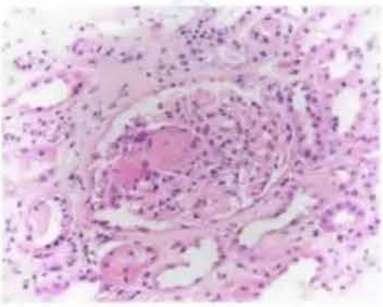

Photomicrograph of the renal biopsy with a ...
researchgate.net

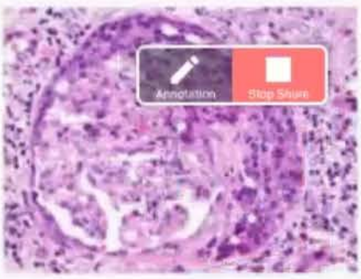

H&E stains showing crescentic glomerulone...
researchgate.net

Discover Updates Search Recent More

Audio Video Share Participants More

11:44

A 38-year-old man with a 12-year history of human immunodeficiency virus (HIV), with a good response to therapy, was admitted with a 12-day history of weakness, nausea, dysuria, myalgia and decreased urine output. His last CD4 lymphocyte count was 368 × 10^6/l (normal range 500-900). The current medications included didanosine, stavudine, atorvastatin, trimethoprim-sulfamethoxazole, and he had been commenced on Indinavir.

On examination, he was afebrile, pulse 100/min and regular, BP 176/99 mmHg, the JVP was not elevated; the chest and abdominal examinations were normal.

Investigations:

Hb	13.5 g/dl
WCC	6.7 × 10^9/l
PLT	200 × 10^9/l
Na^+	135 mmol/l
K^+	5.2 mmol/l
Cl^-	102 mmol/l
Bicarbonate	16 mmol/l
Urea	29.2 mmol/l
Creatinine	765 µmol/l
Bone profile	Normal
Creatine kinase	100 U/l
Antineutrophil cytoplasmic antibodies (ANCA)	Negative

Rana Alnasser's screen

11:45

Bicarbonate	18 mmol/l
Urea	29.2 mmol/l
Creatinine	765 µmol/l
Bone profile	Normal
Creatine kinase	100 U/l
Antineutrophil cytoplasmic antibodies (ANCA)	Negative
Anti-GBM	Negative
Hep B/Hep C	Negative
Antistreptolysin O titre (ASOT)	Negative

Cultures of blood/urine/sputum were negative.

Which one of the following investigations will be most helpful in making the diagnosis?

A Native renal biopsy

B Renal ultrasound scan

C Serum immunoglobulins

D Urine for crystals

E X-ray studies of kidneys, ureters, bladder (KUB)

Rana Alnasser's screen

C Serum immunoglobulins

D Urine for crystals

E X-ray studies of kidneys, ureters, bladder (KUB)

Explanation

D Urine for crystals

Testing the urine for crystals would confirm nephrolithiasis as the cause of AKI and specifically point to indinavir as the causative agent. Drugs used in patients with HIV may cause AKI. This occurs most commonly with protease inhibitors, in particular indinavir; therefore, it is the causative agent in this case by causing intratubular crystal obstruction. It has also been reported with ritonavir.

A Native renal biopsy

Nephrolithiasis may not be detected and the presence of acute tubular necrosis would not allow you to differentiate the offending agent.

B Renal ultrasound scan

Renal ultrasound scan would be useful if obstruction was suspected or to detect shrunken kidneys from chronic kidney disease. Although the blood pressure is high, there is no sign of fluid overload and the acute kidney injury (AKI) is related to medication changes.

C Serum immunoglobulins

There are no clinical or biochemical parameters to suggest

acute tubular necrosis would not allow you to differentiate the offending agent.

B Renal ultrasound scan

Renal ultrasound scan would be useful if obstruction was suspected or to detect shrunken kidneys from chronic kidney disease. Although the blood pressure is high, there is no sign of fluid overload and the acute kidney injury (AKI) is related to medication changes.

C Serum immunoglobulins

There are no clinical or biochemical parameters to suggest myeloma or light chain deposition disease as the cause of AKI. There is no anaemia and bone profile is normal.

E X-ray studies of kidneys, ureters, bladder (KUB)

The radiological imaging procedures typically used in the diagnosis of ureteral stones appear to be unreliable in the diagnosis of non-opaque stones due to indinavir.

71287

Rate this question:

© Pastest 2019

Rana Alnasser's screen

11:52

A 23-year-old man was admitted to hospital with severe left loin pain and vomiting. Prior to this he described a 5-week history of worsening generalised weakness and anorexia. He was previously well and on no regular medication.

On examination, he was in obvious discomfort and hyperventilating. There was tenderness and guarding in the left renal angle, but no other significant findings.

Investigation results are below:

Hb	14 g/dl
WCC	6.0×10^9/l
PLT	200×10^9/l
Mean corpuscular volume (MCV)	96 fl
Na^+	142 mmol/l
K^+	2.9 mmol/l
Urea	5.2 mmol/l
Creatinine	120 µmol/l
Bicarbonate	16 mmol/l
Chloride	120 mmol/l
Phosphate	0.7 mmol/l (0.8-1.4)
Urate	0.32 mmol/l

Arterial blood gases (on air):

pH	7.210
$P_a(O_2)$	12.6 kPa
$P_a(CO_2)$	4.8 kPa
Urinalysis	pH 6.3, blood ++

Rana Alnasser's screen

A 23-year-old man was admitted to hospital with severe left loin pain and vomiting. Prior to this he described a 5-week history of worsening generalised weakness and anorexia. He was previously well and on no regular medication.

On examination, he was in obvious discomfort and hyperventilating. There was tenderness and guarding in the left renal angle, but no other significant findings.

Investigation results are below:

Hb	14 g/dl
WCC	6.0×10^9/l
PLT	200×10^9/l
Mean corpuscular volume (MCV)	96 fl
Na^+	142 mmol/l
K^+	2.9 mmol/l
Urea	5.2 mmol/l
Creatinine	120 µmol/l
Bicarbonate	16 mmol/l
Chloride	120 mmol/l
Phosphate	0.7 mmol/l (0.8-1.4)
Urate	0.32 mmol/l

Arterial blood gases (on air):

pH	7.210
$P_a(O_2)$	12.6 kPa
$P_a(CO_2)$	4.8 kPa
Urinalysis	pH 6.3, blood ++
Abdominal	Speckled calcification in the left and right

Urea	5.2 mmol/l
Creatinine	120 µmol/l
Bicarbonate	16 mmol/l
Chloride	120 mmol/l
Phosphate	0.7 mmol/l (0.8-1.4)
Urate	0.32 mmol/l

Arterial blood gases (on air):

pH	7.210
$P_a(O_2)$	12.6 kPa
$P_a(CO_2)$	4.8 kPa
Urinalysis	pH 6.3, blood ++
Abdominal X-ray	Speckled calcification in the left and right upper quadrants

What is the most likely diagnosis?

A Fanconi syndrome

B Medullary sponge kidney

C Type 1 (distal) renal tubular acidosis

D Type 2 (proximal) renal tubular acidosis

E Type 4 renal tubular acidosis

Submit

Urinalysis	pH 6.3, blood ++
Abdominal X-ray	Speckled calcification in the left and right upper quadrants

What is the most likely diagnosis?

Your answer was correct

A Fanconi syndrome

B Medullary sponge kidney

C Type 1 (distal) renal tubular acidosis

D Type 2 (proximal) renal tubular acidosis

E Type 4 renal tubular acidosis

Explanation

C Type 1 (distal) renal tubular acidosis

The kidneys are unable to create an acid urine due to failure of hydrogen ion excretion in the distal tubule. Urine pH will be greater than 5.5, often in the presence of a severe systemic acidosis. There is almost invariably hypokalaemia, which can cause severe weakness. Hypercalciuria and hyperphosphaturia occur due to the release of calcium phosphate from bone in order to buffer excess hydrogen ions during acidosis, and the direct effects of acidosis on tubular reabsorption of these ions. Other clinical features include bone pain due to osteomalacia, renal stones, constipation, fatigue and anorexia. Nephrocalcinosis may be seen. Renal function is usually preserved. In children it commonly presents with

C Type 1 (distal) renal tubular acidosis

The kidneys are unable to create an acid urine due to failure of hydrogen ion excretion in the distal tubule. Urine pH will be greater than 5.5, often in the presence of a severe systemic acidosis. There is almost invariably hypokalaemia, which can cause severe weakness. Hypercalciuria and hyperphosphaturia occur due to the release of calcium phosphate from bone in order to buffer excess hydrogen ions during acidosis, and the direct effects of acidosis on tubular reabsorption of these ions. Other clinical features include bone pain due to osteomalacia, renal stones, constipation, fatigue and anorexia. Nephrocalcinosis may be seen. Renal function is usually preserved. In children it commonly presents with polyuria, thirst and failure to thrive. Biochemically, there is a hyperchloraemic metabolic acidosis with a normal anion gap. Causes of type 1 renal tubular acidosis include autoimmune diseases (eg systemic lupus erythematosus), drugs (eg amphotecerin B), or it may be inherited or idiopathic. Treatment is with bicarbonate replacement (1–3 mmol/kg/day); however hypokalaemia must be corrected before the acidosis in order to prevent a further fall in the potassium and the risk of cardiac arrest. Nephrocalcinosis is not a feature of proximal renal tubular acidosis.

A Fanconi syndrome

Fanconi syndrome is a generalised descriptive term for proximal tubular dysfunction. There is a failure of the proximal tubules to reabsorb many filtered substances and classically there is phosphate wasting. There is bone pain and osteomalacia. The causes are as for proximal renal tubular acidosis (see below). Investigations would show a metabolic acidosis, reduced serum phosphate, reduced serum urate, glycosuria, proteinuria and increased urinary phosphate and citrate.

11:59

phosphate and citrate.

B Medullary sponge kidney

Medullary sponge kidney is a benign common condition characterised by diffuse medullary cystic formation. Impaired calcium handling leads to formation of calcium-containing stones. There are no other biochemical abnormalities such as acidosis seen in this case.

D Type 2 (proximal) renal tubular acidosis

There is impaired retention of bicarbonate in the proximal tubule leading to bicarbonate wasting and systemic acidosis. There is hypercholoraemic metabolic acidosis. Common causes include myeloma, amyloidosis, cystinosis, Wilson's disease and heavy metal toxicity.

E Type 4 renal tubular acidosis

This is known as hyporeninaemic hypoaldosteronism. Aldosterone promotes urinary potassium loss so its absence leads to hyperkalaemia. Investigations would show hyperkalaemia, low bicarbonate (rarely less than 16 mmol/l), normal anion gap with increased chloride, negative urinary anion gap, reduced urinary citrate. Urine pH is variable but often less than 5.3.

Rate this question:

Rana Alnasser's screen

A 19-year-old man with malaria has been admitted to the Zambia University Teaching Hospital. He has no past medical history of note.

On admission, he was started on oral chloroquine. After being on the ward for 3 days, his condition continues to worsen and a nurse notices that he has not passed urine. He is already managed with IV fluids.

His blood results are as follows:

Na^+	138 mmol/l
K^+	6.2 mmol/l
Urea	54 mmol/l
Creatinine	785 µmol/l
Hb	8.7 g/dl
MCV	80 fl
WCC	6×10^9/l
Platelets	213×10^9 /l
Blood film	+++ for ring forms

The patient is catheterised and only 50 ml of dark urine is drained. He is given IV calcium for CV protection because of his potassium.

What is the appropriate step in the immediate management of this patient's infection?

A Arrange a blood transfusion

B Peritoneal dialysis

C Repeat the blood film

His blood results are as follows:

Na^+	138 mmol/l
K^+	6.2 mmol/l
Urea	54 mmol/l
Creatinine	785 μmol/l
Hb	8.7 g/dl
MCV	80 fl
WCC	6×10^9/l
Platelets	213×10^9 /l
Blood film	+++ for ring forms

The patient is catheterised and only 50 ml of dark urine is drained. He is given IV calcium for CV protection because of his potassium.

What is the appropriate step in the immediate management of this patient's infection?

A Arrange a blood transfusion

B Peritoneal dialysis

C Repeat the blood film

D Start intravenous quinine

E Urine microscopy and culture

12:02
594-042-7551 Leave

A 19-year-old man with malaria has been admitted to the Zambia University Teaching Hospital. He has no past medical history of note.

On admission, he was started on oral chloroquine. After being on the ward for 3 days, his condition continues to worsen and a nurse notices that he has not passed urine. He is already managed with IV fluids.

His blood results are as follows:

Na^+	138 mmol/l
K^+	6.2 mmol/l
Urea	54 mmol/l
Creatinine	785 µmol/l
Hb	8.7 g/dl
MCV	80 fl
WCC	6×10^9/l
Platelets	213×10^9 /l
Blood film	+++ for ring forms

The patient is catheterised and only 50 ml of dark urine is drained. He is given IV calcium for CV protection because of his potassium.

What is the appropriate step in the immediate management of this patient's infection?

A
B
C
D
E

Your answer was incorrect

Audio Video Share Participants More

Explanation

D Start intravenous quinine

This patient has severe malaria and renal impairment is common among adults with severe falciparum malaria. Blackwater fever is characterised by massive haemolysis, black urine and kidney disease. If the anuric patient survives the acute phase and effective dialysis is undertaken, the flow of urine usually recommences in about 4 days. The patient should be started on intravenous quinine with a loading dose of 20 mg/kg (up to maximum dose of 1.4 g) infused over 4 hours. You may like to refer to up-to-date evidence on the NICE website for further reference.

A Arrange a blood transfusion

There is no role for blood transfusion in malaria treatment unless there is co-existent symptomatic anaemia.

B Peritoneal dialysis

This patient has acute kidney disease which may be reversible with malaria treatment and supportive care which includes intravenous fluids. There is no indication for acute dialysis in this scenario. Acute dialysis may be required if there is pulmonary oedema resistant to medical treatment, life-threatening hyperkalaemia, flash pulmonary oedema, metabolic acidosis resistant to medical treatment or uraemic pericarditis or encephalopathy.

C Repeat the blood film

A repeat blood film will confirm the diagnosis, but will not be helpful in this scenario as the patient needs treatment.

10:45

MyPastest
https://mypastest.pastest.com

Pastest+

A 42-year-old banker was admitted with a 2-hour history of central crushing chest pain radiating down his left arm. He admits to abusing intravenous drugs in the past and is a life-long smoker. His past medical history includes hypertension and irritable bowel syndrome.

On admission, a fast-track troponin level was raised. ECG demonstrated anterolateral ST segments elevated > 2 mm. He was treated for a myocardial infarction (MI) with intravenous thrombolysis followed by intravenous heparin infusion. ST segments returned to normal. Three days later in hospital this man developed a purpuric rash over his legs.

On examination, there were normal heart sounds with no added murmurs. Chest examination revealed clinically a small left-sided pleural effusion. The abdominal examination was unremarkable. Neurological examination revealed weakness of his left arm: the patient felt this has been present for a while now since sustaining an injury playing football. ECG demonstrated sinus rhythm and anterolateral Q waves.

Blood results at this time show:

Na^+	139 mmol/l
K^+	4.6 mmol/l
Urea	15.0 mmol/l
Creatinine	179 µmol/l
CRP	150 mg/l
ESR	87 mm/h
ANA	Positive
ANCA	Negative
Hb	10 g/dl

Rana Alnasser's screen

Creatinine	175 μmol/l
CRP	150 mg/l
ESR	87 mm/h
ANA	Positive
ANCA	Negative
Hb	10 g/dl
WCC	11.4×10^9/l
Neutrophils	8.0×10^9/l
Eosinophils	0.09×10^9/l
PLT	560×10^9/l
HBsAg	Positive
HBeAg	Negative
Hep B anti-core AB	Positive
Hep C AB	Negative

What is the most likely diagnosis?

A Microscopic polyangiitis

B Polyarteritis nodosa

C Streptokinase-induced vasculitis

D Systemic lupus erythematosus

E Wegener's granulomatosis

10:48

MyPastest
https://mypastest.pastest.com

Pastest+

Explanation

B Polyarteritis nodosa

The American College of Rheumatology states that patients must have three of the following to have a diagnosis of polyarteritis nodosa (PAN): weight loss >5 kg, livedo reticularis, testicular pain/tenderness, myalgia, mono/polyneuropathy, diastolic BP >90 mmHg, elevated urea/creatinine, hepatitis B virus. This man clearly has a systemic vasculitis given a history of cardiac, gastrointestinal and renal involvement. The recent neurological involvement clinches the diagnosis of PAN.

A Microscopic polyangiitis

In this scenario, the test for antineutrophil cytoplasmic antibodies (ANCA) is negative which rules out microscopic polyangiitis.

C Streptokinase-induced vasculitis

A vasculitis secondary to streptokinase occurs mainly in those who have received previous streptokinase therapy and does not explain the other manifestations. It is an immune-complex phenomenon and antistreptokinase antibodies can be measured. Renal impairment can occur.

D Systemic lupus erythematosus

Patients with SLE tend to present with other skin manifestations and low platelets.

E Wegener's granulomatosis

A 38-year-old woman, who underwent a live related renal transplant for chronic kidney disease secondary to chronic pyelonephritis 12 weeks previously, attends the clinic for routine follow up. She is taking tacrolimus and mycophenolate mofetil (MMF).

Her urea and electrolytes are below:

Na^+	136 mmol/l
K^+	3.7 mmol/l
Urea	7.2 mmol/l
Creatinine	146 µmol/l

She had last been seen in clinic 2 weeks previously, when her urea was 4.2 mmol/l and creatinine 98 µmol/l. She is clinically well and asymptomatic.

On examination, she was apyrexial and normotensive. Her transplant site was non-tender with no swelling and there were no other signs to be found.

Which of the following is the next radiological investigation of choice?

A	CT abdomen
B	Doppler ultrasound scan of the transplant site
C	Intravenous urography
D	Plain abdominal film
E	Renal angiography

B Doppler ultrasound scan of the transplant site

C Intravenous urography

D Plain abdominal film

E Renal angiography

Explanation

B Doppler ultrasound scan of the transplant site

Graft dysfunction is an early complication of renal transplantation and can present asymptomatically with a rising serum creatinine. It is important to exclude sepsis in these patients, even if they are asymptomatic and apyrexial, and cultures should always be checked. Tacrolimus levels should also be measured, as this drug can be directly nephrotoxic. Mycophenolate mofetil (MMF) does not need levels monitoring. Doppler ultrasound of the transplant site should be arranged to look for any obstruction, arterial or venous occlusion and is the initial radiological investigation of choice.

A CT abdomen

CT abdomen will be normal in graft dysfunction and will not show any abnormality in this case. In addition, you would not want to expose the patient to unnecessary radiation.

C Intravenous urography

Intravenous urography will show any obstruction in the urinary tracts. It would not be helpful in this situation as the

does not need levels monitoring. Doppler ultrasound of the transplant site should be arranged to look for any obstruction, arterial or venous occlusion and is the initial radiological investigation of choice.

A CT abdomen

CT abdomen will be normal in graft dysfunction and will not show any abnormality in this case. In addition, you would not want to expose the patient to unnecessary radiation.

C Intravenous urography

Intravenous urography will show any obstruction in the urinary tracts. It would not be helpful in this situation as the first step is to carry out a simple Doppler ultrasound of the transplant site. If there was a ureteric obstruction you would expect some abdominal pain which is absent in this case.

D Plain abdominal film

A plain abdominal film would not be helpful in graft dysfunction. It may be used to diagnose intestinal obstruction. This patient has no abdominal pain which would indicate the need for a plain abdominal film to be carried out.

E Renal angiography

Renal angiography or biopsy may be needed in due course, but it is not a first-line investigation. This investigation may be used to diagnose any thrombosis causing renal graft dysfunction.

Rate this question:

A 65-year-old man was admitted with pneumonia and hyponatraemia with sodium of 116 mmol/l.

He was treated with antibiotics and rapid infusion of 3% hypertonic sodium chloride, but despite initial improvement deteriorated neurologically with fits and subsequent coma.

What is the possible cause of his deterioration?

A	Syndrome of inappropriate antidiuretic hormone secretion
B	Acute cerebrovascular event
C	Central pontine myelinolysis
D	Normal pressure hydrocephalus
E	Encephalomyelitis

Submit

Previous Q... Skip Questi...

© Pastest 2019

C Central pontine myelinolysis

Central pontine myelinolysis (CPM) occurs as a result of too-rapid correction of hyponatraemia; ideally correction should not exceed more than 1 mmol/h. There is demyelination of the central basal pons or other areas of the brain. Various types of neurological deficits have been described from quadriparesis to coma and death. Magnetic resonance imaging (MRI) is the investigation of choice to demonstrate classical demyelination.

A Syndrome of inappropriate antidiuretic hormone secretion

SIADH is defined by hyponatraemia and hypo-osmolality due to inappropriate, continued secretion of ADH despite normal or increased plasma volume, which results in impaired water excretion. In this scenario the sodium was corrected prior to fits.

B Acute cerebrovascular event

Stroke would not occur as a result of rapid correction of sodium.

D Normal pressure hydrocephalus

Normal pressure hydrocephalus is a clinical symptom due to a build-up of cerebrospinal fluid. It is characterised by an abnormal gait, urinary incontinence and potentially reversible dementia.

E Encephalomyelitis

There is no indication of viral infection in this case. Encephalomyelitis is not associated with sodium

10:54

A 42-year-old woman with known systemic lupus erythematosus presents with a 3-month history of fatigue, bilateral leg swelling and increasing abdominal distension.

On examination, she had periorbital oedema, ascites and pitting oedema to the groin. Her chest was clear, the heart sounds were normal and her jugular venous pressure was not raised.

Investigation results are below:

(Hb)	9.0 g/dl
(WCC)	3.6×10^9/l
PLT	120×10^9/l
Mean corpuscular volume (MCV)	82 fl
Albumin	28 g/l
Na^+	147 mmol/l
K^+	3.1 mmol/l
Bilirubin	10 µmol/l
Urea	8.2 mmol/l
Alkaline phosphatase (AST)	80 iu/l
Creatinine	162 mmol/l
Aspartate transaminase	22 iu/l
Cholesterol	8.2 mmol/l
Urinalysis	Protein +++
24 h urinary protein excretion	4.5 g

She was commenced on treatment with high-dose diuretics and immunosuppressant therapy. Several weeks later, she was readmitted with abdominal pain. On examination, she had a mild pyrexia and was tender in both loins.

Rana Alnasser's screen

Urinalysis	Protein +++
24 h urinary protein excretion	4.5 g

She was commenced on treatment with high-dose diuretics and immunosuppressant therapy. Several weeks later, she was readmitted with abdominal pain. On examination, she had a mild pyrexia and was tender in both loins.

Repeat investigation results are below:

Hb	8.9 g/dl
WCC	3.2×10^9/l
Creatinine	320 μmol/l
Na^+	148 mmol/l
K^+	5.2 mmol/l
Urea	14.6 mmol/l
Urinalysis	Protein +++ blood +++

What is the most likely cause for the acute deterioration in renal function?

A Acute pyelonephritis

B Renal artery stenosis

C Renal infarction

D Renal vein thrombosis

E Renal calculus

Na^+	147 mmol/l
K^+	3.1 mmol/l
Bilirubin	10 µmol/l
Urea	8.2 mmol/l
Alkaline phosphatase (AST)	80 iu/l
Creatinine	162 mmol/l
Aspartate transaminase	22 iu/l
Cholesterol	8.2 mmol/l
Urinalysis	Protein +++
24 h urinary protein excretion	4.5 g

She was commenced on treatment with high-dose diuretics and immunosuppressant therapy. Several weeks later, she was readmitted with abdominal pain. On examination, she had a mild pyrexia and was tender in both loins.

Repeat investigation results are below:

Hb	8.9 g/dl
WCC	3.2×10^9/l
Creatinine	320 µmol/l
Na^+	148 mmol/l
K^+	5.2 mmol/l
Urea	14.6 mmol/l
Urinalysis	Protein +++ blood +++

What is the most likely cause for the acute deterioration in renal function?

Your answer was correct

10:58
On
594-042-7551
Leave

D Renal vein thrombosis

The initial diagnosis was nephrotic syndrome secondary to systemic lupus erythematosus, which was then complicated by renal vein thrombosis. This occurs in 10–20% of patients with nephrotic syndrome and is more common in those with membranous glomerulonephritis. Patients with nephrotic syndrome are in a hypercoagulable state due to a combination of intravascular volume depletion (exacerbated by diuretics) and the loss of clotting factors in the urine (particularly antithrombin III), and are therefore at high risk of thromboses. Renal vein thrombosis may be silent, causing gradually worsening renal impairment, or can present acutely as in this case. Diagnosis is with Doppler ultrasound of the renal veins, computed tomography (CT)/magnetic resonance imaging (MRI) or venography. Management includes mobilisation, avoidance of volume depletion and long-term anticoagulation. The imaging results are not described here but the bilateral signs and symptoms do suggest involvement of both kidneys.

Bilateral renal vein thrombosis, although less common than the unilateral form, can occur as an acute phenomenon and is an indication for more aggressive management including, if necessary, thrombolysis.

A Acute pyelonephritis

Pyelonephritis would tend to present with more severe pain, dysuria and haematuria; the clinical picture of nephritic syndrome would not be typical and is much better explained here by a diagnosis of renal vein thrombosis.

B Renal artery stenosis

Renal artery stenosis is not associated with systemic lupus erythematosus (SLE), and it does not present with

Audio Video Share Participants More

10:58
On
594-042-7551
Leave

A 39-year-old man presents with a history of poor urine output over the past 2 days. Other than bloody diarrhoea about a week ago, he has no other significant history. There were several other patients who had presented with bloody diarrhoea in the last 24 h and who had attended the same eatery that he had attended. He takes no regular medications.

On examination, his blood pressure is 150/90 mmHg, with a heart rate of 110 bpm.

Which of the following tests would be useful for establishing the cause of his acute kidney disease?

A	AXR
B	Blood film
C	Clotting screen
D	Potassium measurement
E	Stool culture

71100

Submit

Audio
Video
Share
Participants
More

10:59
On
594-042-7551
Leave

A 39-year-old man presents with a history of poor urine output over the past 2 days. Other than bloody diarrhoea about a week ago, he has no other significant history. There were several other patients who had presented with bloody diarrhoea in the last 24 h and who had attended the same eatery that he had attended. He takes no regular medications.

On examination, his blood pressure is 150/90 mmHg, with a heart rate of 110 bpm.

Which of the following tests would be useful for establishing the cause of his acute kidney disease?

Your answer was correct

A	AXR
B	Blood film
C	Clotting screen
D	Potassium measurement
E	Stool culture

Explanation

B Blood film

You should suspect a diagnosis of haemolytic–uraemic syndrome (HUS) associated with diarrhoea caused by Escherichia [illegible] Once the bacteria colonize, diarrhoea followed by bloody diarrhoea with oliguria, haematuria and

Audio
Video
Share
Participants
More

C Clotting screen

D Potassium measurement

E Stool culture

Explanation

B Blood film

You should suspect a diagnosis of haemolytic–uraemic syndrome (HUS) associated with diarrhoea caused by *Escherichia coli*. Once the bacteria colonize, diarrhoea followed by bloody diarrhoea with oliguria, haematuria and kidney disease ensues. On the blood tests there is thrombocytopenia and destruction of red blood cells – microangiopathic haemolytic anaemia – and this may be seen on blood film.

A AXR

The bowel loops may be distended due to colitis, but it will not be diagnostic of HUS. Distended bowel loops may be present in many other forms of diarrhoea.

C Clotting screen

The clotting screen will be normal unless the patient becomes so unwell they show a disseminated intravascular coagulation (DIC) picture.

D Potassium measurement

Th[illegible] concentration may well be high in cases of

not be diagnostic of HUS. Distended bowel loops may be present in many other forms of diarrhoea.

C Clotting screen

The clotting screen will be normal unless the patient becomes so unwell they show a disseminated intravascular coagulation (DIC) picture.

D Potassium measurement

The potassium concentration may well be high in cases of both acute kidney disease and haemolysis, but it will not give you the diagnosis.

E Stool culture

Shiga-like toxin-producing bacteria such as enterohaemorrhagic *Escherichia coli* (EHEC), of which *E. coli* O157:H7 is the most common serotype, may be the cause of HUS. However, it is the toxin rather than culture of bacteria which would be indicative of the cause.

Rate this question:

Next Question

Previous Q... Tag Questi... Feedback End Session

Blog About Pastest Contact Us Help

Rana Alnasser's screen

10:59

A 50-year-old woman received a cadaveric renal transplant 8 weeks ago for diabetic nephropathy. Upon discharge, her serum creatinine was normal. She attended the Transplant Follow-up Clinic.

You understand that her GP prescribed an antibiotic for a respiratory tract infection during the last 2 weeks, and she is penicillin allergic. Her BP is 135/72 mmHg, and her transplant scar is healing well.

Investigations:

Hb	11.5 g/dl
WCC	9×10^9 /l
Platelets	350×10^9 /l
Na^+	140 mmol/l
K^+	5.2 mmol/l
Urea	14.8 mmol/l
Creatinine	150 µmol/l

Which one of the following is most likely to explain the rise in creatinine?

A Acute ciclosporin toxicity

B Acute graft rejection

C Chronic graft rejection

D Cytomegalovirus infection

E Vascular thrombosis of the transplant vessels

Rana Alnasser's screen

Explanation

A	Acute ciclosporin toxicity

Ciclosporin toxicity can occur either as acute or chronic in otherwise well patients. Given the recent history of antibiotic use for respiratory tract infection in a patient who is penicillin allergic, it's likely she was exposed to erythromycin or clarithromycin. These two macrolides are potent inhibitors of CYP3A4, and as such lead to elevated levels of ciclosporin. Given its narrow therapeutic window, a relatively small elevation in ciclosporin can result in renal toxicity. Erythromycin and clarithromycin should be avoided in patients treated with ciclosporin if at all possible. Azithromycin is associated with a lesser degree of 3A4 inhibition.

B	Acute graft rejection

Acute graft rejection is a sudden deterioration in renal function associated with specific immunopathological changes, as categorised according to histological criteria called the Banff classification. The risk is greater up to 2 weeks postoperatively, and it occurs in about 30–50% of all transplants. Classically the presentation includes fever, painful graft and oligo-anuria, but this is now rare. It now usually presents with asymptomatic rise in creatinine. The recent infection with antibiotic makes ciclosporin toxicity more likely in this case.

C	Chronic graft rejection

Both immunological and non-immunological factors play a role in graft dysfunction and loss beyond 3 months. It is used to describe the appearances found with a progressively declining graft function. At 2 years post-transplant, 70–90% of grafts will demonstrate features of

Both immunological and non-immunological factors play a role in graft dysfunction and loss beyond 3 months. It is used to describe the appearances found with a progressively declining graft function. At 2 years post-transplant, 70–90% of grafts will demonstrate features of chronic allograft nephropathy. In this scenario it is too early to be chronic graft rejection.

D Cytomegalovirus infection

Transplant recipients are immunosuppressed, and therefore they are susceptible to a range of infections. Patients who are at risk of CMV are generally started on prophylaxis such as valganciclovir/ganciclovir – and therefore these infections are less likely. There may be a low white cell count associated with CMV infection, which is not demonstrated in this case.

E Vascular thrombosis of the transplant vessels

Transplant renal artery thrombosis may occur, and would present with reduction in renal function, hypertension and salt and water retention. Doppler ultrasound and angiography will diagnose any thrombosis. The infection history is not relevant in vascular thrombosis, so makes this diagnosis less likely in this case.

32389

Rate this question:

11:05

A 66-year-old man on peritoneal dialysis for end-stage kidney disease presents with a 3-month history of tiredness secondary to anaemia, in spite of increased subcutaneous erythropoietin therapy.

Investigations:

Hb	6.2 g/dl
WCC	6.2×10^9/l
Differential WCC	normal
Platelets	200×10^9/l
Haematocrit	0.2
MCV	80 fl
Reticulocyte count	0%
Faecal occult bloods	negative
Colonoscopy	normal
Upper GI endoscopy	normal
Haptoglobins	normal

What is the most likely cause of his anaemia?

A Hypothyroidism

B Myelodysplasia

C Myelofibrosis

D Pure red cell aplasia

Rana Alnasser's screen

Hb	6.2 g/dl
WCC	$6.2 \times 10^9/l$
Differential WCC	normal
Platelets	$200 \times 10^9/l$
Haematocrit	0.2
MCV	80 fl
Reticulocyte count	0%
Faecal occult bloods	negative
Colonoscopy	normal
Upper GI endoscopy	normal
Haptoglobins	normal

What is the most likely cause of his anaemia?

Your answer was correct

A Hypothyroidism

B Myelodysplasia

C Myelofibrosis

D Pure red cell aplasia

E Chronic lymphocytic leukaemia

Explanation

E Chronic lymphocytic leukaemia

Explanation

D Pure red cell aplasia

Pure red cell aplasia (PRCA) is a rare condition defined by the absence of erythroblasts in the bone marrow, leading to profound anaemia with normal leucocyte and platelet counts, and characterised by low or absent circulating reticulocytes. Serum iron and ferritin rise sharply as iron cannot be incorporated into the erythrocytes.

PRCA occurs due to neutralising antibodies to erythropoietin. There has been a recent increase in PRCA in patients with chronic kidney disease on subcutaneous erythropoietin alpha. Treatment includes discontinuation of the EPO preparation and repeated transfusions.

A Hypothyroidism

The normal MCV and WCC make hypothyroidism unlikely.

B Myelodysplasia

The normal MCV and WCC make myelodysplasia unlikely. The myelodysplastic syndromes comprise a heterogeneous group of malignant hematopoietic stem cell disorders characterised by dysplastic and ineffective blood cell production and a variable risk of transformation to acute leukaemia.

C Myelofibrosis

In myelofibrosis the blood film shows a leucoerythroblastic picture with an increased reticulocyte count.

A Hypothyroidism

The normal MCV and WCC make hypothyroidism unlikely.

B Myelodysplasia

The normal MCV and WCC make myelodysplasia unlikely. The myelodysplastic syndromes comprise a heterogeneous group of malignant hematopoietic stem cell disorders characterised by dysplastic and ineffective blood cell production and a variable risk of transformation to acute leukaemia.

C Myelofibrosis

In myelofibrosis the blood film shows a leucoerythroblastic picture with an increased reticulocyte count.

E Chronic lymphocytic leukaemia

The normal MCV and WCC make chronic lymphocytic leukaemia unlikely.

Rate this question:

© Pastest 2019

Rana Alnasser's screen

A 42-year-old man presents with generalised oedema. He has a background history of intravenous drug use and excess alcohol intake. He smokes 20 cigarettes per day. He suffers from depression and mild asthma and is currently on fluoxetine, and has progressively lost weight and energy over the past few weeks and months.

On physical examination, his blood pressure (BP) is 150/70 mmHg, chest and abdominal examination is unremarkable. There is bilateral peripheral leg oedema. BMI is 25.

Initial investigations reveal:

Sodium (Na^+)	146 mmol/l
Potassium (K^+)	4.1 mmol/l
Urea	3.4 mmol/l
Creatinine	103 µmol/l
Albumin	23 g/l
24-hour urinary protein collection	3.6 g/24 h (< 0.2)
Renal biopsy	Focal segmental glomerulosclerosis

In this patient what is the most likely association with this disease?

A Alcohol abuse

B Cigarette smoking

C Hepatitis A

D Hepatitis C

on fluoxetine, and has progressively lost weight and energy over the past few weeks and months.

On physical examination, his blood pressure (BP) is 150/70 mmHg, chest and abdominal examination is unremarkable. There is bilateral peripheral leg oedema. BMI is 25.

Initial investigations reveal:

Sodium (Na^+)	146 mmol/l
Potassium (K^+)	4.1 mmol/l
Urea	3.4 mmol/l
Creatinine	103 µmol/l
Albumin	23 g/l
24-hour urinary protein collection	3.6 g/24 h (< 0.2)
Renal biopsy	Focal segmental glomerulosclerosis

In this patient what is the most likely association with this disease?

A Alcohol abuse

B Cigarette smoking

C Hepatitis A

D Hepatitis C

E HIV

E HIV

FSGS can present with nephrotic syndrome. It has been associated with HIV, hepatitis B, intravenous heroin use and massive obesity. The outcome varies and some patients will progress to end-stage renal disease.

With nephrotic syndrome, he is at risk of thromboembolism, infection (especially pneumococcus) and hyperlipidaemia. In HIV-related FSGS, highly active retroviral therapy (HAART) is associated with a reduction in proteinuria.

Other measures include following a low-salt diet and use of ACE inhibitors. Where heroin addiction persists, discontinuation of heroin may also result in a reduction in proteinuria.

A Alcohol abuse

Chronic alcohol abuse increases the risk of acute kidney disease in unobstructed acute pyelonephritis and is a rare cause of renal papillary necrosis. However, alcohol abuse is not associated with focal segmental glomerulosclerosis (FSGS).

B Cigarette smoking

Cigarette smoking is not associated with FSGS, but studies have shown that cigarette smoking is a risk factor for the development and progression of chronic kidney disease in the community. Many studies also indicate a relationship between smoking and renal function deterioration in lupus patients, polycystic kidney disease, Goodpasture syndrome, renal artery stenosis, glomerulonephritis and proximal tubular dysfunction. However, the mechanism is not always clear.

between smoking and renal function deterioration in lupus patients, polycystic kidney disease, Goodpasture syndrome, renal artery stenosis, glomerulonephritis and proximal tubular dysfunction. However, the mechanism is not always clear.

C Hepatitis A

Hepatitis A runs a benign course in children, but may have atypical presentations in adults. Very rarely, acute kidney disease complicates non-fulminant hepatitis A. Hepatitis A is associated with acute kidney disease, but not FSGS.

D Hepatitis C

There is a strong and likely causal association between chronic hepatitis C virus (HCV) infection and glomerular disease. Several types of renal disease have been recognised, including mixed cryoglobulinaemia, membranoproliferative glomerulonephritis (MPGN), membranous nephropathy, and polyarteritis nodosa (PAN). Less commonly, other glomerular lesions have been reported in HCV-infected patients, including proliferative glomerulonephritis, and fibrillary and immunotactoid glomerulopathies.

Rate this question:

Next Question

Previous Q... Tag Questi... Feedback End Session

Blog About Pastest Contact Us Help

A 31-year-old, previously healthy man presents with a 6-month history of nasal congestion and sinusitis. Over a 6-month period he was treated with antibiotic therapy, but his symptoms persisted. His current complaints include frontal headache and a nose bleed.

On examination, he is pyrexial and dyspnoeic. He has a rash on his legs (image below) and a right foot drop.

Investigations:

Na^+	140 mmol/l
K^+	5.5 mmol/l
Urea	15 mmol/l
Creatinine	230 µmol/l
Hb	10.8 g/dl
WCC	12.0×10^9/l
ESR	84 mm/h
Urine dipstick	Blood ++ Protein ++
Chest X-ray	Cavitating lesion in the right upper lobe

Rash:

Urine dipstick	Blood ++ Protein ++
Chest X-ray	Cavitating lesion in the right upper lobe

Rash:

What is the most likely diagnosis?

A Churg-Strauss syndrome

B Wegener's granulomatosis

C Polyarteritis nodosa

D Post-streptococcal glomerulonephritis

E Subacute bacterial endocarditis

Submit

B Wegener's granulomatosis

Wegener's granulomatosis (WG) is a necrotising vasculitis involving the respiratory tract and kidneys. It causes epistaxis, sinusitis, destruction of the nasal cartilage and glomerulonephritis and kidney disease. The serum contains antibodies reacting with the cytoplasm of neutrophils (cANCA).

WG is an idiopathic, systemic inflammatory disease characterised by the presence of granulomas, necrosis and/or vasculitis. Although WG typically affects the upper and lower airways and the kidneys, it may involve any organ system. WG is classified, along with microscopic polyangiitis (MPA) and Churg–Strauss syndrome (CSS), as a primary systemic small-medium-sized vessel vasculitis associated with anti-neutrophil cytoplasmic antibodies (ANCAs). However, WG can also affect medium and even large arteries, and may lack an association with ANCAs. It is a renal/pulmonary disease which often presents with haemoptysis, sinusitis, oral lesions and otitis.

The diagnosis of WG is based on a combination of clinical, laboratory and, if necessary, pathological features. If a typical clinical picture is associated with a positive ANCA finding with specificity for proteinase 3 (PR3), the diagnosis of WG can be presumed. It remains incumbent for the clinician to be certain that WG 'mimics', especially granulomatous infection, are not present. In the setting of only a moderate suspicion of WG and a negative ANCA result, it would be judicious to pursue histological support for the diagnosis. The outcome of WG has been dramatically altered by treatment with glucocorticoids (GCs) and cyclophosphamide (CP).

A Churg–Strauss syndrome

There would be respiratory symptoms such as asthmatic wheeze. Investigations in Churg-Strauss syndrome will show microscopic evidence of red cells and casts in the

A 21-year-old woman, who works as a receptionist in a doctor's surgery, is admitted to the Emergency Department after fainting at work. She puts it down to it being a particularly hot day but, on further questioning, admits to extreme fatigue and muscle cramps when she takes on relatively minor exercise, for as long as she can remember.

Her mother, who has come to the Emergency Department to collect her, confirms she was always missing school sports because of lethargy and muscle pains.

Examination reveals a blood pressure (BP) of 100/70 mmHg; pulse is 75/min and regular. She is of normal height and her BMI is 22.

Investigations:

Hb	12.5 g/dl
WCC	6.1×10^9/l
PLT	189×10^9/l
Na^+	138 mmol/l
K^+	3.0 mmol/l
Bicarbonate	31 mmol/l
Creatinine	80 µmol/l

Which of the following is the most likely diagnosis?

A Bartter syndrome

B Conn syndrome

C Cushing syndrome

D Diuretic abuse

sports because of lethargy and muscle pains.

Examination reveals a blood pressure (BP) of 100/70 mmHg; pulse is 75/min and regular. She is of normal height and her BMI is 22.

Investigations:

Hb	12.5 g/dl
WCC	6.1×10^9/l
PLT	189×10^9/l
Na^+	138 mmol/l
K^+	3.0 mmol/l
Bicarbonate	31 mmol/l
Creatinine	80 µmol/l

Which of the following is the most likely diagnosis?

A Bartter syndrome

B Conn syndrome

C Cushing syndrome

D Diuretic abuse

E Gitelman syndrome

Submit

11:12
On
594-042-7551
Leave

Investigations:

Hb	12.5 g/dl
WCC	6.1×10^9/l
PLT	189×10^9/l
Na^+	138 mmol/l
K^+	3.0 mmol/l
Bicarbonate	31 mmol/l
Creatinine	80 µmol/l

Which of the following is the most likely diagnosis?

Your answer was correct

A Bartter syndrome

B Conn syndrome

C Cushing syndrome

D Diuretic abuse

E Gitelman syndrome

Explanation

E Gitelman syndrome

This patient, in all likelihood, has suffered from hypokalaemia for many years, leading in conjunction with

Audio Video Share Participants More

11:12
On
594-042-7551
Leave

Explanation

E Gitelman syndrome

This patient, in all likelihood, has suffered from hypokalaemia for many years, leading in conjunction with hypomagnesaemia to severe fatigue and muscle cramps.

Gitelman syndrome presents with hypokalaemic metabolic alkalosis in the absence of hypertension. Gitelman syndrome may be associated with milder disease and presents later than Bartter syndrome. Work-up to confirm the diagnosis includes a diuretic screen and urinary calcium excretion. Gitelman syndrome is associated with reduced calcium excretion, whereas Bartter syndrome is not, and this helps to differentiate between the two conditions.

A Bartter syndrome

Bartter syndrome usually presents in childhood because of failure to thrive. If urinary calcium is elevated to levels > 6.9 mmol over a 24-hour period, this suggests Bartter syndrome.

B Conn syndrome

Conn syndrome is associated with hypertension. Conn syndrome also presents with hypokalaemic metabolic alkalosis. There may be other symptoms such as myalgia, muscle spasms, paraesthesiae and polyuria. Complications may include stroke, myocardial infarction and kidney disease.

C Cushing syndrome

Audio
Video
Share
Participants
More

mmol over a 24-hour period, this suggests Bartter syndrome.

B Conn syndrome

Conn syndrome is associated with hypertension. Conn syndrome also presents with hypokalaemic metabolic alkalosis. There may be other symptoms such as myalgia, muscle spasms, paraesthesiae and polyuria. Complications may include stroke, myocardial infarction and kidney disease.

C Cushing syndrome

Cushing syndrome is associated with hypertension, weight gain, abdominal striae, round facies, fat pad between shoulder blades, muscle wasting and poor wound healing.

D Diuretic abuse

Given the long history, although she works in a doctor's surgery, access to or abuse of diuretics seems unlikely.

Rate this question:

Next Question

Previous Q... Tag Questi... Feedback End Session

Blog About Pastest Contact Us Help

© Pastest 2019

As the renal registrar, you attend a joint meeting with the Renal and Pathology Departments to discuss the pathology of some of the renal patients. The histopathologist displays a slide and asks you to describe it. Your description is as follows:

'Section of a kidney showing glomeruli, most of which appear to be filled with a pink, homogenous substance. There appears to be an inflammatory infiltrate in the interstitial tissues consisting mainly of lymphocytes.'

Being rather impressed with your description, the histopathologist asks you for your diagnosis.

What would be your answer?

A	Acute pyelonephritis
B	Acute diffuse proliferative glomerulonephritis (ADPG)
C	Chronic glomerulonephritis
D	Diffuse diabetic glomerulosclerosis
E	Toxic acute tubular necrosis (TATN)

Submit

As the renal registrar, you attend a joint meeting with the Renal and Pathology Departments to discuss the pathology of some of the renal patients. The histopathologist displays a slide and asks you to describe it. Your description is as follows:

'Section of a kidney showing glomeruli, most of which appear to be filled with a pink, homogenous substance. There appears to be an inflammatory infiltrate in the interstitial tissues consisting mainly of lymphocytes.'

Being rather impressed with your description, the histopathologist asks you for your diagnosis.

What would be your answer?

Your answer was correct

A	Acute pyelonephritis
B	Acute diffuse proliferative glomerulonephritis (ADPG)
C	Chronic glomerulonephritis
D	Diffuse diabetic glomerulosclerosis
E	Toxic acute tubular necrosis (TATN)

Explanation

C	Chronic glomerulonephritis

D Diffuse diabetic glomerulosclerosis

E Toxic acute tubular necrosis (TATN)

Explanation

C Chronic glomerulonephritis

Chronic glomerulonephritis is an end-stage condition of nearly all forms of acute glomerulonephritis and affects the majority of the glomeruli. This diagnosis can be made without knowing the cause. The glomeruli will show different degrees of hyalinisation, and eventually hyalinosclerosis will occur, whereby all the glomeruli and Bowman's space are replaced by hyaline. Hyaline is a homogenous, amorphous pink material, and glomeruli that are totally hyalinised are atrophic and non-functional. An abundant inflammatory infiltrate, consisting mainly of lymphocytes, is present in the interstitial tissues. The remaining functional nephrons have dilated tubules.

A Acute pyelonephritis

In acute pyelonephritis, a purulent exudate is present in the interstitium. The glomeruli are normal in the early stages.

In diabetic glomerulosclerosis, a protein is deposited in the basement membrane of the capillary loops of the glomeruli, resulting in basement membrane thickening. TATN is caused by toxic damage to the proximal tubular epithelium, causing necrosis. The basement membrane is intact.

B Acute diffuse proliferative glomerulonephritis (ADPG)

In diabetic glomerulosclerosis, a protein is deposited in the basement membrane of the capillary loops of the glomeruli, resulting in basement membrane thickening. TATN is caused by toxic damage to the proximal tubular epithelium, causing necrosis. The basement membrane is intact.

B Acute diffuse proliferative glomerulonephritis (ADPG)

In ADPG, there is proliferation of endothelial and mesangial cells, but the tubules are not affected.

D Diffuse diabetic glomerulosclerosis

An abundance of lymphocytes would be unusual in diabetic glomerulosclerosis.

E Toxic acute tubular necrosis (TATN)

TATN would not present with pink homogenous substance on renal biopsy.

Rate this question:

Next Question

Previous Q... Tag Questi... Feedback End Session

© Pastest 2019

A 50-year-old woman with a diagnosis of systemic sclerosis is seen in Rheumatology Outpatient Clinic. She has recently had severe Raynaud's phenomenon, with some infarction of the pulps of two of her fingertips. This is being treated with prostacyclin infusions, with some success. However, she is now reporting excessive weakness, fatigue and malaise.

Besides pallor, the only features on examination are longstanding and relate to her rheumatological diagnosis. Her blood pressure is 170/90 mmHg.

Blood results are as follows:

Haemoglobin (Hb)	8.7 g/dl
Mean corpuscular volume (MCV)	90 fl
White cell count (WCC)	8.4×10^9/l-normal differential
Platelets (PLT)	99×10^9/l
Blood film	Schistocytes, increased reticulocytes and helmet cells

Results from today:

Sodium (Na^+)	139 mmol/l
Potassium (K^+)	5.2 mmol/l
Urea	15 mmol/l
Creatinine (Cr)	280 µmol/l
Bicarbonate	15 mmol/l

Results from 6 weeks ago:

Na^+	137

Results from 6 weeks ago:

Na^+	137
K^+	5.1
Urea	9 mmol/l
Cr	110 µmol/l
Bicarbonate	20 mmol/l

		Normal Range
International normalised ratio	1.2	0.9-1.3
Activated partial thromboplastin time (APTT)	45 s	35-45

What is the most beneficial treatment likely to be over the longer term?

A Angiotensin-converting enzyme (ACE) inhibitor

B Cyclophosphamide

C High-dose corticosteroids

D Plasma exchange

E Stopping the prostacyclin infusions

Submit

Explanation

A	Angiotensin-converting enzyme (ACE) inhibitor

This patient has evidence of a scleroderma renal crisis, with acute kidney disease, significant hypertension and microangiopathic haemolytic anaemia, evidenced by schistocytes and helmet cells (red blood cell fragments caused by intravascular shredding of the cells by abnormal fibrin strands).

The treatment most likely to benefit her at this stage is the commencement of ACE inhibitors, which will improve hypertension and slow further renal impairment.

The prognosis of this complication used to be abysmal, and it was the main cause of death in systemic sclerosis. Since the introduction of ACE inhibitors, prognosis is better. Unfortunately, however, many patients do ultimately progress to end-stage kidney disease and the prognosis remains poor due to multiple organ involvement.

B	Cyclophosphamide

Immunosuppressive regimes can be helpful in autoimmune forms of thrombotic thrombocytopenic purpura (TTP) but are not helpful in systemic sclerosis.

C	High-dose corticosteroids

Immunosuppressive regimes can be helpful in autoimmune forms of TTP but are not helpful in systemic sclerosis. High-dose corticosteroids may even worsen a scleroderma crisis.

D	Plasma exchange

are not helpful in systemic sclerosis.

C High-dose corticosteroids

Immunosuppressive regimes can be helpful in autoimmune forms of TTP but are not helpful in systemic sclerosis. High-dose corticosteroids may even worsen a scleroderma crisis.

D Plasma exchange

Plasma exchange is sometimes used, along with fresh frozen plasma, in treating TTP to remove causative antibodies. Plasma exchange may be used for treatment of antiglomerular basement membrane (GBM) disease and vasculitis. This is to remove autoantibodies that are causative for the condition.

E Stopping the prostacyclin infusions

Prostacyclin may actually improve the situation by preserving renal blood flow and can be beneficial in treating TTP.

Rate this question:

Next Question

Previous Q... Tag Questi... Feedback End Session

© Pastest 2019

Rana Alnasser's screen

11:20

A 28-year-old woman sustained a minor head injury, was seen in the emergency department with headache and was discharged following a normal computed tomography of the head.

She presented again 2 months later with polyuria and polydipsia. She has a 2-year history of recurrent pyelonephritis and is under investigation by the urologists.

A water deprivation test was performed:

Water deprivation phase:

Plasma osmolality	330 mOsmol/kg (285–295 mOsmol/kg)
Urine osmolality	220 mOsmol/kg

Desmopressin (DDAVP) phase (after administration of 2 μg desmopressin):

Plasma osmolality	300 mOsmol/kg
Urine osmolality	250 mOsmol/kg

What is the diagnosis?

A Psychogenic polydipsia

B Cranial diabetes insipidus

C Partial cranial diabetes insipidus

D Nephrogenic diabetes insipidus

E Diabetes mellitus

6976

Rana Alnasser's screen

11:23
On
594-042-7551
Leave

C Partial cranial diabetes insipidus

D Nephrogenic diabetes insipidus

E Diabetes mellitus

Explanation

D Nephrogenic diabetes insipidus

In nephrogenic diabetes insipidus, the water deprivation test after overnight fast shows the maximal osmolality of urine is abnormally low <250 mosmol/kg. After administration of exogenous vasopressin (DDAVP), there is only slight increase in urine osmolality <50%.

C Partial cranial diabetes insipidus

In partial cranial diabetes insipidus, there is urinary osmolality of 300–750 mosmol/kg after water deprivation and this remains below 750 mosmol/kg after administration of vasopressin.

A Psychogenic polydipsia

In psychogenic polydipsia, a low initial plasma and urine osmolality is usual at the start of the test. This increases after water deprivation since vasopressin can be stimulated normally.

B Cranial diabetes insipidus

In cranial diabetes insipidus, DDAVP produces a rise in urine osmolality of about 50%.

Audio Video Share Participants More

11:23

MyPastest
https://mypastest.pastest.com

A 28-year-old woman sustained a minor head injury, was seen in the emergency department with headache and was discharged following a normal computed tomography of the head.

She presented again 2 months later with polyuria and polydipsia. She has a 2-year history of recurrent pyelonephritis and is under investigation by the urologists.

A water deprivation test was performed:

Water deprivation phase:

Plasma osmolality	330 mOsmol/kg (285–295 mOsmol/kg)
Urine osmolality	220 mOsmol/kg

Desmopressin (DDAVP) phase (after administration of 2 µg desmopressin):

Plasma osmolality	300 mOsmol/kg
Urine osmolality	250 mOsmol/kg

What is the diagnosis?

Your answer was incorrect

A Psychogenic polydipsia

B Cranial diabetes insipidus

C Partial cranial diabetes insipidus

D Nephrogenic diabetes insipidus

In partial cranial diabetes insipidus, there is urinary osmolality of 300–750 mosmol/kg after water deprivation and this remains below 750 mosmol/kg after administration of vasopressin.

A Psychogenic polydipsia

In psychogenic polydipsia, a low initial plasma and urine osmolality is usual at the start of the test. This increases after water deprivation since vasopressin can be stimulated normally.

B Cranial diabetes insipidus

In cranial diabetes insipidus, DDAVP produces a rise in urine osmolality of about 50%.

E Diabetes mellitus

There is polyuria and polydipsia in uncontrolled diabetes with high blood sugar. But the water deprivation test would yield normal results.

Rate this question:

Next Question

Previous Q... Tag Questi... Feedback End Session

© Pastest 2019

A 63-year-old man was admitted to hospital for an elective coronary angiogram. The procedure went ahead without any obvious complications.

A day after the procedure, he complained of generalised aching abdominal pain, which improved following the administration of lactulose, although it did not resolve entirely. A day later, he became acutely unwell.

On examination, he appeared drowsy and confused. He had a pulse rate of 100 bpm, with a blood pressure of 135/80 mmHg. He had peripheral oedema and coarse crackles in both lung bases. His abdominal examination showed diffuse tenderness, but no rebound or guarding. There was a bluish discoloration of his toes and signs of peripheral emboli.

His urgent blood test results are as follows:

		Normal Values
Haemoglobin (Hb)	15.3 g/dl	
White cell count (WCC)	10.0×10^9/l	
Platelets (PLT)	349×10^9/l	
Neutrophils	6.0×10^9/l	1.5-7.0
Lymphocytes	2.0×10^9/l	1.5-4.0
Eosinophils	2.1×10^9/l	0.04-0.40
Basophils	0.1×10^9/l	< 0.1
Monocytes	0.2×10^9/l	< 0.8
Sodium (Na^+)	143 mmol/l	
Potassium (K^+)	6.2 mmol/l	
Urea	18.5 mmol/l	
Creatinine (Cr)	490 μmol/l	

What is the most likely diagnosis?

Eosinophils	2.1×10^9/l	0.04-0.40
Basophils	0.1×10^9/l	< 0.1
Monocytes	0.2×10^9/l	< 0.8
Sodium (Na^+)	143 mmol/l	
Potassium (K^+)	6.2 mmol/l	
Urea	18.5 mmol/l	
Creatinine (Cr)	490 µmol/l	

What is the most likely diagnosis?

A Acute kidney disease secondary to contrast-induced nephropathy

B Acute kidney disease secondary to generalised sepsis

C Acute kidney disease secondary to multiple cholesterol emboli

D Acute kidney disease secondary to a catastrophic intra-abdominal event

E Acute kidney disease secondary to exacerbation of congestive cardiac failure

Submit

intra-abdominal event

E Acute kidney disease secondary to exacerbation of congestive cardiac failure

Explanation

C Acute kidney disease secondary to multiple cholesterol emboli

This patient has developed acute kidney disease and is severely unwell. The presentation with abdominal pain and eosinophilia all support a diagnosis of multiple cholesterol emboli. Data about cholesterol embolisation are largely based on postmortem examinations which are, by definition, a selected group of poor outcomes. However, some studies suggest that as many as 25–30% of patients undergoing angiography will have atherosclerotic emboli.

A Acute kidney disease secondary to contrast-induced nephropathy

We are not told of any risk factors that would increase the chance of contrast-induced nephrotoxicity (such as age over 70 years; coexisting nephrotoxicity, especially if diabetic; concomitant administration of nephrotoxic drugs; dehydration before a procedure; or pre-existing congestive cardiac failure).

B Acute kidney disease secondary to generalised sepsis

There are no convincing signs of severe sepsis.

D Acute kidney disease secondary to a catastrophic intra-abdominal event

over 70 years; coexisting nephrotoxicity, especially if diabetic; concomitant administration of nephrotoxic drugs; dehydration before a procedure; or pre-existing congestive cardiac failure).

B	Acute kidney disease secondary to generalised sepsis

There are no convincing signs of severe sepsis.

D	Acute kidney disease secondary to a catastrophic intra-abdominal event

The abdominal pain is probably caused by bowel ischaemia, but the lack of signs of peritonism in this case makes this a less likely primary cause for his deterioration.

E	Acute kidney disease secondary to exacerbation of congestive cardiac failure

The degree of cardiac insufficiency is unlikely to have caused such a significant deterioration.

Rate this question:

© Pastest 2019

A 39-year-old man presents to the renal clinic with hypertension and worsening renal function. His GP has tried to manage his blood pressure for many years and he is currently treated with ramipril and amlodipine. He does not know his family medical history as he is adopted.

On examination, his BP is 155/92 mmHg and you can feel bilateral flank masses; you also feel an irregularly enlarged liver.

Investigations:

Hb	10.9 g/dl
WCC	4.8×10^9/l
PLT	294×10^9/l
Na^+	139 mmol/l
K^+	5.4 mmol/l
Creatinine	290 µmol/l
Abdominal USS	Multiple cysts in both kidneys, cysts also visualised in the liver
Urine dipstick	blood +

Which of the following is the most important problem associated with his likely underlying diagnosis?

A Male infertility

B Cerebral aneurysms

C Colonic carcinoma

D Type 1 diabetes

Hb	10.9 g/dl
WCC	4.8×10^9/l
PLT	294×10^9/l
Na^+	139 mmol/l
K^+	5.4 mmol/l
Creatinine	290 μmol/l
Abdominal USS	Multiple cysts in both kidneys, cysts also visualised in the liver
Urine dipstick	blood +

Which of the following is the most important problem associated with his likely underlying diagnosis?

A Male infertility

B Cerebral aneurysms

C Colonic carcinoma

D Type 1 diabetes

E Mitral stenosis

18659

Submit

Hb	10.9 g/dl
WCC	4.8×10^9/l
PLT	294×10^9/l
Na^+	139 mmol/l
K^+	5.4 mmol/l
Creatinine	290 µmol/l
Abdominal USS	Multiple cysts in both kidneys, cysts also visualised in the liver
Urine dipstick	blood +

Which of the following is the most important problem associated with his likely underlying diagnosis?

Your answer was correct

A Male infertility

B Cerebral aneurysms

C Colonic carcinoma

D Type 1 diabetes

E Mitral stenosis

Explanation

B Cerebral aneurysms

Explanation

B Cerebral aneurysms

This patient has a clinical picture which is consistent with polycystic kidney disease. The condition is autosomal dominant, but we are told that he is adopted, so there is no clue as to his family history. Cerebral aneurysms are associated with greatly increased risk of haemorrhagic stroke and, as such, should be managed by a specialist neurosurgeon. Other associations include pancreatic and hepatic cysts, colonic diverticula and mitral valve prolapse.

A Male infertility

Patients with polycystic kidney disease have normal fertility. Because the condition is autosomal dominant it is important to give patients genetic counselling as to the likelihood of any offspring having polycystic kidney disease and the need to have screening if they are adults.

C Colonic carcinoma

Colonic diverticulum is associated with polycystic kidney disease rather than colonic carcinoma. Malignancy may be associated with other renal disease such as membranous nephropathy.

D Type 1 diabetes

Diabetes is not associated with polycystic kidney disease. The most common renal abnormality with type 1 diabetes is diabetic nephropathy.

E Mitral stenosis

11:30

A 72-year-old man with a history of hypertension presents to the Emergency Department in extremis. He awoke in the early hours of the morning with severe shortness of breath as if he was going to gasp his last breath. You understand that his GP has commenced him on ramipril 5 mg daily a short time ago.

On examination, he has a BP of 175/85 mmHg, a pulse of 100 bpm and is in left ventricular failure. You manage him with a nitrate infusion and furosemide and he improves.

Investigations:

Hb	13.1 g/dl
WCC	5.0×10^9/l
PLT	212×10^9/l
Na^+	139 mmol/l
K^+	4.5 mmol/l
Creatinine	204 µmol/l (134 1 month earlier)

Echo shows mild LVH.

What is the most likely cause of his presentation with pulmonary oedema?

A Coronary artery disease

B Hypertensive heart disease

C Hypertrophic cardiomyopathy

D Aortic stenosis

E Renal artery stenosis

Rana Alnasser's screen

E Renal artery stenosis

Patients with renal artery stenosis may present in this manner with rapidly worsening renal function, an increase in blood pressure and so-called flash pulmonary oedema. In this case, the presentation has almost certainly been accelerated by the starting of an ACE inhibitor. Investigations to confirm the diagnosis include ultrasound, which may show differential kidney size, and magnetic resonance angiography. Management centres on non-ACE inhibitor control of blood pressure. Large-scale studies have suggested little or no benefit of angioplasty in renal artery stenosis, although it may be appropriate in patients with recurrent episodes of pulmonary oedema.

A Coronary artery disease

Myocardial infarction may be a cause of pulmonary oedema and renal impairment. However, the start of ACEI recently would not result in coronary artery disease. The echo would show left ventricular failure rather than just mild LVH.

B Hypertensive heart disease

Hypertensive heart disease can cause left ventricular failure for patients who have hypertension over a long period of time. There would be severe left ventricular hypertrophy and left ventricular failure on the echo.

C Hypertrophic cardiomyopathy

Hypertrophic cardiomyopathy is the leading cause of death in young athletes. This condition can produce symptoms that mimic congestive heart failure, such as activity intolerance and dyspnoea. On the echo there is systolic anterior motion of the anterior leaflet of the mitral valve. In

time. There would be severe left ventricular hypertrophy and left ventricular failure on the echo.

C Hypertrophic cardiomyopathy

Hypertrophic cardiomyopathy is the leading cause of death in young athletes. This condition can produce symptoms that mimic congestive heart failure, such as activity intolerance and dyspnoea. On the echo there is systolic anterior motion of the anterior leaflet of the mitral valve. In this scenario, the echo findings do not show this.

D Aortic stenosis

Aortic stenosis may be a cause of flash pulmonary oedema. However, you would expect severe left ventricular hypertrophy if there is sufficiently severe aortic stenosis to result in renal impairment and pulmonary oedema. Furthermore ACEI should be helpful in aortic stenosis for cardiac remodelling and blood pressure control. In this case, the ACEI resulting in acceleration of renal impairment suggests renal artery stenosis.

Rate this question:

Next Question

Previous Q... Tag Questi... Feedback End Session

Blog About Pastest Contact Us Help

© Pastest 2019

A 65-year-old man presents with a 6-week history of anorexia, malaise and breathlessness which he relates to rapidly worsening asthma. He takes NSAIDs for osteoarthritis of his knees, paroxetine and also inhalers for mild asthma. He was on lithium carbonate 2–5 years ago.

Examination reveals mild peripheral oedema, bilateral pleural effusions and a skin rash. He is hypertensive at 210/100 mmHg.

Investigations:

Hb	7.0 g/dl
Eosinophils	2.2×10^9/l
Serum IgG	8.0 g/l (6.0–13.0 g/l)
Corrected calcium	1.9 mmol/l
Serum IgA	1.2 g/l (0.8–3.0 g/l)
Phosphate	2.5 mmol/l serum
IgM	1.5 g/l (0.4–2.5 g/l)
Urea	79.0 mmol/l
Serum IgE	200 kU/l (<120 kU/l)
Creatinine	800 µmol/l
Potassium	7.1 mmol/l
Urinalysis	Blood ++, protein ++
Abdominal ultrasound scan (USS)	No obstruction, kidneys 11 and 12 cm

The likely diagnosis is:

A Amyloidosis

B Chronic analgesic nephropathy

11:33

MyPastest
https://mypastest.pastest.com

Pastest+

Serum IgG	8.0 g/l (6.0–13.0 g/l)
Corrected calcium	1.9 mmol/l
Serum IgA	1.2 g/l (0.8–3.0 g/l)
Phosphate	2.5 mmol/l serum
IgM	1.5 g/l (0.4–2.5 g/l)
Urea	79.0 mmol/l
Serum IgE	200 kU/l (<120 kU/l)
Creatinine	800 µmol/l
Potassium	7.1 mmol/l
Urinalysis	Blood ++, protein ++
Abdominal ultrasound scan (USS)	No obstruction, kidneys 11 and 12 cm

The likely diagnosis is:

A Amyloidosis

B Chronic analgesic nephropathy

C Churg–Strauss syndrome

D Lithium nephrotoxicity

E Membranous glomerulonephritis

This man has presented with biochemical evidence of kidney disease. The key to the diagnosis here is the significantly raised eosinophil count and raised serum IgE both of which are characteristic of Churg–Strauss syndrome. Churg–Strauss syndrome is characterised by asthma and blood eosinophilia together with an eosinophilic vasculitis. The initial phase of the disorder is one of asthma and allergic rhinitis, often followed by peripheral blood eosinophilia with eosinophilic tissue disease. The vasculitic phase that follows is life threatening; however, it can often be treated effectively with immunosuppression. Renal disease consists of focal glomerulonephritis in the vasculitic phase with non-selective proteinuria, haematuria and red cell casts on microscopy.

B Chronic analgesic nephropathy

Chronic analgesic nephropathy is incorrect. Analgesic nephropathy will not present with blood and protein in the urine and there is no skin rash. There may be papillary necrosis with visible blood in the urine and abdominal pain or insidious renal impairment with no blood or protein in the urine.

A Amyloidosis

Amyloidosis is incorrect. Amyloidosis typically presents with a nephrotic picture. Presentation involves heavy proteinuria in the form of nephrotic syndrome and chronic kidney disease. There is fatigue, weight loss, bruising and easy bleeding (including the gastrointestinal tract). AL amyloidosis may affect other organs such as heart to produce cardiomegaly and liver with hepatomegaly.

D Lithium nephrotoxicity

Lithium nephrotoxicity is incorrect. Lithium nephrotoxicity

11:38

MyPastest
https://mypastest.pastest.com

Pastest+

A 65-year-old man presents with a 6-week history of anorexia, malaise and breathlessness which he relates to rapidly worsening asthma. He takes NSAIDs for osteoarthritis of his knees, paroxetine and also inhalers for mild asthma. He was on lithium carbonate 2–5 years ago.

Examination reveals mild peripheral oedema, bilateral pleural effusions and a skin rash. He is hypertensive at 210/100 mmHg.

Investigations:

Hb	7.0 g/dl
Eosinophils	2.2×10^9/l
Serum IgG	8.0 g/l (6.0–13.0 g/l)
Corrected calcium	1.9 mmol/l
Serum IgA	1.2 g/l (0.8–3.0 g/l)
Phosphate	2.5 mmol/l serum
IgM	1.5 g/l (0.4–2.5 g/l)
Urea	79.0 mmol/l
Serum IgE	200 kU/l (<120 kU/l)
Creatinine	800 µmol/l
Potassium	7.1 mmol/l
Urinalysis	Blood ++, protein ++
Abdominal ultrasound scan (USS)	No obstruction, kidneys 11 and 12 cm

A
B
C
D
E

The likely diagnosis is:

kidney disease. There is fatigue, weight loss, bruising and easy bleeding (including the gastrointestinal tract). AL amyloidosis may affect other organs such as heart to produce cardiomegaly and liver with hepatomegaly.

D Lithium nephrotoxicity

Lithium nephrotoxicity is incorrect. Lithium nephrotoxicity is associated with nephrogenic diabetes insipidus and may be associated with tubule-intersitial fibrosis and tubular dilatation. The presentation would be gradual worsening of renal function over a period of years. There is no blood in the urine or skin rash.

E Membranous glomerulonephritis

Membranous glomerulonephritis is incorrect. Membranous gomerulonephritis is the most common cause of nephrotic syndrome in the adult population in the developed world. There would not be any blood in the urine or any skin rash. Progressive renal impairment with proteinuria is a common presentation. The diagnosis is by renal biopsy which would show glomerular basement membrane (GBM) thickening and 'spikes' of GBM extending around subepithelial deposits often best seen on silver stains. There is loss of podocyte foot processes with a variable degree of acute tubular necrosis and tubule-interstitial fibrosis.

Rate this question:

A 52-year-old man is referred by the general practitioner (GP) with painless macroscopic haematuria. He is a smoker and is on bendroflumethiazide for hypertension. He takes no other medication and has no other significant past medical history.

On examination, his blood pressure (BP) is 138/78 mmHg, pulse is 75/min and regular. There are changes consistent COPD on auscultation of his chest. His BMI is 23 and there are no masses on palpation of the abdomen.

Initial investigations reveal:

Haemoglobin (Hb)	12.2 g/dl
White cell count (WCC)	7×10^9/l
Platelet (PLT)	310×10^9/l
Sodium (Na^+)	138 mmol/l
Potassium (K^+)	3.8 mmol/l
Urea	8.2 mmol/l
Creatinine	109 µmol/l
Urine dipstick	Blood +++
INR	1.0

Which one of the following is the best way to determine the diagnosis?

A Computed tomography (CT) of the renal tract with contrast

B Flexible cystoscopy

C Retrograde urography

11:39

MyPastest
https://mypastest.pastest.com

Pastest+

A 52-year-old man is referred by the general practitioner (GP) with painless macroscopic haematuria. He is a smoker and is on bendroflumethiazide for hypertension. He takes no other medication and has no other significant past medical history.

On examination, his blood pressure (BP) is 138/78 mmHg, pulse is 75/min and regular. There are changes consistent COPD on auscultation of his chest. His BMI is 23 and there are no masses on palpation of the abdomen.

Initial investigations reveal:

Haemoglobin (Hb)	12.2 g/dl
White cell count (WCC)	7×10^9/l
Platelet (PLT)	310×10^9/l
Sodium (Na^+)	138 mmol/l
Potassium (K^+)	3.8 mmol/l
Urea	8.2 mmol/l
Creatinine	109 μmol/l
Urine dipstick	Blood +++
INR	1.0

Which one of the following is the best way to determine the diagnosis?

A Computed tomography (CT) of the renal tract with contrast

B Flexible cystoscopy

Rana Alnasser's screen

COPD on auscultation of his chest. His BMI is 23 and there are no masses on palpation of the abdomen.

Initial investigations reveal:

Haemoglobin (Hb)	12.2 g/dl
White cell count (WCC)	7×10^9/l
Platelet (PLT)	310×10^9/l
Sodium (Na^+)	138 mmol/l
Potassium (K^+)	3.8 mmol/l
Urea	8.2 mmol/l
Creatinine	109 µmol/l
Urine dipstick	Blood +++
INR	1.0

Which one of the following is the best way to determine the diagnosis?

A Computed tomography (CT) of the renal tract with contrast

B Flexible cystoscopy

C Retrograde urography

D Urine culture

E Ultrasound scan (USS) renal tract

Rana Alnasser's screen

11:40
On
594-042-7551
Leave
MyPastest
https://mypastest.pastest.com

E Ultrasound scan (USS) renal tract

Explanation

A Computed tomography (CT) of the renal tract with contrast

With painless macroscopic haematuria in a 52-year-old patient, a neoplastic process has to be ruled out. Initially, the best investigations are urine microscopy to look for malignant cells and contrast CT to rule out upper urinary tract pathology. If there is no evidence of upper urinary tract pathology, then cystoscopy and further imaging are required to elucidate the cause. Smoking is of course associated with increased risk of transitional cell carcinoma, as are occupational activities such as work in the plastics and dye industries.

B Flexible cystoscopy

Cystoscopy would be required if CT with contrast does not prove to be fruitful in order to exclude lower urinary tract abnormalities such as a bladder tumour. This is particularly relevant in patients who have previous occupational exposures such as working in the dye industry.

C Retrograde urography

Retrograde urography is an X-ray examination of the urinary tract following the injection of a contrast agent directly into the bladder, ureter or renal pelvis. Although it allows visualisation of urinary tracts, especially for any blockages, it would be diagnostic only in emergency.

Audio Video Share Participants More

C Retrograde urography

Retrograde urography is an X-ray examination of the urinary tract following the injection of a contrast agent directly into the bladder, ureter or renal pelvis. Although it allows visualisation of urinary tracts, especially for any blockages, it will not be diagnostic of malignancy.

D Urine culture

Urine culture is used for urinary tract infection diagnosis. It would not be helpful in this scenario. There are no other urinary tract infection symptoms such as dysuria or frequency.

E Ultrasound scan (USS) renal tract

USS renal tract is useful to exclude hydronephrosis or diagnosis of cysts in kidneys. It is more accurate to carry out a CT with contrast to identify any malignancy because an USS is unlikely to identify any renal malignancy.

Rate this question:

Next Question

Previous Q... Tag Questi... Feedback End Session

Blog About Pastest Contact Us Help

© Pastest 2019

A 68-year-old man complained of weight loss, polyuria, chronic cough and left shoulder pain. Over the past few days, he has suffered from increasing nausea and vomiting. He is an ex-smoker who smoked 15 cigarettes/day for 20 years.

On examination, he looks dehydrated. His blood pressure (BP) is 112/72 mmHg, and his pulse is 85 bpm and regular. There are coarse crackles on auscultation of the chest, consistent with chronic obstructive pulmonary disease (COPD). He is thin, with a body mass index (BMI) of 21.

His blood results are:

Haemoglobin (Hb)	11.6 g/dl
Erythrocyte sedimentation rate (ESR)	78 mm/h
Albumin (Alb)	23 g/l
Corrected calcium (Ca^{2+})	3.24 mmol/l
Sodium (Na^{+})	153 mmol/l

Which initial step is the most appropriate to begin to correct his hypercalcaemia?

A Calcitonin nitrate intravenously (iv)

B Corticosteroids

C iv furosemide

D Hydration with normal saline/5% dextrose alternating bags

E Thiazide diuretics

(BP) is 112/72 mmHg, and his pulse is 85 bpm and regular. There are coarse crackles on auscultation of the chest, consistent with chronic obstructive pulmonary disease (COPD). He is thin, with a body mass index (BMI) of 21.

His blood results are:

Haemoglobin (Hb)	11.6 g/dl
Erythrocyte sedimentation rate (ESR)	78 mm/h
Albumin (Alb)	23 g/l
Corrected calcium (Ca^{2+})	3.24 mmol/l
Sodium (Na^{+})	153 mmol/l

Which initial step is the most appropriate to begin to correct his hypercalcaemia?

Your answer was correct

A Calcitonin nitrate intravenously (iv)

B Corticosteroids

C iv furosemide

D Hydration with normal saline/5% dextrose alternating bags

E Thiazide diuretics

Explanation

D Hydration with normal saline/5% dextrose alternating bags

D Hydration with normal saline/5% dextrose alternating bags

E Thiazide diuretics

Explanation

D Hydration with normal saline/5% dextrose alternating bags

Hypercalcaemia is due to parathyroid hormone (PTH)-related peptide secreted by the tumour cells. The calcium level can be reduced in a relatively short time by rehydrating with iv fluids. iv bisphosphonates are very effective but work over a few hours.

A Calcitonin nitrate intravenously (iv)

Calcitonin is rarely given and not usually as initial therapy. Calcitonin works by inhibiting bone resorption, which is primarily responsible for hypercalcaemia.

B Corticosteroids

Corticosteroids have variable efficacy but may be added to iv fluids and bisphosphonates. Patients with calcitriol-mediated hypercalcaemia are effectively treated with corticosteroids because it reduces calcitriol production by macrophages and can correct the serum calcium level within three to five days after the initial dose.

C iv furosemide

Furosemide is calciuric but should initially be avoided until the patient is rehydrated adequately. Furosemide is limited

primarily responsible for hypercalcaemia.

B Corticosteroids

Corticosteroids have variable efficacy but may be added to iv fluids and bisphosphonates. Patients with calcitriol-mediated hypercalcaemia are effectively treated with corticosteroids because it reduces calcitriol production by macrophages and can correct the serum calcium level within three to five days after the initial dose.

C iv furosemide

Furosemide is calciuric but should initially be avoided until the patient is rehydrated adequately. Furosemide is limited to patients with signs of volume overload.

E Thiazide diuretics

Thiazide diuretics have no role in the treatment of high calcium levels; it may only be used in patients with fluid overload for fluid removal.

Rate this question:

Next Question

Previous Q... Tag Questi... Feedback End Session

Blog About Pastest Contact Us Help

© Pastest 2019

A 58-year-old woman presents with lethargy, confusion and vomiting. She has not presented to health services for many years, although she has been known to use paracetamol/dextropropoxyphene (co-proxamol) tablets for arthritis in the past and takes a diuretic for management of hypertension.

On examination, her blood pressure is 165/85 mmHg and she is confused, with evidence of nystagmus, hyper-reflexia and clonus. General examination reveals evidence of vaginal bleeding.

Blood tests reveal:

Urea	48.2 mmol/l
Creatinine	845 µmol/l
Potassium	6.2 mmol/l

Which one of the following diagnoses fit best with this clinical picture?

A Hypertensive encephalopathy

B Intracranial metastases

C Opiate intoxication

D Subdural haematoma

E Uraemic encephalopathy

A Hypertensive encephalopathy

B Intracranial metastases

C Opiate intoxication

D Subdural haematoma

E Uraemic encephalopathy

Explanation

E Uraemic encephalopathy

The evidence of vaginal bleeding is suggestive of uterine or cervical cancer. Cervical cancer is much more likely to lead to ureteric obstruction and this type of presentation with kidney disease. The neurological findings are suggestive of uraemic encephalopathy, which progresses to coma, seizures and death if left untreated. The standard therapy for uraemic encephalopathy is initiation of dialysis, although a long-term commitment to renal replacement therapy should be considered carefully in the light of possible underlying advanced cervical carcinoma. Conventionally, in this case, urgent imaging would be considered to elucidate the extent of any underlying tumour and consequent obstruction before necessarily committing to dialysis.

D Subdural haematoma

Any head injury may predispose to subdural haematoma especially in the elderly or patients consuming alcohol in excess. There are no risk factors in this case for subdural haematoma. The presentation of a subdural bleed can include hyper-reflexia and upward going plantars

11:48

MyPastest
https://mypastest.pastest.com

A 58-year-old woman presents with lethargy, confusion and vomiting. She has not presented to health services for many years, although she has been known to use paracetamol/dextropropoxyphene (co-proxamol) tablets for arthritis in the past and takes a diuretic for management of hypertension.

On examination, her blood pressure is 165/85 mmHg and she is confused, with evidence of nystagmus, hyper-reflexia and clonus. General examination reveals evidence of vaginal bleeding.

Blood tests reveal:

Urea	48.2 mmol/l
Creatinine	845 µmol/l
Potassium	6.2 mmol/l

Which one of the following diagnoses fit best with this clinical picture?

Your answer was incorrect

A Hypertensive encephalopathy

B Intracranial metastases

C Opiate intoxication

D Subdural haematoma

E Uraemic encephalopathy

The evidence of vaginal bleeding is suggestive of uterine or cervical cancer. Cervical cancer is much more likely to lead to ureteric obstruction and this type of presentation with kidney disease. The neurological findings are suggestive of uraemic encephalopathy, which progresses to coma, seizures and death if left untreated. The standard therapy for uraemic encephalopathy is initiation of dialysis, although a long-term commitment to renal replacement therapy should be considered carefully in the light of possible underlying advanced cervical carcinoma. Conventionally, in this case, urgent imaging would be considered to elucidate the extent of any underlying tumour and consequent obstruction before necessarily committing to dialysis.

D Subdural haematoma

Any head injury may predispose to subdural haematoma especially in the elderly or patients consuming alcohol in excess. There are no risk factors in this case for subdural haematoma. The presentation of a subdural bleed can include hyper-reflexia and upward going plantars.

A Hypertensive encephalopathy

Hypertensive encephalopathy is a syndrome consisting of a sudden elevation of arterial pressure usually preceded by severe headache and followed by convulsions, coma or a variety of transitory cerebral phenomena. The syndrome may complicate acute glomerulonephritis, toxaemia of pregnancy and essential or malignant hypertension. In this scenario, the history of vaginal bleeding would not be consistent with hypertensive encephalopathy.

B Intracranial metastases

excess. There are no risk factors in this case for subdural haematoma. The presentation of a subdural bleed can include hyper-reflexia and upward going plantars.

A Hypertensive encephalopathy

Hypertensive encephalopathy is a syndrome consisting of a sudden elevation of arterial pressure usually preceded by severe headache and followed by convulsions, coma or a variety of transitory cerebral phenomena. The syndrome may complicate acute glomerulonephritis, toxaemia of pregnancy and essential or malignant hypertension. In this scenario, the history of vaginal bleeding would not be consistent with hypertensive encephalopathy.

B Intracranial metastases

Malignancy with intracranial metastases can present with headaches and vomiting, but the kidney disease would not be in keeping with this diagnosis as the best explanation.

C Opiate intoxication

Opiates may give rise to vomiting, nausea and confusion. Intoxication is more likely in renal impairment because opioids are renally excreted. The hyper-reflexia and clonus would go against this diagnosis because with opiate poisoning there would not be increased reflexes. We would expect small pupils on examination.

A 29-year-old man with a history of polycystic kidney disease presents to the Emergency Department with 24 h of left loin pain. He is managed with ramipril and amlodipine for his blood pressure (BP) and has suffered a progressive rise in his creatinine over the past few years.

On examination, his BP is 142/82 mmHg. The pain gradually resolves in the Emergency Department with simple analgesia.

Investigations:

Hb	11.4 g/dl
WCC	5.2×10^9/l
PLT	201×10^9/l
Na^+	141 mmol/l
K^+	4.9 mmol/l
Creatinine	156 µmol/l (153 3 months earlier in the clinic)
CRP	12 mg/l
Urine	blood +, protein –

Which of the following is the most appropriate next step?

A Admit for observation

B Discharge with ciprofloxacin

C Arrange an abdominal CT scan

D Arrange an abdominal ultrasound scan

E Arrange review in 3 days for urine culture results

D Arrange an abdominal ultrasound scan

The most likely diagnosis is haemorrhage into a renal cyst. Haematuria is usually self-limiting and, as the pain has resolved, it seems likely that there is no further bleeding. Given that the renal function has remained stable, he can be reassured. That being said, given the easy availability of ultrasound scanning it would seem sensible to arrange a scan to rule out other causes of haematuria/proteinuria.

A Admit for observation

Haematuria is usually self-limiting, and as the pain has resolved it seems likely that there is no further bleeding. Therefore, there is no need to keep the patient in for observation. Any investigations can be carried out as an outpatient.

B Discharge with ciprofloxacin

As explained above, this man is unlikely to have a urinary tract infection as a cause of the pain because he did not have any urinary symptoms such as dysuria and frequency of urination. You may expect some white cells in the urine if there is a urinary tract infection. As a result, treatment with ciprofloxacin is unlikely to be helpful.

C Arrange an abdominal CT scan

An abdominal CT will show haemorrhage into the renal cyst. However, the treatment would still be conservative, ie analgesia for any pain and rest. Therefore, there is no indication at present to subject the patient to high doses of radiation from a CT scan.

E Arrange review in 3 days for urine culture results

observation. Any investigations can be carried out as an outpatient.

B Discharge with ciprofloxacin

As explained above, this man is unlikely to have a urinary tract infection as a cause of the pain because he did not have any urinary symptoms such as dysuria and frequency of urination. You may expect some white cells in the urine if there is a urinary tract infection. As a result, treatment with ciprofloxacin is unlikely to be helpful.

C Arrange an abdominal CT scan

An abdominal CT will show haemorrhage into the renal cyst. However, the treatment would still be conservative, ie analgesia for any pain and rest. Therefore, there is no indication at present to subject the patient to high doses of radiation from a CT scan.

E Arrange review in 3 days for urine culture results

This patient did not have any urinary symptoms such as dysuria and frequency of urination. You may expect some white cells in the urine if there is a urinary tract infection. Therefore, this man is more likely to have haemorrhage into a renal cyst for which a review with urine cultures will not help.

21239

Rate this question:

A 25-year-old woman presents to Medical Clinic complaining of back pain. Past medical history of note includes hypertension which is currently monitored by the GP. Apparently, one of her family died suddenly of a stroke at the age of 41.

On physical examination, her blood pressure is 175/80 mmHg, BMI was 27 kg/m^2, her chest was clear and abdomen examination was unremarkable.

Investigations showed:

Na^+	138 mmol/l
K^+	4.8 mmol/l
Urea	15.0 mmol/l
Creatinine	320 µmol/l
CRP	20 mg/l
Hb	15 g/dl
WCC	11.4×10^9/l
PLTg	560×10^9/l
Erythropoietin level	Raised

What investigation should be performed next?

A Arterial blood gases (ABGs)

B Bone marrow examination to exclude myeloproliferative disorder

C Chest X-ray

D Lactate dehydrogenase (LDH) levels

11:55
https://mypastest.pastest.com

at the age of 41.

On physical examination, her blood pressure is 175/80 mmHg, BMI was 27 kg/m², her chest was clear and abdomen examination was unremarkable.

Investigations showed:

Na^+	138 mmol/l
K^+	4.8 mmol/l
Urea	15.0 mmol/l
Creatinine	320 µmol/l
CRP	20 mg/l
Hb	15 g/dl
WCC	11.4×10^9/l
PLTg	560×10^9/l
Erythropoietin level	Raised

What investigation should be performed next?

A Arterial blood gases (ABGs)

B Bone marrow examination to exclude myeloproliferative disorder

C Chest X-ray

D Lactate dehydrogenase (LDH) levels

E Renal USS

Rana Alnasser's screen

Explanation

E Renal USS

The combination of back pain and raised Hb should raise the suspicion of renal cystic disease. One cause may be autosomal-dominant polycystic kidney disease (ADPKD) accounting for the death of a relative at an early age. Because this lady is 25 years old, the kidneys would not have been so enlarged to have been detectable on physical examination, therefore the abdominal examination is unremarkable. APKD is a common autosomal dominant disease with a gene defect on the short arm of chromosome 16 and usually presents in the fourth and fifth decades. APKD may present at any age from the second decade with acute loin pain or haematuria due to cyst haemorrhage or infection, loin pain due to increased renal size, subarachnoid haemorrhage due to berry aneurysm rupture, complications of hypertension, complications of liver cyst formation or symptoms of chronic kidney disease.

A Arterial blood gases (ABGs)

The ABG result will be normal in ADKPD and therefore would not help in discerning any differentials.

B Bone marrow examination to exclude myeloproliferative disorder

The bone marrow in ADPKD may be normal providing there is no associated renal bone disease associated with kidney disease. There would be an increased production of erythropoietin from the kidneys though.

C Chest X-ray

In ADPKD, the chest X-ray is typically normal.

The ABG result will be normal in ADKPD and therefore would not help in discerning any differentials.

B Bone marrow examination to exclude myeloproliferative disorder

The bone marrow in ADPKD may be normal providing there is no associated renal bone disease associated with kidney disease. There would be an increased production of erythropoietin from the kidneys though.

C Chest X-ray

In ADPKD, the chest X-ray is typically normal.

D Lactate dehydrogenase (LDH) levels

LDH may be abnormal in myeloproliferative and lymphoproliferative disorders. Haemolytic anaemia would be one example where LDH would be elevated. In ADPKD, the LDH level would be normal.

Rate this question:

Next Question

Previous Q... Tag Questi... Feedback End Session

Blog About Pastest Contact Us Help

© Pastest 2019

11:56

A 55-year-old man presents to the clinic for review. He has suffered one episode of transient loss of vision in his right eye, and most recently has suffered a mononeuritis affecting his left common peroneal nerve. He also has a history of hypertension, for which he currently takes ramipril and amlodipine.

On examination, his blood pressure (BP) is 155/85 mmHg, he has left foot drop consistent with his nerve injury. You notice that he also has livedo reticularis.

Investigations:

Hb	12.2 g/dl
WCC	12.3×10^9/l (increased neutrophils)
PLT	192×10^9/l
Na^+	139 mmol/l
K^+	4.8 mmol/l
Creatinine	194 µmol/l
P-ANCA	Negative
ESR	61 mm/h
Renal angiogram	Multiple microaneurysms

Which of the following is the most likely diagnosis?

A Wegener's granulomatosis

B SLE

C Polyarteritis nodosa

Rana Alnasser's screen

eye, and most recently has suffered a mononeuritis affecting his left common peroneal nerve. He also has a history of hypertension, for which he currently takes ramipril and amlodipine.

On examination, his blood pressure (BP) is 155/85 mmHg, he has left foot drop consistent with his nerve injury. You notice that he also has livedo reticularis.

Investigations:

Hb	12.2 g/dl
WCC	12.3×10^9/l (increased neutrophils)
PLT	192×10^9/l
Na^+	139 mmol/l
K^+	4.8 mmol/l
Creatinine	194 µmol/l
P-ANCA	Negative
ESR	61 mm/h
Renal angiogram	Multiple microaneurysms

Which of the following is the most likely diagnosis?

A Wegener's granulomatosis

B SLE

C Polyarteritis nodosa

D Berger's disease

E Goodpasture's syndrome

Hb	12.2 g/dl
WCC	12.3 × 10^9/l (increased neutrophils)
PLT	192 × 10^9/l
Na^+	139 mmol/l
K^+	4.8 mmol/l
Creatinine	194 µmol/l
P-ANCA	Negative
ESR	61 mm/h
Renal angiogram	Multiple microaneurysms

Which of the following is the most likely diagnosis?

Your answer was correct

A Wegener's granulomatosis

B SLE

C Polyarteritis nodosa

D Berger's disease

E Goodpasture's syndrome

Explanation

C Polyarteritis nodosa

Both CNS and PNS symptoms are common presenting features of polyarteritis nodosa (PAN). Angiography

E Goodpasture's syndrome

Explanation

C Polyarteritis nodosa

Both CNS and PNS symptoms are common presenting features of polyarteritis nodosa (PAN). Angiography revealing small to medium-sized artery renal aneurysms is very typical of the condition. Hepatitis B is associated with an increased risk of PAN, and for this reason prevalence is increased in populations where Hep B is endemic. Histology of lesions reveals microscopic polyangitis, which is also seen in Wegener's granulomatosis. Corticosteroids and cyclophosphamide form the mainstay of therapy for idiopathic PAN. Multiple renal microaneurysms are very typical of PAN, and this pushes us away from a diagnosis of Wegeners, SLE, etc.

A Wegener's granulomatosis

Wegener's granulomatosis is a small vessel vasculitis characterised by the presence of anti-neutrophil cytoplasmic antibodies (ANCA). The presentation includes fever, weight loss, malaise, myalgia and flitting polyarthralgia. There are usually ear, nose and throat symptoms such as nasal discharge, epistaxis, sinusitis, oral or nasal ulcers and otitis media.

B SLE

SLE is a heterogenous multi-system disease characterised by auto-antibody production and impaired immune complex clearance. It is more common in Afro-Caribbean, Hispanic or Asian females in youth or young adulthood. The American College of Rheumatology has established clinical criteria for diagnosis. These include malar rash

Hispanic or Asian females in youth or young adulthood. The American College of Rheumatology has established clinical criteria for diagnosis. These include malar rash, photosensitivity, oral ulcers, arthritis, serositis and kidney disease.

D Berger's disease

Berger's disease is otherwise known as IgA nephropathy. It is the most common cause of haematuria in the developed world. The clinical presentation is asymptomatic, with patients being investigated for incidental haematuria on dipstick. The haematuria may occasionally be classically timed with the onset of upper respiratory illnesses (synpharyngetic haematuria). Associated proteinuria is common and it may present with rapidly progressive glomerulonephritis with acute kidney disease.

E Goodpasture's syndrome

Goodpasture, also known as anti-GBM disease, occurs because of anti-basement membrane autoantibodies directed against type-IV collagen. HLA-DR2 and HLA-B7 are thought to occur with increased frequency in patients who have Goodpasture. Renal biopsy demonstrates features of crescenteric necrotising glomerulonephritis. Worsening haemoptysis due to pulmonary haemorrhage, and acute kidney disease, is typical of Goodpasture syndrome.

Rana Alnasser's screen

A 19 year old from West Africa presents to the clinic. She gives a history of several months of pitting oedema, which is now to mid-leg, and there is associated abdominal swelling. There is no shortness of breath, but she does complain of general malaise and intermittent fevers. There has been an episode of headache, upper abdominal pain and vomiting with associated diarrhoea 2 years ago, but nil else of note. She was working on a fish farm during her time in Africa.

Examination revealed evidence of ascites and marked lower limb oedema. Cardiovascular and respiratory examinations were unremarkable.

Investigations:

Hb	10.1 g/dl
ALT	125 U/l
Creatinine	132 µmol/l
Other liver function tests	Unremarkable
Albumin	26 g/l
Hepatic ultrasound	Evidence of hepatosplenomegaly
Urine dipstick	Blood +, protein +++

Which of the following investigations is the next most appropriate?

A Cardiac ultrasound scan

B Hepatitis serology

C Liver biopsy

Rana Alnasser's screen

and vomiting with associated diarrhoea 2 years ago, but nil else of note. She was working on a fish farm during her time in Africa.

Examination revealed evidence of ascites and marked lower limb oedema. Cardiovascular and respiratory examinations were unremarkable.

Investigations:

Hb	10.1 g/dl
ALT	125 U/l
Creatinine	132 μmol/l
Other liver function tests	Unremarkable
Albumin	26 g/l
Hepatic ultrasound	Evidence of hepatosplenomegaly
Urine dipstick	Blood +, protein +++

Which of the following investigations is the next most appropriate?

A Cardiac ultrasound scan

B Hepatitis serology

C Liver biopsy

D Renal biopsy

E Urinary protein estimation

E Urinary protein estimation

Explanation

E Urinary protein estimation

We are aware that this patient has marked ascites and lower limb oedema. There are no signs of cardiac dysfunction on examination. Renal protein loss is one likely explanation for the oedema and hypo-albuminaemia, and it can be easily excluded. Significant exposure to mosquitoes is likely as this patient worked on a fish farm. She has a history suggestive of chronic malarial infection. It is well known that *Plasmodium malariae* may be associated with membranous glomerulonephritis, the most likely cause of her significant proteinuria. Chloroquine would be appropriate treatment in this case.

B Hepatitis serology

The presentation is not in keeping with hepatitis. Hepatosplenomegaly is not a feature of hepatitis, although it may present with fever, general malaise and jaundice.

A Cardiac ultrasound scan

There are no signs of cardiac dysfunction on examination, and therefore a cardiac ultrasound is unlikely to be helpful.

C Liver biopsy

A liver biopsy would not help in the diagnosis of malaria. Liver biopsy would be useful in grading of severity of liver injury, although not in malaria. It may be useful in cases where the cause of liver dysfunction is unknown and infiltrative disorders are thought to be responsible.

her significant proteinuria. Chloroquine would be appropriate treatment in this case.

B Hepatitis serology

The presentation is not in keeping with hepatitis. Hepatosplenomegaly is not a feature of hepatitis, although it may present with fever, general malaise and jaundice.

A Cardiac ultrasound scan

There are no signs of cardiac dysfunction on examination, and therefore a cardiac ultrasound is unlikely to be helpful.

C Liver biopsy

A liver biopsy would not help in the diagnosis of malaria. Liver biopsy would be useful in grading of severity of liver injury, although not in malaria. It may be useful in cases where the cause of liver dysfunction is unknown and infiltrative disorders are thought to be responsible.

D Renal biopsy

A renal biopsy in malaria may show glomerulonephritis, acute tubular necrosis and acute interstitial nephritis. However, it would not be the next most appropriate investigation.

Rate this question:

A 23-year-old man attends his GP complaining of reduced exercise tolerance, nocturia and frequent hiccups over the course of the past four months. He also has generalised bony pain.

In his past medical history, he has known rheumatoid arthritis and has had a contrast angiography 1 week ago for investigation of chest pain.

Upon examination, his blood pressure is 165/90 mmHg and his BMI is stable at 25. There are a few scattered crepitations at the bases of his lung fields. His abdomen is distended with dullness in both flanks. There are two palpable masses in the abdomen which is palpable above and rises with respiration. No tenderness, rigidity or guarding is detected.

Investigations:

Creatinine	250 µmol/l
Hb	14 g/dl
Phosphate	2.0 mmol/l
Calcium	2.1 mmol/l

What is the most likely cause of these results?

A	Adult polycystic kidney disease
B	Contrast nephropathy
C	Diabetes
D	Diffuse proliferative glomerulonephritis
E	Hypertensive nephropathy

In his past medical history, he has known rheumatoid arthritis and has had a contrast angiography 1 week ago for investigation of chest pain.

Upon examination, his blood pressure is 165/90 mmHg and his BMI is stable at 25. There are a few scattered crepitations at the bases of his lung fields. His abdomen is distended with dullness in both flanks. There are two palpable masses in the abdomen which is palpable above and rises with respiration. No tenderness, rigidity or guarding is detected.

Investigations:

Creatinine	250 µmol/l
Hb	14 g/dl
Phosphate	2.0 mmol/l
Calcium	2.1 mmol/l

What is the most likely cause of these results?

Your answer was correct

A Adult polycystic kidney disease

B Contrast nephropathy

C Diabetes

D Diffuse proliferative glomerulonephritis

E Hypertensive nephropathy

Explanation

12:11

MyPastest
https://mypastest.pastest.com

Phosphate	2.0 mmol/l
Calcium	2.1 mmol/l

What is the most likely cause of these results?

Your answer was correct

- A Adult polycystic kidney disease
- B Contrast nephropathy
- C Diabetes
- D Diffuse proliferative glomerulonephritis
- E Hypertensive nephropathy

Explanation

A Adult polycystic kidney disease

These results are a picture of chronic kidney disease (CKD) as there is a raised phosphate and creatinine. This has probably resulted in hypovitaminosis D and secondary hyperparathyroidism. Adult polycystic kidney disease (APKD) is correct because it can cause chronic kidney disease with a maintained haemoglobin level due to excess erythropoietin secretion.

B Contrast nephropathy

probably resulted in hypovitaminosis D and secondary hyperparathyroidism. Adult polycystic kidney disease (APKD) is correct because it can cause chronic kidney disease with a maintained haemoglobin level due to excess erythropoietin secretion.

B Contrast nephropathy

It would cause an acute kidney disease with normal phosphate, calcium and haemoglobin levels. Contrast nephropathy accounts for about 10% of all in hospital acute kidney disease. The clinical features include a drop in renal function immediately after contrast exposure, though creatinine may be initially unchanged. The earliest sign may be oliguria. Unlike other causes of acute tubular necrosis, fractional excretion of sodium is <1%.

C Diabetes

Although this can cause CKD you would expect to see a chronic anaemia picture. Diabetic nephropathy results from diabetes and is due to microvascular and macrovascular glycosylation. The renal impairment is generally progressive. One of the first signs of disease is microalbuminuria. Important treatment methods to prevent kidney disease progression would be good blood pressure control, diabetic control and, once proteinuria occurs, to commence an angiotensin-converting enzyme (ACE) inhibitor.

D Diffuse proliferative glomerulonephritis

Similar to contrast nephropathy, this would cause an acute kidney disease rather than chronic kidney disease which is the biochemical picture in this case. Typical presentations of diffuse proliferative glomerulonephritis would be a rapidly progressive acute kidney disease (oliguria, pulmonary oedema, peripheral oedema, rising creatinine levels) with haematuria/proteinuria. Depending on the

Rana Alnasser's screen

A 28-year-old woman presented to the Emergency Department with a 2-month history of headache and visual disturbance. Urgent magnetic resonance imaging of the head revealed a pituitary adenoma.

Baseline pituitary function tests were normal, except serum prolactin level of 15 000 mu/l (< 450 mu/l).

Trans-sphenoidal surgery (TSS) two days after admission was successful. However, in the first 6 hours post-surgery, her urine output was 2.5 litres. Otherwise, she was well, with no particular symptoms or complications.

Urgent biochemical tests were performed.

Results are shown below:

Plasma osmolality	295 mOsmol/kg (275–290 mOsmol/kg)
Urine osmolality	300 mOsmol/kg
Sodium (Na^+)	147 mmol/l
Potassium (K^+)	5.0 mmol/l
Urea	7.5 mmol/l
Creatinine (Cr)	105 µmol/l
Glucose	5.8 mmol/l
0900 h cortisol	400 nmol/l (280–700nmol/l)

What is the most appropriate initial therapy?

A Encourage the patient to drink as much as they want

B Fluid restriction of up to 1000 ml per day

Rana Alnasser's screen

C Intravenous (IV) hydrocortisone 200 mg

was successful. However, in the first 6 hours post-surgery, her urine output was 2.5 litres. Otherwise, she was well, with no particular symptoms or complications.

Urgent biochemical tests were performed.

Results are shown below:

Plasma osmolality	295 mOsmol/kg (275–290 mOsmol/kg)
Urine osmolality	300 mOsmol/kg
Sodium (Na^+)	147 mmol/l
Potassium (K^+)	5.0 mmol/l
Urea	7.5 mmol/l
Creatinine (Cr)	105 µmol/l
Glucose	5.8 mmol/l
0900 h cortisol	400 nmol/l (280–700nmol/l)

What is the most appropriate initial therapy?

A Encourage the patient to drink as much as they want

B Fluid restriction of up to 1000 ml per day

C Intravenous (iv) hydrocortisone 200 mg

D Immediate intranasal desmpressin (DDAVP)

E Match fluid output with appropriate replacement

D Immediate intranasal desmpressin (DDAVP)

E Match fluid output with appropriate replacement

Explanation

E Match fluid output with appropriate replacement

DI post-pituitary surgery is very common. All patients should be monitored for signs of DI, such as urine output of > 800 ml/h over four consecutive hours. The symptom of thirst is unusual. Urgent paired osmolality and electrolytes should be requested if there is any suspicion of DI.

Plasma osmolality of > 285 mOsmol/kg, with paired urine osmolality of < 500 mOsmol/kg, suggests DI. This may settle a few days after surgery though, so in the initial period, ensuring adequate fluid replacement is reasonable. Only some patients will require long-term DDAVP replacement.

D Immediate intranasal desmpressin (DDAVP)

Only some patients will require long-term DDAVP replacement for DI post-pituitary surgery.

A Encourage the patient to drink as much as they want

To ensure adequate fluid replacement is important initially; encouraging the patient to drink as much as they want is not necessarily keeping a close monitor of urine output as patients may not drink enough.

B Fluid restriction of up to 1000 ml per day

Fluid restriction would not be appropriate; dehydration

A 28-year-old woman presented to the Emergency Department with a 2-month history of headache and visual disturbance. Urgent magnetic resonance imaging of the head revealed a pituitary adenoma.

Baseline pituitary function tests were normal, except serum prolactin level of 15 000 mu/l (< 450 mu/l).

Trans-sphenoidal surgery (TSS) two days after admission was successful. However, in the first 6 hours post-surgery, her urine output was 2.5 litres. Otherwise, she was well, with no particular symptoms or complications.

Urgent biochemical tests were performed.

Results are shown below:

Plasma osmolality	295 mOsmol/kg (275-290 mOsmol/kg)
Urine osmolality	300 mOsmol/kg
Sodium (Na^+)	147 mmol/l
Potassium (K^+)	5.0 mmol/l
Urea	7.5 mmol/l
Creatinine (Cr)	105 µmol/l
Glucose	5.8 mmol/l
0900 h cortisol	400 nmol/l (280-700nmol/l)

What is the most appropriate initial therapy?

Your answer was incorrect

A Encourage the patient to drink as much as they want

B Fluid restriction of up to 1000 ml per day

C

D

E

D Immediate intranasal desmpressin (DDAVP)

Only some patients will require long-term DDAVP replacement for DI post-pituitary surgery.

A Encourage the patient to drink as much as they want

To ensure adequate fluid replacement is important initially; encouraging the patient to drink as much as they want is not necessarily keeping a close monitor of urine output as patients may not drink enough.

B Fluid restriction of up to 1000 ml per day

Fluid restriction would not be appropriate; dehydration may ensue.

C Intravenous (iv) hydrocortisone 200 mg

Hydrocortisone is not the treatment of diabetes insipidus (DI). She does not have Addison's disease because there would be hypoglycaemia, hyponatraemia, hyperkalaemia and hypercalcaemia.

Symptoms of Addison's disease would include hypotension, syncope, severe vomiting and diarrhoea, resulting in dehydration.

71308

Rate this question:

Next Question

A previously fit and well 23-year-old woman fell down a flight of stairs.

A magnetic resonance scan of the spine has revealed cord compression and she is awaiting the neurosurgeons. She is catheterised and a urine sample is sent to the lab. Her past medical history has no illness of note. The house officer is contacted with the urine microscopy result and phones you for advice.

Urine microscopy reveals the presence of epithelial squames, a few red cells of normal morphology are detected and hyaline and fine granular casts are present. There are no white cells and no bacteria on Gram stain.

What is the most likely cause of this result?

A	Acute tubular necrosis
B	Atypical urinary tract infection
C	Glomerulonephritis
D	Normal urine
E	Renal haematoma

Submit

Rana Alnasser's screen

A magnetic resonance scan of the spine has revealed cord compression and she is awaiting the neurosurgeons. She is catheterised and a urine sample is sent to the lab. Her past medical history has no illness of note. The house officer is contacted with the urine microscopy result and phones you for advice.

Urine microscopy reveals the presence of epithelial squames, a few red cells of normal morphology are detected and hyaline and fine granular casts are present. There are no white cells and no bacteria on Gram stain.

What is the most likely cause of this result?

Your answer was correct

A Acute tubular necrosis

B Atypical urinary tract infection

C Glomerulonephritis

D Normal urine

E Renal haematoma

Explanation

D Normal urine

The above result is compatible with a normal urine specimen. The squames and normal morphology red cells are probably the result of the catheterisation procedure. Fine granular casts and hyaline casts are precipitated protein and occur in normal urine.

What is the most likely cause of this result?

Your answer was correct

A Acute tubular necrosis

B Atypical urinary tract infection

C Glomerulonephritis

D Normal urine

E Renal haematoma

Explanation

D Normal urine

The above result is compatible with a normal urine specimen. The squames and normal morphology red cells are probably the result of the catheterisation procedure. Fine granular casts and hyaline casts are precipitated protein and occur in normal urine.

A Acute tubular necrosis

In acute tubular necrosis, the presence of 'muddy brown casts' is pathognomonic for the condition.

B Atypical urinary tract infection

White blood cells and white cell casts suggest conditions such as urinary tract infection and pyelonephritis.

Rana Alnasser's screen

The above result is compatible with a normal urine specimen. The squames and normal morphology red cells are probably the result of the catheterisation procedure. Fine granular casts and hyaline casts are precipitated protein and occur in normal urine.

A Acute tubular necrosis

In acute tubular necrosis, the presence of 'muddy brown casts' is pathognomonic for the condition.

B Atypical urinary tract infection

White blood cells and white cell casts suggest conditions such as urinary tract infection and pyelonephritis.

C Glomerulonephritis

Dysmorphic red blood cells can suggest glomerular disease. Red cell casts suggest glomerulonephritis. Urine microscopy can reveal bacteria, yeasts, and crystals.

E Renal haematoma

Renal haematoma may show red cells or red cell casts in the urine.

Rate this question:

Next Question

Previous Q... Tag Questi... Feedback End Session

Rana Alnasser's screen

An 18-year-old A-level student comes to the clinic, complaining of amenorrhoea. There is no history of weight loss. She has been recently referred to the dentist for assessment of badly eroded teeth.

On examination, her parotid glands are enlarged, and scratch marks are noticed over the dorsum of the knuckles. The rest of the examination is normal.

She is an active girl, who runs 5 miles daily. Her body mass index (BMI) is 17. Her blood pressure (BP) is 105/70 mmHg.

Her blood results showed:

Sodium (Na^+)	136 mmol/l
Potassium (K^+)	2.8 mmol/l
Urea	5 mmol/l
Bicarbonate	32 mmol/l
pH	7.5

Which of the following conditions is the most likely diagnosis?

A Addison's disease

B Conn syndrome

C Cushing syndrome

D Eating disorder

E Long-term diuretic abuse

71523

Submit

An 18-year-old A-level student comes to the clinic, complaining of amenorrhoea. There is no history of weight loss. She has been recently referred to the dentist for assessment of badly eroded teeth.

On examination, her parotid glands are enlarged, and scratch marks are noticed over the dorsum of the knuckles. The rest of the examination is normal.

She is an active girl, who runs 5 miles daily. Her body mass index (BMI) is 17. Her blood pressure (BP) is 105/70 mmHg.

Her blood results showed:

Sodium (Na^+)	136 mmol/l
Potassium (K^+)	2.8 mmol/l
Urea	5 mmol/l
Bicarbonate	32 mmol/l
pH	7.5

Which of the following conditions is the most likely diagnosis?

Your answer was correct

A Addison's disease

B Conn syndrome

C Cushing syndrome

D Eating disorder

E Long-term diuretic abuse

Explanation

Your answer was correct

A	Addison's disease
B	Conn syndrome
C	Cushing syndrome
D	Eating disorder
E	Long-term diuretic abuse

Explanation

D	Eating disorder

The acid-base disturbance shown is a metabolic alkalosis. Recurrent vomiting ± laxative abuse may well have led to the hypokalaemia and raised bicarbonate levels seen here, with the knuckle callusing also supporting the diagnosis.

A	Addison's disease

Hypokalaemia is not a feature of Addison's disease. Addison's disease is a primary adrenal insufficiency with low cortisol. Symptoms include abdominal pain, weakness and weight loss. Darkening of the skin due to increased pigmentation may occur in non-sun-exposed areas. Blood results may show high calcium, low glucose, low sodium, high potassium and eosinophilia.

B	Conn syndrome

Conn syndrome is associated with hypertension. This syndrome is caused by an excess production of

Conn syndrome is associated with hypertension. This syndrome is caused by an excess production of aldosterone by the adrenal glands, with low renin. There may be few symptoms. High blood pressure, with poor vision and headaches, may be another presentation. Occasionally, there may be muscle weakness, spasms and paraesthesiae. Low potassium is classically described; however, it is only present in about a quarter of patients.

C Cushing syndrome

Cushing syndrome is effectively ruled out by her BMI. It presents with hypertension, abdominal obesity, thin arms, stretch marks, a rotund face and fragile skin with poor wound healing. Women may also complain of hirsutism and irregular periods.

E Long-term diuretic abuse

Long-term diuretic abuse may coexist with an eating disorder, but given her BMI is only 17, it is vomiting that is the likely predominant factor.

Rate this question:

Next Question

Previous Q... Tag Questi... Feedback End Session

Blog About Pastest Contact Us Help

© Pastest 2019

Rana Alnasser's screen

12:23

A 23-year-old woman presents to the surgery after an upper respiratory tract infection and sore throat complaining of passing brown urine, she became ill with the chest cold about 5 days ago. She tells you that she has suffered from blood in the urine on a previous occasion after suffering from a sore throat.

On examination, her BP is slightly elevated at 139/87 mmHg. Otherwise, physical examination is unremarkable.

Investigations:

Hb	11.8 g/dl
WCC	5.4×10^9/l
PLT	145×10^9/l
Na^+	139 mmol/l
K^+	4.5 mmol/l
Creatinine	132 µmol/l
Urine	blood ++, protein +

Which of the following investigations is most likely to confirm the diagnosis?

A Urine culture

B Serum IgA levels

C ASOT

D Renal biopsy

E Cystoscopy

Rana Alnasser's screen

E Cystoscopy

Explanation

D Renal biopsy

Recurrent haematuria, occurring in close proximity to upper respiratory tract infection, is highly suggestive of IgA nephropathy. Renal biopsy is the investigation of choice to confirm the diagnosis, with usual findings including diffuse mesangial proliferation and extracellular matrix expansion. Immunofluorescence is used to visualise IgA deposits, and C3 is also often seen. Aggressive control of hypertension, with ACE inhibition as the main therapeutic option and management of rising creatinine or proteinuria with the use of corticosteroids, form the backbone of therapy.

A Urine culture

Urine culture would diagnose urinary tract infection. However there is no history of dysuria, frequency or hesitancy of urination. The history of sore throat would not be consistent with a diagnosis of urinary tract infection.

B Serum IgA levels

It would seem reasonable to measure IgA levels, as these are usually elevated in IgA nephropathy, but raised IgA levels are not specific for the condition of IgA nephropathy.

C ASOT

ASOT would be more likely to be positive in post-streptococcal glomerulonephritis. This would also give haematuria. The disorder develops 1-2 weeks after an untreated throat or skin infection. It most often occurs in

It would seem reasonable to measure IgA levels, as these are usually elevated in IgA nephropathy, but raised IgA levels are not specific for the condition of IgA nephropathy.

C ASOT

ASOT would be more likely to be positive in post-streptococcal glomerulonephritis. This would also give haematuria. The disorder develops 1-2 weeks after an untreated throat or skin infection. It most often occurs in children aged 6-10 years old. Treatment is symptomatic relief, which would include antibiotics and anti-hypertensives to control blood pressure. Corticosteroids and anti-inflammatories are generally not effective.

E Cystoscopy

Cystoscopy would be useful in excluding bladder cancer. However, in young women without any other significant medical history such as occupational exposure to dye, etc. it is unlikely that haematuria is due to bladder cancer.

Rate this question:

© Pastest 2019

A 78-year-old man presents with tiredness and lethargy, accompanied by weight loss of 1 stone over the past 4 months, and severe lower back pain. He has a history of hypertension which is managed with ramipril and amlodipine and an inferior myocardial infarction some 7 years earlier.

On examination, his blood pressure (BP) is 142/72 mmHg, pulse is 82/min and regular, his BMI is 21. He looks pale and emaciated.

Investigations reveal:

Haemoglobin (Hb)	8.9 g/dl (normocytic)
Platelet (PLT)	125×10^9/l
White cell count (WCC)	8.5×10^9/l
Sodium (Na^+)	135 mmol/l
Potassium (K^+)	4.6 mmol/l
Creatinine	245 µmol/l
Calcium (Ca^{2+})	2.95 mmol/l
Albumin	31 g/l
Erythrocyte sedimentation rate (ESR)	85 mm/h
Renal biopsy	Cast nephropathy

Which of the following is the best initial treatment?

A Interferon alpha

B Interferon gamma

C Melphalan

years earlier.

On examination, his blood pressure (BP) is 142/72 mmHg, pulse is 82/min and regular, his BMI is 21. He looks pale and emaciated.

Investigations reveal:

Haemoglobin (Hb)	8.9 g/dl (normocytic)
Platelet (PLT)	125×10^9/l
White cell count (WCC)	8.5×10^9/l
Sodium (Na^+)	135 mmol/l
Potassium (K^+)	4.6 mmol/l
Creatinine	245 µmol/l
Calcium (Ca^{2+})	2.95 mmol/l
Albumin	31 g/l
Erythrocyte sedimentation rate (ESR)	85 mm/h
Renal biopsy	Cast nephropathy

Which of the following is the best initial treatment?

A Interferon alpha

B Interferon gamma

C Melphalan

D Methotrexate

E Non-steroidal anti-inflammatory agents

White cell count (WCC)	8.5×10^9/l
Sodium (Na^+)	135 mmol/l
Potassium (K^+)	4.6 mmol/l
Creatinine	245 µmol/l
Calcium (Ca^{2+})	2.95 mmol/l
Albumin	31 g/l
Erythrocyte sedimentation rate (ESR)	85 mm/h
Renal biopsy	Cast nephropathy

Which of the following is the best initial treatment?

Your answer was correct

A Interferon alpha

B Interferon gamma

C Melphalan

D Methotrexate

E Non-steroidal anti-inflammatory agents

Explanation

C Melphalan

This man has a clinical picture which is highly suggestive of myeloma with renal involvement. Diagnosis of myeloma

C Melphalan

This man has a clinical picture which is highly suggestive of myeloma with renal involvement. Diagnosis of myeloma relies on plasma electrophoresis and bone marrow biopsy to assess plasma cell infiltration. Cast nephropathy is classically associated with myeloma of the kidney and is characterised by eosinophilic, dense, homogeneous casts that are often fractured or laminated and are partially surrounded by multinucleated foreign body-type giant cells. Congo-red-positive casts have been reported in a few cases. Intratubular light chains apparently may undergo alteration in situ, resulting in amyloid formation.

Conventional treatment of myeloma typically involves a regime including melphalan and corticosteroids. An aggressive regime involving the VAMP combination of agents, or CVAMP may be considered in younger patients with better initial functional status.

A Interferon alpha

Interferons are soluble proteins produced naturally by cells in response to viruses. Interferon alpha has both antiproliferative and immunomodulating properties and is one of the first examples of a biological response modifier used to treat multiple myeloma. Despite considerable efforts, numerous clinical trials and two large meta-analysis, its exact role in the management of multiple myeloma still remains unclear.

Interferon as a single induction agent or co-induction agent with other chemotherapy agents appears to have only minimal benefit in myeloma. Its role as maintenance therapy in the plateau phase of myeloma also remains uncertain.

B Interferon gamma

Rana Alnasser's screen

B Interferon gamma

Interferon gamma (IFN-gamma) showed the most powerful inhibiting activity on myeloma cell proliferation in in-vitro studies. However, IFN-gamma has not been translated to be used in common practice for multiple myeloma treatment.

D Methotrexate

Methotrexate is an immunosuppressant but it is not used commonly for treatment of multiple myeloma. It is more frequently prescribed for rheumatological diseases such as rheumatoid arthritis for disease control.

E Non-steroidal anti-inflammatory agents

Non-steroidal anti-inflammatory agents would aid in pain relief; however, they are not a definitive treatment for multiple myeloma. Furthermore, they may worsen renal function. Therefore, it should be avoided in renal impairment.

Rate this question:

Next Question

Previous Q... Tag Questi... Feedback End Session

© Pastest 2019

Rana Alnasser's screen

A 23-year-old woman presents with a 3-week history of increasing swelling of her ankles. There are no preceding symptoms and there is no past medical or drug history of note. She then develops hand and facial swelling and finds her trousers increasingly tight around the waist. She has no rash, joint pains or other symptoms.

On examination, her blood pressure is 160/70 mmHg, she has gross pitting oedema of both legs, ascites and facial, hand and sacral oedema.

Investigations show:

Na^+	140 mmol/l
K^+	4.2 mmol/l
Urea	10.2 mmol/l
Creatinine	67 µmol/l
Hb	8.5 g/dl
WCC	5.1×10^9/l
PLT	243×10^9 /l
Albumin	16 g/l
Glucose	4 mmol/l
Cholesterol	10 mmol/l
24-hour urine collection	4.2 g/24-hours proteinuria
Chest X-ray	Small bilateral pleural effusions
Urine dipstick	4+ proteinuria and no blood

What is the most likely diagnosis?

A Post-infectious glomerulonephritis

B Goodpasture's syndrome

WCC	5.1×10^9/l
PLT	243×10^9 /l
Albumin	16 g/l
Glucose	4 mmol/l
Cholesterol	10 mmol/l
24-hour urine collection	4.2 g/24-hours proteinuria
Chest X-ray	Small bilateral pleural effusions
Urine dipstick	4+ proteinuria and no blood

What is the most likely diagnosis?

A Post-infectious glomerulonephritis

B Goodpasture's syndrome

C Minimal change disease

D IgA nephropathy

E Diabetic nephropathy

Submit

A Post-infectious glomerulonephritis

B Goodpasture's syndrome

C Minimal change disease

D IgA nephropathy

E Diabetic nephropathy

Explanation

C Minimal change disease

This woman has nephrotic syndrome (oedema, hypoalbuminemia, hypercholesterolaemia and more than 3.5g/24-hours proteinuria). The commonest cause in young people is minimal change disease. A renal biopsy would be required to confirm the diagnosis of minimal change disease and the treatment would be steroids, although in practice response to steroids may obviate the need for biopsy.

A Post-infectious glomerulonephritis

This is more likely to present as a nephritic illness with hypertension and haematuria, as well as proteinuria, oedema and renal impairment.

B Goodpasture's syndrome

This will more likely present with nephritic syndrome with associated haematuria with proteinuria. By definition there will also be pulmonary haemorrhage.

12:31

You are asked to check the blood results on a 32-year-old man who was admitted earlier in the day on the medical take. He is very overweight and has been admitted with an infective exacerbation of asthma. He is being treated with oral prednisolone 60 mg od, 4-hourly 5 mg salbutamol nebulisers with amoxicillin 500 mgs tds and erythromycin 250 mg tds. Besides his normal inhalers, he does not take any regular medications. He is a smoker. The team commented that it was very difficult to gain venous access.

The results are as follows:

Na^+	140 mmol/l
K^+	6.9 mmol/l
Urea	4.0 mmol/l
Creatinine	82 µmol/l
C-reactive protein	139 mg/l
Glucose	5.8 mmol/l

You visit him on the ward. He is having a nebuliser and reading the newspaper.

What is the best course of action?

A Urgent calcium gluconate 10 ml 10% intravenous (iv) followed by insulin/dextrose infusion

B Urgent electrocardiogram (ECG), followed by calcium gluconate 10 ml 10% iv followed by insulin/dextrose infusion

C Repeat laboratory urea and electrolyte sample, and hold off further treatment until this result is returned

Rana Alnasser's screen

The results are as follows:

Na^+	140 mmol/l
K^+	6.9 mmol/l
Urea	4.0 mmol/l
Creatinine	82 µmol/l
C-reactive protein	139 mg/l
Glucose	5.8 mmol/l

You visit him on the ward. He is having a nebuliser and reading the newspaper.

What is the best course of action?

A Urgent calcium gluconate 10 ml 10% intravenous (iv) followed by insulin/dextrose infusion

B Urgent electrocardiogram (ECG), followed by calcium gluconate 10 ml 10% iv followed by insulin/dextrose infusion

C Repeat laboratory urea and electrolyte sample, and hold off further treatment until this result is returned

D Repeat laboratory urea and electrolyte sample and check potassium on an arterial blood gas machine if available

E Urgent ECG. Repeat laboratory urea and electrolyte sample and check potassium on an arterial blood gas machine if available in the meantime

meantime

Explanation

E	Urgent ECG. Repeat laboratory urea and electrolyte sample and check potassium on an arterial blood gas machine if available in the meantime

This young man has no recognised reasons for hyperkalaemia. He is not on any medications which would predispose him to high potassium; indeed, his regular salbutamol treatment is likely to give him low serum potassium by driving potassium into the cells. His urea and electrolytes are otherwise normal. His glucose is normal. The most likely cause of the high potassium in this case is either mild haemolysis not picked up in the laboratory, or the long use of a tourniquet during blood taking, leading to relative tissue acidosis when the sample was taken and therefore a high potassium. It is likely to be artefactual. However, it would be prudent to check for evidence of cardiac toxicity which is easy to do with an ECG. It would also be worth rechecking the potassium, and if a blood gas machine is available it may be worth rechecking the potassium locally pending the formal laboratory result.

A	Urgent calcium gluconate 10 ml 10% intravenous (iv) followed by insulin/dextrose infusion

As explained above, it is important to determine whether there is any cardiac toxicity and also to confirm hyperkalaemia.

B	Urgent electrocardiogram (ECG), followed by calcium gluconate 10 ml 10% iv followed by insulin/dextrose infusion

Calcium gluconate is given if there are any cardiac

Rana Alnasser's screen

You are asked to check the blood results on a 32-year-old man who was admitted earlier in the day on the medical take. He is very overweight and has been admitted with an infective exacerbation of asthma. He is being treated with oral prednisolone 60 mg od, 4-hourly 5 mg salbutamol nebulisers with amoxicillin 500 mgs tds and erythromycin 250 mg tds. Besides his normal inhalers, he does not take any regular medications. He is a smoker. The team commented that it was very difficult to gain venous access.

The results are as follows:

Na^+	140 mmol/l
K^+	6.9 mmol/l
Urea	4.0 mmol/l
Creatinine	82 µmol/l
C-reactive protein	139 mg/l
Glucose	5.8 mmol/l

You visit him on the ward. He is having a nebuliser and reading the newspaper.

What is the best course of action?

Your answer was correct

A Urgent calcium gluconate 10 ml 10% intravenous (iv) followed by insulin/dextrose infusion

B Urgent electrocardiogram (ECG), followed by calcium gluconate 10 ml 10% iv followed by insulin/dextrose infusion

A
B
C
D
E

A 72-year-old Bangladeshi man with a new diagnosis of type 2 diabetes, presented with a 3-week history of leg oedema. His past medical history includes hospitalisation after a road traffic accident 20 years ago in Bangladesh and stable angina. There was no history of retinopathy or neuropathy.

Current medications include aspirin 75 mg, atorvastatin 20 mg, amlodipine 5 mg once daily, and isosorbide mononitrate SR 60 mg once a day. His diabetic control with dietary modification has been satisfactory with an HbA1c of 44 mmol/mol (6.2%).

Investigations:

Creatinine	68 µmol/l
Bilirubin	5 µmol/l
ALT	30 U/l
ALP	98 U/l
Gamma-GT	45 U/l
Total protein	32 g/l
Albumin	18 g/l
Cholesterol	9.8 mmol/l
Urine microscopy	granular casts
Urine protein	14.2 g/day
Hepatitis serology:	
B e antigen	negative
B core IgG antibody	positive
B surface antigen	positive
C antibody	negative

Urine microscopy	granular casts
Urine protein	14.2 g/day
Hepatitis serology:	
B e antigen	negative
B core IgG antibody	positive
B surface antigen	positive
C antibody	negative

Renal biopsy was performed and is shown below:

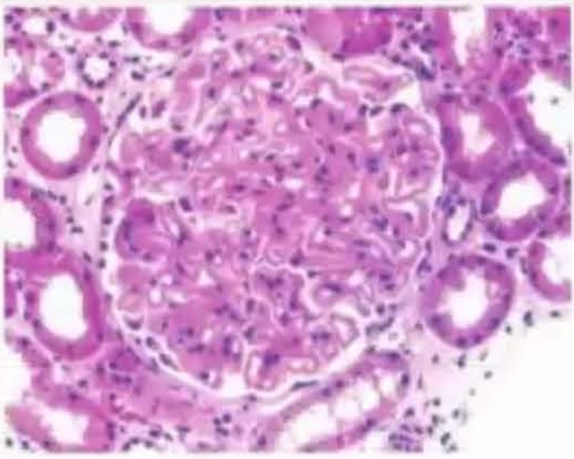

What is the most likely diagnosis?

A	Renal TB
B	Mesangiocapillary glomerulonephritis
C	Minimal change disease
D	Diabetic glomerulosclerosis
E	Membranous nephropathy

B surface antigen	positive
C antibody	negative

Renal biopsy was performed and is shown below:

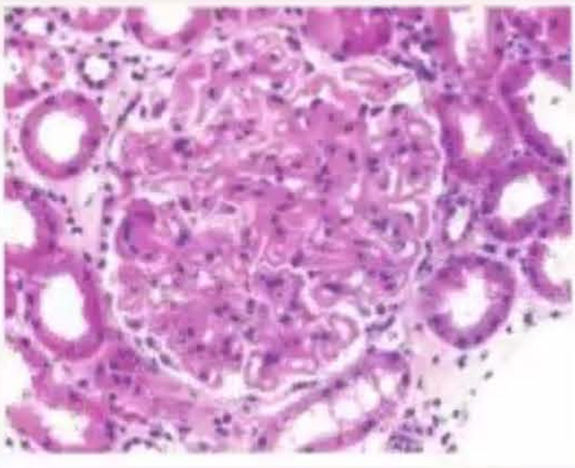

What is the most likely diagnosis?

A Renal TB

B Mesangiocapillary glomerulonephritis

C Minimal change disease

D Diabetic glomerulosclerosis

E Membranous nephropathy

70065

Submit

E Membranous nephropathy

Explanation

E Membranous nephropathy

The answer is Membranous nephropathy -

Nephrotic syndrome with hepatitis B infection and carriage is associated with secondary membranous nephropathy. Other common causes of secondary membranous nephropathy include SLE, drugs (gold, penicillamine) and malignancies.

A Renal TB

Renal TB is incorrect, it is not commonly associated with nephrotic syndrome.

B Mesangiocapillary glomerulonephritis

Mesangiocapillary glomerulonephritis is incorrect, It is a rare cause in a hepatitis B-positive patient and is typically associated with red cell casts.

C Minimal change disease

Minimal change disease is incorrect. The renal biopsy is typically normal in appearance on light microscopy, the characteristic histologic lesion is diffuse effacement of the epithelial foot processes on electron microscopy. Thickened basement membranes are evident in membranous nephropathy.

D Diabetic glomerulosclerosis

12:39
On ...
594-042-7551
Leave

Google

membranous gn pathology

ALL IMAGES NEWS VIDEOS MAPS SHOPPING BOOKS FLIG

Latest GIF HD Product

spike and dome appearance | post streptococcal glomerulonephritis | imm

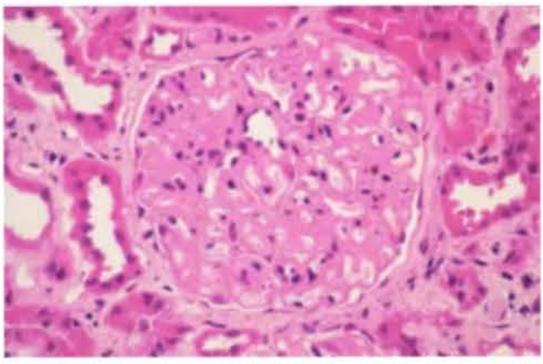

Primary membranous glomerulonephritis
pathologyoutlines.com

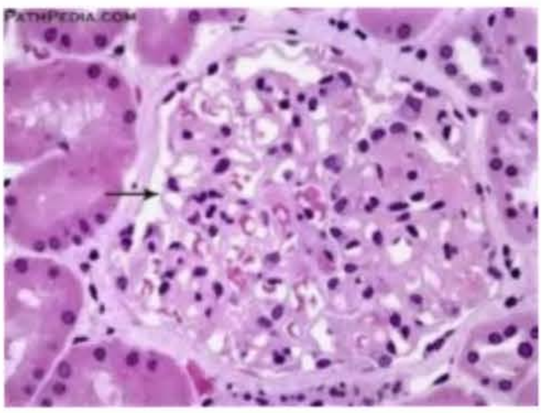

Membranous nephropathy by PathPedia ...
pathpedia.com

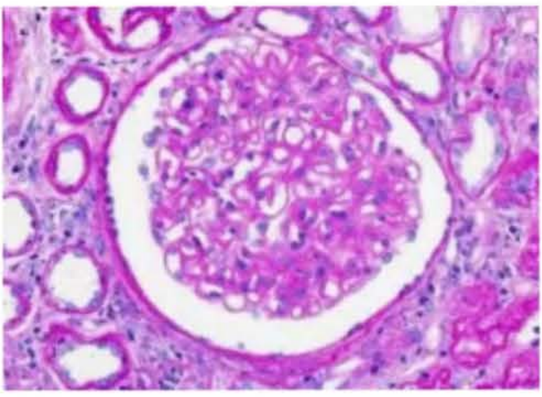

Membranous glomerulonephritis ...
flickr.com

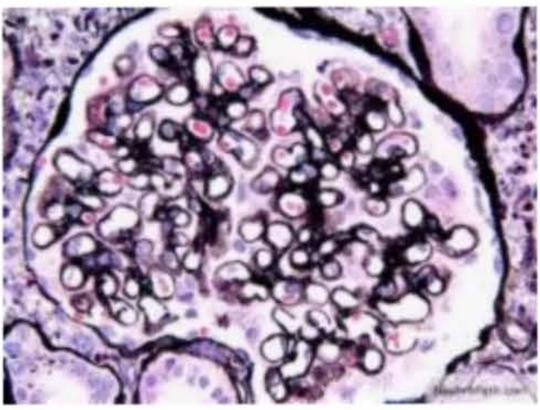

Primary membranous glomerulonephritis
pathologyoutlines.com

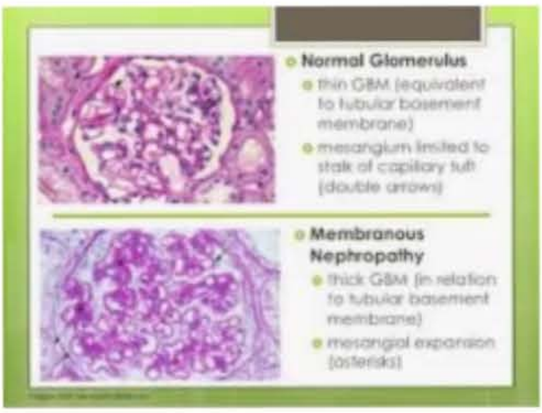

Pathophysiology of Membranous GN
slideshare.net

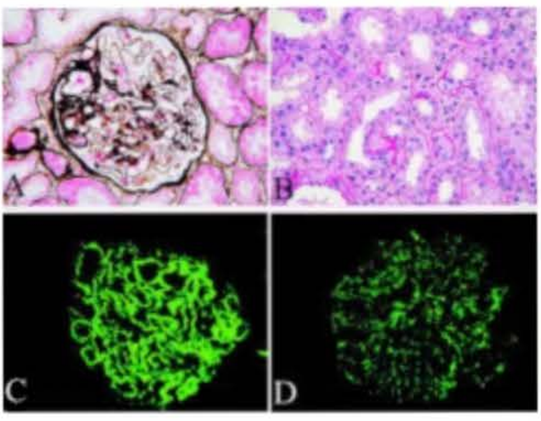

Mercury-Induced Membranous Nephropathy ...

Discover Updates Search Recen
Audio Video Share Participants More

12:40
On
594-042-7551
Leave

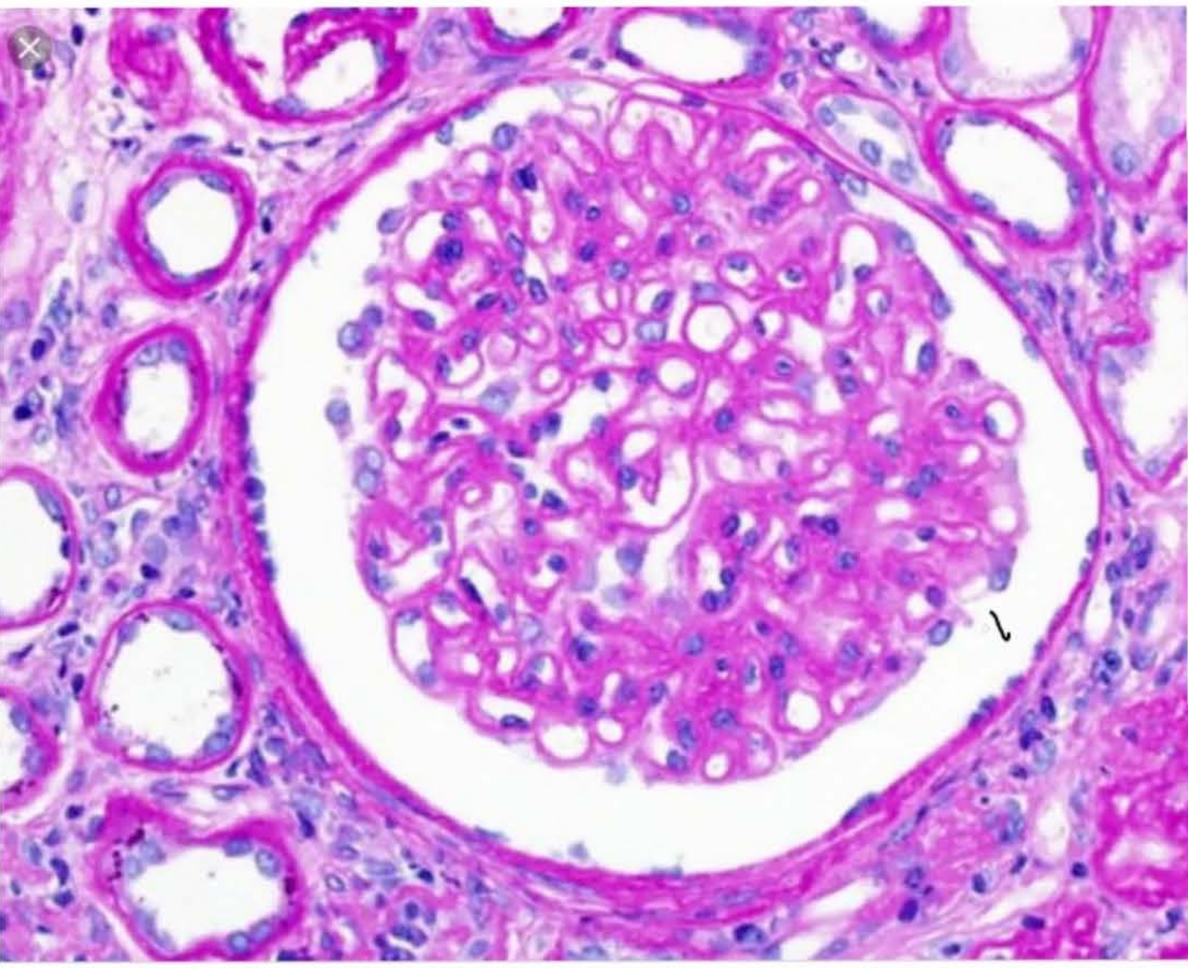

Stop Annotation Spotlight Pen Highlighter Line Rectangle Oval Undo Redo Clear Color

Qiao's Pathology: Membranous glomerulonephritis | Advanced M... | Flickr

... Qiao's Pathology: Membranous glomerulonephritis | by Qiao's Pathology (Art and Science in Medicine)

Images may be subject to copyright. Learn more

RELATED IMAGES

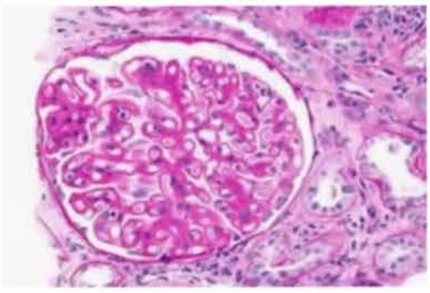

File:Membranous nephropathy - pas - very hi...

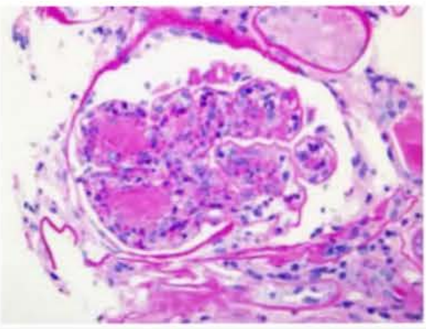

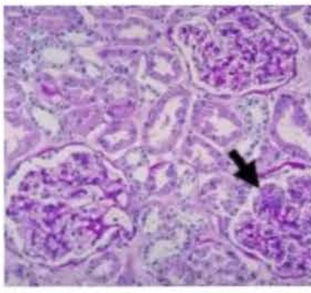

Henoch-Schönlein purpura: prolife

Discover Updates Search Recent More
Audio Video Share Participants More

12:41
On
594-042-7551
Leave

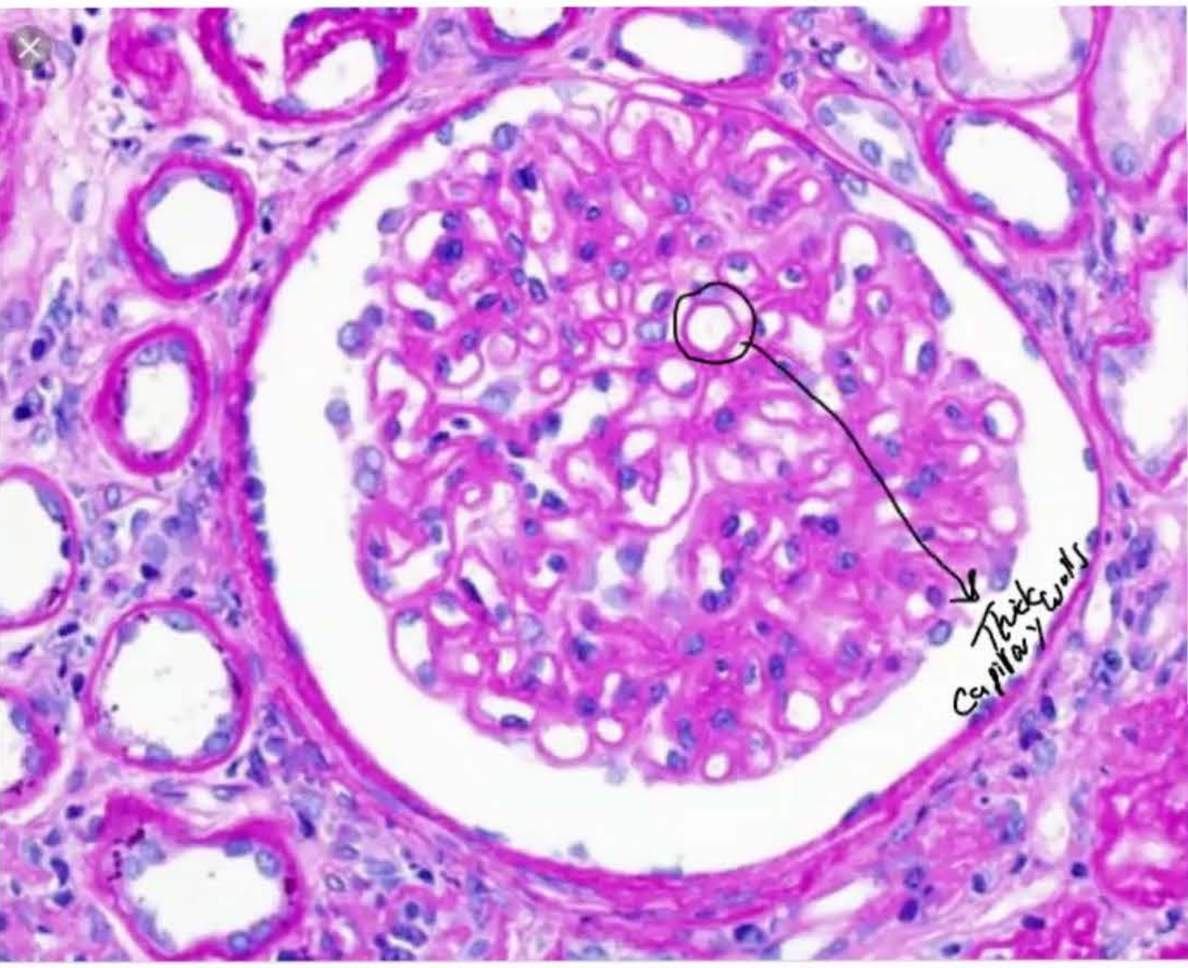

Stop Annotation
Spotlight
Pen
Highlighter
Line
Rectangle
Oval
Undo
Redo
Clear
Color

Qiao's Pathology: Membranous glomerulonephritis | Advanced M... | Flickr

... Qiao's Pathology: Membranous glomerulonephritis | by Qiao's Pathology (Art and Science in Medicine)

Images may be subject to copyright. Learn more

RELATED IMAGES

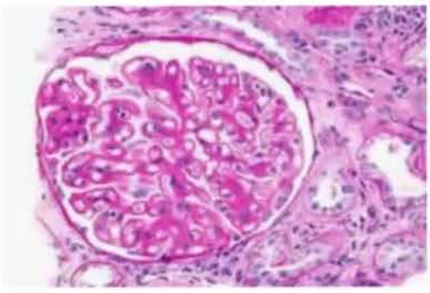

File:Membranous nephropathy - pas - very hi...

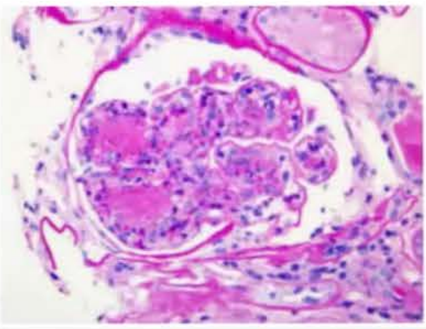

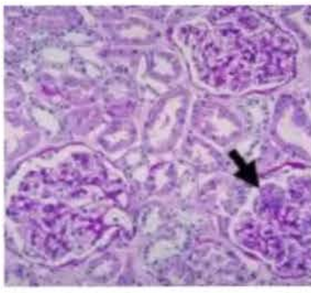

Henoch-Schönlein purpura: prolife

Discover
Updates
Search
Recent
More
Audio
Video
Share
Participants
More

12:43
On ...
594-042-7551
Leave

B Mesangiocapillary glomerulonephritis

Mesangiocapillary glomerulonephritis is incorrect, It is a rare cause in a hepatitis B-positive patient and is typically associated with red cell casts.

C Minimal change disease

Minimal change disease is incorrect. The renal biopsy is typically normal in appearance on light microscopy, the characteristic histologic lesion is diffuse effacement of the epithelial foot processes on electron microscopy. Thickened basement membranes are evident in membranous nephropathy.

D Diabetic glomerulosclerosis

Diabetic glomerulosclerosis is incorrect. The duration of diabetes and the absence of other microvascular complications such as retinopathy make diabetic nephropathy less likely.

Rate this question:

Next Question

© Pastest 2019

Audio Video Share Participants More

12:43
On
594-042-7551
Leave

A 50-year-old woman with a 4-year history of type 2 diabetes was referred to the Renal Clinic. She was commenced on 5 mg of lisinopril five weeks ago for hypertension. Otherwise, she is well, without any symptoms. Her diabetes is controlled with twice-daily (bd) mixed insulin.

On examination, her blood pressure (BP) is 153/81 mmHg and her pulse rate is 75 bpm and regular. There is minor loss of sensation affecting both feet.

Electrolytes five weeks ago:

Sodium (Na^+)	138 mmol/l
Potassium (K^+)	4.0 mmol/l
Urea	4.0 mmol/l
Creatinine (Cr)	120 µmol/l

Electrolyte results in clinic today are as follows:

		Normal Values
Na^+	138 mmol/l	
K^+	5.5 mmol/l	
Urea	6.0 mmol/l	
Cr	150 µmol/l	
HbA1c	54.10 mmol/mol (7.1%)	9.29-53.0 mmol/mol (3-7%)

What is the most likely cause for the electrolyte change?

A Progression of diabetic nephropathy

B Starting angiotensin-converting enzyme (ACE) inhibitor treatment

Audio Video Share Participants More

Sodium (Na^+)	138 mmol/l
Potassium (K^+)	4.0 mmol/l
Urea	4.0 mmol/l
Creatinine (Cr)	120 µmol/l

Electrolyte results in clinic today are as follows:

		Normal Values
Na^+	138 mmol/l	
K^+	5.5 mmol/l	
Urea	6.0 mmol/l	
Cr	150 µmol/l	
HbA1c	54.10 mmol/mol (7.1%)	9.29-53.0 mmol/mol (3–7%)

What is the most likely cause for the electrolyte change?

A	Progression of diabetic nephropathy
B	Starting angiotensin-converting enzyme (ACE) inhibitor treatment
C	Renal artery stenosis
D	Diabetic ketoacidosis (DKA)
E	Hypertension

12:44
On
594-042-7551
Leave

Urea	4.0 mmol/l
Creatinine (Cr)	120 µmol/l

Electrolyte results in clinic today are as follows:

		Normal Values
Na^+	138 mmol/l	
K^+	5.5 mmol/l	
Urea	6.0 mmol/l	
Cr	150 µmol/l	
HbA1c	54.10 mmol/mol (7.1%)	9.29-53.0 mmol/mol (3–7%)

What is the most likely cause for the electrolyte change?

Your answer was correct

A Progression of diabetic nephropathy

B Starting angiotensin-converting enzyme (ACE) inhibitor treatment

C Renal artery stenosis

D Diabetic ketoacidosis (DKA)

E Hypertension

Explanation

B Starting angiotensin-converting enzyme (ACE)

Audio Video Share Participants More

12:44
On
594-042-7551
Leave

E Hypertension

Explanation

B Starting angiotensin-converting enzyme (ACE) inhibitor treatment

When starting an ACE inhibitor, a non-progressive rise in Cr levels of 20–30% is normal. This is observed in almost all intervention trials, with respect to the renin–angiotensin system, and is associated with an initial reduction in BP; it has no prognostic significance. It is due to the ACE inhibitor affecting the glomerular perfusion. It is reversed once the ACE inhibitor is stopped.

Guidelines generally suggest checking serum creatinine levels one week, one month and then periodically, after starting an ACE inhibitor.

A Progression of diabetic nephropathy

Due to it being five weeks, this is too short to be progression. Diabetic nephropathy is not generally a rapidly progressive disease; it progresses generally over years.

C Renal artery stenosis

A progressive rise of > 30% in Cr levels should prompt consideration of renal artery stenosis. In this case, the rise is smaller than this. Renal artery stenosis can be diagnosed with renal Doppler or renal magnetic resonance angiography (MRA).

D Diabetic ketoacidosis (DKA)

DKA would present with vomiting and abdominal pain. It would not cause a rise in Cr levels, unless there was

Audio Video Share Participants More

rapidly progressive disease, it progresses generally over years.

C Renal artery stenosis

A progressive rise of > 30% in Cr levels should prompt consideration of renal artery stenosis. In this case, the rise is smaller than this. Renal artery stenosis can be diagnosed with renal Doppler or renal magnetic resonance angiography (MRA).

D Diabetic ketoacidosis (DKA)

DKA would present with vomiting and abdominal pain. It would not cause a rise in Cr levels, unless there was dehydration or hypoperfusion.

E Hypertension

There are no signs of malignant hypertension such as headache, vomiting or visual disturbances. The BP is not particularly high in this case.

71324

Rate this question:

Next Question

© Pastest 2019

A 60-year-old man presents to the general practitioner (GP) with tiredness and stress at work. He is due to retire in five years and wants to work out his time, but he is being forced to retire early.

Past medical history of note includes hypertension, which is managed with ramipril.

Clinical examination reveals a blood pressure (BP) of 142/78 mmHg. Otherwise, there are no other abnormal findings.

Investigations:

		Normal Values
Hb	12.9 g/dl	
WCC	7.8×10^9/l	
PLT	192×10^9/l	
Na^+	139 mmol/l	
K^+	4.5 mmol/l	
Creatinine	130 µmol/l (127 µmol/l some two years earlier)	
Plasma Viscosity	1.78 mPa/s	1.50-1.72
Immunoglobulins	Immunoglobulin G (IgG) paraprotein band, total IgG elevated at 27 g	
Bone marrow	Plasma cells < 10%	

Which of the following is the most likely diagnosis?

A Hodgkin's lymphoma

Investigations:

		Normal Values
Hb	12.9 g/dl	
WCC	7.8×10^9/l	
PLT	192×10^9/l	
Na^+	139 mmol/l	
K^+	4.5 mmol/l	
Creatinine	130 µmol/l (127 µmol/l some two years earlier)	
Plasma Viscosity	1.78 mPa/s	1.50-1.72
Immunoglobulins	Immunoglobulin G (IgG) paraprotein band, total IgG elevated at 27 g	
Bone marrow	Plasma cells < 10%	

Which of the following is the most likely diagnosis?

A Hodgkin's lymphoma

B Non-Hodgkin's lymphoma

C Monoclonal gammopathy of unknown significance (MGUS)

D Multiple myeloma

E Waldenstrom's macrogammaglobulinaemia

Explanation

C Monoclonal gammopathy of unknown significance (MGUS)

The incidental finding of a paraprotein band, without evidence of end-organ damage, and < 10% plasma cell involvement of the bone marrow is typical of MGUS. Progression to myeloma is around 1% per year, and the vast majority of patients can be managed conservatively. Evidence of deteriorating renal function or impaired immunity may indicate that transformation to myeloma has occurred.

A Hodgkin's lymphoma

Symptoms of Hodgkin's lymphoma include fever, night sweats and weight loss. There may be lymphadenopathy and hepatosplenomegaly, and patients feel lethargic with pruritus. Fifty per cent of cases of Hodgkin's lymphoma are due to Epstein–Barr virus. Diagnosis is made by lymph node biopsy which shows multinucleated Reed–Sternberg cells. There is no IgG paraprotein band in Hodgkin's lymphoma.

B Non-Hodgkin's lymphoma

Non-Hodgkin's lymphoma is differentiated from Hodgkin's lymphoma by the absence of multinucleated Reed–Sternberg cells; otherwise, the symptoms are similar. Symptoms may include fever, night sweats and weight loss. There may be lymphadenopathy and hepatosplenomegaly, and patients feel lethargic with pruritus. The diagnosis is made by lymph node biopsy. It may be associated with Epstein–Barr virus, human T-cell leukaemia virus and *Helicobacter pylori*. There is no IgG paraprotein band in

There may be lymphadenopathy and hepatosplenomegaly, and patients feel lethargic with pruritus. The diagnosis is made by lymph node biopsy. It may be associated with Epstein–Barr virus, human T-cell leukaemia virus and *Helicobacter pylori*. There is no IgG paraprotein band in Hodgkin's lymphoma.

D	Multiple myeloma

Multiple myeloma is a dyscrasia of the plasma cells; therefore, you would expect the bone marrow biopsy to show plasma cells of > 10%. Initially, there are often no symptoms. However, in advanced multiple myeloma, there may be bone pain, bleeding, frequent infections and anaemia.

E	Waldenstrom's macrogammaglobulinaemia

Waldenstrom's macrogammaglobulinaemia is also known as lymphoplasmacytic lymphoma. It is a cancer affecting B-cells, and the main antibody in excess is immunoglobulin M, and not IgG, paraprotein. Symptoms of Waldenstrom's macrogammaglobulinaemia are related to the hyperviscosity of excessive immunoglobulins, including visual problems - blurred vision, confusion, dizziness, headaches and loss of co-ordination.

Rate this question:

Next Question

Previous Q... Tag Questi... Feedback End Session

Blog About Pastest Contact Us Help

1:19

A 56-year-old woman is admitted to the ward. She developed a sore throat a week ago and the general practitioner commenced her on penicillin. She now feels more unwell and has developed generalised joint pains and shivering attacks with a rash. For bipolar disorder she has also been taking lithium for the past two years.

On physical examination, her blood pressure is 140/80 mmHg, and chest and abdominal examination is unremarkable.

Investigations:

Haemoglobin	12.2 g/dl
White cell count	11.2×10^9/l
Platelets	282×10^9/l
Na^+	135 mmol/l
K^+	4.3 mmol/l
Urea	15.2 mmol/l
Creatinine	160 µmol/l
Urine microscopy	Eosinophils, red blood cells

What is the most likely diagnosis?

A Acute tubulo-interstitial nephritis

B Immunoglobulin A (IgA) nephropathy

C Lithium toxicity

D Post-streptococcal glomerulonephritis

E Systemic lupus erythematosus

Rana Alnasser's screen

Explanation

A Acute tubulo-interstitial nephritis

Acute tubule-interstitial nephritis presents with arthralgia, skin rashes, fever and kidney disease. It is mainly caused by drug reactions, commonly non-steroidal anti-inflammatory agents, antibiotics (penicillin, sulphonamides, cephalosporins, rifampicin, quinolones), allopurinol and phenytoin. Investigations can reveal eosinophilia, urinary eosinophils and raised immunoglobulin E (IgE) levels.

B Immunoglobulin A (IgA) nephropathy

There would not be eosinophils in the urine. There would be haematuria. IgA nephropathy is the most common primary glomerulonephritis in the world.

C Lithium toxicity

Lithium toxicity presents with neurological symptoms of tremor, weakness, and dysarthria. It can also cause nephrogenic diabetes insipidus.

D Post-streptococcal glomerulonephritis

Although blood and protein in the urine after an episode of sore throat may suggest post-streptococcal glomerulonephritis, there would not be any eosinophils in the urine.

E Systemic lupus erythematosus

Systemic lupus erythematosus can cause a chronic tubule-interstitial nephritis. Apart from joint pains there are no other symptoms of SLE, such as malar rash, alopecia or weakness.

1:21

A 60-year-old woman presents with refractory hypertension first picked up on a routine health check. She is a long-term smoker. She has mild asthma and eczema but no other significant medical history.

She has recently complained to her general practitioner of pains in her calves which have occurred while she is walking her dog. Her blood pressure remains 150/95 mmHg in spite of multiple medical therapy trials.

Her blood results are as follows:

Na^+	144 mmol/l
K^+	3.2 mmol/l
Urea	4.8 mmol/l
Creatinine	76 µmol/l

She has had a test of her renin and aldosterone activity both of which were high.

The most likely diagnosis is:

A	Bilateral adrenal hyperplasia
B	Cushing's disease
C	Primary hyperaldosteronism (Conn's syndrome)
D	Renovascular hypertension secondary to fibromuscular dysplasia
E	Renovascular hypertension secondary to renal arterial sclerosis

Rana Alnasser's screen

Explanation

E	Renovascular hypertension secondary to renal arterial sclerosis

This woman has evidence of secondary hyperaldosteronism with high normal sodium and low potassium levels in the presence of high renin and aldosterone activity. This is likely to be a result of renal artery stenosis from atherosclerosis. She has a risk factor for arteriosclerosis and has symptoms that could reflect peripheral vascular disease which is recognised to occur with atherosclerotic renal artery sclerosis. Limb arteries can be affected by fibromuscular dysplasia, but this occurs only in about 5% of cases.

A	Bilateral adrenal hyperplasia

Adrenal hyperplasia may lead to increased secretion of aldosterone. This is primary hyperaldosteronism, and therefore the renin would be suppressed.

B	Cushing's disease

Potassium is normal in Cushing's disease because the underlying disease is due to an excess of cortisol production.

C	Primary hyperaldosteronism (Conn's syndrome)

In Conn's syndrome the renin activity would be suppressed.

D	Renovascular hypertension secondary to fibromuscular dysplasia

1:23

A 19-year-old man presented with a 2-day history of a painful rash, constipation, lethargy and generalised body pain. He has no significant past medical history apart from hospitalisation as a child for peritonitis secondary to a ruptured appendix.

Examining his legs, you note the following:

Investigations:

Creatinine	162 μmol/l
LFTs	normal
FBC	normal
Urine microscopy	red cell casts
ANCA	negative
ASOT	normal
Hepatitis B/C	negative

What is the diagnosis?

A IgA nephropathy

Rana Alnasser's screen



Investigations:

Creatinine	162 μmol/l
LFTs	normal
FBC	normal
Urine microscopy	red cell casts
ANCA	negative
ASOT	normal
Hepatitis B/C	negative

What is the diagnosis?

A IgA nephropathy

B Infective endocarditis

C Henoch-Schönlein purpura

D Erythema nodosum

E Polyarteritis nodosa

Submit

Explanation

C Henoch-Schönlein purpura

In a young patient with microscopic haematuria and renal impairment, the differential diagnosis includes HSP, IgA nephropathy and thin-membrane disease. HSP is uncommon after the second decade of life and the renal involvement is often transient. The rash is a purpuric vasculitis, usually spreading on the extensor surfaces. Histology shows a leucocytoclastic vasculitis with IgA deposits in blood vessel walls.

A IgA nephropathy

Both IgA nephropathy (IgAN) and Henoch-Schönlein nephritis are characterised by mesangial IgA deposition. The latter is differentiated from IgAN by extrarenal manifestations, such as purpura (as in this gentleman), polyarthralgia, and abdominal pain caused by gut vasculitis with IgA deposition.

B Infective endocarditis

It does not explain all the extra-renal manifestations and normal FBC.

D Erythema nodosum

Erythema nodosum is characterised by red or violet subcutaneous nodules that usually develop in a pretibial location.

E Polyarteritis nodosa

PAN typically presents with systemic symptoms (fatigue, weight loss, weakness, fever, arthralgias) and signs (skin

1:27
On
594-042-7551
Leave

A 23-year-old man presents with a 4-day history of sore throat. He also mentions a change in colour of urine and it looks blood-stained. There are no other associated urinary complaints.

His past medical history is unremarkable.

Upon examination, his temperature is 36 °C, blood pressure 130/80 mmHg, chest and abdominal examination unremarkable. Chest X-ray is normal. Blood results are normal. Renal biopsy shows mesangial proliferation with positive immunofluorescence for immunoglobulin A (IgA) and C3.

What is the most likely diagnosis?

A	Adult polycystic kidney disease
B	Henoch–Schönlein purpura
C	IgA nephropathy
D	Kawasaki disease
E	Post-streptococcal glomerulonephritis

70767

Submit

Previous Q...

Skip Questi...

Audio
Video
Share
Participants
More

E Post-streptococcal glomerulonephritis

Explanation

C IgA nephropathy

Immunoglobulin A (IgA) nephropathy, or Berger's disease, is the commonest cause of glomerulonephritis worldwide. A typical patient is a young male with asymptomatic microscopic haematuria or episodic macroscopic haematuria, precipitated by infection (e.g. pharyngitis). Recovery is usually rapid between attacks. The pathology consists of focal proliferative glomerulonephritis with mesangial deposits of IgA. Prognosis is usually good in patients with normal blood pressure, normal kidney function and absence of proteinuria at presentation. Approximately 20% of patients develop kidney disease 20 years from the time of diagnosis.

A Adult polycystic kidney disease

Polycystic kidney disease is not associated with sore throat or any abnormality in immunofluoresence. Diagnosis is with genetic studies or ultrasound identification of cysts.

B Henoch–Schönlein purpura

There would be a history of skin rash with this condition.

D Kawasaki disease

Kawasaki disease is associated with sore throat. However, it generally occurs in children and there may be coronary artery aneurysms and peeling of the skin of the hands and feet.

1:28
On
594-042-7551
Leave

Polycystic kidney disease is not associated with sore throat or any abnormality in immunofluoresence. Diagnosis is with genetic studies or ultrasound identification of cysts.

B Henoch–Schönlein purpura

There would be a history of skin rash with this condition.

D Kawasaki disease

Kawasaki disease is associated with sore throat. However, it generally occurs in children and there may be coronary artery aneurysms and peeling of the skin of the hands and feet.

E Post-streptococcal glomerulonephritis

Post-streptococcal glomerulonephritis is characterised by sudden onset of haematoproteinuria, oedema and hypertension. It is not associated with predominantly IgA in the renal biopsy.

Rate this question:

Next Question

© Pastest 2019

Audio Video Share Participants More

1:28

A 30-year-old woman with a history of intravenous (IV) drug use is admitted feeling generally unwell. She has a fever, arthralgia and a rash, and has been deteriorating with increasing tiredness over the past six weeks. She admits to having run out of injection sites and is currently using areas around her groin and in her feet.

Her blood pressure (BP) is 110/70 mmHg, pulse is 85/min and regular, her temperature is 37.8 °C.

On examination, she has a soft systolic murmur at the lower left sternal edge.

Investigations reveal:

Electrocardiogram	Sinus tachycardia
Haemoglobin (Hb)	10.2 g/dl
White cell count (WCC)	12.2×10^9/l
Platelet (PLT)	474×10^9/l
Sodium (Na^+)	132 mmol/l
Potassium (K^+)	4.6 mmol/l
Urea	15.2 mmol/l
Creatinine	145 µmol/l
Urine microscopy	Red cell casts
Erythrocyte sedimentation rate	32 mm/h (0–20)
C-reactive protein	64 mg/l (< 10)
Complement C3	20 mg/dl (65–190)
Complement C4	3 mg/dl (15–50)
Renal biopsy	Focal segmental proliferative glomerulonephritis

Rana Alnasser's screen

1:30

MyPastest
https://mypastest.pastest.com

Pastest+

Creatinine	145 µmol/l
Urine microscopy	Red cell casts
Erythrocyte sedimentation rate	32 mm/h (0–20)
C-reactive protein	64 mg/l (< 10)
Complement C3	20 mg/dl (65–190)
Complement C4	3 mg/dl (15–50)
Renal biopsy	Focal segmental proliferative glomerulonephritis

Which one of the following is an appropriate next investigation?

A Anti-double stranded DNA antibodies

B Anticardiolipin antibodies

C Computed tomography (CT) of the thorax and abdomen

D Rheumatoid factor

E Serial blood cultures

Submit

E Serial blood cultures

Explanation

E Serial blood cultures

This patient has hypocomplementaemia and glomerulonephritis with features in the history and examination suggesting infective endocarditis as the aetiology. The blood results suggest an underlying infection with the raised white cell count and C-reactive protein. The erythrocyte sedimentation rate, an indicator for inflammation, is also raised. Serial blood cultures from different sites and an echocardiogram are the next investigations of choice. She should be managed with intravenous (iv) flucloxacillin and gentamicin and there is no need to wait for investigations before commencing therapy.

A Anti-double stranded DNA antibodies

The anti-double-stranded DNA antibody (anti-dsDNA) is a specific type of ANA antibody found in about 30% of people with systemic lupus. Less than 1% of healthy individuals have this antibody, making it helpful in confirming a diagnosis of systemic lupus. This patient does not have systemic lupus erythematosus (SLE) because SLE is associated with complement activation, therefore the complement levels would be raised rather than reduced as in this scenario.

B Anticardiolipin antibodies

Anticardiolipin antibodies are antibodies often directed against cardiolipin and found in syphilis, antiphospholipid syndrome, livedoid vasculitis, Behçet syndrome, idiopathic spontaneous abortion and SLE. This patient does not have systemic lupus erythematosus (SLE) given the clinical

complement levels would be raised rather than reduced as in this scenario.

B Anticardiolipin antibodies

Anticardiolipin antibodies are antibodies often directed against cardiolipin and found in syphilis, antiphospholipid syndrome, livedoid vasculitis, Behçet syndrome, idiopathic spontaneous abortion and SLE. This patient does not have systemic lupus erythematosus (SLE) given the clinical scenario and anti-double-stranded DNA antibody (anti-dsDNA) is negative.

C Computed tomography (CT) of the thorax and abdomen

A CT may identify any malignancy or abnormal masses but it is not useful in infective endocarditis.

D Rheumatoid factor

Rheumatoid factor is the autoantibody that was first found in rheumatoid arthritis. It is defined as an antibody against the Fc portion of IgG and different rheumatoid factors can recognise different parts of the IgG-Fc. Although it is found in rheumatoid arthritis, it is not present in every patient. This test would not be useful in infective endocarditis.

Rate this question:

Next Question

Previous Q... Tag Questi... Feedback End Session

A 40-year-old man who is now approaching end-stage renal disease requires haemodialysis three times a week. His brother, who is an identical twin, has perfectly normal kidney function.

During the initial work-up for the kidney transplant, his twin brother is cardiovascularly fit for surgery. The kidney is placed anteriorly in the abdomen.

His twin brother's investigations:

Sodium	140 mmol/l
Potassium	4.2 mmol/l
Urea	7.2 mmol/l
Creatinine	80 μmol/l
Hb	12.0 g/dl
WCC	5.1×10^9/l
Urine dipstick	Trace protein

This type of transplantation is described as:

A Heterotopic isograft

B Heterotopic xenograft

C Orthotopic allograft

D Orthotopic autograft

E Orthotopic isograft

Explanation

A Heterotopic isograft

Transplants are classified as:

- autografts: in which the same individual acts as both donor and recipient;
- isografts: in which the donor and recipient are genetically identical;
- allografts: where the donor and recipient are genetically dissimilar but belong to the same species;
- xenografts: in which the donor and recipient belong to different species.

In orthotopic transplants the transplanted part is placed in its normal anatomical location, while in heterotopic transplants it is placed in a different anatomical location.

C Orthotopic allograft

Donor and recipient are genetically dissimilar but belong to the same species.

B Heterotopic xenograft

Xenografts are from different species such as pig and human.

D Orthotopic autograft

The same individual acts as both donor and recipient.

E Orthotopic isograft

its normal anatomical location, while in heterotopic transplants it is placed in a different anatomical location.

C Orthotopic allograft

Donor and recipient are genetically dissimilar but belong to the same species.

B Heterotopic xenograft

Xenografts are from different species such as pig and human.

D Orthotopic autograft

The same individual acts as both donor and recipient.

E Orthotopic isograft

The transplanted part is placed in the normal anatomical location.

Rate this question:

© Pastest 2019

A 70-year-old woman is admitted via the Emergency Department with complaints of weakness, nausea and malaise. Unfortunately, she has not brought all of her regular medications with her. She tells you that she is a tablet-controlled diabetic, with high blood pressure and kidney problems. She has with her a packet of lisinopril which she takes at 10 mg/day. In addition, she has a packet of gliclazide which she takes at 80 mg/day. She takes several other tablets, which she left on the sideboard at home when the ambulance collected her.

She attended an outpatient appointment two weeks ago when she was prescribed a new medication. She does not know the name of this medication and does not have it with her; she was told that it was a medication also used to treat people with liver problems and had been taking one tablet a day.

On examination, she is overweight and appears unwell. She has evidence of mild biventricular cardiac insufficiency, with elevated jugular venous pressure and pitting oedema of her ankles. The remainder of the examination is unremarkable.

An electrocardiogram (ECG) shows an increased PR interval, with widening of the QRS complex.

Urgent biochemical analysis shows:

Sodium (Na^+)	140 mmol/l
Potassium (K^+)	7.1 mmol/l
Urea	11.0 mmol/l
Creatinine (Cr)	146 µmol/l

Appropriate treatment is instigated.

What is the most likely cause for this patient's presentation on this occasion?

tablet a day.

On examination, she is overweight and appears unwell. She has evidence of mild biventricular cardiac insufficiency, with elevated jugular venous pressure and pitting oedema of her ankles. The remainder of the examination is unremarkable.

An electrocardiogram (ECG) shows an increased PR interval, with widening of the QRS complex.

Urgent biochemical analysis shows:

Sodium (Na^+)	140 mmol/l
Potassium (K^+)	7.1 mmol/l
Urea	11.0 mmol/l
Creatinine (Cr)	146 µmol/l

Appropriate treatment is instigated.

What is the most likely cause for this patient's presentation on this occasion?

A	A recent 2-day course of ibuprofen 400 mg three times daily (tid)/as required (prn) for backache
B	Recent commencement of spironolactone 50 mg
C	Recent commencement of digoxin 62.5 µg once daily (od)
D	Recent commencement of bisoprolol fumarate 2.5 mg od
E	Recent commencement of amiloride hydrochloride 5 mg twice daily (bd)

1:36

This woman has life-threatening hyperkalaemia, with evidence of cardiotoxicity on ECG, requiring urgent intervention to prevent potentially fatal cardiac arrhythmias. All of the drugs listed can be associated with hyperkalaemia. However, we know that this lady has renal disease. In addition, we know that she is already taking an angiotensin-converting enzyme (ACE) inhibitor.

Following the Randomised Aldactone Evaluation Study (RALES) clinical trial, when it was shown that aldosterone antagonists can reduce mortality in severe chronic congestive cardiac failure when given in conjunction with an ACE inhibitor, the prescription rates of spironolactone increased, along with hospital admission rates and deaths from hyperkalaemia. Although this medication can be given safely with ACE inhibitors, and indeed be beneficial, there is a risk of causing life-threatening hyperkalaemia, particularly in those with renal impairment.

The combination of ACE inhibitor therapy with spironolactone therefore needs to be carefully considered and monitored to avoid significant side-effects. The standard dose used for heart failure is at a lower level than that seen here (around 25–50 mg daily).

A	A recent 2-day course of ibuprofen 400 mg three times daily (tid)/as required (prn) for backache

Non-steroidal anti-inflammatory agents can be associated with hyperkalaemia in the context of renal impairment, although we might expect this with a longer duration of use if this were the cause in this case.

C	Recent commencement of digoxin 62.5 µg once daily (od)

Digoxin toxicity can be complicated by hypokalaemia, although it is hyperkalaemia which is seen here.

Rana Alnasser's screen

although we might expect this with a longer duration of use if this were the cause in this case.

C	Recent commencement of digoxin 62.5 µg once daily (od)

Digoxin toxicity can be complicated by hypokalaemia, although it is hyperkalaemia which is seen here.

D	Recent commencement of bisoprolol fumarate 2.5 mg od

Non-selective b blockade can lead to hyperkalaemia by decreasing the uptake of potassium from extracellular into intracellular spaces. This would not be expected with the highly selective b1 blocker bisoprolol.

E	Recent commencement of amiloride hydrochloride 5 mg twice daily (bd)

Amiloride can cause hyperkalaemia in similar situations; however, it is not so commonly used in current practice.

Rate this question:

Next Question

Previous Q... Tag Questi... Feedback End Session

Blog About Pastest Contact Us Help

© Pastest 2019

A 50-year-old white woman presented to her GP with a 2-week history of nausea, vomiting, and anorexia. She had mild epistaxis and scant haemoptysis for the last 6 to 8 months, with three episodes of sinusitis, treated with antibiotics and inhaled steroids. Her serum creatinine on presentation was 144 µmol/l with protein ++ and blood +++. Urine microscopy revealed granular casts and dysmorphic red blood cells.

She was referred to the hospital medical team the next day when her creatinine was 175 µmol/l. Her BP was measured at 160/98 mmHg, with no rashes or other findings on physical examination.

Investigations:

Creatinine	256 µmol/l
Haematocrit	0.36
Platelets	300 × 109/l
WCC	6.1 × 109/l
ANA	negative
C3	71 mg/dl (65-190 mg/dl)
C4	37 mg/dl (15-50 mg/dl)

What is the most likely diagnosis?

A pANCA-positive vasculitis

B cANCA-positive vasculitis

C Lupus nephritis

D Post-streptococcal glomerulonephritis

E Henoch-Schönlein purpura

Touc... 00:10 1:38

Your answer was correct

A pANCA-positive vasculitis

B cANCA-positive vasculitis

C Lupus nephritis

D Post-streptococcal glomerulonephritis

E Henoch-Schönlein purpura

Explanation

B cANCA-positive vasculitis

This is a classic presentation of Granulomatosis with Polyangiitis (GPA), (previously referred to as Wegener's granulomatosis). It is a necrotising granulomatous vasculitis affecting the small vessels, associated with circulating anti-neutrophil cytoplasmic antibodies (ANCA). It may manifest in a combination of upper and/or lower respiratory tract and/or renal disease. On immunofluorescence, ANCA staining is cytoplasmic with specificity to proteinase-3.

A pANCA-positive vasculitis

pANCA-positive vasculitis is not classically associated with upper respiratory tract symptoms.

C Lupus nephritis

Lupus nephritis is associated with a positive ANA and

Rana Alnasser's screen

Touc... 00:17 1:38

A patient with chronic kidney disease related to diabetes mellitus comes to the clinic. She is managed with a number of anti-hypertensive medications and BD insulin to control her blood sugar. She also takes atorvastatin and aspirin.

On examination, her BP is 142/82 mmHg, pulse is 85 bpm and regular. Her chest and abdominal examination is unremarkable.

Investigations:

Hb	10.9 g/dl
WCC	5.9×10^9/l
PLT	201×10^9/l
Na^+	139 mmol/l
K^+	5.0 mmol/l
Creatinine	230 µmol/l
Ca^{++}	2.1 mmol/l
PO_4^{3-}	0.85 mmol/l
PTH	16.1 pmol/l (0.9-5.4)

Which of the following is the most appropriate treatment?

A Ergocalciferol

B Alphacalcidol

C Calcitonin

D Sevelamer

E Cinacalcet

Investigations:

Hb	10.9 g/dl
WCC	5.9×10^9/l
PLT	201×10^9/l
Na^+	139 mmol/l
K^+	5.0 mmol/l
Creatinine	230 µmol/l
Ca^{++}	2.1 mmol/l
PO_4^{3-}	0.85 mmol/l
PTH	16.1 pmol/l (0.9-5.4)

Which of the following is the most appropriate treatment?

Your answer was correct

A Ergocalciferol

B Alphacalcidol

C Calcitonin

D Sevelamer

E Cinacalcet

Explanation

B Alphacalcidol

Hyperparathyroidism in renal disease can be managed with

B Alphacalcidol

Hyperparathyroidism in renal disease can be managed with the use of alphacalcidol, because the drive for increased PTH comes at least in part from low levels of 1, 25-OH vitamin D. If vitamin D replacement fails to achieve a reduction in PTH levels, then surgery may be considered.

A Ergocalciferol

Ergocalciferol is vitamin D_2 and is used to prevent and treat vitamin D deficiency. However, it is the inactive form of vitamin D and therefore alphacalcidol should be used instead in this case.

C Calcitonin

Calcitonin is used for treatment of hypercalcaemia or osteoporosis. Calcitonin acts on the osteoclasts, resulting in inhibition of bone resorption and attenuation of subchondral bone turnover. It also acts directly on the chronocytes, attenuating cartilage degradation and stimulating cartilage formation.

D Sevelamer

Sevelamer is a phosphate-binding agent. Therefore, it will act to lower the phosphate levels but the phosphate is normal in this scenario. The disadvantages of sevelamer compared with other phosphate binders include its cost, its side effects of GI intolerance, the large doses that are usually needed and the potential to cause mild metabolic acidosis.

A 62-year-old man presents to the Emergency Department with severe left loin pain and fevers which have increased over the past 48 h. He has a history of chronic tophaceous gout, for which he takes allopurinol and benzbromarone, and hypertension, for which he takes amlodipine 5 mg once daily.

Examination reveals a BP of 100/60 mmHg, pulse is 95/min and regular. He is pyrexial 38.5 °C. Abdominal examination reveals severe left loin pain.

Investigations:

Hb	13.1 g/dl
WCC	16.1×10^9/l
PLT	201×10^9/l
Na^+	138 mmol/l
K^+	4.4 mmol/l
Creatinine	187 µmol/l (up from 121 µmol/l at last clinic appointment)
CRP	271 mg/l
Urine	Red cells++, white cells++, nitrites+

Which of the following is the most useful next investigation?

A	Cystoscopy
B	Intravenous pyelogram (IVP)
C	Kidney, ureter and bladder X-ray (KUB)
D	Non-contrast enhanced computed tomography (CT)

1:41

Examination reveals a BP of 100/60 mmHg, pulse is 95/min and regular. He is pyrexial 38.5 °C. Abdominal examination reveals severe left loin pain.

Investigations:

Hb	13.1 g/dl
WCC	16.1×10^9/l
PLT	201×10^9/l
Na^+	138 mmol/l
K^+	4.4 mmol/l
Creatinine	187 µmol/l (up from 121 µmol/l at last clinic appointment)
CRP	271 mg/l
Urine	Red cells++, white cells++, nitrites+

Which of the following is the most useful next investigation?

A Cystoscopy

B Intravenous pyelogram (IVP)

C Kidney, ureter and bladder X-ray (KUB)

D Non-contrast enhanced computed tomography (CT)

E Ultrasound abdomen

Rana Alnasser's screen

1:45
On
594-042-7551
Leave

D Non-contrast enhanced computed tomography (CT)

The potential diagnosis here is obstructed pyelonephritis due to a urate-containing stone within the left ureter. Benzbromarone, which the patient takes, increases urate excretion, thus leading to increased risk of stones. In this situation, with a significant rise in creatinine, contrast-enhanced imaging carries risk. Out of the other remaining options, non-contrast enhanced CT is thought to be more sensitive in detecting obstruction versus ultrasound scanning.

In the presence of significant infection, a conservative approach is not appropriate. Intravenous antibiotics plus cystoscopy and potential JJ stent insertion is therefore the management of choice.

E Ultrasound abdomen

Ultrasound scanning is not as sensitive in detecting obstruction compared with non-contrast enhanced CT. Ultrasound is operator-dependent, and also a large patient body habitus may make obtaining an adequate image difficult.

A Cystoscopy

Cystoscopy will need to be performed later on after the diagnosis with potential JJ stent insertion; however, to first obtain the diagnosis, the next investigation of choice would be non-contrast enhanced CT.

B Intravenous pyelogram (IVP)

An IVP will involve injection of contrast, therefore this will carry risk of worsening renal impairment and also there may be added fluid load of contrast. Extra fluid from

Audio Video Share Participants More

A Cystoscopy

Cystoscopy will need to be performed later on after the diagnosis with potential JJ stent insertion; however, to first obtain the diagnosis, the next investigation of choice would be non-contrast enhanced CT.

B Intravenous pyelogram (IVP)

An IVP will involve injection of contrast, therefore this will carry risk of worsening renal impairment and also there may be added fluid load of contrast. Extra fluid from contrast is particularly important to avoid in patients who are already fluid overloaded if they are renally impaired as well.

C Kidney, ureter and bladder X-ray (KUB)

A KUB is only sensitive in identifying calcium containing renal stones. Urate stones are radiolucent and will not be identified on KUB.

Rate this question:

Next Question

Previous Q... Tag Questi... Feedback End Session

© Pastest 2019

A 32-year-old man is being treated with an indinavir-containing HAART regime for HIV infection.

Other medication of note includes co-trimoxazole which was recently started as prophylaxis against PCP. He has noticed increasing nausea and tiredness over the past few weeks.

Investigations:

Hb	10.4 g/dl
WCC	6.1×10^9/l
PLT	180×10^9/l
Na^+	139 mmol/l
K^+	4.9 mmol/l
Creatinine	276 µmol/ll
Urine	Blood +, Protein +

Given the most likely renal diagnosis, which of the following is the most appropriate therapy for this patient?

A	IV hydrocortisone
B	Co-amoxiclav
C	IV methylprednisolone and cyclophosphamide
D	IV normal saline
E	IV sodium bicarbonate

20636

B Co-amoxiclav

C IV methylprednisolone and cyclophosphamide

D IV normal saline

E IV sodium bicarbonate

Explanation

D IV normal saline

This patient has crystal nephropathy, a condition known to be associated with indinavir use, which is a common component of HAART. Certain drug-drug interactions lead to increased indinavir concentration, one of which is co-trimoxazole. Adequate rehydration is crucial to avoid crystal nephropathy, and patients taking indinavir are recommended to take at least 2-3 litres of fluid per day. IV rehydration is the treatment of choice for crystal nephropathy and, given adequate fluid replacement, indinavir therapy can often continue.

A IV hydrocortisone

IV hydrocortisone is not a treatment for crystal nephropathy. Hydrocortisone may be used for treatment of adrenal failure as a replacement for corticosteroids.

B Co-amoxiclav

Co-amoxiclav would treat any bacterial urinary tract infection. Although blood and protein in the urine may be mistaken for a urinary tract infection (UTI), you would

A 75-year-old woman with a history of type 2 diabetes presents with symptoms of a urinary tract infection (UTI). She takes a mix of medications, including gliclazide modified release (MR), ramipril, amlodipine and atorvastatin.

On examination, she has a temperature of 37.8 °C; her blood pressure (BP) is 125/80 mmHg and her pulse is 75 bpm. She has suprapubic and left loin tenderness, consistent with a UTI.

Investigations reveal:

Haemoglobin (Hb)	12.3 g/dl
White cell count (WCC)	14.1×10^9/l
Platelets (PLT)	202×10^9/l
Sodium (Na^+)	139 mmol/l
Potassium (K^+)	4.9 mmol/l
Creatinine (Cr)	182 µmol/l
Urine	White cells ++, Protein ++

Which of the following is the most appropriate therapy?

A Intravenous (iv) amoxicillin

B Oral amoxicillin

C Oral ciprofloxacin

D Oral nitrofurantoin

E Oral trimethoprim

Fluoroquinolone-resistant *Escherichia coli* make up > 10% of those tested in some areas, although ciprofloxacin has still been recommended as first-line therapy by the Scottish Intercollegiate Guidelines Network (SIGN) for symptoms of an upper UTI, as seen here.

A Intravenous (iv) amoxicillin

There is no indication for iv therapy in this case. One may consider iv therapy in overt sepsis, such as low blood pressure and tachycardia. In addition, there is significant resistance to amoxicillin for urinary tract pathogens, so amoxicillin would not be the agent of choice.

B Oral amoxicillin

Significant resistance to amoxicillin exists with respect to urinary tract pathogens, being present in up to 50% of isolates in some areas. Co-amoxiclav effectively overcomes this resistance problem, but we are not presented with co-amoxiclav as an option here.

D Oral nitrofurantoin

Nitrofurantoin may be associated with peripheral neuropathy and is not a first-line choice. However, it is one of the few drugs commonly used in pregnancy to treat UTIs. Other drugs that may be safe for UTIs in pregnancy include cephalexin, amoxicillin and pivmecillinam.

E Oral trimethoprim

Trimethoprim resistance is apparently as high as 40%, but it is still recommended as a 3-day course for uncomplicated lower UTI.

A 19-year-old man presents to the clinic with raised BP of 152/82 mmHg. He has been previously fit and well as a child, with no developmental problems.

On examination, apart from the raised blood pressure, his chest and abdominal examination is unremarkable. You are concerned that he may have serious underlying pathology and arrange a series of tests.

Investigations:

Hb	12.1 g/dl
WCC	5.0×10^9/l
PLT	204×10^9/l
Na^+	139 mmol/l
K^+	3.0 mmol/l
Creatinine	105 µmol/l
Bicarbonate	35 mmol/l
Aldosterone erect	150 pmol/l (200-1000)
Renin erect	2.2 pmol/ml/hr (2.8-4.5)

Which of the following is the most likely diagnosis?

A Renal artery stenosis

B Bartter syndrome

C Gitelman syndrome

D Conn syndrome

E Liddle syndrome

Hb	12.1 g/dl
WCC	5.0×10^9/l
PLT	204×10^9/l
Na^+	139 mmol/l
K^+	3.0 mmol/l
Creatinine	105 µmol/l
Bicarbonate	35 mmol/l
Aldosterone erect	150 pmol/l (200-1000)
Renin erect	2.2 pmol/ml/hr (2.8-4.5)

Which of the following is the most likely diagnosis?

Your answer was correct

A Renal artery stenosis

B Bartter syndrome

C Gitelman syndrome

D Conn syndrome

E Liddle syndrome

Explanation

E Liddle syndrome

This man has hypertension presenting at a young age with profound hypokalaemia, alkalosis and suppressed renin and

E Liddle syndrome

This man has hypertension presenting at a young age with profound hypokalaemia, alkalosis and suppressed renin and aldosterone. This fits with the picture of Liddle syndrome, a rare autosomal dominant condition causing a mutation in the highly selective epithelial sodium channel in the distal nephron. This results in sodium retention independent of mineralocorticoid activity, and hence the clinical picture seen here.

A Renal artery stenosis

Renal artery stenosis would be associated with elevated renin and aldosterone levels. There may also be a renal bruit on abdominal examination.

B Bartter syndrome

Bartter syndrome is associated with normo-tension or slightly reduced blood pressure. Bartter syndrome is an autosomal recessive inheritance, usually diagnosed in children or adolescents with failure to thrive, polydipsia, polyuria and cramps. There is hypokalaemia, mild metabolic alkalosis, increased urinary sodium, potassium and calcium with increased serum renin and aldosterone.

C Gitelman syndrome

Gitelman syndrome is associated with normo-tension or slightly reduced blood pressure. This is an autosomal recessive inheritance. It is usually diagnosed in young adults who are asymptomatic with low serum potassium (2.0-3.0 mmol/l), reduced magnesium with mild metabolic alkalosis and increased renin and aldosterone. Urinary calcium is low, unlike Barrter syndrome.

Rana Alnasser's screen

A 68-year-old man with a long history of hypertension and chronic kidney disease (creatinine 190 μmol/l on admission) is admitted for angiography. He is kept in over the weekend and you are asked to review him three days post procedure. Nursing staff have noticed a purpuric rash over his feet and think the blood supply to his lower limbs is impaired.

Blood tests reveal erythrocyte sedimentation rate (ESR) of 86, eosinophilia and a creatinine level of 450 μmol/l.

Which of the following stems represents the most likely diagnosis?

A	Acute vasculitis
B	Cholesterol embolism
C	Contrast nephropathy
D	Renal artery thrombosis
E	Renal vein thrombosis

71298

Submit

Previous Q... Skip Questi...

A 68-year-old man with a long history of hypertension and chronic kidney disease (creatinine 190 μmol/l on admission) is admitted for angiography. He is kept in over the weekend and you are asked to review him three days post procedure. Nursing staff have noticed a purpuric rash over his feet and think the blood supply to his lower limbs is impaired.

Blood tests reveal erythrocyte sedimentation rate (ESR) of 86, eosinophilia and a creatinine level of 450 μmol/l.

Which of the following stems represents the most likely diagnosis?

Your answer was correct

A	Acute vasculitis
B	Cholesterol embolism
C	Contrast nephropathy
D	Renal artery thrombosis
E	Renal vein thrombosis

Explanation

B Cholesterol embolism

This patient has cholesterol embolism, which is most commonly seen in patients with existing arterial disease who have undergone arterial manipulation. Pre-existing kidney disease, diabetes mellitus and hypovolaemia at time

Vasculitic rash is classically a palpable purpura that occurs in crops. Vasculitis is a systemic illness and there would be other associated symptoms such as fever, weight loss, fatigue and joint pains. This scenario is not a presentation of vasculitis.

C Contrast nephropathy

Contrast nephropathy can occur after a contrast load in patients with renal impairment, particularly if there is co-existent diabetes mellitus. It would not account for the eosinophilia in this case.

D Renal artery thrombosis

Renal artery thrombosis can cause renal impairment due to complete occusion of the renal artery from thromboemboli, atherosclerosis or fibromuscular disease. However, it would not cause an eosinophilia.

E Renal vein thrombosis

Although renal vein thrombosis can cause renal impairment, it does not present like this scenario. It occurs most commonly in patients with nephrotic syndrome with heavy proteinuria, hypoalbuminemia, hypercholesterolemia and peripheral oedema. This is due to a hypercoagulable state.

A 24-year-old South Asian woman presented with acute onset of left-sided flank pain with microscopic haematuria. She had a KUB X-ray performed.

She has a history of recurrent urinary tract infections since childhood and in the past was investigated and treated by a Urology Specialist. Her maternal first cousin is on peritoneal dialysis for chronic kidney disease.

Her KUB X-ray is shown below:

Investigations:

Creatinine	96 µmol/l
Ca^{2+}	2.48 mmol/l
PO_4^-	1.02 mmol/l
Albumin	40 g/l
Urine protein	0.5 g / 24 h
Creatinine clearance	68 ml/minute
24-h urine calcium	10 mmol (< 7.5 mmol)
24-h urine oxalate	1.4 mmol (< 0.36 mmol)
24-h urine urate	3.2 mmol (< 4.5 mmol)

What is the most likely diagnosis?

Investigations:

Creatinine	96 µmol/l
Ca^{2+}	2.48 mmol/l
PO_4^-	1.02 mmol/l
Albumin	40 g/l
Urine protein	0.5 g / 24 h
Creatinine clearance	68 ml/minute
24-h urine calcium	10 mmol (< 7.5 mmol)
24-h urine oxalate	1.4 mmol (< 0.36 mmol)
24-h urine urate	3.2 mmol (< 4.5 mmol)

What is the most likely diagnosis?

A Primary hyperoxaluria

B Primary hyperparathyroidism

C Secondary hyperparathyroidism

D Nephrogenic diabetes insipidus

E Surreptitious antacid ingestion

Submit

Investigations:

Creatinine	96 µmol/l
Ca^{2+}	2.48 mmol/l
PO_4^-	1.02 mmol/l
Albumin	40 g/l
Urine protein	0.5 g / 24 h
Creatinine clearance	68 ml/minute
24-h urine calcium	10 mmol (< 7.5 mmol)
24-h urine oxalate	1.4 mmol (< 0.36 mmol)
24-h urine urate	3.2 mmol (< 4.5 mmol)

What is the most likely diagnosis?

Your answer was correct

A Primary hyperoxaluria

B Primary hyperparathyroidism

C Secondary hyperparathyroidism

D Nephrogenic diabetes insipidus

E Surreptitious antacid ingestion

Explanation

A Primary hyperoxaluria

1:59
On 594-042-7551 Leave
MyPastest
https://mypastest.pastest.com

E Surreptitious antacid ingestion

Explanation

A Primary hyperoxaluria

Elevated urinary oxalate levels may be due to increased dietary intake, malabsorption or an inherited enzyme deficiency that leads to excessive metabolism of oxalate (primary hyperoxaluria). There are three types: types I and III are due to an enzyme defect in the liver glyoxalatepathway and in type II there is failure of reduction of glyoxalate to glycolate. Type I is the commonest and results in widespread calcium oxalate deposition throughout the body.

Treatment of primary hyperoxaluria is aimed at increasing urinary pH to make calcium oxalate more soluble. This is by administering supplemental citrate and magnesium. Renal insufficiency is common and patients require a combined liver and kidney transplant in type I disease.

B Primary hyperparathyroidism

Her normal serum calcium and phosphate levels are not consistent with hyperparathyroidism.

C Secondary hyperparathyroidism

Her normal serum calcium and phosphate levels are not consistent with hyperparathyroidism.

D Nephrogenic diabetes insipidus

Audio Video Share Participants More

2:00
On
594-042-7551
Leave

A 28-year-old man with Alport's syndrome received a pre-emptive living related renal transplant from his mother. He has excellent primary graft function and the baseline Creatinine was 102 µmol/l. Three months later, he presented with a 1-week history of decreased urine output with a raised creatinine of 188 µmol/l.

The biopsy did not show evidence of acute rejection. Urine microscopy showed dysmorphic red blood cells. He became progressively oligo-anuric and became dialysis dependent.

What is the most likely diagnosis?

A	Anti-glomerular basement membrane disease
B	Aspergillus pneumonia
C	Post-transplant lymphoproliferative disorder
D	Mycoplasma pneumonia
E	Granulomatosis with polyangiitis

70061

Submit

Audio
Video
Share
Participants
More

2:01
On
594-042-7551
Leave

A 28-year-old man with Alport's syndrome received a pre-emptive living related renal transplant from his mother. He has excellent primary graft function and the baseline Creatinine was 102 µmol/l. Three months later, he presented with a 1-week history of decreased urine output with a raised creatinine of 188 µmol/l.

The biopsy did not show evidence of acute rejection. Urine microscopy showed dysmorphic red blood cells. He became progressively oligo-anuric and became dialysis dependent.

What is the most likely diagnosis?

Your answer was correct

A	Anti-glomerular basement membrane disease
B	Aspergillus pneumonia
C	Post-transplant lymphoproliferative disorder
D	Mycoplasma pneumonia
E	Granulomatosis with polyangiitis

Explanation

A	Anti-glomerular basement membrane disease

Alport's is an inherited disorder resulting in microscopic haematuria, progressive nephritis with renal impairment, sensorineural deafness and ocular abnormalities. It is due to mutations of tissue-specific type IV collagen chains

Audio
Video
Share
Participants
More

2:02
On
594-042-7551
Leave

Explanation

A	Anti-glomerular basement membrane disease

Alport's is an inherited disorder resulting in microscopic haematuria, progressive nephritis with renal impairment, sensorineural deafness and ocular abnormalities. It is due to mutations of tissue-specific type IV collagen chains, leading to formation of autoantibodies similar to those on Goodpasture's syndrome. Therefore, a minority of Alport's patients with a renal transplant develop a rapidly progressive glomerulonephritis indistinguishable from Goodpasture's syndrome but without pulmonary haemorrhage. Treatment is similar to that of de novo anti-GBM disease but treatment efficacy is limited.

B	Aspergillus pneumonia

Opportunistic infections are common in transplant recipients, especially with over-immunosuppression, but would not explain the graft loss. Other common infections in transplant patients include cytomegalovirus, varicella zoster virus and fungal diseases.

C	Post-transplant lymphoproliferative disorder

Post-transplant lymphoproliferative disorder is an uncommon but serious manifestation of immunosuppression. The early onset of disease in this patient with likely minimal immunosuppression from a live donor transplant makes this answer incorrect. The majority of PTLD are B-cell clonality associated with Epstein-Barr virus. Treatment is often by a reduction of the immunosuppression and chemotherapy. Graft loss is common.

Audio
Video
Share
Participants
More

2:02
On 594-042-7551 Leave

Opportunistic infections are common in transplant recipients, especially with over-immunosuppression, but would not explain the graft loss. Other common infections in transplant patients include cytomegalovirus, varicella zoster virus and fungal diseases.

C Post-transplant lymphoproliferative disorder

Post-transplant lymphoproliferative disorder is an uncommon but serious manifestation of immunosuppression. The early onset of disease in this patient with likely minimal immunosuppression from a live donor transplant makes this answer incorrect. The majority of PTLD are B-cell clonality associated with Epstein-Barr virus. Treatment is often by a reduction of the immunosuppression and chemotherapy. Graft loss is common.

D Mycoplasma pneumonia

Opportunistic infections are common in transplant recipients, especially with over-immunosuppression, but would not explain the graft loss.

E Granulomatosis with polyangiitis

The short duration of illness and known association of anti-GBM in patients with Alport's syndrome.

Rate this question:

Next Question

Audio Video Share Participants More

2:02

A 64-year-old man presents with a 2-month history of dysuria, urinary urgency and pelvic discomfort. He was investigated last year for proteinuria and haematuria picked up on urinalysis at the general practitioner's surgery, although no specific cause was found. He smokes ten cigarettes per day and has travelled extensively as a missionary in the Asian subcontinent working as a teacher.

Repeated urine cultures sent at this time showed no growth. He also reports weight loss over the last year of two stone.

Investigations:

Haemoglobin (Hb)	11.9 g/dl
White cell count (WCC)	9.2×10^9/l
Platelets	479×10^9/l
Mean corpuscular volume (MCV)	92 fl
Mean corpuscular haemoglobin content (MCHC)	32 g/dl
Na^+	139 mmol/l
K^+	3.8 mmol/l
Urea	6.9 mmol/l
Creatinine	101 μmol/l
Erythrocyte sedimentation rate (ESR)	73 mm/h
C-reactive protein	56 mg/l

Urinalysis:

Protein	1+

Rana Alnasser's screen

K^+	3.8 mmol/l
Urea	6.9 mmol/l
Creatinine	101 µmol/l
Erythrocyte sedimentation rate (ESR)	73 mm/h
C-reactive protein	56 mg/l

Urinalysis:

Protein	1+
Blood	1+
Leucoctyes	3+
Glucose	Negative

Two recent urine cultures have shown mixed growth on one and no growth on a second.

What is the most likely diagnosis?

A	Chronic/recurrent *E. coli* infection
B	Chronic prostatitis
C	Renal cell carcinoma
D	Renal tract tuberculosis
E	Squamous cell carcinoma of the bladder

A 64-year-old man presents with a 2-month history of dysuria, urinary urgency and pelvic discomfort. He was investigated last year for proteinuria and haematuria picked up on urinalysis at the general practitioner's surgery, although no specific cause was found. He smokes ten cigarettes per day and has travelled extensively as a missionary in the Asian subcontinent working as a teacher.

Repeated urine cultures sent at this time showed no growth. He also reports weight loss over the last year of two stone.

Investigations:

Haemoglobin (Hb)	11.9 g/dl
White cell count (WCC)	9.2×10^9/l
Platelets	479×10^9/l
Mean corpuscular volume (MCV)	92 fl
Mean corpuscular haemoglobin content (MCHC)	32 g/dl
Na^+	139 mmol/l
K^+	3.8 mmol/l
Urea	6.9 mmol/l
Creatinine	101 µmol/l
Erythrocyte sedimentation rate (ESR)	73 mm/h
C-reactive protein	56 mg/l

Urinalysis:

2:05
MyPastest
https://mypastest.pastest.com

Explanation

D Renal tract tuberculosis

This man has very long-standing urinalysis abnormalities with weight loss and symptoms of bladder irritation. In addition, he has evidence of an inflammatory response with a mild anaemia. These raise the suspicion of either malignant disease or severe chronic infective disease such as tuberculosis. The renal tract is a common site for tuberculous infection after the lungs, and is commonly involved in association with primary TB infection (albeit often without being detected clinically). It can be difficult to diagnose and requires repeated early morning urine cultures and occasionally more invasive steps such as urinary tract biopsy on cystoscopy.

E Squamous cell carcinoma of the bladder

Although squamous cell carcinoma of the bladder is a possibility, this would be more likely to be a transitional cell lesion.

A Chronic/recurrent *E. coli* infection

Occult bacterial infection is unlikely to be the cause in view of the repeated negative urinary cultures.

B Chronic prostatitis

Although prostatic symptoms are present, such as dysuria and urgency. Penile discharge may be present and we would expect the urinary growth to be positive for

E Squamous cell carcinoma of the bladder

Although squamous cell carcinoma of the bladder is a possibility, this would be more likely to be a transitional cell lesion.

A Chronic/recurrent *E. coli* infection

Occult bacterial infection is unlikely to be the cause in view of the repeated negative urinary cultures.

B Chronic prostatitis

Although prostatic symptoms are present, such as dysuria and urgency. Penile discharge may be present and we would expect the urinary growth to be positive for bacteria.

C Renal cell carcinoma

The symptoms of bladder irritation are unlikely to occur with renal cell carcinoma.

Rate this question:

Next Question

Previous Q... Tag Questi... Feedback End Session

© Pastest 2019

A 62-year-old man with a long history of type 2 diabetes and chronic kidney disease comes to the clinic complaining of tiredness. Current therapy includes Mixtard insulin, ramipril, amlodipine, atorvastatin and aspirin.

On examination, his blood pressure is 130/80 mmHg, he looks pale and his chest and abdominal examination is unremarkable.

Investigations:

Hb	9.7 g/dl
WCC	4.9×10^9 /l
PLT	201×10^9 /l
Na^+	141 mmol/l
K^+	5.1 mmol/l
Creatinine	210 µmol/l
Ferritin	260 µg/l

Which of the following is the most appropriate management for him?

A Commence oral ferrous sulphate

B Treat with EPO to a target Hb of 13.5g/dl

C Arrange IV iron replacement

D Treat with EPO to a target Hb of 11 g/dl

E No current intervention, but plan for review in three months

Explanation

D Treat with EPO to a target Hb of 11 g/dl

Further iron replacement will not improve his Hb levels further. A Cochrane meta-analysis suggested that treating to the higher Hb target of 13.5 g/dl may result in increased risk of hypertensive crises. European renal guidelines therefore recommend a lower target haemoglobin of 11 g/dl.

A Commence oral ferrous sulphate

This patient is iron replete. The recommendation from the UK Renal Association is for the ferritin to be >100mg/L and TSAT >20% (or <10% hypochromic red cells). Therefore, there is no need for further iron replacement.

B Treat with EPO to a target Hb of 13.5g/dl

As explained above, a Cochrane meta-analysis suggested that treating to the higher Hb target of 13.5 g/dl may result in increased risk of hypertensive crises. European renal guidelines therefore recommend a lower target haemoglobin of 11 g/dl.

C Arrange IV iron replacement

The recommendation from the UK Renal Association is for the ferritin to be >100 mg/l and TSAT >20% (or <10% hypochromic red cells). Therefore, this patient is iron replete and there is no need for additional iron replacement.

E No current intervention, but plan for review in three months

A 40-year-old man with life-long episodes of fever and acute severe abdominal and chest pain presents to outpatients. He has lived most of his life in Turkey and several members of his family have suffered with similar symptoms, often being admitted as emergencies to local hospitals. He has been taking high doses of painkillers and anti-inflammatory medications for many years to help with his symptoms.

On physical examination, his temperature is 38 °C, blood pressure is 130/80 mmHg and chest and abdominal examination is unremarkable.

He was last seen over a year ago and a comparison of his blood results from that attendance and this shows:

Results now:

Na^+	138 mmol/l
K^+	4.6 mmol/l
Urea	12.4 mmol/l
Creatinine	180 µmol/l

Results 14 months ago:

Na^+	142 mmol/l
K^+	3.8 mmol/l
Urea	8.3 mmol/l
Creatinine	109 µmol/l

The single most useful test to confirm the pathological basis of his renal dysfunction would be?

A Intravenous urogram (IVU)

examination is unremarkable.

He was last seen over a year ago and a comparison of his blood results from that attendance and this shows:

Results now:

Na^+	138 mmol/l
K^+	4.6 mmol/l
Urea	12.4 mmol/l
Creatinine	180 µmol/l

Results 14 months ago:

Na^+	142 mmol/l
K^+	3.8 mmol/l
Urea	8.3 mmol/l
Creatinine	109 µmol/l

The single most useful test to confirm the pathological basis of his renal dysfunction would be?

A Intravenous urogram (IVU)

B MEFV gene analysis for familial Mediterranean fever (FMF)

C Rectal biopsy

D Renal biopsy

E Serum amyloid P component (SAP scan)

E Serum amyloid P component (SAP scan)

Explanation

D Renal biopsy

This man is likely to have familial Mediterranean FEVER (FMF), an inherited condition resulting in repeated episodes of polyserositis mimicking acute abdominal surgical presentations such as acute appendicitis, and often leading to unnecessary surgical exploration until the diagnosis is made. It is relatively common in the Middle East, especially in Turkey, Syria, Lebanon, Israel and Egypt. It relates to abnormal triggering of the inflammatory response and can lead to AA-type amyloid deposition and therefore kidney disease. However, patients with this condition frequently take high doses of analgesics and anti-inflammatory drugs, which puts them at risk of analgesic nephropathy.

B MEFV gene analysis for familial Mediterranean fever (FMF)

Although gene testing might confirm the suspected diagnosis, it would not conclusively indicate the cause of the renal impairment.

A Intravenous urogram (IVU)

IVU might show characteristic 'cup and spill' calices suggesting possible analgesic nephropathy, but this would not be confirmatory.

C Rectal biopsy

Rectal biopsy followed by examination with polarised light

diagnosis, it would not conclusively indicate the cause of the renal impairment.

A Intravenous urogram (IVU)

IVU might show characteristic 'cup and spill' calices suggesting possible analgesic nephropathy, but this would not be confirmatory.

C Rectal biopsy

Rectal biopsy followed by examination with polarised light leading to 'apple-green' birefringence might confirm amyloidosis, but this may not indicate the cause for the renal impairment if not identified.

E Serum amyloid P component (SAP scan)

Serum amyloid P component (SAP) scan may likewise confirm the presence of amyloid, but a renal biopsy would be diagnostic for either analgesic- or amyloid-associated nephropathy.

Rate this question:

Next Question

© Pastest 2019

A 78-year-old woman was admitted to the Accident & Emergency Department with lethargy and lower limb swelling.

On examination, the ST2 noticed that her left leg was markedly more swollen, consistent with a deep vein thrombosis (DVT). Her blood pressure was 140/60 mmHg, chest and abdominal examination was unremarkable.

Investigations show:

Hb	11.0 g/dl
Urea	10.0 mmol/l
Creatinine	90 µmol/l
Sodium	135mmol/l
Potassium	4.5 mmol/l
Cholesterol	7.0 mmol/l
Albumin	25 g/l
Urinalysis	Blood none, protein +++
24-hour protein	>3 g
Renal biopsy	Evidence of membranous disease

What is the most direct cause of DVT in patients with marked proteinuria?

A Antithrombin deficiency

B Chronic inflammation

C Hypoalbuminaemia

D Hypercholesterolaemia

2:15
MyPastest
https://mypastest.pastest.com

Potassium	4.5 mmol/l
Cholesterol	7.0 mmol/l
Albumin	25 g/l
Urinalysis	Blood none, protein +++
24-hour protein	>3 g
Renal biopsy	Evidence of membranous disease

What is the most direct cause of DVT in patients with marked proteinuria?

A Antithrombin deficiency

B Chronic inflammation

C Hypoalbuminaemia

D Hypercholesterolaemia

E Volume depletion

70799

this is thought to be one risk factor in increased development of DVT in these patients. Antithrombin deficiency may also be inherited in autosomal dominant fashion and occur in association with trauma, major surgery or use of the oral contraceptive pill.

B Chronic inflammation

Although chronic inflammation may be associated with hypoalbuminaemia, this is not the mechanism for DVT. Studies have shown that chronic inflammation is a result of DVT rather than a cause of the DVT.

C Hypoalbuminaemia

Nephrotic syndrome is associated with loss of albumin however this is not the mechanism by which DVT is formed. It is loss of other factors such as antithrombin that causes the DVT. Low albumin may be found in other conditions such as liver failure or malnutrition.

D Hypercholesterolaemia

A high cholesterol is found in nephrotic syndrome because there is both an increased in synthesis and decreased clearance of lipoproteinemia. There is an increased level of total and low-density lipoprotein (LDL) cholesterol as the most characteristic abnormality. This does not relate to DVT in any way.

E Volume depletion

Although colloid osmotic pressure is low as a result of hypoalbuminaemia, it is less likely to be a cause of DVT than excretion of antithrombin III as a result of marked proteinuria.

A 38-year-old Asian woman presents with several weeks of increased urinary frequency and dysuria. She had already been treated with two courses of antibiotics from her general practitioner, which had not helped. She had been feeling unusually lethargic recently and had lost a small amount of weight, but had no other specific symptoms.

On examination, she was thin with a low grade fever of 37.6 °C. Her abdomen was soft with mild suprapubic tenderness but no palpable masses. The rest of the clinical examination was normal.

Investigation results are below:

Hb	10.2 g/dl
WCC	10.8×10^9/l
Platelets	390×10^9/l
Mean corpuscular volume (MCV)	82 fl
Erythrocyte sedimentation rate (ESR)	30mm/h
Na^+	138 mmol/l
Ca^{2+}	2.52 mmol/l
K^+	3.6 mmol/l
Urea	5.2 mmol/l
Creatinine	98 µmol/l
Urinalysis	Blood + protein +

Urine microscopy:

WCC	22/mm^3
Red blood count	3/mm^3
Few hyaline casts	
No organisms seen	

A 38-year-old Asian woman presents with several weeks of increased urinary frequency and dysuria. She had already been treated with two courses of antibiotics from her general practitioner, which had not helped. She had been feeling unusually lethargic recently and had lost a small amount of weight, but had no other specific symptoms.

On examination, she was thin with a low grade fever of 37.6 °C. Her abdomen was soft with mild suprapubic tenderness but no palpable masses. The rest of the clinical examination was normal.

Investigation results are below:

Hb	10.2 g/dl
WCC	10.8×10^9/l
Platelets	390×10^9/l
Mean corpuscular volume (MCV)	82 fl
Erythrocyte sedimentation rate (ESR)	30mm/h
Na^+	138 mmol/l
Ca^{2+}	2.52 mmol/l
K^+	3.6 mmol/l
Urea	5.2 mmol/l
Creatinine	98 µmol/l
Urinalysis	Blood + protein +

Urine microscopy:

WCC	22/mm^3
Red blood count	3/mm^3
Few hyaline casts	
No organisms seen	

K^+	3.6 mmol/l
Urea	5.2 mmol/l
Creatinine	98 µmol/l
Urinalysis	Blood + protein +

Urine microscopy:

WCC	22/mm^3
Red blood count	3/mm^3
Few hyaline casts	
No organisms seen	
Urine culture	No growth after 5 days

What is the next most appropriate investigation?

A Micturating cystourethrography

B Renal biopsy

C Plain abdominal radiograph

D Urine electrophoresis

E Urine for mycobacterial culture

Submit

E Urine for mycobacterial culture

This woman has a sterile pyuria which could be due to a partially treated bacterial urinary tract infection; however genitourinary tuberculosis has to be excluded, especially in the context of malaise and weight loss and the patient's ethnic origin. Genitourinary TB develops in approximately 5% of cases of pulmonary TB and is usually due to haematogenous spread to the renal cortex during the primary phase of infection. The cortical lesion may then ulcerate into the pelvis, ultimately involving the bladder, seminal vesicles and prostate. It tends to present between 20 and 40 years of age. Other clinical features include haematuria, urethral strictures, cold abscesses and chronic epididymo-orchitis. Kidney disease may occur due to extensive destruction of the kidneys or by obstruction secondary to fibrosis. The diagnosis can be made with intravenous urography, ultrasound or computed tomography (CT) scan, in combination with several early morning urine samples for mycobacterial culture, in order to demonstrate active infection. The treatment is the same as for pulmonary TB.

A Micturating cystourethrography

This investigation visualises the urinary tract from bladder to urethra as the patient urinates. It is used for diagnosis of vesicoureteral reflux (VUR) where there is reflux of urine from the bladder up the ureters back into the kidneys. Radiologists may grade the degree/staging of VUR from the micturating cystourethrography. This investigation would be normal in renal TB.

B Renal biopsy

Although renal TB may reveal interstitial nephritis and caseating granulomata in the renal biopsy, there are easier and non-invasive methods of diagnosing this from urine cultures and investigations described above. Renal biopsy

A 32-year-old man attends the clinic as an urgent referral from his GP, he has been suffering from a cough, fevers and increasing lethargy over the past few days, but most recently has begun to suffer from haemoptysis.

When he makes it to the clinic, he looks quite unwell, with a raised respiratory rate of 31/min. His BP is 155/82 mmHg and he has crackles at both lung bases on auscultation.

Investigations:

Hb	10.9 g/dl
WCC	12.1 × 109/l
PLT	185 × 109/l
Na^+	141 mmol/l
K^+	5.9 mmol/l
Creatinine	194 µmol/l
c-ANCA	Negative
ESR	74 mm/h
Chest X-ray	Patchy perihilar and basal infiltration
PFTS	Transfer factor increased

Which of the following tests would you do next?

A Anti-nuclear antibodies

B Anti-smooth muscle antibodies

C P-ANCA

D Anti-GBM antibodies

Rana Alnasser's screen

When he makes it to the clinic, he looks quite unwell, with a raised respiratory rate of 31/min. His BP is 155/82 mmHg and he has crackles at both lung bases on auscultation.

Investigations:

Hb	10.9 g/dl
WCC	12.1 × 109/l
PLT	185 × 109/l
Na^+	141 mmol/l
K^+	5.9 mmol/l
Creatinine	194 µmol/l
c-ANCA	Negative
ESR	74 mm/h
Chest X-ray	Patchy perihilar and basal infiltration
PFTS	Transfer factor increased

Which of the following tests would you do next?

A Anti-nuclear antibodies

B Anti-smooth muscle antibodies

C P-ANCA

D Anti-GBM antibodies

E Anti-Ro antibodies

D Anti-GBM antibodies

The presentation with worsening haemoptysis due to pulmonary haemorrhage, and acute kidney disease, is typical of Goodpasture syndrome.

A Anti-nuclear antibodies

The anti-nuclear antibodies would be negative in this case. This test is used to identify connective tissue diseases such as rheumatoid arthritis, systemic lupus erythematosus (SLE), polymyositis and scleroderma. It is an auto-antibody that binds to contents of the cell nucleus.

B Anti-smooth muscle antibodies

Anti-smooth muscle antibodies are antibodies that are formed against smooth muscle. They are directed against actin, troponin and tropomyosin. These antibodies are found in autoimmune hepatitis.

C P-ANCA

P-ANCA shows a perinuclear staining pattern and the most common p-ANCA target is myeloperoxidase, a neutrophil granule protein. P-ANCA is associated with ulcerative colitis, eosinophilic granulomatosis with polyangiitis, microscopic polyangiitis and focal necrotising and crescentic glomerulonephritis.

E Anti-Ro antibodies

Anti-Ro antibodies are associated with many autoimmune diseases such as SLE, neonatal lupus and primary biliary

A 40-year-old man is undergoing regular haemodialysis is receiving erythropoietin, but his Hb is still low. There is no evidence of active or past infection. Other than chronic kidney disease of unknown cause, he has no other past medical history.

He is on oral iron, which was started after a confirmed low ferritin.

Upon examination, his BMI is 28 kg/m^2, and chest and abdominal examination was unremarkable.

Investigations showed:

Na^+	138 mmol/l
K^+	4.8 mmol/l
Urea	15.0 mmol/l
Creatinine	530 µmol/l
CRP	20 mg/l
Hb	7 g/dl
WCC	11.4 × 10^9/l
PLT	560 × 10^9/l

What is the next step in his management?

A Check for antibodies against erythropoietin

B Give higher doses of iron tablets

C Give folic acid

D Give IV iron

Rana Alnasser's screen

kidney disease of unknown cause, he has no other past medical history.

He is on oral iron, which was started after a confirmed low ferritin.

Upon examination, his BMI is 28 kg/m^2, and chest and abdominal examination was unremarkable.

Investigations showed:

Na^+	138 mmol/l
K^+	4.8 mmol/l
Urea	15.0 mmol/l
Creatinine	530 µmol/l
CRP	20 mg/l
Hb	7 g/dl
WCC	11.4 × 10^9/l
PLT	560 × 10^9/l

What is the next step in his management?

A Check for antibodies against erythropoietin

B Give higher doses of iron tablets

C Give folic acid

D Give IV iron

E Transfuse

Rana Alnasser's screen

E Transfuse

Explanation

D Give IV iron

Iron given orally is poorly absorbed in patients with chronic kidney disease. The gold standard method of replacement recommended by renal physicians is IV. According to the UK Renal Association guidelines, in renal patients we would aim to achieve a ferritin of >100 mg/l and TSAT >20% (or <10% hypochromic red cells).

A Check for antibodies against erythropoietin

Antibodies to erythropoietin can occur but iron should be given IV to dialysis patients, as in this case. Antibodies are not routinely checked.

B Give higher doses of iron tablets

Iron is poorly absorbed orally in chronic kidney disease; therefore higher doses will only increase risk of side effects such as constipation, with little gain.

C Give folic acid

There is no evidence of folic acid deficiency in this case. This patient has an iron-deficiency anaemia.

E Transfuse

The first step is to give intravenous iron. Transfusion should only be given with caution in patients with renal disease because of risk of fluid overload and sensitisation with antibodies which may render the patient difficult for future renal transplant.

Rana Alnasser's screen

Antibodies to erythropoietin can occur but iron should be given IV to dialysis patients, as in this case. Antibodies are not routinely checked.

B Give higher doses of iron tablets

Iron is poorly absorbed orally in chronic kidney disease; therefore higher doses will only increase risk of side effects such as constipation, with little gain.

C Give folic acid

There is no evidence of folic acid deficiency in this case. This patient has an iron-deficiency anaemia.

E Transfuse

The first step is to give intravenous iron. Transfusion should only be given with caution in patients with renal disease because of risk of fluid overload and sensitisation with antibodies which may render the patient difficult for future renal transplant.

Rate this question:

© Pastest 2019

A 74-year-old woman is admitted by ambulance having been found by her daughter on her hall floor. It appears that she had been there for some hours. She has a past history of hypertension, which is treated with ramipril 10 mg daily, and a TIA for which she is treated with aspirin.

On examination in the Emergency Department, her blood pressure is 120/70 mmHg, with a pulse of 105/min; she is pyrexial (38.2 °C) and has evidence of right-sided pneumonia. There is a fractured left femoral neck in addition.

Investigations:

Hb	10.9 g.dl
WCC	13.1×10^9/l
PLT	235×10^9/l
Na^+	138 mmol/l
K^+	5.8 mmol/l
Creatinine	199 µmol/l
CK	3890 U/l (24-170)
Urine output 25ml over 2	No significant residual on catheterisation
Urine	Positive to blood on dipstick, but no cells seen on microscopy
Chest X-ray	Right-sided pneumonia
ECG	Lateral ST depression

Which of the following apart from pneumonia would best explain some of the other results seen here?

A Anterior myocardial infarction

WCC	13.1 × 10⁹/l
PLT	235 × 10^9/l
Na^+	138 mmol/l
K^+	5.8 mmol/l
Creatinine	199 µmol/l
CK	3890 U/l (24-170)
Urine output 25ml over 2	No significant residual on catheterisation
Urine	Positive to blood on dipstick, but no cells seen on microscopy
Chest X-ray	Right-sided pneumonia
ECG	Lateral ST depression

Which of the following apart from pneumonia would best explain some of the other results seen here?

A Anterior myocardial infarction

B Urinary tract infection

C Rhabdomyolysis

D Fat embolus

E Subendocardial myocardial infarction

18655

Submit

C Rhabdomyolysis

This patient has a raised CK and urine testing, which is suggestive of myoglobinuria (positive dipstick but no cells seen). It is likely she has been lying on the floor for some time, which has precipitated muscle breakdown and the picture consistent with rhabdomyolysis seen here. Her creatinine of 199 μmol/l is likely to represent a degree of acute on chronic renal impairment. Vigorous rehydration with isotonic crystalloid is the mainstay of therapy for rhabdomyolysis. Severe or refractory cases may require haemodialysis.

A Anterior myocardial infarction

An anterior myocardial infarction would result from an occlusion of the left anterior descending artery. This carries the worst prognosis of all infarct locations, mainly because it affects a large area. The ECG finding would be ST segment elevation with Q wave formation in the precordial leads (V1-6) and possible the high lateral leads (I and aVL). There would be reciprocal ST depression in the inferior leads (III and aVF). In this scenario there is lateral ST depression, which is not consistent with anterior myocardial infarction.

B Urinary tract infection

Although urinary tract infection may result in blood and protein in the urine with fever, this does not produce a raised creatinine kinase which, in this case, is the key to diagnosis.

D Fat embolus

A fat embolism is a clot that consists of fatty material. This may result from physical trauma such as a fracture of a long bone, soft tissue trauma or burns. If fat embolism is severe it may cause respiratory failure or myocardial

D Fat embolus

A fat embolism is a clot that consists of fatty material. This may result from physical trauma such as a fracture of a long bone, soft tissue trauma or burns. If fat embolism is severe it may cause respiratory failure or myocardial infarction. There may be purpura that appears on the upper anterior body including chest, neck and upper arm – this is pathognomonic sign of fat embolism syndrome. This is not present in this case.

E Subendocardial myocardial infarction

Subendocardial myocardial infarction involves infarction of the subendocardial wall of the left ventricle, ventricular septum or papillary muscles. In established infarction you would expect to see Q waves. In this case there is subendocardial ischaemia because of myocardial strain from anaemia and pneumonia. Myocardial strain occurs with inadequate oxygenation to the heart. This is evidenced by the lateral ST depression.

Rate this question:

Next Question

Previous Q... Tag Questi... Feedback End Session

Blog About Pastest Contact Us Help

© Pastest 2019

A 28-year-old woman presents to the clinic with microscopic haematuria and proteinuria.

Other past history of note is that she has suffered progressive bilateral hearing loss which was first noticed during a school medical in her early teenage years. She has also noticed that her vision has deteriorated over the past few years and she has gone through three pairs of glasses in the past five years.

On examination, she is a slim looking woman with a BMI of 21 and blood pressure of 155/90 mmHg.

Investigations reveal:

K^+	5.4 mmol/l
Na^+	138 mmol/l
Creatinine	195 µmol/l
Urea	7.1 mmol/l
Renal ultrasound	Bilateral small kidneys

Which of the following diagnoses fits best with this clinical picture?

A Alport's syndrome

B Hypertensive renal disease

C IgA nephropathy

D Reflux nephropathy

E Wegener's granulomatosis

9:28
Pastest+ 594-042-7551 Leave

Explanation

A Alport's syndrome

Alport's syndrome accounts for around 0.6% of patients presenting in Europe with end-stage renal disease. Around 90% are said to develop kidney disease by the age of 40 years. Two forms of the syndrome exist, one with an X-linked inheritance pattern (XLAS) and one with an autosomal recessive inheritance pattern (ARAS). XLAS tends to be less severe in females, whereas ARAS is equally severe in males and females. It occurs due to a gene mutation coding for type IV collagen and a number of different mutations have been characterised. Specifically, mutations in the α 3, 4 and 5 chains of type IV collagen are the ones responsible for Alport's as these code for glomerular basement membrane. Patients present with haematuria and proteinuria. Ocular manifestations include anterior lenticonus, dot and fleck retinopathy and corneal dystrophy. Leiomyomatosis has also been observed in some families with Alport's. Skin or renal biopsy aid in the diagnosis of Alport's, with monoclonal antibody staining for potentially missing type IV chains. ACE inhibitors may be of some value in controlling blood pressure and proteinuria in this condition and some studies have suggested a potential role for ciclosporin. At present the only option is renal transplantation for those with chronic kidney disease.

B Hypertensive renal disease

We would expect a history of long-standing hypertension with cardiovascular risk factors such as myocardial infarction or stroke. The young age would make hypertensive renal disease less likely. Furthermore, hypertensive nephropathy is not associated with hearing impairment.

Audio Video Share Participants More

in the developed world. It is frequently detected by incident on a dipstick of urine. There is no associated with hearing loss.

D	Reflux nephropathy

Reflux nephropathy would present with a history of urinary tract infection or renal stones as a child and is frequently a result of vesicoureteric reflux in childhood. As an adult, there would be a progressive decline in renal function. There may be white cells in the urine. Hearing loss is not associated with reflux.

E	Wegener's granulomatosis

Although Wegener's granulomatosis may be associated with hearing problems, this is normally a conductive hearing loss with nasal crusting. There may also be pulmonary haemorrhage and vasculitic rash. The bilateral small kidneys suggest a chronic kidney problem which would be unusual for a first presentation of Wegener's granulomatosis.

© Pastest 2019

9:29

A 58-year-old man comes to the Oncology Clinic some 6 weeks after right nephrectomy for metastatic renal carcinoma that had resulted in a pathological fracture of the right humerus. He has recovered well from the surgery and is keen to discuss next steps.

On examination, his BP is 138/82 mmHg; pulse is 80 bpm and regular. His BMI is 23 and he has a nephrectomy scar on examination of the abdomen.

Investigations:

Hb	10.9 g/dl
WCC	9.1×10^9/l
PLT	181×10^9/l
ESR	64 mm/1st hour
Na^+	137 mmol/l
K^+	4.5 mmol/l
Creatinine	162 μmol/l
Glucose	5.6 mmol/l
Bone scan	Widespread hotspots consistent with metastatic disease

Treatment with recombinant IL-2 is planned.

Which of the following other therapies can be added?

A Bevacizumab

B Everolimus

C Pazopanib

Rana Alnasser's screen

and is keen to discuss next steps.

On examination, his BP is 138/82 mmHg; pulse is 80 bpm and regular. His BMI is 23 and he has a nephrectomy scar on examination of the abdomen.

Investigations:

Hb	10.9 g/dl
WCC	9.1×10^9/l
PLT	181×10^9/l
ESR	64 mm/1st hour
Na^+	137 mmol/l
K^+	4.5 mmol/l
Creatinine	162 µmol/l
Glucose	5.6 mmol/l
Bone scan	Widespread hotspots consistent with metastatic disease

Treatment with recombinant IL-2 is planned.

Which of the following other therapies can be added?

A Bevacizumab

B Everolimus

C Pazopanib

D Sorafenib

E Sunitinib

Na^+	137 mmol/l
K^+	4.5 mmol/l
Creatinine	162 µmol/l
Glucose	5.6 mmol/l
Bone scan	Widespread hotspots consistent with metastatic disease

Treatment with recombinant IL-2 is planned.

Which of the following other therapies can be added?

Your answer was correct

A Bevacizumab

B Everolimus

C Pazopanib

D Sorafenib

E Sunitinib

Explanation

E Sunitinib

Sunitinib is a tyrosine kinase inhibitor recommended for patients with metastatic renal carcinoma with a good functional status who are suitable for cytokine therapy. The other choices are no longer recommended by NICE as therapies for metastatic renal cancer.

Explanation

E Sunitinib

Sunitinib is a tyrosine kinase inhibitor recommended for patients with metastatic renal carcinoma with a good functional status who are suitable for cytokine therapy. The other choices are no longer recommended by NICE as therapies for metastatic renal cancer.

Prognosis is closely related to the presence of metastases; in patients with distant metastases, 5-year survival is only 10%, versus 90% for those with early kidney cancer.

A Bevacizumab

Bevacizumab is no longer recommended by NICE as therapy for metastatic renal cancer. Bevacizumab may be used for treatment for colon cancer, lung cancer and glioblastoma. It may also be used in age-related macular degeneration by injection into the eye. Common side-effects include headache, hypertension and skin rash.

B Everolimus

Everolimus is no longer recommended by NICE as therapy for metastatic renal cancer. Everolimus is a derivative of sirolimus and works in a similar manner with inhibition of mammalian target of rapamycin (mTOR). It may be used as an immunosuppressant to prevent organ transplant rejection.

C Pazopanib

In those who are not suitable for cytokine therapy, pazopanib is an alternative option. Pazopanib is a protein kinase inhibitor. It works by interfering with the signalling pathway that affects cancer cell growth. This drug is approved by NICE[2]. However, it is the incorrect answer in

Bevacizumab is no longer recommended by NICE as therapy for metastatic renal cancer. Bevacizumab may be used for treatment for colon cancer, lung cancer and glioblastoma. It may also be used in age-related macular degeneration by injection into the eye. Common side-effects include headache, hypertension and skin rash.

B Everolimus

Everolimus is no longer recommended by NICE as therapy for metastatic renal cancer. Everolimus is a derivative of sirolimus and works in a similar manner with inhibition of mammalian target of rapamycin (mTOR). It may be used as an immunosuppressant to prevent organ transplant rejection.

C Pazopanib

In those who are not suitable for cytokine therapy, pazopanib is an alternative option. Pazopanib is a protein kinase inhibitor. It works by interfering with the signalling pathway that affects cancer cell growth. This drug is approved by NICE[2]. However, it is the incorrect answer in this scenario because it is only funded by the NHS in the UK if patients have had no previous cytokine therapy. In this case, the agent is being added to IL2, so it is the incorrect answer. Currently, sunitinib is recommended by NICE as first-line treatment of advanced renal cell carcinoma, not pazopanib.

D Sorafenib

Sorafenib is no longer recommended by NICE as therapy for metastatic renal cancer. Sorafenib is an inhibitor of tyrosine protein kinases, such as VEGFR. The treatment induces autophagy which may suppress tumour growth. However, autophagy can also cause drug resistance.

A 40-year-old man is referred by his GP to Accident and Emergency with severe acute left-sided flank pain. This is the first time he has had such severe sudden pain. He has no past medical history of cardiovascular or kidney disease.

On examination, his BMI is 30 kg/m^2 and pulse 78 bpm and regular. His jugular venous pressure is not raised, heart sounds are normal and his chest is clear. His liver is not palpable but he has a mass in the left flank. The mass is bimanually palpable and you can get above it.

Investigations are as follows:

Na^+	140 mmol/l
K^+	4.2 mmol/l
Urea	10.2 mmol/l
Creatinine	203 µmol/l
Hb	15.0 g/dl
WCC	5.1×10^9/l
MCV	81 fl
PLT	243×10^9 /l
ESR	8 mm/h
Urine dipstick	blood +++, protein +

What other disorder is this patient likely to suffer from?

A Aortic valve prolapse

B Berry aneurysms in 50–75%

C Hypertension

9:37
MyPastest
https://mypastest.pastest.com

Na^+	140 mmol/l
K^+	4.2 mmol/l
Urea	10.2 mmol/l
Creatinine	203 µmol/l
Hb	15.0 g/dl
WCC	5.1×10^9/l
MCV	81 fl
PLT	243×10^9 /l
ESR	8 mm/h
Urine dipstick	blood +++, protein +

What other disorder is this patient likely to suffer from?

A Aortic valve prolapse

B Berry aneurysms in 50–75%

C Hypertension

D Gallstones

E Diabetes mellitus

Submit

E Diabetes mellitus

Explanation

C Hypertension

The most likely diagnosis in this patient is adult polycystic kidney disease. It is a common autosomal-dominant disease with a gene defect on the short arm of chromosome 16 and usually presents in the fourth and fifth decades. In this patient, it was most likely complicated by haemorrhage into a cyst, and hence the pain. It usually presents with haematuria, hypertension, loin pain, urinary tract infection and kidney disease. It is associated with hepatic, pancreatic and ovarian cysts, and subarachnoid haemorrhage, renal calculi, mitral valve prolapse, polycythaemia and anaemia of chronic kidney disease.

A Aortic valve prolapse

The common valvular condition in autosomal dominant polycystic kidney disease (ADPKD) is mitral valve prolapse rather than aortic valve.

B Berry aneurysms in 50–75%

The incidence of berry aneurysms in ADPKD is a lot lower, in the region of 20–25%.

D Gallstones

With respect to a diagnosis of gallstones, that seems unlikely here: there is no association between APKD and gallstones, and no symptoms to suggest that as the underlying acute problem.

A 38-year-old man with a 12-year history of human immunodeficiency virus (HIV), with a good response to therapy, was admitted with a 12-day history of weakness, nausea, dysuria, myalgia and decreased urine output. His last CD4 lymphocyte count was 368 × 10^6/l (normal range 500–900).

The current medications included didanosine, stavudine, atorvastatin, trimethoprim–sulfamethoxazole, and he had been commenced on indinavir.

On examination, he was afebrile, pulse 100/min and regular, BP 176/99 mmHg, the jugular venous pressure (JVP) was not elevated; the chest and abdominal examinations were normal.

Investigations:

Hb	13.5 g/dl
WCC	6.7 × 10^9/l
PLT	200 × 10^9/l
Na^+	135 mmol/l
K^+	5.2 mmol/l
Cl^-	102 mmol/l
Bicarbonate	16 mmol/l
Urea	29.2 mmol/l
Creatinine	765 μmol/l
Bone profile	Normal
Creatine kinase	100 U/l
Antineutrophil cytoplasmic antibodies (ANCA)	Negative
Anti-GBM	Negative

Cl	102 mmol/l
Bicarbonate	16 mmol/l
Urea	29.2 mmol/l
Creatinine	765 µmol/l
Bone profile	Normal
Creatine kinase	100 U/l
Antineutrophil cytoplasmic antibodies (ANCA)	Negative
Anti-GBM	Negative
Hep B/Hep C	Negative
Antistreptolysin O titre (ASOT)	Negative

Cultures of blood/urine/sputum were negative.

Which one of the following medications is the most likely cause of his acute kidney disease?

A Atorvastatin

B Didanosine

C Indinavir

D Stavudine

E Trimethoprim–sulfamethoxazole

70057

Submit

E Trimethoprim-sulfamethoxazole

Explanation

C Indinavir

Drugs used in patients with HIV may cause acute kidney injury (AKI). This occurs most commonly with protease inhibitors, in particular indinavir, by causing intratubular crystal obstruction. It has also been reported with ritonavir.

A Atorvastatin

Atorvastatin may cause myositis but in this patient the serum creatine kinase is normal. In general, atorvastatin will not cause acute kidney disease.

B Didanosine

Didanosine is a nucleoside analogue (NRTI), the most common side-effect being peripheral neuropathy. There is no lactate provided to suggest lactic acidosis as the cause of acidaemia.

D Stavudine

Stavudine is a nucleoside analogue (NRTI), the most common side-effect being peripheral neuropathy. There is no lactate provided to suggest lactic acidosis as the cause of acidaemia.

E Trimethoprim-sulfamethoxazole

9:42

A 44-year-old woman presented with haematuria and loin pain.

Her computed tomography (CT) scan is shown below:

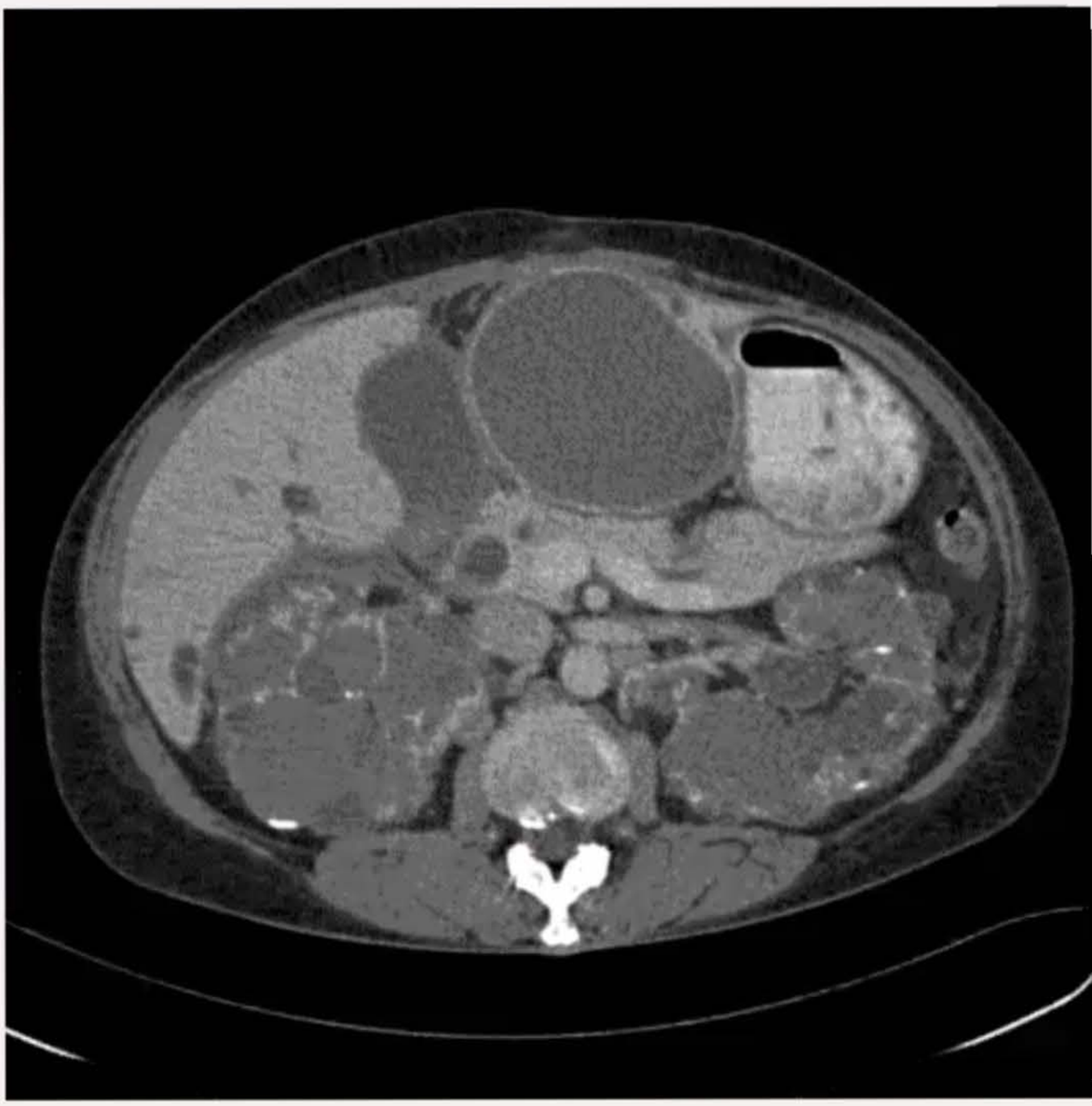

What is the diagnosis?

A Autosomal dominant polycystic kidney disease

B Medullary sponge kidney

C Hydatid disease

D Nephronophthisis

E Von Hippel-Lindau syndrome

Audio Video Share Participants More

9:43
Pastest+
594-042-7551
Leave

What is the diagnosis?

Your answer was correct

A	Autosomal dominant polycystic kidney disease
B	Medullary sponge kidney
C	Hydatid disease
D	Nephronophthisis
E	von Hippel-Lindau syndrome

Explanation

Audio
Video
Share
Participants
More

Explanation

A Autosomal dominant polycystic kidney disease

The CT scan shows the classic appearance of polycystic kidneys with multiple hepatic cysts (these occur in 30–70% of patients). Autosomal dominant polycystic kidney diseas is an autosomal dominant condition and is a common cause of chronic kidney disease. It can present at any age from the second decade onwards. Presenting features include loin pain, haematuria, hypertension and abdominal mass. Associated features include intracranial aneurysms (8%) and subarachnoid haemorrhage, mitral valve prolapse and renal calculi. Cysts may become infected or haemorrhaged. Children and siblings of patients with this condition should be screened with ultrasound after 20 years of age.

B Medullary sponge kidney

Medullary sponge kidney is a benign, common condition where there is diffuse medullary cyst formation. It is a developmental disorder that can be detected on imaging.

C Hydatid disease

Hydatid disease is caused by an infection with the tapeworm *Echinococcus*. The kidneys are the most common site of infection. Treatment is frequently with surgery.

D Nephronophthisis

Nephronophthisis is a renal disorder that affects children. Unlike medullary sponge kidney, it is a genetic disorder

A 26-year-old man is referred to you by his general practitioner (GP) with persistent microscopic haematuria. He has recently been diagnosed with coeliac disease and commenced on a gluten-free diet. The dermatologists have also started oral dapsone. The patient otherwise has remained asymptomatic.

Initial investigations show:

Blood pressure	115/65 mmHg
Haemoglobin	13.5 g/dl
White cell count	8×10^9/l
Platelets	320×10^9/l
Immunoglobulin G (IgG)	7.3 g/l (6.0–13.0)
IgA	2.8 g/l (0.8–3.0)
IgM	0.6 g/l (0.4–2.5)
Sodium	143 mmol/l
Potassium	3.9 mmol/l
Urea	8.5 mmol/l
Creatinine	115 μmol/l
Bilirubin	30 μmol/l
Aspartate aminotransferase	10 u/l
Alkaline phosphatase	60 u/l
Albumin	43 g/l

9:46

Alkaline phosphatase	60 u/l
Albumin	43 g/l
24-h urinary protein collection	1.8 g/24 h (< 0.2 g)
Urine microscopy	Red cell casts present
Renal biopsy light microscopy	Mesangial proliferation

What is the most likely diagnosis?

A Amyloidosis

B Cryoglobulinaemia

C Dapsone side-effect

D Immunoglobulin (IgA) nephropathy

E Renal cell carcinoma

Submit

Rana Alnasser's screen

Cryoglobulinaemia usually presents with more cutaneous and articular manifestations. It is associated with haematological malignancies and connective tissue diseases.

C Dapsone side-effect

Dapsone causes haemolytic anaemia. Side-effects of dapsone can present with an allergic reaction with difficulty in breathing, angio-oedema and swelling of the lips. There may be a bluish skin colour, muscle weakness, numbness or tingling and abdominal pain.

E Renal cell carcinoma

Renal cell carcinoma arises from the tubular epithelium. Typically, renal cell carcinoma may present with painless haematuria, with a palpable abdominal mass

For further reference:

Lai K N et al. 2015. The treatment of IgA nephropathy. Kidney Disease (Basel), 1, 19–26.

Rate this question:

Next Question

Previous Q... Tag Questi... Feedback End Session

Blog About Pastest Contact Us Help

Rana Alnasser's screen

9:47

A 52-year-old man with diabetes presents with weight loss fevers and dull, persistent left loin pain. The general practitioner has been treating him for relapsing urinary tract infections with oral antibiotics.

On examination, his temperature is 37.9 °C, blood pressure is 130/80 mmHg and chest and abdominal examination is unremarkable.

Investigations:

Haemoglobin	14.3 g/dl
White cell count	18×10^9/l
Platelets	510×10^9/l
Na^+	145 mmol/l
K^+	4.2 mmol/l
Urea	12 mmol/l
Creatinine	120 µmol/l
ESR	67 mm/h (0-20)

Computerised tomography scan shows a heterogeneous non-enhancing mass on the left kidney, which is hydronephrotic. The right kidney is normal.

Renal biopsy shows lipid-laden macrophages with lymphocytes and polymorphonuclear leukocytes.

What is the definitive treatment in this patient?

A Antituberculous treatment

B Intravenous antibiotics

C Left nephrectomy

Rana Alnasser's screen

unremarkable.

Investigations:

Haemoglobin	14.3 g/dl
White cell count	18×10^9/l
Platelets	510×10^9/l
Na^+	145 mmol/l
K^+	4.2 mmol/l
Urea	12 mmol/l
Creatinine	120 µmol/l
ESR	67 mm/h (0-20)

Computerised tomography scan shows a heterogeneous non-enhancing mass on the left kidney, which is hydronephrotic. The right kidney is normal.

Renal biopsy shows lipid-laden macrophages with lymphocytes and polymorphonuclear leukocytes.

What is the definitive treatment in this patient?

A Antituberculous treatment

B Intravenous antibiotics

C Left nephrectomy

D Lithotripsy

E Radiotherapy

Haemoglobin	14.3 g/dl
White cell count	18×10^9/l
Platelets	510×10^9/l
Na^+	145 mmol/l
K^+	4.2 mmol/l
Urea	12 mmol/l
Creatinine	120 µmol/l
ESR	67 mm/h (0-20)

Computerised tomography scan shows a heterogeneous non-enhancing mass on the left kidney, which is hydronephrotic. The right kidney is normal.

Renal biopsy shows lipid-laden macrophages with lymphocytes and polymorphonuclear leukocytes.

What is the definitive treatment in this patient?

Your answer was incorrect

A Antituberculous treatment

B Intravenous antibiotics

C Left nephrectomy

D Lithotripsy

E Radiotherapy

Explanation

C Left nephrectomy

Xanthogranulomatous pyelonephritis can be difficult to distinguish from a renal cell carcinoma. It typically presents with symptoms of fever, weight loss and loin pain. It is more common in diabetics, the immunocompromised and patients with obstructive uropathy. The most common organism is *Proteus mirabilis*. Histology combined with clinical and radiological evidence confirms the diagnosis. The definitive treatment is nephrectomy, as medical therapy is insufficient.

A Antituberculous treatment

This man does not have renal tuberculosis. Tuberculosis of the kidneys would present with sterile pyuria. Diagnosis may be obtained with three early morning urine cultures.

B Intravenous antibiotics

It is difficult for intravenous antibiotics alone to treat xanthogranulomatous pyelonephritis completely.

D Lithotripsy

Lithotripsy is an ultrasound treatment for renal stones. It is not utilised in this case.

E Radiotherapy

Radiotherapy will not help in the treatment for this mass. As it is an infection, it is important to include antibiotics and nephrectomy for treatment.

Radiopaedia

Xanthogranulomatous pyelonephritis | Radiology Case | Radiopaedia.org

Xanthogranulomatous pyelonephritis

Images may be subject to copyright. Learn more

RELATED IMAGES

View Image

Acute Pyelonephritis: Right kidney is marked...

pinterest.com

Acute pyelonephritis. Contrast-enhanced CT

Discover Updates Search Recent More

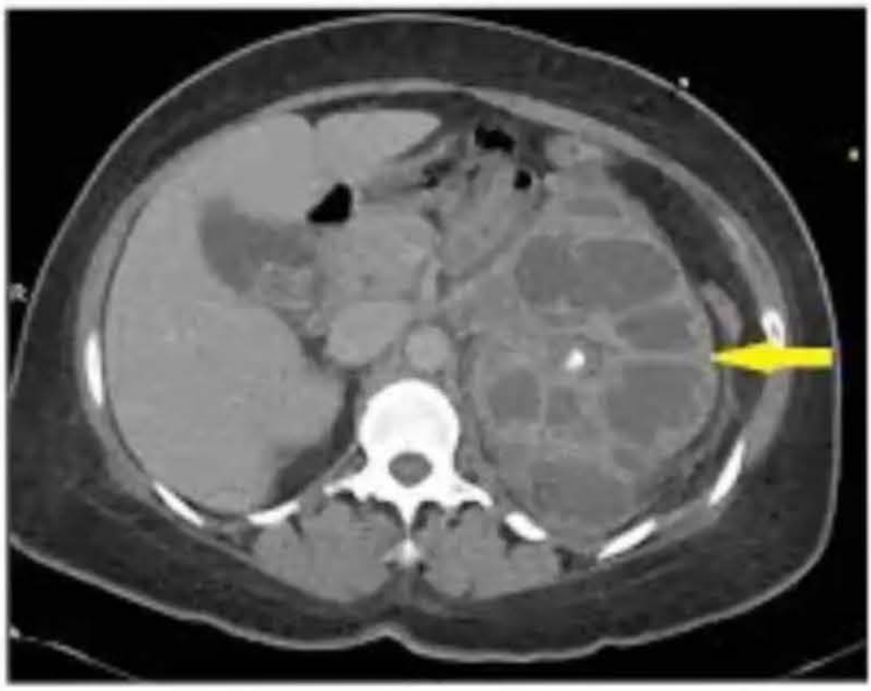

Semantic Scholar

Annotation Stop Shar

Figure 1 from Xanthogranulomatous pyelonephritis. - Semantic Scholar

Figure 1 (A) CT scan of the abdomen and pelvis showing a large left

Images may be subject to copyright. Learn more

RELATED IMAGES

My Pathologist on Twitter: "#grossognosi...
twitter.com

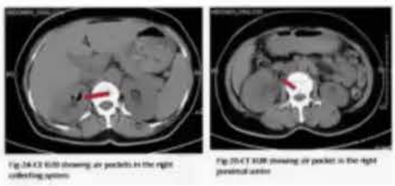

A-CT KUB showing bilateral emphysematous...
researchgate.net

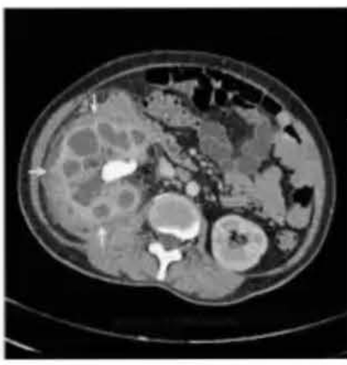

Imagewk14(16-04-2012)
bimjonline.com

Discover Updates Search Recent More

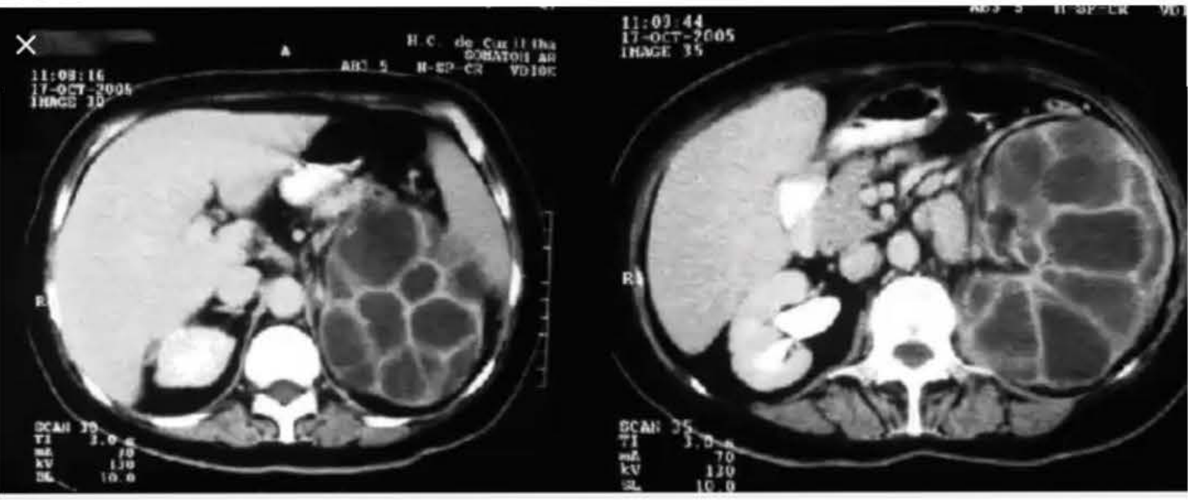

ResearchGate

CT scan of xanthogranulomatous pyelonephritis. There is diffuse ...

CT scan of xanthogranulomatous pyelonephritis. There is diffuse enlargement of the left kidney and the

Images may be subject to copyright. Learn more

RELATED IMAGES

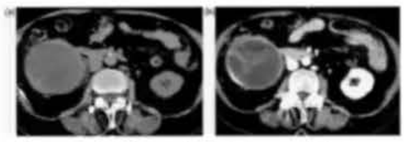

CT scan of abdomen (a) before and (b) after ...
researchgate.net

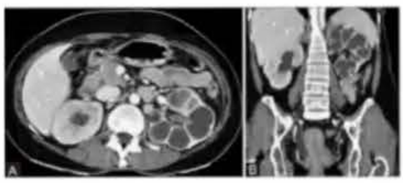

View Image
ijri.org

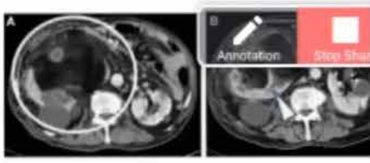

Massive Renal Replacement Lipomatosis W
sciencedirect.com

Xanthogranulomatous pyelonephritis causin...
bmj.com

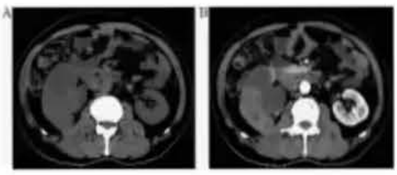

Primary kidney parenchyma squamous cell c...
spandidos-publications.com

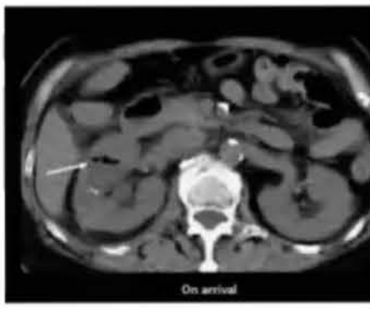

View Image
onlinejets.org

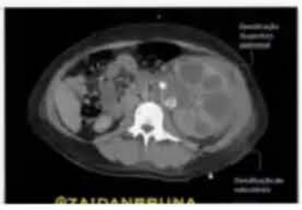

Sinal da pata de urso

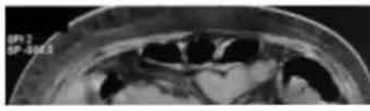

Discover Updates Search Recent More

clinical and radiological evidence confirms the diagnosis. The definitive treatment is nephrectomy, as medical therapy is insufficient.

A Antituberculous treatment

This man does not have renal tuberculosis. Tuberculosis of the kidneys would present with sterile pyuria. Diagnosis may be obtained with three early morning urine cultures.

B Intravenous antibiotics

It is difficult for intravenous antibiotics alone to treat xanthogranulomatous pyelonephritis completely.

D Lithotripsy

Lithotripsy is an ultrasound treatment for renal stones. It is not utilised in this case.

E Radiotherapy

Radiotherapy will not help in the treatment for this mass. As it is an infection, it is important to include antibiotics and nephrectomy for treatment.

Rana Alnasser's screen

9:52
594-042-7551
Leave

A 50-year-old retired bank manager attended a 'Well Man' Clinic. He has always enjoyed good health, but has recently developed a dry cough. He takes daily over-the-counter multivitamin tablets.

On examination, he is extremely well, with no abnormality detected.

Screening investigations reveal:

Creatinine (Cr)	80 μmol/l
Urea	5.0 mmol/l
Haemoglobin (Hb)	12.0 g/dl
Potassium (K^+)	4.0 mmol/l
Corrected calcium	2.82 mmol/l
White cell count (WCC)	9.0×10^9/l

A repeat uncuffed sample with simultaneous plasma parathyroid hormone (PTH) level reveals:

		Normal Values
Corrected calcium	2.86 mmol/l	
Parathyroid hormone (PTH)	5.4 pmol/l	0.9–5.4

Which of the following is the most likely diagnosis?

A Multiple myeloma

B Primary hyperparathyroidism

C Prolonged tourniquet application

Audio Video Share Participants More

Creatinine (Cr)	80 μmol/l
Urea	5.0 mmol/l
Haemoglobin (Hb)	12.0 g/dl
Potassium (K^+)	4.0 mmol/l
Corrected calcium	2.82 mmol/l
White cell count (WCC)	9.0×10^9/l

A repeat uncuffed sample with simultaneous plasma parathyroid hormone (PTH) level reveals:

		Normal Values
Corrected calcium	2.86 mmol/l	
Parathyroid hormone (PTH)	5.4 pmol/l	0.9–5.4

Which of the following is the most likely diagnosis?

A Multiple myeloma

B Primary hyperparathyroidism

C Prolonged tourniquet application

D Sarcoidosis

E Vitamin D excess

parathyroid hormone (PTH) level reveals:

		Normal Values
Corrected calcium	2.86 mmol/l	
Parathyroid hormone (PTH)	5.4 pmol/l	0.9–5.4

Which of the following is the most likely diagnosis?

Your answer was incorrect

A Multiple myeloma

B Primary hyperparathyroidism

C Prolonged tourniquet application

D Sarcoidosis

E Vitamin D excess

Explanation

B Primary hyperparathyroidism

Plasma PTH is the best single test for differentiating between hypercalcaemia due to parathyroid overactivity and that due to non-parathyroid causes. Primary hyperparathyroidism can be associated with a plasma PTH level within the normal range. The normal response to hypercalcaemia is suppression of plasma PTH to below the lower reference limit. Levels within the reference limit are

Explanation

B	Primary hyperparathyroidism

Plasma PTH is the best single test for differentiating between hypercalcaemia due to parathyroid overactivity and that due to non-parathyroid causes. Primary hyperparathyroidism can be associated with a plasma PTH level within the normal range. The normal response to hypercalcaemia is suppression of plasma PTH to below the lower reference limit. Levels within the reference limit are inappropriately high and suggestive of parathyroid disease.

Familial hypocalciuric hypercalcaemia is a hereditary disease with autosomal dominant transmission and is characterised by moderate chronic hypercalcaemia and normal or moderately elevated plasma PTH concentrations. The fractional excretion of calcium is lower than in primary hyperparathyroidism, and the urine calcium/creatinine ratio is usually < 0.01.

The importance of this condition is that hypercalcaemia rarely leads to significant clinical signs and parathyroidectomy is unsuccessful as therapy.

D	Sarcoidosis

Plasma PTH levels would not be in the normal range and would be reduced. Hypercalcemia is common in sarcoidosis. This is due to an uncontrolled synthesis of 1,25-dihydroxyvitamin D3 by macrophages. 1,25-dihydroxyvitamin D3 leads to an increased absorption of calcium in the intestine and an increased resorption of calcium in the bone.

A	Multiple myeloma

Plasma PTH levels would not be in the normal range and would be reduced. Hypercalcaemia is a common feature in multiple myeloma where there is frequently calcium

sarcoidosis. This is due to an uncontrolled synthesis of 1,25-dihydroxyvitamin D3 by macrophages. 1,25-dihydroxyvitamin D3 leads to an increased absorption of calcium in the intestine and an increased resorption of calcium in the bone.

A Multiple myeloma

Plasma PTH levels would not be in the normal range and would be reduced. Hypercalcaemia is a common feature in multiple myeloma where there is frequently calcium elevation, renal insufficiency, anaemia and bone disease.

Ten to 15% of patients present with hypercalcaemia in multiple myeloma. The cause is multifactorial, but bone destruction from osteolytic tumour lesions is the main contributing factor.

C Prolonged tourniquet application

This would not be a cause because PTH and corrected calcium were repeated on an uncuffed sample, with persistent hypercalcemia.

E Vitamin D excess

Plasma PTH levels would not be in the normal range and would be reduced. Vitamin D excess is associated with hypercalcaemia because there is an increased absorption of calcium in the intestine and an increased resorption of calcium in the bone.

Rate this question:

Next Question

Annotation Stop Share

A 56-year-old man with chronic kidney disease is admitted for an arthroscopy of the right knee. His admission in U&E reveals potassium of 5.9 mmol/l, creatinine of 450 μmol/l and urea of 28 mmol/l.

Which of the following stems represents the best plan with respect to his surgery?

A	He should be commenced on calcium resonium and surgery can proceed
B	He should be given nebulised salbutamol and surgery be postponed by 6 h
C	He is safe to continue with surgery
D	He should be given insulin and dextrose and surgery may proceed
E	Surgery should be delayed until his potassium is below 5.5 mmol/l

Submit

10:01

A 56-year-old man with chronic kidney disease is admitted for an arthroscopy of the right knee. His admission in U&E reveals potassium of 5.9 mmol/l, creatinine of 450 μmol/l and urea of 28 mmol/l.

Which of the following stems represents the best plan with respect to his surgery?

Your answer was correct

A	He should be commenced on calcium resonium and surgery can proceed
B	He should be given nebulised salbutamol and surgery be postponed by 6 h
C	He is safe to continue with surgery
D	He should be given insulin and dextrose and surgery may proceed
E	Surgery should be delayed until his potassium is below 5.5 mmol/l

Explanation

E	Surgery should be delayed until his potassium is below 5.5 mmol/l

Guidelines for surgery in patients with chronic kidney disease suggest that surgery should be postponed until serum potassium is <5.5 mmol/l. In addition, in patients undergoing surgery potassium should be monitored

Annotation Stop Share
Rana Alnasser's screen

10:01

MyPastest
https://mypastest.pastest.com

and surgery can proceed

B He should be given nebulised salbutamol and surgery be postponed by 6 h

C He is safe to continue with surgery

D He should be given insulin and dextrose and surgery may proceed

E Surgery should be delayed until his potassium is below 5.5 mmol/l

Explanation

E Surgery should be delayed until his potassium is below 5.5 mmol/l

Guidelines for surgery in patients with chronic kidney disease suggest that surgery should be postponed until serum potassium is <5.5 mmol/l. In addition, in patients undergoing surgery potassium should be monitored immediately after and then again 4–6 h later. Where surgery is likely to involve significant circulatory compromise and acute or chronic kidney disease may be precipitated, such as in coronary artery bypass surgery, patients should ideally be stabilised on dialysis first.

A He should be commenced on calcium resonium and surgery can proceed

Calcium m would not work quickly – it takes at least 4 ntly lower the potassium.

Annotation Stop Share

10:02

A 54-year-old man, who is on continuous peritoneal ambulatory dialysis, presents to the Emergency Department with dull abdominal pain.

He has a history of hypertension for which he takes a number of agents, and type 2 diabetes for which he takes BD insulin.

On examination, he is pyrexial, 37.8 °C; the dialysate fluid is cloudy but the site of the catheter looks clean.

Investigations:

Hb	10.2 g/dl
WCC	12.1 x10^9/l
PLT	204 x10^9/l
Na^+	140 mmol/l
K^+	4.9 mmol/l
Creatinine	321 µmol/l
Dialysate fluid	120 white cells/ml

Which of the following is the most appropriate initial treatment?

A IV ciprofloxacin

B IV gentamicin and vancomycin

C Intraperitoneal vancomycin and gentamicin

D Oral ciprofloxacin

E Oral vancomycin

Rana Alnasser's screen

This man has symptoms and signs consistent with spontaneous bacterial peritonitis associated with continuous ambulatory peritoneal dialysis (CAPD). Standard therapy involves instilling IP vancomycin and gentamicin, as coagulase-negative *Staphylococcus* is a very common pathogen. Once culture results are available, antibiotics can then be tailored appropriately. Persistent or relapsing peritonitis, erosion or protrusion of the cuff around the dialysis catheter may unfortunately necessitate removal.

A IV ciprofloxacin

Generally IP antibiotics are recommended as first line. Ciprofloxacin may be used in resistant peritonitis.

B IV gentamicin and vancomycin

Generally IP antibiotics are recommended as first line. This regimen of antibiotics is, however, commonly used for tunnel line infections.

D Oral ciprofloxacin

Generally IP antibiotics are recommended as first line. Oral ciprofloxacin may be useful in exit site infections.

E Oral vancomycin

Generally IP antibiotics are recommended as first line. Oral vancomycin is used in the treatment of *Clostridium difficile* diarrhoea, but it is not helpful in CAPD peritonitis.

Rate this question:

Next Question

A 61-year-old man who came to your clinic complains of weakness and loss of weight. His voice is hoarse. He has no past medical history of note.

On examination, he has pedal oedema up to the tibial tuberosity, enlarged tongue and liver edge palpable up to three finger breadths below the right costal margin.

Investigations

Na^+	140 mmol/l
K^+	4.2 mmol/l
Urea	7.2 mmol/l
Creatinine	80 µmol/l
Hb	12.0 g/dl
WCC	5.1×10^9/l
Urine dipstick	3+++ protein

What is the most appropriate test that will lead to the correct diagnosis?

A Liver spleen scan

B 24 h urinary protein

C Subcutaneous fat biopsy

D Urine protein electrophoresis

E Urine protein immunophoresis

D Urine protein electrophoresis

E Urine protein immunophoresis

Explanation

C Subcutaneous fat biopsy

The clinical features of the patient are suggestive of amyloidosis. It is characterised by extracellular deposition of fibrous protein in various tissues and organs. It may be primary or associated with other chronic diseases like myeloma or rheumatoid arthritis. Diagnosis is made by typical findings and demonstration of amyloid fibrils by Congo red staining under polarised light. Abdominal subcutaneous fat pad aspirate or rectal submucosal biopsy are often performed to reach a final diagnosis.

A Liver spleen scan

In amyloid there may be an enlarged spleen and liver. This is not specific for amyloidosis. Lymphoproliferative diseases may also cause hepatosplenomegaly. Therefore, this would not be the investigation of choice for diagnosis.

B 24 h urinary protein

Heavy proteinuria is a feature of amyloidosis. However, proteinuria may be found in other glomerular diseases such as minimal-change glomerulopathy and membranous glomerulopathy. Therefore, quantification of protein would not give the definitive diagnosis.

D Urine protein electrophoresis

in amyloid there may be an enlarged spleen and liver. This is not specific for amyloidosis. Lymphoproliferative diseases may also cause hepatosplenomegaly. Therefore, this would not be the investigation of choice for diagnosis.

B 24 h urinary protein

Heavy proteinuria is a feature of amyloidosis. However, proteinuria may be found in other glomerular diseases such as minimal-change glomerulopathy and membranous glomerulopathy. Therefore, quantification of protein would not give the definitive diagnosis.

D Urine protein electrophoresis

Urine protein electrophoresis would be abnormal in myeloma.

E Urine protein immunophoresis

Similarly, in myeloma the urine immunophoresis would be abnormal.

Rate this question:

Next Question

Previous Q... Tag Questi... Feedback End Session

© Pastest 2019

Rana Alnasser's screen

10:06

You are asked to urgently review a 62-year-old man who is admitted to the Emergency Department. There is a past history of chronic kidney disease. On this occasion, he complains of increasing shortness of breath.

On examination, he has a blood pressure 90/60 mmHg, heart rate of 100 bpm. He has a pericardial rub and there are bibasal crackles consistent with heart failure. Both legs are swollen up to the thighs.

Investigations show:

Na^+	134 mmol/l
K^+	5.9 mmol/l
Urea	48 mmol/l
Creatinine	570 µmol/l
Hb	8.9 g/dl
WCC	5.1×10^9/l
PLT	243×10^9 /l

Which of the following represents the best treatment option in this patient?

A Blood transfusion

B Erythropoietin

C Urgent haemodialysis

D Intravenous furosemide

E Intravenous iron replacement

Rana Alnasser's screen

Explanation

C Urgent haemodialysis

This man has uraemic pericarditis, an indication for urgent haemodialysis. Haemorrhagic pericardial effusion and atrial fibrillation are often associated. Anticoagulation is not advised because of the risk of precipitating cardiac tamponade. Uraemic pericarditis usually resolves after a period of intensive dialysis. Uraemic neuropathy is also an indication for urgent dialysis, as is evidence of fluid overload coupled with kidney disease which is non-responsive to diuretics.

A Blood transfusion

Giving blood transfusion in this scenario would exacerbate the problem as the patient is already fluid overloaded.

B Erythropoietin

Erythropoietin will increase the haemoglobin, but will need time to act. It may be given subcutaneously or intravenously. However, it would not be a treatment of uraemic pericarditis and has no effect on uraemia.

D Intravenous furosemide

Furosemide may be useful to reduce fluid overload if the patient is still passing urine. However, it would potentially exacerbate uraemia and would not be the definitive treatment for uraemic pericarditis.

E Intravenous iron replacement

Since giving intravenous iron adds to fluid load, it would especially not be recommended in this case.

10:07

A 29-year-old woman of Jamaican origin presented to her general practitioner with four months' of amenorrhoea and increasing tiredness. She was adopted as a child and recalls that her immediate brother died of an uncertain kidney disease a few years ago in Jamaica.

Routine examination reveals a blood pressure of 210/135 mmHg, a heart murmur and a palpable mass in the abdomen. She was sent for a routine blood test and ultrasound of the abdomen and pelvis.

Investigations:

Ultrasound scan	Enlarged kidneys with multiple cysts, consistent with polycystic kidneys
Prolactin	1200 mU/l (< 360 mU/l)
Hb	14.5 g/dl
WCC	9×10^9/l
Platelets	350×10^9/l
Na^+	140 mmol/l
K^+	6.2 mmol/l
Urea	16.8 mmol/l
Creatinine	750 µmol/l

Which of the following is the most likely diagnosis?

A Autosomal dominant polycystic kidney disease

B Chronic ureteric reflux

C Renal cell carcinoma

D Renovascular disease

Rana Alnasser's screen

Routine examination reveals a blood pressure of 210/135 mmHg, a heart murmur and a palpable mass in the abdomen. She was sent for a routine blood test and ultrasound of the abdomen and pelvis.

Investigations:

Ultrasound scan	Enlarged kidneys with multiple cysts, consistent with polycystic kidneys
Prolactin	1200 mU/l (< 360 mU/l)
Hb	14.5 g/dl
WCC	9×10^9/l
Platelets	350×10^9/l
Na^+	140 mmol/l
K^+	6.2 mmol/l
Urea	16.8 mmol/l
Creatinine	750 μmol/l

Which of the following is the most likely diagnosis?

A Autosomal dominant polycystic kidney disease

B Chronic ureteric reflux

C Renal cell carcinoma

D Renovascular disease

E Transitional cell carcinoma

Submit

ultrasound of the abdomen and pelvis.

Investigations:

Ultrasound scan	Enlarged kidneys with multiple cysts, consistent with polycystic kidneys
Prolactin	1200 mU/l (< 360 mU/l)
Hb	14.5 g/dl
WCC	9×10^9/l
Platelets	350×10^9/l
Na^+	140 mmol/l
K^+	6.2 mmol/l
Urea	16.8 mmol/l
Creatinine	750 µmol/l

Which of the following is the most likely diagnosis?

Your answer was correct

A Autosomal dominant polycystic kidney disease

B Chronic ureteric reflux

C Renal cell carcinoma

D Renovascular disease

E Transitional cell carcinoma

Explanation

Rana Alnasser's screen

10:10

Explanation

A Autosomal dominant polycystic kidney disease

Autosomal dominant polycystic kidney disease (APKD) presents with hypertension and haematuria, and later in middle age with chronic kidney disease. Hyperprolactinaemia is common in chronic kidney disease. Acute loin pain or haematuria due to haemorrhage into the cysts are common. Cysts may be found in other organs such as the liver and ovaries, but liver cysts are more commonly associated with childhood autosomal recessive polycystic kidney disease. Hypertension develops in over 75% of cases. Subarachnoid haemorrhage from berry aneurysm is reported to occur in about 9% of patients, and 8% of patients with APKD are thought to have asymptomatic intracranial aneurysms. Early aggressive management of blood pressure is the cornerstone of therapy.

B Chronic ureteric reflux

There is no mention of recurrent urinary tract infections. Chronic ureteric reflux generally presents with chronic renal impairment as an adult, and may be due to recurrent urinary infections as a child. In children, vesico-ureteric reflux, a congenital defect, is a cause of the urinary tract infections.

C Renal cell carcinoma

Renal cell carcinoma classically presents with haematuria, flank pain and abdominal mass. The lack of flank pain and anaemia, with the relatively young age, would make renal cell carcinoma unlikely. By the time there is the classical triad of symptoms, we would expect the renal cell carcinoma to be in an advanced stage.

Rana Alnasser's screen

10:11

A 22-year-old woman is admitted with a third episode of syncope over the past six months. She says that she tries her best in hot weather to maintain her fluid intake, but often feels light-headed. She does not take any regular medication apart from the combined oral contraceptive pill.

On examination, her blood pressure (BP) is 110/80 mmHg, pulse is 75/min and regular. Body mass index (BMI) is 23. There are no abnormal findings.

Investigations:

Hb	13.1 g/dl
WCC	8.9×10^9/l
PLT	183×10^9/l
Na^+	138 mmol/l
K^+	3.1 mmol/l
Bicarbonate	33 mmol/l
Creatinine	100 micromol/l

Which of the following is the most likely diagnosis?

A Bartter syndrome

B Conn syndrome

C Cushing syndrome

D Gitelman syndrome

E Vasovagal syncope

Rana Alnasser's screen

D Gitelman syndrome

Gitelman's presents with hypokalaemic metabolic alkalosis in the absence of hypertension. Gitelman's may be associated with milder disease and presents later than Bartter syndrome. Gitelman syndrome is associated with reduced calcium excretion, whereas Bartter's is not, and this helps to differentiate between the two conditions.

A Bartter syndrome

Bartter syndrome presents with hypokalaemic metabolic alkalosis in the absence of hypertension. Bartter's normally presents in childhood with constipation, growth failure, muscle cramps and weakness. Renin and aldosterone are both elevated.

B Conn syndrome

Conn syndrome presents with hypokalaemic metabolic alkalosis but with hypertension. There may be other symptoms such as myalgia, muscle spasms, paraesthesiae and polyuria. Complications may include stroke, myocardial infarction and kidney disease.

C Cushing syndrome

Cushing syndrome is associated with obesity. Other symptoms and signs include hypertension, abdominal striae, round facies, fat pad between shoulder blades, muscle wasting and poor wound healing.

E Vasovagal syncope

Vasovagal syncope will present with low blood pressure; however, there would not be any metabolic disturbance such as hypokalaemic metabolic alkalosis which would suggest a different diagnosis. In vasovagal syncope, when

10:13

A 69-year-old woman is found on the floor, having slipped in the bathroom at home. She has been lying on the floor for up to 8 hours before being found by her carer.

There is a past history of ischaemic heart disease, for which she is treated with ramipril, bisoprolol, aspirin and atorvastatin.

Her blood pressure (BP) is 122/72 mmHg, pulse is 80/min, sinus rhythm. She has signs of left lower lobe consolidation and there is extensive bruising over the left hip and pelvis.

Investigations show:

Hb	13.1 g/dl
WCC	8.9×10^9/l
PLT	183×10^9/l
Na^+	138 mmol/l
K^+	5.2 mmol/l
Urea	7.3 mmol/l
Urine dipstick	3+ blood

You are concerned about the possibility of rhabdomyolysis.

Which of the following is the most appropriate investigation to confirm the diagnosis?

A Albumin

B Creatinine

C Creatine kinase

D Lactate dehydrogenase (LDH)

Rana Alnasser's screen

D Lactate dehydrogenase (LDH)

E Urine microscopy

Explanation

C Creatine kinase

The options for diagnosing rhabdomyolysis include serum creatine kinase (CK) and urine microscopy. The presence of blood on urine dipstick and an absence of cells on microscopy would suggest that it is myoglobinuria rather than haematuria which is responsible for the positive test. However, CK is the preferred answer, as the level is predictive of possible renal impairment.

A Albumin

In rhabdomyolysis, at an early stage, dehydration causes hyperalbuminaemia, whereas later malnutrition, inflammation, capillary leak and fluid overload cause hypoalbuminaemia. Changes in serum albumin may result in the misinterpretation of total plasma calcium concentrations. Albumin is not specific for rhabdomyolysis.

B Creatinine

While elevated creatinine may be seen, it does not reveal the underlying cause of renal impairment. Creatinine is raised in renal impairment of any cause.

D Lactate dehydrogenase (LDH)

A rise in LDH is seen in muscle necrosis but it occurs later in the process. LDH may be raised in myocardial infarction

Rana Alnasser's screen

10:14

An overweight 43-year-old man with stable bipolar affective disorder, treated with lithium carbonate, is seen for the second time in the General Medical Outpatients Clinic. He was originally referred by the Psychiatric team with polyuria associated with excessive thirst and drinking.

The psychiatric nurse who has been seeing him in the community wondered whether he might be suffering from diabetes mellitus; however, a capillary blood glucose measurement was normal.

His results from the last visit are as follows:

Fasting blood glucose	6.9 mmol/l	
Potassium (K^+)	3.9 mmol/l	
Serum osmolality	309 mOsmol/kg	275–295 mOsmol/kg

What is the most useful management step?

A	Admission for a water deprivation test with antidiuretic hormone (ADH) administration
B	Advice to the patient to reduce fluid intake, with explanation
C	Admission for further investigation of pituitary function
D	Commencement of metformin 500 mg twice daily (bd)
E	Withdrawal of lithium carbonate

Rana Alnasser's screen

A Admission for a water deprivation test with antidiuretic hormone (ADH) administration

This man is likely to have nephrogenic diabetes insipidus (DI) as a result of lithium therapy. He has borderline high serum osmolality. However, an alternative cause has not been excluded by the investigations carried out so far, and a water deprivation test will clarify the cause and enable confident and accurate management.

It may be appropriate to consider stopping the lithium therapy. However, in view of his serious psychiatric diagnosis, which has significant mortality associated with poor control of symptoms, it would be unwise to stop this medication without psychiatric review, unless there are life-threatening and urgent indications necessitating treatment withdrawal.

His fasting blood sugar suggests that he has impaired fasting glucose (IFG). This is unlikely to cause his symptoms and would be best treated at this stage with dietary advice and encouragement to lose weight and increase exercise, rather than oral hypoglycaemic medication. In view of the serum osmolality, the possibility of psychogenic polydipsia, which must also be considered in this situation, is rejected.

In this condition, the osmolality would be normal or low, and not high. It is too early to say whether investigation of pituitary function would be appropriate (eg if cranial diabetes insipidus was suspected). Again, the water deprivation test should clarify this.

E Withdrawal of lithium carbonate

It may be appropriate to consider stopping the lithium therapy. However, in view of his serious psychiatric diagnosis, which has significant mortality associated with poor control of symptoms, it would be unwise to stop this medication without psychiatric review, unless there are life-

deprivation test should clarify this.

E Withdrawal of lithium carbonate

It may be appropriate to consider stopping the lithium therapy. However, in view of his serious psychiatric diagnosis, which has significant mortality associated with poor control of symptoms, it would be unwise to stop this medication without psychiatric review, unless there are life-threatening and urgent indications necessitating treatment withdrawal.

B Advice to the patient to reduce fluid intake, with explanation

Reduction in fluid intake is the treatment for syndrome of inappropriate antidiuretic hormone (SIADH) secretion, and not DI.

C Admission for further investigation of pituitary function

This scenario does not suggest pituitary failure, but nephrogenic DI as a likely cause.

D Commencement of metformin 500 mg twice daily (bd)

The issue is not diabetes control, so starting metformin is not the appropriate step.

Rate this question:

Next Question

A 24-year-old white man is referred to the Renal Clinic for further investigation of an abnormal urinalysis result, detected at a routine private health insurance medical some 3 months earlier.

At this medical, he was noted to have a BP of 159/89 mmHg. Urinalysis revealed 2+ blood and 1+ protein. The patient feels well and denies any significant past medical history. He is on no regular medication and denies any illicit drug use. As he was adopted, he is unable to say whether there is a family history of renal disease.

On examination, he has a blood pressure of 154/96 mmHg. The rest of the clinical examination is unremarkable.

Laboratory and radiology results are as follows:

Urine microscopy	Red blood cells visualised
Na^+	140 mmol/l
K^+	3.7 mmol/l
Urea	5.3 mmol/l
Creatinine	95 µmol/l
Complement C3	108 mg/dl (65–190 mg/dl)
Complement C4	37 mg/dl (15–50 mg/dl)

Renal ultrasound scan:

Right kidney	10 cm, with two simple cysts
Left kidney	10 cm, normal morphology

What is the next most appropriate course of action?

A	Check antiglomerular basement membrane (anti-GBM) antibodies
B	Carry out genetic testing for adult polycystic

On examination, he has a blood pressure of 154/96 mmHg. The rest of the clinical examination is unremarkable.

Laboratory and radiology results are as follows:

Urine microscopy	Red blood cells visualised
Na^+	140 mmol/l
K^+	3.7 mmol/l
Urea	5.3 mmol/l
Creatinine	95 µmol/l
Complement C3	108 mg/dl (65–190 mg/dl)
Complement C4	37 mg/dl (15–50 mg/dl)

Renal ultrasound scan:

Right kidney	10 cm, with two simple cysts
Left kidney	10 cm, normal morphology

What is the next most appropriate course of action?

A	Check antiglomerular basement membrane (anti-GBM) antibodies
B	Carry out genetic testing for adult polycystic kidney disease
C	Check immunoglobulin levels
D	Prescribe an antihypertensive drug
E	Renal biopsy

C Check immunoglobulin levels

D Prescribe an antihypertensive drug

E Renal biopsy

Explanation

D Prescribe an antihypertensive drug

The differential diagnosis includes IgA nephropathy and thin basement membrane disease. Although the gold standard diagnostic test is a renal biopsy it would not help management at present. A renal biopsy confers risk, and therefore there is no point in carrying out a potentially kidney-threatening procedure for little gain. The patient's hypertension does need treatment, however, so he should be commenced on an antihypertensive drug. He should be monitored periodically in the renal clinic for any progression of proteinuria or worsening renal function.

E Renal biopsy

The gold standard way to distinguish between the two main differential diagnoses in this case, which is IgA nephropathy and thin membrane disease, is to carry out a renal biopsy, but at this stage it would not impact on management (although it is something that should be considered at a later date).

A Check antiglomerular basement membrane (anti-GBM) antibodies

The patient is too well to have Goodpasture's syndrome, so it would not be helpful to check anti-GBM antibodies.

therefore there is no point in carrying out a potentially kidney-threatening procedure for little gain. The patient's hypertension does need treatment, however, so he should be commenced on an antihypertensive drug. He should be monitored periodically in the renal clinic for any progression of proteinuria or worsening renal function.

E Renal biopsy

The gold standard way to distinguish between the two main differential diagnoses in this case, which is IgA nephropathy and thin membrane disease, is to carry out a renal biopsy, but at this stage it would not impact on management (although it is something that should be considered at a later date).

A Check antiglomerular basement membrane (anti-GBM) antibodies

The patient is too well to have Goodpasture's syndrome, so it would not be helpful to check anti-GBM antibodies.

B Carry out genetic testing for adult polycystic kidney disease

The two simple cysts in the normal-sized right kidney are incidental and are of no clinical significance. Therefore, this patient does not need to be screened for adult polycystic kidney disease.

C Check immunoglobulin levels

The differential diagnosis includes IgA nephropathy and thin basement membrane disease. If the patient has IgA disease, his serum IgA levels may well be abnormal, but checking the levels would not constitute a diagnostic test.

Rana Alnasser's screen

10:27

polycystic kidney disease diagnostic criteria

ALL IMAGES NEWS MAPS SHOPPING VIDEOS BOOKS FLIGHTS TABLET

Ultrasonographic **diagnostic criteria** for ADPKD1 are as follows : At least 2 cysts in 1 **kidney** or 1 cyst in each **kidney** in an at-risk patient younger than 30 years. At least 2 cysts in each **kidney** in an at-risk patient aged 30-59 years. At least 4 cysts in each **kidney** for an at-risk patient aged 60 years or older.26 Apr 2018

Polycystic Kidney Disease: Practice Essentials, Background, ...
https://emedicine.medscape.com › article

About this result Feed

PEOPLE ALSO ASK

How is polycystic kidney disease diagnosed?

What age is PKD diagnosed?

Is there a genetic test for polycystic kidney disease?

What is the life expectancy of someone with polycystic kidney disease?

Feed

Polycystic Kidney Disease: Practice Essentials, Background, Pathophysiology - Medscape eMedicine
https://emedicine.medscape.com › article

Discover Updates Search Recent More

Rana Alnasser's screen

10:27
594-042-7551 Leave

A 21-year-old Nigerian woman was referred by her GP with a progressive history of polydipsia and polyuria of 6 months' duration.

She has a history of sickle cell disease and had been admitted on two previous occasions to hospital with chest pain precipitated by crisis. Fasting blood glucose is 4.5 mmol/l. She is not on any medication.

On examination, her blood pressure is 120/60 mmHg and heart rate is 90 bpm. A water deprivation test was performed.

Water deprivation phase:

Plasma osmolality	298 mosm/kg (278–305 mosm/kg)
Urine osmolality	300 mosm/kg (350-1000 mosm/kg)

DDAVP Phase:

Plasma osmolality	295 mosm/kg (278–305 mosm/kg)
Urine osmolality	325 mosm/kg (350-1000 mosm/kg)

What diagnosis would best fit the clinical picture and investigation result?

A Analgesic nephropathy

B Cranial diabetes insipidus

C Lithium-induced nephrotoxicity

D Nephrogenic diabetes insipidus

E Psychogenic polydipsia

Audio Video Share Participants 8 More

10:30
594-042-7551 Leave

Urine osmolality	300 mosm/kg (350-1000 mosm/kg)

DDAVP Phase:

Plasma osmolality	295 mosm/kg (278-305 mosm/kg)
Urine osmolality	325 mosm/kg (350-1000 mosm/kg)

What diagnosis would best fit the clinical picture and investigation result?

Your answer was correct

A Analgesic nephropathy

B Cranial diabetes insipidus

C Lithium-induced nephrotoxicity

D Nephrogenic diabetes insipidus

E Psychogenic polydipsia

Explanation

D Nephrogenic diabetes insipidus

Nephrogenic diabetes insipidus (NDI) is characterised by the inability to concentrate urine due to the lack of response of renal tubules to antidiuretic hormone (ADH). Normally the kidneys concentrate urine by increasing water resorption by the collecting duct in the presence of ADH; this mechanism helps to maintain plasma osmolality and extracellular volume. Without ADH, a large amount of dilute urine is excreted. The water deprivation test after an

Audio Video Share Participants 8 More

10:31
594-042-7551 Leave

Explanation

D Nephrogenic diabetes insipidus

Nephrogenic diabetes insipidus (NDI) is characterised by the inability to concentrate urine due to the lack of response of renal tubules to antidiuretic hormone (ADH). Normally the kidneys concentrate urine by increasing water resorption by the collecting duct in the presence of ADH; this mechanism helps to maintain plasma osmolality and extracellular volume. Without ADH, a large amount of dilute urine is excreted. The water deprivation test after an overnight fast assesses the kidneys' urine-concentrating ability and response to ADH. The result shows abnormally low (<350 mosmol/kg) urine osmolality, which increases only slightly after exogenous ADH (1-deamino-8-d-arginine-vasopressin (DDAVP), vasopressin). NDI is X-linked recessive.

Homozygous affected people (all males) are completely unresponsive to ADH while heterozygous females show normal or slight impairment. Acquired NDI occurs in disorders that disrupt the medulla or distal nephron and impair concentrating ability. Causes are: sickle cell nephropathy, polycystic kidney disease, pyelonephritis, amyloidosis, and certain nephrotoxins such as lithium and demeclocycline.

A Analgesic nephropathy

The injuries that may be caused by analgesia include renal papillary necrosis and chronic interstitial nephritis. There is also an increased risk of cancers of the urinary system. Water deprivation test is normal.

B Cranial diabetes insipidus

Although there is polyuria and polydipsia associated with cranial diabetes insipidus, the water deprivation test is

Audio Video Share Participants 8 More

10:31
594-042-7551 Leave
MyPastest
https://mypastest.pastest.com

normal or slight impairment. Acquired NDI occurs in disorders that disrupt the medulla or distal nephron and impair concentrating ability. Causes are: sickle cell nephropathy, polycystic kidney disease, pyelonephritis, amyloidosis, and certain nephrotoxins such as lithium and demeclocycline.

A Analgesic nephropathy

The injuries that may be caused by analgesia include renal papillary necrosis and chronic interstitial nephritis. There is also an increased risk of cancers of the urinary system. Water deprivation test is normal.

B Cranial diabetes insipidus

Although there is polyuria and polydipsia associated with cranial diabetes insipidus, the water deprivation test is normal and serum ADH levels low.

C Lithium-induced nephrotoxicity

When lithium induces acute kidney disease, there is associated severe dehydration, natriuresis and water diuresis. Other symptoms include altered mental status and poor oral intake. Water deprivation test is normal.

E Psychogenic polydipsia

There is excessive fluid intake despite physiological stimuli to drink, therefore plasma sodium is low and urinary osmolality is low. However, water deprivation test is not affected.

Audio Video Share Participants 8 More

10:31

A 49-year-old woman presents to the Emergency Department complaining of haemoptysis. She has attended the GP on three previous occasions over the past 6 months complaining of recurrent nose bleeds and sinusitis.

Examination of the chest reveals scattered crackles and signs of consolidation, particularly on the left-hand side. On further questioning, she admits to smoking 30 cigarettes per day.

Investigations:

Hb	11.0 g/dl
WCC	8.1×10^9/l
PLT	430×10^9/l
Na^+	140 mmol/l
K^+	5.7 mmol/l
Creatinine	190 µmol/l
c-ANCA	Positive
Chest X-ray	Consolidation with evidence of granuloma formation

Which of the following is the most likely diagnosis?

A Anti-GBM disease

B Churg-Strauss vasculitis

C Sarcoidosis

D Tuberculosis

E Wegener's granulomatosis

Rana Alnasser's screen

E Wegener's granulomatosis

The picture seen here fits well with a diagnosis of Wegener's, with positive c-ANCA, anaemia with leukocytosis, thrombocytosis, granulomas on CXR and evidence of renal involvement. Diagnosis is confirmed by taking a histology sample from affected tissue. Easiest to obtain is usually a biopsy of nasal/ upper respiratory tract mucosa, but if this is impossible, lung or renal biopsy is the alternative. Most physicians begin treatment with a course of 3 days' high-dose IV methylprednisolone and cyclophosphamide, with the aim of inducing remission from Wegener's. This is followed by conversion to lower doses of orals. IV immunoglobulin may be used in patients who are severely ill. More recently, IV rituximab (an anti-CD20 antibody) has shown promising results in inducing a clinical response in patients resistant to medical treatment.

A Anti-GBM disease

The are no granulomas on chest X-ray in anti-GBM disease. This most typically presents with pulmonary haemorrhage in the context of rapidly deteriorating renal function.

B Churg-Strauss vasculitis

Churg-Strauss vasculitis typically presents with asthma and peripheral blood eosinophilia. There is eosinophilic vasculitis. However, unlike this scenario, there is no granuloma formation in the lungs and it is associated more with p-ANCA positivity.

C Sarcoidosis

Although sarcoid is a granulomatous disease, it is not associated with a positive ANCA.

The are no granulomas on chest X-ray in anti-GBM disease. This most typically presents with pulmonary haemorrhage in the context of rapidly deteriorating renal function.

B Churg-Strauss vasculitis

Churg-Strauss vasculitis typically presents with asthma and peripheral blood eosinophilia. There is eosinophilic vasculitis. However, unlike this scenario, there is no granuloma formation in the lungs and it is associated more with p-ANCA positivity.

C Sarcoidosis

Although sarcoid is a granulomatous disease, it is not associated with a positive ANCA.

D Tuberculosis

Pulmonary tuberculosis may present with haemoptysis. However, C-ANCA would not be positive.

Rate this question:

© Pastest 2019

10:32

A 72-year-old woman was reviewed in Outpatients having recently been treated with furosemide and amiloride combination tablets for heart failure. You understand that the GP increased the number of combination diuretic tablets 6 weeks ago, rather than just increasing the furosemide component. She also has a history of angina, for which she takes a slow-release nitrate preparation.

On examination, her blood pressure is 130/80 mmHg, chest examination was unremarkable and heart sounds were normal.

The results of her blood tests were:

Na^+	134 mmol/l
K^+	5.9 mmol/l
Urea	14.2 mmol/l
Creatinine	258 µmol/l

An electrocardiogram (ECG) showed deep Q waves in the anterior leads but was otherwise unremarkable. Her amiloride has been stopped that day.

What further urgent action needs to be taken with respect to the potassium?

A Intravenous calcium gluconate 10%

B Intravenous insulin 10 U and dextrose 5 %

C None

D Nebulised salbutamol 5 mg

E Oral calcium resonium

10:35

NC ...

MyPastest
https://mypastest.pastest.com

A 72-year-old woman was reviewed in Outpatients having recently been treated with furosemide and amiloride combination tablets for heart failure. You understand that the GP increased the number of combination diuretic tablets 6 weeks ago, rather than just increasing the furosemide component. She also has a history of angina, for which she takes a slow-release nitrate preparation.

On examination, her blood pressure is 130/80 mmHg, chest examination was unremarkable and heart sounds were normal.

The results of her blood tests were:

Na^+	134 mmol/l
K^+	5.9 mmol/l
Urea	14.2 mmol/l
Creatinine	258 µmol/l

An electrocardiogram (ECG) showed deep Q waves in the anterior leads but was otherwise unremarkable. Her amiloride has been stopped that day.

What further urgent action needs to be taken with respect to the potassium?

Your answer was incorrect

A Intravenous calcium gluconate 10%

B Intravenous insulin 10 U and dextrose 5 %

C None

D Nebulised salbutamol 5 mg

E Oral calcium resonium

Explanation

C None

This woman has renal impairment and slightly elevated potassium. In the absence of ECG changes suggestive of hyperkalaemia (peaked T waves, widened QRS), no further action is required immediately. It is likely that the deep Q waves are indicative of previous myocardial infarction. Where peaked T waves and widened QRS exist in conjunction with hyperkalaemia, calcium gluconate and intravenous insulin and dextrose would be initial therapies of choice.

B Intravenous insulin 10 U and dextrose 5 %

Insulin moves the potassium from extracellular to intracellular compartment thereby reducing serum potassium levels.

A Intravenous calcium gluconate 10%

Calcium prevents cardiac arrythmias that occur as a result of hyperkalaemia. Caution must be exercised when administering intravenously because extravasation may lead to localised tissue necrosis.

D Nebulised salbutamol 5 mg

3G 10:37

A 45-year-old man who is a known alcohol abuser is under investigation for hyponatraemia. He drinks several lagers daily, he is otherwise well and not on any medication. He smokes 15 cigarettes/day.

On physical examination, his blood pressure is 130/80 mmHg, chest and abdominal examination is unremarkable.

Investigations reveal:

Chest X-ray	Normal
Computed tomography (CT) of the head	Normal
Thyroid function	Normal
Na^+	115 mmol/l
K^+	4.5 mmol/l
Urea	3.5 mmol/l
Creatinine	110 µmol/l
Glucose	4.5 mmol/l
Plasma osmolality	255 mOsmol/kg
Calculated osmolality	247 mOsmol/kg

What is the cause of the hyponatraemia?

A Addison's disease

B Beer potomania

C Hypothyroidism

D Salt-losing nephropathy

10:39

Investigations reveal:

Chest X-ray	Normal
Computed tomography (CT) of the head	Normal
Thyroid function	Normal
Na^+	115 mmol/l
K^+	4.5 mmol/l
Urea	3.5 mmol/l
Creatinine	110 µmol/l
Glucose	4.5 mmol/l
Plasma osmolality	255 mOsmol/kg
Calculated osmolality	247 mOsmol/kg

What is the cause of the hyponatraemia?

A Addison's disease

B Beer potomania

C Hypothyroidism

D Salt-losing nephropathy

E Syndrome of inappropriate antidiuretic hormone secretion (SIADH)

Rana Alnasser's screen

10:40

K	4.5 mmol/l
Urea	3.5 mmol/l
Creatinine	110 µmol/l
Glucose	4.5 mmol/l
Plasma osmolality	255 mOsmol/kg
Calculated osmolality	247 mOsmol/kg

What is the cause of the hyponatraemia?

Your answer was incorrect

A Addison's disease

B Beer potomania

C Hypothyroidism

D Salt-losing nephropathy

E Syndrome of inappropriate antidiuretic hormone secretion (SIADH)

Explanation

B Beer potomania

Beer potomania is a recognised cause of hyponatraemia in alcohol misusers. The electrolyte imbalance normally corrects itself with cessation of alcohol. The osmolar gap is due to the presence of osmotically active ethanol in the blood.

Rana Alnasser's screen

Beer potomania is a recognised cause of hyponatraemia in alcohol misusers. The electrolyte imbalance normally corrects itself with cessation of alcohol. The osmolar gap is due to the presence of osmotically active ethanol in the blood.

E Syndrome of inappropriate antidiuretic hormone secretion (SIADH)

SIADH is a diagnosis of exclusion. It is defined by hyponatraemia and hypo-osmolality resulting from inappropriate and continued secretion of ADH. Patients would be euvolaemic and the osmolar gap would be normal.

A Addison's disease

Addison's disease is due to deficiency in corticosteroids. Therefore, we would expect a high potassium and a postural drop in blood pressure or low blood pressure.

C Hypothyroidism

The osmolar gap would be normal. There may be associated symptoms such as weight gain, low mood, reduced appetite and intolerance to the cold.

D Salt-losing nephropathy

There may be variety of causes of salt-losing nephropathy including urea-induced osmotic diuresis, glomerulotubular imbalance and impaired tubular salt resorption. The osmolar gap would be normal.

70788

Rate this question:

10:42

secretion (SIADH)

SIADH is a diagnosis of exclusion. It is defined by hyponatraemia and hypo-osmolality resulting from inappropriate and continued secretion of ADH. Patients would be euvolaemic and the osmolar gap would be normal.

A Addison's disease

Addison's disease is due to deficiency in corticosteroids. Therefore, we would expect a high potassium and a postural drop in blood pressure or low blood pressure.

C Hypothyroidism

The osmolar gap would be normal. There may be associated symptoms such as weight gain, low mood, reduced appetite and intolerance to the cold.

D Salt-losing nephropathy

There may be variety of causes of salt-losing nephropathy including urea-induced osmotic diuresis, glomerulotubular imbalance and impaired tubular salt resorption. The osmolar gap would be normal.

70738

Rate this question:

Rana Alnasser's screen

10:42

A 68-year-old Ghanaian man, with a 10-year history of type 2 diabetes, presented with a 3-week history of generalised oedema. In spite of insulin treatment, his diabetes has been poorly controlled. He has background retinopathy.

Investigations revealed normal renal function, albumin 12 g/l, negative ANA, negative ANCA, negative GBM, negative HBsAg, negative hepatitis C antibody, negative cryoglobulins, negative serum electrophoresis. 24 h urine protein excretion was 15.6.

He underwent a renal biopsy shown below:

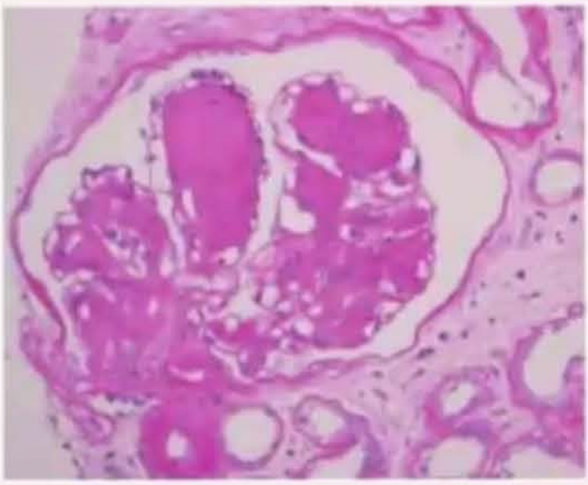

What is the most likely diagnosis?

A	Focal segmental glomerulosclerosis
B	Membranous nephropathy
C	Light-chain disease
D	Diabetic glomerulosclerosis
E	Minimal change disease

Submit

Rana Alnasser's screen

3G 10:45
NC ...

Google

amyloidosis glomerulonephritis pathology

ALL IMAGES NEWS VIDEOS SHOPPING MAPS BOOKS FL

Latest GIF HD Product

nephropathy crescentic biopsy renal histology rapidly

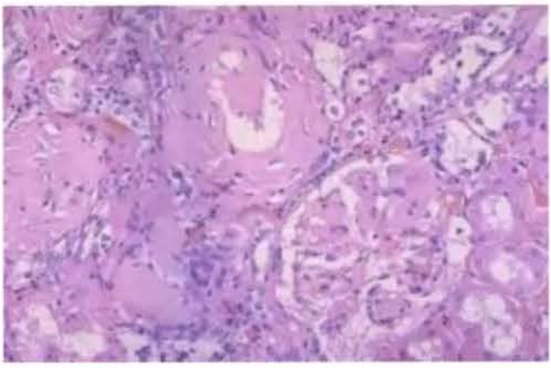

Pathology Outlines - Renal Amyloidosis
pathologyoutlines.com

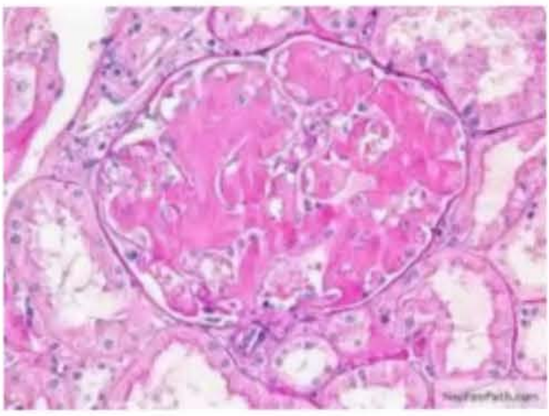

Pathology Outlines - Renal Amyloidosis
pathologyoutlines.com

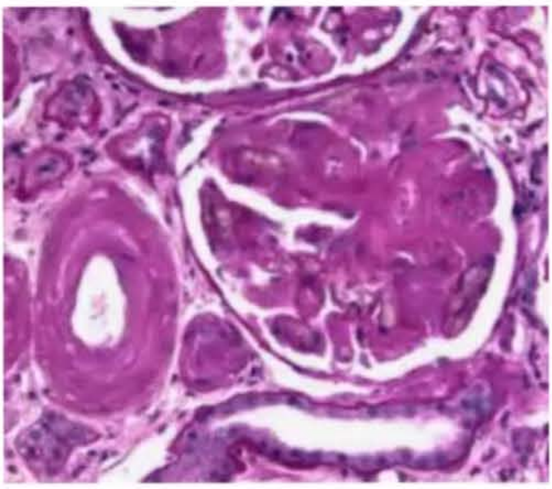

Pathology Outlines - Renal Amyloidosis
pathologyoutlines.com

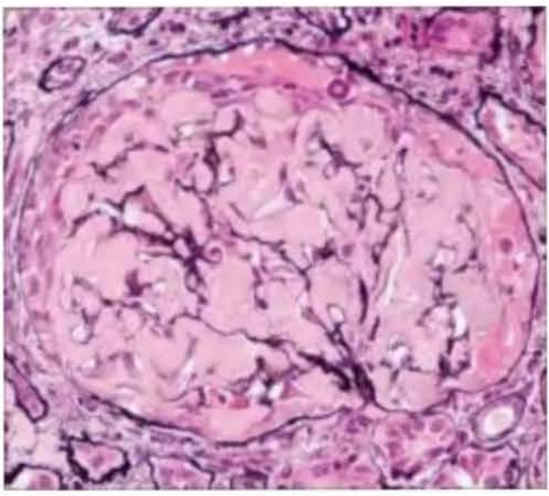

Rapidly progressive glomerulonephritis ...
indianjnephrol.org

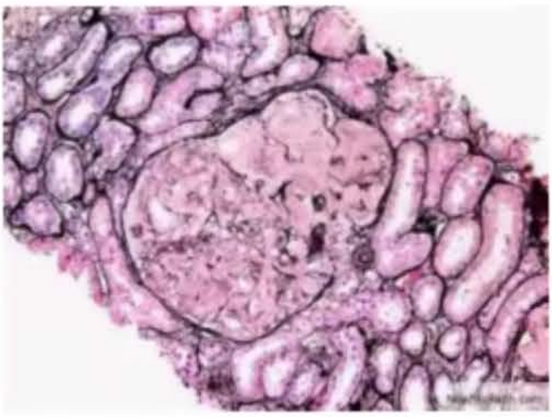

Pathology Outlines - Renal Amyloidosis

Renal pathology: Nephrotic and ...
slideplayer.com

Discover Updates Search Rec

10:45
594-042-7551
Leave

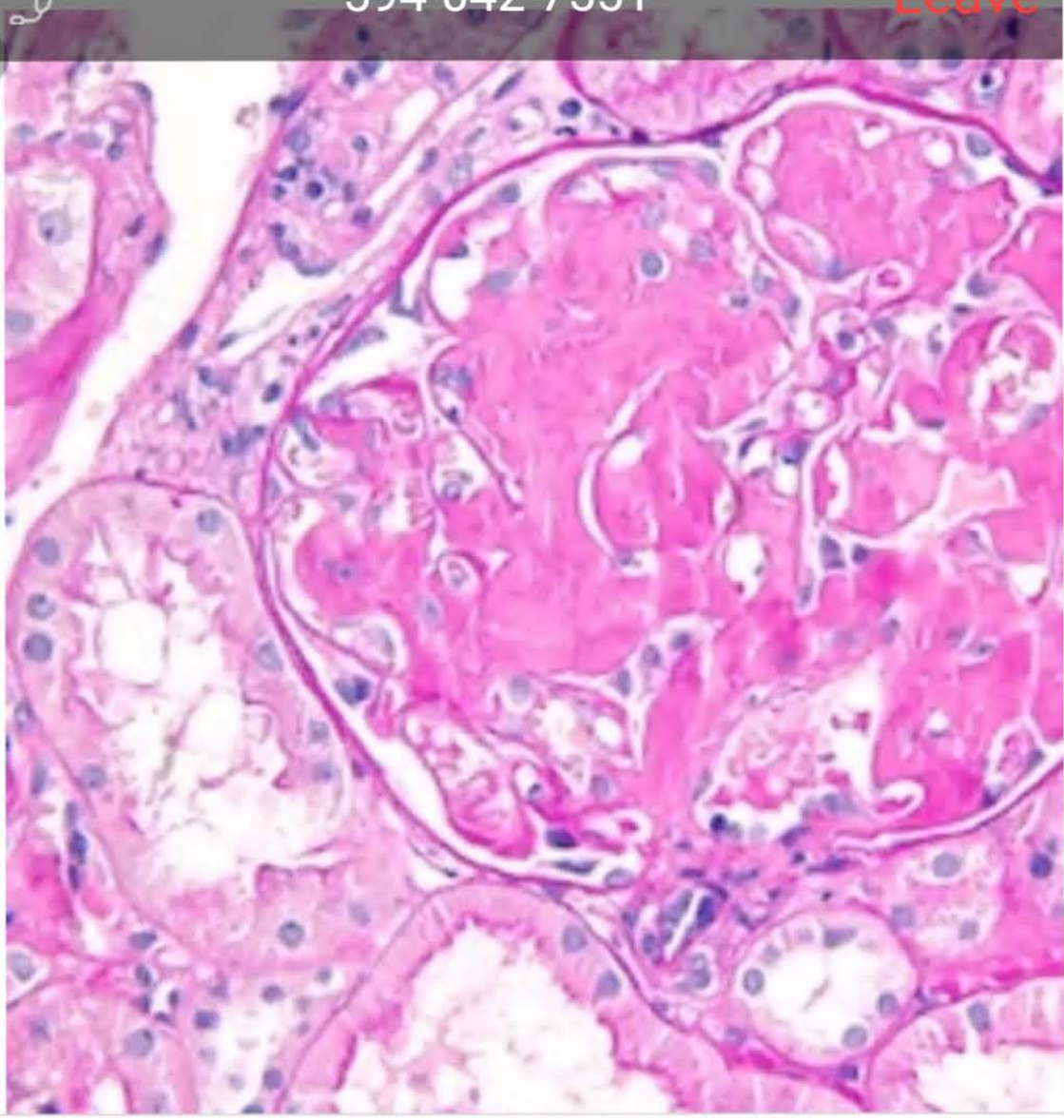

Pathology Outlines

Pathology Outlines - Renal Amyloidosis

Glomerulus (PAS)

Images may be subject to copyright. Learn more

RELATED IMAGES

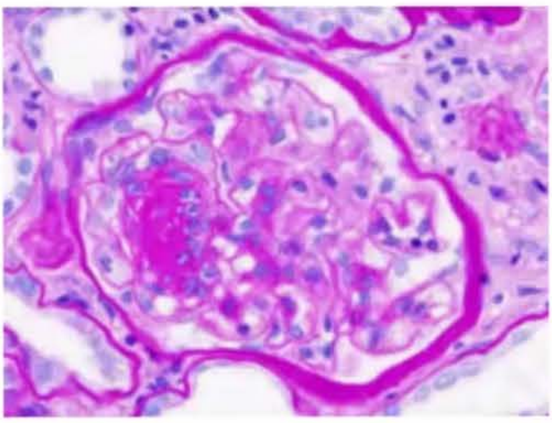

Diabetesnefropati – Wikipedia
sv.wikipedia.org

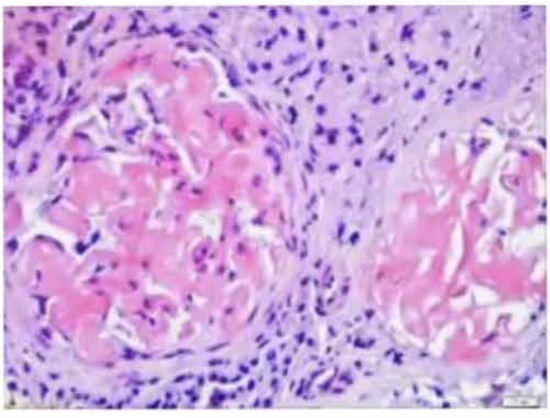

Glomerular amyloid deposition, light microsc...
researchgate.net

Discover
Updates
Search
Rec
Audio
Video
Share
Participants
More

10:46

594-042-7551

Leave

kimmelstiel wilson

ALL IMAGES NEWS VIDEOS SHOPPING MAPS BOOKS FLIGHTS TABLET

Latest GIF HD Product

diabetic nephropathy | lesion | glomerulosclerosis | nodule | histology

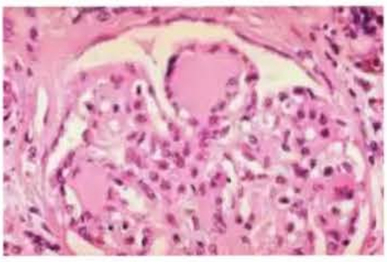

Renal Pathology
library.med.utah.edu

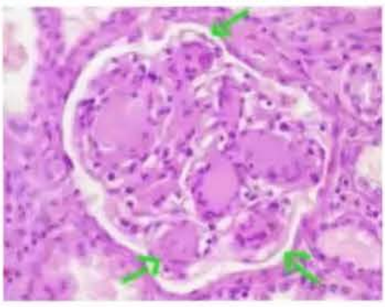

Diabetes and others
kidneypathology.com

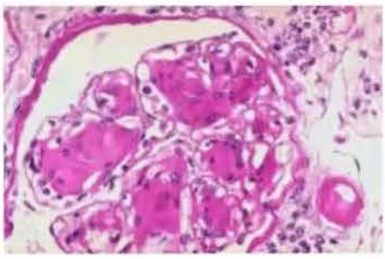

Renal Pathology
library.med.utah.edu

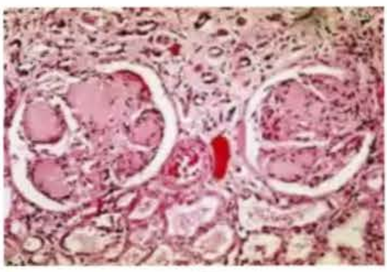

Diabetic nephropathy - Wikipedia
en.wikipedia.org

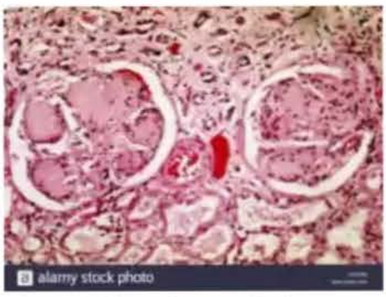

Kimmelstiel Wilson Syndrome Stock ...
alamy.com

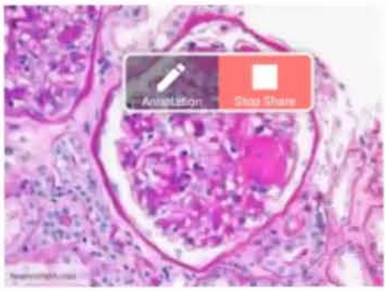

Diabetic glomerulosclerosis
pathologyoutlines.com

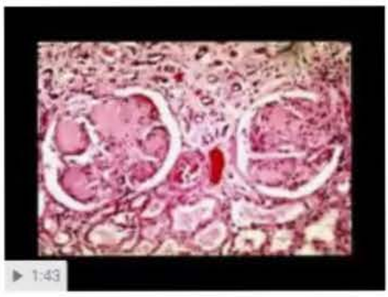

Kimmelstiel-Wilson Nodules ...
youtube.com

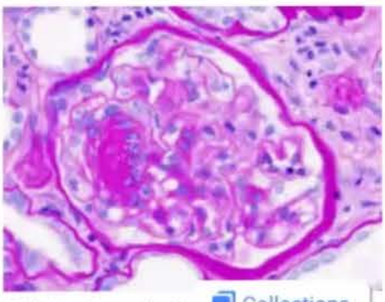

Diabetic glomerulosclerosis
pathologyoutlines.com

Collections

Discover Updates Search Recent More

Audio Video Share Participants More

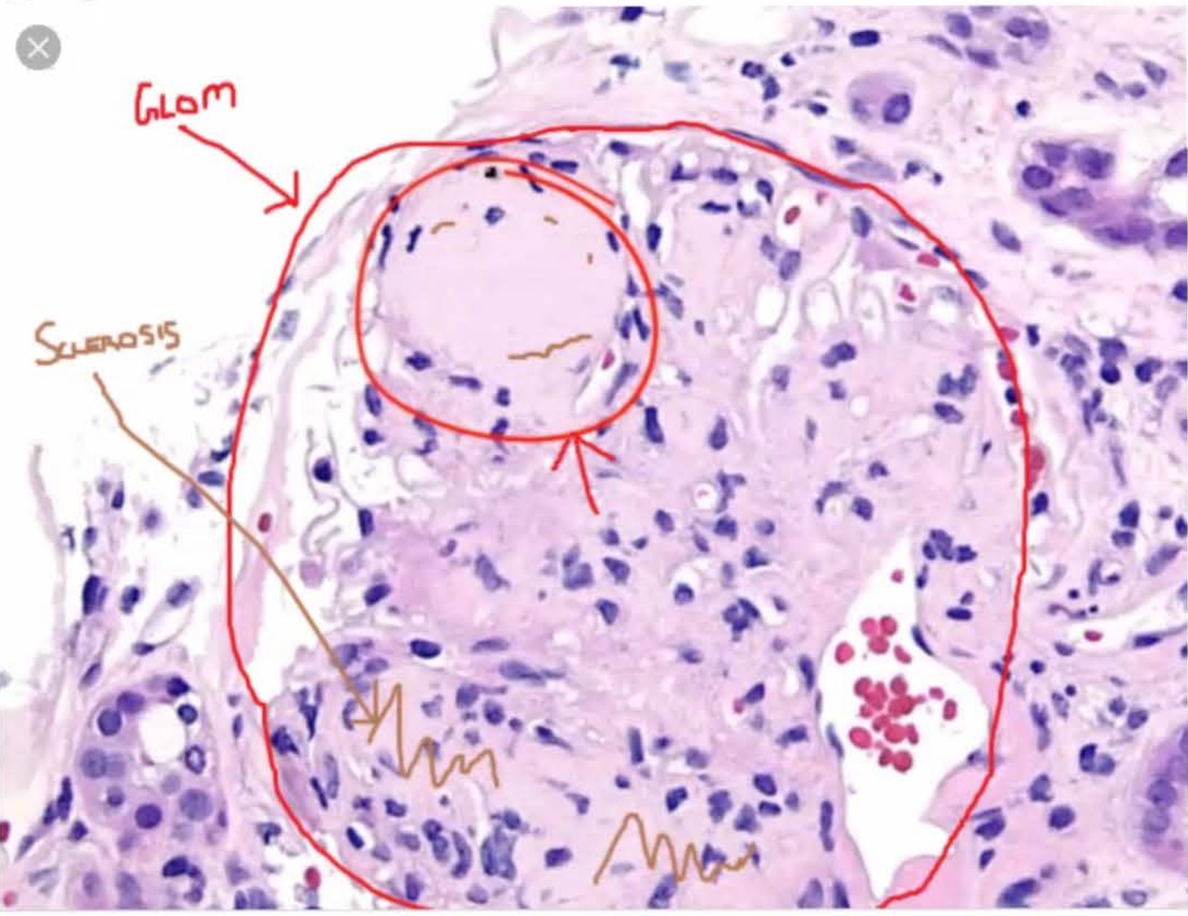

Pinterest

Kimmelstiel-Wilson Nodules***. Sclerosis of Mesangial cells ...

Kimmelstiel-Wilson Nodules*. Sclerosis of Mesangial cells -- Diabetes M Type 2

Images may be subject to copyright. Learn more

RELATED IMAGES

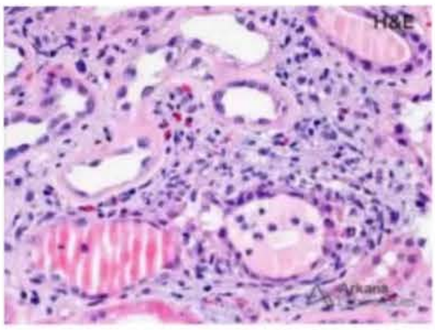

Eosinophil-Rich Inflammation in Diabetic Glo...
arkanalabs.com

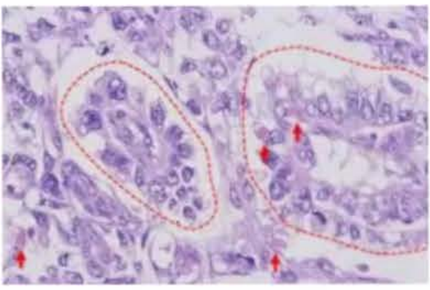

Schiller Duval Bodies Mnemonic 85198 | TIM...
timehd.net

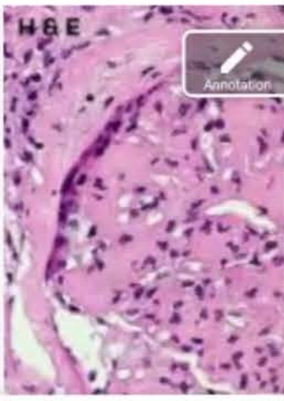

Discover Updates Search Recent Mo

Rana Alnasser's screen

10:47
594-042-7551
Leave

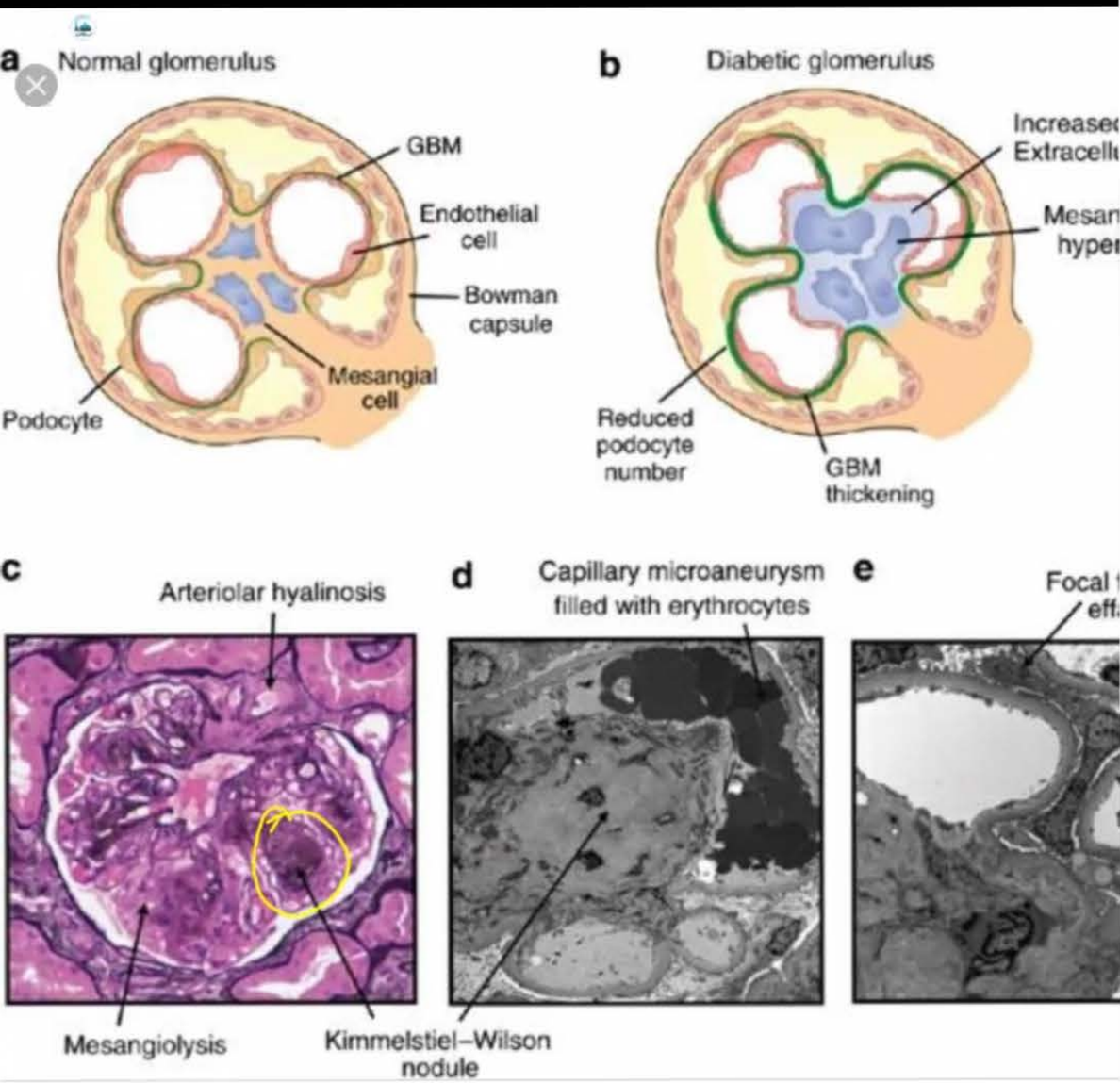

Twitter
حمد البريدي on Twitter: "@Med432 kimmelstiel-wilson nodules are ...
Stop Annotation Spotlight Pen Highlighter Line Rectangle Oval Undo Redo Clear Color
RELATED IMAGES
Discover Updates Search Recent
Audio Video Share Participants More

10:48

D Diabetic glomerulosclerosis

E Minimal change disease

Explanation

D Diabetic glomerulosclerosis

The duration of poorly controlled diabetes and evidence of microvascular disease make diabetic nephropathy the most likely diagnosis. The biopsy shows mesangial expansion with a Kimmelstiel-Wilson nodule at the top of the glomerulus, typical of diabetic glomerulosclerosis.

C Light-chain disease

Inconsistent with the history of poorly controlled diabetes and normal electrophoresis.

A Focal segmental glomerulosclerosis

The renal biopsy findings are not consistent with this, along with the long duration of diabetes.

B Membranous nephropathy

The incidence of membranous nephropathy is increased in diabetics compared with non-diabetic patients but on light microscopy the glomeruli will show capillary loop thickening and normal architecture respectively.

E Minimal change disease

The incidence of minimal-change disease is increased in

Rana Alnasser's screen

10:48

A 61-year-old woman is being reviewed in the medical follow-up clinic. She received a renal transplant 6 months ago because of end-stage kidney disease. She has been fine but complains that she feels embarrassed whenever she laughs because her gums have become very prominent. Her past medical history, apart from the renal transplant, includes long-standing hypertension. Ciclosporin was started after her renal transplant, and this is the only medication she is taking. On examination, she has a blood pressure of 140/80 mmHg, BMI of 27 kg/m^2, gums are swollen, chest is clear, and non-tender renal transplant.

Investigations show:

Na^+	138 mmol/l
K^+	4.2 mmol/l
Urea	12 mmol/l
Creatinine	250 μmol/l
Hb	8.7 g/dl
WCC	6×10^9/l
PLT	213×10^9 /l

What other complications of ciclosporin treatment should this patient be aware of?

A Alopecia

B Hypertrichosis

C Pigmentation

D Purpura

Rana Alnasser's screen

10:48

A 61-year-old woman is being reviewed in the medical follow-up clinic. She received a renal transplant 6 months ago because of end-stage kidney disease. She has been fine but complains that she feels embarrassed whenever she laughs because her gums have become very prominent. Her past medical history, apart from the renal transplant, includes long-standing hypertension. Ciclosporin was started after her renal transplant, and this is the only medication she is taking. On examination, she has a blood pressure of 140/80 mmHg, BMI of 27 kg/m^2, gums are swollen, chest is clear, and non-tender renal transplant.

Investigations show:

Na^+	138 mmol/l
K^+	4.2 mmol/l
Urea	12 mmol/l
Creatinine	250 µmol/l
Hb	8.7 g/dl
WCC	6×10^9/l
PLT	213×10^9 /l

What other complications of ciclosporin treatment should this patient be aware of?

A Alopecia

B Hypertrichosis

C Pigmentation

D Purpura

Rana Alnasser's screen

B Hypertrichosis

Ciclosporin was introduced in 1983 and led to great improvements in patients and graft survivals in organ transplantation. It is metabolised through the cytochrome P450 system in the liver. Drugs affecting this enzyme system affect the blood levels of ciclosporin. Recognised side effects include: hypertension, hypertrichosis, diabetes mellitus, infection, tumours, gingival hyperplasia, nephrotoxicity, headache, hyperkalaemia, hyperuricaemia, gout, hypercholesterolaemia and pancreatitis.

A Alopecia

Alopecia is a known side-effect of another renal transplant immunosuppressant - tacrolimus.

C Pigmentation

Ciclosporin does not affect pigmentation of the skin. Any change in pigmentation of moles in renal transplant should be taken seriously because there is an increased chance of malignancy whilst taking immunosuppression. Renal transplant patients are often advised to wear sun block when exposed to the sun.

D Purpura

Warfarin may have the side effect of purpura.

E Staining of the teeth

Minocycline and doxycycline may have the side effects of dental staining.

Rate this question:

10:51
594-042-7551 Leave

A 25-year-old woman comes to the clinic with a 3-day history of lower abdominal pain that is now beginning to radiate to her right flank. She denies nausea, vomiting or diarrhoea but states that she feels feverish and is worried that she may have the flu. She has noticed an increase in her urinary frequency.

Vital signs are temperature 39.2 °C, blood pressure 120/70 mmHg, pulse 95/min and respiration 16/min.

Physical examination shows tenderness in the suprapubic region, hyperactive bowel sounds and no signs of peritoneal irritation or masses. Her right flank is tender to light percussion. The remainder of the physical examination is within normal limits.

Urinalysis:

Leukocytes	+++
Proteinuria	+
Gram stain	Gram-negative bacilli

What is the most likely diagnosis?

A Acute appendicitis

B Acute pyelonephritis

C Ovarian torsion

D Perinephric abscess

E Pelvic inflammatory disease

Audio Video Share Participants More

her urinary frequency.

Vital signs are temperature 39.2 °C, blood pressure 120/70 mmHg, pulse 95/min and respiration 16/min.

Physical examination shows tenderness in the suprapubic region, hyperactive bowel sounds and no signs of peritoneal irritation or masses. Her right flank is tender to light percussion. The remainder of the physical examination is within normal limits.

Urinalysis:

Leukocytes	+++
Proteinuria	+
Gram stain	Gram-negative bacilli

What is the most likely diagnosis?

Your answer was correct

A Acute appendicitis

B Acute pyelonephritis

C Ovarian torsion

D Perinephric abscess

E Pelvic inflammatory disease

Explanation

B Acute pyelonephritis

This is a typical picture of pyelonephritis. Additional testing, such as renal ultrasonography or intravenous

Explanation

B Acute pyelonephritis

This is a typical picture of pyelonephritis. Additional testing, such as renal ultrasonography or intravenous pyelography, is indicated only if there is suspicion of a complication such as a stone stricture or tumour causing the pyelonephritis. These tests are not necessarily part of the routine management of a simple uncomplicated pyelonephritis. If symptoms persist beyond 3–5 days of effective treatment, an ultrasound or computed tomography (CT) scan of the kidney should be obtained to exclude a perinephric abscess or other drainable collection of fluid.

A Acute appendicitis

Acute appendicitis would not explain the gram negative bacilli in the urine. It would present as right iliac fossa pain, with nausea or vomiting accompanied by fever. There may be blood and leucocytes in the urine.

C Ovarian torsion

Ovarian torsion would not explain the gram negative bacilli in the urine. Ovarian torsion will present with acute onset iliac fossa pain, it may be so severe as to cause hypotension and tachycardia. The patient can be very unwell.

D Perinephric abscess

If symptoms in this scenario persist beyond 3–5 days of effective treatment, an ultrasound or computed tomography (CT) scan of the kidney should be obtained to exclude a perinephric abscess or other drainable collection of fluid.

exclude a perinephric abscess or other drainable collection of fluid.

A Acute appendicitis

Acute appendicitis would not explain the gram negative bacilli in the urine. It would present as right iliac fossa pain, with nausea or vomiting accompanied by fever. There may be blood and leucocytes in the urine.

C Ovarian torsion

Ovarian torsion would not explain the gram negative bacilli in the urine. Ovarian torsion will present with acute onset iliac fossa pain, it may be so severe as to cause hypotension and tachycardia. The patient can be very unwell.

D Perinephric abscess

If symptoms in this scenario persist beyond 3–5 days of effective treatment, an ultrasound or computed tomography (CT) scan of the kidney should be obtained to exclude a perinephric abscess or other drainable collection of fluid.

E Pelvic inflammatory disease

Pelvic inflammatory disease would not explain the Gram-negative bacilli in the urine.

Rate this question:

Next Question

A 24-year-old woman was admitted to hospital with a 3-day history of feeling generally unwell, with fatigue, arthralgia and pruritis.

She had recently finished a 5-day course of antibiotics for a urinary tract infection but there was no other significant past medical history. She had no significant findings on clinical examination except for a widespread erythematous rash.

Investigation results are below:

Hb	12.6 g/dl
WCC	13.0 × 10^9/l (eosinophilia)
PLT	390 × 10^9/l
Creatinine	720 µmol/l
Na^+	135 mmol/l
K^+	5.2 mmol/l
Urea	22.0 mmol/l
Urinalysis	Protein ++ blood +

What is the most important investigation to establish the diagnosis?

A Autoimmune profile

B Renal tract ultrasound scan

C Renal biopsy

D Urine microscopy and culture

E Antistreptolysin-O titre

B Renal tract ultrasound scan

C Renal biopsy

D Urine microscopy and culture

E Antistreptolysin-O titre

Explanation

C Renal biopsy

The diagnosis is acute tubulo-interstitial nephritis. Renal biopsy will show interstitial oedema with a heavy infiltrate of inflammatory cells and variable tubular necrosis. Eosinophilia and eosinophiluria are often seen. The most common cause is a hypersensitivity drug reaction to certain antibiotics (penicillins, cephalosporins), non-steroidal anti-inflammatory drugs (NSAIDS) and allopurinol. The condition generally has a good prognosis with the majority of patients recovering fully on withdrawal of the offending drug. The acute kidney disease can often be managed conservatively unless the patient is uraemic. There is some evidence that a short course of corticosteroids may accelerate recovery and prevent long-term renal damage. Interstitial nephritis may also occur in a chronic form.

D Urine microscopy and culture

This scenario is not a urinary tract infection in view of the eosinophilia. If there were a urinary infection, we may expect white cells in the urine.

A Autoimmune profile

expect white cells in the urine.

A Autoimmune profile

An autoimmune profile might aid in the diagnosis of systemic lupus erythematosus (SLE) particularly as there is arthralgia and rash, but there is no eosinophilia in SLE.

B Renal tract ultrasound scan

In acute tubulo-interstitial nephritis, the kidney sizes would be normal. Renal ultrasound would be useful in cases to exclude hydronephrosis.

E Antistreptolysin-O titre

Streptococcal infection generally presents with a sore throat. Acute glomerulonephritis following streptococcal infection is characterised by the sudden appearance of haematuria, proteinuria, red blood cell casts in the urine, oedema, and hypertension with or without oliguria; this occurs 10–14 days after streptococcal sore throat.

Rate this question:

Next Question

Previous Q... Tag Questi... Feedback End Session

Blog About Pastest Contact Us Help

© Pastest 2019

A 49-year-old diabetic patient is on the ward for investigation of abdominal pain. You are asked to see her blood results on the computer during the night shift.

Review of her medical notes on the ward reveals she has a background of nephropathy, neuropathy and ischaemic heart disease. She is currently taking gliclazide, metformin, atorvastatin, lisinopril, aspirin and bisoprolol.

While on the ward, she developed a urinary tract infection (UTI) and was commenced on trimethoprim. She is being investigated for abdominal pain and recently had an abdominal ultrasound scan and contrast-enhanced computed tomography (CT) performed, which have revealed a solitary left adrenal nodule.

Blood results show:

Today		Yesterday	
Sodium (Na^+)	138 mmol/l	Na^+	139 mmol/l
Potassium (K^+)	4.3 mmol/l	K^+	4.4 mmol/l
Urea	19.4 mmol/l	Urea	12.1 mmol/l
Creatinine (Cr)	210 µmol/l	Cr	129 µmol/l
Bicarbonate	16 mmol/l	Bicarbonate	26 mmol/l

Her trimethoprim dose is reduced on account of the creatinine rise.

What is the most appropriate next management step?

A Intravenous (iv) antibiotics

B iv fluids with furosemide to encourage diuresis

C iv fluids and omit metformin, lisinopril

D Referral for dialysis

10:59
NC ...
MyPastest
https://mypastest.pastest.com

revealed a solitary left adrenal nodule.

Blood results show:

Today		Yesterday	
Sodium (Na^+)	138 mmol/l	Na^+	139 mmol/l
Potassium (K^+)	4.3 mmol/l	K^+	4.4 mmol/l
Urea	19.4 mmol/l	Urea	12.1 mmol/l
Creatinine (Cr)	210 µmol/l	Cr	129 µmol/l
Bicarbonate	16 mmol/l	Bicarbonate	26 mmol/l

Her trimethoprim dose is reduced on account of the creatinine rise.

What is the most appropriate next management step?

A Intravenous (iv) antibiotics

B iv fluids with furosemide to encourage diuresis

C iv fluids and omit metformin, lisinopril

D Referral for dialysis

E Sodium bicarbonate

Submit

blood results on the computer during the night shift.

Review of her medical notes on the ward reveals she has a background of nephropathy, neuropathy and ischaemic heart disease. She is currently taking gliclazide, metformin, atorvastatin, lisinopril, aspirin and bisoprolol.

While on the ward, she developed a urinary tract infection (UTI) and was commenced on trimethoprim. She is being investigated for abdominal pain and recently had an abdominal ultrasound scan and contrast-enhanced computed tomography (CT) performed, which have revealed a solitary left adrenal nodule.

Blood results show:

Today		Yesterday	
Sodium (Na^+)	138 mmol/l	Na^+	139 mmol/l
Potassium (K^+)	4.3 mmol/l	K^+	4.4 mmol/l
Urea	19.4 mmol/l	Urea	12.1 mmol/l
Creatinine (Cr)	210 µmol/l	Cr	129 µmol/l
Bicarbonate	16 mmol/l	Bicarbonate	26 mmol/l

Her trimethoprim dose is reduced on account of the creatinine rise.

What is the most appropriate next management step?

Your answer was correct

A Intravenous (iv) antibiotics

B iv fluids with furosemide to encourage diuresis

C iv fluids and omit metformin, lisinopril

D Referral for dialysis

E Sodium bicarbonate

Explanation

C iv fluids and omit metformin, lisinopril

The patient has worsening renal impairment and is developing an acidosis. Most likely, this is due to contrast-induced nephropathy combined with her medications. She is at risk of metformin-induced lactic acidosis, and her medications would have to be omitted. The effects of this would not be immediate, and she would need hydration with iv fluids and close monitoring of her renal function.

A Intravenous (iv) antibiotics

Antibiotics have no role to play in contrast-induced nephropathy.

B iv fluids with furosemide to encourage diuresis

Furosemide is incorrect, as this may increase the risk of contrast nephropathy.

D Referral for dialysis

As the scenario is potentially reversible, she should not require dialysis at this time. There are no data on how many patients who have contrast nephropathy require dialysis. In fact, recently it has been thought that contrast nephropathy is not as common as we think it is.

E Sodium bicarbonate

The evidence for prevention of contrast nephropathy is iv fluid; sodium bicarbonate is contentious.

B	iv fluids with furosemide to encourage diuresis

Furosemide is incorrect, as this may increase the risk of contrast nephropathy.

D	Referral for dialysis

As the scenario is potentially reversible, she should not require dialysis at this time. There are no data on how many patients who have contrast nephropathy require dialysis. In fact, recently it has been thought that contrast nephropathy is not as common as we think it is.

E	Sodium bicarbonate

The evidence for prevention of contrast nephropathy is iv fluid; sodium bicarbonate is contentious.

For further reference:

Weisbord S D et al. 2018. Outcomes after angiography with sodium bicarbonate and acetylcysteine. The New England Journal of Medicine, 378, 603-614.

Rate this question:

© Pastest 2019

3G 11:01
NC ...

A 62-year-old man, who has been managed with long-term haemodialysis for end-stage kidney disease as a result of type 1 diabetes, presents to the clinic complaining of pain and tingling in his hands, particularly in the early hours of the morning. He also has trouble with dysphagia and indigestion, and echocardiography performed for decreased LV function revealed a suspicion of early constrictive pericarditis.

On further questioning, he also admits to drinking a glass of whisky each evening.

On examination, he has weakness of thumb abduction, apposition and flexion, and there is suspicion of some sensory loss.

Investigations:

Hb	10.1 g/dl
WCC	4.3×10^9/l
PLT	192×10^9/l
Na^+	139 mmol/l
K^+	4.7 mmol/l
Creatinine	421 μmol/l
Urate	0.54 mmol/l
Glucose	9.2 mmol/l

Which of the following is the most likely cause of his upper limb neurological symptoms?

A	Alcoholic neuropathy
B	B_{12} deficiency

Rana Alnasser's screen

On further questioning, he also admits to drinking a glass of whisky each evening.

On examination, he has weakness of thumb abduction, apposition and flexion, and there is suspicion of some sensory loss.

Investigations:

Hb	10.1 g/dl
WCC	4.3×10^9/l
PLT	192×10^9/l
Na^+	139 mmol/l
K^+	4.7 mmol/l
Creatinine	421 µmol/l
Urate	0.54 mmol/l
Glucose	9.2 mmol/l

Which of the following is the most likely cause of his upper limb neurological symptoms?

A Alcoholic neuropathy

B B_{12} deficiency

C Carpal tunnel syndrome

D Diabetic neuropathy

E Uraemic neuropathy

3G 11:03
NC ...

Explanation

C Carpal tunnel syndrome

Evidence of GI involvement, constrictive pericarditis and thenar weakness with sensory loss is suggestive of beta-2 microglobulin deposition. Indigestion and symptoms of reflux occur due to disordered gut motility as a result of amyloid deposition in the GI tract. In the normally functioning kidney, beta-2 microglobulin is cleared by glomerular filtration and catabolised in the proximal tubules. In patients with end-stage kidney disease, particularly those who have undergone long-term dialysis, accumulation occurs and the symptoms of systemic amyloidosis develop. High-flux biocompatible dialysis membranes may reduce accumulation of beta-2 microglobulin, and renal transplantation can lead to a gradual reduction in symptoms, but unfortunately those with significant multi-system disease may be considered unfit for surgical intervention. The carpal tunnel syndrome seen here is associated with peripheral beta-2 microglobulin deposition.

A Alcoholic neuropathy

The other symptoms, such as constrictive pericarditis, do not fit with alcoholic neuropathy.

B B_{12} deficiency

Vitamin B_{12} deficiency may result in sensory or motor deficiencies (absent reflexes, diminished vibration or soft touch sensation), subacute combined degeneration of the spinal cord, seizures and dementia.

D Diabetic neuropathy

A Alcoholic neuropathy

The other symptoms, such as constrictive pericarditis, do not fit with alcoholic neuropathy.

B B_{12} deficiency

Vitamin B_{12} deficiency may result in sensory or motor deficiencies (absent reflexes, diminished vibration or soft touch sensation), subacute combined degeneration of the spinal cord, seizures and dementia.

D Diabetic neuropathy

Diabetic neuropathy occurs after many years of diabetes and is mainly a sensory neuropathy.

E Uraemic neuropathy

Uraemic neuropathy is a distal sensorimotor polyneuropathy caused by uraemic toxins. There is evidence that the severity of the kidney disease is related to the severity of the neuropathy.

Rate this question:

Next Question

© Pastest 2019

11:05
594-042-7551 Leave

A 42-year-old man, who has received long-term haemodialysis for chronic kidney disease due to type 1 diabetes, presents for review. He has been suffering pain and tingling in both hands, which particularly comes on during the early hours of the morning. He has also noticed shoulder pain over the past few months. He is dialysed using a conventional cellulose acetate dialysis membrane.

On physical examination, there is no obvious structural deformity in the hands. An X-ray of both hands is ordered and it shows a destructive arthropathy with periarticular cystic bone radiolucencies.

Which of the following diagnoses fits best with this clinical picture?

A	Uraemic neuropathy
B	Diabetic nephropathy
C	AA amyloidosis
D	AL amyloidosis
E	Beta 2 microglobulin amyloidosis

Submit

Audio Video Share Participants More

11:21

A 42-year-old man, who has received long-term haemodialysis for chronic kidney disease due to type 1 diabetes, presents for review. He has been suffering pain and tingling in both hands, which particularly comes on during the early hours of the morning. He has also noticed shoulder pain over the past few months. He is dialysed using a conventional cellulose acetate dialysis membrane.

On physical examination, there is no obvious structural deformity in the hands. An X-ray of both hands is ordered and it shows a destructive arthropathy with periarticular cystic bone radiolucencies.

Which of the following diagnoses fits best with this clinical picture?

Your answer was correct

A	Uraemic neuropathy
B	Diabetic nephropathy
C	AA amyloidosis
D	AL amyloidosis
E	Beta 2 microglobulin amyloidosis

Explanation

E	Beta 2 microglobulin amyloidosis

Rana Alnasser's screen

Explanation

E Beta 2 microglobulin amyloidosis

Conventional dialysis membranes cannot clear substances with molecular weights of >200 dalton. These allow accumulation of beta-2 microglobulin, which has a molecular weight of 11,800 dalton. A normal functioning kidney would filter this in the glomerulus and it is catalysed in the proximal tubule. In some patients dialysed for more than 5 years on a conventional membrane, accumulation of beta-2 microglobulin amyloid leads to carpal tunnel syndrome, tenosynovitis, scapulohumeral arthropathy, bony cysts and even pathological fractures. GI or cardiovascular manifestations may occur. The mainstays of management are moving towards polyacrylnitrile or polysulphone dialysis membranes, which are higher flux and allow beta-2 microglobulin to be removed, or moving to transplant if a kidney is available. Other forms of renal amyloidosis occur in association with systemic inflammation, such as in rheumatoid arthritis, or haematological malignancies, such as myeloma. Aggressive use of secondary agents may slow deposition of amyloid in inflammatory conditions, as may chemotherapy in conditions such as myeloma.

A Uraemic neuropathy

Similar to diabetic neuropathy, uraemia may lead to neuropathy and hence a neuropathic arthropathy may result in dialysis patients. This is rare and there would be joint deformity with X-ray findings of joint destruction rather than bony cystic changes.

B Diabetic nephropathy

Diabetic nephropathy is likely to be the underlying renal

11:22

C AA amyloidosis

AA amyloidosis may be secondary to causes such rheumatoid arthritis, ankylosing spondylitis, psoriatic arthritis and juvenile arthritis. This is due to the chronic inflammation. These rheumatic conditions may be a cause of joint pain. However, there is no history to suggest rheumatic disease in this scenario. Also, there may be characteristic X-ray signs for these rheumatoid conditions; for instance, X-ray of the hands may show soft tissue swelling and early erosions in the proximal interphalangeal joints. It would not be the bony cystic destruction as seen here.

D AL amyloidosis

AL amyloidosis is due to immunoglobulin light chain production. The musculoskeletal manifestations may include muscle weakness and myopathy with arthropathy and osteopathy. There is no history in this case to suggest that this patient has myeloma, such as light chains in the urine or immunoparesis.

Rate this question:

Next Question

Previous Q... Tag Questi... Feedback End Session

Blog About Pastest Contact Us Help

© Pastest 2019

Rana Alnasser's screen

11:22

A 62-year-old man is referred to the Renal Clinic with swollen ankles. His GP is managing him for hypertension and he is currently managed with ramipril, indapamide and amlodipine. The GP is concerned as he noticed 3+ of proteinuria on dipstick testing.

On examination in the clinic, is BP is 149/91 mmHg, with pulse is 88 bpm and regular. He has bilateral pitting oedema.

Investigations:

Hb	11.4 g/dl
WCC	5.9×10^9/l
PLT	201×10^9/l
Na^+	138 mmol/l
K+	4.9 mmol/l
Creatinine	175 µmol/l
Ca^{++}	2.1 mmol/l
IgA	0.7 g/l (0.8-3.0)
IgG	8.9 g/l (6.0-13.0)
IgM	1.0 g/l (0.4-2.5)
24 h urinary protein	3.5 g

Which of the following is the most likely primary diagnosis?

A Myeloma kidney

B Membranous nephropathy

C AL amyloidosis

Rana Alnasser's screen

11:24

MyPastest
https://mypastest.pastest.com

Pastest+

Investigations:

Hb	11.4 g/dl
WCC	5.9×10^9/l
PLT	201×10^9/l
Na^+	138 mmol/l
K+	4.9 mmol/l
Creatinine	175 µmol/l
Ca^{++}	2.1 mmol/l
IgA	0.7 g/l (0.8-3.0)
IgG	8.9 g/l (6.0-13.0)
IgM	1.0 g/l (0.4-2.5)
24 h urinary protein	3.5 g

Which of the following is the most likely primary diagnosis?

A Myeloma kidney

B Membranous nephropathy

C AL amyloidosis

D Minimal change disease

E Focal segmental glomerulosclerosis

Explanation

B Membranous nephropathy

In this particular age group, membranous nephropathy is the most likely diagnosis (as opposed to minimal change disease, which presents in younger individuals), with the insidious onset as seen here typical of the presentation. Whilst membranous nephropathy may be associated with malignancy, in fact only 5-10% of cases are associated with an underlying cancer. Autoimmune pathology, infectious diseases and drugs may also be associated with the development of the condition.

A Myeloma kidney

In the presence of near-normal immunoglobulins, (IgA is only very slightly reduced), myeloma kidney is not likely to be the underlying diagnosis.

C AL amyloidosis

Given the lack of associated chronic disease, amyloidosis is unlikely. AL amyloidosis is caused by monoclonal light chains (usually lambda) or light-chain fragments produced by a plasma cell dyscrasia that forms amyloid sheets. It is more common in men than women, by a ratio of 2:1, and most frequently in patients >50 years of age.

D Minimal change disease

Minimal change disease is a more common cause of nephrotic syndrome in young children. The renal biopsy is normal on light microscopy and immunofluorescence is negative. Electron microscopy reveals diffuse effacement of podocyte foot processes

11:27
594-042-7551 Leave

In the presence of near-normal immunoglobulins, (IgA is only very slightly reduced), myeloma kidney is not likely to be the underlying diagnosis.

C AL amyloidosis

Given the lack of associated chronic disease, amyloidosis is unlikely. AL amyloidosis is caused by monoclonal light chains (usually lambda) or light-chain fragments produced by a plasma cell dyscrasia that forms amyloid sheets. It is more common in men than women, by a ratio of 2:1, and most frequently in patients >50 years of age.

D Minimal change disease

Minimal change disease is a more common cause of nephrotic syndrome in young children. The renal biopsy is normal on light microscopy and immunofluorescence is negative. Electron microscopy reveals diffuse effacement of podocyte foot processes.

E Focal segmental glomerulosclerosis

Focal segmental glomerulosclerosis (FSGS) could be a differential for proteinuria, but it is less common than membranous disease. The cause is unknown and presentation is proteinuria with microscopic haematuria and hypertension. Impaired renal function is common. It is more common in young black males. There is often profound hypoalbuminaemia (albumin <20 g/l) and renal impairment running a severe course, leading to chronic kidney disease.

21222

Rate this question:

Next Question

Audio Video Share Participants More

3G 11:27
NC ...

A 27-year-old dancer comes to the Emergency Department because of severe pain in her left side and dark urine. The patient denies fever but states that the general practitioner (GP) had seen her several days ago for urinary frequency and burning. She had been treated with trimethoprim at that time, and the dysuria had resolved.

The pain now comes on very suddenly, and the paroxysms are so severe that walking is not possible. There is some nausea and the patient had vomited twice. The pain radiates to her groin. The patient's vital signs are a temperature of 37.2 °C, a blood pressure of 110/70 mmHg, a pulse rate of 95 bpm and a respiratory rate of 14 breaths per min.

Physical examination of the chest and heart is normal. The abdomen is soft and non-tender, with no guarding. Analgesia is given.

Investigations reveal:

Creatinine (Cr)	80 μmol/l
Urea	5.0 mmol/l
Haemoglobin (Hb)	12.0 g/dl
Potassium (K^+)	4.0 mmol/l
Corrected calcium	2.60 mmol/l
White cell count (WCC)	10×10^9/l
Erythrocyte sedimentation rate (ESR)	10 mm/h

Which of the following is the most appropriate early treatment?

A Hydration

B Intravenous (iv) broad-spectrum antibiotics

Rana Alnasser's screen

a pulse rate of 95 bpm and a respiratory rate of 14 breaths per min.

Physical examination of the chest and heart is normal. The abdomen is soft and non-tender, with no guarding. Analgesia is given.

Investigations reveal:

Creatinine (Cr)	80 μmol/l
Urea	5.0 mmol/l
Haemoglobin (Hb)	12.0 g/dl
Potassium (K^+)	4.0 mmol/l
Corrected calcium	2.60 mmol/l
White cell count (WCC)	10×10^9/l
Erythrocyte sedimentation rate (ESR)	10 mm/h

Which of the following is the most appropriate early treatment?

A Hydration

B Intravenous (iv) broad-spectrum antibiotics

C iv furosemide

D Lithotripsy

E Percutaneous removal of stones

Submit

11:30

A Hydration

Kidney stones form when there is a high level of calcium (hypercalciuria), oxalate (hyperoxaluria) or uric acid (hyperuricosuria) in the urine; a lack of citrate in the urine; or insufficient water in the kidneys to dissolve waste products. The kidneys must maintain an adequate amount of water in the body to remove waste products. If dehydration occurs, high levels of substances that do not dissolve completely (eg calcium, oxalate, uric acid) may form crystals that slowly build up into kidney stones.

Urine normally contains chemicals (including citrate, magnesium and pyrophosphate) that prevent the formation of crystals. Low levels of these inhibitors can contribute to the formation of kidney stones. Of these, citrate is thought to be the most important. Approximately 80–85% of stones pass spontaneously. Approximately 20% of patients require hospital admission because of unrelenting pain, inability to retain enteral fluids, proximal urinary tract infection (UTI) or inability to pass the stone.

A ureteral stone associated with obstruction and an upper UTI is a true urological emergency. Complications include perinephric abscess, urosepsis and death. Immediate involvement of the urologist is essential. Diagnosis includes: blood tests, urinalysis, X-rays, iv urography and ultrasound scan. Treatment depends on the type and cause of the stone. The usual initial treatment is hydration and analgesia, which allows spontaneous passage of stones in the majority of patients.

B Intravenous (iv) broad-spectrum antibiotics

Broad-spectrum antibiotics would only be useful if there is an infection. In this scenario, there is no history to suggest an infection - the patient is apyrexial, the WCC is normal and the ESR is not raised.

Rana Alnasser's screen

11:33

MyPastest
https://mypastest.pastest.com

B Intravenous (iv) broad-spectrum antibiotics

Broad-spectrum antibiotics would only be useful if there is an infection. In this scenario, there is no history to suggest an infection - the patient is apyrexial, the WCC is normal and the ESR is not raised.

C iv furosemide

iv furosemide would exacerbate the situation in renal stones. This is because there would be hypercalciuria with furosemide if the stones are due to calcium; then this would increase the deposits.

D Lithotripsy

For those patients whose stones do not pass, methods of stone removal including lithotripsy approaches may be considered. However, in this case, the first treatment is fluids, and most small stones will pass on their own.

E Percutaneous removal of stones

For those patients whose stones do not pass, methods of stone removal including percutaneous removal of stones may be considered. However, in this case, the first treatment is fluids, and most small stones will pass on their own.

Rate this question:

Next Question

Rana Alnasser's screen

A 45-year-old man with a history of IgA nephropathy comes to the Renal Clinic. He has a history of microscopic haematuria and proteinuria which has been under follow-up for 10 years, and a recent renal biopsy has suggested IgA nephropathy with extensive sclerosis.

On examination, he has a BP of 158/92 mmHg and has bilateral ankle oedema.

Investigations:

Hb	11.3 g/dl
WCC	6.1×10^9/l
PLT	201 × 109/l
Na^+	139 mmol/l
K^+	4.8 mmol/l
Creatinine	280 µmol/l
PTH	10 pmol/l (0.9-5.4)
24 h urinary protein	4.7 g

Which of the following is the most important additional therapy for him?

A Vitamin D

B Sevelamer

C Ramipril

D Atenolol

E Prednisolone and azathioprine

C Ramipril

D Atenolol

E Prednisolone and azathioprine

Explanation

C Ramipril

This man has a well-established glomerulosclerosis related to his IgA nephropathy with impaired renal function; as such, aggressive immunosuppressive therapy is less likely than improved blood pressure control to have a significant impact on his prognosis. Among available blood pressure agents, ACE inhibitors are thought to have the greatest effect in reducing progression of proteinuria and worsening of creatinine.

A Vitamin D

Vitamin D would not be a treatment in IgA nephropathy. Many patients with renal disease are vitamin D deficient, and therefore it would be useful for measurement and replacement with vitamin D if levels are low. This is especially if patients have symptoms of lethargy.

B Sevelamer

Sevelamer is a phosphate binder, and we aren't given information on calcium/phosphate status here, but the PTH is within twice the upper limit of normal. Guidelines only recommend treating PTH when it is above twice the upper limit of normal because of the risk of adynamic bone disease

A Vitamin D

Vitamin D would not be a treatment in IgA nephropathy. Many patients with renal disease are vitamin D deficient, and therefore it would be useful for measurement and replacement with vitamin D if levels are low. This is especially if patients have symptoms of lethargy.

B Sevelamer

Sevelamer is a phosphate binder, and we aren't given information on calcium/phosphate status here, but the PTH is within twice the upper limit of normal. Guidelines only recommend treating PTH when it is above twice the upper limit of normal because of the risk of adynamic bone disease.

D Atenolol

Atenolol would be useful to control blood pressure. However, the evidence is for use of ACEI for the reduction of proteinuria and worsening of creatinine in IgA nephropathy.

E Prednisolone and azathioprine

Because glomerulosclerosis is established, aggressive immunosuppressive therapy is less likely than improved blood pressure control to have a significant impact on his prognosis. Prednisolone and azathioprine may be considered if there are crescents in the biopsy or if there is active disease with rapidly worsening renal impairment.

Rate this question:

Next Question

A 42-year-old man with severe acute left-sided flank pain is referred by his GP to Accident and Emergency. This is the first time he has had such severe sudden pain. He has no past medical history of cardiovascular or renal disease, his brother died of a subarachnoid haemorrhage.

On examination, his blood pressure is 170/100 mmHg, pulse 78 bpm and regular. His jugular venous pressure (JVP) is not raised, heart sounds are normal and his chest is clear. His liver is not palpable but he has a mass in the left flank. The mass is bimanually palpable and you can get above it.

Blood results are as follows:

Na^+	143 mmol/l
K^+	4.2 mmol/l
Urea	10.2 mmol/l
Creatinine	205 μmol/l
Hb	15.0 g/dl
WCC	5.1×10^9/l
MCV	81 fl
Platelets	243×10^9 /l
ESR	8 mm/h
Urine dipstick	Blood +++, protein +

Which is the most useful investigation to request?

A CT scan of the abdomen

B Intravenous urogram (IVU)

C MRI scan of the abdomen

On examination, his blood pressure is 170/100 mmHg, pulse 78 bpm and regular. His jugular venous pressure (JVP) is not raised, heart sounds are normal and his chest is clear. His liver is not palpable but he has a mass in the left flank. The mass is bimanually palpable and you can get above it.

Blood results are as follows:

Na^+	143 mmol/l
K^+	4.2 mmol/l
Urea	10.2 mmol/l
Creatinine	205 μmol/l
Hb	15.0 g/dl
WCC	5.1×10^9/l
MCV	81 fl
Platelets	243×10^9 /l
ESR	8 mm/h
Urine dipstick	Blood +++, protein +

Which is the most useful investigation to request?

A CT scan of the abdomen

B Intravenous urogram (IVU)

C MRI scan of the abdomen

D Ultrasound of the abdomen

E Urine microscopy

E Urine microscopy

Explanation

D Ultrasound of the abdomen

Ultrasound of the abdomen is easily performed, non-invasive and plays a critical diagnostic role. The suspicion here would be one of polycystic kidney disease. There is an association with Berry aneurysm which may well have resulted in the death of his brother. Aggressive management of hypertension is the most appropriate way to prevent or at least slow the accelerated deterioration in renal function associated with this condition.

A CT scan of the abdomen

CT scan of the abdomen is incorrect. Although a CT scan of the abdomen would also show polycysts in the kidneys, it would not be as easily performed compared with ultrasound. It would also expose the patient to radiation.

B Intravenous urogram (IVU)

Intravenous urogram (IVU) is incorrect. IVU may be normal in polycystic kidney disease. There would be associated unnecessary contrast exposure.

C MRI scan of the abdomen

MRI scan of the abdomen is incorrect. MRI compared with ultrasound abdomen is more difficult to perform. There is nephrogenic systemic fibrosis with the use of contrast agent in MRI scans in patients with kidney disease.

E Urine microscopy

It would not be as easily performed compared with ultrasound. It would also expose the patient to radiation.

B Intravenous urogram (IVU)

Intravenous urogram (IVU) is incorrect. IVU may be normal in polycystic kidney disease. There would be associated unnecessary contrast exposure.

C MRI scan of the abdomen

MRI scan of the abdomen is incorrect. MRI compared with ultrasound abdomen is more difficult to perform. There is nephrogenic systemic fibrosis with the use of contrast agent in MRI scans in patients with kidney disease.

E Urine microscopy

Urine microscopy is incorrect. The urine microscopy would typically be normal in polycystic kidney disease unless there are associated complications such as bleeding in the cysts where there may be haematuria.

Rate this question:

Next Question

Previous Q... Tag Questi... Feedback End Session

Blog About Pastest Contact Us Help

© Pastest 2019

A 37-year-old woman presents with a 2-week history of malaise, bruising, and altered bowel habit. She has no past medical history of note and is on no medications.

Systemic examination is unremarkable. Urine output for the past 2 hours was 180 ml.

Investigations;

Hb	6.2 g/dl
Haematocrit	0.24
Platelets	56 × 109/l
Blood film	Fragmented red cells
Urea	14 mmol/l
Creatinine	236 µmol/l

What is the best treatment option?

A Transfusion with packed red cells to aim for a haemoglobin of 10 g/dl

B Intravenous vitamin K

C Intravenous Tranexamic acid

D Intravenous fresh frozen plasma

E Haemodialysis

Submit

A 37-year-old woman presents with a 2-week history of malaise, bruising, and altered bowel habit. She has no past medical history of note and is on no medications.

Systemic examination is unremarkable. Urine output for the past 2 hours was 180 ml.

Investigations;

Hb	6.2 g/dl
Haematocrit	0.24
Platelets	56 × 109/l
Blood film	Fragmented red cells
Urea	14 mmol/l
Creatinine	236 µmol/l

What is the best treatment option?

Your answer was correct

A Transfusion with packed red cells to aim for a haemoglobin of 10 g/dl

B Intravenous vitamin K

C Intravenous Tranexamic acid

D Intravenous fresh frozen plasma

E Haemodialysis

Explanation

Explanation

D	Intravenous fresh frozen plasma

Acute kidney injury (AKI), anaemia and thrombocytopaenia with fragmented red cells are diagnostic of haemolyticuraemic syndrome (HUS) in the absence of neurological signs. It is commonly associated with a diarrhoeal illness. Treatment is supportive. The first-line therapy is infusion of fresh frozen plasma or plasma exchange, the latter especially if there is neurological involvement or if the patient is oligo-anuric. Treatment efficacy can be monitored by measurement of plasma LDH.

A	Transfusion with packed red cells to aim for a haemoglobin of 10 g/dl

Transfusion with packed red cells to aim for a haemoglobin of 10 g/dl is incorrect. The use of plasma infusion (to supply a missing anticoagulant factor) or plasma exchange (to supply a missing anticoagulant factor and/or remove procoagulant factor) has been successful in many patients with complement-mediated HUS. Based upon clinical experience, packed red cells should be transfused when the hemoglobin (Hgb) level is <6 g/dl or hematocrit <18%. A post-transfusion goal of an Hgb level between 8 and 9 g/dl is recommended to prevent cardiac and pulmonary complications resulting from high output cardiac failure.

B	Intravenous vitamin K

There is no known role for vitamin K.

C	Intravenous Tranexamic acid

There is no known role for Tranexamic acid

11:44

MyPastest
https://mypastest.pastest.com

Pastest+

Transfusion with packed red cells to aim for a haemoglobin of 10 g/dl is incorrect. The use of plasma infusion (to supply a missing anticoagulant factor) or plasma exchange (to supply a missing anticoagulant factor and/or remove procoagulant factor) has been successful in many patients with complement-mediated HUS. Based upon clinical experience, packed red cells should be transfused when the hemoglobin (Hgb) level is <6 g/dl or hematocrit <18%. A post-transfusion goal of an Hgb level between 8 and 9 g/dl is recommended to prevent cardiac and pulmonary complications resulting from high output cardiac failure.

B Intravenous vitamin K

There is no known role for vitamin K.

C Intravenous Tranexamic acid

There is no known role for Tranexamic acid.

E Haemodialysis

This would only be indicated if the patient is oligo-anuric and not responding to specific treatment.

70069

Rate this question:

Next Question

Previous Q... Tag Questi... Feedback End Session

An 18-year-old woman who works at a local day nursery is admitted to the Emergency Department with a severe headache and weakness affecting the left-hand side of her face. She has been unwell for the past few days with headaches, anorexia and diarrhoea. Apparently, she has eaten the same food as a number of children at the nursery who have fallen ill with diarrhoea - two of whom are in the local hospital with kidney disease.

On examination, her BP is 155/90 mmHg; pulse is 85/min and regular. There is evidence of a purpuric rash and petechial haemorrhages. Abdomen is soft and generally tender, and she has active bowel sounds. You confirm left upper motor neurone 7th nerve palsy.

Investigations:

Hb	9.9 g/dl (schistocytes on blood film)
WCC	12.1×10^9/l
PLT	32×10^9/l
Na^+	137 mmol/l
K^+	5.2 mmol/l
Creatinine	141 µmol/l
Lactate dehydrogenase	950 U/l
Urine	Blood ++ protein ++

Which of the following is the most appropriate intervention?

A Ciprofloxacin

B Intravenous immunoglobulin

petechial haemorrhages. Abdomen is soft and generally tender, and she has active bowel sounds. You confirm left upper motor neurone 7th nerve palsy.

Investigations:

Hb	9.9 g/dl (schistocytes on blood film)
WCC	12.1×10^9/l
PLT	32×10^9/l
Na^+	137 mmol/l
K^+	5.2 mmol/l
Creatinine	141 µmol/l
Lactate dehydrogenase	950 U/l
Urine	Blood ++ protein ++

Which of the following is the most appropriate intervention?

A Ciprofloxacin

B Intravenous immunoglobulin

C Intravenous methylprednisolone

D Plasma exchange

E Platelet transfusion

Submit

Rana Alnasser's screen

D Plasma exchange

The history and blood picture seen here is consistent with thrombotic thrombocytopenic purpura (TTP). TTP is a rare blood disorder that features extensive microscopic clots that form in the small blood vessels throughout the body causing damage to the kidneys, heart and brain. Most cases of TTP arise from autoantibody-mediated inhibition of the enzyme ADAMTS13, a metalloprotease responsible for cleaving large multimers of von Willebrand factor (vWF) into smaller units. The increase in circulating multimers of vWF increases platelet adhesion to areas of endothelial injury, particularly at arteriole–capillary junctions. Haemolytic uraemic syndrome has a similar pathogenic process, although it presents with predominant renal impairment rather than neurological dysfunction.

Plasma exchange is the initial therapy of choice, which has been associated with a reduction in mortality rate to less than 25% since its introduction.

A Ciprofloxacin

Ciprofloxacin has no role to play in the treatment of TTP. Ciprofloxacin would be useful in infection; however, there is no indication of infection in this scenario.

B Intravenous immunoglobulin

Fresh frozen plasma (FFP) is a potential interim solution until plasma exchange is available, but there is no role for intravenous immunoglobulin therapy.

C Intravenous methylprednisolone

There is no evidence that corticosteroids or antibiotics have any benefit in the management of TTP. Current therapy is based on support and plasmapheresis to reduce circulating antibodies against ADAMTS13 and replenish

until plasma exchange is available, but there is no role for intravenous immunoglobulin therapy.

C	Intravenous methylprednisolone

There is no evidence that corticosteroids or antibiotics have any benefit in the management of TTP. Current therapy is based on support and plasmapheresis to reduce circulating antibodies against ADAMTS13 and replenish blood levels of the enzyme. Methylprednisolone will not reduce the levels of the circulating antibodies.

E	Platelet transfusion

Platelet transfusion is contraindicated unless there is life-threatening haemorrhage, although platelets are consumed and there is typically a thrombocytopenia in TTP. The diagnostic criteria for TTP includes fevers, change in mental status, a low platelet count, decreased renal function and anaemia due to shearing by blood clots in the small blood vessels (microangiopathic haemolytic anaemia).

Rate this question:

© Pastest 2019

An 18-year-old girl presented with a 3-day history of fever, abdominal pain, diarrhoea and vomiting. She had returned from holiday in Morocco 1 week ago. She has no significant past medical history and she was well while on holiday.

On examination, she is unwell and slightly jaundiced. There is no lymphadenopathy and abdominal examination was normal. Temperature was 37.8 °C, blood pressure was 98/56 mmHg, pulse of 110 beats/min and Glasgow Coma score of 15/15.

Investigations are shown below:

Haemoglobin (Hb)	6.9 g/l
White cell count (WCC)	15×10^9 g/l
Platelets	22×10^9/l
Mean corpuscular volume (MCV)	86 fl
Reticulocyte count	160×10^9/l ($25–100 \times 10^9$/l)
Blood film	Multiple fragmented red cells
Sodium	134 mmol/l
Potassium	4.5 mmol/l
Urea	21.5 mmol/l
Creatinine	350 µmol/l
Bilirubin	58 µmol/l
Lactate dehydrogenase	300 IU/l (70–250 IU/l)
Aspartate transaminase	38 IU/l
Alanine aminotransferase	36 IU/l

What is the most likely underlying diagnosis?

11:48
594-042-7551 Leave

(MCV)	
Reticulocyte count	160 × 10^9/l (25–100 ×10^9/l)
Blood film	Multiple fragmented red cells
Sodium	134 mmol/l
Potassium	4.5 mmol/l
Urea	21.5 mmol/l
Creatinine	350 µmol/l
Bilirubin	58 µmol/l
Lactate dehydrogenase	300 IU/l (70–250 IU/l)
Aspartate transaminase	38 IU/l
Alanine aminotransferase	36 IU/l

What is the most likely underlying diagnosis?

A Thrombotic thrombocytopaenic purpura (TTP)

B Leptospirosis

C Familial Mediterranean fever

D Haemolytic-uraemic syndrome (HUS)

E Acute hepatitis B infection

Submit

Audio Video Share Participants 1 More

11:48
594-042-7551 Leave

manifestations (confusion, coma) and jaundice (elevated direct and indirect bilirubin). HUS often follows gastroenteritis associated with enterohaemorrhagic *Escherichia coli* 0157 and Shiga-toxin-producing bacteria such as *Shigella dysenteriae*.

A Thrombotic thrombocytopaenic purpura (TTP)

TTP and HUS are part of the same spectrum of microangiopathic disease. Similar to HUS, TTP is characterised by widespread deposition of loose strands of fibrin in multiple small blood vessels, which damage platelets and red blood cells (RBCs), resulting in microangiopathic haemolytic anaemia, disseminated intravascular coagulation and thrombocytopenia. In TTP, manifestation of ischaemic organ damage such as neurological disturbance (confusion and coma) and myocardial damage are characteristically found. TTP is differentiated from HUS by the following points:

- Children account for 90% of the cases of HUS, while adults are more frequently affected with TTP.
- Kidney disease and fever predominates in HUS, while in TTP neurological symptoms are more common.
- The prognosis is worse in TTP compared with HUS.
- Treatment is supportive with plasma exchange until the activity of the disease has subsided. Steroids are also beneficial.

B Leptospirosis

Leptospirosis is caused by a thin, spiral-shaped *Leptospira* bacterium, especially *Leptospira icterohaemorrhagiae*. There may be liver abnormalities with jaundice. Microangiopathic haemolytic anaemia is not a usual feature.

Audio Video Share Participants 1 More

11:48

You saw a 38-year-old man in your clinic two days ago with sore throat, cough and fever. He says that he has been feeling increasingly tired and lethargic over the past 3 weeks. You suspected upper respiratory tract infection and prescribed cephalexin, took some routine blood tests and asked the man to return in two days.

Today, in your clinic, he mentions that his urinary volume has decreased dramatically within the last few days, and he is only passing few millilitres of urine. His blood results show urea of 24 mmol/l and creatinine 186 µmol/l. Screening for streptococcal antigen is negative, and pANCA is positive.

You immediately admit him to the hospital, and repeat bloods today show urea of 38 mmol/l and creatinine of 372 µmol/l. His urine output in hospital is only 5–10 ml in past 2 h. The temperature is 38.3 °C. He has an erythematous oropharynx with tonsillar exudates. Urinanalyis shows red cell casts and dysmorphic red blood cells.

What is the most appropriate next step?

A	Administer broad-spectrum antibiotics
B	Administer penicillin intravenously
C	Give a low dose of methylprednisolone intravenously (IV)
D	Give a high dose of methylprednisolone IV and cyclophosphamide
E	Prescribe a high dose of ciclosporin

Rana Alnasser's screen

has decreased dramatically within the last few days, and he is only passing few millilitres of urine. His blood results show urea of 24 mmol/l and creatinine 186 µmol/l. Screening for streptococcal antigen is negative, and pANCA is positive.

You immediately admit him to the hospital, and repeat bloods today show urea of 38 mmol/l and creatinine of 372 µmol/l. His urine output in hospital is only 5–10 ml in past 2 h. The temperature is 38.3 °C. He has an erythematous oropharynx with tonsillar exudates. Urinanalyis shows red cell casts and dysmorphic red blood cells.

What is the most appropriate next step?

Your answer was correct

A	Administer broad-spectrum antibiotics
B	Administer penicillin intravenously
C	Give a low dose of methylprednisolone intravenously (IV)
D	Give a high dose of methylprednisolone IV and cyclophosphamide
E	Prescribe a high dose of ciclosporin

Explanation

D	Give a high dose of methylprednisolone IV and cyclophosphamide

This is rapidly progressive glomerulonephritis, the blood picture is suggestive of microscopic polyangiitis with granulomatosis. In adults, where the outcome is much worse, early initiation of a high dose of steroids has been

D Give a high dose of methylprednisolone IV and cyclophosphamide

This is rapidly progressive glomerulonephritis, the blood picture is suggestive of microscopic polyangiitis with granulomatosis. In adults, where the outcome is much worse, early initiation of a high dose of steroids has been associated with improved mortality and more rapid return of kidney function. Rapidly progressive glomerulonephritis (RPGN) is a disease of the kidney that results in a rapid decrease in the glomerular filtration rate of at least 50% over a short period (a few days to three months). The main pathological finding is fibrinoid necrosis (> 90% of biopsy specimens); extensive crescent formation is present in at least 50% of glomeruli. This type of glomerulonephritis is also known as crescenteric glomerulonephritis, after the 'crescents' seen on light microscopy. These crescents are collections of epithelial cells and macrophages within Bowman's space.

The presence of crescents indicates that glomerular damage is rapid and progressive (from onset to chronic kidney disease within weeks to months). Immunofluorescence detects deposits of immunoglobulin G (IgG) or complement factor C3 in the glomerular basement membrane. There are three distributions of immunofluorescence in crescentic glomerulonephritis:

- Absent immunofluorescence
- Granular immunofluorescence
- Linear immunofluorescence.
- Internationally: In the UK, the frequency is estimated at 2 cases per 100,000 persons. In Sweden, the frequency is estimated at 1 case per 100,000 persons. Massive pulmonary haemorrhage is the most common cause of death in patients presenting with ANCA-associated disease. However, once immunosuppressive therapy has begun, infection is

The presence of crescents indicates that glomerular damage is rapid and progressive (from onset to chronic kidney disease within weeks to months). Immunofluorescence detects deposits of immunoglobulin G (IgG) or complement factor C3 in the glomerular basement membrane. There are three distributions of immunofluorescence in crescentic glomerulonephritis:

- Absent immunofluorescence
- Granular immunofluorescence
- Linear immunofluorescence.
- Internationally: In the UK, the frequency is estimated at 2 cases per 100,000 persons. In Sweden, the frequency is estimated at 1 case per 100,000 persons. Massive pulmonary haemorrhage is the most common cause of death in patients presenting with ANCA-associated disease. However, once immunosuppressive therapy has begun, infection is more common. *The two major patterns of ANCA are:*
- Proteinase 3 – PR3-ANCA (formerly cytoplasmic or c-ANCA): positive in Wegener's granulomatosis in 90% of cases
- Myeloperoxidase – MPO-ANCA (formerly p-ANCA): positive in Churg–Strauss syndrome, and rarely reported as positive in PAN.
- Symptoms and signs of kidney disease: There may be loin pain, haematuria and systemic symptoms (fever, malaise, myalgia, weight loss). Renal biopsy specimens show a diffuse, proliferative, necrotising glomerulonephritis with crescent formation. High-dose corticosteroids, and cyclophosphamide ± plasma exchange/renal transplantation are the treatments. Prognosis is poor if initial creatinine > 600 μmol/l.

pyelonephritis then broad-spectrum antibiotics would be appropriate.

B	Administer penicillin intravenously

Penicillin is not a required treatment. If this scenario was pyelonephritis (i.e. no dysmorphic red cells in urine), with blood and protein in urine, fever and deranged renal function, then penicillin might be appropriate.

C	Give a low dose of methylprednisolone intravenously (IV)

Methylprednisolone is part of the treatment, but the full answer is corticosteroid and cyclophosphamide.

E	Prescribe a high dose of ciclosporin

Ciclosporin is not the immunosuppressant of choice initially. Ciclosporin may be used as a maintenance immunotherapy for membranous or minimal-change glomerulopathy.

Rate this question:

Next Question

© Pastest 2019

11:56

A 48-year-old man presents with painless microscopic haematuria discovered by his GP at a new patient medical. He also has vague right iliac fossa pain. There is a past history of tuberculosis and chest X-ray is suggestive of right apical fibrosis. His father died of a brain haemorrhage.

On examination, his blood pressure is 160/100 mmHg and there is appears to be a palpable mass on balloting the right kidney.

Investigations show:

Na^+	134 mmol/l
K^+	5.5 mmol/l
Urea	15 mmol/l
Creatinine	370 µmol/l
Hb	10.4 g/dl
WCC	5.1×10^9/l
PLT	243×10^9 /l
Plasma viscosity	Normal

Which of the following stems fits best with this diagnosis?

A Medullary sponge kidney

B Autosomal dominant polycystic kidney disease (APKD)

C Wilms' tumour

D Renal cell carcinoma

E Transitional cell carcinoma

Rana Alnasser's screen

Wilms' tumour (nephroblastoma) is a rare kidney cancer and it affects mainly children. In fact, it is the most common cancer in children.

D Renal cell carcinoma

Renal cell carcinoma is the commonest type of kidney cancer in adults, accounting for between 90% and 95% of cases. The classical triad of symptoms includes haematuria, flank pain and abdominal mass, although this triad of symptoms occurs in only 10–15% of patients and is usually associated with advanced disease. Mostly, nowadays, renal cell carcinoma is asymptomatic and detected incidentally when investigating for other conditions.

E Transitional cell carcinoma

This is also known as urothelial carcinoma; it is the most common type of bladder cancer and cancer of the ureter and urethra. This condition may asymptomatic or present with haematuria, back pain, weight loss, or painful or frequent urination. The normal viscosity, anaemia and hypertension are not due to transitional cell carcinoma.

Rate this question:

Next Question

Previous Q... Tag Questi... Feedback End Session

Blog About Pastest Contact Us Help

© Pastest 2019

Explanation

B Autosomal dominant polycystic kidney disease (APKD)

APKD may present at any age from the second decade with acute loin pain or haematuria due to cyst haemorrhage or infection, loin pain due to increased renal size, subarachnoid haemorrhage due to berry aneurysm rupture, complications of hypertension, complications of liver cyst formation or symptoms of chronic kidney disease. The picture seen here with mild anaemia, hypertension and a palpable right kidney points towards the diagnosis; the normal viscosity counts against renal cell carcinoma.

A Medullary sponge kidney

The diagnosis of medullary sponge kidney is based on the finding of dilated collecting ducts (precalyceal ducts) that may or may not contain calculi and/or nephrocalcinosis. The classic radiological appearance is described as 'papillary blush' or 'paint brush' on early and delayed films during intravenous urography.

C Wilms' tumour

Wilms' tumour (nephroblastoma) is a rare kidney cancer and it affects mainly children. In fact, it is the most common cancer in children.

D Renal cell carcinoma

Renal cell carcinoma is the commonest type of kidney cancer in adults, accounting for between 90% and 95% of cases. The classical triad of symptoms includes haematuria, flank pain and abdominal mass, although this triad of

11:59
594-042-7551 Leave

A 45-year-old man presents with a history of poor urine output over the past two days. He has recently returned from a holiday in Thailand, after which he had suffered diarrhoea about a week ago; otherwise he has no other significant history.

On examination, he had a blood pressure of 98/50 mmHg and a pulse rate of 110 bpm. A diagnosis is reached of haemolytic-uraemic syndrome associated with diarrhoea. Gram stain of the organism found in the stool is shown below.

What would be the most useful treatment for this patient?

A	Antibiotics
B	Diuretics
C	Heparin
D	Intravenous immunoglobulins
E	Supportive (dialysis, fluids, blood transfusions)

Audio Video Share Participants More

12:00

MyPastest
https://mypastest.pastest.com

diarrhoea about a week ago; otherwise
significant history.

On examination, he had a blood pressur
and a pulse rate of 110 bpm. A diagnosis
haemolytic-uraemic syndrome associat
Gram stain of the organism found in the
below.

What would be the most useful treatm

A Antibiotics

E Supportive (dialysis, fluids, blood transfusions)

Explanation

E Supportive (dialysis, fluids, blood transfusions)

Supportive treatment is the mainstay of treatment for haemolytic–uraemic syndrome (HUS). Although in some cases, plasma exchange will remove the inhibitor of the von Willebrand factor protease enzyme. About 70% of affected patients will recover with no long-term problems with supportive treatment alone.

A Antibiotics

There is no evidence that antibiotics will shorten the duration of illness in HUS. For infective diarrhoea, in general, giving antibiotics may prolong infection.

B Diuretics

Giving diuretics may potentially worsen the acute kidney disease by causing further hypotension. This man needs fluid resuscitation as evidenced by the low blood pressure and tachycardia.

C Heparin

Anticoagulation is contraindicated in HUS, particularly in children, because the condition is frequently complicated by both bleeding and hypertension. In adults, heparin increases mortality because of increased bleeding.

D Intravenous immunoglobulins

There is no role of immunoglobulin replacement in HUS.

Rana Alnasser's screen

12:01

MyPastest
https://mypastest.pastest.com

Pastest+

Willebrand factor protease enzyme. About 70% of affected patients will recover with no long-term problems with supportive treatment alone.

A Antibiotics

There is no evidence that antibiotics will shorten the duration of illness in HUS. For infective diarrhoea, in general, giving antibiotics may prolong infection.

B Diuretics

Giving diuretics may potentially worsen the acute kidney disease by causing further hypotension. This man needs fluid resuscitation as evidenced by the low blood pressure and tachycardia.

C Heparin

Anticoagulation is contraindicated in HUS, particularly in children, because the condition is frequently complicated by both bleeding and hypertension. In adults, heparin increases mortality because of increased bleeding.

D Intravenous immunoglobulins

There is no role of immunoglobulin replacement in HUS. There are some immune disorders whereby replacement of immunoglobulins may be useful such as multiple sclerosis, but not in this case.

Rate this question:

Next Question

A 25-year-old mechanic presents to his general practitioner (GP) with a 3-week history of worsening leg swelling. The rest of the history is unremarkable. He is on no medication.

Examination confirms pitting oedema to the thighs. Blood pressure is 125/63 mmHg with no postural drop.

Blood results are shown below (the sample was noted to be lipaemic):

Na^+	121 mmol/l
K^+	4.6 mmol/l
Urea	4.4 mmol/l
Creatinine	90 µmol/l
Albumin	17 g/l
Glucose	4.6 mmol/l
Plasma osmolality	280 mOsmol/kg
24 hour urinary protein	6.2 g

What investigation would help explain this patient's hyponatraemia?

A Plasma antidiuretic hormone

B Plasma lipids

C Spot urinary sodium

D Short synacthen test

E Urine osmolality

Blood results are shown below (the sample was noted to be lipaemic):

Na^+	121 mmol/l
K^+	4.6 mmol/l
Urea	4.4 mmol/l
Creatinine	90 µmol/l
Albumin	17 g/l
Glucose	4.6 mmol/l
Plasma osmolality	280 mOsmol/kg
24 hour urinary protein	6.2 g

What investigation would help explain this patient's hyponatraemia?

Your answer was correct

A Plasma antidiuretic hormone

B Plasma lipids

C Spot urinary sodium

D Short synacthen test

E Urine osmolality

Explanation

B Plasma lipids

B Plasma lipids

This patient has pseudohyponatraemia due to hyperlipidaemia secondary to the nephrotic syndrome. The major clue to this is the normal measured plasma osmolality. The mechanism of pseudohyponatraemia can be explained by the electrolyte exclusion effect. This is the exclusion of electrolytes from the fraction of total plasma volume that is occupied by solids. The volume of total solids (primarily protein and lipid) in an aliquot of plasma is normally approximately 7%. This will be increased in conditions that cause a rise in protein or lipid. A spuriously low sodium result occurs because the measured sodium is confined to the aqueous phase, but has its concentration expressed in terms of the total volume of plasma. It is important to diagnose pseudohyponatraemia, because as the plasma osmolality is normal no treatment is required.

A Plasma antidiuretic hormone

The antidiuretic hormone level would be normal which would not discern the cause of hyponatraemia.

C Spot urinary sodium

Spot urinary sodium may be useful to differentiate the cause of acute kidney disease. In cases of acute kidney disease with a low urinary sodium would suggest a pre-renal cause.

D Short synacthen test

In this case the Short synacthen test would be normal. It would be abnormal in Addison's disease.

E Urine osmolality

A Plasma antidiuretic hormone

The antidiuretic hormone level would be normal which would not discern the cause of hyponatraemia.

C Spot urinary sodium

Spot urinary sodium may be useful to differentiate the cause of acute kidney disease. In cases of acute kidney disease with a low urinary sodium would suggest a pre-renal cause.

D Short synacthen test

In this case the Short synacthen test would be normal. It would be abnormal in Addison's disease.

E Urine osmolality

Urine osmolality would be high in cases of pre-renal kidney disease as the urine is more concentrated. It would not help in this case.

Rate this question:

Next Question

Previous Q... Tag Questi... Feedback End Session

Blog About Pastest Contact Us Help

© Pastest 2019

A 34-year-old woman is admitted as an emergency with a 24-h history of severe headaches, blurred vision and shortness of breath. She had been previously fit and well with no significant past medical history and apart from some recent fatigue, had no other symptoms. She smoked 10 cigarettes per day and drank very little alcohol. She was not sure about family history as she had been adopted.

On examination, she was fully alert and oriented with warm peripheries and a blood pressure of 185/115 mmHg. She had bi-basal chest crepitations, bilateral irregular masses palpable in both flanks and hepatomegaly. Fundoscopy revealed flame haemorrhages and exudates with indistinct disc margins. There were no other focal neurological signs.

Investigation results are below:

Hb	10.2 g/dl
WCC	4.4×10^9/l
PLT	160×10^9/l
Mean corpuscular volume (MCV)	92 fl
Na^+	143 mmol/l
K^+	4.6 mmol/l
Urea	17 mmol/l
Creatinine	250 µmol/l
Bilirubin	15 µmol/l
Alkaline phosphatase	92 U/l
Aspartate transaminase (AST)	32 U/l
Gamma-glutamyl transferase (GGT)	42 U/l

disc margins. There were no other focal neurological signs.

Investigation results are below:

Hb	10.2 g/dl
WCC	4.4×10^9/l
PLT	160×10^9/l
Mean corpuscular volume (MCV)	92 fl
Na^+	143 mmol/l
K^+	4.6 mmol/l
Urea	17 mmol/l
Creatinine	250 µmol/l
Bilirubin	15 µmol/l
Alkaline phosphatase	92 U/l
Aspartate transaminase (AST)	32 U/l
Gamma-glutamyl transferase (GGT)	42 U/l
Urinalysis	Protein ++ blood++
Electrocardiogram (ECG)	Sinus rhythm, left ventricular hypertrophy with strain pattern
Chest X-ray	Cardiomegaly, upper lobe diversion, alveolar shadowing

What is the best way to manage her accelerated hypertension here?

A Admission and cautious oral angiotensin-converting enzyme (ACE) inhibitor introduction

transaminase (AST)	
Gamma-glutamyl transferase (GGT)	42 U/l
Urinalysis	Protein ++ blood++
Electrocardiogram (ECG)	Sinus rhythm, left ventricular hypertrophy with strain pattern
Chest X-ray	Cardiomegaly, upper lobe diversion, alveolar shadowing

What is the best way to manage her accelerated hypertension here?

Your answer was correct

A Admission and cautious oral angiotensin-converting enzyme (ACE) inhibitor introduction

B IV furosemide

C IV labetalol

D IV sodium nitroprusside

E Immediate haemodialysis with ultrafiltration

Explanation

C IV labetalol

Labetalol is an appropriate antihypertensive to use. This should be given by slow titration to avoid rapid blood pressure drops.

Explanation

C	IV labetalol

Labetalol is an appropriate antihypertensive to use. This should be given by slow titration to avoid rapid blood pressure drops.

A	Admission and cautious oral angiotensin-converting enzyme (ACE) inhibitor introduction

This patient has malignant hypertension secondary to previously undiagnosed polycystic kidney disease. This causes vascular fibrinoid necrosis and is usually the first manifestation of hypertension, but it can sometimes occur in known hypertensive individuals. Death mainly occurs from heart failure, kidney disease or stroke, with an untreated mortality of approximately 80%. Management with bed rest and a gradual reduction of the blood pressure over 24–48 h with slow titration of IV antihypertensives is usually sufficient (aim for a diastolic pressure of 100–110 mmHg). If the blood pressure is reduced too rapidly it may cause cerebral, renal, retinal or myocardial infarction. Parenteral therapy should be reserved for cases when very rapid blood pressure reduction is required, such as hypertensive encephalopathy or aortic dissection. The agents of choice are usually labetalol or sodium nitroprusside. Patients with malignant hypertension and a serum creatinine of >300 μmol/l often progress to end-stage kidney disease.

B	IV furosemide

Furosemide will help the pulmonary oedema in this case, but it is important to first control the blood pressure.

D	IV sodium nitroprusside

antihypertensives is usually sufficient (aim for a diastolic pressure of 100–110 mmHg). If the blood pressure is reduced too rapidly it may cause cerebral, renal, retinal or myocardial infarction. Parenteral therapy should be reserved for cases when very rapid blood pressure reduction is required, such as hypertensive encephalopathy or aortic dissection. The agents of choice are usually labetalol or sodium nitroprusside. Patients with malignant hypertension and a serum creatinine of >300 μmol/l often progress to end-stage kidney disease.

B IV furosemide

Furosemide will help the pulmonary oedema in this case, but it is important to first control the blood pressure.

D IV sodium nitroprusside

Cautious control of the blood pressure is needed in this scenario and it should be administered in the simplest method. Therefore IV sodium nitroprusside is not needed here. In addition, there are some potential side-effects of sodium nitroprusside, including skin rashes, nausea, warmth and redness under the skin or darkening of the veins under the skin.

E Immediate haemodialysis with ultrafiltration

Although this woman has pulmonary oedema and signs of fluid overload, her renal impairment is not severe and there are no immediate indications for acute dialysis. Medical therapy should be tried first – to control blood pressure. If she is anuric and medical therapy fails to improve symptoms then dialysis may then be indicated. Absolute indications for acute dialysis include hyperkalaemia (≥6.5 mmol/l) or rapidly rising potassium that is resistant to medical treatment and pulmonary oedema with inadequate response to diuretics particularly in an oligo-anuric patient.

10:30
594-042-7551
Leave

A 28-year-old lawyer, originally from Singapore and who has recently returned from the Far East, presents complaining of passing bright red urine, facial puffiness and malaise. He also has a severe sore throat, which began 2 or 3 days before he noticed the red urine. His past medical history includes hay fever.

On physical examination, his blood pressure is 130/80 mmHg, and chest and abdominal examination is unremarkable.

Urinalysis:

Protein	2+
Blood	3+
Nitrites	Negative
Leucocytes	Negative

The likely diagnosis is?

A Focal segmental glomerulonephritis

B Mesangioproliferative glomerulonephritis (immunoglobulin A [IgA] nephropathy)

C Membranous glomerulonephritis

D Post-streptococcal glomerulonephritis

E Schistosomiasis

Audio Video Share Participants More

and malaise. He also has a severe sore throat, which began 2 or 3 days before he noticed the red urine. His past medical history includes hay fever.

On physical examination, his blood pressure is 130/80 mmHg, and chest and abdominal examination is unremarkable.

Urinalysis:

Protein	2+
Blood	3+
Nitrites	Negative
Leucocytes	Negative

The likely diagnosis is?

Your answer was correct

A Focal segmental glomerulonephritis

B Mesangioproliferative glomerulonephritis (immunoglobulin A [IgA] nephropathy)

C Membranous glomerulonephritis

D Post-streptococcal glomerulonephritis

E Schistosomiasis

Explanation

B Mesangioproliferative glomerulonephritis (immunoglobulin A [IgA] nephropathy)

Rana Alnasser's screen

Explanation

B Mesangioproliferative glomerulonephritis (immunoglobulin A [IgA] nephropathy)

Mesangioproliferative glomerulonephritis (immunoglobulin A [IgA] nephropathy) is primarily a disease of young adults who develop 'synpharyngitic' episodes of glomerulonephritis, i.e. episodes which either coincide or occur within 2–3 days of an upper respiratory tract infection. It is the commonest glomerulonephritis (GN) in adults in the West. It is particularly common in the Far East, which is thought to be associated with a high incidence of the human leucocyte antigen (HLA) DQW7 haplotype in the local population.

A Focal segmental glomerulonephritis

We would expect significant proteinuria with focal segmental glomerulonephritis. The history of sore throat is not typical.

C Membranous glomerulonephritis

Membranous nephropathy is the most common cause of nephrotic syndrome (oedema, hypoalbuminaemia, nephrotic-range proteinuria) in adult patients. There is no haematuria, unlike in this scenario.

D Post-streptococcal glomerulonephritis

Post-streptococcal GN usually occurs several weeks after a streptococcal infection of either the upper respiratory tract or the skin.

E Schistosomiasis

10:32

A 44-year-old woman received a cadaveric renal transplant 8 weeks previously.

At a routine Transplant Clinic appointment, she is well and on the following medication: ciclosporin, azathioprine, prednisolone, co-trimoxazole and lisinopril.

Investigations:

Sodium	138 mmol/l
Potassium	6.9 mmol/l
Urea	11.2 mmol/l
Creatinine	139 µmol/l
Bicarbonate	24 mmol/l

Electrocardiogram (ECG): peaked T waves and prolongation of PR interval.

What is the most appropriate initial therapy?

A IV calcium gluconate

B Immediate withdrawal of lisinopril

C Inhaled salbutamol

D Intravenous (IV) insulin with glucose

E PO polystyrene sulphonate resin

Rana Alnasser's screen

A 44-year-old woman received a cadaveric renal transplant 8 weeks previously.

At a routine Transplant Clinic appointment, she is well and on the following medication: ciclosporin, azathioprine, prednisolone, co-trimoxazole and lisinopril.

Investigations:

Sodium	138 mmol/l
Potassium	6.9 mmol/l
Urea	11.2 mmol/l
Creatinine	139 µmol/l
Bicarbonate	24 mmol/l

Electrocardiogram (ECG): peaked T waves and prolongation of PR interval.

What is the most appropriate initial therapy?

Your answer was correct

A IV calcium gluconate

B Immediate withdrawal of lisinopril

C Inhaled salbutamol

D Intravenous (IV) insulin with glucose

E PO polystyrene sulphonate resin

Explanation

E PO polystyrene sulphonate resin

Explanation

A IV calcium gluconate

This patient has severe hyperkalaemia with typical changes on the electrocardiogram (ECG), indicating that the hyperkalaemia is having an adverse effect on the cardiac conduction system. Although some patients show a gradual progression of ECG findings, many progress rapidly without warning. As such, patients with potassium levels >6.5 mmol/l and ECG changes should be treated as a medical emergency. Protection of the heart is paramount. Calcium gluconate acts within minutes and works by raising the depolarisation threshold for myocytes. The effect of bolus calcium gluconate is transient, and repeated boluses may be necessary until the plasma potassium has been lowered.

B Immediate withdrawal of lisinopril

Withdrawal of lisinopril is important, but will not lead to immediate decrease in potassium.

C Inhaled salbutamol

Nebulised salbutamol is only an interim measure to lower potassium as it moves potassium into the cells. Salbutamol will induce a tachycardia and may predispose to a tachyarrythmia.

D Intravenous (IV) insulin with glucose

The fastest way to decrease the extracellular potassium is to shift it to the intracellular compartment. This can be

10:33
594-042-7551
Leave

immediate decrease in potassium.

C Inhaled salbutamol

Nebulised salbutamol is only an interim measure to lower potassium as it moves potassium into the cells. Salbutamol will induce a tachycardia and may predispose to a tachyarrythmia.

D Intravenous (IV) insulin with glucose

The fastest way to decrease the extracellular potassium is to shift it to the intracellular compartment. This can be accomplished by insulin (along with glucose to prevent hypoglycaemia). However, it is not directly cardioprotective.

E PO polystyrene sulphonate resin

PO polystyrene sulphonate resin takes time to act, and this will be hours to days. Therefore it is not used in the acute setting for rapid reduction in potassium.

Rate this question:

© Pastest 2019

Audio Video Share Participants More

10:33
594-042-7551
Leave

A 56-year-old woman with chronic kidney disease secondary to chronic pyelonephritis was reviewed in the Renal Clinic. She was complaining of some exertional dyspnoea and fatigue but no other symptoms. She had a history of hypertension that was difficult to control, despite being on multiple agents. She has taken oral iron sulphate.

On examination, she was pale, blood pressure was 190/110 mmHg, jugular venous pressure not raised. She had bi-basal crepitations in her chest and mild pitting ankle odema. Her abdomen was soft, non-tender and not distended.

Blood results are below:

Hb	8.2 g/dl
WCC	5.0×10^9/l
PLT	220×10^9/l
Mean corpuscular volume (MCV)	74 fl
Ferritin	90 µg/l (20–260 µg/l)
Folate (serum)	10 µg/l (2-11µg/l)
Vitamin B12 (serum)	240 ng/l (150–675 ng/l)

What is the most appropriate management of the anaemia?

A Blood transfusion

B Intravenous iron infusion

Audio Video Share Participants More

On examination, she was pale, blood pressure was 190/110 mmHg, jugular venous pressure not raised. She had bi-basal crepitations in her chest and mild pitting ankle odema. Her abdomen was soft, non-tender and not distended.

Blood results are below:

Hb	8.2 g/dl
WCC	5.0×10^9/l
PLT	220×10^9/l
Mean corpuscular volume (MCV)	74 fl
Ferritin	90 µg/l (20–260 µg/l)
Folate (serum)	10 µg/l (2-11µg/l)
Vitamin B12 (serum)	240 ng/l (150–675 ng/l)

What is the most appropriate management of the anaemia?

A Blood transfusion

B Intravenous iron infusion

C Subcutaneous erythropoietin

D Oral ferrous gluconate

E Immediate commencement of haemodialysis

PLT	220 × 10^9/l
Mean corpuscular volume (MCV)	74 fl
Ferritin	90 µg/l (20–260 µg/l)
Folate (serum)	10 µg/l (2-11µg/l)
Vitamin B12 (serum)	240 ng/l (150–675 ng/l)

What is the most appropriate management of the anaemia?

Your answer was correct

A Blood transfusion

B Intravenous iron infusion

C Subcutaneous erythropoietin

D Oral ferrous gluconate

E Immediate commencement of haemodialysis

Explanation

B Intravenous iron infusion

Anaemia is present in the majority of patients with chronic kidney disease, and is due to a number of factors, including erythropoietin and haematinic deficiency, increased bleeding tendency due to reduced platelet function, and shortened red cell survival time. The target haemoglobin in these patients is usually 10–12 g/dl. This lady's iron is low

A Blood transfusion

B Intravenous iron infusion

C Subcutaneous erythropoietin

D Oral ferrous gluconate

E Immediate commencement of haemodialysis

Explanation

B Intravenous iron infusion

Anaemia is present in the majority of patients with chronic kidney disease, and is due to a number of factors, including erythropoietin and haematinic deficiency, increased bleeding tendency due to reduced platelet function, and shortened red cell survival time. The target haemoglobin in these patients is usually 10–12 g/dl. This lady's iron is low despite taking oral iron supplements; this may be due to poor oral absorption which commonly occurs. Therefore, it is important to administer the iron intravenously which will bypass the gut. Once iron levels are restored, if haemoglobin is still low then erythropoietin treatment may be considered.

A Blood transfusion

Blood transfusion should be avoided if possible as she is fluid overloaded and it may precipitate pulmonary oedema.

C Subcutaneous erythropoietin

10:35
594-042-7551
Leave

C Subcutaneous erythropoietin

Erythropoietin is usually very effective and is given subcutaneously, usually three times per week. Disadvantages are that it is expensive and can accelerate hypertension and occasionally cause encephalopathy. It should therefore be avoided in this patient until her blood pressure is better controlled (below 170/110) and her ferritin is restored to the mid range (ferritin >100 μg/l), with a normal vitamin B_{12} and folate.

D Oral ferrous gluconate

Oral iron therapy is usually ineffective, and ferrous gluconate is unlikely to be any more successful than oral ferrous sulphate.

E Immediate commencement of haemodialysis

Haemodialysis will not improve anaemia. Dialysis treatment may remove fluid, if any blood transfusion is given.

Rate this question:

Next Question

© Pastest 2019

Audio Video Share Participants More

10:35

A 48-year-old woman presents with severe left loin pain on a background of several months of malaise, thirst and polyuria. She has a long history of chronic headaches which have been extensively investigated, with no pathological cause found. She also suffers from anxiety and depression and recurrent urinary tract infections.

She does not smoke or drink alcohol and has no significant family history. The only significant findings on examination were hypertension and some tenderness in the left loin.

Investigation results are below:

Haemoglobin (Hb)	10.2 g/dl
White cell count (WCC)	10.8×10^9/l
Platelets (PLT)	300×10^9/l
Mean corpuscular volume (MCV)	86 fl
Calcium (Ca^{2+})	2.18 mmol/l
Phosphate	1.80 mmol/l
Urate	0.38 mmol/l
Sodium (Na^+)	130 mmol/l
Potassium (K^+)	3.6 mmol/l
Urea	15.2 mmol/l
Creatinine	380 micromol/l
Plain abdominal film	No visible calculi or calcification
Urinalysis	Protein ++
Urine microscopy	Casts, renal papillary cells and leukocytes. No organisms.

Rana Alnasser's screen

Intravenous (IV) Bilateral clubbed calyces, 'ring signs'.

a background of several months of malaise, thirst and polyuria. She has a long history of chronic headaches which have been extensively investigated, with no pathological cause found. She also suffers from anxiety and depression and recurrent urinary tract infections.

She does not smoke or drink alcohol and has no significant family history. The only significant findings on examination were hypertension and some tenderness in the left loin.

Investigation results are below:

Haemoglobin (Hb)	10.2 g/dl
White cell count (WCC)	10.8×10^9/l
Platelets (PLT)	300×10^9/l
Mean corpuscular volume (MCV)	86 fl
Calcium (Ca^{2+})	2.18 mmol/l
Phosphate	1.80 mmol/l
Urate	0.38 mmol/l
Sodium (Na^+)	130 mmol/l
Potassium (K^+)	3.6 mmol/l
Urea	15.2 mmol/l
Creatinine	380 micromol/l
Plain abdominal film	No visible calculi or calcification
Urinalysis	Protein ++
Urine microscopy	Casts, renal papillary cells and leukocytes. No organisms.
Intravenous (iv) urogram	Bilateral clubbed calyces, 'ring signs', filling defect in left ureter.

Rana Alnasser's screen

B Intravenous iron infusion

Anaemia is present in the majority of patients with chronic kidney disease, and is due to a number of factors, including erythropoietin and haematinic deficiency, increased bleeding tendency due to reduced platelet function, and shortened red cell survival time. The target haemoglobin in these patients is usually 10–12 g/dl. This lady's iron is low despite taking oral iron supplements; this may be due to poor oral absorption which commonly occurs. Therefore, it is important to administer the iron intravenously which will bypass the gut. Once iron levels are restored, if haemoglobin is still low then erythropoietin treatment may be considered.

A Blood transfusion

Blood transfusion should be avoided if possible as she is fluid overloaded and it may precipitate pulmonary oedema.

C Subcutaneous erythropoietin

Erythropoietin is usually very effective and is given subcutaneously, usually three times per week. Disadvantages are that it is expensive and can accelerate hypertension and occasionally cause encephalopathy. It should therefore be avoided in this patient until her blood pressure is better controlled (below 170/110) and her ferritin is restored to the mid range (ferritin >100 μg/l), with a normal vitamin B_{12} and folate.

D Oral ferrous gluconate

Oral iron therapy is usually ineffective, and ferrous gluconate is unlikely to be any more successful than oral ferrous sulphate.

E Immediate commencement of haemodialysis

A 48-year-old woman presents with severe left loin pain on a background of several months of malaise, thirst and polyuria. She has a long history of chronic headaches which have been extensively investigated, with no pathological cause found. She also suffers from anxiety and depression and recurrent urinary tract infections.

She does not smoke or drink alcohol and has no significant family history. The only significant findings on examination were hypertension and some tenderness in the left loin.

Investigation results are below:

Haemoglobin (Hb)	10.2 g/dl
White cell count (WCC)	10.8×10^9/l
Platelets (PLT)	300×10^9/l
Mean corpuscular volume (MCV)	86 fl
Calcium (Ca^{2+})	2.18 mmol/l
Phosphate	1.80 mmol/l
Urate	0.38 mmol/l
Sodium (Na^+)	130 mmol/l
Potassium (K^+)	3.6 mmol/l
Urea	15.2 mmol/l
Creatinine	380 micromol/l
Plain abdominal film	No visible calculi or calcification
Urinalysis	Protein ++
Urine microscopy	Casts, renal papillary cells and leukocytes. No organisms.

Mean corpuscular volume (MCV)	86 fl
Calcium (Ca^{2+})	2.18 mmol/l
Phosphate	1.80 mmol/l
Urate	0.38 mmol/l
Sodium (Na^{+})	130 mmol/l
Potassium (K^{+})	3.6 mmol/l
Urea	15.2 mmol/l
Creatinine	380 micromol/l
Plain abdominal film	No visible calculi or calcification
Urinalysis	Protein ++
Urine microscopy	Casts, renal papillary cells and leukocytes. No organisms.
Intravenous (iv) urogram	Bilateral clubbed calyces, 'ring signs', filling defect in left ureter.

What is the most likely diagnosis?

A Acute interstitial nephritis

B Analgesic nephropathy

C Medullary sponge kidney

D Reflux nephropathy

E Renal stone disease

Explanation

B Analgesic nephropathy

This is a chronic tubulo-interstitial nephritis with papillary necrosis caused by prolonged heavy use of compound analgesics. The incidence has reduced since phenacetin withdrawal, although it can also be seen in association with non-steroidal anti-inflammatory drugs (NSAIDs) and codeine. It is twice as common in women and usually presents in middle-aged depressed or neurotic patients with chronic pain, many of whom may deny analgesic use. It usually causes chronic kidney disease, and 60% of patients are hypertensive at presentation. Sloughing of renal papillae can cause urinary tract obstruction which may precipitate acute kidney disease.

Recurrent urinary tract infections are common, or patients may have persistent sterile pyuria. There is occasionally salt-losing nephropathy. The diagnosis can be made by the history, in combination with characteristic appearances on intravenous urography, urine microscopy and biochemical evidence of tubular dysfunction. Renal biopsy is sometimes performed and will show interstitial fibrosis and tubular atrophy. There is an increased risk of tumours of the uroepithelium.

Treatment includes withdrawal of the offending drug, maintaining a fluid intake of 2–3 litres per day, control of hypertension and biochemical correction. Total recovery of renal function can occur in 25% of patients.

D Reflux nephropathy

Longstanding reflux nephropathy would present with small and scarred kidneys.

A Acute interstitial nephritis

performed and will show interstitial fibrosis and tubular atrophy. There is an increased risk of tumours of the uroepithelium.

Treatment includes withdrawal of the offending drug, maintaining a fluid intake of 2–3 litres per day, control of hypertension and biochemical correction. Total recovery of renal function can occur in 25% of patients.

D Reflux nephropathy

Longstanding reflux nephropathy would present with small and scarred kidneys.

A Acute interstitial nephritis

Acute interstitial nephritis has a shorter history of acute renal dysfunction, often associated with antibiotic use and omeprazole.

C Medullary sponge kidney

Medullary sponge kidney is a benign, common condition where there is diffuse medullary cyst formation. It is a developmental disorder that can be detected on imaging.

E Renal stone disease

Bilateral clubbed calyces and 'ring signs' are not typical of renal stone disease.

Rate this question:

Next Question

Rana Alnasser's screen

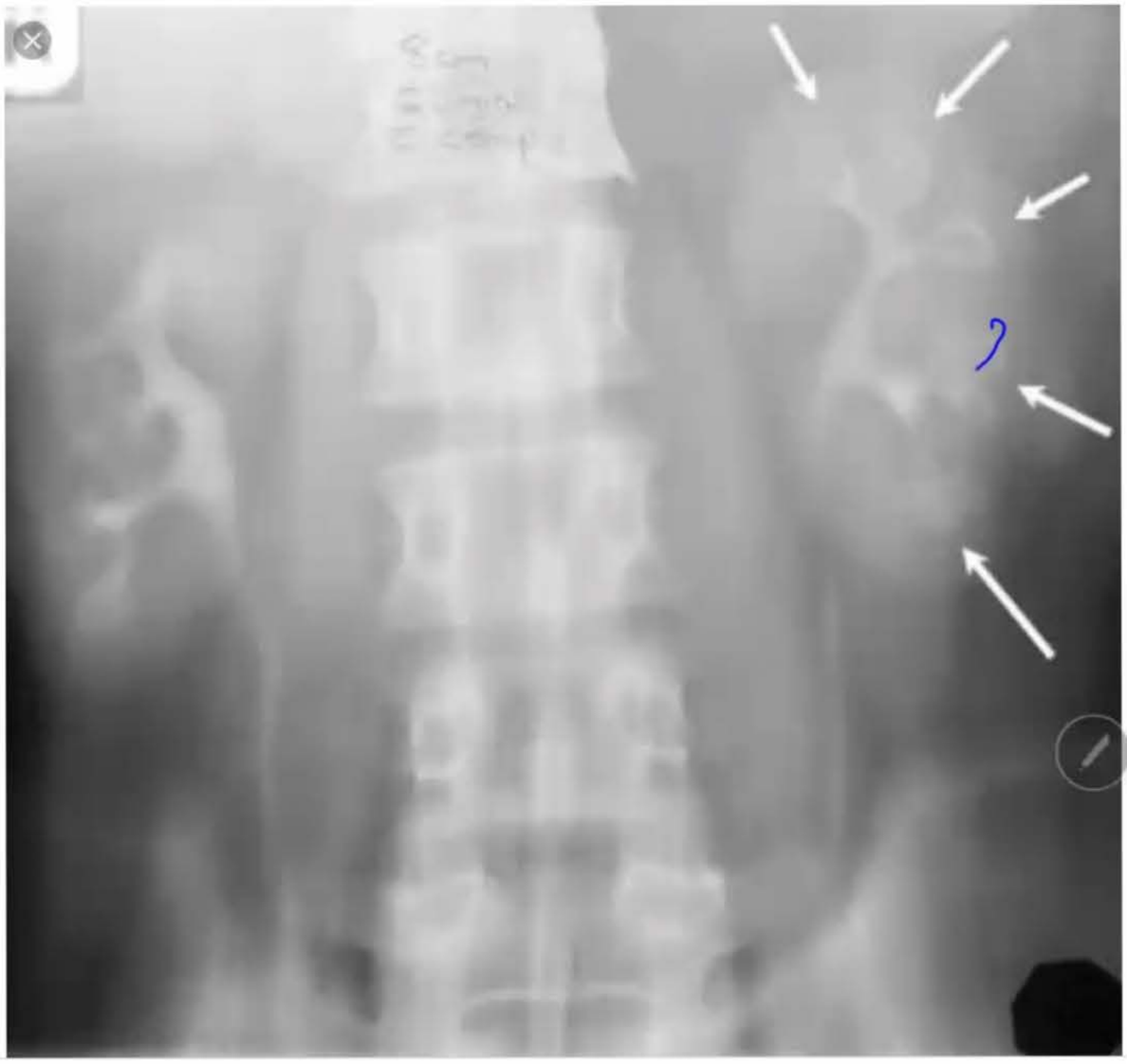

Medscape eMedicine

Papillary Necrosis Imaging: Overview, Radiography, Computed Tomography

Exc

Stop Annotation | Spotlight | Pen | Highlighter | Line | Rectangle | Oval | Undo | Redo | Clear | Color | Stop Share

Images may be subject to copyright. Learn more

RELATED IMAGES

Discover | Updates | Search | Recent | More

Rana Alnasser's screen

10:44
594-042-7551
Leave

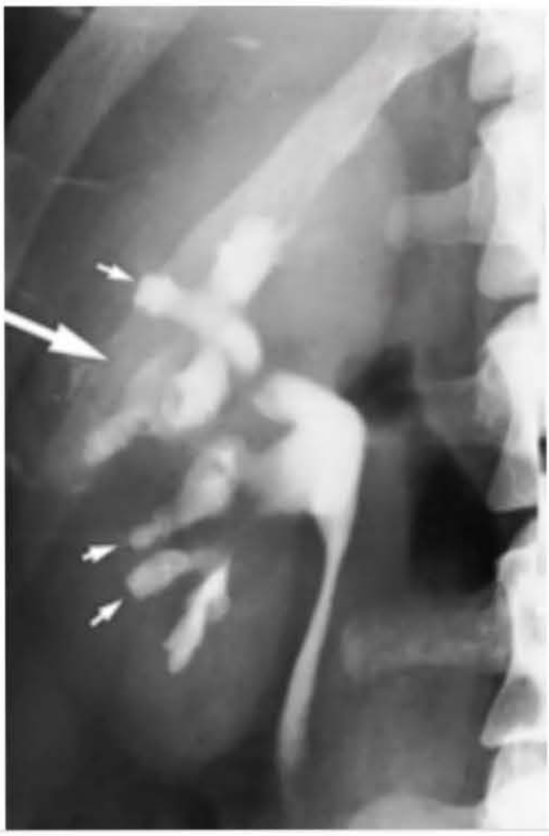

Plastic Surgery Key

Kidneys | Radiology Key

Analgesic nephropathy. Characteristic 'egg in cup' cavities (short arrows) and a 'horn' (long arrow).*

Images may be subject to copyright. Learn more

RELATED IMAGES

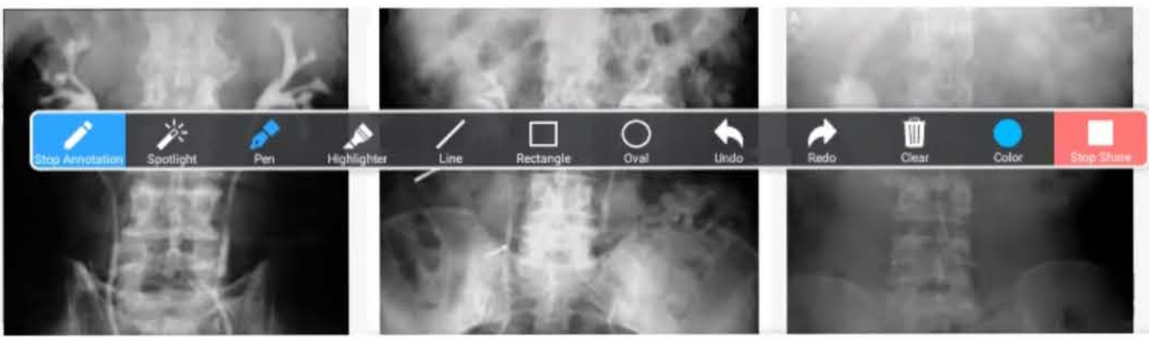

Discover
Updates
Search
Recent
More

Audio
Video
Share
Participants
More

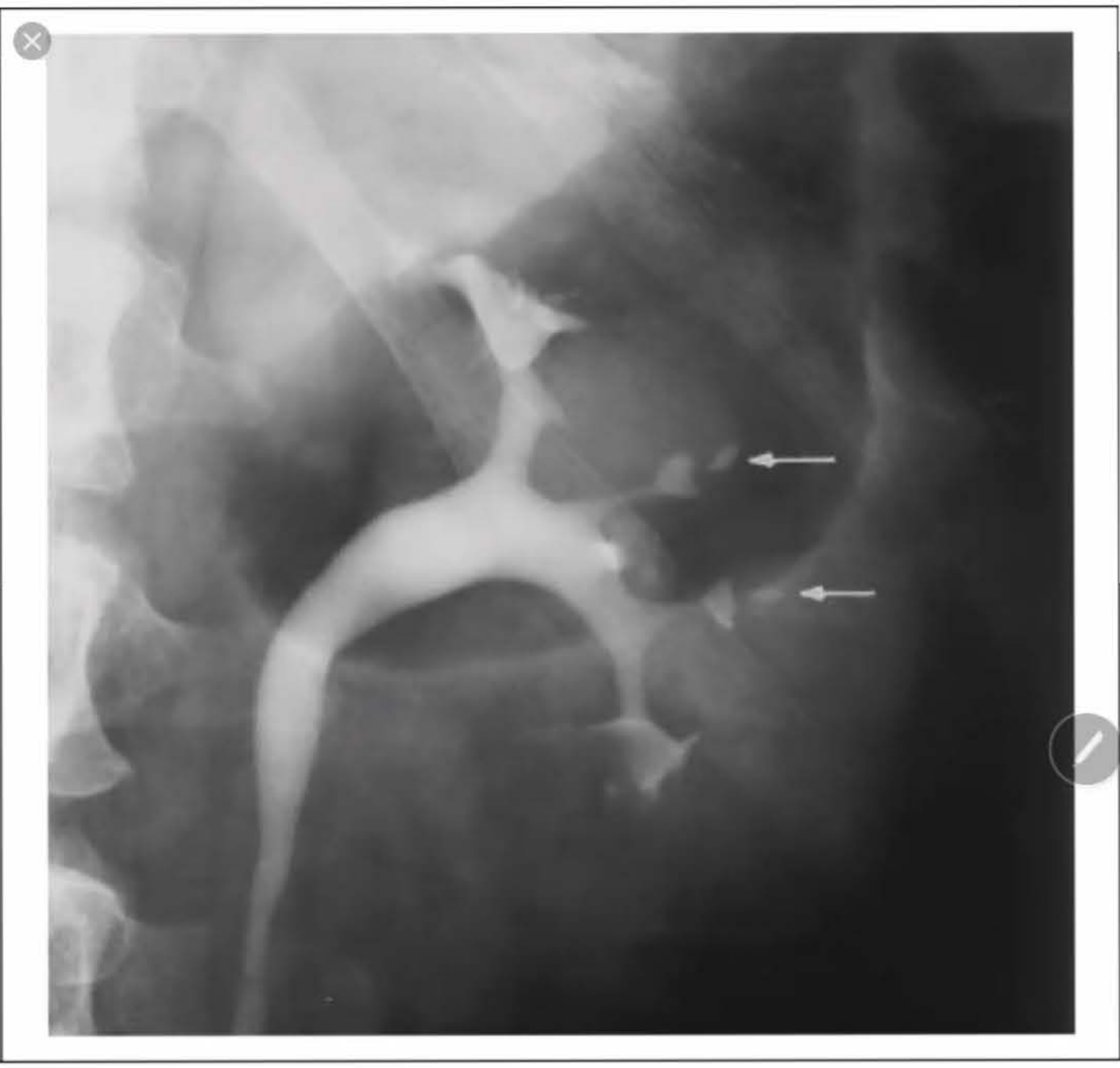

Saudi Journal of Kidney Diseases and Transplantation

An [illegible]ckle cell nephropathy Alhwiesh A - Saudi J Kidney ...

Figure 2: Renal papillary necrosis: Pyelographic image in a patient with sickle cell disease showing central cavities within multiple papillae (arrows).

Images may be subject to copyright. Learn more

RELATED IMAGES

Discover Updates Search Recent More

Rana Alnasser's screen

10:46
594-042-7551
Leave

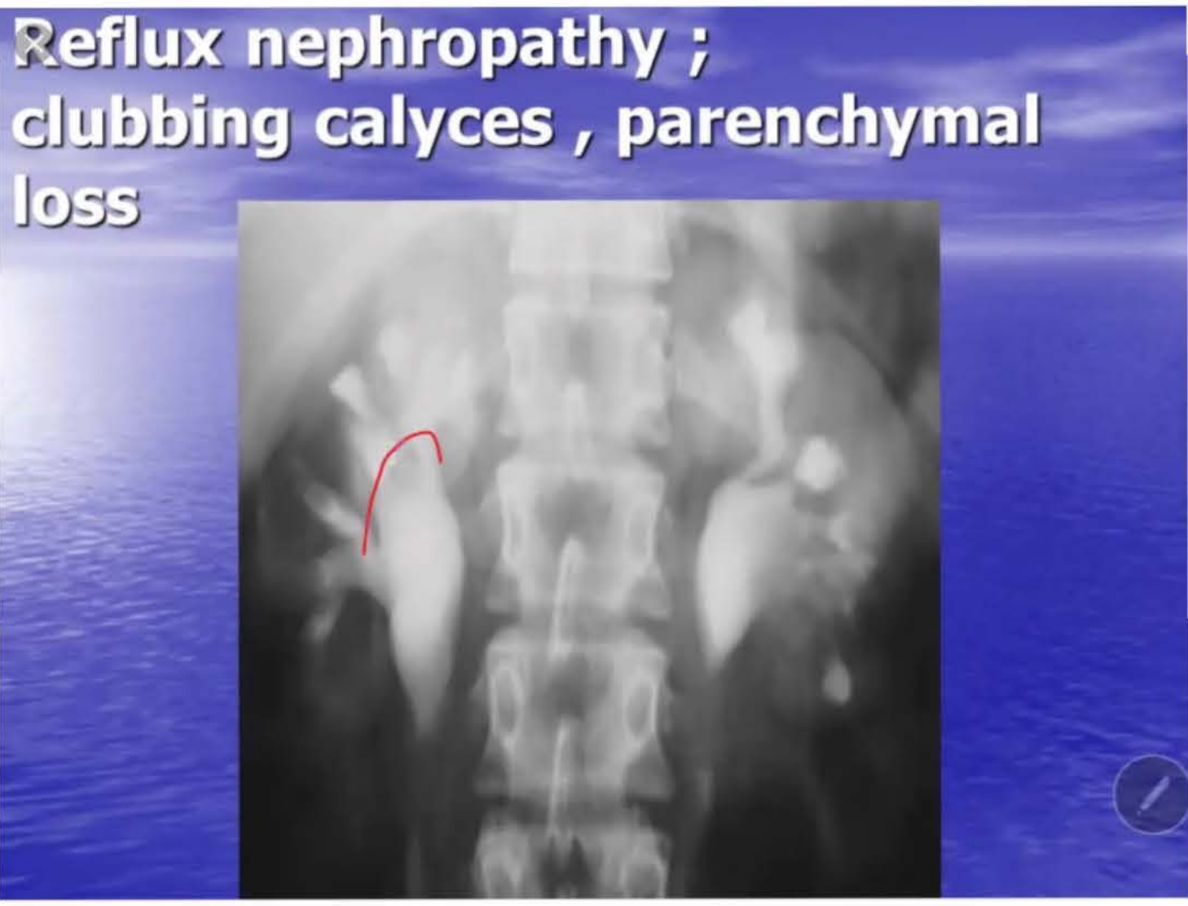

SlidePlayer
Stop Annotation
Spotlight
Pen
Highlighter
Line
Rectangle
Oval
Undo
Redo
Clear
Color
Stop Share

IV

29 Reflux nephropathy ...

Images may be subject to copyright. Learn more

RELATED IMAGES

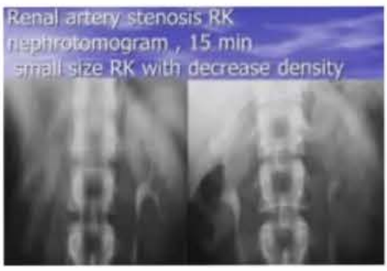

Discover
Updates
Search
Recent
More

Audio
Video
Share
Participants
More

10:47
594-042-7551
Leave

96% 08:47

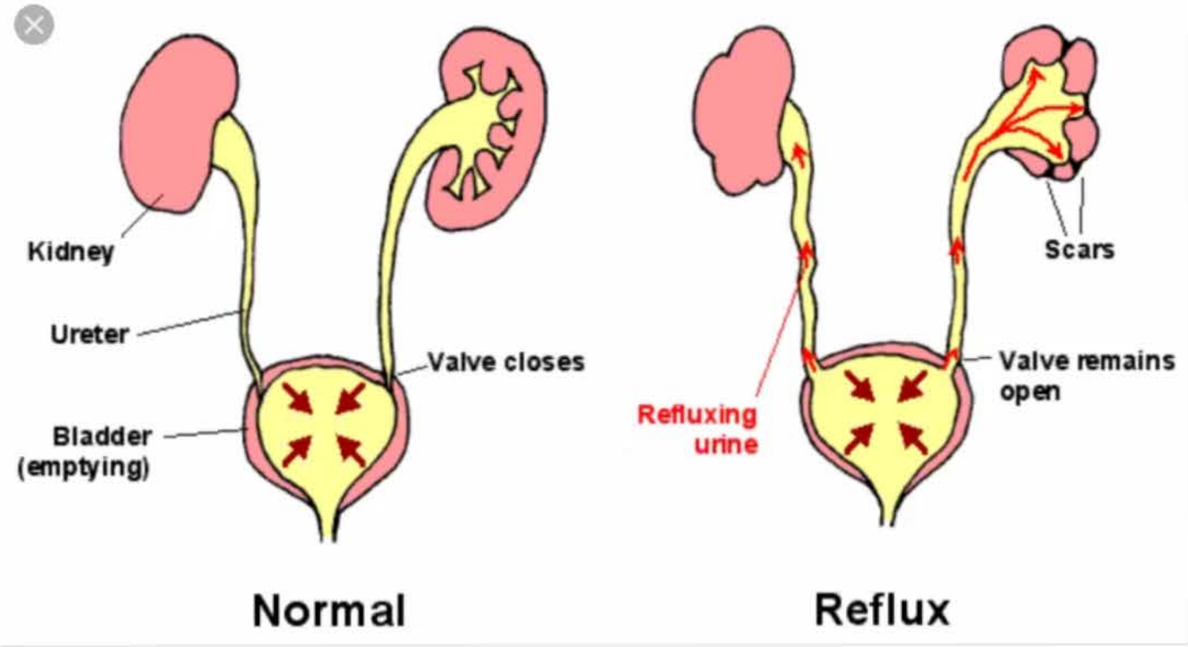

EdRen

Reflux nephropathy – edren.org

In reflux, the valves don't close, and urine is forced back towards the kidney - REFLUX. This may also be called vesico-ureteric reflux, because the urine ...

Images may be subject to copyright. Learn more

RELATED IMAGES

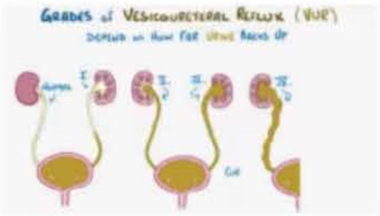

File:Vesicoureteral reflux.webm - Wikimedia ...
commons.wikimedia.org

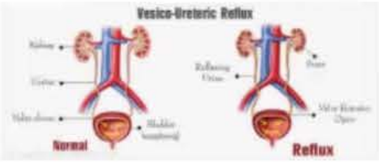

What is vesicoureteral reflux (VUR)? - AddPh...
blog.addpharma4u.com

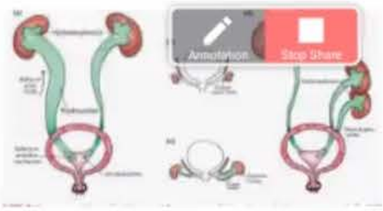

Figure 4 from Lower urinary tract developme...
semanticscholar.org

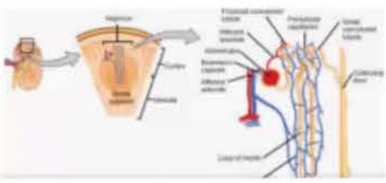

Pediatric Nephrology | Mosaiques Diagnosti...
mosaiques-diagnostics.de

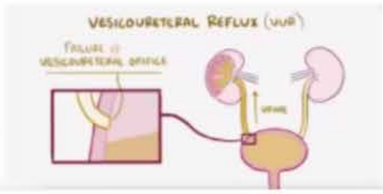

Discover
Updates
Search
Recent
More

Audio
Video
Share
Participants
More

10:47

A 69-year-old man with hypertension comes to the Emergency Department complaining of dysuria, flank pain, fever and chills for 2 days. He takes metoprolol and hydrochlorothiazide for his hypertension.

Vital signs are temperature 39.3 °C, blood pressure 100/60 mmHg, pulse 120/min, respiration 28/min and oxygen saturation 98% on room air. He has mild tenderness at the left costovertebral angle. The rest of the physical examination is normal.

The chest X-ray is normal and urine dipstick positive for blood, protein and nitrites. Blood and urine are sent for analysis and cultures.

What is the most appropriate next step in management?

A	Call for a urological consultation
B	Insert a Foley catheter
C	Obtain an ultrasound of the kidneys
D	Start a dopamine infusion
E	Start intravenous antibiotic therapy

Submit

Previous Q... Skip Questi...

Rana Alnasser's screen

10:48
594-042-7551
Leave

A 69-year-old man with hypertension comes to the Emergency Department complaining of dysuria, flank pain, fever and chills for 2 days. He takes metoprolol and hydrochlorothiazide for his hypertension.

Vital signs are temperature 39.3 °C, blood pressure 100/60 mmHg, pulse 120/min, respiration 28/min and oxygen saturation 98% on room air. He has mild tenderness at the left costovertebral angle. The rest of the physical examination is normal.

The chest X-ray is normal and urine dipstick positive for blood, protein and nitrites. Blood and urine are sent for analysis and cultures.

What is the most appropriate next step in management?

Your answer was correct

A	Call for a urological consultation
B	Insert a Foley catheter
C	Obtain an ultrasound of the kidneys
D	Start a dopamine infusion
E	Start intravenous antibiotic therapy

Explanation

E	Start intravenous antibiotic therapy

The patient is experiencing signs and symptoms of Gram

Audio
Video
Share
Participants
More

10:48
594-042-7551 Leave
MyPastest
https://mypastest.pastest.com

The patient is experiencing signs and symptoms of Gram-negative sepsis stemming from a urinary tract infection. The most important intervention is early antibiotic therapy. The choice of antibiotic depends on history and Gram stain of the urine. The most common pathogens are Gram-negative rods (*E. coli*), so initial antibiotic coverage should include Gram-negative coverage and be adjusted depending on the culture sensitivity. Urinary tract infection in men is less common than in women, due to the anatomical differences, and is usually caused by obstruction because of benign prostatic hyperplasia (BPH), especially in elderly men.

In today's office practice, the dipstick test for nitrite is used as a surrogate marker for bacteriuria. It should be noted that not all uropathogens reduce nitrates to nitrite. For example, enterococci, *S. saprophyticus* and *Acinetobacter* species do not and therefore give false-negative results.

A Call for a urological consultation

Urological consultation may be useful in recurrent urinary tract infections or obstructive uropathy, but urological consult would depend on what ultrasound shows so is not the most appropriate next step.

B Insert a Foley catheter

Insertion of a Foley catheter is only useful if there is suspicion of obstructive uropathy, such as that caused by benign prostatic hypertrophy.

C Obtain an ultrasound of the kidneys

In this scenario, antibiotics need to be started first and an ultrasound would be needed, but that is not the initial step.

Audio Video Share Participants More

tract infections or obstructive uropathy, but urological consult would depend on what ultrasound shows so is not the most appropriate next step.

B Insert a Foley catheter

Insertion of a Foley catheter is only useful if there is suspicion of obstructive uropathy, such as that caused by benign prostatic hypertrophy.

C Obtain an ultrasound of the kidneys

In this scenario, antibiotics need to be started first and an ultrasound would be needed, but that is not the initial step. It would be useful for detecting hydronephrosis.

D Start a dopamine infusion

Dopamine infusion has no role to play in urinary tract infection treatment. Dopamine may be used to support renal blood flow in patients with persistent hypotension and poor urine output.

Rate this question:

Next Question

© Pastest 2019

A 50-year-old woman, who has a 10-year history of chronic kidney disease and is on haemodialysis, is admitted with a pathological fracture of her left femur. She is taking ramipril 10 mg, amlodipine 10 mg, atorvastatin 10 mg, calcium and vitamin D.

On examination, she has hepatosplenomegaly. Her BP is 155/92 mmHg and she has peripheral oedema. Previously, when she was still passing reasonable amounts of urine, her protein excretion was measured at 3.2 g/24 h.

Investigations:

Hb	10.0 g/dl
WCC	4.8×10^9/l
PLT	178×10^9/l
Na^+	139 mmol/l
K^+	4.9 mmol/l
Creatinine	593 µmol/l
Ca^{++} corr	2.61 mmol/l (2.2-2.6 mmol/l)
ALP	295 U/l (45-105 U/l)
PTH	14 pmol/l (1-6 pmol/l)
PO_4^{3-}	0.70 mmol/l
X-ray left femur	lucency in mid-shaft
T score	-3.0

Which of the following is the most likely cause of the fracture?

A Dialysis related amyloid

B Multiple myeloma

155/92 mmHg and she has peripheral oedema. Previously, when she was still passing reasonable amounts of urine, her protein excretion was measured at 3.2 g/24 h.

Investigations:

Hb	10.0 g/dl
WCC	4.8×10^9/l
PLT	178×10^9/l
Na^+	139 mmol/l
K^+	4.9 mmol/l
Creatinine	593 µmol/l
Ca^{++} corr	2.61 mmol/l (2.2-2.6 mmol/l)
ALP	295 U/l (45-105 U/l)
PTH	14 pmol/l (1-6 pmol/l)
PO_4^{3-}	0.70 mmol/l
X-ray left femur	lucency in mid-shaft
T score	-3.0

Which of the following is the most likely cause of the fracture?

A Dialysis related amyloid

B Multiple myeloma

C Hyperparathyroidism

D Osteomalacia

E Malabsorption

WCC	4.8 × 10⁹/l
PLT	178 × 10⁹/l
Na^+	139 mmol/l
K^+	4.9 mmol/l
Creatinine	593 µmol/l
Ca^{++} corr	2.61 mmol/l (2.2-2.6 mmol/l)
ALP	295 U/l (45-105 U/l)
PTH	14 pmol/l (1-6 pmol/l)
PO_4^{3-}	0.70 mmol/l
X-ray left femur	lucency in mid-shaft
T score	-3.0

Which of the following is the most likely cause of the fracture?

Your answer was correct

A Dialysis related amyloid

B Multiple myeloma

C Hyperparathyroidism

D Osteomalacia

E Malabsorption

Explanation

Rana Alnasser's screen

Explanation

C Hyperparathyroidism

This person has familial renal amyloidosis, as evidenced by hepatosplenomegaly, nephrotic syndrome and progressive kidney disease. The fracture is most likely to be related to hyperparathyroidism and loss of bone density. The raised alkaline phosphatase is likely to be as a result of the recent fracture, and the calcium level to slight over-replacement with calcium and vitamin D. Cinacalcet would be the obvious next therapy for this patient.

A Dialysis related amyloid

Features of amyloid arthropathy on radiography will include juxta-articular soft tissue swelling, mild periarticular osteoporosis, subchondral cystic lesions with well-defined sclerotic margins and normal joint space. These lesions were not apparent in the radiograph in this case.

B Multiple myeloma

Fractures and skeletal complications are found in up to 80% of patients with myeloma due to the plasma cell dyscrasias. Radiographically there are multiple destructive lytic lesions in the skeleton, due to severe demineralization that characterises multiple myeloma. This is not the case in this scenario.

D Osteomalacia

Osteomalacia is due to insufficient mineralisation of the osteoid due to vitamin D deficiency or defects in phosphate metabolism. The radiograph shows diffuse demineralisation with the characteristic smudgy, 'erased' type of demineralisation with pseudo-fractures (Looser zones).

B Multiple myeloma

Fractures and skeletal complications are found in up to 80% of patients with myeloma due to the plasma cell dyscrasias. Radiographically there are multiple destructive lytic lesions in the skeleton, due to severe demineralization that characterises multiple myeloma. This is not the case in this scenario.

D Osteomalacia

Osteomalacia is due to insufficient mineralisation of the osteoid due to vitamin D deficiency or defects in phosphate metabolism. The radiograph shows diffuse demineralisation with the characteristic smudgy, 'erased' type of demineralisation with pseudo-fractures (Looser zones).

E Malabsorption

Malabsorption may lead to pathological fractures because of reduced absorption of vitamin D and calcium essential for bone formation. There is no history of malabsorption, such as diarrhoea or weight loss, in this case. We may expect the calcium level to be low.

#1532

Rate this question:

Next Question

Previous Q... Tag Questi... Feedback End Session

Blog About Pastest Contact Us Help

10:50
594-042-7551
Leave

A 50-year-old man with end-stage renal disease had a renal transplant four months ago. His baseline creatinine is 150 µmol/L. On physical examination his blood pressure is 160/70 mmHg and he has tenderness over his transplant kidney. His blood results reveal urea 22 mmol/l, creatinine 500 µmol/l.

Which of the following renal pathologies is most likely to recur in a renal transplant patient?

A	Diabetic renal disease
B	Focal segmental glomerulosclerosis
C	Minimal-change glomerulonephritis
D	Membranous glomerulonephritis
E	Membranoproliferative glomerulonephritis

Submit

Blog About Pastest Contact Us Help
© Pastest 2019
Audio Video Share Participants More

D Membranous glomerulonephritis

E Membranoproliferative glomerulonephritis

Explanation

E Membranoproliferative glomerulonephritis

Membranoproliferative glomerulonephritis is associated with a 30–90% recurrence rate post renal transplant (type 2 much greater than type 1).

A Diabetic renal disease

It takes years to appear in a transplanted kidney.

B Focal segmental glomerulosclerosis

Whilst the recurrence rate is also high with FSGS (40%), it does not quite approach the levels seen with membranoproliferative glomerulonephritis.

C Minimal-change glomerulonephritis

This is not usually a cause of recurrence within renal transplant.

D Membranous glomerulonephritis

The recurrence rates from case series approach 30%, and therefore not as high as option E.

Rate this question:

Rana Alnasser's screen

Question

A 65-year-old man with type 2 diabetes mellitus is seen in the Diabetic Clinic for follow-up. He has been diabetic for nearly 10 years now, diet controlled for 4 years and since that time on gliclazide and metformin.

Unfortunately, he has missed many of his follow-up appointments. His blood pressure is 124/74 mmHg. He has no evidence of peripheral neuropathy.

Investigations from his last visit are as follows:

Haemoglobin A_{1c} (HbA_{1c})	45.36 mmol/mol (6.3 %)
Protein	Negative
Glucose	Negative
Leucocytes	Negative
Nitrites	Negative
Na^+	137 mmol/l
K^+	3.8 mmol/l
Urea	6.8 mmol/l
Creatinine	98 µmol/l

A 24-h urine collection was carried out which demonstrated 180 mg of albumin in the sample.

Which management step is most likely to improve his overall prognosis with respect to renal and other complications?

A Commencing an angiotensin-converting enzyme (ACE) inhibitor in the first instance

B Optimising glycaemic control

C Optimising blood pressure control with other agents besides ACE inhibitors in the first instance

Investigations from his last visit are as follows:

Haemoglobin A_{1c} (HbA_{1c})	45.36 mmol/mol (6.3 %)
Protein	Negative
Glucose	Negative
Leucocytes	Negative
Nitrites	Negative
Na^+	137 mmol/l
K^+	3.8 mmol/l
Urea	6.8 mmol/l
Creatinine	98 μmol/l

A 24-h urine collection was carried out which demonstrated 180 mg of albumin in the sample.

Which management step is most likely to improve his overall prognosis with respect to renal and other complications?

A Commencing an angiotensin-converting enzyme (ACE) inhibitor in the first instance

B Optimising glycaemic control

C Optimising blood pressure control with other agents besides ACE inhibitors in the first instance

D Commencing betablockade

E Commencing angiotensin receptor blockers (ARB) in the first instance

Rana Alnasser's screen

Creatinine	98 μmol/l

A 24-h urine collection was carried out which demonstrated 180 mg of albumin in the sample.

Which management step is most likely to improve his overall prognosis with respect to renal and other complications?

Your answer was correct

A Commencing an angiotensin-converting enzyme (ACE) inhibitor in the first instance

B Optimising glycaemic control

C Optimising blood pressure control with other agents besides ACE inhibitors in the first instance

D Commencing betablockade

E Commencing angiotensin receptor blockers (ARB) in the first instance

Explanation

A Commencing an angiotensin-converting enzyme (ACE) inhibitor in the first instance

ACE inhibitors have been shown to improve outcome in microalbuminuria in diabetic kidney disease and reduce progression to frank proteinuria and kidney disease. Additionally, they show cardiovascular (CV) outcome benefits in large randomised controlled trials (RCTs). Their use in this context has therefore become widespread.

10:54

MyPastest
https://mypastest.pastest.com

agents besides ACE inhibitors in the first instance

Although blood pressure control is important in delaying renal progression, ACE inhibition, in particular, has been proven to improve outcome in microalbuminuria in diabetic kidney disease and reduce progression to frank proteinuria and kidney disease. Therefore, ACE inhibition should be used in the first instance.

D Commencing betablockade

There is no evidence that beta blockade will improve renal prognosis aside from blood pressure control.

E Commencing angiotensin receptor blockers (ARB) in the first instance

There is growing evidence that ARBs have similar benefits to ACE inhibitors in heart failure and other indications, and they may have a lower incidence of side-effects. Whilst evidence of renoprotection from clinical trials is strong however, evidence of ischaemic CV outcome benefit is less clear. Just taking valsartan as one example: whilst a reduction in hospitalisations was seen in the main heart failure study, there was no reduction in mortality seen. For this reason, at the present time ACE inhibitors remain first-line in most cases.

Rate this question:

Next Question

Previous Q... Tag Questi... Feedback End Session

10:54

An 18-year-old woman presents with ankle swelling and facial puffiness. Two weeks previously, she had a flu-like illness with a productive cough. Her father reports that she had suffered a similar episode of swelling two years ago, but that things had returned to normal after a period of treatment.

At this time, urea and electrolytes (U&E) had been normal and her father does not recall her having had a rash.

On examination, there was no rash or fever. She had pitting oedema to the waist.

Initial investigations were as follows:

Albumin	29 g/l
Urea	5.0 mmol/l
Creatinine	60 µmol/l
Sodium	144 mmol/l
Potassium	4.0 mmol/l
Urinalysis	Protein +++
24-h urine collection	3.4 g protein

Given the likely diagnosis, what is the best initial treatment?

A Antibiotics

B Corticosteroids (high dose, 1 mg/kg)

C Cyclophosphamide

D Loop diuretics and an albumin infusion

Rana Alnasser's screen

At this time, urea and electrolytes (U&E) had been normal and her father does not recall her having had a rash.

On examination, there was no rash or fever. She had pitting oedema to the waist.

Initial investigations were as follows:

Albumin	29 g/l
Urea	5.0 mmol/l
Creatinine	60 µmol/l
Sodium	144 mmol/l
Potassium	4.0 mmol/l
Urinalysis	Protein +++
24-h urine collection	3.4 g protein

Given the likely diagnosis, what is the best initial treatment?

A Antibiotics

B Corticosteroids (high dose, 1 mg/kg)

C Cyclophosphamide

D Loop diuretics and an albumin infusion

E Nothing, observation only

71305

Submit

Rana Alnasser's screen

At this time, urea and electrolytes (U&E) had been normal and her father does not recall her having had a rash.

On examination, there was no rash or fever. She had pitting oedema to the waist.

Initial investigations were as follows:

Albumin	29 g/l
Urea	5.0 mmol/l
Creatinine	60 µmol/l
Sodium	144 mmol/l
Potassium	4.0 mmol/l
Urinalysis	Protein +++
24-h urine collection	3.4 g protein

Given the likely diagnosis, what is the best initial treatment?

Your answer was correct

A Antibiotics

B Corticosteroids (high dose, 1 mg/kg)

C Cyclophosphamide

D Loop diuretics and an albumin infusion

E Nothing, observation only

Explanation

Rana Alnasser's screen

Explanation

B	Corticosteroids (high dose, 1 mg/kg)

Nephrotic syndrome is defined by urinary protein loss of > 3.5 g of protein/24 h (0.05 g/kg per 24 h in children), accompanied by hypoalbuminaemia (75% of cases).

Upper respiratory tract infection (URTI) commonly precedes attacks, although a definite causal relationship is debated – the most common bacterial antigens implicated are streptococcal.

Minimal change disease has a good prognosis in childhood; a third have just one episode and a third have infrequent relapses, while a third have frequent relapses throughout childhood that stop in adult life.

Steroids are an effective treatment for minimal change disease, and as this is, by far, the most common cause of childhood nephrotic syndrome, a trial of high-dose steroids is accepted practice, with only those patients who do not respond being investigated for other renal disease.

A	Antibiotics

There is no role for prophylactic antibiotics; however, treatment may be required for infections.

C	Cyclophosphamide

There is no evidence for cyclophosphamide as primary treatment for minimal change disease. Cyclophosphamide is used as one of the standard treatments for vasculitis, as part of the CYCLOPS regimen, which includes methylprednisolone and monthly cyclophosphamide.

D	Loop diuretics and an albumin infusion

Loop diuretics may be required for fluid overload; however,

10:55

A 23-year-old adopted Jewish man is referred to the Renal Clinic by his GP because of proteinuria. The GP also reports that he has suffered intermittent illnesses in the past, characterised by severe fevers which were thought to be due to recurrent viral illnesses.

Other past history of note includes an appendicectomy, and arthritis affecting the hips and knees.

On physical examination, blood pressure is 130/80 mmHg, chest and abdominal examination was unremarkable. ESR checked by the GP during one of the recent attacks of fever was raised at 65 mm/h.

Investigations on the day of clinic visit revealed:

K^+	5.4 mmol/l
Na^+	138 mmol/l
Creatinine	80 µmol/l
Dipstick urine	Protein 3+
24-hour urine testing	>3 g protein

Which of the following diagnoses fits best with this clinical picture?

A AL amyloidosis

B Familial Mediterranean fever

C Minimal change disease

D Still's disease

E Systemic lupus erythematosus (SLE)

Rana Alnasser's screen

10:59

MyPastest
https://mypastest.pastest.com

B Familial Mediterranean fever

The answer is familial Mediterranean fever (FMF). Populations having a high prevalence (1/200-1/1000) of the disease are non-Ashkenazi Jews, Turks, Armenians and Arabs, but is also seen in Italy, Greece and Spain.. The disease is characterised by intermittent paroxysms of fever, chronic arthritis, appendicectomy related to paroxysmal abdominal pain and nephrotic syndrome due to renal amyloidosis. Pleuritic involvement and pericarditis may also occur in around 25% of patients. Mortality is related to deteriorating renal function. Colchicine therapy has been shown in a number of studies to delay deterioration in renal function and is the mainstay of therapy. A large number of patients do still progress and require renal transplantation.

A AL amyloidosis

AL amyloid is due to mononclonal light chains usually lambda or light chain fragments produced by plasma cell dyscrasia. It is more common in women who are over 50 years old. Although nephrotic range proteinuria is a usual presentation, there may be other signs such as easy bleeding, cardiomegaly and hepatomegaly. The young age and high fevers are unusual in AL amyloidosis.

C Minimal change disease

Minimal change disease is the most common cause of nephrotic syndrome in the young, therefore the age and nephrotic range proteinuria would fit with this diagnosis. However, there are no associated symptoms of arthritis or recurrent fevers with minimal change disease.

A 43-year-old man is brought into hospital during the night. He was found on the street smelling strongly of alcohol. Staff recall that he also has a history of intravenous drug use.

He is disorientated, localises pain and will open his eyes in response to a painful stimulus. Reflexes are symmetrically brisk. Pupils are 2 mm in diameter. His pulse is 110/min, blood pressure 95/60 mmHg, respiratory rate 12/min, oxygen saturation 97% on air

Initial Investigations reveal:

Electrocardiogram	Sinus tachycardia, inverted p wave aVr
Chest X-ray	Hyperinflated lung fields, old healed rib fractures
Urine dipstick	Protein +, blood +++
Haemoglobin	14g/dl
White cell count	11.5×10^9/l
Platelets	420×10^9/l
Sodium	135 mmol/l
Potassium	5.7 mmol/l
Urea	10.8 mmol/l
Creatinine	278 µmol/l
Calcium	2.03 mmol/l
Phosphate	1.69 mmol/l (0.8–1.4)

What appropriate step should be taken next?

A Intravenous calcium gluconate

B Vitamin D replacement therapy

Chest X-ray	Hyperinflated lung fields, old healed rib fractures
Urine dipstick	Protein +, blood +++
Haemoglobin	14g/dl
White cell count	11.5×10^9/l
Platelets	420×10^9/l
Sodium	135 mmol/l
Potassium	5.7 mmol/l
Urea	10.8 mmol/l
Creatinine	278 µmol/l
Calcium	2.03 mmol/l
Phosphate	1.69 mmol/l (0.8–1.4)

What appropriate step should be taken next?

A Intravenous calcium gluconate

B Vitamin D replacement therapy

C Catheterise and intravenous saline

D Intravenous antibiotics

E Intravenous naloxone

Submit

Rana Alnasser's screen

11:03
594-042-7551
Leave
MyPastest
https://mypastest.pastest.com

C Catheterise and intravenous saline

The diagnosis is rhabdomyolysis. The patient has high risk factors with alcohol and intravenous drug use. He has most likely been immobile on the street, or could have suffered injury while intoxicated. Inverted P waves in aVR are usually normal. Myoglobinuria gives a 'false-positive' on urine dipstick for blood. Tests reveal typically hyperkalaemia, hypocalcaemia, raised creatinine:urea ratio, hyperphosphataemia. Further confirmatory investigations include urine myoglobin, serum creatine kinase and serum myoglobin. Fluid resuscitation is needed with urine output measurement.

A Intravenous calcium gluconate

Calcium gluconate helps stabilise cardiac membrane in hyperkalaemia. In this case rehydration will help hyperkalaemia. The latter stages of rhabdomyolysis may result in hypercalcaemia as calcium is released from the muscles. This is more likely to occur if supplementary calcium has been given.

B Vitamin D replacement therapy

During later stages of rhabdomylosis, the accumulated calcium is released from the storage sites. This is often associated with hyperparathyroidism and hypervitaminosis D and overt hypercalcaemia. However, the hyperparathyroidism and hypervitaminosis D are not seen in all cases. Therefore, vitamin D is not a treatment.

D Intravenous antibiotics

Audio Video Share Participants More

muscles. This is more likely to occur if supplementary calcium has been given.

B Vitamin D replacement therapy

During later stages of rhabdomylosis, the accumulated calcium is released from the storage sites. This is often associated with hyperparathyroidism and hypervitaminosis D and overt hypercalcaemia. However, the hyperparathyroidism and hypervitaminosis D are not seen in all cases. Therefore, vitamin D is not a treatment.

D Intravenous antibiotics

There is no evidence of any infection. The white cell count is normal. Therefore, antibiotics would not be the treatment of choice.

E Intravenous naloxone

He does not have symptoms of opioid overdose which are sufficiently severe enough to require naloxone, and intravenous calcium can increase the destruction of muscle. The hyperkalaemia needs monitoring but no active treatment is needed currently as fluid hydration will help.

Rate this question:

Rana Alnasser's screen

11:05

A 40-year-old woman is admitted to the medical assessment unit with a history of fatigue, headache and leg oedema. She also complains of pruritus and heartburn.

On examination, she has slight oedema of the fingers and some perioral telangiectasia. Her mouth is dry and her jugular venous pressure (JVP) is slightly elevated. Auscultation of the lungs reveals fine bibasal end inspiratory crepitations. Her pulse is 105/min, respiratory rate 20/min, blood pressure 195/95 mmHg. There is thickening of the skin on the fingers with peripheral calcinosis. Urine dipstick shows proteinuria and blood film shows helmet cells.

Given the likely diagnosis, what treatment is likely to have the most favourable outcome?

A	Beta-blocker
B	Nitroprusside
C	Glucocorticoid
D	Angiotensin-converting enzyme inhibitor
E	Cyclophosphamide

Submit

Rana Alnasser's screen

A 40-year-old woman is admitted to the medical assessment unit with a history of fatigue, headache and leg oedema. She also complains of pruritus and heartburn.

On examination, she has slight oedema of the fingers and some perioral telangiectasia. Her mouth is dry and her jugular venous pressure (JVP) is slightly elevated. Auscultation of the lungs reveals fine bibasal end inspiratory crepitations. Her pulse is 105/min, respiratory rate 20/min, blood pressure 195/95 mmHg. There is thickening of the skin on the fingers with peripheral calcinosis. Urine dipstick shows proteinuria and blood film shows helmet cells.

Given the likely diagnosis, what treatment is likely to have the most favourable outcome?

Your answer was correct

A Beta-blocker

B Nitroprusside

C Glucocorticoid

D Angiotensin-converting enzyme inhibitor

E Cyclophosphamide

Explanation

D Angiotensin-converting enzyme inhibitor

The history and examination give features of scleroderma renal crisis. Histologically interlobular arteries are affected

11:06

MyPastest
https://mypastest.pastest.com

D Angiotensin-converting enzyme inhibitor

The history and examination give features of scleroderma renal crisis. Histologically interlobular arteries are affected with intimal thickening. Features include malignant hypertension, oliguria, fluid retention, and microangiopathic haemolytic anaemia. ACE inhibitors will significantly reduce progression to kidney disease and increase the chance of recovery if kidney disease has already developed.

A Beta-blocker

A beta-blocker may help control blood pressure, but it will not help control renal scleroderma renal crisis. It may make any Raynaud's phenomenon worse.

B Nitroprusside

An excessive reduction in pressure and hypovolaemia should be avoided in renal crisis because both can further diminish renal perfusion and superimpose acute tubular necrosis upon the lesions of scleroderma. Thus, parenteral antihypertensive agents (such as intravenous nitroprusside or labetalol) should be avoided, if possible, as should other nephrotoxins such as nonsteroidal anti-inflammatory drugs and radiocontrast agents.

C Glucocorticoid

Similarly, glucocorticoids are effective immunosuppressants; however, they are not used for the treatment of scleroderma. A side-effect of steroids is dyspepsia and may make heartburn symptoms worse.

Rana Alnasser's screen

An excessive reduction in pressure and hypovolaemia should be avoided in renal crisis because both can further diminish renal perfusion and superimpose acute tubular necrosis upon the lesions of scleroderma. Thus, parenteral antihypertensive agents (such as intravenous nitroprusside or labetalol) should be avoided, if possible, as should other nephrotoxins such as nonsteroidal anti-inflammatory drugs and radiocontrast agents.

C Glucocorticoid

Similarly, glucocorticoids are effective immunosuppressants; however, they are not used for the treatment of scleroderma. A side-effect of steroids is dyspepsia and may make heartburn symptoms worse.

E Cyclophosphamide

Cyclophosphamide is an immunosuppressant. It has not been shown to be an effective treatment for scleroderma renal crisis.

© Pastest 2019

Rana Alnasser's screen

11:06

A 33-year-old white man was admitted with a 1-week history of rash, pyrexia, generalised weakness and decreased urine output.

On examination, he was obese, with a temperature of 38.5 °C, BP 156/70 mmHg. He had nail-fold vasculitic skin lesions. On auscultation, he had a soft systolic murmur. Abdominal examination was limited given his size, but unremarkable.

Initial investigations reveal:

Hb	9 g/dl
WCC	18.5 × 109/l
Neutrophils	16.4 × 109/l
Platelets	80 × 109/l
Creatinine	336 µmol/l
Urine microscopy	Red cell casts
Hepatitis B	negative
Hepatitis C	negative
ANCA/GBM	negative
Cryoglobulins	positive
ASOT	negative
Protein electrophoresis	negative

Ultrasound renal scan of the abdomen showed an 11-cm spleen.

Renal biopsy was not performed, as it was not technically possible.

What is the most likely diagnosis?

Rana Alnasser's screen

Hepatitis B	negative
Hepatitis C	negative
ANCA/GBM	negative
Cryoglobulins	positive
ASOT	negative
Protein electrophoresis	negative

Ultrasound renal scan of the abdomen showed an 11-cm spleen.

Renal biopsy was not performed, as it was not technically possible.

What is the most likely diagnosis?

A Microscopic polyangiitis

B Infective endocarditis

C Acute pyelonephritis

D HIV-associated nephropathy

E Renal tuberculosis

Submit

Previous Q... Skip Questi...

Rana Alnasser's screen

E Renal tuberculosis

Explanation

B Infective endocarditis

The history and investigations are consistent with infective endocarditis. One third of patients with bacterial endocarditis develop AKI. The glomerulonephritis is associated with deposition of immune complexes containing bacterial antigens in glomeruli. Cryoglobulins (polyclonal or type III) are present in 50% of subjects.

A Microscopic polyangiitis

Microscopic polyangiitis may present with nail-fold vasculitic lesions but these patients are commonly ANCA-positive.

C Acute pyelonephritis

The heart murmur, negative urinary sediment and positive cryoglobulins make this unlikely.

D HIV-associated nephropathy

There is no weight loss or lymphopenia. HIVAN occurs almost exclusively in black patients, and they tend to be normotensive.

E Renal tuberculosis

Renal TB is associated with an insidious onset of renal impairment with asymptomatic urinary abnormalities such as persistent sterile pyuria. It may or may not be associated with extrarenal systemic manifestations.

Microscopic polyangiitis may present with nail-fold vasculitic lesions but these patients are commonly ANCA-positive.

C Acute pyelonephritis

The heart murmur, negative urinary sediment and positive cryoglobulins make this unlikely.

D HIV-associated nephropathy

There is no weight loss or lymphopenia. HIVAN occurs almost exclusively in black patients, and they tend to be normotensive.

E Renal tuberculosis

Renal TB is associated with an insidious onset of renal impairment with asymptomatic urinary abnormalities such as persistent sterile pyuria. It may or may not be associated with extrarenal systemic manifestations.

Rate this question:

Next Question

© Pastest 2019

A 42-year-old man has completed 2 years of haemodialysis and is suffering increasing symptoms of tiredness and lethargy. His past medical history includes hypertension and type 2 diabetes mellitus. He is frustrated with waiting for a cadaveric transplant and wants to discuss options for securing a new kidney.

On physical examination, his blood pressure is 140/80 mmHg; chest and abdominal examination is unremarkable.

Investigations:

Hb	10.9 g/dl
WCC	5.4×10^9/l
PLT	167×10^9/l
Na^+	139 mmol/l
K^+	5.4 mmol/l
Creatinine	456 µmol/l

Ejection fraction 48%.

Which of the following is the best advice?

A	Convince him to take his willing 13-year-old son's kidney
B	Suggest that he will have to wait his turn on cadaveric transplant list
C	His wife is highly likely to be a match and should be approached
D	Refer for urgent cadaveric transplant
E	Urge him to contact an overseas supplier to source a kidney

kidney

B Suggest that he will have to wait his turn on cadaveric transplant list

C His wife is highly likely to be a match and should be approached

D Refer for urgent cadaveric transplant

E Urge him to contact an overseas supplier to source a kidney

Explanation

B Suggest that he will have to wait his turn on cadaveric transplant list

Currently he should continue to wait his turn on the cadaveric list, although it should be possible to review the possibility of a transplant from his son in 2 or 3 years time. Clearly should his medical status to deteriorate, then he could be moved to the urgent cadaveric transplant list.

A Convince him to take his willing 13-year-old son's kidney

It's inappropriate for this man to receive a kidney from his 13-year-old son, and his symptoms do not currently suggest that he requires urgent transplantation. Potential indications for urgent transplantation will include lack of dialysis access, severe psychological problems, severe complications of haemodialysis (severe hypotension during treatment) and uraemic polyneuropathy.

Rana Alnasser's screen

possibility of a transplant from his son in 2 or 3 years time. Clearly should his medical status to deteriorate, then he could be moved to the urgent cadaveric transplant list.

A Convince him to take his willing 13-year-old son's kidney

It's inappropriate for this man to receive a kidney from his 13-year-old son, and his symptoms do not currently suggest that he requires urgent transplantation. Potential indications for urgent transplantation will include lack of dialysis access, severe psychological problems, severe complications of haemodialysis (severe hypotension during treatment) and uraemic polyneuropathy.

C His wife is highly likely to be a match and should be approached

A genetically related first-degree relative is more likely to be a match compared to his wife.

D Refer for urgent cadaveric transplant

As explained previously, this gentleman has no indication at present for urgent renal transplantation. Potential indications for urgent transplantation will include lack of dialysis access, severe psychological problems, severe complications of haemodialysis (severe hypotension during treatment) and uraemic polyneuropathy.

E Urge him to contact an overseas supplier to source a kidney

This man does not have any urgent need for renal transplantation. It is preferable for a living donation from a closely related first-degree relative because they are more likely to share the same tissue type and blood group as the recipient.

11:14

A 70-year-old man was admitted with anuria and lower back pain of 24 h duration.

His only medication is bendroflumethiazide 2.5 mg for hypertension. He is awaiting an appointment for urinary frequency, urgency and dribbling; otherwise he is fit and well.

Investigations reveal:

Haemoglobin (Hb)	12.5 g/dl
White cell count (WCC)	5.6×10^9/l
Platelets (PLT)	160×10^9/l
Sodium (Na^+)	134 mmol/l
Potassium (K^+)	6.5 mmol/l
Urea	20.6 mmol/l
Creatinine (Cr)	400 µmol/l
Corrected calcium	2.70 mmol/l
Albumin (Alb)	35 g/l
Total protein	80 g/l

You have given him intravenous (iv) insulin and dextrose to reduce his potassium. A follow-up potassium level is measured at 5.4 mmol/l, and you catheterise him.

Which of the following is the next most appropriate management?

A Urgent haemodialysis

B Central venous line for monitoring intravascular volume

Rana Alnasser's screen

White cell count (WCC)	5.6×10^9/l
Platelets (PLT)	160×10^9/l
Sodium (Na^+)	134 mmol/l
Potassium (K^+)	6.5 mmol/l
Urea	20.6 mmol/l
Creatinine (Cr)	400 µmol/l
Corrected calcium	2.70 mmol/l
Albumin (Alb)	35 g/l
Total protein	80 g/l

You have given him intravenous (iv) insulin and dextrose to reduce his potassium. A follow-up potassium level is measured at 5.4 mmol/l, and you catheterise him.

Which of the following is the next most appropriate management?

A	Urgent haemodialysis
B	Central venous line for monitoring intravascular volume
C	Restrict oral fluid
D	Urgent intravenous urography (IVU)
E	Urgent renal tract ultrasound

6971

Submit

D Urgent intravenous urography (IVU)

E Urgent renal tract ultrasound

Explanation

E Urgent renal tract ultrasound

The symptom of urinary frequency and the age of the patient suggest probable prostatic hypertrophy. Prostatic obstruction is the most common cause of obstructive uropathy in men.

In community studies, urinary tract obstruction is responsible for 25% of cases of acute kidney disease. It is easily treatable if the diagnosis is made accurately and early. The cause of the acute presentation in this case is most likely due to obstructive uropathy.

The first investigation should be renal and pelvic ultrasound to exclude hydronephrosis which, if present, warrants urgent nephrostomy for ureteric obstruction, or transurethral/suprapubic catheterisation, as appropriate, for bladder obstruction. Renal function often normalises with relief of the obstruction.

A Urgent haemodialysis

There are no acute indications in this scenario for urgent haemodialysis such as uraemic symptoms, resistant hyperkalaemia or resistant acidosis and pulmonary oedema not amenable to medical treatment.

B Central venous line for monitoring intravascular volume

early. The cause of the acute presentation in this case is most likely due to obstructive uropathy.

The first investigation should be renal and pelvic ultrasound to exclude hydronephrosis which, if present, warrants urgent nephrostomy for ureteric obstruction, or transurethral/suprapubic catheterisation, as appropriate, for bladder obstruction. Renal function often normalises with relief of the obstruction.

A Urgent haemodialysis

There are no acute indications in this scenario for urgent haemodialysis such as uraemic symptoms, resistant hyperkalaemia or resistant acidosis and pulmonary oedema not amenable to medical treatment.

B Central venous line for monitoring intravascular volume

Central venous line may be useful to discern the volume status of the patient, but in this scenario of obstruction, it would not be helpful.

C Restrict oral fluid

Restriction of oral fluid would make the patient dehydrated and will not resolve the obstruction.

D Urgent intravenous urography (IVU)

IVU would be more invasive than ultrasound of the urinary tract. Ultrasound would be less invasive, easy to carry out and contrast-free.

Rate this question:

Rana Alnasser's screen

A 31-year-old housewife attends the Diabetic Clinic for the first time. She is a patient who has had type 1 diabetes for 8 years, and her blood sugar level is usually between 5 and 9 mmol/l. She leads a sedentary lifestyle, is obese and smokes about 10 cigarettes/day.

On examination, her blood pressure is 140/95 mmHg and her pulse is 68 bpm and regular.

Investigations:

Hb	13.4 g/dl
WCC	5.2×10^9/l
MCV	78 fl
PLT	214×10^9/l
HbA_{1c}	69.40 mmol/mol (8.5%)
Na	135 mmol/l
K	4.0 mmol/l
Urea	7.3 mmol/l
Creatinine	131 µmol/l
24 h protein	200 mg

There is evidence of background diabetic retinopathy.

What is the best medication to initiate to prevent renal disease progression?

A Aspirin

B Gliclazide

C Metformin

D Ramipril

On examination, her blood pressure is 140/95 mmHg and her pulse is 68 bpm and regular.

Investigations:

Hb	13.4 g/dl
WCC	5.2×10^9/l
MCV	78 fl
PLT	214×10^9/l
HbA_{1c}	69.40 mmol/mol (8.5%)
Na	135 mmol/l
K	4.0 mmol/l
Urea	7.3 mmol/l
Creatinine	131 µmol/l
24 h protein	200 mg

There is evidence of background diabetic retinopathy.

What is the best medication to initiate to prevent renal disease progression?

A Aspirin

B Gliclazide

C Metformin

D Ramipril

E Simvastatin

Rana Alnasser's screen

Explanation

D Ramipril

This patient has proteinuria, and there is clear evidence that angiotensin-converting enzyme (ACE) inhibitors such as ramipril slow the rate of decline in renal function in patients with type 2 diabetes and established diabetic nephropathy. The MICRO-HOPE study also showed that there is mortality benefit in this group of patients.

A Aspirin

There is no evidence that aspirin reduces renal disease progression: in fact there may be increased risk of bleeding.

B Gliclazide

This patient has type 1 diabetes. There is no role in this situation for use of gliclazide, which has even fallen out of favour in type 2 diabetes due to weight gain and hypoglycaemia.

C Metformin

Metformin, although useful in Type 2 diabetes as it promotes modest weight loss and glucose control, has no significant role in the treatment of type 1 diabetes. Furthermore, if the eGFR is <30% there is risk of lactic acidosis.

E Simvastatin

Cholesterol control is important in primary cardiovascular prevention in patients with diabetes. However, although there is trial evidence from the SHARPS trial that in

11:21

A 70-year-old white man with a history of intermittent microscopic haematuria presented with generalised fatigue, cough, and vague abdominal pain and diarrhoea. He has a history of hypertension and was on irbesartan. Baseline renal function was normal when checked by his general practitioner (GP) three weeks previously.

Initial investigations:

Hb	7.8 g/dl
Haematocrit	0.4
Platelets	98 × 109/l
Creatinine	250 µmol/l
Amylase	150 U/l
LFTs	normal

Urine microscopy was not done on admission.

Ultrasound scans of abdomen and pelvis were normal.

The chest X-ray is shown below:

He was treated with ciprofloxacin for a presumed chest infection. He then developed acute ischaemic bowel requiring resection, with non-specific pathological findings. The hospital course was complicated by hypotension and multi-organ failure. The creatinine rose to 636 µmol/l with [illegible] initiated.

Rana Alnasser's screen

11:23

rasound scans of abdomer

e chest X-ray is shown belc

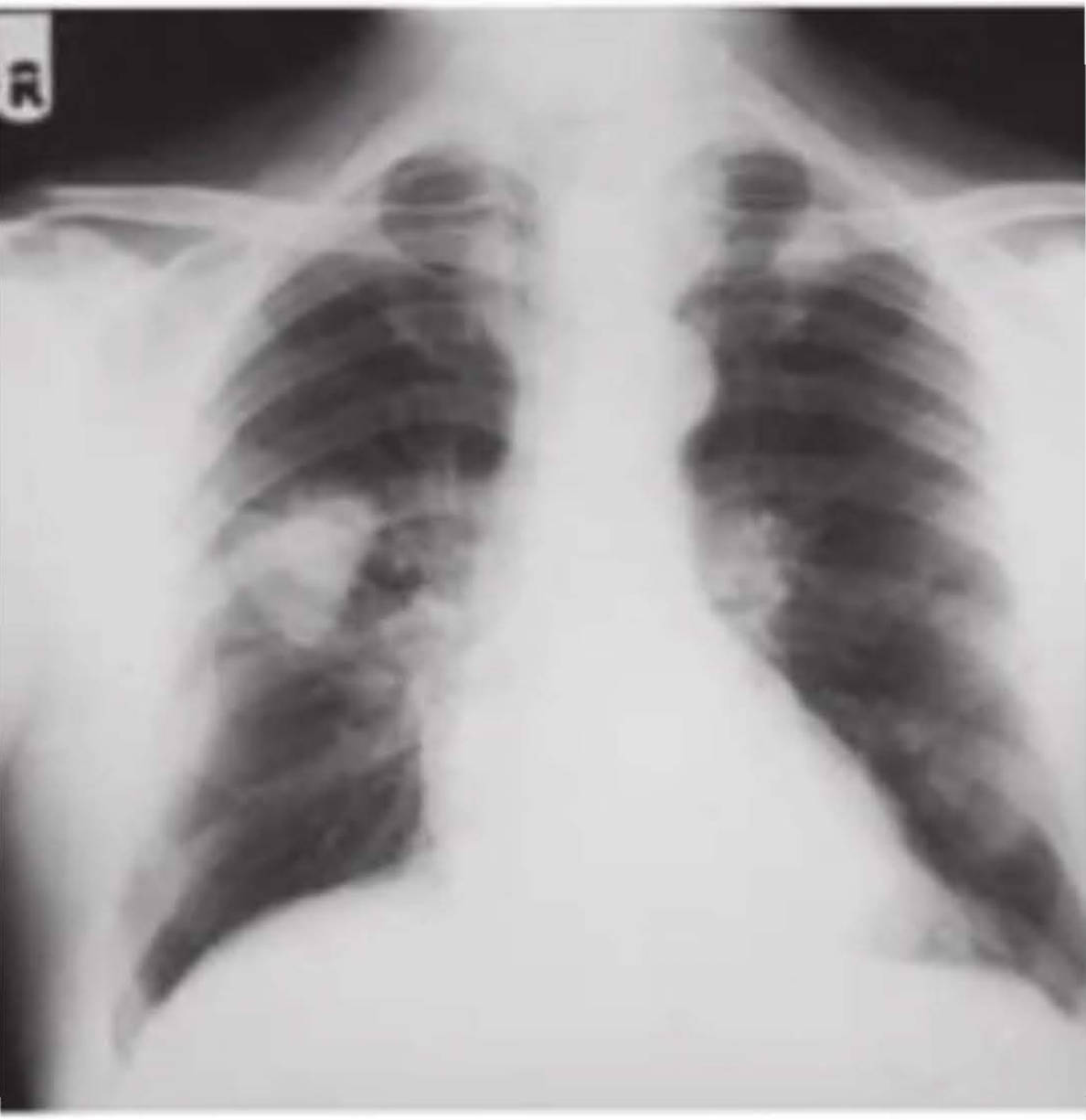

was treated with ciproflox
ection. He then developed
quiring resection, with non-
e hospital course was comp
lti-organ failure. The creati

Rana Alnasser's screen

multi-organ failure. The creatinine rose to 636 µmol/l with anuria; haemodialysis was initiated.

Urine microscopy	Numerous red blood cells
Protein excretion	3 g/24 h
ANA, ANCA	negative
HBsAg	negative
HCV	negative
Cryoglobulins	negative
C3	107 mg/dl (65-190 mg/dl)
C4	38 mg/dl (15-50 mg/dl)
Protein electrophoresis	normal pattern

Renal biopsy was performed which showed crescentic glomerulonephritis with linear IgG staining on immunofluorescence.

What is the most likely diagnosis?

A Acute pyelonephritis

B Anti-glomerular basement membrane disease

C Haemolytic uraemic syndrome

D Microscopic polyangiitis

E Post-streptococcal glomerulonephritis (PSGN)

Submit

11:26

Cryoglobulins	negative
C3	107 mg/dl (65-190 mg/dl)
C4	38 mg/dl (15-50 mg/dl)
Protein electrophoresis	normal pattern

Renal biopsy was performed which showed crescentic glomerulonephritis with linear IgG staining on immunofluorescence.

What is the most likely diagnosis?

Your answer was correct

A Acute pyelonephritis

B Anti-glomerular basement membrane disease

C Haemolytic uraemic syndrome

D Microscopic polyangiitis

E Post-streptococcal glomerulonephritis (PSGN)

Explanation

B Anti-glomerular basement membrane disease

The initial presentation was of a patient with haematuria, subclinical lung haemorrhage and acute kidney injury. Often, lung haemorrhage may present without haemoptysis and in this case was incorrectly diagnosed as chest infection. The clinical presentation and subsequent rapid deterioration was consistent with the syndrome of

Rana Alnasser's screen

B Anti-glomerular basement membrane disease

The initial presentation was of a patient with haematuria, subclinical lung haemorrhage and acute kidney injury. Often, lung haemorrhage may present without haemoptysis and in this case was incorrectly diagnosed as chest infection. The clinical presentation and subsequent rapid deterioration was consistent with the syndrome of alveolar haemorrhage and kidney disease caused by anti-glomerular basement membrane (GBM) antibodies (Goodpasture syndrome).

Diagnosis is made by the presence of circulating anti-GBM antibodies and on renal biopsy. Typical appearances are of diffuse proliferative glomerulonephritis with variable degrees of necrosis, crescent formation as in this case, glomerulosclerosis and tubular loss. Treatment is with cytotoxic immunosuppression and plasma exchange. Poor prognostic factors are advanced kidney disease on presentation and the degree of crescent formation. Other causes of this syndrome are granulomatosis with polyangiitis (previously referred to as Wegener's granulomatosis; ANCA-positive in 95% of patients), systemic lupus erythematosus (SLE), Churg–Strauss syndrome and mixed essential cryoglobulinaemia.

A Acute pyelonephritis

Acute pyelonephritis is incorrect and does not explain the pulmonary findings. Acute pyelonephritis would present with acute fevers, chills and rigors. There may be loin pain. Treatment is with antibiotics and/or drainage of any abscess that are present.

C Haemolytic uraemic syndrome

Haemolytic uraemic syndrome is incorrect, as the renal biopsy findings point against this. Haemolytic uraemic

causes of this syndrome are granulomatosis with polyangiitis (previously referred to as Wegener's granulomatosis; ANCA-positive in 95% of patients), systemic lupus erythematosus (SLE), Churg–Strauss syndrome and mixed essential cryoglobulinaemia.

A Acute pyelonephritis

Acute pyelonephritis is incorrect and does not explain the pulmonary findings. Acute pyelonephritis would present with acute fevers, chills and rigors. There may be loin pain. Treatment is with antibiotics and/or drainage of any abscess that are present.

C Haemolytic uraemic syndrome

Haemolytic uraemic syndrome is incorrect, as the renal biopsy findings point against this. Haemolytic uraemic syndrome is a disease characterised by haemolytic anaemia, acute kidney disease and thrombocytopenia. The renal biopsy would show thrombotic microangiopathy.

D Microscopic polyangiitis

Microscopic polyangiitis may also cause Goodpasture syndrome, but the negative ANCA makes it unlikely. Microscopic polyangiitis is a vasculitis which can affect kidneys, lungs, nerves, skin and joints. The pathological evidence would show necrotising granulomatous inflammation. P-ANCA is positive.

E Post-streptococcal glomerulonephritis (PSGN)

C3 was normal and PSGN rarely results in nephrotic range proteinuria. Renal biopsy is not performed in most patients to confirm the diagnosis of PSGN, since the resolution of PSGN typically begins within one week of presentation.

Touc... 00:15 11:27

A 27-year old African gentleman is admitted with symptoms of generalised muscle weakness. He has a family history of sickle cell anaemia and has needed admission to hospital in the past with renal colic.

On admission, his blood pressure is 120/70 mmHg.

Venous blood results:

Na^+	142 mmol/l
K^+	1.8 mmol/l
Bicarbonate	13 mmol/l
Chloride	117 mmol/l

Arterial blood gas:

pH	7.26
$p(CO_2)$	3.0 kPa

The most likely diagnosis and cause for the above blood results is:

A Distal renal tubular acidosis

B Proximal renal tubular acidosis

C Type 4 renal tubular acidosis

D Bartter's syndrome

E Diabetic ketoacidosis

Rana Alnasser's screen

E Diabetic ketoacidosis

Explanation

A Distal renal tubular acidosis

The information given is ideal to work out the anion gap:

$(Na^+ + K^+) - (Cl^- + HCO_3^-) = (142 + 1.8) - (117 + 13) = 13.8$

Hence we are looking at a normal anion gap acidosis with hypokalaemia. In distal (type 1) renal tubular acidosis there is failure of hydrogen excretion by the distal tubule of the nephron, with associated hypokalaemia. Of the available options this is most likely as there is an association with sickle cell anaemia, and these patients can get renal stones.

B Proximal renal tubular acidosis

In proximal (type 2) renal tubular acidosis there is failure of bicarbonate reabsorption in the proximal tubule of the nephron, usually occurring in infancy.

C Type 4 renal tubular acidosis

Type 4 renal tubular acidosis is also known as hyporeninaemic hypoaldosteronism. This condition would cause acidosis and hyperkalaemia.

D Bartter's syndrome

In this condition there is hyperplasia of the juxtaglomerular apparatus and biochemically there are hypokalaemia, alkalosis and hypercalciuria, with a normal blood pressure.

$(Na^+ + K^+) - (Cl^- + HCO_3^-) = (142 + 1.8) - (117 + 13) = 13.8$

Hence we are looking at a normal anion gap acidosis with hypokalaemia. In distal (type 1) renal tubular acidosis there is failure of hydrogen excretion by the distal tubule of the nephron, with associated hypokalaemia. Of the available options this is most likely as there is an association with sickle cell anaemia, and these patients can get renal stones.

B Proximal renal tubular acidosis

In proximal (type 2) renal tubular acidosis there is failure of bicarbonate reabsorption in the proximal tubule of the nephron, usually occurring in infancy.

C Type 4 renal tubular acidosis

Type 4 renal tubular acidosis is also known as hyporeninaemic hypoaldosteronism. This condition would cause acidosis and hyperkalaemia.

D Bartter's syndrome

In this condition there is hyperplasia of the juxtaglomerular apparatus and biochemically there are hypokalaemia, alkalosis and hypercalciuria, with a normal blood pressure.

E Diabetic ketoacidosis

This causes an elevated anion gap because of the acidic ketones in the blood.

8542

Rate this question:

Next Question

A 28-year-old woman who is 14 weeks' pregnant with her first pregnancy attends for a routine antenatal check. Her only past history of note includes two admissions to hospital with pyelonephritis as a child. She takes no regular medication.

On examination, her blood pressure is 142/92 mmHg. It is rechecked an hour later and found to be 138/90 mmHg. There was no other significant abnormality found.

Investigations:

Na^+	137 mmol/l
K^+	4.2 mmol/l
Urea	4.5 mmol/l
Creatinine	150 µmol/l
Urinalysis	NAD
Ultrasound scan, kidneys:	
Right kidney BPD	10.8 cm
Left kidney BPD	5.5 cm
Left kidney	Irregular outline

What is the likely diagnosis?

A Chronic pyelonephritis

B Congenital renal atrophy

C Glomerulonephritis

D Pre-eclampsia

E Renal artery stenosis

There was no other significant abnormality found.

Investigations:

Na^+	137 mmol/l
K^+	4.2 mmol/l
Urea	4.5 mmol/l
Creatinine	150 µmol/l
Urinalysis	NAD
Ultrasound scan, kidneys:	
Right kidney BPD	10.8 cm
Left kidney BPD	5.5 cm
Left kidney	Irregular outline

What is the likely diagnosis?

Your answer was correct

A Chronic pyelonephritis

B Congenital renal atrophy

C Glomerulonephritis

D Pre-eclampsia

E Renal artery stenosis

Explanation

A Chronic pyelonephritis

Explanation

A	Chronic pyelonephritis

This woman has hypertension in pregnancy, of which there are many causes. Her ultrasound scan showing a damaged left kidney is suggestive of chronic pyelonephritis. Chronic long-term renal damage related to pyelonephritis may predispose to the development of hypertension. Enalapril, bendrofluazide, hydralazine and atenolol are not recommended for the treatment of hypertension at this stage of pregnancy, but methyldopa would be an acceptable choice. Long-term management of the condition involves identification of any predisposing risk factors, such as abnormal ureteric implantation or other structural problem that might be suitable for surgical repair.

B	Congenital renal atrophy

Congenital renal atrophy may be an incidental finding where one kidney is smaller than the other. There are no complications and she does not need any special treatment. The history of pyelonephritis as a child suggests that chronic pyelonephritis is more likely to be the cause rather than congenital renal atrophy.

C	Glomerulonephritis

Glomerulonephritis would not present with one smaller kidney compared with the other unless it is a very chronic process, in which case there would be long-standing renal impairment and hypertension. You would expect blood and protein in the urine in glomerulonephritis.

D	Pre-eclampsia

Pre-eclampsia would not present with one smaller kidney.

impairment and hypertension. You would expect blood and protein in the urine in glomerulonephritis.

D Pre-eclampsia

Pre-eclampsia would not present with one smaller kidney. There would be hypertension and a significant amount of proteinuria. The condition begins after 20 weeks of pregnancy. In severe disease there is microangiopathic anaemia, low platelet count, impaired liver function tests, dyspnoea and oedema.

E Renal artery stenosis

Renal artery stenosis will present with hypertension that may be resistant to treatment. Although the renal size may be smaller on the side of the renal artery stenosis, we would expect the patient to have long-standing renal impairment and hypertension. Also, renal artery stenosis is very uncommon in young patients unless due to rare conditions such as fibromuscular dysplasia or Takayasu's arteritis.

Rate this question:

Next Question

© Pastest 2019

A 31-year-old woman with proven diabetic nephropathy attends the Renal Clinic for follow-up. She is 12 weeks' pregnant.

Her HbA_{1c} has been relatively satisfactory in the past few years, averaging 55.19 mmol/mol (7.2%), and the last recorded creatinine was 145 µmol/l. She has already stopped her ACE inhibitor, but wants to know about the prognosis with respect to her kidney disease.

Her investigations during this clinic appointment reveals:

Dipstick urine	Microalbuminuria
Hb	10.9 g/dl
HBA_{1c}	56 mmol/mol
Na^+	138 mmol/l
K^+	4.2 mmol/l
Creatinine	146 µmol/l
Urea	12.2 mmol/l

Which one of the following best describes the prognosis with respect to her diabetic nephropathy during pregnancy?

A She has a 10% chance of worsening renal function

B She has a 16% chance of worsening renal function

C She has an 80% chance of worsening renal function

D She should be advised to undergo a termination as she is likely to develop acute kidney disease

years, averaging 55.19 mmol/mol (7.2%), and the last recorded creatinine was 145 μmol/l. She has already stopped her ACE inhibitor, but wants to know about the prognosis with respect to her kidney disease.

Her investigations during this clinic appointment reveals:

Dipstick urine	Microalbuminuria
Hb	10.9 g/dl
HBA_{1c}	56 mmol/mol
Na^+	138 mmol/l
K^+	4.2 mmol/l
Creatinine	146 μmol/l
Urea	12.2 mmol/l

Which one of the following best describes the prognosis with respect to her diabetic nephropathy during pregnancy?

A She has a 10% chance of worsening renal function

B She has a 16% chance of worsening renal function

C She has an 80% chance of worsening renal function

D She should be advised to undergo a termination as she is likely to develop acute kidney disease

E There is less than 5% chance of a worsening of her renal function

71275

Rana Alnasser's screen

11:41

MyPastest
https://mypastest.pastest.com

E There is less than 5% chance of a worsening of her renal function

Explanation

B She has a 16% chance of worsening renal function

A recent case series demonstrated that there is worsening of renal function in up to 45% of patients who get pregnant with pre-existing diabetic nephropathy. In a general case series, Katz *et al* demonstrated worsening renal function to chronic kidney disease in 16% of patients with mild renal impairment (creatinine < 150 μmol/l), worsening to chronic kidney disease in 20% with creatinine 150–240 μmol/l, and worsening to end-stage renal disease in 45% where creatinine is above 240 μmol/l. Worsening hypertension is strongly associated with the degree of renal progression. A generally poorer prognosis during pregnancy is associated with lupus as the underlying cause of renal impairment.

E There is less than 5% chance of a worsening of her renal function

A recent case series demonstrated that there is worsening of renal function in up to 45% of patients who get pregnant with pre-existing diabetic nephropathy.

A She has a 10% chance of worsening renal function

A recent case series demonstrated that there is worsening of renal function in up to 45% of patients who get pregnant with pre-existing diabetic nephropathy.

C [illegible] 80% chance of worsening renal

Rana Alnasser's screen

with pre-existing diabetic nephropathy.

A She has a 10% chance of worsening renal function

A recent case series demonstrated that there is worsening of renal function in up to 45% of patients who get pregnant with pre-existing diabetic nephropathy.

C She has an 80% chance of worsening renal function

A recent case series demonstrated that there is worsening of renal function in up to 45% of patients who get pregnant with pre-existing diabetic nephropathy.

D She should be advised to undergo a termination as she is likely to develop acute kidney disease

In a general case series, Katz *et al* demonstrated worsening renal function to end-stage renal disease in 16% of patients with mild renal impairment (creatinine < 150 μmol/l). This woman needs close monitoring of renal function, but will not need a termination.

Rate this question:

© Pastest 2019

Rana Alnasser's screen

11:41
594-042-7551
Leave

A 63-year-old man with known chronic kidney disease (CKD) was admitted to another hospital six months ago with hypertension and congestive cardiac failure (CCF) where he was treated with furosemide (frusemide) 120 mg and enalapril 5 mg. His haemoglobin (Hb) concentration at that time was 11.0 g/dl and his creatinine level was 300 µmol/l. He has now presented to his regular hospital with lethargy.

During the intervening period, his GP has uptitrated his enalapril to 20 mg per day. His blood pressure is 115/70 mmHg, his jugular venous pressure (JVP) is visible and not raised. Chest is clear and abdomen is soft and non-tender. There is no peripheral oedema.

Investigations show:

Hb	8.0 g/dl
WCC	5.1×10^9/l
Na^+	140 mmol/l
K^+	5.3 mmol/l
Urea	15.0 mmol/l
Creatinine	380 µmol/l
Urine dipstick	Protein 3+, blood none

What would be the most appropriate management of this patient?

A Reduce enalapril

B Reduce furosemide (frusemide)

C Stop all drugs

D Stop enalapril

Audio Video Share Participants More

with hypertension and congestive cardiac failure (CCF) where he was treated with furosemide (frusemide) 120 mg and enalapril 5 mg. His haemoglobin (Hb) concentration at that time was 11.0 g/dl and his creatinine level was 300 μmol/l. He has now presented to his regular hospital with lethargy.

During the intervening period, his GP has uptitrated his enalapril to 20 mg per day. His blood pressure is 115/70 mmHg, his jugular venous pressure (JVP) is visible and not raised. Chest is clear and abdomen is soft and non-tender. There is no peripheral oedema.

Investigations show:

Hb	8.0 g/dl
WCC	5.1×10^9/l
Na^+	140 mmol/l
K^+	5.3 mmol/l
Urea	15.0 mmol/l
Creatinine	380 μmol/l
Urine dipstick	Protein 3+, blood none

What would be the most appropriate management of this patient?

A Reduce enalapril

B Reduce furosemide (frusemide)

C Stop all drugs

D Stop enalapril

E Stop furosemide (frusemide)

There is no peripheral oedema.

Investigations show:

Hb	8.0 g/dl
WCC	5.1×10^9/l
Na^+	140 mmol/l
K^+	5.3 mmol/l
Urea	15.0 mmol/l
Creatinine	380 µmol/l
Urine dipstick	Protein 3+, blood none

What would be the most appropriate management of this patient?

Your answer was incorrect

A Reduce enalapril

B Reduce furosemide (frusemide)

C Stop all drugs

D Stop enalapril

E Stop furosemide (frusemide)

Explanation

A Reduce enalapril

In chronic kidney disease, angiotensin-converting enzyme (ACE) inhibitors can reduce the rate of loss of renal

Explanation

A Reduce enalapril

In chronic kidney disease, angiotensin-converting enzyme (ACE) inhibitors can reduce the rate of loss of renal function even if the blood pressure is normal. This is especially true if there is proteinuria. However, ACE inhibitors should be used with caution in kidney disease, preferably under specialist supervision, and their response monitored. Hyperkalaemia and other side-effects from their use are more common in renal impairment. At this stage there is still some room for manoeuvre and his enalpril can be downtitrated to establish the effect on his creatinine and his potassium. This is the most appropriate option here as the creatinine deterioration has corresponded with the uptitration of enalapril by his GP, whereas the worsening anaemia is due to decreased erythropoietin production in kidney as the kidney function deteriorated.

D Stop enalapril

Using ACE inhibitors is important for proteinuria control; therefore to stop enalapril altogether would not be beneficial. There is room for manoeuvre; therefore reduction with careful monitoring would be a more appropriate option.

B Reduce furosemide (frusemide)

Reduction of the loop diuretic dose would contribute to the hyperkalaemia.

C Stop all drugs

Stopping all medications may cause hypertension with

Using ACE inhibitors is important for proteinuria control; therefore to stop enalapril altogether would not be beneficial. There is room for manoeuvre; therefore reduction with careful monitoring would be a more appropriate option.

B Reduce furosemide (frusemide)

Reduction of the loop diuretic dose would contribute to the hyperkalaemia.

C Stop all drugs

Stopping all medications may cause hypertension with stopping the enalapril. There would be a risk of rebound pulmonary oedema with stopping the diuretic.

E Stop furosemide (frusemide)

Temporary withdrawal of the loop diuretic may cause rebound pulmonary oedema.

Rate this question:

Next Question

Previous Q... Tag Questi... Feedback End Session

Blog About Pastest Contact Us Help

© Pastest 2019

A 27-year-old, normotensive type 1 diabetic, who was diagnosed at age 18 years, is seen in the Diabetic Clinic. He has pre-proliferative retinopathy, but no other known diabetic complications.

He has good glycaemic control. A spot urine test in the clinic reveals microalbuminuria. This has not been noted before.

His blood results are below:

Haemoglobin (Hb)	15 g/dl
White cell count (WCC)	5.0×10^9/l
Platelets (PLT)	200×10^9/l
Creatinine (Cr)	90 μmol/l
Sodium (Na^+)	136 mmol/l
Potassium (K^+)	3.8 mmol/l
Urea	5.2 mmol/l

What is the most appropriate initial management strategy?

A Start an angiotensin-converting enzyme (ACE) inhibitor

B Confirm microalbuminuria by sending an early-morning urine sample for albumin-to-creatinine ratio (ACR)

C Start an angiotensin II inhibitor

D Commence a low-protein diet

E Start a calcium channel antagonist

B Confirm microalbuminuria by sending an early morning urine sample for albumin-to-creatinine ratio (ACR)

Microalbuminuria is a reliable predictive marker of progression to nephropathy in type 1 diabetes mellitus. The early urinary albumin excretion rates of 30–300 mg/24 h are too small to be detected on conventional urine dipsticks, and either special dipsticks or radioimmunoassay is used.

The next stages are macroalbuminuria (> 300 mg/24 h) and then persistent proteinuria, by which time chronic kidney disease is usually 5–10 years away.

The optimal treatment for diabetic albuminuria is an ACE inhibitor (or an angiotensin II inhibitor), in combination with meticulous glycaemic and blood pressure control. When the initial detection of proteinuria is between 3 and 70 mg/mmol (microalbuminuria), then this should be confirmed with early-morning samples of urine sent for ACR.

A Start an angiotensin-converting enzyme (ACE) inhibitor

The optimal treatment for diabetic albuminuria is an ACE inhibitor (or an angiotensin II inhibitor), in combination with meticulous glycaemic and blood pressure control.

C Start an angiotensin II inhibitor

The optimal treatment for diabetic albuminuria is an ACE inhibitor (or an angiotensin II inhibitor), in combination with meticulous glycaemic and blood pressure control.

D Commence a low-protein diet

There is no evidence that a low-protein diet can cause long-term reduction in proteinuria. In fact, a low-protein

A 27-year-old, normotensive type 1 diabetic, who was diagnosed at age 18 years, is seen in the Diabetic Clinic. He has pre-proliferative retinopathy, but no other known diabetic complications.

He has good glycaemic control. A spot urine test in the clinic reveals microalbuminuria. This has not been noted before.

His blood results are below:

Haemoglobin (Hb)	15 g/dl
White cell count (WCC)	5.0×10^9/l
Platelets (PLT)	200×10^9/l
Creatinine (Cr)	90 μmol/l
Sodium (Na^+)	136 mmol/l
Potassium (K^+)	3.8 mmol/l
Urea	5.2 mmol/l

What is the most appropriate initial management strategy?

Your answer was incorrect

A Start an angiotensin-converting enzyme (ACE) inhibitor

B Confirm microalbuminuria by sending an early-morning urine sample for albumin-to-creatinine ratio (ACR)

C Start an angiotensin II inhibitor

A 65-year-old man, a retired factory worker, presents with some troublesome urinary symptoms over the last 2 months. He reports feeling the need to empty his bladder frequently and often feels he still needs to void immediately after having been to the toilet. He admits to some terminal dribbling. He denies any systemic symptoms.

He was seen by his general practitioner (GP) who advised that he stops drinking tea and coffee, although this has had little effect on his symptoms. His GP referred him because he found blood on urinalysis.

He has a history of hypertension and diabetes mellitus, for which he takes bendroflumethiazide and metformin. He is a smoker who has smoked around ten cigarettes per day since he was a teenager.

On examination, he appears well; his blood pressure is 160/95 mmHg, with a normal abdominal examination. Rectal examination reveals a smooth, moderately enlarged prostate, with preservation of the median sulcus. A urine sample appears normal on visual inspection.

Blood results are as follows:

Sodium (Na^+)	146 mmol/l
Potassium (K^+)	3.2 mmol/l
Urea	8.5 mmol/l
Creatinine (Cr)	129 µmol/l
Alanine aminotransferase (ALT)	33 iu/l
Alkaline phosphatase (ALP)	98 iu/l
Bilirubin	24 µmol/l
Prostate-specific antigen (PSA)	4 ng/l

Urinalysis reveals:

Blood	++

Potassium (K^+)	3.2 mmol/l
Urea	8.5 mmol/l
Creatinine (Cr)	129 µmol/l
Alanine aminotransferase (ALT)	33 iu/l
Alkaline phosphatase (ALP)	98 iu/l
Bilirubin	24 µmol/l
Prostate-specific antigen (PSA)	4 ng/l

Urinalysis reveals:

Blood	++
Leukocytes	+
Protein	+
Nitrites	Negative

Urine microscopy demonstrates erythrocytes at more than 5 per high power field (HPF) (microscopic haematuria defined as > 3 per HPF). No casts or crystals are seen. No microorganisms are found on Gram stain.

What is the most likely diagnosis?

A Benign

B Non-infectious haemorrhagic cystitis

C Prostatic carcinoma

D Squamous cell carcinoma of the bladder

E Transitional cell carcinoma of the bladder

E Transitional cell carcinoma of the bladder

The likely diagnosis is transitional cell carcinoma of the bladder. This man is a lifelong smoker, and his work in a factory may have exposed him to recognised carcinogens associated with urothelial malignancy.

The combination of symptoms suggesting bladder irritation and persistent, albeit microscopic, haematuria makes this a concern. Persistent microscopic haematuria needs to be taken seriously and investigated appropriately.

A Benign

His symptoms are not suggestive of prostatic hypertrophy, although mild prostatic enlargement is common and might be found coincidentally.

B Non-infectious haemorrhagic cystitis

Non-infectious haemorrhagic cystitis is commonly associated with a specific insult to the bladder (such as metabolites of cyclophosphamide or radiotherapy of the pelvis and lower abdomen), none of which are reported in this case.

C Prostatic carcinoma

The normal rectal examination and low prostate-specific antigen make a diagnosis of prostatic carcinoma less likely, although it would still be on the differential and would need to be excluded.

D Squamous cell carcinoma of the bladder

although mild prostatic enlargement is common and might be found coincidentally.

B Non-infectious haemorrhagic cystitis

Non-infectious haemorrhagic cystitis is commonly associated with a specific insult to the bladder (such as metabolites of cyclophosphamide or radiotherapy of the pelvis and lower abdomen), none of which are reported in this case.

C Prostatic carcinoma

The normal rectal examination and low prostate-specific antigen make a diagnosis of prostatic carcinoma less likely, although it would still be on the differential and would need to be excluded.

D Squamous cell carcinoma of the bladder

Transitional cell carcinoma is much more common than squamous cell carcinoma.

713

Rate this question:

Next Question

Previous Q... Tag Questi... Feedback End Session

Blog About Pastest Contact Us Help

© Pastest 2019

A 45-year-old man from Ghana underwent a live-related renal transplant three weeks ago for chronic kidney disease due to hypertensive nephropathy.

His current medications are ciclosporin, mycophenolate mofetil, prednisolone, cotrimoxazole, ranitidine, amlodipine and atenolol.

There were no complications after the procedure and his creatinine normalised a few days after surgery. He has no symptoms. Two days ago, his serum creatinine was 155 µmol/l.

Investigations:

Na^+	143 mmol/l
K^+	4.5 mmol/l
Cr	165 µmol/l
Urea	10.5 mmol/l

What definitive investigation will confirm that acute rejection is the problem?

A 24 h urine with creatinine estimation

B Ciclosporin level

C Renal biopsy

D Renal ultrasound scan

E Serum immunoglobulin

70772

Submit

Investigations:

Na^+	143 mmol/l
K^+	4.5 mmol/l
Cr	165 μmol/l
Urea	10.5 mmol/l

What definitive investigation will confirm that acute rejection is the problem?

Your answer was correct

A 24 h urine with creatinine estimation

B Ciclosporin level

C Renal biopsy

D Renal ultrasound scan

E Serum immunoglobulin

Explanation

C Renal biopsy

Acute rejection develops in 30–50% of renal transplant recipients. The risk is greater in the first three weeks after transplant. In patients on ciclosporin there are often no symptoms. Patients with deteriorating renal function with normal ciclosporin level should be investigated by percutaneous renal biopsy.

C Renal biopsy

Acute rejection develops in 30–50% of renal transplant recipients. The risk is greater in the first three weeks after transplant. In patients on ciclosporin there are often no symptoms. Patients with deteriorating renal function with normal ciclosporin level should be investigated by percutaneous renal biopsy.

A 24 h urine with creatinine estimation

Creatinine estimation would not help in this situation because a rise in serum creatinine is a good enough indication that there may be abnormality in renal function. Urinary creatinine would only be helpful in conditions such as alcoholism or extremes in weight.

B Ciclosporin level

A high ciclosporin level may affect creatinine levels by causing acute toxicity. However, this will not determine whether there is any acute rejection.

D Renal ultrasound scan

Renal ultrasound scan will identify any obstruction or possible urinary leak post-transplant. It cannot diagnose acute rejection.

E Serum immunoglobulin

There are no characteristic changes in serum immunoglobulins that are associated with rejection.

Rate this question:

A 68-year-old man comes to the renal clinic as a GP referral. He has a long history of hypertension which is managed with ramipril 10 mg daily and amlodipine 10 mg, but most recently he has complained of increasing tiredness.

On physical examination, his blood pressure was 140/80 mmHg, with chest and abdominal examination unremarkable. The GP ran some blood tests and was very concerned about the results.

Investigations:

Hb	9.9 g/dl
WCC	5.6×10^9/l
PLT	184×10^9/l
Na^+	139 mmol/l
K^+	5.7 mmol/l
Urea	12.2 mmol/l
Creatinine	305 µmol/l
Ferritin	90 µg/l (15–300 µg/l)

You plan to treat him with EPO once his ferritin is maintained above 100.

Which of the following is the most appropriate Hb target to get above?

A	9.0 g/dl
B	11.0 g/dl
C	13.0 g/dl
D	14.0 g/dl

D	14.0 g/dl
E	14.5 g/dl

Explanation

B	11.0 g/dl

Guidelines from the European Renal Association support a target for Hb of 10.0–12.0. Additionally, they recommend reaching this target within four months of commencing treatment. Renal patients are often additionally ferritin depleted, and assessment of ferritin level is crucial before starting EPO. Patients who are ferritin depleted should first be given an IV infusion. Some controversy exists as to whether a higher target would lead to lower CV events, but a study sponsored by Roche, which targeted EPO use to achieving an Hb in the normal range, showed no CV benefit.

A	9.0 g/dl

This target is too low and therefore, if patients were treated to this target, there may still be some who experience anaemia symptoms, such as shortness of breath and lethargy.

Guidelines from the European Renal Association support a target for Hb of 10.0–12.0 g/dl This also the midpoint of the NICE guidelines on Hb target.

C	13.0 g/dl

This level of haemoglobin is a little too high, with some concern for risk.

Rana Alnasser's screen

This level of haemoglobin is a little too high, with some concern for risk.

D	14.0 g/dl

The Correction of Haemoglobin and Outcomes in Renal Insufficiency (CHOIR) investigators concluded that a haemoglobin target of 13.5 g/dl was associated with significantly greater risk for the primary composite outcome (death, MI, hospitalization for congestive heart failure without renal replacement therapy, or stroke) compared with a lower target of 11.3 g/dl. Therefore there should be a caution in haemoglobins >13.5g/dl.

E	14.5 g/dl

As above, the CHOIR investigators concluded that a haemoglobin target of 13.5 g/dl was associated with significantly greater risk for the primary composite outcome (death, MI, hospitalization for congestive heart failure without renal replacement therapy, or stroke) compared with a lower target of 11.3 g/dl. Therefore there should be a caution in haemoglobins greater than 13.5 g/dl.

© Pastest 2019

A 65-year-old woman presents for review. She is using acetazolamide and timolol for chronic glaucoma. She has a past medical history of asthma.

On physical examination, her blood pressure is 130/80 mmHg and chest and abdominal examination is unremarkable.

Investigations:

Sodium	145 mmol/l
Potassium	2.6 mmol/l
Urea	4.6 mmol/l
Creatinine	128 μmol/l
Corrected calcium	2.1 mmol/l
Chloride	118 mmol/l (95–110 mmol/l)
Bicarbonate	18 mmol/l (22–28 mmol/l)
Phosphate	0.65 mmol/l (0.8–1.5 mmol/l)

What is the cause of the metabolic abnormality?

A Bartter's syndrome

B Lactic acidosis

C Nephrogenic diabetes insipidus

D Renal tubular acidosis type 1 (distal)

E Renal tubular acidosis type 2 (proximal)

Sodium	145 mmol/l
Potassium	2.6 mmol/l
Urea	4.6 mmol/l
Creatinine	128 µmol/l
Corrected calcium	2.1 mmol/l
Chloride	118 mmol/l (95–110 mmol/l)
Bicarbonate	18 mmol/l (22–28 mmol/l)
Phosphate	0.65 mmol/l (0.8–1.5 mmol/l)

D
E
O

Resp
Resp
Resp
Resp

What is the cause of the metabolic abnormality?

Your answer was correct

A Bartter's syndrome

B Lactic acidosis

C Nephrogenic diabetes insipidus

D Renal tubular acidosis type 1 (distal)

E Renal tubular acidosis type 2 (proximal)

Explanation

E Renal tubular acidosis type 2 (proximal)

Renal tubular acidosis is a disorder of the renal tubules' ability to maintain acid-base balance, leading to chronic hyperchloraemic metabolic acidosis.

Renal tubular acidosis is a disorder of the renal tubules' ability to maintain acid-base balance, leading to chronic hyperchloraemic metabolic acidosis.

The proximal tubule is the major site for reabsorption of filtered bicarbonate. In proximal RTA (type 2 RTA, pRTA), bicarbonate reabsorption is defective. pRTA rarely occurs as an isolated defect of bicarbonate transport and is usually associated with multiple proximal tubule transport defects; therefore, urinary loss of glucose, amino acids, phosphate, uric acid and other organic anions such as citrate can also occur (Fanconi syndrome).
Plasma bicarbonate is <21 mmol/l, and urine pH may fall below 5.5 with acidification.

Features of RTA 2 are:

- acidosis
- hypokalaemia: due to inability of renal tubules to secrete hydrogen ions, potassium is preferentially excreted
- glycosuria
- aminoaciduria
- hyperchloraemia: chloride ions are mobilised to replace lost bicarbonate ions
- osteomalacia: excess hydrogen ions are buffered by calcuim, resulting in depletion of calcium from bone.

Causes and associations of RTA 2 are:

Fanconi syndrome, Wilson's disease, cystinosis and hereditary fructose intolerance and acetazolamide, which leads to increased proximal tubule bicarbonate loss.

A	Bartter's syndrome

Bartter syndrome is an autosomal recessive inheritan
is usually diagnosed in children or adolescents with f
and cramps. There is

Rana Alnasser's screen

B Lactic acidosis

There would be a high anion gap with a raised lactate level in lactic acidosis. Lactic acidosis would occur in sepsis or shock. It may also occur as a complication of metformin use in kidney disease.

C Nephrogenic diabetes insipidus

Nephrogenic diabetes insipidus would not cause a metabolic acidosis. This condition may be caused by drugs, and symptoms include excessive thirst and polyuria.

D Renal tubular acidosis type 1 (distal)

Renal tubular acidosis type 1 will include a normal anion gap acidosis. There is failure to reabsorb bicarbonate ions or insufficient excretion of hydrogen ions. There is hypokalaemia, and other associated features such as urinary stone formation from the alkaline urine, hypercalciuria and low urinary citrate, nephrocalcinosis and bone demineralisation.

Rate this question:

Next Question

Previous Q... Tag Questi... Feedback End Session

© Pastest 2019

Rana Alnasser's screen

1:46

A 35-year-old otherwise healthy man comes to the office one day after running the marathon, complaining of diffuse muscle aches and weakness. He also reports progressive darkening of his urine since the previous night. He denies associated fevers, chills or abdominal pain. He appears to be in no acute distress.

Vital signs are temperature 36.8 °C, blood pressure 100/72 mmHg, pulse 110/min and respiration 18/min. His pupils are equal round and reactive to light and accommodation. His heart is tachycardic with normal sounds. His lungs are clear and his abdomen is soft and non-tender without hepatosplenomegaly.

Examination of extremities shows mild tenderness to palpation over the quadriceps.

Investigations:

Na^+	140 mmol/l
K^+	5.5 mmol/l
Urea	15 mmol/l
Creatinine	230 µmol/l
Hb	12.0 g/dl
WCC	5.1×10^9/l
Urine dipstick	Red blood cells (RBCs) +++ White blood cells (WBCs) +

What is the most likely diagnosis?

A Multiple myeloma

B Nephrolithiasis with haematuria

C Profound dehydration

Rana Alnasser's screen

Vital signs are temperature 38.8 °C, blood pressure 100/72 mmHg, pulse 110/min and respiration 18/min. His pupils are equal round and reactive to light and accommodation. His heart is tachycardic with normal sounds. His lungs are clear and his abdomen is soft and non-tender without hepatosplenomegaly.

Examination of extremities shows mild tenderness to palpation over the quadriceps.

Investigations:

Na^+	140 mmol/l
K^+	5.5 mmol/l
Urea	15 mmol/l
Creatinine	230 µmol/l
Hb	12.0 g/dl
WCC	5.1×10^9/l
Urine dipstick	Red blood cells (RBCs) +++ White blood cells (WBCs) +

What is the most likely diagnosis?

A	Multiple myeloma
B	Nephrolithiasis with haematuria
C	Profound dehydration
D	Rhabdomyolysis
E	Viral syndrome

1:49
594-042-7551
Leave

palpation over the quadriceps.

Investigations:

Na^+	140 mmol/l
K^+	5.5 mmol/l
Urea	15 mmol/l
Creatinine	230 µmol/l
Hb	12.0 g/dl
WCC	5.1×10^9/l
Urine dipstick	Red blood cells (RBCs) +++ White blood cells (WBCs) +

What is the most likely diagnosis?

Your answer was correct

A Multiple myeloma

B Nephrolithiasis with haematuria

C Profound dehydration

D Rhabdomyolysis

E Viral syndrome

Explanation

D Rhabdomyolysis

Rhabdomyolysis is a syndrome that occurs in the setting of

Audio Video Share Participants More

1:49
594-042-7551
Leave

Explanation

D Rhabdomyolysis

Rhabdomyolysis is a syndrome that occurs in the setting of muscle injury, where the intracellular contents of myocytes are released into the plasma. Any vigorous muscular activity can lead to rhabdomyolysis. Complications may be life threatening and include severe electrolyte imbalances (hyperkalaemia, hyperuricaemia, hyperphosphataemia, hypocalcaemia, hypercalacemia), myoglobinuric kidney disease, metabolic acidosis and disseminated intravascular coagulation, although thankfully post-exercise complications are actually rare. Urine stick testing confuses myoglobin with haemoglobin from red blood cells, hence the reason for the results seen here.

A Multiple myeloma

Myeloma does not present with blood and protein in the urine - it would present with proteinuria. There would be plasma immunophoresis.

B Nephrolithiasis with haematuria

You would expect renal colic pain with nephrolithiasis.

C Profound dehydration

Dehydration causes a pre-kidney disease with no blood in the urine. The urinalysis shows no protein or blood.

E Viral syndrome

Although a viral syndrome will present with generalised

Audio Video Share Participants More

A 19-year-old man comes to your office, referred by his rugby coach. He is usually in robust, excellent health and is in the middle of 3 weeks of intensive training before a university tour to Australia and New Zealand. He has been passing dark urine for the past few days, and he is worried that he might have a serious illness. He describes the urine as cola-coloured. He denies fever and has no complaint or discomfort other than the dark urine.

He is a large muscular young man who is in no obvious distress. His temperature is 37.4 °C, his blood pressure 120/70 mmHg and pulse 65 bpm. His extremities are non-oedematous and non-tender. The remainder of the physical examination is unremarkable.

Investigations show:

Creatinine (Cr)	220 μmol/l
Urea	15.0 mmol/l
Haemoglobin (Hb)	12.0 g/dl
Potassium (K^+)	4.0 mmol/l
White cell count (WCC)	10×10^9/l

Which test would be the most appropriate for initial work-up?

A Computed tomography (CT) of the abdomen

B Erythrocyte sedimentation rate (ESR)

C Kidney, ureter and bladder (KUB) X-ray

D Renal ultrasound

E Urinalysis

Rana Alnasser's screen

C Kidney, ureter and bladder (KUB) X-ray

D Renal ultrasound

E Urinalysis

Explanation

E Urinalysis

Urinalysis is the most appropriate test for initial workup because it is simple to carry out in the outpatients and will confirm that haematuria is causing the cola-coloured urine. The differential diagnosis of haematuria includes stones, haematological disorders such as thrombocytopenia, infection, tumours, trauma and treatment like cyclophosphamide.

In this case, the patient is at risk of rhabdomyolysis from the vigorous exercise he has been undergoing. Rhabdomyolysis would give haemoglobin on stick urinalysis, but no red blood cells would be seen on microscopy.

Other causes of haematuria in a young man without pain, who is fit and healthy, such as renal stones or urological malignancy, are highly unlikely. Creatinine kinase may be raised. No specific treatment is required, apart from maintaining adequate hydration.

A Computed tomography (CT) of the abdomen

A CT scan of the abdomen would be normal in rhabdomyolysis. In addition, this would expose the patient to unnecessary radiation exposure.

B Erythrocyte sedimentation rate (ESR)

B Erythrocyte sedimentation rate (ESR)

The ESR may be elevated in infectious or inflammatory causes of rhabdomyolysis. Therefore, ESR may be raised in this situation; however, it would not discern the cause of the haematuria and is not specific for rhabdomyolysis.

C Kidney, ureter and bladder (KUB) X-ray

A KUB is useful for identifying any calcium-containing radio-opaque renal stones. This patient does not present with any symptoms of renal colic or abdominal pain; therefore, a renal stone is unlikely.

D Renal ultrasound

In rhabdomyolysis, the renal ultrasound is normal, so it would not be helpful. Renal ultrasounds are useful to identify kidney sizes, which may be enlarged in certain conditions such as polycystic kidney disease or small in chronic kidney disease. It is useful to exclude hydronephrosis as a cause of acute kidney impairment.

Rate this question:

Next Question

Previous Q... Tag Questi... Feedback End Session

Blog About Pastest Contact Us Help

© Pastest 2019

A 35-year-old woman presents to the Renal Clinic for review. She has difficult-to-manage hypertension – her BP is still elevated despite therapy with ramipril 5 mg, amlodipine 5 mg and indapamide 2.5 mg.

On examination in the clinic, her BP is 160/94 mmHg, with pulse 80 bpm and regular. Her BMI is 23.

Investigations:

Hb	13.2 g/dl
WCC	7.2×10^9/l
PLT	198×10^9/l
Na^+	137 mmol/l
K^+	3.6 mmol/l
Creatinine	135 µmol/l
Renal angiogram	'string of beads' appearance of left renal artery

Which of the following is the most appropriate next intervention?

A Angioplasty

B Add atenolol 50 mg

C Add doxazosin 4 mg

D Increase ramipril to 10 mg

E Surgical renal artery reimplantation

amlodipine 5 mg and indapamide 2.5 mg.

On examination in the clinic, her BP is 160/94 mmHg, with pulse 80 bpm and regular. Her BMI is 23.

Investigations:

Hb	13.2 g/dl
WCC	7.2×10^9/l
PLT	198×10^9/l
Na^+	137 mmol/l
K^+	3.6 mmol/l
Creatinine	135 µmol/l
Renal angiogram	'string of beads' appearance of left renal artery

Which of the following is the most appropriate next intervention?

Your answer was correct

A Angioplasty

B Add atenolol 50 mg

C Add doxazosin 4 mg

D Increase ramipril to 10 mg

E Surgical renal artery reimplantation

Explanation

Explanation

A	Angioplasty

Recent meta-analyses have suggested that atherosclerotic renal artery stenosis medical management is as effective as angioplasty. This is in contrast to fibromuscular hyperplasia, which has the characteristic angiography appearance seen here. In this case angioplasty has superior outcomes with respect to control of blood pressure and long-term sequelae. As such, angioplasty is recommended as the most appropriate intervention. Surgical arterial reimplantation is not recommended, particularly in the light of modern angioplasty and stenting techniques.

B	Add atenolol 50 mg

Angioplasty has superior outcomes for blood pressure control compared to anti-hypertensives. Atenolol is a non-cardioselective beta-blocker. It may have side effects of tiredness and impotence.

C	Add doxazosin 4 mg

Angioplasty has superior outcomes for blood pressure control compared to anti-hypertensives. Doxazocin is an alpha-blocker that may be used as a treatment for hypertension, and also for symptomatic relief for benign prostatic hyperplasia. For the latter condition it promotes smooth muscle relaxation, improving urinary flow and reducing the problem of residual urine in the bladder post-voiding.

D	Increase ramipril to 10 mg

Angioplasty has superior outcomes for blood pressu control compared to anti-hypertensives. Ramipril is a angiotensin-converting enzyme inhibitor.

of modern angioplasty and stenting techniques.

B Add atenolol 50 mg

Angioplasty has superior outcomes for blood pressure control compared to anti-hypertensives. Atenolol is a non-cardioselective beta-blocker. It may have side effects of tiredness and impotence.

C Add doxazosin 4 mg

Angioplasty has superior outcomes for blood pressure control compared to anti-hypertensives. Doxazocin is an alpha-blocker that may be used as a treatment for hypertension, and also for symptomatic relief for benign prostatic hyperplasia. For the latter condition it promotes smooth muscle relaxation, improving urinary flow and reducing the problem of residual urine in the bladder post-voiding.

D Increase ramipril to 10 mg

Angioplasty has superior outcomes for blood pressure control compared to anti-hypertensives. Ramipril is an angiotensin-converting enzyme inhibitor.

E Surgical renal artery reimplantation

Surgical renal artery reimplantation, although a possible intervention for renal artery stenosis, has inherent risks as with all surgical procedures and therefore would be an inferior option compared to renal angioplasty.

Rate this question:

A 70-year-old man is admitted with shortness of breath and peripheral oedema. He is oliguric. He has a history of diabetes associated with renal impairment and has been followed up in the Renal Clinic where he has been relatively stable until now.

His pulse is regular, at a rate of 96 bpm, and his blood pressure is 190/100 mmHg. His respiratory rate is 30 breaths per min and oxygen saturation 92% on high-flow oxygen. He has a raised jugular venous pulse and gross pitting oedema of both his ankles.

Respiratory examination reveals coarse crackles to the mid zones of both lungs. He has a third heart sound on auscultation. His electrocardiogram (ECG) shows prolongation of the PR interval and widening of the QRS complex.

Urgent blood results are as follows:

Sodium (Na^+)	136 mmol/l
Potassium (K^+)	6.7 mmol/l
Urea	36 mmol/l
Creatinine (Cr)	780 µmol/l
Bicarbonate	11 mmol/l

What are the most important interventions while awaiting transfer to the Renal Unit for dialysis?

A 15 units of Actrapid® insulin in 50 ml of 50% dextrose intravenous (iv) plus calcium gluconate

B 15 units of Actrapid® insulin in 50 ml of 50% dextrose iv plus calcium gluconate, with 500 ml of 1.26% sodium bicarbonate

C Salbutamol 5 mg nebulised, 15 units of Actrapid

Urgent blood results are as follows:

Sodium (Na^+)	136 mmol/l
Potassium (K^+)	6.7 mmol/l
Urea	36 mmol/l
Creatinine (Cr)	780 µmol/l
Bicarbonate	11 mmol/l

What are the most important interventions while awaiting transfer to the Renal Unit for dialysis?

A 15 units of Actrapid® insulin in 50 ml of 50% dextrose intravenous (iv) plus calcium gluconate

B 15 units of Actrapid® insulin in 50 ml of 50% dextrose iv plus calcium gluconate, with 500 ml of 1.26% sodium bicarbonate

C Salbutamol 5 mg nebulised, 15 units of Actrapid® insulin in 50 ml of 50% dextrose iv plus calcium gluconate

D Salbutamol 5 mg nebulised, 15 units of Actrapid® insulin in 50 ml of 50% dextrose iv plus calcium gluconate, furosemide bolus iv with glyceryl trinitrate infusion

E Salbutamol 5 mg nebulised, calcium resonium 15 g orally, 15 units of Actrapid® insulin in 50 ml of 50% dextrose iv plus calcium gluconate

Submit

Explanation

C	Salbutamol 5 mg nebulised, 15 units of Actrapid® insulin in 50 ml of 50% dextrose iv plus calcium gluconate

This man has acute kidney disease, with evidence of fluid overload and pulmonary oedema. He also has life-threatening hyperkalaemia with electrocardiogram (ECG) changes. These two features constitute medical emergencies and need to be treated accordingly.

Calcium gluconate needs to be given, in view of its cardioprotective and stabilising effect, followed by attempts to lower the potassium with salbutamol and a carefully monitored dextrose/insulin infusion.

Actrapid® insulin will help push potassium into the cells. Similarly, salbutamol nebuliser will help acutely to move potassium intracellularly and works within minutes. Therefore, this will help lower the potassium, while waiting for dialysis treatment.

D	Salbutamol 5 mg nebulised, 15 units of Actrapid® insulin in 50 ml of 50% dextrose iv plus calcium gluconate, furosemide bolus iv with glyceryl trinitrate infusion

The agent here which is not appropriate is furosemide, which in the context of acute kidney disease is unlikely to be effective and is associated with increased hearing loss when given as an IV therapy.

A	15 units of Actrapid® insulin in 50 ml of 50% dextrose intravenous (iv) plus calcium gluconate

This solution is incomplete. Further measures may he lower the potassium acutely, which includes salbutan nebuliser

A 60-year-old woman presents with a short history of sinus congestion, epistaxis and joint pains in her hands. She becomes increasingly short of breath and develops haemoptysis precipitating admission to hospital. On direct questioning, she admits to passing less urine in the preceding few days.

On examination, she has splinter haemorrhages in both hands and feet. Her blood pressure is 160/80 mmHg. Heart sounds are normal with no murmurs. She has bibasilar fine crackles on auscultation of the lungs but her jugular venous pressure is not elevated and she has no pedal oedema.

Investigations show:

Na^+	140 mmol/l
K^+	4.2 mmol/l
Urea	45 mmol/l
Creatinine	800 µmol/l
Hb	6 g/dl
WCC	5.1×10^9/l
PLT	243×10^9/l
Chest X-ray	Bilateral air space shadowing throughout both lung fields
Urine microscopy	Red blood cells and red blood cell casts

What is the most likely diagnosis?

A Goodpasture's syndrome

B Cryoglobulinaemia

C Antineutrophil cytoplasmic antibody (ANCA)

10:28

MyPastest
https://mypastest.pastest.com

Pastest+

pressure is not elevated and she has no pedal oedema.

Investigations show:

Na^+	140 mmol/l
K^+	4.2 mmol/l
Urea	45 mmol/l
Creatinine	800 μmol/l
Hb	6 g/dl
WCC	5.1×10^9/l
PLT	243×10^9/l
Chest X-ray	Bilateral air space shadowing throughout both lung fields
Urine microscopy	Red blood cells and red blood cell casts

What is the most likely diagnosis?

A	Goodpasture's syndrome
B	Cryoglobulinaemia
C	Antineutrophil cytoplasmic antibody (ANCA)-positive vasculitis
D	IgA nephropathy
E	Uric acid nephropathy

6359

Rana Alnasser's screen

Explanation

C	Antineutrophil cytoplasmic antibody (ANCA)-positive vasculitis

This is a classic history for Wegener's granulomatosis. She would need treatment with dialysis and immunosuppression and most centres would advocate plasma exchange with a creatinine above 400 µmol/l. None of the other diagnoses would classically cause sinus or joint involvement, and pulmonary haemorrhage is typically seen only in Goodpasture's syndrome and ANCA-positive vasculitis. Note left ventricular failure can lead to pink sputum and may be confused with pulmonary haemorrhage. To confirm the diagnosis of pulmonary haemorrhage, a raised KCO would be seen on lung function tests. The low haemoglobin in the setting of acute kidney disease and the disproportionate degree of abnormality seen on chest X-ray compared with clinical findings suggest pulmonary haemorrhage rather than infection or fluid to explain the chest X-ray findings.

A	Goodpasture's syndrome

Goodpasture's syndrome would present with rapidly progressive glomerulonephritis and pulmonary haemorrhage. Severe pulmonary haemorrhage may require intubation. Sinus congestion and upper ear, nose and throat symptoms suggest Wegener's granulomatosis rather than Goodpasture's syndrome.

B	Cryoglobulinaemia

Cryoglobulins deposited in medium and small vessels in the glomeruli lead to complement fixation and inflammation injury which leads to glomerulonephritis. This may be related to lymphoproliferative diseases such as myeloma and Wasldenstom's macroglobulinaemia or infection such

A Goodpasture's syndrome

Goodpasture's syndrome would present with rapidly progressive glomerulonephritis and pulmonary haemorrhage. Severe pulmonary haemorrhage may require intubation. Sinus congestion and upper ear, nose and throat symptoms suggest Wegener's granulomatosis rather than Goodpasture's syndrome.

B Cryoglobulinaemia

Cryoglobulins deposited in medium and small vessels in the glomeruli lead to complement fixation and inflammation injury which leads to glomerulonephritis. This may be related to lymphoproliferative diseases such as myeloma and Wasldenstom's macroglobulinaemia or infection such as hepatitis C.

D IgA nephropathy

There are no ear, nose and throat symptoms nor pulmonary haemorrhage with IgA nephropathy. Furthermore ANCA would be negative.

E Uric acid nephropathy

Uric acid nephropathy may present with renal colic due to uric acid stones. There are no ear, nose and throat symptoms as in this case.

Rate this question:

Next Question

A 58-year-old man presents with haematuria and weight loss. He has a past medical history of hypertension.

On physical examination, his blood pressure is 160/70 mmHg, chest and abdominal examination was unremarkable. His renal function is normal.

His computed tomography (CT) scan is below:

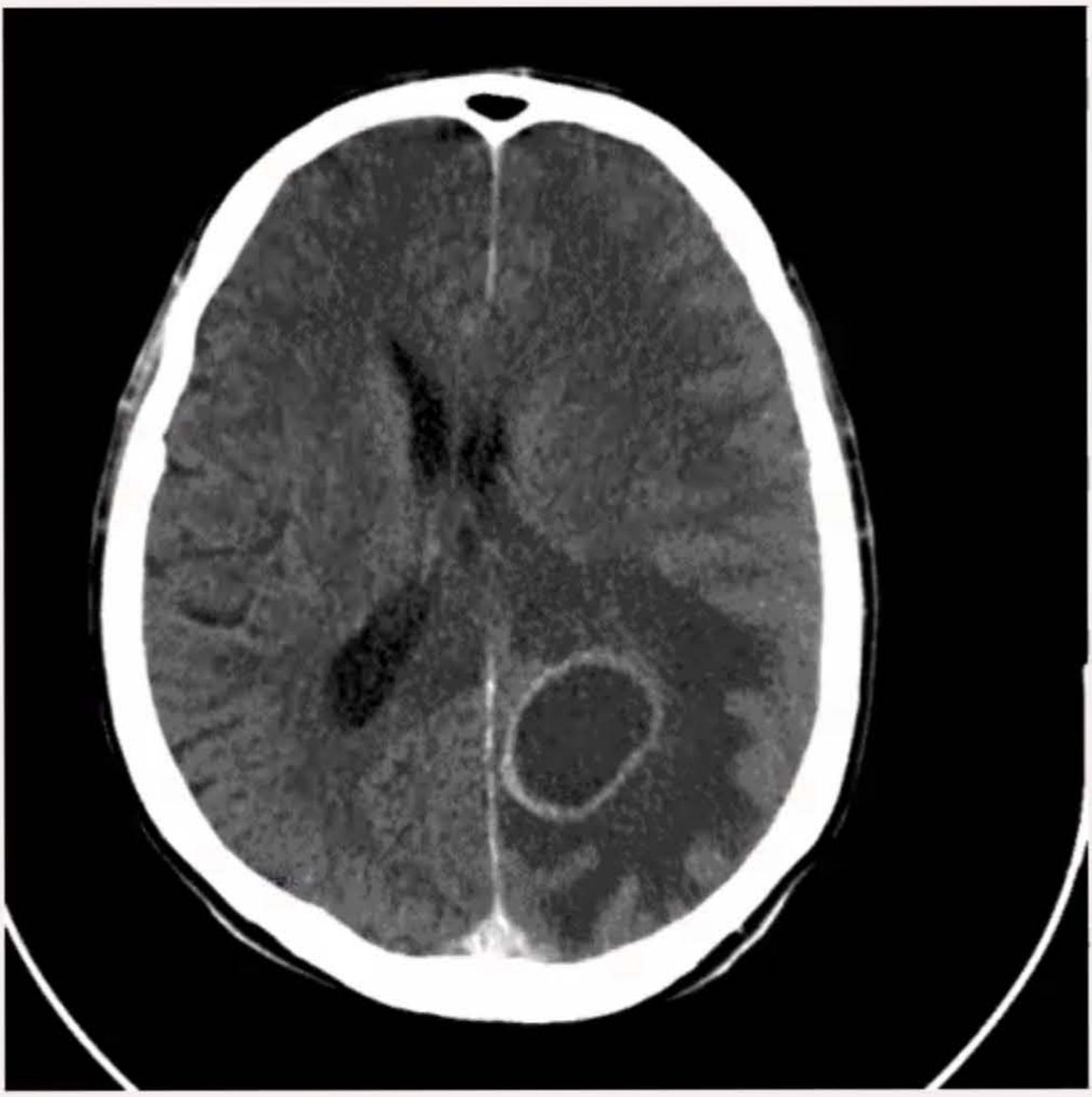

CT abdomen confirms the presence of a renal carcinoma. CT thorax and additional PET scanning does not suggest other metastases apart from the one shown.

What is the most appropriate management strategy?

A Combined nephrectomy and resection of brain lesion

10:32

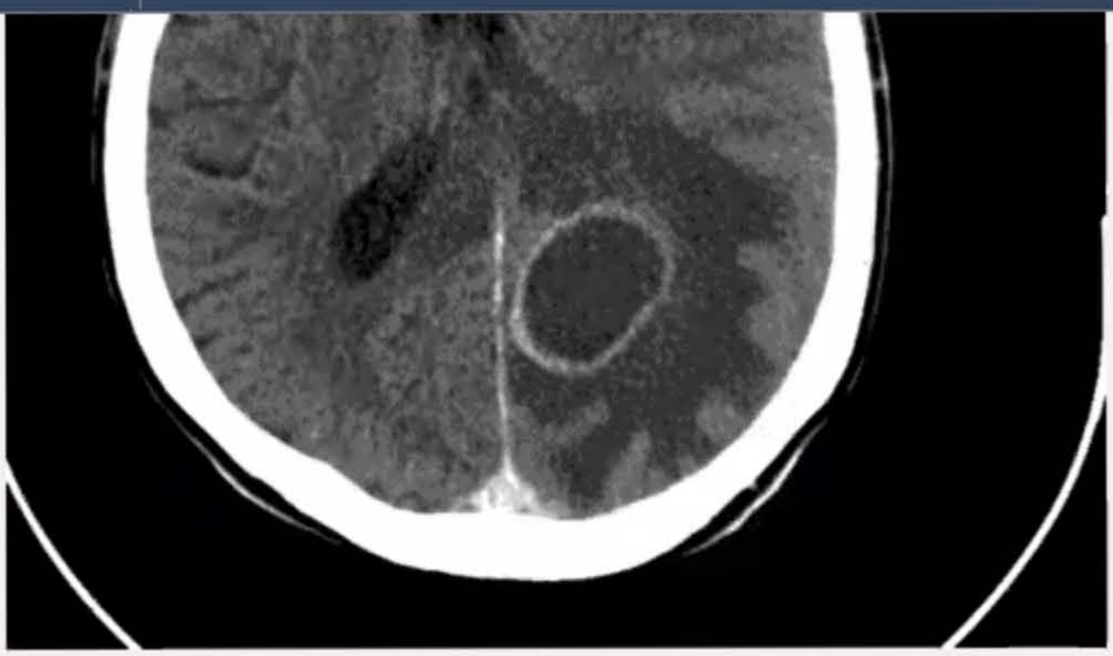

CT abdomen confirms the presence of a renal carcinoma. CT thorax and additional PET scanning does not suggest other metastases apart from the one shown.

What is the most appropriate management strategy?

A	Combined nephrectomy and resection of brain lesion
B	Immunotherapy only
C	Nephrectomy and cranial irradiation
D	Nephrectomy and small molecule kinase inhibitor
E	Palliative chemotherapy only

Submit

Rana Alnasser's screen

CT abdomen confirms the presence of a renal carcinoma. CT thorax and additional PET scanning does not suggest other metastases apart from the one shown.

What is the most appropriate management strategy?

Your answer was correct

A	Combined nephrectomy and resection of brain lesion
B	Immunotherapy only
C	Nephrectomy and cranial irradiation
D	Nephrectomy and small molecule kinase inhibitor
E	Palliative chemotherapy only

Explanation

D	Nephrectomy and small molecule kinase inhibitor

This gentleman has a large renal cell carcinoma with a solitary brain metastasis. Renal cell carcinomas account for 1–2% of malignant tumours, are more common in men and rarely present below the age of 40 years. They are sometimes bilateral. They can present with the 'classic' triad of haematuria, loin pain and a mass in the flank. Other

D Nephrectomy and small molecule kinase inhibitor

This gentleman has a large renal cell carcinoma with a solitary brain metastasis. Renal cell carcinomas account for 1–2% of malignant tumours, are more common in men and rarely present below the age of 40 years. They are sometimes bilateral. They can present with the 'classic' triad of haematuria, loin pan and a mass in the flank. Other clinical features include polycythaemia due to excessive erythropoietin production (5%), hypertension (30%) and a left-sided varicocele due to obstruction of the left testicular vein secondary to tumour involvement of the renal vein. They can also sometimes present as pyrexia of unknown origin. Treatment is usually by nephrectomy (unless bilateral tumours or poor renal function). This is often undertaken in the presence of metastases as these may regress following removal of the primary tumour. For decades, the treatment of renal cell carcinoma has been based on nephrectomy and the limited use of toxic and often inefficient immunotherapy with interleukin-2 or interferon-α. However, new biological agents are now becoming available. Small-molecule multikinase inhibitors that target VEGF receptors (pazopanib, sunitinib and sorafenib) have a favourable toxicity profile and can prolong time to progression and preserve quality of life in patients with renal cell carcinoma. These small molecule kinase inhibitors are enzyme inhibitors that block the action of one or more of the protein kinases. Hyperactive protein kinases play a part in renal cell carcinoma.

A Combined nephrectomy and resection of brain lesion

The prognosis of metastatic renal cell carcinoma is poor. The 5-year survival rate is 60–70% in tumours confined to the kidney, dropping to 5% in those with metastases. Therefore, it would not be appropriate to undergo resection of brain lesion as this would impart further risk. Nephrectomy would be necessary as the metastases may

Radiotherapy and chemotherapy have no proven benefit in renal cell carcinoma. Renal cell carcinoma is resistant in most cases with radiotherapy; there is about a 4–5% success rate, but this is often short lived with more tumours and growths developing later.

E	Palliative chemotherapy only

Radiotherapy and chemotherapy have no proven benefit in renal cell carcinoma. There have been a few case studies that have shown a decrease in the stage and size of the renal cell carcinoma if chemotherapy has been given before surgical removal; therefore this approach is being investigated in clinical trials. In this case palliative chemotherapy is not the answer because there would be some benefit of nephrectomy and small molecule kinase inhibitors.

Reference

(1) Costa LJ, Drabkin HA 2007. Renal cell carcinoma: new developments in molecular biology and potential for targeted therapies. The Oncologist, 2007; 12, (12): 1404--1415.

Rate this question:

© Pastest 2019

A 20-year-old man of Japanese descent who is studying in the UK attends the clinic for advice. He attended the optician for an eye test and was noted to have greenish-gold discoloration within the limbus of both corneas.

Other past medical history of note includes polyarthritis, for which he takes regular analgesia.

On physical examination, his blood pressure is 130/80 mmHg; chest and abdominal examination is unremarkable.

Investigations:

Hb	11.1 g/dl
K^+	3.4 mmol/l
Na^+	138 mmol/l
Creatinine	130 µmol/l
Urea	4.2 mmol/l
Bicarbonate	16 mmol/l
ALT	75 IU/l
Urinary bicarbonate excretion	Increased

Which of the following diagnoses fits best with the renal dysfunction seen here?

A Renal tubular acidosis type IV

B Renal tubular acidosis type II

C Renal tubular acidosis type I

D Acute tubular necrosis

E Papillary necrosis

Radiotherapy and chemotherapy have no proven benefit in renal cell carcinoma. Renal cell carcinoma is resistant in most cases with radiotherapy; there is about a 4–5% success rate, but this is often short lived with more tumours and growths developing later.

E	Palliative chemotherapy only

Radiotherapy and chemotherapy have no proven benefit in renal cell carcinoma. There have been a few case studies that have shown a decrease in the stage and size of the renal cell carcinoma if chemotherapy has been given before surgical removal; therefore this approach is being investigated in clinical trials. In this case palliative chemotherapy is not the answer because there would be some benefit of nephrectomy and small molecule kinase inhibitors.

Reference

(1) Costa LJ, Drabkin HA 2007. Renal cell carcinoma: new developments in molecular biology and potential for targeted therapies. The Oncologist, 2007; 12, (12): 1404--1415.

Rate this question:

© Pastest 2019

A 20-year-old man of Japanese descent who is studying in the UK attends the clinic for advice. He attended the optician for an eye test and was noted to have greenish-gold discoloration within the limbus of both corneas.

Other past medical history of note includes polyarthritis, for which he takes regular analgesia.

On physical examination, his blood pressure is 130/80 mmHg; chest and abdominal examination is unremarkable.

Investigations:

Hb	11.1 g/dl
K^+	3.4 mmol/l
Na^+	138 mmol/l
Creatinine	130 µmol/l
Urea	4.2 mmol/l
Bicarbonate	16 mmol/l
ALT	75 IU/l
Urinary bicarbonate excretion	Increased

Which of the following diagnoses fits best with the renal dysfunction seen here?

A Renal tubular acidosis type IV

B Renal tubular acidosis type II

C Renal tubular acidosis type I

D Acute tubular necrosis

E Papillary necrosis

Hb	11.1 g/dl
K^+	3.4 mmol/l
Na^+	138 mmol/l
Creatinine	130 µmol/l
Urea	4.2 mmol/l
Bicarbonate	16 mmol/l
ALT	75 IU/l
Urinary bicarbonate excretion	Increased

Which of the following diagnoses fits best with the renal dysfunction seen here?

Your answer was correct

A Renal tubular acidosis type IV

B Renal tubular acidosis type II

C Renal tubular acidosis type I

D Acute tubular necrosis

E Papillary necrosis

Explanation

B Renal tubular acidosis type II

The findings from the optician are suggestive of Kayser-Fleischer rings, and Wilson's disease. The raised ALT and polyarthritic picture are suppo. tive of this. Wilson's is

10:37

MyPastest
https://mypastest.pastest.com

Pastest+

E Papillary necrosis

Explanation

B Renal tubular acidosis type II

The findings from the optician are suggestive of Kayser-Fleischer rings, and Wilson's disease. The raised ALT and polyarthritic picture are supportive of this. Wilson's is associated with renal tubular acidosis Type 2. Other causes include Fanconi syndrome, hereditary fructose intolerance, Lowe syndrome, heavy metal poisoning and certain chemotherapeutic agents. It is associated with an inability to reabsorb sodium bicarbonate from urine, leading to increased urinary losses. Treatments for RTA type 2 include bicarbonate replacement and the use of thiazide diuretics.

A Renal tubular acidosis type IV

Type 4 is associated with a decreased response to aldosterone. This presents with hyperkalaemia, reduced serum bicarbonate, normal anion gap with raised chloride, negative urinary anion gap and reduced urinary citrate. It is caused by conditions such as diabetes mellitus, drugs such as NSAIDS and ciclosporin and obstructive uropathy.

C Renal tubular acidosis type I

In contrast to Type II renal tubular acidosis, type 1 RTA is associated with an inability to acidify urine. Type 1 RTA presents as a hyperchloraemic, hypokalaemic metabolic acidosis with hypophosphataemic metabolic bone disease, renal stones or diffuse nephrocalcinosis. It is inherited or due to secondary conditions such as Sjogren syndrome,

associated with an inability to acidify urine. Type I RTA presents as a hyperchloraemic, hypokalaemic metabolic acidosis with hypophosphataemic metabolic bone disease, renal stones or diffuse nephrocalcinosis. It is inherited or due to secondary conditions such as Sjogren syndrome, rheumatoid arthritis or other auto-immune diseases.

D Acute tubular necrosis

Acute tubular necrosis may cause renal impairment. It may result from pre-renal injury such as hypoperfusion from hypovolaemia, reduction in blood flow and sepsis, for example. There is no history in this case to suggest injury that has resulted in acute tubular necrosis such as drop in blood pressure.

E Papillary necrosis

Papillary necrosis is a disorder where there is death of part or some of the renal papillae. This would present with haematuria and abdominal pain. It is a complication of analgesic nephropathy. In this scenario, there is no mention of any abdominal pain. Furthermore, analgesic nephropathy is a result of long-term analgesic abuse; in view of the fact he is only 20 years old, this makes the diagnosis unlikely.

Rate this question:

Next Question

A 35-year-old man with a history of mild asthma comes to your clinic with 10 days' history of malaise, fever and tightness in the chest. On further inquiry, he also mentions shortness of breath, weight loss and swelling in the legs and scrotum. There is no significant past medical history.

On examination, his temperature is 38 °C, blood pressure is 175/90 mmHg, pulse is 77 beats/min and respiratory rate 14 breaths/min. Physical examination confirms bilateral pedal and scrotal oedema. There are also scattered bilateral wheezes. Chest X-ray is unremarkable.

Haematology investigations:

Sodium	140 mmol/l
Potassium	5.1 mmol/l
Chloride	99 mmol/l
Bicarbonate	21 mmol/l
Urea	19 mmol/l
Creatinine	221 mmol/l
Eosinophils	Mildly elevated

Urinalysis:

Specific gravity	1.020
Protein	2+
Blood	4+
Red cell casts	Many
24 h protein	1.9 g

Which laboratory finding would support the most likely diagnosis?

A Anti-glomerular basement membrane antibody

Creatinine	221 mmol/l
Eosinophils	Mildly elevated

Urinalysis:

Specific gravity	1.020
Protein	2+
Blood	4+
Red cell casts	Many
24 h protein	1.9 g

Which laboratory finding would support the most likely diagnosis?

A Anti-glomerular basement membrane antibody

B Anti-streptolysin titre

C c-ANCA (anti-neutrophil cytoplasmic antibodies)

D p-ANCA

E Serum immunoglobulin A (IgA) levels

Submit

E Serum immunoglobulin A (IgA) levels

Explanation

D p-ANCA

This patient has eosinophilic granulomatosis with polyangiitis - a nephritic syndrome associated with eosinophilia and asthma. It is associated with positive p-ANCA. The patient has nephritic syndrome as evidenced by hypertension, oedema and haematuria. Asthma is suggested by his chest tightness and shortness of breath.The American College of Rheumatology has defined the criteria for a diagnosis of eosinophilic granulomatosis with polyangiitis:

- Asthma
- High numbers of eosinophils
- Sensory neuropathy
- Lung abnormalities
- Sinus problems such as abnormal growths (polyps)
- A tissue sample showing a blood vessel with eosinophils around it.

A person with eosinophilic granulomatosis with polyangiitis may have some or all of these symptoms. Besides the criteria for diagnosis listed above, the person with eosinophilic granulomatosis with polyangiitis may have:

- A nodular or purpuric skin rash
- Renal, intestinal or cardiac involvement
- Malaise
- Loss of appetite (anorexia) and weight loss
- Other symptoms specific to the part of the body affected.

Internationally: incidence is approximately 2.5 cases

A person with eosinophilic granulomatosis with polyangiitis may have some or all of these symptoms. Besides the criteria for diagnosis listed above, the person with eosinophilic granulomatosis with polyangiitis may have:

- A nodular or purpuric skin rash
- Renal, intestinal or cardiac involvement
- Malaise
- Loss of appetite (anorexia) and weight loss
- Other symptoms specific to the part of the body affected.

Internationally: incidence is approximately 2.5 cases per 100,000 adults per year. The principal causes of morbidity and mortality are myocarditis and myocardial infarction secondary to coronary arteritis. With treatment, the 1-year survival rate is 90% and the 5-year survival rate is 62%. Overall, without treatment, the 5-year survival rate is about 25%. Glucocorticoids alone usually are adequate for treatment of eosinophilic granulomatosis with polyangiitis. Cytotoxic drugs are necessary in less than 20% of patients. Major life-threatening organ involvement may require treatment with pulse doses of intravenous (IV) corticosteroids as well as other cytotoxic agents. Other treatments include intravenous immune globulin, interferon-alpha and plasma exchange. Plasma exchange has not improved the course of the disease. Complications of eosinophilic granulomatosis with polyangiitis depend on the specific organ system involvement.

A Anti-glomerular basement membrane antibody

10:41

A 40-year-old woman attended Accident and Emergency Department. She is on established peritoneal dialysis (PD) and has presented with generalised abdominal pain, vomiting and pyrexia. She has a past medical history of hypertension.

On questioning, she says her menstruation is erratic and she has not had a menstrual period for several months now. Furthermore, she says she has not passed any urine for a few days.

On physical examination, she has a temperature of 38 °C, heart rate 100 bpm and a blood pressure of 140/80 mmHg. Her abdomen is distended and there is generalised tenderness with no guarding or rigidity.

Investigations showed:

Na^+	136 mmol/l
K^+	4.9 mmol/l
Urea	15.0 mmol/l
Creatinine	530 µmol/l
CRP	150 mg/l
Hb	9 g/dl
WCC	15.4×10^9/l
PLT	560×10^9/l

What is the likely cause of her abdominal pain?

A Appendicitis

B Ectopic pregnancy

C Menstruation

Rana Alnasser's screen

how. Furthermore, she says she has not passed any urine for a few days.

On physical examination, she has a temperature of 38 °C, heart rate 100 bpm and a blood pressure of 140/80 mmHg. Her abdomen is distended and there is generalised tenderness with no guarding or rigidity.

Investigations showed:

Na^+	136 mmol/l
K^+	4.9 mmol/l
Urea	15.0 mmol/l
Creatinine	530 µmol/l
CRP	150 mg/l
Hb	9 g/dl
WCC	15.4×10^9/l
PLT	560×10^9/l

What is the likely cause of her abdominal pain?

A Appendicitis

B Ectopic pregnancy

C Menstruation

D Peritonitis

E UTI

Submit

Urea	15.0 mmol/l
Creatinine	530 μmol/l
CRP	150 mg/l
Hb	9 g/dl
WCC	15.4 × 10^9/l
PLT	560 × 10^9/l

What is the likely cause of her abdominal pain?

Your answer was correct

A Appendicitis

B Ectopic pregnancy

C Menstruation

D Peritonitis

E UTI

Explanation

D Peritonitis

Patients on peritoneal dialysis (PD) are at risk of peritonitis. Enquiry should be made about the colour of the dialysate. A cloudy dialysate would suggest that the possibility of an underlying infection. Microscopy, culture and sensitivity (MC+S) of the fluid should be requested, in addition to the standard septic screen. Many protocols exist for treatment of PD peritonitis; it largely depends on local experience and prevalence of different strains of bacterium. The

Explanation

D Peritonitis

Patients on peritoneal dialysis (PD) are at risk of peritonitis. Enquiry should be made about the colour of the dialysate. A cloudy dialysate would suggest that the possibility of an underlying infection. Microscopy, culture and sensitivity (MC+S) of the fluid should be requested, in addition to the standard septic screen. Many protocols exist for treatment of PD peritonitis; it largely depends on local experience and prevalence of different strains of bacterium. The International Society of Peritoneal Dialysis recommends the following, as a guide: for Gram-positive cover use vancomycin or a cephalosporin, and for Gram-negative cover use an aminoglycoside or third-generation cephalosporin. For example, vancomycin 2 g intraperitoneally on day 1 with a further dose a week later depending on vancomycin levels. In addition, gentamicin 0.6 mg/kg intraperitoneally with adjustment of levels on days 3–5.

A Appendicitis

Appendicitis would give localised right lower quadrant pain.

B Ectopic pregnancy

Patients in chronic kidney disease are unlikely to either pass urine or menstruate. The rate of conception for pregnancy is lower in patients with end-stage renal disease compared with the general population. Pain associated with ectopic pregnancy would be unilateral rather than generalised abdominal pain.

C Menstruation

Appendicitis would give localised right lower quadrant pain.

B Ectopic pregnancy

Patients in chronic kidney disease are unlikely to either pass urine or menstruate. The rate of conception for pregnancy is lower in patients with end-stage renal disease compared with the general population. Pain associated with ectopic pregnancy would be unilateral rather than generalised abdominal pain.

C Menstruation

Menstruation is commonly erratic in patients with renal disease – irregular or cessation of menstruation is common.

E UTI

Patients who have chronic kidney disease may not pass any urine if there is lack of residual renal function.

Rate this question:

© Pastest 2019

A 22-year-old man, with a history of nephrotic syndrome due to minimal change disease, comes to the clinic because he feels more poorly than usual. He has noticed that despite his usual dose of furosemide, his leg oedema is worsening and for the past few days he has suffered from some vague left flank pain.

On examination, his BP is 155/92 mmHg and you confirm the left flank pain.

Investigations:

Hb	11.1 g/dl
WCC	7.1×10^9/l
PLT	232×10^9/l
Na^+	140 mmol/l
K^+	5.4 mmol/l
Creatinine	280 µmol/l (190 µmol/l at clinic a month earlier)
24 h urinary protein	3g (up from 1.6 g last time it was assessed)
Cholesterol	6.9 mmol/l

Which of the following is the most likely diagnosis?

A Renal artery thrombosis

B Renal vein thrombosis

C Acute pyelonephritis

D Nephrolithiasis

despite his usual dose of furosemide, his leg oedema is worsening and for the past few days he has suffered from some vague left flank pain.

On examination, his BP is 155/92 mmHg and you confirm the left flank pain.

Investigations:

Hb	11.1 g/dl
WCC	7.1×10^9/l
PLT	232×10^9/l
Na^+	140 mmol/l
K^+	5.4 mmol/l
Creatinine	280 µmol/l (190 µmol/l at clinic a month earlier)
24 h urinary protein	3g (up from 1.6 g last time it was assessed)
Cholesterol	6.9 mmol/l

Which of the following is the most likely diagnosis?

A Renal artery thrombosis

B Renal vein thrombosis

C Acute pyelonephritis

D Nephrolithiasis

E Left sided renal cysts

10:46
594-042-7551 Leave

he feels more poorly than usual. He has noticed that despite his usual dose of furosemide, his leg oedema is worsening and for the past few days he has suffered from some vague left flank pain.

On examination, his BP is 155/92 mmHg and you confirm the left flank pain.

Investigations:

Hb	11.1 g/dl
WCC	7.1×10^9/l
PLT	232×10^9/l
Na^+	140 mmol/l
K^+	5.4 mmol/l
Creatinine	280 µmol/l (190 µmol/l at clinic a month earlier)
24 h urinary protein	3g (up from 1.6 g last time it was assessed)
Cholesterol	6.9 mmol/l

Which of the following is the most likely diagnosis?

Your answer was incorrect

A Renal artery thrombosis

B Renal vein thrombosis

C Acute pyelonephritis

D Nephrolithiasis

Audio Video Share Participants More

10:48

MyPastest
https://mypastest.pastest.com

E Left sided renal cysts

Explanation

B Renal vein thrombosis

Patients with nephrotic syndrome are known to suffer from a hypercoagulable state and, as such, are more prone to suffering from renal vein thrombosis. This picture of vague flank pain, coupled with worsening creatinine and proteinuria, is fairly typical. Initial investigation with ultrasound is likely to reveal a swollen, oedematous kidney on the left when compared to the other side. Long-term anticoagulation may be considered in this patient for prophylaxis against further thromboembolic events.

A Renal artery thrombosis

Renal artery thrombosis causes complete blockage to the blood flow through the main arteries. This is a rare cause of acute kidney injury. The clinical manifestation depends on the amount of renal tissue being supplied by the renal artery being blocked by the embolism. It may range from mild increase in serum creatinine to complete anuria. Most patients experience a sudden onset of abdominal, flank or back pain. Renal artery thrombosis is not associated with minimal change disease/nephritic syndrome. The major causes of renal artery stenosis include thromboemboli (systemic clot emboli) and atheroemboli (cholesterol emboli).

C Acute pyelonephritis

Rana Alnasser's screen

Pyelonephritis may give left flank pain, but there would be other symptoms such as fever and chills or rigors. You would expect the white cell count to be raised. There is no other history to suggest acute pyelonephritis.

D Nephrolithiasis

Nephrolithiasis typically causes renal colic when passed. Patients are usually male and in their 4th decade. There would be renal angle tenderness and haematuria, which is often macroscopic with urinary symptoms such as dysuria and frequency of urination. Predisposing factors include dehydration, exercise and high protein load. There is no history to support renal stones in this case.

E Left sided renal cysts

Renal cysts may give rise to left flank pain, especially with haemorrhage or rupture of the cyst. There is no increase in incidence of renal cysts in minimal change disease and there is no history in this case to suggest that renal cysts are present.

Rate this question:

© Pastest 2019

A 71-year-old woman is admitted with general deterioration and 'off-legs'. She has no significant past medical history and lives alone.

On examination in the Emergency Department, she looks dry and her skin has a yellow tinge. Blood pressure is 125/50 mmHg, chest examination has a few scattered bibasal crepitations at bases and heart sounds are normal. Abdominal examination is unremarkable. There are peaked T waves on the 12-lead ECG.

Investigations reveal:

Potassium (K^+)	7.2 mmol/l
Sodium (Na^+)	145 mmol/l
Creatinine	512 µmol/l
Urea	36.8 mmol/l

She is immediately put on a cardiac monitor.

Which one of the following measures is next most important in her immediate management?

A Calcium resonium

B Intravenous calcium gluconate

C Intravenous insulin and dextrose infusion

D Intravenous saline infusion

E Salbutamol nebuliser

Submit

likely to have significant cardiotoxicity. Signs include peaked T waves, PR interval prolongation and QRS widening. Calcium gluconate stabilises nerve and muscle membrane excitation and should be considered the first-line therapy in this situation.

Next, immediate measures likely to result in reduction of serum potassium include nebulised salbutamol and insulin and dextrose infusion. After this, it is important to establish fluid status via catheterisation and measurement of urine output, and consideration of line placement to measure central venous pressure. Urgent renal ultrasound may also be useful at this stage to establish pointers towards the aetiology of kidney disease.

A Calcium resonium

Calcium resonium acts by inhibiting absorption of potassium by the gut. The side-effect includes constipation. It is slow acting and therefore would not be the immediate first treatment choice.

C Intravenous insulin and dextrose infusion

Intravenous (iv) insulin and dextrose infusion would be the next treatment step after iv calcium gluconate. The insulin and dextrose act to push potassium into the intracellular compartment thereby reducing serum potassium levels. This is a temporary procedure as the potassium needs to be excreted or removed via dialysis.

D Intravenous saline infusion

Saline will not affect the potassium level, although it may help uraemia and dehydration to improve fluid status. This would not be the immediate first treatment.

E Salbutamol nebuliser

Rana Alnasser's screen

10:49

A 29-year-old woman with renal disease secondary to systemic lupus erythematosis is seen in the Rheumatology Clinic. She has had three urinary tract infections in the past year and was recently admitted to the Emergency Department with acute severe unilateral abdominal pain which settled spontaneously after several hours.

On physical examination, her blood pressure is 130/80 mmHg and chest and abdominal examination is unremarkable.

On her last outpatient visit a number of investigations were requested, the results of which are now available:

Na^+	141 mmol/l
Serum potassium	3.3 mmol/l
Urea	9.0 mmol/
Creatinine	188 µmol/l
Serum bicarbonate	12 mmol/l
Urine	pH 7.4

What is the most likely underlying cause of these results and possibly for some of her recent presentations?

A Bartter syndrome

B Type 1 (distal) renal tubular acidosis

C Type 2 (proximal) renal tubular acidosis

D Type 4 renal tubular acidosis

E Staghorn calculus leading to recurrent urinary sepsis

Rana Alnasser's screen

E Staghorn calculus leading to recurrent urinary sepsis

Explanation

B Type 1 (distal) renal tubular acidosis

This lady has a compensated metabolic acidosis with relatively high urinary pH and low potassium. These are features of type 1 (distal) renal tubular acidosis (RTA), and are probably secondary to her lupus-associated renal impairment. The suggestion of urinary calculi and recurrent urinary infections support this as these are recognised complications of the inability to acidify the urine. A staghorn calculus with recurrent sepsis would not in itself explain her biochemical picture, although nephrocalcinosis can also be associated with RTA. Nephrocalcinosis and recurrent urinary sepsis are also associated with type 1 (distal) RTA, and in the context of her rheumatological disease it is more likely that this is the underlying cause. It would also be highly unusual to find this condition coexisting with lupus renal disease.

A Bartter syndrome

Barrter syndrome is an inherited or sometimes sporadic disorder leading to hypokalaemia; however, this would not cause the urinary abnormalities seen here and, if inherited, would have presented earlier.

C Type 2 (proximal) renal tubular acidosis

Proximal renal tubular acidosis is due to impaired retention of bicarbonate in the proximal tubule leading to bicarbonate wasting and a systemic acidosis. It presents as a hyperchloraemic metabolic acidosis, usually with other

C Type 2 (proximal) renal tubular acidosis

Proximal renal tubular acidosis is due to impaired retention of bicarbonate in the proximal tubule leading to bicarbonate wasting and a systemic acidosis. It presents as a hyperchloraemic metabolic acidosis, usually with other features of proximal tubular dysfunction. Common causes include myeloma, amyloidosis, cystinosis and Wilson's disease.

D Type 4 renal tubular acidosis

This is more common than type 1 and 2 renal tubular acidosis. It is due to aldosterone resistance.

E Staghorn calculus leading to recurrent urinary sepsis

Staghorn calculus is caused by infection with *Proteus*, *Klebsiella* or *Serratia*. Typically, these stones are seen on KUB. It is not associated with SLE.

Rate this question:

Next Question

Previous Q... Tag Questi... Feedback End Session

Blog About Pastest Contact Us Help

© Pastest 2019

A 34-year-old man with chronic kidney disease is seen in the Nephrology Clinic. He is asymptomatic.

His current medications include atenolol 100 mg once daily, ramipril 10 mg once daily, alfacalcidol 0.25 µg once daily, Calcichew® 1 tablet with meals and a multivitamin preparation

Investigations:

Hb	9 g/dl
Haematocrit	0.3
MCV	80 fl
Urea	21 mmol/l
Creatinine	423 µmol/l
PTH	8.5 pmol/l
Ferritin	14 µg/l

What is the most appropriate next intervention for his anaemia?

A Oral ferrous sulphate

B Intravenous iron

C Intravenous erythropoietin

D Red cell transfusion

E Subcutaneous erythropoietin

Submit

MCV	80 fl
Urea	21 mmol/l
Creatinine	423 µmol/l
PTH	8.5 pmol/l
Ferritin	14 µg/l

What is the most appropriate next intervention for his anaemia?

Your answer was correct

A Oral ferrous sulphate

B Intravenous iron

C Intravenous erythropoietin

D Red cell transfusion

E Subcutaneous erythropoietin

Explanation

B Intravenous iron

Anaemia is almost universal in patients with chronic kidney disease; it is characteristically normochromic and normocytic and is associated with erythropoietin (Epo) deficiency and shortening of red cell survival.

Intravenous iron is the most appropriate intervention taking into account the very low ferritin of 14 and given that oral iron absorption is often defective in chronic kidney disease.

E Subcutaneous erythropoietin

Explanation

B Intravenous iron

Anaemia is almost universal in patients with chronic kidney disease; it is characteristically normochromic and normocytic and is associated with erythropoietin (Epo) deficiency and shortening of red cell survival.

Intravenous iron is the most appropriate intervention taking into account the very low ferritin of 14 and given that oral iron absorption is often defective in chronic kidney disease.

A Oral ferrous sulphate

Due to defective oral iron absorption, and the fact that the ferritin level is only 14, oral iron replacement is highly unlikely to be effective.

C Intravenous erythropoietin

This is only used in dialysis patients and given via the dialysis circuit.

D Red cell transfusion

Red cell transfusions should be avoided unless in an emergency, as this patient will develop circulating antibodies which would make future transplantation more difficult.

E Subcutaneous erythropoietin

Eventually, patients are commenced on erythropoietin. Iron

An 18-year-old young man presents with longstanding polyuria, polydipsia and occasional abdominal and calf cramping pains, along with the following biochemical abnormalities. His parents are first cousins.

He has a normal stature and has been noted to have a low-normal blood pressure at around 95/50 mmHg.

Investigations reveal:

Sodium (Na^+)	136 mmol/l
Potassium (K^+)	2.3 mmol/l
Urea	4.5 mmol/l
Creatinine (Cr)	80 µmol/l
Bicarbonate	34 mmol/l
Magnesium (Mg^{2+})	0.59 mmol/l
Urinary calcium excretion	Low (urinary calcium/creatinine ratio 0.1)

What is the likely diagnosis?

A Alport syndrome

B Bartter syndrome

C Gitelman syndrome

D Liddle syndrome

E Severe Cushing syndrome

10:54

D Liddle syndrome

E Severe Cushing syndrome

Explanation

C Gitelman syndrome

The patient has features of Gitelman syndrome with hypokalaemic metabolic alkalosis, hypomagnesaemia and hypocalciuria. His symptoms are relatively mild, and his age at presentation and the low-normal blood pressure all support the diagnosis of Gitelman syndrome. This can occur either as a sporadic or an autosomal recessive condition. The consanguinity in this case suggests that this may be an autosomal recessive case. The prognosis of Gitelman syndrome is very good, and treatment is with potassium and magnesium supplements.

A Alport syndrome

Alport syndrome is an inherited condition, in which an abnormal form of the glomerular basement membrane is produced. It is associated with bilateral sensorineural deafness, kidney disease and haematuria.

B Bartter syndrome

Bartter syndrome shares some features (including hypokalaemia and hypotension) with Gitelman syndrome but is more severe, and patients therefore present earlier with profound hypokalaemia and hypotension in early childhood.

In Gitelman syndrome, urinary calcium excretion is low, and this can also be used as a differentiator, although calcium

Rana Alnasser's screen

Bartter syndrome shares some features (including hypokalaemia and hypotension) with Gitelman syndrome but is more severe, and patients therefore present earlier with profound hypokalaemia and hypotension in early childhood.

In Gitelman syndrome, urinary calcium excretion is low, and this can also be used as a differentiator, although calcium excretion is not the best differentiator between the two conditions.

D	Liddle syndrome

Liddle syndrome is associated with hypokalaemic metabolic alkalosis, but usually in the context of hypertension.

E	Severe Cushing syndrome

Cushing syndrome would be expected to produce other characteristic features, as well as hypertension, without the magnesium and calcium abnormalities seen above.

Rate this question:

Next Question

Previous Q... Tag Questi... Feedback End Session

Blog About Pastest Contact Us Help

© Pastest 2019

A 65-year-old man with no significant previous medical history presents to his GP with symptoms of an upper respiratory tract infection, for which he is prescribed a 10-day course of amoxicillin.

Towards the end of the course of antibiotics, he comes back to the GP complaining of increasing nausea, anorexia and shortness of breath. He has a BP of 145/95 mmHg and a diffuse rash over his groin and thighs.

Investigations:

Hb	13.1 g/dl
WCC	9.2×10^9/l (elevated eosinophil count)
PLT	187 × 109/l
Na^+	139 mmol/l
K^+	6.8 mmol/l
Creatinine	430 µmol/l
Urine	Blood +, protein +, WBC +

Which of the following is the most likely cause?

A	Acute interstitial nephritis
B	Acute tubular necrosis
C	Goodpasture syndrome
D	Henoch-Schonlein purpura
E	IgA nephropathy

WCC	9.2 × 10^9/l (elevated eosinophil count)
PLT	187 × 109/l
Na^+	139 mmol/l
K^+	6.8 mmol/l
Creatinine	430 µmol/l
Urine	Blood +, protein +, WBC +

Which of the following is the most likely cause?

Your answer was correct

A Acute interstitial nephritis

B Acute tubular necrosis

C Goodpasture syndrome

D Henoch-Schonlein purpura

E IgA nephropathy

Explanation

A Acute interstitial nephritis

AIN is an important cause of kidney disease and may be the cause of kidney disease in up to 15% of patients undergoing renal biopsy evaluation. Sulphonamides, penicillins, cephalosporins, diuretics and NSAIDS are all recognised causes. Discontinuation of the possible causative agent is the treatment of choice, and slow recovery is possible over the course of around six weeks. It

A Acute interstitial nephritis

AIN is an important cause of kidney disease and may be the cause of kidney disease in up to 15% of patients undergoing renal biopsy evaluation. Sulphonamides, penicillins, cephalosporins, diuretics and NSAIDS are all recognised causes. Discontinuation of the possible causative agent is the treatment of choice, and slow recovery is possible over the course of around six weeks. It is possible, however, that up to 40% of patients may progress to chronic kidney disease. High-dose prednisolone may improve the outcome when used in the acute situation. The findings of elevated creatinine, peripheral blood eosinophilia and red cells, protein and white cells in the urine all support the underlying diagnosis.

B Acute tubular necrosis

Acute tubular necrosis is associated with a significant period of renal hypoperfusion, which may for example be related to sepsis or haemorrhage.

C Goodpasture syndrome

Goodpasture is associated with pulmonary haemorrhage. In Goodpasture syndrome the anti-GBM antibody is positive.

D Henoch-Schonlein purpura

Henoch-Schonlein purpura does not fit with the eosinophilia seen here. Henoch-Schonlein purpura may have a raised IgA present in the blood.

E IgA nephropathy

IgA nephropathy usually follows a benign course, with no

A 24-year-old man presents with facial swelling. He has recently recovered from an upper respiratory tract infection, for which his general practitioner (GP) had prescribed a course of amoxicillin three days earlier. He was diagnosed with minimal change nephropathy 2 years ago, which was confirmed on biopsy. He is not currently taking corticosteroids.

On examination, his blood pressure (BP) is 150/88 mmHg. Chest and abdominal examination is unremarkable, except he has pitting ankle oedema.

Investigations:

Haemoglobin (Hb)	12.6 g/dl
White cell count (WCC)	7.8×10^9/l
Platelets (PLT)	195×10^9/l
Sodium (Na^+)	139 mmol/l
Potassium (K^+)	4.8 mmol/l
Creatinine (Cr)	130 µmol/l
Albumin (Alb)	25 g/l
Urine protein	+++

Which of the following is the most likely diagnosis?

A Immunoglobulin A (IgA) nephropathy

B Focal segmental glomerulosclerosis

C Membranous nephropathy

D Post-streptococcal glomerulonephritis

E Relapse of minimal change disease

Investigations:

Haemoglobin (Hb)	12.6 g/dl
White cell count (WCC)	7.8 × 10^9/l
Platelets (PLT)	195 × 10^9/l
Sodium (Na^+)	139 mmol/l
Potassium (K^+)	4.8 mmol/l
Creatinine (Cr)	130 µmol/l
Albumin (Alb)	25 g/l
Urine protein	+++

Which of the following is the most likely diagnosis?

Your answer was correct

A Immunoglobulin A (IgA) nephropathy

B Focal segmental glomerulosclerosis

C Membranous nephropathy

D Post-streptococcal glomerulonephritis

E Relapse of minimal change disease

Explanation

E Relapse of minimal change disease

Given the previous diagnosis, a relapse of minimal change disease is the most likely underlying diagnosis here. The

Explanation

E	Relapse of minimal change disease

Given the previous diagnosis, a relapse of minimal change disease is the most likely underlying diagnosis here. The interval between streptococcal infection and appearance of symptoms is too short to indicate that this is post-streptococcal glomerulonephritis. Minimal change disease is usually very responsive to corticosteroids, and hypertension should be managed aggressively, with angiotensin-converting enzyme (ACE) inhibitors as the first-choice therapy.

A	Immunoglobulin A (IgA) nephropathy

IgA nephropathy is the most common cause of glomerulonephritis in developed countries. There would be blood in the urine, instead of heavy proteinuria as in this case. Many patients are asymptomatic and the haematuria is detected incidentally.

B	Focal segmental glomerulosclerosis

Focal segmental glomerulosclerosis may be a cause of proteinuria, but it would be unusual for a new diagnosis of another cause of nephrotic syndrome, considering the previous diagnosis of minimal change disease.

Presentation of focal segmental glomerulosclerosis includes proteinuria, often heavy, microscopic haematuria and hypertension. An impaired renal function is common. Young black men are more commonly affected.

C	Membranous nephropathy

Membranous nephropathy may be a cause of proteinuria,

Young black men are more commonly affected.

C Membranous nephropathy

Membranous nephropathy may be a cause of proteinuria, but it would be unusual for a new diagnosis of another cause of nephrotic syndrome, considering the previous diagnosis of minimal change disease. Findings in membranous nephropathy include nephrotic syndrome, and reduced immunoglobulins are common, with IgG > IgA. Hepatitis B and C may be associated with membranous nephropathy.

D Post-streptococcal glomerulonephritis

Classically, post-streptococcal glomerulonephritis occurs in childhood (< seven years old), with a trigger of streptococcal sore throat 10–21 days before nephritis. There is gross haematuria, oliguria, oedema and hypertension. Bilateral loin pain or renal angle tenderness secondary to renal engorgement may be present. Nephrotic syndrome is not a feature of post-streptococcal glomerulonephritis.

Rate this question:

Next Question

Previous Q... Tag Questi... Feedback End Session

Blog About Pastest Contact Us Help

© Pastest 2019

A 30-year-old woman was admitted yesterday with sudden onset breathlessness while eating dinner and associated cough with frothy pink sputum. She was treated in the Emergency Department and has been transferred to the ward. A similar episode prompted admission to hospital 2 months ago. She has a background medical history of hay fever.

Her chest on auscultation is clear and she feels a lot better. Her blood pressure is 160/90 mmHg. The remainder of the examination is unremarkable.

Investigations on admission:

Electrocardiogram	Sinus rhythm at 120/min
Chest X-ray	Upper lobe diversion, Kerley B lines, cardiothoracic ratio of 0.4
Sodium	140 mmol/l
Potassium	3.8 mmol/l
Urea	7.5 mmol/l
Creatinine	110 μmol/l

What is the most likely underlying diagnosis?

A Wegener's granulomatosis

B Conn's syndrome

C Fibromuscular dysplasia

D Goodpasture's syndrome

E Aortic stenosis

10:59

MyPastest
https://mypastest.pastest.com

Pastest+

A 30-year-old woman was admitted yesterday with sudden onset breathlessness while eating dinner and associated cough with frothy pink sputum. She was treated in the Emergency Department and has been transferred to the ward. A similar episode prompted admission to hospital 2 months ago. She has a background medical history of hay fever.

Her chest on auscultation is clear and she feels a lot better. Her blood pressure is 160/90 mmHg. The remainder of the examination is unremarkable.

Investigations on admission:

Electrocardiogram	Sinus rhythm at 120/min
Chest X-ray	Upper lobe diversion, Kerley B lines, cardiothoracic ratio of 0.4
Sodium	140 mmol/l
Potassium	3.8 mmol/l
Urea	7.5 mmol/l
Creatinine	110 μmol/l

What is the most likely underlying diagnosis?

Your answer was correct

A Wegener's granulomatosis

B Conn's syndrome

C Fibromuscular dysplasia

A
B
C
D
E
O

granulomas, are found in affected tissues.

B Conn's syndrome

Conn's syndrome presents with hypokalaemia and hypertension.

D Goodpasture's syndrome

Also known as antiglomerular basement antibody disease, or anti-GBM disease, it is a rare autoimmune disease in which antibodies attack the basement membrane in lungs and kidneys, leading to bleeding from the lungs and kidney failure. Flash pulmonary oedema is not a feature, pulmonary haemorrhage may be present.

E Aortic stenosis

Pulmonary oedema may be present in patients with severe critical aortic stenosis. However, it is not common in young adults. There is no history of ischaemic heart disease or murmur to suggest aortic stenosis in this case.

Rate this question:

© Pastest 2019

Rana Alnasser's screen

10:59

A 54-year-old man with chronic kidney disease is managed by peritoneal dialysis. He has been on dialysis for the past three years and has a history of long-standing type 1 diabetes.

On examination in the clinic, his BP is 152/84 mmHg, with pulse 70/min and regular. There are no unexpected findings.

Investigations:

Hb	10.4 g/dl
WCC	5.4×10^9/l
PLT	180×10^9/l
Na^+	139 mmol/l
K^+	4.5 mmol/l
Creatinine	480 µmol/l
Ca^{++}	2.85 mmol/l
PO_4^{3-}	1.8 mmol/l
PTH	18.2 pmol/l (0.9-5.4)

Which of the following best treats the range of abnormalities associated with tertiary hyperparathyroidism?

A Calcium and vitamin D

B Cinacalcet

C Low-phosphate diet

D Sevelamer

Rana Alnasser's screen

WCC	5.4×10^9/l
PLT	180×10^9/l
Na^+	139 mmol/l
K^+	4.5 mmol/l
Creatinine	480 µmol/l
Ca^{++}	2.85 mmol/l
PO_4^{3-}	1.8 mmol/l
PTH	18.2 pmol/l (0.9-5.4)

Which of the following best treats the range of abnormalities associated with tertiary hyperparathyroidism?

Your answer was correct

A Calcium and vitamin D

B Cinacalcet

C Low-phosphate diet

D Sevelamer

E Vitamin D

Explanation

B Cinacalcet

Vitamin D (1-alpha-calcidol) is used in the early stages of hyperparathyroidism related to kidney disease, when

the patient is unable to undergo surgery. NICE guidelines recommend that cinacalcet is used only in patients who have refractory secondary hyperparathyroidism and who are resistant to medical therapy for high parathyroid hormone levels (>85 pmol/l) with a normal or high adjusted serum calcium level. In addition, surgical parathyroidectomy is contraindicated. The parathyroid hormone level is checked four months later and, if there is <30% reduction, then cinacalcet should not be continued. There is no evidence from large clinical trials that cincalcet reduced cardiovascular endpoints compared to placebo.

A Calcium and vitamin D

Vitamin D (1-alpha-calcidol) is used in the early stages of hyperparathyroidism related to kidney disease, when calcium levels are low-normal and PTH is above twice the upper limit of the normal range.

C Low-phosphate diet

This would be used in conjunction with cinacalcet. It is unlikely to have an effect on its own in this scenario.

D Sevelamer

This would be used in conjunction with cinacalcet. It is unlikely to have an effect on its own in this scenario.

E Vitamin D

Vitamin D (1-alpha-calcidol) is used in the early stages of hyperparathyroidism related to kidney disease, when calcium levels are low-normal and PTH is above twice the upper limit of the normal range.

Rate this question:

A 78-year old white man presents to the Emergency Department with a 1-day history of haemoptysis and a 2-week history of general malaise, shortness of breath, cough and intermittent fevers. He was prescribed clarithromycin for a presumed chest infection 10 days ago, but he has failed to respond to treatment.

On examination, he has a temperature of 37.8 °C; he is tachypnoeic and has evidence of bilateral lung consolidation.

Investigations show:

Na^+	143 mmol/l
K^+	5.5 mmol/l
Serum bicarbonate	19 mmol/l
Urea	18 mmol/l
Creatinine	220 µmol/l
CRP	120 mg/l
ESR	90 mm/first hour
Hb	10.5 g/dl
WCC	16×10^9/l
Complement C3	73 mg/dl (65–190 mg/dl)
Antibodies to nuclear antigens (ANA)	Positive
Antineutrophil cytoplasmic antigens (ANCA)	Positive
Antiproteinase 3	Positive
Antiglomerular basement membrane antibodies	Negative
	3+ blood and 2+

WCC	16×10^9/l
Complement C3	73 mg/dl (65–190 mg/dl)
Antibodies to nuclear antigens (ANA)	Positive
Antineutrophil cytoplasmic antigens (ANCA)	Positive
Antiproteinase 3	Positive
Antiglomerular basement membrane antibodies	Negative
Urine dipstick	3+ blood and 2+ protein
Urine microscopy	Red cell casts
Chest X-ray	Bilateral infiltrates

What is the most appropriate treatment for this patient?

A High-dose prednisolone alone

B High-dose prednisolone and cyclophosphamide

C Immunoglobulin IV

D Plasmapheresis

E Supportive care and IV antibiotics

Submit

11:01
594-042-7551 Leave

Urine microscopy	Red cell casts
Chest X-ray	Bilateral infiltrates

What is the most appropriate treatment for this patient?

Your answer was correct

A High-dose prednisolone alone

B High-dose prednisolone and cyclophosphamide

C Immunoglobulin IV

D Plasmapheresis

E Supportive care and IV antibiotics

Explanation

B High-dose prednisolone and cyclophosphamide

The patient has evidence of a rapidly progressive glomerulonephritis. The differential diagnosis includes pauci-immune small vessel vasculitides (Wegener's granulomatosis, polyarteritis nodosa (PAN) and microscopic polyangiitis), Goodpasture's syndrome, systemic lupus erythematosus (SLE) and IgA nephropathy. The presence of a pulmonary-renal syndrome coupled with the pattern of autoantibodies points to a diagnosis of Wegener's granulomatosis. The most appropriate treatment for this is high-dose steroids with cyclophosphamide, as this can induce remission in 80-90% of patients.

Audio Video Share Participants More

11:01
594-042-7551 Leave

glomerulonephritis.

C Immunoglobulin IV

There is no evidence that there is any benefit for IV immunoglobulins in this scenario. In fact, it may be important to *remove* the antigenic immunoglobulins for treatment, which is the concept for plasmapheresis.

D Plasmapheresis

When there is significant pulmonary haemorrhage associated with Wegener's granulomatosis and a rapid response to immune intervention isn't seen, then plasmapheresis would be indicated.

E Supportive care and IV antibiotics

It is important to stop progression of the inflammation and damage; therefore supportive care will not be the appropriate treatment. Appropriate immunosuppression in the form of prednisolone and cyclophosphamide is crucial.

Rate this question:

Next Question

Previous Q... Tag Questi... Feedback End Session

© Pastest 2019

Audio Video Share Participants More

11:01

A 35-year-old man attends the Renal Clinic for the first time. He has been referred by his GP because of a progressive decline in renal function over several months. His past medical history includes type 2 diabetes mellitus, repeated urinary tract infections as a child and recent admission to hospital with renal colic.

On examination, he is apyrexial, his blood pressure is 180/70 mmHg, and chest and abdominal examination are unremarkable.

Investigations:

Sodium	140 mmol/l
Potassium	5.5 mmol/l
Urea	15 mmol/l
Creatinine	230 µmol/l
HbA_{1C}	6% (126 mg/dl)
Hb	10.0 g/dl
WCC	5.1×10^9/l
Urine dipstick	No red blood cells White blood cells (WBCs) ++
Urine microscopy	WBC casts

What is the most likely diagnosis?

A Diabetic nephropathy

B Hypertensive nephropathy

C Reflux nephropathy

Rana Alnasser's screen

Sodium	140 mmol/l
Potassium	5.5 mmol/l
Urea	15 mmol/l
Creatinine	230 μmol/l
HbA_{1C}	6% (126 mg/dl)
Hb	10.0 g/dl
WCC	5.1×10^9/l
Urine dipstick	No red blood cells White blood cells (WBCs) ++
Urine microscopy	WBC casts

What is the most likely diagnosis?

A Diabetic nephropathy

B Hypertensive nephropathy

C Reflux nephropathy

D Tuberculosis

E Urinary tract infection

Submit

A 35-year-old man attends the Renal Clinic for the first time. He has been referred by his GP because of a progressive decline in renal function over several months. His past medical history includes type 2 diabetes mellitus, repeated urinary tract infections as a child and recent admission to hospital with renal colic.

On examination, he is apyrexial, his blood pressure is 180/70 mmHg, and chest and abdominal examination are unremarkable.

Investigations:

Sodium	140 mmol/l
Potassium	5.5 mmol/l
Urea	15 mmol/l
Creatinine	230 µmol/l
HbA_{1C}	6% (126 mg/dl)
Hb	10.0 g/dl
WCC	5.1×10^9/l
Urine dipstick	No red blood cells White blood cells (WBCs) ++
Urine microscopy	WBC casts

What is the most likely diagnosis?

Your answer was correct

A Diabetic nephropathy

B Hypertensive nephropathy

A
B
C
D
E
O

E Urinary tract infection

Explanation

C Reflux nephropathy

This man has reflux nephropathy, which is a progressive lesion caused by repeated urinary tract infections in either or both kidneys. The clue is the urinary tract infections as a child, because reflux nephropathy almost always develops in childhood in the setting of an abnormal renal tract. The long-term consequences are scarring and insufficiency, accounting for 5-12% of end stage kidney disease in the developed world. There are a variety of anatomical abnormalities that lead to the urinary tract infections, which include vesico-ureteric reflux, incomplete bladder emptying and outflow tract obstruction. The presentation of reflux nephropathy as an adult includes progressive renal impairment and hypertension. On an intravenous urogram there would be renal scarring and 'clubbed calyces'.

A Diabetic nephropathy

Diabetic nephropathy presents with proteinuria but not white cells in the urine. Nephropathy occurs due to microvascular glycosylation, renal hypertrophy and hyperfiltration. Two per cent of type 2 diabetics develop microalbuminuria annually, and 2.3% have proteinuria with declining glomerular filtration rate.

B Hypertensive nephropathy

There would not be white cells in the urine in hypertensive nephropathy. We would expect proteinuria. Hypertensive nephropathy may present with progressive renal impairment in the context of long-standing hypertension. Associated signs may include retinal haemorrhages and

impairment in the context of long standing hypertension. Associated signs may include retinal haemorrhages and exudates. There may be a history of accompanying cardiovascular disease such as strokes and myocardial infarction.

D Tuberculosis

Tuberculosis is a cause of sterile pyuria. However, in this scenario there are no associated symptoms to suggest tuberculosis such as fever, weight loss, malaise or night sweats. In addition there is no mention of any contact history or foreign travel to suggest exposure to tuberculosis.

E Urinary tract infection

Although urinary tract infections may cause urinary white cell counts to be raised, there is no symptoms that suggest active infection at present. This man does not complain of any symptoms such as urgency or dysuria. The blood white cell count is normal. There is no mention of any growth of bacteria in the urine.

Rate this question:

© Pastest 2019

A 17-year-old patient attends a Follow-up Clinic appointment. She has a family history of autosomal dominant polycystic kidney disease. Her older brother was recently diagnosed with the condition and she was referred by her general practitioner for screening. She has remained asymptomatic and was seen in clinic previously by a colleague.

On physical examination, she has a blood pressure of 135/80 mmHg, with chest and abdominal examination unremarkable.

Investigations:

Na^+	143 mmol/l
K^+	3.9 mmol/l
Urea	7 mmol/l
Creatinine	70 µmol/l
Renal ultrasound	No renal cysts detected

What is the next best management step in this case?

A	Cerebral magnetic resonance angiogram
B	Computerised tomography of the abdomen
C	Discharge from clinic
D	Repeat renal ultrasound after 1 year
E	Repeat renal ultrasound after 3 years

E Repeat renal ultrasound after 3 years

Autosomal polycystic kidney disease (ADPKD) genes are located on chromosomes 16 (majority) and 4 (minority). The best screening tool is ultrasound. In patients below the age of 20 years you can get false-negative test results, and it is recommended to screen patients after the age of 20 years.

A Cerebral magnetic resonance angiogram

There is an association with intra-cranial aneurysms and ADPKD, but screening for these is not indicated in this patient. Routine screening for intracranial aneurysms is recommended only for high-risk patients, such as those with a previous rupture, a positive family history of an intra-cerebral bleed, warning symptoms, and prior surgery that is likely to be associated with hypertension.

B Computerised tomography of the abdomen

A computerised tomography scan, although more sensitive than ultrasound, involves a high radiation dose to this young girl.

C Discharge from clinic

This girl is may have ADPKD, which would have future implications. Therefore, it is essential to follow up and not simply discharge from the clinic.

D Repeat renal ultrasound after 1 year

1 year would be too early - this girl would not be 20 years old at this point. As explained above, there would be false-negative test results when screening too early.

A 50-year -old Turkish male with a 3-year history of liver cirrhosis secondary to hepatitis C was admitted with a right gangreneous leg ulcer of 2 months' duration with pain in his joints. He has developed pleuritic chest pain with dyspnoea over the last few days. He is on interferon for his liver disease. He is a non-smoker and does not drink.

On examination, he is dyspnoeic and slightly jaundiced, with widespread spider naevi. He also has multiple purpuric rashes on his legs with a reticulated pattern to the skin. The leg ulcer is below the right knee with large ulceration and necrosis.

Investigations reveal:

PH	7.45
$p_a(O_2)$	7.2 kPa
$p_a(CO_2)$	3.5 kPa
Chest X-ray	normal
Sodium	135 mmo/l
Potassium	4.8 mmol/l
Urea	18 mmol/l
Creatinine	280 µmol/l
Corrected calcium	2.5 mmol/l
Albumin	27 g/l
Bilirubin	60 µmol/l
Aspartate transaminase (AST)	200 IU/l
Alanine aminotransferase (ALT)	289 IU/l
Haemoglobin (Hb)	11.5 g/dl
White cell count (WCC)	10.5×10^9 /l
Platelets	200×10^9/l

11:07

MyPastest
https://mypastest.pastest.com

Pastest+

Urea	18 mmol/l
Creatinine	280 μmol/l
Corrected calcium	2.5 mmol/l
Albumin	27 g/l
Bilirubin	60 μmol/l
Aspartate transaminase (AST)	200 IU/l
Alanine aminotransferase (ALT)	289 IU/l
Haemoglobin (Hb)	11.5 g/dl
White cell count (WCC)	10.5×10^9 /l
Platelets	200×10^9/l
Mean corpuscular volume (MCV)	88 fl
Urinalysis	Protein +++, blood +++

What is the underlying diagnosis?

A Multiple myeloma

B Rheumatoid arthritis

C Waldestrom's macroglobulinaemia

D Cryoglobulinaemia

E Hepatocellular carcinoma

Explanation

D	Cryoglobulinaemia

Cryoglobulins are immunoglobulins that precipitate when blood is cooled while flowing through the skin and subcutaneous tissues. This leads to small vessel damage in the limbs and deposition on the wall of small vessels resulting in generalised vasculitis, which presents with a reticulated skin pattern of microthrombosis and areas of gangrene. Pulmonary embolism, and arterial and venous thrombosis are common. Vasculitis results in glomerulonephritis, polyneuropathy, Raynaud's phenomenon and leg ulcers. Recognised associations are chronic infections such as hepatitis C, systemic lupus erythematosus, rheumatoid arthritis and Sjögren's syndrome. Management is with plasma exchange, chemotherapy and treatment of the underlying condition.

A	Multiple myeloma

Multiple myeloma is a haematological malignancy. It is characterised by an aberrant clone of plasma cells producing immunoglobulin (IgG or IgA) or immunoglobulin light chain. It generally presents in the over 60s with a male preponderance. Median survival is 3 years. The usual presentation is unexplained renal impairment with normal-sized kidneys and a bland urine deposit. Bone pain, weakness, fatigue, easy bruising, pallor and hepatomegaly (20%) are other features.

B	Rheumatoid arthritis

This history includes large ulcerations which are not a usual feature of rheumatoid arthritis per se, although patients with rheumatoid arthritis are at increased risk of ulcers.

A 63-year-old man is admitted to the ward with generalised oedema. He has a background of bronchial malignancy, treated with chemotherapy, and chronic obstructive pulmonary disease and tells you that the swelling has gradually increased over the past few weeks.

Examination reveals oedema of the legs, arms and face. Blood pressure is 145/75 mmHg.

Investigations:

Hb	13.6 g/dl
WCC	4.7×10^9/l
PLT	315×10^9/l
Na^+	146 mmol/l
K^+	4.3 mmol/l
Urea	7.2 mmol/l
Creatinine	63 µmol/l
INR	1.1
Bilirubin	15 µmol/l
AST	21 U/l
ALP	70 U/l
Albumin	24 g/l
24-h urinary protein collection	3.6 g/24 h (< 0.2)
Renal biopsy	Membranous glomerulonephritis

Diuretic treatment is commenced; which of the following is the other most important step?

A High-dose prednisolone

K^+	4.3 mmol/l
Urea	7.2 mmol/l
Creatinine	63 μmol/l
INR	1.1
Bilirubin	15 μmol/l
AST	21 U/l
ALP	70 U/l
Albumin	24 g/l
24-h urinary protein collection	3.6 g/24 h (< 0.2)
Renal biopsy	Membranous glomerulonephritis

Diuretic treatment is commenced; which of the following is the other most important step?

A High-dose prednisolone

B High-protein diet

C Intravenous albumin

D Prophylactic antibiotics

E Prophylactic LMW heparin

Submit

E Prophylactic LMW heparin

This patient has nephrotic syndrome secondary to membranous glomerulonephritis, which is associated with bronchial malignancies. The best initial management strategies are to restrict dietary sodium and commence diuretics, which is likely to be useful in controlling oedema and blood pressure. With nephrotic syndrome there is an increased risk of thromboembolism (related to loss of anti-thrombin III), and this patient also has a malignancy, and hence anticoagulation is indicated.

A High-dose prednisolone

Useful in minimal-change disease but is not usually effective here.

B High-protein diet

High-protein diet is not beneficial in nephrotic syndrome.

C Intravenous albumin

Albumin intravenously produces only a transient rise in serum levels.

D Prophylactic antibiotics

Although nephrotic syndrome confers an increased risk of infection, prophylactic antibiotics are not recommended; however, vaccinations (e.g. pneumococcal vaccine) can be used. Immunosuppressants are not indicated, at least not initially in this patient.

A 44-year-old man has been referred to the nephrologists with a serum creatinine of 210 μmol/l. He has a 15-year history of osteoarthritis.

One year ago, he was diagnosed with diabetes mellitus and essential hypertension.

His current medications include ramipril 10 mg, aspirin 75 mg, diclofenac 150 mg and atorvastatin 10 mg daily.

On examination, his BP was 110/70 mmHg. Systemic examination was normal.

Investigations:

Hb	10.9 g/dl
WCC	7.2×10^9/l
Platelets	210×10^9/l
Na^+	138 mmol/l
K^+	4.2 mmol/l
Urea	14.2 mmol/l
Creatinine	224 μmol/l
Ca^{2+}	2.28 mmol/l
PO_4^-	1.05 mmol/l
Albumin	38 g/l
HbA1c	37 mmol/mol (5.5%)
ECG	normal
Urine protein	0.9 g/24 h

Renal ultrasound scan reveals unobstructed echogenic kidneys, right kidney 9.4 cm, left kidney 8.8 cm

What is the most likely cause of his renal impairment?

WCC	7.2×10^9/l
Platelets	210×10^9/l
Na^+	138 mmol/l
K^+	4.2 mmol/l
Urea	14.2 mmol/l
Creatinine	224 µmol/l
Ca^{2+}	2.28 mmol/l
PO_4^-	1.05 mmol/l
Albumin	38 g/l
HbA1c	37 mmol/mol (5.5%)
ECG	normal
Urine protein	0.9 g/24 h

Renal ultrasound scan reveals unobstructed echogenic kidneys, right kidney 9.4 cm, left kidney 8.8 cm

What is the most likely cause of his renal impairment?

A Renovascular disease

B Hypertensive nephrosclerosis

C Analgesic nephropathy

D Herbal nephropathy

E Diabetic nephropathy

Explanation

C Analgesic nephropathy

The patient in question has chronic kidney disease due to the long-term use of non-steroidal anti-inflammatory drugs (NSAIDs). Chronic NSAID abuse leads to renal injury due to renal papillary necrosis and chronic interstitial nephritis. The degree of renal injury correlates with the duration of use and analgesic load. There is no specific treatment apart from avoidance of NSAIDs. In this situation, the proteinuria raises the possibility of a membranous nephritis pattern of disease.

A Renovascular disease

As he is on ACE inhibitors, the absence of bruits and symmetrical kidneys make renovascular disease unlikely.

B Hypertensive nephrosclerosis

The duration of diabetes mellitus and the normal blood pressure with no evidence of other end-organ damage (normal fundi, no LVH on voltage criteria in the ECG) excludes hypertensive nephrosclerosis.

D Herbal nephropathy

There is no clue in the history that he has been taking over-the-counter herbal medications. Some Chinese herbs have been implicated in the development of rapidly progressive kidney disease due to interstitial nephritis and progressive tubulo-interstitial fibrosis.

E Diabetic nephropathy

The duration of diabetes mellitus and the normal blood pressure with no evidence of other end-organ damage

A	Essential thrombocythaemia with cerebrovascular accident
B	Antiphospholipid syndrome with reactive thrombocytosis
C	Cerebral lupus with reactive thrombocytosis
D	Chronic myelogenous leukaemia (CML)
E	Acute myeloid leukaemia

Explanation

D	Chronic myelogenous leukaemia (CML)

The history is compatible with a cerebrovascular accident, and the high platelet count is likely to be the cause. Chronic myelogenous leukaemia (a myeloproliferative disorder) usually manifests with thrombocytosis at presentation, usually with a raised white cell count that is grossly left-shifted (where promyelocytes, metamyelocytes and myelocytes are all

You are asked to review the case of a 68-year-old woman who has had a lengthy dental procedure earlier in the day. She has a background of angina.

Current medications are isosorbide mononitrate and co-trimoxazole for a resistant urinary tract infection. She is complaining of a headache and breathlessness.

Examination shows her to be cyanosed.

Arterial blood gas on a 15 l non-rebreathe O_2 mask:

pH	7.42
P_aO_2	39.2 kPa
P_aCO_2	4.1 kPa
O_2 sats	70%
Portable chest X-ray	Normal appearance

What is the most likely diagnosis?

Your answer was correct

A Aspiration

B Carbon monoxide poisoning

C Methaemoglobinaemia

D Pulmonary embolism

E Glucose-6-phosphate dehydrogenase (G6PD) deficiency

Explanation

C Methaemoglobinaemia

Haemoglobin carries iron in its ferrous form (Fe^{2+}). When it is converted to

WCC	$20 \times 10^9/l$
PLT	$450 \times 10^9/l$
CXR	New shadowing at right base

He is diagnosed with acute chest syndrome, possibly related to mycoplasma infection.

What intervention has been shown to reduce the incidence of acute chest syndrome?

A	Low-dose enoxaparin
B	Prophylactic clarithromycin
C	Hydroxyurea
D	Folate supplements
E	Low-dose aspirin

33317

Submit

Previous Question Skip Question

Calculator

Normal Values

Blog About Pastest Contact Us Help

© Pastest 2019

A 24-year-old man presents with weakness of the left arm. He completed chemotherapy for diffuse large B-cell lymphoma 6 months previously. He had stage 4 disease at diagnosis, with lesions in his lungs and bone marrow at diagnosis. He received six courses of RCHOP chemotherapy (rituximab, vincristine, doxorubicin, cyclophosphamide and prednisolone) and six intrathecal injections of methotrexate; computed tomography at the end of treatment confirmed complete remission.

Examination shows power of 3/5 in the left arm biceps and triceps with decreased tone. Reflexes are reduced globally, and plantar reflexes are mute bilaterally.

Investigations:

Hb	16.3 g/dl
WCC	3.9×10^9/l
PLT	195×10^9/l
Bilirubin	9.0 μmol/l

LDH	1503 u/l (10–250)
MRI brain and spine	Unremarkable

CSF investigations:

Protein	1.3 g/l (0.15–0.45)
Cell count 6 (<5/ml)	80% lymphocytes
Culture	No growth at 48 h

What is the most likely diagnosis?

A	Guillain–Barré syndrome
B	Vincristine neuropathy
C	Methotrexate leucoencephalopathy
D	CNS relapse of lymphoma

completed chemotherapy for diffuse large B-cell lymphoma 6 months previously. He had stage 4 disease at diagnosis, with lesions in his lungs and bone marrow at diagnosis. He received six courses of RCHOP chemotherapy (rituximab, vincristine, doxorubicin, cyclophosphamide and prednisolone) and six intrathecal injections of methotrexate; computed tomography at the end of treatment confirmed complete remission.

Examination shows power of 3/5 in the left arm biceps and triceps with decreased tone. Reflexes are reduced globally, and plantar reflexes are mute bilaterally.

Investigations:

Hb	16.3 g/dl
WCC	3.9×10^9/l
PLT	195×10^9/l
Bilirubin	9.0 μmol/l
LDH	1503 u/l (10–250)

bilaterally.

Investigations:

Hb	16.3 g/dl
WCC	3.9 x 10^9/l
PLT	195 x 10^9/l
Bilirubin	9.0 µmol/l
LDH	1503 u/l (10–250)
MRI brain and spine	Unremarkable

CSF investigations:

Protein	1.3 g/l (0.15–0.45)
Cell count 6 (<5/ml)	80% lymphocytes
Culture	No growth at 48 h

What is the most likely diagnosis?

Your answer was incorrect

D CNS relapse of lymphoma

Central nervous system relapse is not uncommon in high-grade lymphoma, particularly if risk factors are present (more than one site of extranodal disease, high lactate dehydrogenase, bone marrow or sinus involvement). Presentation is often initially occult, with no lesion demonstrated on imaging, and several lumbar punctures may be necessary with samples examined by the technique of cytospin, which concentrates cellular material to increase the sensitivity of cytology. Clinical signs are often complicated by the fact that reflexes are suppressed from vincristine exposure. Central nervous system (CNS) lymphoma carries a grave prognosis, but if remission can be induced by high-dose cytosine arabinoside or high-dose methotrexate with folinic acid rescue, then autologous stem cell transplantation or cranial radiotherapy can be effective.

B Vincristine neuropathy

Vincristine neuropathy is progressive, beginning with peripheral sensory loss, rather than the picture seen here.

A Guillain–Barré syndrome

Guillain–Barré syndrome is associated with ascending weakness, which usually begins some 2–3 weeks after a viral illness.

C Methotrexate leucoencephalopathy

Methotrexate leukoencephalopathy is most commonly seen between 2 and 14 days of administration, with symptoms developing over minutes to hours, characterised by headache and progressive deterioration in conscious level accompanied by seizures and later focal neurological deficit. It is more commonly seen in children and is associated with white matter attenuation on CT scanning.

A 72-year-old man presents to the clinic with fever, weight loss, lethargy and a sensation of pins and needles in his feet. He is particularly concerned that he has begun to suffer increasing headaches over the past few weeks.

Other past history of note is gout, which developed a few months ago.

On examination, there are lymphadenopathy and hepatosplenomegaly.

Investigations:

Hb	9.8 g/dl (normal MCV)
WCC	4.1×10^9/l
PLT	95×10^9/l
Na^+	141 mmol/l
K^+	5.1 mmol/l
Creatinine	145 μmol/l
ESR	75 mm/h
IgM	Paraprotein band

Creatinine	145 µmol/l
ESR	75 mm/h
IgM	Paraprotein band
Bone marrow	Plasma cell infiltration

Which of the following is the most likely diagnosis?

A	Chronic lymphocytic leukaemia (CLL)
B	Waldenström's macroglobulinaemia (WM)
C	Acute lymphoblastic leukaemia (ALL)
D	Myelofibrosis
E	Myelodysplasia

B Waldenström's macroglobulinaemia (WM)

The combination of anaemia with low white cell and platelet counts, raised ESR, plasma cell infiltration of bone marrow and IgM paraprotein band is highly suggestive of Waldenström's. Death occurs either due to cardiovascular events because of increased viscosity, or due to progression of bone marrow infiltration leading to suppressed response to infection. Frontline chemotherapy for Waldenström's includes the use of alkylating agents; for patients who suffer from acute manifestations of hyperviscosity syndrome, plasmapheresis is the treatment of choice.

A Chronic lymphocytic leukaemia (CLL)

CLL is associated with splenomegaly, although the predominant abnormality seen is a rise in peripheral blood white

count.

C	Acute lymphoblastic leukaemia (ALL)

ALL is usually associated with severe anaemia and thrombocytopenia, with recurrent infections and bleeding episodes, rather than the picture seen here.

D	Myelofibrosis

Myelofibrosis is not associated with symptoms of hyperviscosity (the neuropathy and headaches seen here).

E	Myelodysplasia

Like myelofibrosis, myelodysplasia is not associated with the hyperviscosity symptoms reported here.

21033

Rate this question:

A 50-year-old man with aggressive lymphoma is receiving combination chemotherapy with rituximab, cyclophosphamide, vincristine, doxorubicin and prednisolone. At the start of therapy he had several cervical and axillary lymph nodes, none larger than 2 cm. Several studies of investigational products are available, and he asks you about the terminology of drug development.

In terms of the process of researching a new drug in the oncology setting, which of the following best applies to phase I studies?

A	The aim of a phase I study is to assess initial therapeutic activity
B	Phase I studies are conducted once an initial therapeutic effect in humans is demonstrated
C	It is common to combine

In terms of the process of researching a new drug in the oncology setting, which of the following best applies to phase I studies?

A	The aim of a phase I study is to assess initial therapeutic activity
B	Phase I studies are conducted once an initial therapeutic effect in humans is demonstrated
C	It is common to combine phase I and II studies
D	Phase I studies usually recruit several hundred patients
E	Phase I studies are classically randomised controlled and double-blinded

C It is common to combine phase I and II studies

Phase I studies study safety, pharmacokinetics and pharmacodynamics, whereas phase II studies study whether there is a therapeutic response. These two phases, in practice, are often combined.

A The aim of a phase I study is to assess initial therapeutic activity

Phase II studies assess whether or not there is a therapeutic response, whereas phase I studies assess safety, pharmacokinetics and pharmacodynamics (which may include initial hints as to the efficacy of the intervention).

B Phase I studies are conducted once an initial therapeutic effect in humans is demonstrated

Phase III studies are performed once initial safety and efficacy evaluation is completed, and usually compare the drug with an alternative.

D	Phase I studies usually recruit several hundred patients

Phase I studies study safety, pharmacokinetics and pharmacodynamics in an investigational agent's first usage in human subjects. They are not designed to assess therapeutic response, and patients should be aware of this as part of the consent process. As such, they tend to be small trials with only a few patients recruited to them.

E	Phase I studies are classically randomised controlled and double-blinded

Usually phase III and sometimes phase II trials are randomised controlled trials. Within the oncology trial setting, sponsors do not need to be blinded. They can be privy to all information

A Two units of HLA (human leucocyte antigen) matched blood from a family member

Non-CMV-screened blood runs the risk of transmission of CMV, and lack of irradiation runs the risk of the unit containing viable

B Two units of ABO matched blood from a family member

Because of previous transfusions, the likelihood of mismatching and a subsequent transfusion reaction is very high.

C Two units of standard cross-matched blood

This runs the risk of HLA mismatch, the presence of T cells in the donor sample and CMV infection.

6381

Rate this question:

You are called to see a 40-year-old woman who has become acutely short of breath, although she denies specific chest pain. She had a total knee replacement the previous day, which was uncomplicated. In the notes it is documented that she had a non-haemolytic febrile reaction this morning during a single-unit blood transfusion, which responded rapidly to hydrocortisone and chlorpheniramine. She has received no additional intravenous fluids. She has no previous medical history of note. She works part-time as an aerobics instructor and has four children. She does not smoke.

On examination, she is acutely short of breath, with a respiratory rate of 45 breaths per minute at rest. She is using accessory muscles and is clearly exhausted. Auscultation of the chest reveals widespread crackles. She has expectorated a small amount of frothy sputum. She is afebrile, blood pressure 150/90 mmHg, pulse 130 regular. Electrocardiogram shows no evidence of acute ischaemia. Chest X-ray shows

Electrocardiogram shows no evidence of acute ischaemia. Chest X-ray shows widespread alveolar shadowing. Heart size is normal. Full blood count and renal function are normal.

What is the most likely diagnosis?

A	Transfusion-related acute lung injury (TRALI)
B	Acute pulmonary oedema due to fluid overload from rapid infusion of blood products
C	Hospital-acquired pneumonia
D	Massive pulmonary embolus
E	Adult respiratory distress syndrome due to overwhelming sepsis

8250

Submit

A Transfusion-related acute lung injury (TRALI)

This lady has a classic history for transfusion-related acute lung injury (TRALI): she is multiparous, had a transfusion reaction and has developed adult respiratory distress within 6 h of a blood transfusion – this is thought to be due to anti-HLA or anti-neutrophil antibodies (hence is more common in multiparous women, and particularly donors rather than recipients).

The condition is diagnosed clinically and is thought to be significantly underdiagnosed. Treatment is with full respiratory support, as the condition is reversible after a few days. The diagnosis can be confirmed by the finding of anti-HLA or anti-neutrophil antibodies in the donor or recipient. Donors who carry such antibodies are resigned from the donor pool.

When recipients who have developed TRALI require further transfusion, male donors can be used to reduce the risk

donors can be used to reduce the risk of subsequent attacks. This is because they have a much lower rate of carriage of anti-HLA or anti-neutrophil antibodies (1–5% vs up to 20% in women).

B	Acute pulmonary oedema due to fluid overload from rapid infusion of blood products

There is no history of the one unit of blood being rapidly transfused. One unit of packed red cells is approximately 300 ml of fluid. Considering that the patient is young, fit and otherwise healthy, it would be unusual to get fluid overload from such a small amount of fluid.

C	Hospital-acquired pneumonia

Despite her shortness of breath and tachycardia, this patient has no other signs of sepsis or infection. Hospital-acquired pneumonias are diagnosed once a patient has been in a healthcare

acquired pneumonias are diagnosed once a patient has been in a healthcare setting for 5 days or more, which is not the case here.

D	Massive pulmonary embolus

This patient has a high heart rate, recent surgery and breathlessness, but she is maintaining a normal blood pressure and has widespread crackles on her lungs. In a massive PE, a patient would usually become haemodynamically compromised.

E	Adult respiratory distress syndrome due to overwhelming sepsis

Although this patient does have evidence of acute respiratory distress syndrome, there are no other signs of sepsis or infection. Her ARDS is due to TRALI.

8250

Rate this question:

A 50-year-old woman presents with lethargy and easy bruising. She was treated with curative intent for early stage breast cancer 5 years ago and has been well since. She is on no medication. There is no other significant previous medical history.

Examination shows a thin woman with bruises on all extremities and pale conjunctiva but is otherwise normal.

Investigations:

Hb	9.9 g/dl
WCC	3.5×10^9/l
PLT	113×10^9/l
Neutrophils	1.0×10^9/l
Reticulocytes	13×10^9/l (25-85)
PT	12 s (11.5-15.5)
APTT	35 s (30-40)
Blood film	Band forms, myelocytes and occasional promyelocytes, as

Blood film	Band forms, myelocytes and occasional promyelocytes, as well as nucleated red blood cells

What diagnosis would best fit this picture?

A	Acute promyelocytic leukaemia
B	Secondary breast cancer
C	Myelofibrosis
D	Thrombotic thrombocytopenic purpura
E	Aplastic anaemia

has been well since. She is on no medication. There is no other significant previous medical history.

Examination shows a thin woman with bruises on all extremities and pale conjunctiva but is otherwise normal.

Investigations:

Hb	9.9 g/dl
WCC	3.5×10^9/l
PLT	113×10^9/l
Neutrophils	1.0×10^9/l
Reticulocytes	13×10^9/l (25-85)
PT	12 s (11.5-15.5)
APTT	35 s (30-40)
Blood film	Band forms, myelocytes and occasional promyelocytes, as well as nucleated red blood cells

What diagnosis would best fit this

B Secondary breast cancer

The patient's blood tests show leuco-erythroblastic anaemia (left-shifted granulocytic series and nucleated red blood cells) with pancytopenia. This can be seen with high bone marrow turnover, e.g. in severe haemolytic anaemia (but the reticulocyte count will be high), myelofibrosis and chronic myeloid leukaemia (where there will be splenomegaly and the white cell and platelet count will usually be raised) or bone marrow invasion. Often in bone marrow invasion the invading malignancy will already have been diagnosed previously. The diagnosis requires a bone marrow trephine, which will usually show replacement of haematopoietic tissue with malignant cells.

E Aplastic anaemia

Aplastic anaemia is associated with peripheral pancytopenia and marrow failure.

A	Acute promyelocytic leukaemia

Acute promyelocytic leukaemia is characterised by the presence of promyelocytes in peripheral blood, rather than the leuco-erythroblastic blood picture seen here.

C	Myelofibrosis

Myelofibrosis does reveal a leucoerythroblastic blood picture, but given the history of lumpectomy, secondary breast cancer is a more likely cause.

D	Thrombotic thrombocytopenic purpura

TTP is associated with increased risk of thrombosis, haemolysis and a low platelet count.

6377

Rate this question:

A 43-year-old man presents to the Emergency department with a fever of 38.9 °C. He had finished a third cycle of chemotherapy for osteosarcoma only a few days earlier and he has an indwelling central venous catheter.

On examination, he looks unwell, he has a fever of 38.9 °C and his BP is 100/70 mmHg, with pulse 95/min and regular. There are no signs of pharyngitis and only minor erythema around the exit site for his catheter.

Investigations:

Hb	10.4 g/dl
WCC	5.4×10^9/l
Neutrophils	0.2×10^9/l
PLT	125×10^9/l
Na^+	138 mmol/l
K^+	4.3 mmol/l
Creatinine	122 μmol/l

Creatinine	122 μmol/l
ALT	174 U/l
ALP	392 U/l
Albumin	26 g/l

Which of the following is the most appropriate antibiotic regimen?

A	Gentamicin, piperacillin/tazobactam, vancomycin
B	Piperacillin/tazobactam, gentamicin, amphotericin
C	Gentamicin, vancomycin, flucloxacillin
D	Gentamicin, vancomycin, flucloxacillin, tazobactam
E	Amphotericin B, gentamicin, flucloxacillin

A Gentamicin, piperacillin/tazobactam, vancomycin

This patient has febrile neutropenia, having recently completed a course of chemotherapy, and with an indwelling vascular catheter. Hence a broad-spectrum antibacterial regimen, including adequate staphylococcal cover, is recommended. Therapy is not delayed whilst awaiting sample results, and anti-fungal therapy is usually considered later if non-response to therapy is seen. The alkaline phosphatase elevation seen here may be due to hepatic dysfunction or. of course, related to the underlying bony tumour.

B Piperacillin/tazobactam, gentamicin, amphotericin

This option sacrifices adequate anti-staphylococcal cover for introduction of an anti-fungal. In practice anti-fungals are introduced in the event that a response to therapy is not seen

that a response to therapy is not seen at 48 h.

C	Gentamicin, vancomycin, flucloxacillin

Piperacillin/tazobactam is the cornerstone of therapy according to **NICE guidelines**. It must therefore be included here.

D	Gentamicin, vancomycin, flucloxacillin, tazobactam

This option doesn't include piperacillin, meaning that it doesn't conform with current NICE guidelines.

E	Amphotericin B, gentamicin, flucloxacillin

Although this option provides good cover for staphylococcal and fungal pathogens, it fails to provide adequate cover against other potential infective agents.

You are asked to see a 60-year-old man on the High Dependency Unit. He underwent coronary artery bypass 7 days ago and has developed some necrotic ulcers on his abdominal wall. He has had two myocardial infarctions in the last year. He was otherwise recovering well post-operatively. He is on intravenous unfractionated heparin, aspirin, atenolol and lisinopril.

Examination shows a breathless, cyanosed man, with tachycardia and a clear chest. His BP is 110/60 mmHg. His left leg is swollen and mottled. Chest X-ray is clear.

Blood tests show:

Hb	10.3 g/dl
WCC	5.3×10^9/l
PLT	25×10^9/l
Blood film	Confirms low PLT
APTT	42 s (30–40s)

How will you manage this patient?

APTT	42 s (30–40s)

How will you manage this patient?

A Give a unit of platelets

B Change to low-molecular weight heparin

C Stop all anticoagulation until the platelet count returns to normal

D Stop heparin and start anticoagulation with danaparoid until the platelet count returns to normal

E Stop heparin and start anticoagulation with warfarin, once a thrombophilia test has ruled out protein C or S deficiency

D Stop heparin and start anticoagulation with danaparoid until the platelet count returns to normal

This patient has low platelets and necrotic skin lesions. Low platelets in association with heparin therapy are associated with heparin-induced thrombocytopenia with thrombosis (HIT type II). The skin lesions are due to heparin-induced skin necrosis. HIT type I is a non-immune condition which occurs with 5 days of starting heparin, and the platelet count rarely falls below 100 10^9/l. HIT type II, also known as heparin-induced thrombocytopenia with thrombosis, presents with a >50% fall in the platelet count and is associated with a very high incidence of venous thromboembolism. In patients newly treated with heparin the condition takes 7 days to develop, but in patients who have previously received heparin the condition can come on within 24 h. The diagnosis is established by confirming the presence of antibodies

the condition can come on within 24 h. The diagnosis is established by confirming the presence of antibodies to heparin bound to co-factor 4, usually by enzyme-linked immunosorbent assay. Treatment is with immediate withdrawal of all heparin, including heparin flushes for indwelling cannulae.

Low-molecular weight heparin will cross-react in most cases, although it carries a lower risk of causing the condition *de novo*. Because of the high incidence of thrombosis (20–50%), alternative anticoagulation with the heparinoid danaparoid (a combination of heparan and dermatan sulphate) or lepirudin (a recombinant direct thrombin inhibitor) should be used in all patients until the platelet count returns to normal. Over the longer term, non-heparin-based anticoagulation (e.g. with lepirudin or a factor Xa inhibitor) may be the better option.

A	Give a unit of platelets

A Give a unit of platelets

Thrombosis which occurs in HIT type 2 is antibody mediated, and thus giving a unit of platelets and continuing heparin runs the risk of further thrombosis occurring.

B Change to low-molecular weight heparin

Although the risk of HIT occurring is lower with low-molecular weight heparin, a switch to non-heparin-based anticoagulation must still be made.

C Stop all anticoagulation until the platelet count returns to normal

Given the likelihood of a DVT and subsequent pulmonary embolus, continuing anticoagulation using a non-heparin-based agent is essential.

E Stop heparin and start anticoagulation with warfarin

A 50-year-old painter who specialises in house restoration goes to see a new GP for a routine signing-on medical.

Past medical history of note includes a recent diagnosis of gout. Some blood tests are arranged, and the GP mails you to discuss the results. He reports on his e-mail that the clinical examination was unremarkable.

Investigations:

Hb	10.5 g/dl
MCV	60 fl
WCC	5.0×10^9/l
PLT	190×10^9/l
Ferritin	300 µmol/l (15-300)
Hb electrophoresis	Normal

Which of the following is the most likely diagnosis?

PLT	190 x 10^9/l
Ferritin	300 µmol/l (15-300)
Hb electrophoresis	Normal

Which of the following is the most likely diagnosis?

A Iron deficiency anaemia

B Beta-thalassaemia

C Anaemia of chronic disease

D Lead poisoning

E Porphyria

21005

Submit

D Lead poisoning

The clue given here is in his occupation as a painter. It is still possible, even in the days of lead-free paints, that he would have had significant lead exposure while stripping the walls in old houses. The blood picture of lead toxicity mimics that seen with iron deficiency anaemia; additionally, disordered handling of uric acid may lead to the development of gout.

B Beta-thalassaemia

The normal Hb electrophoresis and lack of description of an ethnic origin consistent with thalassaemia counts against this as a diagnosis.

A Iron deficiency anaemia

Although iron deficiency anaemia does present with microcytic anaemia, the normal ferritin level would be very unusual in this context.

A Iron deficiency anaemia

Although iron deficiency anaemia does present with microcytic anaemia, the normal ferritin level would be very unusual in this context.

C Anaemia of chronic disease

Anaemia of chronic disease is normally associated with a normochromic, normocytic blood picture.

E Porphyria

Cutaneous porphyrias are associated with a skin rash not seen here, and acute porphyrias are associated with paroxysms of acute psychiatric disturbance with hypertension, tachycardia and hyponatraemia.

21005

Rate this question:

Next Question

A 24-year-old man of Indian ethnic origin is referred for investigation of anaemia by his GP. He is asymptomatic and attended the surgery for new patient blood testing. He has no physical complaints.

Examination is unremarkable.

Investigations:

Full blood count:

Hb	12.5 g/dl (13.5–18.0)
WBC	6.8×10^9/l (4.0–11.0)
PLT	340×10^9/l (150–450)
MCV	65 fl (78–100)

Haemoglobin electrophoresis:

HbA	91.7% (95–98)
HbA_2	7.1% (2.0–3.0)
HbF	1.2% (1.0–2.0)
Other protein bands	None seen

What is the most likely diagnosis?

Haemoglobin electrophoresis:

HbA	91.7% (95–98)
HbA_2	7.1% (2.0–3.0)
HbF	1.2% (1.0–2.0)
Other protein bands	None seen

What is the most likely diagnosis?

A Alpha-thalassaemia trait

B Haemoglobin H disease

C Beta-thalassaemia minor

D Beta-thalassaemia major

E Sickle cell trait

C Beta-thalassaemia minor

Loss of one beta-globin gene results in a mild reduction in normal HbA (2 × alpha- and 2 × beta-globins) production and a compensatory increase in HbA2 production (2 × alpha- and 2 × delta-globins). These patients are asymptomatic with normal examinations and are often not diagnosed until routine bloods detect a mild anaemia and microcytosis.

Haemoglobin is made up of haem (iron-containing compound that binds oxygen) and globin (protein components that bind to and wrap around haem). The majority (95–98%) of adult haemoglobin is made up of HbA (2 × alpha-globins and 2 × beta-globins). A small percentage (2–3%) of adult haemoglobin is HbA2 (2 × alpha-globins and 2 × delta-globins). Adults usually have only a small amount of fetal haemoglobin or HbF (2 × alpha-globins and 2 × gamma-globins). Thalassaemia is a haemoglobinopathy resulting from defective synthesis of globin chains that prevents normal

Thalassaemia is a haemoglobinopathy resulting from defective synthesis of globin chains that prevents normal haemoglobin production and function. There are two genes on each chromosome 16 coding for alpha-globins (four in total), and one gene on each chromosome 11 coding for beta-globins (two in total). Phenotype depends on the number of deleted or mutated genes coding for the corresponding globin.

A	Alpha-thalassaemia trait

Alpha-thalassaemia trait is a result of mutations in two out of the four globin genes. This causes an asymptomatic microcytic anaemia as seen in this case. However, because alpha-globin is present in HbA2 in addition to HbA, you would not find an increase of HbA2 (2 × alpha- and 2 × delta-globins) detected in haemoglobin electrophoresis as seen here. See overall explanation for an overview of thalassaemia.

B	Haemoglobin H disease

Haemoglobin H disease is a result of mutations in three out of the four alpha-globin genes. HbH refers to a very abnormal haemoglobin consisting of four beta-globins. As this is an ineffective haemoglobin, it would cause a more significant and symptomatic anaemia with signs of this on examination. Furthermore, haemoglobin electrophoresis would identify HbH as a separate band and the HbA2 percentage would not be raised, as this requires functioning alpha-globins. See overall explanation for an overview of thalassaemia.

D	Beta-thalassaemia major

Beta-thalassaemia major is a result of mutations in both beta-globin genes resulting in no functioning beta-globin and therefore no HbA. Therefore this presents in childhood with severe, transfusion-dependent microcytic anaemia. Beta-thalassaemia major is not usually apparent at birth due to

A 30-year-old male nurse presents with prolonged bleeding after a routine dental extraction. It is two days since the procedure, and the bleeding has been continuous: he has noticed black stools on three separate occasions.

Past medical history includes a postoperative haemorrhage following tonsillectomy, that required a blood transfusion. He has one brother who is well, and believes a cousin may have died of bleeding during childbirth.

On examination, he is pale but well perfused. Rectal examination confirms melaena.

Investigations:

Hb	8.1 g/dl
PT	28 s (11.5–15.5)
Activated PTT	33 s (30–40)
Fibrinogen	2.3 g/l (1.8–5.4)
Mixing studies with	normal plasma shows complete correction

1:14
tps://mypastest.pastest.com

Fibrinogen	2.3 g/l (1.8–5.4)
Mixing studies with 50;50 test	normal plasma shows complete correction of PT

What diagnosis should be considered at this stage pending further investigation?

A	Inherited Factor IX deficiency
B	Self-dosing with warfarin
C	Acquired Factor IX deficiency
D	Inherited Factor VII deficiency
E	Acquired Factor VII deficiency

1:16
:tps://mypastest.pastest.com

perfused. Rectal examination confirms melaena.

Investigations:

Hb	8.1 g/dl
PT	28 s (11.5–15.5)
Activated PTT	33 s (30–40)
Fibrinogen	2.3 g/l (1.8–5.4)
Mixing studies with 50;50 test	normal plasma shows complete correction of PT

What diagnosis should be considered at this stage pending further investigation?

Your answer was incorrect

A Inherited Factor IX deficiency

B Self-dosing with warfarin

D Inherited Factor VII deficiency

Factor VII is the only factor unique to the prothrombin time (PT), and deficiency of Factor VII therefore gives a prolonged PT and normal APTT. Deficiencies of II, V and X will prolong both activated partial thromboplastin time (APTT) and PT. Deficiencies of XII, XI, IX and VIII will prolong APTT alone. When an abnormality is detected in the PT/APTT, the studies are repeated with a 50:50 mix of test and normal plasma: straightforward factor deficiencies will correct with mixing, but inhibitors (most commonly lupus anticoagulant) do not correct.

A Inherited Factor IX deficiency

Factor IX deficiency results in prolongation of APTT, and would correct with normal plasma mixing.

B Self-dosing with warfarin

Given that other family members have

A 77-year-old man presents to the clinic with extreme tiredness. He also complains of petechiae, bruising and has had a couple of nose bleeds over the past few months.

On examination, you confirm bruising and petechiae; he also looks generally pale and there is splenomegaly on abdominal examination.

Investigations:

Hb	8.9 g/dl
MCV	104 fl
WCC	3.8×10^9/l
PLT	112×10^9/l
Na^+	140 mmol/l
K^+	5.0 mmol/l
Creatinine	140 μmol/l

Which of the following is the best way to confirm the diagnosis?

A Erythropoietin levels

WCC	3.8×10^9/l
PLT	112×10^9/l
Na^+	140 mmol/l
K^+	5.0 mmol/l
Creatinine	140 μmol/l

Which of the following is the best way to confirm the diagnosis?

A Erythropoietin levels

B B_{12} levels

C Bone marrow biopsy

D Bone marrow aspiration

E Ferritin levels

21032

Submit

This man potentially has myelodysplasia or myelofibrosis, and a bone marrow biopsy is therefore the most logical next step. Typical bone marrow biopsy in myelofibrosis reveals non-uniform areas of reticular fibrosis interspersed with some areas of increased cellularity. In myelodysplasia there is an increase in the megakaryocyte component of bone marrow, and cells may be abnormally small or large, containing cytogenetic abnormalities.

A	Erythropoietin levels

EPO levels are most useful in differentiating primary and secondary polycythaemia (due to chronic tissue hypoxia).

B	B_{12} levels

B_{12} levels may be reduced, although B_{12} deficiency doesn't fit with the splenomegaly seen here.

A Erythropoietin levels

EPO levels are most useful in differentiating primary and secondary polycythaemia (due to chronic tissue hypoxia).

B B_{12} levels

B_{12} levels may be reduced, although B_{12} deficiency doesn't fit with the splenomegaly seen here.

D Bone marrow aspiration

Trephine is preferred to demonstrate the abnormal bone marrow architecture seen in patients with myelodysplastic syndrome.

E Ferritin levels

Iron deficiency anaemia is associated with microcytic anaemia rather than the macrocytosis and splenomegaly seen here.

A 20-year-old woman, who is taking the oral contraceptive pill, presents with pleuritic chest pain of sudden onset. She has recently flown back to this country from Australia. She has no family history of venous thromboembolism. She is a full-time mother of two children, aged 3 and 6. Her only medication is the oral contraceptive pill.

Examination shows her to be breathless, cyanosed and in distress. She is tachycardic, with a blood pressure of 110/70 mmHg and a loud pulmonary component of the second heart sound. There is a pleural rub, with a respiratory rate of 35 breaths/min. Chest X-ray is clear.

Results below:

$p(O_2)$	7.9 kPa (11.3–12.6)
$p(CO_2)$	3.5 kPa (4.7–6.0)
Factor V Leiden (FVL) mutation	Heterozygous

She responds promptly to high-flow oxygen and low-molecular-weight (LMW) heparin. A ventilation/perfusion scan shows multiple mismatched perfusion defects.

She agrees to switch to a different mode of contraception.

Which of the following options would be the best option for management?

A	Lifelong warfarin
B	Warfarin for at least 3 months
C	LMW heparin for 3 months
D	Warfarin for 6 months and LMW heparin for future long flights
E	Warfarin for 6 months and low-dose aspirin for future long flights

A 20-year-old woman, who is taking the oral contraceptive pill, presents with pleuritic chest pain of sudden onset. She has recently flown back to this country from Australia. She has no family history of venous thromboembolism. She is a full-time mother of two children, aged 3 and 6. Her only medication is the oral contraceptive pill.

Examination shows her to be breathless, cyanosed and in distress. She is tachycardic, with a blood pressure of 110/70 mmHg and a loud pulmonary component of the second heart sound. There is a pleural rub, with a respiratory rate of 35 breaths/min. Chest X-ray is clear.

Results below:

$p(O_2)$	7.9 kPa (11.3–12.6)
$p(CO_2)$	3.5 kPa (4.7–6.0)
Factor V Leiden (FVL) mutation	Heterozygous

B Warfarin for at least 3 months

FVL is a common polymorphism, found in 2–15% of the population, and carries a 3- to 8-fold relative risk for venous thromboembolism (VTE). The mutation is synergistic with use of the oral contraceptive pill, increasing the rate of VTE in this patient group by a factor of 30, but it has been estimated that 2 million women would need to be screened to prevent one death from VTE, so routine screening is not recommended. Most studies do not show an increased risk of VTE in FVL, compared with negative controls, when patients are not taking the combined oral contraceptive pill, so there is no indication for prolonged or intensified anticoagulation, although she should review her contraceptive arrangements. As such, 3 months of warfarin therapy would be sufficient for this provoked VTE if an alternative method of contraception is sought. If the patient elects to continue the oral contraceptive pill, expert opinion is that extending the duration of

that extending the duration of anticoagulation to 6 months continues to reduce the risk of recurrent VTE.

Cascade screening of adult family members is appropriate, and members who carry FVL mutation can receive lifestyle counselling regarding contraception and long journeys. Proteins C and S, antithrombin III and activated protein C resistance are all affected by recent thrombosis and/or anticoagulation, and testing for these should be delayed until a month after all anticoagulation has ceased.

A	Lifelong warfarin

Lifelong anticoagulation would be considered for recurrent VTE despite discontinuation of the oral contraceptive pill.

C	LMW heparin for 3 months

Although the duration of 3 months is correct for this provoked VTE, providing oral contraception is

stopped, the mode of anticoagulation is not best practice. LMW heparin would only be continued past the initial treatment phase in pregnancy, malignancy or allergies to all oral anticoagulants.

D	Warfarin for 6 months and LMW heparin for future long flights

There is no evidence that this patient will be at an increased risk of VTE once the oral contraceptive pill is discontinued. As such, prophylaxis with LMW heparin is not warranted.

E	Warfarin for 6 months and low-dose aspirin for future long flights

There is no evidence that use of low-dose aspirin is effective in preventing episodes of VTE.

71440

Rate this question:

A 72-year-old man presents with headaches, lethargy and severe intractable back pain. He also recently suffered left lower lobe pneumonia.

Over the past few days, his problems have significantly worsened and he is now unable to keep any food or fluids down and is vomiting several times during the day.

On examination, his BP is 162/95 mmHg and he looks pale. His pulse is 90/min and regular and there are bilateral crackles on auscultation of the chest.

Investigations:

Hb	10.1 g/dl
WCC	4.9×10^9/l
PLT	147×10^9/l
Na^+	142 mmol/l
K^+	6.0 mmol/l
Creatinine	890 μmol/l
Viscosity	2.78 mPa/s (1.50–1.72)

Total protein	110 g/l
Albumin	30 g/l
P-ANCA	+
Urine	Protein++
USS renal tract	Bilateral normal-sized kidneys, no obstruction

Which of the following is the most likely diagnosis?

A	Multiple myeloma
B	Granulomatosis with polyangiitis
C	Polyarteritis nodosa
D	Anti-glomerular basement membrane (GBM) disease
E	Waldenström's macrogammaglobulinaemia

headaches, lethargy and severe intractable back pain. He also recently suffered left lower lobe pneumonia.

Over the past few days, his problems have significantly worsened and he is now unable to keep any food or fluids down and is vomiting several times during the day.

On examination, his BP is 162/95 mmHg and he looks pale. His pulse is 90/min and regular and there are bilateral crackles on auscultation of the chest.

Investigations:

Hb	10.1 g/dl
WCC	4.9×10^9/l
PLT	147×10^9/l
Na^+	142 mmol/l
K^+	6.0 mmol/l
Creatinine	890 μmol/l
Viscosity	2.78 mPa/s (1.50–1.72)
Total	110 g/l

A Multiple myeloma

Whilst we are not given a serum calcium result here, the clinical history of severe backpain, headaches, lethargy and an episode of sepsis is typical of myeloma. The clinical findings of decreased serum albumin, marked elevation in total protein and proteinuria further support the diagnosis. Serum electrophoresis is likely to reveal a paraprotein band. Slightly confusingly, p-ANCA positivity is associated with both multiple myeloma and vasculitis. A period of dehydration associated with the pneumonia may well have been enough to precipitate acute on chronic kidney disease here.

B Granulomatosis with polyangiitis

Granulomatosis with polyangiitis is associated with positive c-ANCA. P-ANCA positivity is associated with multiple myeloma.

unexpected in the absence of evidence of haematuria.

D	Anti-glomerular basement membrane (GBM) disease

Anti-GBM disease is associated with pulmonary haemorrhage and glomerulonephritis, rather than the picture here of acute on chronic kidney disease with proteinuria.

E	Waldenström's macrogammaglobulinaemia

Waldenström's is associated with an IgM paraprotein band as well as features of hyperviscosity syndrome and cryoglobulinaemia. Although this patient has headaches there are no other features to suggest Waldenstrom's such as ischaemic symptoms due to hyperviscosity or cryoglobulinaemia.

21435

Rate this question:

A 40-year-old man is admitted to a Surgical Day Ward with a mild haematemesis and is awaiting endoscopy when he suffers a massive haematemesis and loses consciousness.

On examination, he is cool to the touch, with a tachypnoeic pulse of 140 beats per minute (bpm) and blood pressure 60/30 mmHg. He has already had blood taken for group-and-save that day.

Investigations:

Hb	10.5 g/dl
WBC	10×10^9/l
PLT	520×10^9/l

What is the most suitable fluid to give in the first instance?

A	Crystalloid such as normal saline
B	Group O rhesus-negative

Investigations:

Hb	10.5 g/dl
WBC	10×10^9/l
PLT	520×10^9/l

What is the most suitable fluid to give in the first instance?

A	Crystalloid such as normal saline
B	Group O rhesus-negative packed red cells
C	Group-specific packed red cells
D	Fully cross-matched packed red cells
E	Immediate spin cross-matched packed red cells

A Crystalloid such as normal saline

The priority in this situation is maintenance of perfusion – the patient will die of shock before they die of anaemia – and crystalloid is likely to be readily available.

B Group O rhesus-negative packed red cells

Small stocks of group O rhesus-negative blood are kept at theatres, accident and emergency and obstetrical departments, but are only required when the patient's blood group is unknown.

C Group-specific packed red cells

Blood grouping takes 10 min, so group-specific blood can usually be issued early on in an ongoing massive haemorrhage.

A 35-year-old man is referred to the clinic by his general practitioner. He gives a 12-month history of intermittent night sweats, weight loss, itching and chronic cough. There is no significant reported GI disturbance.

Most recently, he has noticed increasing shortness of breath on climbing the stairs, and has been suffering from an urticarial rash.

Investigations:

Eosinophils	3.0×10^9/l (0.04–0.4) or greater on 3 occasions in the last year
Creatinine	128 μmol/l
ANCA	-
CXR	Interstitial infiltrates and small bilateral pleural effusions
Echocardiogram	Suggestive of restrictive cardiomyopathy

CXR	Interstitial infiltrates and small bilateral pleural effusions
Echocardiogram	Suggestive of restrictive cardiomyopathy
IgE	Raised

Which of the following is the most likely diagnosis in this case?

A	Churg-Strauss syndrome
B	Hyper-eosinophilic syndrome
C	Acute eosinophilic pneumonia
D	Chronic pulmonary eosinophilia
E	Chronic parasitic infection

clinic by his general practitioner. He gives a 12-month history of intermittent night sweats, weight loss, itching and chronic cough. There is no significant reported GI disturbance.

Most recently, he has noticed increasing shortness of breath on climbing the stairs, and has been suffering from an urticarial rash.

Investigations:

Eosinophils	3.0×10^9/l (0.04–0.4) or greater on 3 occasions in the last year
Creatinine	128 μmol/l
ANCA	-
CXR	Interstitial infiltrates and small bilateral pleural effusions
Echocardiogram	Suggestive of restrictive cardiomyopathy
IgE	Raised

B Hyper-eosinophilic syndrome

This is a myeloproliferative disorder of unknown cause and is rare, occurring most commonly in men in the 30–40-year-old age group. It is associated with a persistent and markedly raised peripheral blood eosinophil count. Lung involvement may occur, as may cardiovascular involvement with fibrosis and restrictive cardiomyopathy, which may lead to mural thrombus formation and considerable morbidity and mortality. There may also be associated angioedema or urticaria. Treatment is with high-dose corticosteroids (e.g. prednisolone 50 mg, which leads to a response in around 50% of cases). Steroid-sparing agents such as cyclophosphamide or azathioprine may also be of some value. In those patients who carry the FIP1L1/PDGFRA mutation, imatinib is the drug of choice.

A Churg-Strauss syndrome

30–40% of patients with Churg–Strauss are positive for pANCA, and they have symptoms of asthma rather than merely the chronic cough seen here. Other features include mononeuritis multiplex, GI bleeds and glomerulonephritis, which aren't seen here.

C	Acute eosinophilic pneumonia

Acute eosinophilic pneumonia has a much more rapid onset of symptoms, with significant evidence of respiratory failure within 7 days to 1 month from when features first appear.

D	Chronic pulmonary eosinophilia

The extra-pulmonary features seen here are inconsistent versus a diagnosis of chronic pulmonary eosinophilia. Hence this is much less likely to be the underlying diagnosis.

E	Chronic parasitic infection

A 65-year-old woman, known to have stable rheumatoid arthritis for 20 years, has been re-referred to the Rheumatology Clinic with symptoms of chronic foul-smelling diarrhoea. She says she has lost 10 kg in weight in last 6 months. Her general appetite is quite poor as well. She finds herself quite lethargic and has noticed peripheral oedema early in the mornings. According to her, her joints have not troubled her for a long time. She is currently on methotrexate and folic acid.

On examination, she has waxy skin, with plaques clustered in the axillary folds, and multiple bruises are seen. No lymph nodes are palpable. Joint examination showed no evidence of synovitis. Her pulse rate is 80 bpm, blood pressure (BP) 140/90 mmHg and respiratory rate (RR) 16 breaths/min. Heart sounds are normal, and she has good air entry bilaterally, with no added sounds. Abdominal examination reveals hepatosplenomegaly. There is no ascites, and no other masses are felt.

hepatosplenomegaly. There is no ascites, and no other masses are felt. Central nervous system examination shows evidence of peripheral neuropathy.

Investigations:

Sodium (Na^+)	143 mmol/l
Potassium (K^+)	4.5 mmol/l
Urea	7.8 mmol/l
Creatinine (Cr)	120 μmol/l
Liver function tests	Normal
Thyroid function tests	Normal
C-reactive protein (CRP)	20 mg/l
Erythrocyte sedimentation rate (ESR)	9 mm/first hour
24-h urinary analysis	Shows 5 g of proteinuria

Chest X-ray	Shows an enlarged cardiac silhouette
Electrocardiogram (ECG)	Shows low-voltage QRS complexes

Which one of the following will be of most diagnostic value?

A	Bone marrow aspirate and biopsy
B	Serial sputum samples for acid-fast bacilli and tuberculosis (TB) culture
C	Rectal biopsy
D	Nerve conduction studies
E	Faecal elastase

C Rectal biopsy

This patient has many of the hallmarks of systemic amyloidosis. An abdominal fat biopsy or a rectal biopsy is the best way to make the diagnosis. A positive Congo red histological stain helps to establish diagnosis. The AA type of amyloid is seen secondary to a host of chronic inflammatory conditions, including long-standing rheumatoid arthritis, tuberculosis, bronchiectasis, familial Mediterranean fever, and leprosy. Amyloidosis should be suspected in any patient with an underlying chronic inflammatory disease who develops hepatosplenomegaly, malabsorption, cardiac disease or proteinuria. Cardiac disease usually consists of congestive heart failure with low QRS-complex voltage and exquisite sensitivity to digitalis.

Echocardiography shows a characteristic speckled appearance and may also be helpful in contributing to the diagnostic process. Waxy

to the diagnostic process. Waxy papules in the axillary folds may signal the deposition of amyloid in the skin; purpura after minor skin trauma is not uncommon. In addition to amyloid-induced synovitis, peripheral neuropathy and carpal tunnel syndrome may be seen.

A	Bone marrow aspirate and biopsy

Bone marrow aspirate may reveal amyloid deposits, but it is significantly more invasive, when compared to a rectal biopsy, and is therefore not the preferred option.

B	Serial sputum samples for acid-fast bacilli and tuberculosis (TB) culture

Given respiratory examination is normal and there are no symptoms of cough, TB is unlikely as the cause of her current symptoms.

A 40-year-old man presents with breathlessness of 3 months' duration. He is now moderately breathless on climbing a single flight of stairs. He had been working as a gym instructor before the onset of symptoms.

He first noticed his symptoms after a heavy bout of 'indigestion' that occurred on the day of a close relative's funeral. He was treated with chemotherapy and mediastinal radiotherapy for Hodgkin's disease 10 years previously and has been in complete remission ever since, although he says his chest X-ray remains abnormal.

His chest X-ray shows a widened mediastinum and borderline cardiomegaly, and an electrocardiogram (ECG) shows poor R-wave progression in the anterior chest leads with Q waves in V2, 3 and 4. On examination he has a few crackles throughout the chest, most prominent at the bases and an audible third heart sound. He has prominent neck veins.

R-wave progression in the anterior chest leads with Q waves in V2, 3 and 4. On examination he has a few crackles throughout the chest, most prominent at the bases and an audible third heart sound. He has prominent neck veins.

What is the most likely diagnosis?

A	Cardiac amyloid infiltration
B	Cardiac failure secondary to previous anthracycline administration
C	Heart failure secondary to anterior myocardial infarction
D	Pericardial effusion from progressive Hodgkin's disease
E	Progressive pulmonary fibrosis from bleomycin

C Heart failure secondary to anterior myocardial infarction

This man has developed heart failure which was associated with chest pain, the 'heavy bout of indigestion', with a characteristic ECG diagnostic of an infarct more than a few days previously. He is at high risk of coronary artery disease given his previous radiotherapy to the mediastinum.

B Cardiac failure secondary to previous anthracycline administration

Anthracycline cardiomyopathy would not explain the sudden change in symptoms, but it can occur late after chemotherapy – classically with doses exceeding 450 mg/m^2.

A Cardiac amyloid infiltration

Amyloid can occur with myeloma but is not seen with Hodgkin's disease.

chemotherapy – classically with doses exceeding 450 mg/m^2.

A	Cardiac amyloid infiltration

Amyloid can occur with myeloma but is not seen with Hodgkin's disease.

D	Pericardial effusion from progressive Hodgkin's disease

Progressive Hodgkin's disease is unlikely but not impossible at 10 years – persistent masses are common after treatment in Hodgkin's patients.

E	Progressive pulmonary fibrosis from bleomycin

Pulmonary fibrosis secondary to bleomycin would not explain the cardiac changes or the sudden change in symptoms.

71093

Rate this question:

A 56-year-old woman has been referred to clinic. She has had two episodes of shingles in the past 2 months and her GP had noticed persisting lymphadenopathy. The patient currently feels well and there is no past history of note.

Examination reveals some petechiae on her back, cervical lymphadenopathy and mild splenomegaly.

Investigations:

Hb	8.9 g/dl
WBC	48 x 10^9/l (lymphocytes 40 x 10^9/l)
PLT	116 x 10^9/l
Blood film	Smear cells

What is the most likely diagnosis?

A	Hairy cell leukaemia
B	Acute lymphoblastic

Hb	6.5 g/dl
WBC	48 x 10^9/l (lymphocytes 40 x 10^9/l)
PLT	116 x 10^9/l
Blood film	Smear cells

What is the most likely diagnosis?

A	Hairy cell leukaemia
B	Acute lymphoblastic leukaemia
C	Splenic lymphoma
D	Non-Hodgkin's lymphoma
E	Chronic lymphocytic leukaemia

Submit

months and her GP had noticed persisting lymphadenopathy. The patient currently feels well and there is no past history of note.

Examination reveals some petechiae on her back, cervical lymphadenopathy and mild splenomegaly.

Investigations:

Hb	8.9 g/dl
WBC	48 x 10^9/l (lymphocytes 40 x 10^9/l)
PLT	116 x 10^9/l
Blood film	Smear cells

What is the most likely diagnosis?

Your answer was correct

A	Hairy cell leukaemia
B	Acute lymphoblastic leukaemia

E Chronic lymphocytic leukaemia

CLL is the most common adult leukaemia in the Western world. The diagnosis can be discovered incidentally, or patients can have symptoms of anaemia, recurrent bleeding and recurrent infections. Examination can reveal lymphadenopathy with hepatosplenomegaly. A full blood count will show a raised WBC with a lymphocytosis. The blood film will show smudge cells, as these are more friable. Immunophenotyping will confirm the diagnosis, with CD19 and CD5 white cell markers likely to be present.

A Hairy cell leukaemia

Hairy cell leukaemia is usually associated with a low white blood cell count rather than the mature lymphocytosis seen here.

B Acute lymphoblastic leukaemia

ALL is unlikely to be the diagnosis given that blast cells have not been found to be present on the blood film.

C Splenic lymphoma

Primary splenic lymphoma is associated with enlargement of the spleen as is seen here, but is not associated with the marked elevation in white blood cell count.

D Non-Hodgkin's lymphoma

Non-Hodgkin's lymphoma is associated with peripheral lymphadenopathy and impaired immune function, although the marked elevation in peripheral blood lymphocyte count is not seen.

7080

Rate this question:

A 56-year-old woman presents with headaches and malaise. She is hypertensive and has a past medical history of deep venous thrombosis (DVT) following a long-haul trip on an airliner. She is a non-smoker.

The examination is unremarkable apart from the fact she is obese, with a BMI of 31. Blood gases were normal.

Investigations:

Urate	0.53 mmol/l (0.19–0.36)
Hb	19.0 g/dl
WCC	15.0 x 10^9/l
PLT	450 x 10^9/l
Erythropoietin	1 mU/ml (0–19)

What is the most likely diagnosis?

A	Polycythaemia rubra vera
B	Chronic myelocytic leukaemia

Urate	0.53 mmol/l (0.19–0.36)
Hb	19.0 g/dl
WCC	15.0 x 10^9/l
PLT	450 x 10^9/l
Erythropoietin	1 mU/ml (0–19)

What is the most likely diagnosis?

A Polycythaemia rubra vera

B Chronic myelocytic leukaemia

C Essential thrombocythaemia

D Obstructive sleep apnoea

E Renal cell carcinoma

9844

Submit

of 31. Blood gases were normal.

Investigations:

Urate	0.53 mmol/l (0.19–0.36)
Hb	19.0 g/dl
WCC	15.0 x 10^9/l
PLT	450 x 10^9/l
Erythropoietin	1 mU/ml (0–19)

What is the most likely diagnosis?

Your answer was correct

A Polycythaemia rubra vera

B Chronic myelocytic leukaemia

C Essential thrombocythaemia

D Obstructive sleep apnoea

A Polycythaemia rubra vera

The results are the picture of polycythaemia due to increase in red blood cells (absolute polycythaemia) or decrease in the plasma volume (relative polycythaemia).

Polycythaemia rubra vera (PRV) is a malignant disorder of stem cells (i.e. they display abnormal responses to growth factors) characterised by over-proliferation in the bone marrow of erythroid, myeloid and megakaryocytic elements. It has an incidence of 5–17/million population/year. Patients may present with venous thromboses at unusual sites (e.g. portal vein, hepatic vein). Neurological manifestations are also common (transitory ischemic attack (TIAs), cardiovascular accident (CVAs), fluctuating dementia), as is joint pain and gout.

Bone marrow examination shows hypercellularity with clustered mature megakaryocytes and the formation of erythroid colonies without exogenous EPO

B	Chronic myelocytic leukaemia

CML is a myeloproliferative disorder with predominant elevation in white cells. The marked elevation in haemoglobin makes this less likely as the underlying diagnosis. In CML a greater increase in cells from the myelocytic line, including for example basophils, would be expected.

C	Essential thrombocythaemia

In essential thrombocythaemia, it is usually only the platelets that are elevated.

D	Obstructive sleep apnoea

Secondary polycythaemia due to chronic hypoxia causes erythropoietin release in chronic obstructive pulmonary disease (COPD), Eisenmenger syndrome and OSA.

E	Renal cell carcinoma

A 32-year-old woman presents with dizziness. Symptoms have been coming on for the last few months, and she now needs help with standing. She is treated with bendroflumethiazide for recently diagnosed hypertension, smokes 10 cigarettes daily and drinks around 30 units per week of alcohol. She is one of four children, a brother having died in the past of renal cancer.

On direct questioning, she admits to cough productive of phlegm, present most mornings for the last few years, but has normal exercise tolerance.

On examination, she is noticeably plethoric. There is an audible expiratory wheeze throughout the chest. Oxygen saturations are normal. There is nystagmus present looking left or right. Fundoscopy reveals dilated retinal veins. She has a broad-based gait, and is unsteady with eyes open or closed.

Investigations:

Hb	20.3 g/dl
WCC	7.1 x 10^9/l

Hb	20.3 g/dl
WCC	7.1 x 10^9/l
Platelets	169 x 10^9/l
Haematocrit	0.61
Red cell mass	2312 ml (1312–2187)
Plasma volume	2392 ml (2362–3938)
Erythroid culture in the absence of erythropoeitin	No endogenous erythroid colony formation

Which of the following is the most likely diagnosis?

A Primary polycythaemia rubra vera

B Von Hippel–Lindau syndrome

C Renal cell carcinoma with endogenous erythropoietin production

Erythroid culture in the absence of erythropoeitin	No endogenous erythroid colony formation

Which of the following is the most likely diagnosis?

A	Primary polycythaemia rubra vera
B	Von Hippel–Lindau syndrome
C	Renal cell carcinoma with endogenous erythropoietin production
D	Gaisbock syndrome
E	Alcohol abuse

She is one of four children, a brother having died in the past of renal cancer.

On direct questioning, she admits to cough productive of phlegm, present most mornings for the last few years, but has normal exercise tolerance.

On examination, she is noticeably plethoric. There is an audible expiratory wheeze throughout the chest. Oxygen saturations are normal. There is nystagmus present looking left or right. Fundoscopy reveals dilated retinal veins. She has a broad-based gait, and is unsteady with eyes open or closed.

Investigations:

Hb	20.3 g/dl
WCC	7.1×10^9/l
Platelets	169×10^9/l
Haematocrit	0.61
Red cell mass	2312 ml (1312–2187)
Plasma volume	2392 ml (2362–

B Von Hippel–Lindau syndrome

This patient has a high haematocrit; with an increased red cell mass and a low–normal plasma volume, confirming true polycythaemia. Von Hippel–Lindau (VHL) syndrome is an autosomal dominant condition that leads to retinal and central nervous system tumours, as well as phaeochromocytomas. Signs of VHL syndrome include balance disturbance, hypertension, headaches and dizziness. Death is often due to renal cell carcinoma.

Criteria are the following:

- More than one hemangioblastoma in the CNS (brain, spinal cord) or eye.
- A single hemangioblastoma in the CNS or retina, plus a visceral manifestation (multiple renal, pancreatic or hepatic cysts; pheochromocytoma; renal cancer).

- Positive family history plus any one of the above clinical manifestations.
- Elucidation of a deleterious mutation in the *VHL* gene.

Management depends on the site of individual tumours, but close ophthalmic, renal and radiographical follow-up is recommended for all patients. There is no ultimate cure for VHL. A proportion of cerebellar haemangiomas secrete erythropoietin-like substances, leading to a secondary polycythaemia.

Erythroid colony studies suggest that her red cells do not show autonomous growth; autonomous growth of erythroid colonies is taken as a sign of primary polycythaemia, where erythropoiesis has escaped the control of erythropoietin; erythroid colony studies are thought to have high specificity for detecting primary versus secondary polycythaemia, but the technique is poorly standardized so remains an experimental tool.

This is caused by bone marrow overproduction of red blood cells (and sometimes white cells and platelets). Patients maybe asymptomatic, presenting with blood clots, itching and skin changes.

C	Renal cell carcinoma with endogenous erythropoietin production

Rare cases of renal cell carcinoma proliferate with endogenous erythropoietin production. There was no endogenous erythroid colony found on testing.

D	Gaisbock syndrome

This is a form of pseudo-polycythaemia, usually found in obese men with hypertension causing a reduction in plasma volume.

E	Alcohol abuse

It is not uncommon to see borderline

erythropoietin production. There was no endogenous erythroid colony found on testing.

D	Gaisbock syndrome

This is a form of pseudo-polycythaemia, usually found in obese men with hypertension causing a reduction in plasma volume.

E	Alcohol abuse

It is not uncommon to see borderline plasma volumes in patients with excessive alcohol intake (or on diuretics).

7538

Rate this question:

An 18-year-old girl presents with sudden-onset dysarthria and right-sided weakness. You see her 12 h after the event and her symptoms have now resolved. She takes the oral contraceptive pill. She is in full-time education and smokes 5–10 cigarettes daily. Alcohol intake is minimal. She lives with her parents. Family history is unremarkable other than a possible deep vein thrombosis in an aunt.

Examination is unremarkable, other than a lacy rash over her thighs and a grade II ejection systolic murmur. Computed tomography of the brain performed 2 h after admission is unremarkable.

Investigations:

Hb	12.3 g/dl
WCC	3.5×10^9/l
PLT	135×10^9/l
APTT	45 s (30–40)

What is the most likely identity of the rash?

Hb	12.3 g/dl
WCC	3.5 x 10^9/l
PLT	135 x 10^9/l
APTT	45 s (30–40)

What is the most likely identity of the rash?

A	Erythaema ab igne
B	Erythaema chronicum migrans
C	Livedo reticularis
D	Erythroderma
E	Erythaema multiforme

6378

Submit

education and smokes 5–10 cigarettes daily. Alcohol intake is minimal. She lives with her parents. Family history is unremarkable other than a possible deep vein thrombosis in an aunt.

Examination is unremarkable, other than a lacy rash over her thighs and a grade II ejection systolic murmur. Computed tomography of the brain performed 2 h after admission is unremarkable.

Investigations:

Hb	12.3 g/dl
WCC	3.5 x 10^9/l
PLT	135 x 10^9/l
APTT	45 s (30–40)

What is the most likely identity of the rash?

Your answer was correct

A	Erythaema ab igne

C Livedo reticularis

This is a case of a young woman with anti-phospholipid syndrome, also known as Hughes syndrome. This is diagnosed in patients with characteristic clinical phenomena (venous and arterial thromboembolism, recurrent first trimester miscarriages, livedo reticularis, chorea and Libman–Sacks endocarditis) in whom positive anti-cardiolipin antibodies or a lupus anticoagulant are detected on two separate occasions, separated by at least 6 weeks.

The condition is managed by lifelong anticoagulation with warfarin, at a target international normalised ratio (INR) of 2–3 (higher targets were previously used, but a randomised controlled double-blind trial (Crowther et al, *New England Journal of Medicine*, 2003) did not support any greater therapeutic effect of high intensity anticoagulation. The paradoxical prolongation of the activated partial

prolongation of the activated partial thromboplastin time is due to antibodies to phospholipids, which is critical to the functioning of the assay. However, a normal APTT does not rule out the presence of a lupus anticoagulant; to rule this out you need to assess phospholipid-dependent measures of clotting, such as the dilute Russell viper venom time.

A	Erythaema ab igne

Erythema ab igne is associated with reticulated erythema, hyperpigmentation, skin scaling and telangiectasia over the area which has been subject to local heat.

B	Erythaema chronicum migrans

Erythema chronicum migrans is a rash characteristic of Lyme disease, which extends out from the original tick bite or eschar.

A 70-year-old woman presents with fatigue and confusion that has come on gradually over several weeks. She is a retired secondary school teacher who was still tutoring on a part-time basis until 3 months ago but has recently become reliant on family and neighbours for basic self-care. She has no previous medical history of note and is taking only antacids for occasional dyspepsia.

On examination, she is obese, with a blood pressure of 175/100 mmHg. She is disorientated; tone, power and reflexes are all within normal limits. Plantar responses are downgoing. Fundoscopy shows prominent retinal veins, but is otherwise normal. There are bi-basal crackles at both bases.

Blood tests are shown below:

		Normal values
Haemoglobin (Hb)	9.5 g/dl	
White cell count (WCC)	5.3 × 10^9/l	

Haemoglobin (Hb)	9.5 g/dl	
White cell count (WCC)	5.3 × 10^9/l	
Platelets (PLT)	120 × 10^9/l	
Urea	10.3 mmol/l	2.5–7.5
Bilirubin	21 µmol/l	1–22
Albumin	29 g/l	37–49
Protein	113 g/l	60–76
Erythrocyte sedimentation rate (ESR)	95 mm/first hour	
Calcium	2.3 mmol/l	2.2–2.6

What test is most likely to help establish the cause of confusion?

A Bone scan

Erythrocyte sedimentation rate (ESR)	95 mm/first hour	
Calcium	2.3 mmol/l	2.2–2.6

What test is most likely to help establish the cause of confusion?

A	Bone scan
B	Urine for Bence Jones protein
C	Serum protein electrophoresis
D	Skeletal survey
E	Magnetic resonance imaging (MRI) brain

33294

Submit

C Serum protein electrophoresis

The question asks for the test most likely to confirm the cause of the confusion. Myeloma or Waldenström's macroglobulinaemia leading to clinically significant hyperviscosity are the most likely cause here. Serum immunoglobulins do not confirm the presence of a paraprotein, whereas serum protein electrophoresis will. This is because a number of inflammatory conditions may result in a global increase in immunoglobulins.

If a paraprotein is found, a bone marrow trephine can help make a tissue diagnosis of an associated myeloma [in the case of immunoglobulin G (IgG)/immunoglobulin A (IgA) paraproteins] or lymphoplasmacytoid lymphoma [in the case of immunoglobulin M (IgM) paraprotein] and help to differentiate between Waldenström's macroglobulinaemia and myeloma, but this test will not directly help explain the patient's confusion. Great care should be

confusion. Great care should be exercised before patients with hyperviscosity are transfused, as any further increase in viscosity may precipitate a cerebral event. Treatment is with chemotherapy targeted to the underlying condition and, where transfusion is urgently required, plasmapheresis first.

A Bone scan

Bone scanning is of value in multiple myeloma, but of no utility in Waldenström's macroglobulinaemia due to only very rare reports of skeletal system involvement.

B Urine for Bence Jones protein

Although urine for Bence Jones protein should certainly be performed in all suspected myelomas, it is extremely rare for light chain disease to cause clinically apparent hyperviscosity. This is because viscosity is directly proportional to the size of the molecule causing it:

extremely rare for light chain disease to cause clinically apparent hyperviscosity. This is because viscosity is directly proportional to the size of the molecule causing it; therefore, IgM, which is pentameric, is most likely to cause hyperviscosity, followed by the dimeric IgA, then IgG.

D	Skeletal survey

The skeleton is usually not involved in Waldenström's macroglobulinaemia, meaning that a skeletal survey is not usually considered of value in the workup of the condition.

E	Magnetic resonance imaging (MRI) brain

MRI brain may show periventricular white matter changes, but it is not helpful in differentiating whether these are due to microvascular disease or due to an underlying hyperviscosity syndrome.

A 23-year-old woman presents with a swollen, tender left calf having returned from Australia on a long-haul flight. She takes the oral contraceptive pill, but is a non-smoker and has no other significant risk factors.

On examination, her blood pressure and pulse are normal and her chest is clear. Her left leg is swollen and tender, and the calf is significantly larger than the right. D-dimers are slightly elevated at 420. An initial ultrasound is negative.

Which of the following is the next step?

A	Start low-molecular weight heparin
B	Repeat ultrasound in 7 days
C	Reassure
D	Start warfarin

On examination, her blood pressure and pulse are normal and her chest is clear. Her left leg is swollen and tender, and the calf is significantly larger than the right. D-dimers are slightly elevated at 420. An initial ultrasound is negative.

Which of the following is the next step?

Your answer was correct

A	Start low-molecular weight heparin
B	Repeat ultrasound in 7 days
C	Reassure
D	Start warfarin
E	Start rivaroxaban

Explanation

B Repeat ultrasound in 7 days

In the presence of a definitive investigation result, even though the d-dimer is positive and clinical suspicion of DVT is high, according to SIGN guidelines this patient shouldn't be anticoagulated, but instead should be re-scanned, either with an ultrasound or a venogram 7 days after the initial event. It is of course possible that she has suffered a calf muscle tear leading to the elevated d-dimers and symptom presentation seen here.

A Start low-molecular weight heparin

Given an initial normal ultrasound scan and a slightly elevated D-dimer at only 420, there is no indication to begin low molecular weight heparin. It may indeed cause an increased risk of bleeding with little immediate obvious benefit.

C Reassure

C Reassure

The clinical suspicion for a DVT is high, and therefore the patient should be advised to attend for a repeat scan 7 days later.

D Start warfarin

According to SIGN guidelines, the patient should be re-scanned in 7 days and not anticoagulated. Warfarin is the preferred anticoagulant for patients in whom factor Xa or direct thrombin inhibitors are not available, and for patients with severe renal insufficiency. Warfarin requires multiple visits for INR monitoring and has a higher bleeding risk when compared to direct oral anticoagulants; however, antidotes for warfarin-related bleeding are more readily available. Thus, it may also be preferred in those with a preference or requirement for a readily reversible antidote (e.g. need for frequent interventions) and those for whom therapeutic anticoagulation needs to be monitored (e.g. poor compliance).

interventions) and those for whom therapeutic anticoagulation needs to be monitored (e.g. poor compliance).

E	Start rivaroxaban

According to SIGN guidelines, the patient should be re-scanned in 7 days and not anticoagulated. Factor Xa inhibitors (e.g. rivaroxaban, apixaban, edoxaban) and oral direct thrombin inhibitors (dabigatran) are preferred anticoagulants for most hemodynamically stable, non-pregnant patients who do not have severe renal insufficiency or active cancer. While rivaroxaban and apixaban can be administered as monotherapy, edoxaban and dabigatran are preferably administered following a 5-day course of heparin (ie as dual therapy – low-molecular weight or unfractionated heparin).

34961

Rate this question:

Next Question

A 19-year-old woman is referred from her GP complaining of menorrhagia and easy bruising. Her older sister also has menorrhagia and frequent nose bleeds.

A summary given by her GP of tests already performed shows:

PT	13 s (10–14)
aPTT	50 s (30–45)
PLT	263×10^9/l (150–400)
INR	0.9 (0.0–1.2)
Hb	10.5 g/dl (11.5–16.0)
Ristocetin co-factor (RoCF)	24 IU/dl (50–200)
Group & save blood type	A-positive
Activated protein C resistance ratio	2.4 (>2.1)

What diagnosis would best fit this

Ristocetin co-factor (RoCF)	24 IU/dl (50–200)
Group & save blood type	A-positive
Activated protein C resistance ratio	2.4 (>2.1)

What diagnosis would best fit this clinical picture?

A	Haemophilia A
B	Factor V deficiency
C	Christmas disease
D	Antiphospholipid syndrome
E	Von Willebrand's disease (vWD)

A 19-year-old woman is referred from her GP complaining of menorrhagia and easy bruising. Her older sister also has menorrhagia and frequent nose bleeds.

A summary given by her GP of tests already performed shows:

PT	13 s (10–14)
aPTT	50 s (30–45)
PLT	263 × 10^9/l (150–400)
INR	0.9 (0.0–1.2)
Hb	10.5 g/dl (11.5–16.0)
Ristocetin co-factor (RoCF)	24 IU/dl (50–200)
Group & save blood type	A-positive
Activated protein C resistance ratio	2.4 (>2.1)

E Von Willebrand's disease (vWD)

Von Willebrand's disease is a common, inherited, genetically and clinically heterogeneous haemorrhagic disorder caused by a deficiency or dysfunction of the protein termed von Willebrand factor (vWF). This is a large, multimeric glycoprotein which functions as the carrier protein for factor VIII, by binding to and stabilizing this factor, and it also mediates the adhesion of platelets to sites of vascular injury.

The VWF gene is located near the tip of the short arm of chromosome 12. vWD is divided into three major categories:

(1) partial quantitative deficiency (type I),
(2) qualitative deficiency (type II), and
(3) total deficiency (type III).

Males and females are affected equally although the disease manifestations are more obvious in the female due to

are more obvious in the female due to menstruation and the associated menorrhagia.

The screening test used to diagnose the condition includes prothrombin time (PT), activated partial thromboplastin time (aPTT), factor VIII activity, vWF activity (ristocetin cofactor) and vWF antigen level determination. Ristocetin is an antibiotic that causes vWF to bind to and activate platelets. Platelets rapidly agglutinate in response to ristocetin, but the presence of plasma vWF is necessary for this reaction to occur. The PT is within the reference range, but the aPTT is mildly prolonged in half of these patients. The degree of platelet agglutination is proportional to the concentration of vWF in the plasma. This is called the vWF activity or ristocetin cofactor assay, and is variably reduced in patients with vWD.

A	Haemophilia A

In this X-linked recessive condition, PT

In this X-linked recessive condition, PT is normal and APTT will either be severely prolonged in severe haemophilia A or normal/mildly prolonged in less severe case. It only occurs in males.

B Factor V deficiency

This is a prothrombotic condition resulting from the mutation of factor V. There is a decreased activated protein C ratio with this condition.

C Christmas disease

Also known as haemophilia , this is a genetic mutation of factor IX and would show normal levels of von Willebrand's factor, normal PT and normal or slightly prolonged APTT. There would be very low or absent levels of factor IX. It also is X-linked and occurs in males.

D Antiphospholipid syndrome

C Christmas disease

Also known as haemophilia , this is a genetic mutation of factor IX and would show normal levels of von Willebrand's factor, normal PT and normal or slightly prolonged APTT. There would be very low or absent levels of factor IX. It also is X-linked and occurs in males.

D Antiphospholipid syndrome

This is a prothrombotic condition and is diagnosed by lupus anticoagulant present on two tests more than 12 weeks apart, anticardiolipin antibody presence, and the presence of anti-2-beta-glycoprotein I. APTT maybe prolonged due to positive lupus anticoagulant.

7642

Rate this question:

Next Question

A 32-year-old woman who has suffered a bleed post-caesarean section receives the second unit of a 3-unit blood transfusion and develops sudden onset shortness of breath, fever and cough. There is no history of flank pain. The unit is immediately stopped.

On examination, she looks unwell; her BP is 100/62 mmHg, with a pulse of 95/min. Auscultation of the chest reveals bilateral crackles consistent with pulmonary oedema.

Investigations:

Hb	9.6 g/dl
WCC	3.9×10^9/l
PLT	130×10^9/l
Na^+	139 mmol/l
K^+	4.9 mmol/l
Urea	8.1 mmol/l
Creatinine	110 µmol/l

Which of the following is the most

Na^+	139 mmol/l
K^+	4.9 mmol/l
Urea	8.1 mmol/l
Creatinine	110 µmol/l

Which of the following is the most likely diagnosis?

A ABO incompatability

B Rhesus incompatability

C Transfusion Associated Lung Injury

D Circulatory overload

E Anaphylaxis

20949

Submit

C Transfusion Associated Lung Injury

In all likelihood this is non-cardiogenic pulmonary oedema, as evidenced by the chest signs. The lack of an elevated JVP and the low normal blood pressure count against a diagnosis of fluid overload. This fits best with a diagnosis of TRALI.

Two hypotheses exist as to the cause of TRALI: (1) anti-HLA antibodies are transfused into the patient, leading to neutrophil activation, release of cytokines and pulmonary oedema; and (2) neutrophils ready primed by surgery or infection react with bioactive substances in the transfused blood, leading to similar neutrophil activation. Non-cardiogenic pulmonary oedema can be differentiated from fluid overload by measurement of BNP if there is an element of diagnostic confusion. Diuretics are not beneficial in the management of the condition, and she should be managed with supportive care, including transfer to ITU for consideration of intubation and

ITU for consideration of intubation and ventilation if required. The mortality of TRALI is estimated at 5–13% depending on case series.

A ABO incompatability

ABO incompatibility leads to acute haemolysis with a severe transfusion reaction, associated with mortality of up to 10%. Symptoms are similar to anaphylaxis, although the reaction is not mediated by IgE.

B Rhesus incompatability

Non-ABO incompatibility reactions – for example, those associated with rhesus incompatibility, are less severe than ABO incompatibility, although significant haemolysis is still seen.

D Circulatory overload

Given that this patient is a 32-year-old woman, circulatory overload in

D Circulatory overload

Given that this patient is a 32-year-old woman, circulatory overload in response to a blood transfusion is extremely unlikely. The low blood pressure would also not fit well with circulatory overload.

E Anaphylaxis

Bacterial contamination of units of red cells is thankfully extremely rare but, where it occurs, circulatory collapse with hypotension and rigors is seen early on in the transfusion process.

20949

Rate this question:

A 50-year-old man with myelodysplasia complains of breathlessness on exertion. He was diagnosed with myelodysplasia 3 years ago and since then has been on 2 units of blood every 3 weeks to maintain his haemoglobin above 10 g/dl. He has noticed over the last 3 months increasing exertional breathlessness despite maintaining his haemoglobin above 10.

Examination shows a slim man with a greyish skin colour. Pulse 90 beats per minute (bpm), sinus rhythm. Heart sounds are normal. Jugular venous pressure is not raised. Cardiac apex is palpable at the anterior axillary line. There are bilateral basal crackles on auscultation of the chest, abdominal examination is normal.

Investigations:

Hb	11.3 g/dl
WCC	1.3×10^9/l
PLT	23×10^9/l
Neutrophils	0.3×10^9/l

Glucose	12.4 mmol/l (3.0–6.0)

What is the most appropriate intervention?

A	Increase the transfusion program to maintain haemoglobin above 12 g/dl
B	Commence subcutaneous recombinant erythropoietin to raise the haemoglobin to 12 g/dl
C	Start venesection program to reduce ferritin to less than 1000
D	Commence iron chelation with subcutaneous desferrioxamine
E	Commence hydroxyurea or similar cytotoxic to treat myelodysplasia

D Commence iron chelation with subcutaneous desferrioxamine

This patient has early signs of iron overload secondary to chronic blood transfusion – grey skin, early heart failure and diabetes. There are limited options for intervention, and given the transfusion needs of this patient with iron overload, desferrioxamine is the most appropriate choice. It needs to be given for 8-12 h per day for 5-7 days per week and is thus a major undertaking for the patient. Side effects of therapy are common and include high-frequency deafness and retinopathy.

E Commence hydroxyurea or similar cytotoxic to treat myelodysplasia

Hydroxyurea won't reduce transfusion requirements or iron overload in the short term, and thus intervention with an iron chelator is the preferred choice

haemoglobin above 12 g/dl

This runs the risk of further worsening iron overload and won't improve symptoms of cardiac failure.

B	Commence subcutaneous recombinant erythropoietin to raise the haemoglobin to 12 g/dl

Commencing erythropoietin to reduce the transfusion requirement is an attractive option, but is only likely to work in patients with low transfusion requirements (<1 unit per month) and does not address the underlying problem of iron overload.

C	Start venesection program to reduce ferritin to less than 1000

Although this would impact on iron overload, it would worsen anaemia and defeat the object of regular transfusions.

A 42-year-old man is admitted with headaches and visual disturbance. The patient is known to have Waldenström's macroglobulinaemia. While in the Assessment Unit, he has a nosebleed that is continuing to ooze and is difficult to control.

Fundoscopy shows dilated retinal veins with retinal haemorrhage in the right eye. He has pale conjunctivae and appears breathless.

Observations:

Blood pressure	115/65 mmHg
Heart rate	120 bpm
Temperature	37 °C

The on-call ear, nose and throat (ENT) surgeon is called to pack his nose.

What is the best acute treatment for his hyperviscosity?

A	Cyclophosphamide
B	Plasmapheresis

Blood pressure	115/65 mmHg
Heart rate	120 bpm
Temperature	37 °C

The on-call ear, nose and throat (ENT) surgeon is called to pack his nose.

What is the best acute treatment for his hyperviscosity?

A	Cyclophosphamide
B	Plasmapheresis
C	Haemoperfusion
D	Intravenous (IV) fresh frozen plasma (FFP)
E	IV methylprednisolone

33299

Submit

B Plasmapheresis

The patient is displaying signs and symptoms of hyperviscosity syndrome, most likely secondary to Waldenström's macroglobulinaemia. Patients present with bleeding, visual disturbances and neurological symptoms. Other conditions leading to hyperviscosity can include multiple myeloma, polycythaemia rubra vera and leukaemia. Initial treatment of choice is plasmapheresis, which can rapidly reduce the viscosity and the risk of thromboembolic events.

A Cyclophosphamide

Cyclophosphamide has a role in the primary treatment of Waldenström's macroglobulinaemia, but as part of combination therapy, usually with dexamethasone and rituximab. An acute presentation requires plasmapheresis.

C Haemoperfusion

C Haemoperfusion

Haemoperfusion is usually instigated to remove a toxic metabolite, with activated charcoal and resins both used as materials to pass blood over.

D Intravenous (IV) fresh frozen plasma (FFP)

Both FFP and albumin may be used to replace plasma removed in the plasmapheresis process, but case series suggest a better profile with respect to adverse events where albumin is replaced in place of FFP.

E IV methylprednisolone

Dexamethasone is the standard corticosteroid used in the treatment of Waldenström's macroglobulinaemia, in conjunction with rituximab and cyclophosphamide.

33299

Rate this question:

A 60-year-old Asian man presents to the Pre-clerking Clinic prior to his laparoscopic cholecystectomy for gallstones.

He has a history of hypertension, for which he takes ramipril 10 mg, but no other past medical history of note.

Investigations:

Hb	10.4 g/dl
WCC	4.5×10^9/l
PLT	195×10^9/l
Na^+	139 mmol/l
K^+	4.5 mmol/l
Creatinine	105 μmol/l
MCV	60 fl (80–96)
Ferritin	300 μmol/l (15–300)
Upper GI endoscopy	Normal

Which of the following is the most appropriate investigation to confirm

	300)
Upper GI endoscopy	Normal

Which of the following is the most appropriate investigation to confirm the underlying cause of his anaemia?

A	Colonoscopy
B	Mesenteric angiography
C	Transferrin
D	Haemoglobin electrophoresis
E	Bone marrow aspirate

33319

Submit

D Haemoglobin electrophoresis

This man has asymptomatic microcytic anaemia and he is of Asian ethnic origin. His upper GI endoscopy is normal, as is his ferritin, which reduces the possibility of this being iron deficiency anaemia. The most likely cause is beta-thalassaemia trait, the diagnosis of which is best confirmed with haemoglobin electrophoresis. Patients with thalassaemia trait do not usually require any intervention. Bearing in mind that his ferritin of 300 is within the normal range, his anaemia will not be responsive to iron supplementation. Chelation therapy is only required in patients with thalassaemia major. Blood loss associated with laparoscopic cholescystectomy is likely to be relatively minor, and so blood transfusion would not be required prior to surgery.

A Colonoscopy

This would be the appropriate

This would be the appropriate investigation for iron deficiency anaemia after a normal gastroscopy.

B Mesenteric angiography

This would be the investigation of choice in cases of unexplained blood loss or unidentifiable source (normal gastroscopy and colonoscopy), and in persistent iron deficiency anaemia.

C Transferrin

High transferrin levels are seen in iron deficiency anaemia, with subsequent decrease of the transferrin saturation and increase in TIBC (total iron-binding capacity).

E Bone marrow aspirate

This is performed for the diagnosis of lympho- or myeloproliferative disorders.

33319

Rate this question:

A 30-year-old woman presents to her general practitioner with a 3-day history of cramping abdominal pain and vomiting.

A week previously, she had been absent from her job as a paint factory worker, with flu-like symptoms. She has now developed a rash (see image).

What complication might she be at most risk of developing?

What complication might she be at most risk of developing?

A	Epistaxis
B	Haemarthrosis
C	Pulmonary haemorrhage
D	Visual loss
E	Glomerulonephritis

6340

Submit

E Glomerulonephritis

The rash is that of Henoch–Schönlein purpura (HSP), an immunoglobulin A (IgA)-mediated small-vessel vasculitis characterised by purpura, arthritis, abdominal pain and haematuria. The cause is unknown; IgA-dominant immune complexes are present in smaller venules, capillaries and arterioles, representing a diffuse vasculitis that is secondary to hypersensitivity. HSP affects predominantly children (75% of cases occur between the ages of 2 and 11 years) and males are affected twice as commonly as females. However, adults can rarely be affected. Renal disease is the most common serious sequela (haematuria, proteinuria, nephritis, nephritic syndrome). Possible rarer complications include hepatosplenomegaly, myocardial infarction, pulmonary haemorrhage, pleural effusion, unnecessary abdominal surgery, intussusception, gastrointestinal bleeding, bowel infarction and nervous system vasculitic involvement.

HSP doesn't increase the risk of bleeding or cause a significant increase in blood pressure for the majority of cases, meaning that the risk of epistaxis is low.

B Haemarthrosis

Joint haemorrhage is rarely seen in association with HSP, although polyarthritis is a common feature.

C Pulmonary haemorrhage

Pulmonary haemorrhage is a more usual feature of Goodpasture syndrome and granulomatosis with polyangitis.

D Visual loss

Episcleritis and episodes of central retinal artery occlusion are seen in HSP, although they are very much rarer than other manifestations such as glomerulonephritis and small-joint polyarthritis.

A 65-year-old man is admitted with sudden-onset left upper limb and lower limb weakness. Apart from headaches, he was previously fit and well. He has never smoked and drinks two pints of beer a day.

Examination confirms left-sided motor and sensory deficit. He has an ejection systolic murmur at the right second intercostal space. His lungs sound clear, with good air entry. Abdominal examination reveals a mass in the left upper quadrant that is dull to percussion and moves downwards on inspiration.

Blood pressure is 157/89 mmHg, heart rate 70 bpm and regular, temperature 36.9 °C and oxygen saturation 92%.

Investigations:

Haemoglobin (Hb)	189 g/dl
White cell count (WCC)	12.2×10^9/l
Platelets (PLT)	462×10^9/l
Sodium (Na^+)	144 mmol/l

Platelets (PLT)	402 × 10⁹/l
Sodium (Na^+)	144 mmol/l
Potassium (K^+)	5.0 mmol/l
Urea	7.4 mmol/l
Creatinine	108 µmol/l
Hamatocrit	0.58
Leukocyte alkaline phosphatase (LAP) score	210 (reference 25-180)

What is the most likely diagnosis?

A	Chronic myeloid leukaemia (CML)
B	Primary polycythaemia (PP)
C	Secondary polycythaemia
D	Chuvash polycythaemia
E	Renal cell carcinoma

Blood pressure is 107/55 mmHg, heart rate 70 bpm and regular, temperature 36.9 °C and oxygen saturation 92%.

Investigations:

Haemoglobin (Hb)	189 g/dl
White cell count (WCC)	12.2×10^9/l
Platelets (PLT)	462×10^9/l
Sodium (Na^+)	144 mmol/l
Potassium (K^+)	5.0 mmol/l
Urea	7.4 mmol/l
Creatinine	108 µmol/l
Hamatocrit	0.58
Leukocyte alkaline phosphatase (LAP) score	210 (reference 25-180)

What is the most likely diagnosis?

Your answer was incorrect

A Chronic myeloid leukaemia (CML)

B Primary polycythaemia (PP)

PP is a disorder resulting in an increase in the production of red blood cells (RBCs), WCCs and PLT. Patients can be asymptomatic but can also present with symptoms of headaches, tinnitus, visual disturbance and pruritus. Complications include arterial and venous thromboses, and patients with PP can present with Budd–Chiari syndrome. Other conditions associated with polycythaemia include gout, peptic ulceration and worsening of angina and intermittent claudication. Examination can reveal plethora, cyanosis, splenomegaly and hepatomegaly.

Investigations show increased Hb and haematocrit, with some patients also having increased WCC and PLT counts. Other tests can show elevated LAP scores, elevated vitamin B_{12}, normal/increased plasma volume, increased red cell mass and low erythropoietin levels. Treatment includes venesection, hydroxyurea and allopurinol. There is a risk for

erythropoietin levels. Treatment includes venesection, hydroxyurea and allopurinol. There is a risk for leukaemic transformation.

C	Secondary polycythaemia

There is no evidence of chronic obstructive pulmonary disease (COPD) to suggest chronic hypoxia, and thus secondary polycythaemia. This would be a common explanation in patients with established chronic hypoxia.

A	Chronic myeloid leukaemia (CML)

CML is more likely to be associated with anaemia and increased mature white cells (often an increase in basophils and eosinophils is seen), rather than the predominant increase in Hb featured here.

D	Chuvash polycythaemia

Chuvash polycythaemia is congenital

CML is more likely to be associated with anaemia and increased mature white cells (often an increase in basophils and eosinophils is seen), rather than the predominant increase in Hb featured here.

D	Chuvash polycythaemia

Chuvash polycythaemia is congenital erythrocytosis, which is inherited in an autosomal recessive fashion and is prominent in the autonomous Russian Republic of Chuvashia.

E	Renal cell carcinoma

The absence of a renal mass and the elevated LAP score favours a haematological malignancy, rather than renal cell carcinoma here.

7066

Rate this question:

Next Question

A 64-year-old man presents with a first spontaneous haematoma in his right thigh. Past medical history of note includes rheumatoid arthritis, for which he takes sulphasalazine and low-dose prednisolone.

Investigations:

Hb	11.9 g/dl
WCC	6.1×10^9/l
PLT	201×10^9/l
Na^+	140 mmol/l
K^+	4.4 mmol/l
Creatinine	100 μmol/l
PT	15s (11.5-15.5)
APTT	41s (30-40)
Lupus anti-coagulant	-

Which of the following is the most likely diagnosis?

A Haemophilia A

Creatinine	100 μmol/l
PT	15s (11.5-15.5)
APTT	41s (30-40)
Lupus anti-coagulant	-

Which of the following is the most likely diagnosis?

A	Haemophilia A
B	Haemophilia B
C	Anti-phospholipid antibody syndrome
D	Von Willebrand's disease
E	Acquired haemophilia

21196

Submit

A 64-year-old man presents with a first spontaneous haematoma in his right thigh. Past medical history of note includes rheumatoid arthritis, for which he takes sulphasalazine and low-dose prednisolone.

Investigations:

Hb	11.9 g/dl
WCC	6.1×10^9/l
PLT	201×10^9/l
Na^+	140 mmol/l
K^+	4.4 mmol/l
Creatinine	100 μmol/l
PT	15s (11.5-15.5)
APTT	41s (30-40)
Lupus anti-coagulant	-

Which of the following is the most likely diagnosis?

Your answer was correct

E Acquired haemophilia

Acquired haemophilia is associated with anti-factor VIII IgG antibodies and is idiopathic in the majority of cases. In others there appears to be an association with other autoimmune diseases such as rheumatoid arthritis or inflammatory bowel disease, or with drugs such as phenytoin. Where there are low levels of the anti-factor VIII antibodies, factor VIII replacement may be all that is required. Where bleeding is a serious problem then immunosuppression with corticosteroids ± steroid-sparing agents such as ciclosporin may be required. Use of recombinant factor VII in patients with severe acquired haemophilia is a further potential option.

A Haemophilia A

APTT is prolonged in keeping with factor VIII deficiency, although haemophilia A would not present *de novo* at the age of 64.

B Haemophilia B

Haemophilia B related to factor IX deficiency is associated with bleeding tendency, although like haemophilia A, it doesn't present for the first time at age 64.

C Anti-phospholipid antibody syndrome

Anti-phospholipid antibody syndrome is associated with prolongation of the APTT, although it is associated with thrombosis rather than bleeding.

D Von Willebrand's disease

In VWD the APTT is mildly prolonged in 50% of cases. Presentation at an earlier age than 64 would almost certainly be expected, however; hence the scenario here is much more consistent with acquired haemophilia.

21196

Rate this question:

An 18-year-old Caucasian with a 4-month history of non-specific chest pain is seen in your Outpatient Clinic. She had been having intermittent twinges that initially settled with mild analgesics, but they have become more frequent and painful of late. She is most aware of them just underneath her sternum and there is no radiation. Movement does not exacerbate the pain. However, the more severe pains make her feel dizzy and she has almost passed out on three occasions. There is no history of night sweats, weight loss or fever. She is not short of breath on exertion, but admits that recently she has been too tired to play sport. She does not smoke or take illicit drugs and has recently gone off alcohol. She had asthma as a child but rarely used her salbutamol inhaler. She is on the oral contraceptive pill and has a steady boyfriend.

On examination, she looks tired and slightly anxious. She is afebrile. Her pulse is 64 bpm and regular, BP 105/62 mmHg, respirations at rest 16 breaths/min and saturations 97% on

room air. She has a small lymph node in the left submandibular region. Heart sounds are normal, her chest is clear and her abdomen is soft with no enlarged organs. ECG shows sinus rhythm. Chest X-ray PA reveals an enlarged mediastinum, with clear lung fields; an anterior mediastinal mass can be seen on the lateral chest X-ray.

Investigations:

Hb	8.9 g/dl
WCC	6.4×10^9/l
PLT	165×10^9/l
Na^+	139 mmol/l
K^+	4.2 mmol/l
Creatinine	68 μmol/l
Urea	4.1 mmol/l
Glucose	4.9 mmol/l
LDH	1652 U/l
MCV	79.3 fl

CT of the thorax, abdomen and pelvis reveals: a large anterior mediastinal mass with irregular borders, 10.1 cm × 9.3 cm × 5.6 cm, surrounding the left pulmonary artery and ligamentum arteriosum; no infiltration of surrounding tissues; a large group of lymph nodes in the left axilla; no abnormalities in the abdomen and pelvis.

Bone marrow biopsy shows non-specific fibrous tissue. What is the most likely diagnosis?

A	Hodgkin's lymphoma
B	Hairy cell leukaemia
C	Malignant teratoma
D	Thymoma
E	Tuberculosis

A Hodgkin's lymphoma

Hodgkin's lymphoma is a malignant proliferation of lymphocytes. Some 25% of patients have a constitutional upset (i.e. night sweats, weight loss, fever, pruritus and lethargy). Rarely, there may be alcohol-induced pain or features due to mass effects of the affected nodes. An isolated bone marrow biopsy may not yield any significant results as Hodgkin's disease can cause patchy bone marrow infiltration, Lymph node biopsies are often more useful. Reed–Sternberg cells are evident on microscopy. Treatment depends on classification and staging, but usually involves multiple chemotherapy agents. Prognosis is usually good.

B Hairy cell leukaemia

Patients with hairy cell leukaemia have infiltration of the bone marrow by malignant B lymphocytes (the 'hairy cells'). This leads to failure to produce

cells'). This leads to failure to produce red blood cells, white bloods cells and platelets. Leukaemic cells accumulate within the spleen, leading to massive splenomegaly. Fatigue is also a key sign. Not all patients with hairy cell leukaemia require treatment but, if they do, often single-agent treatment will suffice. This patient's presentation is not in keeping with a diagnosis of hairy cell leukaemia.

C	Malignant teratoma

A differential for an anterior mediastinal mass includes teratoma. However, teratomas are extremely rare and are often associated with pelvic disease, which the patient in this case does not have. These are usually tumours that develop in utero but that are only picked up much later on in life. Diagnosis is usually via histology. Some teratomas contain yolk sac elements that secrete alpha-fetoprotein (AFP). However, AFP levels are more commonly used to monitor for disease recurrence after diagnosis rather than

teratomas contain yolk sac elements that secrete alpha-fetoprotein (AFP). However, AFP levels are more commonly used to monitor for disease recurrence after diagnosis rather than being diagnostic.

D	Thymoma

This patient has an anterior mediastinal mass which could be in keeping with a thymoma. However, the mass in this patient has irregular borders and usually with a thymoma you see a smooth, encapsulated tumour.

E	Tuberculosis

This patient has a clear lung fields on CT where you would normally expect to find lesions. The patient also is not suffering with temperatures, productive cough or haemoptysis, all of which make a diagnosis of TB less likely.

2301

Rate this question:

A 45-year-old man is referred from his general practitioner with an abnormal white cell count found on routine testing.

On examination, he has several 1–2 cm lymph nodes and 3 cm splenomegaly.

Investigations:

Hb	9.5g/dl
WCC	34.3 x 10^9/l
PLT	94 x 10^9/l
Lymphocytes	31 x 10^9/l

Immunophenotype was positive for B-cell markers (CD19 and CD20) with aberrant expression of the T-cell marker CD5.

What is the most likely diagnosis?

A	Acute myeloid leukaemia (AML)
B	Acute lymphoblastic leukaemia (ALL)

Lymphocytes	31 x 10^9/l

Immunophenotype was positive for B-cell markers (CD19 and CD20) with aberrant expression of the T-cell marker CD5.

What is the most likely diagnosis?

A	Acute myeloid leukaemia (AML)
B	Acute lymphoblastic leukaemia (ALL)
C	Chronic lymphocytic leukaemia (CLL)
D	Chronic myeloid leukaemia (CML)
E	Non-Hodgkin's lymphoma (NHL)

C Chronic lymphocytic leukaemia (CLL)

This man has an increase in mature lymphocytes in his peripheral blood. Immunophenotyping can be used to identify leucocytes by staining them with antibodies to the 'CD' (cluster differentiation) system, and is standard testing in unexplained lymphocytosis. Chronic lymphocytic leukaemia, a condition of B lymphocytes, paradoxically expresses CD5, a T-cell marker. Chronic lymphocytic leukaemia (CLL) can be staged according to two systems – Binet's and Rai's classifications – which use a combination of clinical features and number of cytopenia. Although Binet's stage A CLL (less than three sites of lymphadenopathy, normal platelets and haemoglobin) carries a normal life expectancy (and does not require treatment), this man has much more advanced disease with widespread lymphadenopathy and advanced marrow failure, and this is what drives the need to explain to him about

the need to explain to him about limited life expectancy. Recent advances have shown that positivity to ZAP (zeta-associated protein) 70 is associated with poorer prognosis disease.

B	Acute lymphoblastic leukaemia (ALL)

ALL blood film examination reveals circulating blasts, and flow cytometry with cytogenetics can be used to differentiate ALL from AML. AML is usually associated with blasts that are positive for CD33, whereas ALL-associated cells are not.

A	Acute myeloid leukaemia (AML)

Circulating blasts with markers on flow cytometry consistent with immature lymphocytes are found in the peripheral blood of patients with AML.

D	Chronic myeloid leukaemia

An 18-year-old woman presents with an episode of epistaxis, which settles with conservative management. Apparently she has had a recent flu-like illness.

On examination, she has a number of petechiae and some bruising where she has taken knocks or bangs to her legs. She is on no significant medication and has a clean past medical history. You understand that her aunt had a splenectomy as a young adult.

Investigations:

Hb	11.0 g/dl
WCC	5.0 $\times 10^9$/l
PLT	16.0 $\times$ 10^9/l
Na^+	139 mmol/l
K^+	4.0 mmol/l
Creatinine	105 μmol/l

Which of the following is the most appropriate treatment?

WCC	5.0 x10^9/l
PLT	16.0 × 10^9/l
Na^+	139 mmol/l
K^+	4.0 mmol/l
Creatinine	105 µmol/l

Which of the following is the most appropriate treatment?

A Platelet transfusion

B Prednisolone 20 mg daily

C Prednisolone 60 mg daily

D Splenectomy

E Azathioprine 100 mg daily

20556

Submit

A 19-year-old woman presents with a 12 h history of sudden loss of power in the left arm. She is previously fit and well, smokes five cigarettes daily and is on the combined oral contraceptive pill. Her grandfather had a stroke in his eighties, and she has five siblings who are well.

Examination shows increased tone and brisk reflexes in the left arm. There is a 12 cm splenomegaly. Computed tomography of the head is normal.

Investigations:

Hb	12.3 g/dl
WCC	18.5 x 10^9/l
Platelets	1035 x 10^9/l

A blood film shows a left shift with markedly increased platelets, which vary significantly in size (anisothrombia). Bone marrow shows a translocation between chromosomes 9 and 22.

What is the most likely diagnosis?

Platelets	1035 x 10^9/l

A blood film shows a left shift with markedly increased platelets, which vary significantly in size (anisothrombia). Bone marrow shows a translocation between chromosomes 9 and 22.

What is the most likely diagnosis?

A	Essential thrombocythaemia with cerebrovascular accident
B	Antiphospholipid syndrome with reactive thrombocytosis
C	Cerebral lupus with reactive thrombocytosis
D	Chronic myelogenous leukaemia (CML)
E	Acute myeloid leukaemia

D Chronic myelogenous leukaemia (CML)

The history is compatible with a cerebrovascular accident, and the high platelet count is likely to be the cause. Chronic myelogenous leukaemia (a myeloproliferative disorder) usually manifests with thrombocytosis at presentation, usually with a raised white cell count that is grossly left-shifted (where promyelocytes, metamyelocytes and myelocytes are all visible on the peripheral blood). There is usually marked splenomegaly and the bone marrow is nearly always positive for the Philadelphia chromosome (the abnormally small chromosome 22 is the 'Philadelphia' chromosome). The basophil count is often increased in myeloproliferative disorders.

A Essential thrombocythaemia with cerebrovascular accident

Essential thrombocythaemia can

A Essential thrombocythaemia with cerebrovascular accident

Essential thrombocythaemia can present with splenomegaly, but where the Philadelphia chromosome is found the disease is always classified as chronic myeloid leukaemia. There would not be a translocation of chromosomes 9 and 22 in essential thrombocythaemia.

B Antiphospholipid syndrome with reactive thrombocytosis

Platelet counts are characteristically low in anti-phospholipid syndrome, but are high in all the myeloproliferative disorders such as CML. Also, there would not be a translocation of chromosomes 9 and 22 in anti-phospholipid syndrome.

C Cerebral lupus with reactive thrombocytosis

Central lupus usually presents with low

C	Cerebral lupus with reactive thrombocytosis

Central lupus usually presents with low platelets and pancytopenia. It can give rise to strokes, seizures or changes to the mental state. There would not be a translocation of chromosomes 9 and 22 in lupus.

E	Acute myeloid leukaemia

Acute myeloid leukaemia occurs when there is a maturational arrest in bone marrow cells early on in their development, leading to a variety of blood test results. These include thrombocytopenia, anaemia and low, high or normal white cell counts. Circulating blasts are seen on a blood film and there is no translocation of chromosomes with AML.

8255

Rate this question:

A 30-year-old man has been admitted for an elective knee arthroscopy. You are asked to review him prior to the operation. He has a past history of gallstones, and had jaundice as a child, but otherwise he is fit and well.

Examination reveals mild splenomegaly.

Investigations:

Hb	12.7 g/dl
WCC	8.2×10^9/l
PLT	400×10^9/l
MCV	78 fl
MCHC	43 g/dl (32-35 g/dl)
Reticulocytes	3.3% (0.5-2.4%)

What is the most likely diagnosis?

A Sickle cell disease

B Sideroblastic anaemia

WCC	$8.2 \times 10^9/l$
PLT	$400 \times 10^9/l$
MCV	78 fl
MCHC	43 g/dl (32-35 g/dl)
Reticulocytes	3.3% (0.5-2.4%)

What is the most likely diagnosis?

A Sickle cell disease

B Sideroblastic anaemia

C Iron deficiency anaemia

D Thalassaemia trait

E Hereditary spherocytosis

7074

Submit

E Hereditary spherocytosis

Hereditary spherocytosis is inherited as an autosomal dominant condition and is one of the most common inherited haemolytic anaemias. The defect is in the membrane skeleton (usually the spectrin component), resulting in the appearance of spherocytes in the blood film. The spleen removes these spherocytes from the blood. Symptoms are variable in severity but include anaemia, jaundice and splenomegaly. With haemolysis, patients are at increased risk of pigment gallstones. The mean cell volume is usually low and the mean corpuscular haemoglobin concentration is usually high. The most sensitive test to confirm the diagnosis is the osmotic fragility test. Folic acid can be given to aid haemopoiesis, but occasionally splenectomy is required.

A Sickle cell disease

Given that this patient is 30 years old,

a history of sickle cell crisis would be expected in a patient with sickle cell disease.

B	Sideroblastic anaemia

Sideroblastic anaemia presents with more significant symptoms of anaemia than those reported here, and also leads to iron overload, which itself can present with cardiac failure and hepatic fibrosis/cirrhosis.

C	Iron deficiency anaemia

Iron deficiency anaemia is associated with microcytic anaemia. Although increased reticulocytes are associated with haemolytic anaemia, gallstones would not be expected.

D	Thalassaemia trait

Thalassaemia trait is generally associated with slightly lower MCV (in the 65–75 range) and is not associated with elevated reticulocytes.

An 18-year-old man presents with sudden onset left-sided weakness of 24 h duration. He has sickle cell anaemia, and has required admissions in the past for management of chest crises. He is on ibuprofen for pain when necessary, penicillin V and folic acid. He smokes ten cigarettes daily and drinks 21 units of alcohol per week. His mother and father are both carriers for HbS, and he has no siblings or children.

On examination, he has dense, left-sided weakness, with brisk reflexes and up-going plantars on the left-hand side. Computed tomography (CT) of the brain confirms a right-sided hypodense lesion. His haemoglobin (Hb) is 110 g/l.

What is the most appropriate short-term intervention?

A	Hydroxyurea
B	5′-Azacytidine

His mother and father are both carriers for HbS, and he has no siblings or children.

On examination, he has dense, left-sided weakness, with brisk reflexes and up-going plantars on the left-hand side. Computed tomography (CT) of the brain confirms a right-sided hypodense lesion. His haemoglobin (Hb) is 110 g/l.

What is the most appropriate short-term intervention?

A	Hydroxyurea
B	5′-Azacytidine
C	Bone marrow transplantation
D	Thrombolytic therapy
E	Exchange transfusion

E Exchange transfusion

6–10% of sickle cell patients will suffer a stroke, usually during childhood. The risk can be predicted by transcranial Doppler measurement of the middle cerebral artery flow rate, and prompt institution of a prophylactic transfusion programme to reduce the HbS percentage can prevent future strokes. Silent infarcts can lead to reduced cognition and limited educational attainment. In this case, with symptoms of acute stroke, exchange transfusion is the most appropriate next step.

A Hydroxyurea

There is growing evidence that in addition to its effects on painful and chest crises, hydroxyurea may impact positively on the stroke rate in patients with sickle cell disease, although in the short term exchange transfusion is more effective.

B	5′-Azacytidine

5′-Azacytidine is a DNA methylating agent that can improve HbF levels where hydroxyurea has failed, but it is cytotoxic and its use remains limited, particularly given the young age of this patient.

C	Bone marrow transplantation

Due to the high procedure-related mortality, transplant is usually only considered suitable for patients under 16 with a matched sibling donor; it is not considered superior to a transfusion therapy.

D	Thrombolytic therapy

24 h after symptoms began, this patient is outside the window for thrombolysis and this is therefore not an option.

6310

Rate this question:

A 70-year-old man presents with severe, unremitting epistaxis from both nostrils. The ENT registrar successfully packs the nose, but the patient complains of continuous post-nasal drip and has had several episodes of melaena. He has been suffering from prominent joint pains in the knees and hands for several months.

There is no previous medical history of note other than an uncomplicated hernia repair a year ago. Family history reveals nothing of significance. He is on no medication.

On examination, he has moderate synovitis of several proximal interphalangeal, metacarpo-phalangeal and large joints. Blood pressure is 90/60 mmHg, pulse 120 beats per minute (bpm), respiratory rate 25 breaths per minute. His skin is cool to the touch. He is covered in large bruises.

Investigations:

Hb	7.3 g/dl
WCC	4.3 × 10^9/l

the touch. He is covered in large bruises.

Investigations:

Hb	7.3 g/dl
WCC	4.3×10^9/l
PLT	556×10^9/l
ESR	74 mm/first hour
APTT (does not correct in mixing study)	75 s (30–40 s)
PT	12 s (11.5–15.5 s)
Factor VIII activity	Reduced

What is the most appropriate therapy for this man's bleeding?

A	Recombinant factor VIII
B	Recombinant factor IX

ESR	mm/first hour
APTT (does not correct in mixing study)	75 s (30–40 s)
PT	12 s (11.5–15.5 s)
Factor VIII activity	Reduced

What is the most appropriate therapy for this man's bleeding?

A	Recombinant factor VIII
B	Recombinant factor IX
C	Cryoprecipitate
D	FFP
E	Recombinant activated factor VII

E	Recombinant activated factor VII

Initially developed for use in patients with congential haemophilia with allo-antibody inhibitors, recombinant activated factor VII has been successfully used in patients with acquired haemophilia. It binds to the surface of activated platelets, where it supports thrombin generation and by-passes the need for FVIII.

A	Recombinant factor VIII

This gentleman has an acquired factor VIII deficiency, probably associated with rheumatoid arthritis. Acquired haemophilia is more common in the elderly or during pregnancy, often in association with concurrent autoimmune disease or malignancy. It is due to an antibody to a coagulation factor, most commonly factor VIII, often referred to as an 'inhibitor'. Bleeding can be severe to the point that great care should be taken with

Bleeding can be severe to the point that great care should be taken with cannula insertion since compartment syndrome may ensue. Diagnosis is by performing mixing studies with patients and normal plasma: a simple factor deficiency will be corrected by mixing with normal plasma, but an acquired inhibitor will not correct with mixing. The inhibitor can then be measured by the Bethesda assay, which can be used to monitor response to treatment. Treatment with factor VIII is usually ineffective as the inhibitor has rapid activity.

B	Recombinant factor IX

Recombinant factor IX is used in patients with inherited factor IX deficiency (haemophilia B). It isn't of significant utility in patients with acquired factor VIII deficiency.

C	Cryoprecipitate

Cryoprecipitate, derived from FFP,

Recombinant factor IX is used in patients with inherited factor IX deficiency (haemophilia B). It isn't of significant utility in patients with acquired factor VIII deficiency.

C	Cryoprecipitate

Cryoprecipitate, derived from FFP, contains fibrinogen, von Willebrand factor, factor VIII, factor XIII and fibronectin, and is not likely to be effective here versus activated factor VII.

D	FFP

Given that FFP is a product derived from blood transfusion, it does contain factor VII, but recombinant activated factor VII is much preferred as it doesn't carry any risk of contamination.

6384

Rate this question:

A 71-year-old man with a long history of rheumatoid arthritis presents for review. He has recently complained of loss of weight and a number of episodes of dark urine, but normal stools. He admits to drinking 20 units of alcohol per week and has previously lived in the tropics, but has not travelled abroad recently.

On examination, he weighs 80 kg. There is a palpable spleen. His liver function tests were normal, apart from raised total bilirubin. Urine analysis showed urobilinogen, urosiderin, no bilirubin and no red blood cells. Haemoglobin was reduced at 10 g/dl, there was an increase in spherocytes, and both haptoglobins and platelets were reduced.

Which of the following is the next best investigation in this case?

A	Hepatic ultrasound scan
B	Endoscopic retrograde cholangiopancreatography (ERCP)

There is a palpable spleen. His liver function tests were normal, apart from raised total bilirubin. Urine analysis showed urobilinogen, urosiderin, no bilirubin and no red blood cells. Haemoglobin was reduced at 10 g/dl, there was an increase in spherocytes, and both haptoglobins and platelets were reduced.

Which of the following is the next best investigation in this case?

A	Hepatic ultrasound scan
B	Endoscopic retrograde cholangiopancreatography (ERCP)
C	Direct antiglobulin test
D	Bone marrow
E	Thick and thin film

11:27
:tps://mypastest.pastest.com
13

stools. He admits to drinking 20 units of alcohol per week and has previously lived in the tropics, but has not travelled abroad recently.

On examination, he weighs 80 kg. There is a palpable spleen. His liver function tests were normal, apart from raised total bilirubin. Urine analysis showed urobilinogen, urosiderin, no bilirubin and no red blood cells. Haemoglobin was reduced at 10 g/dl, there was an increase in spherocytes, and both haptoglobins and platelets were reduced.

Which of the following is the next best investigation in this case?

Your answer was correct

A	Hepatic ultrasound scan
B	Endoscopic retrograde cholangiopancreatography (ERCP)

C Direct antiglobulin test

This picture suggests the possibility of haemolytic anaemia. We are aware that he has a long history of rheumatoid arthritis, which is associated with increased haemolytic anaemia. Clinical pointers include spherocytosis as a result of red cell damage, positive direct antiglobulin test and the coexistence of autoimmune thrombocytopaenia. His weight loss is likely to be related to disease activity of his rheumatoid arthritis. Doses of prednisolone of 1 mg/kg are sufficient to induce remission in around 80% of cases. Other immunosuppressive drugs such as azathioprine and cyclophosphamide may be used in relapsed patients or in those who fail initial therapy. Splenectomy may be considered in patients with refractory disease.

A Hepatic ultrasound scan

The scenario points towards

A	Hepatic ultrasound scan

The scenario points towards haemolysis. There are no signs/symptoms of liver disease. Patient reports dark urine with normal stool, thus excluding any relevance to hepatic pathology.

B	Endoscopic retrograde cholangiopancreatography (ERCP)

There is no evidence of biliary system pathology. The raised bilirubin is secondary to haemolysis.

D	Bone marrow

This investigation is invasive and will not aid the diagnosis, since all the tests needed to confirm haemolytic anaemia can be done on peripheral blood.

E	Thick and thin film

stool, thus excluding any relevance to hepatic pathology.

B	Endoscopic retrograde cholangiopancreatography (ERCP)

There is no evidence of biliary system pathology. The raised bilirubin is secondary to haemolysis.

D	Bone marrow

This investigation is invasive and will not aid the diagnosis, since all the tests needed to confirm haemolytic anaemia can be done on peripheral blood.

E	Thick and thin film

Malaria can be a cause for haemolysis, but there are no pointers in the clinical scenario towards that diagnosis.

33305

Rate this question:

A 62-year-old man with chronic lymphatic lymphoma (CLL) presents to the GP complaining of increased shortness of breath and wheeze. He has a history of asthma for which he takes seretide, and he takes fludarabine for the CLL.

On examination, he is pyrexial 38.1 °C, and there is wheeze and coarse crackles on auscultation of the chest.

Investigation:

Hb	10.0 g/dl
WCC	17.9×10^9/l
PLT	92×10^9/l
Na^+	135 mmol/l
K^+	4.2 mmol/l
Creatinine	140 μmol/l
IgG	5.3 g/l (6.0-13.0)

Which of the following is the most appropriate prophylaxis against further pneumonia episodes?

Na^+	135 mmol/l
K^+	4.2 mmol/l
Creatinine	140 µmol/l
IgG	5.3 g/l (6.0-13.0)

Which of the following is the most appropriate prophylaxis against further pneumonia episodes?

A	Immunoglobulin transfusion
B	Regular ciprofloxacin
C	Regular co-trimoxazole
D	Chlorambucil combination therapy
E	Alemtuzumab combination therapy

C Regular co-trimoxazole

Patients who take fludarabine are at increased risk of infection with a range of pathogens including *Pneumocystis*, *Listeria*, *Neisseria* and *Legionella*. Both daily and thrice weekly regimens for dosing co-trimoxazole are effective.

A Immunoglobulin transfusion

Where IgG is markedly reduced, regular immunoglobulin transfusions may be required, although here IgG is only just below the lower limit of normal.

B Regular ciprofloxacin

Ciprofloxacin is a potentially useful prophylaxis against organisms such as *Listeria*, but it is not effective against *Pneumocystis*.

D Chlorambucil combination therapy

Ciprofloxacin is a potentially useful prophylaxis against organisms such as *Listeria*, but it is not effective against *Pneumocystis*.

D	Chlorambucil combination therapy

Chlorambucil is likely to promote further immunosuppression when used in combination with fludarabine, and studies of the two combined showed no greater efficacy than fludarabine monotherapy in the treatment of CLL.

E	Alemtuzumab combination therapy

Alemtuzumab targets lymphocytes bearing the CD52 cell surface protein. It is used as combination therapy for CLL, but it doesn't reduce the risk of opportunistic infection.

21527

Rate this question:

A 78-year-old man presents with sudden deterioration of vision in his left eye, with no eye pain. There are flame haemorrhages in one quadrant on retinal examination.

He has a history of hypertension and is awaiting investigations for anaemia; recent haemoglobin is 10.5 g/dl.

What diagnosis fits best with this clinical picture?

A	Branch retinal vein occlusion
B	Branch retinal artery occlusion
C	Central retinal vein occlusion
D	Central retinal artery occlusion
E	CMV retinitis

A Branch retinal vein occlusion

Patients often complain of a sudden painless decrease of vision in the affected eye. Some patients may complain of a scotoma. Risk factors for retinal vein occlusion include systemic hypertension, hypertriglyceridaemia and hyperviscosity syndromes. Some inflammatory (e.g. sarcoidosis) and thrombophilic conditions (e.g. SLE) may also be involved. Management involves screening for risk factors and anticoagulation. Further management depends on which underlying condition has been identified.

B Branch retinal artery occlusion

This is usually embolic in aetiology. Patients with branch retinal artery occlusion typically present with acute, unilateral, painless, partial visual loss. Visual field defects may be central or sectoral. Patients may also be asymptomatic. Risk factors include

sectoral. Patients may also be asymptomatic. Risk factors include smoking, hypertension, hypercholesterolaemia, diabetes, coronary artery disease and history of stroke or transient ischemic attack.

C	Central retinal vein occlusion

Patients can be either asymptomatic or present with decreased vision, photophobia and painful or red eyes. Fundoscopy shows tortuosity and dilatation of all branches of the central retinal vein, dot/blot and flame-shaped hemorrhages, throughout all four quadrants and most numerous in the periphery, and optic disc and macular oedema. This tends to be more severe in ischaemic CRVO than non-ischaemic CRVO.

D	Central retinal artery occlusion

This is embolic in aetiology. The most common presenting complaint is an acute, persistent, painless loss of vision

appear normal. The classic findings of retinal whitening and a cherry red spot are due to opacification of the nerve fibre layer as it becomes oedematous from ischeamia. The fovea is cherry red because it has no overlying nerve fibre layer. This finding may take hours to develop, and the oedema is associated with a worse visual prognosis. Over the course of about a month, the inner retina becomes atrophic as the swelling resolves

E	CMV retinitis

Presenting symptoms vary depending on the location of retinal involvement. Posterior lesions present with diminished visual acuity. More peripheral lesions initially can be asymptomatic. Floaters often are noted if significant vitreitis is present. The eye usually is white and quiet. In immunocompromised individuals, CMV most commonly presents as a viral necrotising retinitis with a characteristic ophthalmoscopic appearance.

A 49-year-old woman presents with fatigue. She has chronic kidney diease (CKD) secondary to systemic lupus erythematosus, requiring dialysis for the last three years. She is on prednisolone 20 mg daily and erythropoietin alpha 3500 units three times weekly.

Examination is unremarkable other than noticeable pallor.

Investigations:

Hb	4.9 g/dl
WCC	3.5×10^9/l
PLT	455×10^9/l
Neutrophils	3.0×10^9/l
MCV	83 fl (80–96)
Reticulocytes	13×10^9/l (25–85)
Serum B_{12}	163 ng/l (160–760)
Serum folate	5 µg/l (2.0–11.0)
	Plentiful megakaryocytes, normal myeloid

Serum folate	5 μg/l (2.0–11.0)
Bone marrow	Plentiful megakaryocytes, normal myeloid maturation, absent erythropoiesis and no infiltrates

What is the most likely diagnosis?

A	Diamond Blackfan anaemia
B	Anaemia of chronic disease
C	Lupus-associated myelofibrosis
D	Paroxysmal nocturnal haemoglobinuria
E	Pure red cell aplasia

(CKD) secondary to systemic lupus erythematosus, requiring dialysis for the last three years. She is on prednisolone 20 mg daily and erythropoietin alpha 3500 units three times weekly.

Examination is unremarkable other than noticeable pallor.

Investigations:

Hb	4.9 g/dl
WCC	3.5×10^9/l
PLT	455×10^9/l
Neutrophils	3.0×10^9/l
MCV	83 fl (80–96)
Reticulocytes	13×10^9/l (25–85)
Serum B_{12}	163 ng/l (160–760)
Serum folate	5 µg/l (2.0–11.0)
Bone marrow	Plentiful megakaryocytes, normal myeloid maturation, absent erythropoiesis and no

E Pure red cell aplasia

Pure red cell aplasia is diagnosed when there is unexplained anaemia and reticulocytopenia, with a complete absence of red cell precursors in the bone marrow but with preservation of other cell lines. It can occur spontaneously, or in association with autoimmune diseases, lymphoproliferative disorders or viral illnesses such as HIV, hepatitis and herpes. Treatment is supportive, with immunosuppression. Rarely, the condition can occur where recombinant erythropoietin is administered and patients respond to withdrawal of erythropoietin.

A Diamond Blackfan anaemia

Diamond Blackfan anaemia is an inherited pure red cell aplasia which would present in infancy rather than in the fifth decade. Diagnosis is made via a full blood count and bone marrow biopsy. Treatment is with

biopsy. Treatment is with corticosteroids and transfusions as required. Bone marrow transplantation can also be considered. This diagnosis is unlikely due to the patient presenting in their 40s.

B	Anaemia of chronic disease

Anaemia of chronic disease is a possibility in a patient with SLE who is requiring dialysis. To be able to diagnose an anaemia of chronic disease, we would need to have carried out transferrin saturations (high) and ferritin levels (normal/high). Also it is usual for a patient on dialysis to have regular bloods, in which case the ongoing anaemia would have been picked up earlier.

C	Lupus-associated myelofibrosis

Myelofibrosis can be seen in lupus, but the bone marrow is characteristically a dry tap and marked fibrosis is seen on the bone marrow trephine.

Myelofibrosis can be seen in lupus, but the bone marrow is characteristically a dry tap and marked fibrosis is seen on the bone marrow trephine.

D	Paroxysmal nocturnal haemoglobinuria

Classically presents with red discoloration of urine. However, a patient on dialysis may not produce any urine. Other symptoms include anaemia, abdominal pain, difficulty in swallowing and thrombosis. Diagnosis is usually by bloods in keeping with an intravascular haemolytic anaemia (raised bilirubin and LDH and low Hb and haptoglobin) and a positive Ham test (with increased RBC fragility indicating PNH). Treatment is usually with steroids and transfusions, as required.

6298

Rate this question:

Next Question

A 63-year-old man is admitted to Accident and Emergency with a 5-day history of vomiting, diarrhoea and bloody stools. The diarrhoea and vomiting stopped 2 days ago, but he noticed his abdomen was distended and had constant colicky pain. He also complains of dyspnoea on minimal exertion and increasing urinary frequency, with small volumes of urine. Apart from attending a wedding reception a week ago, he has only eaten home-made food. He has hypertension and gout and takes an ACE inhibitor, calcium-channel blocker, allopurinol and a statin. He is a non-smoker but enjoys a bottle of red wine at weekends.

On examination, he is pale and slightly agitated. His temperature is 37.1 °C, pulse 96 regular, BP 142/92 mmHg. His respirations are 24 breaths/min at rest and his saturations are 96% on room air. His heart sounds are normal but basal crackles can be heard on chest examination. His abdomen is distended and tympanic, mildly tender and bowel sounds are reduced. Rectal

sounds are reduced. Rectal examination reveals a brown stool.

Investigations:

Hb	9.8 g/dl
WCC	28.7×10^9/l
PLT	65×10^9/l
Na^+	130 mmol/l
K^+	4.7 mmol/l
Creatinine	8462 μmol/l
Urea	40.8 mmol/l
Albumin	12 g/l
Bilirubin	100 μmol/l
ALT	60 U/l
ALP	61 U/l
MCV	91 fl
LDH	1240 U/l
CRP	354 mg/l

CRP	354 mg/l

The blood film shows schistocytes and burr cells.

Chest X-ray reveals alveolar shadowing at both bases, with small bilateral pleural effusions.

What is the diagnosis?

A	Crohn's colitis
B	Gastroenteritis
C	Haemolytic–uraemic syndrome
D	Polyarteritis nodosa
E	*Legionella* pneumonia

12:22
:tps://mypastest.pastest.com
13

C Haemolytic-uraemic syndrome

HUS is characterised by the triad of micro-angiopathic haemolytic anaemia, thrombocytopenia and acute kidney disease. Typically, HUS occurs after a prodrome of diarrhoea. In adults, HUS is usually caused by the enterohaemorrhagic serotypes of *Escherichia coli,* especially *E. coli* O157:H7. The source of the infection is usually contaminated beef, poultry or cider, although faecal-to-hand transmission can occur. HUS is associated with: malignant hypertension; infection (e.g. *E. coli*, *Shigella* spp, HIV); vasculitis; radiation nephritis; collagen vascular diseases (e.g. scleroderma); cryoglobulinaemia; malignancy, mainly adenocarcinoma; drugs (e.g. oral contraceptive therapy, chemotherapy, ciclosporin); bone marrow transplantation; eclampsia; and postpartum acute kidney disease.

Uraemia cannot explain all the haematological findings in this case, particularly the presence of schistocytes and burr cells on the blood film. These indications of micro-angiopathic anaemia suggest red cell trauma due to fibrin deposition in the microvasculature. When thrombotic micro-angiopathy involves the kidneys, thrombosis of glomerular capillaries and renal arterioles can lead to kidney disease. In the severe form of the disease, bilateral cortical necrosis and irreversible kidney disease may occur. Plasmapheresis with fresh-frozen plasma as the replacement fluid is the current treatment of choice. Renal replacement therapy might also be required.

Some patients can have atypical HUS. This is an extremely rare, progressive and potentially life-threatening condition seen in both children and adults and which often (70%) has a genetic component. It can also be referred to as diarrhoea-negative HUS. It is commonly caused by mutations in the complement regulatory proteins

the complement regulatory proteins causing a chronic, uncontrolled activation of the complement system leading to systemic thrombotic micro-angiopathy which ultimately causes sudden or progressive damage to vital organs. Historically, approximately 40% of patients died or developed chronic kidney disease following their first episode of atypical HUS. Subsequent episodes led to 65% of patients dying, requiring dialysis or suffering long-term renal damage in spite of plasma exchange.

More recently, eculizumab has been used in patients with atypical HUS. Eculizumab is a human monoclonal antibody, produced from murine myeloma cells, that binds to complement C5 and blocks pro-thrombotic and pro-inflammatory processes. It has been found to improve renal function, reduce thrombotic micro-angiopathic activity and improve patient quality of life, although there is a lack of randomised controlled trials.

Crohn's usually presents in 15–25-year-olds, although there is a second peak at around 55–70 years. As in this patient's case, the presentation is one of severe diarrhoea and abdominal tenderness with distension. Patients often also suffer with perianal fistulae and mouth ulcers. This patient is unlikely to have Crohn's disease as the diarrhoea lasted only 48 h and also, after this point, the patient noted increased urinary frequency. If the patient had Crohn's colitis, you would expect ongoing diarrhoea (possibly bloods) with acute kidney disease as a result of fluid depletion secondary to diarrhoea.

B	Gastroenteritis

You may have considered gastroenteritis as a possible diagnosis given the history of a recent meal out with subsequent diarrhoea lasting 24–48 h. However, gastroenteritis would not explain the subsequent increase in urinary frequency.

D	Polyarteritis nodosa

PAN is a necrotising arteritis of small and/or medium vessels without glomerulonephritis. Patients often present with skin lesions, mononeuritis multiplex and involvement of the GI tract, heart, central nervous system and kidneys, as well as myalgia. Bloods show a hypergammaglobulinaemia, leucocytosis and raised neutrophil count. The mainstay of treatment is with corticosteroids. This patient is unlikely to have PAN as you would expect a raised protein level, and although GI and renal symptoms can be present, these are less common compared to the incidence in other diseases.

E	*Legionella* pneumonia

If the patient had a *Legionella* pneumonia you would expect them to have a cough and fevers in addition to the hyponatraemia, auscultation findings and dyspnoea. This also doesn't fully explain his abdominal

count. The mainstay of treatment is with corticosteroids. This patient is unlikely to have PAN as you would expect a raised protein level, and although GI and renal symptoms can be present, these are less common compared to the incidence in other diseases.

E	*Legionella* pneumonia

If the patient had a *Legionella* pneumonia you would expect them to have a cough and fevers in addition to the hyponatraemia, auscultation findings and dyspnoea. This also doesn't fully explain his abdominal findings or bloody diarrhoea. *Legionella* pneumonia could be on your differentials but is not a unifying diagnosis for this patient's findings.

2299

Rate this question:

Next Question

A 52-year-old woman is bought to her GP by her carer who has become concerned after noticing that the patient's gums have progressively become more prominent over the last few months. She tried to take the patient to the dentist but no NHS dental appointments were available. The patient lives in a home since she has learning difficulties.

Her past medical history is unremarkable except for three infections in the last 6 weeks. The carer has also noticed that recently the patient has become increasingly fatigued by even the lightest of activities and is commonly short of breath on exertion. She is not currently on any medications but has taken various courses of antibiotics recently.

On examination, she is noted to be anaemic and has multiple bruises over her body. She has hypertrophic bleeding gums and, on auscultation of the heart, she is found to have a flow murmur. She has mild splenomegaly on palpation of her abdomen. Routine blood tests were requested and

palpation of her abdomen. Routine blood tests were requested and confirmed the presence of anaemia, a raised white cell count, low neutrophil count and thrombocytopenia. A blood film shows increased numbers of blast cells and the presence of Auer rods.

Given these findings, what is the most likely diagnosis?

A	Acute myeloid leukaemia (AML)
B	Acute lymphoblastic leukaemia (ALL)
C	Chronic myeloid leukaemia (CML)
D	Chronic lymphoid leukaemia (CLL)
E	Chronic myelomonocytic leukaemia (CMML)

On examination, she is noted to be anaemic and has multiple bruises over her body. She has hypertrophic bleeding gums and, on auscultation of the heart, she is found to have a flow murmur. She has mild splenomegaly on palpation of her abdomen. Routine blood tests were requested and confirmed the presence of anaemia, a raised white cell count, low neutrophil count and thrombocytopenia. A blood film shows increased numbers of blast cells and the presence of Auer rods.

Given these findings, what is the most likely diagnosis?

Your answer was correct

A	Acute myeloid leukaemia (AML)
B	Acute lymphoblastic leukaemia (ALL)
C	Chronic myeloid leukaemia (CML)

A Acute myeloid leukaemia (AML)

Acute myeloid leukaemia (AML) is a malignant disease of the bone marrow in which the blast cells derived from the myeloid marrow elements undergo a neoplastic proliferation. AML is distinguished by the presence of >20% blasts in the blood and/or bone marrow. It is more common in men and the prevalence increases with age, but it can affect all age groups. It is, however, becoming more common as a long-term complication of chemotherapy. Symptoms are usually related to marrow failure (anaemia, infections, bleeding) and/or organ infiltration with leukaemic cells (bone pain, hepatosplenomegaly, gum hypertrophy, proptosis), but patients can also have constitutional symptoms (weakness, fever, lethargy).

B Acute lymphoblastic leukaemia (ALL)

AML is differentiated from ALL by the

AML is differentiated from ALL by the presence of Auer rods, which are eosinophilic needle-like cytoplasmic inclusions found in blast cells and that are pathognomonic of AML.

C	Chronic myeloid leukaemia (CML)

CML is a myeloproliferative disorder characterised by the proliferation of the precursors for white blood cells, but these precursors retain the ability to differentiate. Symptoms tend to be chronic and the blood profile shows an increased (++) white cell count, with a low or normal haemoglobin and a variable platelet count.

D	Chronic lymphoid leukaemia (CLL)

The most noteworthy laboratory abnormality found in CLL is lymphocytosis in the peripheral blood and bone marrow. Although the absolute blood lymphocyte threshold

absolute blood lymphocyte threshold for diagnosing CLL has been placed at >5000/microl (5×10^9/l) B lymphocytes, a significant proportion of patients presents with counts as high as 100,000/microl (100×10^9/l). The peripheral blood smear of patients with CLL demonstrates a lymphocytosis. The leukemic cells are typically small, mature-appearing lymphocytes with a dense nucleus, partially aggregated (clumped) chromatin and lacking discernible nucleoli. There is a narrow border of clear to slightly basophilic cytoplasm. The blood film in this scenario is not that of CLL.

E	Chronic myelomonocytic leukaemia (CMML)

CMML is characterised by a progressive cytopenia in the presence of a hypercellular bone marrow and usually involves all three cell lines (myeloid/monocyte, erythroid, megakaryocyte).

A 30-year-old woman with known sickle cell disease (SC phenotype) presents with severe abdominal pain. She has had multiple admissions in the past for abdominal pain, requiring large doses of parenteral opiates. She has not had any chest crises or strokes in the past.

She is on folic acid 5 mg daily, penicillin V 250 mg twice daily, morphine sulphate slow-release 200 mg twice daily with 80 mg morphine sulphate for breakthrough pains. She works as a nurse in intensive care and has two children aged 8 and 10, who are both well. Her brother died from sickle cell disease 1 year ago.

On examination, her blood pressure is 132/82, pulse is 88 and regular. Her temperature is 38.4 °C. She is in extreme pain, particularly in the upper region of her abdomen.

Investigations:

Hb	6.4 g/dl
WCC	13.3×10^9/l

Hb	6.4 g/dl
WCC	13.3×10^9/l
PLT	403×10^9/l
Bilirubin	135 μmol/l (1–22)
ALP	235 U/l

What do you think is the most likely cause of this patient's abdominal pain?

A	Opiate-seeking behaviour
B	Splenic sequestration crisis
C	Vaso-occlusive sickle-cell crisis
D	Cholecystitis
E	Transfusion-associated hepatitis

She is on folic acid 5 mg daily, penicillin V 250 mg twice daily, morphine sulphate slow-release 200 mg twice daily with 80 mg morphine sulphate for breakthrough pains. She works as a nurse in intensive care and has two children aged 8 and 10, who are both well. Her brother died from sickle cell disease 1 year ago.

On examination, her blood pressure is 132/82, pulse is 88 and regular. Her temperature is 38.4 °C. She is in extreme pain, particularly in the upper region of her abdomen.

Investigations:

Hb	6.4 g/dl
WCC	13.3 × 10^9/l
PLT	403 x 10^9/l
Bilirubin	135 µmol/l (1–22)
ALP	235 U/l

What do you think is the most likely cause of this patient's abdominal pain?

D Cholecystitis

The patient has severe abdominal pain with obstructive jaundice. The bilirubin is too high to be due to chronic haemolysis, and the raised alkaline phosphatase fits better with hepatic obstruction rather than a vaso-occlusive crisis. The raised white count and pyrexia further support cholecystitis as the underlying diagnosis. Cholecystitis is more common in patients with sickle cell disease due to chronic haemolysis.

C Vaso-occlusive sickle-cell crisis

Vaso-occlusive sickle cell crisis may present with chest or abdominal pain, but the obstructive picture on LFTs and pyrexia don't fit with a diagnosis of vaso-occlusive crisis.

A Opiate-seeking behaviour

Great care should be taken before

Great care should be taken before deciding that a patient is truly addicted to opioids. Addiction has a variety of definitions, but usually implies abnormal behaviour to gain access to a drug, either with craving or compulsive use or use despite harmful effects of a drug. Sickle cell patients are often tolerant to opioids – requiring large doses to obtain a therapeutic effect and occasionally dependent – developing withdrawal effects if opioids are stopped suddenly.

B	Splenic sequestration crisis

Splenic infarction is progressive in patients with sickle cell disease, meaning that splenic sequestration crisis becomes rarer as age increases.

E	Transfusion-associated hepatitis

Transfusion-associated hepatitis isn't associated with an acute presentation with acute abdominal pain, but with features of chronic liver disease

A 50-year-old woman undergoes routine cholecystectomy. Her preoperative full blood count was normal and her operative progress was unremarkable other than a small postoperative bleed that settled with simple pressure to the wound. You are asked to see her, as she has become confused. She has no previous medical history of note and works as a computer programmer.

On examination, she is disorientated in time and place. Temperature 37.9 °C, pulse 110 beats per minute (bpm), blood pressure 110/70 mmHg, respiratory rate 24 breaths per minute. Heart sounds are normal and jugular venous pressure is not raised. Chest reveals some bronchial breathing on the right lower and middle zones. Her O_2 saturation is 91% on air. Abdominal examination reveals mild tenderness around the operative scar but is otherwise normal.

Investigations:

Hb	9.5 g/dl

Investigations:

Hb	9.5 g/dl
WCC	12.3×10^9/l
PLT	790×10^9/l
Na^+	139 mmol/l
K^+	4.5 mmol/l
Creatinine	197 μmol/l
CRP	272

A blood film shows a dramatic increase in platelets with many enlarged forms. There is an increase in left-shifted granulocytes including metamyelocytes, myelocytes and promyelocytes.

In addition to basic resuscitation, what action would you take?

A	Aspirin 300 mg with ceftazidime 1 g twice daily intravenously

A blood film shows a dramatic increase in platelets with many enlarged forms. There is an increase in left-shifted granulocytes including metamyelocytes, myelocytes and promyelocytes.

In addition to basic resuscitation, what action would you take?

A	Aspirin 300 mg with ceftazidime 1 g twice daily intravenously
B	Aspirin 75 mg plus hydroxyurea 1 g twice daily
C	Apheresis to reduce the platelet count urgently
D	Anticoagulation with heparin to therapeutic levels
E	Levofloxacin intravenously

On examination, she is disorientated in time and place. Temperature 37.9 °C, pulse 110 beats per minute (bpm), blood pressure 110/70 mmHg, respiratory rate 24 breaths per minute. Heart sounds are normal and jugular venous pressure is not raised. Chest reveals some bronchial breathing on the right lower and middle zones. Her O_2 saturation is 91% on air. Abdominal examination reveals mild tenderness around the operative scar but is otherwise normal.

Investigations:

Hb	9.5 g/dl
WCC	12.3×10^9/l
PLT	790×10^9/l
Na^+	139 mmol/l
K^+	4.5 mmol/l
Creatinine	197 µmol/l
CRP	272

E Levofloxacin intravenously

This patient has developed postoperative pneumonia, which is making her confused secondary to hypoxia. The platelet count is raised secondary to infection – the normal preoperative count makes a primary haematological diagnosis unlikely in the extreme; the left shift is also secondary to infection. First-line therapy in this situation is usually a quinolone, accompanied by metronidazole if there is evidence of aspiration.

B Aspirin 75 mg plus hydroxyurea 1 g twice daily

Hydroxyurea with aspirin is standard treatment for essential thrombocytosis, a clonal stem cell disorder associated with increased risk of thrombosis and haemorrhage.

A Aspirin 300 mg with ceftazidime 1 g twice daily

	ceftazidime 1 g twice daily intravenously

Aspirin is not required in this situation given that the increased platelet count is reactive; ceftazidime is an appropriate antibiotic choice where *Pseudomonas* is suspected.

C	Apheresis to reduce the platelet count urgently

Given that the platelet count increase is reactive as a result of ongoing infection, there is no indication for apheresis to take place.

D	Anticoagulation with heparin to therapeutic levels

Anticoagulation with heparin to therapeutic levels isn't indicated, and may in the postoperative period increase the risk of haemorrhage. Prophylactic dosing with low-molecular weight heparin may, however, be used here.

A 74-year-old patient presents to the GP with headache, dizziness, vertigo, vague abdominal pain and general lethargy. He has previously been fit and well, with mild hypertension as his only significant past medical history. On examination his BP is 155/95 mmHg and he has a ruddy complexion.

Investigations:

Hb	17.9 g/dl
WCC	19.5 $\times 10^9$/l
PLT	450 $\times 10^9$/l
Na^+	141 mmol/l
K^+	4.9 mmol/l
Creatinine	145 µmol/l
Haematocrit	0.56

You suspect primary polycythaemia. Which of the following investigations is most likely to provide a diagnosis?

A	LDH levels

PLT	450 x10⁹/l
Na^+	141 mmol/l
K^+	4.9 mmol/l
Creatinine	145 μmol/l
Haematocrit	0.56

You suspect primary polycythaemia. Which of the following investigations is most likely to provide a diagnosis?

A	LDH levels
B	JAK-2 mutation testing
C	Arterial blood gas estimation
D	Uric acid levels
E	C282Y mutation testing

B JAK-2 mutation testing

JAK-2 mutation testing is widely available, with the V617F mutation being found in approximately 96% of patients with primary polycythaemia. The protein is a signalling protein within the JAK-STAT pathway, which drives production of red blood cells.

A LDH levels

Although LDH levels are elevated in the presence of haematological malignancy, they are non-specific so could not be used to confirm a diagnosis of primary polycythaemia here.

C Arterial blood gas estimation

Absence of hypoxia makes secondary polycythaemia less likely, although in conditions such as obesity hypoventilation syndrome, where hypoxia is more marked at night, hypoxia may be missed in the clinic.

A 37-year-old nurse presents to the ENT Department with a flu-like illness. She gives a 10-year history of tendency to have a blocked, stuffy nose and frequent recurrent coughs and colds.

The Occupational Health team has also noticed that she failed to show a response to hepatitis B and tetanus vaccinations.

In which immunoglobulin is she likely to be deficient?

A	IgA
B	IgE
C	IgD
D	IgM
E	IgG

A 37-year-old nurse presents to the ENT Department with a flu-like illness. She gives a 10-year history of tendency to have a blocked, stuffy nose and frequent recurrent coughs and colds.

The Occupational Health team has also noticed that she failed to show a response to hepatitis B and tetanus vaccinations.

In which immunoglobulin is she likely to be deficient?

Your answer was correct

A	IgA
B	IgE
C	IgD
D	IgM
E	IgG

A IgA

This patient is most likely to have IgA deficiency, which is particularly associated with recurrent sinus infections due to encapsulated bacteria such as *Haemophilus influenzae*. Selective IgA deficiency is probably the most common of the primary immunodeficiency disorders, but it may also be asymptomatic. In Caucasians, IgA deficiency is said to occur in 1 in 600–700 individuals. There is often a deficient response to polysaccharide-based vaccinations. In patients with IgA deficiency, 10–44% of patients may have anti-IgA antibodies; this risks a severe reaction to IgA-containing products such as blood, plasma or immunoglobulin.

B IgE

There are few case reports in the literature regarding IgE deficiency.

C	IgD

IgD immunodeficiency is quite rare, and individuals with this condition do not seem to be predisposed to infections.

D	IgM

Sometimes, in cases of IgA deficiency, compensatory IgM increase may occur.

E	IgG

IgG immunodeficiency is also common. IgG-subclass deficiency and its importance have been characterised. Antibodies against pneumococcal polysaccharide antigens are predominantly IgG2 and, to a lesser degree, IgG4. Antibodies against protein antigens, such as tetanus, are predominantly IgG1 and, to a lesser degree, IgG3. Finally, antibodies against large extracellular parasites, such as *Schistosoma* and *Filaria* organisms, exclusively belong to the

infections.

D	IgM

Sometimes, in cases of IgA deficiency, compensatory IgM increase may occur.

E	IgG

IgG immunodeficiency is also common. IgG-subclass deficiency and its importance have been characterised. Antibodies against pneumococcal polysaccharide antigens are predominantly IgG2 and, to a lesser degree, IgG4. Antibodies against protein antigens, such as tetanus, are predominantly IgG1 and, to a lesser degree, IgG3. Finally, antibodies against large extracellular parasites, such as *Schistosoma* and *Filaria* organisms, exclusively belong to the IgG4 subclass. The history of sinus infections in the present scenario points towards IgA immunodeficiency.

33306

Rate this question:

A 62-year-old woman presents to her GP complaining of lethargy. Past history includes hypertension, for which she takes amlodipine and bendroflumethiazide, osteoarthritis for which she takes paracetamol, recurrent urinary tract infections for which she is currently taking a 6-week course of cephalexin, and epilepsy for which she takes sodium valproate.

On examination, she looks pale and her skin is yellow-tinged. Her pulse is 100 bpm and regular, and her BP is 110/70 mmHg. Direct Coomb's test is positive; serum haptoglobins are low; reticulocyte count is elevated. Urine dipstick is positive for blood. You suspect haemolysis.

Which of the following agents is most likely to be responsible?

A	Paracetamol
B	Sodium valproate
C	Cephalexin

takes sodium valproate.

On examination, she looks pale and her skin is yellow-tinged. Her pulse is 100 bpm and regular, and her BP is 110/70 mmHg. Direct Coomb's test is positive; serum haptoglobins are low; reticulocyte count is elevated. Urine dipstick is positive for blood. You suspect haemolysis.

Which of the following agents is most likely to be responsible?

A	Paracetamol
B	Sodium valproate
C	Cephalexin
D	Amlodipine
E	Bendroflumethiazide

which she takes amlodipine and bendroflumethiazide, osteoarthritis for which she takes paracetamol, recurrent urinary tract infections for which she is currently taking a 6-week course of cephalexin, and epilepsy for which she takes sodium valproate.

On examination, she looks pale and her skin is yellow-tinged. Her pulse is 100 bpm and regular, and her BP is 110/70 mmHg. Direct Coomb's test is positive; serum haptoglobins are low; reticulocyte count is elevated. Urine dipstick is positive for blood. You suspect haemolysis.

Which of the following agents is most likely to be responsible?

Your answer was correct

A	Paracetamol
B	Sodium valproate
C	Cephalexin

C Cephalexin

The more common causes of drug-induced haemolytic anaemia include penicillin and penicillin derivatives, cephalosporins, levodopa, methyldopa, quinidine and some non-steroidal anti-inflammatory agents. Discontinuing the causative agent usually leads to a rapid improvement in the condition, and a short course of oral prednisolone may accelerate recovery. The underlying condition most frequently associated with drug-induced haemolytic anaemia is G6PD deficiency, an X-linked condition which occurs most frequently in men of black, Asian or Mediterranean origin.

A Paracetamol

The main concern with respect to use of paracetamol is hepatic failure rather than haemolytic anaemia. Given that this is a widely used over-the-counter medication, it has an excellent safety profile.

B Sodium valproate

Sodium valproate can cause anaemia, but this is related to bone marrow abnormalities rather than to haemolytic anaemia. These bone marrow abnormalities resolve on discontinuation of the medication.

D Amlodipine

Amlodipine in rare cases is associated with reductions in the white blood cell count and/or low platelets.

E Bendroflumethiazide

Blood dyscrasias are rarely reported in patients treated with thiazides, although these are not related to haemolytic anaemia.

18523

Rate this question:

A 73-year-old man attends the clinic complaining of headaches and dizziness. He also complains of generalised lethargy and sweating, predominantly at night.

On examination, he has a plethoric ruddy complexion, bruising and there is splenomegaly on abdominal examination. His blood pressure is elevated at 155/90 mmHg.

Investigations:

Hb	18.5 g/dl
WCC	10.2×10^9/l
PLT	456×10^9/l
Na^+	140 mmol/l
K^+	4.9 mmol/l
Creatinine	150 µmol/l

You wonder about a possible diagnosis of primary polycythaemia.

Which of the following is the most specific test to confirm a diagnosis of

Na^+	140 mmol/l
K^+	4.9 mmol/l
Creatinine	150 μmol/l

You wonder about a possible diagnosis of primary polycythaemia.

Which of the following is the most specific test to confirm a diagnosis of primary polycythaemia?

A	Ferritin levels
B	JAK2 screening
C	Erythropoeitin levels
D	JNK2 screening
E	Arterial blood gasses

21031

Submit

B JAK2 screening

JAK2 mutation screening is most specific for the diagnosis of primary polycythaemia. JAK2 is a crucial tyrosine kinase which transmits the EPO signal to increase red cell production. The majority of PCV is caused by a mutation in the gene coding for JAK2, which leads to red cell production independent of EPO levels. A small number of other mutations leading to PCV have also now been identified.

A Ferritin levels

Ferritin levels are usually low in primary polycythaemia, although a normal ferritin wouldn't necessarily rule out the diagnosis.

C Erythropoeitin levels

These are generally suppressed in primary polycythaemia, although where there is co-existent hypoxia they

primary polycythaemia, although a normal ferritin wouldn't necessarily rule out the diagnosis.

C Erythropoeitin levels

These are generally suppressed in primary polycythaemia, although where there is co-existent hypoxia they may be in the normal range.

D JNK2 screening

JNK2 is a protein kinase activated by a variety of environmental stressors including UV radiation.

E Arterial blood gasses

Arterial blood gases are useful when secondary polycythaemia is suspected because of the existence of hypoxia.

21031

Rate this question:

Next Question

An 89-year-old woman is an inpatient recovering from community-acquired pneumonia. She is on warfarin for atrial fibrillation, and has been put on intravenous ampicillin since admission 48 hours ago.

You are contacted for advice regarding management of her high international normalised ratio (INR). She is currently well, with no symptoms or signs of bleeding. INR > 10 (target 2.5).

What is the most appropriate management?

A	Observation alone
B	5 mg of oral vitamin K or 0.5–1 mg of IV vitamin K
C	15 ml/kg of fresh frozen plasma
D	10 units of cryoprecipitate
E	Prothrombin complex

1:14
:tps://mypastest.pastest.com
13

You are contacted for advice regarding management of her high international normalised ratio (INR). She is currently well, with no symptoms or signs of bleeding. INR > 10 (target 2.5).

What is the most appropriate management?

Your answer was correct

A	Observation alone
B	5 mg of oral vitamin K or 0.5–1 mg of IV vitamin K
C	15 ml/kg of fresh frozen plasma
D	10 units of cryoprecipitate
E	Prothrombin complex concentrate containing

B	5 mg of oral vitamin K or 0.5–1 mg of IV vitamin K

It will take several days for the INR to fall to a safe level, and patients over 70 years of age are at increased risk of haemorrhagic complications. Also at risk of haemorrhage are patients who already have minor bleeding. e.g. gum bleeding or epistaxis, or those who have bled in the past on warfarin. Both oral and IV vitamin K are potential options with an INR >8, without active bleeding at the doses described above (5 mg oral, or 0.5–1 mg IV).

A	Observation alone

At an INR >10, spontaneous and potentially significant bleeding can be seen at any time. As such, intervention with vitamin K is required.

C	15 ml/kg of fresh frozen plasma

C	15 ml/kg of fresh frozen plasma

A level of 15 ml/kg of fresh frozen plasma is unlikely to raise coagulation factors above 20%: higher doses, while more likely to correct adequately, can cause fluid overload. Fresh frozen plasma is not virally inactivated and can cause transfusion complications such as transfusion-related acute lung injury. As such other options for acute correction of INR related to warfarin excess are preferred.

D	10 units of cryoprecipitate

Cryoprecipitate contains higher levels of factor VIII and fibrinogen: its use is therefore limited mainly to the treatment of dysfibrinogenaemia or hypofibrinogenaemia.

E	Prothrombin complex concentrate containing factors II, VII, IX and X

such as transfusion related acute lung injury. As such other options for acute correction of INR related to warfarin excess are preferred.

D	10 units of cryoprecipitate

Cryoprecipitate contains higher levels of factor VIII and fibrinogen: its use is therefore limited mainly to the treatment of dysfibrinogenaemia or hypofibrinogenaemia.

E	Prothrombin complex concentrate containing factors II, VII, IX and X

Prothrombin complex concentrate is extremely useful for rapidly reversing over-anticoagulation with warfarin, but it is a pooled plasma product and can cause disseminated intravascular coagulation: its use is therefore in life-threatening bleeding associated with over-anticoagulation.

6304

Rate this question:

A 33-year-old woman is admitted to hospital with a 1-week history of dark urine and severe fatigue. On further questioning she admits to increasing tiredness over a matter of weeks.

One day before admission, she developed severe abdominal pain and abdominal distension. On examination, she has pallor, jaundice, an enlarged tender liver and ascites.

Investigations:

Hb	7.9 g/dl
WCC	3.2×10^9/l
Platelets	89×10^9/l
MCV	101 fl
Peripheral smear	Mild polychromasia
AST	144 U/l
ALT	130 U/l
Bilirubin	54 μmol/l
Urine	++

Bilirubin	54 μmol/l
Urine Haemosiderin	++
Urobilinogen	+

Abdominal ultrasound reveals an enlarged liver, ascites and absent flow in the hepatic veins.

What single test would you request to confirm the underlying diagnosis?

A	Viral hepatitis serology
B	Liver biopsy
C	Inherited thrombophilia screen
D	Flow cytometry for CD55 and CD59 expression
E	Glucose-6-phosphate dehydrogenase (G6PD) assay

D Flow cytometry for CD55 and CD59 expression

This patient has paroxysmal nocturnal haemoglobinuria (PNH) complicated by acute hepatic vein thrombosis (Budd–Chiari syndrome). PNH is an acquired clonal disorder of haematopoietic stem cells, characterised by a variable combination of intravascular haemolysis, thrombosis and bone marrow failure. A somatic mutation in the phosphatidylinositol glycan-A (PIG-A) gene on the X chromosome leads to deficiency of several glycosyl-phosphatidylinositol (GPI)-linked molecules. Deficiency of decay accelerating factor (DAF, CD55) and the membrane inhibitor of reactive lysis (MIRL, CD59) increases susceptibility to complement-mediated lysis of blood cells. Currently, diagnosis is made by flow cytometric evaluation of blood, which confirms the CD55 and CD59 deficiencies and deficiency of expression of other GPI-linked proteins. This test is replacing older,

expression of other GPI linked proteins. This test is replacing older, complement-based assays (such as Ham's test and the sucrose lysis test) because it is less affected by blood transfusion, is more sensitive and specific and it measures the size of the PNH clone, which is useful for follow-up.

A	Viral hepatitis serology

This patient does not have viral hepatitis. Although with similar presentation symptoms of fatigue, dark urine, abdominal pain and jaundice, there would not be a disturbance of flow across the hepatic veins or evidence of haemolysis or anaemia.

B	Liver biopsy

A liver biopsy would not be diagnostic for PNH. It may show evidence of scarring or fibrosis. There is a high risk of bleeding with liver biopsies and, with low platelets and altered liver

C	Inherited thrombophilia screen

PNH is an acquired condition. It is not inherited and so would not give a diagnosis of PNH on testing for inherited thrombophilias. It is likely that a thrombophilia screen would be largely negative. One study has shown an increase in anti-phospholipid antibody in some patients with PNH, although it is unsure how this affects the patient.

E	Glucose-6-phosphate dehydrogenase (G6PD) assay

Looking for G6PD deficiency is not appropriate in this instance. G6PD deficiency does produce haemolysis and jaundice but it is an X-linked inherited condition unlike PNH, which is acquired and doesn't affect males and females differently.

8590

Rate this question:

A 34-year-old woman attends the Anticoagulant Clinic as she is on warfarin for recurrent emboli. Her first pulmonary embolus arose after hospitalisation for fixation of a fractured tibia four years previously. She has had at least three further episodes since then. She has not yet had children but wishes to conceive and is concerned about the effects of warfarin.

What is the most appropriate advice for her regarding the possibility of conception and pregnancy?

A	Continue warfarin but change to low-molecular weight heparin within six weeks of conception
B	Replace warfarin with low-dose aspirin and use additional low-molecular weight heparin during the first trimester and the postpartum period

heparin within six weeks of conception

B Replace warfarin with low-dose aspirin and use additional low-molecular weight heparin during the first trimester and the postpartum period

C Switch to aspirin until the birth of the child then revert to warfarin

D Stop warfarin immediately and replace with low-molecular weight heparin

E Stop warfarin and consider low-molecular weight heparin if she has a further thromboembolic event

D Stop warfarin immediately and replace with low-molecular weight heparin

Warfarin is teratogenic and should be avoided in the first trimester of pregnancy. Warfarin not be used before the sixth week of pregnancy to minimise the risk of fetal abnormalities. In an ideal situation stopping warfarin prior to conception could be preferable, but in reality may elevate the risk of thrombotic events (even if heparin was substituted) during an undefined, and possibly long, period while this patient waited to become pregnant because of less good compliance with injectable therapy. As this woman is high risk for further pulmonary emboli, she should be converted to low-molecular weight heparin for the duration of her pregnancy. However, it should be noted that in this difficult clinical situation, for which inadequate evidence is available on which to base clinical decision making, the risk–benefit ratio must be judged on an

benefit ratio must be judged on an individual case basis to some extent.

A Continue warfarin but change to low-molecular weight heparin within six weeks of conception

Warfarin is teratogenic and should be avoided in the first trimester of pregnancy. Warfarin should be stopped before the sixth week of pregnancy to minimise the risk of fetal abnormalities.

B Replace warfarin with low-dose aspirin and use additional low-molecular weight heparin during the first trimester and the postpartum period

As this woman is high risk for further pulmonary emboli, she should be converted to low-molecular weight heparin for the duration of her pregnancy, rather than just during first trimester and postpartum only

pregnancy, rather than just during first trimester and postpartum only.

C	Switch to aspirin until the birth of the child then revert to warfarin

As this woman is high risk for further pulmonary emboli, she should be converted to low-molecular weight heparin for the duration of her pregnancy.

E	Stop warfarin and consider low-molecular weight heparin if she has a further thromboembolic event

As this woman is high risk for further pulmonary emboli, she should be converted to low-molecular weight heparin for the duration of her pregnancy. It would be prudent to prevent a thromboembolic event rather than to treat it when it occurs, as we already know she is high risk.

71094

Rate this question:

A 65-year-old man is admitted to hospital with confusion. His wife says he has been complaining of abdominal pain and, in his confused state, suffered a head injury. He has a background of angina.

Examination is difficult, but unremarkable.

Observations:

Blood pressure	110/60 mmHg
Heart rate	120 bpm, regular

Investigations:

Haemoglobin (Hb)	9.6 g/dl
White blood cells (WBC)	4.9×10^9/l
Platelets (PLT)	360×10^9/l
Sodium (Na^+)	135 mmol/l
Potassium (K^+)	4.6 mmol/l
Urea	12.2 mmol/l
Creatinine (Cr)	132 μmol/l

Urea	12.2 mmol/l
Creatinine (Cr)	132 µmol/l
Calcium	3.6 mmol/l
Electrocardiogram (ECG)	Reduced QT interval

A skull X-ray done in Accident and Emergency shows multiple lytic lesions.

What is the most important initial step?

A	Bendroflumethiazide
B	Furosemide
C	Prednisolone
D	Intravenous (IV) fluids
E	IV bisphosphonate

D Intravenous (IV) fluids

This patient has hypercalcaemia, most likely due to metastatic cancer or multiple myeloma. Patients are described as presenting with bone pain, renal stones, confusion and abdominal pain (bones, stones, psychic moans and abdominal groans). IV fluids can lead to a modest, but relatively rapid, fall in serum calcium, so this would be the first option here.

A Bendroflumethiazide

Thiazide diuretics reduce calcium excretion and are therefore likely to further increase calcium levels in this situation.

B Furosemide

Loop diuretics do reduce serum calcium, but in the presence of dehydration, their use is not advised, and IV fluids are the preferred initial intervention

Loop diuretics do reduce serum calcium, but in the presence of dehydration, their use is not advised, and IV fluids are the preferred initial intervention.

C Prednisolone

Steroids do lower serum calcium, more modestly where there is an underlying solid neoplasm versus a haematological malignancy, but they take a number of hours to do this.

E IV bisphosphonate

IV bisphosphonates are appropriate but take 1–2 days before their use is associated with a significant fall in serum calcium.

33296

Rate this question:

Next Question

A 40-year-old man presented to his GP with fatigue.

Investigations:

Hb	11.2 g/dl
WBC	5.6 x 10^9/l
PLT	360 x 10^9/l
Serum Ferritin	12 µg/l (15-300)

He was commenced on iron sulphate tablets for presumed iron deficiency anaemia. The GP has referred him to the Outpatient Clinic. The patient still feels fatigued, but also complains of numbness and tingling in the lower limbs. He recalls having an operation on his abdomen a few years ago while abroad for severe abdominal pain and upper GI haemorrhage, but cannot recall the specifics of the surgery. Otherwise, he has been fit and well.

Examination reveals pale conjunctivae and a lemon-yellow tinge to his skin. He has slight distal lower limb sensory loss and absence of ankle jerks with

loss and absence of ankle jerks with exaggerated knee reflexes. Abdominal examination shows a longitudinal median scar, but no organomegaly.

Repeat investigations:

Hb	10.4 g/dl
WBC	4.5 x 10^9/l
PLT	250 x 10^9/l
MCV	112 fl

Which operation is he most likely to have had?

A Hemicolectomy

B Terminal ileal resection

C Pancreaticoduodenectomy

D Splenectomy

E Partial gastrectomy

E Partial gastrectomy

The patient has combined iron deficiency and B_{12} deficiency. A gastrectomy can cause this scenario. Gastric acid helps iron in the ferric form to be absorbed by enhancing solubility; without it, iron absorption is therefore reduced. Vitamin B_{12} is best absorbed in the terminal ileum when combined with intrinsic factor, which is produced by gastric parietal cells. Partial gastrectomy is likely to have driven a significant reduction in intrinsic factor production.

A Hemicolectomy

Hemicolectomy should not significantly impact on either B_{12} or ferritin absorption.

B Terminal ileal resection

Although terminal ileal resection does result in B_{12} deficiency and bile salt malabsorption, it should not lead to

Although terminal ileal resection does result in B_{12} deficiency and bile salt malabsorption, it should not lead to significant iron deficiency.

C Pancreaticoduodenectomy

Pancreaticoduodenectomy isn't performed for severe upper GI haemorrhage, but is performed for resectable pancreatic or ampulla of Vater carcinomas.

D Splenectomy

Emergency splenectomy is performed for trauma, not for acute upper GI haemorrhage. It is also not associated with B_{12} or iron deficiency.

7075

Rate this question:

Next Question

A 50-year-old man is referred to clinic by his general practitioner (GP). He recently suffered a fracture of his right humerus, with minimal trauma.

He has been complaining of increasing tiredness over the past few weeks and months and has been unable to continue his job working in a builder's merchants.

Bloods taken at the GP practice prompted his referral:

Haemoglobin (Hb)	8.9 g/dl
White blood cells (WBC)	9.5×10^9/l
Platelets (PLT)	140×10^9/l
Mean corpuscular volume (MCV)	86 fl
Erythrocyte sedimentation rate (ESR)	60 mm/first hour
Sodium (Na^+)	149 mmol/l
Potassium (K^+)	3.6 mmol/l

Urea	15 mmol/l
Creatinine (Cr)	160 µmol/l
Calcium (corrected)	2.89 mmol/l
Albumin	28 g/l
Total protein	89 g/l

An X-ray of the right humerus reported as a possible pathological fracture.

What next investigation would best help to confirm the diagnosis?

A	Chest X-ray
B	Radioisotope bone scan
C	Immunoglobulin electrophoresis
D	Prostate-specific antigen
E	Serum alkaline phosphatase

C Immunoglobulin electrophoresis

The most likely diagnosis with anaemia, raised ESR, hypercalcaemia, renal impairment and raised total protein with low albumin is multiple myeloma. This is a B-cell malignancy, resulting in paraproteinaemia. The diagnosis is confirmed by showing the presence of paraproteins, > 10% of plasma cells in the bone marrow and lytic bone lesions.

A Chest X-ray

The significant elevation in total protein and hypercalcaemia fit much better with multiple myeloma vs an underlying chest malignancy.

B Radioisotope bone scan

Radioisotope bone scans are insensitive, with respect to identifying lytic lesions in myeloma.

Radioisotope bone scans are insensitive, with respect to identifying lytic lesions in myeloma.

D	Prostate-specific antigen

Although a polyclonal increase in immunoglobulins may be seen in patients with prostatic malignancy, the magnitude of increase seen here is much more consistent with a diagnosis of multiple myeloma.

E	Serum alkaline phosphatase

Alkaline phosphatase levels are significantly lower in patients with multiple myeloma vs patients with solid tumour bony metastases.

33298

Rate this question:

Next Question

An 18-year-old Cypriot tourist is admitted to A&E with severe abdominal pain. Over the last few days he had been coughing up green sputum and had pleuritic chest pain. He was given ciprofloxacin for presumed infection. This morning he awoke with sharp, very painful abdominal pain, worst in the epigastric area. No other symptoms. He drinks socially and doesn't smoke.

On examination, he is jaundiced and in pain. His temperature is 39.5 °C, pulse 120 bpm, BP 102/48 mmHg and his respirations are 20 breaths/min. His saturations on room air are 95%. Some crackles and bronchial breathing at the right base can be heard. His abdomen is generally tender on palpation but with no guarding. Chest X-ray shows shadowing at the right lung base; ECG shows sinus tachycardia.

Investigations:

Hb	6.2 g/dl
WCC	17.3×10^9/l
PLT	465×10^9/l

PLT	465×10^9/l
Na^+	136 mmol/l
K^+	4.5 mmol/l
Creatinine	84 µmol/l
Urea	4.5 mmol/l
Glucose	5.7 mmol/l
Albumin	38 g/l
Bilirubin	71 µmol/l
ALT	62 U/l
ALP	124 U/l
Amylase	45 U/l
MCV	97 fl
LDH	1256 U/l
Urine	Urobilinogen+
Blood film	Heinz bodies and bite cells noted

What is the diagnosis?

ALP	124 U/l
Amylase	45 U/l
MCV	97 fl
LDH	1256 U/l
Urine	Urobilinogen+
Blood film	Heinz bodies and bite cells noted

What is the diagnosis?

A	G6PD deficiency
B	Familial Mediterranean fever
C	Atypical pneumonia
D	Acute intermittent porphyria
E	Acute pancreatitis

A G6PD deficiency

G6PD deficiency is the commonest red blood cell enzyme defect. It is a condition that is X-linked recessive in inheritance and is commonly found in Mediterranean and African populations. It is often triggered by infections, certain drugs (including ciprofloxacin), certain foods (including broad beans) and, at times, there can be no identifiable trigger. When exposed to an oxidative crisis there is typically a rapid. Patients are often noted as having anaemia, Heinz bodies on blood film (due to haemolysis), an elevated LDH and reduced haptoglobin levels. The mainstay of treatment is supportive measures. In chronic disease, it may be appropriate to consider a splenectomy.

B Familial Mediterranean fever

Familial Mediterranean fever (FMF) is an autosomal recessive disease that is more commonly found in

A 25-year-old man presented with a 2-month history of drenching night sweats and weight loss of 6 kg. During history taking, he denied any foreign travel, diarrhoea or cough.

Clinical examination revealed a 2 cm lymph node in the right supraclavicular fossa. There was no hepatosplenomegaly.

Investigations:

Hb	11.2 g/l
WCC	5.3 × 109/l (85% neutrophils, 8% eosinophils)
PLT	160 × 10^9/l
CXR	Mediastinal mass (5 cm)
Abdominal ultrasound	Normal

What is the most likely diagnosis?

A Non-Hodgkin's lymphoma

WCC	5.3 × 109/l (85% neutrophils, 8% eosinophils)
PLT	160 × 10^9/l
CXR	Mediastinal mass (5 cm)
Abdominal ultrasound	Normal

What is the most likely diagnosis?

A	Non-Hodgkin's lymphoma
B	Hodgkin's lymphoma
C	Seminoma
D	Thymoma
E	Aspergilloma

33315

B Hodgkin's lymphoma

The incidence of Hodgkin's lymphoma peaks in the age grouos 15–34 and >50 years, whereas non-Hodgkin's lymphoma is much commoner in older patients. For this reason, the clinical picture fits much more closely with Hodgkin's lymphoma. Hodgkin's disease is a neoplasm of lymphoid tissue that is defined histopathologically by the presence of malignant Reed–Sternberg cells with an appropriate cellular background. For an adequate sample of tissue, a formal biopsy is needed, and in this case the most accessible tissue would be from the supraclavicular fossa node. Constitutional symptoms may accompany the diagnosis of Hodgkin's disease. Patients with fever in excess of 38°C, drenching night sweats and weight loss exceeding 10% of baseline body weight during the 6 months preceding diagnosis are designated as having 'B' symptoms.

A typical presentation is the observation, usually by the patient, of

observation, usually by the patient, of a painless, enlarging mass, most often in the neck, but occasionally in the axilla or inguinal-femoral region. In other patients, a chest X-ray demonstrates a moderate or even massive mediastinal enlargement with associated lower cervical lymphadenopathy.

A	Non-Hodgkin's lymphoma

About 85% of all malignant lymphomas are NHLs. The median age at diagnosis is the sixth decade of life, although Burkitt lymphoma and lymphoblastic lymphoma occur in younger patients. Low-grade lymphomas do not usually present with beta symptoms, as opposed to intermediate- and high-grade lymphomas.

C	Seminoma

Seminomas account for one third of testicular germ cell tumours (GCTs), which are the most common

testicular germ cell tumours (GCTs), which are the most common malignancy in men aged 15–35 years. The most common sign at presentation is a painless testicular mass.

D	Thymoma

Of patients with a thymoma, one third to one half are asymptomatic and one third present with local symptoms related to tumour encroachment on surrounding structures. These patients may present with cough, chest pain, superior vena cava syndrome, dysphagia and hoarseness if the recurrent laryngeal nerve is involved. One third of cases are found incidentally on radiographic examinations during a work-up for myasthenia gravis.

E	Aspergilloma

Aspergilloma may manifest as an asymptomatic radiographic abnormality in a patient with pre-existing cavitating lung disease due to

dysphagia and hoarseness if the recurrent laryngeal nerve is involved. One third of cases are found incidentally on radiographic examinations during a work-up for myasthenia gravis.

E	Aspergilloma

Aspergilloma may manifest as an asymptomatic radiographic abnormality in a patient with pre-existing cavitating lung disease due to sarcoidosis, tuberculosis or other necrotising pulmonary processes. It may also occur in cystic areas resulting from prior *Pneumocystis jirovecii* pneumonia in patients with HIV infection. The clinical presentation includes haemoptysis, which may be massive and life-threatening, in 40–60% of patients and, less commonly, cough and fever.

33315

Rate this question:

Next Question

A 62-year-old man has been referred by his GP for investigation of weight loss and night sweats. He has a history of treated hypertension and angina.

Examination reveals painless enlarged bilateral axillary lymph nodes. The other lymph node regions are normal. He also has splenomegaly.

Investigations:

Hb	12.0 g/dl
WBC	4.4×10^9/l
PLT	320×10^9/l
MCV	82 fl
Lymph node biopsy	Reed Sternberg cells with a nodules divided by collagen bands
Staging computed tomography (CT) scan	Axillary lymph nodes and splenomegaly

What is the stage of this disease with

Lymph node biopsy	Reed Sternberg cells with a nodules divided by collagen bands
Staging computed tomography (CT) scan	Axillary lymph nodes and splenomegaly

What is the stage of this disease with regards to the Ann Arbor classification?

A	II A
B	II B
C	III A
D	III B
E	IV

D | III B

This patient is classified as having stage III B Hodgkin's lymphoma because of the presence of axillary lymph nodes, splenomegaly and 'B' symptoms – in this case, significant weight loss coupled with night sweats. Pel–Ebstein fever has been described, where patients have a swinging pyrexia in 1–2–weekly cycles. Characteristically the Reed–Sternberg cell is found on biopsy and there are four subtypes on histology (nodular-sclerosing, mixed cellularity, lymphocyte-depleted, lymphocyte-rich).

E | IV

Extra-nodal involvement, such as involvement of the liver and bone marrow, is required to fulfil the criteria for stage IV disease.

A | II A

The fact there is splenic enlargement

A II A

The fact there is splenic enlargement moves the staging from II to III here, because there is disease on both sides of the diaphragm.

B II B

Although there are B symptoms reported here, the presence of disease above and below the diaphragm means this is stage III rather than stage II disease.

C III A

The presence of significant night sweats and weight loss precipitating presentation to the doctor, means this patient has 'B' disease.

7069

Rate this question:

Next Question

You are asked to review the case of a 68-year-old woman who has had a lengthy dental procedure earlier in the day. She has a background of angina.

Current medications are isosorbide mononitrate and co-trimoxazole for a resistant urinary tract infection. She is complaining of a headache and breathlessness.

Examination shows her to be cyanosed.

Arterial blood gas on a 15 l non-rebreathe O_2 mask:

pH	7.42
P_aO_2	39.2 kPa
P_aCO_2	4.1 kPa
O_2 sats	70%
Portable chest X-ray	Normal appearance

What is the most likely diagnosis?

P_aCO_2	4.1 kPa
O_2 sats	70%
Portable chest X-ray	Normal appearance

What is the most likely diagnosis?

A	Aspiration
B	Carbon monoxide poisoning
C	Methaemoglobinaemia
D	Pulmonary embolism
E	Glucose-6-phosphate dehydrogenase (G6PD) deficiency

7071

Submit

C Methaemoglobinaemia

Haemoglobin carries iron in its ferrous form (Fe^{2+}). When it is converted to the ferric form (Fe^{3+}) methaemoglobin is created. This reduces the red cells' ability to carry oxygen. The body has a normal reparative mechanism involving reduced nicotinamide adenine dinucleotide phosphatase (NADPH), which reduces Fe^{3+} to Fe^{2+}. This mechanism is not fully operational in infants, making them susceptible to methaemoglobinaemia.

Drugs that provide oxidative stress, such as local anaesthetics (especially on mucosae), sulphonamides and nitrates can induce methaemoglobinaemia. Symptoms include headache, confusion, breathlessness and chest pain. Patients are cyanosed with no obvious cardiorespiratory cause, and despite increased oxygen delivery the oxygen saturations remain low. The blood is described as chocolate brown in colour and can be tested for

described as chocolate brown in colour and can be tested for methaemoglobin levels. Treatment is with methylene blue. If unsuccessful, exchange transfusion can be employed.

A Aspiration

Given that the P_aO_2 is reported as 39.2 kPa on 15 l/min, aspiration is very unlikely. There is also no report of any vomiting or possible mechanism for aspiration during the procedure.

B Carbon monoxide poisoning

Carbon monoxide poisoning is not associated with cyanosis, but rather with a cherry red skin coloration.

D Pulmonary embolism

There is no history of chest pain to suggest pulmonary embolism, and it would be extremely unusual to have

B	Carbon monoxide poisoning

Carbon monoxide poisoning is not associated with cyanosis, but rather with a cherry red skin coloration.

D	Pulmonary embolism

There is no history of chest pain to suggest pulmonary embolism, and it would be extremely unusual to have onset of a PE in such a short period after immobility in the dentist's chair.

E	Glucose-6-phosphate dehydrogenase (G6PD) deficiency

We are told this patient has a history of angina and is taking a nitrate. Nitrates may precipitate haemolysis in G6PD deficiency, and theiruse in this patient therefore counts against G6PD and acute haemolysis as a potential cause of her symptoms.

7071

Rate this question:

You are asked to see a 30-year-old man who is undergoing inpatient treatment for acute myeloid leukaemia. He completed combination chemotherapy 6 days ago and was well until this morning when he noticed increasing breathlessness.

On examination, he is pale and clammy, with a high respiratory rate. Pulse is 130 bpm, blood pressure 110/70 mmHg, and his skin is cool to touch. He is slightly drowsy and disorientated. Temperature is 35.6 °C, and he has several crops of black lesions over his arms and legs. A chest X-ray is unremarkable.

Blood tests are shown below:

		Normal values
Haemoglobin (Hb)	73 g/l	
White cell count (WCC)	0.2 × 10^9/l	
Platelets (PLT)	13 × 10^9/l	

Neutrophils	0 × 10^9/l	
Urea	10.3 mmol/l	2.5–7.5

A platelet transfusion is arranged.

Which other measure would you instigate?

A	Biopsy the skin lesions
B	Commence voriconazole
C	Take blood and urine cultures and start antibiotics when results are available
D	Commence broad-spectrum antibiotics with antipseudomonal cover
E	Transfuse packed red cells to maintain Hb level above 100 g/l

D Commence broad-spectrum antibiotics with antipseudomonal cover

This patient is developing septic shock. The black lesions on the skin are ecthyma gangrenosum, a cutaneous manifestation of *Pseudomonas aeruginosa* infection. Given a WCC of 0.2 and neutrophil count of 0, commencement of broad-spectrum antibiotics with antipseudomonal cover, according to local guidelines, is the intervention of choice.

A Biopsy the skin lesions

Invasive procedures, including skin biopsy, should be avoided in patients with neutropenia; in this case, a clinical diagnosis can be made.

B Commence voriconazole

In this situation, antibacterials are usually commenced first, with antifungal cover added in patients who

In this situation, antibacterials are usually commenced first, with antifungal cover added in patients who fail to respond after 48 h.

C	Take blood and urine cultures and start antibiotics when results are available

This risks a significant delay in treating any associated bacterial sepsis and a significantly increased risk of mortality.

E	Transfuse packed red cells to maintain Hb level above 100 g/l

Surviving sepsis guidelines suggest a target of 70 g/l for Hb is adequate.

33295

Rate this question:

Next Question

2:00
https://www.google.com/sea
13

eScholarship

Ecthyma gangrenosum: Presentation in a normal neonate

Figure 1, Figure 2

Images may be subject to copyright. Learn More

RELATED IMAGES SEE MORE

2:00
https://www.google.com/sea
13

Antimicrobe.org

Ecthyma gangrenosum

Osteomyelitis demonstrated clinically and radiographically.

Images may be subject to copyright. Learn More

RELATED IMAGES SEE MORE

What Parents Need to Know a...
chla.org

2:01
https://www.google.com/sea
13

ResearchGate

Multiple ecthyma gangrenosum lesions associated with Pseudo...

Multiple ecthyma gangrenosum lesions associated with Pseudomonas septicemia.

Images may be subject to copyright. Learn More

RELATED IMAGES SEE MORE

A 34-year-old man with a history of minimal change glomerulonephritis presents to the Emergency Department with a swollen right lower leg.

Medication includes ramipril 10 mg daily and furosemide. He has recently spent a few hours on a flight home from Italy.

On examination, he has an obvious right DVT and his BP is 145/82 mmHg.

Investigations:

Hb	13.1 g/dl
WCC	8.2 x 10^9/l
PLT	231 x 10^9/l
Na^+	141 mmol/l
K^+	4.8 mmol/l
Urea	12.1 mmol/l
Creatinine	170 µmol/l
Albumin	23 g/l

Which of the following is the most

K^+	4.8 mmol/l
Urea	12.1 mmol/l
Creatinine	170 μmol/l
Albumin	23 g/l

Which of the following is the most likely cause of his thrombosis?

A	Factor V Leiden mutation
B	Antithrombin III deficiency
C	Protein C deficiency
D	Hyperviscosity due to volume depletion
E	Anti-phospholipid antibody syndrome

21452

Submit

B Antithrombin III deficiency

This patient has significant protein loss and is taking furosemide in an attempt to control the resultant peripheral oedema. Whilst volume depletion increases the risk of peripheral thrombosis, the more likely cause is loss of antithrombin III into his urine because of nephrotic range proteinuria. Management in this case would involve anti-coagulation with warfarin therapy.

A Factor V Leiden mutation

Factor V Leiden is a variant of factor V, which cannot be easily degraded by activated protein C. This leads to hypercoagulability and increased risk of venous thromboembolism.

C Protein C deficiency

No significant reduction in protein C is seen in nephrotic syndrome. Protein C deficiency is genetic, and it is inherited

C	Protein C deficiency

No significant reduction in protein C is seen in nephrotic syndrome. Protein C deficiency is genetic, and it is inherited in autosomal dominant fashion.

D	Hyperviscosity due to volume depletion

Although hyperviscosity due to volume depletion does impact on risk of DVT in patients with nephrotic syndrome, antithrombin III deficiency is likely to have the greater impact here.

E	Anti-phospholipid antibody syndrome

Although co-existent anti-phospholipid antibody syndrome is theoretically possible, it is more likely to be associated with systemic lupus erythematosus.

21452

Rate this question:

A 52-year-old woman presents with lethargy and easy bruising. She has also noticed breathlessness on exertion and has lost 4 kg in weight over the past couple of months. She was treated with curative intent for early-stage breast cancer 5 years ago and has been well since. She is on no medication. There is no other significant previous medical history.

Examination shows a thin woman with bruises on all extremities and pale conjunctiva but is otherwise normal.

Investigations:

Hb	9.9 g/dl
WCC	3.5×10^9/l
PLT	113×10^9/l
Neutrophils	1.0×10^9/l
Reticulocytes	13×10^9/l (25–85 × 10^9/l)
PT	12 s (11.5–15.5s)
aPTT	35 s (30–40)

aPTT	35 s (30–40)
Blood film	Band forms, myelocytes and occasional promyelocytes as well as nucleated red blood cells

What diagnosis would best fit this picture?

A	Acute promyelocytic leukaemia
B	Invasion of bone marrow by breast cancer
C	Myelofibrosis
D	Thrombotic thrombocytopaenic purpura
E	Aplastic anaemia

B Invasion of bone marrow by breast cancer

The patient's blood tests show a leucoerythroblastic anaemia (left-shifted granulocytic series and nucleated red blood cells) with pancytopaenia. This can be seen with high bone marrow turnover, e.g. in severe haemolytic anaemia (in which case the reticulocyte count would be high), myelofibrosis and chronic myeloid leukaemia or bone marrow invasion. Often in bone marrow invasion the invading malignancy will already have been diagnosed previously, i.e. breast cancer in this case. The diagnosis requires a bone marrow trephine, which will usually show replacement of haematopoietic tissue with malignant cells.

A Acute promyelocytic leukaemia

In APML, which is a subtype of acute myeloid leukaemia, the blood film would show myeloblasts with Auer

There would usually be a raised platelet count and either leukopaenia or leucocytosis with myelofibrosis. A blood film would show a leuco-erythroblastic picture but be associated with teardrop poikilocytes. Splenomegaly is often present on examination.

D	Thrombotic thrombocytopaenic purpura

TTP presents with neurological and psychological disturbances, thrombocytopenia, reduced renal function and haemolytic anaemia. Schistocytes or helmet cells are seen on a blood film.

E	Aplastic anaemia

Aplastic anaemia does cause pancytopenia but does not show a leuco-erythroblastic blood film. It is a result of haemopoietic stem cell failure in the bone marrow.

A 70-year-old man presents with a 200 ml fresh haematemesis. He is managed with long-term warfarin therapy for chronic atrial fibrillation and is usually on a stable dose of 4 mg per day.

Most recently, he has been prescribed a course of ciprofloxacin for a dental abscess.

On admission, his BP is 100/65 mmHg, with a pulse of 110/min.

Investigations:

Hb	10.0 g/dl
WCC	4.9×10^9/l
PLT	120×10^9/l
Na^+	139 mmol/l
K^+	5.9 mmol/l
Creatinine	185 µmol/l
INR	8.7 (<1.4)

Which of the following is most appropriate to reverse his

Na^+	139 mmol/l
K^+	5.9 mmol/l
Creatinine	185 μmol/l
INR	8.7 (<1.4)

Which of the following is most appropriate to reverse his coagulopathy?

A	Recombinant factor VIIa
B	FFP
C	Prothrombin complex concentrate (PCC)
D	IV vitamin K
E	Protamine sulphate

20633

Submit

C Prothrombin complex concentrate (PCC)

This patient is in significant danger of massive haemorrhage and circulatory collapse. Intervention with PCC, targeted at rapidly reversing warfarin specifically, is therefore the intervention of choice.

A Recombinant factor VIIa

Recombinant factor VIIa has a role in partial reversal of factor Xa anticoagulants rather than warfarin. It may also have a role in treatment of patients with acquired haemophilia.

B FFP

FFP is less effective in reversing anticoagulation than PCC; it is therefore the default choice only when PCC is not available.

D IV vitamin K

patients with acquired haemophilia.

B	FFP

FFP is less effective in reversing anticoagulation than PCC; it is therefore the default choice only when PCC is not available.

D	IV vitamin K

IV vitamin K does reverse warfarin-related coagulopathy, although its onset of action is much slower versus PCC.

E	Protamine sulphate

Protamine sulphate is given as the antidote for excess heparinisation.

20633

Rate this question:

Next Question

A 72-year-old man attends clinic for investigation of anaemia. He has noticed occasional episodes of dark urine, especially in the morning. He reports that he recently was admitted and treated for a portal vein thrombosis, and he now takes regular dalteparin. Other than that, he takes gliclizide for diabetes.

Examination reveals pale conjunctivae; his blood pressure is 132/89 mmHg, with pulse 75 and regular. Heart sounds are normal, the abdomen is soft and non-tender, and he has soft calves bilaterally.

Investigations:

Hb	11.2 g/dl (135–180)
WBC	3.9×10^9/l (4.0–11.0)
PLT	150×10^9/l (150–450)
Plasma haptoglobin	0.09 g/l (0.3–2.0)
PT	12s (11–14)
APTR	35 s (24–37)

soft and non-tender, and he has soft calves bilaterally.

Investigations:

Hb	11.2 g/dl (135–180)
WBC	3.9×10^9/l (4.0–11.0)
PLT	150×10^9/l (150–450)
Plasma haptoglobin	0.09 g/l (0.3–2.0)
PT	12s (11–14)
APTR	35 s (24–37)
INR	1.0 (0.7–1.3)
Bilirubin	45 μmol/l (3–17)
ALT	25 IU/l (<40)
ALP	55 IU/l (40–130)
GGT	25 IU/l (10–50)
Albumin	39 g/l (35–50)
Morning urine	Haemoglobin and haemosiderin present

What is the most likely diagnosis?

ALP	55 IU/l (40–130)
GGT	25 IU/l (10–50)
Albumin	39 g/l (35–50)
Morning urine	Haemoglobin and haemosiderin present

What is the most likely diagnosis?

A	Chronic lymphocytic leukaemia
B	Bladder cancer
C	Paroxysmal nocturnal haemoglobinuria
D	Glucose-6-phosphate dehydrogenase deficiency
E	Acute liver failure

C Paroxysmal nocturnal haemoglobinuria

This patient has evidence of intravascular haemolysis – low haptoglobins, haemoglobin and haemosiderin in the urine and a raised bilirubin. If tested, his LDH would also be raised. This haemolysis has resulted in anaemia. He has also had a recent thrombosis in a rare location. He describes dark urine, which could be associated with any haemolytic disorder; however, the fact that the dark urine occurs in the morning, in the context of haemolysis and unusual thrombosis, points towards paroxysmal nocturnal haemoglobinuria (PNH).

PNH is a very rare acquired disorder associated with glycophosphatidylinositol deficiency, which results in the absence of certain red cell membrane proteins, namely CD55 and CD59. This leaves the cells prone to haemolysis, resulting in the

CD55 and CD59. This leaves the cells prone to haemolysis, resulting in the classical early morning 'Coca-Cola'-coloured urine (as this is when the urine is most concentrated). It is also associated with thrombosis, particularly in unusual locations such as the portal vein, mesenteric veins or hepatic vein (Budd–Chiari syndrome).

Diagnostic investigations would include flow cytometry to identify the absence of CD55 and CD59 on the red cell surface. Bone marrow aspiration and trephine is useful to classify PNH (i.e. in the absence or in the setting of another bone marrow disorder). The Ham test, looking at red cell fragility in acid, is no longer used due to its low specificity. Referral to the Haematology Registrar would be the most appropriate first step.

A	Chronic lymphocytic leukaemia

Chronic lymphocytic leukaemia (CLL) would be associated with a low

A 55-year-old gentleman complained of a 2-month history of lower back pain. He had been feeling increasingly tired over the last few months and had noted weight loss of 1 stone. He had also noted some tingling in his hands and feet.

On examination, he was found to have gynaecomastia, a palpable 2 cm liver edge and peripheral oedema. There was evidence of loss of pinprick and joint position sense to the mid-shins bilaterally, and diffuse hyperpigmentation of the extremities.

Investigations:

Hb	9.6 g/dl
WCC	5.4 × 109/l
PLT	130 × 109/l
MCV	86 fl
Total protein	95 g/l
Albumin	30 g/l
Fasting Glucose	11 mmol/l

Fasting Glucose	11 mmol/l
Thyrotropin	7.5 mU/l (0.5–5.5 mU/l)
Thyroxine (total free)	50 nmol/l (75–150 nmol/l)

What diagnosis best explains the patient's presentation?

A	Non Hodgkin's lymphoma
B	Waldenstrom's macroglobulinaemia
C	Classical multiple myeloma
D	Polyneuropathy, organomegaly, endocrinopathy, monoclonal gammopathy and skin changes syndrome (POEMS)
E	Chronic lymphocytic leukaemia

D Polyneuropathy, organomegaly, endocrinopathy, monoclonal gammopathy and skin changes syndrome (POEMS)

POEMS syndrome is a rare multi-system disease that occurs in the setting of plasma cell dyscrasia. The pathophysiology of the disease is not known; however, elevated levels of cytokines and growth factors have been implicated.

The polyneuropathy associated with POEMS syndrome is a bilateral symmetric disturbance. It involves both motor and sensory nerves, begins distally and has a progressive proximal spread. Associated cranial or autonomic nerves are not involved. Both demyelination and axonal degeneration are noted. The liver, the lymph nodes, and the spleen are the organs most frequently involved.

Multiple endocrinopathies have been associated with POEMS syndrome, and

associated with POEMS syndrome, and most patients have more than one endocrine abnormality. POEMS syndrome is seen in the setting of a plasma cell dyscrasia. Although many plasma cell disorders have been reported in patients with POEMS syndrome, most patients are seen with osteosclerotic myeloma or monoclonal gammopathy of unknown significance (MGUS). Classic multiple myeloma is not usually associated with the disease.

A	Non Hodgkin's lymphoma

Most patients present with lymphadenopathy. Indermediate- or high-grade lymphomas can also be accompanied by beta symptoms (weight loss, temperature >38 °C, night sweats).

B	Waldenstrom's macroglobulinaemia

This is usually accompanied by

This usually presents with bone pain, pathological fractures, weakness, anaemia, infection (often pneumococcal), hypercalcaemia, spinal cord compression or kidney disease. It can also be accompanied by hyperviscosity syndrome (mucosal bleeding, visual changes and neurological symptoms).

E	Chronic lymphocytic leukaemia

Patients with chronic lymphocytic leukaemia (chronic lymphoid leukaemia, CLL) present with a wide range of symptoms and signs. Onset is insidious, and it is not unusual for CLL to be discovered incidentally after a blood cell count is performed for another reason; 25–50% of patients will be asymptomatic at time of presentation.

Other signs include lymphadenopathy, hepatospenomegaly, petechiae due to low platelet count, and pallor due to anaemia.

A 50-year-old man presents with fatigue. Two years ago, the patient received six cycles of combination therapy (each cycle consisted of cyclophosphamide, doxorubicin, vincristine and prednisolone) for non-Hodgkin's lymphoma in chest and abdominal sites.

The patient entered complete remission and has been followed expectantly since that point. His last visit was 3 months ago, at which time he had no evidence of recurrent lymphoma, felt well and had normal laboratory examination.

This time, his physical examination is remarkable for a purple discoloration of the fingertips, ears and nose. The patient is somewhat pale. There is no peripheral lymphadenopathy.

WCC	10×10^9/l (Neutrophils 7, lymphocytes 1, eosinophils 0.3, basophils 0.1, metamyelocytes 0.2, myelocytes 0.1 and nucleated red cells 0.1)

Haematocrit	28%
Hb	8.7 g/dl
Platelets	300 x 10^9/l
MCV	98 fl
LDH	400 U/l
Total bilirubin	51μmol/l (1–22)
Conjugated bilirubin	0.5 μmol/l (0–0.4)
Peripheral blood smear	Clumped cells
Polyspecific sera	+ for complement components

Which of the following is most likely to be expected on further testing?

A	Positive direct Coombs' test (using anti-IgG antiserum) if the specimen is processed without allowing cooling

Which of the following is most likely to be expected on further testing?

A	Positive direct Coombs' test (using anti-IgG antiserum) if the specimen is processed without allowing cooling
B	Positive indirect Coombs' test detected with anti-IgG antibodies
C	Circulating antibodies against Epstein–Barr virus
D	Circulating antibodies against red cells bearing the I antigen
E	Circulating antibodies against *Mycoplasma pneumoniae*

7709

Submit

remarkable for a purple discoloration of the fingertips, ears and nose. The patient is somewhat pale. There is no peripheral lymphadenopathy.

WCC	10 x 10^9/l (Neutrophils 7, lymphocytes 1, eosinophils 0.3, basophils 0.1, metamyelocytes 0.2, myelocytes 0.1 and nucleated red cells 0.1)
Haematocrit	28%
Hb	8.7 g/dl
Platelets	300 x 10^9/l
MCV	98 fl
LDH	400 U/l
Total bilirubin	51μmol/l (1–22)
Conjugated bilirubin	0.5 μmol/l (0–0.4)
Peripheral blood smear	Clumped cells

D Circulating antibodies against red cells bearing the I antigen

This patient has cold-reactive haemolysis or cold agglutinin disease. If patients develop circulating anti-IgM antibodies with specificity for polysaccharide antigens on red cell membranes, they may suffer from so-called 'cold-reactive haemolysis'. The clinical manifestations of presence of such antibodies are haemolysis, which is generally not severe and a mild elevation of the reticulocyte count, agglutination of red cells, and an increased rate of haemolysis at temperatures below 37°C. A second clinical manifestation of cold haemolysis is the presence of acrocyanosis, characterized by marked purple discoloration of the extremities, ears and nose during cooling. IgM antibodies may be missed if the blood is allowed to cool after it is drawn because of absorption onto the patient's own red blood cells and subsequent removal as the blood clots. Therefore, the blood should be allowed

to clot at a warm temperature. Serological analysis will reveal a positive direct Coombs' test if anti-C3 antiserum is used. The specificity of cold agglutinin antibody may be helpful in that a reaction with adult red cells compared with fetal blood is more common in benign lymphoproliferative disorders. On the other hand, antibodies that react more strongly with fetal cells compared with adult red cells are called anti-i and are generally seen in lymphomas and in infectious mononucleosis. This patient may well have recurrence of his lymphoma, which is presenting as cold haemolytic disease because of the presence of monoclonal IgM antibody. The problem is best treated with anti-lymphoma therapy.

B	Positive indirect Coombs' test detected with anti-IgG antibodies

Indirect Coombs' testing is mainly used in cross-matching for blood transfusions or prenatal testing for

transfusions or prenatal testing for serum IgG antibodies that may cross the placenta and cause haemolytic disease of the newborn.

A	Positive direct Coombs' test (using anti-IgG antiserum) if the specimen is processed without allowing cooling

A direct Coombs' test will be only positive with anti-C3 serum for cold reactive haemolysis, because the auto-antibody is IgG-complement based and, in cold temperatures, IgG causes complement to irreversibly bind to red blood cells.

C	Circulating antibodies against Epstein–Barr virus

EBV can cause autoimmune haemolysis. IgG antibodies to EBV show a previous infection, a positive IgM antibodies show a current infection. Complement components would not be positive in this case.

EBV can cause autoimmune haemolysis. IgG antibodies to EBV show a previous infection, a positive IgM antibodies show a current infection. Complement components would not be positive in this case. Blood film in EBV would show 50% lymphocytes and 10% atypical lymphocytes.

E	Circulating antibodies against *Mycoplasma pneumoniae*

Gold standard testing for mycoplasma pneumoniae is having two positive IgM or IgG results 2-4 weeks apart, as a single positive may be the result of a recent previous infection and some people do not mount an immune response. Patients usually have non-specific flu-like or cold-like symptoms. Many patients will have a leucocytosis and some have a raised ESR.

7709

Rate this question:

Next Question

A 65-year-old man is admitted with dehydration following an attack of infectious gastritis.

His initial blood results revealed a raised calcium and erythrocyte sedimentation rate. He has a background of hypertension, angina, chronic obstructive airways disease and diabetes.

His most recent results arrive on the ward:

Hb	13.8 g/dl
WCC	7.7×10^9/l
PLT	212×10^9/l
Na^+	138 mmol/l
K^+	4.7 mmol/l
Creatinine	104 μmol/l
Urea	7.2 mmol/l
Ca^{2+}	2.4 mmol/l
Albumin	38 g/l
	19 g/l (6.0–13.0,

IgG	19 g/l (6.0–13.0, monoclonal band identified)
IgA	2.1 g/l (0.8–3.0)
IgM	1.3 g/l (0.4–2.5)
Urine, Bence Jones protein	-
Chest X-ray	Heart and mediastinal contours normal, lungs clear, osteopenia of bony skeleton with no lytic lesions

What is the most likely diagnosis?

A	Monoclonal gammopathy of undetermined significance
B	Multiple myeloma
C	Waldenström's macroglobulinaemia

protein	
Chest X-ray	Heart and mediastinal contours normal, lungs clear, osteopenia of bony skeleton with no lytic lesions

What is the most likely diagnosis?

A	Monoclonal gammopathy of undetermined significance
B	Multiple myeloma
C	Waldenström's macroglobulinaemia
D	Inflammatory amyloidosis
E	Chronic lymphocytic leukaemia

Albumin	38 g/l
IgG	19 g/l (6.0–13.0, monoclonal band identified)
IgA	2.1 g/l (0.8–3.0)
IgM	1.3 g/l (0.4–2.5)
Urine, Bence Jones protein	-
Chest X-ray	Heart and mediastinal contours normal, lungs clear, osteopenia of bony skeleton with no lytic lesions

What is the most likely diagnosis?

Your answer was correct

A Monoclonal gammopathy of undetermined significance

A Monoclonal gammopathy of undetermined significance

monoclonal gammopathy of undetermined significance (MGUS), which is a monoclonal paraproteinaemia without evidence of disorders such as myeloma, Waldenström's macroglobulinaemia or amyloidosis. It is usually picked up incidentally. There is mild increase in a serum monoclonal protein without paresis of the other monoclonal bands. The presence of anaemia, hypercalcaemia, kidney disease or lytic bone lesions points towards myeloma. The initial raised calcium is most likely to have been related to dehydration. In MGUS the urine does not contain Bence Jones protein. These patients need to be followed up as they are at increased risk of developing myeloma. A bone marrow biopsy should reveal <10% plasma cells and a skeletal survey should reveal no lytic lesions to be compatible with MGUS.

B	Multiple myeloma

Multiple myeloma is associated with evidence of end-organ damage, where for example elevated creatinine would be expected. A greater increase in the monoclonal gammopathy may also be expected.

C	Waldenström's macroglobulinaemia

Waldenström's macroglobulinaemia is associated with elevated IgM and with hyperviscosity rather than the features seen here.

D	Inflammatory amyloidosis

In inflammatory amyloidosis a polyclonal increase in immunoglobulins would be expected against a background of chronic inflammatory disease.

E	Chronic lymphocytic leukaemia

A 38-year-old woman, who had a deep vein thrombosis (DVT) during pregnancy 10 years previously, attends her general practitioner (GP) as she is due to fly to Australia and has been reading in the newspapers about 'traveller's thrombosis' and 'economy class syndrome'.

She is not currently on any medication, except for the combined oral contraceptive pill; she has a past medical history of fibromyalgia and irritable bowel syndrome, smokes 20 cigarettes per day and drinks 20 units of alcohol per week.

The GP performs a thrombophilia screen, shown below:

Protein C	90 iu/dl (80–135)
Protein S	85 iu/dl (80–120)
Antithrombin III	80 iu/dl (80–120)
Activated protein C resistance	3.2 (2.12–4.0)

	120)
Activated protein C resistance	3.2 (2.12–4.0)
D-dimer	0.3 mg/l (< 0.5 mg/l)

The GP then contacts you with the results, and asks what he should give her for her journey.

What management do you recommend for this patient?

A	Aspirin
B	Warfarin
C	Low-molecular weight heparin
D	Regular ankle and calf exercises only
E	Graduated compression stockings

A 38-year-old woman, who had a deep vein thrombosis (DVT) during pregnancy 10 years previously, attends her general practitioner (GP) as she is due to fly to Australia and has been reading in the newspapers about 'traveller's thrombosis' and 'economy class syndrome'.

She is not currently on any medication, except for the combined oral contraceptive pill; she has a past medical history of fibromyalgia and irritable bowel syndrome, smokes 20 cigarettes per day and drinks 20 units of alcohol per week.

The GP performs a thrombophilia screen, shown below:

Protein C	90 iu/dl (80–135)
Protein S	85 iu/dl (80–120)
Antithrombin III	80 iu/dl (80–120)
Activated protein C	

E Graduated compression stockings

There has recently been considerable media interest in the risk of blood clots triggered by air flights. A study from North America indicated that the risk of a fatal blood clot after a transatlantic flight is < 1 in a million. Additional studies indicate that the greatest risk of a blood clot is when there are additional risk factors such as surgery in the previous few weeks. The risk is related to the duration of travel, with the lowest risk for journeys of < 6 h. This particular patient has a moderate risk for DVT, as she had a DVT in the past. She is also on an oral contraceptive and smokes cigarettes, both of which increase her risk from low to moderate.

Classification of risk category and suggested precautions for continuous journeys lasting > 6 h are as follows:

Low risk:

- no history of DVT or pulmonary

Low risk:

- no history of DVT or pulmonary embolism (PE)
- no surgery in the previous 4 weeks
- no other risk factors.

Recommendations:

- Do not take excessive alcohol or sleeping tablets.
- Regularly flex the ankles to contract the calf muscles.

Moderate risk:

- previous history of DVT (or PE)
- surgery under general anaesthesia (GA) lasting > 30 minutes in the previous 2 months but not in the last 4 weeks
- pregnant or postpartum
- cardiac disease or other major acute illness (eg pneumonia)

acute illness (eg pneumonia)
- oral contraceptives or hormone replacement therapy
- obesity
- family history of first-degree relative with VTE
- polycythaemia
- lower limb fracture in a plaster cast.

Recommendations:

- Do not take excessive alcohol or sleeping tablets.
- Regularly flex the ankles to contract the calf muscles.
- Wear graduated compression travel stockings.

High risk:

- surgery under GA lasting > 30 minutes in the previous 4 weeks
- active cancer
- known thrombophilia

High risk:

- surgery under GA lasting > 30 minutes in the previous 4 weeks
- active cancer
- known thrombophilia.

Recommendations:

- Assess suitability for long-haul flights.
- Do not take excessive alcohol or sleeping tablets.
- Regularly flex the ankles to contract the calf muscles.
- Wear graduated compression travel stockings.
- Consider a single injection of LMWH before departure, and ensure there is enough for the flight back.

D Regular ankle and calf

D Regular ankle and calf exercises only

This is recommended for patients who are low risk. This patient is moderate risk and is recommended to do the ankle and calf exercises regularly, as well as wearing graduated compression stockings. Calf and ankle exercises should be undertaken by all people travelling on long-haul flights, in addition to other recommendations by their medical doctor.

A Aspirin

Aspirin is not recommended as venous thromboembolism (VTE) treatment or prophylaxis. There is controversial evidence available for the use of aspirin in VTE prevention. There have been a few studies that showed it is not inferior to low-molecular-weight heparin (LMWH) for post-operative orthopaedic patients. In the case of this patient, however, she is moderate risk, and therefore, drug treatment is

heparin (LMWH) for post-operative orthopaedic patients. In the case of this patient, however, she is moderate risk, and therefore, drug treatment is not recommended.

B	Warfarin

Warfarin is used in the case of established VTE, and not as prevention. Regardless, in the case of this patient, however, she is moderate risk, and therefore, drug treatment is not recommended.

C	Low-molecular weight heparin

LMWH is used as a one-off dose pre-flight for patients who have a high risk for developing VTE. This patient is moderate risk and therefore does not require LMWH.

8546

Rate this question:

An 18-year-old single man is referred who suffers recurrent oesophageal candidiasis. He has a background medical history of asthma treated with inhaled steroids and eczema.

Labs show no B cells and reduced immunoglobulins, CD4 T-lymphocyte count is normal and platelet count is reduced.

What diagnosis fits best with this clinical picture?

A	Chronic myeloid leukaemia
B	HIV infection
C	Inappropriate inhaler use
D	Infectious mononucleosis
E	Primary immunodeficiency

An 18-year-old single man is referred who suffers recurrent oesophageal candidiasis. He has a background medical history of asthma treated with inhaled steroids and eczema.

Labs show no B cells and reduced immunoglobulins, CD4 T-lymphocyte count is normal and platelet count is reduced.

What diagnosis fits best with this clinical picture?

Your answer was correct

A	Chronic myeloid leukaemia
B	HIV infection
C	Inappropriate inhaler use
D	Infectious mononucleosis
E	Primary immunodeficiency

E	Primary immunodeficiency

Wiskott–Aldrich syndrome is an X-linked disorder associated with eczema and thrombocytopenia, associated with reduced levels of immunoglobulins. Patients often suffer from associated autoimmune disorders and are at increased risk of lymphoreticular malignancy.

A	Chronic myeloid leukaemia

CML has a tri- or biphasic clinical course: a chronic phase, which is present at the time of diagnosis in approximately 85% of patients; an accelerated phase, in which neutrophil differentiation becomes progressively impaired and leukocyte counts are more difficult to control with treatment; and blast crisis, a condition resembling acute leukaemia in which myeloid or lymphoid blasts proliferate in an uncontrolled manner. The peripheral smear typically demonstrates a leukocytosis with a median white count of approximately

demonstrates a leukocytosis with a median white count of approximately 10 × 109 mmol/l. The WBC differential typically shows virtually all cells of the neutrophilic series, from myeloblasts to mature neutrophils with peaks in the percentages of myelocytes and segmented neutrophils. Blasts typically account for <2%. The presence of a greater percentage of myelocytes than the more mature metamyelocytes ('leukemic hiatus' or 'myelocyte bulge') is one of the classic findings in CML. The granulocytes of the chronic phase are morphologically normal with no evidence of dysplasia, but dysplasia can develop in more advanced disease, and particularly in the accelerated phase. The blood picture in this scenario is not consistent with CML.

B	HIV infection

The normal CD4 count makes AIDS less likely as the cause in this case.

C	Inappropriate inhaler use

C	Inappropriate inhaler use

Inappropriate inhaler use will not provide an explanation for the blood picture here.

D	Infectious mononucleosis

Infectious mononucleosis (IM) is characterised by a triad of fever, tonsillar pharyngitis and lymphadenopathy. The most common laboratory finding in association with infectious mononucleosis (IM) is lymphocytosis, defined as an absolute count >4500/microl or, on peripheral smear, a differential count >50%. The smear may also identify significant atypical lymphocytosis, defined as >10% of total lymphocytes. The majority of reactive lymphocytes in patients with IM are CD8+ cytotoxic T cells. In one study, the severity of illness correlated with the magnitude of CD8+ lymphocytosis (as well as with blood Epstein–Barr viral (EBV) load). The blood picture in this scenario is not consistent with IM.

A 24-year-old woman presented to the Emergency Department with an 18 h history of a severe headache, right-sided hemiparesis and new-onset grand mal seizures. She denied taking any medication or recreational drugs.

She had a temperature of 37.6 °C, pulse 120 bpm, sinus rhythm and a blood pressure of 110/80 mmHg.

Investigations:

Hb	6.4 g/dl
WCC	10.0×10^9/l
PLT	10.0×10^9/l
INR	1.3
APTT	26 s (25–41)
Creatinine	150 μmol/l
Urea	10.0 mmol/l
Bilirubin	90 μmol/l
AST	21 U/l
ALT	25 U/l
LDH	3200 U/l

Urea	10.0 mmol/l
Bilirubin	90 µmol/l
AST	21 U/l
ALT	25 U/l
LDH	3200 U/l

What is the most likely unifying diagnosis?

A	Idiopathic thrombocytopenic purpura
B	Disseminated intravascular coagulation
C	Thrombotic thrombocytopenic purpura
D	Haemolytic uraemic syndrome
E	Cocaine abuse

C Thrombotic thrombocytopenic purpura

Thrombotic thrombocytopenic purpura (TTP) is a life-threatening multi-system disorder characterised by micro-angiopathic haemolytic anaemia, thrombocytopenia, neurological abnormalities, fever and renal dysfunction. With the introduction of plasma exchange, the survival rate has improved from approximately 3% prior to the 1960s to 82% now. Platelet transfusions are contraindicated. Fresh-frozen plasma, methylprednisolone and red cell support are all important additional supportive measures.

A Idiopathic thrombocytopenic purpura

Idiopathic thrombocytopenic purpura (ITP), also known as primary immune thrombocytopenic purpura and autoimmune thrombocytopenic purpura, is defined as isolated thrombocytopenia with normal bone

thrombocytopenia with normal bone marrow in the absence of other causes of thrombocytopenia.

B	Disseminated intravascular coagulation

Disseminated intravascular coagulation (DIC) is a complex systemic thrombo-haemorrhagic disorder involving the generation of intravascular fibrin and the consumption of procoagulants and platelets. It is seen in association with a number of well-defined clinical situations, including sepsis, major trauma and abruptio placenta. It is associated with prolonged clotting times, low fibrinogen, raised fibrin degradation products and thrombocytopenia.

D	Haemolytic uraemic syndrome

Haemolytic uraemic syndrome (HUS) is characterised by acute kidney disease, micro-angiopathic haemolytic anaemia, fever and thrombocytopenia

E	Cocaine abuse

Cocaine is a complex drug that can cause lethal cardiovascular events, including myocardial infarction and ventricular arrhythmias. The exact mechanism of cocaine-related stroke remains unclear, and there are likely to be a number of factors involved. There does not appear to be any direct neurotoxic action, and potential mechanisms involved in cocaine induced stroke include vasospasm, cerebral vasculitis, enhanced platelet aggregation, cardio-embolism and hypertensive surges associated with altered cerebral autoregulation and cerebral blood flow. Cocaine use is associated with both intracerebral haemorrhage and subarachnoid haemorrhage. As with ischaemic stroke, the exact mechanism involved is not fully understood, though may involve cocaine-induced haemodynamic changes in susceptible individuals

A 35-year-old alcoholic is admitted after an upper GI haemorrhage. An endoscopy is performed soon after admission with variceal banding, but you are asked to see him the following morning as he is drowsy and confused.

On examination, his BP is 100/60 mmHg, pulse is 75/min and regular and his temperature is 36.5°C. He is mildly tender in the epigastrium and there is evidence of ascites. He is very drowsy and appears confused when you wake him from sleep. PR reveals melaena.

Investigations:

Hb	9.1 g/dl
WCC	10.5×10^9/l
PLT	131×10^9/l
Na^+	128 mmol/l
K^+	5.1 mmol/l
Creatinine	122 micromol/l
CRP	17 mg/l
Albumin	23 g/l

Creatinine	122 micromol/l
CRP	17 mg/l
Albumin	23 g/l
ALT	231 U/l
Glucose	5.9 mmol/l

Which of the following is most likely to reveal the cause of his confusion?

A Serum ammonia

B Ascitic tap

C Blood cultures

D CT head

E Lumbar puncture

37191

Submit

A Serum ammonia

The fact that the increased confusion has occurred following the upper GI bleed is suggestive that blood ingestion has led to increased ammonia production by the bacteria within the GI tract. Strategies to reduce bacterial ammonia production include use of neomycin and lactulose.

B Ascitic tap

Spontaneous bacterial peritonitis is potentially one of the differential diagnoses in a case of confusion in a patient with decompensated alcoholic liver disease; in the current situation, however, the onset of confusion soon after the GI bleed points towards the blood ingestion and ammonia production as the likeliest cause.

C Blood cultures

Sepsis is a potential cause of confusion, but in this scenario there is

C Blood cultures

Sepsis is a potential cause of confusion, but in this scenario there is no evidence for it, either from the physical examination/observations or from the blood results.

D CT head

A subdural haematoma could be another cause for confusion, but in our case there is no history of fall or head injury.

E Lumbar puncture

Neither the history nor the blood results support the diagnosis of meningitis/encephalitis.

37191

Rate this question:

Next Question

You are called urgently to see a 60-year-old man with an acute blood transfusion reaction. The patient had a total hip replacement the previous day and had just started a routine blood transfusion when he complained of feeling faint and breathless.

Examination shows an unwell, breathless man: pulse 120 bpm, blood pressure 70 mmHg systolic, respiratory rate 35 breaths/min, temperature 38.9 °C, Glasgow Coma Scale (GCS) score 13/15. There is widespread wheeze on auscultation of the chest. The patient's blood group is group A rhesus-negative; the blood transfusion is group O rhesus-negative.

What is the most likely cause of this patient's deterioration?

A	Bacterial contamination of the unit of blood
B	Transfusion related acute lung injury (TRALI)

blood group is group A rhesus-negative; the blood transfusion is group O rhesus-negative.

What is the most likely cause of this patient's deterioration?

A	Bacterial contamination of the unit of blood
B	Transfusion related acute lung injury (TRALI)
C	Acute intravascular haemolysis due to inappropriate ABO crossmatching
D	Acute transfusion reaction due to donor cytokines
E	Acute intravascular haemolysis due to inappropriate Kell crossmatching

total hip replacement the previous day and had just started a routine blood transfusion when he complained of feeling faint and breathless.

Examination shows an unwell, breathless man: pulse 120 bpm, blood pressure 70 mmHg systolic, respiratory rate 35 breaths/min, temperature 38.9 °C, Glasgow Coma Scale (GCS) score 13/15. There is widespread wheeze on auscultation of the chest. The patient's blood group is group A rhesus-negative; the blood transfusion is group O rhesus-negative.

What is the most likely cause of this patient's deterioration?

Your answer was incorrect

A	Bacterial contamination of the unit of blood
B	Transfusion related acute lung injury (TRALI)
C	Acute intravascular

A Bacterial contamination of the unit of blood

Bacterial contamination is a possibility, although this is very rare with red cell transfusions and more common with platelet transfusions (which are stored at room temperature). However, if such contaminated blood is stored for a few days at room temperature (eg platelets) or for a few weeks at refrigerated temperature (eg red cells), bacteria may grow and elaborate endotoxin, which is a major adverse factor in such reactions and drives the acute presentation seen here.

D Acute transfusion reaction due to donor cytokines

When patients donate blood at the time of viral infection, increased levels of inflammatory cytokines may be present in the donated unit. These usually cause mild pyrexia, rather than the acute symptoms seen here.

TRALI is associated with acute-onset non-cardiogenic pulmonary oedema; it is thought to be related to donor antibodies to human leukocyte antigens, which drive neutrophil activation.

C	Acute intravascular haemolysis due to inappropriate ABO crossmatching

Immunoglobulin M (IgM) anti-A and anti-B antibodies cause acute haemolytic transfusion reactions, and as little as 4 ml of transfused ABO-incompatible blood can be fatal. As far as we are aware, the labelling of the blood as O rhesus-negative means that an acute transfusion reaction should not be seen.

E	Acute intravascular haemolysis due to inappropriate Kell crossmatching

immunoglobulin M (IgM) anti-A and anti-B antibodies cause acute haemolytic transfusion reactions, and as little as 4 ml of transfused ABO-incompatible blood can be fatal. As far as we are aware, the labelling of the blood as O rhesus-negative means that an acute transfusion reaction should not be seen.

E	Acute intravascular haemolysis due to inappropriate Kell crossmatching

Delayed haemolytic transfusion reactions are more likely to be seen in patients with inappropriate Kell crossmatching, rather than the acute presentation seen here. In addition, Kell positivity is relatively rare in the Caucasian population (approximately 9%) and is done as part of a standard crossmatch panel.

33293

Rate this question:

Next Question

A 28-year-old woman is brought to the Emergency Department by her husband. She has had a fever and abdominal pain for four days and has been complaining of a headache for the past 24 h. Her husband tells you that they visited a hobby / petting farm with their two children a few days earlier.

On examination, she is restless and has a temperature of 38 °C, pallor and a purpuric rash on her legs and abdomen. There is no nuchal rigidity. Her blood pressure is 150/90 mmHg. The rest of the examination is normal.

Investigations:

Hb	8.7 g/dl
WCC	11.0×10^9/l
PLT	10.0×10^9/l
D-dimer	-
Urea	8.4 mmol/l
Creatinine	150 μmol/l

Lactate dehydrogenase (LDH)	2160 IU/l (200–450)
Antinuclear antibody (ANA)	-
Direct agglutination test (DAT)	-
Peripheral smear	Anisocytosis, poikilocytosis, frequent schistocytes and polychromasia, marked thrombocytopenia, leukocytes normal
Urinalysis	Trace protein

A CT scan of the brain and an abdominal ultrasound scan are both normal. Lumbar puncture is not performed because of the thrombocytopenia.

Which one of the following diagnoses

Urinalysis	Trace protein

A CT scan of the brain and an abdominal ultrasound scan are both normal. Lumbar puncture is not performed because of the thrombocytopenia.

Which one of the following diagnoses best fits the above picture?

A	Evans syndrome
B	Systemic lupus erythematosus (SLE)
C	Thrombotic thrombocytopenic purpura (TTP)
D	Meningococcal meningitis
E	Metastatic cancer

C Thrombotic thrombocytopenic purpura (TTP)

A high index of suspicion is necessary to make this diagnosis, and the visit to a farm raises the possibility of *E coli* infection, recognised as a cause of TTP. Although characterised by the pentad of fever, micro-angiopathic haemolytic anaemia (MAHA), thrombocytopenia, neurological abnormalities and kidney disease, in practice the triad of schistocytes, thrombocytopenia and an elevated LDH are sufficient to make the diagnosis. Coagulation tests are normal and there is no evidence of disseminated intravascular coagulation (DIC). The introduction of daily plasma exchange has transformed the prognosis of this previously fatal disorder. Pathologically, widespread platelet microthrombi are evident. These result from aggregates of platelets and circulating ultra-high-molecular weight von Willebrand factor (vWF) multimers; the latter are normally cleaved by a circulating

normally cleaved by a circulating metalloprotease, ADAMTS 13. This enzyme is deficient in TTP. Plasmapheresis is thought to replace this enzyme, and also may aid in the removal of large vWF multimers..

A	Evans syndrome

This autoimmune disorder with unknown pathophysiology is characterised by the simultaneous or sequential co-existence of autoimmune haemolytic anaemia with immune-mediated thrombocytopenia.

B	Systemic lupus erythematosus (SLE)

This is an autoimmune disorder and the antinuclear antibody test is positive. Other features including joint pains and a photosensitive rash are also absent.

D	Meningococcal meningitis

B	Systemic lupus erythematosus (SLE)

This is an autoimmune disorder and the antinuclear antibody test is positive. Other features including joint pains and a photosensitive rash are also absent.

D	Meningococcal meningitis

This is the main differential, although the visit to a hobby farm makes us more suspicious of TTP as the underlying cause of her symptoms.

E	Metastatic cancer

The normal CT brain and ultrasound of the abdomen make this much less likely.

8591

Rate this question:

Next Question

A 72-year-old patient is treated with warfarin for a prosthetic aortic valve. He has completed a 5-day course of oral ciprofloxacin for a sinus infection, and he is attending for an international normalised ratio (INR) check. There is no increase in bruising or bleeding from mucus membranes.

Investigations:

Hb	12.5 g/dl
WCC	7.1×10^9/l
PLT	203×10^9/l
Na^+	139 mmol/l
K^+	4.4 mmol/l
Creatinine	129 μmol/l
INR	6.8

Which of the following is the most appropriate management with respect to his INR?

A	Stop warfarin and review INR in 24 hours

Na^+	139 mmol/l
K^+	4.4 mmol/l
Creatinine	129 µmol/l
INR	6.8

Which of the following is the most appropriate management with respect to his INR?

A	Stop warfarin and review INR in 24 hours
B	Give 10 mg IV vitamin K
C	Give fresh frozen plasma (FFP)
D	Give prothrombin complex concentrate
E	Give dextran sulphate

A 72-year-old patient is treated with warfarin for a prosthetic aortic valve. He has completed a 5-day course of oral ciprofloxacin for a sinus infection, and he is attending for an international normalised ratio (INR) check. There is no increase in bruising or bleeding from mucus membranes.

Investigations:

Hb	12.5 g/dl
WCC	7.1 x 10^9/l
PLT	203 x 10^9/l
Na^+	139 mmol/l
K^+	4.4 mmol/l
Creatinine	129 µmol/l
INR	6.8

Which of the following is the most appropriate management with respect to his INR?

Your answer was incorrect

A Stop warfarin and review INR in 24 hours

This man has an artificial valve and, as such, must maintain his INR around 3.0. He is not actively bleeding and therefore the most appropriate management is to allow his INR to drift down slowly over the next few days. Given that over-reversal of anticoagulation may be associated with significant embolic risk, dose omission in the absence of active bleeding is the safest option.

B Give 10 mg IV vitamin K

This risks over-reversal of the elevated INR and arterial embolism related to the prosthetic aortic valve.

C Give fresh frozen plasma (FFP)

FFP or other warfarin reversal agents, such as prothrombin complex concentrate, should only be

FFP or other warfarin reversal agents, such as prothrombin complex concentrate, should only be considered when there is life-threatening haemorrhage or surgery is urgently required.

D	Give prothrombin complex concentrate

PCC is considered when patients who have been taking warfarin need to progress urgently to surgery or have life-threatening haemorrhage.

E	Give dextran sulphate

Dextran sulphate is the reversal agent for over-heparinisation, and is not of value in treating excessive warfarinisation.

23325

Rate this question:

A 58-year-old woman is admitted for resection of a caecal carcinoma. She is not taking any medications, has no other past medical history, is a non-smoker and drinks little alcohol. Preoperative physical examination is unremarkable, with a blood pressure of 125/85 mmHg, pulse 76/min and regular. BMI is 23.

Preoperative bloods:

Hb	9.0 g/dl
MCV	76 fl
WCC	10.0×10^9/l
PLT	250×10^9/l

The operation was uneventful. with no evidence of secondary spread and the patient received 2 units of blood during the procedure. Five days later she was icteric and tired. She is apyrexial, and apart from tenderness around her scar, she tells you that her surgical pain is gradually improving.

Repeat bloods:

Repeat bloods:

Hb	6.0 g/dl
WCC	15.0×10^9/l
PLT	450×10^9/l
MCV	100 fl
Bilirubin	80 μmol/l
AST	30 IU/l
ALP	100 IU/l
Blood film	Polychromasia, spherocytes

Which investigation will most likely lead to a confirmed diagnosis?

A Anti-cardiolipin antibodies

B Serum haptoglobin

C Reticulocyte count

D Abdominal ultrasound scan

MCV	100 fl
Bilirubin	80 μmol/l
AST	30 IU/l
ALP	100 IU/l
Blood film	Polychromasia, spherocytes

Which investigation will most likely lead to a confirmed diagnosis?

A Anti-cardiolipin antibodies

B Serum haptoglobin

C Reticulocyte count

D Abdominal ultrasound scan (USS)

E Direct antiglobulin test

The operation was uneventful. with no evidence of secondary spread and the patient received 2 units of blood during the procedure. Five days later she was icteric and tired. She is apyrexial, and apart from tenderness around her scar, she tells you that her surgical pain is gradually improving.

Repeat bloods:

Hb	6.0 g/dl
WCC	15.0×10^9/l
PLT	450×10^9/l
MCV	100 fl
Bilirubin	80 µmol/l
AST	30 IU/l
ALP	100 IU/l
Blood film	Polychromasia, spherocytes

Which investigation will most likely lead to a confirmed diagnosis?

E Direct antiglobulin test

Delayed transfusion reactions occur 5–10 days after transfusion and are almost invariably delayed haemolytic reactions due to the development of red cell (RBC) allo-antibodies. Clinical features are usually minimal but can include unexplained pyrexia, jaundice or unexplained drop in haemoglobin. Urinalysis shows urobilinogenuria and a blood shows fragile ballooned spherocytes. Diagnosis is confirmed by a direct antiglobulin (Coombs') test that detects the presence of antibody on the RBCs. The test is performed by adding anti-human globulin (AHG) (anti-Ig G and anti-complement) to the patient's washed RBCs. A positive test results in red cell agglutination.

A Anti-cardiolipin antibodies

Anti-cardiolipin antibodies lead to prolongation of APTT and increased risk of thrombosis, rather than haemolysis.

prolongation of APTT and increased risk of thrombosis, rather than haemolysis.

B	Serum haptoglobin

Haptoglobin is decreased in conditions of haemolysis, although it does not confirm the underlying cause.

C	Reticulocyte count

Reticulocytes are elevated in patients with haemolysis, although they don't indicate the underlying cause.

D	Abdominal ultrasound scan (USS)

Although blood loss as a result of the procedure may result in a haemoglobin of 60 g/l, the elevated bilirubin suggests that haemolysis as the more likely cause here.

9856

Rate this question:

A 71-year-old woman presents with tiredness and lethargy. Her GP had previously noted that she was anaemic and commenced iron therapy.

Examination reveals obvious splenic enlargement.

Investigations:

WCC	2.1×10^9 mmol/l
Neutrophils	0.9×10^9 mmol/l (1.5–7.0)
Lymphocytes	0.8×10^9 mmol/l (1.5–4.0)
Monocytes	0.1×10^9 mmol/l (0–0.8)
Eosinophils	0×10^9 mmol/l (0.04–0.4)
Basophils	0×10^9 mmol/l (0–0.1)
Hb	9.1 g/dl
MCV	80 fl (76–96)
PLT	90×10^9 mmol/l (150–400)

Hb	9.1 g/dl
MCV	80 fl (76–96)
PLT	90×10^9 mmol/l (150–400)

Bone marrow biopsy reveals increased cellularity.

What diagnosis fits best with this clinical picture?

A	Acute myeloid leukaemia (AML)
B	Chronic myeloid leukaemia
C	Myelodysplasia
D	Myelofibrosis
E	Myeloma

Lymphocytes	0.8×10^9 mmol/l (1.5–4.0)
Monocytes	0.1×10^9 mmol/l (0–0.8)
Eosinophils	0×10^9 mmol/l (0.04–0.4)
Basophils	0×10^9 mmol/l (0–0.1)
Hb	9.1 g/dl
MCV	80 fl (76–96)
PLT	90×10^9 mmol/l (150–400)

Bone marrow biopsy reveals increased cellularity.

What diagnosis fits best with this clinical picture?

Your answer was correct

A	Acute myeloid leukaemia (AML)

C Myelodysplasia

Myelodysplasia occurs mainly in the elderly and presents with anaemia, infection or bleeding due to pancytopenia. Serial blood counts show evidence of increasing bone marrow failure and the bone marrow shows increased cellularity. Patients with <5% blasts in the bone marrow are managed conservatively, 'gentle' chemotherapy is used in patients with high WBC counts and intensive chemotherapy is usually reserved for patients under the age of 60 years. Transformation into AML occurs in around 30% of patients.

A	Acute myeloid leukaemia (AML)

Patients with AML generally present with symptoms related to complications of pancytopenia (e.g. anaemia, neutropenia and thrombocytopenia), including weakness and easy fatigability, infections of variable severity and/or

infections of variable severity and/or haemorrhagic findings such as gingival bleeding, ecchymoses, epistaxis or menorrhagia. Bone marrow aspiration and biopsy (usually unilateral) is a key component in the diagnosis of AML. The bone marrow is usually hypercellular due to a partial or almost total replacement of the normal cellular components by immature or undifferentiated cells, although AML can sometimes present with a hypocellular marrow.

B	Chronic myeloid leukaemia

CML has a tri- or biphasic clinical course: a chronic phase, which is present at the time of diagnosis in approximately 85% of patients; an accelerated phase, in which neutrophil differentiation becomes progressively impaired and leukocyte counts are more difficult to control with treatment; and blast crisis, a condition resembling acute leukaemia in which myeloid or lymphoid blasts proliferate in an uncontrolled manner. The

in an uncontrolled manner. The peripheral smear typically demonstrates a leukocytosis with a median WCC of approximately 10×10^9 mmol/l. The white blood cell differential typically shows virtually all cells of the neutrophilic series, from myeloblasts to mature neutrophils with peaks in the percentages of myelocytes and segmented neutrophils . Blasts typically account for <2%. The presence of a higher percentage of myelocytes than the more mature metamyelocytes ('leukemic hiatus' or 'myelocyte bulge') is one of the classic findings in CML. The granulocytes of the chronic phase are morphologically normal with no evidence of dysplasia, but dysplasia can develop in more advanced disease, and particularly in the accelerated phase.

D	Myelofibrosis

Primary myelofibrosis (PMF) is one of the chronic myeloproliferative disorders, which are collectively characterised by clonal proliferation of

characterised by clonal proliferation of myeloid cells with variable morphologic maturity and haematopoietic efficiency. Splenomegaly is a marked feature. Bone marrow biopsy is necessary to demonstrate fibrosis. Some degree of fibrosis is seen in almost all patients; the fibrosis is typically extensive and is better visualised with a silver stain (reticulin) or a trichrome stain (mature collagen). Bone marrow sinusoids are expanded and there is intravascular haematopoiesis. The fibrosis is generally associated with atypical megakaryocytic hyperplasia, and thickening and distortion of the bony trabeculae (osteosclerosis).

E	Myeloma

Multiple myeloma (MM) is characterised by the neoplastic proliferation of plasma cells producing a monoclonal immunoglobulin. The plasma cells proliferate in the bone marrow, and this often results in extensive skeletal destruction with

osteolytic lesions, osteopenia and/or pathological fractures. The diagnosis of MM is often suspected because of one (or more) of the following clinical presentations: bone pain with lytic lesions discovered on routine skeletal films or other imaging modalities; an increased total serum protein concentration and/or the presence of a monoclonal protein in the urine or serum; systemic signs or symptoms suggestive of malignancy, such as unexplained anaemia, or hypercalcaemia, which is either symptomatic or discovered incidentally; acute kidney disease with a bland urinalysis; or, rarely, nephrotic syndrome due to concurrent immunoglobulin light-chain (AL) amyloidosis. The vast majority (97%) of patients with MM will have a monoclonal (M) protein produced and secreted by the malignant plasma cells, and this can be detected by protein electrophoresis of the serum and/or an aliquot of urine from a 24 h collection, combined with immunofixation of the serum and urine.

A 25-year-old woman is referred to the Haematology Clinic by her general practitioner (GP) after complaining of fatigue and breathlessness on exertion.

On examination, she is pale, with a spleen just palpable and no other abnormal findings.

The haemoglobin level is 9.6 g/dl.

Her blood film is shown below:

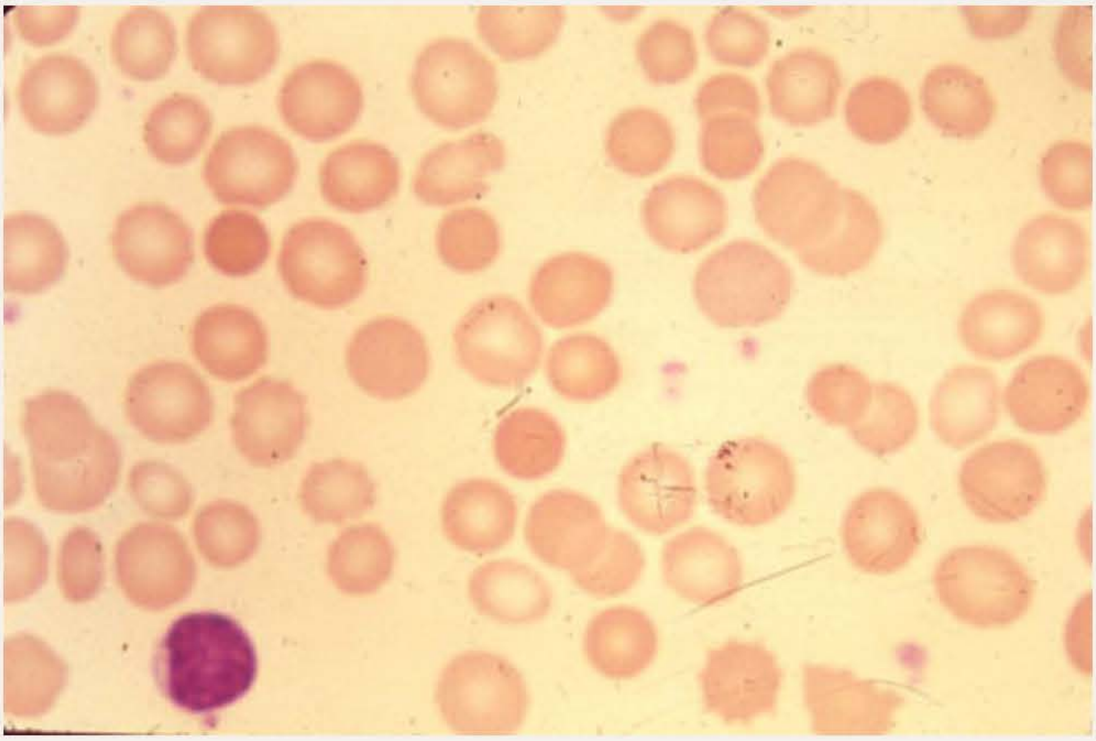

Image courtesy of the Crookston Collection, Toronto.

What is the most likely diagnosis?

A	Hyposplenism

Image courtesy of the Crookston Collection, Toronto.

What is the most likely diagnosis?

A	Hyposplenism
B	Hereditary elliptocytosis (HE)
C	Hereditary spherocytosis (HS)
D	Heinz body haemolytic anaemia
E	Sickle cell anaemia

6339

Submit

C Hereditary spherocytosis (HS)

The blood film shows spherocytes which have a lack of central pallor seen in normal red blood cells, and a reduced diameter: this is the picture of hereditary spherocytosis. This disorder of the red cell membrane leads to spherical red blood cells with osmotic fragility, resulting in chronic haemolysis. HS is a heterogeneous group of disorders with regard to clinical severity, protein defects and mode of inheritance. It is relatively common in Caucasian populations; most affected individuals having mild or only moderate haemolysis. It may present in childhood with jaundice, but milder cases may go undiagnosed until early adulthood. There is usually a family history and a typical clinical and laboratory picture, so that the diagnosis is often easily made without additional laboratory tests. Moderately and severely affected individuals are likely to benefit from splenectomy, which should be performed after the age of 6 years and with appropriate

likely to benefit from splenectomy, which should be performed after the age of 6 years and with appropriate counselling about the infection risk. It is particularly important to rule out stomatocytosis, where splenectomy is contraindicated because of the thrombotic risk.

A Hyposplenism

Features of hyposplenism include Howell-Jolly bodies, Pappenheimer bodies, target cells and irregular contracted red blood cells, rather than the spherocytes seen here.

B Hereditary elliptocytosis (HE)

HS is commoner than HE, and loss of central pallor when erythrocytes are examined is less prominent in HE than in HS.

D Heinz body haemolytic anaemia

the spherocytes seen here.

B	Hereditary elliptocytosis (HE)

HS is commoner than HE, and loss of central pallor when erythrocytes are examined is less prominent in HE than in HS.

D	Heinz body haemolytic anaemia

Heinz bodies are inclusion bodies seen in red blood cells and they represent denatured DNA.

E	Sickle cell anaemia

Blood films in sickle cell anaemia show features of hyposplenism and may show sickled red blood cells.

6339

Rate this question:

Next Question

A 79-year-old man is flagged by the Haematology Service because his routine international normalised ratio (INR) monitoring has revealed an INR of 10.8. He normally takes 7 mg warfarin per day for atrial fibrillation.

You call him at home and he is well, apart from some mild indigestion and bleeding around his gums.

On examination, his blood pressure (BP) is 132/82 mmHg and he looks well.

Investigations:

Haemoglobin (Hb)	12.1 g/dl
White cell count (WCC)	4.5×10^9/l
Platelets (PLT)	201×10^9/l
Sodium (Na^+)	141 mmol/l
Potassium (K^+)	4.9 mmol/l
Creatinine (Cr)	110 μmol/l
Faecal occult blood	Negative

Which of the following is the most

Platelets (PLT)	201×10^9/l
Sodium (Na^+)	141 mmol/l
Potassium (K^+)	4.9 mmol/l
Creatinine (Cr)	110 μmol/l
Faecal occult blood	Negative

Which of the following is the most appropriate course of management?

A Low-dose vitamin K and stop warfarin

B Fresh frozen plasma (FFP)

C Prothrombin complex

D Stop warfarin

E Reduce warfarin dose to 3 mg

21175

Submit

12:27
Copy Share Select all Web search

of 10.8. He normally takes 7 mg warfarin per day for atrial fibrillation.

You call him at home and he is well, apart from some mild indigestion and bleeding around his gums.

On examination, his blood pressure (BP) is 132/82 mmHg and he looks well.

Investigations:

Haemoglobin (Hb)	12.1 g/dl
White cell count (WCC)	4.5×10^9/l
Platelets (PLT)	201×10^9/l
Sodium (Na^+)	141 mmol/l
Potassium (K^+)	4.9 mmol/l
Creatinine (Cr)	110 μmol/l
Faecal occult blood	Negative

Which of the following is the most appropriate course of management?

Your answer was correct

12:27
Copy Share Select all Web search

A	Low-dose vitamin K and stop warfarin

The correct answer is Low-dose vitamin K and stop warfarin (Option A).

For many years, it was thought that low-dose vitamin K would interfere with rewarfarinisation; however, in practice, this is not a major problem. This has resulted in a change in guidelines over recent years, with most now recommending low-dose vitamin K with warfarin cessation when the INR is > 8 and there is minor bleeding.

B	Fresh frozen plasma (FFP)

Fresh frozen plasma (FFP) (Option B) is incorrect.

For the immediate reversal of INR in anticoagulated patients who are actively bleeding, prothrombin complex concentrates are preferred over FFP. FFP should only be used if more effective alternative treatments, such as prothrombin complex, are not

major bleeding corresponding to less 2000 ml or > 30% of blood volume, it is recommended that prothrombin complex should be given in conjunction with vitamin K.

D	Stop warfarin

Stop warfarin (Option D) is incorrect.

Simply stopping warfarin is not recommended in situations where the INR has such high values. Omitting warfarin is recommended for INR values of between 4.5 and 10 in patients with a low risk of bleeding or in patients where bleeding is present, but minor, and the INR value is < 4.5.

E	Reduce warfarin dose to 3 mg

Reduce warfarin dose to 3 mg (Option E) is incorrect.

Reducing the dose of warfarin is recommended in cases where the INR is < 4.5 and patients have no active signs of bleeding.

INR	1.2
APTT	27 s
Urea	10 mmol/l
Creatinine	130 μmol/l
Liver function tests	Normal

Which of the following is the most likely explanation for his presentation and blood results?

A	Disseminated intravascular coagulation
B	Post-transfusion purpura
C	Heparin-induced thrombocytopaenia
D	Thrombotic thombocytopenic purpura
E	Immune thrombocytopaenic purpura

A 60-year-old man received unfractionated heparin perioperatively following a routine knee replacement. He was not known to have any cardiovascular risk factors. His blood pressure preoperatively was 130/80 mmHg.

He was slow to mobilise, and 4 days post-operatively developed a large wound haematoma and the heparin was stopped. The patient required a transfusion of two units of blood and decompression of the wound. He was not known to have a history of bleeding problems and the operation otherwise was uncomplicated. All preoperative blood tests were normal.

A few days later, the patient is readmitted with right-sided chest pain and shortness of breath.

Chest X-ray was unremarkable.

Investigations:

Hb	11 g/dl
WCC	$12 \times 10^9/l$
PLT	$7 \times 10^9/l$

C Heparin-induced thrombocytopaenia

Heparin-induced thrombocytopenia (HIT) is a severe, immune-mediated drug reaction that can occur in any patient exposed to heparin. This includes patients receiving unfractionated heparin (at both full therapeutic doses and low prophylactic doses, including the minute amounts in heparin flushes and on heparin-coated catheters) and those receiving low-molecular weight heparin (LMWH). Antibodies usually develop after a patient has been on heparin for five or more days, but may develop sooner if there has been previous heparin exposure.
Despite thrombocytopenia, bleeding is rare. HIT is strongly associated with thrombosis. Thrombo-embolic complications can be venous, arterial or both; these include deep venous thrombosis, pulmonary embolism, myocardial infarction, thrombotic stroke and occlusion of limb arteries. When HIT is suspected clinically

stroke and occlusion of limb arteries.
When HIT is suspected clinically, heparin should be stopped and an alternative anticoagulant commenced, such as danaparoid, lepirudin or argatroban, which do not cross-react with HIT antibodies.
Oral anticoagulation with warfarin should not be initiated for longer-term protection from further events until substantial platelet count recovery has occurred. HIT patients who are switched to warfarin alone after the discontinuation of heparin may paradoxically have worsening thrombosis and develop venous limb gangrene and skin necrosis.
The diagnosis of HIT remains a clinical one, supported by confirmatory laboratory testing. The criteria include:

- thrombocytopenia (i.e. a drop in the platelet count to below 100×10^9/l or a drop of >50% from the patient's baseline platelet count)
- the exclusion of other causes of thrombocytopenia
- the resolution of

- the resolution of thrombocytopenia after cessation of heparin.

Regarding the laboratory tests, HIT antibodies can be demonstrated in vitro by functional tests and immunoassays. Functional tests, which measure platelet activity in the presence of the patient's serum and heparin, including heparin-induced platelet aggregation (HIPA) and the serotonin release assay (SRA), are more specific than the immunoassays and are therefore preferred in the diagnosis of HIT.

A	Disseminated intravascular coagulation

Disseminated intravascular coagulation (DIC) is a complex systemic thrombo-haemorrhagic disorder involving the generation of intravascular fibrin and the consumption of procoagulants and platelets. It is seen in association with a number of well-defined clinical

number of well-defined clinical situations, including sepsis, major trauma and abruptio placenta. It is associated with prolonged clotting times, low fibrinogen, raised fibrin degradation products and thrombocytopenia.

B	Post-transfusion purpura

Post-transfusion purpura (PTP) is an adverse reaction to a blood transfusion or platelet transfusion that occurs when the body produces allo-antibodies to the introduced platelets' antigens. These allo-antibodies destroy the patient's platelets, leading to thrombocytopenia. PTP usually presents 5–12 days after transfusion, and is therefore not relevant in this case.

D	Thrombotic thombocytopenic purpura

Thrombotic thrombocytopenic purpura (TTP) is a life-threatening

A 67-year-old woman is admitted with a large haematoma of the right arm after minimal trauma. She has noticed over the past few weeks increased bruising of the skin. The patient has recently completed a course of penicillin for a chest infection. She has a past history of psoriasis and hypertension.

Examination reveals multiple bruises and a large painful haematoma in the right upper arm. The venepuncture site displays prolonged bleeding.

Investigations:

Hb	10.2 g/dl
WCC	9.8×10^9/l
PLT	325×10^9/l
INR	1.0
APPT	53 s (30–40); does not correct with the addition of normal plasma

What is the most likely diagnosis?

WCC	$9.8 \times 10^9/l$
PLT	$325 \times 10^9/l$
INR	1.0
APPT	53 s (30–40); does not correct with the addition of normal plasma

What is the most likely diagnosis?

A	Von Willebrand's disease
B	Haemophilia A
C	Haemophilia B
D	Anti-phospholipid antibody syndrome
E	Acquired factor VIII deficiency

7076

Submit

E	Acquired factor VIII deficiency

Acquired factor VIII deficiency results from the development of antibodies against factor VIII, which prevent its action. This can occur in the elderly and is associated with malignancy, psoriasis, pemphigus and drugs (cephalosporins, penicillins). Patients develop bleeding tendencies and the activated partial thromboplastin time (APTT) is prolonged (intrinsic pathway). The APTT doesn't correct/will only correct slightly with the addition of normal plasma. The Bethesda titre can quantify the inhibitor. There is a 20% mortality rate from acquired factor VIII deficiency.

A	Von Willebrand's disease

Although Von Willebrand's disease is associated with prolongation of APTT in 50% of patients due to low levels of factor VIII, it corrects on mixing with normal plasma.

B Haemophilia A

Although haemophilia A does lead to bleeding and is associated with prolongation of APTT, presentation for the first time at this stage would be very unusual, and correction with normal plasma would be expected.

C Haemophilia B

Haemophilia B is associated with bleeding, although correction of clotting disorder on mixing with normal plasma would be expected.

D Anti-phospholipid antibody syndrome

APAS is associated with a prolonged APTT, although it results in a propensity towards thrombosis rather than increased risk of bleeding.

7076

Rate this question:

A 29-year-old patient who has undergone a bone marrow transplant for previous acute myeloid leukaemia presents for review complaining of increased bruising.

On examination, she has a number of areas of bruising and looks pale; her BP is 142/84 mmHg.

Investigations:

Hb	10.9 g/dl
WCC	3.9×10^9/l
PLT	6.0×10^9/l
Na^+	141 mmol/l
K^+	4.9 mmol/l
Creatinine	121 μmol/l

Which of the following is the most appropriate form of platelets to use for transfusion?

A	Washed

K^+	4.9 mmol/l
Creatinine	121 μmol/l

Which of the following is the most appropriate form of platelets to use for transfusion?

A Washed

B HLA-matched

C Family donated

D Gamma-irradiated

E Leukocyte-depleted

21174

Submit

D Gamma irradiated

Patients who have undergone bone marrow transplantation are at increased risk of transfusion-associated graft-versus-host disease (GVHD) because of lymphocytes within the donor material. Gamma-irradiated blood products are generally recommended for patients undergoing HLA-matched transfusions and those with an inherited immune system disorder, acquired immune disorder such as Hodgkin's disease or post bone-marrow transplantation. The irradiation minimises the chances of surviving leukocytes being found within the donated platelets.

A Washed

Platelet washing is designed to remove about 99% of plasma. It does, however, result in decreased quality of platelet function, is labour- and time-intensive and can result in delays to transfusion.

B HLA-matched

A 40-year-old woman presents with enlarging lumps in her neck. She first noticed them 6 weeks ago after a viral infection, but they have persisted and she feels they are enlarging.

She has lost 2 kg in weight and has had fevers that necessitate changing of the bedding two or three times per week. She has no previous medical history of note and is on no medication. She works full-time as a secretary, lives alone and keeps several cats (which she says regularly scratch her).

On examination, she has two 3 cm supraclavicular lymph nodes but no other obviously palpable disease. Chest X-ray shows mediastinal widening.

Investigations:

Hb	11.3 g/dl
WCC	3.5×10^9/l
PLT	170×10^9/l
Eosinophils	0.7×10^9/l (0.04–0.4)

WCC	$3.5 \times 10^9/l$
PLT	$170 \times 10^9/l$
Eosinophils	$0.7 \times 10^9/l$ (0.04–0.4)
Lymphocytes	$1.5 \times 10^9/l$ (1.5–4.0)

What investigation is most likely to be diagnostic?

A Bone marrow aspirate and trephine

B Fine needle aspiration of supraclavicular lymph nodes with immunocytochemistry

C Mediastinoscopy with biopsy

D Removal of entire supraclavicular lymph node for histological examination

E Serology for antibodies to *Bartonella henselae*

D Removal of entire supraclavicular lymph node for histological examination

This woman is likely to have lymphoma; although cat scratch fever is possible it rarely involves the mediastinum and the 'B' symptoms are dramatic. Removal of an entire lymph node is preferable to tru-cut biopsy: lymphoma diagnosis is fraught with technical difficulties and when subject to central review up to 30% of lymphomas are mis-classified, so every effort should be made to get the best biopsy specimen possible.

E Serology for antibodies to *Bartonella henselae*

A positive IgM test strongly suggests acute disease (or very recent infection) of cat scratch fever, but the production of IgM is usually brief. Thus, the serological diagnosis of acute infection can be elusive. However, a negative serologic test should not rule out CSD

can be elusive. However, a negative serologic test should not rule out CSD if there is a high clinical suspicion for disease. Prevalence of positive *Bartonella* serology in the general population is 4–6%, which creates false-positive test results. In this case the diagnosis is lymphoma, and therefore serology for antibodies to *B. henselae* is incorrect.

A	Bone marrow aspirate and trephine

Bone marrow examination is part of the staging of lymphoma, but would only be used for diagnostic purposes if there were no tissue accessible to biopsy.

B	Fine needle aspiration of supraclavicular lymph nodes with immunocytochemistry

Fine needle aspiration of lymph nodes is appropriate where nasopharyngeal carcinoma is suspected, but has a poor specificity/sensitivity in lymphoma.

A 40-year-old female patient on the Haematology Ward has become increasingly unwell over the past few days. She is 2 weeks' post-allogenic haemopoietic stem cell transplant (HSCT) for acute myeloid leukaemia.

On examination, she is jaundiced with ascites, hepatomegaly and right upper quadrant tenderness. Further examination reveals bi-basal inspiratory crepitations and peripheral oedema.

Initial investigations:

Hb	8.9 g/dl (120–155)
WCC	2.8×10^9/l (4.0–11.0)
Neutrophil count	1.8×10^9/l (2.0–7.5)
PLT	60×10^9/l (150–450)
Bilirubin	119 μmol/l (3–17)
ALT	39 IU/l (<40)
ALP	290 IU/l (40–130)
GGT	260 IU/l (10–50)

Albumin	28 g/l (35–50)
CRP	9 mg/l (<5)
Portable chest X-ray	Upper lobe diversion with blunted right costophrenic angle
Pre and post-transplant viral screens	-

What is the most likely diagnosis?

A	Veno-occlusive disease of the liver
B	Hepatitis B infection
C	Transfusion-associated cardiac overload (TACO)
D	Cyclosporin toxicity
E	Cholangitis

A man aged 62 years is referred to the Haematology Clinic for review. He received a routine blood screen from his general practitioner (GP) that revealed a raised erythrocyte sedimentation rate (ESR) (85 mm/h) and a raised immunoglobulin G (IgG) paraprotein band (1.9 g/l). No urinary light chain excretion was detected.

Three years later, he remains well; however, he still has an increased ESR and IgG paraprotein band, though there is still no urinary light chain excretion.

Which of the following diagnoses fit best with this clinical picture?

A	Waldenstrom's macroglobulinaemia
B	Monoclonal gammopathy of unknown significance (MGUS)
C	Myeloma

paraprotein band (1.9 g/l). No urinary light chain excretion was detected.

Three years later, he remains well; however, he still has an increased ESR and IgG paraprotein band, though there is still no urinary light chain excretion.

Which of the following diagnoses fit best with this clinical picture?

A	Waldenstrom's macroglobulinaemia
B	Monoclonal gammopathy of unknown significance (MGUS)
C	Myeloma
D	B-cell lymphoma
E	Chronic myeloid leukaemia

B Monoclonal gammopathy of unknown significance (MGUS)

MGUS occurs in older people and is characterised by the presence of a paraprotein band (immunoglobulin G [IgG] <20 g/l). Patients may be asymptomatic and the condition discovered by chance. Blood count is usually normal, and there is no renal dysfunction. No specific treatment is required. Around 1% of patients with MGUS may progress to myeloma annually. In many patients with disease progression, immunoglobulin (Ig) gene rearrangement can be detected in B lymphocytes before the appearance of myeloma. This suggests that MGUS is a clonal, pre-malignant condition.

A Waldenstrom's macroglobulinaemia

This is one of the malignant monoclonal gammopathies and is a chronic, indolent, lymphoproliferative disorder. It is characterised by the

chronic, indolent, lymphoproliferative disorder. It is characterised by the presence of a high level of a macroglobulin (immunoglobulin M [IgM]), elevated serum viscosity and the presence of a lymphoplasmacytic infiltrate in the bone marrow.

C	Myeloma

There is no light chain excretion in the urine that would confirm the diagnosis of myeloma, and no organ involvement (e.g. bone, liver, spleen).

D	B-cell lymphoma

Non-Hodgkin's lymphoma is a collective term for a heterogeneous group of lymphoproliferative malignancies with differing patterns of behaviour and responses to treatment. Most NHLs (80–85%) are of B-cell origin. There is no distinct paraprotein in the serum electrophoresis, but there may be a diffuse increase in the IgG region.

A 40-year-old woman presents with a 24 h history of unilateral swelling of the left leg. She has recently flown back to this country from Australia. She is previously fit and well, does not smoke and is on no medication. She has no family history of note.

Other than the swollen leg, examination is unremarkable. Ultrasound of the deep veins of the leg confirms an above-knee deep vein thrombosis, and she is commenced on enoxaparin 1.5 mg/kg daily subcutaneously and started on 10 mg of warfarin. On the second day after starting warfarin she has developed black lesions over her buttocks. Platelet count remains stable at 205 × 10^9/l.

What is the most likely cause of the lesions over her buttocks?

A	Heparin-induced thrombocytopenia type 2
B	Protein C deficiency

thrombosis, and she is commenced on enoxaparin 1.5 mg/kg daily subcutaneously and started on 10 mg of warfarin. On the second day after starting warfarin she has developed black lesions over her buttocks. Platelet count remains stable at 205 × 10^9/l.

What is the most likely cause of the lesions over her buttocks?

A	Heparin-induced thrombocytopenia type 2
B	Protein C deficiency
C	Prothrombin gene 20210 mutation
D	Antithrombin III deficiency
E	Anti-phospholipid antibody syndrome

Other than the swollen leg, examination is unremarkable. Ultrasound of the deep veins of the leg confirms an above-knee deep vein thrombosis, and she is commenced on enoxaparin 1.5 mg/kg daily subcutaneously and started on 10 mg of warfarin. On the second day after starting warfarin she has developed black lesions over her buttocks. Platelet count remains stable at 205 × 10^9/l.

What is the most likely cause of the lesions over her buttocks?

Your answer was incorrect

A	Heparin-induced thrombocytopenia type 2
B	Protein C deficiency
C	Prothrombin gene 20210 mutation

B Protein C deficiency

This lady has developed warfarin-induced skin necrosis (WISN); this occurs when warfarin is started and there is a defect in the protein C anticoagulant pathway. Protein C is vitamin K dependent and falls rapidly following the commencement of warfarin, leading to an initial paradoxical prothrombotic state: this explains why heparin is started concurrently with warfarin, to cover this initial period. The condition has been reported in association with most forms of thrombophilia, but defects in the protein C pathway (classically protein C deficiency, but also including protein S and activated protein C resistance) are the most common pre-existing conditions. Microthrombi form in the blood vessels of the skin, particularly in adipose areas such as buttocks and breast. The condition is severe, and plastic surgery is often required. Treatment is supportive, with vitamin K and possibly fresh frozen plasma to replace protein C levels.

Prostacyclin and protein C infusion have been trialled. Warfarin can be reintroduced at a lower loading dose, but recurrence may occur.

C Prothrombin gene 20210 mutation

The prothrombin gene 20210 mutation is a cause of thrombophilia, rather than a cause of protein C deficiency in association with warfarin initiation.

A Heparin-induced thrombocytopenia type 2

HIT is associated with the development of necrotic skin ulcers, although the maintenance of a stable platelet count counts against this as the underlying diagnosis.

D Antithrombin III deficiency

Antithrombin III deficiency is associated with recurrent thrombosis, and is seen as an autosomal dominant

diagnosis.

D	Antithrombin III deficiency

Antithrombin III deficiency is associated with recurrent thrombosis, and is seen as an autosomal dominant congenital disorder and in patients with severe proteinuria. It is not associated with commencement of warfarin.

E	Anti-phospholipid antibody syndrome

This occurs either in isolation or against a background of SLE and is associated with recurrent venous thrombosis and other features such as livedo reticularis.

6306

Rate this question:

Next Question

A 33-year-old ward sister who is currently on an oral contraceptive pill (OCP) is requesting sterilisation, as she is concerned about the risks of venous thrombosis involved with the OCP.

Her maternal aunt at the age of 65 years developed pulmonary embolism following her knee surgery, for which she was anticoagulated. Her aunt went on to have subsequent screening of pro-coagulant tendencies, and heterozygous factor V Leiden was identified. The patient's mother has suffered no problems, having had three normal pregnancies and varicose veins only.

What advice would you give the patient?

A	Reassure and inform the patient that risk is minimal in continuing OCP
B	Stop OCP immediately and seek gynaecological operation for sterilisation

heterozygous factor V Leiden was identified. The patient's mother has suffered no problems, having had three normal pregnancies and varicose veins only.

What advice would you give the patient?

A	Reassure and inform the patient that risk is minimal in continuing OCP
B	Stop OCP immediately and seek gynaecological operation for sterilisation
C	Use other methods of contraception
D	Finish current pill pack and then continue with progesterone-only pill
E	Check for factor V Leiden and if positive stop OCP

E Check for factor V Leiden and if positive stop OCP

About 5% of the UK population carry a factor V Leiden mutation. The mutation slows the normal breakdown of factor V, leading increased circulating thrombin levels. Heterozygotes for the mutation have a slightly increased risk of developing venous thromboembolism, but most will never have any clinically relevant episode. Heterozygote carriers have 4–8-fold increased risk of venous thrombo-embolism (VTE), and homozygous carriers have an 80-fold increased risk. Women who take the OCP, however, have a significantly raised risk of venous thrombosis and currently the use of any type OCP in women with confirmed factor V Leiden is not recommended.

C Use other methods of contraception

A switch of contraception may not be

A switch of contraception may not be required in the event that screening for factor V Leiden is negative. Hence a switch of contraception without screening isn't needed.

A	Reassure and inform the patient that risk is minimal in continuing OCP

From the point of view of relatives known to be affected by VTE, screening of patients for mutation is recommended. If a mutation is found, then non-hormonal contraception should be recommended unless a woman has completed her family and expresses a preference for sterilisation.

B	Stop OCP immediately and seek gynaecological operation for sterilisation

It may be appropriate to continue the OCP in the event that screening for thrombophilia is negative.

recommended. If a mutation is found, then non-hormonal contraception should be recommended unless a woman has completed her family and expresses a preference for sterilisation.

B	Stop OCP immediately and seek gynaecological operation for sterilisation

It may be appropriate to continue the OCP in the event that screening for thrombophilia is negative.

D	Finish current pill pack and then continue with progesterone-only pill

Switching to the POP would be an option, although it is less effective than the combined oral contraceptive pill with respect to contraception. Hence a switch isn't advised unless the patient has prothrombotic tendencies.

9843

Rate this question:

PLT	450 × 10^9/l
CXR	New shadowing at right base

He is diagnosed with acute chest syndrome, possibly related to mycoplasma infection.

What intervention has been shown to reduce the incidence of acute chest syndrome?

A	Low-dose enoxaparin
B	Prophylactic clarithromycin
C	Hydroxyurea
D	Folate supplements
E	Low-dose aspirin

33317

Submit

C Hydroxyurea

The appearance of a new pulmonary infiltrate on the chest radiograph of a patient with sickle cell disease is termed 'acute chest syndrome'. The syndrome can develop because of infection, infarction or a combination of the two. Infectious causes include Gram-positive or -negative bacteria, atypical bacteria and viruses. The usual organisms include *Pneumococcus*, *Mycoplasma* and *Chlamydia*. Acute chest syndrome is usually accompanied or preceded by pain in the chest or extremities, fever, respiratory distress and/or low oxygen saturation. The white blood cell count is generally high. Although the chest radiograph may be normal initially, subsequent radiographs will reveal an infiltrate, which may extend rapidly, involving one or more lobes as well as the pleura.

One randomised control trial in adults found that hydroxyurea reduced acute chest syndrome and the need for blood transfusion in people with sickle

blood transfusion in people with sickle cell disease over a mean of 21 months. It found no significant difference in stroke, hepatic sequestration and mortality related to sickle cell disease between hydroxyurea and placebo, but the sample size is likely to have been too small to draw any conclusions in this respect.

B	Prophylactic clarithromycin

Empirical antibiotics should be initiated and given intravenously, after obtaining samples for appropriate cultures. If women with sickle cell disease have not undergone a preconceptual review, they should be advised to take daily folic acid and prophylactic antibiotics (if not contraindicated).

A	Low-dose enoxaparin

This is not indicated for the management of acute chest syndrome. There is not enough evidence in the literature supporting the use of low-

literature supporting the use of low-molecular weight heparin in the management of sickle cell crisis. A few studies demonstrated that it may reduce the painful symptoms, but the data were not sufficient for it to be used routinely in clinical practice. Women with sickle cell disease should be advised to receive prophylactic low-molecular weight heparin during antenatal hospital admissions.

D	Folate supplements

Long-term folate supplementation is recommended for patients with sickle cell anaemia and also during pregnancy, but not for the acute management of acute chest syndrome.

E	Low-dose aspirin

This is not recommended as part of the management of the acute chest syndrome. Women with sickle cell disease should be considered for low-dose aspirin 75 mg once daily from 12

A 38-year-old nurse is admitted to the Emergency department of her local hospital having begun feeling very unwell whilst eating a fruit salad. She takes a calcium channel blocker for hypertension but is on no other medications of note. She has wheeze and stridor, and generalised erythema. Her BP is 95/60 mmHg and her pulse is 98/min and regular. She is treated with adrenaline and hydrocortisone.

Which of the following blood tests taken at the time of an attack may be useful in confirming anaphylaxis?

A	Eosinophil count
B	IgE
C	Mast cell tryptase
D	Histamine
E	Cortisol

C Mast cell tryptase

Tryptase is a trypsin-like proteinase that is found mostly in mast cells and basophils, with the former containing almost 300 times more tryptase than the latter. As such, tryptase is specific to mast cell granules and can provide information about mast cell number, distribution and activation depending on the clinical context. Tryptase exerts sequential actions similar to histamine, namely as a vasoactive, pro-inflammatory and chemotactic substance. Mast cell tryptase is measured within 1–2 h of an episode of anaphylaxis and is the preferred measure of mast cell degranulation. Acute management of anaphylaxis includes SC or IM adrenalin, coupled with IV hydrocortisone and antihistamine. In this case, the patient's occupation as a nurse raises the possibility of latex fruit syndrome.

A Eosinophil count

Mild eosinophilia can be seen in allergic diseases, including allergic rhinitis, atopic asthma and atopic dermatitis. It is not a specific marker capable of confirming the diagnosis of anaphylaxis. Markedly raised eosinophil count (>1500 mm^3) is characteristic of the hypereosinophilic syndromes, which are a heterogeneous group of disorders presenting with persistent eosinophilia and/or evidence of end organ damage after exclusion of known causes of eosinophilia, including parasitic infections and drug reactions.

B	IgE

Elevated IgE levels are seen in patients with atopic diseases, with the highest levels generally being seen in atopic dermatitis, followed by atopic asthma, perennial allergic rhinitis and seasonal allergic rhinitis. Elevated IgE levels are also seen in other disorders, including parasitic infections (e.g. strongyloidiasis, ascariasis, schistosomiasis), non-parasitic

infections (e.g. EBV, CMV, HIV, *Mycobacterium tuberculosis*) and haematological malignancies (e.g. Hodgkin's lymphoma, IgE myeloma. For seasonal allergens, peak IgE levels occur 4–6 weeks after the peak of pollen season; therefore raised IgE levels are neither a direct nor a specific marker for anaphylaxis.

D	Histamine

Histamine is an endogenous biogenic amine present in high concentrations in the lungs, skin and gastrointestinal tract. Histamine is synthesised and stored at high concentrations within granules in basophils and mast cells, where it is associated with heparin. In addition, non-mast cell histamine occurs at high concentrations in enterochromaffin-like cells in the stomach, lymph nodes and thymus, with modest levels in the liver, lung and in varicosities of the histaminergic neurons in the brain. Histamine acts as a neurotransmitter in the nervous system and as a local mediator in the

neurons in the brain. Histamine acts as a neurotransmitter in the nervous system and as a local mediator in the gut, skin and immune system. Its functions include neurotransmission, inflammation, smooth muscle contraction, dilatation of capillaries, chemotaxis, cytokine production and gastric acid secretion. There is no evidence that measurement of histamine levels will be useful in confirming anaphylaxis. Whilst histamine is also elevated, the rise in histamine seen in association with anaphylaxis is much more transient.

E	Cortisol

Any stress response leads to an elevation of cortisol, which therefore is not a specific marker for confirming anaphylaxis.

36023

Rate this question:

A 40-year-old woman presents with indigestion of seven weeks' duration. She has no ongoing medical problems, and is otherwise asymptomatic. She is on no medication.

Examination is unremarkable. She undergoes gastro-oesophageal endoscopy, which reveals gastritis. Stomach biopsies confirm the presence of a mucosa-associated lymphoid tissue lymphoma (maltoma/marginal zone lymphoma) of low-grade type; *Helicobacter pylori* is demonstrated. Computed tomography (CT) of chest, abdomen and pelvis reveals no additional disease, and a bone marrow trephine is unremarkable; the stomach wall is not clearly thickened.

What treatment would you recommend?

A	Cyclophosphamide, vincristine, doxorubicin and prednisolone (CHOP)
B	Observation alone

disease, and a bone marrow trephine is unremarkable; the stomach wall is not clearly thickened.

What treatment would you recommend?

A	Cyclophosphamide, vincristine, doxorubicin and prednisolone (CHOP)
B	Observation alone
C	*H. pylori* eradication therapy
D	Partial gastrectomy
E	High-dose dexamethasone

6312

Submit

C *H. pylori* eradication therapy

Maltomas, also known as marginal zone lymphomas, are low-grade lymphomas, most often diagnosed in the stomach. They are peculiar in that they are often associated with chronic inflammation of one of the following types:

- In the stomach secondary to chronic *H. pylori* gastritis
- In the eyes secondary to Sjogren syndrome
- In the thyroid secondary to Hashimoto's thyroiditis
- In the intestine secondary to Crohn's or coeliac disease.

Treatment against *H. pylori* is safe and will cause regression in 90% of low-grade gastric maltomas; response is less likely if cytogenetic abnormalities have been acquired (t11:18 being the most common), or if the muscularis mucosa has been invaded. This patient has early-stage disease, so triple

has early-stage disease, so triple therapy coupled with close oncological and gastroenterological follow-up is appropriate.

A	Cyclophosphamide, vincristine, doxorubicin and prednisolone (CHOP)

R-CHOP (including rituximab) is a treatment option for more advanced gastric lymphoma.

B	Observation alone

Observation alone risks significant lymphoma progression, meaning that *H. pylori* eradication would then in all likelihood be ineffective.

D	Partial gastrectomy

Surgery is rarely employed in the treatment of gastric maltoma, because it is usually not curative and results in significant operative morbidity.

A 60-year-old woman is referred with symptoms of generalised malaise. She feels lethargic and breathless on moderate exertion. She has also noticed increased bleeding of her gums on brushing her teeth and has had several chest infections over the past month.

Past history is of diabetes, hypertension and gout.

Investigations:

Hb	8.6 g/dl
WCC	$3.5 \times 10^9/l$
PLT	$64 \times 10^9/l$
Bone marrow aspirate	Myeloid blast cells
Chromosome analysis	t(15:17) translocation

What is the most likely diagnosis?

A	Chronic myeloid leukaemia

WCC	$3.5 \times 10^9/l$
PLT	$64 \times 10^9/l$
Bone marrow aspirate	Myeloid blast cells
Chromosome analysis	t(15:17) translocation

What is the most likely diagnosis?

A	Chronic myeloid leukaemia
B	Acute promyelocytic leukaemia
C	Myelomonocytic leukaemia
D	Erythroleukaemia
E	Megacaryoblastic leukaemia

B Acute promyelocytic leukaemia

Acute promyelocytic leukaemia is also known as FAB (French–American–British) classification type M3. It characteristically denotes a translocation of t(15:17) that involves a retinoic acid receptor gene. This leukaemia is associated with disseminated intravascular coagulation, and can be treated initially with all-trans retinoic acid. The leukaemic cells are generally hypergranular promyelocytes. Other important translocations include:

t(8:14) – Burkitt's lymphoma

t(9:22) – Philadelphia chromosome in chronic myeloid leukaemia.

A Chronic myeloid leukaemia

CML is associated with hepatosplenomegaly and with an increase in granulocytes at all stages of development, including eosinophils and basophils

C	Myelomonocytic leukaemia

In chronic myelomonocytic leukaemia an increase in the peripheral blood monocyte count is expected, which has not been seen here.

D	Erythroleukaemia

Erythroleukaemia does present with pancytopenia as has been seen here, but isn't associated with the t(15:17) translocation, which is typical for acute promyelocytic leukaemia.

E	Megacaryoblastic leukaemia

This is a rare condition where the majority of blast cells are megakaryoblastic. It is seen more commonly in patients with Down syndrome, and is associated with t(1;22)(p13;q13) in approximately 1/3 of cases.

7077

Rate this question:

A 60-year-old woman with rheumatoid arthritis presents with breathlessness and chest pain, developing over a week.

Examination shows a pale, jaundiced patient in some distress, pulse 110 beats per minute (bpm) and third heart sound audible with jugular venous pressure raised. Widespread crackles are audible throughout the chest. There is a 3 cm spleen palpable. An electrocardiogram shows widespread depression of ST segments.

Investigations:

Hb	4.9 g/dl
MCV	105 fl (80–96)
Coombs' test	IgG+
Bilirubin	45 μmol/l (1–22)
LDH	1157 U/l (10–250)

How would you best interpret these tests?

LDH	1157 U/l (10–250)

How would you best interpret these tests?

A Raised MCV is probably due to reticulocytosis

B Urine examination for haemosiderin is likely to be positive

C Haemolysis cannot be confidently ruled out unless the result of a haptoglobin assay is available

D Raised LDH is most likely to be cardiac in origin

E If haemolysis is truly present then close to 100% of bilirubin will be unconjugated

A Raised MCV is probably due to reticulocytosis

This patient has haemolytic anaemia (the IgG antibodies cause warm autoimmune haemolytic anaemia, i.e. the antibody is active at body temperature). Transfusion can be life-saving until immunosuppression can take effect. The bone marrow responds by increasing red cell production; this is in evidence in the peripheral blood by an increase in reticulocytes – immature red blood cells, which have a larger MCV. All patients with active haemolysis are at risk of acquiring folate deficiency due to increased metabolic demands, and all should receive replacement therapy.

B Urine examination for haemosiderin is likely to be positive

The haemolysis occurs extravascularly (e.g. in the liver and spleen), so measures of intravascular haemolysis

(haemoglobinuria, haemoglobinaemia, urinary haemosiderin) will be negative.

C	Haemolysis cannot be confidently ruled out unless the result of a haptoglobin assay is available

The haptoglobins are not a specific marker for haemolysis since these can be decreased or absent in other conditions as well (e.g. genetics, cirrhosis, infancy, pregnancy, burns).

D	Raised LDH is most likely to be cardiac in origin

LDH is increased in haemolysis, although in this patient it would be prudent to exclude a cardiac cause. It is most likely to be due to haemolysis, with the ischaemic picture on ECG being related to anaemia.

E	If haemolysis is truly present then close to 100% of bilirubin will be unconjugated

although in this patient it would be prudent to exclude a cardiac cause. It is most likely to be due to haemolysis, with the ischaemic picture on ECG being related to anaemia.

E	If haemolysis is truly present then close to 100% of bilirubin will be unconjugated

In haemolytic anaemia there is an excess of unconjugated bilirubin in the blood; because the unconjugated bilirubin is not water soluble, one will not see an increase in bilirubin in the urine. Since there is no problem with the liver or bile systems, this excess unconjugated bilirubin will go through all of the normal processing mechanisms that occur (i.e. conjugation, excretion in bile, metabolism to urobilinogen, reabsorption) and will show up as an increase in urine urobilinogen.

33302

Rate this question:

A 45-year-old Cypriot man attends his GP for a new patient appointment. He feels well and works long hours running a painting and decorating business.

The only past history of note is mild hypertension, for which he has been recommended to lose weight and institute lifestyle improvements.

Investigations:

Hb	7.0 g/dl (MCV 68; target cells)
WCC	4.9×10^9/l
PLT	190×10^9/l
Na^+	140 mmol/l
K^+	5.0 mmol/l
Creatinine	130 μmol/l
HbF	Slightly elevated
HbA2	Normal
Faecal occult blood	+

Creatinine	130 μmol/l
HbF	Slightly elevated
HbA2	Normal
Faecal occult blood	+

Which of the following is the most likely diagnosis?

A	Lead poisoning
B	Beta-thalassaemia minor
C	Iron deficiency anaemia
D	Co-existent beta-thalassaemia minor and iron deficiency anaemia
E	Hereditary spherocytosis

D Co-existent beta-thalassaemia minor and iron deficiency anaemia

We are given various clues to the diagnosis here: his nationality points us towards the possibility of thalassaemia minor, yet the anaemia seems unexpectedly severe and HbA2 levels are normal, which is out of keeping with the diagnosis. The faecal occult blood positivity, however, suggests the possibility of co-existent GI tract blood loss, and in cases of severe iron deficiency anaemia the HbA2 may be normal in thalassaemia minor. Hence he requires adequate investigation of his iron status, with iron studies and imaging of the GI tract to rule out occult GI blood loss.

B Beta-thalassaemia minor

Beta-thalassaemia minor may be associated with microcytosis, but wouldn't fit with the positive faecal occult blood reported in this patient.

wouldn't fit with the positive faecal occult blood reported in this patient.

A	Lead poisoning

Lead poisoning is associated with microcytic anaemia, although it wouldn't explain the positive faecal occult blood seen here.

C	Iron deficiency anaemia

Iron deficiency anaemia alone wouldn't explain the significant reduction in MCV seen here with regard to the level of anaemia.

E	Hereditary spherocytosis

Hereditary spherocytosis is associated with haemolysis, not with microcytic anaemia and positive faecal occult bloods as in this patient.

21035

Rate this question:

A 69-year-old retired headteacher with rapidly deteriorating back pain comes to see you in the clinic. The pain started 6 months ago following a fall down the stairs.

Lumbar spine X-ray then confirmed vertebral collapse of L2 and L4. She started calcium/vitamin D3 and a bisphosphonate. The pain has now spread to her thoracic spine. The pain does not vary with time of day or exercise. Although her appetite has decreased, her weight seems steady. She smoked in her youth. She has hypertension.

Current medication comprises regular opioid analgesia, a diuretic and a statin.

On examination, she is pale. Her cardiovascular, chest and abdominal investigations are normal. She is non-specifically tender over her thoracic and lumbar spine. Although her neurological examination is hindered by pain, nothing of note was found. Chest X-ray reveals a slightly enlarged cardiac shadow; T-spine, collapse of

Chest X-ray reveals a slightly enlarged cardiac shadow; T-spine, collapse of T5; L-spine, collapse of L2, L4.

Investigations:

Hb	8.7 g/dl
WCC	3.4×10^9/l
PLT	124×10^9/l
Na^+	142 mmol/l
K^+	4.9 mmol/l
Creatinine	141 μmol/l
Urea	10.1 mmol/l
Ca^+	2.34 mmol/l
Albumin	36 g/l
Bilirubin	12 mmol/l
ALT	36 U/l
ALP	12 mmol/l
TP	84 g/l
PO_4	1.01 mmol/l

ALP	12 mmol/l
TP	84 g/l
PO_4	1.01 mmol/l
ESR	42 mm/h
CRP	6 mg/l

A blood film shows a normocytic anaemia and some rouleaux formation. Urinalysis reveals 2+ of protein.

What is the most likely diagnosis?

A	Osteoporosis
B	Renal cell carcinoma
C	Multiple myeloma
D	Osteoporosis and over-diuresis
E	Squamous cell lung carcinoma

C Multiple myeloma

The rapidly increasing severity of back pain that does not vary with time or movement is significant. Although her calcium is not elevated, her globulins are (by virtue of the fact her total protein is raised and albumin is relatively normal), as is her ESR. She also has renal impairment and multiple areas of vertebral collapse.

Multiple myeloma is a disease in which there is accumulation of malignant plasma cells, generally derived from one clone in the bone marrow. It is characterised by the production of a monoclonal immunoglobulin that can be detected in the serum or urine. It is often associated with bone pain, kidney disease and anaemia.

Diagnostic tests include bone marrow examination, the presence of more than 10% plasma cells being required for diagnosis. A skeletal survey is required for lytic lesions and serum/urine electrophoresis is needed to identify the presence of paraprotein.

to identify the presence of paraprotein. Urinalysis can be performed to identify Bence Jones protein.

Treatment is based around melphalan chemotherapy. In patients under 65 years of age, bortezomib is often used as an induction therapy for those patients going on to high-dose chemotherapy and autologous stem cell transplantation, which often leads to a prolonged remission compared to conventional chemotherapy.

A Osteoporosis

Patients often present with back pain and fractures (including compression fractures) worsening slowly over time. The key points to note are the raised protein levels, renal impairment, raised ESR and proteinuria, which are not in keeping with a diagnosis of osteoporosis, meaning that this is incorrect.

B Renal cell carcinoma

Renal cell carcinomas can metastasise to the lymph nodes, bone, liver, lung and brain, so it would be one of the differentials for this patient. Renal cell cancer can present with bony involvement, anaemia and renal impairment, However, the protein level would usually be normal to low and the overall picture of this patient with raised ESR coupled with vertebral collapse and renal impairment, is more in keeping with a diagnosis of myeloma. Renal cell cancer patients often present with haematuria, unilateral abdominal pain, abdominal mass, fatigue, anorexia and weight loss.

D	Osteoporosis and over-diuresis

Osteoporosis tends to have a more insidious onset. This patient's picture is also not in keeping with a patient who has been over-diuresed. If that were the case, you would expect the patient to have a low sodium and potassium alongside a raised urea and creatinine.

Renal cell carcinomas can metastasise to the lymph nodes, bone, liver, lung and brain, so it would be one of the differentials for this patient. Renal cell cancer can present with bony involvement, anaemia and renal impairment, However, the protein level would usually be normal to low and the overall picture of this patient with raised ESR coupled with vertebral collapse and renal impairment, is more in keeping with a diagnosis of myeloma. Renal cell cancer patients often present with haematuria, unilateral abdominal pain, abdominal mass, fatigue, anorexia and weight loss.

D	Osteoporosis and over-diuresis

Osteoporosis tends to have a more insidious onset. This patient's picture is also not in keeping with a patient who has been over-diuresed. If that were the case, you would expect the patient to have a low sodium and potassium alongside a raised urea and creatinine.

insidious onset. This patient's picture is also not in keeping with a patient who has been over-diuresed. If that were the case, you would expect the patient to have a low sodium and potassium alongside a raised urea and creatinine. However, this patient has normal electrolyte levels.

E	Squamous cell lung carcinoma

This diagnosis is a possibility in this patient. The X-ray commented on an enlarged heart border, but an X-ray is unable to exclude a central mass. The cancer could have spread to the bone but you would usually expect a raised calcium, either secondary to bony involvement or due to a paraneoplastic phenomenon of hypercalcaemia of malignancy in squamous cell lung cancer. This patient's clinical picture does not quite fit with this and, as such, means it is not the most likely diagnosis for this patient.

2297

Rate this question:

A 35-year-old woman is found to have a right-sided deep vein thrombosis (DVT) 3 days after an elective cholecystectomy. She had been started on prophylactic low-molecular weight heparin 2 days prior to the surgery.

Three years ago, she had also suffered a DVT in the same leg, affecting the calf, also following an operation. She had been warfarinised for several months following that incident.

Investigations:

Hb	12.8 g/dl
WCC	7.7×10^9/l
PLT	178×10^9/l
Na^+	140 mmol/l
K^+	4.5 mmol/l
Creatinine	110 μmol/l
PT	14 s
APTT	29 s

Na^+	140 mmol/l
K^+	4.5 mmol/l
Creatinine	110 μmol/l
PT	14 s
APTT	29 s

How long should she be warfarinised for this time?

A 6 weeks

B 3 months

C 6 months

D 1 year

E Lifelong

21539

Submit

C 6 months

In the absence of thrombophilia, the recommendation from guidelines for treatment of a second provoked DVT is 6 months of warfarin. The APTT is in the normal range, which reduces the likelihood of her suffering from anti-phospholipid antibody syndrome, although she may of course have an alternative inherited thrombophilic disorder such as the factor V Leiden mutation.

B 3 months

At least 3 months' anticoagulation is recommended for a first proximal lower limb DVT.

A 6 weeks

Six weeks' warfarinisation may be considered for the treatment of an isolated calf vein DVT.

Six weeks' warfarinisation may be considered for the treatment of an isolated calf vein DVT.

D	1 year

There is no value in giving longer than 6 months' anticoagulation unless the patient has life-long risk factors for further venous thromboembolism; in this case life-long anticoagulation rather than 1 year's treatment is recommended.

E	Lifelong

Recurrence of DVT whilst on warfarin would be an indication for life-long anticoagulation, as would diagnosis of a recognised cause of thrombophilia.

21539

Rate this question:

Next Question

An 18-year-old man presents to the Emergency Department with a haemarthrosis of his left knee after a relatively minor traumatic incident playing football in the park.

You understand from his sister that there have been a number of similar incidents over the past 10 years. The child is adopted, but you understand from previous notes that he may have a bleeding disorder which runs in the family.

Investigations:

Hb	12.1 g/dl
WCC	$5.4 \times 10^9/l$
PLT	$190 \times 10^9/l$
Factor VIII	Normal
PT	13.1 s
APTT	48 s
Bleeding time	Normal

Which of the following is the most likely diagnosis?

Factor VIII	Normal
PT	13.1 s
APTT	48 s
Bleeding time	Normal

Which of the following is the most likely diagnosis?

A Von Willebrand's disease (VWD)

B Haemophilia A

C Acquired haemophilia

D Haemophilia B

E Glanzman thrombasthaenia

21034

Submit

D	Haemophilia B

Haemophilia B, or inherited factor IX deficiency, is responsible for around 20% of cases of haemophilia. Patients usually present in childhood with easy bruising, prolonged bleeding after dental work or haemarthrosis after a relatively minor incident of trauma. Both haemophilia A and B are inherited as x-linked diseases, and as such only male individuals present with the bleeding disorder. Given that his factor VIII levels are normal, factor IX deficiency is the likely diagnosis. Cut-offs for classification of haemophilia range from less than 1% of normal levels of the clotting factor (severe), 1–5% (moderately severe) to 5–40% (mild).

A	Von Willebrand's disease (VWD)

APTT is only mildly prolonged in 50% of patients with VWD, and it is therefore less likely to be the cause of his symptoms versus haemophilia B

his symptoms versus haemophilia B.

B	Haemophilia A

Haemophilia A is ruled out by the normal factor VIII levels seen here.

C	Acquired haemophilia

Acquired haemophilia occurs later in life in patients with collagen vascular disease due to cross-reacting antibodies, and anti-clotting factor antibodies in patients treated for a number of years for haemophilia may lead to reduced effectiveness.

E	Glanzman thrombasthaenia

Glanzmann's is a disorder of platelet function; it is an extremely rare coagulopathy in which the platelets contain defective or low levels of glycoprotein IIb/IIIa, a receptor for fibrinogen.

A 38-year-old woman with a history of systemic lupus erythematosus (SLE) presents with right-sided pleural chest pain and a dry cough, which she has had for 3 weeks.

On examination, she is apyrexial. Auscultation of the chest reveals normal breath sounds although shallow respiration is noted. Chest X-ray is normal.

On further questioning, she reveals that her SLE is usually well controlled and that all her SLE tests were normal when she was seen in clinic 3 months ago.

Investigations:

CRP	8 mg/l
Serum IgG	16.0 g/l (6.0–13.0)
Complement C_3	150 mg/dl (65–190)
Complement C_4	10 mg/dl (15–50)
$p_a(O_2)$	11.5 kPa
$p_a(CO_2)$	4.8 kPa

Complement C_3	150 mg/dl (65–190)
Complement C_4	10 mg/dl (15–50)
$p_a(O_2)$	11.5 kPa
$p_a(CO_2)$	4.8 kPa
oxygen saturation	98%

What is the most likely diagnosis?

A	Reactivation of SLE
B	*Pneumocystis jirovecii* pneumonia (PCP)
C	Pneumonia
D	Pulmonary embolus (PE)
E	Costochondritis

6:08
tps://mypastest.pastest.com
14

On examination, she is apyrexial. Auscultation of the chest reveals normal breath sounds although shallow respiration is noted. Chest X-ray is normal.

On further questioning, she reveals that her SLE is usually well controlled and that all her SLE tests were normal when she was seen in clinic 3 months ago.

Investigations:

CRP	8 mg/l
Serum IgG	16.0 g/l (6.0–13.0)
Complement C_3	150 mg/dl (65–190)
Complement C_4	10 mg/dl (15–50)
$p_a(O_2)$	11.5 kPa
$p_a(CO_2)$	4.8 kPa
oxygen saturation	98%

A Reactivation of SLE

Systemic lupus erythematosus is a relapsing and remitting non-organ-specific autoimmune disease characterised by vasculitis and the presence of antinuclear antibodies. Respiratory symptoms are common (in 65%), and these include non-infective pleurisy. Cases of pneumonia are also more common in the general population due to a relative immune paresis.

Early markers of SLE disease activity include falling C_4 levels, although congenital C_4 deficiency is itself a predisposing factor for SLE development, so these tests must be interpreted with caution. Other markers of disease activity include rising immunoglobulins, falling haemoglobin (Hb), white cell count (WCC), platelets and albumin.

B *Pneumocystis jirovecii* pneumonia (PCP)

PCP is an opportunistic infection associated with immunosuppression due to HIV, haematological disorders (especially leukaemia and post-bone marrow transplant) and oncology and renal transplantation. A decrease in oxygen saturation, as measured by pulse-oximetry during exercise, indicates PCP, especially when the patient doesn't appear acutely unwell and with minimal symptoms.

C	Pneumonia

Pneumonia is an unlikely diagnosis as there are no focal chest signs and CXR is normal. Pathogenic infection of the lungs presents with a productive cough and signs of hyperthermia, tachypnoea and tachycardia, with altered mental status.

D	Pulmonary embolus (PE)

PE may present with the similar symptoms, but ABG results may show reduced PaO_2 and $PaCO_2$. The classic

D	Pulmonary embolus (PE)

PE may present with the similar symptoms, but ABG results may show reduced PaO_2 and $PaCO_2$. The classic findings are not useful in the diagnosis of PE. Many conditions also cause hypoxaemia, but hypocapnia usually is present with embolism; hypercapnia, on the other hand, is rare. A massive PE may show combined respiratory and metabolic acidosis due to circulatory collapse.

E	Costochondritis

This condition is diagnosed after other causes of pleuritic chest pain are ruled out. It presents with tenderness on palpation over the area where the chest pain is reported.

9845

Rate this question:

An 18-year-old man presents to the Accident and Emergency Department with severe back pain that came on while he was ice-skating. He has recently recovered from a viral upper respiratory tract infection, but is otherwise fit and well. He developed back pain without any obvious trauma, and passed dark red urine: he has not passed urine since (four hours ago). He is on no medications and does not smoke or drink. There is no family history of note.

On examination, he is in severe discomfort, temperature 38.3 °C, pulse 120 beats per minute, blood pressure 145/83 mmHg, peripheries are well perfused and there is no cyanosis. He is icteric. Abdominal, respiratory and cardiovascular examinations are unremarkable.

Investigations:

Hb	8.3 g/dl
WCC	4.7×10^9/l
PLT	263×10^9/l

Reticulocytes	145×10^9/l
Blood film	Macrophages with ingested erythrocytes
Creatinine	195 μmol/l
Direct Coomb's test at room temperature	-

What is the most likely diagnosis?

A	Cold haemagglutinin disease
B	Paroxysmal cold haemoglobinuria
C	Rhabdomyolysis
D	Paroxysmal nocturnal haemoglobinuria
E	Evan's syndrome

An 18-year-old man presents to the Accident and Emergency Department with severe back pain that came on while he was ice-skating. He has recently recovered from a viral upper respiratory tract infection, but is otherwise fit and well. He developed back pain without any obvious trauma, and passed dark red urine: he has not passed urine since (four hours ago). He is on no medications and does not smoke or drink. There is no family history of note.

On examination, he is in severe discomfort, temperature 38.3 °C, pulse 120 beats per minute, blood pressure 145/83 mmHg, peripheries are well perfused and there is no cyanosis. He is icteric. Abdominal, respiratory and cardiovascular examinations are unremarkable.

Investigations:

Hb	8.3 g/dl
WCC	4.7×10^9/l

B Paroxysmal cold haemoglobinuria

This patient has developed acute intravascular haemolysis (anaemia, high reticulocyte count, jaundice, haemoglobinuria) in response to cold exposure. In PCH, an antibody that binds temporarily in the cold develops in response to infection – classically syphilis, but more commonly various viral infections including Epstein–Barr virus – and on warming, dissociates and activates complement, causing rapid intravascular haemolysis, with rigors and severe bone pain. The antibody is to the P blood group, and is confirmed by the finding of a Donath-Landsteiner antibody – the patient's serum is incubated with red blood cells at 4°C and warmed, with subsequent haemolysis. P-negative blood (pp) can be used as a negative control. The Coombs test, now more appropriately called the direct agglutination test, is often negative, particularly if taken some time after the episode. It is more likely to be positive if samples are tested at an

positive if samples are tested at an appropriate temperature. Kidney disease can ensue, but patients in general have a single episode that responds to supportive care.

D	Paroxysmal nocturnal haemoglobinuria

PNH is associated with repeated complement-mediated haemolysis and presents with more marked urinary discoloration in the morning.

A	Cold haemagglutinin disease

Cold haemagglutinin disease is not usually paroxysmal in nature, and the Coombs test is positive for C3d: the blood film usually shows agglutination of red cells. Taking these factors together, cold haemagglutinin disease is incorrect.

C	Rhabdomyolysis

Rhabdomyolysis is associated with

A Cold haemagglutinin disease

Cold haemagglutinin disease is not usually paroxysmal in nature, and the Coombs test is positive for C3d: the blood film usually shows agglutination of red cells. Taking these factors together, cold haemagglutinin disease is incorrect.

C Rhabdomyolysis

Rhabdomyolysis is associated with significant muscle necrosis and also with trauma, although none has been described here.

E Evan's syndrome

Evans is Coombs-positive autoimmune haemolytic anaemia, a rare condition of unknown aetiology.

6305

Rate this question:

Next Question

C Thoracoplasty

This question is a 'spot diagnosis'. Clues that this is a thoracoplasty and not any of the alternative options are that there is evidence of rib resection in conjunction with loss of lung volume. The CXR shows a thoracoplasty. This lady had tuberculosis in the 1940s, prior to the use of anti-tuberculosis chemotherapy. She had a thoracoplasty, which was one of the main surgical treatments for tuberculosis between 1930 and 1955. Several ribs were resected, which reduced the thoracic volume and collapsed the underlying lung. The aim was to close the tuberculous cavity and 'rest the lung'. Control of pulmonary tuberculosis and survival was good. However, patients were left with severe chest deformity and the associated respiratory compromise, a restrictive defect.

B Left pneumonectomy

A 28-year-old woman is admitted to the ward from the Gastroenterology Clinic. She has ulcerative colitis which is usually quiescent, but despite maximal mesalazine and prednisolone 60 mg daily she is opening her bowels some 8–10 times per day with bloody diarrhoea.

You examine her on the ward; her BP is 110/70 mmHg, pulse 92/min. Her temperature is 37.8 °C.

On examination, her abdomen is distended and tender, with sparse bowel sounds. Her right leg is also swollen.

Investigations:

Hb	10.0 g/dl
WCC	10.2×10^9/l
PLT	130×10^9/l
CRP	72 mg/l
Na^+	139 mmol/l
K^+	3.8 mmol/l

K^+	3.8 mmol/l
Creatinine	110 μmol/l
Abdominal X-ray	Dilated left-sided colon with evidence of mucosal oedema
Right leg venogram	Above-knee deep venous thrombosis (DVT)

Which of the following is the most appropriate way to manage her DVT?

A Clopidogrel and aspirin

B Elastic stockings

C Rivaroxaban

D Fondaparinux

E Unfractionated heparin

CRP	72 mg/l
Na^+	139 mmol/l
K^+	3.8 mmol/l
Creatinine	110 μmol/l
Abdominal X-ray	Dilated left-sided colon with evidence of mucosal oedema
Right leg venogram	Above-knee deep venous thrombosis (DVT)

Which of the following is the most appropriate way to manage her DVT?

Your answer was correct

A	Clopidogrel and aspirin
B	Elastic stockings
C	Rivaroxaban

E Unfractionated heparin

Patients with an exacerbation of ulcerative colitis are at greatly increased risk of thromboembolic disease. This patient has an extensive right-sided DVT and is at significant risk of developing a pulmonary embolus. Heparinisation is the most appropriate intervention, which can be reversed in the event that surgery is required.

A Clopidogrel and aspirin

Dual anti-platelet therapy neither prevents DVT nor impacts on its progression, and it is therefore not an appropriate intervention here.

B Elastic stockings

Although stockings may be considered for prophylaxis, they aren't appropriate as treatment for an above-knee DVT.

C Rivaroxaban

B Elastic stockings

Although stockings may be considered for prophylaxis, they aren't appropriate as treatment for an above-knee DVT.

C Rivaroxaban

Rivaroxaban is a factor X inhibitor. Although it is useful as a long-term intervention for anti-coagulation in AF or venous thromboembolism, it cannot easily be reversed if surgery is required.

D Fondaparinux

Fondaparinux is a factor Xa inhibitor primarily used in the treatment of acute coronary syndrome.

20948

Rate this question:

Next Question

An 84-year old man presents with easy bruising of 3 months' duration. He was previously fit and well, but has lost a stone in weight recently. He is on no medication and has no allergies. Direct questioning is unremarkable other than some symptoms of prostatism.

Examination shows him to be icteric, with multiple bruises. Abdomen is soft and non-tender with no abnormal masses.

Investigations:

Hb	8.0 g/dl
WCC	13.7×10^9/l
PLT	56×10^9/l
Activated PTT	48 s (30-40)
Fibrinigen	0.9 g/l (1.8-5.4)
Bilirubin	35 μmol/l
Blood film	Schistocytes, nucleated red blood cells, metamyelocytes and myelocytes

Blood film	Schistocytes, nucleated red blood cells, metamyelocytes and myelocytes
Na^+	139 mmol/l
K^+	4.5 mmol/l
Creatinine	167 μmol/l (up from 138 some 6 months earlier)

What is the most likely diagnosis?

A	Prostate cancer
B	Chronic myeloid leukaemia (CML)
C	Myelofibrosis
D	Thrombotic thrombocytopenic purpura
E	Haemolytic uraemic syndrome

A Prostate cancer

This elderly man has evidence of disseminated intravascular coagulation (DIC) – abnormal clotting, low fibrinogen and low platelets – with an associated microangiopathic haemolytic anaemia (MAHA) – schistocytes, also known as fragmented red cells. The commonest cause of chronic DIC in an elderly man with prostatic symptoms is prostate cancer: the presence of immature red (nucleated red blood cells) and white (metamyelocytes and myelocytes) cells in the blood is known as a leucoerythroblastic blood film, and is often seen in cases of bone marrow invasion (and is relatively frequently present in metastatic prostatic cancer, particularly hormone-resistant cases). The diagnosis could be confirmed by measuring prostatic-specific antigen and taking a bone marrow trephine, which may show marrow invasion by gland-forming metastases.

B Chronic myeloid leukaemia

CML most often presents in the 4th and 5th decades. In more than half of patients with CML, the spleen extends more than 5 cm below the left costal margin at the time of discovery. Peripheral blood findings in CML show a typical leukoerythroblastic blood picture, with circulating immature cells from the bone marrow.

C	Myelofibrosis

Like CML, myelofibrosis is commonly associated with splenomegaly, and symptoms of prostatism with evidence of haemolysis would not be expected.

D	Thrombotic thrombocytopenic purpura

TTP can cause MAHA, but does not lead to elevation in APTT, and is associated with cerebral infarction.

E	Haemolytic uraemic syndrome

A 50-year-old white man is referred by his general practitioner (GP) with cellulitis of his right leg that has been difficult to treat with oral antibiotics. The patient has been experiencing increased fatigue and breathlessness. He drinks a glass of wine at the weekends and is a non-smoker. Apart from childhood asthma, he is well and on no regular medication.

On examination: Pale conjunctivae and multiple bruises over all four limbs. There is hepatosplenomegaly and cellulitis of right leg.

Investigations:

Hb	8.2 g/dl
WBC	3×10^9/l
PLT	95×10^9/l
MCV	83 fl
Bone marrow aspirate	Dry tap
Bone marrow biopsy	Cells with a 'fried egg' appearance

Bone marrow aspirate	Dry tap
Bone marrow biopsy	Cells with a 'fried egg' appearance
Tartrate-resistant acid phosphatase stain (TRAP)	strongly positive

What is the most likely diagnosis?

A	Chronic myeloid leukaemia
B	Hairy cell leukaemia
C	Myelodysplasia
D	Myelofibrosis
E	Chronic lymphocytic leukaemia

Hb	8.2 g/dl
WBC	3 x 10^9/l
PLT	95 x 10^9/l
MCV	83 fl
Bone marrow aspirate	Dry tap
Bone marrow biopsy	Cells with a 'fried egg' appearance
Tartrate-resistant acid phosphatase stain (TRAP)	strongly positive

What is the most likely diagnosis?

Your answer was incorrect

A Chronic myeloid leukaemia

B Hairy cell leukaemia

C Myelodysplasia

B Hairy cell leukaemia

Hairy cell leukaemia is a β-lymphocyte disorder. The abnormal cell has hair-like cytoplasmic projections. Infiltration of the bone marrow leads to pancytopenia and patients have hepatosplenomegaly. The abnormal cells are strongly positive for tartrate-resistant acid phosphatase stain (TRAP). Infiltration of the bone marrow gives a dry tap, and a bone marrow biopsy reveals cells that are said to have the characteristic 'fried egg' appearance. Purine analogues and interferon have been used for treatment, and occasionally splenectomy has been required.

Stains:

- TRAP: tends to be positive in hairy cell leukaemia
- Sudan black B stain and myeloperoxidase: tends to be positive in acute myeloblastic leukaemia
- Terminal deoxynucleotidyl

- Terminal deoxynucleotidyl transferase stain (TDT): tends to be positive in acute lymphoblastic leukaemia
- LAP: tends to be raised in polycythemia rubra vera and myelofibrosis; tends to be low in chronic myeloid leukaemia.

D Myelofibrosis

Primary myelofibrosis (PMF) is one of the chronic myeloproliferative disorders, which are collectively characterised by clonal proliferation of myeloid cells with variable morphologic maturity and haematopoietic efficiency. Splenomegaly is a marked feature. Bone marrow biopsy is necessary to demonstrate fibrosis. Some degree of fibrosis is seen in almost all patients; the fibrosis is typically extensive and visualised better with a silver stain (reticulin) or a trichrome stain (mature collagen). Bone marrow sinusoids are

collagen). Bone marrow sinusoids are expanded and there is intravascular haematopoiesis. The fibrosis is generally associated with atypical megakaryocytic hyperplasia, and thickening and distortion of the bony trabeculae (osteosclerosis).

A	Chronic myeloid leukaemia

CML is a myeloproliferative disorder characterised by the proliferation of the precursors for white blood cells, but these precursors retain the ability to differentiate. Symptoms tend to be chronic and the blood profile shows an increased (++) white cell count, with a low or normal haemoglobin and a variable platelet count.

C	Myelodysplasia

Myelodysplasia occurs mainly in the elderly and presents with anaemia, infection or bleeding due to pancytopenia. Serial blood counts show evidence of increasing bone marrow failure and the bone marrow

marrow failure and the bone marrow shows increased cellularity. Patients with <5% blasts in the bone marrow are managed conservatively, 'gentle' chemotherapy is used in patients with high white blood cell counts and intensive chemotherapy is usually reserved for patients under the age of 60 years. Transformation into AML occurs in around 30% of patients. Bone marrow biopsy revealing cells that are said to have the characteristic 'fried egg' appearance is characteristic of hairy cell leukaemia.

E	Chronic lymphocytic leukaemia

The most noteworthy laboratory abnormality found in CLL is lymphocytosis in the peripheral blood and bone marrow. Although the absolute blood lymphocyte threshold for diagnosing CLL has been placed at >5000/microl (5 × 109/l) B lymphocytes, a significant proportion of patients presents with counts as high as 100,000/microl (100 × 109/l). The peripheral blood smear of patients

The most noteworthy laboratory abnormality found in CLL is lymphocytosis in the peripheral blood and bone marrow. Although the absolute blood lymphocyte threshold for diagnosing CLL has been placed at >5000/microl (5 × 109/l) B lymphocytes, a significant proportion of patients presents with counts as high as 100,000/microl (100 × 109/l). The peripheral blood smear of patients with CLL demonstrates a lymphocytosis. The leukemic cells are typically small, mature-appearing lymphocytes with a dense nucleus, partially aggregated (clumped) chromatin and lacking discernible nucleoli. There is a narrow border of clear to slightly basophilic cytoplasm. The blood film in this scenario is not that of CLL. Bone marrow biopsy revealing cells that are said to have the characteristic 'fried egg' appearance' is characteristic of hairy cell leukaemia, and therefore CLL is an incorrect option.

7067

Rate this question:

You are asked to counsel a married couple expecting a baby. They are both fit and well, with no previous medical history.

They both originate from South East Asia, and have no family history of birth abnormalities. There are no abnormalities on examination.

Investigations:

MALE

Hb	11.7 g/dl
Mean cell volume	70 fl (80–96)
Mean cell haemoglobin	19 pg (27–33)
Red cell count	5.6×10^{12}/l (4.7–6.9)
Haemoglobin electrophoresis	normal

FEMALE

Hb	10.1 g/dl
Mean cell volume	68 fl

FEMALE

Hb	10.1 g/dl
Mean cell volume	68 fl
Mean cell haemoglobin	18 pg
Red cell count	6.0 x 10^{12}/l
Haemoglobin electrophoresis	normal

What condition is the fetus at risk from inheriting?

A	ß-Thalassaemia trait
B	Thalassaemia intermedia
C	Hydrops fetalis
D	β -Thalassaemia major
E	Homozygous haemoglobin E

C Hydrops fetalis

Both patients come from an area endemic for a-thalassaemia, and appear to be carriers, with high red blood cell counts and hypochromia/microcytosis. Hydrops fetalis is associated with homozygous alpha-thalassaemia, thus driving the correct answer.

B Thalassaemia intermedia

The terms thalassaemia minor, intermedia and major do not pertain to a- or β-thalassaemia - rather they describe whether the patient is asymptomatic (minor), transfusion dependent (major) or in between (intermedia). Loss of a single a chain (aa/–a) is common (30% in Africa); loss of two a chains (aa/––) is less common, and co-inheritance can lead to hydrops fetalis (––/––), where no a chains are produced, and haemoglobin (Hb) Barts is produced (a gamma-4 tetramer). Loss of three alpha chains

tetramer). Loss of three alpha chains (a-/--) leads to haemoglobin H (HbH) disease (HbH is composed of beta-4 tetramers), usually with a thalassaemia intermedia phenotype.

A	ß-Thalassaemia trait

Patients with β-thalassaemia trait nearly always have a raised haemoglobin A2 and fetal haemoglobin on haemoglobin electrophoresis (although normal A2 variants do exist). The fact that both parents have normal haemoglobin electrophoresis means there is effectively very low/no significant risk of the fetus inheriting beta-thalassaemia trait.

D	β -Thalassaemia major

β-Thalassaemia trait in the parents has effectively been ruled out by the normal haemoglobin electrophoresis, and therefore β-thalassaemia won't occur in the fetus in this case.

haemoglobin on haemoglobin electrophoresis (although normal A2 variants do exist). The fact that both parents have normal haemoglobin electrophoresis means there is effectively very low/no significant risk of the fetus inheriting beta-thalassaemia trait.

D	β -Thalassaemia major

β-Thalassaemia trait in the parents has effectively been ruled out by the normal haemoglobin electrophoresis, and therefore β-thalassaemia won't occur in the fetus in this case.

E	Homozygous haemoglobin E

Haemoglobin-E is associated with mild β-thalassaemia which presents in the first few months of life, and isn't usually a cause of fetal loss.

6307

Rate this question:

Next Question

A 65-year-old gentleman presented to the Emergency Department with persistent nose and gum bleeding. He had also noticed some blurred vision and frontal headaches over the past few hours.

On examination, he was pale and only his gums were actively bleeding. Neurological examination revealed bilateral horizontal nystagmus on left lateral gaze. Ophthalmic examination revealed bilateral decreased visual acuity and retinal haemorrhages.

Investigations:

Hb	9.1 g/dl
WCC	8×10^9/l
PLT	130×10^9/l
Urea	10 mmol/l
Creatinine	170 µmol/l
Corrected calcium	2.8 mmol/l
Phosphate	1.77 mmol/l
Total protein	89 g/dl

Phosphate	1.77 mmol/l
Total protein	89 g/dl
Albumin	30 g/dl
PT	16 s (10–13 seconds)
APTT	55 s (20–35 s)
Peripheral blood smear	Rouleaux formation

What is the most likely cause for his presentation?

A	Hypercalcaemia
B	Bernard–Soulier syndrome
C	Glanzmann thrombasthenia
D	Hyperviscosity syndrome
E	Acute kidney disease

1:32
:tps://mypastest.pastest.com

On examination, he was pale and only his gums were actively bleeding. Neurological examination revealed bilateral horizontal nystagmus on left lateral gaze. Ophthalmic examination revealed bilateral decreased visual acuity and retinal haemorrhages.

Investigations:

Hb	9.1 g/dl
WCC	8×10^9/l
PLT	130×10^9/l
Urea	10 mmol/l
Creatinine	170 μmol/l
Corrected calcium	2.8 mmol/l
Phosphate	1.77 mmol/l
Total protein	89 g/dl
Albumin	30 g/dl
PT	16 s (10–13 seconds)

D Hyperviscosity syndrome

Hyperviscosity syndrome (HSV) refers to the clinical sequelae of increased blood viscosity. Increased serum viscosity usually results from increased circulating serum immunoglobulins, and can be seen in such diseases as Waldenström macroglobulinaemia and multiple myeloma. HVS can also result from increased cellular blood components (typically white or red blood cells) in hyperproliferative states such as the leukaemias, polycythaemia and the myeloproliferative disorders. The clinical presentation in HVS consists principally of the triad of mucosal bleeding, visual changes and neurologic symptoms. Plasmapheresis is the treatment of choice. This removes the circulating paraproteins and reduces the viscosity.

A Hypercalcaemia

The neurological symptoms and gum bleeding do not correspond to the clinical presentation of hypercalcaemia

clinical presentation of hypercalcaemia (lack of concentration, feeling of 'pins and needles').

B	Bernard–Soulier syndrome

This is caused by a deficiency on the surface of the platelet of the glycoprotein Ib/IX receptor that results in a failure of platelets to stick together in a clump at the site of an injury.

C	Glanzmann thrombasthenia

This results in a deficiency in platelet adhesion as a consequence of a deficiency of the surface protein glycoprotein IIb/IIIa.

E	Acute kidney disease

Uraemic encephalopathy would not cause the neurological symptoms described in this scenario. Acute kidney disease usually presents with

A 32-year-old woman presents with increasing breathlessness and angina pain.

Examination reveals pale conjunctivae. She has evidence of a left lower lobe consolidation on auscultation of the chest. Petechiae are present on the lower limbs.

Observations:

Blood pressure	125/79 mmHg
Heart rate	100 bpm, regular
Temperature	37.9 °C
Oxygen saturations	94% on air

Investigations:

Haemoglobin (Hb)	7.5 g/dl
White blood cells (WBC)	2.5×10^9/l
Platelets (PLT)	23×10^9/l

Haemoglobin (Hb)	7.5 g/dl
White blood cells (WBC)	$2.5 \times 10^9/l$
Platelets (PLT)	$23 \times 10^9/l$
Blood film	Blast cells with Auer rods

Given the likely clinical diagnosis, what feature is most associated with a negative outlook?

A Low total WBC count

B Translocation t(8:21)

C Deletion of part of chromosome 5, (5q–)

D Age 32

E Platelet count of 23

C Deletion of part of chromosome 5, (5q–)

With the diagnosis being acute myeloid leukaemia (AML), there are a number of abnormalities which are considered unfavourable when they occur in cases that do not also contain favourable karyotypic changes; these include del (5q–); add (5q+); del (7q–); add (7q+); monosomies of chromosome 5 or 7 and other more complex translocations and additions are also associated with a poor outlook.

A Low total WBC count

Although a low total WBC count may be associated with an increased risk of infection at initial presentation, it does not significantly impact on prognosis vs other abnormalities such as changes in karyotype.

B Translocation t(8:21)

B Translocation t(8:21)

A number of favourable karyotype abnormalities exist in AML; these include t(8;21), inv(16)(p13;q22), t(16;16)(p13;q22) and t(15;17)(q24.1;q21.1), which identifies acute promyelocytic leukaemia.

D Age 32

Survival in AML deteriorates significantly at age 40 and above, with survival at age 60 or greater falling to 13% or lower.

E Platelet count of 23

Thrombocytopenia is commonly observed in patients with AML and does not significantly impact prognosis vs other factors such as renal impairment, performance status, prior haematological malignancy and karyotype abnormalities.

A confused 68-year-old man was brought to the Emergency Department with a 3-day history of severe headaches, blurred vision and spontaneous gum bleeding. Prior to his acute presentation, he had been generally unwell for several months with malaise and weight loss.

On examination, he was drowsy and had widespread lymphadenopathy and a palpable spleen. Heart sounds were normal and his chest was clear to auscultation. Ophthalmoscopy revealed several retinal haemorrhages. There were no focal neurological signs.

Investigations:

Hb	10.0 g/dl
WCC	3.5×10^9/l
PLT	130×10^9/l
Na^+	135 mmol/l
K^+	4.2 mmol/l
Creatinine	170 μmol/l

MCV	96 fl
Urea	7.2 mmol/l
ESR	90 mm/h
Blood film	Rouleaux formation

Serum immunoglobulins:

IgA	3.5 g/l (0.5–4.0)
IgG	10.0 g/l (5.0–13.0)
IgM	22.0 g/l (0.3–2.2)

What is the most likely diagnosis?

A	Tuberculous meningitis
B	Multiple myeloma
C	Herpes simplex encephalitis
D	Waldenstrom's macroglobulinaemia

ESR	90 mm/h
Blood film	Rouleaux formation

Serum immunoglobulins:

IgA	3.5 g/l (0.5–4.0)
IgG	10.0 g/l (5.0–13.0)
IgM	22.0 g/l (0.3–2.2)

What is the most likely diagnosis?

A	Tuberculous meningitis
B	Multiple myeloma
C	Herpes simplex encephalitis
D	Waldenstrom's macroglobulinaemia
E	Chronic lymphocytic leukaemia

D Waldenstrom's macroglobulinaemia

This man has a hyperviscosity syndrome, which occurs when the plasma viscosity rises to a level at which the micro-circulation is impaired (typically >5). Waldenstrom's macroglobulinaemia is the most common cause of this. Waldenstrom's is a lymphoplasmacytoid malignancy, which tends to occur in older men. There is a recently identified genetic component with a high percentage of patients carrying the *MYD88* gene. It usually presents with peripheral lymph node enlargement, enlarged spleen and symptoms of bone marrow infiltration, and is associated with an IgM paraprotein. The high circulating levels of IgM paraprotein form aggregates therefore increase the viscosity of the blood, leading to hyperviscosity syndrome.

Criteria for diagnosis of Waldenström's macroglobulinemia (WM) include:

1. IgM monoclonal gammopathy that

Criteria for diagnosis of Waldenström's macroglobulinemia (WM) include:

1. IgM monoclonal gammopathy that excludes chronic lymphocytic leukaemia and Mantle cell lymphoma
2. Evidence of anaemia, systemic symptoms, hyperviscosity, enlarged lymph nodes or hepatomegaly orand/or splenomegaly that can be attributed to an underlying lymphoproliferative disorder.

Treatment is with alkylating agents or doxorubicin-containing regimes. Plasmapheresis is used for hyperviscosity due to IgM levels.

Less common causes include myeloma (immunoglobulin A (IgA) or IgM paraprotein), polycythaemia or leukaemia (leucostasis).

A	Tuberculous meningitis

This patient has no history of exposure to tuberculosis. TB meningitis is

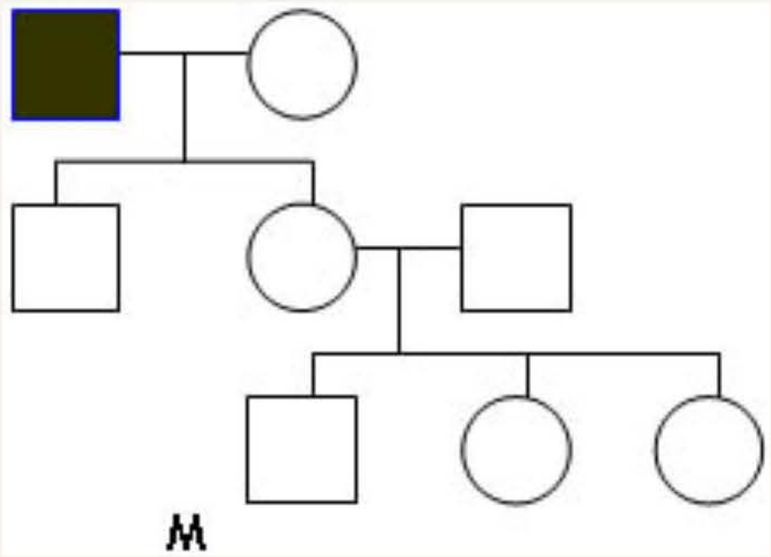

This is the family tree of a family affected with haemophilia A (males denoted by squares, females denoted by circles).

What are the chances of 'M' being affected?

A	1 in 1
B	1 in 2
C	1 in 3
D	1 in 4
E	1 in 6

B 1 in 2

Haemophilia A is a sex-linked inherited disease in humans. Males are hemizygous and receive their only X chromosome from their mother. Females are heterozygous and receive one X chromosome from each parent. Consequently, if a male has an affected X chromosome, he will be affected by an X-linked disease. In the above family tree, the daughter of the affected individual will receive the diseased X chromosome from her father and a normal X chromosome from her mother, so that she is a carrier of the disease. Her son, in turn, will have a 1 in 2 chance of receiving the diseased chromosome from his carrier mother, so the chance of him being affected with haemophilia A is 1 in 2.

E 1 in 6

1 in 6 doesn't fit with a pattern of Mendelian inheritance.

A 70-year-old man presents with recurrent chest infections and abdominal discomfort. He was well until a year ago, but has required recurrent courses of antibiotics from his general practitioner (GP) for chest infections. He has discomfort in the left upper part of his abdomen, and finds that he feels full despite eating only a few mouthfuls at each meal.

On examination, he has a large spleen, palpable 10 cm below the costal margin.

Investigations:

Hb	8.7 g/dl
WCC	$23.2 \times 10^9/l$
Platelets	$25 \times 10^9/l$
Neutrophils	$0.3 \times 10^9/l$
Monocytes	-
Lymphocytes	$21 \times 10^9/l$
	Large numbers of atypical monocytes with abnormal villous

Lymphocytes	$21 \times 10^9/l$
Blood film	Large numbers of atypical monocytes with abnormal villous projections (not picked up on the automated count)

Which of the following is the most likely diagnosis?

A Chronic lymphocytic leukaemia

B Infectious mononucleosis

C Splenic lymphoma with villous lymphocytes

D Pro-lymphocytic leukaemia

E Hairy cell leukaemia

E Hairy cell leukaemia

This gentleman has anaemia, thrombocytopenia, massive splenomegaly and monocytopenia – the last of these is classic for hairy cell leukaemia, and the diagnosis is confirmed by the morphological appearances on the blood film. The typical hairy cells are named because of their characteristic cytoplasmic projections, which appear as fine (hair-like) microvilli when seen by light microscopy, phase-contrast and electron microscopy. These are abnormal B-lymphocyte cells with eccentric or centrally placed nuclei. Hairy cell leukaemia responds dramatically to the purine analogues cladribine and pentostatin, with resulting survival rates at five years of 95–98%.

A Chronic lymphocytic leukaemia

CLL can often be picked up on routine blood tests. It often presents

blood tests. It often presents asymptomatically, but sometimes patients have splenomegaly or enlarged lymph nodes. Smudge cells and abnormal B-lymphocytes (without villous projections) are seen on a blood film.

B	Infectious mononucleosis

This is caused by Epstein–Barr Virus (EBV), and a positive monospot test is diagnostic. There is an increase in lymphocytes on full blood count. It tends to affect a younger population.

C	Splenic lymphoma with villous lymphocytes

This condition is extremely rare. This patient's blood film shows villous projections on monocytes, not lymphocytes, and it does not cause monocytopenia.

D	Pro-lymphocytic leukaemia

A 70-year-old man presents with worsening headaches, three TIAs in the past 6 months and exertional angina. He is a smoker of 30 cigarettes per day and has a history of hypertension for which he takes ramipril 10 mg daily.

On examination, his BP is 165/90 mmHg and he looks plethoric.

Investigations:

Hb	18.5 g/dl
WCC	14.1 x 10^9/l
PLT	520 x 10^9/l
K^+	5.4 mmol/l
Creatinine	160 µmol/l

Which of the following results of further investigations is most likely to differentiate between primary and secondary polycythaemia?

A	Hypoxia on arterial blood gas testing

WCC	14.1 x 10^9/l
PLT	520 x 10^9/l
K^+	5.4 mmol/l
Creatinine	160 µmol/l

Which of the following results of further investigations is most likely to differentiate between primary and secondary polycythaemia?

A Hypoxia on arterial blood gas testing

B Hypercapnia on arterial blood gas testing

C Low erythropoietin

D Elevated CO levels

E Raised viscosity

33318

C Low erythropoietin

Patients with primary polycythaemia carry a mutation that leads to hypersensitivity to erythropoietin. As such, even in the presence of low erythropoietin levels there is a drive to produce more red blood cells. The symptoms seen here are due to increased red cell mass, consequent increase in plasma volume and raised plasma viscosity.
An activating mutation in JAK2 is identified in many patients diagnosed with primary polycythaemia; this induces EPO hypersensitivity. Eventual transformation of primary polycythaemia may occur to acute myeloid leukaemia, chronic lymphocytic leukaemia or chronic myeloid leukaemia.

A Hypoxia on arterial blood gas testing

Chronic hypoxia can cause secondary polycythaemia. This can be due to various conditions such as respiratory

various conditions such as respiratory diseases (COPD, asthma) or cardiac causes (heart failure). It is not a marker used to differentiate between primary and secondary polycythaemia.

B	Hypercapnia on arterial blood gas testing

Hypercapnia is a marker of respiratory conditions such as COPD. Again, this will lead to secondary polycythaemia with raised erythropoietin levels.

D	Elevated CO levels

These are elevated in carbon monoxide poisoning. Elevated CO levels of at least 3–4% in non-smokers and at least 10% in smokers are significant. Diagnosis is confirmed by demonstrating an elevated level of carboxyhaemoglobin (HbCO).

E	Raised viscosity

This is not a specific test and can be

conditions such as COPD. Again, this will lead to secondary polycythaemia with raised erythropoietin levels.

D	Elevated CO levels

These are elevated in carbon monoxide poisoning. Elevated CO levels of at least 3–4% in non-smokers and at least 10% in smokers are significant. Diagnosis is confirmed by demonstrating an elevated level of carboxyhaemoglobin (HbCO).

E	Raised viscosity

This is not a specific test and can be raised in inflammatory, infectious and autoimmune conditions.

33318

Rate this question:

A 70-year-old man presents unconscious to the Accident and Emergency Department. He had been found at his sheltered accommodation by the warden, who brought in his medications: warfarin, furosemide and amoxycillin (10-day course, 5 days' used).

Examination showed a Glasgow coma scale of 5/15, a dilated left-sided pupil and right-sided upper motor neurone signs in the upper and lower limbs. A computed tomography scan of the brain shows a large, left-sided subdural haematoma. Ten milligrams intravenous vitamin K was given immediately.

Investigations:

Hb	9.5 g/dl
WCC	5.3 x 10^9/l
PLT	403 x 10^9/l
APTT	43 s (30–40s)
INR	7.0 (target INR 2.5)

WCC	5.3 x 10^9/l
PLT	403 x 10^9/l
APTT	43 s (30–40s)
INR	7.0 (target INR 2.5)

What is the best way to reverse his warfarin?

A	Prothrombin complex concentrate up to 3000U according to body weight
B	Fresh frozen plasma 15 ml/kg stat
C	Factor VIII bypassing agent (FEIBA)
D	Ten units of cryoprecipitate
E	IV vitamin K

A Prothrombin complex concentrate up to 3000U according to body weight

Prothrombin complex concentrate contains the vitamin K-dependent factors and normalises clotting within minutes of administration; it is the recommended product for life-threatening bleeding due to over-anticoagulation with warfarin. It is plasma derived, so there is a potential risk of transfusion-transmitted infection, and it is prothrombotic.

B Fresh frozen plasma 15 ml/kg stat

Fresh frozen plasma (FFP) contains low levels of coagulation factors and it is estimated that even at a dose of 15 ml/kg, levels of most factors will only approach 20% of normal. In addition, the large volumes of FFP required are likely to precipitate pulmonary oedema, particularly in an elderly man on furosemide. It is only really considered if other options such as

on furosemide. It is only really considered if other options such as PCC are not available.

C	Factor VIII bypassing agent (FEIBA)

FEIBA contains activated factors II, VII, IX and X and is highly thrombogenic; its main use is in the management of acquired inhibitors in haemophilia.

D	Ten units of cryoprecipitate

Cryoprecipitate contains predominantly fibrinogen and factor VIII and it is therefore less effective in reversing bleeding due to warfarin versus PCC.

E	IV vitamin K

Vitamin K given intravenously will start to affect the INR for prothrombin activity within 4–8 h, but this patient is showing signs of temporal lobe herniation (ipsilateral fixed and dilated

FEIBA contains activated factors II, VII, IX and X and is highly thrombogenic; its main use is in the management of acquired inhibitors in haemophilia.

D	Ten units of cryoprecipitate

Cryoprecipitate contains predominantly fibrinogen and factor VIII and it is therefore less effective in reversing bleeding due to warfarin versus PCC.

E	IV vitamin K

Vitamin K given intravenously will start to affect the INR for prothrombin activity within 4–8 h, but this patient is showing signs of temporal lobe herniation (ipsilateral fixed and dilated pupil) and needs immediate cessation of bleeding if he is to survive.

6379

Rate this question:

Next Question

A 30-year-old woman presents with a 3-week history of easy bruising and menorrhagia. On the day of presentation, she developed 'heaviness' in her left arm and slurred speech. She is taking tranexamic acid, prescribed for the menorrhagia. She has no previous medical history of note. According to her husband she was incoherent and confused for half an hour. She is seen in casualty and is conversing easily.

Examination shows a Glasgow coma scale of 15/15, normal neurological examination and normal speech. Temperature is 37.5 °C, pulse is 105 beats per minute (bpm), blood pressure is 130/70 mmHg and heart sounds are normal. She has several bruises on her shins and forearms. A computed tomography (CT) scan of the brain is normal.

Investigations:

Hb	8.5 g/dl
PLT	17 x 10^9/l
MCV	102 fl

MCV	102 fl
Reticulocytes	130 x 10^9/l (25–85)
LDH	735 U/l (10–250)
Blood film	Low counts, numerous schistocytes
PT	15 s (11.5–15.5)
APTT	33 s (30–40)
Pregnancy test	-

Her tranexamic acid is stopped.

Which of the following is the most appropriate intervention?

A Plasmapheresis

B Clopidogrel 75 mg

C Aspirin 75 mg

Blood film	Low counts, numerous schistocytes
PT	15 s (11.5–15.5)
APTT	33 s (30–40)
Pregnancy test	-

Her tranexamic acid is stopped.

Which of the following is the most appropriate intervention?

A Plasmapheresis

B Clopidogrel 75 mg

C Aspirin 75 mg

D Platelet transfusion

E Epsilon aminocaproic acid

A Plasmapheresis

The results show anaemia with a raised reticulocyte count and lactate dehydrogenase, implying haemolysis, and the presence of schistocytes is most compatible with a micro-angiopathic mechanism. Coupled with low platelets and fluctuating neurological signs, this is classical for thrombotic thrombocytopenic purpurae (TTP). The treatment for this is urgent plasmapheresis with fresh frozen plasma or cryosupernate, which is thought to significantly reduce mortality, although there is an absence of randomised controlled trials in this area. In this patient the tranexamic acid is prothrombotic and may be worsening the condition, and hence it has been stopped. Eculizumab may also be utilised in patients with refractory TTP.

The condition is caused by an acquired auto-antibody to a metalloproteinase ADAMTS13, the function of which is to control the size of von Willebrand's

ADAMTS13, the function of which is to control the size of von Willebrand's factor multimers. As a result, ultra-large von Willebrand's factor multimers, with enhanced activity, accumulate and cause increased binding of platelets to small blood vessels. The platelet count falls and red cells are damaged when they pass through the narrowed vessels, causing micro-angiopathy. It is not clear why the brain is the main organ affected in TTP compared with the kidney in the related condition haemolytic uraemic syndrome.

B	Clopidogrel 75 mg

Case reports of TTP occurring in association with clopidogrel therapy exist, although it is sometimes used in patients with TTP once the platelet count reaches >50, in the event that the patient is unable to take aspirin.

C	Aspirin 75 mg

association with clopidogrel therapy exist, although it is sometimes used in patients with TTP once the platelet count reaches >50, in the event that the patient is unable to take aspirin.

C	Aspirin 75 mg

Aspirin is only used on the context of TTP once the platelet count reaches >50.

D	Platelet transfusion

Platelet transfusion is not recommended in patients with TTP, and it may actually have a negative impact on outcomes.

E	Epsilon aminocaproic acid

Epsilon aminocaproic acid is used as a treatment for acute haemorrhage, but is not in the treatment of TTP.

33291

Rate this question:

An 18-year-old Greek woman with beta-thalassaemia major, and who has had several blood transfusions and uses desferrioxamine for prevention of iron overload, comes to the clinic with her sister who is 25 years old and wants to start a family.

They want to discuss the mutation that is the basis of the 18-year old's underlying disease.

Which of the following is the basis of beta-thalassaemia major?

A	1 alpha-chain gene mutation
B	1 beta-chain gene mutation
C	2 alpha-chain gene mutations
D	1 alpha- and one beta-chain gene mutation
E	2 beta-chain mutations

E 2 beta-chain mutations

Beta-thalassaemia major is due to mutations in the genes coding for each of the beta-globin chains. This results in grossly ineffective erythropoiesis and severe hypochromic microcytic anaemia with iron overload. The profound anaemia is associated with erythroid hyperplasia and extramedullary haemopoiesis. Given that her parents were unaffected by thalassaemia major but must have suffered from the thalassaemia trait, the 25-year-old sister has a 66% chance of having the thalassaemia trait, (she is symptomless, meaning that she must either be normal or carry a mutation for 1 of the 2 beta-globin genes). She should be advised to have haemoglobin electrophoresis prior to beginning a family with her new partner.

A 1 alpha-chain gene mutation

One alpha-chain mutation leads to so-

One alpha-chain mutation leads to so called silent alpha-thalassaemia, which is asymptomatic.

B	1 beta-chain gene mutation

This leads to beta-thalassaemia trait, which is the likely diagnosis in the 25-year-old sibling of the patient with thalassaemia major.

C	2 alpha-chain gene mutations

Two alpha-chain mutations lead to alpha-thalassaemia trait microcytic anaemia, which is usually asymptomatic.

D	1 alpha- and one beta-chain gene mutation

Mixed alpha- and beta-thalassaemia is said to carry a milder clinical course than thalassaemia major.

20998

Rate this question:

A 53-year-old man presents with tiredness of 3 months' duration. He has had abdominal pains in the past year that are fleeting in nature, and he has lost one stone in weight. He is on antacids and has no significant previous medical history.

On examination, he is slim with pale conjunctivae, but otherwise there is nothing abnormal to find.

Investigations:

Hb	5.5 g/dl
WCC	4.3×10^9/l
PLT	523×10^9/l
Ferritin	5 µg/l (15–300)
Calcium	2.05 mmol/l

Colonoscopy and gastroscopy are normal (although gastroscopy was abandoned before biopsies were taken due to patient discomfort).

Which investigation would be most useful in making a diagnosis?

Ferritin	5 µg/l (15–300)
Calcium	2.05 mmol/l

Colonoscopy and gastroscopy are normal (although gastroscopy was abandoned before biopsies were taken due to patient discomfort).

Which investigation would be most useful in making a diagnosis?

A	Repeat colonoscopy and gastroscopy
B	Isotope-labelled red cell scan
C	Isotope-labelled white cell scan
D	Tissue transglutaminase antibodies
E	Bone marrow aspirate and trephine

D Tissue transglutaminase antibodies

This gentleman's anaemia is due to iron deficiency, and the most likely cause is blood loss within the gastrointestinal tract. Repeating invasive imaging is unlikely to have as high a yield as tissue transglutamase antibodies, which may reveal an underlying diagnosis of coeliac disease, particularly as this patient failed to tolerate the gastroscopy well last time.

B Isotope-labelled red cell scan

Isotope-labelled red cell scans are useful to exclude significant bleeding, not the limited chronic blood loss which is likely here.

A Repeat colonoscopy and gastroscopy

An adequately prepared colonoscopy and gastroscopy is likely to exclude

An adequately prepared colonoscopy and gastroscopy is likely to exclude significant pathology from the oesophagus, stomach and colon, and thus repeating them has limited utility versus other investigations.

C	Isotope-labelled white cell scan

Isotope-labelled white cell scans are most useful in locating occult intra-abdominal abscesses.

E	Bone marrow aspirate and trephine

Given that there is evidence of iron deficiency anaemia, bone marrow examination is not of value in this case.

6388

Rate this question:

Next Question

An 18-year-old woman presents with an episode of epistaxis, which settles with conservative management. Apparently she has had a recent flu-like illness.

On examination, she has a number of petechiae and some bruising where she has taken knocks or bangs to her legs. She is on no significant medication and has a clean past medical history. You understand that her aunt had a splenectomy as a young adult.

Investigations:

Hb	11.0 g/dl
WCC	5.0 $\times 10^9$/l
PLT	16.0 $\times$ 10^9/l
Na^+	139 mmol/l
K^+	4.0 mmol/l
Creatinine	105 µmol/l

Which of the following is the most appropriate treatment?

Hb	116 g/dl
WCC	5.0 x10^9/l
PLT	16.0 × 10^9/l
Na^+	139 mmol/l
K^+	4.0 mmol/l
Creatinine	105 µmol/l

Which of the following is the most appropriate treatment?

A	Platelet transfusion
B	Prednisolone 20 mg daily
C	Prednisolone 60 mg daily
D	Splenectomy
E	Azathioprine 100 mg daily

20556

On examination, she has a number of petechiae and some bruising where she has taken knocks or bangs to her legs. She is on no significant medication and has a clean past medical history. You understand that her aunt had a splenectomy as a young adult.

Investigations:

Hb	11.0 g/dl
WCC	5.0 x10^9/l
PLT	16.0 × 10^9/l
Na^+	139 mmol/l
K^+	4.0 mmol/l
Creatinine	105 µmol/l

Which of the following is the most appropriate treatment?

Your answer was correct

A	Platelet transfusion

C Prednisolone 60 mg daily

This patient has idiopathic thrombocytopaenic purpura (ITP). Over recent years a familial propensity for the development of ITP has been identified, although the particular gene for susceptibility is yet to be identified. First-line treatment involves the use of high-dose corticosteroids with or without IV immunoglobulins. Thrombopoietin receptor agonists may also reduce the need over the longer term for splenectomy.

A Platelet transfusion

Platelet transfusions may be required for uncontrolled haemorrhage, although they don't reduce the underlying autoantibody burden resulting in platelet destruction. They are not therefore the initial intervention of choice.

B Prednisolone 20 mg daily

resulting in platelet destruction. They are not therefore the initial intervention of choice.

B	Prednisolone 20 mg daily

This dose is likely to prove inadequate to reduce immune-mediated platelet destruction significantly.

D	Splenectomy

Splenectomy is required for patients who don't respond to immune intervention for treatment of their thrombocytopenia.

E	Azathioprine 100 mg daily

Azathioprine is a potential steroid-sparing agent in the treatment of ITP in patients who are unable to significantly reduce their dose of prednisolone without a fall in platelet count.

20556

Rate this question:

You are asked to the Accident and Emergency Department (A&E) to see middle-aged gentleman who has been found unconscious. He has been brought in by ambulance and there is no medical history available, although he has apparently attended A&E in an intoxicated state on a number of occasions over the past year. He has a packet of vitamin tablets but no identifying information.

On examination, his temperature is 36.3 °C, blood pressure 105/65 mmHg and pulse 98 beats per minute. He has a Glasgow coma scale of 9/15 and is breathing deeply. Cranial nerves are intact and peripheral reflexes are normal. A spleen tip is palpable. He has palmar erythema, is jaundiced and has several spider naevi over his chest. Rectal examination reveals melaena.

Investigations:

Hb	98 g/dl
WCC	2.5×10^9/l
PLT	102×10^9/l

Hb	98 g/dl
WCC	2.5×10^9/l
PLT	102×10^9/l
Fibrinogen	0.5g/l (1.8–5.4)
APTT	42 s (30–40 s)
PT	17 s (11.5–15.5 s)

What is the most appropriate blood product to use in this situation?

A	Two units of packed red cells
B	15ml/kg of fresh frozen plasma
C	IV Factor VIII
D	Platelet transfusion
E	10 mg IV vitamin K

2:58
:tps://mypastest.pastest.com

Hb	98 g/dl
WCC	2.5×10^9/l
PLT	102×10^9/l
Fibrinogen	0.5g/l (1.8–5.4)
APTT	42 s (30–40 s)
PT	17 s (11.5–15.5 s)

What is the most appropriate blood product to use in this situation?

Your answer was correct

A Two units of packed red cells

B 15ml/kg of fresh frozen plasma

C IV Factor VIII

D Platelet transfusion

B 15ml/kg of fresh frozen plasma

This gentleman has advanced liver disease with portal hypertension and hypersplenism. He is bleeding internally – possibly from varices, a common cause of hepatic encephalopathy – and has deranged clotting, the most notable feature of which is the low fibrinogen. This is best replaced with cryoprecipitate, which is rich in factor VIII and fibrinogen, although current NICE guidance does not assume widespread availability of cryoprecipitate and therefore recommends FFP, which contains a smaller amount of fibrinogen.

A Two units of packed red cells

Although there may be a fall in Hb once adequate fluid resuscitation is initiated, replacing packed cells won't reduce the risk of further bleeding.

C IV Factor VIII

reduce the risk of further bleeding.

C IV Factor VIII

Factor VIII replacement alone won't adequately reduce bleeding tendency; a source of fibrinogen is also required, which is why cryoprecipitate is preferred.

D Platelet transfusion

Platelet transfusion is of little value where platelets are above 50, and is only usually considered when platelets are below 20 in the face of active bleeding.

E 10 mg IV vitamin K

The PT is not significantly prolonged, and vitamin K will therefore have very limited impact in reducing the risk of further bleeding.

6389

Rate this question:

A 45-year-old woman is referred for investigation of a paraprotein found at a Well-Woman check. She is currently asymptomatic and working full-time as a teacher. She is on no medication and does not smoke. She has three sisters who are all well.

On examination, pulse is 90 beats per minute, blood pressure 110/64 mmHg, heart sounds normal, chest is clear. There is no palpable lymphadenopathy or organomegaly. Neurological examination is unremarkable, with normal fundoscopy and intact sensation.

Investigations:

Hb	14.3 g/dl
WCC	6.3×10^9/l
Platelets	355×10^9/l
Na^+	138 mmol/l
K^+	4.5 mmol/l
Creatinine	100 μmol/l
Protein	

Protein electrophoresis	M band present
Paraprotein quantification IgG kappa	12 g/l
Serum corrected calcium	2.24 mM
Urine	negative for Bence Jones protein
Skeletal survey	unremarkable
Bone marrow aspirate	shows 25% plasma cells
Karyotyping	no high risk features

What is the most appropriate management?

A Regular follow up with blood tests only

B Melphalan and prednisolone

	protein
Skeletal survey	unremarkable
Bone marrow aspirate	shows 25% plasma cells
Karyotyping	no high risk features

What is the most appropriate management?

A	Regular follow up with blood tests only
B	Melphalan and prednisolone
C	Thalidomide and dexamethasone
D	Bortezomib
E	Vincristine, doxorubicin and dexamethasone

Platelets	355 x 10^9/l
Na^+	138 mmol/l
K^+	4.5 mmol/l
Creatinine	100 µmol/l
Protein electrophoresis	M band present
Paraprotein quantification IgG kappa	12 g/l
Serum corrected calcium	2.24 mM
Urine	negative for Bence Jones protein
Skeletal survey	unremarkable
Bone marrow aspirate	shows 25% plasma cells
Karyotyping	no high risk features

What is the most appropriate

A Regular follow up with blood tests only

This patient has probable early myeloma – bone marrow diagnostic of myeloma, but IgG paraprotein of less than 30 g/l and with no evidence of myeloma-associated organ damage (i.e. normal blood count, calcium, renal function and skeletal survey). In this case, early treatment has so far not been proven to change the course of the illness.

B Melphalan and prednisolone

Melphalan is reserved for the treatment of myeloma in more elderly patients with co-morbidities for whom more aggressive intervention is inappropriate.

C Thalidomide and dexamethasone

Thalidomide is a component of modern

C	Thalidomide and dexamethasone

Thalidomide is a component of modern myeloma therapy regimens, and is thought to be effective because of anti-angiogenic properties. It is used in triple combination with dexamethasone and bortezomib.

D	Bortezomib

Bortezomib inhibits the 26S proteasome and is therefore an indirect inhibitor of nuclear factor kappa B, leading to apoptosis. It is used as an induction chemotherapy agent in some regimens.

E	Vincristine, doxorubicin and dexamethasone

This was previously considered the gold standard protocol for myeloma, although this has now been largely superseded by better-tolerated, more effective combination regimens.

A 28-year-old man is newly diagnosed with acute myeloid leukaemia (AML). He receives an initial dose of chemotherapy on day 1 and has become neutropenic at day 7.

At day 14, he is given a broad-spectrum antibiotic after admission via the Emergency Department for fever and rigors. His indwelling catheter is not infected, but unfortunately the fever does not respond. At day 16 there is a cavitating lesion on his chest X-ray.

Which of the following represents the most likely diagnosis?

A	Tuberculosis
B	Invasive *Aspergillus fumigatus*
C	Cytomegalovirus
D	Coagulase-negative *Staphylococcus*

At day 14, he is given a broad-spectrum antibiotic after admission via the Emergency Department for fever and rigors. His indwelling catheter is not infected, but unfortunately the fever does not respond. At day 16 there is a cavitating lesion on his chest X-ray.

Which of the following represents the most likely diagnosis?

A	Tuberculosis
B	Invasive *Aspergillus fumigatus*
C	Cytomegalovirus
D	Coagulase-negative *Staphylococcus*
E	*Pneumocystis jirovecii* pneumonia (PCP)

A 28-year-old man is newly diagnosed with acute myeloid leukaemia (AML). He receives an initial dose of chemotherapy on day 1 and has become neutropenic at day 7.

At day 14, he is given a broad-spectrum antibiotic after admission via the Emergency Department for fever and rigors. His indwelling catheter is not infected, but unfortunately the fever does not respond. At day 16 there is a cavitating lesion on his chest X-ray.

Which of the following represents the most likely diagnosis?

Your answer was incorrect

A	Tuberculosis
B	Invasive *Aspergillus fumigatus*
C	Cytomegalovirus

B Invasive *Aspergillus fumigatus*

The acute onset of fever and rigors in a neutropenic patient and the failure to respond to antibiotics, coupled with the lesion on chest X-ray, suggest infection with *Aspergillus*. The most common infections in the neutropenic patient are Gram-positive bacterial infections (60%), such as *Staphylococcus epidermidis*. Gram-negative infections, such as *Escherichia coli*, also occur with relatively high frequency (30%). Fungal infections occur in less than 10% of patients, but are more likely in those with profound and prolonged neutropenia and pre-existing lung disease.

E *Pneumocystis jirovecii* pneumonia (PCP)

PCP may be seen in patients with neutropenia although patchy alveolar infiltration, rather than cavitation, is the more usual finding.

A Tuberculosis

Primary tuberculosis lesions are not usually associated with cavitation, with caseating granuloma formation including calcification much more usual.

C Cytomegalovirus

Patchy infiltration is usually seen on the CXR in patients suffering from CMV pneumonitis, rather than the discrete area of calcification seen here.

D Coagulase-negative *Staphylococcus*

Coagulase negative *Staphylococcus* would usually be covered by the broad-spectrum antibiotic approach taken in the treatment of patients with febrile neutropenia.

6630

Rate this question:

A 28-year-old woman comes to the Haematology Clinic for review. She has developed a right calf DVT without any precipitating risk factors.

Her only medication of note was the oral contraceptive pill, which she has now stopped and is making alternative arrangements for contraception. She is screened for thrombophilia and is found to be heterozygous for factor V Leiden deficiency.

For how long should she be warfarinised?

A	1 month
B	3 months
C	6 months
D	1 year
E	Lifelong

A 28-year-old woman comes to the Haematology Clinic for review. She has developed a right calf DVT without any precipitating risk factors.

Her only medication of note was the oral contraceptive pill, which she has now stopped and is making alternative arrangements for contraception. She is screened for thrombophilia and is found to be heterozygous for factor V Leiden deficiency.

For how long should she be warfarinised?

Your answer was correct

A	1 month
B	3 months
C	6 months
D	1 year

C 6 months

Without pre-disposing risk factors, guidelines suggest that anticoagulation is continued for 3–6 months in total. Given that we know that this patient is heterozygous for factor V Leiden, it would seem sensible to continue the warfarin for 6 months. Recent population analyses/case series have, however, now suggested that the risk–benefit for lifelong warfarin in a patient with factor V Leiden who has a first DVT may not be positive, due to bleeding risk. As such, lifelong warfarin is no longer recommended in this situation for a first event.

A 1 month

Most patients with a first episode of venous thromboembolism (VTE; provoked or unprovoked) should receive anticoagulation for a minimum of 3 months. Extending anticoagulation beyond 3 months is not routinely considered in patients who have a

considered in patients who have a provoked episode of VTE with the following: transient risk factors, assuming the risk factor is no longer present (e.g. surgery, cessation of hormonal therapy), isolated distal DVT, sub-segmental or incidental pulmonary embolism (PE) or those in whom the risk of bleeding is considered to be high.

B	3 months

This lady has no predisposing factors, so 3–6 months is the recommended duration for anticoagulation. Given that she is heterozygous for factor V Leiden deficiency, it would be sensible to continue up to 6 months.

D	1 year

The benefits of prolonged anticoagulation (6–12 months) even in selected populations (e.g. persisting but reversible risk factor) are unproven.

B	3 months

This lady has no predisposing factors, so 3–6 months is the recommended duration for anticoagulation. Given that she is heterozygous for factor V Leiden deficiency, it would be sensible to continue up to 6 months.

D	1 year

The benefits of prolonged anticoagulation (6–12 months) even in selected populations (e.g. persisting but reversible risk factor) are unproven.

E	Lifelong

There is no benefit in lifelong anticoagulation in patients with factor V Leiden deficiency.

34962

Rate this question:

Next Question

A 37-year-old woman is admitted with confusion. She has no past medical history of note and was previously fit and well.

Examination reveals small petechial haemorrhages on the legs and pale conjunctivae. Her abdomen is soft and non-tender, with no organomegaly detectable. Chest is clear and thorough systemic examination reveals no abnormalities except for a fluctuant Glasgow Coma Scale.

Observations: heart rate 110 bpm, BP 115/72 mmHg, temperature 38.4 °C and O_2 sats 97% on room air.

Investigations:

Hb	9.3 g/dl !120–155)
WCC	13 × 10^9/l (4.0–11.0)
PLT	34 × 10^9/l (150–450)
Na^+	142 mmol/l (135–145)
K^+	5.1 mmol/l (3.5–5.3)

Creatinine	168 μmol/l (45–84)
Plasma haptoglobulin	0.19 g/l (0.3–2.0)
Urea	11.2 mmol/l (2.5–7.8)
CRP	8 mg/l (<5)
Bilirubin	35 μmol/l (3–17)
ALT	38 IU/l (<40)
ALP	100 IU/l (40–130)
GGT	32 IU/l (10–50)
Albumin	38 g/l (35–50)
Urine dipstick	Blood+, protein+
Blood film	Schistocytes
Chest X-ray	Lung fields clear, no other abnormalities detected

Blood film	Schistocytes
Chest X-ray	Lung fields clear, no other abnormalities detected

What is the most likely diagnosis?

A	Henoch–Schönlein purpura (HSP)
B	Thrombotic thrombocytopenic purpura (TTP)
C	Haemolysis, elevated liver enzymes and low platelet count (HELLP) syndrome
D	Chest sepsis
E	Systemic lupus erythematosus (SLE)

B Thrombotic thrombocytopenic purpura (TTP)

TTP is classically associated with the pentad of clinical signs and findings: confusion, pyrexia, kidney disease, thrombocytopenia and microangiopathic haemolytic anaemia. The patient in this case exhibits all of these criteria, although it should be noted that not all patients will display all five.

Thrombotic thrombocytopenic purpura is a condition that causes a microangiopathic haemolytic anaemia. The exact aetiology is unclear, but it has been found to be associated with auto-antibodies to ADAMTS13, a protein responsible for cleaving von Willebrand factor (VWF) into smaller units. Ultra-long VWF is very pro-thrombotic and can form a mesh in the vessels which causes fragmentation of red cells (a microangiopathic haemolytic anaemia). It can be associated with pregnancy and the postpartum period, but is also seen in

haemolytic anaemia). It can be associated with pregnancy and the postpartum period, but is also seen in non-pregnant individuals. TTP is characterised by five symptoms or signs: confusion, pyrexia, kidney disease, thrombocytopenia and microangiopathic haemolytic anaemia. Patients are often treated with plasma exchange. Eculizumab may be useful in patients with refractory disease.

A	Henoch–Schönlein purpura (HSP)

HSP classically affects children post-mild infection. This would be a differential diagnosis for petechial haemorrhages on the patient's legs, but this patient is suffering from many other symptoms (fever and confusion) which would not be explained by HSP. Furthermore, whilst HSP can cause deranged renal function, the low platelet count, raised bilirubin and signs of haemolysis on the blood film seen in this case are not associated with HSP.

C	Haemolysis, elevated liver enzymes and low platelet count (HELLP) syndrome

HELLP syndrome is associated with confusion, haemolysis and low platelets, as seen in this case. However, it is only seen in the setting of pregnancy, or recent delivery, usually associated with pre-eclampsia.

D	Chest sepsis

Sepsis can present very similarly to TTP, i.e. with a fever, confusion and signs of microangiopathic haemolytic anaemia (if deteriorated to disseminated intravascular coagulation) and is always a very important differential diagnosis to be considered in these patients. However, the history and examination suggest that there is no clear source of sepsis, the patient's CRP is not raised and the chest X-ray is normal.

E	Systemic lupus

considered in these patients. However, the history and examination suggest that there is no clear source of sepsis, the patient's CRP is not raised and the chest X-ray is normal.

E	Systemic lupus erythematosus (SLE)

SLE is the great mimic and can affect all organs including the kidneys, brain and blood. However, SLE is a more chronic condition than the history described here. Furthermore, if this answer referred to SLE flares, these are typically in the context of a history of SLE, which this patient does not have and commonly presents with painful joints, rashes and fatigue. Therefore, this is not the most likely diagnosis.

7073

Rate this question:

Next Question

A 53-year-old gentleman was admitted with right-sided hemiparesis. He was known to be on warfarin for a mitral valve replacement and had been adequately anticoagulated. He was taking furosemide and had recently started taking St John's wort for low mood.

On examination, his pulse was 90 beats/min and regular, and his blood pressure was 150/80 mmHg. Cardiac examination demonstrated normal prosthetic valve sounds with an ejection systolic murmur at the left sternal edge. The patient had a right-sided hemiparesis and right upper motor neuron VII nerve palsy.

A computed tomography (CT) scan shows evidence of a left middle cerebral artery infarction.

What is a possible explanation for the presentation?

A	St John's wort is prothrombotic

A computed tomography (CT) scan shows evidence of a left middle cerebral artery infarction.

What is a possible explanation for the presentation?

A	St John's wort is prothrombotic
B	St John's wort reduces the activity of warfarin
C	St John's wort increases platelet aggregation
D	St John's wort increases blood cholesterol levels
E	St John's wort causes vasospasm of the cerebral vessels

B St John's wort reduces the activity of warfarin

St John's wort reduces the INR because it is a potent inducer of cytochrome P450, thus leading to greatly increased warfarin metabolism. Careful monitoring of INR is therefore required if a patient on warfarin wishes to take St John's wort, with up-titration of the warfarin dose according to INR. Ideally an alternative antidepressant should be considered if required, and they should be warned if they do take it that dose reduction of warfarin will be needed when they discontinue the herbal remedy. Echocardiography should also be considered to exclude valve thrombosis, but the immediate priority is assessing and correcting his coagulation status.

A St John's wort is prothrombotic

It is a liver enzyme inducer.

C	St John's wort increases platelet aggregation

It is a liver enzyme inducer, thus increasing the metabolism of warfarin and decreasing the INR, subsequently predisposing to embolic/thrombotic episodes.

D	St John's wort increases blood cholesterol levels

It is a liver enzyme inducer affecting the metabolism of warfarin.

E	St John's wort causes vasospasm of the cerebral vessels

Cerebral vasospasm can be a complication of subarachnoid haemorrhage. The traditional treatment of subarachnoid haemorrhage (SAH) from a ruptured cerebral aneurysm included strict blood pressure control, with fluid restriction and antihypertensive

A 40-year-old female patient on the Haematology Ward has become increasingly unwell over the past few days. She is 2 weeks' post-allogenic haemopoietic stem cell transplant (HSCT) for acute myeloid leukaemia.

On examination, she is jaundiced with ascites, hepatomegaly and right upper quadrant tenderness. Further examination reveals bi-basal inspiratory crepitations and peripheral oedema.

Initial investigations:

Hb	8.9 g/dl (120–155)
WCC	2.8×10^9/l (4.0–11.0)
Neutrophil count	1.8×10^9/l (2.0–7.5)
PLT	60×10^9/l (150–450)
Bilirubin	119 μmol/l (3–17)
ALT	39 IU/l (<40)
ALP	290 IU/l (40–130)
GGT	260 IU/l (10–50)

Albumin	28 g/l (35–50)
CRP	9 mg/l (<5)
Portable chest X-ray	Upper lobe diversion with blunted right costophrenic angle
Pre and post-transplant viral screens	-

What is the most likely diagnosis?

A	Veno-occlusive disease of the liver
B	Hepatitis B infection
C	Transfusion-associated cardiac overload (TACO)
D	Cyclosporin toxicity
E	Cholangitis

days. She is 2 weeks' post-allogenic haemopoietic stem cell transplant (HSCT) for acute myeloid leukaemia.

On examination, she is jaundiced with ascites, hepatomegaly and right upper quadrant tenderness. Further examination reveals bi-basal inspiratory crepitations and peripheral oedema.

Initial investigations:

Hb	8.9 g/dl (120–155)
WCC	2.8×10^9/l (4.0–11.0)
Neutrophil count	1.8×10^9/l (2.0–7.5)
PLT	60×10^9/l (150–450)
Bilirubin	119 µmol/l (3–17)
ALT	39 IU/l (<40)
ALP	290 IU/l (40–130)
GGT	260 IU/l (10–50)
Albumin	28 g/l (35–50)
CRP	9 mg/l (<5)

A Veno-occlusive disease of the liver

This patient is exhibiting signs and investigation findings suggestive of veno-occlusive disease of the liver. Veno-occlusive disease of the liver, otherwise known as sinusoidal obstruction syndrome, is a serious complication of allogeneic stem cell transplantation that can rarely occur within 2 weeks of the transplant. The pathophysiology is unclear, but is thought to be related to the patient's inherent haemostatic derangements.

Classically the patient will start to gain weight, become oedematous, jaundiced and have ascites with tender hepatomegaly. Blood tests will show a hyperbilirubinaemia with often a raised ALP and GGT. A Doppler ultrasound scan will help in confirming the diagnosis, and histology would reveal centrilobular necrosis. Management is difficult and includes maintaining fluid volume while treating ascites and pulmonary oedema. Other treatments tried include heparin and tissue

tried include heparin and tissue plasminogen activator. These patients are at risk of developing multi-organ failure and are often best managed on the intensive therapy unit (ITU) with the transplant team's daily input.

Of note, two weeks' post-transplant, the patient's haemoglobin, platelet, white cell counts and white cell differentials will still be low, although hopefully climbing, as the donor stem cells engraft in the patient's bone marrow and start to produce normal blood cell precursors. This patient's full blood count is therefore not unusual in these circumstances. Post-stem cell transplant patients are only transfused blood products if (1) their Hb is <8.0 g/dl; (2) their platelet count is $<10 \times 10^9$/l or $<20 \times 10^9$/l and septic, or the patient is bleeding; or (3) their platelet count is too low to safely have a necessary procedure.

D Cyclosporin toxicity

Ciclosporin (used post-HSCT to prevent graft-vs-host disease) is a

prevent graft-vs-host disease) is a toxic medication and requires close drug level monitoring. It classically causes gastrointestinal side effects including diarrhoea and nausea, skin side effects including rashes and can be nephrotoxic. Ciclosporin toxicity is not associated with acute fluid overload as seen in this case.

B	Hepatitis B infection

Hepatitis B would be unlikely to present acutely with fluid overload. Furthermore, all patients receiving HSCT (as for solid tumour transplants) are required to have a full viral screen prior to transplant, including HIV, hepatitis B and C, CMV and EBV. This patient's viral screens were negative.

C	Transfusion-associated cardiac overload (TACO)

Patients post-HSCT are very susceptible to TACO, as they receive a very large number of blood products. However, this patient is exhibiting

are required to have a full viral screen prior to transplant, including HIV, hepatitis B and C, CMV and EBV. This patient's viral screens were negative.

C	Transfusion-associated cardiac overload (TACO)

Patients post-HSCT are very susceptible to TACO, as they receive a very large number of blood products. However, this patient is exhibiting upper right quadrant pain and her liver function is markedly deranged, pointing away from TACO.

E	Cholangitis

This patient's CRP is unremarkable, which points away from acute inflammation. However, post-transplant patients are very susceptible to infection and this would be a fair differential diagnosis.

7072

Rate this question:

A 67-year-old woman is reviewed on the ITU after having presented with hypotension, tachycardia and pyrexia. She has been intubated and ventilated, and treatment with IV co-amoxiclav commenced.

Forty-eight hours later, she is deteriorating, requiring noradrenaline support and her creatinine has increased from 145 μmol/l on admission to 235 μmol/l. CRP and white count remain elevated at 310 mg/l and 15.2 x10^9/l, respectively. Glucose is 8.1 mmol/l.

Which of the following is the most appropriate next step?

A	Add hydrocortisone to the regimen
B	Change the antibiotic regime to vancomycin and piperacillin/tazobactam
C	Institute intensive insulin therapy

increased from 145 μmol/l on admission to 235 μmol/l. CRP and white count remain elevated at 310 mg/l and 15.2 x10^9/l, respectively. Glucose is 8.1 mmol/l.

Which of the following is the most appropriate next step?

A	Add hydrocortisone to the regimen
B	Change the antibiotic regime to vancomycin and piperacillin/tazobactam
C	Institute intensive insulin therapy
D	Increase the dose of noradrenaline
E	Start additional dopamine therapy

B Change the antibiotic regime to vancomycin and piperacillin/tazobactam

This woman has signs of ongoing sepsis, as evidenced by her raised inflammatory markers and ongoing hypotension requiring noradrenaline support, and it is likely that the co-amoxiclav has provided inadequate coverage so far. As such, switching to a combination with wide coverage and activity versus *Pseudomonas* is most appropriate, such as vancomycin and piperacillin/tazobactam.

A Add hydrocortisone to the regimen

Guidelines recommend against the routine use of glucocorticoids in patients with sepsis. Hydrocortisone may have a role in the presence of severe sepsis not responding to adequate fluid resuscitation and vasopressors.

C	Institute intensive insulin therapy

Capillary blood glucose should be monitored carefully and IV insulin infusion should be started if capillary blood glucose is persistently higher than 12 mmol/l and the patient is unable to eat and drink. For people with type 1 diabetes, the long-acting insulin should be continued at all times. In our case, capillary blood glucose of 8.1 mmol/l doesn't require intervention.

Concern about the potentially deleterious effects of hyperglycaemia in critically ill patients has motivated multiple randomized controlled trials investigating glycaemic management in ICUs. Several subsequent studies conducted in a variety of settings similarly failed to demonstrate clear benefits to tight glycaemic control in critically ill patients, but consistently highlighted an increased risk of hypoglycaemia among patients treated with intensive insulin protocols.

hypoglycaemia among patients treated with intensive insulin protocols.

D	Increase the dose of noradrenaline

In the present case, there is still the option to escalate the antibiotic therapy prior to increasing the dose of noradrenaline.

E	Start additional dopamine therapy

In patients who remain hypotensive despite adequate fluid resuscitation, appropriate antibiotic choice and noradrenaline, the addition of a second or third agent to noradrenaline may be required (e.g. adrenaline, dobutamine or vasopressin) with little data to support agent selection. Some studies showed improved survival with dobutamine. In the present case, there is still room for antibiotic escalation prior to the addition of a second inotropic agent.

A 22-year-old student is brought to the Emergency Department with recurrent seizures. He had collapsed at the bar and had witnessed seizures. His flatmate reckoned he had nine cocktails that evening. Over the last few weeks he had been missing his first morning lecture and complained of intermittent fever and a dry cough. Intravenous lorazepam terminated the seizure.

On examination, he is lethargic and pale with bruises over his left arm, leg and his right buttock. His temperature is 37.8 °C, pulse 104 bpm and regular, BP 120/68 mmHg. He has gum hypertrophy, poor dentition but no mouth ulcers. His liver had descended to 2 cm but the spleen is not palpable. Neurological examination is symmetrical. Fundoscopy is unremarkable.

Investigations:

U&E	Normal
Ca^{2+}	2.43 mmol/l

U&E	Normal
Ca^{2+}	2.43 mmol/l
Bilirubin	12 μmol/l
ALT	108 U/l
ALP	51 U/l
Glucose	5.2 mmol/l
Albumin	35 g/l
GGT	101 U/l
CRP	62 mg/l
WCC	105.2×10^9/l
Hb	7.3 g/dl
PLT	65×10^9/l
MCV	101 fl

You call the haematology registrar, who immediately performs a bone marrow biopsy which shows the presence of multiple blasts and Auer rods.

Bone marrow cytochemistry:

presence of multiple blasts and Auer rods.

Bone marrow cytochemistry:

Sudan Black	+
Myeloperoxidase	+
Periodic acid–Schiff	-
Non-specific esterase	++

What is the diagnosis?

A	Acute lymphoblastic leukaemia
B	Bacterial meningitis
C	Promyelocytic leukaemia
D	Acute monocytic leukaemia
E	Human T-cell lymphoma virus type-I

Glucose	5.2 mmol/l
Albumin	35 g/l
GGT	101 U/l
CRP	62 mg/l
WCC	105.2×10^9/l
Hb	7.3 g/dl
PLT	65×10^9/l
MCV	101 fl

You call the haematology registrar, who immediately performs a bone marrow biopsy which shows the presence of multiple blasts and Auer rods.

Bone marrow cytochemistry:

Sudan Black	+
Myeloperoxidase	+
Periodic acid–Schiff	-
Non-specific esterase	++

What is the diagnosis?

D Acute monocytic leukaemia

This patient presents with a short history of increasing malaise followed by a grand mal seizure. High counts of circulating blasts (>100 × 10^9/l) may lead to symptoms of cellular hyperviscosity (headache, confusion, fits, focal neurology and coma). Tissue deposits of leukaemic cells (e.g. causing gum hypertrophy) are common in the myelomonocytic and monocytic varieties of acute monocytic leukaemia. Auer rods are a typical finding on bone marrow biopsies. Acute monocytic leukaemia cells characteristically stain positive for Sudan black and myeloperoxidase.

C Promyelocytic leukaemia

This is a subtype of acute myeloid leukaemia (AML). Patients can present with pallor, non-specific infections, thrombocytopenia, petechiae, hepatomegaly, splenomegaly and gingivitis. Cytogenetic studies are

hepatomegaly, splenomegaly and gingivitis. Cytogenetic studies are useful in identifying patients with promyelocytic leukaemia as they will have translocation of the long-arm chromosomes of 15 and 17. There will also be Auer rods present on blood films.

A	Acute lymphoblastic leukaemia

Patients usually present with recurrent infections, bone and joint pain, fatigue, splenomegaly, headaches or complications due to DIC. Patients usually have a raised white cell count, raised LDH and severe anaemia. Blood films show blast cells. For a diagnosis of ALL, there needs to be over 20% blast cells on bone marrow biopsy. Treatment usually consists of short-term intensive chemotherapy initially for remission induction followed by consolidation and maintenance.

B	Bacterial meningitis

for remission induction followed by consolidation and maintenance.

B	Bacterial meningitis

Bacterial meningitis is a reasonable consideration in a student who presents with a history of fevers and seizures. However, the other symptoms such as gum hypertrophy and bruising, coupled with his investigation findings, do not fit with a diagnosis of bacterial meningitis.

E	Human T-cell lymphoma virus type-I

This virus is known to cause a highly aggressive non-Hodgkin's lymphoma. It often causes hypercalcaemia, visceral involvement, skin lesions and lytic bone lesions. This is not in keeping with the patient in this case. meaning that this is unlikely to be the diagnosis.

2300

Rate this question:

A 65-year-old lady attends the Emergency Department complaining of increasing lower back pain, after a weekend of gardening. Her symptoms are relieved with ibuprofen. She denies any bowel or bladder symptoms, and is able to weight bear. She has a past medical history of osteoarthritis of the neck, type 2 diabetes and carcinoma of the colon, which was treated by hemicolectomy 3 years previously.

On examination, heart sounds are normal, the chest is clear, there is a laparotomy scar but no organomegaly and anal tone is normal. Cranial and peripheral nervous system examination are normal.

Investigations:

Hb	10.2 g/dl
WCC	$5.1 \times 10^9/l$
Neutrophils	$2.5 \times 10^9/l$
Lymphocytes	$2.0 \times 10^9/l$
Monocytes	$0.5 \times 10^9/l$
Eosinophils	$0.1 \times 10^9/l$

Eosinophils	$0.1 \times 10^9/l$
Basophils	$0.01 \times 10^9/l$
MCV	82 fl
MCH	27 pg
MCHC	$5 \times 10^9/l$
PLT	250 × 109/l
Sodium	138 mmol/l
Potassium	4.5 mmol/l
Urea	7.4 mmol/l
Creatinine	130 µmol/l
Bilirubin	10 µmol/l
Albumin	32 g/l (37–49)
ALP	55 U/l (45–105)
AST	20 U/l (1–31)
Protein	85 g/l (61–76)
Calcium	2.5 mmol/l (2.2–2.6)
Phosphate	0.9 mmol/l (0.8–1.4)

Calcium	2.5 mmol/l (2.2–2.6)
Phosphate	0.9 mmol/l (0.8–1.4)

Which one of the following tests would best confirm the suspected underlying diagnosis?

A Bone scan

B Serum tumour markers

C Blood film

D Bone marrow aspirate

E Urine dipstick for protein

33303

Submit

Basophils	0.01×10^9/l
MCV	82 fl
MCH	27 pg
MCHC	5×10^9/l
PLT	250 × 109/l
Sodium	138 mmol/l
Potassium	4.5 mmol/l
Urea	7.4 mmol/l
Creatinine	130 µmol/l
Bilirubin	10 µmol/l
Albumin	32 g/l (37–49)
ALP	55 U/l (45–105)
AST	20 U/l (1–31)
Protein	85 g/l (61–76)
Calcium	2.5 mmol/l (2.2–2.6)
Phosphate	0.9 mmol/l (0.8–1.4)

Which one of the following tests

D Bone marrow aspirate

The patient has myeloma, as suggested by the history of bone pain and the findings of a normocytic anaemia, mild renal impairment and a raised total protein in the presence of an albumin just below the normal range, indicating the presence of raised immunoglobulins.
Myeloma is a clonal B-cell malignancy characterised by proliferation of plasma cells that accumulate mainly in bone marrow and usually secrete paraprotein. It accounts for 1% of all malignancies and 10% of haematological malignancies. Bone marrow plasma cell load is a key criterion for the diagnosis of myeloma and, as such, is the correct answer here.

Diagnostic criteria for myeloma: International myeloma working group 2015:

Clonal bone marrow plasma cells >10% or biopsy-proven bony or extramedullary plasmacytoma and any

or biopsy-proven bony or extramedullary plasmacytoma and any one or more of the following features and myeloma-defining events:

- Evidence of end organ damage that can be attributed to the underlying plasma cell proliferative disorder, specifically:
  - Hypercalcaemia: serum calcium >0.25 mmol/l higher than the upper limit of normal or >2.75 mmol/l
  - Renal insufficiency: creatinine clearance <40 ml per minute or serum creatinine >177 mmol/l
  - Anaemia: haemoglobin value of >20 g/l below the lowest limit of normal, or a haemoglobin value <100 g/l
  - Bone lesions: one or more osteolytic lesion on skeletal radiography, CT or PET/CT. If bone marrow has <10% clonal plasma cells, more than one bone lesion is

- Bone lesions: one or more osteolytic lesion on skeletal radiography, CT or PET/CT. If bone marrow has <10% clonal plasma cells, more than one bone lesion is required to distinguish from solitary plasmacytoma with minimal marrow involvement.

- Any one or more of the following biomarkers of malignancy:
  - 60% or greater clonal plasma cells on bone marrow examination
  - Serum involved/uninvolved free light chain ratio of 100 or greater, provided the absolute level of the involved light chain is at least 100 mg/l
  - More than one focal lesion on MRI that is at least 5 mm or greater in size.

A Bone scan

A 29-year-old man presents to the Emergency Department. He has suffered from nearly three hours of severe central chest pain. ECG shows clear evidence of an anterior myocardial infarction.

Other past medical history of note includes severe short-sightedness; he has also suffered from joint laxity with recurrent shoulder dislocation and a left inguinal hernia.

On examination, he is slim, with a BMI of 21, and is 190 cm in height.

Investigations:

Hb	12.1 g/dl
WCC	4.8×10^9/l
PLT	210×10^9/l
Na^+	132 mmol/l
K^+	5.1 mmol/l
Creatinine	120 μmol/l
Urea	5.4 mmol/l
Total cholesterol	5.1 mmol/l

K^+	5.1 mmol/l
Creatinine	120 μmol/l
Urea	5.4 mmol/l
Total cholesterol	5.1 mmol/l

Which of the following diagnoses fits best with the underlying cause of his myocardial infarction?

A	Protein C deficiency
B	Protein S deficiency
C	Familial mixed hyperlipidaemia
D	Homocystinuria
E	Cystinuria

18522

Submit

A 29-year-old man presents to the Emergency Department. He has suffered from nearly three hours of severe central chest pain. ECG shows clear evidence of an anterior myocardial infarction.

Other past medical history of note includes severe short-sightedness; he has also suffered from joint laxity with recurrent shoulder dislocation and a left inguinal hernia.

On examination, he is slim, with a BMI of 21, and is 190 cm in height.

Investigations:

Hb	12.1 g/dl
WCC	4.8×10^9/l
PLT	210×10^9/l
Na^+	132 mmol/l
K^+	5.1 mmol/l
Creatinine	120 μmol/l
Urea	5.4 mmol/l

D Homocystinuria

This man has a history of short-sightedness, ligamentous laxity and thromboembolic phenomena, all of which fit with the possibility of homocystinuria. Marfan syndrome would be associated with ligamentous laxity and lens dislocation, but also with aortic dissection rather than thromboembolic phenomena. Psychiatric features may be seen in up to 50% of patients with homocystinuria, and pyramidal tract symptoms may also be seen. The skin is usually pale and pink, and occasionally livedo reticularis and a malar rash may be seen. Diagnosis may be based on urinary homocysteine levels or other parameters, such as measuring cystathione synthase activity in liver biopsy samples. Possible treatments include pyridoxine and folic acid.

A Protein C deficiency

Protein C deficiency is associated with

Protein C deficiency is associated with increased risk of venous thromboembolism, but not with the marfanoid features seen here.

B	Protein S deficiency

Like protein C deficiency, protein S deficiency can lead to increased risk of venous thromboembolism, although it isn't associated with marfanoid features.

C	Familial mixed hyperlipidaemia

Familial mixed hyperlipidaemia is unlikely given that his total cholesterol is 5.1 mmol/l. High-dose statin therapy is the intervention of choice where there is marked hypercholesterolaemia.

E	Cystinuria

Cystinuria is associated with renal stones, but not the marfanoid picture seen here or with increased risk of

You review a woman who is 34 weeks pregnant. Fetal growth has been normal so far. She presents with epigastric pain and increasing ankle oedema.

Her midwife has noted her blood pressure to be 159/95 mmHg (increased from 132/81 mmHg some 2 weeks earlier). She has proteinuria. Platelet count is reduced at $7 \times 10^9/l$ (down from $160 \times 10^9/l$ some 4 weeks earlier). She has raised transaminases and bilirubin.

What would be the most appropriate treatment for this patient?

A	Hydralazine IV and admit for bed rest
B	Delivery of the baby post replacement of blood products
C	Observation

Her midwife has noted her blood pressure to be 159/95 mmHg (increased from 132/81 mmHg some 2 weeks earlier). She has proteinuria. Platelet count is reduced at 7×10^9/l (down from 160×10^9/l some 4 weeks earlier). She has raised transaminases and bilirubin.

What would be the most appropriate treatment for this patient?

A	Hydralazine IV and admit for bed rest
B	Delivery of the baby post replacement of blood products
C	Observation
D	Oral nifedipine and discharge
E	Urgent ultrasound scan of the liver

B Delivery of the baby post replacement of blood products

This woman has evidence of pre-eclampsia, with a deteriorating blood picture (decreased platelet count and abnormal liver enzymes) and rapidly worsening hypertension. Nearly 10% of women with severe pre-eclampsia and 30–50% of women with eclampsia are affected by the syndrome of haemolysis, elevated liver enzymes and low platelet count (HELLP). The exact relationship between HELLP syndrome and pre-eclampsia is unknown. Women with pre-eclampsia and HELLP syndrome develop hepatocellular necrosis and liver dysfunction. They also have an increased mortality rate, and one third of women with pre-eclampsia develop disseminated intravascular coagulation. The best treatment for this woman would be to deliver the baby. Mild hypertension in pregnancy has been managed with oral nifedipine or labetalol. In this case, IV hydralazine or labetalol may well be

IV hydralazine or labetalol may well be required for blood pressure reduction/control pre-op.

A	Hydralazine IV and admit for bed rest

Women with pre-eclampsia and HELLP syndrome will be unlikely to settle with blood pressure control alone, so delivery of the baby is the best treatment.

C	Observation

Women with pre-eclampsia and HELLP syndrome need treatment, so observation is incorrect.

D	Oral nifedipine and discharge

Women with pre-eclampsia and HELLP syndrome will need more than oral nifedipine for blood pressure control. It would not be appropriate to discharge without treatment.

A 72-year-old woman presents with back pain over the past several months. Additionally, she has suffered from increasing tiredness and lack of energy for the past six months. She has hypertension which is currently controlled on two oral agents and a long history of osteoarthritis affecting her hips and her back.

On examination, she looks relatively well, has a normal blood pressure (BP) of 142/82 mmHg and there are no significant findings on physical examination.

Investigations:

Hb	11.5 g/dl
WCC	5.8×10^9/l
PLT	201×10^9/l
Na^+	139 mmol/l
K^+	5.4 mmol/l
Creatinine	130 μmol/l

Creatinine	130 µmol/l
Bone marrow	8% plasma cells
MM-protein found on electrophoresis	22 g/l

Which of the following is the most likely diagnosis?

A Monoclonal gammopathy of unknown significance (MGUS)

B Multiple myeloma

C Asymptomatic myeloma

D Myelofibrosis

E Myelodysplasia

A Monoclonal gammopathy of unknown significance (MGUS)

According to guidelines, this patient seems likely to have MGUS. The criteria for diagnosis of MGUS include an M-protein level of <30 g/l, <10% plasma cells on bone marrow investigation and no end organ damage associated with myeloma. There should also be no evidence of amyloidosis.

B Multiple myeloma

The fact that the percentage of plasma cells in bone marrow is less than 10% effectively rules out multiple myeloma here.

C Asymptomatic myeloma

Where there is no end organ damage and more than 10% of the bone marrow contains plasma cells, or M-protein is >30 g/l, then this is deemed asymptomatic myeloma.

Where there is no end organ damage and more than 10% of the bone marrow contains plasma cells, or M-protein is >30 g/l, then this is deemed asymptomatic myeloma.

D Myelofibrosis

Myelofibrosis is associated with anaemia, with tear-drop red cells, a leuko-erythroblastic blood picture and splenomegaly, features not seen here.

E Myelodysplasia

Unexplained macrocytic anaemia may predate the diagnosis of myelodysplasia by months or years, and neutropenia and low platelets are also seen. Splenomegaly and lymphadenopathy are very uncommonly seen in patients with myelodysplasia.

21224

Rate this question:

Next Question

A 64-year-old woman was brought into the Emergency Department with a history of increasing confusion and headaches. She was noted to have multiple bruises on her shins and arms.

On examination, she had a temperature of 38 °C. There was evidence of a petechial rash over her chest. She was tachycardic and had a blood pressure of 110/65 mmHg. There was evidence of bronchial breathing at the right base and 1-cm palpable hepatosplenomegaly.

Investigations:

Haemoglobin (Hb)	55 g/l
White cell count (WCC)	18×10^9/l
Platelets (PLT)	20×10^9/l
Sodium (Na)	135 mmol/l
Potassium (K)	4.0 mmol/l
	100

Potassium (K)	4.0 mmol/l
Creatinine (Cr)	100 µmol/l
Prothrombin time (PT)	24 s
Activated partial thromboplastin time (APTT)	46 s
Fibrinogen	0.6 g/l (1.5–5)
Urea	6.0 mmol/l
Glucose	10.0 mmol/l
Calcium (Ca)	2.36 mmol/l
Albumin	35 g/l

What is the recommended treatment for this condition?

A	Imatinib

Glucose	mmol/l
Calcium (Ca)	2.36 mmol/l
Albumin	35 g/l

What is the recommended treatment for this condition?

A	Imatinib
B	All-trans-retinoic acid (ATRA)
C	CHOP chemotherapy: cyclophosphamide, doxorubicin, vincristine and prednisolone
D	Radiotherapy
E	Fludarabine

B All-trans-retinoic acid (ATRA)

The answer is All-trans-retinoic acid (ATRA) (Option B).

The combined presentation of a chest infection, high WCC and disseminated intravascular coagulation (DIC) is typical of acute promyelocytic leukaemia (APL). The presence of DIC is suggestive of APL. DIC is a state of disruption of normal coagulation and fibrinolysis. There is activation of intravascular coagulation, leading to fibrin deposition, which causes platelet consumption (thrombocytopenia), consumption of coagulation factors (high PT and APTT) and fibrinolysis (high D-dimer). This leads to impaired coagulation and bleeding. In addition, fibrin deposition and endothelial activation lead to microvascular thrombosis, which can result in organ failure. This patient has high PT and APTT indicating coagulation factor consumption and low fibrinogen indicating fibrinolysis. Bruising and petechiae is a clinical manifestation of

indicating fibrinolysis. Bruising and petechiae is a clinical manifestation of coagulopathy in this patient. In APL, rearrangement of RARA activates promoters of tissue factors leaking to coagulation, triggering fibrin coagulation and DIC. APL cell apoptosis may also play a role, as may primary hyperfibrinolysis as a result of other prothrombotic factors.

APL is a malignancy of the bone marrow, in which there is a deficiency of mature blood cells in the myeloid line of cells and an excess of immature cells called promyelocytes. APL is considered a type of acute myeloid leukaemia (AML) and is classified as the M3 variant in the internationally accepted French–American–British (FAB) classification. APL is due to a translocation between chromosomes 15 and 17 (t(15;17)). The break in chromosome 15 disrupts the promyelocytic leukaemia (*PML*) gene, which encodes a transcription factor. The break in chromosome 17 interrupts the retinoic acid receptor alpha (*RARα*) gene, which regulates myeloid differentiation. The translocation

differentiation. The translocation creates a *PML/RARα* fusion gene, which leads to an increased proliferation of promyelocytes.

Treatment of APL differs from that for all other forms of AML. Most APL patients are now treated with all-trans-retinoic acid (ATRA). ATRA activates the retinoid receptor RAR and causes promyelocytes to differentiate, which deters them from proliferating. ATRA can induce a complete remission in most patients with APL by stimulating the APL-blasts to mature. However, ATRA cannot eliminate the leukaemic clone. ATRA is therefore used in combination with chemotherapy, including an anthracycline drug.

A	Imatinib

Imatinib (Option A) is incorrect.

Imatinib is used for chronic myelogenous leukaemia (CML) and acute lymphocytic leukaemia (ALL) that is Philadelphia chromosome-positive (Ph^+), and in certain types of

positive (Ph^+), and in certain types of gastrointestinal stromal tumours (GISTs), systemic mastocytosis and myelodysplastic syndrome.

C	CHOP chemotherapy: cyclophosphamide, doxorubicin, vincristine and prednisolone

CHOP chemotherapy: cyclophosphamide, doxorubicin, vincristine and prednisolone (Option C) is incorrect.

This is used for non-Hodgkin's lymphoma.

D	Radiotherapy

Radiotherapy (Option D) is incorrect.

Radiotherapy can be used in ALL or AML in cases of central nervous system involvement.

E	Fludarabine

cyclophosphamide, doxorubicin, vincristine and prednisolone (Option C) is incorrect.

This is used for non-Hodgkin's lymphoma.

D	Radiotherapy

Radiotherapy (Option D) is incorrect.

Radiotherapy can be used in ALL or AML in cases of central nervous system involvement.

E	Fludarabine

Fludarabine (Option E) is incorrect.

Fludarabine is used in the treatment of chronic lymphocytic leukaemia, AML and some types of lymphoma.

33311

Rate this question:

A 40-year-old man presents with the complaint of worsening back pain to his GP. The pain has been present for a couple of months and is no longer relieved with analgesia.

On further questioning, the patient reports that he feels 'tired all the time', and has a reduced appetite with associated weight loss which he had attributed to the analgesics that he was taking. He is otherwise well at present but, 5 years previously, had been treated successfully for stage IA Hodgkin's lymphoma. Apart from analgesics, he is on no other medication.

Positive findings on clinical examination include axillary and inguinal lymphadenopathy, 6 cm splenomegaly and tenderness along the length of his lumbar spine.

Investigations:

Hb	8.1 g/dl
WCC	$12 \times 10^9/l$
Neutrophils	$8 \times 10^9/l$

WCC	$12 \times 10^9/l$
Neutrophils	$8 \times 10^9/l$
Promyelocytes	Increased
PLT	$96 \times 10^9/l$
Lumbar spine X-ray	Normal

What investigation would you perform to confirm the diagnosis?

A	CT scan of the thorax and abdomen
B	Deoxyglucose-labelled PET scan
C	Excision biopsy of an axillary lymph node
D	Splenectomy
E	LDH measurement

C Excision biopsy of an axillary lymph node

The suspicion here is of marrow infiltration secondary to a recurrence of his lymphoma. Bone marrow involvement is low at the initial presentation of patients with stages I and II of Hodgkin's disease. Marrow infiltration causes anaemia, a low white cell count and thrombocytopenia. To confirm the diagnosis, a biopsy of a gland is required.

A CT scan of the thorax and abdomen

CT scan of the thorax, abdomen and pelvis usually follows a lymph node biopsy, accompanied by bone marrow investigation.

B Deoxyglucose-labelled PET scan

PET is combined with CT for staging of Hodgkin's, rather than being the initial

pelvis usually follows a lymph node biopsy, accompanied by bone marrow investigation.

B	Deoxyglucose-labelled PET scan

PET is combined with CT for staging of Hodgkin's, rather than being the initial investigation.

D	Splenectomy

Splenectomy carries significant morbidity, and given that axillary lymph nodes are significantly more accessible, biopsy of an axillary lymph node is the preferred next step.

E	LDH measurement

LDH is a non-specific marker of haematological malignancy and won't help establish the underlying diagnosis.

A 62-year-old patient on warfarin for mitral valve disease and atrial fibrillation had his INR checked and it was markedly raised at 6.9.

There was no history of bleeding. He had received a course of erythromycin over the past few days for a respiratory tract infection.

Which of the following represents the most appropriate management in this case?

Your answer was correct

A	Give fresh frozen plasma (FFP)
B	Give vitamin K
C	Give vitamin K and FFP
D	Omit warfarin for a few days and monitor INR each day

D Omit warfarin for a few days and monitor INR each day

This man has a clear indication for warfarin and would be at risk of embolic stroke if his warfarin was permanently stopped. Current guidelines state that where the INR is less than 8, warfarin can be omitted for a few days and then restarted at an appropriate dose after INR has fallen. Giving vitamin K, FFP or both may confuse dosing in the future, although guidance is to give vitamin K where there is active bleeding because this alters the benefit–risk ratio of giving warfarin in a positive way.

A Give fresh frozen plasma (FFP)

FFP is given only in cases of active bleeding.

B Give vitamin K

Vitamin K is given where there is active

FFP is given only in cases of active bleeding.

B	Give vitamin K

Vitamin K is given where there is active bleeding.

C	Give vitamin K and FFP

As above, vitamin K and FFP is only indicated where there is active bleeding.

E	Stop the warfarin permanently

The patient is still at risk of thromboembolism due to mitral valve disease and atrial fibrillation, and he therefore still needs anticoagulation once INR is optimised.

71095

Rate this question:

A 35-year-old patient is 1-month post-allogeneic bone marrow transplantation, when her condition deteriorates. She has developed a maculopapular rash on the palms of her hands and the soles of her feet, and has become jaundiced. The patient has also been having bouts of vomiting and diarrhoea and, as a result, has lost weight. She is currently taking ciclosporin.

Investigations:

Sodium (Na^+)	137 mmol/l
Potassium (K^+)	3.4 mmol/l
Urea	9.2 mmol/l
Creatinine (Cr)	112 μmol/l
Bilirubin	79 μmol/l
Alkaline phosphatase (ALP)	310 iu/l

(ALP)	310 iu/l
Alanine aminotransferase (ALT)	55 iu/l
Albumin	27 g/l

Skin biopsy shows a lymphocytic infiltrate in the dermis. She is commenced on total parenteral nutrition (TPN).

Which of the following is the next best management step?

A	Stop ciclosporin
B	Commence methylprednisolone
C	Give tissue plasminogen activator (tPA)
D	Commence ganciclovir
E	Commence prostacyclin

A 35-year-old patient is 1-month post-allogeneic bone marrow transplantation, when her condition deteriorates. She has developed a maculopapular rash on the palms of her hands and the soles of her feet, and has become jaundiced. The patient has also been having bouts of vomiting and diarrhoea and, as a result, has lost weight. She is currently taking ciclosporin.

Investigations:

Sodium (Na^+)	137 mmol/l
Potassium (K^+)	3.4 mmol/l
Urea	9.2 mmol/l
Creatinine (Cr)	112 µmol/l
Bilirubin	79 µmol/l

B Commence methylprednisolone

The patient has acute graft-versus-host disease (GVHD). This presents within 100 days of an allogeneic bone marrow transplantation with a skin rash (can progress to erythroderma), liver dysfunction (cholestatic) and diarrhoea (sometimes bloody). It remains a serious cause of mortality and morbidity among bone marrow transplant recipients.

Patients are staged on the severity of involvement of the skin, liver and gastrointestinal tract. Initial aggressive treatment with intravenous (IV) corticosteroids is recommended. Anti-T cell antibodies, such as OKT3, have been used in patients with resistant disease, as have rituximab and anti-thymocyte globulin.

A Stop ciclosporin

Ciclosporin should not be stopped, unless levels are considered in the

Ciclosporin should not be stopped, unless levels are considered in the toxic range.

C	Give tissue plasminogen activator (tPA)

tPA is most useful in veno-occlusive disease associated with bone marrow transplantation.

D	Commence ganciclovir

There is no evidence that the skin lesions are related to cytomegalovirus (CMV); as such, ganciclovir is not required here.

E	Commence prostacyclin

Like tPA, prostacyclin is useful in veno-occlusive disease associated with stem cell transplantation because it leads to small vessel dilatation.

33300

Rate this question:

A 73-year-old man with a history of ischaemic heart disease has been treated with cyclophosphamide and prednisolone for myeloma, diagnosed some time ago.

Over the past two follow-up visits, there has been a gradual rise in his free light chain excretion and an increase in his creatinine from 122 to 142 μmol/l. His blood pressure (BP) is well controlled at 142/70 mmHg on amlodipine 5 mg.

Which of the following interventions is most likely to prevent further renal deterioration?

A	ACE inhibition
B	Fluid intake ≥3 l/day
C	Low-phosphate diet
D	Low-salt diet
E	Spironolactone

A 73-year-old man with a history of ischaemic heart disease has been treated with cyclophosphamide and prednisolone for myeloma, diagnosed some time ago.

Over the past two follow-up visits, there has been a gradual rise in his free light chain excretion and an increase in his creatinine from 122 to 142 μmol/l. His blood pressure (BP) is well controlled at 142/70 mmHg on amlodipine 5 mg.

Which of the following interventions is most likely to prevent further renal deterioration?

Your answer was correct

A	ACE inhibition
B	Fluid intake ≥3 l/day
C	Low-phosphate diet
D	Low-salt diet

B Fluid intake ≥3 l/day

In the majority of cases, renal impairment is caused by the accumulation and precipitation of light chains, which form casts in the distal tubules resulting in renal obstruction. In addition, myeloma light chains are also directly toxic to proximal renal tubules, further adding to renal dysfunction. Adequate hydration, correction of hypercalcaemia and hyperuricaemia and anti-myeloma therapy should be initiated promptly.

Renal function is optimised by maintenance of a high fluid intake (≥3 l/day), according to the results of the MRC myeloma trial from 1984 (see weblink below). This advice still holds (Myeloma guidelines, 2010), and all patients should be instructed as to the importance of this throughout the course of the disease. Potentially nephrotoxic drugs, including aminoglycosides and non-steroidal anti-inflammatory drugs (NSAIDs), should be avoided.

Because BP is relatively well controlled on amlodipine, a second antihypertensive agent is not indicated. Moreover, the introduction of an ACE inhibitor could potentially deteriorate his renal function.

C	Low-phosphate diet

This is recommended in advanced stages of kidney disease.

D	Low-salt diet

This is recommended in hypertension and heart failure. In the present scenario, the key advice in order to maintain/improve renal function is adequate fluid intake.

E	Spironolactone

There is no indication for spironolactone in the current scenario; in addition, it is contraindicated for eGFR <30%.

A 23-year-old plumber presents with gum swelling and drowsiness. Previously fit and well, he first noticed some bleeding from his gums, coupled with easy bruising, over the last week. He takes no medications, smokes 10 cigarettes daily and drinks within 21 units per week.

On examination, he has markedly swollen gums, several enlarged lymph nodes in the neck and groin and 3 cm hepatosplenomegaly. Basic observations were unremarkable. Fundoscopy reveals several retinal haemorrhages and dilated retinal veins.

Investigations:

Hb	6.3 g/dl
WCC	353.7×10^9/l
PLT	6.0×10^9/l
Blood film	Heavy infiltrate of blasts with monocytoid features
Serum lysozyme	73 mg/l (4–13)
APTT	45 s (30–40)

Serum lysozyme	73 mg/l (4–13)
APTT	45 s (30–40)

What is the most appropriate treatment?

A	Combination chemotherapy including arabinosylcytosine after apheresis
B	Transfusion of two units of irradiated blood after apheresis
C	Transfusion of two units of non-irradiated, cytomegalovirus-negative blood before apheresis
D	All-trans-retinoic acid
E	Dexamethasone and vincristine combination chemotherapy

some bleeding from his gums, coupled with easy bruising, over the last week. He takes no medications, smokes 10 cigarettes daily and drinks within 21 units per week.

On examination, he has markedly swollen gums, several enlarged lymph nodes in the neck and groin and 3 cm hepatosplenomegaly. Basic observations were unremarkable. Fundoscopy reveals several retinal haemorrhages and dilated retinal veins.

Investigations:

Hb	6.3 g/dl
WCC	353.7×10^9/l
PLT	6.0×10^9/l
Blood film	Heavy infiltrate of blasts with monocytoid features
Serum lysozyme	73 mg/l (4–13)
APTT	45 s (30–40)

What is the most appropriate treatment?

A Combination chemotherapy including arabinosylcytosine after apheresis

This patient has acute myeloid leukaemia (AML) of either subtype M4 (myelomonocytic) or M5 (monocytic). AML M4/5 are characterised by gum infiltration, organomegaly and lymphadenopathy, monocytoid blasts and raised serum lysozyme. Hypokalaemia and coagulopathy are common. Chemotherapy regimens are designed to achieve induction, (attaining remission), followed by post-remission consolidation, (intensification). Regimes commonly include arabinosylcytosine, mitoxantrone and daunorubicin. The patient also has leucostasis/hyperviscosity, with a high white cell count, drowsiness and retinal vein dilation. Even though he is significantly anaemic, blood transfusion in this situation can cause rapid deterioration and should be done after the white cell count has been brought under control – often blood is

brought under control – often blood is transfused during therapeutic apheresis.

B	Transfusion of two units of irradiated blood after apheresis

Irradiated blood products are used to prevent transfusion-associated graft-versus-host disease in patients with suppressed cellular immunity (Hodgkin's disease, purine analogue therapy and post-stem cell transplant).

C	Transfusion of two units of non-irradiated, cytomegalovirus-negative blood before apheresis

Transfusion of blood before apheresis in a patient with hyperviscosity runs the risk of precipitating rapid deterioration due to an acute thrombosis.

D	All-trans-retinoic acid

Transfusion of blood before apheresis in a patient with hyperviscosity runs the risk of precipitating rapid deterioration due to an acute thrombosis.

D	All-trans-retinoic acid

All-trans-retinoic acid is used in AML M3 (acute promyelocytic leukaemia), where high white cell counts are the exception, lysozyme is not raised and organomegaly and gum hypertrophy are not usual.

E	Dexamethasone and vincristine combination chemotherapy

These agents are used to induce remission in acute lymphoblastic leukaemia.

33290

Rate this question:

Next Question

A 45-year-old self-employed painter and decorator who specialises in renovating old houses is referred to the Haematology Clinic complaining of lethargy and tiredness.

His GP has checked a blood sample and found that he is anaemic, with an Hb of 101 g/l. In addition, the film is commented on and is said to contain polychromatophilic, stippled red blood cells. MCV is 69 fl and serum ferritin is reported as normal.

Which of the following diagnoses fits best with this clinical picture?

A	Ethanol abuse
B	Thalassaemia
C	Lead poisoning
D	Myelodysplasia
E	Myelofibrosis

and found that he is anaemic, with an Hb of 101 g/l. In addition, the film is commented on and is said to contain polychromatophilic, stippled red blood cells. MCV is 69 fl and serum ferritin is reported as normal.

Which of the following diagnoses fits best with this clinical picture?

Your answer was correct

A	Ethanol abuse
B	Thalassaemia
C	Lead poisoning
D	Myelodysplasia
E	Myelofibrosis

Explanation

C	Lead poisoning

C Lead poisoning

There is a major clue in the occupation of this gentleman, in that he may have been exposed to significant quantities of lead in his occupation renovating old buildings. Whilst lead-containing paint was discontinued some years ago, it is still found in older properties. Lead poisoning is a cause of sideroblastic anaemia, characterised by microcytosis, polychromatic, stippled red blood cells and ring sideroblasts with erythroid hyperplasia on bone marrow examination. Elimination of lead exposure in this case may lead to a slow recovery.

A Ethanol abuse

The direct toxic effects of alcohol can lead to sideroblastic anaemia, although it seems perhaps unlikely with a significant alcohol addiction that he would be able to hold down his job as a painter and decorator.

B Thalassaemia

B Thalassaemia

Thalassaemia does result in microcytic anaemia, although it also leads to elevated iron and ferritin, and many other features of chronic disease not seen here.

D Myelodysplasia

The blood film is not typical for myelodysplasia. The blood film characteristically shows dimorphic red cells, with Pappenheimer bodies, basophilic stippling and dysplastic erythrocytes, as evidenced by anisocytosis and poikilocytosis.

E Myelofibrosis

Given the age of this patient, myelofibrosis is very unlikely; in addition, teardrop-shaped red blood cells and a leucoerythroblastic blood picture are more usual features.

The following panel results were seen for a transfusion recipient and the donor unit of blood.

Donor sample is positive for the following antibodies;

Anti A positive
Anti B positive
Anti rhesus positive

Recipient is positive for the following antibodies;

Anti-A positive
Anti-B negative
Anti rhesus negative

What blood group was the recipient?

A	AB-
B	B+
C	A+
D	A-
E	B-

B B+

This man has antibodies to the A blood group antigen, which means he does not possess it himself. In contrast, he has no anti-B or anti-rhesus antibodies, and therefore he must have a B+ blood group. The donor panel suggests that the donor has antibodies to all three antigens, A, B and rhesus. As such, he or she must be blood group O–, the so-called universal donor.

A AB-

The presence of anti-A antibodies means this patient's red cells cannot carry the A antigen. Blood groups B or O may be associated with anti-A antibodies.

C A+

The presence of anti-A antibodies means this patient's red cells cannot carry the A antigen.

C A+

The presence of anti-A antibodies means this patient's red cells cannot carry the A antigen.

D A-

Anti-A antibodies rule out the presence of the A blood group antigen. The fact that the recipient is anti-rhesus negative means that his blood cells must carry the rhesus antigen.

E B-

Although the fact he is anti-A positive would fit with the B blood group, anti-rhesus negativity fits with his red cells carrying the rhesus antigen.

20997

Rate this question:

Next Question

A 38-year-old motorcyclist is admitted to the Emergency Department. It quickly becomes apparent that he has suffered an unstable pelvic fracture during his accident and is gravely ill.

The Emergency Department staff carry out blood testing, and his Hb is revealed as 40 g/l. He confirms that he is of sound mind and that he is a Jehovah's witness, his religion meaning that he should refuse a blood transfusion. He later dies.

To which of the following ethical principles should the treating physician refer in explaining his reasons for not carrying out a transfusion?

A	Autonomy
B	Beneficence
C	Non-maleficence
D	Justice

The Emergency Department staff carry out blood testing, and his Hb is revealed as 40 g/l. He confirms that he is of sound mind and that he is a Jehovah's witness, his religion meaning that he should refuse a blood transfusion. He later dies.

To which of the following ethical principles should the treating physician refer in explaining his reasons for not carrying out a transfusion?

A	Autonomy
B	Beneficence
C	Non-maleficence
D	Justice
E	Utilitarianism

A 38-year-old motorcyclist is admitted to the Emergency Department. It quickly becomes apparent that he has suffered an unstable pelvic fracture during his accident and is gravely ill.

The Emergency Department staff carry out blood testing, and his Hb is revealed as 40 g/l. He confirms that he is of sound mind and that he is a Jehovah's witness, his religion meaning that he should refuse a blood transfusion. He later dies.

To which of the following ethical principles should the treating physician refer in explaining his reasons for not carrying out a transfusion?

Your answer was incorrect

A Autonomy

B Beneficence

A Autonomy

In the case of a competent adult, patient autonomy must be respected as being of utmost importance, and patient beliefs related to being a Jehovah's Witness are an example of where autonomy must be supported.

E Utilitarianism

Utilitarianism is essentially the principle of doing the 'greatest good for the greatest number'. Utilitarianism may have applied if the doctor had treated a man who had a number of dependants, and was under-insured, making an argument that preserving this man's life had a much wider benefit (although at the time of injury this is of course highly unlikely to be apparent!).

B Beneficence

This is the medical principle that any

this is of course highly unlikely to be apparent!).

B Beneficence

This is the medical principle that any treatment intervention must be for the benefit of the patient.

C Non-maleficence

Non-maleficence is the principle of 'first do no harm' when initiating patient treatments.

D Justice

In medical ethics, the concept of justice can be subdivided into three categories: fair distribution of healthcare resources (distributive justice), respect for people's rights (rights based justice) and respect for the law (legal justice).

20995

Rate this question:

You are asked to see a 20-year-old man with a temperature of 39 °C. He is an in-patient receiving an allogeneic bone marrow transplant. He was diagnosed with chronic myeloid leukaemia three months previously and was treated with imatinib mesylate, which brought about a rapid haematological and cytogenetic remission.

He received myeloablative conditioning with total body irradiation and cyclophosphamide 10 days previously, and received stem cells collected from his brother, with whom he is fully HLA (human leucocyte antigen) compatible. He first became febrile five days ago, and has received ceftazidime (changed to meropenem after 48 h) and vancomycin intravenously.

Examination shows an unwell young man; pulse 120 beats per minute, blood pressure 110/60 mmHg, heart sounds normal; capillary refill < 2 s; respiratory rate 24 breaths per minute, crackles in the right mid-zone; abdomen normal. Urine output is above 30 ml/h, and has

the right mid-zone, abdomen normal. Urine output is above 30 ml/h, and has been negative to date.

Investigations:

Hb	9.3 g/dl
WCC	0.2 x 10^9/l
PLT	12 x 10^9/l
Blood cultures	- at 48 h
Urine cultures	- at 48 h
Chest X-ray	Right middle lobe patchy consolidation

What is the most appropriate management?

A	Add in metronidazole for anaerobic cover
B	Change vancomycin to linezolid to cover vancomycin resistant enterococcus

Chest X-ray	Right middle lobe patchy consolidation

What is the most appropriate management?

A	Add in metronidazole for anaerobic cover
B	Change vancomycin to linezolid to cover vancomycin resistant enterococcus
C	Add in acyclovir 10 mg/kg to cover systemic herpes infection
D	Add in liposomal amphotericin 3 mg/kg to cover invasive aspergillosis
E	Add in intravenous fluconazole 400 mg daily to cover invasive candidiasis

Examination shows an unwell young man; pulse 120 beats per minute, blood pressure 110/60 mmHg, heart sounds normal; capillary refill < 2 s; respiratory rate 24 breaths per minute, crackles in the right mid-zone; abdomen normal. Urine output is above 30 ml/h, and has been negative to date.

Investigations:

Hb	9.3 g/dl
WCC	0.2 x 10^9/l
PLT	12 x 10^9/l
Blood cultures	- at 48 h
Urine cultures	- at 48 h
Chest X-ray	Right middle lobe patchy consolidation

What is the most appropriate management?

Your answer was incorrect

D Add in liposomal amphotericin 3 mg/kg to cover invasive aspergillosis

The gravest concern is that the fevers are due to invasive aspergillosis (IA) or related fungal infection. Systemic herpes infection or candidiasis are both possible, but less likely. Diagnosing IA is difficult; computed tomography of the chest is useful at identifying lesions, but is not completely sensitive or specific. Bronchoscopy with lavage suffers from the same limitations, and invasive procedures are discouraged in neutropenic patients. Various serological assays have been trialled, including using the polymerase chain reaction to detect early invasive disease. IA can only be confidently diagnosed by the finding of characteristic hyphae on a biopsy specimen, but for obvious reasons this is rarely available. Vorconazole is the treatment of choice followed by posaconazole. Amphoteracin is used if neither of these agents is effective.

treatment of choice followed by posaconazole. Amphoteracin is used if neither of these agents is effective. Caspofungin, micafungin and anidulafungin can be used if first-line agents are either ineffective or not tolerated. Any immunosuppressive drugs may be reduced, or granulocyte-stimulating colony factor can be used to rectify neutropenia whilst a patient is unwell

B	Change vancomycin to linezolid to cover vancomycin resistant enterococcus

VRE would only be considered at this point if there was microbiological evidence.

A	Add in metronidazole for anaerobic cover

The patient has been well treated for neutropenic sepsis and meropenem will provide reasonable anaerobic cover, so metronidazole is not

neutropenic sepsis and meropenem will provide reasonable anaerobic cover, so metronidazole is not required.

C	Add in acyclovir 10 mg/kg to cover systemic herpes infection

Although systemic herpes infection is possible, it is less likely than other infections such as fungal infections and, as such, would not be the next step in treatment.

E	Add in intravenous fluconazole 400 mg daily to cover invasive candidiasis

Invasive candidiasis should be a consideration but is less likely to be the cause of the ongoing symptoms than invasive aspergillosis and treatment of candidiasis would, therefore, not be the next step.

6300

Rate this question:

A 49-year-old white woman presents to a locum GP to find out the results of some blood investigations performed by her own GP.

She was found to have splenomegaly on a routine examination when she visited her GP, with feelings of excessive tiredness and fatigue. Her blood film had shown elevated basophils and eosinophils with poikilocytes and normoblasts.

Investigations:

Hb	11.0 g/dl
WCC	$38 \times 10^9/l$
PLT	$119 \times 10^9/l$

Which diagnosis would fit the above data?

A	Sideroblastic anaemia
B	Chronic myeloid leukaemia
C	Polycythaemia rubra vera

basophils and eosinophils with poikilocytes and normoblasts.

Investigations:

Hb	11.0 g/dl
WCC	$38 \times 10^9/l$
PLT	$119 \times 10^9/l$

Which diagnosis would fit the above data?

A	Sideroblastic anaemia
B	Chronic myeloid leukaemia
C	Polycythaemia rubra vera
D	Essential thrombocythaemia
E	Thalassaemia

A 49-year-old white woman presents to a locum GP to find out the results of some blood investigations performed by her own GP.

She was found to have splenomegaly on a routine examination when she visited her GP, with feelings of excessive tiredness and fatigue. Her blood film had shown elevated basophils and eosinophils with poikilocytes and normoblasts.

Investigations:

Hb	11.0 g/dl
WCC	$38 \times 10^9/l$
PLT	$119 \times 10^9/l$

Which diagnosis would fit the above data?

A	Sideroblastic anaemia
B	Chronic myeloid leukaemia
C	Polycythaemia rubra vera

B Chronic myeloid leukaemia

Chronic myeloid leukaemia (CML) is one of the myeloproliferative disorders and results from an uncontrolled proliferation of myeloid cells. It is an acquired abnormality involving the haematopoietic stem cell and a reciprocal chromosomal translocation, resulting in the Philadelphia (Ph) chromosome. This chromosome is present in the granulocyte, RBC and platelet precursors of >95% of patients with CML. Poikilocytes are variably shaped erythrocytes. Of the conditions listed, the only one which would cause such a marked elevation of the WCC, thrombocytopenia and mild anaemia is CML.

A Sideroblastic anaemia

Sideroblastic anaemia is associated with the formation of ring sideroblasts, because of defective incorporation of iron into red blood cells.

C Polycythaemia rubra vera

PCRV is associated with predominant elevation in haemoglobin, rather than the marked elevation in white count seen here.

D Essential thrombocythaemia

Essential thrombocythaemia is primarily associated with an increase in platelet count, rather than the increase in white count seen here.

E Thalassaemia

Thalassaemia would not account for the marked elevation in white count with immature red blood cells seen on the film here.

7641

Rate this question:

Next Question

A 30-year-old man presents with breathlessness on exertion of 3 months' duration. He is usually fit and relatively athletic and now needs to stop for breath on climbing a single flight of stairs.

His general practitioner has arranged investigations for possible renal stones, and he completed a 6-month course of warfarin for deep vein thrombosis (DVT) in the last year, but otherwise he has no significant previous medical history.

Examination shows pale conjunctivae and a pulse of 100 bpm; heart sounds are normal, and the jugular venous pressure is not raised.

Investigations:

Haemoglobin (Hb)	6.3 g/dl
White cell count (WCC)	2.5×10^9/l
Neutrophils	1.1×10^9/l
Platelet	16.3×10^9/l

Neutrophils	1.1×10^9/l
Platelet (PLT)	163×10^9/l
Mean corpuscular volume (MCV)	80 fl (80–96)
Reticulocytes	90×10^9/l (25–85)
Blood film	Marked anisocytosis, with polychromasia and hypochromatic cells
Ferritin	10 µg/l (15–300)
Urine dipstick	Blood+++
Mid-stream urinalysis	No cells
Urine culture	Negative

What is the most likely diagnosis?

A Warm autoimmune haemolysis

Urine dipstick	Blood+++
Mid-stream urinalysis	No cells
Urine culture	Negative

What is the most likely diagnosis?

A	Warm autoimmune haemolysis
B	Cold haemagglutinin disease
C	Paroxysmal cold haemoglobinuria
D	Blackwater fever
E	Paroxysmal nocturnal haemoglobinuria (PNH)

and he completed a 6-month course of warfarin for deep vein thrombosis (DVT) in the last year, but otherwise he has no significant previous medical history.

Examination shows pale conjunctivae and a pulse of 100 bpm; heart sounds are normal, and the jugular venous pressure is not raised.

Investigations:

Haemoglobin (Hb)	6.3 g/dl
White cell count (WCC)	2.5×10^9/l
Neutrophils	1.1×10^9/l
Platelet (PLT)	163×10^9/l
Mean corpuscular volume (MCV)	80 fl (80–96)
Reticulocytes	90×10^9/l (25–85)
	Marked anisocytosis

E Paroxysmal nocturnal haemoglobinuria (PNH)

This patient has iron deficiency, mild pancytopenia and urine that is positive for Hb but with no red cells seen in the urine. This is most likely to be due to chronic intravascular haemolysis where free circulating Hb is filtered in the kidneys (haemoglobinaemia and haemoglobinuria). A Perl's stain of the urine will be positive due to iron absorption in uro-epithelial cells, which are then shed in the urine. The causes of chronic intravascular haemolysis are chronic micro-angiopathies, particularly chronic disseminated intravascular coagulation (often secondary to prostatic cancer) and PNH.

PNH is characterised by loss of resistance to complement lysis, so that under acidic conditions, red cells are spontaneously lysed. The condition is confirmed by showing loss of PIG-A anchored proteins that confer resistance to complement-mediated lysis – such as DAF (decay accelerating factor) and MIRL (membrane inhibitor

resistance to complement-mediated lysis – such as DAF (decay accelerating factor) and MIRL (membrane inhibitor of reactive lysis), although in the past, the condition was confirmed with either Ham's or the sucrose lysis test.

This diagnosis is also consistent with previous deep vein thrombosis. PNH is associated with a 40% prevalence of venous thrombosis in the intra-abdominal venous network and is generally prothrombotic. The mechanism for this is poorly understood.

A	Warm autoimmune haemolysis

Warm autoimmune haemolytic anaemia (AIHA) is the most common haemolytic anaemia. Usually, patients present with an increased MCV and hyperbilirubinaemia. The direct Coombs test is diagnostic and also tests for antibodies attached to the surface of red blood cells. Treatment is with corticosteroids and

with corticosteroids and immunoglobulins. This patient's MCV is not in keeping with warm AIHA. Also in AIHA, you would not expect to find Hb in the urine, meaning that AIHA is not the most likely diagnosis for this patient.

B	Cold haemagglutinin disease

Cold haemagglutinin disease is a rare autoimmune haemolytic disease. The cause of the disease is usually unknown in primary disease, but secondary cold agglutinin disease may be associated with certain cancers or viral, bacterial or parasitic infections. Treatment is usually supportive, with any identifiable causes requiring treatment. This patient could potentially have cold haemagglutinin disease. However, this is less likely, given that he did not appear to have a triggering infection, and this diagnosis would not explain pancytopenia, as noted here.

Paroxysmal cold haemoglobinuria is a rare AIHA, characterised by exposure to cold temperatures, leading to Hb in the urine. Triggers include viral and bacterial infections such as measles, mumps, influenza, cytomegalovirus and Epstein–Barr virus. Treatment for the disease itself is not required, as it is usually self-limiting. Antibiotics can be used to resolve bacterial infections.

D	Blackwater fever

Blackwater fever is usually a complication of malaria whereby red blood cells haemolyse, leading to deposition of Hb within the blood vessels and urine. It is associated with pyrexia, jaundice, rapidly progressing anaemia and dark red/black urine. This patient has some features in keeping with blackwater fever, such as dark urine and anaemia, but the anaemia was insidious in onset and he has neither fevers nor any notable travel history and has pancytopenia.

A 57-year-old man is referred to hospital by his GP. Previously well, he gives a history of progressive weakness and breathlessness on exertion over a 2-week period. He is also complaining of symptoms of indigestion. On examination, he is pale and tachycardic. His blood pressure is 110/70 mm Hg. His heart sounds are normal and his chest is clear.

He brings along with him results of blood tests done by his GP:

Hb	8.3 g/dl
WCC	5.2×10^9/l
PLT	410×10^9/l
MCV	69 fl
Peripheral smear	RBCs hypochromic and microcytic, target cells +, pencil cells +, WBC and platelet morphology normal

Which one of the following would you consider an appropriate next step to

Peripheral smear	microcytic, target cells +, pencil cells +, WBC and platelet morphology normal

Which one of the following would you consider an appropriate next step to measure?

A	Serum iron and total iron-binding capacity (TIBC)
B	Serum ferritin
C	Blood lead level
D	Hb electrophoresis and Hb H preparation
E	Liver function tests

33304

Submit

B Serum ferritin

This patient is most likely to have iron-deficiency anaemia due to gastrointestinal blood loss. Hypo-ferritinaemia confirms iron deficiency and is the preferred screening test. Ferritin levels may be falsely elevated in acute inflammatory states (ferritin is an acute-phase reactant).

Stool for occult blood is a relatively insensitive test of gastrointestinal bleeding. Malabsorption, hookworm infestation and chronic haematuria may also result in iron deficiency. Other causes of microcytosis include haemoglobinopathy (in certain ethnic groups), anaemia of chronic disease (normal/high ferritin levels), lead poisoning (check urine and blood lead levels) and myelodysplastic syndromes with ringed sideroblasts.

A Serum iron and total iron-binding capacity (TIBC)

In order to properly understand a value

In order to properly understand a value for TIBC, one also must know the serum iron, the percentage transferrin saturation and the individual clinical situation.

In modern laboratory testing, serum ferritin levels are generally accepted as reliable single indicators of the presence of iron deficiency.

C	Blood lead level

Acute lead poisoning can cause anaemia through haemolysis, accompanied by haemoglobinuria. There is no evidence in this scenario which would support this diagnosis. Symptoms in chronic lead poisoning usually occur with blood levels greater than 50 μg/dl.

D	Hb electrophoresis and Hb H preparation

Haemoglobinopathy is one cause of microcytosis, but it is not the

Symptoms in chronic lead poisoning usually occur with blood levels greater than 50 μg/dl.

D	Hb electrophoresis and Hb H preparation

Haemoglobinopathy is one cause of microcytosis, but it is not the commonest and it is usually discovered earlier in life.

E	Liver function tests

There is no evidence of liver disease from the history and clinical examination, and therefore liver function testing would not be essential for the diagnosis.

33304

Rate this question:

A 26-year-old nurse who has experienced anaphylaxis after eating a fruit salad is recovering in the Emergency Department. She was treated with IV hydrocortisone, antihistamines and IM adrenaline. This is the first occasion that she has had an allergic reaction to fruit.

Her BP is now 122/72 mmHg, with pulse 80/min and regular. Her chest is clear, O_2 saturations are 95%.

Which of the following is the most appropriate observation time prior to discharge?

A	4 hrs
B	6 hrs
C	8 hrs
D	12 hrs
E	24 hrs

D 12 hrs

Anaphylaxis is the result of immunoglobulin E-mediated mast cell degranulation, which releases inflammatory immune mediators. These mediators cause increased vascular permeability, peripheral vasodilation, increased mucus production and bronchial smooth muscle contraction. Anaphylactoid reactions do not require a previous exposure to an allergen, but the clinical course and treatment are identical to those of anaphylaxis.

The primary precipitants of anaphylactic reactions are foods (e.g. milk, soy, eggs, nuts and shellfish), medications (e.g. antibiotics [penicillin], non-steroidal anti-inflammatory drugs, anaesthetics), venom (*Hymenoptera* stings), intravenous contrast materials and latex. Up to 20% of anaphylactic reactions are idiopathic.

Patients with severe anaphylactic reactions, particularly of rapid onset, are at risk of biphasic or rebound

reactions, particularly of rapid onset, are at risk of biphasic or rebound anaphylaxis. The recurrence rate is as high as to 20%. The severity of the reaction, the time of onset after exposure to antigen before the occurrence of symptoms of the primary response, the presence of hypotension or laryngeal oedema during the primary response, and previous history of a biphasic reaction have all been mentioned as risk factors. On average the latest these are seen is 8–10 h after the primary reaction; 12 h is therefore sufficient observation time. All patients being sent home from the Emergency Department should have immediate access to epinephrine injections.

C 8 hrs

Although the majority of cases occur before the 8 h time point, some serious second-phase reactions may be missed.

A 4 hrs

9:21

404 — Not Found × | 404 — Not Found × | Home Feed | Re ×

https://mypastest.pastest.com/Secure/TestMe/

Pastest+

A 62-year-old man with a 40 pack-year history of smoking presents for review with a history of chronic cough and weight loss for some time. A recent episode of haemoptysis has precipitated his attendance at hospital.

On examination, he is emaciated and there is evidence of Horner syndrome. Serum calcium is 3.4 mmol/l. Chest X-ray and bronchoscopy with transbronchial biopsies confirm the presence of a stage IIIa bronchial neoplasm. His calcium is managed with rehydration and pamidronate.

Which of the following is the best way to manage this patient's lung cancer?

A	Surgical excision
B	Radiotherapy
C	Platinum-based chemotherapy and radiotherapy
D	Neoadjuvant chemotherapy followed by surgery
E	Surgical excision followed by chemotherapy

Submit

Rana Alnasser's screen

9:23

404 — Not Found × | 404 — Not Found × | Home Feed | Re ×

https://mypastest.pastest.com/Secure/TestMe/

Pastest+

Question 1 of 102

A 62-year-old man with a 40 pack-year history of smoking presents for review with a history of chronic cough and weight loss for some time. A recent episode of haemoptysis has precipitated his attendance at hospital.

On examination, he is emaciated and there is evidence of Horner syndrome. Serum calcium is 3.4 mmol/l. Chest X-ray and bronchoscopy with transbronchial biopsies confirm the presence of a stage IIIa bronchial neoplasm. His calcium is managed with rehydration and pamidronate.

Which of the following is the best way to manage this patient's lung cancer?

Your answer was correct

A	Surgical excision
B	Radiotherapy
C	Platinum-based chemotherapy and radiotherapy
D	Neoadjuvant chemotherapy followed by surgery
E	Surgical excision followed by chemotherapy

Explanation

C Platinum-based chemotherapy and radiotherapy

Rana Alnasser's screen

9:23

C Platinum-based chemotherapy and radiotherapy

The presence of Horner syndrome suggests significant local invasion and that surgical resection is likely to be impossible. The presence of raised serum calcium suggests the possibility of a squamous cell carcinoma, the most likely to produce PTHrp (parathyroid hormone-related peptide). The most pressing acute need is of course to reduce the serum calcium, and rehydration and IV pamidronate would be the main treatments in this case. Platinum-based chemotherapy and radiotherapy would be the standard care in patients with an irresectable tumour of this type, given concurrently, since studies show that there is an overall improvement in survival rates versus each modality used alone. Cisplatin/vinblastine, and cisplatin/etoposide are commonly used regimens. Immunotherapy with checkpoint inhibitor-based drugs shows promise and will become available over the next few years.

A Surgical excision

Given this patient has Horner syndrome, surgical excision will prove impossible, driving chemotherapy and radiotherapy as the most appropriate intervention.

B Radiotherapy

Radiotherapy alone is proven to be less effective than in combination with chemotherapy. As such, radiotherapy as a single treatment modality is inappropriate unless there are significant tolerability issues with chemotherapy regimens.

D Neoadjuvant chemotherapy followed by surgery

This patient is unsuitable for surgery based on locally

Rana Alnasser's screen

9:24
594-042-7551 Leave

Radiotherapy alone is proven to be less effective than in combination with chemotherapy. As such, radiotherapy as a single treatment modality is inappropriate unless there are significant tolerability issues with chemotherapy regimens.

D	Neoadjuvant chemotherapy followed by surgery

This patient is unsuitable for surgery based on locally advanced disease/invasion leading to Horner syndrome. For this reason the option is incorrect.

E	Surgical excision followed by chemotherapy

This is the approach of choice for patients with stage III disease that is suitable for resection, but in this case the Horner syndrome precludes proceeding to surgery.

Rate this question:

© Pastest 2019

Audio Video Share Participants More

9:24
594-042-7551 Leave

A 26-year-old woman is found to have 'moderate dyskaryosis' on a routine cervical smear examination.

What should be recommended as follow-up of this result?

A	Repeat smear to confirm result
B	HPV vaccination
C	Colposcopy
D	Cone biopsy
E	Reassure and review in three years

Submit

Previous Q... Skip Questi...

© Pastest 2019

Audio Video Share Participants More

9:25

404 — Not Found × | 404 — Not Found × | Home Feed | Re ×

https://mypastest.pastest.com/Secure/TestMe/

Pastest+

Question 2 of 102

A 26-year-old woman is found to have 'moderate dyskaryosis' on a routine cervical smear examination.

What should be recommended as follow-up of this result?

Your answer was incorrect

A	Repeat smear to confirm result
B	HPV vaccination
C	Colposcopy
D	Cone biopsy
E	Reassure and review in three years

Explanation

C Colposcopy

Dyskaryosis or dysplasia refers to the precancerous change in cells. There are four types:

- Borderline
- Mild
- Moderate

Rana Alnasser's screen

C Colposcopy

Dyskaryosis or dysplasia refers to the precancerous change in cells. There are four types:

- Borderline
- Mild
- Moderate
- Severe

A smear result may also refer to CIN (cervical intra-epithelial neoplasia) 1, CIN 2 or CIN 3 rather than mild, moderate or severe. This classification is not strictly accurate, as CIN can only really be diagnosed with a biopsy and relate to the thickness of the skin covering the cervix that is affected.

Women with smears showing moderate or severe precancerous changes will be referred for colposcopy, as they have a significant risk of proceeding to cervical cancer if left untreated.

A Repeat smear to confirm result

If the patient has been identified as having moderate dyskaryosis, this is taken to be the diagnosis and should be referred for colposcopy

A repeat smear in six months is indicated if the smear shows mild cell changes or CIN 1. Sometimes these slightly abnormal cells can revert to normal spontaneously. If the following smear is abnormal, then referral is made for colposcopy. The NHS guidelines say that you should have three negative 6-monthly smears, one after the other, before it is safe for you to go back to regular screening..

B HPV vaccination

B HPV vaccination

The HPV vaccination is being offered as a preventative measure for girls aged 12–13 years. The vaccine consists of two injections given 6–24 months apart, on the upper arm. Within the NHS, the HPV vaccine (Gardasil) protects against four types of HPV which are responsible for up to 70% of cervical cancer. The vaccine also prevents against genital warts. At present, girls receiving the vaccine when over the age of 15 will require three injections to mount an appropriate response. Girls are able to have catch-up vaccinations up to the age of 18. HPV vaccination is currently used in the preventative setting.

Patients noted as having an abnormal colposcopy result are routinely tested for HPV virus, and this affects their future management.

D Cone biopsy

Cone biopsies can be undertaken after smears and colposcopy if the abnormal cells extend deep into the cervix. A cone-shaped (wedge) biopsy can be taken to investigate the extent of the disease, which is useful when determining future treatment. In some cases all abnormal cells can be fully excised, meaning that no further treatment is required. A cone biopsy may be necessary in the future, but is not the next step in management.

E Reassure and review in three years

Three years is far too long to wait for further review this patient. All women are invited for routine screening from the age of 25 years until the age of 49 on a 3-yearly basis, and 5-yearly from 50–64 years. If the patient had a normal cervical smear, then she would simply need to maintain 3-yearly screening checks. However, this patient has

Rana Alnasser's screen

9:28

404 — Not Found × | 404 — Not Found × | Home Feed | Re ×

https://mypastest.pastest.com/Secure/TestMe/

Pastest+

A 35-year-old woman presents with enlarged cervical lymph nodes. She is asymptomatic.

Blood tests show a low-grade anaemia, elevated white cell count and thrombocytopenia. Lymph node biopsy is suggestive of diffuse large B-cell non-Hodgkin's lymphoma.

Which of the following is most likely to be found expressed on the lymphoma cells?

A	CD3
B	CD19
C	CD30
D	CD5
E	CD177

Submit

Previous Q... | Skip Questi...

Rana Alnasser's screen

9:29

404 — Not Found × | 404 — Not Found × | Home Feed | Re ×

https://mypastest.pastest.com/Secure/TestMe/

A 35-year-old woman presents with enlarged cervical lymph nodes. She is asymptomatic.

Blood tests show a low-grade anaemia, elevated white cell count and thrombocytopenia. Lymph node biopsy is suggestive of diffuse large B-cell non-Hodgkin's lymphoma.

Which of the following is most likely to be found expressed on the lymphoma cells?

Your answer was correct

A	CD3
B	CD19
C	CD30
D	CD5
E	CD177

Explanation

B	CD19

A number of B lymphocyte cell surface antigens are expressed on lymphoma cells. These include CD19, CD20, CD22 and CD79a, as well as CD45. Between 50 and 75% of

Rana Alnasser's screen

9:29

B CD19

A number of B lymphocyte cell surface antigens are expressed on lymphoma cells. These include CD19, CD20, CD22 and CD79a, as well as CD45. Between 50 and 75% of B-cell lymphomas also express immunoglobulin.

A CD3

CD3 is a T-cell receptor and hence it is not usually expressed on B-cell lymphomas.

C CD30

CD30 is expressed in approximately 30% of cases of B-cell lymphoma, and it is associated with a favourable prognosis.

D CD5

CD5 is uncommonly expressed on B-cell lymphomas and is associated with a poor prognosis.

E CD177

CD177 is expressed by neutrophils and is therefore not relevant with respect to evaluation of B-cell lymphoma.

Rate this question:

Next Question

Previous Q... Tag Questi... Feedback End Session

Rana Alnasser's screen

9:31
594-042-7551 Leave

A 59-year-old man presents with epigastric pain radiating to his back. He is diagnosed with pancreatic carcinoma and receives an aggressive regime of chemotherapy.

Which of the following, when measured serially, may be indicative of recurrence or progressive disease?

A	CA-125
B	CA19-9
C	CA15-3
D	CEA
E	β-HCG

185.27

Submit

Previous Q... Skip Questi...

© Pastest 2019

Audio Video Share Participants More

A 59-year-old man presents with epigastric pain radiating to his back. He is diagnosed with pancreatic carcinoma and receives an aggressive regime of chemotherapy.

Which of the following, when measured serially, may be indicative of recurrence or progressive disease?

Your answer was correct

A	CA-125
B	CA19-9
C	CA15-3
D	CEA
E	β-HCG

Explanation

B CA19-9

CA-19-9 is a tumour marker which is raised in cases of gastrointestinal or pancreatic cancer. It may also be raised in cases of inflammatory bowel disease, pancreatitis or gallstones. CA-19-9 is not recommended by the American Society of Clinical Oncology (ASCO) as a diagnostic tool for pancreatic carcinoma or as a sole measure of disease recurrence, but serial testing as a measure of treatment response (in conjunction with other tests) may be useful.

Explanation

B	CA19-9

CA-19-9 is a tumour marker which is raised in cases of gastrointestinal or pancreatic cancer. It may also be raised in cases of inflammatory bowel disease, pancreatitis or gallstones. CA-19-9 is not recommended by the American Society of Clinical Oncology (ASCO) as a diagnostic tool for pancreatic carcinoma or as a sole measure of disease recurrence, but serial testing as a measure of treatment response (in conjunction with other tests) may be useful.

A	CA-125

CA-125 is a marker of ovarian carcinoma, but can occasionally also be raised in breast, uterine or gastrointestinal tumours.

C	CA15-3

CA15-3 is a tumour marker suggestive of breast cancer.

D	CEA

A raised serum CEA can occur with colorectal malignancies (but can also be elevated in non-small cell lung cancer and breast cancer).

E	β-HCG

β-HCG is a marker for testicular and trophoblastic tumours, and alongside serum alpha-fetoprotein and lactate dehydrogenase, is a validated prognostic marker for germ cell tumours.

9:32

A 50-year-old man is undergoing therapy for lung cancer. He has had a 3-day history of severe back pain and now presents with a 24-h history of difficulty in walking. He has also noticed difficulty in passing urine over the last 12 hours. An urgent MRI spine shows a soft tissue mass compressing the spinal cord at T12.

What is the best immediate management of this patient?

A	Surgical opinion
B	Radiotherapy
C	Intravenous (iv) dexamethasone
D	Chemotherapy
E	Physiotherapy

Submit

Previous Q... Skip Questi...

© Pastest 2019

Rana Alnasser's screen

9:32

A 50-year-old man is undergoing therapy for lung cancer. He has had a 3-day history of severe back pain and now presents with a 24-h history of difficulty in walking. He has also noticed difficulty in passing urine over the last 12 hours. An urgent MRI spine shows a soft tissue mass compressing the spinal cord at T12.

What is the best immediate management of this patient?

Your answer was correct

A	Surgical opinion
B	Radiotherapy
C	Intravenous (iv) dexamethasone
D	Chemotherapy
E	Physiotherapy

Explanation

C Intravenous (iv) dexamethasone

IV dexamethasone (usually 16 mg OD or 8 mg BD) with PPI cover can be commenced as soon as the patient arrives in hospital or as soon as the possibility of spinal cord compression is raised. The steroid will help reduce swelling around the vertebral body and can start to take effect while further investigations and decisions regarding future management are made.

Rana Alnasser's screen

9:32

C Intravenous (iv) dexamethasone

IV dexamethasone (usually 16 mg OD or 8 mg BD) with PPI cover can be commenced as soon as the patient arrives in hospital or as soon as the possibility of spinal cord compression is raised. The steroid will help reduce swelling around the vertebral body and can start to take effect while further investigations and decisions regarding future management are made.

A Surgical opinion

It would be worth considering whether the patient is an appropriate candidate for surgery. As a rule of thumb, the surgical team only consider patients with a prognosis of greater than six months to account for the recovery time post-surgery. Regardless of whether the patient is a surgical candidate, surgery would not be the first-line treatment in either case and is, therefore, not the correct answer.

B Radiotherapy

Radiotherapy is the often the treatment of choice for patients with spinal cord compression. However, in order for the treatment to be planned, the patient often has to undergo a MRI of the whole spine which can take up to 24 h following admission. Once the treatment is planned and then administered, it can take days or even weeks for the radiotherapy to start taking effect. The question asks for the best immediate treatment. Radiotherapy can be an effective treatment but can take a while to organise. It is possible to give an alternative treatment in the meantime.

D Chemotherapy

Chemotherapy is a systemic treatment that can be used to

Rana Alnasser's screen

9:34
594-042-7551
Leave
404 — Not Found
404 — Not Found
Home Feed | Re
https://mypastest.pastest.com/Secure/TestMe/B

Pastest+

A 65-year-old man presents with dysphagia, dyspnoea, haemoptysis, early morning headaches, facial congestion and oedema of the upper limbs.

On examination, the jugular veins are distended. Heart sounds are normal. Chest X-ray shows round shadows in the right lower lobe, bilateral hilar lymphadenopathy and right pleural effusion. Fibre-optic bronchoscopy reveals lesions in the right lower lobe bronchi. He is referred to a consultant surgeon who rules out surgery.

What is the optimal way to treat his symptoms of superior vena cava (SVC) obstruction?

A	Endovascular stenting
B	High-dose corticosteroids
C	Radiotherapy
D	Right pneumonectomy
E	Surgical decompression

Audio
Video
Share
Participants
More

9:34

404 – Not Found × | 404 – Not Found × | Home Feed | Re

https://mypastest.pastest.com/Secure/TestMe/B

A 65-year-old man presents with dysphagia, dyspnoea, haemoptysis, early morning headaches, facial congestion and oedema of the upper limbs.

On examination, the jugular veins are distended. Heart sounds are normal. Chest X-ray shows round shadows in the right lower lobe, bilateral hilar lymphadenopathy and right pleural effusion. Fibre-optic bronchoscopy reveals lesions in the right lower lobe bronchi. He is referred to a consultant surgeon who rules out surgery.

What is the optimal way to treat his symptoms of superior vena cava (SVC) obstruction?

Your answer was correct

A	Endovascular stenting
B	High-dose corticosteroids
C	Radiotherapy
D	Right pneumonectomy
E	Surgical decompression

Explanation

A Endovascular stenting

Vena caval obstruction related to lung cancer is a contraindication for surgery and is a progressive patholo As such, intervention is indicated. Venous stenting is recommended by NICE and leads to rapid resolution of symptoms. It is therefore the intervention of choice here.

B High-dose corticosteroids

Although corticosteroids may have some impact on local oedema related to an underlying bronchial carcinoma, thi is usually minor compared to the impact in haematologic malignancies and is relatively short lived.

C Radiotherapy

Radiotherapy is effective in reducing vena caval obstruction, although it takes some time to impact on symptoms. It also leads to vascular scarring, making stenting technically much more difficult at a later date.

D Right pneumonectomy

Pneumonectomy isn't curative and represents a significar operative risk. As such, it isn't indicated here.

E Surgical decompression

Surgical decompression is associated with bleeding risk and offers no advantage versus endovascular stenting. It therefore not the preferred option here.

A 73-year-old man who takes finasteride for symptoms o prostatism presents to his GP complaining of pain in his right femur, left humerus and back. He has a past history hypertension for which he takes amlodipine, but nil else c note.

Investigations:

Haemoglobin (Hb)	10.3 g/dl
White cell count (WCC)	4.5×10^9/l
Platelet (PLT)	199×10^9/l
Sodium (Na^+)	139 mmol/l
Potassium (K^+)	4.9 mmol/l
Creatinine (Cr)	187 µmol/l
Calcium (Ca)	3.05 mmol/l
Bone scan	Multiple hot spots, including in the areas identified as painful
Chest X-ray	Normal

Which of the following is the most likely diagnosis?

A Multiple myeloma

B Bony metastases

C Hyperparathyroidism

D Hypercalcaemic hypocalciuria

prostatism presents to his GP complaining of pain in his right femur, left humerus and back. He has a past history hypertension for which he takes amlodipine, but nil else c note.

Investigations:

Haemoglobin (Hb)	10.3 g/dl
White cell count (WCC)	4.5×10^9/l
Platelet (PLT)	199×10^9/l
Sodium (Na^+)	139 mmol/l
Potassium (K^+)	4.9 mmol/l
Creatinine (Cr)	187 µmol/l
Calcium (Ca)	3.05 mmol/l
Bone scan	Multiple hot spots, including in the areas identified as painful
Chest X-ray	Normal

Which of the following is the most likely diagnosis?

A Multiple myeloma

B Bony metastases

C Hyperparathyroidism

D Hypercalcaemic hypocalciuria

E Paget's disease

B Bony metastases

The most likely answer is bony metastases given the history of bone pains, hypercalcaemia, mild anaemia and renal impairment together with the abnormal bone scintigraphy. The history is suggestive of perhaps prostat cancer as a likely primary site.

A Multiple myeloma

It is incorrect as a result of the abnormal bone scan. This not a standard investigation in multiple myeloma, as the sensitivity of detecting lesions is actually less than that o plain film skeletal survey. Bone scans can be normal in multiple myeloma and large lesions can be hot or cold.

C Hyperparathyroidism

Whilst hyperparathyroidism may be associated with kidn disease (and therefore anaemia) and hypercalcaemia, ren osteodystrophy is the more common complication of secondary and tertiary hyperparathyroidism – this typica results in telescopic shortening of the phalanges rather than long bone pain.

D Hypercalcaemic hypocalciuria

Hypercalcaemic hypocalciuria is a benign, inherited condition associated with hypercalcaemia which is usuall incidentally diagnosed. The patient is usually asymptoma and the condition is not usually associated with either anaemia or renal impairment.

E Paget's disease

A Multiple myeloma

It is incorrect as a result of the abnormal bone scan. This not a standard investigation in multiple myeloma, as the sensitivity of detecting lesions is actually less than that o plain film skeletal survey. Bone scans can be normal in multiple myeloma and large lesions can be hot or cold.

C Hyperparathyroidism

Whilst hyperparathyroidism may be associated with kidn disease (and therefore anaemia) and hypercalcaemia, ren osteodystrophy is the more common complication of secondary and tertiary hyperparathyroidism – this typical results in telescopic shortening of the phalanges rather than long bone pain.

D Hypercalcaemic hypocalciuria

Hypercalcaemic hypocalciuria is a benign, inherited condition associated with hypercalcaemia which is usuall incidentally diagnosed. The patient is usually asymptoma and the condition is not usually associated with either anaemia or renal impairment.

E Paget's disease

Hypercalcaemia is not a feature of Paget's disease and therefore makes this diagnosis unlikely.

Rate this question:

A 65-year-old woman has recently been diagnosed with invasive ductal carcinoma of the right breast.

At operation, one of ten lymph nodes was found to be involved. The rest of her metastatic screen was negative.

A decision is made to treat with tamoxifen for five years.

Which of the following side-effects is most recognised as a complication of long-term tamoxifen treatment?

A	It usually causes osteoporosis
B	It may increase her risk of heart disease
C	It may cause blood clots
D	It may reduce the risk of endometrial cancer
E	It often causes weight loss

Submit

A 65-year-old woman has recently been diagnosed with invasive ductal carcinoma of the right breast.

At operation, one of ten lymph nodes was found to be involved. The rest of her metastatic screen was negative.

A decision is made to treat with tamoxifen for five years.

Which of the following side-effects is most recognised as a complication of long-term tamoxifen treatment?

Your answer was correct

A	It usually causes osteoporosis
B	It may increase her risk of heart disease
C	It may cause blood clots
D	It may reduce the risk of endometrial cancer
E	It often causes weight loss

Explanation

C	It may cause blood clots

Tamoxifen has oestrogen-like properties, which explains the increase in venous thromboembolism noted in patien taking tamoxifen. The risk is greater in older patients and greatest in the first two yea, s of taking the medication.

C It may cause blood clots

Tamoxifen has oestrogen-like properties, which explains the increase in venous thromboembolism noted in patien taking tamoxifen. The risk is greater in older patients and greatest in the first two years of taking the medication.

A It usually causes osteoporosis

Tamoxifen has weak-oestrogen like properties meaning it actually can help increase bone density. Studies have shown that using tamoxifen prior to use of an aromatase inhibitor, which can lead to reduced bone density, can actually slow the loss of bone density.

B It may increase her risk of heart disease

Tamoxifen has actually been shown in multiple studies to reduce the risk of coronary heart disease.

Reference:

Rosell J, Nordenskjöld B, Bengtsson N, Fornander T, Hatschek T, Lindman H, Malmström P, Wallgren A, Stål O, Carstensen A. (April 2013). Effects of adjuvant tamoxifen therapy on cardiac disease: results from a randomized tri with long-term follow-up. *Breast Cancer Research and Treatment*. 138 (2):467–73.

D It may reduce the risk of endometrial cancer

Tamoxifen can actually increase the risk, albeit minimally, developing endometrial cancer.

E It often causes weight loss

9:44
404 — Not Found × 404 — Not Found × Home Feed | Re
https://mypastest.pastest.com/Secure/TestMe/B
Pastest+ Question 8 of 102

reduce the risk of coronary heart disease.

Reference:

Rosell J, Nordenskjöld B, Bengtsson N, Fornander T, Hatschek T, Lindman H, Malmström P, Wallgren A, Stål O, Carstensen A. (April 2013). Effects of adjuvant tamoxifen therapy on cardiac disease: results from a randomized tri with long-term follow-up. *Breast Cancer Research and Treatment*. 138 (2):467–73.

D	It may reduce the risk of endometrial cancer

Tamoxifen can actually increase the risk, albeit minimally, developing endometrial cancer.

E	It often causes weight loss

Tamoxifen has been linked with causing weight gain (ofte caused be fluid retention) in patients that are administere it. Other side effects include:

- Hot flushes
- Indigestion or feeling sick
- Sweats
- Vaginal dryness
- Vaginal discharge.

Rate this question:

Next Question

9:44
404 – Not Found × 404 – Not Found × Home Feed | Re
https://mypastest.pastest.com/Secure/TestMe/B

Pastest+ Question 9 of 102

A 63-year-old woman with breast cancer had her last cyc of chemotherapy eight days ago. She now presents to th admission unit with acute shortness of breath. She complains of pain on the right side of her chest. She has other medical history and had some anti-emetics prescribed for her following her chemotherapy, which she has not used.

On examination, she has reduced air entry on the right si of her chest, some crackles bibasally and she appears flushed and tachycardic. Her blood pressure is 114/76, her heart rate is 115, temperature is 39.4, respiratory rate is 24 and her oxygen saturation is 95% on 28% oxygen.

What would be the immediate treatment required for this patient?

A	Intravenous (iv) piperacillin with tazobactam
B	Therapeutic heparin at 1.5 mg/kg
C	35% oxygen
D	Chest drain
E	Broad-spectrum oral antibiotics

Submit

Rana Alnasser's screen

9:45
594-042-7551
Leave
404 — Not Found
404 — Not Found
Home Feed | Re
https://mypastest.pastest.com/Secure/TestMe/Brow

A 63-year-old woman with breast cancer had her last cycle of chemotherapy eight days ago. She now presents to the admission unit with acute shortness of breath. She complains of pain on the right side of her chest. She has no other medical history and had some anti-emetics prescribed for her following her chemotherapy, which she has not used.

On examination, she has reduced air entry on the right side of her chest, some crackles bibasally and she appears flushed and tachycardic. Her blood pressure is 114/76, her heart rate is 115, temperature is 39.4, respiratory rate is 24 and her oxygen saturation is 95% on 28% oxygen.

What would be the immediate treatment required for this patient?

A	Intravenous (iv) piperacillin with tazobactam
B	Therapeutic heparin at 1.5 mg/kg
C	35% oxygen
D	Chest drain
E	Broad-spectrum oral antibiotics

7296
Audio
Video
Share
Participants
More

9:46
594-042-7551
Leave

A Intravenous (iv) piperacillin with tazobactam

This patient is neutropenic until proven otherwise and, as such, requires urgent iv antibiotics. Most hospitals employ a door-to-needle target of 1 h, meaning that patients should receive iv antibiotics within 1 h of arriving at the hospital. If the patient subsequently turns out not to be neutropenic, iv antibiotics can be converted to oral if clinically appropriate.

E Broad-spectrum oral antibiotics

This patient is potentially neutropenic and as such requires urgent iv antibiotics. Oral antibiotics would be neither effective nor sufficiently rapid in treating sepsis if the patient was neutropenic. The patient may later be switched to oral antibiotics if stable and not neutropenic, or later on in her admission when she has clinically improved.

B Therapeutic heparin at 1.5 mg/kg

It is reasonable to consider that this patient with a malignancy, chest pain and a history of acute shortness of breath may have suffered a pulmonary embolism and therefore requires treatment with subcutaneous heparin at a dose of 1.5 mg/kg (reduced if the patient is renally impaired). However, in this situation, there are other factors to consider. This patient has had chemotherapy and, although we are not told which regime, is possibly neutropenic and septic, meaning that antibiotics would need to be considered first. Heparin may subsequently be indicated.

C 35% oxygen

The patient's saturation is adequate on 28% oxygen and does not require an increase in oxygen, although this would

Audio Video Share Participants More

9:46
404 — Not Found
404 — Not Found
Home Feed | Re
https://mypastest.pastest.com/Secure/TestMe/Brow

Pastest+

A 64-year-old chronic smoker with known small cell carcinoma of the lung complains of inability to get out of bed in the mornings. However, after moving around for a few minutes, he is able to regain his strength. Anti-voltage-gated calcium channel antibodies are positive.

Which one of the following is the most appropriate initial intervention?

A	Azathioprine
B	Ciclosporin
C	3,4-diaminopyridine
D	Prednisolone
E	Pyridostigmine

Submit

9:47

404 — Not Found × | 404 — Not Found × | Home Feed | Re ×

https://mypastest.pastest.com/Secure/TestMe/Brow

A 64-year-old chronic smoker with known small cell carcinoma of the lung complains of inability to get out of bed in the mornings. However, after moving around for a few minutes, he is able to regain his strength. Anti-voltage-gated calcium channel antibodies are positive.

Which one of the following is the most appropriate initial intervention?

Your answer was correct

A	Azathioprine
B	Ciclosporin
C	3,4-diaminopyridine
D	Prednisolone
E	Pyridostigmine

Explanation

C 3,4-diaminopyridine

This patient has LEMS, a rare non-metastatic manifestation of small cell carcinoma of the bronchus. Proximal muscle weakness with absent reflexes is the characteristic finding

C 3,4-diaminopyridine

This patient has LEMS, a rare non-metastatic manifestation of small cell carcinoma of the bronchus. Proximal muscle weakness with absent reflexes is the characteristic finding in this condition. Unlike classical myasthenia gravis, weakness tends to improve after a few minutes of muscular contraction and absent reflexes return. Antibodies to muscle calcium channel components are found in most cases (90%). 3,4-diaminopyridine is the initial treatment of choice, and can significantly improve muscle strength.

A Azathioprine

This is a steroid-sparing agent used in severe Lambert–Eaton myasthenic-myopathic syndrome (LEMS). Azathioprine is commenced in patients who require systemic corticosteroids to maintain muscle strength.

B Ciclosporin

Ciclosporin is an alternative steroid-sparing agent for the treatment of LEMs; other options apart from ciclosporin and azathioprine include mycophenolate and methotrexate.

D Prednisolone

Prednisolone is the first-line option for immunosuppression in patients who fail to gain adequate improvement in muscle strength from 3,4-diaminopyridine alone.

E Pyridostigmine

Although pyridostigmine is effective in treating myasthenia gravis, it is not of value in treating LEMS.

9:47
404 — Not Found
404 — Not Found
Home Feed | Re
https://mypastest.pastest.com/Secure/TestMe/Brow

Pastest+

A 55-year-old male smoker presents with a 1-month history of progressive dysphagia to solids and weight loss. He admits to long-term reflux for which he takes anti-acid tablets from the chemist. Endoscopy shows a large polypoid, obstructing mass in the lower third of the oesophagus.

What is the likely histology?

A	Squamous carcinoma
B	Adenocarcinoma
C	Leiomyoma
D	Metastatic nodule from another site
E	Small cell carcinoma

Submit

Previous Q...

Skip Questi...

B Adenocarcinoma

Adenocarcinomas are now the most common form of oesophageal cancer, with 95% either squamous cell or adenocarcinoma. Adenocarcinomas are found mainly in the lower third of the oesophagus, and are most associated with acid reflux and Barrett's oesophagus. The prognosis for oesophageal carcinoma varies depending on the stage at presentation, but is generally poor. The overall 5-year survival rate for resectable tumours ranges from 10 to 25%. The prognosis for more advanced tumours is much worse.

A Squamous carcinoma

Nearly 50% of the oesophageal cancers diagnosed in the UK are squamous cell carcinomas. This type of cancer is found mainly in the upper third and middle of the oesophagus.

C Leiomyoma

Leiomyomas are the most common benign tumour within the oesophagus. They are usually found in the distal third of the oesophagus and are generally single lesions, but occasionally can be multiple. Although leiomyoma is a legitimate consideration, the question asks for the most likely histology and an adenocarcinoma is far more likely simply because it's incidence is so much greater than leiomyoma.

D Metastatic nodule from another site

A metastatic deposit in the oesophagus is a possibility but is extremely rare. The question asks for the most likely diagnosis and, although metastatic nodule from another site is a feasible answer, it is the not likely to be the histology that would be found.

A 45-year-old woman, previously in good health, is referred by the gynaecologists with a new diagnosis of stage 3 ovarian carcinoma after presenting to the general practitioner (GP) with progressive bloating and abdominal pain over the previous four months.

She undergoes a hysterectomy and bilateral salpingo-oophorectomy (BSO), and is referred for chemotherapy.

Which of the following is the usual first-line chemotherapy regimen?

A	Gemcitabine and Carboplatin
B	Paclitaxel and Carboplatin
C	Single agent Carboplatin
D	Single agent Topetecan
E	Single agent Caelyx

38567

Submit

A 45-year-old woman, previously in good health, is referred by the gynaecologists with a new diagnosis of stage 3 ovarian carcinoma after presenting to the general practitioner (GP) with progressive bloating and abdominal pain over the previous four months.

She undergoes a hysterectomy and bilateral salpingo-oophorectomy (BSO), and is referred for chemotherapy.

Which of the following is the usual first-line chemotherapy regimen?

A	Gemcitabine and Carboplatin
B	Paclitaxel and Carboplatin
C	Single agent Carboplatin
D	Single agent Topetecan
E	Single agent Caelyx

38567

Submit

9:50
594-042-7551
Leave

A 45-year-old woman, previously in good health, is referred by the gynaecologists with a new diagnosis of stage 3 ovarian carcinoma after presenting to the general practitioner (GP) with progressive bloating and abdominal pain over the previous four months.

She undergoes a hysterectomy and bilateral salpingo-oophorectomy (BSO), and is referred for chemotherapy.

Which of the following is the usual first-line chemotherapy regimen?

Your answer was correct

A Gemcitabine and Carboplatin

B Paclitaxel and Carboplatin

C Single agent Carboplatin

D Single agent Topetecan

E Single agent Caelyx

Explanation

B Paclitaxel and Carboplatin

This patient has locally advanced stage III ovarian cancer and has undergone tumour debulking in the form of a hysterectomy and bilateral salpingo-oophorectomy. Subsequently patients tend to receive chemotherapy – patients with a good performance status are offered

Audio Video Share Participants More

9:50

404 – Not Found × | 404 – Not Found × | Home Feed | Re ×

https://mypastest.pastest.com/Secure/TestMe/Brow

B Paclitaxel and Carboplatin

This patient has locally advanced stage III ovarian cancer and has undergone tumour debulking in the form of a hysterectomy and bilateral salpingo-oophorectomy. Subsequently patients tend to receive chemoptherapy – patients with a good performance status are offered combination chemotherapy with carboplatin and paclitaxel (Option B) as per NICE guidelines.

A Gemcitabine and Carboplatin

Gemcitabine and carboplatin is a potential treatment option upon relapse following first line treatment.

C Single agent Carboplatin

Single agent carboplatin Using combination chemotherapy (with a platinum based compound and a taxol) is optimal as there is approximately an 8% increased response compared with single agent carboplatin alone.

D Single agent Topetecan

Single agent topetecan is a possible second line option for ovarian cancer.

E Single agent Caelyx

Single agent Caelyx may be used as a potential second line [illegible] cancer.

Rana Alnasser's screen

A Gemcitabine and Carboplatin

Gemcitabine and carboplatin is a potential treatment option upon relapse following first line treatment.

C Single agent Carboplatin

Single agent carboplatin Using combination chemotherapy (with a platinum based compound and a taxol) is optimal as there is approximately an 8% increased response compared with single agent carboplatin alone.

D Single agent Topetecan

Single agent topetecan is a possible second line option for ovarian cancer.

E Single agent Caelyx

Single agent Caelyx may be used as a potential second line option for relapsed ovarian cancer.

Rate this question:

Next Question

© Pastest 2019

9:51
594-042-7551 Leave

A 69-year-old patient is being investigated for breathlessness, cough and severe weight loss. On the medical ward round, their chest X-ray is reviewed and this shows hilar lymphadenopathy and multiple, well-circumscribed circular peripheral lung metastases.

Which of the following tumours is most likely to be the underlying cause of the appearance in the lung?

A	Renal cell carcinoma
B	Colorectal carcinoma
C	Anal carcinoma
D	Brain
E	Tongue

Submit

Previous Q... Skip Questi...

© Pastest 2019

Audio Video Share Participants More

11:51
MyPastest
Home Feed | Re
Tumor Marke
https://mypastest.pastest.com/Secure/TestMe/B

A 59-year-old man with a history of chronic cough and weight loss presents to the clinic. He has a 50-pack year smoking history. A chest X-ray conducted by the general practitioner (GP) was reported as showing right-sided apical lung changes consistent with old TB or an underlying malignancy. He has a past medical history of hypertension which has been managed with combination of ramipril and amlodipine therapy.

On examination, he looks thin – his BMI is 18. He has right sided supraclavicular lymphadenopathy.

Investigations:

Haemoglobin (Hb)	11.1 g/dl
White cell count (WCC)	9.2×10^9 /l
Platelet (PLT)	193×10^9 /l
Sodium (Na^+)	140 mmol/l
Potassium (K^+)	4.9 mmol/l
Creatinine	142 µmol/l
Plasma Viscosity	2.4 mPa/s (1.50-1.72)
CT thorax	Apical right lung tumour, with evidence of local invasion

Which of the following neurological signs might you expect to find?

A Right radial nerve palsy

Rana Alnasser's screen

11:52
MyPastest
Home Feed | Re
Tumor Marke
https://mypastest.pastest.com/Secure/TestMe/B

Investigations:

Haemoglobin (Hb)	11.1 g/dl
White cell count (WCC)	9.2×10^9 /l
Platelet (PLT)	193×10^9 /l
Sodium (Na^+)	140 mmol/l
Potassium (K^+)	4.9 mmol/l
Creatinine	142 µmol/l
Plasma Viscosity	2.4 mPa/s (1.50-1.72)
CT thorax	Apical right lung tumour, with evidence of local invasion

Which of the following neurological signs might you expect to find?

A	Right radial nerve palsy
B	Right median nerve palsy
C	Dilated right pupil that constricts in response to atropine
D	Constricted right pupil that dilates with atropine
E	Constricted right pupil that does not dilate in

E Constricted right pupil that does not dilate in response to atropine

This man has a right apical, most likely non-small cell lung cancer, which has resulted in the development of Pancoast syndrome. This is associated with Horner syndrome, caused by invasion of the lower cervical and first thoracic ganglia, which leads to ptosis, enophthalmos and pupil constriction that does not dilate in response to atropine.

D Constricted right pupil that dilates with atropine

In Horner syndrome the constricted right pupil does not dilate in response to atropine.

A Right radial nerve palsy

Pancoast's tumour is more likely to lead to a phrenic nerve palsy rather than a radial or median nerve palsy.

B Right median nerve palsy

The median nerve is made up of ventral roots from C5–C7, C8 and T1, and is not normally encroached upon by a Pancoast's tumour.

C Dilated right pupil that constricts in response to atropine

Horner syndrome leads to pupil constriction rather than pupil dilatation.

21563

Rate this question:

Next Question

12:00
On
594-042-7551
Leave

A 69-year-old woman known with metastatic breast cancer presents to the Emergency Department complaining of nausea and vomiting that has increased over the last 48 h, associated with polyuria and polydipsia. She is also complaining of abdominal pain.

An Emergency Medicine physician suspects she may have hypercalcaemia and orders an urgent calcium and albumin level. Her corrected serum calcium level is 3.1 mmol/l.

Which of the following statements is true?

A	Corrected serum calcium = measured calcium (mmol/l) – [40 + serum albumin (g/l)] x 0.027
B	Corrected serum calcium = measured calcium (mmol/l) + [40 – serum albumin (g/l)]/0.027
C	The patient should be immobilised
D	The patient should be rehydrated with intravenous normal saline
E	90 mg of Pamidronate in 500 ml of normal saline should be administered immediately over a 2-hour period

6672

Submit

Previous Q...
Audio
Video
Share
Participants
Skip Questi...
More

The first line of treatment is to try and rehydrate the patient with normal saline. After at least 2 l of normal saline (usually 4-6 l), you can then consider the addition of bisphosphonates to try lowering the calcium levels.

A	Corrected serum calcium = measured calcium (mmol/l) – [40 + serum albumin (g/l)] x 0.027

Since hypoalbuminaemia is common in malignancy and will affect the total serum calcium concentration, the correct serum calcium concentration is obtained using the formula:

B	Corrected serum calcium = measured calcium (mmol/l) + [40 – serum albumin (g/l)]/0.027

The correct formula is: Corrected serum calcium = measured calcium (mmol/l) + [40 – serum albumin (g/dl)] × 0.027.

C	The patient should be immobilised

This is actually the opposite of what is recommended. Immobilisation is usually recommended in situations such as spinal cord compression.

E	90 mg of Pamidronate in 500 ml of normal saline should be administered immediately over a 2-hour period

Pamidronate should be considered for patients with hypercalcaemia. However, the first-line treatment is normal IV saline. Only if this does not reduce calcium levels would you consider administering a bisphosphonate.

6672

Rate this question:

A 30-year-old woman presents with a 2-month history of general malaise and bruising.

On examination, she is pale with some petechiae and quite marked bruising; there are no other obvious abnormalities.

Investigations:

Haemoglobin (Hb)	10.4 g/dl (normocytic)
Platelet (PLT)	60×10^9/l
White cell count (WCC)	11×10^9/l
Erythrocyte sedimentation rate (ESR)	30 mm/h
Autoimmune profile (AIP)	Negative

Which of the following is the most likely diagnosis?

A Idiopathic thrombocytopenic purpura

B Systemic lupus erythematosus

C Felty's syndrome

D Rheumatoid arthritis

E Infectious mononucleosis

Submit

A 30-year-old woman presents with a 2-month history of general malaise and bruising.

On examination, she is pale with some petechiae and quite marked bruising; there are no other obvious abnormalities.

Investigations:

Haemoglobin (Hb)	10.4 g/dl (normocytic)
Platelet (PLT)	60×10^9/l
White cell count (WCC)	11×10^9/l
Erythrocyte sedimentation rate (ESR)	30 mm/h
Autoimmune profile (AIP)	Negative

Which of the following is the most likely diagnosis?

Your answer was correct

A Idiopathic thrombocytopenic purpura

B Systemic lupus erythematosus

C Felty's syndrome

D Rheumatoid arthritis

E Infectious mononucleosis

Explanation

A Idiopathic thrombocytopenic purpura

In adults, ITP generally presents gradually and is associated is spontaneous bruising, petechiae and thrombocytopenia. ITP is more common in women (2.6:1) and in adults tends to present between ages 20–50. The cause is IgG anti-platelet antibodies, which are not tested as part of a standard autoimmune profile, hence the negative result shown above. Management involves the use of oral corticosteroids, with splenectomy an option for patients who fail to respond to medical therapy. Chronic GI blood loss is the likely cause for the haemoglobin seen here.

B Systemic lupus erythematosus

ITP is more likely given the negative autoimmune profile, and is unlikely to cause bruising. SLE can cause an anaemia of chronic disease, haemolytic anaemia or thrombocytopenia, but the autoimmune profile is likely to be positive (in particular anti-dsDNA, antinuclear, antiphospholipid or anti-Sm positive).

C Felty's syndrome

One would expect a positive rheumatoid factor or anti-CCP screen within the autoimmune profile. Furthermore, whilst Felty syndrome can cause a pancytopenia, it generally follows several years of active, destructive rheumatoid disease rather than the relatively short 2-month history within the case vignette.

D Rheumatoid arthritis

This is less likely given the presentation of bruising and petechiae; the negative autoimmune profile also points against rheumatoid arthritis.

12:05
MyPastest
Home Feed | Re
Tumor Markers
https://mypastest.pastest.com/Secure/TestMe/Brow

within the case vignette.

D Rheumatoid arthritis

This is less likely given the presentation of bruising and petechiae; the negative autoimmune profile also points against rheumatoid arthritis.

E Infectious mononucleosis

Whilst infectious mononucleosis is associated with a history of arthralgia, general malaise as well as thrombocytopenia and raised ESR, it remains an unlikely cause for this patient's presentation. The history of bruising and the presence of anaemia and petechiae all point to an alternate diagnosis. Anaemia is rarely seen with infectious mononucleosis and in fact its presence warrants further investigation.

2279
Rate this question:

Next Question

© Pastest 2019

12:05
MyPastest
Home Feed | Re
Tumor Markers
https://mypastest.pastest.com/Secure/TestMe/Brow

A 33-year-old man presents to his general practitioner (GP) after his wife discovered a lump in his right testicle. The lump is painless and the patient is not aware how long the lump has been present. He is otherwise fit and well and has no other past medical history, except mumps at the age of 8. He is a smoker of 10 cigarettes per day.

On examination, a hard, well-defined non-transilluminating lump (approximately 1 cm) is felt attached to the right testis. After laboratory investigations, scrotal ultrasonography was performed which showed the presence of a homogeneous hypoechoic testicular mass; CT scanning of the abdomen and pelvis with IV and oral contrast failed to identify any metastatic disease. A radical inguinal orchidectomy was performed and histology on the removed lump showed it to be a pure seminoma that was limited to the testis.

Which of the following serum tumour markers would you expect to be elevated in this patient and is most indicative of the diagnosis?

A	α-Fetoprotein
B	Lactate dehydrogenase
C	β-Human chorionic gonadotrophin
D	Placenta-like alkaline phosphatase
E	Acid phosphatase

12:07
On 594-042-7551 Leave

ultrasonography was performed which showed the presence of a homogeneous hypoechoic testicular mass; CT scanning of the abdomen and pelvis with IV and oral contrast failed to identify any metastatic disease. A radical inguinal orchidectomy was performed and histology on the removed lump showed it to be a pure seminoma that was limited to the testis.

Which of the following serum tumour markers would you expect to be elevated in this patient and is most indicative of the diagnosis?

Your answer was correct

A	α-Fetoprotein
B	Lactate dehydrogenase
C	β-Human chorionic gonadotrophin
D	Placenta-like alkaline phosphatase
E	Acid phosphatase

Explanation

C	β-Human chorionic gonadotrophin

β-human chorionic gonadotrophin (β-hCG) is the most specific marker for a patient with a testicular seminoma, since it is secreted by the syncytiotrophoblast cells within GCTs. However, it is only elevated in 5–10% of patients with seminoma.

Audio Video Share Participants More

A α-Fetoprotein

α-Fetoprotein is often seen in patients with hepatocellular carcinoma or in some testicular tumours. However, this patient has a testicular seminoma which does not fit with a raised α-fetoprotein, as this is secreted by the yolk sac elements.

B Lactate dehydrogenase

LDH is a fairly non-specific marker and can give a general idea of tumour burden, but is not specific to testicular seminoma.

D Placenta-like alkaline phosphatase

Placenta-like alkaline phosphatase can be elevated in patients with seminoma, especially with increasing tumour burden, but it may also increase with smoking.

E Acid phosphatase

Acid phosphatase was the first real tumour marker, used in the 1940s and 1950s, to monitor prostate cancer, but is not useful in monitoring or diagnosing seminoma.

12:07
MyPastest
Home Feed | Re
Tumor Markers
https://mypastest.pastest.com/Secure/TestMe/Brow

A concerned 29-year-old woman attends her general practitioner (GP) practice complaining of two days of painless rectal bleeding. There has been no change in her bowel habit. She denies any other constitutive symptoms and has no significant travel history. She is particularly concerned since her mother, who is 48 years old, has recently been diagnosed with cancer of the bowel. On further questioning, it appears that her maternal grandfather also died with bowel cancer.

The GP suspects that there may be an inherited tendency towards this disease and is especially concerned about familial adenomatous polyposis.

What physical feature is most commonly found in this condition?

A	Hypertrophy of the retinal pigment epithelium
B	Early onset cataracts
C	Axillary freckling
D	Cutaneous lipomas
E	Pre-auricular skin tags

Submit

A Hypertrophy of the retinal pigment epithelium

Familial adenomatous polyposis (FAP) is an autosomal dominant condition characterised by the presence of hundreds of adenomatous polyps throughout the colon. There is a wide phenotypic spectrum of FAP, with all phenotypes having an underlying germ-line mutation in the adenomatous polyposis coli gene. The average age of the polyposis is 16 years, with all patients having this syndrome developing colon cancer if left untreated. The average age of onset of colorectal cancer is 39 years. Physical features associated with this condition include congenital hypertrophy of the retinal pigment epithelium, dental abnormalities including supernumerary teeth and dentigerous cysts, osteomas of the skull and mandible, and fibromas and epidermoid cysts in prepubescent patients.

D Cutaneous lipomas

Lipomas *per se* are not associated with increased risk of cancer, although weight gain is associated with a range of cancers including colon and breast cancer, which are linked to increased insulin resistance.

B Early onset cataracts

Early onset cataracts may be associated with decreased antioxidative activity, and have been shown in epidemiological studies to be associated with increased risk of head and neck cancer and hepatoma.

C Axillary freckling

Axillary freckling is identified in hereditary non-polyposis cancer, rather than FAP.

12:09

hypertrophy retinal pigment epithelium fap

ALL IMAGES VIDEOS SHOPPING NEWS MAPS BOOKS

Latest GIF HD Product

bear tracks chrpe eye genotype phenotype lacunae

Familial adenomatous ...
slideshare.net

Congenital Hypertrophy of the RPE ...
columbiaeye.org

retinal pigment epithelium ...
semanticscholar.org

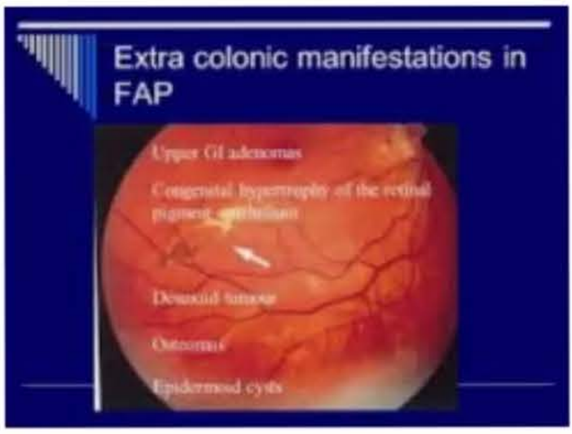

Familial adenomatous polyposis - ppt ...
slideplayer.com

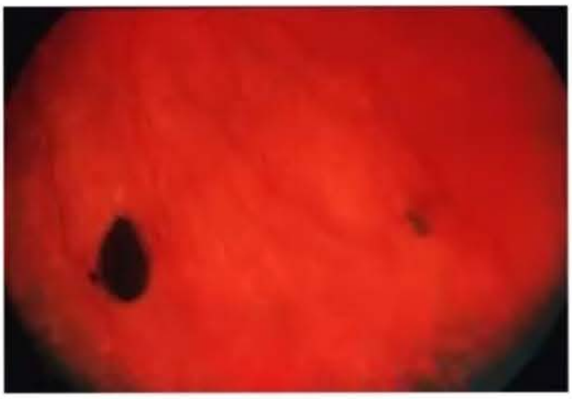

retinal pigment epithelium.jpg ...
commons.wikimedia.org

Discover Updates Search

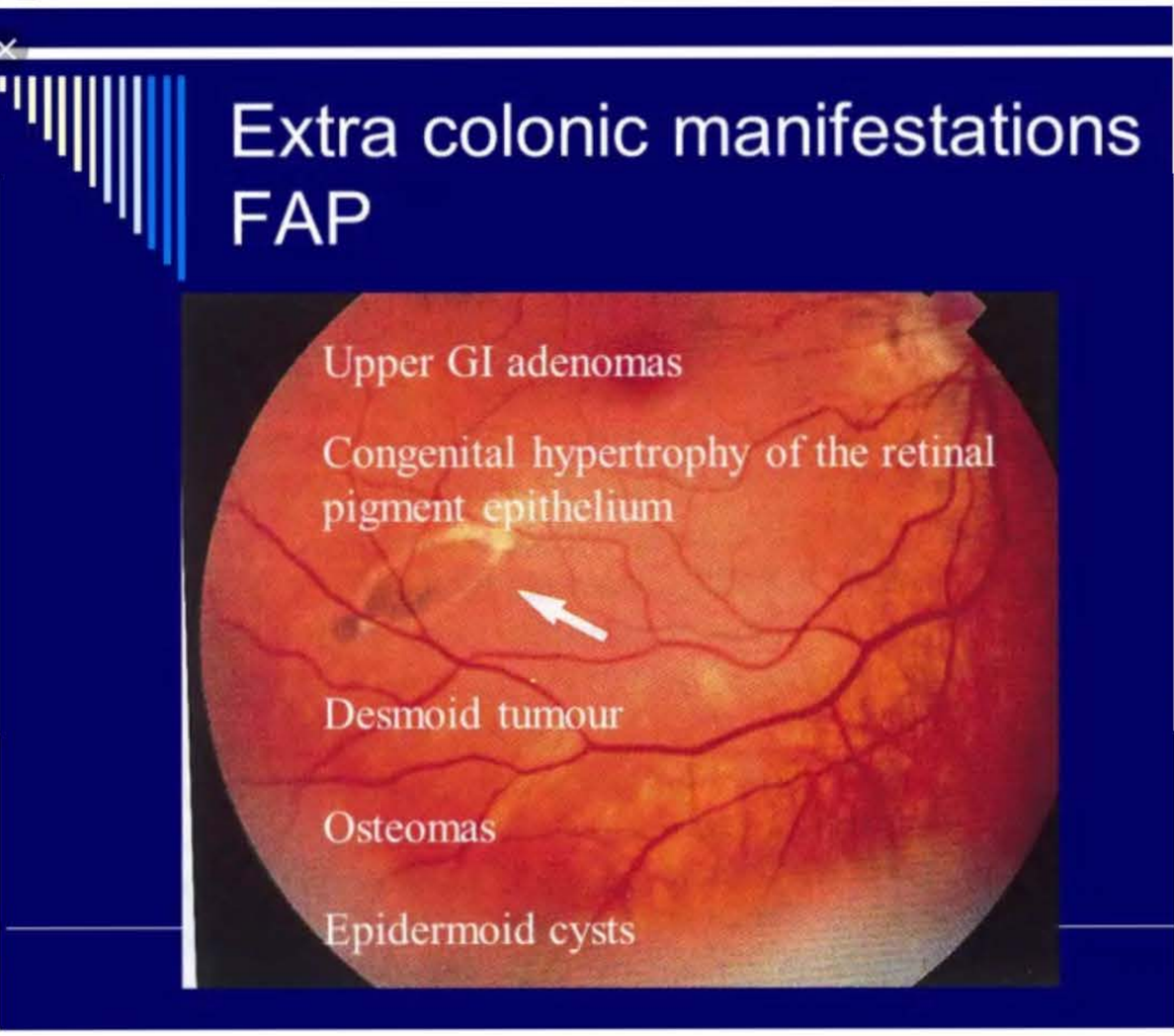

SlidePlayer

Familial adenomatous polyposis - ppt download

mages may be subject to copyright. Learn more

RELATED IMAGES

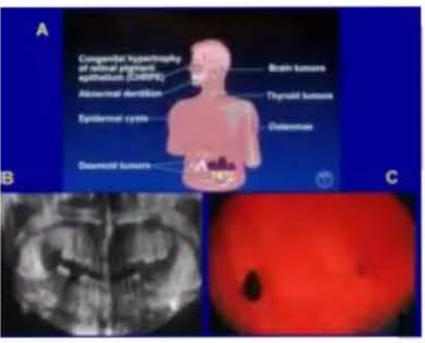

Discover Updates Search Recent

© 2014 DOUGLAS RIEGERT-JOHNSON

The Skin and FAP

- Nearly half of FAP patients will have one or more lipomas, fibromas or epidermal cysts (general population about 30%). Lipomas are the most common skin finding in FAP patients.

Epidermal cyst
(often able to express material)

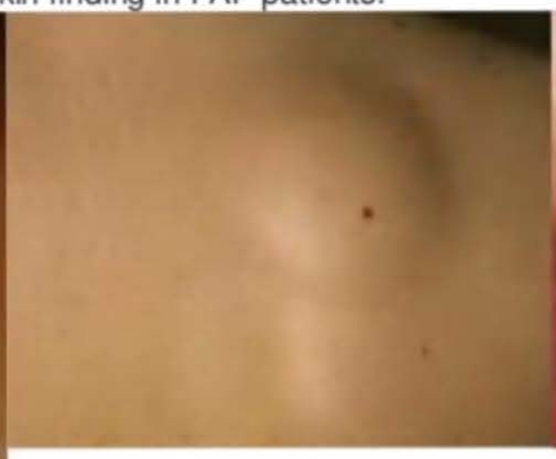

Lipoma
(Soft, "sub-skin")

Fibroma

Oncologist. 2011;16(12):1698-705. doi: 10.1634/theoncologist.2011-0244. Epub 2011 Dec 1.
Prevalence of skin lesions in familial adenomatous polyposis: a marker for presymptomatic diagnosis?
Burger B1, Cattani N, Trueb S, de Lorenzo R, Albertini M, Bontognali E, Itin C, Schaub N, Itin PH, Heinimann K.

www.slideshare.net

Companion slideshow for polyppolyp.com (Familial adenomatous polyposi

Images may be subject to copyright. Learn more

RELATED IMAGES

Images of Peutz Jeghers Syndrome Pronunc...
rock-cafe.info

Discover Updates Search Recent More

12:11
On
594-042-7551
Leave

Fundus Photographs

Right Eye

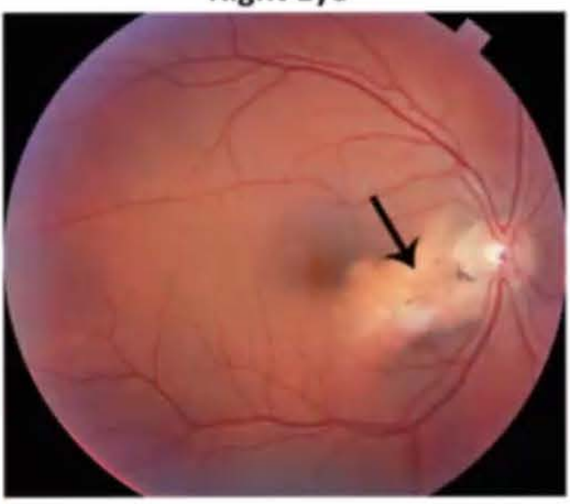

Left Eye

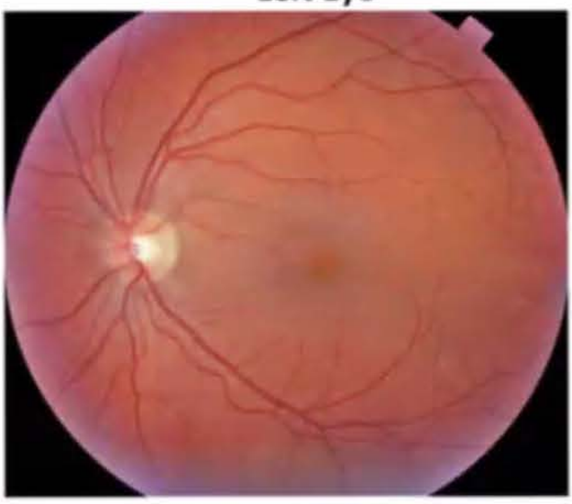

Optical Coherence Tomography

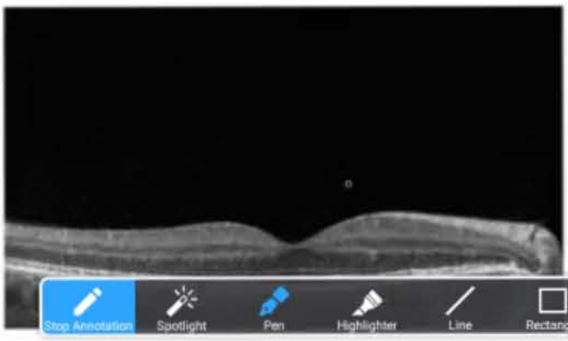

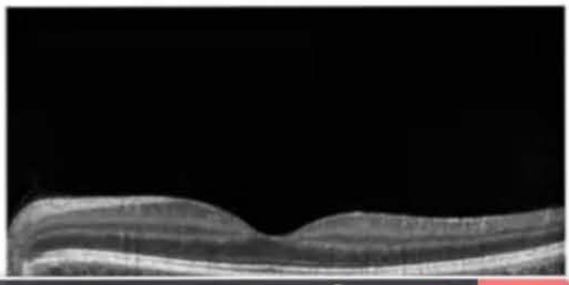

Stop Annotation Spotlight Pen Highlighter Line Rectangle Oval Undo Redo Clear Color Stop Share

www.retinareference.com

Unusual Case of Congenital Hypertrophy of the Retinal Pigment Epithelium - The Retina Reference

Images may be subject to copyright. Learn more

RELATED IMAGES

EXTRAINTESTINAL FEATURES OF FAP (GARDNERS)

Macular Degeneration
Normal
Subretinal Neovascularization

Discover Updates Search Recent More

Audio Video Share Participants More

12:12

A 54-year-old man is receiving cycles of 5-FU for right-sided colon cancer. Abdominal CT did not indicate liver metastases and the liver looked normal at the time of hemicolectomy. He comes to clinic three weeks after his chemotherapy and feels relatively well, but his blood tests are shown below.

Haemoglobin (Hb)	10.2 g/dl
White cell count (WCC)	2.9×10^9/l
Platelet (PLT)	72×10^9/l
Sodium (Na^+)	141 mmol/l
Potassium (K^+)	5.2 mmol/l
Creatinine	130 µmol/l
Prothrombin time (PT)	17.1 s
Fibrinogen	Raised
Alanine transaminase (ALT)	55 U/l

Which of the following is the most appropriate management plan?

A Arrange for him to receive GCSF

B Arrange a platelet transfusion

C Admit him for barrier nursing

D Ask him to return for repeat blood testing in a few days

E Arrange a 2 unit blood transfusion for him

Rana Alnasser's screen

A 54-year-old man is receiving cycles of 5-FU for right-sided colon cancer. Abdominal CT did not indicate liver metastases and the liver looked normal at the time of hemicolectomy. He comes to clinic three weeks after his chemotherapy and feels relatively well, but his blood tests are shown below.

Haemoglobin (Hb)	10.2 g/dl
White cell count (WCC)	2.9×10^9/l
Platelet (PLT)	72×10^9/l
Sodium (Na^+)	141 mmol/l
Potassium (K^+)	5.2 mmol/l
Creatinine	130 µmol/l
Prothrombin time (PT)	17.1 s
Fibrinogen	Raised
Alanine transaminase (ALT)	55 U/l

Which of the following is the most appropriate management plan?

A Arrange for him to receive GCSF

B Arrange a platelet transfusion

C Admit him for barrier nursing

D Ask him to return for repeat blood testing in a few days

E Arrange a 2 unit blood transfusion for him

Rana Alnasser's screen

D Ask him to return for repeat blood testing in a few days

The changes in this patient's full blood count and biochemistry are most likely secondary to adjuvant chemotherapy with 5-FU. He has attended the Oncology Clinic for review prior to potentially further treatment. The nadir count following cytotoxic chemotherapy usually occurs around 10–14 days following treatment and the bone marrow usually recovers thereafter.

The best option in this scenario is to repeat the blood test in a few days, after which his bone marrow should recover and the biochemical changes settle. The patient will most likely need a dose adjustment in his chemotherapy going forward given the thrombocytopenia.

A Arrange for him to receive GCSF

The patient's total WCC is 2.9 and we have not been given his neutrophil count. There is no indication that the patient is currently neutropenic or febrile to prompt treatment with G-CSF.

B Arrange a platelet transfusion

A platelet transfusion is not indicated as the platelet level is currently 72 and there is no suggestion of bleeding. A platelet transfusion is usually indicated when the platelet count falls below 10 in otherwise well patients (ie no fever or bleeding), below 20 when the patient has a fever/other signs of sepsis and below 50 if the patient is actively bleeding. Note: these values may vary between different institutions.

C Admit him for barrier nursing

There is no evidence that suggests the patient needs to be

forward given the thrombocytopenia.

A Arrange for him to receive GCSF

The patient's total WCC is 2.9 and we have not been given his neutrophil count. There is no indication that the patient is currently neutropenic or febrile to prompt treatment with G-CSF.

B Arrange a platelet transfusion

A platelet transfusion is not indicated as the platelet level is currently 72 and there is no suggestion of bleeding. A platelet transfusion is usually indicated when the platelet count falls below 10 in otherwise well patients (ie no fever or bleeding), below 20 when the patient has a fever/other signs of sepsis and below 50 if the patient is actively bleeding. Note: these values may vary between different institutions.

C Admit him for barrier nursing

There is no evidence that suggests the patient needs to be barrier nursed – a low white cell count is not an indication for barrier nursing.

E Arrange a 2 unit blood transfusion for him

A 2-unit blood transfusion is not required as the Hb is currently greater than 7 and the patient is asymptomatic. His bone marrow recovery will usually include a recovery in his haemoglobin.

Rate this question:

Next Question

12:15
On
594-042-7551
Leave

Two sisters from a Scandinavian family, aged 19 and 22 years of age, present to the Cancer Genetics Clinic for a consultation. They are very worried as three close female relatives have suffered from breast cancer in their 30s, and 6 out of 10 people making up their aunts and cousins have suffered from malignant melanomas.

Which one of the following gene mutations or proteins may be responsible?

A	Transforming growth factor beta receptor-1 (TGFBR-1)
B	P53
C	Adenomatous polyposis coli (APC)
D	Human epidermal growth factor receptor-2 (HER-2)
E	Cyclin dependent kinase inhibitor-2A (CDKN2A)

Submit

Blog About Pastest Contact Us Help
Audio Video Share Participants More

12:16
On
594-042-7551
Leave

Two sisters from a Scandinavian family, aged 19 and 22 years of age, present to the Cancer Genetics Clinic for a consultation. They are very worried as three close female relatives have suffered from breast cancer in their 30s, and 6 out of 10 people making up their aunts and cousins have suffered from malignant melanomas.

Which one of the following gene mutations or proteins may be responsible?

Your answer was incorrect

A	Transforming growth factor beta receptor-1 (TGFBR-1)
B	P53
C	Adenomatous polyposis coli (APC)
D	Human epidermal growth factor receptor-2 (HER-2)
E	Cyclin dependent kinase inhibitor-2A (CDKN2A)

Explanation

E	Cyclin dependent kinase inhibitor-2A (CDKN2A)

CDKN2A (also known as cyclin-dependent kinase inhibitor 2) is associated with familial clusters of malignant melanoma and breast cancer. In Europeans with this mutation (characteristic of familial atypical multiple mole melanoma (FAMMM)), around [illegible]% develop malignant

Audio Video Share Participants More

Explanation

E	Cyclin dependent kinase inhibitor-2A (CDKN2A)

CDKN2A (also known as cyclin-dependent kinase inhibitor 2) is associated with familial clusters of malignant melanoma and breast cancer. In Europeans with this mutation (characteristic of familial atypical multiple mole melanoma (FAMMM)), around 60% develop malignant melanoma by age 80.

B	P53

This gene mutation is not associated with a strong family history of malignant melanoma. It is a tumour-suppressor gene associated with cervical, breast, lung and colon cancers.

A	Transforming growth factor beta receptor-1 (TGFBR-1)

TGFBR-1 is not associated with malignancy.

C	Adenomatous polyposis coli (APC)

This is a tumour suppressor gene. Mutations in APC lead to colon cancer – familial adenomatous polyposis is the familial syndrome associated with this gene mutation.

D	Human epidermal growth factor receptor-2 (HER-2)

This is a proto-oncogene that is associated with aggressive HER-2-positive breast cancer in approximately 15–30% of all breast cancer cases. It is not associated with melanoma.

Rana Alnasser's screen

12:18
On
594-042-7551
Leave

A 50-year-old white man has recently been diagnosed with locally advanced prostate cancer.

Which of the following factors is most associated with increasing his risk of developing the disease?

A	Family history
B	Eating a low-fat diet
C	His age
D	History of benign prostatic hypertrophy
E	Caucasian

Submit

Previous Q... Skip Questi...

© Pastest 2019

Audio Video Share Participants More

A Family history

Patients with a family history have an increased risk of developing prostate cancer. Having a first-degree relative with prostate cancer can increase an individual's risk by two- to threefold.

D History of benign prostatic hypertrophy

There has been no convincing causal relationship discovered between benign prostatic hypertrophy and prostate cancer.

B Eating a low-fat diet

High-fat diets may represent one of the factors causing geographical variation in cancer risk in the world, with those patients having a high-fat diet seeming to have a higher incidence of malignancy in general.

C His age

Increasing age increases the risk of developing prostate cancer. This man is quite young to receive a diagnosis of prostate cancer. As a rule of thumb, a younger diagnosis often means a more aggressive form, and at autopsy approximately 80% of men aged 80 years or above have evidence of prostate cancer.

E Caucasian

African-Americans represent one of the highest-risk populations in the world and are overall more likely to die from prostate cancer than their white counterparts.

12:21
On
594-042-7551
Leave

A 45-year-old, premenopausal woman has been identified as having a high chance of developing breast cancer due to a strong family history of breast and ovarian cancer. She initially declined prophylactic drug treatment with tamoxifen due to concerns raised by an article she read. She has since been diagnosed with breast cancer.

Following initial treatment with surgery, she is returning to the clinic to discuss further treatment with tamoxifen. She raises concerns about being on tamoxifen long-term.

Which of the following statements is true?

A	There is no clinical evidence showing any benefit in this lady taking tamoxifen
B	She will remain on tamoxifen indefinitely
C	Taking tamoxifen can reduce the risk of a cancer developing in her other breast
D	Her cholesterol levels will increase
E	She will develop osteoporosis

Submit

Audio
Video
Share
Participants
More

12:22
On
594-042-7551
Leave

C Taking tamoxifen can reduce the risk of a cancer developing in her other breast

Tamoxifen has been shown to reduce the risk of recurrence in the previously affected breast and also to reduce the risk of developing breast cancer in the contralateral breast. In patients who have developed metastatic breast cancer, tamoxifen has halted and, in some cases, reduced the cancer burden within a patient.

A There is no clinical evidence showing any benefit in this lady taking tamoxifen

Tamoxifen is useful in patients with breast cancer and in those with an increased risk of breast cancer even if they do not have the disease. There is evidence that taking tamoxifen when premenopausal with a moderate or high risk of developing breast cancer can reduce the patient's chances of developing breast cancer. Taking tamoxifen after a diagnosis of breast cancer reduced the risk of recurrencealso reduces the risk of developing cancer in the also reduced the risk of cancer in the other breast.

B She will remain on tamoxifen indefinitely

After surgical intervention, tamoxifen reduces the risk of recurrence of ductal carcinoma *in situ* and early stage invasive disease. This is the basis for patients for being commenced on tamoxifen following surgical intervention. It is usually taken once daily for five years only. Tamoxifen can be taken for a longer period if the patient has metastatic disease.

D Her cholesterol levels will increase

In fact, the opposite has been observed with patients exhibiting a reduction in cholesterol levels once on

Audio Video Share Participants More

Tamoxifen is useful in patients with breast cancer and in those with an increased risk of breast cancer even if they do not have the disease. There is evidence that taking tamoxifen when premenopausal with a moderate or high risk of developing breast cancer can reduce the patient's chances of developing breast cancer. Taking tamoxifen after a diagnosis of breast cancer reduced the risk of recurrencealso reduces the risk of developing cancer in the also reduced the risk of cancer in the other breast.

B She will remain on tamoxifen indefinitely

After surgical intervention, tamoxifen reduces the risk of recurrence of ductal carcinoma *in situ* and early stage invasive disease. This is the basis for patients for being commenced on tamoxifen following surgical intervention. It is usually taken once daily for five years only. Tamoxifen can be taken for a longer period if the patient has metastatic disease.

D Her cholesterol levels will increase

In fact, the opposite has been observed with patients exhibiting a reduction in cholesterol levels once on tamoxifen.

E She will develop osteoporosis

Tamoxifen may not directly prevent osteoporosis but it has been shown to slow down the rate of bone loss when used prior to aromatase inhibitors. Usually, patients suffer a small loss in bone density but this is not felt to be significant. Osteoporosis is a multifactorial condition and cannot be solely attributed to the use of tamoxifen.

A 32-year-old man presents for yearly review after orchidectomy for a testicular neoplasm.

Which of the following blood tests is likely to be most sensitive for detecting tumour recurrence?

A	Acid phosphatase
B	Alkaline phosphatase
C	PSA
D	Testosterone levels
E	β-Human chorionic gonadotrphin (β-HCG)

Submit

Previous Q... Skip Questi...

© Pastest 2019

Rana Alnasser's screen

E β-Human chorionic gonadotrphin (β-HCG)

Along with α-fetoprotein (AFP) and LDH, ß-human chorionic gonadotrophin levels are measured to monitor for recurrence and also to monitor the burden of disease. In 70% of testicular tumours either β-HCG or α-fetoprotein is raised. They can also be raised in ovarian, cervical, endometrial and trophoblastic neoplasms.

A Acid phosphatase

Acid phosphatase was one of the first tumour markers used in clinical practice. It was used to identify patients with prostate cancer. However, in more recent times, advances and the identification of more specific tumour markers have meant that acid phosphatase has fallen out of favour.

B Alkaline phosphatase

Alkaline phosphatase has been used as a tumour marker in many gonadal and urological cancers (e.g. testicular germ cell), but is not the mainstay in clinical practice.

C PSA

PSA is a useful tumour marker in the diagnosis and management of prostate cancer, but adds little value when dealing with testicular seminoma.

D Testosterone levels

This patient would still be expected to produce testosterone given he has only had a unilateral orchidec[illegible] however, testosterone is not routinely used to monitor for testicular seminoma and would therefore

Annotation Stop Share

12:24
On
594-042-7551
Leave

C PSA

PSA is a useful tumour marker in the diagnosis and management of prostate cancer, but adds little value when dealing with testicular seminoma.

D Testosterone levels

This patient would still be expected to produce testosterone given he has only had a unilateral orchidectomy. However, testosterone is not routinely used to monitor for testicular seminoma and would therefore not be useful in diagnosing a recurrence in this patient.

Overall Explanation

The incidence of testicular tumours is 2–3 cases/100 000 men per year, and these account for 1–2% of all cancers in males. Average age at presentation is 30–36 years. Management depends on stage: orchidectomy is the mainstay of therapy, ± the addition of radiotherapy or chemotherapy.

Rate this question:

Audio Video Share Participants More

12:25
MyPastest
Home Feed | Res
Tumor Markers
https://mypastest.pastest.com/Secure/TestMe/

Pastest+

A 70-year-old man complains of vague left flank pain without any evidence of diarrhoea, nausea, vomiting or weight loss. He is aware of intermittent sweats, particularly at night, that improve with eating. On one occasion, he has fainted between meals.

An ultrasound of his abdomen was technically difficult to perform and a computerised tomography (CT) scan was recommended. This revealed a 3 cm mass in the tail of the pancreas. Blood biochemistry was normal. A blood glucose taken after an overnight fast and period on an exercise bike was recorded as 2 mmol/l. A CT-guided needle biopsy of the pancreas reveals ill-defined nests of cells separated by vascularised stroma, which stain strongly positive for chromogranin and synaptophysin.

What is the most likely diagnosis?

A	Vasoactive intestinal peptide endocrine tumour (VIPoma)
B	Gastrinoma
C	Somatostatinoma
D	Insulinoma
E	Glucagonoma

Submit
Rana Alnasser's screen

12:28
MyPastest
Home Feed | Re
Tumor Markers
https://mypastest.pastest.com/Secure/TestMe/

pancreas. Blood biochemistry was normal. A blood glucose taken after an overnight fast and period on an exercise bike was recorded as 2 mmol/l. A CT-guided needle biopsy of the pancreas reveals ill-defined nests of cells separated by vascularised stroma, which stain strongly positive for chromogranin and synaptophysin.

What is the most likely diagnosis?

Your answer was correct

A	Vasoactive intestinal peptide endocrine tumour (VIPoma)
B	Gastrinoma
C	Somatostatinoma
D	Insulinoma
E	Glucagonoma

Explanation

D	Insulinoma

Insulinomas are the most common pancreatic endocrine tumour, the incidence being about 1 case per 250 000. Approximately 50% of islet cell tumours are insulinomas. Patients with insulinomas may present with neurological or psychiatric disturbances. An important feature is that

Annotation
Stop Share

12:28
MyPastest
Home Feed | Re
Tumor Markers
https://mypastest.pastest.com/Secure/TestMe/

Pastest+

Insulinomas are the most common pancreatic endocrine tumour, the incidence being about 1 case per 250 000. Approximately 50% of islet cell tumours are insulinomas. Patients with insulinomas may present with neurological or psychiatric disturbances. An important feature is that symptoms tend to occur at night or early in the morning. The diagnosis is made by demonstrating inappropriately high concentrations of both insulin and C-peptide in the blood, and a blood glucose level of < 2.0–2.2 mmol/l, together with the clinical picture of a hypoglycaemic episode (confusion, altered consciousness, visual disturbances, weakness, sweating, tremulousness and, less commonly, seizures). Provocative testing with an overnight fast followed by exercise on a static bike can be done in a hospital setting. Frequent measurements of the blood glucose concentration should be made during the fast. Only when a low value is recorded should a sample be taken to provide serum for insulin and C-peptide assay.

A Vasoactive intestinal peptide endocrine tumour (VIPoma)

Patients suffering from a VIPoma present with large-volume secretory diarrhoea, not seen here.

B Gastrinoma

Gastrinomas are associated with development of the Zollinger–Ellison syndrome, and multiple peptic ulcers.

C Somatostatinoma

Annotation
Stop Share

A 59-year-old man under follow-up for cirrhosis secondary to hepatitis C infection comes to see you for his regular outpatient appointment. He has lost 5 kg in weight since his last clinic appointment four months ago and you notice his abdomen is larger than you would expect for someone with his physical frame.

On examination, you note splenomegaly, shifting dullness and you are unable to feel a liver edge due to his abdominal girth. You note that he has had some liver function tests and are able to compare the results to the bloods he had prior to his last clinic appointment.

	Today	Four months ago
ALT	59 IU/l	62 IU/l
ALP	220 IU/l	117 IU/l
Bilirubin	22 µmol/l	17 µmol/l
Albumin	26 g/l	35 g/l

Which of the following features most likely indicates that he may have developed hepatocellular carcinoma?

A Splenomegaly

B Low albumin

C Development of ascites

D Non-palpable liver

E Elevated serum alkaline phosphatase levels

12:31
On
MyPastest
594-042-7551
Leave
https://mypastest.pastest.com/Secure/TestMe/

his abdomen is larger than you would expect for someone with his physical frame.

On examination, you note splenomegaly, shifting dullness and you are unable to feel a liver edge due to his abdominal girth. You note that he has had some liver function tests and are able to compare the results to the bloods he had prior to his last clinic appointment.

	Today	Four months ago
ALT	59 IU/l	62 IU/l
ALP	220 IU/l	117 IU/l
Bilirubin	22 µmol/l	17 µmol/l
Albumin	26 g/l	35 g/l

Which of the following features most likely indicates that he may have developed hepatocellular carcinoma?

Your answer was correct

A Splenomegaly

B Low albumin

C Development of ascites

D Non-palpable liver

E Elevated serum alkaline phosphatase levels

Audio
Video
Share
Participants
More

E Elevated serum alkaline phosphatase levels

Elevated serum alkaline phosphatase levels can occur in cirrhosis. However, a sudden rise in levels, as in this patient's case, is suggestive of development of hepatocellular carcinoma.

A Splenomegaly

Splenomegaly is often associated with portal hypertension developed as a result of chronic liver disease, and therefore his cirrhosis, rather than as a result of hepatocellular cancer.

B Low albumin

Low albumin levels can be seen in both cirrhosis and hepatocellular carcinoma, so this is neither an effective nor a specific laboratory test to utilise in this scenario.

C Development of ascites

Ascites can be present in patients with cirrhosis. It is important to consider a malignant process if a rapid increase in abdominal girth is seen. A key point in the patient's history is that his ascites has been long-standing, meaning that an underlying malignant process is less likely. The way to determine whether the patient's ascites is due to a malignant process would be to perform an ascitic tap and then calculate the serum ascites-albumin gradient (SA-AG).

SA - AG = serum albumin concentration - ascitic albumin concentration

If SA-AG ≥ 11 g/l, the likely causes include cirrhosis, cardiac failure and nephrotic syndrome.

C Development of ascites

Ascites can be present in patients with cirrhosis. It is important to consider a malignant process if a rapid increase in abdominal girth is seen. A key point in the patient's history is that his ascites has been long-standing, meaning that an underlying malignant process is less likely. The way to determine whether the patient's ascites is due to a malignant process would be to perform an ascitic tap and then calculate the serum ascites-albumin gradient (SA-AG).

SA - AG = serum albumin concentration - ascitic albumin concentration

If SA-AG ≥ 11 g/l, the likely causes include cirrhosis, cardiac failure and nephrotic syndrome.

If SA-AG < 11 g/l, the likely causes include malignancy, pancreatitis and tuberculosis.

D Non-palpable liver

In well-established cirrhosis secondary to the hepatitis C virus, a small, shrunken liver follows the initial hepatomegaly. An irregularly enlarged and tender liver may be suggestive of hepatocellular carcinoma. It is difficult to fully assess this patient as he clearly has significant ascites which could be masking an enlarged liver. Equally, he may have a shrunken liver secondary to long-standing cirrhosis.

12:33
On
594-042-7551
Leave

A 55-year-old lawyer presents to the haemato-oncology unit, having been recently diagnosed with chronic lymphocytic leukaemia (CLL) after recurrent herpes simplex infection, two episodes of pneumonia and lymphadenopathy, accompanied by a white count of 62 × 10^9/l, with an overwhelming lymphocytosis. You note that from the consultant notes he is to be started on fludarabine.

What must the patient be started on prior to treatment commencing?

A	IV immunoglobulin
B	Cefuroxime
C	Tazocin
D	Tazocin plus gentamicin
E	Co-trimoxazole

Submit

Audio
Video
Share
Participants
More

12:35
On
MyPastest
594-042-7551
Leave
https://mypastest.pastest.com/Secure/TestMe/Brov

Pastes+

Question 13 of 90

A 55-year-old lawyer presents to the haemato-oncology unit, having been recently diagnosed with chronic lymphocytic leukaemia (CLL) after recurrent herpes simplex infection, two episodes of pneumonia and lymphadenopathy, accompanied by a white count of 62 × 10^9/l, with an overwhelming lymphocytosis. You note that from the consultant notes he is to be started on fludarabine.

What must the patient be started on prior to treatment commencing?

Your answer was incorrect

A IV immunoglobulin

B Cefuroxime

C Tazocin

D Tazocin plus gentamicin

E Co-trimoxazole

Explanation

E Co-trimoxazole

Fludarabine is a nucleoside analogue chemotherapeutic agent and is currently the most commonly used first line

Audio
Video
Share
Participants
More

12:35
On
594-042-7551
Leave

E Co-trimoxazole

Fludarabine is a nucleoside analogue chemotherapeutic agent and is currently the most commonly used first-line treatment in the management of CLL. Fludarabine is a successful therapy for CLL with response rates of over 80% and a 37% complete remission rate.

Patients with CLL are prone to opportunistic infections (both common and unusual). Pneumococcal and influenza vaccines are usually recommended prior to treatment.

As with a number of other chemotherapeutic agents, fludarabine causes pancytopenia, and as a result leucopenia places CLL patients at increased risk of *Pneumocystis jiroveci* pneumonia. As a result, patients usually commence co-trimoxazole prophylaxis or receive nebulised pentamidine monthly whilst on treatment with fludarabine.

A IV immunoglobulin

IV immunoglobulin has no evidence in PCP prophylaxis.

B Cefuroxime

Cefuroxime may be used in the treatment of neutropenic sepsis. usually in penicillin allergic patients (local guidelines may vary). It has no role in PCP prophylaxis.

C Tazocin

Tazocin is the initial empiric antibiotic therapy recommended by **NICE** to patients with suspected neutropenic sepsis unless there are patient-specific or local guidelines recommending a different antibiotic. It is not used either in the treatment or provision of prophylaxis against PCP.

Audio Video Share Participants More

12:38
MyPastest
Home Feed | Re
Tumor Markers
https://mypastest.pastest.com/Secure/TestMe/Brov

sepsis. usually in penicillin allergic patients (local guidelines may vary). It has no role in PCP prophylaxis.

C Tazocin

Tazocin is the initial empiric antibiotic therapy recommended by **NICE** to patients with suspected neutropenic sepsis unless there are patient-specific or local guidelines recommending a different antibiotic. It is not used either in the treatment or provision of prophylaxis against PCP.

D Tazocin plus gentamicin

Tazocin plus gentamicin may be used in the treatment of neutropenic sepsis but has no role in prophylaxis against PCP.

Rate this question:

Next Question

Previous Q... Tag Questi... Feedback End Session

Blog About Pastest Contact Us Help

© Pastest 2019

12:39
MyPastest
Home Feed | Re
Tumor Markers
https://mypastest.pastest.com/Secure/TestMe/Brov

A 32-year-old woman is admitted under the palliative care team with severe pain going down her left leg. She has advanced ovarian carcinoma and is only expected to live for a few weeks.

On examination, she has constant pain in the left posterior thigh and calf, radiating down to the great toe. She is currently taking paracetamol and morphine.

Investigations:

Haemoglobin (Hb)	10.4 g/dl
White cell count (WCC)	9.1×10^9/l
Platelet (PLT)	256×10^9/l
Sodium (Na^+)	140 mmol/l
Potassium (K^+)	4.9 mmol/l
Creatinine	195 µmol/l
Magnetic resonance imaging (MRI)	Tumour invasion of the left foramen of S1

Which of the following is the most appropriate way to manage her pain?

A Increase her morphine

B Oral diclofenac

C Surgical decompression

D Transcutaneous electrical nerve stimulation

12:39
MyPastest
Home Feed | Res
Tumor Markers
https://mypastest.pastest.com/Secure/TestMe/Brov
Pastest+

On examination, she has constant pain in the left posterior thigh and calf, radiating down to the great toe. She is currently taking paracetamol and morphine.

Investigations:

Haemoglobin (Hb)	10.4 g/dl
White cell count (WCC)	9.1×10^9/l
Platelet (PLT)	256×10^9/l
Sodium (Na^+)	140 mmol/l
Potassium (K^+)	4.9 mmol/l
Creatinine	195 µmol/l
Magnetic resonance imaging (MRI)	Tumour invasion of the left foramen of S1

Which of the following is the most appropriate way to manage her pain?

A Increase her morphine

B Oral diclofenac

C Surgical decompression

D Transcutaneous electrical nerve stimulation (TENS) machine

E S1 bupivacaine block

E S1 bupivacaine block

Palliative care physicians have considerable success in relieving pain with bupivacaine infiltration of a single nerve root. For an S1 block, a catheter is inserted under X-ray guidance towards the inferior lip of the S1 foramen and tunnelled subcutaneously to the hip, allowing easy access and reducing any chance of infection.

C Surgical decompression

Given very limited life expectancy and poor functional status, surgical decompression is not appropriate at this point.

A Increase her morphine

Increasing her morphine is likely to increase her level of drowsiness and affect her functioning, without necessarily completely relieving her pain. Patients often find mental clouding very distressing at a time when they want to maximise time with their family.

B Oral diclofenac

Diclofenac is inappropriate here as it is unlikely to significantly impact on her pain control, whilst risking a deterioration in her renal function.

D Transcutaneous electrical nerve stimulation (TENS) machine

Although TENS may be of value in relieving nerve pain, it is not likely to be as effective as a nerve block.

12:42

MyPastest | Home Feed | Re | Tumor Markers

https://mypastest.pastest.com/Secure/TestMe/Brov

Pastest+

A 48-year-old woman presents with a left leg deep venous thrombosis (DVT). On further questioning, there is a history of increasing abdominal distension and bloating over the past few months.

She has had no children and her menses began when she was aged 14. She used the oral contraceptive pill intermittently over the course of 20 years. Her father died of colon cancer at the age of 72.

On examination, there is evidence of ascites and a left ovarian mass. Ultrasound confirms the ovarian mass, and raised CA-125 is suggestive of ovarian carcinoma.

Which one of the following factors in her history is most associated with risk of ovarian cancer?

A	Family history of colonic carcinoma
B	History of previous DVT
C	Menarche at age 14
D	Use of oral contraceptive pill
E	Nulliparity

Submit

12:45
On 594-042-7551 Leave
MyPastest Home Feed | Re Tumor Markers
https://mypastest.pastest.com/Secure/TestMe/Brov

Pastes+ Question 15 of 90

E Nulliparity

Ovarian carcinoma can occur in girls as young as 15 years, but the commonest age at presentation is 56 years. It occurs most commonly in Caucasian women from industrialised countries. There is an association with early menarche, late menopause and nulliparity. Amongst lifestyle factors a high-fat diet has been linked in some cohort studies to the development of the disease. A steady decrease in risk is seen in association with increased parity and use of the oral contraceptive pill.

A Family history of colonic carcinoma

A history of breast carcinoma and a family history of breast and ovarian carcinoma are associated with increased risk of ovarian cancer, (in this case due to increased risk of the BRCA1 mutation).

B History of previous DVT

Although current DVT is associated with cancer, history of previous deep venous thrombosis isn't a risk factor.

C Menarche at age 14

Menarche at age 14 is relatively late, this isn't associated with increased risk of ovarian cancer.

D Use of oral contraceptive pill

Audio Video Share Participants More

12:47
On
594-042-7551
Leave

A Family history of colonic carcinoma

A history of breast carcinoma and a family history of breast and ovarian carcinoma are associated with increased risk of ovarian cancer, (in this case due to increased risk of the BRCA1 mutation).

B History of previous DVT

Although current DVT is associated with cancer, history of previous deep venous thrombosis isn't a risk factor.

C Menarche at age 14

Menarche at age 14 is relatively late, this isn't associated with increased risk of ovarian cancer.

D Use of oral contraceptive pill

Use of the oral contraceptive pill is associated with protection from, not with increased risk of, ovarian cancer.

Rate this question:

Next Question

Blog About Pastest Contact Us Help
Audio Video Share Participants More

12:47
On
594-042-7551
Leave

A 51-year-old woman visits her general practitioner (GP) after becoming concerned about the change in appearance of a mole on her right thigh. The mole has been there for about two years, but in the last few months, the patient has noticed that it has become increasingly dark in colour and appears to have grown in size.

On examination, she has a slightly elevated brown lesion on the anterior aspect of her right thigh. The lesion measures 7 mm and has an irregular border.

The GP immediately refers the patient to the local Dermatology Unit for an excisional biopsy for a suspected diagnosis of melanoma.

Which of the following is NOT a primary risk factor for the development of melanoma?

A	Fair complexion
B	A personal or a family history in a first-degree relative of melanoma
C	Female sex
D	Greater than 50 naevi, 2 mm or greater in diameter
E	A sunny climate located near the equator

Submit
Audio
Video
Share
Participants
More

C Female sex

Male patients (especially those >50 years old) are more likely to develop a malignant melanoma.

A Fair complexion

Fair complexion is a well-known risk factor for malignant melanoma.

B A personal or a family history in a first-degree relative of melanoma

Patients with a family history of melanoma are more likely to develop melanoma themselves.

D Greater than 50 naevi, 2 mm or greater in diameter

This is a well-known risk factor for malignant melanoma.

E A sunny climate located near the equator

Patients who live near the equator, suffer sunburn and have greater exposure to UV radiation have an increased risk of developing malignant melanoma.

Rate this question:

Next Question

Previous Q... Tag Questi... Feedback End Session

12:52

A 63-year-old man presented to the general practitioner (GP) with a 4-week history of lethargy and occasional fevers. More recently, he has noticed he is feeling dizzy and short of breath on exertion.

On examination, he appears pale. Interestingly, he noticed blood in the sink when brushing his teeth, and his wife thinks his gums have become swollen.

On examination, the GP noticed the patient has splenomegaly and a petechial rash on his shins.

Investigations:

Haemoglobin (Hb)	89 g/l
White cell count (WCC)	125×10^9/l
Platelet (PLT)	75×10^9/l
Urea	5.2 mmol/l
Creatinine	87 µmol/l

What is the definitive choice for the management of this case?

A Correct anaemia and thrombocytopenia

B Treat infection

C Administer allopurinol

D Urgent induction chemotherapy

E Start IV fluid therapy

Rana Alnasser's screen

D Urgent induction chemotherapy

This patient has hyperleukocytosis, for which he has started to become symptomatic with exertional dyspnoea and dizziness. This is indicative of acute myeloid leukaemia and needs urgent cytoreduction. This can be achieved with either induction chemotherapy, hydroxyurea or leukapheresis.

The most appropriate option would be to arrange immediate hospital admission to start induction chemotherapy with IV fluids and allopurinol as tumour lysis prophylaxis. Leukapheresis is a controversial choice and should only be used for symptomatic hyperleukocytosis when factors would delay induction chemotherapy.

A Correct anaemia and thrombocytopenia

Despite the Hb and PLT levels being low, they are not low enough to completely prohibit commencing chemotherapy. You may want to consider blood products to normalise these levels before commencing chemotherapy, or to monitor bloods and treat with blood products as required.

B Treat infection

This patient does have a markedly raised WCC and a history of fever. However, in this case, the raised WCC is for more likely to be due to acute myeloid leukaemia, rather than as a result of an infection. This is supported by the clinical findings of splenomegaly and petechial rash.

C Administer allopurinol

This patient is at risk of tumour lysis syndrome, for which allopurinol can be given prophylactically. In tumour lysis

monitor bloods and treat with blood products as required.

B Treat infection

This patient does have a markedly raised WCC and a history of fever. However, in this case, the raised WCC is for more likely to be due to acute myeloid leukaemia, rather than as a result of an infection. This is supported by the clinical findings of splenomegaly and petechial rash.

C Administer allopurinol

This patient is at risk of tumour lysis syndrome, for which allopurinol can be given prophylactically. In tumour lysis syndrome, chemotherapy causes rapid necrosis of neoplastic cells that results in hypocalcaemia, hyperphosphataemia and hyperkalaemia. The increased phosphate levels are thought to lead to tissue deposition of calcium phosphate. This condition is potentially life-threatening but can usually be prevented by making sure that chemotherapy is not started until the uric acid level is normal, and by diuresis established with intravenous (IV) fluids or now with use of rasburicase.

This question asks for the definitive management for this patient. Tumour lysis syndrome is a concern in this patient but is not a definite consequence of having chemotherapy.

E Start IV fluid therapy

IV fluids can be beneficial in normalising the uric acid levels before commencing chemotherapy when tumour lysis syndrome is a concern. You may have thought that IV fluids may have a dilutional effect on the WCC, which it may do to a certain degree, but it will not be significant enough to reduce the WCC sufficiently for chemotherapy to be commenced safely.

A 35-year-old patient with newly diagnosed stage III diffuse large B cell lymphoma is being considered for CHOP chemotherapy with additional rituximab.

What one of the following side-effects is most commonly seen in association with rituximab therapy?

A	PML
B	Bullous skin reactions
C	Oral mucositis
D	Fever and rigors
E	Palmar plantar syndrome

33422

Submit

© Pastest 2019

12:55

D Fever and rigors

Rituximab is a monoclonal antibody that targets CD20 on the surface of B lymphocytes.

The most common side effects are:

- flu-like symptoms – these include a high temperature, chills, weakness, muscle aches, tiredness, dizziness and headaches during the infusion
- low blood pressure during the infusion
- nausea and occasional vomiting
- tumour pain
- allergic reactions – signs of this include skin rashes and itching, a feeling of swelling in the tongue or throat, irritation of the nasal passages, wheezing, a cough and breathlessness
- facial flushing during the infusion.

C Oral mucositis

Oral mucositis is more likely to be seen in patients treated with conventional chemotherapy agents rather than with rituximab.

A PML

PML, or progressive multifocal leukoencephalopathy, is very rarely reported with rituximab therapy, usually when this is used in combination with other therapies.

B Bullous skin reactions

Rana Alnasser's screen

rely seen in patients treated

- tumour pain
- allergic reactions – signs of this include skin rashes and itching, a feeling of swelling in the tongue or throat, irritation of the nasal passages, wheezing, a cough and breathlessness
- facial flushing during the infusion.

C Oral mucositis

Oral mucositis is more likely to be seen in patients treated with conventional chemotherapy agents rather than with rituximab.

A PML

PML, or progressive multifocal leukoencephalopathy, is very rarely reported with rituximab therapy, usually when this is used in combination with other therapies.

B Bullous skin reactions

Bullous skin reactions are rarely seen in patients treated with rituximab. Other skin disorders such as itching, erythematous rashes and alopecia are commonly seen.

E Palmar plantar syndrome

Palmar plantar syndrome, also known as chemotherapy-induced acral erythema, is associated with capecitabine therapy.

Rate this question:

Next Question

12:57

https://www.google.com/sea

19

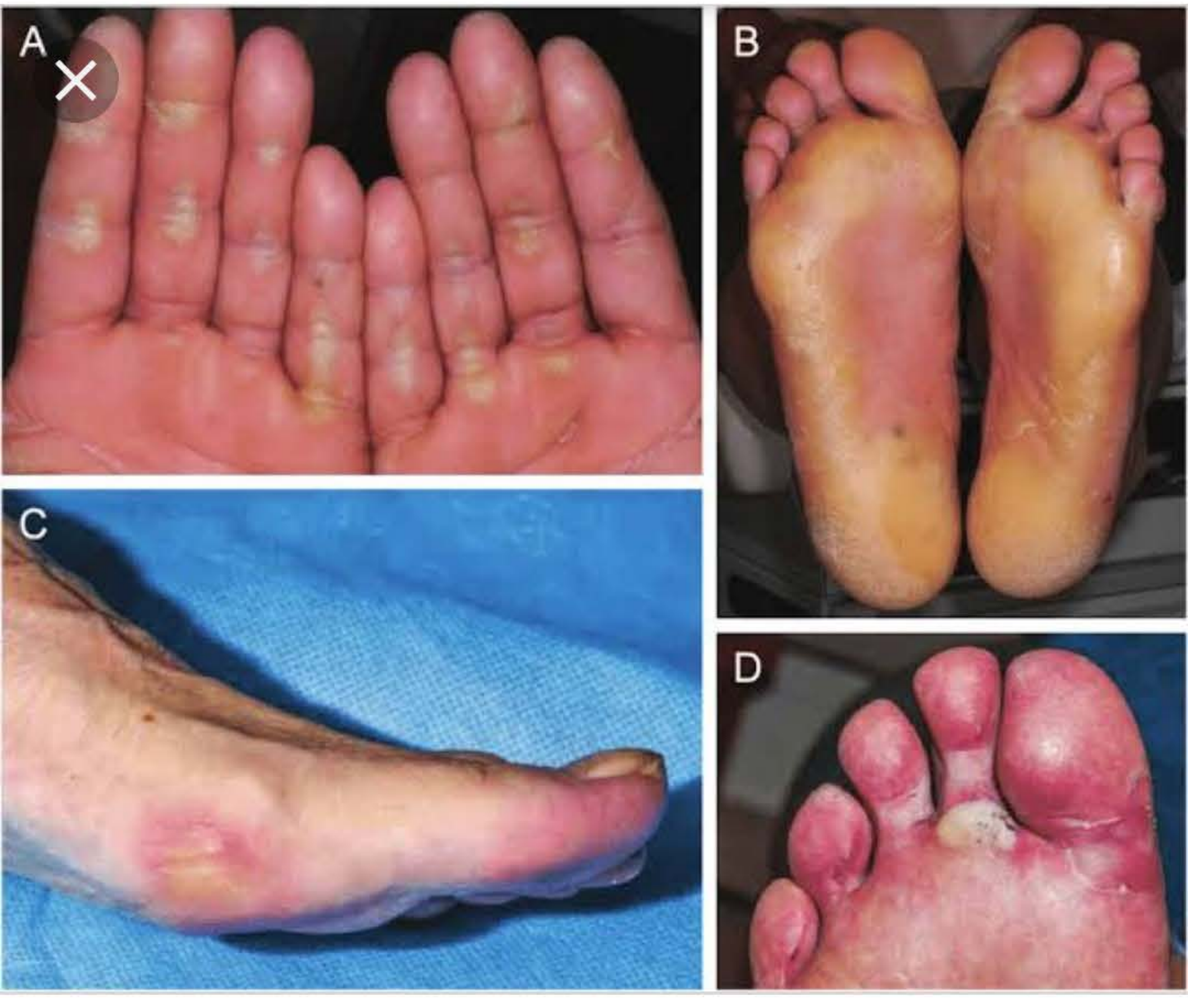

ResearchGate

examples of palmar-plantar erythrodysesthesia syndrome r...

Images may be subject to copyright. Learn More

RELATED IMAGES

[Full text] Practical managem...
dovepress.com

Palmar erythema, with fissur...
researchgate.net

Springer Link

Antineoplastic Therapy—Induced Palmar Plantar Erythrodysesthe...

Images may be subject to copyright. Learn More

RELATED IMAGES

SOUTHWEST JOURNAL of PU...
swjpcc.com

VIRTUAL GRAND ROUNDS IN ...
vgrd.blogspot.com

12:58
On
594-042-7551
Leave

A 35-year-old woman is worried because her mother developed breast cancer at 45 years of age, as did both maternal aunts at the ages of 48 and 52. She presents to the cancer genetics clinic for review. She has no past medical history of note, menarche was at age 13 and she is of normal body weight.

Which of the following genetic mutations would you expect to find on testing?

A	Breast cancer susceptibility gene 1 (BRCA1)
B	Breast Cancer susceptibility gene 2 (BRCA2)
C	P53
D	No known mutation identified
E	Phosphatase and tensin homolog (pTEN)

33429

Submit

Pastest Contact Us Help
Audio Video Share Participants More

developed breast cancer at 45 years of age, as did both maternal aunts at the ages of 48 and 52. She presents to the cancer genetics clinic for review. She has no past medical history of note, menarche was at age 13 and she is of normal body weight.

Which of the following genetic mutations would you expect to find on testing?

Your answer was incorrect

A	Breast cancer susceptibility gene 1 (BRCA1)
B	Breast Cancer susceptibility gene 2 (BRCA2)
C	P53
D	No known mutation identified
E	Phosphatase and tensin homolog (pTEN)

Explanation

D	No known mutation identified

The majority of breast cancer is sporadic. Genetic breast cancer occurs in women with an alteration in a breast cancer susceptibility gene, which has been inherited through the germline. Familial breast cancer occurs in women and is associated with both ovarian and pancreatic cancer.

Some susceptibility genes for breast cancer have been identified. These include BRCA1, BRCA2, p53 and pTEN. Most genetic susceptibility, however, is as a consequence

Annotation Stop Share

D No known mutation identified

The majority of breast cancer is sporadic. Genetic breast cancer occurs in women with an alteration in a breast cancer susceptibility gene, which has been inherited through the germline. Familial breast cancer occurs in women and is associated with both ovarian and pancreatic cancer.

Some susceptibility genes for breast cancer have been identified. These include BRCA1, BRCA2, p53 and pTEN. Most genetic susceptibility, however, is as a consequence of as yet undetermined genes or those of low penetrance.

NICE recommends referral to a specialist clinic when the following conditions are met:

1. mother or sister diagnosed with breast cancer before the age of 40 years
2. close relatives from the same side of the family diagnosed with breast cancer – at least one must be a mother, sister or daughter
3. three close relatives diagnosed with breast cancer at any age
4. father or brother diagnosed with breast cancer at any age
5. mother or sister with breast cancer in both breasts – the first cancer diagnosed before the age of 50 years
6. one close relative with ovarian cancer and one with breast cancer, diagnosed at any age – at least one must be a mother, sister or daughter.

A Breast cancer susceptibility gene 1 (BRCA1)

BRCA1 is associated with breast and ovarian cancer due to a defect in a DNA repair gene. The absence of any history of ovarian cancer counts against BRCA1, as does the relatively older age at presentation of her relatives.

Rana Alnasser's screen

the first cancer diagnosed before the age of 50 years

6. one close relative with ovarian cancer and one with breast cancer, diagnosed at any age – at least one must be a mother, sister or daughter.

A Breast cancer susceptibility gene 1 (BRCA1)

BRCA1 is associated with breast and ovarian cancer due to a defect in a DNA repair gene. The absence of any history of ovarian cancer counts against BRCA1, as does the relatively older age at presentation of her relatives.

B Breast Cancer susceptibility gene 2 (BRCA2)

Like BRCA1, BRCA2 is associated with the development of breast and ovarian cancer at a young age. The age at presentation and lack of ovarian disease counts against a BRCA2 mutation being present.

C P53

P53 mutations are associated with a range of cancers including breast cancer; the absence of other tumours being seen here counts against a P53 mutation as the cause.

E Phosphatase and tensin homolog (pTEN)

pTEN mutations lead to defective tumour suppression and result in breast cancer, but usually as part of Cowden syndrome with endometrial and thyroid cancer.

33429

Rate this question:

Next Question

Rana Alnasser's screen

1:08
MyPastest
Home Feed | Re
Tumor Markers
https://mypastest.pastest.com/Secure/TestMe/Browse

A 72-year-old woman presents to the clinic with gradual weight loss of 3 kg without actually trying. She takes no medication and works part-time as a volunteer at the local hospital.

On examination, she looks pale and there is evidence of hepatosplenomegaly. Her weight 6 months ago was 70 kg.

Investigations:

Haemoglobin (Hb)	11.5 g/dl
White cell count (WCC)	29.1×10^9/l (CD20-, CD5-positive lymphocytes)
Platelet (PLT)	160×10^9/l
Sodium (Na^+)	139 mmol/l
Potassium (K^+)	5.3 mmol/l
Creatinine	130 µmol/l
Immunoglobulins	Reduced

Which of the following is the most appropriate way to manage her case?

A Arrange for periodic review

B Start immunoglobulin replacement

C Start fludarabine

D Start rituximab

Rana Alnasser's screen

1:08
https://mypastest.pastest.com/Secure/TestMe/Browse

On examination, she looks pale and there is evidence of hepatosplenomegaly. Her weight 6 months ago was 70 kg.

Investigations:

Haemoglobin (Hb)	11.5 g/dl
White cell count (WCC)	29.1×10^9/l (CD20-, CD5-positive lymphocytes)
Platelet (PLT)	160×10^9/l
Sodium (Na^+)	139 mmol/l
Potassium (K^+)	5.3 mmol/l
Creatinine	130 µmol/l
Immunoglobulins	Reduced

Which of the following is the most appropriate way to manage her case?

A Arrange for periodic review

B Start immunoglobulin replacement

C Start fludarabine

D Start rituximab

E Start iron sulphate replacement

21017

Submit

Haemoglobin (Hb)	11.5 g/dl
White cell count (WCC)	29.1 × 10^9/l (CD20-, CD5-positive lymphocytes)
Platelet (PLT)	160 × 10^9/l
Sodium (Na^+)	139 mmol/l
Potassium (K^+)	5.3 mmol/l
Creatinine	130 µmol/l
Immunoglobulins	Reduced

Which of the following is the most appropriate way to manage her case?

Your answer was correct

A Arrange for periodic review

B Start immunoglobulin replacement

C Start fludarabine

D Start rituximab

E Start iron sulphate replacement

Explanation

A Arrange for periodic review

This woman has chronic lymphocytic leukaemia, but is relatively asymptomatic at the current time. As such, the

A Arrange for periodic review

This woman has chronic lymphocytic leukaemia, but is relatively asymptomatic at the current time. As such, the recommendation is merely to arrange for periodic follow-up. Indications to begin chemotherapy include particularly troublesome symptoms such as night sweats, fevers or rapid weight loss; progressive marrow failure as characterised by rapidly worsening anaemia or thrombocytopenia; progressive lymphocytosis as characterised by a doubling time of less than six months; and symptomatic splenomegaly (presenting with severe pain or anorexia).

B Start immunoglobulin replacement

Intravenous (iv) immunoglobulin replacement is considered in chronic lymphocytic leukaemia (CLL) for patients who suffer from recurrent infections due to deficient antibody production.

C Start fludarabine

Fludarabine is the most extensively studied of chemotherapy agents in CLL, although monotherapy is not recommended. For patients who can tolerate it, fludarabine combined with rituximab is a commonly utilised initial treatment regimen.

D Start rituximab

Rituximab is used in combination with both fludarabine and chlorambucil; partial responses only are seen when it is used as monotherapy.

E Start iron sulphate replacement

1:11

MyPastest | Home Feed | Re | Tumor Markers

https://mypastest.pastest.com/Secure/TestMe/Browse

Fludarabine is the most extensively studied of chemotherapy agents in CLL, although monotherapy is not recommended. For patients who can tolerate it, fludarabine combined with rituximab is a commonly utilised initial treatment regimen.

D	Start rituximab

Rituximab is used in combination with both fludarabine and chlorambucil; partial responses only are seen when it is used as monotherapy.

E	Start iron sulphate replacement

The Hb is on the limit of the normal range, there are no symptoms of anaemia and iron deficiency is unlikely to be the cause here.

Rate this question:

Next Question

Previous Q... Tag Questi... Feedback End Session

Blog About Pastest Contact Us Help

© Pastest 2019

A 70-year-old man presents to his general practitioner (GP) practice complaining of a change in the colour of his urine for the past two weeks – it is more pink than yellow. This change is not associated with any pain and he is not experiencing any increased frequency of urination.

He is otherwise fit and well but does suffer from nocturia related to prostatic enlargement. He is non-smoker. He has only recently retired from his job as an engineer in a paint manufacturing plant. The GP suspects that this patient may have an underlying bladder cancer and hence initiates appropriate investigations. The patient wants to discuss any potential risk factors he may have for bladder cancer.

Which of the following is the strongest risk factor for the development of bladder cancer?

A	Excessive alcohol consumption
B	Exposure to aromatic amines
C	Coffee consumption
D	Artificial sweetener intake
E	Mutation of chromosome 11q13

73408

Submit

experiencing any increased frequency of urination.

He is otherwise fit and well but does suffer from nocturia related to prostatic enlargement. He is non-smoker. He has only recently retired from his job as an engineer in a paint manufacturing plant. The GP suspects that this patient may have an underlying bladder cancer and hence initiates appropriate investigations. The patient wants to discuss any potential risk factors he may have for bladder cancer.

Which of the following is the strongest risk factor for the development of bladder cancer?

Your answer was correct

A Excessive alcohol consumption

B Exposure to aromatic amines

C Coffee consumption

D Artificial sweetener intake

E Mutation of chromosome 11q13

Explanation

B Exposure to aromatic amines

Bladder cancer is a common urological cancer, with most cases being transitional cell carcinomas. It has a male : female ratio of 3 : 1, with women generally having a worse prognosis than men. The most classical presentation is with total, gross, painless haematuria. Bladder cancer is associated with a number of environmental risk factors, including smoking, industrial exposure to aromatic amines,

B Exposure to aromatic amines

Bladder cancer is a common urological cancer, with most cases being transitional cell carcinomas. It has a male : female ratio of 3 : 1, with women generally having a worse prognosis than men. The most classical presentation is with total, gross, painless haematuria. Bladder cancer is associated with a number of environmental risk factors, including smoking, industrial exposure to aromatic amines, prior radiation treatment to the pelvis and exposure to a urinary metabolite of cyclophosphamide (acrolein).

A Excessive alcohol consumption

Alcohol consumption is linked to a range of cancers including oesophageal, primary liver and a range of cancers linked to weight gain and increased insulin resistance.

C Coffee consumption

Coffee *per se* has not been identified as a cause of cancer, although very hot drinks are associated with increased risk of carcinoma of the oesophagus.

D Artificial sweetener intake

Although initial concerns were raised about artificial sweeteners being linked to bladder cancer, extensive epidemiological studies have revealed no link.

E Mutation of chromosome 11q13

Certain genetic mutations have also been identified as causing bladder cancer. These include mutations on 17p13.1, the gene coding for p53, mutations of which are associated with high-grade bladder cancer, and 9p15 and 9p16,

A Excessive alcohol consumption

Alcohol consumption is linked to a range of cancers including oesophageal, primary liver and a range of cancers linked to weight gain and increased insulin resistance.

C Coffee consumption

Coffee *per se* has not been identified as a cause of cancer, although very hot drinks are associated with increased risk of carcinoma of the oesophagus.

D Artificial sweetener intake

Although initial concerns were raised about artificial sweeteners being linked to bladder cancer, extensive epidemiological studies have revealed no link.

E Mutation of chromosome 11q13

Certain genetic mutations have also been identified as causing bladder cancer. These include mutations on 17p13.1, the gene coding for p53, mutations of which are associated with high-grade bladder cancer, and 9p15 and 9p16, another tumour suppressor gene associated with low-grade and superficial tumours. 11q13 gene mutations are associated with increased risk of oral cancers.

Rate this question:

Next Question

Previous Q... Tag Questi... Feedback End Session

Rana Alnasser's screen

A 62-year-old woman presents with persistent cough, chest pain, confusion, nausea and irritability.

Bronchoscopy reveals a small cell carcinoma of the lung.

Which of the following options is a possible endocrine manifestation of this tumour?

A	Galactorrhoea
B	Impaired glucose tolerance
C	Cold intolerance
D	Hypercalcaemia
E	Depigmentation

Submit

Previous Q... Skip Questi...

© Pastest 2019

1:15

B Impaired glucose tolerance

Approximately 20% of cases with bronchial carcinoma are of the small cell type and arise from endocrine (Kulchitsky) cells. Syndrome of inappropriate ADH secretion (SIADH) and ectopic secretion of ACTH are the two commonest endocrine paraneoplastic manifestations, occurring in 5–10 and 5% of cases, respectively. Ectopic atrial natriuretic peptide secretion can also occur. Features of ectopic ACTH secretion include weight gain, abdominal striae, hypertension and impaired glucose tolerance.

A Galactorrhoea

Galactorrhoea is associated with hyperprolactinaemia, which isn't a feature of small cell bronchial carcinoma.

C Cold intolerance

Cold intolerance suggests hypothyroidism, which isn't a feature of small cell bronchial carcinoma.

D Hypercalcaemia

Hypercalcaemia is associated with production of PTHrp, which is produced by squamous cell carcinoma of the bronchus.

E Depigmentation

Depigmentation suggests vitiligo, which is an autoimmune phenomenon.

Rate this question:

Rana Alnasser's screen

1:16
On 594-042-7551 Leave

A 75-year-old man with metastatic prostate cancer is admitted to the medical admission unit following a general practitioner (GP) referral for uncontrolled pain. He is currently on zoladex injections 6-monthly and 0.5 mg dexamethasone for his prostate cancer. His PSA remains stable at 18. Other medication includes atenolol and paracetamol.

A week ago, his GP prescribed codeine 30 mg and ibuprofen 400 mg, both to be taken as required. Since then, his abdominal and back pain has increased, leading to his emergency admission.

On admission, he is haemodynamically stable. His urine dipstick is positive for protein (++) and he has not opened his bowels for several days.

What would be the most appropriate management?

A	Nothing: his pain is due to the underlying malignancy
B	Try subcutaneous morphine next to avoid overloading the patient with tablets
C	Try to continue giving his pain relief on an as-required basis
D	Laxatives and anti-emetics are often needed with analgesics
E	Try tramadol instead of codeine to alleviate pain

Submit

Audio Video Share Participants More

ibuprofen 400 mg, both to be taken as required. Since then, his abdominal and back pain has increased, leading to his emergency admission.

On admission, he is haemodynamically stable. His urine dipstick is positive for protein (++) and he has not opened his bowels for several days.

What would be the most appropriate management?

Your answer was correct

A	Nothing: his pain is due to the underlying malignancy
B	Try subcutaneous morphine next to avoid overloading the patient with tablets
C	Try to continue giving his pain relief on an as-required basis
D	Laxatives and anti-emetics are often needed with analgesics
E	Try tramadol instead of codeine to alleviate pain

Explanation

D Laxatives and anti-emetics are often needed with analgesics

This patient has noticed a spike in pain and this could be partially due to the fact he has been commenced on codeine, which causes constipation, without any laxatives. Many analgesics, such as morphine-based medications, commonly cause constipation and nausea and good practice involves prophylactically prescribing concurrent

D Laxatives and anti-emetics are often needed with analgesics

This patient has noticed a spike in pain and this could be partially due to the fact he has been commenced on codeine, which causes constipation, without any laxatives. Many analgesics, such as morphine-based medications, commonly cause constipation and nausea and good practice involves prophylactically prescribing concurrent medication to try and reduce the side effect profile for the patient.

A Nothing: his pain is due to the underlying malignancy

It is important to bear in mind that the malignancy is not always the cause of pain in a patient with advanced cancer; for example, abdominal pain may be due to constipation, or indigestion pain may be due to the side-effects of nonsteroidal anti-inflammatory drugs (NSAIDs).

B Try subcutaneous morphine next to avoid overloading the patient with tablets

Oral administration is always the most favourable route of administration and often gives the patient the most freedom.

C Try to continue giving his pain relief on an as-required basis

The aim is to try and stabilise the patient on a regular prophylactic regime of analgesia with prn doses for breakthrough pain.

E Try tramadol instead of codeine to alleviate pain

breakthrough pain.

E	Try tramadol instead of codeine to alleviate pain

The WHO analgesic ladder is a concept of controlling pain using medications of increasing potency when one medication of the rung of the ladder does not work.

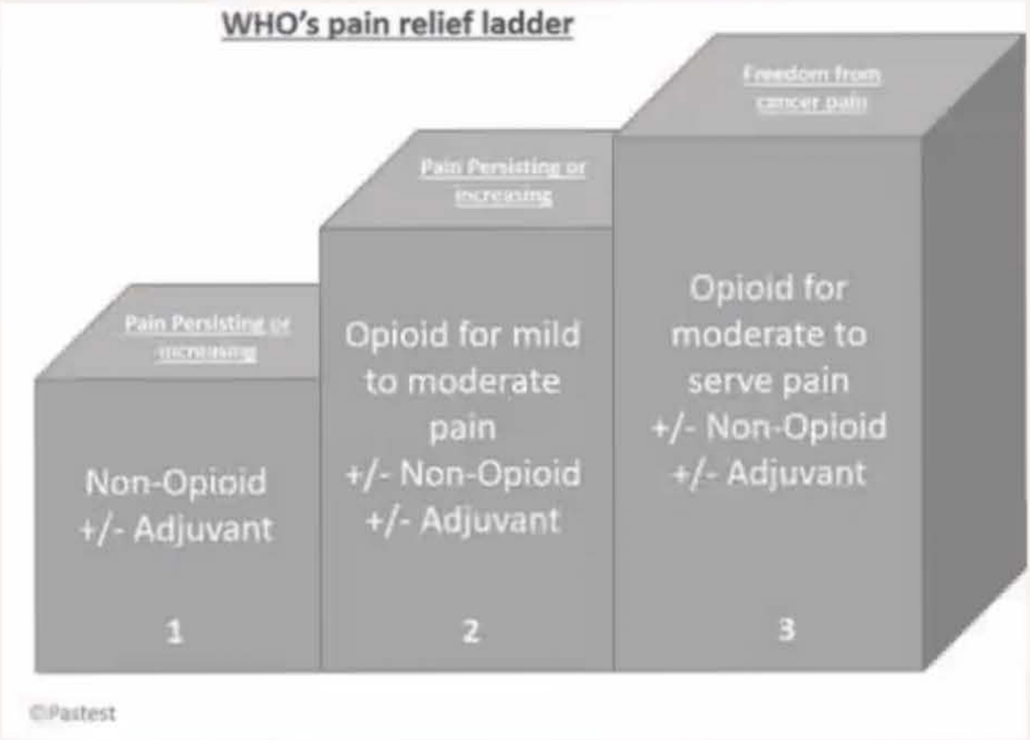

If one drug in a category (rung of the ladder) does not work, the aim is to move up the ladder without trying another drug at the same level. In severe pain, it would be acceptable to jump on at rung three. In this man's case, we cannot completely exclude that the jump in pain over the last week is related to constipation. Regardless, he has been to see the GP prior to this when he was simply on paracetamol. It would be worth considering commencing oral morphine sulphate initially on an as-required basis with anti-emetic and laxative cover. If the patient was requiring many doses of the oral morphine, it would be worth considering starting a long-acting morphine sulphate tablet with the oral morphine being used for breakthrough pain.

Rate this question:

1:20

MyPastest | Home Feed | Re | Tumor Markers

https://mypastest.pastest.com/Secure/TestMe/Browse

A 67-year-old woman comes to the clinic complaining of weakness and lethargy with generalized bony aches and pains over the past few months. She saw the general practitioner (GP) some three months earlier because of an episode of pneumococcal pneumonia.

On examination, she looks pale and tired. Her blood pressure (BP) is 135/80 mmHg, with pulse 70/min and regular. There are no specific findings on cardiovascular, respiratory and abdominal examinations.

Investigations:

Haemoglobin (Hb)	10.8 g/dl
White cell count (WCC)	9.9×10^9/l
Platelet (PLT)	162×10^9/l
Sodium (Na^+)	139 mmol/l
Potassium (K^+)	4.9 mmol/l
Creatinine	182 µmol/l
Albumin	23 g/l
Immunoglobulin electrophoresis	IgG paraprotein band
24 h urinary protein	3.2 g
Bone marrow	30% plasma cells

Which of the following is the most useful test with respect to establishing prognosis?

A Haemoglobin

B Beta-2 microglobulin

Rana Alnasser's screen

1:21

MyPastest | Home Feed | Re | Tumor Markers

https://mypastest.pastest.com/Secure/TestMe/Browse

Haemoglobin (Hb)	10.8 g/dl
White cell count (WCC)	9.9×10^9/l
Platelet (PLT)	162×10^9/l
Sodium (Na^+)	139 mmol/l
Potassium (K^+)	4.9 mmol/l
Creatinine	182 µmol/l
Albumin	23 g/l
Immunoglobulin electrophoresis	IgG paraprotein band
24 h urinary protein	3.2 g
Bone marrow	30% plasma cells

Which of the following is the most useful test with respect to establishing prognosis?

A Haemoglobin

B Beta-2 microglobulin

C C-reactive protein (CRP)

D Albumin

E Platelet count

Rana Alnasser's screen

B Beta-2 microglobulin

Beta-2 microglobulin is a very useful surrogate marker for the overall myeloma disease burden. Additionally, levels of beta-2 microglobulin are elevated in chronic kidney disease and hence measurement provides a useful integrated measure of the degree of renal dysfunction and myeloma burden. In a series of 148 patients, beta-2-microglobulin > 2.5 mg/l was associated with a 5-year risk of disease progression of 64%.

A Haemoglobin

Although haemoglobin is associated with poor prognosis in a univariate analysis, at is an Hb level < 100 g/l that drives a poor prognostic outcome.

C C-reactive protein (CRP)

CRP is not a strong prognostic indicator in patients with myeloma. It is primarily a marker of systemic inflammation.

D Albumin

Serum albumin < 30 g/l is a poor prognostic indicator in myeloma, because it is an indicator of significant proteinuria and nutritional status, although it's a less specific marker of disease burden than beta-2 microglobulin.

E Platelet count

Platelet count < 150 is associated with poor prognostic outcome in patients with myeloma.

Hypercalcaemia, serum creatinine elevation and performance status are other markers of poor prognosis in

Rana Alnasser's screen

Beta-2 microglobulin is a very useful surrogate marker for the overall myeloma disease burden. Additionally, levels of beta-2 microglobulin are elevated in chronic kidney disease and hence measurement provides a useful integrated measure of the degree of renal dysfunction and myeloma burden. In a series of 148 patients, beta-2-microglobulin > 2.5 mg/l was associated with a 5-year risk of disease progression of 64%.

A Haemoglobin

Although haemoglobin is associated with poor prognosis in a univariate analysis, at is an Hb level < 100 g/l that drives a poor prognostic outcome.

C C-reactive protein (CRP)

CRP is not a strong prognostic indicator in patients with myeloma. It is primarily a marker of systemic inflammation.

D Albumin

Serum albumin < 30 g/l is a poor prognostic indicator in myeloma, because it is an indicator of significant proteinuria and nutritional status, although it's a less specific marker of disease burden than beta-2 microglobulin.

E Platelet count

Platelet count < 150 is associated with poor prognostic outcome in patients with myeloma.

Hypercalcaemia, serum creatinine elevation and performance status are other markers of poor prognosis in multiple myeloma.

A 50-year-old man underwent a routine pre-employment medical check. He has no symptoms to report.

He is a lifelong non-smoker who drinks approximately 5–8 units of alcohol a week. His body mass index (BMI) is 26 kg/m^2, and he plays football with the local five-a-side team on a weekly basis.

He underwent an echocardiogram and chest X-ray as part of his routine check-up. His X-ray is shown below.

What could be the most likely cause in this case?

A	Primary bronchial carcinoma
B	Gastric carcinoma
C	Renal cell carcinoma
D	Pulmonary tuberculosis
E	Sarcoidosis

1:26

MyPastest | Home Feed | Re | Tumor Markers

https://mypastest.pastest.com/Secure/TestMe/Browse

C Renal cell carcinoma

Cannonball metastases or smooth, round metastases often relate to a malignancy of renal origin, meaning this is the most likely cause of his lesion.

D Pulmonary tuberculosis

Typical X-ray findings in a patient with pulmonary TB would be patchy or nodular shadowing in the upper zones, loss of volume and fibrosis, with or without cavitation. This patient has a well-circumscribed lesion, making a diagnosis of pulmonary TB less likely.

A Primary bronchial carcinoma

Primary bronchial carcinoma is unlikely at this age in a non-smoker without any palpable lymph nodes.

B Gastric carcinoma

Gastric cancer usually involves the mediastinal glands and spreads along the lymphatics of both lungs, which makes gastric carcinoma less likely to be the cause of his lesion.

E Sarcoidosis

Typically, X-rays would show bilateral hilar lymphadenopathy in patients with sarcoidosis, rather than a solitary round lesion.

Rate this question:

1:27
On 594-042-7551 Leave

An 18-year-old man presents to his general practitioner (GP) complaining of lower left-sided back pain that has been present for a few weeks. He reports that it initially started off intermittently but has now become more intense. On further questioning, he admits to having lost about 4 kg in weight over the last month. He denies any travel history.

On examination, a tender and palpable mass can just be felt over his left iliac crest. An urgent magnetic resonance imaging (MRI) scan is requested by the GP, as well as routine blood investigations. The blood results show a mild anaemia but no leukocytosis; C-reactive protein is normal. The MRI findings are compatible with a diagnosis of Ewing's sarcoma.

Which of the following is most associated with a poor prognosis in this patient?

A Anaemia

B Age 18 years

C Lack of inflammatory response

D Presence of back pain

E Weight loss

Submit

Audio Video Share Participants More

1:29

A Anaemia

Ewing's sarcoma is the most lethal malignant primary bone tumour derived from the red bone marrow. It is most common in children and adolescents and rare after the age of 30 years. It has a male-to-female ratio of 3: 2. The earliest symptom is pain, which is usually intermittent but becomes increasingly intense. Delay in the diagnosis can occur due to the fact that the clinical picture may be similar to that of acute or chronic osteomyelitis. However, eventually most patients have a large, palpable rapidly growing mass, which is tense and tender. Anaemia is associated with a poor prognosis because it implies more extensive disease.

B Age 18 years

Age >12 years is associated with a poor outlook in Ewing's, although here the anaemia is more closely related to a poor prognosis.

C Lack of inflammatory response

Prognosis is not related to the presence or absence of CRP in Ewing's.

D Presence of back pain

Presence of back pain is a common presenting feature of Ewing's, and isn't strongly linked to prognosis.

E Weight loss

Other features apart from anaemia linked to poor prognosis in Ewing's include male sex and elevated lactate dehydrogenase levels.

Rana Alnasser's screen

1:31
On 594-042-7551 Leave

A 46-year-old man presents with a first grand mal seizure while at a Christmas party. On admission, he is post-ictal and drowsy. His girlfriend reports he has been having increasingly severe headaches over the past few weeks.

The following morning, he receives a CT scan with contrast and he is found to have a primary brain tumour with surrounding oedema, which is isodense to surrounding brain tissue. Biopsy reveals highly atypical, poorly differentiated, small, round cells.

Which is the optimal intervention for this patient's likely brain tumour?

A Immunotherapy

B Complete surgical excision

C Surgical debulking

D Boron neutron capture therapy

E Cisplatin

Submit

Previous Q... Skip Questi...

Audio Video Share Participants More

Explanation

C Surgical debulking

This patient has glioblastoma multiforme, characterised by a rapidly growing tumour consisting of poorly differentiated small round cells. Patients commonly present with rapidly increasing headaches or seizures, but may also suffer from focal neurological deficits. Treatment involves surgical debulking (as excision is impossible), radiotherapy and chemotherapy with agents such as temozolamide (an oral alkylating agent).

A Immunotherapy

Immunotherapies including novel vaccine approaches show promise in the treatment of glioblastoma, although currently none are actually approved for treatment of the condition.

B Complete surgical excision

Complete surgical excision is not usually successful for glioblastoma.

D Boron neutron capture therapy

Although boron neutron capture therapy has shown promise in some clinical trials, debulking with adjuvant chemotherapy remains the mainstay of treatment.

E Cisplatin

Temozolamide, not platinum-based therapy, is the main agent used in the treatment of glioblastoma. Median survival for cases of glioblastoma multiforme has barely improved past one year.

1:34
On 594-042-7551 Leave

A 49-year-old man is undergoing chemotherapy for high-grade non-Hodgkin's lymphoma. Two days after starting chemotherapy, the patient reports not feeling well and routine blood tests show that he has rapidly developed hyperuricaemia, hyperkalaemia, hyperphosphataemia, hypocalcaemia and acute kidney disease.

Which of the following statements on treatment are true in relation to this patient's diagnosis?

A	Treat electrolyte abnormalities
B	Urinary acidisation
C	Continue with aggressive chemotherapeutic regimen to ensure the greatest chance of success
D	Use diuretics, such as furosemide or mannitol
E	No dietary modifications are necessary

6675

Submit

Previous Q... Skip Questi...

Audio Video Share Participants More

1:36

MyPastest | Home Feed | Re | Tumor Markers

https://mypastest.pastest.com/Secure/TestMe/Browse

Pastest+ Question 28 of 90

A 49-year-old man is undergoing chemotherapy for high-grade non-Hodgkin's lymphoma. Two days after starting chemotherapy, the patient reports not feeling well and routine blood tests show that he has rapidly developed hyperuricaemia, hyperkalaemia, hyperphosphataemia, hypocalcaemia and acute kidney disease.

Which of the following statements on treatment are true in relation to this patient's diagnosis?

Your answer was correct

A	Treat electrolyte abnormalities
B	Urinary acidisation
C	Continue with aggressive chemotherapeutic regimen to ensure the greatest chance of success
D	Use diuretics, such as furosemide or mannitol
E	No dietary modifications are necessary

Explanation

A Treat electrolyte abnormalities

This patient is exhibiting signs of tumour lysis syndrome (TLS). TLS tends to occur in patients with bulky, rapidly proliferating, treatment-responsive tumours and is classically associated with acute leukaemias and high-

Rana Alnasser's screen

1:36

A Treat electrolyte abnormalities

This patient is exhibiting signs of tumour lysis syndrome (TLS). TLS tends to occur in patients with bulky, rapidly proliferating, treatment-responsive tumours and is classically associated with acute leukaemias and high-grade non-Hodgkin's lymphomas. TLS is characterised by the rapid development of hyperuricaemia, hyperkalaemia, hyperphosphataemia, hypocalcaemia and acute kidney disease, typically 48–72 h after initiation of chemotherapy. LDH levels are checked prior to commencing chemotherapy to identify patients that have a high risk of tumour lysis syndrome, enabling prophylactic measures, such as commencing allopurinol and administration of rasburicase, to prevent development of TLS.

B Urinary acidisation

Urinary alkalinisation (with sodium bicarbonate) prevents renal precipitation of uric acid and allopurinol is given prior to commencing treatment to reduce the conversion of nucleic acid by-products to uric acid, thereby reducing the incidence or degree of TLS.

C Continue with aggressive chemotherapeutic regimen to ensure the greatest chance of success

All chemotherapy should be withheld if the patient develops TLS until the patient has recovered fully. TLS can be a potentially fatal and should be taken seriously if a patient develops it.

D Use diuretics, such as furosemide or mannitol

This in fact opposite of what patients are advised. Osmotic diuretics may actually contributes to the precipitation of uric acid in the renal tubules and is therefore not

Rana Alnasser's screen

A 30-year-old man presents with a 3-month history of diarrhoea.

On examination, he is found to have a blood pressure of 180/100 mmHg. A firm, enlarged thyroid is also noted.

On taking his history, the patient mentions that his father had an operation to remove a gland and had a scar on his neck. His uncle also had the same gland removed due to cancer, and also had kidney failure.

Investigations:

Haemoglobin (Hb)	11 g/dl
White cell count (WCC)	4.0 g/dl
Platelet (PLT)	450×10^9/l
Sodium (Na^+)	135 mmol/l
Potassium (K+)	3.5 mmol/l
Creatinine	80 µmol/l
Urea	5.5 mmol/l
Corrected calcium	2.72 mmol/l

What is a possible unifying diagnosis?

A Carcinoid syndrome

B Multiple endocrine neoplasia (MEN) 1

C MEN 2a

D Phaeochromocytoma

E Vasoactive intestinal peptide (VIP)oma

C MEN 2a

It is important to note that this patient has a thyroid mass, hypertension and hypercalcaemia. MEN 2A is defined by medullary thyroid carcinoma (MTC), which causes diarrhoea; pheochromocytoma, which causes hypertension; and hyperparathyroidism caused by parathyroid gland hyperplasia, which causes hypercalcaemia. MEN 2A is a unifying diagnosis for this patient.

A Carcinoid syndrome

Carcinoid tumours arise from the enterochromaffin cells in the intestine and the main bronchi and do not usually manifest as thyroid masses. These tumours secrete peptides such as 5-hydroxytryptophan. Carcinoid syndrome is a manifestation of advanced disease and is characterised by facial flushing, diarrhoea and wheezing.

B Multiple endocrine neoplasia (MEN) 1

MEN 1 affects the parathyroid glands, the pancreatic islets and the anterior pituitary. Associated tumours include lipomas, angiofibromas or those located in the adrenal gland cortex. This patient has a distinct thyroid mass which is not in keeping with MEN 1.

D Phaeochromocytoma

Phaeochromocytoma is an adrenal tumour known to secrete large amounts of catecholamines. It is associated with a variety of symptoms including headache, palpitations, sweating and anxiety. Hypertension, which may be sustained or paroxysmal, is believed to be the most consistent clinical sign.

E Vasoactive intestinal peptide (VIP)oma

characterised by facial flushing, diarrhoea and wheezing.

B	Multiple endocrine neoplasia (MEN) 1

MEN 1 affects the parathyroid glands, the pancreatic islets and the anterior pituitary. Associated tumours include lipomas, angiofibromas or those located in the adrenal gland cortex. This patient has a distinct thyroid mass which is not in keeping with MEN 1.

D	Phaeochromocytoma

Phaeochromocytoma is an adrenal tumour known to secrete large amounts of catecholamines. It is associated with a variety of symptoms including headache, palpitations, sweating and anxiety. Hypertension, which may be sustained or paroxysmal, is believed to be the most consistent clinical sign.

E	Vasoactive intestinal peptide (VIP)oma

VIPomas in adults are neuroendocrine islet cell tumours of the pancreas that produce high amounts of vasoactive intestinal peptide (VIP). Other secreted hormones may include secreted gastrin and pancreatic polypeptide. Episodic diarrhoea is often the presenting symptom. These presenting symptoms do not fit with this patient's symptoms, making it an unlikely diagnosis.

Rate this question:

Next Question

Previous Q... Tag Questi... Feedback End Session

A 65-year-old man with known adult-onset polycystic kidney disease presents with gradual worsening shortness of breath and lethargy. A chest X-ray is performed that shows multiple coin lesions throughout both lung fields.

Investigations:

Haemoglobin (Hb)	17.3 g/dl
White cell count (WCC)	7.2×10^9/l
Platelet (PLT)	300×10^9/l
Urea	40 mmol/l
Creatinine	390 µmol/l

Which investigation is the most appropriate next step?

A Bronchoscopy

B Mediastinoscopy

C Transthoracic lung biopsy

D CT abdomen and thorax

E Sputum cytology

Submit

of breath and lethargy. A chest X-ray is performed that shows multiple coin lesions throughout both lung fields.

Investigations:

Haemoglobin (Hb)	17.3 g/dl
White cell count (WCC)	7.2×10^9/l
Platelet (PLT)	300×10^9/l
Urea	40 mmol/l
Creatinine	390 µmol/l

Which investigation is the most appropriate next step?

Your answer was correct

A Bronchoscopy

B Mediastinoscopy

C Transthoracic lung biopsy

D CT abdomen and thorax

E Sputum cytology

Explanation

D CT abdomen and thorax

This is a case of a renal cell carcinoma with lung metastases, a very rare but recognised complication of adult-onset polycystic kidney disease (APCKD). The patient has inappropriately high haemoglobin in relation to the

D CT abdomen and thorax

This is a case of a renal cell carcinoma with lung metastases, a very rare but recognised complication of adult-onset polycystic kidney disease (APCKD). The patient has inappropriately high haemoglobin in relation to the renal impairment. This may be because of ectopic erythropoietin production, which is a paraneoplastic feature of hypernephroma. In addition there may be some haemoconcentration due to dehydration, perhaps from an associated hypercalcaemia. A computed tomography (CT) scan will localise a solid renal mass and a bone scan will allow further staging of the disease. It will also provide further information on any accessible lesion to biopsy. A protocol involving lower doses of contrast will be considered because of the risk of contrast nephropathy given the raised creatinine.

A Bronchoscopy

Although a transthoracic lung biopsy may provide tissue, risks include creating an air leak and haemorrhage from the biopsy site. As such, potentially obtaining tissue from the abdomen or making a diagnosis based on radiological appearance is preferred.

B Mediastinoscopy

For similar reasons given for avoiding bronchoscopy, other methods to obtain imaging and tissue are preferred.

C Transthoracic lung biopsy

A transthoracic lung biopsy can obtain a biopsy from peripheral tissue, but carries risks similar to a transbronchial biopsy (ie bleeding and potentially creating an air leak).

feature of hypernephroma. In addition there may be some haemoconcentration due to dehydration, perhaps from an associated hypercalcaemia. A computed tomography (CT) scan will localise a solid renal mass and a bone scan will allow further staging of the disease. It will also provide further information on any accessible lesion to biopsy. A protocol involving lower doses of contrast will be considered because of the risk of contrast nephropathy given the raised creatinine.

A Bronchoscopy

Although a transthoracic lung biopsy may provide tissue, risks include creating an air leak and haemorrhage from the biopsy site. As such, potentially obtaining tissue from the abdomen or making a diagnosis based on radiological appearance is preferred.

B Mediastinoscopy

For similar reasons given for avoiding bronchoscopy, other methods to obtain imaging and tissue are preferred.

C Transthoracic lung biopsy

A transthoracic lung biopsy can obtain a biopsy from peripheral tissue, but carries risks similar to a transbronchial biopsy (ie bleeding and potentially creating an air leak).

E Sputum cytology

The potential yield from sputum cytology is very low, and will not provide information on tumour architecture.

Rate this question:

1:40

MyPastest | Home Feed | Re | Tumor Markers

https://mypastest.pastest.com/Secure/TestMe/Browse

A 55-year-old woman with recurrent breast cancer presents with confusion, abdominal pain and constipation. A recent bone scan did not reveal any 'hot spots'.

Investigations:

Sodium (Na^+)	135 mmol/l
Potassium (K^+)	3.4 mmol/l
Creatinine	120 µmol/l
Urea	10.0 mmol/l
Corrected Calcium (Ca^{++})	3.5 mmol/l

What is the most likely cause of her presentation?

A	Tumour production of 1,25-dihydroxy vitamin D
B	Widespread bony metastatic disease
C	Tumour production of parathyroid hormone-related protein (PTH-RP)
D	Tumour production of parathyroid hormone
E	Defect in calcium-sensing receptor

7529

Rana Alnasser's screen

In solid tumours, hypercalcaemia is often caused by PTH-RP, which is produced by the tumour. This acts on ostoeclasts in bone to increase bone resorption and promote calcium release from the bone. It also inhibits calcium excretion in the distal tubule of the kidney.

A Tumour production of 1,25-dihydroxy vitamin D

Tumour production of 1,25-dihydroxy vitamin D has been shown to cause malignant hypercalcaemia in malignancies such as lymphoma. However, in breast cancer, there have been preliminary studies actually showing an 'anti-cancer effect' of administering active vitamin D.

B Widespread bony metastatic disease

Hypercalcaemia of malignancy is not thought to be a product of widespread bony metastases and bone destruction. Instead it is felt to be secondary to tumour production of parathyroid hormone-related protein.

D Tumour production of parathyroid hormone

Hypercalcaemia in patients with malignancies is often caused by PTH-RP which is produced by the tumour. In these cases, the parathyroid hormone level is normal and is not produced by the tumour.

E Defect in calcium-sensing receptor

The calcium-sensing receptor (CaSR) is a G protein-coupled receptor that allows the parathyroid chief cells, the thyroidal C cells, and the ascending limb of the loop of Henlé (renal tubular epithelial cells) to respond to changes in the extracellular calcium concentration. There are three uncommon human disorders due to abnormalities of the

Rana Alnasser's screen

effect' of administering active vitamin D.

B Widespread bony metastatic disease

Hypercalcaemia of malignancy is not thought to be a product of widespread bony metastases and bone destruction. Instead it is felt to be secondary to tumour production of parathyroid hormone-related protein.

D Tumour production of parathyroid hormone

Hypercalcaemia in patients with malignancies is often caused by PTH-RP which is produced by the tumour. In these cases, the parathyroid hormone level is normal and is not produced by the tumour.

E Defect in calcium-sensing receptor

The calcium-sensing receptor (CaSR) is a G protein-coupled receptor that allows the parathyroid chief cells, the thyroidal C cells, and the ascending limb of the loop of Henlé (renal tubular epithelial cells) to respond to changes in the extracellular calcium concentration. There are three uncommon human disorders due to abnormalities of the CaSR gene: (1) familial benign hypocalciuric hypercalcemia, (2) neonatal severe hyperparathyroidism, and (3) autosomal dominant hypocalcaemia with hypercalciuria. None of these are related to a patient having a malignancy.

Rate this question:

Next Question

Previous Q... Tag Questi... Feedback End Session

1:46
https://en.m.wikipedia.org/wi
19
WIKIPEDIA

Pseudohypoparathyroidism

Pseudohypoparathyroidism is a condition associated primarily with resistance to the parathyroid hormone.[1] Those with the condition have a low serum calcium and high phosphate, but the parathyroid hormone level (PTH) is appropriately high (due to the low level of calcium in the blood). Its pathogenesis has been linked to dysfunctional G Proteins (in particular, Gs alpha subunit). The condition is extremely rare, with an estimated overall prevalence of 7.2/1,000,000 or approximately 1/140,000.

Pseudohypoparathyroidism	
Specialty	Endocrinology

1:46
On
594-042-7551
Leave
MyPastest
Home Feed | Re
Tumor Markers
https://mypastest.pastest.com/Secure/TestMe/Brow

Pastest+

Question 32 of 90

A 70-year-old Asian man who has recently come to the UK complains of weight loss, anorexia, a vague ache in the right upper abdomen and swelling of the abdomen over the past two months. He is a non-smoker and teetotaller.

On examination, an enlarged, tender, irregular liver is palpable. Ascites can be demonstrated. His viral screen is negative and he has elevated liver function tests.

What is the most likely diagnosis in this case?

A	Hydatid disease
B	Amoebic liver abscess
C	Chronic active hepatitis
D	Cirrhosis
E	Hepatocellular carcinoma

7298

Submit

Previous Q...

Skip Questi...

Audio
Video
Share
Participants
More

1:48
MyPastest
Home Feed | Re
Tumor Markers
https://mypastest.pastest.com/Secure/TestMe/Brow

Pastest+

Question 32 of 90

A 70-year-old Asian man who has recently come to the UK complains of weight loss, anorexia, a vague ache in the right upper abdomen and swelling of the abdomen over the past two months. He is a non-smoker and teetotaller.

On examination, an enlarged, tender, irregular liver is palpable. Ascites can be demonstrated. His viral screen is negative and he has elevated liver function tests.

What is the most likely diagnosis in this case?

Your answer was correct

A	Hydatid disease
B	Amoebic liver abscess
C	Chronic active hepatitis
D	Cirrhosis
E	Hepatocellular carcinoma

Explanation

E	Hepatocellular carcinoma

The rapid development of weight loss, anorexia and ascites is more suggestive of hepatocellular carcinoma than cirrhosis [illegible]nic active hepatitis.

Annotation
Stop Share

E Hepatocellular carcinoma

The rapid development of weight loss, anorexia and ascites is more suggestive of hepatocellular carcinoma than cirrhosis or chronic active hepatitis.

A Hydatid disease

Hydatid disease is caused by *Echinococcus granulosus* and is usually asymptomatic, except for a dull ache and swelling in the right hypochondrium. This patient's symptoms do not fit with the presenting symptoms for hydatid disease.

B Amoebic liver abscess

Amoebic liver abscesses can present with weight loss, anorexia and abdominal pain. However, it is unusual for patients to present with ascites – ie amoebic liver abscess is not the most likely disease in this case.

C Chronic active hepatitis

Although this patient's symptoms can be explained by chronic active hepatitis, it is not the most likely option proposed with the question.

D Cirrhosis

This patient's symptoms can be explained by cirrhosis. However, the patient would often have a history of a chronic hepatitis infection, alcohol abuse or non-alcoholic fatty liver disease, which this gentleman does not appear to have.

Annotation Stop Share

Rate this question:

A 75-year-old gentleman presents with weight loss and polyuria. He has had some vague lower abdominal and upper back pain for several months. He has smoked 10 cigarettes per day all his life and drinks occasionally. He has taken tamsulosin 0.4 mg for the last few years for obstructive urinary symptoms.

On examination, he is pale and thin. There are fine crackles at both lung bases. There is no hepatosplenomegaly or lymph node enlargement.

Investigations:

Haemoglobin (Hb)	11.0 g/dl
White cell count (WCC)	3.5×10^9/l
Platelet (PLT)	100×10^9/l
Sodium (Na^+)	138 mmol/l
Potassium (K^+)	3.6 mmol/l
Creatinine	140 µmol/l
Erythrocyte sedimentation rate (ESR)	60 mm/1st h
Urea	10.0 mmol/l
Corrected Calcium (Ca^{2+})	3.2 mmol/l
Phosphate	1.3 mmol/l (0.75–1.5 mmol/l)
Alkaline phosphatase (ALP)	205 U/l
Albumin	35 g/l
Total protein (TP)	60 g/l (65–75 g/l)
Blood film	Occasional nucleated red

Rana Alnasser's screen

Potassium (K^+)	3.6 mmol/l
Creatinine	140 µmol/l
Erythrocyte sedimentation rate (ESR)	60 mm/1st h
Urea	10.0 mmol/l
Corrected Calcium (Ca^{2+})	3.2 mmol/l
Phosphate	1.3 mmol/l (0.75–1.5 mmol/l)
Alkaline phosphatase (ALP)	205 U/l
Albumin	35 g/l
Total protein (TP)	60 g/l (65–75 g/l)
Blood film	Occasional nucleated red blood cells and myelocytes

What best describes the features suggested on the blood film?

A Rouleaux formation

B Leuco-erythroblastic anaemia

C Sideroblastic anaemia

D Smudge cells

E Right shift

Alkaline phosphatase (ALP)	205 U/l
Albumin	35 g/l
Total protein (TP)	60 g/l (65–75 g/l)
Blood film	Occasional nucleated red blood cells and myelocytes

What best describes the features suggested on the blood film?

Your answer was correct

A Rouleaux formation

B Leuco-erythroblastic anaemia

C Sideroblastic anaemia

D Smudge cells

E Right shift

Explanation

B Leuco-erythroblastic anaemia

The blood film is suggestive of leuco-erythroblastic anaemia. This is defined when there are immature cells (e.g. myelocytes and nucleated red blood cells) seen on the peripheral blood film.
Causes include:

- myelofibrosis

B Leuco-erythroblastic anaemia

The blood film is suggestive of leuco-erythroblastic anaemia. This is defined when there are immature cells (e.g. myelocytes and nucleated red blood cells) seen on the peripheral blood film.
Causes include:

- myelofibrosis
- malignant marrow infiltration
- chronic myeloid leukaemia
- myeloma
- polycythaemia rubra vera
- osteopetrosis
- tuberculous infiltration of the bone marrow
- sarcoidosis.

The blood results also demonstrate a significantly raised calcium level. Cancer-induced hypercalcaemia, associated with bone metastases, arises as a consequence of increased bone resorption with calcium mobilisation into the extracellular fluid. There is an associated rise in ALP and reduction in the levels of parathyroid hormone (PTH). The blood picture seen therefore fits with disseminated carcinoma.

A Rouleaux formation

Rouleaux is seen when red cells aggregate due to increased plasma proteins and elevated ESR. This is seen in haematological malignancies such as myeloma.

C Sideroblastic anaemia

Sideroblasts are erythroblasts with atypical nuclei, which

the extracellular fluid. There is an associated rise in ALP and reduction in the levels of parathyroid hormone (PTH). The blood picture seen therefore fits with disseminated carcinoma.

A Rouleaux formation

Rouleaux is seen when red cells aggregate due to increased plasma proteins and elevated ESR. This is seen in haematological malignancies such as myeloma.

C Sideroblastic anaemia

Sideroblasts are erythroblasts with atypical nuclei, which occur because of defective iron incorporation into cells. This may be congenital or is seen in myelodysplastic syndromes.

D Smudge cells

Smudge cells are remnants of white cells that lack any identifiable cytoplasmic membrane or nuclear structure. Smudge cells, also known as basket cells, are most often associated with abnormally fragile lymphocytes in disorders such as chronic lymphocytic leukaemia (CLL).

E Right shift

A right shift is characterised by a lack of immature neutrophils and is associated with suppression of bone marrow activity: it is in effect the opposite of what is seen here.

Rate this question:

Next Question

A 52-year-old man with known bronchial carcinoma and a solitary brain metastasis presents 11 days after cranial radiotherapy with excessive drowsiness, clumsiness, mental slowness and lethargy.

On examination, he looks thin and tired. His blood pressure (BP) is 142/71 mmHg and there is no papilloedema. No focal neurology is identified.

Which of the following is the most likely cause?

A	Worsening anaemia
B	Further cerebral metastases
C	Post-cranial irradiation somnolence syndrome
D	Cerebral oedema
E	Post-irradiation hypercalcaemia

Submit

Previous Q... Skip Questi...

© Pastest 2019

A 52-year-old man with known bronchial carcinoma and a solitary brain metastasis presents 11 days after cranial radiotherapy with excessive drowsiness, clumsiness, mental slowness and lethargy.

On examination, he looks thin and tired. His blood pressure (BP) is 142/71 mmHg and there is no papilloedema. No focal neurology is identified.

Which of the following is the most likely cause?

Your answer was correct

A Worsening anaemia

B Further cerebral metastases

C Post-cranial irradiation somnolence syndrome

D Cerebral oedema

E Post-irradiation hypercalcaemia

Explanation

C Post-cranial irradiation somnolence syndrome

Post-cranial irradiation somnolence syndrome is characterised by excessive somnolence, lethargy and clumsiness and tends to occur around 11–21 or 31–35 days after high-dose cranial radiotherapy. No focal cause is identified and it is postulated that the condition may occur due to post-irradiation demyelination. No specific therapy

C Post-cranial irradiation somnolence syndrome

Post-cranial irradiation somnolence syndrome is characterised by excessive somnolence, lethargy and clumsiness and tends to occur around 11–21 or 31–35 days after high-dose cranial radiotherapy. No focal cause is identified and it is postulated that the condition may occur due to post-irradiation demyelination. No specific therapy is required, but some case reports suggest that corticosteroids may be of use although the evidence is not firmly established.

A Worsening anaemia

The symptoms of drowsiness, clumsiness and mental slowness are not typically associated with anaemia. Cranial radiotherapy does not usually cause anaemia either.

B Further cerebral metastases

The clinical vignette reports no papilloedema or focal neurology, which would be expected in further cerebral metastases.

D Cerebral oedema

The history does not report papilloedema or focal neurological signs, which would be consistent with cerebral oedema.

E Post-irradiation hypercalcaemia

Radiotherapy does not cause hypercalcaemia.

1:55
On
594-042-7551
Leave

A 56-year-old man with known Hodgkin's lymphoma is admitted to the ward with a 2-week history of increasing chest pain and a 2-day history of a swollen plethoric face, prominent neck veins and swelling of his right arm. He was diagnosed two years ago and unsuccessfully treated with ABVD chemotherapy; he received a stem cell transplant four months ago.

A superior vena cava obstruction (SVCO) has now been diagnosed, and a CT of his neck and thorax has demonstrated a large tumour encapsulating his superior vena cava that is beginning to invade his myocardium.

What is the best immediate management for this man?

A	Stenting of superior vena cava (SVC)
B	Radiotherapy
C	Emergency debulking surgery
D	Intravenous dexamethasone and LMWH
E	Diamorphine infusion

Submit

Audio
Video
Share
Participants
More

1:56
On
594-042-7551
Leave

A 56-year-old man with known Hodgkin's lymphoma is admitted to the ward with a 2-week history of increasing chest pain and a 2-day history of a swollen plethoric face, prominent neck veins and swelling of his right arm. He was diagnosed two years ago and unsuccessfully treated with ABVD chemotherapy; he received a stem cell transplant four months ago.

A superior vena cava obstruction (SVCO) has now been diagnosed, and a CT of his neck and thorax has demonstrated a large tumour encapsulating his superior vena cava that is beginning to invade his myocardium.

What is the best immediate management for this man?

Your answer was incorrect

A Stenting of superior vena cava (SVC)

B Radiotherapy

C Emergency debulking surgery

D Intravenous dexamethasone and LMWH

E Diamorphine infusion

Explanation

D Intravenous dexamethasone and LMWH

This combination will give some initial immediate relief and then you can decide whether radiotherapy, SVC stenting or

Audio Video Share Participants More

1:57
On
594-042-7551
Leave

D Intravenous dexamethasone and LMWH

This combination will give some initial immediate relief and then you can decide whether radiotherapy, SVC stenting or even surgery may be appropriate. Whilst these discussions are taking place, the dexamethasone and LMWH can be alleviating symptoms.

A Stenting of superior vena cava (SVC)

SVCO is caused by external pressure of a tumour, usually a lung primary, on the SVC. SVC stenting is an effective procedure performed by the interventional radiology team to try and reopen the vessel. It is a valid treatment option for the patient in due course. However, it is key to read the question carefully. The question asks for the best immediate management for the patient and SVC stenting, although a possible subsequent treatment, is not the best immediate management.

B Radiotherapy

Radiotherapy is likely to be one of the treatment modalities used to try and help treat the patient. However, the question asks for the best immediate management. Radiotherapy will take days if not weeks to take effect and there are other treatments that can alleviate symptoms in the meantime, meaning this cannot be the best immediate management.

C Emergency debulking surgery

This is a highly risky procedure for any patient to undergo and requires assessment from the surgical teams. Due to the high mortality and morbidity risks, this is unlikely to be a treatment option for this cohort of patients although

Audio Video Share Participants More

SVCO is caused by external pressure of a tumour, usually a lung primary, on the SVC. SVC stenting is an effective procedure performed by the interventional radiology team to try and reopen the vessel. It is a valid treatment option for the patient in due course. However, it is key to read the question carefully. The question asks for the best immediate management for the patient and SVC stenting, although a possible subsequent treatment, is not the best immediate management.

B	Radiotherapy

Radiotherapy is likely to be one of the treatment modalities used to try and help treat the patient. However, the question asks for the best immediate management. Radiotherapy will take days if not weeks to take effect and there are other treatments that can alleviate symptoms in the meantime, meaning this cannot be the best immediate management.

C	Emergency debulking surgery

This is a highly risky procedure for any patient to undergo and requires assessment from the surgical teams. Due to the high mortality and morbidity risks, this is unlikely to be a treatment option for this cohort of patients although each case should be examined on an individual basis.

E	Diamorphine infusion

This might have been suggested to try and alleviate breathing or in an aim to palliate the patient. SVCO infers a poor prognosis for the patient, but usually in the region of months rather than hours to days and, as such, palliation with diamorphine is inappropriate.

2307

Rate this question:

1:58

A 50-year-old man presents with a 2-week history of shortness of breath and haemoptysis. He has smoked 20 cigarettes a day for many years.

On examination, there is no clubbing and no lymphadenopathy.

The chest X-ray is shown below.

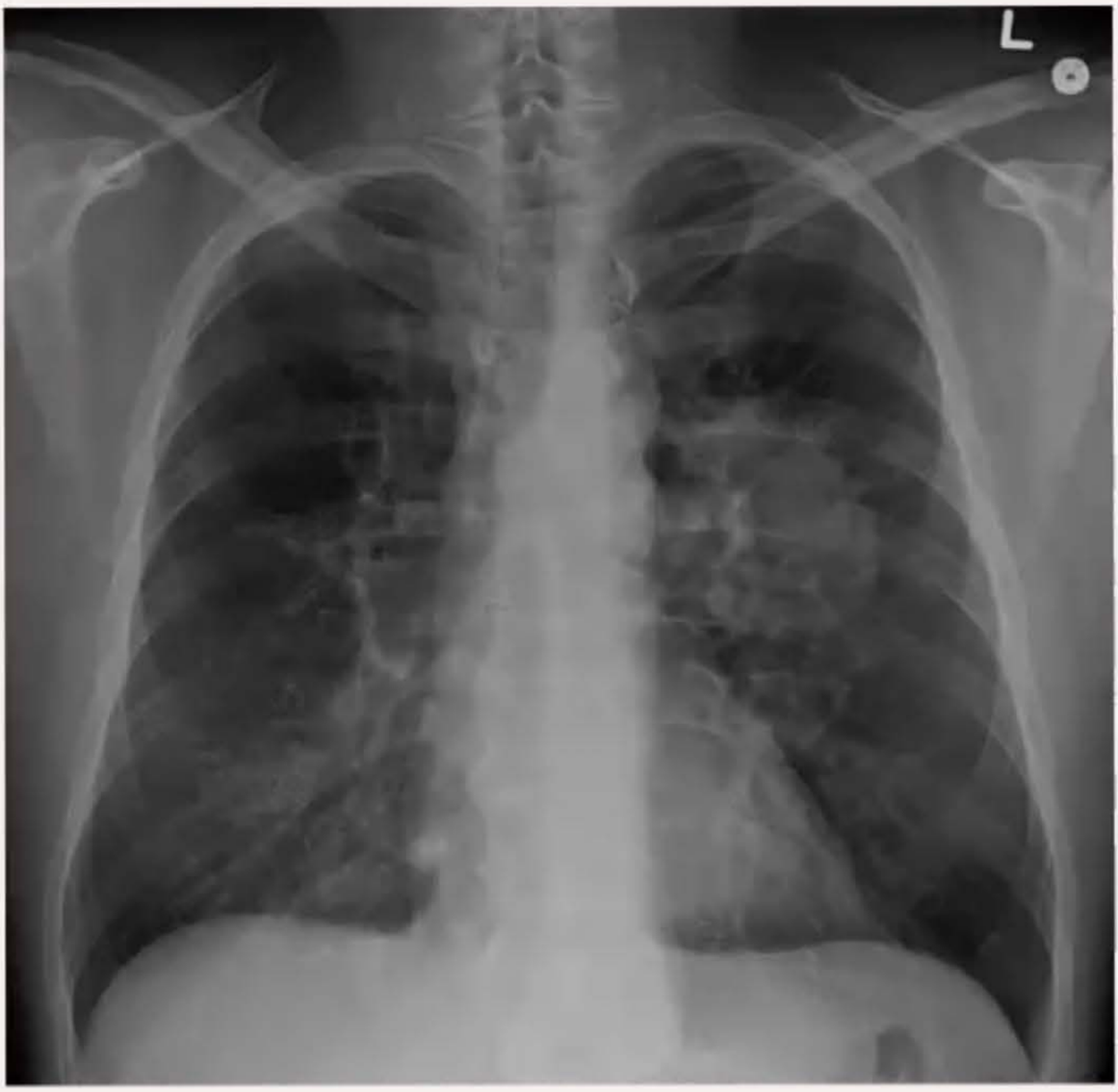

By James Heilman, MD [CC BY-SA 4.0 (https://creativecommons.org/licenses/by-sa/4.0)], via Wikimedia Commons

Investigations:

Sodium (Na^+)	140 mmol/l
Potassium (K^+)	4.6 mmol/l
Urea	5.0 mmol/l

Rana Alnasser's screen

1:58
On
594-042-7551
Leave

Sodium (Na^+)	140 mmol/l
Potassium (K^+)	4.6 mmol/l
Urea	5.0 mmol/l
Creatinine	100 µmol/l
Corrected calcium	2.74 mmol/l
Haemoglobin (Hb)	12 g/dl
White cell count (WCC)	7×10^9/l
Platelet (PLT)	400×10^9/l
Tumour markers	Normal

A computed tomography (CT) scan shows no evidence of metastases.

What is the most likely histological diagnosis?

A Small cell carcinoma

B Squamous cell carcinoma (SCC)

C Adenocarcinoma

D Carcinoid

E Large cell carcinoma

Submit

Audio Video Share Participants More

B Squamous cell carcinoma (SCC)

A known phenomenon seen in patients with SCC is the production of parathyroid hormone-related protein, which leads to hypercalcaemia, as seen here. The X-ray findings of a large mass on the left lung is consistent with SCC, which tend to be more centrally placed. Although not demonstrated on this X-ray, large SCC tumours may undergo central necrosis, leading to cavitation. In addition, SCCs are more common in male smokers than adenocarcinomas, which are more prevalent with female smokers.

A Small cell carcinoma

Small cell lung cancers account for < 15% of all cases of lung cancer and have often metastasised at the time of presentation. The fact that this patient has hypercalcaemia with no evidence of metastases makes the diagnosis of non-small cell carcinoma more likely.

C Adenocarcinoma

Adenocarcinomas tend to be peripheral tumours. However, in this case, the patient was also noted as having hypercalcaemia, and this is not usually seen in patients with adenocarcinoma. It would be more common to see metastases to the pleurae and mediastinal lymph nodes. It should, however, be noted that adenocarcinomas are the most common type of lung tumour.

D Carcinoid

Carcinoid tumours are associated with early haemoptysis, and flushing can be seen in metastatic disease. These tumours can be found centrally or peripherally (mo common). A carcinoid tumour is a possibility, although less

Rana Alnasser's screen

1:59

A 50-year-old man presents with a 2-month history of shortness of breath, haemoptysis and a 5 cm lesion on chest X-ray. A computed tomography (CT) scan shows mediastinal lymphadenopathy.

On examination, he is noted to have facial plethora and enlarged neck veins. A diagnosis of superior vena cava obstruction (SVCO) is made.

What is the most appropriate definitive therapy?

A	Radiotherapy
B	Chemotherapy
C	Superior vena cava (SVC) stent insertion
D	Dexamethasone
E	Fluids

Submit

Rana Alnasser's screen

C Superior vena cava (SVC) stent insertion

SVC stenting can be a very successful treatment and is usually performed by the interventional radiology teams. Given its early positive effects on symptom relief and the fact it does not affect underlying tissue with respect to biopsy / gaining a diagnosis, it is the initial intervention of choice.

A Radiotherapy

Radiotherapy is an important treatment to consider in a patient with SVCO; however, it would not be the first-line treatment as it can take days to weeks to take effect. It is usually more effective in SVCO caused by haematological malignancies compared to lung cancers. Also, if SVC stenting is being considered, it is important to perform the stent insertion prior to radiotherapy as the latter can cause fibrosis which can make subsequent stent insertion difficult.

B Chemotherapy

Chemotherapy is a systemic treatment that can take weeks to months to take effect, and the extent of effectiveness depends on the cell type. Therefore, it is not the most appropriate first-line treatment but should be considered in each case of SVCO as a possible treatment option.

D Dexamethasone

High-dose dexamethasone (either 16 mg OD or 8 mg BD) with PPI can be administered to help alleviate symptoms such as swelling when there is SVC obstruction. Its on limiting / relieving symptoms, however, are limite comparison to SVC stenting.

2:03
MyPastest
Home Feed | Re
Tumor Markers
https://mypastest.pastest.com/Secure/TestMe/Brow

B Chemotherapy

Chemotherapy is a systemic treatment that can take weeks to months to take effect, and the extent of effectiveness depends on the cell type. Therefore, it is not the most appropriate first-line treatment but should be considered in each case of SVCO as a possible treatment option.

D Dexamethasone

High-dose dexamethasone (either 16 mg OD or 8 mg BD) with PPI can be administered to help alleviate symptoms such as swelling when there is SVC obstruction. Its effects on limiting / relieving symptoms, however, are limited in comparison to SVC stenting.

E Fluids

There is very little evidence for the benefit of fluids in a patient with SVCO. They may be considered if a patient is struggling with oral intake due to their SVCO, but the fluids themselves will not help treat the SVCO.

SVCO is extrinsic compression of the SVC by tumour. Potential causes of SVCO include the following.

- Primary bronchial carcinoma
- Lymphadenopathy due to lymphoma
- Constrictive pericarditis
- Chronic fibrotic mediastinitis
- Clot associated with indwelling catheter or pacemaker wires

Rana Alnasser's screen

2:03
MyPastest
Home Feed | Re
Tumor Markers
https://mypastest.pastest.com/Secure/TestMe/Brow

- Lymphadenopathy due to lymphoma
- Constrictive pericarditis
- Chronic fibrotic mediastinitis
- Clot associated with indwelling catheter or pacemaker wires
- Thymoma
- Localised infection
- Thyroid cancer
- Synovial cell carcinoma
- Teratoma
- Retro-sternal goitre
- Mediastinal fibrosis
- Thoracic aortic aneurysm
- Aortic aneurysm
- Angiosarcoma.

Rate this question:

Next Question

Previous Q... Tag Questi... Feedback End Session

Blog About Pastest Contact Us Help

© Pastest 2019

2:03
MyPastest
Home Feed | Re
Tumor Markers
https://mypastest.pastest.com/Secure/TestMe/Brow

A 65-year-old man is urgently referred by his general practitioner (GP) to the local Gastroenterology Department with a history of dysphagia, postprandial fullness, loss of appetite and weight loss. He reports that he has been fit and well until a few months ago when his symptoms started and he is not taking any medication. He is a non-smoker.

On examination, he is noted to have lost weight and is anaemic. Other positive findings include an enlarged palpable stomach with a succussion splash, an enlarged liver and an enlarged left supraclavicular node.

Which of the following investigations is likely to be most useful in this patient?

A	Human leukocyte antigen (HLA) typing
B	Lactate dehydrogenase (LDH) levels
C	*H. pylori* breath test
D	Plain abdominal X-ray
E	Oesophago-gastroduodenoscopy (OGD)

Submit

2:07
MyPastest
Home Feed | Re
Tumor Markers
https://mypastest.pastest.com/Secure/TestMe/Brow

E Oesophago-gastroduodenoscopy (OGD)

Gastric cancer is the second leading cause of cancer-related deaths in the world owing to the fact that patients often present in an advanced stage of the disease. Even those patients who present early and undergo curative surgical resection often die of disease recurrence. It is slightly more prevalent in men than in women and most patients tend to be elderly, with the median age at diagnosis being 65 years. Early disease tends to have no associated symptoms, with the development of physical signs being a late manifestation of the disease. The aim of investigations is to plan the most suitable treatment regimen for the patient. Laboratory investigations are essential to determine the patient's physical and nutritional status and their suitability for surgery, although are non-specific with respect to the underlying diagnosis. Amongst imaging studies, an OGD is clearly the most useful, as the primary method for obtaining a tissue diagnosis and a permanent photographic record of the lesion, and a computed tomography (CT) or MRI of the chest, abdomen and pelvis is also of value to assess the extent of spread of the disease.

A Human leukocyte antigen (HLA) typing

The enlarged left supra-clavicular node is consistent with a gastric malignancy. HLA typing is not of value in assessing for the presence of a tumour.

B Lactate dehydrogenase (LDH) levels

LDH levels correlate with solid tumour burden, but they are

and pelvis is also of value to assess the extent of spread of the disease.

A Human leukocyte antigen (HLA) typing

The enlarged left supra-clavicular node is consistent with a gastric malignancy. HLA typing is not of value in assessing for the presence of a tumour.

B Lactate dehydrogenase (LDH) levels

LDH levels correlate with solid tumour burden, but they are not useful in determining the underlying tumour type.

C *H. pylori* breath test

Although *H. pylori* is a risk factor for development of gastric malignancy, in this situation it provides no further useful information.

D Plain abdominal X-ray

Plain abdominal films are insensitive with respect to detecting underlying GI malignancy.

Rate this question:

Next Question

Previous Q... Tag Questi... Feedback End Session

Blog About Pastest Contact Us Help

2:08

A 26-year-old woman presents to the clinic with increasing shortness of breath and a dry, non-productive cough. She had undergone chemotherapy some nine months earlier for Hodgkin's lymphoma. Over the past few months, she has suffered increasing shortness of breath.

On examination, she has inspiratory crackles throughout both lung fields. Her blood pressure (BP) is normal at 142/78 mmHg, her pulse 88/min and there is no ankle swelling. Her O_2 saturation is 94% at rest on air. The remainder of her clinical examination is unremarkable.

Investigations:

Haemoglobin (Hb)	12.4 g/dl
White cell count (WCC)	5.9×10^9/l
Platelet (PLT)	193×10^9/l
Sodium (Na^+)	139 mmol/l
Potassium (K^+)	4.6 mmol/l
Creatinine	120 µmol/l
Chest X-ray	Fine interstitial shadowing throughout both lung fields, more marked in the lower zones

Which of the following is the most likely diagnosis?

A Bleomycin toxicity

B Cisplatin toxicity

C Lymphangitis carcinomatosa

Rana Alnasser's screen

suffered increasing shortness of breath.

On examination, she has inspiratory crackles throughout both lung fields. Her blood pressure (BP) is normal at 142/78 mmHg, her pulse 88/min and there is no ankle swelling. Her O_2 saturation is 94% at rest on air. The remainder of her clinical examination is unremarkable.

Investigations:

Haemoglobin (Hb)	12.4 g/dl
White cell count (WCC)	5.9×10^9/l
Platelet (PLT)	193×10^9/l
Sodium (Na^+)	139 mmol/l
Potassium (K^+)	4.6 mmol/l
Creatinine	120 µmol/l
Chest X-ray	Fine interstitial shadowing throughout both lung fields, more marked in the lower zones

Which of the following is the most likely diagnosis?

A Bleomycin toxicity

B Cisplatin toxicity

C Lymphangitis carcinomatosa

D Pulmonary metastases

E Lapatinib toxicity

Rana Alnasser's screen

2:09
On
594-042-7551
Leave

A 26-year-old woman presents to the clinic with increasing shortness of breath and a dry, non-productive cough. She had undergone chemotherapy some nine months earlier for Hodgkin's lymphoma. Over the past few months, she has suffered increasing shortness of breath.

On examination, she has inspiratory crackles throughout both lung fields. Her blood pressure (BP) is normal at 142/78 mmHg, her pulse 88/min and there is no ankle swelling. Her O_2 saturation is 94% at rest on air. The remainder of her clinical examination is unremarkable.

Investigations:

Haemoglobin (Hb)	12.4 g/dl
White cell count (WCC)	5.9×10^9/l
Platelet (PLT)	193×10^9/l
Sodium (Na^+)	139 mmol/l
Potassium (K^+)	4.6 mmol/l
Creatinine	120 µmol/l
Chest X-ray	Fine interstitial shadowing throughout both lung fields, more marked in the lower zones

Which of the following is the most likely diagnosis?

Your answer was correct

A Bleomycin toxicity

B Cisplatin toxicity

Audio Video Share Participants More

2:10
On 594-042-7551 Leave
MyPastest Home Feed | Re Tumor Markers
https://mypastest.pastest.com/Secure/TestMe/Brow

A Bleomycin toxicity

Bleomycin is used in chemotherapy regimens for haematological malignancies, and is associated with pulmonary fibrosis. In clinical trials, interstitial pneumonia /pulmonary fibrosis was said to occur in around 10% of patients. The mechanism of bleomycin toxicity is not known – it may be due to oxidative stress and up-regulation of inflammatory cytokines. Case series suggest there may be a response to glucocorticoids, although no randomised controlled trials have been conducted.

B Cisplatin toxicity

Cisplatin is association with neuro- and nephrotoxicity, including the development of acute kidney injury, hypomagnesaemia and distal renal tubular acidosis.

C Lymphangitis carcinomatosa

Lymphangitis carcinomatosa would be unusual as a manifestation of recurrent Hodgkin's, especially as the time period since chemotherapy is so short and there are no manifestations of disease outside the lungs.

D Pulmonary metastases

Pulmonary metastases are associated with discrete rather than the interstitial shadowing seen here.

E Lapatinib toxicity

Lapatinib is associated with a reversible decrease in left

Audio Video Share Participants More

haematological malignancies, and is associated with pulmonary fibrosis. In clinical trials, interstitial pneumonia /pulmonary fibrosis was said to occur in around 10% of patients. The mechanism of bleomycin toxicity is not known – it may be due to oxidative stress and up-regulation of inflammatory cytokines. Case series suggest there may be a response to glucocorticoids, although no randomised controlled trials have been conducted.

B Cisplatin toxicity

Cisplatin is association with neuro- and nephrotoxicity, including the development of acute kidney injury, hypomagnesaemia and distal renal tubular acidosis.

C Lymphangitis carcinomatosa

Lymphangitis carcinomatosa would be unusual as a manifestation of recurrent Hodgkin's, especially as the time period since chemotherapy is so short and there are no manifestations of disease outside the lungs.

D Pulmonary metastases

Pulmonary metastases are associated with discrete masses rather than the interstitial shadowing seen here.

E Lapatinib toxicity

Lapatanib is associated with a reversible decrease in left ventricular ejection fraction rather than the pulmonary symptoms and signs seen here.

Rate this question:

Rana Alnasser's screen

A 62-year-old man presents with increasing shortness of breath over the past few months, weight loss and anorexia. He also has thoracic back pain. He has no other past medical history of note and used to work as a shipbuilder.

On examination, he looks thin, his body mass index (BMI) is 18. He has supraclavicular and inguinal lymphadenopathy. The left side of his chest is dull to percussion.

Investigations:

Haemoglobin (Hb)	10.4 g/dl
White cell count (WCC)	10.2×10^9/l
Platelet (PLT)	192×10^9/l
Sodium (Na^+)	139 mmol/l
Potassium (K^+)	4.3 mmol/l
Creatinine	140 µmol/l
Calcium (Ca^{2+})	2.71 mmol/l
Alanine transaminase (ALT)	185 U/l
Albumin	35 g/l
Chest X-ray	Left-sided pleural effusion
Pleural effusion	Undifferentiated adenocarcinoma cells
Thoracic spine X-ray	T7 wedge fracture

Which of the following is the most appropriate way to make the diagnosis with respect to his bony lesion?

A MRI spine

Rana Alnasser's screen

investigations:

Haemoglobin (Hb)	10.4 g/dl
White cell count (WCC)	10.2×10^9/l
Platelet (PLT)	192×10^9/l
Sodium (Na^+)	139 mmol/l
Potassium (K^+)	4.3 mmol/l
Creatinine	140 µmol/l
Calcium (Ca^{2+})	2.71 mmol/l
Alanine transaminase (ALT)	185 U/l
Albumin	35 g/l
Chest X-ray	Left-sided pleural effusion
Pleural effusion	Undifferentiated adenocarcinoma cells
Thoracic spine X-ray	T7 wedge fracture

Which of the following is the most appropriate way to make the diagnosis with respect to his bony lesion?

A MRI spine

B Bone biopsy

C Bone densitometry

D Tumour markers

E Parathyroid hormone assay

B Bone biopsy

A bone biopsy will deliver further histology on the underlying adenocarcinoma and allow for more detailed phenotyping versus the cytology sample obtained from pleural fluid. It is relatively easily accessible and can significantly improve targeting of appropriate chemotherapy intervention.

A MRI spine

MRI scanning may be useful to evaluate any neurological impingement, and to provide supporting evidence that the wedge fracture is related to tumour, but it won't provide a tissue diagnosis.

C Bone densitometry

Bone densitometry is helpful in assessing future risk of fracture if the underlying diagnosis is one of osteoporosis, but that seems unlikely here.

D Tumour markers

Testing specific tumour markers implies at least some knowledge of the underlying carcinoma type, and not all adenocarcinomas express conventional tumour markers.

E Parathyroid hormone assay

Calcium is only just above the upper limit of normal, and renal function is only slightly deranged with a creatinine of 140. Hyperparathyroidism is therefore very unlikely to be the cause of the wedge fracture seen here.

Rate this question:

2:14
MyPastest
Home Feed | Re
Tumor Markers
https://mypastest.pastest.com/Secure/TestMe/Brow

A 75-year-old man complains of headaches and intermittent blurred vision.

On further questioning, he admits to repeated episodes of epistaxis over the past few months. He is generally lethargic and has lost approximately 7 kg in weight over the past few weeks.

On examination, his cervical lymph nodes are enlarged and a purpuric rash is noted on his arms.

Investigations:

Haemoglobin (Hb)	11 g/dl
White cell count (WCC)	6×10^9/l
Platelet (PLT)	130×10^9/l
Erythrocyte sedimentation rate (ESR)	85 mm/1st hr

He then went on to have a bone marrow aspirate with showed infiltration with lyphoplasmacytoid cells.

What is the most likely diagnosis?

A Multiple myeloma

B Waldenstrom's macroglobulinaemia

C Non-Hodgkin's lymphoma

D Chronic lymphocytic leukaemia

E Chronic myeloid leukaemia

the past few weeks.

On examination, his cervical lymph nodes are enlarged and a purpuric rash is noted on his arms.

Investigations:

Haemoglobin (Hb)	11 g/dl
White cell count (WCC)	6×10^9/l
Platelet (PLT)	130×10^9/l
Erythrocyte sedimentation rate (ESR)	85 mm/1st hr

He then went on to have a bone marrow aspirate with showed infiltration with lyphoplasmacytoid cells.

What is the most likely diagnosis?

Your answer was correct

A Multiple myeloma

B Waldenstrom's macroglobulinaemia

C Non-Hodgkin's lymphoma

D Chronic lymphocytic leukaemia

E Chronic myeloid leukaemia

Explanation

B Waldenstrom's macroglobulinaemia

Waldenstrom's macroglobulinaemia is a type of lymphoplasmacytoid lymphoma. Patients tend to be older

B Waldenstrom's macroglobulinaemia

Waldenstrom's macroglobulinaemia is a type of lymphoplasmacytoid lymphoma. Patients tend to be older men who present with peripheral lymph node enlargement and symptoms that are due to bone marrow infiltration. The illness is associated with a paraprotein (IgM) that is responsible for symptoms of hyperviscosity. Clinical features include symptoms of hyperviscosity (headaches, visual disturbance), general malaise, weight loss, lymphadenopathy, anaemia and bleeding tendencies. The blood count usually shows normal or low haemoglobin, white cell and platelet counts. ESR is raised. The blood film shows a rouleaux formation. A bone marrow aspirate usually shows infiltration with lymphoplasmacytoid cells. Protein electrophoresis shows an IgM paraprotein (>20 g/l). Treatment is usually with alkylating agents in elderly patients. Younger patients may be started on doxorubicin-containing regimens. Recurrence is inevitable. In patients in whom hyperviscosity is the main problem, regular plasmapheresis can be helpful.

A Multiple myeloma

Multiple myeloma patients often suffer with recurrent infections, complain of bony pain and have a raised calcium. On a blood film and bone marrow aspirate, you would expect to see a high proportion of plasma cells. The bone marrow biopsy can be used for plasma cell phenotyping.

C Non-Hodgkin's lymphoma

You would expect patients with non-Hodgkin's lymphoma to have anaemia, thrombocytopenia and neutropenia. In some cases, you may see lymphocytosis and thrombocytosis. However, this is not the picture for patient, meaning it is not the likely diagnosis.

A Multiple myeloma

Multiple myeloma patients often suffer with recurrent infections, complain of bony pain and have a raised calcium. On a blood film and bone marrow aspirate, you would expect to see a high proportion of plasma cells. The bone marrow biopsy can be used for plasma cell phenotyping.

C Non-Hodgkin's lymphoma

You would expect patients with non-Hodgkin's lymphoma to have anaemia, thrombocytopenia and neutropenia. In some cases, you may see lymphocytosis and thrombocytosis. However, this is not the picture for this patient, meaning it is not the likely diagnosis.

D Chronic lymphocytic leukaemia

Bone marrow aspirate shows lymphocytic replacement of normal bone marrow elements rather than lymphoplasmacytoid cells.

E Chronic myeloid leukaemia

Bone marrow aspiration and biopsy in CML patients are essential to quantify the percentage of blasts and basophils, to assess the degree of fibrosis and to obtain material for cytogenetic-molecular analyses. None of these characteristics are commented upon in this patient's work-up, meaning that chronic myeloid leukaemia is an unlikely diagnosis.

7305

Rate this question:

Next Question

Touc... 00:38 2:21

Lymphoplasmacytic Lymp

Cells: lymphocytes, lymphoplasmacytoid
excess mast cells in association wi
aggregates

BM: interstitial pattern with diffuse or no
excess mast cells in association wi
aggregates

LN/SP: diffuse pattern

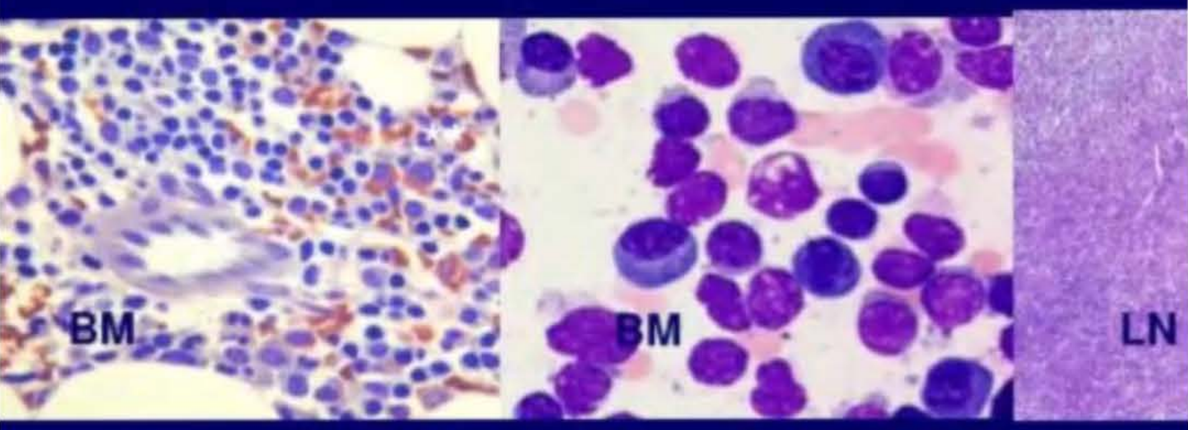

SlideServe

PPT - Waldenström's macroglobulinemia : Similar but Differ

nages may be subject to copyright. Learn more

ELATED IMAGES

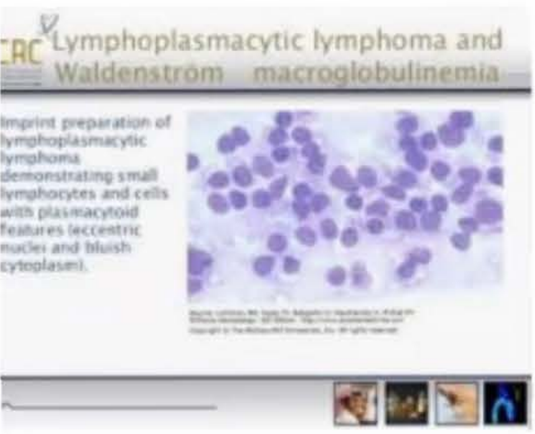

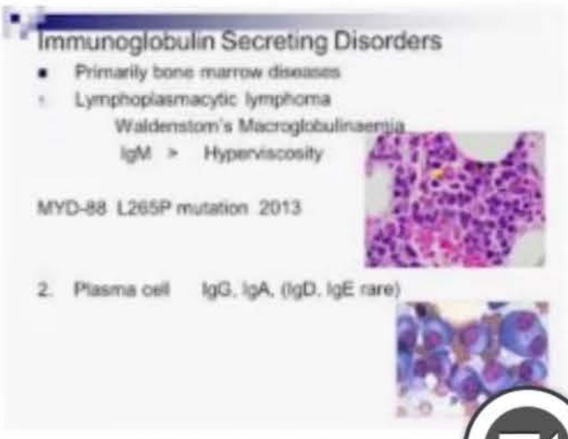

Discover Updates Search Rece

2:22
On 594-042-7551 Leave

E Chronic myeloid leukaemia

Explanation

B Waldenstrom's macroglobulinaemia

Waldenstrom's macroglobulinaemia is a type of lymphoplasmacytoid lymphoma. Patients tend to be older men who present with peripheral lymph node enlargement and symptoms that are due to bone marrow infiltration. The illness is associated with a paraprotein (IgM) that is responsible for symptoms of hyperviscosity. Clinical features include symptoms of hyperviscosity (headaches, visual disturbance), general malaise, weight loss, lymphadenopathy, anaemia and bleeding tendencies. The blood count usually shows normal or low haemoglobin, white cell and platelet counts. ESR is raised. The blood film shows a rouleaux formation. A bone marrow aspirate usually shows infiltration with lymphoplasmacytoid cells. Protein electrophoresis shows an IgM paraprotein (>20 g/l). Treatment is usually with alkylating agents in elderly patients. Younger patients may be started on doxorubicin-containing regimens. Recurrence is inevitable. In patients in whom hyperviscosity is the main problem, regular plasmapheresis can be helpful.

A Multiple myeloma

Multiple myeloma patients often suffer with recurrent infections, complain of bony pain and have a raised calcium. On a blood film and bone marrow aspirate, you would expect to see a high proportion of plasma cells. The bone marrow biopsy can be used for plasma cell phenotyping.

C Non-Hodgkin's lymphoma

Audio Video Share Participants More

2:22
On
594-042-7551
Leave
MyPastest
Home Feed | Re
Tumor Markers
https://mypastest.pastest.com/Secure/TestMe/Brow

Pastest+

Question 42 of 90

A 60-year-old smoker presents with cough, chest pain, dyspnoea and haemoptysis. A chest X-ray shows round shadows in the right intermediate lobe of the lung with ipsilateral hilar node involvement. A biopsy reveals small cell carcinoma. Computerised tomography (CT) and positron emission tomography (PET) scanning do not suggest distant metastases, either on the opposite side of the thorax or beyond the thoracic cavity.

What is the most appropriate treatment in this case?

A	Surgical resection
B	Combination chemo- and radiotherapy
C	External irradiation
D	Tracheobronchial stenting
E	Endobronchial irradiation

7307

Submit

Previous Q...
Skip Questi...
Audio
Video
Share
Participants
More

A 60-year-old smoker presents with cough, chest pain, dyspnoea and haemoptysis. A chest X-ray shows round shadows in the right intermediate lobe of the lung with ipsilateral hilar node involvement. A biopsy reveals small cell carcinoma. Computerised tomography (CT) and positron emission tomography (PET) scanning do not suggest distant metastases, either on the opposite side of the thorax or beyond the thoracic cavity.

What is the most appropriate treatment in this case?

Your answer was incorrect

A Surgical resection

B Combination chemo- and radiotherapy

C External irradiation

D Tracheobronchial stenting

E Endobronchial irradiation

Explanation

B Combination chemo- and radiotherapy

In small cell lung cancer, the disease has almost always disseminated by the time of diagnosis and surgery is thus inappropriate. A very small percentage of patients h early disease that is amenable to lobectomy. These ts who progress to surgery always have stage 1 disease. Compared to non-small cell lung cancer, this tumour is very

B Combination chemo- and radiotherapy

In small cell lung cancer, the disease has almost always disseminated by the time of diagnosis and surgery is thus inappropriate. A very small percentage of patients have early disease that is amenable to lobectomy. These patients who progress to surgery always have stage 1 disease. Compared to non-small cell lung cancer, this tumour is very chemosensitive and approximately 75% of patients will respond to combination chemotherapy (e.g. etoposide and cisplatin). Single or combination chemotherapy has resulted in a fivefold increase in median survival, even in extensive disease, from two to ten months. A small proportion of small cell lung cancer patients with limited disease will be cured.

A Surgical resection

Given that there is already ipsilateral hilar node involvement, surgical resection is inappropriate for this patient.

C External irradiation

Given that small cell cancer is particularly chemosensitive, radiotherapy alone is inappropriate here.

D Tracheobronchial stenting

Tracheobronchial stenting is most useful for patients with extreme local symptoms from bronchial compression, including recurrent infection and haemoptysis.

E Endobronchial irradiation

Similar to tracheobronchial stenting, endobronchial irradiation is reserved for patients with significant

who progress to surgery always have stage 1 disease. Compared to non-small cell lung cancer, this tumour is very chemosensitive and approximately 75% of patients will respond to combination chemotherapy (e.g. etoposide and cisplatin). Single or combination chemotherapy has resulted in a fivefold increase in median survival, even in extensive disease, from two to ten months. A small proportion of small cell lung cancer patients with limited disease will be cured.

A Surgical resection

Given that there is already ipsilateral hilar node involvement, surgical resection is inappropriate for this patient.

C External irradiation

Given that small cell cancer is particularly chemosensitive, radiotherapy alone is inappropriate here.

D Tracheobronchial stenting

Tracheobronchial stenting is most useful for patients with extreme local symptoms from bronchial compression, including recurrent infection and haemoptysis.

E Endobronchial irradiation

Similar to tracheobronchial stenting, endobronchial irradiation is reserved for patients with significant symptoms of local bronchial compression.

2:24
On
594-042-7551
Leave

A 79-year-old woman who has been using co-codamol 30/500 tablets to control pain from an inoperable right breast carcinoma comes to the clinic. Other medication of note includes indapamide for hypertension.

On examination, her blood pressure (BP) is 140/82 mmHg; she is complaining of right breast pain, as the tumour has broken through the skin and is covered by a large dressing.

Which of the following is the most appropriate way to manage her pain?

A	Add diclofenac to her regime
B	Stop the co-codamol, institute regular paracetamol with titrated prn oral morphine
C	Continue the co-codamol and add oral morphine
D	Add tramadol to her regime
E	Stop the co-codamol, institute regular paracetamol and bd MST

21462

Submit

Audio Video Share Participants More

B Stop the co-codamol, institute regular paracetamol with titrated prn oral morphine

The optimal way to manage this patient with severe local symptoms from her breast cancer is to establish regular paracetamol as a base for pain relief and then titrate oral morphine until her pain is controlled. At this point the prn morphine dose can be titrated to an appropriate level of MST.

A Add diclofenac to her regime

Whilst it is reasonable to add a NSAID to her regime, it's very unlikely to be effective until a stable morphine dose has been established.

C Continue the co-codamol and add oral morphine

It's illogical to maintain codeine (a weak opiate) at the same time as starting oral morphine. When it comes to transferring to MST it will only make dose calculation more complicated.

D Add tramadol to her regime

Although tramadol has the advantage of causing less constipation than codeine, it is only marginally more effective as an analgesic and hence changing to titrated morphine is the preferred option.

E Stop the co-codamol, institute regular paracetamol and bd MST

Titrating MST is much more difficult compared to titrating regular oral morphine, and hence this is not the recommended approach.

2:29
MyPastest
Home Feed | Re
Tumor Markers
https://mypastest.pastest.com/Secure/TestMe/Browse

A 52-year-old man who smokes 50 cigarettes per day complains to his general practitioner (GP) of chronic cough, which has worsened recently, and his sputum is now yellow-green in colour and blood-stained. He has lost approximately 2 kg in weight over the past four months.

Investigations:

Haemoglobin (Hb)	10.9 g/dl
White cell count (WCC)	10.1×10^9/l
Platelet (PLT)	175×10^9/l
Sodium (Na^+)	140 mmol/l
Potassium (K^+)	5.0 mmol/l
Creatinine	140 µmol/l
Calcium (Ca^{2+})	2.85 mmol/l
Plasma viscosity	2.14 mPa/s (1.5–1.72)
C-reactive protein	45 mg/l

His chest X-ray is shown below.



Which of the following is the most likely underlying diagnosis?

A	Squamous cell carcinoma
B	Alveolar cell carcinoma
C	Small cell carcinoma
D	Bronchial carcinoid
E	Adenocarcinoma

Submit

Previous Q... Skip Questi...

© Pastest 2019

A Squamous cell carcinoma

Squamous cell bronchial carcinoma is most commonly associated with hypercalcaemia. The chest X-ray, raised viscosity and hypercalcaemia, coupled with cough and haemoptysis, point towards a neoplasm as the most likely diagnosis. Hypercalcaemia is usually due to production of parathyroid hormone-related protein (PTHrp) by the tumour. Treatment of symptomatic hypercalcaemia is with intravenous (iv) rehydration, corticosteroids and iv bisphosphonates. His underlying tumour is best elucidated with a combination of CT and transbronchial biopsy to gain a tissue diagnosis.

B Alveolar cell carcinoma

Alveolar cell carcinoma originates from non-endocrine cells, and hence an alveolar cell carcinoma couldn't account for the hypercalcaemia seen here.

C Small cell carcinoma

Some small cell lung cancers secrete antidiuretic hormone (ADH) and adrenocorticotropic hormone (ACTH), leading to the development of either the syndrome of inappropriate antidiuretic hormone secretion (SIADH) or features of Cushing syndrome.

D Bronchial carcinoid

Bronchial carcinoid occurs as a single vascular tumour, and is associated with recurrent haemoptysis and pneumonia. It is not associated with smoking.

E Adenocarcinoma

These tumours are not hormone secreting and therefore

MyPastest
Home Feed | Re
Tumor Markers
https://mypastest.pastest.com/Secure/TestMe/Browse

Pastest

Question 44 of 90

Some small cell lung cancers secrete antidiuretic hormone (ADH) and adrenocorticotropic hormone (ACTH), leading to the development of either the syndrome of inappropriate antidiuretic hormone secretion (SIADH) or features of Cushing syndrome.

D Bronchial carcinoid

Bronchial carcinoid occurs as a single vascular tumour, and is associated with recurrent haemoptysis and pneumonia. It is not associated with smoking.

E Adenocarcinoma

These tumours are not hormone secreting and therefore cannot account for the hypercalcaemia seen here.

Rate this question:

Next Question

Previous Q... Tag Questi... Feedback End Session

Blog About Pastest Contact Us Help

© Pastest 2019

Rana Alnasser's screen

2:30
MyPastest
Home Feed | Res
Tumor Markers f
https://mypastest.pastest.com/Secure/TestMe/

A 67-year-old man presents to his general practitioner (GP) with his wife, complaining of non-specific symptoms consisting of anorexia, malaise, nausea, fatigue and mid-epigastric pain that have gradually worsened over the past few months. He also reports that he has lost 5 kg in weight over this same period of time. He confides that he is feeling depressed and had attributed his symptoms to his depression, but has come to see the GP at the insistence of his wife who feels that the patient's skin colour has changed. He has also been recently diagnosed with diabetes mellitus, controlled with tablets, and is a smoker of a pack a day since his mid-twenties. General examination of the patient confirmed the weight loss and showed some mild mid-epigastric tenderness as well as a yellow hue to the sclera.

Investigations:

Haemoglobin (Hb)	12.1 g/dl
White cell count (WCC)	4.3×10^9/l
Platelet (PLT)	550×10^9/l
Sodium (Na^+)	139 mmol/l
Potassium (K^+)	4.2 mmol/l
Creatinine	90 µmol/l
Urea	7.9 mmol/l
Serum total bilirubin	77 µmol/l
ALP	401 U/l
AST	51 U/l
ALT	45 U/l

Rana Alnasser's screen

2:31
MyPastest
Home Feed | Re
Tumor Markers
https://mypastest.pastest.com/Secure/TestMe/

Potassium (K^+)	4.2 mmol/l
Creatinine	90 µmol/l
Urea	7.9 mmol/l
Serum total bilirubin	77 µmol/l
ALP	401 U/l
AST	51 U/l
ALT	45 U/l
γGT	99 U/l
Amylase	91 U/l

What is the most likely diagnosis?

A Duodenal ulcer

B Adenocarcinoma of the stomach

C Choledocholithiasis

D Adenocarcinoma of the pancreas

E Chronic pancreatitis

Submit

2:34
MyPastest
Home Feed | Re
Tumor Markers
https://mypastest.pastest.com/Secure/TestMe/

D Adenocarcinoma of the pancreas

Pancreatic cancer is the third most common malignancy affecting the gastrointestinal tract, but it is a difficult disease to diagnose in its early stages and therefore most patients present at an advanced and incurable stage. It is slightly more common in men than in women and in the absence of predisposing factors, such as chronic pancreatitis, it is rare in people younger than 45 years of age. The initial symptoms tend to be vague and non-specific and can delay the diagnosis of the condition, but significant weight loss is a characteristic feature. Mid-epigastric pain is a common symptom, but radiation of the pain to the lower back is a sinister sign indicating retroperitoneal invasion of the splanchnic nerve plexus by the tumour. The recent onset of diabetes mellitus can sometimes be attributed to pancreatic cancer. If the carcinoma involves the head of the pancreas, the patient may present with painless obstructive jaundice with no abdominal pain, with associated darkening of the urine, lightening of the stools and pruritus. Depression is also a common symptom in patients with pancreatic carcinoma. Laboratory investigations tend to be non-specific for pancreatic carcinoma, although patients may have a mild normochromic anaemia and thrombocytosis. If a patient has obstructive jaundice, significant elevations in bilirubin, alkaline phosphatase, γ-glutamyl transpeptidase and, to a lesser extent, aspartate aminotransferase and alanine aminotransferase, may be seen, but amylase and lipase levels are not elevated.

Stop Annotation Spotlight Pen Highlight Line Rectangle Oval Undo

2:34

A 67-year-old man presents to his general practitioner (GP) with his wife, complaining of non-specific symptoms consisting of anorexia, malaise, nausea, fatigue and mid-epigastric pain that have gradually worsened over the past few months. He also reports that he has lost 5 kg in weight over this same period of time. He confides that he is feeling depressed and had attributed his symptoms to his depression, but has come to see the GP at the insistence of his wife who feels that the patient's skin colour has changed. He has also been recently diagnosed with diabetes mellitus, controlled with tablets, and is a smoker of a pack a day since his mid-twenties. General examination of the patient confirmed the weight loss and showed some mild mid-epigastric tenderness as well as a yellow hue to the sclera.

A
B
C
D
E

Investigations:

Haemoglobin (Hb)	12.1 g/dl
White cell count (WCC)	4.3×10^9/l
Platelet (PLT)	550×10^9/l
Sodium (Na^+)	139 mmol/l
Potassium (K^+)	4.2 mmol/l
Creatinine	90 µmol/l
Urea	7.9 mmol/l
Serum total bilirubin	77 µmol/l
ALP	401 U/l
AST	51 U/l
ALT	45 U/l
γGT	99 U/l
Amylase	91 U/l

Rana Alnasser's screen

aminotransferase, may be seen, but amylase and lipase levels are not elevated.

A Duodenal ulcer

Duodenal ulcer may be associated with epigastric pain and mild anaemia, although it would be inconsistent with the picture of obstructive jaundice seen here.

B Adenocarcinoma of the stomach

In adenocarcinoma of the stomach more pronounced early satiety would be expected and anaemia would be seen, although obstructive jaundice would be unusual except in the presence of extensive liver metastases.

C Choledocholithiasis

Gallstones may lead to obstructive jaundice, although acute episodes of right upper quadrant pain would be expected rather than the slowly progressive symptoms with epigastric pain seen here.

E Chronic pancreatitis

There are no risk factors here for acute pancreatitis, such as alcoholism, and patients usually complain of severe epigastric pain and features of malabsorption. Obstructive jaundice wouldn't be expected in chronic pancreatitis.

Rate this question:

Next Question

Previous Q... Tag Questi... Feedback End Session

A 67-year-old man attends Accident and Emergency with a 2-week history of uncontrollable headaches which have been increasing in intensity. They are not relieved by a combination of paracetamol and ibuprofen. He has also noticed oedema affecting his face and arms over the past few days. He smokes 30 cigarettes per day and has a chronic cough, which has become productive of blood tinged sputum over the past month.

On examination, his blood pressure (BP) is 155/90 mmHg, pulse is 90/min and regular, and he looks in pain. He has a plethoric face and dilated veins over the upper body.

Investigations:

Haemoglobin (Hb)	10.9 g/dl
White cell count (WCC)	9.1×10^9/l
Platelet (PLT)	181×10^9/l
Sodium (Na^+)	137 mmol/l
Potassium (K^+)	4.5 mmol/l
Creatinine	122 µmol/l
Calcium	2.71 mmol/l
Alkaline phosphotase (ALP)	125 U/l
Alanine transaminase (ALT)	75 U/l
Chest X-ray	Right hilar mass consistent with bronchial carcinoma

Which of the following is the most effective management for his superior vena cava (SVC) obstruction?

Haemoglobin (Hb)	10.9 g/dl
White cell count (WCC)	9.1×10^9/l
Platelet (PLT)	181×10^9/l
Sodium (Na^+)	137 mmol/l
Potassium (K^+)	4.5 mmol/l
Creatinine	122 µmol/l
Calcium	2.71 mmol/l
Alkaline phosphotase (ALP)	125 U/l
Alanine transaminase (ALT)	75 U/l
Chest X-ray	Right hilar mass consistent with bronchial carcinoma

Which of the following is the most effective management for his superior vena cava (SVC) obstruction?

A Chemotherapy

B Methylprednisolone

C Radiotherapy

D Stenting

E Systemic thrombolysis

D Stenting

The clinical vignette corresponds with superior vena cava obstruction, likely secondary to lung malignancy.

Stenting is recognised to provide rapid symptomatic benefit in 95% of patients and rapid restoration of the normal pattern of flow. However, stenting is used less frequently in potentially curable cancer such as lymphoma.

A Chemotherapy

Urgent chemotherapy is an alternative to stenting for patients with curable chemosensitive cancers, eg germ cell tumours, lymphoma. It is used as an addition to stenting for other cancers such as small cell lung cancers.

B Methylprednisolone

In cases of first presentation of a suspected malignancy, hold off on steroids unless there is evidence of cardiorespiratory compromise as they can compromise interpretation of subsequent biopsies.

C Radiotherapy

Radiotherapy may be recommended if the occlusion is not amenable to stent placement, but this is not the most effective treatment.

E Systemic thrombolysis

Full anticoagulation should be given, where appropriate, for those with evidence of thrombus. Prophylactic anticoagulation or antiplatelet therapy should be considered as there is a high incidence of thrombus with intravascular stents. Systemic thrombolysis is not indicated

4:07
On
594-042-7551
Leave

A 76-year-old man presents with lethargy and pain, affecting the lower back and left femur in particular. He is awaiting investigations for anaemia and an upper GI endoscopy is planned.

Investigations:

Haemoglobin (Hb)	9.1 g/dl
Viscosity	2.4
Creatinine	215 µmol/l
Faecal occult bloods	-
Prostate-specific Antigen (PSA)	4
X-ray left femur	Multiple osteolytic lesions

Which is the likeliest underlying diagnosis?

A Multiple myeloma

B Multiple metastases from unknown carcinoma

C Chronic myeloid leukaemia

D Occult GI malignancy

E Lymphoma

Submit
Audio
Video
Share
Participants
More

A Multiple myeloma

This patient has a raised creatinine, indicating renal involvement, a raised blood viscosity (normal range 1.5–1.72) and has multiple lytic lesions which would be in keeping with a diagnosis of myeloma. It would be useful to investigate immunoglobulin levels (looking for raised levels) and check for the presence of Bence Jones proteins on urinalysis.

The age-adjusted annual incidence of myeloma is around 4/100 000 in Caucasians, and this is doubled in Afro-Caribbean populations. Incidence increases with age. Bone pain is the most commonly presenting symptom, present in 70% of patients at the time of diagnosis, and 93% of patients with myeloma have more than one bony site involved.

Other presentations may be with complications as a result of hyperviscosity, bleeding due to thrombocytopenia or increased susceptibility to infections such as *Pneumococcus*, *Haemophilus* or herpes zoster. Radiotherapy is extremely effective for bony lesions and is the mainstay of treatment, in conjunction with corticosteroids for lesions leading to spinal cord compression. Commonly used therapeutic agents include melphalan and oral corticosteroids.

B Multiple metastases from unknown carcinoma

Metastatic disease should be considered. However, given that this patient has raised viscosity and renal impairment means that metastatic disease is a less likely diagnosis compared to myeloma.

C Chronic myeloid leukaemia

CML tends to cause recurrent infections, splenomegaly,

4:10

MyPastest | Home Feed | Tumor Mar

https://mypastest.pastest.com/Secure/TestMe/Browse

Pastest+

As part of your training rotation, you are about to start a genetic counselling clinic with your consultant advising families of the risk of familial cancer syndromes.

In which of the following is the strongest association between a chromosomal abnormality and a known cancer syndrome?

A	Retinoblastoma 13q14 gene (Rb)
B	Hereditary non-polyposis colon cancer 2p gene (HNPC)
C	Multiple endocrine neoplasia type (MEN) I 13q gene (MEN1)
D	Neurofibromatosis (NF) type I 11q gene (NF1)
E	Neurofibromatosis type (NF) II 17p gene (NF2)

6674

Submit

Previous Q... Skip Questi...

Blog About Pastest Contact Us Help

4:12
On
594-042-7551
Leave
MyPastest
Home Feed | Re
Tumor Mar
https://mypastest.pastest.com/Secure/TestMe/Browse

Pastest+

Question 2 of 44

A Retinoblastoma 13q14 gene (Rb)

Approximately 45% of all retinoblastomas are hereditary and exhibit autosomal dominant inheritance with approximately 90% penetrance.

B Hereditary non-polyposis colon cancer 2p gene (HNPC)

The correct answer would be hereditary non-polyposis colon cancer 1 and chromosome 2p gene MSH2.

C Multiple endocrine neoplasia type (MEN) I 13q gene (MEN1)

The correct association is MEN I and chromosome 11q.

D Neurofibromatosis (NF) type I 11q gene (NF1)

The correct association is NF type I and chromosome 17q gene NF1.

E Neurofibromatosis type (NF) II 17p gene (NF2)

The correct association is NF type II and chromosome 22 gene NF2.

Rate this question:

Next Question
Audio
Video
Share
Participants
More

4:13
MyPastest
Home Feed | Re
Tumor Mar
https://mypastest.pastest.com/Secure/TestMe/Browse

Pastest+

A 67-year-old man presents with increasing fatigue and low back pain for the past four months.

Clinical examination reveals a pale-looking man who is slim, with a body mass index (BMI) of 20.5. Blood tests reveal a mild normocytic, normochromic anaemia, low white cell and platelet counts and a high ESR. Blood urea, electrolytes and serum alkaline phosphatase levels are normal, and liver function testing reveals raised total protein and globulin fraction. An X-ray of the lumbosacral spine shows lytic lesions.

Which of the following investigations would be most helpful in confirming the diagnosis?

A	Serum calcium
B	Lymph node biopsy
C	24 h urinary albumin excretion
D	Bone marrow aspirate
E	Bone densitometry

Submit

Rana Alnasser's screen

D Bone marrow aspirate

Clear criteria have been defined for the diagnosis of myeloma and the other causes of paraproteinaemia, and bone marrow examination is crucial in confirming the diagnosis.

MGUS Monoclonal gammopathy of unknown	Asymptomatic myeloma	Symptomatic myeloma
• Monoclonal protein in serum < 30 g/l	• Monoclonal protein in serum > 30 g/l and/or	• Monoclonal protein in serum and/or urine
• Bone marrow clonal plasma cells < 10% and low level of plasma cell infiltration in a trephine biopsy	• Bone marrow clonal plasma cells > 10%	• Bone marrow (clonal) plasma cells or biopsy-proven plasmacytoma
• No myeloma-related organ or tissue impairment (including bone lesions) or symptoms	• No myeloma-related organ or tissue impairment (including bone lesions) or symptoms	• Any myeloma-related organ or tissue impairment (including bone lesions)
• No evidence of other B-cell proliferative disorders or light chain-associated amyloidosis or other light chain-, heavy chain- or immunoglobulin-		

4:16
MyPastest
Home Feed | Re
Tumor Mar
https://mypastest.pastest.com/Secure/TestMe/Browse

lymphoma, which isn't suggested here by the significant elevation in globulin fraction.

C	24 h urinary albumin excretion

Multiple myeloma may present with nephrotic range proteinuria, related to the development of amyloidosis, although albumin excretion measurement won't confirm the underlying diagnosis.

E	Bone densitometry

Bone scintigraphy, not densitometry, is used in the evaluation of skeletal malignancy, although in myeloma it may not be abnormal because of an absence of osteoblastic activity. For this reason, skeletal survey is preferred in evaluation of myeloma.

Rate this question:

Next Question

Previous Q... Tag Questi... Feedback End Session

Blog About Pastest Contact Us Help

© Pastest 2019

Rana Alnasser's screen

4:16
MyPastest
Home Feed | Re
Tumor Mar
https://mypastest.pastest.com/Secure/TestMe/Browse

Pastest+

Question 4 of 44

A 50-year-old man, who has smoked heavily in the past, presents with a 6-month history of progressive generalised weakness and fatigue. He had particularly noted difficulty in climbing the stairs. He also complained of a dry mouth and light-headedness on standing. Symptoms were variable throughout the day but typically worse in the evening.

Examination revealed mild proximal weakness in the lower extremities with absent reflexes. Nerve conduction studies showed low-amplitude motor responses that normalised after a brief 10 s maximal isometric contraction, increasing two to threefold in amplitude.

What is the likely diagnosis?

A	Myaesthenia gravis
B	Myotonic dystrophy
C	Lambert–Eaton myasthenic syndrome
D	Polymyositis
E	Subacute motor neuronopathy

Submit

Previous Q...

Skip Questi...

Rana Alnasser's screen

4:17

C Lambert-Eaton myasthenic syndrome

In Lambert-Eaton myasthenic syndrome (LEMS), there is a reduced release of the neurotransmitter acetylcholine from the nerve terminals into the synaptic gap. This presynaptic disorder is caused by autoantibodies against a membrane protein of the nerve cell, the voltage-gated calcium channel (VGCC). Patients with LEMS typically present with fatigue and weakness predominately affecting proximal muscles, especially of the lower extremities, with little or no bulbar or extra-ocular muscle involvement. Autonomic dysfunction, especially xerostomia and impotence, is very common. Strength may improve transiently after brief exercise and then may wane with continued activity. Reflexes are typically reduced or absent, but may improve or normalise transiently after brief strenuous muscle activity. LEMS may be difficult to distinguish clinically from myasthenia gravis. Diagnosis is confirmed with nerve conduction studies (NCS) and seropositivity for P/Q-type VGCC autoantibodies, which are present in 95% of LEMS patients. Once a diagnosis of LEMS is made, a rigorous search for occult malignancy, especially, small cell lung cancer, should be undertaken.

A Myaesthenia gravis

Myasthenia gravis (MG) is an acquired, humoral autoimmune disease. Specific acetylcholine receptor autoantibodies (ACHRAB) lead to a reduced impulse transmission to the postsynaptic membrane of the neuromuscular endplate. It produces fluctuating, fatiguable weakness of muscle strength. Symptoms usually worsen later in the day or after prolonged use of specific muscles. In contrast to Lambert-Eaton myasthenic syndrome (LEMS), most MG patients have ocular or bulbar weakness.

B Myotonic dystrophy

Rana Alnasser's screen

A 55-year-old man has recently been started on imatinib mesylate for chronic myeloid leukaemia.

What does it specifically target?

A	The ras gene
B	The cell membrane
C	All tumour cells
D	The proteosome
E	An abnormality identified as BCR-ABL

Submit

Previous Q... Skip Questi...

© Pastest 2019

E An abnormality identified as BCR-ABL

In CML, a chromosomal rearrangement among white blood cells fuses two genes together to create an oncogene. This produces a damaged tyrosine kinase receptor protein, BCR-ABL, that signals cells to grow and divide even when no growth factor is present. Ultimately this leads to an overproduction of immature white blood cells. Imatinib mesylate is a tyrosine kinase inhibitor. It binds to the damaged BCR-ABL receptors, thereby inhibiting tumour growth.

A The ras gene

There are currently no ras-targeted treatments used in clinical practice. Ras gene mutations have been noted in patients with chronic myeloid leukaemia (CML).

B The cell membrane

Imatinib binds directly to damaged BCR-ABL receptors (seen in CML), which inhibits tumour growth.

C All tumour cells

Imatinib is a targeted treatment; it thus specifically targets BCR-ABL receptors within cells, meaning that it can affect both normal and tumour cells. Usually, a normal cell can continue to function regardless of whether imatinib binds to it. However, in some cases imatinib can lead to death of tumour cells as well as some normal cells.

D The proteosome

Imatinib competitively inhibits and occupies the tyrosine kinase active site on abl, which leads to inhibition of tumour proliferation.

An 85-year-old woman with metastatic small cell lung cancer was discharged home on regular oral morphine sulphate for pain relief. She had originally found good relief from the medication, but after several weeks required readmission because her pain was again poorly controlled. She had taken her medication as prescribed.

During admission, she developed hospital-acquired pneumonia and deteriorated, developing respiratory failure and an impaired Glasgow Coma Scale (GCS). She remained in considerable discomfort.

Which of the following statements is correct with respect to her resuscitation status?

A	A form used some 2 months ago to elucidate her preferred treatment options could be used here
B	Where death is expected, relatives must be asked for permission not to resuscitate
C	Once a decision is made not to resuscitate, anything that might prolong life must also be discontinued
D	Relatives have the right to demand resuscitation
E	Once a decision about resuscitation is made, it cannot be altered later

Submit

A A form used some 2 months ago to elucidate her preferred treatment options could be used here

Where possible, any treatment options with respect to end of life care should be discussed at the time with the patient. In this case, however, this isn't possible, although the discussion from some 2 months ago is likely to represent the closest approximation to her wishes. As such, the form can be used to guide decisions regarding resuscitation.

B Where death is expected, relatives must be asked for permission not to resuscitate

At this stage it's expected, as a health care professional, that you will take any relatives through the reasons for your discussion, the consultation with the relatives being used to inform and guide in the best interests of the patient.

C Once a decision is made not to resuscitate, anything that might prolong life must also be discontinued

Although a decision not to resuscitate may have been made, treatments which allow an improvement in the patient's condition, potentially allowing them to return home for a while or to a hospice, may of course be considered.

D Relatives have the right to demand resuscitation

Although the course of action should ideally be agreed with relatives, you are only under an obligation to act in the patient's best wishes, not to carry out the demands of any relatives.

E Once a decision about resuscitation is made, it

B Where death is expected, relatives must be asked for permission not to resuscitate

At this stage it's expected, as a health care professional, that you will take any relatives through the reasons for your discussion, the consultation with the relatives being used to inform and guide in the best interests of the patient.

C Once a decision is made not to resuscitate, anything that might prolong life must also be discontinued

Although a decision not to resuscitate may have been made, treatments which allow an improvement in the patient's condition, potentially allowing them to return home for a while or to a hospice, may of course be considered.

D Relatives have the right to demand resuscitation

Although the course of action should ideally be agreed with relatives, you are only under an obligation to act in the patient's best wishes, not to carry out the demands of any relatives.

E Once a decision about resuscitation is made, it cannot be altered later

Often a review date is set on such decisions, to allow status to be reassessed – for example, once an acute episode of sepsis is over.

33434

Rate this question:

Next Question

4:26
On
594-042-7551
Leave
MyPastest
Home Feed | Re
Tumor Mar
https://mypastest.pastest.com/Secure/TestMe/Browse

Pastest+

Question 7 of 44

A 70-year-old man complains of increasing delay and difficulty in passing urine. There is no history of pain or discoloration of the urine.

A rectal examination reveals an enlarged, irregular prostate gland. A provisional diagnosis of prostatic cancer is made.

Which of the following investigations would be most useful in the staging the size and local spread of the prostatic cancer in this patient?

A	Serum prostate-specific antigen levels
B	Prostatic biopsy
C	Bone scan
D	Trans-rectal ultrasonography
E	Excretion urography

Submit

Previous Q...

Skip Questi...

Audio
Video
Share
Participants
More

4:26

Explanation

D Trans-rectal ultrasonography

Trans-rectal ultrasonography is of value in defining the size of the gland and staging any tumour present with respect to size relative to the prostate gland and any local extension.

A Serum prostate-specific antigen levels

Serum PSA levels are elevated in patients with prostatic cancer, although de-differentiation may mean that PSA doesn't correlate absolutely with tumour burden.

B Prostatic biopsy

Prostatic biopsy will provide information on histological grading of the tumour, but is not as useful as ultrasonography in assessing tumour size and spread.

C Bone scan

Bone scanning is useful in assessing the presence of distant metastases rather than local tumour spread.

E Excretion urography

Although excretion urography may provide an estimate of the degree of obstruction, this may not correlate absolutely with local spread of cancer within the prostate gland.

Rate this question:

Next Question

Rana Alnasser's screen

4:27

A 67-year-old woman with known pancreatic carcinoma was suffering from continued severe pain despite up-titration of oral morphine. The last oncology letter on the hospital computer states that there are multiple liver metastases and increasing signs of obstruction on her LFT monitoring, not responsive to a recent round of chemotherapy. Her general practitioner (GP) switched the patient from oral morphine to fentanyl patches following a recent review.

Unfortunately, her relatives misunderstood the advice of the palliative care nurse and applied a second patch after 24 h. Her relatives called an ambulance as she appeared to have deteriorated rapidly.

On examination in the Emergency Department, she is unrousable with pinpoint pupils and a respiratory rate of 15 breaths/min. Her blood pressure is 110/60 mmHg, pulse 66/min and O_2 saturation on air is 95%.

Which of the following is the most appropriate intervention?

A	Infusion of naloxone
B	Switch to fentanyl 72-hourly
C	Remove the patch, support her with an airway, and titrate oral morphine as required
D	Consider intubation
E	Switch to s/c diamorphine

Submit

Rana Alnasser's screen

monitoring, not responsive to a recent round of chemotherapy. Her general practitioner (GP) switched the patient from oral morphine to fentanyl patches following a recent review.

Unfortunately, her relatives misunderstood the advice of the palliative care nurse and applied a second patch after 24 h. Her relatives called an ambulance as she appeared to have deteriorated rapidly.

On examination in the Emergency Department, she is unrousable with pinpoint pupils and a respiratory rate of 15 breaths/min. Her blood pressure is 110/60 mmHg, pulse 66/min and O_2 saturation on air is 95%.

Which of the following is the most appropriate intervention?

Your answer was incorrect

A	Infusion of naloxone
B	Switch to fentanyl 72-hourly
C	Remove the patch, support her with an airway, and titrate oral morphine as required
D	Consider intubation
E	Switch to s/c diamorphine

Explanation

C	Remove the patch, support her with an airway, and titrate oral morphine as required

This patient is not responding to palliative chemotherapy

Rana Alnasser's screen

C Remove the patch, support her with an airway, and titrate oral morphine as required

This patient is not responding to palliative chemotherapy for her advanced metastatic pancreatic cancer, as evidenced by increasing pain and worsening liver function tests. Thus, symptom relief must be a priority. The patient is exhibiting signs of opioid toxicity as evidenced by difficult in rousing her and pinpoint pupils following the incorrect dosing by the family, and the move by her GP to a fentanyl patch prior to stability with her morphine dosing. However, her respiratory rate and saturations remain reasonable. Thus, it would be most reasonable to remove the patch, support her airway and provide any analgesia (including morphine – titrated against pain) as required.

D Consider intubation

It would be inappropriate given that simple supportive measures are much more appropriate as next steps.

A Infusion of naloxone

This would be likely to cause significant distress because of arousal, confusion and the return of pain.

B Switch to fentanyl 72-hourly

It would not help as both the patches are 72-hourly patches and it is important that the patches are only changed every three days.

E Switch to s/c diamorphine

It will not deal with the morphine toxicity aspects of the scenario and thus is not the best option.

Rana Alnasser's screen

4:34
MyPastest
Home Feed | Res
Tumor Mar
https://mypastest.pastest.com/Secure/TestMe/Browse

A 65-year-old man presents with pain in the right loin, frank haematuria, anorexia and weight loss. He has no past medical history of note.

On examination, his blood pressure is 160/100 mmHg.

Investigations:

Haemoglobin (Hb)	8.9 g/dl
White cell count (WCC)	10×10^9/l
Platelet (PLT)	220×10^9/l
Mean corpuscular hemoglobin (MCH)	29 pg
Mean corpuscular volume (MCV)	79 fl
Creatinine	97 µmol/l
Urea	3.4 mmol/l
Urate	0.27 mmol/l

An MRI scan reveals a lesion in the upper cortex of the right kidney with enlarged para-aortic nodes and involvement of the right renal vein.

What would be the most appropriate management in this case?

A Palliative treatment

B Partial nephrectomy followed by chemotherapy

C Radiotherapy

Rana Alnasser's screen

On examination, his blood pressure is 160/100 mmHg.

Investigations:

Haemoglobin (Hb)	8.9 g/dl
White cell count (WCC)	10×10^9/l
Platelet (PLT)	220×10^9/l
Mean corpuscular hemoglobin (MCH)	29 pg
Mean corpuscular volume (MCV)	79 fl
Creatinine	97 µmol/l
Urea	3.4 mmol/l
Urate	0.27 mmol/l

An MRI scan reveals a lesion in the upper cortex of the right kidney with enlarged para-aortic nodes and involvement of the right renal vein.

What would be the most appropriate management in this case?

A	Palliative treatment
B	Partial nephrectomy followed by chemotherapy
C	Radiotherapy
D	Renal biopsy, nephrectomy and treatment with a kinase inhibitor
E	Renal biopsy followed by nephrectomy

Mean corpuscular volume (MCV)	79 fl
Creatinine	97 µmol/l
Urea	3.4 mmol/l
Urate	0.27 mmol/l

An MRI scan reveals a lesion in the upper cortex of the right kidney with enlarged para-aortic nodes and involvement of the right renal vein.

What would be the most appropriate management in this case?

Your answer was correct

A Palliative treatment

B Partial nephrectomy followed by chemotherapy

C Radiotherapy

D Renal biopsy, nephrectomy and treatment with a kinase inhibitor

E Renal biopsy followed by nephrectomy

Explanation

D Renal biopsy, nephrectomy and treatment with a kinase inhibitor

This patient is likely to have a renal cell carcinoma, and should have histological confirmation prior to pursuing further treatment. The patient would undergo a

D Renal biopsy, nephrectomy and treatment with a kinase inhibitor

This patient is likely to have a renal cell carcinoma, and should have histological confirmation prior to pursuing further treatment. The patient would undergo a nephrectomy regardless of whether metastases are present. A nephrectomy is still the first line of management, since regression of metastases has been reported after removal of the main tumour mass and nephrectomy will impact positively on other symptoms such as local pain and anaemia due to blood loss. Treatment with a small-molecule kinase inhibitor such as pazopanib or sunitinib is superior to other options (ie interleukin-2 and α-interferon).

A Palliative treatment

This patient has no past medical history to note and, therefore, is likely to have a performance status of 0 or 1. We do not have all the information to hand regarding the lesion noted within the kidney, meaning that palliative treatment would be premature at this point.

B Partial nephrectomy followed by chemotherapy

Although the patient is likely to have a renal cell carcinoma, at this point this has not been confirmed. Prior to a nephrectomy and chemotherapy, the patient will need a histologically proven diagnosis. Following this, a full nephrectomy may be considered. A partial nephrectomy would be considered if the patient had poor renal function or required bilateral nephrectomy.

C Radiotherapy

There is little clinical value in administering radiotherapy to

4:37

MyPastest

Home Feed | Re

Tumor Mar

https://mypastest.pastest.com/Secure/TestMe/Browse

Pastest+

A 62-year-old man with advancing jaundice is referred by his general practitioner (GP). There is a history of variable alcohol consumption and a long spell working in the Far East and Africa for an oil company, and mild hypertension, but there is no other history of note.

On examination, he has features of advanced cirrhosis. Alpha-fetoprotein is elevated and hepatic ultrasound is suggestive of a hepatocellular carcinoma.

Which one of the following would you associate with hepatocellular carcinoma in this patient?

A	Dietary exposure to aflatoxin
B	Caffeine exposure
C	Aniline dye exposure
D	Hepatitis E infection
E	Primary sclerosing cholangitis

Submit

Previous Q...

Skip Questi...

4:39

MyPastest | Home Feed | Tumor Mar

https://mypastest.pastest.com/Secure/TestMe/Browse

Pastest+

A 62-year-old man with advancing jaundice is referred by his general practitioner (GP). There is a history of variable alcohol consumption and a long spell working in the Far East and Africa for an oil company, and mild hypertension, but there is no other history of note.

On examination, he has features of advanced cirrhosis. Alpha-fetoprotein is elevated and hepatic ultrasound is suggestive of a hepatocellular carcinoma.

Which one of the following would you associate with hepatocellular carcinoma in this patient?

Your answer was correct

- A Dietary exposure to aflatoxin
- B Caffeine exposure
- C Aniline dye exposure
- D Hepatitis E infection
- E Primary sclerosing cholangitis

Explanation

A Dietary exposure to aflatoxin

Conditions associated with increased risk of hepatocellular carcinoma include hepatitis B infection, hepatitis C

4:39
MyPastest
Home Feed | Re
Tumor Mar
https://mypastest.pastest.com/Secure/TestMe/Browse

A Dietary exposure to aflatoxin

Conditions associated with increased risk of hepatocellular carcinoma include hepatitis B infection, hepatitis C infection, haemochromatosis and exposure to dietary aflatoxin (found in mouldy foodstuffs in Africa and the Far East; results in DNA damage and p53 mutations). Rarer associations include primary biliary cirrhosis, androgenic steroids, oral contraceptives and porphyria cutanea tarda. Treatment options involve chemical and radiofrequency ablation, and embolisation. Surgical resection is rarely performed, and only around 5% of cases are considered suitable for liver transplant.

B Caffeine exposure

Caffeine exposure is not associated with liver cancer, and epidemiology studies suggest it may actually be protective against conditions such as pancreatitis and cholecystitis.

C Aniline dye exposure

Aniline dye exposure is associated with increased risk of bladder cancer.

D Hepatitis E infection

Hepatitis E is usually associated with short-term hepatitis transmitted by the faeco-oral route, in a similar way to

Scroll capture Draw Crop

E Primary sclerosing cholangitis

A 69-year-old patient is being investigated for breathlessness, cough and severe weight loss. On the medical ward round, their chest X-ray is reviewed and this shows hilar lymphadenopathy and multiple, well-circumscribed circular peripheral lung metastases.

Which of the following tumours is most likely to be the underlying cause of the appearance in the lung?

A	Renal cell carcinoma
B	Colorectal carcinoma
C	Anal carcinoma
D	Brain
E	Tongue

© Pastest 2019

A Renal cell carcinoma

Patients with renal cell carcinoma often have disease that, if metastatic, involves lung metastases. The lung metastases have a typically 'cannon-ball' appearance and are multiple throughout the lung. They are also associated with hilar lymphadenopathy.

B Colorectal carcinoma

Colorectal cancers often metastasise to the liver and lung. Within the lung, they often have hilar lymphadenopathy and peripheral masses. However, they do not typically have a 'cannon-ball' appearance.

C Anal carcinoma

Anal cancers metastasise in less than 10% of patients and, in the majority of those patients, the cancer metastasises to the lymph nodes and liver, meaning that the incidence of lung metastases in anal cancer is infrequent and therefore not the most likely cause of this patient's presentation.

D Brain

Most primary brain tumours do not metastasise. Some brain tumours derived from neural elements do metastasise, but in these cases intra-parenchymal metastasis generally precedes distant haematogenous spread.

E Tongue

Head and neck tumours metastasise in less than 1% of cases, making this an unlikely cause of this patient's findings. If these tumours do metastasise, they commonly involve the lymph nodes and lungs.

A 45-year-old former television presenter is admitted with increasing confusion. Breast cancer was diagnosed six years ago and she had a lumpectomy of her right breast and local radiotherapy. Two years ago, she had further surgery and chemotherapy for a recurrence.

Her husband tells you she has become more confused over the last week. She has lost weight, has no appetite, feels sick and is constipated.

Medication comprises anostrozole, laxatives and morphine sulphate tablets together with antiemetics prn.

On examination, she is pale, agitated and looks dry. Her right arm is swollen. She is afebrile, pulse 104 bpm and regular, blood pressure 95/57 mmHg and her respirations are 20 breaths/min at rest. She is dull to percussion at the right lung base with decreased air entry. Her liver is non-tender and descends 4 cm below the right costal margin. The neurological examination is normal. Chest X-ray shows a pleural effusion at the right base. Urine is pale and dilute and negative for leukocytes and nitrites.

Results of blood tests show:

Na^+	136 mmol/l
K^+	3.4 mmol/l
Urea	16.3 mmol/l
Creatinine	142 µmol/l
Bilirubin	13 µmol/l
Glucose	6.1 mmol/l
Albumin	31 g/l
ALT	121 U/l
ALP	269 U/l
CRP	58 µg/l

4:41
On
594-042-7551
Leave

K^+	3.4 mmol/l
Urea	16.3 mmol/l
Creatinine	142 µmol/l
Bilirubin	13 µmol/l
Glucose	6.1 mmol/l
Albumin	31 g/l
ALT	121 U/l
ALP	269 U/l
CRP	58 µg/l
WCC	10.4×10^9/l
Hb	9.4 g/dl
PLT	347×10^9/l

What is the most likely cause of her confusion?

A Empyema

B Brain metastases

C Urinary tract Infection

D Sepsis of unknown origin

E Hypercalcaemia of malignancy

Audio
Video
Share
Participants
More

4:44
MyPastest
Home Feed | Re
Tumor Mar
https://mypastest.pastest.com/Secure/TestMe/Browse
Pastest+

E Hypercalcaemia of malignancy

Hypercalcaemia of malignancy is a paraneoplastic syndrome and the most common metabolic emergency in oncology and palliative care, affecting 40% of breast cancer and myeloma patients. Usually the corrected calcium concentration is > 2.8 mmol/l before the onset of symptoms. It presents with increasing thirst and polyuria (nephrogenic diabetes insipidus), anorexia, nausea and vomiting, constipation, dehydration and increasing confusion, and is easily confused with terminal disease progression. This patient exhibited many of the classic symptoms. Treatment is usually with intravenous (iv) fluids. If these fail to normalise calcium levels, iv bisphosphonates can be used. The calcium concentration usually takes two to three days to come down, and bisphosphonates may be required monthly to keep the level down. Both the enlarged liver and the pleural effusion which is likely non-infective in origin raise the possibility of hepatic and pleural metastases.

A Empyema

An empyema is a pus-filled space that develops in the pleural cavity usually after a bacterial infection in the lung. The reduced air entry at the right base and chest X-ray findings could raise empyema as a possibility, but you would expect the patient to have a temperature, a preceding chest infection, a cough and to have a higher respiratory rate, making this a far less likely diagnosis.

B Brain metastases

4:45
MyPastest
Home Feed | Re
Tumor Mar
https://mypastest.pastest.com/Secure/TestMe/Browse

C Urinary tract Infection

If the patient were to have urinary tract infection (UTI), we would expect her urine to be more concentrated, possibly cloudy and offensive smelling and for a urine dipstick to be positive for leukocytes and nitrites. However, in this patient's case, the urine was dilute and tested negative for leukocytes and nitrites, meaning a UTI is unlikely.

D Sepsis of unknown origin

This could be considered due to the blood results, which showed a raised C-Reactive Protein (CRP), and acute kidney injury coupled with hypotension and confusion could point towards sepsis. However, you would expect a raised temperature and tachycardia plus infective changes on the chest X-ray or a positive urine dipstick. This makes sepsis of unknown origin less likely as a diagnosis.

Rate this question:

Next Question

Previous Q... Tag Questi... Feedback End Session

Blog About Pastest Contact Us Help

© Pastest 2019

4:45
MyPastest
Home Feed | Re
Tumor Mar
https://mypastest.pastest.com/Secure/TestMe/Browse
Pastest+

A 57-year-old woman is found to have a white cell count (WCC) of 25×10^9/l (44% lymphocytes) during a routine screening at a menopausal clinic. She has mild hypertension treated with amlodipine 5 mg daily, but takes no other regular medications.

On examination, her blood pressure (BP) is 135/85 mmHg, with pulse 82/min and regular. Her body mass index (BMI) is 23. There is no lymphadenopathy or splenomegaly. Her haemoglobin (Hb) is 125 g/l and platelets 170×10^9/l. Renal function is normal.

What would be the most appropriate management in this case?

A	Start chlorambucil
B	Start fludarabine
C	Start alpha-interferon
D	Allogeneic bone marrow transplant
E	Wait and watch

7304

Submit

4:46
MyPastest
Home Feed | Re
Tumor Mar
https://mypastest.pastest.com/Secure/TestMe/Browse

with pulse 82/min and regular. Her body mass index (BMI) is 23. There is no lymphadenopathy or splenomegaly. Her haemoglobin (Hb) is 125 g/l and platelets 170 × 10^9/l. Renal function is normal.

What would be the most appropriate management in this case?

Your answer was correct

A	Start chlorambucil
B	Start fludarabine
C	Start alpha-interferon
D	Allogeneic bone marrow transplant
E	Wait and watch

Explanation

E Wait and watch

This lady most probably has chronic lymphocytic leukaemia (CLL). The disease may be asymptomatic and stable for many years. There is no advantage in starting treatment before there is a clinical indication such as anaemia, recurrent infections, bleeding, symptomatic lymphadenopathy, a rapidly increasing lymphocyte count or increasing splenomegaly. Her current stage according to

Rana Alnasser's screen

4:46

E Wait and watch

This lady most probably has chronic lymphocytic leukaemia (CLL). The disease may be asymptomatic and stable for many years. There is no advantage in starting treatment before there is a clinical indication such as anaemia, recurrent infections, bleeding, symptomatic lymphadenopathy, a rapidly increasing lymphocyte count or increasing splenomegaly. Her current stage according to the Rai and Binet staging systems for CLL is '0' or 'A', respectively, with a low risk. The median survival rate even without any treatment is more than 10 years.

A Start chlorambucil

Chlorambucil is used in patients with symptomatic CLL, although this is only recommended in combination therapy if fludarabine and bendamustine are unsuitable.

B Start fludarabine

Fludarabine isn't usually considered as monotherapy for CLL; it is used in combination with cyclophosphamide and rituximab.

C Start alpha-interferon

Alpha-interferon was previously considered for maintenance of remission in patients with CLL post-fludarabine therapy.

D Allogeneic bone marrow transplant

Allogenic stem cell transplant is considered for younger patients with CLL, but usually only once symptoms have appeared, and it is dependent on a good initial functional

Rana Alnasser's screen

A 22-year-old male student complains of increasing shortness of breath, severe backache, weight loss and bilateral supraclavicular adenopathy. He has a past history of an undescended left testicle which was corrected by surgery as a child.

On examination, there is evidence of bilateral supraclavicular lymphadenopathy and a large mass in the left inguinal area. A chest X-ray shows multiple coin lesions. An abdominal computerised tomography (CT) scan shows left-sided paravertebral lymph nodes and a large retroperitoneal mass behind the pancreas. A biopsy of the inguinal mass is arranged.

What other diagnostic test would be most helpful in determining the nature of the mass?

A	Lactate dehydrogenase (LDH)
B	Carcino-embryonic antigen (CEA)
C	Cancer antigen 19-9 (Ca 19-9)
D	Cancer antigen 125 (Ca 125)
E	Alpha-fetoprotein (AFP)

33424

Submit

A 22-year-old male student complains of increasing shortness of breath, severe backache, weight loss and bilateral supraclavicular adenopathy. He has a past history of an undescended left testicle which was corrected by surgery as a child.

On examination, there is evidence of bilateral supraclavicular lymphadenopathy and a large mass in the left inguinal area. A chest X-ray shows multiple coin lesions. An abdominal computerised tomography (CT) scan shows left-sided paravertebral lymph nodes and a large retroperitoneal mass behind the pancreas. A biopsy of the inguinal mass is arranged.

What other diagnostic test would be most helpful in determining the nature of the mass?

Your answer was incorrect

A Lactate dehydrogenase (LDH)

B Carcino-embryonic antigen (CEA)

C Cancer antigen 19-9 (Ca 19–9)

D Cancer antigen 125 (Ca 125)

E Alpha-fetoprotein (AFP)

Explanation

E Alpha-fetoprotein (AFP)

E Alpha-fetoprotein (AFP)

Testicular cancer primarily affects young men in the 20–44-year-old age group, where it is the most common cancer. Clinical presentation of testicular cancer varies considerably. Among serum tumour markers, elevated levels of AFP are seen with non-seminomatous germ cell tumours. Beta human chorionic gonadotropin (bHCG) is raised in the case of seminomatous germ cell tumours.

A Lactate dehydrogenase (LDH)

LDH is a marker of tumour bulk in solid cancers, eg lymphoma and testicular cancer, and is of prognostic significance, although it is not specific for the underlying tumour type.

B Carcino-embryonic antigen (CEA)

CEA is a non-specific marker used to monitor colorectal malignancies.

C Cancer antigen 19-9 (Ca 19–9)

Ca19-9 is often raised in pancreatic cancer, although it is used to monitor for recurrence rather than for making the initial diagnosis.

D Cancer antigen 125 (Ca 125)

Ca 125 is associated with ovarian and peritoneal tumours, and is not of value, therefore, in evaluating testicular cancer.

33424

Rate this question:

A 35-year-old patient who underwent orchidopexy surgery as a child comes to the clinic for review with an abnormal chest X-ray. He presented to the general practitioner (GP) with a chronic cough, occasionally productive of blood-stained sputum, and some shortness of breath. The chest X-ray report came back as suggesting the presence of multiple metastases.

On examination, you wonder whether the left testis is larger than the right, but it does not appear to be painful.

Investigations:

Haemoglobin (Hb)	11.5 g/dl
White cell count (WCC)	7.9×10^9/l
Platelet (PLT)	201×10^9/l
Sodium (Na^+)	139 mmol/l
Potassium (K^+)	4.4 mmol/l
Creatinine	130 µmol/l

Which of the following is the most appropriate next investigation?

A Beta-HCG

B Lactate dehydrogenase (LDH)

C Alpha-fetoprotein

D Testicular ultrasound

E Computerised tomography (CT) thorax

D Testicular ultrasound

Cryptorchidism is associated with a greatly increased risk of seminoma (10–40-fold), although surgery in many cases permits earlier detection of the tumour. Around 75% of patients present with localised disease, 15% with regional lymph node involvement and around 10% with distant metastases. Scrotal ultrasonography is the investigation of choice, with typical appearances revealing a hypoechoic mass with areas of calcification.

E Computerised tomography (CT) thorax

Although CT thorax may reveal anatomy consistent with lung metastases, and confirm their presence, it won't contribute to identifying the underlying cause.

A Beta-HCG

Beta-HCG levels are elevated in only around 10% of patients with seminomas, although the level, when elevated, may correlate with metastatic burden.

B Lactate dehydrogenase (LDH)

LDH is potentially of value in investigation of patients with possible teratomas, although it is a non-specific indicator of disease versus progressing to an ultrasound of the testes.

C Alpha-fetoprotein

AFP elevation is primarily associated with yolk sac tumours, and is also seen in hepatocellular carcinoma.

Rate this question:

4:56
On
594-042-7551
Leave

A 65-year-old woman presents to her general practitioner (GP) complaining of a painless lump in the lower part of her anterior neck, which was found incidentally as she was fiddling around with her necklace. She is otherwise fit and well and denies any recent chest or throat infections. She is a non-smoker.

On examination, the GP confirms the presence of a solitary hard, immobile lump measuring approximately 2 cm in the patient's lower anterior neck, which moves with swallowing and appears to be positioned in the thyroid gland. The patient is apyrexial and the remainder of the physical examination is normal. The patient is referred for a fine needle aspiration biopsy and relevant laboratory studies. The biopsy confirms that the patient has a papillary carcinoma of the thyroid. She undergoes total thyroidectomy and radioiodine treatment.

Which of the following is the most useful marker of tumour recurrence?

A	Alkaline phosphatase
B	Beta-HCG
C	Thyroglobulin
D	Thyroxine
E	Thyroid-stimulating hormone

Submit

Audio
Video
Share
Participants
More

C Thyroglobulin

Papillary carcinoma of the thyroid is the most common thyroid carcinoma and accounts for 80% of such cases. It is a slow-growing and well-differentiated carcinoma but it has a propensity for spread to the cervical lymph nodes. The male to female ratio is 1:3, with females having an overall better prognosis. Risk factors for developing this condition include excessive intake of iodine and external radiation to the neck. Thyroidectomy and radioiodine ablation are the mainstays of therapy. Since thyroglobulin is synthesised by well-differentiated thyroid carcinomas, it can serve as a useful tumour marker for assessment of recurrence of the tumour, but only after total thyroid ablation.

A Alkaline phosphatase

Alkaline phosphatase is elevated in the presence of bony metastases from well-differentiated thyroid cancer, although this would be a very late feature.

B Beta-HCG

Beta-HCG is useful in the monitoring of malignant germ cell rather than thyroid tumours.

D Thyroxine

Given that this patient requires thyroid hormone replacement, thyroxine is not useful as a marker of tumour recurrence.

E Thyroid-stimulating hormone

Like thyroxine, TSH cannot be used as a marker of tumour

4:58
MyPastest
Home Feed | Re
Tumor Ma
https://mypastest.pastest.com/Secure/TestMe/Brows

Pastest+

Question 17 of 44

A 55-year-old builder presents with a 3-week history of progressive shortness of breath, dry cough and right pleuritic chest pain.

A chest X-ray shows bilateral pleural plaques, a right-sided pleural effusion and associated irregular thickening of the pleura. Pleural biopsies confirm a diagnosis of mesothelioma.

Besides asbestos exposure, what other factor is thought to contribute most significantly to the aetiology of malignant mesothelioma?

A	Significant previous radiation exposure
B	Family history
C	Cigarette smoking
D	Previous lung operations
E	Exposure to fibreglass

Submit

Previous Q...
Skip Questi...

A Significant previous radiation exposure

There has been a link between significant radiation and mesothelioma noted. In those patients with radiation exposure, development of mesothelioma tends to occur more rapidly than in those patients who have asbestos exposure.

C Cigarette smoking

There has been no causal relationship identified between cigarette smoking and mesothelioma.

B Family history

There has not been any increase noted in the risk of developing mesothelioma if a patient has a family history of mesothelioma. Mesothelioma has historically been a disease attributed to exposure to asbestos.

D Previous lung operations

There has been no link noted between previous lung operations and mesothelioma.

E Exposure to fibreglass

There has been a link between all three types of asbestos (blue, brown and white) and mesothelioma. Mesothelioma does not usually develop until 10–60 years after exposure to asbestos, and for this reason it is often difficult to discover the exact cause. There has not been any causal relationship identified between exposure to other building materials and mesothelioma.

Rate this question:

Rana Alnasser's screen

5:02

A 59-year-old general practitioner (GP) with a previous history of alcoholism complains of deep, boring abdominal pain radiating through into the back. He smokes 10 cigarettes per day. There is a history of anorexia and weight loss over the past three months.

A computed tomography (CT) scan shows the presence of a mass 3 cm in diameter in the body of the pancreas. CA-19-9 levels are elevated, FNA reveals a ductal adenocarcinoma. He wants more information about his cancer.

Which of the following is true with regards to his disease?

A	He is likely to be cured with a Whipple's procedure
B	His tumour is likely to be insulin secreting
C	5-year survival is more than 20%
D	Smoking is likely to have contributed to the development of his cancer
E	Immunotherapy is proven to influence survival in the disease

53417

Submit

Rana Alnasser's screen

D Smoking is likely to have contributed to the development of his cancer

Smoking is thought to increase the risk of pancreatic cancer twofold, and in total smoking is thought to account for up to 30% of cases of the disease.

A He is likely to be cured with a Whipple's procedure

Only around 20% of patients are suitable to undergo resection, and in those who do, combination surgery and chemotherapy achieves a survival of around 20% at 5 years.

B His tumour is likely to be insulin secreting

Pancreatic cancer is usually ductal adenocarcinoma in histology, and is exocrine rather than endocrine in nature.

C 5-year survival is more than 20%

5-year survival only approaches 20% when resection is possible; where it isn't, survival is less than 5%.

E Immunotherapy is proven to influence survival in the disease

Although immunotherapy (involving activated T cells and vaccination against pancreatic carcinoma cell antigens) shows promise, as yet it is not proven to impact on survival in the disease.

Rate this question:

5:05

A 60-year-old man complains of progressive breathlessness on walking up stairs and weight loss of 1 stone in the last six months. He has had longstanding obstructive urinary symptoms over the past three to four years. He has experienced some vague generalised abdominal pains and denies any change in bowel symptoms. He is a non-smoker.

Investigations:

Haemoglobin (Hb)	8.5 g/l
Mean corpuscular volume (MCV)	65 fl
Ferritin	15–16 µg/l
Total Iron Binding Capacity (TIBC)	450 mg/dl (200–400 mg/dl)
Urine dipstick	Blood and protein both negative

What most appropriate further investigation/s should be done next to make the diagnosis?

A Bone marrow trephine

B Cystoscopy

C Colonscopy and upper gastrointestinal endoscopy

D Barium enema

E Haemoglobin electrophoresis

Rana Alnasser's screen

5:07

C Colonscopy and upper gastrointestinal endoscopy

A man of any age with an unexplained iron deficiency anaemia and a haemoglobin of 11 g/100 ml or below should be urgently referred for a upper gastrointestinal (GI) endoscopy and colonoscopy to exclude an upper or lower gastrointestinal malignancy. The absence of symptoms raises the possibility of a right-sided colonic tumour. Faecal occult blood (FOB) test on stool is a means of screening for lower GI malignancies. A false negative may be caused by ingestion of large doses of vitamin C or by not collecting multiple samples, as many conditions only bleed intermittently. False-positive results may arise as a consequence of other causes of bleeding, other sources of haemoglobin, such as eating red meat, or by ingesting substances that will react with the test such as fish, turnips, horseradish or oxidising drugs.

A Bone marrow trephine

This is a potentially unpleasant and unnecessary procedure, and given that ferritin is low, chronic blood loss should be excluded first before considering other explanations for anaemia.

B Cystoscopy

There is no blood on the urine dipstick, and whilst this doesn't exclude intermittent blood loss from the GU tract, GI tract blood loss should be excluded first.

D Barium enema

Barium enema is less sensitive than colonoscopy with respect to pick-up of any underlying malignant polyp. As such, colonoscopy is preferred here.

Rana Alnasser's screen

Faecal occult blood (FOB) test on stool is a means of screening for lower GI malignancies. A false negative may be caused by ingestion of large doses of vitamin C or by not collecting multiple samples, as many conditions only bleed intermittently. False-positive results may arise as a consequence of other causes of bleeding, other sources of haemoglobin, such as eating red meat, or by ingesting substances that will react with the test such as fish, turnips, horseradish or oxidising drugs.

A Bone marrow trephine

This is a potentially unpleasant and unnecessary procedure, and given that ferritin is low, chronic blood loss should be excluded first before considering other explanations for anaemia.

B Cystoscopy

There is no blood on the urine dipstick, and whilst this doesn't exclude intermittent blood loss from the GU tract, GI tract blood loss should be excluded first.

D Barium enema

Barium enema is less sensitive than colonoscopy with respect to pick-up of any underlying malignant polyp. As such. colonoscopy is preferred here.

E Haemoglobin electrophoresis

Although sickle cell trait is a possible cause of microcytic anaemia, the vague abdominal pains and low ferritin point us towards blood loss as the more likely cause of the presentation here.

Rate this question:

5:09

A 45-year-old woman had stage II breast cancer and was treated with surgery, adjuvant chemotherapy and radiotherapy. The cancer was oestrogen receptor positive and progesterone receptor negative. Following the radiotherapy, she was given tamoxifen. The patient's periods had stopped before completion of the chemotherapy course and she now complains of debilitating hot flushes.

Which of the following can you recommend?

A	Replacement oestrogen therapy
B	Megestrol
C	Reassurance
D	Soy products
E	Green tea

Submit

Previous Q... Skip Questi...

Rana Alnasser's screen

A 45-year-old woman had stage II breast cancer and was treated with surgery, adjuvant chemotherapy and radiotherapy. The cancer was oestrogen receptor positive and progesterone receptor negative. Following the radiotherapy, she was given tamoxifen. The patient's periods had stopped before completion of the chemotherapy course and she now complains of debilitating hot flushes.

Which of the following can you recommend?

Your answer was incorrect

A Replacement oestrogen therapy

B Megestrol

C Reassurance

D Soy products

E Green tea

Explanation

B Megestrol

Certain chemotherapies can induce a medical menopause. Hot flushes can get worse when tamoxifen (or other anti-oestrogen therapies) are added after chemotherapy. Although these drugs don't cause menopause, they can mimic some of the symptoms which may then continue for some time. Progesterone in low doses is effective in

B Megestrol

Certain chemotherapies can induce a medical menopause. Hot flushes can get worse when tamoxifen (or other anti-oestrogen therapies) are added after chemotherapy. Although these drugs don't cause menopause, they can mimic some of the symptoms, which may then continue for some time. Progesterone in low doses is effective in relieving hot flushes. Commonly prescribed drugs include megoestrol (Megace), medroxyprogesterone (Provera) and norethisterone (Primolut N, Utovlan). There is some evidence that the antidepressant drugs venlafaxine and fluoxetine can be effective for some women. They are given in lower doses than when they are prescribed for depression, and are not expected to have antidepressant effects.

C Reassurance

Symptoms of the menopause can be extremely debilitating. Offering a therapy intervention with progesterone replacement is therefore considered essential.

A Replacement oestrogen therapy

Given that HRT is associated with increased risk of breast cancer, it is generally avoided in patients with the condition.

D Soy products

Soy products are rich in isoflavones, which are thought to act as phyto-oestrogens. They are not thought to increase breast density and impact on risk of breast cancer, but in this situation progesterone is preferred.

E Green tea

evidence that the antidepressant drugs venlafaxine and fluoxetine can be effective for some women. They are given in lower doses than when they are prescribed for depression, and are not expected to have antidepressant effects.

C Reassurance

Symptoms of the menopause can be extremely debilitating. Offering a therapy intervention with progesterone replacement is therefore considered essential.

A Replacement oestrogen therapy

Given that HRT is associated with increased risk of breast cancer, it is generally avoided in patients with the condition.

D Soy products

Soy products are rich in isoflavones, which are thought to act as phyto-oestrogens. They are not thought to increase breast density and impact on risk of breast cancer, but in this situation progesterone is preferred.

E Green tea

Although green tea may positively impact on weight control, it may worsen symptoms of menopause and isn't therefore the default intervention here.

Rate this question:

Next Question

A 19-year-old man presents to the clinic with symptoms of lethargy and weight loss. He has a past history of orchidopexy for an undescended testis, but nil else of note.

On examination, he looks thin, with a body mass index (BMI) of 18, and he has gynaecomastia. Testicular examination reveals no abnormal masses.

Investigations:

Haemoglobin (Hb)	12.9 g/dl
White cell count (WCC)	8.1×10^9/l
Platelet (PLT)	201×10^9/l
Sodium (Na^+)	138 mmol/l
Potassium (K^+)	4.3 mmol/l
Creatinine	95 µmol/l
Follicle-stimulating hormone (FSH)/ Luteinizing hormone (LH)	Low
Alpha-fetoprotein (AFP)	Normal
Carcino-embryonic antigen (CEA)	Normal
Human chorionic gonadotrophin (b-HCG)	Markedly elevated
Alanine transaminase (ALT)	130 U/l
Alkaline phosphatase (ALP)	258 U/l

Which of the following is the most likely diagnosis?

A Hepatoma

B Seminoma

Investigations:

Haemoglobin (Hb)	12.9 g/dl
White cell count (WCC)	8.1×10^9/l
Platelet (PLT)	201×10^9/l
Sodium (Na^+)	138 mmol/l
Potassium (K^+)	4.3 mmol/l
Creatinine	95 µmol/l
Follicle-stimulating hormone (FSH)/ Luteinizing hormone (LH)	Low
Alpha-fetoprotein (AFP)	Normal
Carcino-embryonic antigen (CEA)	Normal
Human chorionic gonadotrophin (b-HCG)	Markedly elevated
Alanine transaminase (ALT)	130 U/l
Alkaline phosphatase (ALP)	258 U/l

Which of the following is the most likely diagnosis?

A Hepatoma

B Seminoma

C Teratoma

D Testicular choriocarcinoma

E Hepatocellular carcinoma

D Testicular choriocarcinoma

Pure testicular choriocarcinomas are rare, but they are associated with marked elevation in b-HCG in the presence of a normal AFP and CEA. The abnormal LFTs here suggest that metastases have already occurred. It is not unusual for the primary tumour to be very small and go undetected on testicular examination. Scrotal ultrasound is used to support the diagnosis, and staging computerised tomography (CT) scans are of significant value. Choriocarcinoma is extremely sensitive to cisplatin-based chemotherapy, with cure rates of up to 80% being achievable, even in advanced disease.

B Seminoma

Classical seminomas are associated with a rise in placental alkaline phosphatase in 50% of cases. B-HCG may also be elevated, but not to the marked level seen here.

A Hepatoma

AFP is markedly elevated in hepatocellular carcinoma. Beta-HCG is not elevated in patients with hepatoma.

C Teratoma

AFP is elevated in a significant proportion of patients with a teratoma,; the marked elevation in beta-HCG seen here is not a usual feature.

E Hepatocellular carcinoma

Hepatocellular carcinoma is associated with rising levels of AFP, and it is also usually associated with worsening features of chronic liver disease such as ascites.

that metastases have already occurred. It is not unusual for the primary tumour to be very small and go undetected on testicular examination. Scrotal ultrasound is used to support the diagnosis, and staging computerised tomography (CT) scans are of significant value. Choriocarcinoma is extremely sensitive to cisplatin-based chemotherapy, with cure rates of up to 80% being achievable, even in advanced disease.

B Seminoma

Classical seminomas are associated with a rise in placental alkaline phosphatase in 50% of cases. B-HCG may also be elevated, but not to the marked level seen here.

A Hepatoma

AFP is markedly elevated in hepatocellular carcinoma. Beta-HCG is not elevated in patients with hepatoma.

C Teratoma

AFP is elevated in a significant proportion of patients with a teratoma,; the marked elevation in beta-HCG seen here is not a usual feature.

E Hepatocellular carcinoma

Hepatocellular carcinoma is associated with rising levels of AFP, and it is also usually associated with worsening features of chronic liver disease such as ascites.

Rate this question:

Next Question

A 50-year-old patient with newly diagnosed colorectal cancer has a severe peripheral neuropathy secondary to poorly controlled diabetes.

Which drug should be avoided most when planning treatment?

A	5-Fluorouracil
B	Irinotecan
C	Capecitabine
D	Cetuximab
E	Oxaliplatin

Submit

Previous Q... Skip Questi...

© Pastest 2019

Rana Alnasser's screen

5:19
On
594-042-7551
Leave

A 50-year-old patient with newly diagnosed colorectal cancer has a severe peripheral neuropathy secondary to poorly controlled diabetes.

Which drug should be avoided most when planning treatment?

Your answer was correct

A	5-Fluorouracil
B	Irinotecan
C	Capecitabine
D	Cetuximab
E	Oxaliplatin

Explanation

E Oxaliplatin

Although oxaliplatin is a commonly used chemotherapy agent, it commonly causes peripheral neuropathy to varying degrees in patients receiving it. Often patients complain of numbness and tingling, which are often triggered by extremes in temperatures, more often by the cold. Patients can see progression of symptoms as their treatment course progresses. Dose reductions can be made or cessation of treatment can be considered. However, damage can be irreversible leaving patients with the long term consequences of their treatment. Other side

Audio Video Share Participants More

5:19
On
594-042-7551
Leave

E Oxaliplatin

Although oxaliplatin is a commonly used chemotherapy agent, it commonly causes peripheral neuropathy to varying degrees in patients receiving it. Often patients complain of numbness and tingling, which are often triggered by extremes in temperatures, more often by the cold. Patients can see progression of symptoms as their treatment course progresses. Dose reductions can be made or cessation of treatment can be considered. However, damage can be irreversible leaving patients with the long-term consequences of their treatment. Other side effects include nausea and vomiting, diarrhoea, mouth sores, low blood counts and fatigue.

A 5-Fluorouracil

Common side effects of 5-FU include diarrhoea, nausea and vomiting, mucositis, anorexia, photophobia, changes in taste (especially metallic taste) and low blood counts.

B Irinotecan

Common side effects of irinotecan include diarrhoea, nausea and vomiting, weakness and low blood counts. Any form of neurological damage is not a common side effect of this chemotherapy agent.

C Capecitabine

Capecitabine is an oral form of 5-FU. As such, it has a similar side effect profile including low blood counts, palmar-plantar erythrodysaesthesia, diarrhoea, abnormal liver function tests (LFTs), fatigue, nausea and vomiting, rash and itching and abdominal pain.

D Cetuximab

Audio Video Share Participants More

sores, low blood counts and fatigue.

A 5-Fluorouracil

Common side effects of 5-FU include diarrhoea, nausea and vomiting, mucositis, anorexia, photophobia, changes in taste (especially metallic taste) and low blood counts.

B Irinotecan

Common side effects of irinotecan include diarrhoea, nausea and vomiting, weakness and low blood counts. Any form of neurological damage is not a common side effect of this chemotherapy agent.

C Capecitabine

Capecitabine is an oral form of 5-FU. As such, it has a similar side effect profile including low blood counts, palmar-plantar erythrodysaesthesia, diarrhoea, abnormal liver function tests (LFTs), fatigue, nausea and vomiting, rash and itching and abdominal pain.

D Cetuximab

Cetuximab is a monoclonal antibody and epidermal growth factor receptor inhibitor. It is used in the treatment of metastatic colorectal cancer, squamous cell head, neck and skin cancer and for non-small cell lung cancer. Common side effects include skin reaction, diarrhoea, fatigue, nausea and vomiting, abdominal pain, nail changes, infection, stomatitis, low blood counts and abnormal LFTs. Some patients do complain of peripheral neuropathy, but there is another drug within this question that has a greater incidence of peripheral neuropathy.

Rate this question:

A 61-year-old police chief is admitted with a sudden-onset loss of power in his lower limbs. He was diagnosed with a right renal cell carcinoma 18 months ago and at laparotomy was found to have intraperitoneal spread. He has had increasing mid-back pain over the last two weeks. He last passed urine the previous night and opened his bowels a couple of days ago. This morning, he could not get out of bed.

On examination, he looks anxious but otherwise well. Neurological examination demonstrates: increased tone in his lower limbs and no power in his legs; a sensory level at T6 to light touch and pin-prick; brisk knee and ankle reflexes and upgoing plantars; and normal upper limbs and central nervous system. Chest X-ray reveals two cannonball metastases in his right lung and three in his left. A urinary catheter has been inserted and a residual of 1.4 litres of urine has drained out. A provisional diagnosis of cord compression has been made.

Which of the following investigations will best help management?

A	Bone scan
B	X-ray dorsal spine
C	MRI whole spine
D	CT thoracic spine
E	Contrast myelography

Submit

C MRI whole spine

An MRI will give information regarding both soft tissues and bony material. This is extremely helpful in identifying areas of spinal cord compression. The benefit of including the whole spine is that any other current or impending areas of spinal cord compression can be identified and pre-emptively treated with radiotherapy.

The working differential in a patient with known metatstatic cancer with back pain, altered neurology and urinary retention would be spinal cord compression. Immediate management would consist of bed rest and high-dose dexamethasone (usually 16 mg OD) with PPI cover to try and reduce the swelling around the vertebral body. This is usually followed by radiotherapy, but in some cases it may be worth liaising with the spinal surgeons as they may offer surgery to the patient. As a rule of thumb, they tend to want a patient to have a life expectancy of >6 months to offer surgery, as that is the approximate recovery time.

A Bone scan

A bone scan can be useful in identifying evidence of bony metastases. However, it gives little or no information regarding soft tissues, such as spinal cord, which are in close proximity. Using a bone scan we will not be able to identify areas of spinal cord compression, which is essential in correctly diagnosing this patient and also for planning of future treatment.

B X-ray dorsal spine

An X-ray of the dorsal spine will only give information regarding the vertebrae and not about any soft tissue and is, therefore, not the best image modality to use.

A 62-year-old woman is undergoing cycles of chemotherapy with a paclitaxel- and trastuzumab-based regime. As per guidance, she is monitored after every cycle of chemotherapy for changes in her ejection fraction. After the second cycle, she develops increased shortness of breath and reduced exercise tolerance. Ejection fraction has reduced from 54% at baseline to 40%. Her blood pressure is 105/82 mmHg. There are bi-basal crackles on auscultation of the chest, although there is no ankle swelling.

Which of the following is the most appropriate next step?

A	Start bisoprolol
B	Start furosemide
C	Start ramipril
D	Start valsartan
E	Temporarily discontinue trastuzumab

Submit

A 62-year-old woman is undergoing cycles of chemotherapy with a paclitaxel- and trastuzumab-based regime. As per guidance, she is monitored after every cycle of chemotherapy for changes in her ejection fraction. After the second cycle, she develops increased shortness of breath and reduced exercise tolerance. Ejection fraction has reduced from 54% at baseline to 40%. Her blood pressure is 105/82 mmHg. There are bi-basal crackles on auscultation of the chest, although there is no ankle swelling.

Which of the following is the most appropriate next step?

Your answer was correct

A Start bisoprolol

B Start furosemide

C Start ramipril

D Start valsartan

E Temporarily discontinue trastuzumab

Explanation

E Temporarily discontinue trastuzumab

Guidance from the prescribing information on trastuzumab is clear: that it should be discontinued when there is a 10% or worse deterioration in ejection fraction. The statement

E Temporarily discontinue trastuzumab

Guidance from the prescribing information on trastuzumab is clear: that it should be discontinued when there is a 10% or worse deterioration in ejection fraction. The statement from the drug information leaflet is reproduced below:

'If LVEF drops 10 ejection fraction (EF) points from baseline AND to below 50%, treatment should be suspended and a repeat LVEF assessment performed within approximately three weeks. If LVEF has not improved, or declined further, discontinuation of Herceptin™ should be strongly considered, unless the benefits for the individual patient are deemed to outweigh the risks. All such patients should be referred for assessment by a cardiologist and followed up'.

The her2 receptor is thought to play a key role in protection against the development of cardiomyopathy. As such, antagonising her2 with trastuzumab significantly increases the risk of development of cardiomyopathy (see weblink below).

A Start bisoprolol

Although bisoprolol does improve outcomes in heart failure, there is limited scope to institute beta blockade given her blood pressure, and it's more important to discontinue the causative agent.

B Start furosemide

Limited fluid retention means that offloading with diuretics will only have a minor impact at best on her symptoms.

C Start ramipril

Angiotensin-converting enzyme (ACE) inhibitors are the intervention of choice in this scenario in the event that

5:25
On
594-042-7551
Leave
MyPastest
Home Feed | Re
Tumor Ma
https://mypastest.pastest.com/Secure/TestMe/Browse

B Start furosemide

Limited fluid retention means that offloading with diuretics will only have a minor impact at best on her symptoms.

C Start ramipril

Angiotensin-converting enzyme (ACE) inhibitors are the intervention of choice in this scenario in the event that ejection fraction does not improve given the cessation of trastuzumab.

D Start valsartan

ARBs such as valsartan would be considered in the event that ACE inhibition is not tolerated – for example, due to chronic cough.

Rate this question:

Previous Q... Tag Questi... Feedback End Session

Blog About Pastest Contact Us Help

Scroll capture
Draw
Crop
Audio Video Share Participants More

5:25

MyPastest | Home Feed | Tumor Ma

https://mypastest.pastest.com/Secure/TestMe/Browse

Pastest+

A 49-year-old woman presents to the clinic with rectal (PR) bleeding and change in bowel habit. She has been feeling increasingly lethargic over the past few months. You understand that her father died of colonic carcinoma at the age of 58. She has no other significant history of note.

On examination, her body mass index (BMI) is 21, performance status is 1 and her blood pressure (BP) is 142/70 mmHg. There are no abnormal external findings and her abdomen is soft and non-tender.

Investigations:

Haemoglobin (Hb)	10.9 g/dl
White cell count (WCC)	8.1×10^9/l
Platelet (PLT)	201×10^9/l
Erythrocyte sedimentation rate (ESR)	45 mm/hr
Sodium (Na^+)	139 mmol/l
Potassium (K^+)	4.5 mmol/l
Creatinine	100 µmol/l
Flexible colonoscopy	Sigmoid carcinoma
Computerised tomography (CT) abdomen	Annular sigmoid carcinoma with two liver metastases in the right lobe, each 1 cm in diameter

Which of the following is the most appropriate management?

5:26
MyPastest
Home Feed | Re
Tumor Ma
https://mypastest.pastest.com/Secure/TestMe/Browse
Pastest+

Platelet (PLT)	201×10^9/l
Erythrocyte sedimentation rate (ESR)	45 mm/hr
Sodium (Na^+)	139 mmol/l
Potassium (K^+)	4.5 mmol/l
Creatinine	100 µmol/l
Flexible colonoscopy	Sigmoid carcinoma
Computerised tomography (CT) abdomen	Annular sigmoid carcinoma with two liver metastases in the right lobe, each 1 cm in diameter

Which of the following is the most appropriate management?

A Surgical resection of the primary cancer and liver metastases + chemotherapy

B Surgical resection of the primary cancer and liver metastases

C Radical radiotherapy

D Radiofrequency ablation

E Combined chemo- and radical radiotherapy to the primary tumour

5:26
MyPastest
Home Feed | Re
Tumor Ma
https://mypastest.pastest.com/Secure/TestMe/Browse

Creatinine	100 µmol/l
Flexible colonoscopy	Sigmoid carcinoma
Computerised tomography (CT) abdomen	Annular sigmoid carcinoma with two liver metastases in the right lobe, each 1 cm in diameter

Which of the following is the most appropriate management?

Your answer was correct

A Surgical resection of the primary cancer and liver metastases + chemotherapy

B Surgical resection of the primary cancer and liver metastases

C Radical radiotherapy

D Radiofrequency ablation

E Combined chemo- and radical radiotherapy to the primary tumour

Explanation

A Surgical resection of the primary cancer and liver metastases + chemotherapy

A Surgical resection of the primary cancer and liver metastases + chemotherapy

Given this woman's young age and lack of significant comorbidities, attempting curative surgical resection of both the primary tumour and isolated right lobe liver metastases would seem appropriate. Although this patient has two metastases, they are both small and hence are still amenable to resection. A multivariate analysis of 1001 patients identified size > 5 cm, presence of more than one tumour, primary lymph node positivity and markedly elevated carcinoembryonic antigen (CEA) as factors associated with poor outcome. There is now evidence which supports the use of chemotherapy either in the neoadjuvant (preferably) or the adjuvant setting, and combination surgery and chemotherapy is the best approach especially in a young patient with a good performance status. Chemotherapy is seen to have an additive benefit in terms of survival. Therefore, this surgery and chemotherapy combined approach is superior to surgical resection of the primary cancer and liver metastases alone.

B Surgical resection of the primary cancer and liver metastases

It is a potential treatment option but there is evidence for superior outcomes with the addition of chemotherapy either in the adjuvant and neo-adjuvant setting.

C Radical radiotherapy

This is a treatment option for rectal cancer as it is immobile and fixed within the pelvis. However, in colonic cancer, radiotherapy is usually only utilised in the palliative setting due to the significant risk of bowel perforation with radical doses. Furthermore, radical radiotherapy to the liver is fraught with danger. This young patient has potentially

5:28
MyPastest
Home Feed | Re
Tumor Ma
https://mypastest.pastest.com/Secure/TestMe/Browse

Pastest+

A 45-year-old woman presents with frequent headaches, excessive sweating, reduction in peripheral vision, deepening of her voice and amenorrhoea. She has also noticed a prominence of her lower jaw.

On examination, there is mild hirsutism. Visual tests show bitemporal hemianopia. Investigations reveal a fasting blood glucose of 7.8 mmol/l and a 2-h post-prandial value of 12.5 mmol/l. Prolactin is elevated at 1000. Her BP is elevated at 165/99 mmHg. An MRI scan shows a 20 mm pituitary adenoma.

What would be the most appropriate line of management in this case?

A	Cabergoline followed by trans-sphenoidal surgery
B	Trans-sphenoidal surgery
C	External radiotherapy followed by octreotide
D	Somatostatin analogue followed by trans-sphenoidal surgery
E	Pegvisomant in combination with a somatostatin analogue

Submit

5:29

MyPastest | Home Feed | Tumor Marke

https://mypastest.pastest.com/Secure/TestMe/Browse

Pastest+

A 45-year-old woman presents with frequent headaches, excessive sweating, reduction in peripheral vision, deepening of her voice and amenorrhoea. She has also noticed a prominence of her lower jaw.

On examination, there is mild hirsutism. Visual tests show bitemporal hemianopia. Investigations reveal a fasting blood glucose of 7.8 mmol/l and a 2-h post-prandial value of 12.5 mmol/l. Prolactin is elevated at 1000. Her BP is elevated at 165/99 mmHg. An MRI scan shows a 20 mm pituitary adenoma.

What would be the most appropriate line of management in this case?

A	Cabergoline followed by trans-sphenoidal surgery
B	Trans-sphenoidal surgery
C	External radiotherapy followed by octreotide
D	Somatostatin analogue followed by trans-sphenoidal surgery
E	Pegvisomant in combination with a somatostatin analogue

7301

Submit

Rana Alnasser's screen

5:31
https://mypastest.pastest.com/Secure/TestMe/Browse

Explanation

D	Somatostatin analogue followed by trans-sphenoidal surgery

Somatostatin analogues are associated with tumour shrinkage and resolution of some clinical symptoms, following which trans-sphenoidal surgery is performed. Reduction in tumour size makes subsequent surgery much easier.

References:

Lake MG, Krook LS, Cruz SV; Pituitary adenomas: an overview. *Am Fam Physician*. 2013 Sep 1 88(5):319–27.

Colao A, Auriemma RS, Pivonello R; The effects of somatostatin analogue therapy on pituitary tumour volume in patients with acromegaly. *Pituitary*. 2016. 19 (2):210.

A	Cabergoline followed by trans-sphenoidal surgery

Cabergoline is a very effective treatment for prolactinoma. This patient has a raised prolactin level, but this is likely to be due to pressure effect rather than as a result of a primary prolactinoma. Regardless, carbegoline is likely to be given in isolation rather than with trans-sphenoidal surgery.

B	Trans-sphenoidal surgery

Trans-sphenoidal surgery in isolation can be performed but medical management is preferred, and if surgery is performed it is usually following treatment with somatostatin analogues.

Rana Alnasser's screen

5:31
On
594-042-7551
Leave

Cabergoline is a very effective treatment for prolactinoma. This patient has a raised prolactin level, but this is likely to be due to pressure effect rather than as a result of a primary prolactinoma. Regardless, carbegoline is likely to be given in isolation rather than with trans-sphenoidal surgery.

B Trans-sphenoidal surgery

Trans-sphenoidal surgery in isolation can be performed but medical management is preferred, and if surgery is performed it is usually following treatment with somatostatin analogues.

C External radiotherapy followed by octreotide

Radiotherapy is not the first-line treatment of choice in patients with a pituitary adenoma and has been shown to reduce prolactin levels in only approximately 25% of patients. There is also the risk of hypopituitarism as well as localised neurological damage. Radiotherapy can be considered further down the line if the patient is hypersecretory and if the tumour is not fully resected. Octreotide can be used to treat patients with acromegaly, but again this option would not be the first-line treatment.

E Pegvisomant in combination with a somatostatin analogue

Pegvisomant and somatostatins are commonly used individually in clinical practice, but are only licensed for use in combination in patients where there is an effective response with somatostatin analogues alone.

Rate this question:
Audio Video Share Participants More

A 54-year-old lifelong smoker presents with a 2-week history of gradually worsening confusion, abdominal pain and constipation. He admits to a chronic cough which has worsened over the past six to eight months, and that he has lost 5 kg in weight.

On examination, his blood pressure (BP) is 152/82, with pulse 79 and regular. There is bilateral wheeze on auscultation of the chest consistent with COPD. He looks thin, with a BMI of 21.

Investigations:

Sodium (Na^+)	135 mmol/l
Potassium (K^+)	4.5 mmol/l
Creatinine	120 µmol/l
Urea	8.0 mmol/l
Calcium	2.94 mmol/l
Albumin	28 g/l
Alkaline phosphatase (ALP)	165 U/l (20–120 U/l)
Parathyroid hormone (PTH)	5 pg/ml (10–65 pg/ml)

What is the most likely cause of his hypercalcaemia?

A Lytic bony metastases

B Parathyroid-related peptide-associated hypercalcaemia

C Primary hyperparathyroidism

D Hypoparathyroidism

E Secondary hyperparathyroidism

thin, with a BMI of 21.

Investigations:

Sodium (Na^+)	135 mmol/l
Potassium (K^+)	4.5 mmol/l
Creatinine	120 µmol/l
Urea	8.0 mmol/l
Calcium	2.94 mmol/l
Albumin	28 g/l
Alkaline phosphatase (ALP)	165 U/l (20–120 U/l)
Parathyroid hormone (PTH)	5 pg/ml (10–65 pg/ml)

What is the most likely cause of his hypercalcaemia?

A Lytic bony metastases

B Parathyroid-related peptide-associated hypercalcaemia

C Primary hyperparathyroidism

D Hypoparathyroidism

E Secondary hyperparathyroidism

33428

Submit

B Parathyroid-related peptide-associated hypercalcaemia

The low parathyroid hormone seen here, accompanied by hypercalcaemia, points us towards parathyroid hormone-related peptide (PTHrp) as the cause of this patient's disease. PTH stimulates bone resorption and formation, whereas PTHrP stimulates bone resorption with lower osteoblastic activity, and thus alkaline phosphatase levels are usually only just above the normal range. Elevated PTHrp is most commonly seen with squamous cell carcinomas of the lung (as is likely in this case), oesophagus, cervix, head and neck.

Treatment is aimed at reducing the tumour burden (chemotherapy or radiotherapy), reducing osteoclastic resorption of the bone (bisphosphonates) and increasing urinary calcium excretion (diuretics with careful attention to fluid balance).

A Lytic bony metastases

Lytic bony metastases rarely lead to significant hypercalcaemia. Elevation in calcium may be particularly seen when patients with lytic metastases spend a large period of time recumbent in bed.

C Primary hyperparathyroidism

Primary hyperparathyroidism is effectively excluded here by the low PTH in the presence of hypercalcaemia.

D Hypoparathyroidism

Hypoparathyroidism is of course associated with hypocalcaemia, not with elevated levels of serum calcium.

carcinomas of the lung (as is likely in this case), oesophagus, cervix, head and neck.

Treatment is aimed at reducing the tumour burden (chemotherapy or radiotherapy), reducing osteoclastic resorption of the bone (bisphosphonates) and increasing urinary calcium excretion (diuretics with careful attention to fluid balance).

A Lytic bony metastases

Lytic bony metastases rarely lead to significant hypercalcaemia. Elevation in calcium may be particularly seen when patients with lytic metastases spend a large period of time recumbent in bed.

C Primary hyperparathyroidism

Primary hyperparathyroidism is effectively excluded here by the low PTH in the presence of hypercalcaemia.

D Hypoparathyroidism

Hypoparathyroidism is of course associated with hypocalcaemia, not with elevated levels of serum calcium.

E Secondary hyperparathyroidism

The low PTH and relatively normal renal function effectively rule this out as the cause of hypercalcaemia.

33428

Rate this question:

Next Question

A 53-year-old woman presents to her general practitioner (GP) with a painless mass in the lower right quadrant of her left breast associated with new-onset nipple discharge. The patient is extremely anxious as there is a strong family history of breast cancer within her family. A diagnosis of breast cancer is strongly suspected and she is referred to the triple breast assessment clinic. A subsequent biopsy confirms a diagnosis of breast cancer.

The patient then goes on to have surgery to remove her breast mass, which is successfully carried out with good margins. She is also noted as having positive lymph nodes and is listed for discussion at the MDT. In the meantime, she contacts the breast cancer nurses as she is concerned about the results. Her main concern is regarding the prognosis.

For the MDT, which of the following is most useful in determining her breast cancer prognosis?

A Location of the tumour

B Size of the tumour

C Extent of skin involvement

D Histological grading

E Lymph node metastases

Submit

E Lymph node metastases

Lymph node metastases confirm that the cancer has spread outside of the breast, albeit to adjacent lymph nodes. Lymph node metastases, along with tumour size and histological grading, are key determinants in the Nottingham prognostic index which is used to determine prognosis following surgery. Out of all three of these factors, lymph node metastases have the greatest impact on future prognosis.

Nottingham prognostic index:

NPI = [0.2 × S] + N + G

S = size of the lesion in cm

N = node status (0 nodes = 1, 1-4 nodes = 2, > 4 nodes = 3)

G = tumour grade (Grade I = 1, Grade II = 2, Grade III = 3)

A Location of the tumour

Location of tumour is important when assessing treatment options such as surgery and radiotherapy, but does not directly affect prognosis.

B Size of the tumour

Size of the tumour can affect prognosis, with a larger tumour often leading to a poorer prognosis but this is not the greatest factor out of those listed.

C Extent of skin involvement

Skin involvement, such as peau d'orange (orange peel skin), can be a sign of breast cancer but is difficult to quantify and is not used as a prognostic indicator.

5:37
On
594-042-7551
Leave
MyPastest
Home Feed | Re
Tumor Mark
https://mypastest.pastest.com/Secure/TestMe/Browse

Pastest+

G = tumour grade (Grade I = 1, Grade II = 2, Grade III = 3)

A Location of the tumour

Location of tumour is important when assessing treatment options such as surgery and radiotherapy, but does not directly affect prognosis.

B Size of the tumour

Size of the tumour can affect prognosis, with a larger tumour often leading to a poorer prognosis but this is not the greatest factor out of those listed.

C Extent of skin involvement

Skin involvement, such as peau d'orange (orange peel skin), can be a sign of breast cancer but is difficult to quantify and is not used as a prognostic indicator.

D Histological grading

Histological grading gives information regarding how aggressive a tumour is and can be instrumental in determining prognosis. However, the question asks for the 'most useful factor' in determining prognosis and histological grading is not the most useful factor.

Rate this question:

Next Question

Audio
Video
Share
Participants
More

A 43-year-old man is reviewed in the Endocrinology Clinic and given a diagnosis of Cushing's disease with a 0.9 cm pituitary adenoma. He has multiple medical problems including severe hypertension currently managed with three agents, poorly controlled diabetes mellitus and morbid obesity.

On examination, his blood pressure (BP) is 166/95 mmHg, pulse is 75/min and regular. His body mass index (BMI) is 38. He has bilateral lower limb swelling with severe varicose veins.

Investigations:

Haemoglobin (Hb)	14.1 g/dl
White cell count (WCC)	8.9×10^9/l
Platelet (PLT)	258×10^9/l
Sodium (Na^+)	138 mmol/l
Potassium (K^+)	3.5 mmol/l
Creatinine	132 micromol/l
Glucose	15.1 mmol/l

Which of the following is the most appropriate next step?

A Proceed directly to trans-sphenoidal resection

B Start mitotane

C Start ketoconazole

D Pituitary radiotherapy

E Proceed directly to adrenalectomy

C Start ketoconazole

This patient has severe Cushing's with multiple complications including poorly controlled hypertension, diabetes and obesity. As such he is at significant operative risk. Ketoconazole is an effective agent for control of cortisol synthesis prior to surgery. It acts on several of the P450 enzymes, including the first step in cortisol synthesis, cholesterol side-chain cleavage, and conversion of 11-deoxycortisol to cortisol. A daily dose of 600-800 mg often decreases cortisol production significantly and will help in controlling blood sugar and blood pressure before moving to pituitary surgery.

D Pituitary radiotherapy

Pituitary radiotherapy is considered in patients who have persistently raised adrenocorticotropic hormone (ACTH), but this is usually reserved for patients who have undergone surgery.

A Proceed directly to trans-sphenoidal resection

Whilst this is the preferred option given the presence of a pituitary adenoma, the patient is a high operative risk given his co-morbidities of severe hypertension, poorly controlled diabetes and morbid obesity making this option not the best of those available.

B Start mitotane

Mitotane is used in the treatment of adrenal cancer, rather than in the treatment of pituitary adenoma or Cushing's.

E Proceed directly to adrenalectomy

P-450 enzymes, including the first step in cortisol synthesis, cholesterol side-chain cleavage, and conversion of 11-deoxycortisol to cortisol. A daily dose of 600-800 mg often decreases cortisol production significantly and will help in controlling blood sugar and blood pressure before moving to pituitary surgery.

D Pituitary radiotherapy

Pituitary radiotherapy is considered in patients who have persistently raised adrenocorticotropic hormone (ACTH), but this is usually reserved for patients who have undergone surgery.

A Proceed directly to trans-sphenoidal resection

Whilst this is the preferred option given the presence of a pituitary adenoma, the patient is a high operative risk given his co-morbidities of severe hypertension, poorly controlled diabetes and morbid obesity making this option not the best of those available.

B Start mitotane

Mitotane is used in the treatment of adrenal cancer, rather than in the treatment of pituitary adenoma or Cushing's.

E Proceed directly to adrenalectomy

Firstlyhe patient is too high an operative risk given his multiple medical problems. Secondly, the patient does not have a adrenal adenoma requiring adrenalectomy. The mechanism for ACTH production is via the pituitary adenoma.

36478

Rate this question:

A 35-year-old man presents with a 2-month history of weight loss and headaches.

On examination, he is noted to have a blood pressure (BP) of 175/110 mmHg and 180/102 mmHg on three successive readings at the general practitioner (GP) surgery, despite having been started on an angiotensin-converting enzyme (ACE) inhibitor and calcium channel blocker. He smokes five cigarettes per day. His body mass index (BMI) as measured in the clinic is 23.

Investigations:

Sodium (Na^+)	145 mmol/l
Potassium (K^+)	4.1 mmol/l
Urea	10.6 mmol/l
Calcium (Ca^{2+})	3.1 mmol/l
Phosphate	0.4 mmol/l

What is the likely cause of his presentation?

A	Extra-adrenal phaeochromocytoma
B	Small-cell lung cancer
C	Multiple endocrine neoplasia (MEN) type 1
D	Multiple endocrine neoplasia (MEN) type 2
E	Zollinger–Ellison syndrome

5:43
On
594-042-7551
Leave

D Multiple endocrine neoplasia (MEN) type 2

The patient in this case is young, hypertensive and has hypercalcaemia. The high calcium level can be explained by the presence of parathyroid hypertrophy, and the hypertension is secondary to the presence of a phaeochromocytoma. Both abnormalities may be visualised on ultrasound imaging. Clearly the presence of hyperparathyroidism will be clarified by normal or raised levels on blood testing in the presence of hypercalcaemia. Medullary thyroid cancer doesn't cause hypercalcaemia, it is due to cancer affecting the thyroid C cell line, (which produce calcitonin).

There are two forms of MEN II, A and B. Patients with MEN2A and MEN2B experience two main complications, medullary thyroid cancer (MTC) and phaeochromocytoma. MEN2A patients have a predisposition to hypertrophy of the parathyroid glands and subsequent tumour development. MEN2B patients show a variety of additional conditions: a characteristic facial appearance with swollen lips; tumours of the mucous membranes of the eye, mouth, tongue and nasal cavity; enlarged colon; and skeletal abnormalities. MEN2A shows no distinct physical features and must be identified by either measuring hormone levels or finding endocrine tumours.

A Extra-adrenal phaeochromocytoma

Although this may explain the hypertension seen here, it wouldn't explain the hypercalcaemia.

B Small-cell lung cancer

Small cell lung cancer is associated with the production of ectopic adrenocorticotropic hormone (ACTH), leading to features of hypercortisolism. Although hypertension may be a feature, the lack of significant weight gain or dyscalcaemia and the modest smoking history count

Audio Video Share Participants More

A Extra-adrenal phaeochromocytoma

Although this may explain the hypertension seen here, it wouldn't explain the hypercalcaemia.

B Small-cell lung cancer

Small cell lung cancer is associated with the production of ectopic adrenocorticotropic hormone (ACTH), leading to features of hypercortisolism. Although hypertension may be a feature, the lack of significant weight gain or dysglycaemia and the modest smoking history count against this.

C Multiple endocrine neoplasia (MEN) type 1

MEN1 is associated with pancreatic endocrine tumours, not with phaeochromocytoma.

E Zollinger–Ellison syndrome

This is the syndrome of hypergastrinaemia and recurrent peptic ulceration related to a gastrinoma.

A 37-year-old woman underwent resection of a carcinoma of her left breast two years ago. She was given postoperative radiotherapy of 4000 cGy. The general practitioner has referred her for evaluation of a painful left arm associated with weakness.

On examination in the clinic, she is alert and anxious. The left palpebral fissure is slightly smaller than the right. Ocular movements are, however, normal. The left pupil is smaller than the right. Facial expression is normal, as are swallow and speech. The small muscles of the left hand are wasted and weak. Clawing is present, particularly affecting the left ring and little fingers. Hypo-aesthesia to pinprick is seen on the ulnar border of the left hand and forearm.

What is the most likely underlying diagnosis?

A	Metastatic infiltration of the brachial plexus
B	Radiation plexopathy
C	Cervical ribs
D	Syringomyelia
E	Monomelic motor neurone disease

32849

Submit

5:46
On
594-042-7551
Leave

arm associated with weakness.

On examination in the clinic, she is alert and anxious. The left palpebral fissure is slightly smaller than the right. Ocular movements are, however, normal. The left pupil is smaller than the right. Facial expression is normal, as are swallow and speech. The small muscles of the left hand are wasted and weak. Clawing is present, particularly affecting the left ring and little fingers. Hypo-aesthesia to pinprick is seen on the ulnar border of the left hand and forearm.

What is the most likely underlying diagnosis?

Your answer was correct

A	Metastatic infiltration of the brachial plexus
B	Radiation plexopathy
C	Cervical ribs
D	Syringomyelia
E	Monomelic motor neurone disease

Explanation

A	Metastatic infiltration of the brachial plexus

The lesion localises to the lower brachial plexus since the small muscles of the hand are wasted and weak, and the clawing involves all fingers but predominantly the fourth and fifth. No fasciculations are mentioned. The sensory los is in the C8 T1 distribution and the associated Horner syndrome points to the involvement of the T1 root.

Audio Video Share Participants More

A Metastatic infiltration of the brachial plexus

The lesion localises to the lower brachial plexus since the small muscles of the hand are wasted and weak, and the clawing involves all fingers but predominantly the fourth and fifth. No fasciculations are mentioned. The sensory los is in the C8 T1 distribution and the associated Horner syndrome points to the involvement of the T1 root.

B Radiation plexopathy

Radiation plexopathy usually occurs after doses of more than 6000 cGy have been used and involves the upper brachial plexus. It is usually painless and associated with lymphoedema.

C Cervical ribs

A cervical rib leads to thoracic outlet syndrome involving C7; it is rare, occurring in 1 in 500 people, and a lesion related to breast cancer should be considered first.

D Syringomyelia

Syringomyelia presents with progressive bilateral weaknes affecting the arms and legs, accompanied by dissociated sensory loss.

E Monomelic motor neurone disease

This is a focal motor neurone disease which would not lead to the sensory loss seen here, and cannot therefore be responsible for the symptoms seen.

Rana Alnasser's screen

A 54-year-old man presents with a 4-month history of intermittent dysuria, some pain on ejaculation and intermittent problems passing urine. He was previously fit and well and has no significant past medical history.

On examination, his blood pressure (BP) is 135/75 mmHg and general physical examination is unremarkable. PR reveals a normal-sized prostate which is mildly tender and nodular to palpation.

Investigations:

Haemoglobin (Hb)	13.1 g/dl
White cell count (WCC)	8.4×10^9/l
Platelet (PLT)	201×10^9/l
Sodium (Na^+)	140 mmol/l
Potassium (K^+)	4.5 mmol/l
Creatinine	110 µmol/l
Prostate specific antigen (PSA)	6 µg/l (< 4)

Which of the following is the most likely diagnosis?

A Prostatic carcinoma

B Benign prostatic hypertrophy

C Acute prostatitis

D Chronic intermittent prostatitis

E Non-specific urethritis

Rana Alnasser's screen

Haemoglobin (Hb)	13.1 g/dl
White cell count (WCC)	8.4×10^9/l
Platelet (PLT)	201×10^9/l
Sodium (Na^+)	140 mmol/l
Potassium (K^+)	4.5 mmol/l
Creatinine	110 µmol/l
Prostate specific antigen (PSA)	6 µg/l (< 4)

Which of the following is the most likely diagnosis?

Your answer was correct

A Prostatic carcinoma

B Benign prostatic hypertrophy

C Acute prostatitis

D Chronic intermittent prostatitis

E Non-specific urethritis

Explanation

D Chronic intermittent prostatitis

The nodularity with mild diffuse tenderness is consistent with chronic infection. Mild elevation in the PSA is also consistent with a chronic prostatitis. A trial of antibiotics is required ± an alpha antagonist if symptoms of obstruction

D Chronic intermittent prostatitis

The nodularity with mild diffuse tenderness is consistent with chronic infection. Mild elevation in the PSA is also consistent with a chronic prostatitis. A trial of antibiotics is required ± an alpha antagonist if symptoms of obstruction are present.

A Prostatic carcinoma

This is unlikely given the intermittent (rather than progressive) nature of symptoms and only very mildly elevated PSA. Prostate carcinoma should remain within the differential given the mild nodularity, but a trial of antibiotics remains a priority followed by further investigations and repeat prostate assessment at the end of treatment.

B Benign prostatic hypertrophy

This is unlikely to be the diagnosis given the normal-sized prostate.

C Acute prostatitis

This does not usually cause intermittent symptoms over 4 months and there are usually more systemic symptoms such as fever. Ejaculatory pain is more typical with chronic prostatitis rather than in the acute presentation. Furthermore, one would expect the prostate to be acutely tender (rather than mildly tender), hot, nodular or boggy on digital examination.

E Non-specific urethritis

This does not usually present over a 4-month period. There

5:48
On
MyPastest 594-042-7551
Leave
https://mypastest.pastest.com/Secure/TestMe/Bro

Pastest+ Question 32 of 44

prostate.

C Acute prostatitis

This does not usually cause intermittent symptoms over 4 months and there are usually more systemic symptoms such as fever. Ejaculatory pain is more typical with chronic prostatitis rather than in the acute presentation. Furthermore, one would expect the prostate to be acutely tender (rather than mildly tender), hot, nodular or boggy on digital examination.

E Non-specific urethritis

This does not usually present over a 4-month period. There is no mention of urethral discharge and the mildly tender, nodular prostate is more consistent with prostatitis.

Rate this question:

Previous Q... Tag Questi... Feedback End Session

Blog About Pastest Contact Us Help
© Pastest 2019
Audio Video Share Participants More

5:48
On
MyPastest 594-042-7551
Leave
https://mypastest.pastest.com/Secure/TestMe/Bro

Pastest+

A 50-year-old man with newly-diagnosed Duke C colorectal carcinoma received his first cycle of adjuvant 5-fluorouracil (5-FU) (bolus and infusion) and folinic acid (bolus) chemotherapy five days ago. He is brought into the Emergency Department with new-onset florid diarrhoea and severe oral mucositis. He is clinically dehydrated and drowsy.

Which of the following is the most likely explanation for his presentation?

A	The dose of 5-fluorouracil was too high
B	The dose of folinic acid was too low
C	Genetic susceptibility to toxicity from 5-fluorouracil due to a deficiency of the catabolising enzyme
D	Genetic susceptibility to toxicity from 5-fluorouracil due to an excess of the anabolising enzyme
E	Too rapid administration of 5-fluorouracil bolus

Submit

Audio Video Share Participants More

C Genetic susceptibility to toxicity from 5-fluorouracil due to a deficiency of the catabolising enzyme

5-FU is a fluorine-substituted analogue of uracil, and must be metabolically activated to 5-fluoro-2'deoxyuridine-5-monophosphate (F-dUMP). Cytotoxicity is primarily due to the inhibition of DNA synthesis by FdUMP blocking thymidylate synthetase. This enzyme normally transfers a methylene group from reduced folic acid to deoxyuridylate monophosphate (dUMP) to form thymidylate, which is essential for DNA synthesis.

Dihydropyrimidine dehydrogenase (DPD) is the enzyme responsible for the breakdown of 5-FU. A pharmacogeneti disorder has been described concerning cancer patients with a complete or partial deficiency of DPD. In this they suffer from severe toxicity and can present with severe diarrhoea and mucositis following the administration of 5-FU. It is similar to the picture seen with an overdose of 5FU, and is recognised in approximately 3% of patients. Both an overdose of 5-FU and partial or complete DPD deficiency can potentially be fatal in the affected individua

D Genetic susceptibility to toxicity from 5-fluorouracil due to an excess of the anabolising enzyme

As described above, toxicity to 5-FU is caused by a deficiency (partial or complete) of the DPD enzyme. This option is therefore incorrect.

A The dose of 5-fluorouracil was too high

There are strict guidelines to follow when dosing chemotherapy, but occasionally patients can suffer with severe toxicity, as in this patient's case, and present with

As described above, toxicity to 5-FU is caused by a deficiency (partial or complete) of the DPD enzyme. This option is therefore incorrect.

A The dose of 5-fluorouracil was too high

There are strict guidelines to follow when dosing chemotherapy, but occasionally patients can suffer with severe toxicity, as in this patient's case, and present with severe diarrhoea and mucositis. However, the question asks for the most likely explanation for the patient's symptoms and there is another option within the question that best fits this presentation.

B The dose of folinic acid was too low

Folinic acid is given concurrently with 5-FU. It enhances bonding of 5-FU to an enzyme within the cancer cell, thereby increasing the time 5-FU remains in the patient. It can, therefore, increase the side effect profile of 5-FU. This patient's presenting symptoms would be more in keeping with an excessive dose of folinic acid rather than the opposite.

E Too rapid administration of 5-fluorouracil bolus

Rapid administration can contribute to reactions, such as vasospasm, at the time of administration or shortly afterwards. but is unlikely to have caused this patient's symptoms.

5:52
MyPastest
Home Feed | Re
Tumor M
https://mypastest.pastest.com/Secure/TestMe/Brows

Pastest+

A 35-year-old patient with locally advanced breast cancer presents to the Emergency Department two days after her first dose of chemotherapy, complaining of restlessness and facial grimacing. You can see from her notes that her regimen was graded as associated with moderate risk of emesis (30–60%).

Which drug is most likely to be responsible for her presentation?

A	Cyclizine
B	Dexamethasone
C	Domperidone
D	Granisetron
E	Metoclopramide

Submit

5:56

MyPastest | Home Feed | Re | Tumor M

https://mypastest.pastest.com/Secure/TestMe/Brows

Pastest+

Question 34 of 44

A 35-year-old patient with locally advanced breast cancer presents to the Emergency Department two days after her first dose of chemotherapy, complaining of restlessness and facial grimacing. You can see from her notes that her regimen was graded as associated with moderate risk of emesis (30–60%).

Which drug is most likely to be responsible for her presentation?

Your answer was correct

A	Cyclizine
B	Dexamethasone
C	Domperidone
D	Granisetron
E	Metoclopramide

Explanation

E	Metoclopramide

Metoclopramide is a dopamine antagonist anti-emetic that acts on the chemoreceptor trigger zone. It also increases

E Metoclopramide

Metoclopramide is a dopamine antagonist anti-emetic that acts on the chemoreceptor trigger zone. It also increases resting pressure in the lower oesophageal sphincter and the gastric fundus, resulting in hastened oesophageal clearance, accelerated gastric emptying and shortened transit time through the small bowel.

In some patients, metoclopramide may produce sedation, drowsiness, galactorrhoea, menstrual disorders and extrapyramidal reactions. Extrapyramidal symptoms are more frequent at higher than recommended doses, but occur with therapeutic doses, particularly in children, young women and in patients with impaired renal or hepatic function.

A Cyclizine

Cyclizine is an H1 receptor antagonist with anti-cholinergic properties. It may lead to a dry mouth and drowsiness.

B Dexamethasone

Potent corticosteroids are used as part of a combination therapy for treatment of emesis, although they are not associated with extrapyramidal side-effects.

C Domperidone

Domperidone does have dopamine antagonist properties, although it is associated with much lower risk of extrapyramidal side-effects versus metoclopramide.

D Granisetron

Granisetron is a 5HT-3 antagonist and is not associated with extrapyramidal side effects, but is associated with

drowsiness, galactorrhoea, menstrual disorders and extrapyramidal reactions. Extrapyramidal symptoms are more frequent at higher than recommended doses, but occur with therapeutic doses, particularly in children, young women and in patients with impaired renal or hepatic function.

A Cyclizine

Cyclizine is an H1 receptor antagonist with anti-cholinergic properties. It may lead to a dry mouth and drowsiness.

B Dexamethasone

Potent corticosteroids are used as part of a combination therapy for treatment of emesis, although they are not associated with extrapyramidal side-effects.

C Domperidone

Domperidone does have dopamine antagonist properties, although it is associated with much lower risk of extrapyramidal side-effects versus metoclopramide.

D Granisetron

Granisetron is a 5HT-3 antagonist and is not associated with extrapyramidal side effects, but is associated with constipation and drowsiness in some patients.

Rate this question:

Next Question

A 54-year-old man comes to the clinic for review some ten weeks after undergoing a Whipple's procedure for pancreatic carcinoma. He has recovered well and just returned to his job working in an office.

Examination reveals a blood pressure (BP) of 105/70 mmHg, pulse is 80/min and regular. He has a large abdominal scar, his body mass index (BMI) is 20.

Investigations:

		Normal Values
Haemoglobin (Hb)	10.0 g/dl	
White cell count (WCC)	7.1×10^9/l	
Platelets (PLT)	198×10^9/l	
Sodium (Na^+)	137 mmol/l	
Potassium (K^+)	4.0 mmol/l	
Creatinine (Cr)	100 mmol/l	
Alanine transaminase (ALT)	22 U/l	
Alkaline phosphatase (ALP)	95 U/l	
CA19-9	23 U/ml	< 37

Which of the following may have been a risk factor in developing pancreatic cancer?

A Systemic lupus erythematosus (SLE)

B Familial adenomatous polyposis (FAP)

C Occupational exposure to diesel exhaust

D Non-steroidal anti-inflammatory drugs (NSAIDs)

Investigations:

		Normal Values
Haemoglobin (Hb)	10.0 g/dl	
White cell count (WCC)	7.1×10^9/l	
Platelets (PLT)	198×10^9/l	
Sodium (Na^+)	137 mmol/l	
Potassium (K^+)	4.0 mmol/l	
Creatinine (Cr)	100 mmol/l	
Alanine transaminase (ALT)	22 U/l	
Alkaline phosphatase (ALP)	95 U/l	
CA19-9	23 U/ml	< 37

Which of the following may have been a risk factor in developing pancreatic cancer?

A Systemic lupus erythematosus (SLE)

B Familial adenomatous polyposis (FAP)

C Occupational exposure to diesel exhaust

D Non-steroidal anti-inflammatory drugs (NSAIDs)

E Statins

Submit

5:58

Explanation

B Familial adenomatous polyposis (FAP)

Pancreatic cancer is associated with smoking, chronic pancreatitis and familial syndromes e.g. HNPCC (hereditary non-polyposis colon cancer), hereditary pancreatitis, FAP and BRCA-2 mutations. The relative risk of pancreatic cancer in patients with FAP is approximately 4 fold.

A Systemic lupus erythematosus (SLE)

SLE is associated with an increased risk of non-Hodgkin's lymphoma, lung, liver, vulvar/vaginal, and thyroid malignancies but there is no evidence of SLE causing pancreatic cancer.

C Occupational exposure to diesel exhaust

Pooled/meta-analyses have demonstrated no effect on pancreatic cancer from occupational exposure to diesel exhaust. There is a link between air pollution and lung cancer.

D Non-steroidal anti-inflammatory drugs (NSAIDs)

Non-steroidal anti-inflammatory drugs (NSAIDs) are not considered a risk factor for the development of pancreatic cancer. There is evidence to support the fact they actually reduce the incidence of colon cancer.

E Statins

Some studies have demonstrated a possible protective effect in some malignancies although this remains contentious.

Rana Alnasser's screen

5:59
On
594-042-7551
Leave

A 65-year-old patient was found to have a colonic carcinoma invading through the muscularis propria, with five regional nodes involved.

With optimal treatment, what is the likely 5-year survival for this patient?

A	< 5%
B	60%
C	20%
D	80%
E	95%

Submit

5:59
MyPastest
Home Feed | Re
Tumor M
https://mypastest.pastest.com/Secure/TestMe/Brows

Pastest+

Question 36 of 44

A 65-year-old patient was found to have a colonic carcinoma invading through the muscularis propria, with five regional nodes involved.

With optimal treatment, what is the likely 5-year survival for this patient?

Your answer was incorrect

A	< 5%
B	60%
C	20%
D	80%
E	95%

Explanation

B	60%

The Dukes staging system is widely employed for classifying colorectal cancers and is a useful predictor of survival. Tumour grade and depth of penetration are also important. Duke A (stage I) defines a tumour confined to the bowel wall (i.e. mucosa and submucosa). Duke B (stage

B 60%

The Dukes staging system is widely employed for classifying colorectal cancers and is a useful predictor of survival. Tumour grade and depth of penetration are also important. Duke A (stage I) defines a tumour confined to the bowel wall (i.e. mucosa and submucosa). Duke B (stage II) invades through the muscle wall. Duke C (stage III) involves lymph nodes. After this the patient presents with metastatic disease at distant sites (stage IV).

Prognosis after resection is related not only to regional lymph node involvement but also to the number of involved nodes. The prognosis for patients with colorectal cancer is more favourable when tumour specimens reveal involvement of one to four lymph nodes than when they reveal five or more involved nodes. According to most recent cancer survival statistics, Dukes C, the classification here, now has survival rates which approach 60%.

C 20%

20% is the 5-year survival rate for colon cancer where the stage isn't known/is unclassified in UK mortality statistics. It's likely to represent patients presenting with mainly late stage disease.

A < 5%

Approximately 5% survival rates at five years are seen for patients with stage IV disease who have metastatic disease at distant sites.

D 80%

This is the 5-year survival rate for Dukes B (stage II) disease where cancer has invaded through the muscle wall only.

II) invades through the muscle wall. Duke C (stage III) involves lymph nodes. After this the patient presents with metastatic disease at distant sites (stage IV).

Prognosis after resection is related not only to regional lymph node involvement but also to the number of involved nodes. The prognosis for patients with colorectal cancer is more favourable when tumour specimens reveal involvement of one to four lymph nodes than when they reveal five or more involved nodes. According to most recent cancer survival statistics, Dukes C, the classification here, now has survival rates which approach 60%.

C	20%

20% is the 5-year survival rate for colon cancer where the stage isn't known/is unclassified in UK mortality statistics. It's likely to represent patients presenting with mainly late stage disease.

A	< 5%

Approximately 5% survival rates at five years are seen for patients with stage IV disease who have metastatic disease at distant sites.

D	80%

This is the 5-year survival rate for Dukes B (stage II) disease where cancer has invaded through the muscle wall only.

E	95%

This would be the survival rate at five years for Dukes A (stage I) disease where there is tumour confined to the bowel wall only.

Rana Alnasser's screen

6:03

MyPastest | Home Feed | Tumor Ma

https://mypastest.pastest.com/Secure/TestMe/Browse

A 65-year-old female smoker presents with a 1-month history of generalised abdominal pain, abdominal distension and constipation. She has been feeling very tired for several months and in addition has lost 2 kg in weight over this time period, but feels that her abdomen has become larger.

On examination, she has a distended abdomen with shifting dullness. There are no palpable masses or evidence of organomegaly.

Investigations:

Haemoglobin (Hb)	10.5 g/dl
White cell count (WCC)	6.00×10^9/l
Platelet (PLT)	547×10^9/l
Sodium (Na^+)	137 mmol/l
Potassium (K^+)	3.7 mmol/l
Creatinine	101 µmol/l
Urea	7.4 mmol/l
eGFR	64

Which malignant cause is most likely to explain her presentation?

A Gastric carcinoma

B Medulloblastoma

C Small-cell carcinoma of the lung

Rana Alnasser's screen

over this time period, but feels that her abdomen has become larger.

On examination, she has a distended abdomen with shifting dullness. There are no palpable masses or evidence of organomegaly.

Investigations:

Haemoglobin (Hb)	10.5 g/dl
White cell count (WCC)	6.00×10^9/l
Platelet (PLT)	547×10^9/l
Sodium (Na^+)	137 mmol/l
Potassium (K^+)	3.7 mmol/l
Creatinine	101 µmol/l
Urea	7.4 mmol/l
eGFR	64

Which malignant cause is most likely to explain her presentation?

A Gastric carcinoma

B Medulloblastoma

C Small-cell carcinoma of the lung

D Ovarian cancer

E Retroperitoneal lymphoma

D Ovarian cancer

Ovarian cancer patient often present with constipation, increasing abdominal girth due to ascites but with loss of fat and muscle mass elsewhere. Unfortunately, patients often present in their seventh decade of life with late-stage disease and, as such, prognosis and five-year survival is very poor.

A Gastric carcinoma

Patients with gastric carcinoma usually patients present with early satiety, anorexia, weight loss and abdominal pain. They can also have ascites. However, the overall picture of someone with gastric cancer differs from that presented by the patient within the question.

B Medulloblastoma

Medulloblastomas do not affect endocrine function or cause a significant increase in abdominal girth. They are more likely to present with symptoms such as neurological deficit, headache, nausea and vomiting and seizures, and are therefore not a likely explanation for this patient's symptoms.

C Small-cell carcinoma of the lung

Small cell lung carcinoma can produce the syndrome of inappropriate antidiuretic hormone secretion, and patients can have a normal or low serum sodium level. Although patients can also present with weight loss, ascites and abdominal pain and distension are not usual signs associated with small cell lung cancer.

E Retroperitoneal lymphoma

6:04

MyPastest | Home Feed | Tumor Ma

https://mypastest.pastest.com/Secure/TestMe/Browse

symptoms.

C Small-cell carcinoma of the lung

Small cell lung carcinoma can produce the syndrome of inappropriate antidiuretic hormone secretion, and patients can have a normal or low serum sodium level. Although patients can also present with weight loss, ascites and abdominal pain and distension are not usual signs associated with small cell lung cancer.

E Retroperitoneal lymphoma

Patients with retroperitoneal lymphoma rarely present with ascites. They commonly present with fevers, night sweats and abdominal pain, which is not in keeping with this patient's presenting symptoms.

Rate this question:

Next Question

Previous Q... Tag Questi... Feedback End Session

Blog About Pastest Contact Us Help

© Pastest 2019

6:04
MyPastest
Home Feed | Re
Tumor Ma
https://mypastest.pastest.com/Secure/TestMe/Browse

A 37-year-old is referred to the Emergency Department with extreme tiredness, such that she is unable to cope. She has progressive shortness of breath, nausea and anorexia which has worsened significantly over the past six weeks. She has lost 5 kg in weight over the past six months.

On examination, her blood pressure (BP) is 100/60 mmHg, pulse is 90/min and regular. She looks pale. Her abdomen is distended, her chest is dull to percussion at the left base and there are decreased breath sounds.

Investigations:

Haemoglobin (Hb)	9.9 g/dl
White cell count (WCC)	11.2×10^9/l
Platelet (PLT)	178×10^9/l
Sodium (Na^+)	138 mmol/l
Potassium (K^+)	5.3 mmol/l
Creatinine	139 micromol/l
Alanine transaminase (ALT)	312 U/l
Bilirubin	35 micromol/l
Alkaline phosphatase (ALP)	285 U/l
International normalised ratio (INR)	1.2
Ultrasound scan (USS) liver	Multiple metastases of unknown origin

6:04
On
594-042-7551
Leave

Platelet (PLT)	178 × 10^9/l
Sodium (Na^+)	138 mmol/l
Potassium (K^+)	5.3 mmol/l
Creatinine	139 micromol/l
Alanine transaminase (ALT)	312 U/l
Bilirubin	35 micromol/l
Alkaline phosphatase (ALP)	285 U/l
International normalised ratio (INR)	1.2
Ultrasound scan (USS) liver	Multiple metastases of unknown origin
Chest X-ray	Left pleural effusion

Which of the following is the optimal next step?

A Referral to palliative care

B Liver biopsy

C Pleural biopsy under image guidance

D Blood transfusion

E Blind pleural aspiration

Audio
Video
Share
Participants
More

Creatinine	139 micromol/l
Alanine transaminase (ALT)	312 U/l
Bilirubin	35 micromol/l
Alkaline phosphatase (ALP)	285 U/l
International normalised ratio (INR)	1.2
Ultrasound scan (USS) liver	Multiple metastases of unknown origin
Chest X-ray	Left pleural effusion

Which of the following is the optimal next step?

Your answer was incorrect

A Referral to palliative care

B Liver biopsy

C Pleural biopsy under image guidance

D Blood transfusion

E Blind pleural aspiration

Explanation

C Pleural biopsy under image guidance

This young, 37-year-old patient presents with disseminated

C Pleural biopsy under image guidance

This young, 37-year-old patient presents with disseminated metastatic malignancy of unknown origin.

The optimal approach is to obtain a tissue diagnosis and the question debates which is the best route to diagnostic certainty - pleural biopsy under image guidance is the least invasive approach.

A Referral to palliative care

It may be appropriate but the single most important next management step is ascertaining diagnostic certainty.

B Liver biopsy

The least invasive method, with the lowest associated procedural risks will be preferred and thus pleural biopsy is considered to be the best option rather than a liver biopsy which is associated with a higher morbidity and mortality rate.

D Blood transfusion

It is not indicated with a haemoglobin of 9.9 g/dl.

E Blind pleural aspiration

It is no longer considered to be good practice unless the patient is in an emergent situation. Furthermore, pleural fluid cytology has a sensitivity of approximately 60% compared with 90-95% with image guided pleural biopsy.

Rate this question:

A 71-year-old man is found to be anaemic on routine testing when he changes to a new general practitioner (GP). He has hypertension which is treated with lisinopril and amlodipine, but nil else of note.

On examination, his blood pressure (BP) is 132/72, pulse is 85 and regular. There is mild bilateral pitting oedema of the ankles.

Investigations:

Haemoglobin (Hb)	10.8 g/dl
White cell count (WCC)	11.1×10^9/l
Platelets (PLT)	187×10^9/l
Sodium (Na^+)	138 mmol/l
Potassium (K^+)	4.3 mmol/l
Creatinine (Cr)	105 micromol/l
Albumin (Alb)	28 g/l
Total protein	61 g/l

Which of the following would fit best with a diagnosis of symptomatic myeloma?

A	Creatinine 105 micromol/l
B	Femoral and lumbar spine lytic lesions on skeletal survey
C	Hb of 10.8 g/dl
D	8% clonal plasma cells on bone marrow sampling
E	Urine negative for protein

B Femoral and lumbar spine lytic lesions on skeletal survey

Criteria for diagnosis of symptomatic myeloma were drawn up in 2015 and are listed below:

Symptomatic myeloma diagnosis criteria:

- Monoclonal plasma cells in bone marrow (aspirate or trephine) ≥ 10%
- Serum paraprotein ≥ 30 g/l (if IgM paraprotein exclude lymphoplasmacytic lymphoma).

Evidence of end organ damage that can be attributed to myeloma. This is termed myeloma-related organ or tissue injury (ROTI) and commonly called the CRAB criteria:

- C: hypercalcaemia (corrected Ca2+>0.25 mmol/l above normal or > 2.75 mmol/l)
- R: renal impairment (no other cause)
- A: anaemia (Hb < 100 g/l or more than 20 g below normal, not due to other causes)
- B: bone lesions (lytic lesions or osteoporosis).

A Creatinine 105 micromol/l

It is within the normal range and thus would be unusual in symptomatic myeloma.

C Hb of 10.8 g/dl

It would be insufficient to meet the diagnostic criteria for symptomatic myeloma.

D 8% clonal plasma cells on bone marrow sampling

6:07
On
594-042-7551
Leave
MyPastest
Home Feed | Re
Tumor Ma
https://mypastest.pastest.com/Secure/TestMe/Browse

It is within the normal range and thus would be unusual in symptomatic myeloma.

C	Hb of 10.8 g/dl

It would be insufficient to meet the diagnostic criteria for symptomatic myeloma.

D	8% clonal plasma cells on bone marrow sampling

This is more consistent with monoclonal gammopathy of unknown significance – in myeloma, the clonal plasma cells should be >10% on bone marrow biopsy.

E	Urine negative for protein

Proteinuria is a feature of symptomatic multiple myeloma.

Rate this question:

© Pastest 2019

Audio Video Share Participants More

6:07
MyPastest
Home Feed | Re
Tumor Ma
https://mypastest.pastest.com/Secure/TestMe/Browse

Pastest

A 17-year-old man presents with mild breast tenderness, weight loss and anxiety. He is known to have Kleinfelter syndrome and had an undescended testis for which he underwent orchidoplexy as a child. He has no other past medical history of note.

On examination, his blood pressure (BP) is 125/73 mmHg, his body mass index (BMI) is 21, he has gynaecomastia and small testes, his left appears more swollen than the right, but he tells you this is the one he had the operation on.

Investigations:

Haemoglobin (Hb)	12.3 g/dl
White cell count (WCC)	16.9×10^9/l
Platelet (PLT)	203×10^9/l
Sodium (Na^+)	139 mmol/l
Potassium (K^+)	4.4 mmol/l
Creatinine	103 µmol/l
Beta human chorionic gonadotropin (B-HCG)	9000 U/l (< 5)
Thyroid-stimulating hormone (TSH)	< 0.05 U/l (< 0.5-4.5)

Which of the following is the next most appropriate investigation?

A Ultrasound scan testes

B Thyroid autoantibodies

Rana Alnasser's screen

On examination, his blood pressure (BP) is 125/73 mmHg, his body mass index (BMI) is 21, he has gynaecomastia and small testes, his left appears more swollen than the right, but he tells you this is the one he had the operation on.

Investigations:

Haemoglobin (Hb)	12.3 g/dl
White cell count (WCC)	16.9×10^9/l
Platelet (PLT)	203×10^9/l
Sodium (Na^+)	139 mmol/l
Potassium (K^+)	4.4 mmol/l
Creatinine	103 µmol/l
Beta human chorionic gonadotropin (B-HCG)	9000 U/l (< 5)
Thyroid-stimulating hormone (TSH)	< 0.05 U/l (< 0.5-4.5)

Which of the following is the next most appropriate investigation?

A Ultrasound scan testes

B Thyroid autoantibodies

C Ultrasound thyroid

D MRI pituitary

E Chest X-ray

Rana Alnasser's screen

Potassium (K^+)	4.4 mmol/l
Creatinine	103 µmol/l
Beta human chorionic gonadotropin (B-HCG)	9000 U/l (< 5)
Thyroid-stimulating hormone (TSH)	< 0.05 U/l (< 0.5-4.5)

Which of the following is the next most appropriate investigation?

Your answer was correct

A Ultrasound scan testes

B Thyroid autoantibodies

C Ultrasound thyroid

D MRI pituitary

E Chest X-ray

Explanation

A Ultrasound scan testes

The suspicion here is testicular cancer. Patients with a history of hypogonadism / undescended testis have a doubling or greater risk of developing testicular carcinoma. Due to commonality between HCG and TSH, profound rises in B-HCG can result in hyperthyroidism, hence the symptoms of weight loss and anxiety, coupled with the [illegible] scan of the testes is the

Rana Alnasser's screen

A Ultrasound scan testes

The suspicion here is testicular cancer. Patients with a history of hypogonadism / undescended testis have a doubling or greater risk of developing testicular carcinoma. Due to commonality between HCG and TSH, profound rises in B-HCG can result in hyperthyroidism, hence the symptoms of weight loss and anxiety, coupled with the suppressed TSH. Ultrasound scan of the testes is the optimal way to investigate suspected testicular carcinoma. Testicular biopsy is not recommended, where ultrasound scanning is highly suggestive of a carcinoma, and other findings correlate, such as raised HCG, progression to orchidectomy is the most appropriate management.

B Thyroid autoantibodies

The suppressed TSH is due to B-HCG rather than related to thyroid stimulating autoantibodies.

C Ultrasound thyroid

There is no suspicion of a thyroid mass, a toxic adenoma, goitre related to Graves' or a multinodular goitre. In the presence of a raised B-HCG there is no value in an ultrasound scan.

D MRI pituitary

Pituitary driven thyrotoxicosis is associated with an elevated TSH rather than the suppressed TSH seen here.

E Chest X-ray

Chest X-ray is of value in evaluating possible metastases, although the most important next step is to confirm

Rana Alnasser's screen

A 29-year-old man presents to his general practitioner (GP) complaining of marked weight loss over the last three months associated with drenching night sweats. He is also complaining of generalised itchiness, which he finds quite irritating and embarrassing. He reports no past medical problems and is a non-smoker. He has had no recent travel history of note.

On examination, he is apyrexial but there is noted to be generalised symmetrical lymphadenopathy in the cervical and supraclavicular areas. There is no hepatomegaly or splenomegaly.

Blood investigations are ordered and the results are as follows:

Erythrocyte sedimentation rate (ESR)	188
Haemoglobin (Hb)	12.8 g/dl
White cell count (WCC)	4.7×10^9/l
Platelet (PLT)	230×10^9/l
Sodium (Na^+)	139 mmol/l
Potassium (K^+)	4.2 mmol/l
Urea	4.4 mmol/l
Creatinine	90 µmol/l

A computerised tomography (CT) scan of the chest, abdomen and pelvis confirms the involvement of two lymph node areas in the neck only; lymph node biopsy confirms the diagnosis of Hodgkin's disease.

Based on the above information, what would be the clinical stage of this patient's disease according to the Ann Arbor classification?

Rana Alnasser's screen

Blood investigations are ordered and the results are as follows:

Erythrocyte sedimentation rate (ESR)	188
Haemoglobin (Hb)	12.8 g/dl
White cell count (WCC)	4.7×10^9/l
Platelet (PLT)	230×10^9/l
Sodium (Na^+)	139 mmol/l
Potassium (K^+)	4.2 mmol/l
Urea	4.4 mmol/l
Creatinine	90 µmol/l

A computerised tomography (CT) scan of the chest, abdomen and pelvis confirms the involvement of two lymph node areas in the neck only; lymph node biopsy confirms the diagnosis of Hodgkin's disease.

Based on the above information, what would be the clinical stage of this patient's disease according to the Ann Arbor classification?

A Stage I B

B Stage II A

C Stage II B

D Stage III A

E Stage III B

6:13
On
594-042-7551
Leave

C Stage II B

Stage II refers to involvement of two or more lymph node areas on the same side of the diaphragm. Stage II B refers to a presence of B symptoms (fever, night sweats and weight loss (> 10%). This patient fulfils the criteria for stage II disease and has B symptoms, meaning he has Stage II B disease.

A Stage I B

Stage I refers to involvement of a single lymph node area or a single extra-nodal site, and B refers to B symptoms such as drenching night sweats, fevers (> 38 °C) or > 10% weight loss. Looking at this patient's CT findings and symptoms, he is greater that stage I disease and has B symptoms.

B Stage II A

Stage II refers to involvement of two or more lymph node areas on the same side of the diaphragm. Stage A refers to an absence of B symptoms (fever, night sweats and weight loss (> 10%). This patient fulfils the criteria for stage II disease but does have B symptoms.

D Stage III A

Stage III refers to involvement of lymph node areas on both sides of the diaphragm. However, this patient only has two lymph nodes in the neck, meaning he has Stage II disease. Stage A refers to an absence of B symptoms (fever, night sweats and weight loss (> 10%). However, this patient does suffer with B symptoms, meaning Stage IIIA is incorrect.

Audio Video Share Participants More

Hodgkin's disease is a potentially curable malignant lymphoma, slightly more common in males than females and with a bimodal distribution, with a first peak in young adults (15–34 years) and a second peak in older individuals (> 55 years). It is characterised histologically by the presence of neoplastic Reed–Sternberg cells against a background of reactive mixed inflammatory cells. The aetiology is unknown. A histological sample is always required to make the diagnosis, and the Ann Arbor classification[1] is most commonly used for staging the disease. Both clinical examination and imaging techniques are used to establish the stage of the disease. The staging system is as follows:

- Stage I: Involvement of a single lymph node area or a single extranodal site
- Stage II: Involvement of two or more lymph node areas on the same side of the diaphragm
- Stage III: Involvement of lymph node areas on both sides of the diaphragm
- Stage IV: Multiple involvement of extra-nodal organs. Involvement of the liver or the bone marrow is considered stage IV disease.

For staging classification, the spleen is considered a lymph node area. Each stage is further designated as A or B depending on the absence or presence of B symptoms, respectively. A stage is labelled B if there is the presence of one or more of the following: fever (temperature > 38 °C), drenching night sweats and/or unexplained loss of more than 10% of body weight within the preceding 6 months.

[1]Smithers DW. Summary of papers delivered at the Conference on Staging in Hodgkin's Disease (Ann Arbor). *Cancer Research*, 1971, 31: 1869–70.

Rate this question:

Rana Alnasser's screen

A young patient undergoing chemotherapy summons the nurses to report pain and swelling at the site of the infusion cannula. The oncology registrar assumes that this is due to extravasation of the chemotherapeutic agent.

Which of the following would be part of your management of this patient?

A	Stop the infusion and remove the cannula
B	Administer oral corticosteroids to reduce inflammation at the cannula site
C	Consult with a plastic surgeon for any doxorubicin or daunorubicin extravasation injuries
D	In the case of vinca alkaloids, immediately apply a cold pack
E	Stop the infusion and administer IV fluids

Submit

© Pastest 2019

A young patient undergoing chemotherapy summons the nurses to report pain and swelling at the site of the infusion cannula. The oncology registrar assumes that this is due to extravasation of the chemotherapeutic agent.

Which of the following would be part of your management of this patient?

Your answer was correct

A	Stop the infusion and remove the cannula
B	Administer oral corticosteroids to reduce inflammation at the cannula site
C	Consult with a plastic surgeon for any doxorubicin or daunorubicin extravasation injuries
D	In the case of vinca alkaloids, immediately apply a cold pack
E	Stop the infusion and administer IV fluids

Explanation

C	Consult with a plastic surgeon for any doxorubicin or daunorubicin extravasation injuries

Doxorubicin or daunorubicin extravasation injuries are particularly prone to causing ulceration, particularly on the back of the hand, and hence a plastic surgery consultation is likely to be needed.

Rana Alnasser's screen

C Consult with a plastic surgeon for any doxorubicin or daunorubicin extravasation injuries

Doxorubicin or daunorubicin extravasation injuries are particularly prone to causing ulceration, particularly on the back of the hand, and hence a plastic surgery consultation is likely to be needed.

A Stop the infusion and remove the cannula

After stopping the infusion and immobilising the arm, the next step would be to aspirate it through the cannula PRIOR to removing it, in an aim to aspirate as much of the drug as possible.

B Administer oral corticosteroids to reduce inflammation at the cannula site

Patients are sent home with topical corticosteroids and strict instructions to contact the department urgently if the extravasation site becomes red, blackened, ulcerated and/or painful.

D In the case of vinca alkaloids, immediately apply a cold pack

In cases of extravasation of vinca alkaloids, patients should have a heat compress immediately applied to the affected area.

E Stop the infusion and administer IV fluids

The cannula is not working correctly and as such the infusion of chemotherapy drug must be stopped urgently. Following this, nothing should be administered via the cannula and it should be aspirated to remove any

is likely to be needed.

A Stop the infusion and remove the cannula

After stopping the infusion and immobilising the arm, the next step would be to aspirate it through the cannula PRIOR to removing it, in an aim to aspirate as much of the drug as possible.

B Administer oral corticosteroids to reduce inflammation at the cannula site

Patients are sent home with topical corticosteroids and strict instructions to contact the department urgently if the extravasation site becomes red, blackened, ulcerated and/or painful.

D In the case of vinca alkaloids, immediately apply a cold pack

In cases of extravasation of vinca alkaloids, patients should have a heat compress immediately applied to the affected area.

E Stop the infusion and administer IV fluids

The cannula is not working correctly and as such the infusion of chemotherapy drug must be stopped urgently. Following this, nothing should be administered via the cannula and it should be aspirated to remove any chemotherapy drug. Treatment is with topical corticosteroid, plastics referral (if required) and agent-specific antidotes, after receiving specialist advice.

6681

Rate this question:

6:17
On
MyPastest
594-042-7551
Leave
https://mypastest.pastest.com/Secure/TestMe/

Pastest+

A 35-year-old woman attended for routine follow-up following successful treatment for Hodgkin's disease at the age of 15 years with mantle radiotherapy. She was well and had no abnormal findings on examination.

Full blood count and biochemistry were normal. Routine chest X-ray was unremarkable. A breast MRI is arranged.

What other investigation is mandatory for this patient?

A	Bone marrow aspiration and trephine
B	Thyroid function tests
C	CT scan of the chest
D	ECHOcardiogram
E	Pulmonary function tests

Submit

Audio
Video
Share
Participants
More

6:17

A 35-year-old woman attended for routine follow-up following successful treatment for Hodgkin's disease at the age of 15 years with mantle radiotherapy. She was well and had no abnormal findings on examination.

Full blood count and biochemistry were normal. Routine chest X-ray was unremarkable. A breast MRI is arranged.

What other investigation is mandatory for this patient?

Your answer was incorrect

A Bone marrow aspiration and trephine

B Thyroid function tests

C CT scan of the chest

D ECHOcardiogram

E Pulmonary function tests

Explanation

B Thyroid function tests

Mantle radiotherapy was introduced during the 1960s for people with Hodgkin's disease and whose cancer was confined to lymph glands in the chest, neck or under the

Rana Alnasser's screen

B Thyroid function tests

Mantle radiotherapy was introduced during the 1960s for people with Hodgkin's disease and whose cancer was confined to lymph glands in the chest, neck or under the arms. The aim of the treatment was to give radiotherapy to all the lymph glands lying above the diaphragm.

Thyroid disease is common in patients irradiated in the mantle portion of the chest. Studies show that approximately one-third of patients who received radiotherapy between 1961 and 1989 had evidence of thyroid disease, with an actuarial risk of 52% at 20 years and 67% at 26 years. Hyperthyroidism is the most common problem, and the incidence of Graves' hyperthyroidism (Graves' disease) is small but still 7–20-fold more common than in people not receiving radiation therapy. Thyroid nodules appeared in a small percentage, with a very small percentage of papillary or follicular cancers forming. The risk of thyroid cancer is measured at over 15-fold that the general population.

Women who were treated with mantle radiotherapy are also at a greater risk of developing breast cancer. If they were treated in childhood, between 1 in 7 and 1 in 3 women will get breast cancer at some point in the 25 years following their Hodgkin's lymphoma treatment. If they were treated in their 20s, between 1 in 7 and 1 in 4 women will get breast cancer at some point in the 25 years following treatment.
The individual risk for any woman depends on:

- age when treated
- the total dose of radiotherapy administered
- time since radiotherapy administered
- current age.

Because of the increased breast cancer risk, the Department of Health has arranged for radiotherapy

Rana Alnasser's screen

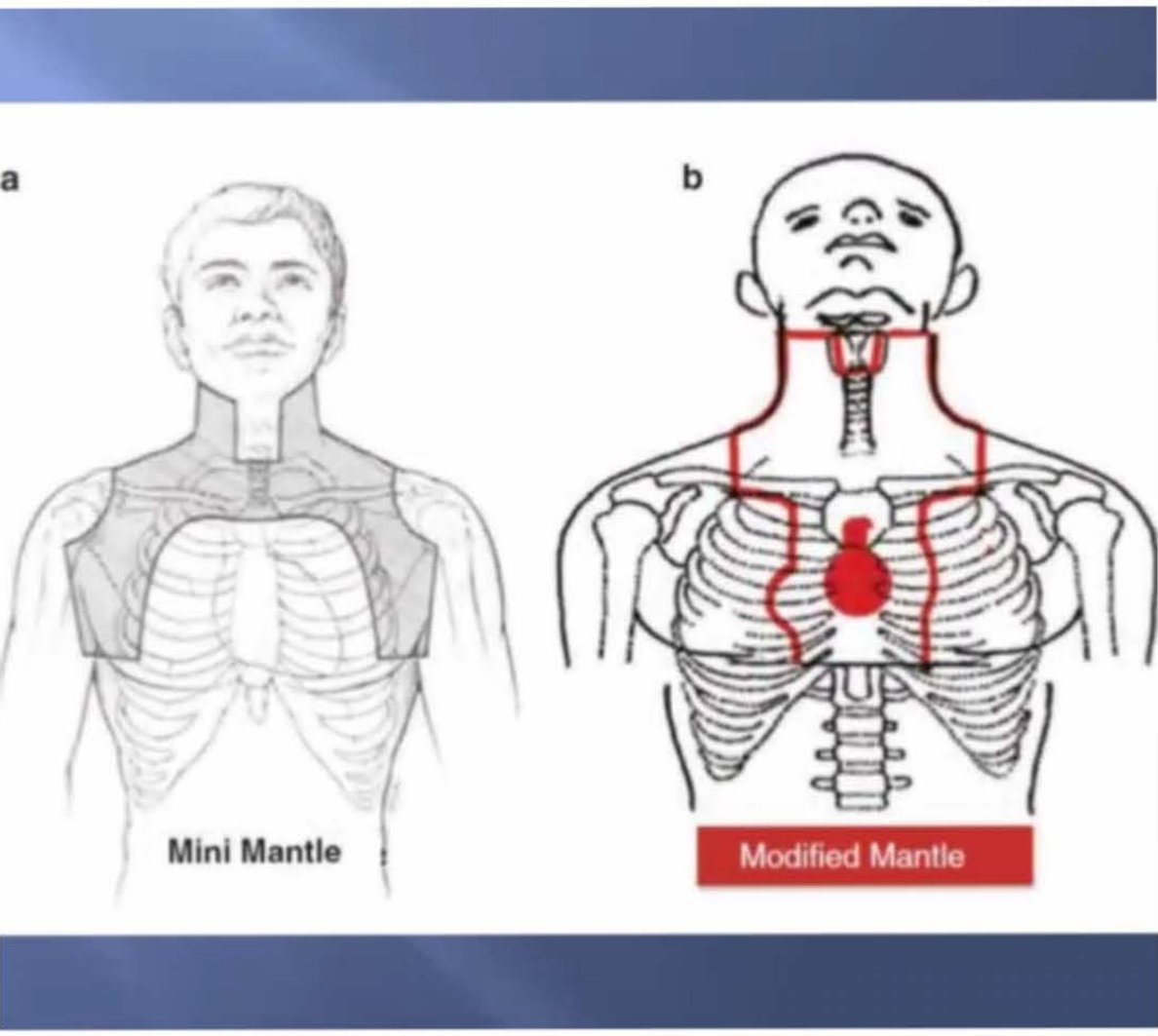

lideshare

tle technique

may be subject to copyright. Learn more

ED IMAGES

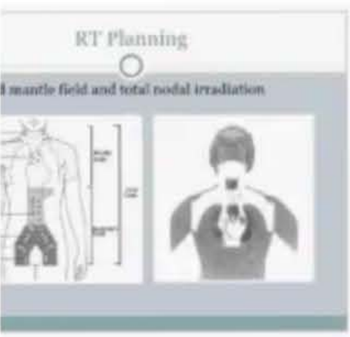

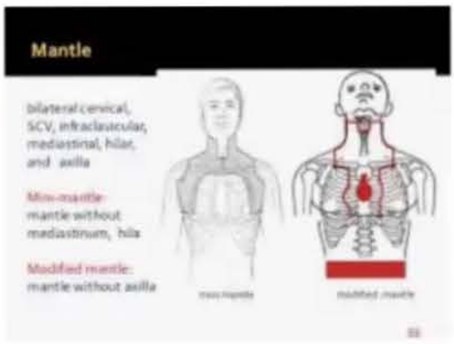

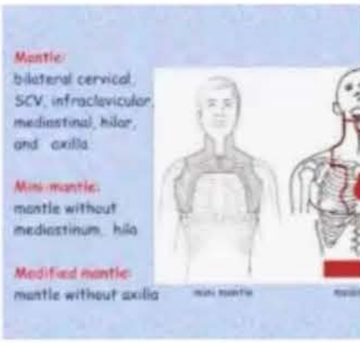

Discover Updates Search Recent More

6:21

E Pulmonary function tests

Radiation-induced lung fibrosis is seen although radiotherapy is targeted to the mediastinum in Hodgkin's, reducing the risk of significant pulmonary fibrosis.

A Bone marrow aspiration and trephine

The main dose of radiation from mantle radiotherapy affects the anterior neck and chest, and hence evaluation of the thyroid and breasts is most important.

C CT scan of the chest

CT scanning of the chest involves a further large dose of radiation. Where possible MRI imaging is preferred in this scenario.

D ECHOcardiogram

Over the long term radiotherapy can lead to constrictive pericarditis, although without any symptoms this is less likely to be the diagnosis here.

Rate this question:

Next Question

Rana Alnasser's screen

6:21

As a registrar at the Well-Women Clinic, you have just received the histology results via phone from the pathology department on a fine needle aspiration biopsy of a 35-year-old professional woman that indicates that she has a carcinoma of the breast. Your consultant is away and it is up to you to break the news to the patient who will be attending clinic the same afternoon.

Which of the following is important to adhere to when informing the patient of her diagnosis?

A	Phone the patient immediately and inform her of the bad news
B	Ensure you have a private room for her clinic consultation
C	Ensure that it is only you and the patient in the consulting room
D	Avoid eye contact
E	Reassure the patient that there is nothing to worry about given her young age

33407

Submit

Previous Q...

Rana Alnasser's screen

6:24

Explanation

B Ensure you have a private room for her clinic consultation

The way a doctor breaks bad news to a patient leaves an indelible mark on the patient–doctor relationship, and most doctors feel unprepared to deal with the emotional demands of such sessions. However, informing a patient that he or she has cancer for the first time is made easier for most doctors since hope can be offered in the form of treatment options. Talking face to face in a private room is obviously key with respect to allowing the patient time to voice concerns about her diagnosis.

C Ensure that it is only you and the patient in the consulting room

It's important to make sure that a third person joins you, such as a specialist nurse, who can offer further support and advice once the diagnosis has been discussed.

A Phone the patient immediately and inform her of the bad news

This leaves the discussion open to misinterpretation versus a face-to-face consultation, and leaving the patient without immediate support, particularly in the event that she is home alone.

D Avoid eye contact

It's important to maintain eye contact, repeating key points, listening to and not interrupting the patient, so that they have the maximum chance to gain key information about their diagnosis.

Rana Alnasser's screen

11:20

A 20-year-old man from Italy, previously fit and well, is admitted to hospital with jaundice. He had recently been commenced on antibiotics by a general practitioner (GP) for a presumed urinary tract infection.

Examination reveals jaundice, and a spleen tip is just palpable under the left costal margin.

Investigations:

Hb	9.3 g/dl
WCC	14×10^9/l
PLT	290×10^9/l
Na+	147 mmol/l
K+	4.3 mmol/l
Creatinine	85 µmol/l
Urea	7.2 mmol/l
Bilirubin	72 µmol/l
ALP	80 U/l
ALT	28 U/l
Albumin	39 g/dl
Blood film	Heinz bodies
Urine dipstick	Positive for urobilinogen and leukocyte esterase

What antibiotic is most appropriate for treating this patient?

A Chloramphenicol

Rana Alnasser's screen

11:21
594-042-7551
Leave

ALT	28 U/l
Albumin	39 g/dl
Blood film	Heinz bodies
Urine dipstick	Positive for urobilinogen and leukocyte esterase

What antibiotic is most appropriate for treating this patient?

A Chloramphenicol

B Nitrofurantoin

C Ciprofloxacin

D Co-amoxiclav

E Co-trimoxazole

7055

Annotation Stop Share
Audio Video Share Participants More

11:21
594-042-7551 Leave

D Co-amoxiclav

The patient has glucose-6-phoshate dehydrogenase (G6PD) deficiency, and Heinz bodies are the give-away here. The enzyme is required in the body for the conversion of glucose-6-phosphate to 6-phosphogluconolactone. This step is part of the hexose monophosphate pathway, needed for the generation of NADPH (reduced nicotinamide dinucleotide phosphate). NADPH maintains glutathione in a reduced form, which is required for the removal of oxidative metabolites.

Deficiency of this enzyme shows X-linked inheritance and results in haemolysis when the patient is exposed to oxidants.

A Chloramphenicol

Chloramphenicol leads to haemolysis in G6PD deficiency and should be avoided. It is now mainly used for infections such as Salmonella that are resistant to multiple other antibiotics.

B Nitrofurantoin

Although nitrofurantoin is effective in treating UTIs, it should be avoided in patients with G6PD deficiency.

C Ciprofloxacin

Urinary pathogens are exhibiting significant levels of resistance to quinolones, and they are a class that should be avoided in patients with G6PD deficiency.

E Co-trimoxazole

Co-trimoxazole is usually reserved for treatment of pneumocystis pneumonia, and is avoided in patients with

Audio Video Share Participants More

11:22
594-042-7551
Leave

An unknown middle-aged man has been brought into the Emergency Department, having been found collapsed in the street. He has a suicide note in his pocket, along with a quantity of various loose tablets.

One of the nursing staff recognises that some of the tablets are temazepam and others may be amitriptyline. His Glasgow Coma Scale (GCS) score is 9. Pupils are dilated, blood pressure (BP) is 122/82, pulse is 72 and regular and a finger-prick glucose is 5.6 mmol/l. His O_2 sats measured by probe are 90%. Electrocardiogram (ECG) reveals a QRS of 90 ms.

What would the next optimal treatment be?

A	Intravenous (iv) sodium bicarbonate
B	iv flumazenil
C	iv naloxone
D	Airway protection
E	iv glucagon

Submit

Audio
Video
Share
Participants
More

11:25
594-042-7551 Leave

D Airway protection

We are unaware of the time lapse since this patient took his overdose, and the relative contribution of benzodiazepines versus amitriptyline to his conscious level. As such, the most appropriate next intervention is protection of his airway, particularly as the GCS is significantly reduced at 9 and benzodiazepine reversal agents are contraindicated here.

A Intravenous (iv) sodium bicarbonate

Sodium bicarbonate is indicated in tricyclic antidepressant overdose when the QRS is greater than 100 ms, to reduce the risk of seizures and ventricular arrhythmia.

B iv flumazenil

Flumazenil is indicated only for acute overdose of benzodiazepines where there is no history of either chronic use of the class of medication or concomitant use of tricyclic antidepressants because of the risk of inducing seizures.

C iv naloxone

iv naloxone is a reversal agent for opiates, not for benzodiazepines.

E iv glucagon

iv glucagon used at high dose is a reversal agent in those patients who have taken an overdose of beta blockers.

Rate this question:

Next Question
Audio Video Share Participants More

11:28
594-042-7551
Leave

A 34-year-old taxi driver is admitted to your ward having taken a mixed overdose. His partner is en route to the hospital with the empty packets and bottles. Your house officer questions whether the use of multiple-dose activated charcoal could be used.

For which of the following overdoses is multiple-dose activated charcoal most useful?

A	Paraquat
B	Ferrous sulphate
C	Ethylene glycol
D	Carbamazepine
E	Lithium carbonate

Submit

Previous Q... Skip Questi...

© Pastest 2019

Audio Video Share Participants More

11:30

A 34-year-old taxi driver is admitted to your ward having taken a mixed overdose. His partner is en route to the hospital with the empty packets and bottles. Your house officer questions whether the use of multiple-dose activated charcoal could be used.

For which of the following overdoses is multiple-dose activated charcoal most useful?

Your answer was incorrect

A	Paraquat
B	Ferrous sulphate
C	Ethylene glycol
D	Carbamazepine
E	Lithium carbonate

Explanation

D Carbamazepine

Delayed gastric emptying is recognised in carbamazepine overdose, and multiple-dose activated charcoal is therefore a useful option. Repeated administration prevents delayed absorption of carbamazepine and is associated with improved outcomes. Other agents where multiple doses of activated charcoal can be given include dapsone, phenobarbitone, digoxin, theophylline and quinine.

Rana Alnasser's screen

D Carbamazepine

Delayed gastric emptying is recognised in carbamazepine overdose, and multiple-dose activated charcoal is therefore a useful option. Repeated administration prevents delayed absorption of carbamazepine and is associated with improved outcomes. Other agents where multiple doses of activated charcoal can be given include dapsone, phenobarbitone, digoxin, theophylline and quinine.

C Ethylene glycol

Activated charcoal is not of value in the treatment of methanol or ethylene glycol administration. The most important step here is inhibition of alcohol dehydrogenase, either with ethanol itself or fomepizole.

A Paraquat

Minimal amounts of paraquat are fatal when ingested; administration of Fuller's earth may reduce absorption, although activated charcoal has no role at all in the treatment of paraquat overdose.

B Ferrous sulphate

Ferrous sulphate does not have significant binding to activated charcoal. Removal of tablets via gastric lavage or whole-bowel irrigation are important potential options for treatment.

E Lithium carbonate

Activated charcoal has no impact on absorption of charged particles such as lithium and is therefore not the correct answer here. Where there is significant lithium overdose, haemodialysis is considered.

11:32
594-042-7551
Leave

Having taken several handfuls of aspirin tablets 4 h previously, a 45-year-old woman attends her local Emergency Department. She has symptoms of salicylism, with hyperventilation, sweating and tinnitus.

Which of the following is most appropriate to enhance the elimination of salicylate?

A	Single-dose oral activated charcoal
B	Sodium bicarbonate IV
C	Forced alkaline diuresis
D	Urinary acidification
E	Oral ipecacuanha

7567

Submit

Previous Q... Skip Questi...

© Pastest 2019

Audio Video Share Participants More

11:33
594-042-7551
Leave

Having taken several handfuls of aspirin tablets 4 h previously, a 45-year-old woman attends her local Emergency Department. She has symptoms of salicylism, with hyperventilation, sweating and tinnitus.

Which of the following is most appropriate to enhance the elimination of salicylate?

Your answer was incorrect

A	Single-dose oral activated charcoal
B	Sodium bicarbonate IV
C	Forced alkaline diuresis
D	Urinary acidification
E	Oral ipecacuanha

Explanation

B Sodium bicarbonate IV

Alkalinisation of the urine can be achieved by the administration of 1.5 l of 1.26% sodium bicarbonate IV over 3 h. If the urinary pH is increased from 5 to 8, the elimination of salicylate is increased up to a factor of 12. In this alkaline environment, the weakly acidic salicylate tends to become ionised and not resorbed from the tubular fluid.

C Forced alkaline diuresis
Audio Video Share Participants More

11:33
594-042-7551
Leave

B Sodium bicarbonate IV

Alkalinisation of the urine can be achieved by the administration of 1.5 l of 1.26% sodium bicarbonate IV over 3 h. If the urinary pH is increased from 5 to 8, the elimination of salicylate is increased up to a factor of 12. In this alkaline environment, the weakly acidic salicylate tends to become ionised and not resorbed from the tubular fluid.

C Forced alkaline diuresis

Forced alkaline diuresis can drive marked fluid shifts and may exacerbate the risk of pulmonary oedema, and for this reason it is best avoided here.

A Single-dose oral activated charcoal

Activated charcoal is usually given within 1 h of overdose to reduce drug absorption and multiple doses may increase elimination, although given the elapsed time here it's likely that urinary alkalinisation will be the more effective of the two.

D Urinary acidification

Urinary acidification is not used in the treatment of salicylic acid, which is already an acid. Urinary alkalinisation is, however, effective.

E Oral ipecacuanha

Administration of agents that drive vomiting, such as ipecacuanha, should be avoided here.

Rate this question
Audio Video Share Participants More

A 28-year-old man presents to A&E with a history of chest pain. He describes a burning retrosternal pain which is precipitated by heavy meals and worse on lying down. He denies any dysphagia, nausea, vomiting or haematemesis. His bowels are regular and there is no history of melaena. He has no past medical history or family history of note. There is a 30 units per week history of alcohol consumption.

On examination, he is comfortable, his pulse is 70 bpm and regular, heart sounds are normal and his chest is clear. His abdomen is soft and non-tender, with no masses or organomegaly. He has normal bowel sounds, and rectal examination reveals no blood, melaena or masses. Routine bloods, including a haemoglobin, are entirely normal. He plans to reduce his alcohol intake.

What is the most appropriate next step in management?

A	Oesophago-gastro-duodenoscopy (OGD)
B	Omeprazole 20 mg daily, clarithromycin 500 mg twice daily, and amoxicillin 1 g twice daily for one week
C	Omeprazole 40 mg daily for month
D	Barium swallow
E	Urea breath test

Submit

11:38

A 28-year-old man presents to A&E with a history of chest pain. He describes a burning retrosternal pain which is precipitated by heavy meals and worse on lying down. He denies any dysphagia, nausea, vomiting or haematemesis. His bowels are regular and there is no history of melaena. He has no past medical history or family history of note. There is a 30 units per week history of alcohol consumption.

On examination, he is comfortable, his pulse is 70 bpm and regular, heart sounds are normal and his chest is clear. His abdomen is soft and non-tender, with no masses or organomegaly. He has normal bowel sounds, and rectal examination reveals no blood, melaena or masses. Routine bloods, including a haemoglobin, are entirely normal. He plans to reduce his alcohol intake.

What is the most appropriate next step in management?

Your answer was correct

A Oesophago-gastro-duodenoscopy (OGD)

B Omeprazole 20 mg daily, clarithromycin 500 mg twice daily, and amoxicillin 1 g twice daily for one week

C Omeprazole 40 mg daily for month

D Barium swallow

E Urea breath test

Explanation

Rana Alnasser's screen

C Omeprazole 40 mg daily for month

This patient has symptoms of heartburn without any sinister symptoms such as vomiting, bleeding, weight loss, abdominal mass or dysphagia. He is also very young at the age of 28. In this case the optimal intervention is lifestyle advice, including advice on healthy eating, weight reduction, alcohol reduction, smoking cessation and promotion of antacid/alginate use. Full-dose proton pump inhibitor (PPI) for one month can also be considered.

A Oesophago-gastro-duodenoscopy (OGD)

Patients under the age of 55 without any significant alarm features do not require referral for endoscopy.

B Omeprazole 20 mg daily, clarithromycin 500 mg twice daily, and amoxicillin 1 g twice daily for one week

Helicobacter pylori eradication therapy is only required where presence of *H. pylori* is proven.

D Barium swallow

There are no significant features to suggest oesophageal obstruction; barium swallow is therefore not required.

E Urea breath test

If there is no response or relapse after PPI therapy, patients should have a test for *H. pylori* by carbon-13 urea breath test or stool antigen test, and subsequent eradication if necessary.

Rate this question:

11:39

A 30-year-old man is admitted one evening by the local out-of-hours general practitioner (GP). Although not his patient, he is able to tell you that the man has a history of schizophrenia, and has recently had his medications altered.

Clinically, he has evidence of a lower respiratory tract infection, and bloods taken earlier that day indicate a neutropenic picture.

What is the most likely causative agent?

A	Olanzapine
B	Clozapine
C	Risperidone
D	Sulpiride
E	Prochlorperazine

Submit

Previous Q... Skip Questi...

© Pastest 2019

Rana Alnasser's screen

11:39

Explanation

B Clozapine

Clozapine is an atypical antipsychotic used in the treatment of schizophrenia, and in patients who are intolerant to, or unresponsive to, other antipsychotics. Many antipsychotic drugs can cause bone marrow depression, but agranulocytosis is particularly associated with clozapine. The patient's leucocyte count and differential should be taken prior to its commencement, and at regular intervals thereafter. Agranulocytosis is seen in up to 32/100,000 weeks of observation within the first 18 weeks of therapy for patients treated with the drug.

A Olanzapine

Although decreases in white cell count are reported as common, reports of agranulocytosis exist as case reports only versus the quantified risk versus exposure identified for clozapine.

C Risperidone

Like olanazapine, agranulocytosis was not reported in clinical trials for risperidone but was reported in post-marketing case reports.

D Sulpiride

Like other anti-psychotics, agranulocytosis is reported but not commonly enough to estimate an exposure-response relationship.

E Prochlorperazine

Rana Alnasser's screen

A 32-year-old man with rheumatoid arthritis and bipolar disorder is brought to the Emergency Department complaining of bilateral deafness, tinnitus and blurred vision. These symptoms had started 3 h ago.

He is vomiting repeatedly on arrival in the Emergency Department and is restless, sweating and dehydrated. Respiratory rate is 34/min. His blood pressure is 102/70 mmHg and pulse is 86 and regular. His GCS is 13.

Investigations:

WCC	12×10^9/l
Hb	12 g/dl
Na^+	135 mmol/l
K^+	2.3 mmol/l

Arterial blood gases initially reveal:

pH	7.64
$paCO_2$	2.8 kPa
HCO_3^-	22 mmol/l
Chloride	90 mmol/l

and some 3 h later:

pH	7.3
$paCO_2$	2.8 kPa
HCO_3^-	10 mmol/l

What is the most likely underlying diagnosis?

A Ethylene glycol poisoning

B Metformin poisoning

Investigations:

WCC	12×10^9/l
Hb	12 g/dl
Na^+	135 mmol/l
K^+	2.3 mmol/l

Arterial blood gases initially reveal:

pH	7.64
$paCO_2$	2.8 kPa
HCO_3^-	22 mmol/l
Chloride	90 mmol/l

and some 3 h later:

pH	7.3
$paCO_2$	2.8 kPa
HCO_3^-	10 mmol/l

What is the most likely underlying diagnosis?

A	Ethylene glycol poisoning
B	Metformin poisoning
C	Naproxen poisoning
D	Salicylate poisoning
E	Sulfasalazine poisoning

Na^+	135 mmol/l
K^+	2.3 mmol/l

Arterial blood gases initially reveal:

pH	7.64
$paCO_2$	2.8 kPa
HCO_3^-	22 mmol/l
Chloride	90 mmol/l

and some 3 h later:

pH	7.3
$paCO_2$	2.8 kPa
HCO_3^-	10 mmol/l

What is the most likely underlying diagnosis?

Your answer was correct

A Ethylene glycol poisoning

B Metformin poisoning

C Naproxen poisoning

D Salicylate poisoning

E Sulfasalazine poisoning

Explanation

D Salicylate poisoning

This patient presented with bilateral deafness, tinnitus, visual blurring, repeated vomiting and initially had respiratory alkalosis followed by severe metabolic acidosis with an increased anion gap. These features are typical of salicylate poisoning.

Increased anion gap metabolic acidosis occurs is several conditions which include
(1) diabetic ketoacidosis;
(2) methanol overdose;
(3) ethylene glycol poisoning;
(4) lactic acidosis;
(5) salicylate poisoning.

It is calculated by the formula:

anion gap = plasma ([sodium] + [potassium]) - ([chloride] + [bicarbonate])

Normal values in health range between 8 and 14 mmol/l; in this patient the anion gap is 25 mmol/l.
Fluid resuscitation and urinary alkalinisation are mainstays of management for salicylate poisoning; in severe cases, where plasma concentration is >700 mg/l, haemodialysis may be considered. Indications for haemodialysis include:

- kidney disease
- congestive cardiac failure
- non-cardiogenic pulmonary oedema
- coma convulsions CNS effects not resolved by correction of acidosis
- persistently high salicylate concentrations unresponsive to urinary alkalinisation
- severe metabolic acidosis (pH <7.2).

A Ethylene glycol poisoning

Ethylene glycol poisoning is associated with a raised anion

A Ethylene glycol poisoning

Ethylene glycol poisoning is associated with a raised anion gap metabolic acidosis, but tinnitus and deafness are not features of ethylene glycol poisoning.

B Metformin poisoning

Metformin is associated with raised anion gap metabolic acidosis, but again is not associated with tinnitus.

C Naproxen poisoning

Naproxen poisoning is associated with headache, nausea, vomiting and epigastric pain, but is less likely to be associated with tinnitus compared to aspirin overdose

E Sulfasalazine poisoning

Sulfasalazine is associated with very low levels of acute toxicity in overdose.

Rate this question:

Next Question

© Pastest 2019

11:45
594-042-7551
Leave

A 26-year-old man is prescribed thalidomide for erythema nodosum that has been resistant to other therapeutic interventions. He has recently acquired a new female partner and asks about contraceptive advice.

Which of the following represents the correct advice with respect to contraception?

A	No precautions are needed as thalidomide only represents a risk if it is taken by the female partner
B	He should use barrier contraception and his partner should use effective contraception
C	Only the female need use contraception
D	The male should refrain from starting a family for 3 years after using thalidomide
E	Thalidomide is only teratogenic in the last trimester of pregnancy

Submit

Blog About Pastest Contact Us Help
Audio Video Share Participants More

11:46

B He should use barrier contraception and his partner should use effective contraception

Thalidomide can be transferred in semen and, as such, males should be advised to use barrier contraception until at least 1 week after cessation of therapy. Two modes of contraception (male and female) are recommended to minimise the risk of the female becoming pregnant.

A No precautions are needed as thalidomide only represents a risk if it is taken by the female partner

As thalidomide can be transmitted in semen, adequate contraception for the male and female is essential.

C Only the female need use contraception

Due to the (albeit low) failure rate of female contraception, protection for the male and female is recommended.

D The male should refrain from starting a family for 3 years after using thalidomide

Only a 1-week thalidomide-free period is needed.

E Thalidomide is only teratogenic in the last trimester of pregnancy

The original thalidomide malformations were identified following use for first trimester morning sickness.

18634

Rate this question:

Next Question

Rana Alnasser's screen

A 30-year-old woman attends A&E with a 3-day history of fever, abdominal pain and dysuria. Her past medical history includes migraine, for which she takes sumatriptan prophylactically, and mild childhood asthma for which she has a salbutamol inhaler which she has not needed to use for years. She is looking forward to going on holiday to Tanzania in a week's time, and has just started primaquine for malarial prophylaxis. She is a non-smoker and drinks alcohol socially. She works for an advertising company.

Clinical examination is unremarkable, except for some suprapubic tenderness but no loin pain. Her urinalysis is positive for white blood cells and nitrites, and a pregnancy test negative. She is discharged on trimethoprim for a urinary tract infection, and given codeine for the abdominal pain.

She returns to A&E 2 days later with headache, nausea, dizziness and mild dyspnoea. On examination, she is slightly agitated, and appears cyanosed. Her temperature is 36.2 °C. Her pulse is 100 bpm, regular and blood pressure is 106/66 mmHg. Heart sounds are normal. Her respiratory rate is 30/min, but her chest sounds clear, with no crepitations or wheeze. Oxygen saturations are 85%. Her abdomen is soft and non-tender, with normal bowel sounds.

ECG shows sinus tachycardia. Chest X-ray appears clear.

Her ABG reveals a PO_2 of 12.6 kPa.

Her primaquine and trimethoprim are stopped.

What would be the next most appropriate step?

A	Give IV methylene blue
B	Give IV hydrocortisone
C	Stop sumatriptan

alcohol socially. She works for an advertising company.

Clinical examination is unremarkable, except for some suprapubic tenderness but no loin pain. Her urinalysis is positive for white blood cells and nitrites, and a pregnancy test negative. She is discharged on trimethoprim for a urinary tract infection, and given codeine for the abdominal pain.

She returns to A&E 2 days later with headache, nausea, dizziness and mild dyspnoea. On examination, she is slightly agitated, and appears cyanosed. Her temperature is 36.2 °C. Her pulse is 100 bpm, regular and blood pressure is 106/66 mmHg. Heart sounds are normal. Her respiratory rate is 30/min, but her chest sounds clear, with no crepitations or wheeze. Oxygen saturations are 85%. Her abdomen is soft and non-tender, with normal bowel sounds.

ECG shows sinus tachycardia. Chest X-ray appears clear.

Her ABG reveals a PO_2 of 12.6 kPa.

Her primaquine and trimethoprim are stopped.

What would be the next most appropriate step?

A	Give IV methylene blue
B	Give IV hydrocortisone
C	Stop sumatriptan
D	CT head
E	Commence noninvasive positive pressure ventilation (NIPPV)

11:53

urinary tract infection, and given codeine for the abdominal pain.

She returns to A&E 2 days later with headache, nausea, dizziness and mild dyspnoea. On examination, she is slightly agitated, and appears cyanosed. Her temperature is 36.2 °C. Her pulse is 100 bpm, regular and blood pressure is 106/66 mmHg. Heart sounds are normal. Her respiratory rate is 30/min, but her chest sounds clear, with no crepitations or wheeze. Oxygen saturations are 85%. Her abdomen is soft and non-tender, with normal bowel sounds.

ECG shows sinus tachycardia. Chest X-ray appears clear.

Her ABG reveals a PO_2 of 12.6 kPa.

Her primaquine and trimethoprim are stopped.

What would be the next most appropriate step?

Your answer was correct

A	Give IV methylene blue
B	Give IV hydrocortisone
C	Stop sumatriptan
D	CT head
E	Commence noninvasive positive pressure ventilation (NIPPV)

Explanation

A Give IV methylene blue

The patient has methaemoglobinaemia, which may be due

Rana Alnasser's screen

11:53

A Give IV methylene blue

The patient has methaemoglobinaemia, which may be due to trimethoprim and/or primaquine. Other causative agents include sulphonamides, lidocaine, dapsone, phenacetin, chloroquine, amyl nitrate, metoclopramide and aniline dyes.

Methaemoglobin inducers act by oxidising ferrous (Fe^{2+}) to ferric (Fe^{3+}) haemoglobin. This abnormal haemoglobin is incapable of carrying oxygen, inducing a functional anaemia. In addition, the shape of the oxygen–haemoglobin dissociation curve is altered, aggravating cellular hypoxia. Severity of symptoms usually correlates with measured methaemoglobin levels, and they are caused by decreased oxygen content and cellular hypoxia. They include headache, dizziness and nausea, progressing to dyspnoea, confusion, seizures and coma. Even at low levels, skin discolouration ('chocolate cyanosis'), especially of the nails, lips and ears, is striking. Diagnosis is suggested by a normal PO_2 in the presence of cyanosis and low O_2 saturations. The blood also appears chocolate brown when compared with normal blood. Methaemoglobin levels can be measured by the co-oximeter type of arterial blood gas analyser. Usually mild methaemoglobinaemia (<15–20%) resolves spontaneously and requires no intervention. Methylene blue is indicated in the symptomatic patient with methaemoglobin levels >20% or when even minimal compromise of oxygen-carrying capacity is potentially harmful (pre-existing anaemia, cardiac failure, ischaemic heart disease). Methylene blue is given at 1–2 mg/kg over several minutes. The causative agent should also be discontinued.

B Give IV hydrocortisone

The picture here is more consistent with hypoxia related to methaemoglobinaemia rather than acute asthma; IV hydrocortisone is therefore not of value here.

Rana Alnasser's screen

several minutes. The causative agent should also be discontinued.

B Give IV hydrocortisone

The picture here is more consistent with hypoxia related to methaemoglobinaemia rather than acute asthma; IV hydrocortisone is therefore not of value here.

C Stop sumatriptan

Although this patient has headache, it is as a result of hypoxia rather than migraine, hence sumatriptan is not of value.

D CT head

Given the lack of focal neurology and normal blood pressure, an intracerebral lesion accounting for the headache is very unlikely.

E Commence noninvasive positive pressure ventilation (NIPPV)

Given the methaemoglobinaemia, improved delivery of oxygen via NIPPV is only likely to have a minor impact on symptoms of hypoxia.

Rana Alnasser's screen

A 70-year-old woman is seen in clinic, complaining of low mood and anhedonia. Her only past medical history is of atrial fibrillation, for which she takes digoxin and warfarin. Her rate is well controlled at 68 bpm. She feels she has become more withdrawn and would like to consider an antidepressant treatment.

Which is the most appropriate treatment which would minimises any effect on her warfarin treatment?

A	Fluoxetine
B	Venlafaxine
C	Amitriptyline
D	St John's Wort
E	Paroxetine

Submit

Previous Q... Skip Questi...

© Pastest 2019

11:59
594-042-7551
Leave

A 70-year-old woman is seen in clinic, complaining of low mood and anhedonia. Her only past medical history is of atrial fibrillation, for which she takes digoxin and warfarin. Her rate is well controlled at 68 bpm. She feels she has become more withdrawn and would like to consider an antidepressant treatment.

Which is the most appropriate treatment which would minimises any effect on her warfarin treatment?

Your answer was incorrect

A Fluoxetine

B Venlafaxine

C Amitriptyline

D St John's Wort

E Paroxetine

A
B
C
D
E
0

Resp
Resp
Resp
Resp

Explanation

C Amitriptyline

Amitriptyline is a tricyclic antidepressant which does not interact with warfarin. Whilst amitriptyline increases the risk of atrial fibrillation, this woman already has the condition and is rate controlled, so the extra risk associated

Audio Video Share Participants More

11:59

MyPastest
https://mypastest.pastest.com

Pastest+

Explanation

C Amitriptyline

Amitriptyline is a tricyclic antidepressant which does not interact with warfarin. Whilst amitriptyline increases the risk of atrial fibrillation, this woman already has the condition and is rate controlled, so the extra risk associated with prescribing it for depression is low.

B Venlafaxine

Like SSRIs, SNRIs also inhibit platelet function, this is thought to be because of a decrease in intraplatelet 5-HT.

A Fluoxetine

SSRIs enhance the anticoagulant effect of warfarin by interfering with platelet function.

D St John's Wort

St John's Wort is derived from the herb *Hypericum perforatum*, and can reduce the anticoagulant effect of warfarin because of P450 enzyme induction.

E Paroxetine

Paroxetine, like fluoxetine, is an SSRI, which is recognised to interfere with platelet function.

Rate this question:

12:01
594-042-7551
Leave

A 43-year-old woman presents to the clinic feeling very depressed about weight gain that has occurred over the past two to three years. This is against a background of caring for three young school-age children.

She takes no medication of note, and has no significant past medical history.

On examination, her BP is 144/82 mmHg and her BMI is 31. A fasting glucose is measured at 6.2 mmol/l.

Which of the following is the most appropriate next step?

A	Metformin
B	Liraglutide
C	Gastric banding
D	Group-based dietary intervention
E	Prescribed exercise

Submit

Audio
Video
Share
Participants
More

A 43-year-old woman presents to the clinic feeling very depressed about weight gain that has occurred over the past two to three years. This is against a background of caring for three young school-age children.

She takes no medication of note, and has no significant past medical history.

On examination, her BP is 144/82 mmHg and her BMI is 31. A fasting glucose is measured at 6.2 mmol/l.

Which of the following is the most appropriate next step?

Your answer was correct

A	Metformin
B	Liraglutide
C	Gastric banding
D	Group-based dietary intervention
E	Prescribed exercise

Explanation

D	Group-based dietary intervention

Group weight loss programmes have been shown to be superior to individual effort with respect to dieting. As such, WeightWatchers, Slimming World and other such clubs are recommended to patients for initial weight

Explanation

D Group-based dietary intervention

Group weight loss programmes have been shown to be superior to individual effort with respect to dieting. As such, WeightWatchers, Slimming World and other such clubs are recommended to patients for initial weight management.

A Metformin

Metformin causes very modest weight loss and in this context (impaired fasting glucose), diet and exercise are superior to pharmacological intervention.

B Liraglutide

Liraglutide 3 mg is licensed for weight loss, but in this case with a BMI of 31, a period of attempted diet and exercise alone is advised.

C Gastric banding

Gastric banding is recommended for patients with morbid obesity and who are unable to lose weight by other means and have significant co-existing medical complications of obesity.

E Prescribed exercise

Although prescribed exercise will significantly impact on cardiovascular fitness, it has little impact on weight control

A 21-year-old man is admitted unconscious. There is no history available.

On examination, his Glasgow Coma Scale (GCS) score is 3/15, blood pressure is 122/82 mmHg, pulse is 75 bpm and regular, respiratory rate is 14. There are stigmata of previous self-harm. He is intubated and sent to the ITU. A toxicity screen is sent and shows a paracetamol level of 330 μg/ml. *N*-acetylcysteine is commenced. On day 2, he is extubated. His progress is monitored over the next few days.

Which of the following is the most important determinant of liver transplant in paracetamol overdose?

A	Alanine aminotransferase (ALT)
B	pH
C	Prothrombin time (PT)
D	Bicarbonate
E	Alkaline phosphatase

A 21-year-old man is admitted unconscious. There is no history available.

On examination, his Glasgow Coma Scale (GCS) score is 3/15, blood pressure is 122/82 mmHg, pulse is 75 bpm and regular, respiratory rate is 14. There are stigmata of previous self-harm. He is intubated and sent to the ITU. A toxicity screen is sent and shows a paracetamol level of 330 µg/ml. *N*-acetylcysteine is commenced. On day 2, he is extubated. His progress is monitored over the next few days.

Which of the following is the most important determinant of liver transplant in paracetamol overdose?

Your answer was correct

A Alanine aminotransferase (ALT)

B pH

C Prothrombin time (PT)

D Bicarbonate

E Alkaline phosphatase

Explanation

B pH

The King's College Hospital criteria for liver transplantation

B pH

The King's College Hospital criteria for liver transplantation in paracetamol-induced acute liver failure are what drive the answer to this question. They state that a patient should be listed for transplantation if arterial pH <7.3 or arterial lactate >3.0 mmol/l after adequate fluid resuscitation.

A Alanine aminotransferase (ALT)

Elevated transaminases are not considered a criterion for liver transplantation. Although elevated transaminases may demonstrate hepatocellular damage, it is impaired hepatic synthetic function which most affects outcomes.

C Prothrombin time (PT)

PT is one of three other criteria apart from pH which may drive transplantation; all three should be satisfied in a 24-hour period:

- Creatinine >300 μmol/l
- PT >100 (INR >6.5)
- Grade III/IV encephalopathy.

D Bicarbonate

Although low bicarbonate is a pointer to metabolic acidosis, it is decompensated metabolic acidosis with low pH which drives referral for transplantation.

E Alkaline phosphatase

C Prothrombin time (PT)

PT is one of three other criteria apart from pH which may drive transplantation; all three should be satisfied in a 24-hour period:

- Creatinine >300 μmol/l
- PT >100 (INR >6.5)
- Grade III/IV encephalopathy.

D Bicarbonate

Although low bicarbonate is a pointer to metabolic acidosis, it is decompensated metabolic acidosis with low pH which drives referral for transplantation.

E Alkaline phosphatase

Like ALT, alkaline phosphatase may be elevated in paracetamol-related liver failure, but it is not strongly associated with outcomes.

© Pastest 2019

A 72-year-old woman is admitted to hospital with symptoms of weakness. She describes intermittent double vision and difficulty chewing and swallowing food. The patient has a background of angina, rheumatoid arthritis, atrial fibrillation and hypertension.

On examination, she has a general paucity of facial expression and she appears to be frowning her forehead intermittently. There is symmetrical upper limb weakness, while lower limb power is normal. She has normal sensation and reflexes are normal. She has ptosis that appears to fluctuate. Eye movements appear to be normal.

What is the most likely medication in this patient that could cause these symptoms?

A	Nitrates
B	Penicillamine
C	Methotrexate
D	Hydralazine
E	Amiodarone

Submit

12:08
594-042-7551
Leave

A 72-year-old woman is admitted to hospital with symptoms of weakness. She describes intermittent double vision and difficulty chewing and swallowing food. The patient has a background of angina, rheumatoid arthritis, atrial fibrillation and hypertension.

On examination, she has a general paucity of facial expression and she appears to be frowning her forehead intermittently. There is symmetrical upper limb weakness, while lower limb power is normal. She has normal sensation and reflexes are normal. She has ptosis that appears to fluctuate. Eye movements appear to be normal.

What is the most likely medication in this patient that could cause these symptoms?

Your answer was incorrect

A	Nitrates
B	Penicillamine
C	Methotrexate
D	Hydralazine
E	Amiodarone

Explanation

Audio
Video
Share
Participants
More

B Penicillamine

This patient has symptoms suggestive of myasthenia gravis (MG). Symptoms include weakness of facial muscles, ptosis (which can cause compensatory use of the frontalis muscle), extraocular muscle weakness, poor swallow and speech. Respiratory muscle involvement is a serious complication. The weakness worsens with exercise and reflexes are normal. Penicillamine can cause MG, and patients can have raised acetylcholine receptor antibodies. It is used for the treatment of rheumatoid arthritis and as a chelator for copper in Wilson's disease. Side-effects of penicillamine also include proteinuria and a lupus-like syndrome. Stopping penicillamine should reverse the myasthenic symptoms in the majority of cases.

D Hydralazine

Hydralazine is most strongly associated with drug-induced lupus (seen in up to 20% of patients who take the medication).

A Nitrates

Nitrates can result in headaches and syncope rather than MG.

C Methotrexate

Methotrexate results in hepatic and pulmonary fibrosis; liver function test and pulmonary function test monitoring during therapy is advised.

E Amiodarone

Rana Alnasser's screen

It is used for the treatment of rheumatoid arthritis and as a chelator for copper in Wilson's disease. Side-effects of penicillamine also include proteinuria and a lupus-like syndrome. Stopping penicillamine should reverse the myasthenic symptoms in the majority of cases.

D Hydralazine

Hydralazine is most strongly associated with drug-induced lupus (seen in up to 20% of patients who take the medication).

A Nitrates

Nitrates can result in headaches and syncope rather than MG.

C Methotrexate

Methotrexate results in hepatic and pulmonary fibrosis; liver function test and pulmonary function test monitoring during therapy is advised.

E Amiodarone

Amiodarone is associated with pulmonary fibrosis and skin photosensitivity.

Rate this question:

Next Question

Previous Q... Tag Questi... Feedback End Session

12:09
594-042-7551
Leave

A 38-year-old patient is admitted with an overdose of aspirin. She has a background of depression and self-harm. The patient admitted the overdose to her friend and states she took the overdose about 5 h ago. You understand from her friend that she took approximately 80 × 500 mg aspirin tablets. She is complaining of nausea and tinnitus.

On examination, her pulse is 115 bpm regular, respiratory rate 24/min, blood pressure 145/80 mmHg.

Investigations:

Blood gases on air

pH	7.28
$p_a(O_2)$	12.3 kPa
$p_a(CO_2)$	3.3 kPa

Hb	14.1 g/dl
WCC	5.5×10^9/l
PLT	235×10^9/l
Bicarbonate	15 mmol/l
Na^+	142 mmol/l
K^+	3.1 mmol/l
Urea	6.3 mmol/l
Creatinine	82 µmol/l
Salicylate	55 mg/dl

What is the next management step?

A. IV bicarbonate

Audio Video Share Participants More

pH	7.28
$p_a(O_2)$	12.3 kPa
$p_a(CO_2)$	3.3 kPa

Hb	14.1 g/dl
WCC	5.5×10^9/l
PLT	235×10^9/l
Bicarbonate	15 mmol/l
Na^+	142 mmol/l
K^+	3.1 mmol/l
Urea	6.3 mmol/l
Creatinine	82 µmol/l
Salicylate	55 mg/dl

What is the next management step?

A IV bicarbonate

B IV ammonium chloride

C IV potassium replacement

D IV β-blockade

E IV magnesium

Investigations:

Blood gases on air

pH	7.28
$p_a(O_2)$	12.3 kPa
$p_a(CO_2)$	3.3 kPa

Hb	14.1 g/dl
WCC	5.5×10^9/l
PLT	235×10^9/l
Bicarbonate	15 mmol/l
Na^+	142 mmol/l
K^+	3.1 mmol/l
Urea	6.3 mmol/l
Creatinine	82 µmol/l
Salicylate	55 mg/dl

What is the next management step?

Your answer was incorrect

A IV bicarbonate

B IV ammonium chloride

C IV potassium replacement

C IV potassium replacement

Potassium replacement is the key next step in patients presenting with aspirin overdose who have significant hypokalaemia. As potassium falls near to and below 3.0 mmol/l, the risk of cardiac arrhythmia is significantly elevated.

A IV bicarbonate

IV bicarbonate is recommended when pH is particularly low (around 7.1 or lower). In this situation, with a very large overdose, progression to dialysis is likely (it is indicated when levels approach 700 mg/l and with deteriorating acidosis or conscious level).

B IV ammonium chloride

Ammonium chloride can be considered for urinary alkalinisation, but at this stage potassium replacement is most important.

D IV β-blockade

As acidosis worsens this patient is likely to become increasingly haemodynamically unstable. Beta-blockade is therefore not indicated for treatment of tachycardia.

E IV magnesium

Although the patient may be hypomagnesaemic, potassium replacement should be commenced first.

32790

Rate this question:

A 39-year-old woman who is pregnant with her first child comes to the clinic for review. She had chronic hypertension prior to becoming pregnant and was treated with ramipril, but this was changed to methyldopa. She is now 20 weeks' pregnant and the dose was recently increased to 1 g BD. Unfortunately, she has an excessively dry mouth and feels tired all the time and wants the medication changed to something else.

On examination, her blood pressure (BP) is 145/90 mmHg compared to 148/88 mmHg at her booking visit.

Investigations:

Haemoglobin (Hb)	10.8 g/dl
White cell count (WCC)	5.6×10^9/l
Platelets (PLT)	201×10^9/l
Sodium (Na^+)	140 mmol/l
Potassium (K^+)	4.5 mmol/l
Creatinine (Cr)	90 μmol/l

Which of the following would be the most appropriate medication from the list below to switch her to?

A Ramipril

B Bendroflumethiazide

C Valsartan

D Atenolol

E Labetalol

12:13

Explanation

E Labetalol

Labetalol is not associated with intra-uterine growth retardation (as is seen with some other beta blockers), and hence it is now the recommended NICE first-line intervention for control of hypertension in pregnancy.

A Ramipril

ACE inhibitors are contraindicated in pregnancy and are associated with a range of fetal abnormalities including renal and skeletal malformations.

B Bendroflumethiazide

This reduces the volume expansion associated with normal pregnancy and is also associated with renal tract abnormalities.

C Valsartan

Like ACE inhibitors, ARBs are associated with renal tract and skeletal abnormalities in the fetus when prescribed in pregnancy.

D Atenolol

This is not associated with congenital malformations, but is associated with intra-uterine growth retardation, driving the use of labetalol in preference to it.

Rate this question:

Rana Alnasser's screen

12:14
594-042-7551
Leave

A 25-year-old woman was brought to the Emergency Department with a history of episodic abnormal posturing of her torso and neck for the past few hours. She had a long history of behavioural problems and was known to have had brawls with her neighbours. Her mother had recently taken her to the psychiatrist and she has been initiated on antipsychotic medication.

On examination, she was afebrile. Her neck was in forced extension, there was arching of her back and her arms were internally rotated. There was extension of the elbows and wrists.

What is the correct description of her clinical picture?

A	Decerebrate rigidity
B	Anterocollis
C	Opisthotonus
D	Chorea
E	Decorticate posturing

32856

Submit

Audio
Video
Share
Participants 3
More

A 25-year-old woman was brought to the Emergency Department with a history of episodic abnormal posturing of her torso and neck for the past few hours. She had a long history of behavioural problems and was known to have had brawls with her neighbours. Her mother had recently taken her to the psychiatrist and she has been initiated on antipsychotic medication.

On examination, she was afebrile. Her neck was in forced extension, there was arching of her back and her arms were internally rotated. There was extension of the elbows and wrists.

What is the correct description of her clinical picture?

Your answer was correct

A Decerebrate rigidity

B Anterocollis

C Opisthotonus

D Chorea

E Decorticate posturing

Explanation

C Opisthotonus

This is the typical picture of an acute generalised dystonic reaction to neuroleptic drugs (e.g. phenothiazines

C Opisthotonus

This is the typical picture of an acute generalised dystonic reaction to neuroleptic drugs (e.g. phenothiazines, butyrophenones, metoclopramide and even atypical antipsychotic agents such as olanzapine). The description given here (retrocollis, arching of the back, internal rotation of the arms and extension of the elbows) suggests an extreme dystonic reaction in the form of opisthotonus. Opisthotonus also occurs in other neurological situations, including (classically) tetanus or hypoxic-ischaemic brain injury. It is also seen in strychnine poisoning.

A Decerebrate rigidity

Decerebrate rigidity results from a midbrain lesion and is manifest by an exaggerated extensor posture of all four limbs.

B Anterocollis

Anterocollis is forward flexion of the head and neck, rather than the extensor posture seen here.

D Chorea

Chorea is abnormal involuntary movement characterised by brief, abrupt, irregular, unpredictable, non-stereotyped movements.

E Decorticate posturing

Decorticate posturing is characterised by arm flexion and inward turning, extended lower limbs.

A 68-year-old man is admitted to the Emergency Department with an acute myocardial infarction. He is hypotensive and sweating on admission, with a BP of 100/60 mmHg and pulse of 105/min. There is anterior ST elevation. Past history of note is hypertension, for which he receives ramipril 5 mg, indapamide 2.5 mg and amlodipine 5 mg.

Within a few minutes of admission, he suffers a cardiac arrest. In total he receives CPR for 6 min before he regains his output. His BP is 95/60 mmHg, with pulse 100/min and regular. He later goes to the catheter lab where he is stented. Creatinine on admission is 135 micromol/l.

What is the optimal initial intervention to prevent acute tubular necrosis?

A	Start IV furosemide
B	Start renal dose dopamine
C	Start dobutamine
D	Increase ramipril
E	Fluid replacement with CVP monitoring

36523

Submit

A 65 year old man is admitted to the Emergency Department with an acute myocardial infarction. He is hypotensive and sweating on admission, with a BP of 100/60 mmHg and pulse of 105/min. There is anterior ST elevation. Past history of note is hypertension, for which he receives ramipril 5 mg, indapamide 2.5 mg and amlodipine 5 mg.

Within a few minutes of admission, he suffers a cardiac arrest. In total he receives CPR for 6 min before he regains his output. His BP is 95/60 mmHg, with pulse 100/min and regular. He later goes to the catheter lab where he is stented. Creatinine on admission is 135 micromol/l.

What is the optimal initial intervention to prevent acute tubular necrosis?

Your answer was correct

A	Start IV furosemide
B	Start renal dose dopamine
C	Start dobutamine
D	Increase ramipril
E	Fluid replacement with CVP monitoring

Explanation

E	Fluid replacement with CVP monitoring

This patient is at significant risk of ischaemic acute tubular necrosis due to a prolonged period of renal hypoperfusion associated with his anterior MI and subsequent cardiac

E Fluid replacement with CVP monitoring

This patient is at significant risk of ischaemic acute tubular necrosis due to a prolonged period of renal hypoperfusion associated with his anterior MI and subsequent cardiac arrest. Maintaining CVP in the normal range with tailored fluid replacement is the best way to minimise deterioration in renal function.

A Start IV furosemide

Although loop diuretics are used in this situation, there is little evidence that they have a positive impact on renal outcomes.

B Start renal dose dopamine

Although renal dose dopamine was historically used to prevent ATN, there is no evidence that it is any more effective than placebo.

C Start dobutamine

Dobutamine is used as a cardiac inotrope, and may increase the risk of arrhythmia and myocardial ischaemia in this situation.

D Increase ramipril

Ramipril increases the risk of renal hypoperfusion and has a potentially negative impact on the risk of ATN.

36523

Rate this question:

12:18
594-042-7551
Leave

An 18-year-old woman is admitted to the Emergency Department. She has begun vomiting and feels that she cannot keep any food down at all. She admits to taking an overdose of 48 × 500 mg paracetamol tablets some three days earlier because of concerns about her A-level exams. There is no past medical history of note.

On examination, her blood pressure (BP) is 100/60 mmHg, with pulse 85/min and regular. She is markedly tender in the right upper quadrant of her abdomen.

Investigations:

Haemoglobin (Hb)	12.2 g/dl
White cell count (WCC)	11.1×10^9/l
Platelet (PLT)	203×10^9/l
Sodium (Na^+)	140 mmol/l
Potassium (K^+)	5.3 mmol/l
Bicarbonate	18 mmol/l
Creatinine (Cr)	141 umol/l
International normalised ratio (INR)	4.2
Alanine transaminase (ALT)	3430 U/l

Which of the above is the most important indication for referral to a specialist unit?

A ALT 3430 U/l

B Bicarbonate 18 mmol/l

C Creatinine 141 μmol/l/l

D INR 4.2

Audio Video Share Participants More

There is no past medical history of note.

On examination, her blood pressure (BP) is 100/60 mmHg, with pulse 85/min and regular. She is markedly tender in the right upper quadrant of her abdomen.

Investigations:

Haemoglobin (Hb)	12.2 g/dl
White cell count (WCC)	11.1×10^9/l
Platelet (PLT)	203×10^9/l
Sodium (Na^+)	140 mmol/l
Potassium (K^+)	5.3 mmol/l
Bicarbonate	18 mmol/l
Creatinine (Cr)	141 umol/l
International normalised ratio (INR)	4.2
Alanine transaminase (ALT)	3430 U/l

Which of the above is the most important indication for referral to a specialist unit?

A	ALT 3430 U/l
B	Bicarbonate 18 mmol/l
C	Creatinine 141 µmol/l/l
D	INR 4.2
E	K^+ 5.3 mmol/l

Rana Alnasser's screen

D INR 4.2

Elevated INR is a strong indicator of impaired hepatic synthetic function, and INR >2.0 at or before 48 h or >3.5 at or before 72 h (peak elevation occurs around 72-96 h), is an indication for referral to a specialist liver unit. INR >6.5 is an indication for referral for liver transplant.

A ALT 3430 U/l

Although ALT elevation is indicative of hepatocellular necrosis, it is impaired hepatic synthetic function that is most predictive of poor outcome in paracetamol overdose.

B Bicarbonate 18 mmol/l

Bicarbonate isn't called out as an indicator for specialist referral, although arterial pH <7.3 or lactate >3.0 mmol/l after adequate fluid resuscitation are reasons to refer.

C Creatinine 141 µmol/l/l

Creatinine >200 is considered a criterion for specialist referral, with creatinine >300 one of the criteria for referral for liver transplant.

E K^+ 5.3 mmol/l

This is towards the upper end of the normal range, but is likely to correct with adequate fluid resuscitation.

Rate this question:

Next Question

A 26-year old woman who is 36 weeks pregnant presents with a history of palpitations, sweating and diarrhoea. She has no past medical history of note and her pregnancy has otherwise been unremarkable.

On examination, she has a resting tremor. Her pulse is 100 bpm, regular. Blood pressure is 118/68 mmHg. Heart sounds are normal. Her chest is clear and abdominal examination reveals a gravid uterus correct for her dates.

Blood results are as follows:

Hb	12.6 g/dl
WCC	6.2×10^9/l
PLT	214×10^9/l
MCV	86 fl
Na^+	142 mmol/l
K^+	4.1 mmol/l
Creatinine	62 µmol/l
Urea	4.2 mmol/l
Bilirubin	6 µmol/l
Albumin	38 g/l
Alkaline phosphatase	68 U/l
ALT	26 U/l
TSH	0.01 mU/l (0.4–5 mU/l)
Free T4	36.4 pmol/l

She plans to breastfeed her baby after delivery.

What is the most appropriate therapy?

A Lugol's iodine

Rana Alnasser's screen

MCV	88 fl
Na^+	142 mmol/l
K^+	4.1 mmol/l
Creatinine	62 µmol/l
Urea	4.2 mmol/l
Bilirubin	6 µmol/l
Albumin	38 g/l
Alkaline phosphatase	68 U/l
ALT	26 U/l
TSH	0.01 mU/l (0.4–5 mU/l)
Free T4	36.4 pmol/l

She plans to breastfeed her baby after delivery.

What is the most appropriate therapy?

A Lugol's iodine

B Carbimazole

C Propylthiouracil

D Radioiodine therapy after delivery of the baby

E Blocking dose of carbimazole with supplemental thyroxine

MCV	88 fl
Na^+	142 mmol/l
K^+	4.1 mmol/l
Creatinine	62 µmol/l
Urea	4.2 mmol/l
Bilirubin	6 µmol/l
Albumin	38 g/l
Alkaline phosphatase	68 U/l
ALT	26 U/l
TSH	0.01 mU/l (0.4–5 mU/l)
Free T4	36.4 pmol/l

She plans to breastfeed her baby after delivery.

What is the most appropriate therapy?

Your answer was correct

A Lugol's iodine

B Carbimazole

C Propylthiouracil

D Radioiodine therapy after delivery of the baby

E Blocking dose of carbimazole with supplemental thyroxine

Explanation

B Carbimazole

The choice here is between carbimazole and propylthiouracil at a dose to control thyroid hormone levels without blocking them completely. What drives the choice between propylthiouracil and carbimazole in this situation is the adverse event profile. Cases of fatal hepatotoxicity have been described with propylthiouracil, and for this reason carbimazole is always recommended in late pregnancy. Neither is recommended in breastfeeding, although if she insists on a plan to breastfeed, switching to propylthiouracil post-partum is potentially the safer option.

A Lugol's iodine

Lugol's iodine is occasionally prescribed for patients undergoing thyroid surgery, but causes goitre in infants. It is primarily used for short-term control of thyrotoxicosis.

C Propylthiouracil

Propylthiouracil is not recommended here because of the risk of maternal hepatotoxicity.

D Radioiodine therapy after delivery of the baby

Radioiodine therapy is contraindicated in pregnancy and breastfeeding, and it is recommended that patients avoid becoming pregnant for six months after therapy. It also presents logistical difficulties in that the woman would not be able to remain in close proximity to her baby for some time after dosing.

E Blocking dose of carbimazole with supplemental thyroxine

Carbimazole crosses the placenta but thyroxine does not,

propylthiouracil post-partum is potentially the safer option.

A Lugol's iodine

Lugol's iodine is occasionally prescribed for patients undergoing thyroid surgery, but causes goitre in infants. It is primarily used for short-term control of thyrotoxicosis.

C Propylthiouracil

Propylthiouracil is not recommended here because of the risk of maternal hepatotoxicity.

D Radioiodine therapy after delivery of the baby

Radioiodine therapy is contraindicated in pregnancy and breastfeeding, and it is recommended that patients avoid becoming pregnant for six months after therapy. It also presents logistical difficulties in that the woman would not be able to remain in close proximity to her baby for some time after dosing.

E Blocking dose of carbimazole with supplemental thyroxine

Carbimazole crosses the placenta but thyroxine does not, so the 'block and replace' approach could render the neonate profoundly hypothyroid.

6392

Rate this question:

An 18-year-old male is admitted with a history of being confused since a couple of hours before. His mother confessed that her son was trying to lose weight and had joined a local gym. He was consuming a powder which she recalled as being called 'Cherry Meth'. This is mixed with water and he had told her that it tasted like seaweed.

On examination he was agitated, but drowsy. His pulse was 45/min and blood pressure was 90/70 mmHg. The remainder of the physical examination was unremarkable.

However, he gradually lapsed into coma during the period of observation and had Cheyne–Stokes breathing. Respiration became progressively depressed and he was intubated and ventilated. Supportive treatment was started. Surprisingly, he regained consciousness spontaneously and pulled out the endotracheal tube within 3 h.

Investigations:

Glucose	10.5 mmol/l
Na^+	150 mmol/l
K^+	6.3 mmol/l
pH	7.3
Bicarbonate	23 mmol/l
Base deficit	2
Urea	6.0 mmol/l
Creatinine	120 mmol/l
ALT	34 U/l
Ammonia	25 μmol/l

What is the most likely diagnosis?

A Urea cycle disorder

of observation and had Cheyne–Stokes breathing. Respiration became progressively depressed and he was intubated and ventilated. Supportive treatment was started. Surprisingly, he regained consciousness spontaneously and pulled out the endotracheal tube within 3 h.

Investigations:

Glucose	10.5 mmol/l
Na^+	150 mmol/l
K^+	6.3 mmol/l
pH	7.3
Bicarbonate	23 mmol/l
Base deficit	2
Urea	6.0 mmol/l
Creatinine	120 mmol/l
ALT	34 U/l
Ammonia	25 µmol/l

What is the most likely diagnosis?

A Urea cycle disorder

B Metabolic encephalopathy

C Gamma-hydroxybutyrate overdose

D LSD overdose

E Dextropropoxyphene overdose

C Gamma-hydroxybutyrate overdose

Gamma-hydroxybutric acid (GHB) is sold illegally for bodybuilding, weight loss and as a replacement for L-tryptophan. It is in a powder form and dissolved in water. Its taste is similar to that of seaweed. It is popularly known as Liquid X, Cherry Meth, Easy Lay, Scoop or GBH. Dependent on the dose, patients develop gastrointestinal effects, euphoria, drowsiness, Cheyne–Stokes respiration, coma, decreased cardiac output and severe respiratory depression. Fatalities have been reported, usually in malicious overdose when taken with other substances. Patients recover quickly, often within 1–2 h, and they may have rapid reversal of coma and may remove the endotracheal tube themselves. Metabolic acidosis, hyperglycaemia, hyperkalaemia and hypernatraemia can occur. Supportive care includes activated charcoal for up to 1 h after ingestion, so it is a little outside the time window here. For a couple of hours, monitoring of blood pressure, heart rate, respiratory rate and oxygenation should be done. Naloxone has shown benefit in animals. Diazepam is the drug of choice for treating convulsions.

A Urea cycle disorder

Urea cycle disorders are inborn errors of nitrogen metabolism that lead to accumulation of ammonia.

B Metabolic encephalopathy

Metabolic encephalopathy is a differential, but the history of Cherry Meth consumption drives us more towards drug induced metabolic disorder as the most likely answer.

D LSD overdose

Rana Alnasser's screen

coma, decreased cardiac output and severe respiratory depression. Fatalities have been reported, usually in malicious overdose when taken with other substances. Patients recover quickly, often within 1-2 h, and they may have rapid reversal of coma and may remove the endotracheal tube themselves. Metabolic acidosis, hyperglycaemia, hyperkalaemia and hypernatraemia can occur. Supportive care includes activated charcoal for up to 1 h after ingestion, so it is a little outside the time window here. For a couple of hours, monitoring of blood pressure, heart rate, respiratory rate and oxygenation should be done. Naloxone has shown benefit in animals. Diazepam is the drug of choice for treating convulsions.

A Urea cycle disorder

Urea cycle disorders are inborn errors of nitrogen metabolism that lead to accumulation of ammonia.

B Metabolic encephalopathy

Metabolic encephalopathy is a differential, but the history of Cherry Meth consumption drives us more towards drug induced metabolic disorder as the most likely answer.

D LSD overdose

LSD overdose is associated with hallucinations and agitation, rather than the obtunded picture seen here.

E Dextropropoxyphene overdose

Codeine overdose may present with decreased consciousness, but of course it isn't marketed as a weight loss agent.

A 60-year-old woman with a history of chronic atrial fibrillation has collapsed at home and has been admitted through Accident & Emergency. She is taking digoxin. She has no history of ischaemic heart disease.

Other medication of note includes ketoconazole for a chronic fungal infection, and an antibiotic started by the duty general practitioner (GP) for a lower respiratory tract infection.

On examination, her blood pressure is 132/82 mmHg, pulse is 63 bpm and regular. Her heart sounds are normal and there are coarse breath sounds at the right base on auscultation.

Investigations:

ECG: sinus rhythm, a heart rate of 65 bpm, axis 30 °, PR interval 120 ms, QRS interval of 107 ms and QTc of 510 ms.

Which antibiotic is most likely to have been started in this patient?

A	Amoxicillin
B	Doxycycline
C	Cefalexin
D	Clarithromycin
E	Co-amoxiclav

Rana Alnasser's screen

12:37
594-042-7551
Leave

A 60-year-old woman with a history of chronic atrial fibrillation has collapsed at home and has been admitted through Accident & Emergency. She is taking digoxin. She has no history of ischaemic heart disease.

Other medication of note includes ketoconazole for a chronic fungal infection, and an antibiotic started by the duty general practitioner (GP) for a lower respiratory tract infection.

On examination, her blood pressure is 132/82 mmHg, pulse is 63 bpm and regular. Her heart sounds are normal and there are coarse breath sounds at the right base on auscultation.

Investigations:

ECG: sinus rhythm, a heart rate of 65 bpm, axis 30 °, PR interval 120 ms, QRS interval of 107 ms and QTc of 510 ms.

Which antibiotic is most likely to have been started in this patient?

Your answer was correct

A	Amoxicillin
B	Doxycycline
C	Cefalexin
D	Clarithromycin
E	Co-amoxiclav

Explanation

Audio
Video
Share
Participants
More

12:37

Explanation

D Clarithromycin

This woman has an abnormal ECG and presented with a collapse. Her QTc is prolonged. Both ketoconazole and clarithromycin are known to prolong the QT interval, and clarithromycin is therefore the correct answer here. The antibiotic should be stopped, as should the ketoconazole if possible, and the patient monitored for episodes of torsades. In the event that there is hypokalaemia or hypomagnesaemia, then these electrolyte abnormalities should be corrected.

A Amoxicillin

Penicillin-based antibiotics are not associated with QT prolongation.

B Doxycycline

Tetracycline-based antibiotics are not associated with QT prolongation; a main concern of their use is that they can cause symptomatic gastro-oesophageal reflux.

C Cefalexin

Cephalosporins, like penicillins, do not cause prolonged QT.

E Co-amoxiclav

This is amoxicillin plus clavulanic acid. Clavulanic does not have significant effects on the cardiac action potential.

Rana Alnasser's screen

12:37

A 28-year-old man presents with cyanosis, headache and confusion. You understand he has been recently started on primaquine as malaria prophylaxis prior to a trip Africa on holiday.

On examination, he has a respiratory rate of 16/min and is relatively comfortable breathing air. There is clear cyanosis; in particular, his tongue is blue.

Investigations:

Hb	13.0 g/dl
MCV	86 fl
WCC	4.9×10^9/l
PLT	195×10^9/l
Na^+	141 mmol/l
K^+	4.9 mmol/l
Creatinine	130 μmol/l
Sat	94%
MetHb	10%

Which of the following is the most appropriate therapy?

A Ascorbic acid

B Exchange transfusion

C N-acetylcysteine

D Methylene blue

E Chlorpheniramine

Rana Alnasser's screen

D Methylene blue

Primaquine and its metabolites can act as oxidising agents, increasing the risk of methaemoglobinaemia where iron in haemoglobin is in the Fe^{3+} state, meaning that the haemoglobin holds strongly onto oxygen. This leads to tissue hypoxia. Methylene blue IV is the first-line therapy for methaemoglobinaemia. It must be administered with care, however, as at doses >7 mg/kg it becomes an oxidant itself. Other drug-induced causes of methaemoglobinaemia include nitrites, aniline dyes, nitroprussides, local anaesthetics and dapsone.

A Ascorbic acid

Ascorbic acid is used as a second-line therapy, usually when methaemoglobin levels approach 30% or greater.

B Exchange transfusion

Exchange transfusion can be considered when patients fail to respond to 1st- and 2nd-line interventions for methaemoglobinaemia and still suffer significant tissue hypoxia.

C N-acetylcysteine

N-acetylcysteine is more conventionally used as an antidote to paracetamol toxicity, although case series suggest it may be of value in resistant methaemoglobinaemia.

E Chlorpheniramine

Chlorpheniramine is an antihistamine and is not of value in treating methaemoglobinaemia.

12:40

A 68-year-old woman presents to the Emergency Department with vomiting, diarrhoea and confusion. Her medical history reveals mild renal impairment, with a creatinine level of 189 μmol/l and a potassium level of 6.2 mmol/l. Other history of note is chronic atrial fibrillation, which is rate-controlled with digoxin.

Her general practitioner (GP) had recently increased the dose of digoxin and commenced diuretics for heart failure. Her digoxin level is 18 ng/ml. Soon after admission, she becomes unwell, with a blood pressure of 95/50 mmHg.

Her electrocardiogram (ECG) is shown below.

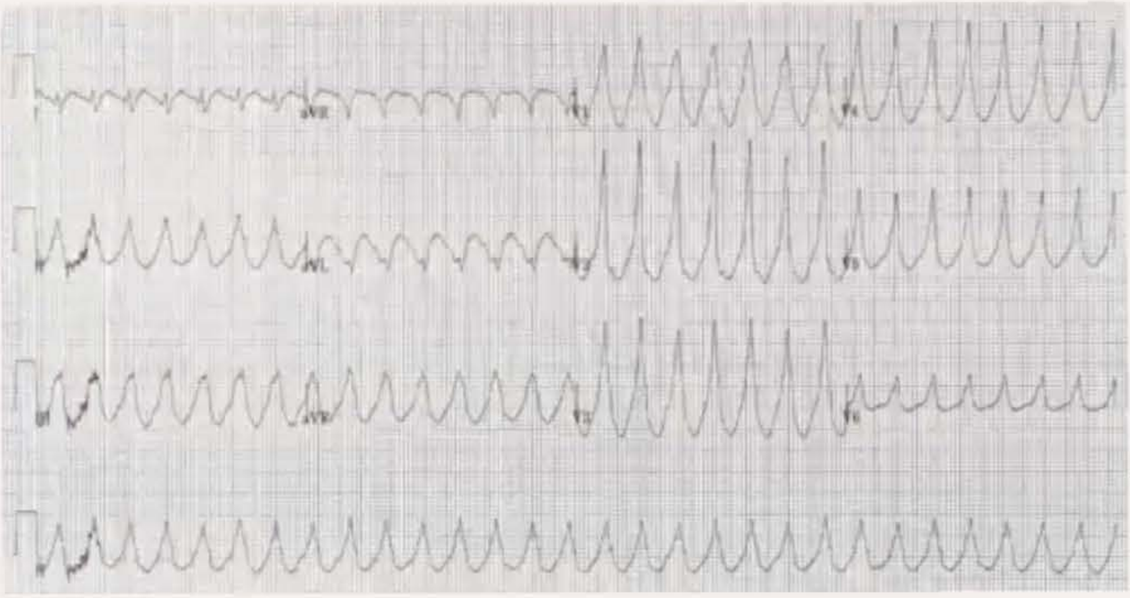

Image created by Karthik Sheka, M.D. [CC BY-SA 2.5 (https://creativecommons.org/licenses/by-sa/2.5)], via Wikimedia Commons

What is the most appropriate immediate intervention in this case?

A Wait for intravenous (IV) Digibind® to become available

B Give phenytoin 250 mg IV over 5 minutes

Rana Alnasser's screen

12:40
594-042-7551
Leave

B Give phenytoin 250 mg IV over 5 minutes

The ECG demonstrates monomorphic ventricular tachycardia (VT). Phenytoin prolongs effective refractory period and depresses spontaneous depolarization in ventricular tissue. It can therefore be used to terminate VT in affected patients with digoxin overdose.

C Give lidocaine 100 mg IV loading

Lidocaine is the next alternative for VT in the context of digoxin overdose if phenytoin is ineffective.

A Wait for intravenous (IV) Digibind® to become available

Digibind® consists of digoxin-binding antibody fragments, and the dose used depends on the digoxin level and the patient's weight. Prognostic indicators of severe digoxin toxicity include digoxin levels of > 15 ng/ml and serum potassium level of > 5 mmol/l. Susceptibility to toxicity is further increased by kidney disease, hypothyroidism or hypomagnesaemia. Were Digibind® available, then it should be given concurrently with phenytoin. Waiting risks this patient suffering a cardiac arrest.

D Give insulin and dextrose IV

Although correction of hyperkalaemia may be required, it is the VT which requires immediate intervention.

E Arrange for direct current (DC) cardioversion

This woman is maintaining a systolic blood pressure of 95 mmHg, and DC cardioversion in the context of digoxin overdose is usually unsuccessful. Attempts at chemical

Audio Video Share Participants More

12:46
594-042-7551
Leave

A 18-year-old man attends clinic for investigation of epilepsy. His schoolwork has been declining. Friends and relatives have noticed he will have tendencies to stop in mid-sentence and then start again. The attacks come on suddenly with no warning and last less than 30 seconds. There is no limb jerking or post-ictal confusion. He has had an electroencephalogram recording that has shown 3 Hz spike and wave complexes during the attack.

Which of the following antiepileptic medications would you consider?

A Carbamazepine

B Sodium valproate

C Vigabatrin

D Gabapentin

E Phenytoin

32799

Submit

Previous Q...
Skip Questi...

Blog About Pastest Contact Us Help
Audio Video Share Participants More

12:47

A 18-year-old man attends clinic for investigation of epilepsy. His schoolwork has been declining. Friends and relatives have noticed he will have tendencies to stop in mid-sentence and then start again. The attacks come on suddenly with no warning and last less than 30 seconds. There is no limb jerking or post-ictal confusion. He has had an electroencephalogram recording that has shown 3 Hz spike and wave complexes during the attack.

Which of the following antiepileptic medications would you consider?

Your answer was correct

A	Carbamazepine
B	Sodium valproate
C	Vigabatrin
D	Gabapentin
E	Phenytoin

A
B
C
D
E
0

Resp
Resp
Resp
Resp

Explanation

B Sodium valproate

The patient is having absence seizures, probably in the context of idiopathic generalised epilepsy, and the preferred first-line agent is sodium valproate. Use of sodium valproate has reduced in recent years, particularly in the female population, largely due to a PCOS-like

Rana Alnasser's screen

12:49
594-042-7551 Leave

31% 10:49
MyPastest
https://mypastest.pastest.com

The patient is having absence seizures, probably in the context of idiopathic generalised epilepsy, and the preferred first-line agent is sodium valproate. Use of sodium valproate has reduced in recent years, particularly in the female population, largely due to a PCOS-like syndrome which can result in weight gain, skin changes including acne, and hair loss. Valproate is also associated with a higher risk of major fetal malformation than other antiepileptic drugs. This has prompted increased use of lamotrigine, particularly in females, which is not associated with a PCOS-like syndrome, and is not a P450 enzyme inhibitor. Another alternative to sodium valproate is ethosuximide, although it can cause abdominal pain, agrunolocytosis, drowsiness and the Stevens–Johnson syndrome, and is much less commonly used.

Annotation Stop Share

A Carbamazepine

Carbamazepine can actually worsen seizures in primary generalised epilepsy and should therefore be avoided here.

C Vigabatrin

Like carbamazepine, vigabatrin can worsen seizure control in primary generalised epilepsy and is best avoided here.

D Gabapentin

Although gabapentin is effective, it is associated with significant drowsiness and apraxia at high doses. As such it is now less utilised for the treatment of primary generalised epilepsy.

E Phenytoin

Audio Video Share Participants More

12:49

Carbamazepine can actually worsen seizures in primary generalised epilepsy and should therefore be avoided here.

C Vigabatrin

Like carbamazepine, vigabatrin can worsen seizure control in primary generalised epilepsy and is best avoided here.

D Gabapentin

Although gabapentin is effective, it is associated with significant drowsiness and apraxia at high doses. As such it is now less utilised for the treatment of primary generalised epilepsy.

E Phenytoin

Phenytoin has an adverse side-effect profile versus other anti-epileptic choices including skin rashes, gingival hypertrophy and osteoporosis, meaning that it is not a first choice here.

Rate this question:

Next Question

Previous Q... Tag Questi... Feedback End Session

Blog About Pastest Contact Us Help

© Pastest 2019

Rana Alnasser's screen

12:49

A 25-year-old nursery teacher attends the Emergency Department having deliberately ingested a number of tablets 14 h earlier. She believes that she has probably taken around 35 co-dydramol tablets that were prescribed for her father. She takes a herbal remedy for low mood which she self-prescribes.

On examination, she is alert, with a Glasgow Coma Scale (GCS) score of 15, pupils are mid-sized and reactive, she has a heart rate of 80 bpm and blood pressure of 115/75 mmHg.

The next best intervention would be:

A	50 g of activated charcoal orally
B	Gastric lavage
C	*N*-acetyl cysteine intravenously
D	Methionine orally
E	Check paracetamol levels and act if they are raised

Submit

Previous Q... Skip Questi...

Rana Alnasser's screen

A 25-year-old nursery teacher attends the Emergency Department having deliberately ingested a number of tablets 14 h earlier. She believes that she has probably taken around 35 co-dydramol tablets that were prescribed for her father. She takes a herbal remedy for low mood which she self-prescribes.

On examination, she is alert, with a Glasgow Coma Scale (GCS) score of 15, pupils are mid-sized and reactive, she has a heart rate of 80 bpm and blood pressure of 115/75 mmHg.

The next best intervention would be:

Your answer was incorrect

A	50 g of activated charcoal orally
B	Gastric lavage
C	*N*-acetyl cysteine intravenously
D	Methionine orally
E	Check paracetamol levels and act if they are raised

Explanation

C *N*-acetyl cysteine intravenously

Paracetamol ingestion makes up 40% of admissions for poisoning in the UK, and leads to between 200 and 300 deaths annually. Toxicity is possible in those who have ingested 150 mg/kg bodyweight or > 12 g in total (for a patient of 75 kg). St John's Wort (*Hypericum perforatum*)

12:53

C *N*-acetyl cysteine intravenously

Paracetamol ingestion makes up 40% of admissions for poisoning in the UK, and leads to between 200 and 300 deaths annually. Toxicity is possible in those who have ingested 150 mg/kg bodyweight or > 12 g in total (for a patient of 75 kg). St John's Wort (*Hypericum perforatum*) is commonly taken for mild-to-moderate depression, and is an inducer of hepatic enzymes, which would place the user at high risk of toxicity. From what she has told you she has ingested a potentially lethal dose of paracetamol, and *N*-acetylcysteine should therefore be started without waiting, as it has definitive benefit if given within the first 15 h after overdose.

E Check paracetamol levels and act if they are raised

This risks a potentially significant delay, during which hepatotoxicity will worsen significantly.

A 50 g of activated charcoal orally

Activated charcoal is generally recommended within 1 h of a potentially toxic dose; at this stage it is far too late to have a significant impact.

B Gastric lavage

Gastric lavage has a very limited role in the treatment of poisoning, and would not impact on outcomes here. It is no longer used at all in the management of paracetamol overdose.

D Methionine orally

Methionine is used for patients who are unable to tolerate

Rana Alnasser's screen

12:54
594-042-7551 Leave

A 54-year-old man has suffered an episode of collapse while playing squash, and when paramedics arrived at the scene he was found to be in cardiorespiratory arrest, with underlying ventricular fibrillation. An output was restored with one biphasic DC shock of 150 J, and he quickly regained consciousness, albeit with mild confusion.

He has a history of diabetes mellitus and was recently commenced on some new medication by his general practitioner (GP) because of leg pains, not sleeping and feeling generally down. He is not sure what this is, nor what it is for. An electrocardiogram (ECG) shows prolongation of the QT interval.

Which drug is the most likely cause of his QT prolongation?

A Diclofenac

B Amitryptyline

C Co-amoxiclav

D Paroxetine

E Sodium valproate

Submit

Previous Q... Skip Questi...

Audio Video Share Participants More

A 54-year-old man has suffered an episode of collapse while playing squash, and when paramedics arrived at the scene he was found to be in cardiorespiratory arrest, with underlying ventricular fibrillation. An output was restored with one biphasic DC shock of 150 J, and he quickly regained consciousness, albeit with mild confusion.

He has a history of diabetes mellitus and was recently commenced on some new medication by his general practitioner (GP) because of leg pains, not sleeping and feeling generally down. He is not sure what this is, nor what it is for. An electrocardiogram (ECG) shows prolongation of the QT interval.

Which drug is the most likely cause of his QT prolongation?

Your answer was correct

A	Diclofenac
B	Amitryptyline
C	Co-amoxiclav
D	Paroxetine
E	Sodium valproate

Explanation

B Amitryptyline

A prolonged QT interval (measured from the beginning of the QRS complex to the end of the T wave) increases the risk of ventricular dysrhythmias occurring, particularly

B Amitryptyline

A prolonged QT interval (measured from the beginning of the QRS complex to the end of the T wave) increases the risk of ventricular dysrhythmias occurring, particularly torsades de pointes, which may then deteriorate to ventricular fibrillation. The normal QT interval is approximately 0.38–0.46 s when corrected for ventricular rate, but may be prolonged due to an underlying genetic abnormality: Romano–Ward syndrome and Jervell–Lange-Nielsen syndrome are examples. Acquired causes include electrolyte abnormalities such as hypocalcaemia and hypomagnesaemia, and drugs. These include classes Ia, Ic and III anti-arrhythmic agents, tricyclic antidepressants, erythromycin, haloperidol and azole antifungals.

A Diclofenac

Diclofenac does not lead to QT prolongation, but can promote salt and water retention, leading to worsening of blood pressure control and fluid retention, and also to gastric irritation.

C Co-amoxiclav

Neither clavulanic acid nor penicillins impact on the QT interval, and we're given no indication of recent infection.

D Paroxetine

Paroxetine is associated with episodes of both sinus tachycardia and bradycardia, but isn't associated with QT prolongation.

E Sodium valproate

The main concerns with respect to sodium valproate use

A Diclofenac

Diclofenac does not lead to QT prolongation, but can promote salt and water retention, leading to worsening of blood pressure control and fluid retention, and also to gastric irritation.

C Co-amoxiclav

Neither clavulanic acid nor penicillins impact on the QT interval, and we're given no indication of recent infection.

D Paroxetine

Paroxetine is associated with episodes of both sinus tachycardia and bradycardia, but isn't associated with QT prolongation.

E Sodium valproate

The main concerns with respect to sodium valproate use are liver dysfunction, pancreatitis and teratogenicity in women of child-bearing potential.

7579

Rate this question:

Next Question

Previous Q... Tag Questi... Feedback End Session

Blog About Pastest Contact Us Help

A 55-year-old man with a history of chronic alcohol abuse is admitted to hospital having had a witnessed generalised tonic-clonic seizure in the street following which a bystander called an ambulance. He had a further seizure while in the ambulance on the way to hospital, terminated by PR diazepam. A third, brief seizure occurs on arrival at the A&E department.

He has no other significant past medical history of note, and is not on any regular medications. He denies recreational drug use, and has not drunk any alcohol in the past 24 hours.

Baseline observations are as follows:

Temperature	36.5 °C
Pulse	88 bpm
Blood Pressure	132/68 mmHg
O_2 sats	97% air
Blood glucose	5.4 mmol/l

A computed tomography (CT) brain is performed which is normal. On return from the scanner, he suffers a further seizure which has lasted for around 2 minutes.

What is the most appropriate short-term intervention?

A Oral carbamazepine

B Give intravenous (iv) lorazepam followed by long term sodium valproate

C Give iv lorazepam

D No intervention required

12:56

and is not on any regular medications. He denies recreational drug use, and has not drunk any alcohol in the past 24 hours.

Baseline observations are as follows:

Temperature	36.5 °C
Pulse	88 bpm
Blood Pressure	132/68 mmHg
O_2 sats	97% air
Blood glucose	5.4 mmol/l

A computed tomography (CT) brain is performed which is normal. On return from the scanner, he suffers a further seizure which has lasted for around 2 minutes.

What is the most appropriate short-term intervention?

A	Oral carbamazepine
B	Give intravenous (iv) lorazepam followed by long term sodium valproate
C	Give iv lorazepam
D	No intervention required
E	Start oral sodium valproate

Submit

Rana Alnasser's screen

12:57

C Give iv lorazepam

Alcohol withdrawal seizures usually occur after an 8- to 24-hour alcohol-free period. If there is no known history of epilepsy, and no underlying structural brain lesion is identified, long-term antiepileptic treatment is not required. In the acute setting, iv lorazepam has been shown to reduce the risk of recurrent seizures. Patients are then managed according to a CIWA alcohol withdrawal protocol.

B Give intravenous (iv) lorazepam followed by long term sodium valproate

There is no indication for long-term sodium valproate unless generalised seizures are seen post alcohol withdrawal.

A Oral carbamazepine

Oral carbamazepine is mainly used in the management of partial seizures, which may of course result from alcohol abuse, although here short-term prevention of further withdrawal seizures with lorazepam is most important.

D No intervention required

Not treating with benzodiazepines in this situation runs the risk of further withdrawal seizures with associated mortality and morbidity.

E Start oral sodium valproate

In this situation, iv benzodiazepines are the intervention of choice to prevent further withdrawal seizures. Anti-epileptics are not required unless seizures occur over the longer term.

Rana Alnasser's screen

12:57
594-042-7551 Leave

You review a man who is currently receiving 6-mercaptopurine (6-MP) as part of his treatment regimen for inflammatory bowel disease.

Which of the following drugs may cause a fatal drug interaction when used in conjunction with 6-MP?

A Allopurinol

B Erythromycin

C Theophylline

D Propranolol

E Ciprofloxacin

Submit

Previous Q... Skip Questi...

© Pastest 2019

Audio Video Share Participants More

A Allopurinol

6-mercaptopurine (6-MP) is a purine antagonist that interferes with the process of DNA synthesis and the drug is usually used as part of chemotherapy in the treatment of acute leukaemias and as a treatment for inflammatory bowel disease. Allopurinol is a xanthine oxidase inhibitor, and xanthine oxidase is responsible for the metabolism of 6-MP. Therefore, co-administration of allopurinol and 6-MP may result in a build up to toxic levels of 6-MP. Azathioprine is metabolised to 6-MP and therefore should also be avoided in patients receiving allopurinol therapy.

B Erythromycin

The main concern with erythromycin prescription is the fact that it is a potent CYP 450 3A4 inhibitor, which drives accumulation of co-prescribed drugs such as statins which are metabolised via this route.

C Theophylline

Theophylline undergoes extensive hepatic metabolism, and it is theophylline which is a cause of toxicity when its metabolism is blocked by P450 inhibitors.

D Propranolol

The main concern with respect to propranolol use is bronchospasm in susceptible patients.

E Ciprofloxacin

Ciprofloxacin is a moderate inhibitor of CYP 1A2, which can promote accumulation of agents such as theophylline.

Rate this question:

A 50-year-old Asian man had recently been diagnosed with pulmonary tuberculosis and was started on quadruple anti-TB therapy. He seemed withdrawn, however, and had insomnia. He had attempted suicide on several occasions in the presence of friends by trying to stab himself, though had been rescued every time. He had been referred urgently to the psychiatrist. However, he was brought to the Emergency Department in a comatose state with ongoing generalised convulsions and vomiting.

On examination, temperature was 38 °C, pulse 120/min and blood pressure 90/50 mmHg.

Investigations:

Na^+	140 mmol/l
K^+	3.3 mmol/l
Chloride	95 mmol/l
Bicarbonate	20 mmol/l
pH	7.2
Urea	18 mmol/l
Creatinine	440 µmol/l

Given the overall clinical picture, what is the most likely cause of his acute symptoms and signs?

A Tuberculous meningitis

B Fungal meningitis

C Overdose of isoniazid

D Overdose of ethambutol

E Overdose of pyrizinamide

1:01

MyPastest
https://mypastest.pastest.com

Pastest+

A 50-year-old Asian man had recently been diagnosed with pulmonary tuberculosis and was started on quadruple anti-TB therapy. He seemed withdrawn, however, and had insomnia. He had attempted suicide on several occasions in the presence of friends by trying to stab himself, though had been rescued every time. He had been referred urgently to the psychiatrist. However, he was brought to the Emergency Department in a comatose state with ongoing generalised convulsions and vomiting.

On examination, temperature was 38 °C, pulse 120/min and blood pressure 90/50 mmHg.

Investigations:

Na^+	140 mmol/l
K^+	3.3 mmol/l
Chloride	95 mmol/l
Bicarbonate	20 mmol/l
pH	7.2
Urea	18 mmol/l
Creatinine	440 µmol/l

Given the overall clinical picture, what is the most likely cause of his acute symptoms and signs?

A Tuberculous meningitis

B Fungal meningitis

C Overdose of isoniazid

had been rescued every time. He had been referred urgently to the psychiatrist. However, he was brought to the Emergency Department in a comatose state with ongoing generalised convulsions and vomiting.

On examination, temperature was 38 °C, pulse 120/min and blood pressure 90/50 mmHg.

Investigations:

Na^+	140 mmol/l
K^+	3.3 mmol/l
Chloride	95 mmol/l
Bicarbonate	20 mmol/l
pH	7.2
Urea	18 mmol/l
Creatinine	440 µmol/l

Given the overall clinical picture, what is the most likely cause of his acute symptoms and signs?

A Tuberculous meningitis

B Fungal meningitis

C Overdose of isoniazid

D Overdose of ethambutol

E Overdose of pyrizinamide

Submit

C Overdose of isoniazid

This patient has taken an overdose of isoniazid, possibly in combination with rifampicin. He has presented with refractory convulsions and metabolic acidosis with an increased anion gap and coma. This is calculated as ($[Na^+] + [K^+]$) – ($[Cl^-] + [HCO_3^-]$). Its normal value is 10–14 mmol/l, but in this patient it is 28.3 mmol/l. The kidney disease is probably due to rhabdomyolysis. Isoniazid is recognised as inhibiting conversion of pyridoxine to both its active form, and to lactate dehydrogenase, which is thought to contribute to a presentation with metabolic acidosis.

A Tuberculous meningitis

Tuberculous meningitis is associated with a subacute course, and the rapid deterioration in association with presentation to the psychiatrist is more suggestive of overdose.

B Fungal meningitis

Fungal meningitis is more likely to be seen in patients with significant immunosuppression, and we are given no history of immunosuppressive disease here.

D Overdose of ethambutol

Ethambutol overdose is associated with headache, confusion, pyrexia and GI upset.

E Overdose of pyrizinamide

Pyrazinamide overdose is associated with abnormal liver function testing and hyperuricaemia.

During a clinical trial of a new proton pump inhibitor (PPI) drug, concerns were raised as to a possible link between the drug and the incidence of oesophageal carcinoma.

In a trial population of 12,300 patients with gastro-oesophageal reflux disease (GORD), 41 patients developed oesophageal carcinoma compared with 31 patients in the control arm of the study. Nine patients in a normal (matched for age and sex) population of the same size as the treatment group without GORD developed oesophageal cancer over the same time period.

Which of the following statements best describes the relevance of this concerning the safety of the drug?

A	The trial should be stopped immediately
B	A further 10,000 patients should be entered into the trial and the results re-assessed afterwards
C	The drug should be withdrawn from the market
D	The discrepancy between trial and the age and sex matched group is likely to be related to the indication for treatment in the trial population, (underlying GORD, rather than the drug)
E	The small number of oesophageal carcinomas makes a chance association between GORD and cancer likely

6507

Submit

D The discrepancy between trial and the age and sex matched group is likely to be related to the indication for treatment in the trial population, (underlying GORD, rather than the drug)

The discrepancy between trial and matched control group is likely to be related to the indication for treatment in the trial population. The normal group does not have any evidence of gastro-oesophageal reflux and is merely a randomly selected group from the population, matched for age and sex criteria. GORD can lead to the development of Barrett's oesophagus, which is associated with a markedly increased risk of oesophageal carcinoma. Given the size of the trial it is likely that neither treatment significantly affected the risk of developing cancer in high risk patients, and the difference between the two arms of the study is play of chance. Barrett's is characterised by the development of areas of columnar metaplasia within the lower oesophagus and this is associated with transformation to adenocarcinoma. Patients with symptoms of reflux are said to be 8 times more likely to develop oesophageal carcinoma than the general population.

A The trial should be stopped immediately

The difference of 10 between new treatment and control arms of the study is highly unlikely to be statistically significant and further evaluation is essential.

B A further 10,000 patients should be entered into the trial and the results re-assessed afterwards

Oesophageal cancer is thankfully rare, and cases take time to acquire, adding a further 10,000 patients is likely to be a very inefficient way to study this new agent.

C The drug should be withdrawn from the market

A 37-year-old woman is scheduled to receive a 3-unit blood transfusion. The nurses check that the first unit is appropriately matched and begin the transfusion. One hour later, the transfusion is stopped as her temperature spikes at 37.9 °C and she is suffering from back pain.

Bloods taken after the transfusion is stopped reveal no evidence of haemolysis.

Which of the following is the most appropriate next option?

A	Give chlorpheniramine
B	Give paracetamol
C	Recheck the label and then restart the transfusion
D	Give hydrocortisone
E	Give S/C adrenaline

Submit

© Pastest 2019

1:15
594-042-7551
Leave

A 37-year-old woman is scheduled to receive a 3-unit blood transfusion. The nurses check that the first unit is appropriately matched and begin the transfusion. One hour later, the transfusion is stopped as her temperature spikes at 37.9 °C and she is suffering from back pain.

Bloods taken after the transfusion is stopped reveal no evidence of haemolysis.

Which of the following is the most appropriate next option?

Your answer was incorrect

A Give chlorpheniramine

B Give paracetamol

C Recheck the label and then restart the transfusion

D Give hydrocortisone

E Give S/C adrenaline

Explanation

B Give paracetamol

Non-haemolytic transfusion reactions characterised by pyrexia are usually due to the presence of cytokines within the transfused unit of blood. Despite this type of reaction following [illegible] course, it is still important to differentiate [illegible] from haemolytic transfusion reactions, as [illegible] where [illegible] clear [illegible] there [illegible] evidence [illegible]

Audio Video Share Participants More

1:15

MyPastest
https://mypastest.pastest.com

A Give chlorpheniramine

B Give paracetamol

C Recheck the label and then restart the transfusion

D Give hydrocortisone

E Give S/C adrenaline

Explanation

B Give paracetamol

Non-haemolytic transfusion reactions characterised by pyrexia are usually due to the presence of cytokines within the transfused unit of blood. Despite this type of reaction following a benign course, it is still important to differentiate them from haemolytic transfusion reactions, as here, where we are clearly told there is no evidence of haemolysis. Management of choice is to stop the transfusion and treat the patient with paracetamol.

A Give chlorpheniramine

Antihistamines are only required when there is evidence of an allergic reaction to the unit of blood.

C Recheck the label and then restart the transfusion

differentiate them from haemolytic transfusion reactions, as here, where we are clearly told there is no evidence of haemolysis. Management of choice is to stop the transfusion and treat the patient with paracetamol.

A Give chlorpheniramine

Antihistamines are only required when there is evidence of an allergic reaction to the unit of blood.

C Recheck the label and then restart the transfusion

The pyrexia is indicative of cytokine release, suggesting that intervention with paracetamol is required.

D Give hydrocortisone

Hydrocortisone is most useful for serious transfusion reactions related to red cell antigen incompatibility and anaphylaxis.

E Give S/C adrenaline

Similar to hydrocortisone, adrenaline, usually given IM, is considered for an acute anaphylactic transfusion reaction related to antigen incompatibility.

20996

Rate this question:

1:16

A 56-year-old man is brought to Accident and Emergency (A&E) one evening by the police, having been arrested for breach of the peace. He had been found wandering along the street shouting at passers-by, and had then proceeded to vomit over a parked car. Since his arrest, he has become increasingly confused and agitated, complaining of headache and nausea, and vomiting profusely. He was not known to have any past medical history, but was well-known to the police as having no fixed abode, and would be frequently picked up by the police when drunk. The police decided to bring the patient to A&E as his agitation and vomiting have been worsening.

On arrival in A&E, he is disorientated and confused. On examination, he is unkempt, and his breath smells of ketones. He is afebrile. His heart rate is 90 bpm, regular, and blood pressure is 116/70 mmHg. Heart sounds are normal. His respiratory rate is 28/min, but his chest is clear. Oxygen saturations are 96% on air. Abdominal examination reveals mild epigastric tenderness but no guarding or rebound. He is uncooperative with neurological examination, and apart from complaints of blurred vision, and dilated, sluggish pupils, no focal signs are elicited.

His investigations are as follows:

Hb	12.6 g/dl
WBC	6.7 $\times 10^9$/l
PLT	268 $\times 10^9$/l
Na^+	135 mmol/l
K^+	5.2 mmol/l
Urea	7.6 mmol/l
Creatinine	116 µmol/l
Cl^-	106 mmol/l
HCO_3^-	11 mmol/l
Glucose	4.5 mmol/l

Rana Alnasser's screen

PLT	268 $\times 10^9$/l
Na^+	135 mmol/l
K^+	5.2 mmol/l
Urea	7.6 mmol/l
Creatinine	116 µmol/l
Cl^-	106 mmol/l
HCO_3^-	11 mmol/l
Glucose	4.6 mmol/l
Lactate	3.6 mmol/l (0.6 – 1.7)
ECG	Normal sinus rhythm
ABG (air)	PaO_2 13.6 kPa, $PaCO_2$ 4.4 kPa, pH 7.24
Urinalysis	No crystals seen

He is started on sodium bicarbonate IV in an attempt to correct his acidosis.

Which of the following is the most appropriate next treatment?

A IV thiamine

B IV tazocin

C IV ethanol

D IV naloxone

E IV dexamethasone

1:21
594-042-7551
Leave

HCO_3^-	11 mmol/l
Glucose	4.6 mmol/l
Lactate	3.6 mmol/l (0.6 – 1.7)
ECG	Normal sinus rhythm
ABG (air)	PaO_2 13.6 kPa, $PaCO_2$ 4.4 kPa, pH 7.24
Urinalysis	No crystals seen

He is started on sodium bicarbonate IV in an attempt to correct his acidosis.

Which of the following is the most appropriate next treatment?

Your answer was correct

A IV thiamine

B IV tazocin

C IV ethanol

D IV naloxone

E IV dexamethasone

Explanation

C IV ethanol

This patient has methanol toxicity. Methanol is sometimes used as a substitute for ethanol by alcoholics, as it similarly causes inebriation. The metabolites of methanol produce

Audio Video Share Participants More

C IV ethanol

This patient has methanol toxicity. Methanol is sometimes used as a substitute for ethanol by alcoholics, as it similarly causes inebriation. The metabolites of methanol produce metabolic acidosis, blindness, and death after a characteristic latent period of 6–30 hours.

Methanol is slowly metabolised by alcohol dehydrogenase to formaldehyde, and subsequently by aldehyde dehydrogenase to formic acid. Systemic acidosis is caused by both formate and lactate. Both ethanol and methanol compete for the enzyme alcohol dehydrogenase and block metabolism of methanol to its toxic metabolites.

In the first few hours after ingestion, methanol-intoxicated patients present with inebriation and gastritis. Acidosis is not usually present because metabolism to toxic products has not occurred yet. There may be a noticeable elevation in the osmolar gap. After a latent period of up to 30 hours, severe anion gap metabolic acidosis, visual disturbances, blindness, seizures, coma and death may occur. Fundoscopic examination may reveal disc hyperaemia, venous engorgement or papilloedema.

Diagnosis is based on history, symptoms, large anion gap, serum methanol and serum formate levels. Treatment includes correction of the acidosis with IV bicarbonate, and administration of IV ethanol or fomepizole which saturate the enzyme alcohol dehydrogenase and prevent metabolism of methanol. Haemodialysis may be necessary to rapidly remove methanol and formate.

A IV thiamine

IV thiamine is essential in the treatment of Wernicke–Korsakoff syndrome, and should therefore be considered here, but it will not correct the acidosis or prevent methanol-related optic nerve damage.

Rana Alnasser's screen

blindness, seizures, coma and death may occur. Fundoscopic examination may reveal disc hyperaemia, venous engorgement or papilloedema.

Diagnosis is based on history, symptoms, large anion gap, serum methanol and serum formate levels. Treatment includes correction of the acidosis with IV bicarbonate, and administration of IV ethanol or fomepizole which saturate the enzyme alcohol dehydrogenase and prevent metabolism of methanol. Haemodialysis may be necessary to rapidly remove methanol and formate.

A IV thiamine

IV thiamine is essential in the treatment of Wernicke–Korsakoff syndrome, and should therefore be considered here, but it will not correct the acidosis or prevent methanol-related optic nerve damage.

B IV tazocin

There are no signs of sepsis to indicate a need for broad-spectrum antibiotics.

D IV naloxone

IV naloxone is the first-line intervention for the treatment of opiate overdose.

E IV dexamethasone

IV corticosteroids would be considered where there is evidence of cerebral oedema or adrenal crisis. It does not prevent the optic neuropathy associated with methanol intoxication.

Rate this question:

1:22

A 28-year-old car mechanic, who specialised in battery repair, is admitted with history of episodic abdominal pain for the past six months. This time, he had a severe episode and was admitted to a surgical unit for evaluation. He has a history of anorexia, constipation and intermittent nausea and vomiting from the inception of his illness.

He has also found it increasing difficult to use his gadgets, due to weakness of hands, for the past three weeks.

A medical registrar's opinion was sought. On examination, he was alert but apprehensive. Cranial nerves were normal. The distal muscles of his limbs were weak. Upper limbs were 3/5, mainly extensor group and in the lower limbs, ankle dorsiflexors were 4±5. Tendon stretch reflexes were absent. Plantar responses were flexor. Sensory system was intact.

Investigations:

WCC	8.0×10^9/l
Hb	10 g/dl
MCV	65 fl
MCH	26 pg
MCHC	29 g/dl
Erythrocytes	3.5×10^{12}/l
Fasting blood glucose	5.5 mmol/l
Na^+	135 mmol/l
K^+	3.6 mmol/l
Urinanalysis	Glucose ++, amino acids +

Which of the following investigations would confirm the suspected diagnosis?

A. Serum cadmium

Rana Alnasser's screen

were 3/5, mainly extensor group and in the lower limbs, ankle dorsiflexors were 4±5. Tendon stretch reflexes were absent. Plantar responses were flexor. Sensory system was intact.

Investigations:

WCC	8.0×10^9/l
Hb	10 g/dl
MCV	65 fl
MCH	26 pg
MCHC	29 g/dl
Erythrocytes	3.5×10^{12}/l
Fasting blood glucose	5.5 mmol/l
Na^+	135 mmol/l
K^+	3.6 mmol/l
Urinanalysis	Glucose ++, amino acids +

Which of the following investigations would confirm the suspected diagnosis?

A Serum cadmium

B Serum magnesium

C Serum copper

D Serum lead

E 24 h urinary copper excretion

D Serum lead

This scenario is typical of chronic lead poisoning in adults. A combination of gastrointestinal symptoms with pure motor polyneuropathy and predominantly bilateral wrist drop should raise the suspicion of this toxicity. There is usually a microcytic anaemia, proximal renal tubular acidosis and amino acid leak. Moderate poisoning occurs at blood lead concentrations of 450–750 μgm/l. Basophilic stippling may be seen. Because lead inhibits the conversion of delta-aminolevulinic acid dehydrase and ferrochelatase, delta-aminolevulinic acid cannot be converted to porphobilinogen, and iron is not incorporated into protoporphyrin. Hence, erythrocyte protoporphyrin is elevated to levels >35 mcg/dl, a finding that is also common in iron deficiency anaemia. The most important aspect of management is to remove the patient from the source of lead poisoning. Chelation therapy with oral DMSA (2–3 dimercaptosuccinic acid) or IV EDTA (sodium calcium edetate) should be discussed with a poison centre.

A Serum cadmium

Cadmium toxicity is seen less frequently than inadvertent lead exposure, although the pictures seen with respect to renal impairment and proximal renal tubular acidosis are similar.

B Serum magnesium

Symptoms of magnesium toxicity are similar to those of calcium toxicity with nausea, vomiting, depression and lethargy, rather than the picture of renal tubular acidosis and microcytic anaemia seen here.

C Serum copper

aspect of management is to remove the patient from the source of lead poisoning. Chelation therapy with oral DMSA (2-3 dimercaptosuccinic acid) or IV EDTA (sodium calcium edetate) should be discussed with a poison centre.

A Serum cadmium

Cadmium toxicity is seen less frequently than inadvertent lead exposure, although the pictures seen with respect to renal impairment and proximal renal tubular acidosis are similar.

B Serum magnesium

Symptoms of magnesium toxicity are similar to those of calcium toxicity with nausea, vomiting, depression and lethargy, rather than the picture of renal tubular acidosis and microcytic anaemia seen here.

C Serum copper

Copper toxicity is rare, and is usually seen in association with cooking of acid foods in copper cooking utensils or with exposure to copper in water. Symptoms of very long-term copper exposure include hepatic dysfunction.

E 24 h urinary copper excretion

This is most useful in screening for patients with Wilson's disease.

Rate this question:

Next Question

Rana Alnasser's screen

A 66-year-old woman is admitted with a febrile illness of one week's duration. She was prescribed amoxicillin for cough and right-sided pleuritic pain but had not completed the course. One day ago, she developed a severe headache and became more confused. She was diagnosed with diabetes mellitus some ten years ago and is managed with metformin and sitagliptin.

On examination there is obvious herpes labialis, her BP is 100/80 mmHg and pulse is 88 and regular. She is pyrexial with a temperature of 38.8 °C. Her GCS is 13 and there is obvious neck stiffness and meningism. Fundi are not seen. Auscultation reveals basal crackles at the right lung base.

Investigations:

Hb	12.0 g/l
WCC	15×10^9/l
Na^+	135 mmol/l
K^+	3.6 mmol/l
Urea	8 mmol/l
ALT	44 U/l
Urine	glucose ++, no ketones

What is the most likely cause of the lung findings here?

A Cryptococcus

B Listeria monocytogenes

C Streptococcus pneumoniae

D Staphylococcus aureus

This lady has a febrile illness with signs of consolidation of the right base of the lung with leucocytosis, suggestive of community-acquired pneumonia, the most common of which is *S. pneumoniae*. She has developed signs of bacterial meningitis and her level of consciousness has deteriorated. Herpes labialis is also commonly associated with *S. pneumoniae* infection. CT scanning should be carried out to exclude signs of raised intracerebral pressure, and to assess the risks of lumbar puncture to confirm the diagnosis of *S. pneumoniae* meningitis and rule out potential herpes encephalitis.

A Cryptococcus

Cryptococcus is a cause of meningitis in patients who are immunocompromised.

B Listeria monocytogenes

Listeria is a cause of meningitis, primarily in pregnant women and the elderly.

D Staphylococcus aureus

S. aureus pneumonia is usually seen in association with influenza infection.

E Mycoplasma pneumoniae

Mycoplasma pneumoniae is a rarer cause of community-acquired pneumonia, and is often associated with much more marked changes on CXR than would be expected given the examination findings.

52662

Rate this question:

A 42-year-old homeless man is admitted to the Emergency Department having been found collapsed outside a nightclub. He is hypoxic, confused and extremely unwell.

His blood pressure (BP) is 100/70 mmHg, with pulse 97/min and regular. Respiratory rate is 32/min. Pulse oximetry reveals oxygen saturations of 84%. In his pocket i an empty flask of amyl nitrite.

Which of the following represents the best treatment to reverse his tissue hypoxia?

A	Methylene blue
B	Hyperbaric oxygen
C	Intubation and ventilation
D	Non-invasive positive pressure ventilation (NIPPV)
E	GTN infusion

Submit

© Pastest 2019

A 42-year-old homeless man is admitted to the Emergency Department having been found collapsed outside a nightclub. He is hypoxic, confused and extremely unwell.

His blood pressure (BP) is 100/70 mmHg, with pulse 97/min and regular. Respiratory rate is 32/min. Pulse oximetry reveals oxygen saturations of 84%. In his pocket i an empty flask of amyl nitrite.

Which of the following represents the best treatment to reverse his tissue hypoxia?

Your answer was correct

A	Methylene blue
B	Hyperbaric oxygen
C	Intubation and ventilation
D	Non-invasive positive pressure ventilation (NIPPV)
E	GTN infusion

Explanation

A Methylene blue

This patient has methaemoglobinaemia as a result of ingestion of amyl nitrite. Amyl nitrite promotes the formation of methaemoglobin, which avidly conserves oxygen and leads to decreased tissue oxygen saturations. Treatments of choice include methylene blue and vitamin C. These act by reducing methaemoglobin to haemoglobin

Rana Alnasser's screen

A Methylene blue

This patient has methaemoglobinaemia as a result of ingestion of amyl nitrite. Amyl nitrite promotes the formation of methaemoglobin, which avidly conserves oxygen and leads to decreased tissue oxygen saturations. Treatments of choice include methylene blue and vitamin C. These act by reducing methaemoglobin to haemoglobin

B Hyperbaric oxygen

In other circumstances, for example carbon monoxide overdose, hyperbaric oxygen may improve tissue delivery of O_2 but where there is methaemoglobinaemia, it has little impact.

C Intubation and ventilation

Methaemoglobinaemia means that even under conditions of artificial ventilation, oxygen delivery cannot be improved.

D Non-invasive positive pressure ventilation (NIPPV)

Because O_2 is avidly bound to methaemoglobin, NIPPV does not improve tissue hypoxia.

E GTN infusion

Infusion of further nitrate has no positive impact in the treatment of methaemoglobinaemia. It may reduce blood pressure further and have a negative impact on outcomes.

Rate this question:

Rana Alnasser's screen

1:27

A 17-year-old girl is admitted to hospital having taken a paracetamol overdose. The precipitant was an argument with her boyfriend which ended in them splitting up. She took 24 × 500 mg tablets of paracetamol with a bottle of cider.

The following morning, she regretted her actions and told her parents what she had done.

On further evaluation, which of the following would be most likely to prompt specialist liver unit referral in this patient?

A	INR 1.8
B	pH 7.35
C	Creatinine 330 μmol/l
D	Serum ALT > 3000 IU/l
E	Systolic blood pressure 90 mmHg

6398

Submit

Previous Q... Skip Questi...

Audio Video Share Participants More
Blog About Pastest Contact Us Help

1:28
MyPastest
https://mypastest
594-042-7551
Leave

C Creatinine 330 μmol/l

The cut off for creatinine in the context of paracetamol toxicity is 300 μmol/l. Studies have shown that where creatinine is >300 μmol/l at presentation, mortality approaches 80% (survival is 23% in one case series).

Paracetamol overdose causes hepatic injury through its reactive metabolite *N*-acetylbenzoquinoneimine (NAPQI), which is normally rapidly detoxified by glutathione in liver cells. In overdose, NAPQI production exceeds glutathione capacity, and the metabolite reacts directly with hepatic macromolecules, causing liver injury. Renal damage may occur by the same way, owing to renal P450 metabolism. Ingestion of more than 6–7 g in adults is potentially hepatotoxic.

Treatment includes oral activated charcoal if the patient presents within 1 hour of ingestion. Antidotal treatment is with *N*-acetylcysteine (Parvolex®). Methionine can be used in patients allergic to *N*-acetylcysteine.

A INR 1.8

The INR conveys the synthetic function of the liver and is the most accurate marker for severity of liver damage. Poo prognostic signs, and thus indications for transfer to a liver unit, include: INR >2 within 48 hours, INR >3.5 within 72 hours.

B pH 7.35

Paracetamol overdose is associated with lactic acidosis, and it is a pH of <7.3 which is associated with the poorest outcome.

Audio Video Share Participants More

the most accurate marker for severity of liver damage. Poc prognostic signs, and thus indications for transfer to a liver unit, include: INR >2 within 48 hours, INR >3.5 within 72 hours.

B pH 7.35

Paracetamol overdose is associated with lactic acidosis, and it is a pH of <7.3 which is associated with the poorest outcome.

D Serum ALT > 3000 IU/l

Although significantly elevated transaminases are indicative of hepatocellular damage, it is impairment of hepatic synthetic function which most stratifies poor prognostic outcome.

E Systolic blood pressure 90 mmHg

Systolic BP <80 mmHg is associated with the worst outcomes in patients with paracetamol overdose.

© Pastest 2019

Rana Alnasser's screen

You are asked to review a 73-year-old man who complains of failure to maintain his erection during sexual intercourse over the past two months. He has a history of psychiatric disorder, for which he is treated with lithium, type 2 diabetes diagnosed some three years earlier, managed wit diet and metformin, and angina, for which atenolol was recently added, and angiotensin-converting enzyme (ACE) inhibition for blood pressure and renoprotection.

Blood pressure is 145/85 mmHg; recent haemoglobin A1c (HbA1c) was measured at 75.96 mmol/mol (9.1%).

Which of the following would represent the most likely cause of his deteriorating sexual function over the past two months?

A	Vascular disease
B	Lithium therapy
C	Beta-blocker therapy
D	Metformin therapy
E	ACE inhibitor therapy

Submit

Rana Alnasser's screen

E ACE inhibitor therapy

Explanation

C Beta-blocker therapy

It is likely that he has some pre-existing vascular disease affecting the blood supply to the penis, but the acute cause of his deteriorating sexual function is likely to be the beta-blocker therapy. Switching the atenolol to a cardioselective beta blocker such as bisoprolol, or a non-beta blocker therapy for his angina, should result in an improvement in his erectile function.

A Vascular disease

Given he has only been diagnosed with type 2 diabetes for 3 years, significant vascular disease leading to erectile dysfunction is unlikely.

B Lithium therapy

Lithium therapy is associated with diabetes insipidus, not with erectile dysfunction.

D Metformin therapy

Metformin therapy is not associated with vascular dysfunction and may indeed be associated with improvement in vasoreactivity.

E ACE inhibitor therapy

ACE inhibitors are protective against micro- and macrovascular disease in diabetes, and are not associated with erectile dysfunction.

A 27-year-old man is admitted, following an overdose, having taken 70 of his amitriptyline 25-mg tablets.

An electrocardiogram (ECG) rhythm strip is shown below.

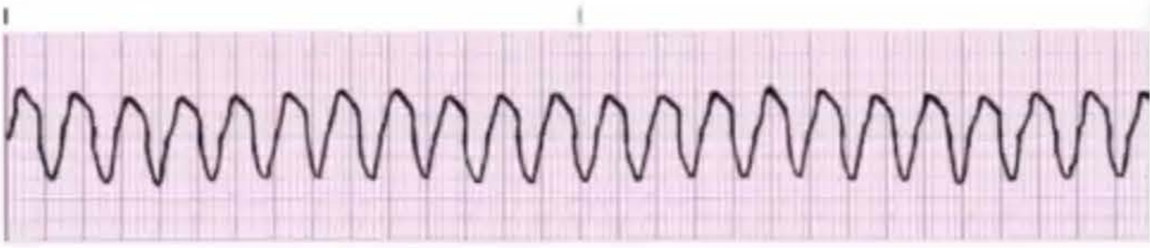

Arterial blood gases reveal a pH of 7.15.

Which of the following represents the best treatment option?

A	Intravenous (IV) lidocaine
B	IV sotalol
C	IV magnesium sulfate
D	IV sodium bicarbonate
E	IV flecainide

Submit

A 27-year-old man is admitted, following an overdose, having taken 70 of his amitriptyline 25-mg tablets.

An electrocardiogram (ECG) rhythm strip is shown below.

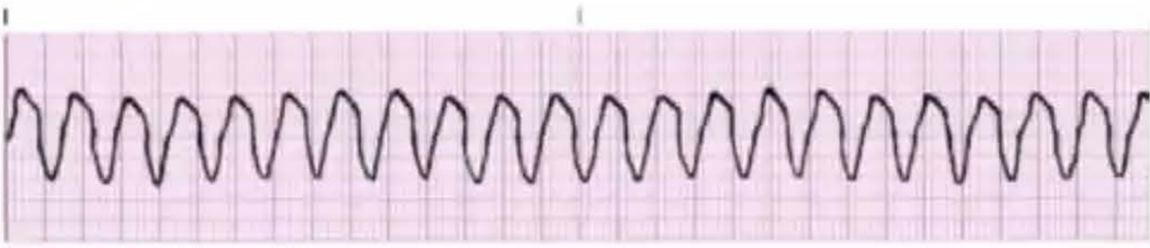

Arterial blood gases reveal a pH of 7.15.

Which of the following represents the best treatment option?

Your answer was correct

A Intravenous (IV) lidocaine

B IV sotalol

C IV magnesium sulfate

D IV sodium bicarbonate

E IV flecainide

Explanation

D IV sodium bicarbonate

IV sodium bicarbonate would be the treatment of choice in this case. Most class I antiarrhythmics are ineffective and may worsen conduction disorders. Phenytoin or lidocaine represent the best choices of antiarrhythmics, but ideally hypoxia or acidosis should be corrected first. Ventricular

Rana Alnasser's screen

Explanation

D IV sodium bicarbonate

IV sodium bicarbonate would be the treatment of choice in this case. Most class I antiarrhythmics are ineffective and may worsen conduction disorders. Phenytoin or lidocaine represent the best choices of antiarrhythmics, but ideally hypoxia or acidosis should be corrected first. Ventricular arrhythmias generally only develop when QRS is > 160 ms. Death may follow with as little as 1000 mg of tricyclic antidepressant ingestion.

A Intravenous (IV) lidocaine

Lidocaine is an important further option if short episodes of ventricular tachycardia (VT) persist despite correction of acidosis with sodium bicarbonate.

B IV sotalol

Sotalol prolongs the action potential and actually further increases the risk of VT occurring.

C IV magnesium sulfate

Magnesium sulfate is of most value in the treatment of torsades de pointes VT.

E IV flecainide

Flecainide, like sotalol, may actually increase the risk of an episode of VT occurring.

6543

Rate this question:

Rana Alnasser's screen

You are seen by a pharmaceutical representative who asks you to try out a recently launched antihypertensive agent in one of your patients. The second patient who tries the medication returns a few days later with rash.

In clinical trials up to phase 3, rash occurring with which o the following frequencies is likely to be identified?

A	1:10,000
B	1:300
C	1:20,000
D	1:2000
E	1:50,000

Submit

© Pastest 2019

Scroll capture Draw Crop

B 1:300

In general, about 10 times as many patients need to be studied in a trial program versus the number needed to see one event from a frequency calculation. Most modern clinical study programmes for drugs with a cardiovascular disease indication study between 5 and 10,000 patients. Hence an event occurring with a frequency of 1 in 300 should be identified.

A 1:10,000

Events occurring with this type of frequency are only reliably confirmed in post-marketing surveillance via the Medicines and Healthcare Regulatory Agency (MHRA). The yellow card system invites healthcare professionals to report suspected adverse drug reactions, complementary to this system is prescription event monitoring, where doctors identified from a sample of scripts for a particular medicine are surveyed for any changes in clinical markers in patients given that medicine.

C 1:20,000

Events occurring with this frequency may only be identified significantly after launch, particularly if they are related to prolonged drug exposure.

D 1:2000

In this frequency a numerical imbalance between arms may be seen in the phase 3 study program, but it's unlikely a difference could be reliably confirmed between active and placebo.

E 1:50,000

1:35
594-042-7551
Leave

A 54-year-old patient post renal transplant is taking azathioprine as part of his immunosuppressive regime and he develops gout. He is reviewed by his general practitioner (GP), who prescribes allopurinol. He is admitted with aplastic anaemia.

Which of the following stems fits best as the cause of his bone marrow failure?

A	Azathioprine toxicity
B	Allopurinol toxicity
C	Acute viral infection
D	Mercaptopurine toxicity
E	Xanthine oxidase upregulation

Submit

Previous Q... Skip Questi...

© Pastest 2019
Audio Video Share Participants More

1:36

A 54-year-old patient post renal transplant is taking azathioprine as part of his immunosuppressive regime and he develops gout. He is reviewed by his general practitioner (GP), who prescribes allopurinol. He is admitted with aplastic anaemia.

Which of the following stems fits best as the cause of his bone marrow failure?

Your answer was correct

A Azathioprine toxicity

B Allopurinol toxicity

C Acute viral infection

D Mercaptopurine toxicity

E Xanthine oxidase upregulation

Explanation

D Mercaptopurine toxicity

Azathioprine is metabolised to 6-mercaptopurine (6-MP), which itself is metabolised by xanthine oxidase. Xanthine oxidase inhibition leads to accumulation of 6-MP which then precipitates bone marrow failure. This may be potentially fatal if unrecognised. Ideally concomitant medication should be altered to reduce the risk of gout rather than using allopurinol in this situation.

Rana Alnasser's screen

D Mercaptopurine toxicity

Azathioprine is metabolised to 6-mercaptopurine (6-MP), which itself is metabolised by xanthine oxidase. Xanthine oxidase inhibition leads to accumulation of 6-MP which then precipitates bone marrow failure. This may be potentially fatal if unrecognised. Ideally concomitant medication should be altered to reduce the risk of gout rather than using allopurinol in this situation.

A Azathioprine toxicity

Allopurinol does not interfere with the metabolism of azathioprine itself, but interferes with the metabolism of mercaptopurine, one step on from initial azathioprine metabolism.

B Allopurinol toxicity

Bone marrow failure here is not due to accumulation of allopurinol, it is due to accumulation of 6-mercaptopurine.

C Acute viral infection

Although acute viral infection can lead to bone marrow failure, this is more usually seen against a background of sickle cell disease or hereditary spherocytosis.

E Xanthine oxidase upregulation

Xanthine oxidase inhibition is responsible for accumulation of mercaptopurine.

Rate this question:

8:11
https://www.google.com/sea
17

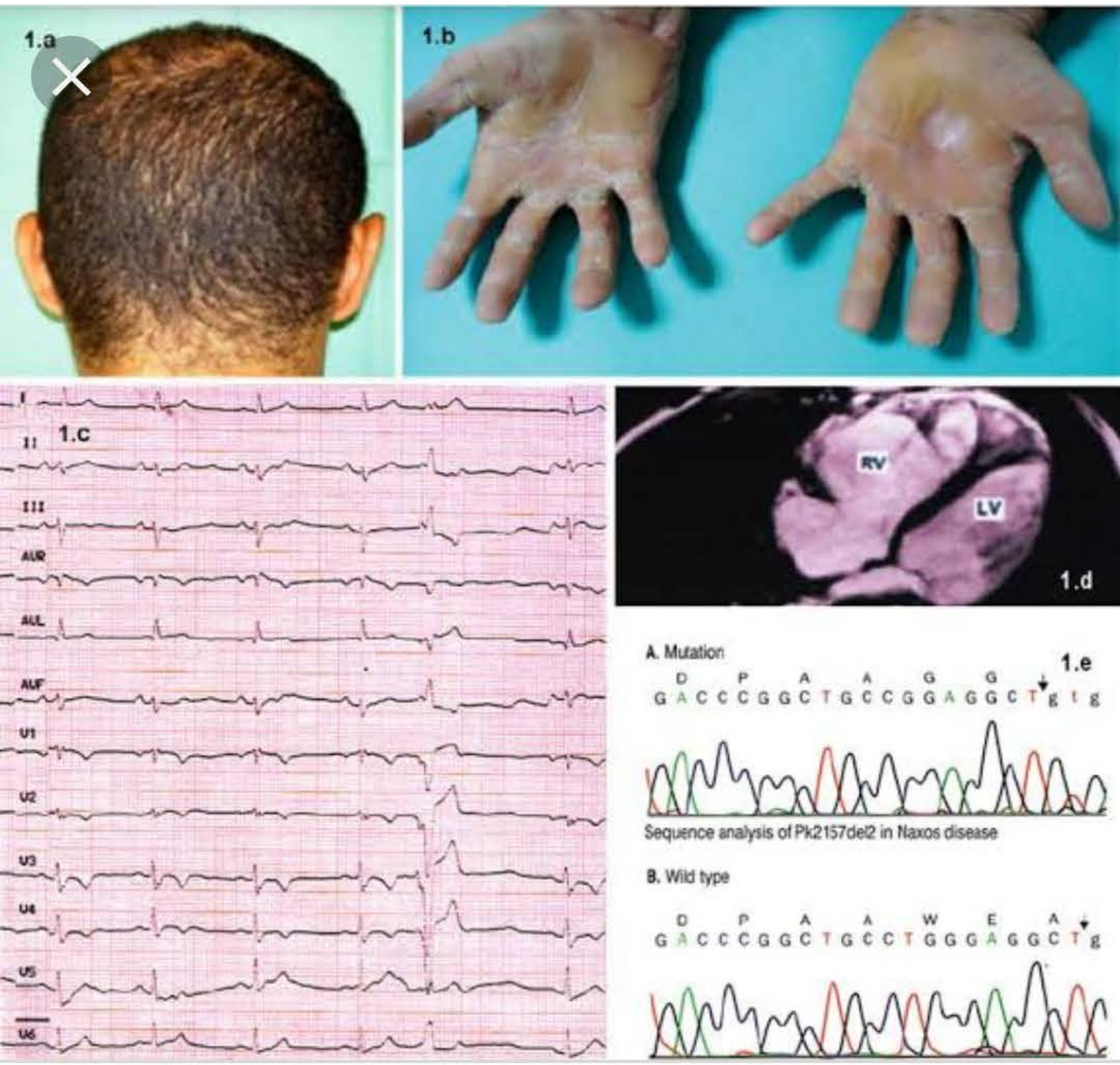

ResearchGate

a, b Patient's characteristic phenotype including woolly hair…

Images may be subject to copyright. Learn More

RELATED IMAGES

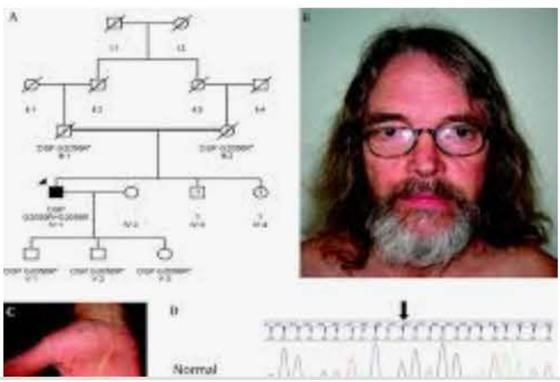

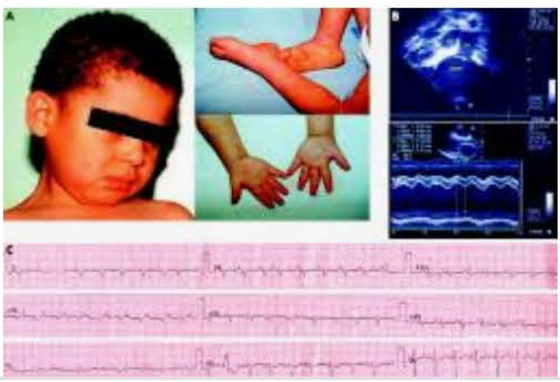

8:48

An 18-year-old woman is admitted after a collapse at a nightclub. Her friends tell you that she does not drink alcohol. She was out celebrating her birthday with friends. Apparently, she was looking for water to drink and seemed a little confused just before she collapsed.

On examination, she is pyrexial (40 °C) and unconscious. She has bilateral dilated pupils. Her blood pressure (BP) is 165/92 mmHg and her pulse is 110/min.

Investigations:

		Normal Values
Hb	14.9 g/dl	
WCC	6.9×10^9/l	
PLT	72×10^9/l	
Na^+	140 mmol/l	
K^+	6.0 mmol/l	
Creatinine	190 µmol/l	
CK	1210 u/l	24-170
Urine	Blood ++, no red cells on microscopy	

Which of the following is the most likely diagnosis?

A Neuroleptic malignant syndrome

B Malignant hyperthermia

C Serotonin syndrome

D 3,4-methylenedioxymethamphetamine (MDMA)

Rana Alnasser's screen

		Normal Values
Hb	14.9 g/dl	
WCC	6.9×10^9/l	
PLT	72×10^9/l	
Na^+	140 mmol/l	
K^+	6.0 mmol/l	
Creatinine	190 µmol/l	
CK	1210 u/l	24-170
Urine	Blood ++, no red cells on microscopy	

Which of the following is the most likely diagnosis?

A Neuroleptic malignant syndrome

B Malignant hyperthermia

C Serotonin syndrome

D 3,4-methylenedioxymethamphetamine (MDMA) toxicity

E Cocaine toxicity

21195

Submit

8:49

D 3,4-methylenedioxymethamphetamine (MDMA) toxicity

Given the popularity of MDMA (ecstasy), it seems most likely that she will have had access to it at her birthday party. The picture of extreme hyperthermia, rhabdomyolysis, renal impairment, low platelets and decreased consciousness level with dilated pupils is typical of the condition. Initial basic life support with assessment of ABC is crucial, with benzodiazepines the main agents used for sedation and for control of seizures. Hypertension is managed aggressively with agents such as phentolamine and sodium nitroprusside. Where there is significant rhabdomyolysis as in this case, urinary alkalinisation may reduce progression to acute kidney disease.

A Neuroleptic malignant syndrome

This is most often seen in patients prescribed conventional dopamine antagonist anti-psychotic medication, and this is very rarely seen as a drug of abuse.

B Malignant hyperthermia

Malignant hyperthermia is seen in response to anaesthetic agents, particularly in patients with inherited neuromuscular disorders.

C Serotonin syndrome

Serotonin syndrome is associated with SSRIs, prescribed for depression, which are not associated with an immediate neuropsychological impact, and therefore not used as drugs of abuse.

E Cocaine toxicity

Rana Alnasser's screen

8:50

This is most often seen in patients prescribed conventional dopamine antagonist anti-psychotic medication, and this is very rarely seen as a drug of abuse.

B Malignant hyperthermia

Malignant hyperthermia is seen in response to anaesthetic agents, particularly in patients with inherited neuromuscular disorders.

C Serotonin syndrome

Serotonin syndrome is associated with SSRIs, prescribed for depression, which are not associated with an immediate neuropsychological impact, and therefore not used as drugs of abuse.

E Cocaine toxicity

Cocaine toxicity can be associated with hypertension, tachycardia and rhabdomyolysis, but access to it as a drug of abuse is less than for MDMA.

2N95

Rate this question:

© Pastest 2019

Rana Alnasser's screen

8:50

A 27-year-old woman, who is 16 weeks pregnant, is referred by her GP with hypertension. The midwife noted her booking visit BP to be 135/82 mmHg, and it is now 155/92 mmHg. She has no previous significant medical history, but is overweight with a BMI of 28.

Investigations:

Hb	11.4 g/dl
WCC	5.4×10^9/l
PLT	201×10^9/l
Na+	141 mmol/l
K+	4.9 mmol/l
Creatinine	92 µmol/l

You elect to start treatment. Which of the following is the most appropriate therapy for her?

A Valsartan

B Bendroflumethiazide

C Labetalol

D Nifedipine

E Nitroprusside

Submit

Rana Alnasser's screen

blockers such as atenolol, it isn't associated with intra-uterine growth retardation.

A Valsartan

Valsartan is contraindicated due to the risk of renal agenesis and subsequent fetal death. This is true for the ACE inhibitor and ARB classes.

B Bendroflumethiazide

Diuretics interfere with natural volume expansion associated with pregnancy and are associated with increased risk of renal tract abnormalities.

D Nifedipine

There is evidence to support the use of dihydropyridines in pregnancy, although they are the second or third choice option for patients who are unable to take beta blockers or methyldopa.

E Nitroprusside

This is a consideration for acute management of hypertension and is delivered intravenously.

Rate this question:

Next Question

Rana Alnasser's screen

8:51

An 18-year-old man, the son of a farmer, is admitted with a history of progressive weight loss, anorexia, nausea and constipation for the past four months. He had recently been taking a keen interest in helping his father to eradicate mice from their grain storage silos.
He also had episodes of headaches and was at times losing his way around his home for a few minutes, though subsequently would recover completely.

He had also been aware of numbness in his toes for the past two months.

On examination, he had thickened palms and some transverse lines were evident on his nails.

He was alert and cooperative. Mild weakness and wasting was evident in the small muscles of his feet. Tendon reflexes were absent and plantar responses were flexor. Diminished sensation to pinprick was seen in the distal feet and fingertips.

What is the most likely diagnosis?

A	Acute intermittent porphyria
B	Coproporphyria
C	Erythropoietic protoporphyria
D	Arsenic poisoning
E	Lead poisoning

Rana Alnasser's screen

An 18-year-old man, the son of a farmer, is admitted with a history of progressive weight loss, anorexia, nausea and constipation for the past four months. He had recently been taking a keen interest in helping his father to eradicate mice from their grain storage silos.
He also had episodes of headaches and was at times losing his way around his home for a few minutes, though subsequently would recover completely.

He had also been aware of numbness in his toes for the past two months.

On examination, he had thickened palms and some transverse lines were evident on his nails.

He was alert and cooperative. Mild weakness and wasting was evident in the small muscles of his feet. Tendon reflexes were absent and plantar responses were flexor. Diminished sensation to pinprick was seen in the distal feet and fingertips.

What is the most likely diagnosis?

Your answer was correct

A Acute intermittent porphyria

B Coproporphyria

C Erythropoietic protoporphyria

D Arsenic poisoning

E Lead poisoning

Explanation

D Arsenic poisoning

D Arsenic poisoning

This patient has been involved in distributing rodent pesticides over a period of at least 4 months. He has developed weight loss, gastrointestinal symptoms, hyperkeratosis of the palms and some transverse lines on the nails. probably suggestive of Mees' lines. He also has features of a sensorimotor polyneuropathy.
All of these symptoms fit very well with chronic arsenic poisoning. There is increased risk of cancers in such patients. Arsenic can be detected in the hair and nails for months following exposure. Dimercaptosuccinic acid (DMSA, succimer) and penicillamine have been used successfully in the treatment of arsenic poisoning. The family should of course be warned about the safe handling of poisons.

A Acute intermittent porphyria

AIP is associated with acute episodes of hypertension and hyponatraemia, accompanied by psychiatric symptoms. As such, it doesn't fit with the picture seen here.

B Coproporphyria

Coproporphyria, like AIP, is an acute porphyria associated with acute episodes of abdominal pain and psychological disturbance. It is, however, also associated with a skin rash, unlike AIP.

C Erythropoietic protoporphyria

EP presents with a photosensitive skin rash and hepatic dysfunction.

E Lead poisoning

8:54

senic keratoses (below) on the palms of a p
gested arsenic from a contaminated well ove
olonged period (photo courtesy Dr. Joseph C

Agency for Toxic Substances and Disease Registry - CDC

enic Toxicity Case Study: What are the Physiologic Effects of

es may be subject to copyright. Learn more

TED IMAGES

Discover Updates Search Recent

8:54

www.slideshare.net

enic Poisoning in Bihar - Problem and Mitigation

es may be subject to copyright. Learn more

TED IMAGES

Ayurvedic Surgical Management of Plantar K...

Discover Updates Search Recent

8:55
594-042-7551
Leave

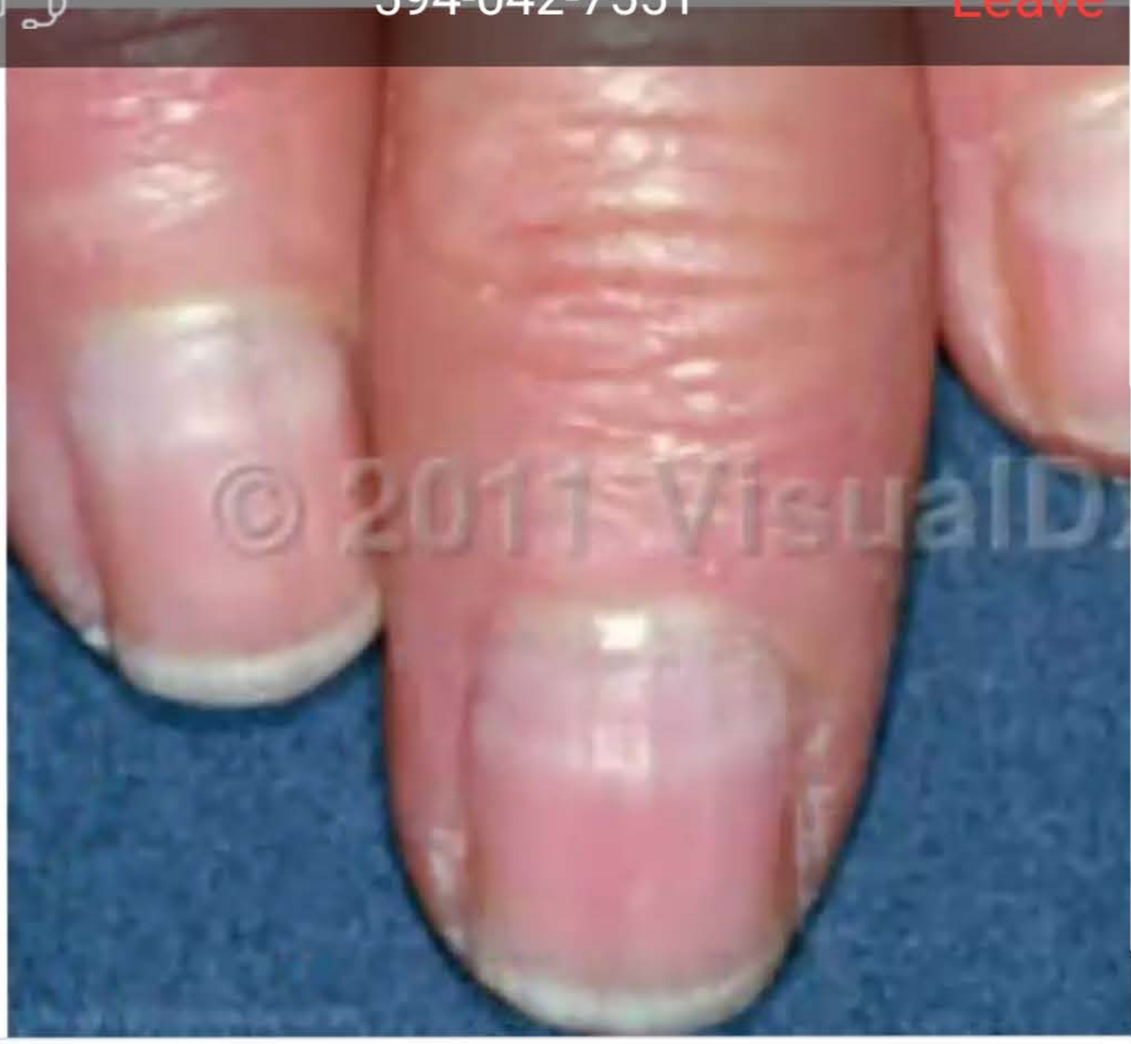

VisualDx

enic poisoning

es may be subject to copyright. Learn more

TED IMAGES

ster Hand Center - Systemic Diseases
erhandcenter.com

World's Tragic In Medlife,.....You May Know ...
rahulmallickblog.blogspot.com

A Day in the
nailsmag.com

Discover Updates Search Recent
Audio Video Share Participants More

8:55
594-042-7551
Leave

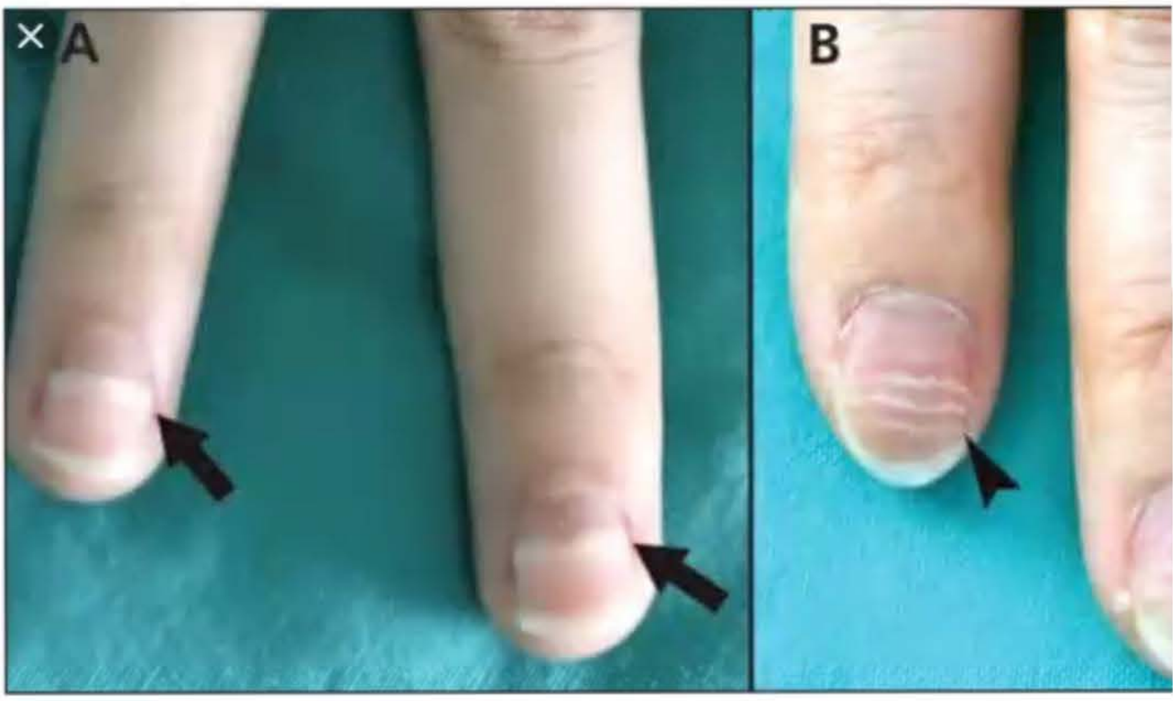

CMAJ

Mees lines and Beau lines after chemotherapy | CMAJ

Images may be subject to copyright. Learn more

RELATED IMAGES

View Image
ejdv.eg.net

Muehrcke's Lines | NEJM
nejm.org

Mees' lines
thelancet.co

Clubbing of the Fiingers: Bulbous appearanc...
grepmed.com

A Case of
synapse.kor

Discover
Updates
Search
Recent
Audio
Video
Share
Participants
More

8:57
594-042-7551 Leave

A 34-year-old woman with human immunodeficiency virus (HIV) is reviewed in clinic six weeks after starting highly active antiretroviral therapy (HAART). She had been feeling clinically well prior to starting therapy, but over the past fortnight has been feeling increasingly tired and weak. She is also complaining of exertional dyspnoea.

She denies fever, chest pain or cough. She has no other previous medical history of note, and is taking tenofovir, emtricitabine and elvitegravir/cobicistat, along with co-trimoxazole for prophylaxis against *Pneumocystis jirovecii* pneumonia.

Her blood results are as follows:

Test	Pre-treatment	After six weeks
Hb	13.2g/dl	8.6 g/dl
MCV	95 fl	102 fl
CD4	205	266

What is the most likely cause for the anaemia?

A Bone marrow infiltration by Mycobacterium avium-intracellulare (MAI)

B Haemolytic anaemia with anti-erythrocyte antibodies

C Folic acid deficiency

D Red cell hypoplasia

E Erythropoietin suppression

Audio Video Share Participants More

D Red cell hypoplasia

The anaemia associated with emtricitabine therapy is due to red cell hypoplasia or aplasia. This is seen more rarely than with zidovudine and lamivudine and more frequently in children than in adults. Bone marrow examination may demonstrate pure red cell aplasia, erythroid maturation arrest, erythroid hypoplasia, and megaloblastic erythropoiesis. Erythropoietin levels are normal or increased.

C Folic acid deficiency

Folate deficiency is usually only seen with co-trimoxazole therapy when it is given concurrently with other anti-folate drugs such as methotrexate.

A Bone marrow infiltration by Mycobacterium avium-intracellulare (MAI)

Given this patient has commenced treatment and has seen an improvement in their CD4 count, infiltration by MAI is unlikely versus other causes of anaemia.

B Haemolytic anaemia with anti-erythrocyte antibodies

Overt haemolysis is rarely seen in the context of HIV infection, and is likely to be less common once HAART is initiated.

E Erythropoietin suppression

Levels of erythropoietin are usually increased in patients with red cell hypoplasia.

Touc... 00:34 9:02
594-042-7551 Leave

A 30-year-old lady with known recurrent attacks of migraine presents to Accident and Emergency complaining of central dull chest pain. She normally takes amitriptyline, and started sumatriptan for the acute attack. She has just returned from a holiday in Spain.

Her examination is normal with all observations within normal range. Initial blood tests reveal normal haematology and biochemistry. Both D-dimer and troponin T assays are within the normal range and chest X-ray is normal. 12-lead ECG is unremarkable.

What is the most appropriate course of action?

A	Start heparin and arrange a ventilation/perfusion scan
B	Obtain a psychiatric opinion
C	Stop sumatriptan
D	Arrange a gastroscopy
E	Reassure and discharge

Submit

Previous Q... Skip Questi...

Audio Video Share Participants More

Touc... 01:28 9:03

A 30-year-old lady with known recurrent attacks of migraine presents to Accident and Emergency complaining of central dull chest pain. She normally takes amitriptyline, and started sumatriptan for the acute attack. She has just returned from a holiday in Spain.

Her examination is normal with all observations within normal range. Initial blood tests reveal normal haematology and biochemistry. Both D-dimer and troponin T assays are within the normal range and chest X-ray is normal. 12-lead ECG is unremarkable.

What is the most appropriate course of action?

Your answer was correct

A	Start heparin and arrange a ventilation/perfusion scan
B	Obtain a psychiatric opinion
C	Stop sumatriptan
D	Arrange a gastroscopy
E	Reassure and discharge

Explanation

C Stop sumatriptan

Sumatriptan has been associated with chest pain, and various studies have suggested up to 17% of people taking it report chest pain, possibly due to vasospasm.

C Stop sumatriptan

Sumatriptan has been associated with chest pain, and various studies have suggested up to 17% of people taking it report chest pain, possibly due to vasospasm. Furthermore, sumatriptan has been associated with myocardial infarctions and is contraindicated in people with known ischaemic heart disease (IHD). Although troponin is normal today, this patient would be considered at significant risk of a myocardial infarction in the coming months.

A Start heparin and arrange a ventilation/perfusion scan

Given the chest pain is dull and retrosternal in nature, it is much more consistent with cardiac chest pain. As such a VQ is not indicated.

B Obtain a psychiatric opinion

Given the strong link between sumatriptan and vasospasm, symptomatic cardiac chest pain should be excluded first before a functional disorder and psychiatric referral are considered.

D Arrange a gastroscopy

Although reflux oesophagitis may cause similar pain, the link between sumatriptan and cardiac vasospasm should be explored first before considering gastroscopy.

E Reassure and discharge

This runs the risk of the patient returning with an NSTEMI due to vasospasm over the next few months.

A 69-year-old man is admitted to the Emergency Department with palpitations and syncope. He has a history of end-stage COPD for which he takes high-dose seretide and tiotropium, and uses home oxygen. He had an inferior myocardial infarction some 5 years earlier.

On examination, his BP is 100/50 mmHg, with pulse 135/min, and atrial fibrillation. There are bilateral crackles on auscultation of the chest consistent with left ventricular failure, and widespread wheeze. He has bilateral ankle swelling.

Investigations:

Hb	12.7 g/dl
WCC	11.1×10^9/l
PLT	201×10^9/l
Na^+	138 mmol/l
K^+	4.3 mmol/l
Creatinine	115 micromol/l
Glucose	6.7 mmol/l
ECG	Fast AF, antero-lateral ST depression

He is given IV furosemide.

Which other intervention is most appropriate?

A IV flecainide

B IV amiodarone

C IV digoxin

D Oral bisoprolol

inferior myocardial infarction some 5 years earlier.

On examination, his BP is 100/50 mmHg, with pulse 135/min, and atrial fibrillation. There are bilateral crackles on auscultation of the chest consistent with left ventricular failure, and widespread wheeze. He has bilateral ankle swelling.

Investigations:

Hb	12.7 g/dl
WCC	11.1×10^9/l
PLT	201×10^9/l
Na^+	138 mmol/l
K^+	4.3 mmol/l
Creatinine	115 micromol/l
Glucose	6.7 mmol/l
ECG	Fast AF, antero-lateral ST depression

He is given IV furosemide.

Which other intervention is most appropriate?

A	IV flecainide
B	IV amiodarone
C	IV digoxin
D	Oral bisoprolol
E	Oral verapamil

9:12
594-042-7551
Leave

C IV digoxin

This patient has long-term COPD and, as such, he is very likely to have significant atrial dilatation and chronic AF. In this case rate control is the most appropriate intervention. Given that his BP is borderline low at 100/50 mmHg and there are signs of LVF, digoxin, which is a mildly positive inotrope, is the best option.

A IV flecainide

Flecainide is indicated for new onset AF in the absence of significant structural or ischaemic heart disease, which is clearly not the case here.

B IV amiodarone

Amiodarone is indicated for rhythm control in patients with paroxysmal AF who have a history of IHD. In this scenario, rate control is the desired intervention.

D Oral bisoprolol

Although bisoprolol is indicated for rate control in AF, in this stage with unstable blood pressure and signs of cardiac failure, it may worsen symptoms of LVF in the short term.

E Oral verapamil

Verapamil would have a significantly negative inotropic effect in this situation and is likely to worsen symptoms of heart failure and reduce systolic blood pressure further.

Rate this question:
Audio Video Share Participants More

9:12
594-042-7551
Leave

You are called to the resuscitation room by an anxious Emergency Department Senior House Officer. A middle-aged male farmer has been brought in by ambulance, and there is little history to be gained from the paramedics, but he appears extremely unwell.

He appears agitated, with pinpoint pupils, is sweating profusely, hypersalivating, and producing frothy white sputum. His wet trousers smell strongly of urine.

What is he most likely to have been poisoned with?

A	Morphine
B	Paraquat
C	Organophosphate insecticide
D	Venlafaxine
E	Dosulepin

17157

Submit

Previous Q...
Skip Questi...

© Pastest 2019

Audio Video Share Participants More

9:13
594-042-7551
Leave

You are called to the resuscitation room by an anxious Emergency Department Senior House Officer. A middle-aged male farmer has been brought in by ambulance, and there is little history to be gained from the paramedics, but he appears extremely unwell.

He appears agitated, with pinpoint pupils, is sweating profusely, hypersalivating, and producing frothy white sputum. His wet trousers smell strongly of urine.

What is he most likely to have been poisoned with?

Your answer was correct

A	Morphine
B	Paraquat
C	Organophosphate insecticide
D	Venlafaxine
E	Dosulepin

Explanation

C Organophosphate insecticide

The **symptoms and signs**+ demonstrated are classical of the toxidrome seen in poisoning with a cholinomimetic agent. Organophosphate insecticides act as cholinesterase inhibitors, thereby increasing the amount of acetylcholine at various receptors by inhibiting its breakdown. The effects seen are due to the acetylcholine acting at

Audio Video Share Participants More

9:13
594-042-7551
Leave

Explanation

C Organophosphate insecticide

The **symptoms and signs** demonstrated are classical of the toxidrome seen in poisoning with a cholinomimetic agent. Organophosphate insecticides act as cholinesterase inhibitors, thereby increasing the amount of acetylcholine at various receptors by inhibiting its breakdown. The effects seen are due to the acetylcholine acting at postganglionic parasympathetic nerve endings, on nicotinic receptors and on the central nervous system. Therapeutic strategies include the use of atropine, oximes (pralidoxime and obidoxime) and benzodiazepines.

A Morphine

Morphine is associated with respiratory depression, decreased consciousness and pinpoint pupils.

B Paraquat

Poisoning with paraquat may be associated with no symptoms initially, but it later presents with persistent vomiting, acidosis and kidney disease.

D Venlafaxine

Venlafaxine overdose is associated with tachycardia, seizures, vomiting and hypertension.

E Dosulepin

Dosulepin presents with the typical features of tricyclic antidepressant overdose, including decreased consciousness, seizures, progressive metabolic acidosis, long QT and consequent ventricular arrhythmias.

Audio Video Share Participants More

https://mypastest.pastest.com

A 28-year-old patient on a methadone programme has newly moved into the area. He visits the general practitioner (GP) for a repeat prescription but is refused. He is known to abuse benzodiazepines. Two days later, he is admitted to the Emergency Department after being found having a generalised tonic-clonic seizure in the street.

On admission, he is hypertensive, soiled with diarrhoea and appears to have been vomiting.

Which of the following represents the best treatment for him with respect to hypertension and agitation?

A	Fluoxetine
B	Recommencement of methadone with specialist advice
C	Diazepam as required for seizures
D	Intravenous (iv) Diamorphine prn
E	Dihydrocodeine as required

Submit

9:16
594-042-7551
Leave

A 28-year-old patient on a methadone programme has newly moved into the area. He visits the general practitioner (GP) for a repeat prescription but is refused. He is known to abuse benzodiazepines. Two days later, he is admitted to the Emergency Department after being found having a generalised tonic-clonic seizure in the street.

On admission, he is hypertensive, soiled with diarrhoea and appears to have been vomiting.

Which of the following represents the best treatment for him with respect to hypertension and agitation?

Your answer was incorrect

A	Fluoxetine
B	Recommencement of methadone with specialist advice
C	Diazepam as required for seizures
D	Intravenous (iv) Diamorphine prn
E	Dihydrocodeine as required

Explanation

B	Recommencement of methadone with specialist advice

He clearly has an opiate withdrawal syndrome which reaches its peak on the second or third day after opiate abstinence. The syndrome may be characterised by severe

Audio
Video
Share
Participants
More

9:17
594-042-7551 Leave

Explanation

B Recommencement of methadone with specialist advice

He clearly has an opiate withdrawal syndrome which reaches its peak on the second or third day after opiate abstinence. The syndrome may be characterised by severe agitation or muscular twitching, aches and pains, abdominal cramps, vomiting, diarrhoea, hypertension, insomnia, anorexia and profuse sweating. The most appropriate intervention is methadone, a long-acting opiate agonist, which because it is long acting is less likely to produce an opiate-related 'high'.

C Diazepam as required for seizures

Use of benzodiazepines may be required to manage seizures, but they will not treat underlying opiate withdrawal, and seizures are usually associated with benzodiazepine withdrawal, not with opiate abuse.

A Fluoxetine

Fluoxetine should not be used in this case, as it would reduce the threshold for further seizures.

D Intravenous (iv) Diamorphine prn

Diamorphine is short acting and likely to perpetuate the opiate addiction cycle in this patient.

E Dihydrocodeine as required

Like diamorphine, this is short acting and likely to perpetuate the opiate addiction cycle.

Audio Video Share Participants More

A 22-year-old Chinese man is started on phenytoin for epilepsy. He subsequently presents with a severe blistering skin rash and oral and genital ulceration.

On examination he is pyrexial (38.2 °C); his BP is 105/72 mmHg, with pulse is 85/min and regular. There are extensive target lesions and a number of de-roofed, blistered lesions.

Which of the following is his most likely HLA type?

A	HLA A3101
B	HLA B1502
C	HLA B5701
D	HLA B5801
E	HLA DQ2

Submit

Previous Q... Skip Questi...

© Pastest 2019

A 22-year-old Chinese man is started on phenytoin for epilepsy. He subsequently presents with a severe blistering skin rash and oral and genital ulceration.

On examination he is pyrexial (38.2 °C); his BP is 105/72 mmHg, with pulse is 85/min and regular. There are extensive target lesions and a number of de-roofed, blistered lesions.

Which of the following is his most likely HLA type?

Your answer was correct

A	HLA A3101
B	HLA B1502
C	HLA B5701
D	HLA B5801
E	HLA DQ2

A
B
C
D
E
0

Resp
Resp
Resp
Resp

Explanation

B	HLA B1502

HLA types related to drug reactions have appeared in a number of examinations over recent years, because they have featured in EMA and FDA alerts. HLA B1502 is associated with Stevens-Johnson syndrome in patients of Chinese origin taking phenytoin.

B HLA B1502

HLA types related to drug reactions have appeared in a number of examinations over recent years, because they have featured in EMA and FDA alerts. HLA B1502 is associated with Stevens-Johnson syndrome in patients of Chinese origin taking phenytoin.

A HLA A3101

A3101 is associated with Stevens-Johnson syndrome in European or Japanese patients treated with carbamazepine.

C HLA B5701

HLA B5701 is associated with abacavir hypersensitivity, which resulted in the development of HLA screening before the medication was initiated for HIV.

D HLA B5801

HLA B5801 is associated with allopurinol hypersensitivity.

E HLA DQ2

DQ2 HLA type is associated with the development of dermatitis herpetiformis.

Rate this question:

Next Question

A 42-year-old man is referred to a Dermatology Clinic with a rash which has developed over his arms over the past two weeks.

His past history includes hypertension, for which he takes lisinopril and bendroflumethiazide. He is also known to suffer from manic depression with significant psychotic episodes, and had been taking chlorpromazine for six years. He was reviewed by his psychiatrist six months ago, who started him on lithium. He has recently been complaining of some indigestion, and so his general practitioner (GP) started lansoprazole two months ago.

On examination, he has a scaly rash localised over the extensor aspects of his elbows.

Which agent is most likely to have precipitated his rash?

A	Chlorpromazine
B	Bendroflumethiazide
C	Lanzoprazole
D	Lithium
E	Lisinopril

Submit

A 42-year-old man is referred to a Dermatology Clinic with a rash which has developed over his arms over the past two weeks.

His past history includes hypertension, for which he takes lisinopril and bendroflumethiazide. He is also known to suffer from manic depression with significant psychotic episodes, and had been taking chlorpromazine for six years. He was reviewed by his psychiatrist six months ago, who started him on lithium. He has recently been complaining of some indigestion, and so his general practitioner (GP) started lansoprazole two months ago.

On examination, he has a scaly rash localised over the extensor aspects of his elbows.

Which agent is most likely to have precipitated his rash?

Your answer was correct

A	Chlorpromazine
B	Bendroflumethiazide
C	Lanzoprazole
D	Lithium
E	Lisinopril

Explanation

D Lithium

The rash is psoriasis, which can be precipitated by lithium. Drugs which are known to trigger or exacerbate psoriasis

Explanation

D Lithium

The rash is psoriasis, which can be precipitated by lithium. Drugs which are known to trigger or exacerbate psoriasis include lithium, antimalarials, nonsteroidal anti-inflammatory drugs (NSAIDs) and β-blockers. Lisinopril is also rarely associated with this adverse effect. Precipitation of the rash may take up to a year to develop after initiation of the medication. Treatment involves withdrawal of the causative agent, and the use of emollients, topical compresses or topical steroids. It may be necessary to use etretinate, methotrexate or phototherapy. Of course, lithium prescription with ACE inhibition is not recommended due to the problem of a significant increase in serum lithium levels.

A Chlorpromazine

Chlorpromazine is associated with dermatitis and urticaria, rather than with psoriasis.

B Bendroflumethiazide

Bendroflumethiazide is associated with exfoliative dermatitis and photosensitivity, rather than with psoriasis.

C Lanzoprazole

Lanzoprazole is associated with an urticarial rash, rather than with psoriasis.

E Lisinopril

Lisinopril is less likely to be associated with psoriasis than

9:24
594-042-7551
Leave

A 24-year-old woman takes 48 × 300 mg aspirin tablets. She presents voluntarily to the Casualty Department around 1 h after her overdose, complaining of nausea. She is 62 kg in weight.

On examination in the Emergency Department, her blood pressure is 110/72 mmHg, her respiratory rate is 33/min.

Which one of the following features would you most expect to see?

A	Respiratory acidosis
B	Respiratory alkalosis
C	Diarrhoea
D	GI bleeding
E	Compensated metabolic acidosis

32814

Submit

Previous Q... Skip Questi...

© Pastest 2019

Audio Video Share Participants More

9:25
594-042-7551
Leave

B Respiratory alkalosis

Typical features of salicylate toxicity include sweating, epigastric pain, vomiting, epigastric tenderness, blurring of vision and tinnitus. Adults develop early respiratory alkalosis before the development of metabolic acidosis, hypocalcaemia and hyponatraemia or hypernatraemia.

A Respiratory acidosis

Respiratory acidosis is seen with overdoses of agents which cause respiratory depression, such as benzodiazepines and opiates.

C Diarrhoea

Vomiting rather than diarrhoea which is seen in the early period after aspirin overdose rather than diarrhoea.

D GI bleeding

GI bleeding is not a prominent early feature of aspirin overdose, but may be seen later as vomiting persists and acidosis develops further.

E Compensated metabolic acidosis

Compensated metabolic acidosis is also known as the second stage of acid base disturbance in aspirin overdose, and only seen a few hours after ingestion of the tablets.

Rate this question:

Next Question

Audio Video Share Participants More

9:25
594-042-7551
Leave

An 18-year-old student attends the Emergency Department having ingested a couple of handfuls of tablets after an argument with her boyfriend, 2.5 h previously. She fully regrets her actions and does not want to die. She is unsure as to which tablets she has taken, but believes that they may have been painkillers.

On examination, she has a Glasgow Coma Score of 15, blood pressure (BP) is 122/80 mmHg, pulse is 78 and regular and, apart from being rather tearful, is asymptomatic.

Which of the following is the most useful next investigation?

A Liver function tests

B Paracetamol levels at 4 h

C Salicylate levels at 4 h

D International normalised ratio

E Arterial blood gas

Submit

Previous Q...

Skip Questi...

Audio
Video
Share
Participants
More

9:26
594-042-7551
Leave

having ingested a couple of handfuls of tablets after an argument with her boyfriend, 2.5 h previously. She fully regrets her actions and does not want to die. She is unsure as to which tablets she has taken, but believes that they may have been painkillers.

On examination, she has a Glasgow Coma Score of 15, blood pressure (BP) is 122/80 mmHg, pulse is 78 and regular and, apart from being rather tearful, is asymptomatic.

Which of the following is the most useful next investigation?

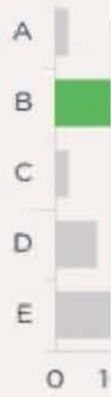

Your answer was correct

A	Liver function tests
B	Paracetamol levels at 4 h
C	Salicylate levels at 4 h
D	International normalised ratio
E	Arterial blood gas

Explanation

B Paracetamol levels at 4 h

Paracetamol intoxication generally has no signs or symptoms in the initial time period post-overdose. Treatment depends on taking blood for paracetamol concentration, and relating this result to the nomogram in order to decide whether N-acetyl cysteine should be initiated. This probably offers full protection if administered within 15 h.

Audio
Video
Share
Participants
More

9:26
594-042-7551
Leave

B Paracetamol levels at 4 h

Paracetamol intoxication generally has no signs or symptoms in the initial time period post-overdose. Treatment depends on taking blood for paracetamol concentration, and relating this result to the nomogram in order to decide whether N-acetyl cysteine should be initiated. This probably offers full protection if administered within 15 h.

A Liver function tests

Liver function tests do not predict outcome in paracetamol overdose versus other investigations such as PT and renal function. They are of less value here.

C Salicylate levels at 4 h

The absence of symptoms of salicylism, including hyperventilation and tinnitus, means that significant aspirin overdose is highly unlikely here.

D International normalised ratio

INR is most predictive of outcomes in paracetamol overdose from the 24 h stage. Therefore, early after overdose it isn't of value with respect to outcomes prediction.

E Arterial blood gas

Given there are no symptoms and the patient is cardiovascularly stable, there is little utility in testing arterial blood gas at this stage.

Rate this question:
Audio
Video
Share
Participants
More

9:26
594-042-7551
Leave

Pastest+

Question 13 of 178

A patient with severe asthma visits you with a press cutting about a phase 2 study of a new pharmacological agent which he would like to take part in.

What is the main objective of a phase 2 study?

A	Evaluation of efficacy in a pre-launch population
B	First time in human study
C	Dose ranging for efficacy surrogates, safety and tolerability in a patient population
D	Initial pharmacokinetic (PK) assessment
E	Assessment of drug-drug interaction

Submit

Previous Q... Skip Questi...

Blog About Pastest Contact Us Help

© Pastest 2019

Audio Video Share Participants More

A patient with severe asthma visits you with a press cutting about a phase 2 study of a new pharmacological agent which he would like to take part in.

What is the main objective of a phase 2 study?

Your answer was incorrect

A	Evaluation of efficacy in a pre-launch population
B	First time in human study
C	Dose ranging for efficacy surrogates, safety and tolerability in a patient population
D	Initial pharmacokinetic (PK) assessment
E	Assessment of drug-drug interaction

A
B
C
D
E
0

Resp
Resp
Resp
Resp

Explanation

C	Dose ranging for efficacy surrogates, safety and tolerability in a patient population

Phase 2 studies for a chronic condition such as asthma or diabetes commonly take place in around 500 patients and are designed to evaluate safety and toxicity and effective dose range and monitor pharmacokinetic and pharmacodynamic effects.

A	Evaluation of efficacy in a pre-launch population

Phase 3 studies are designed to assess safety and efficacy

C Dose ranging for efficacy surrogates, safety and tolerability in a patient population

Phase 2 studies for a chronic condition such as asthma or diabetes commonly take place in around 500 patients and are designed to evaluate safety and toxicity and effective dose range and monitor pharmacokinetic and pharmacodynamic effects.

A Evaluation of efficacy in a pre-launch population

Phase 3 studies are designed to assess safety and efficacy in the pre-launch population, and for a chronic condition this may involve studying many thousands of patients for one year or more.

B First time in human study

This is a phase 1 study, which are increasingly, even outside an indication for cancer treatment, conducted in a relevant patient population.

D Initial pharmacokinetic (PK) assessment

Initial PK assessment is conducted in a phase 1 setting, with intensive blood sampling around single and multi-dose cohorts in humans.

E Assessment of drug-drug interaction

These are conducted for a relevant drug in the context of the patient population and the new agent being trialed. One agent is dosed to steady state, and the other is then introduced with intensive monitoring of pharmacokinetics and pharmacodynamic effects of each drug.

Rana Alnasser's screen

A 72-year-old man is admitted after being found by his home help in a confused state. He is usually able to care for himself, with help for cooking and cleaning, but on this occasion she found him slumped in a chair complaining of pain in his right knee, and shouting at her to get help. He has a history of gout and drinks four pints of beer per day. It is unclear whether he is compliant with medication for blood pressure.

On examination, he is pyrexial (39.1 °C), BP is 95/70 mmHg and pulse 95/min and regular. The right knee is swollen and erythematous, and he cannot flex it more than 30 degrees.

Investigations:

Hb	130 g/l
WCC	16.1×10^9/l
PLT	189×10^9/l
Na^+	138 mmol/l
K^+	4.5 mmol/l
Creatinine	132 umol/l
CRP	225 mg/l
Urate	520 umol/l
Knee joint asperate	-ve birefringent crystals, 350 neutrophils/ml

Which of the following is the most appropriate intervention?

A Allopurinol

B Colchicine

C Flucloxacillin

blood pressure.

On examination, he is pyrexial (39.1 °C), BP is 95/70 mmHg and pulse 95/min and regular. The right knee is swollen and erythematous, and he cannot flex it more than 30 degrees.

Investigations:

Hb	130 g/l
WCC	16.1×10^9/l
PLT	189×10^9/l
Na^+	138 mmol/l
K^+	4.5 mmol/l
Creatinine	132 umol/l
CRP	225 mg/l
Urate	520 umol/l
Knee joint asperate	-ve birefringent crystals, 350 neutrophils/ml

Which of the following is the most appropriate intervention?

A Allopurinol

B Colchicine

C Flucloxacillin

D Naproxen

E Prednisolone

C Flucloxacillin

Given significant evidence of sepsis, with relative hypotension, tachycardia and marked pyrexia, antibiotic intervention is essential until blood culture results are known. The neutrophil count is outside the normal range and may represent septic arthritis. Although urate crystals are seen in the joint, it is possible for sepsis and gout to co-exist.

A Allopurinol

Even in proven acute gout, allopurinol can worsen symptoms initially and therefore should be avoided during the initial period of therapy.

B Colchicine

This is a first-line option for the treatment of gout, but given the degree of systemic symptoms, sepsis should be ruled out/treated first. It is associated with symptoms of diarrhoea, which means it be poorly tolerated in some patients.

D Naproxen

In this situation with a moderate elevation in creatinine, colchicine is potentially preferred as an anti-inflammatory.

E Prednisolone

This is an option for acute gout, but there are significant signs of sepsis and this should be the assumed initial diagnosis.

Rate this question:

You review a 58-year-old man with severe hypertension who has presented to the Emergency Department with intractable headache, diplopia, nausea and vomiting.

On examination, his blood pressure (BP) is 195/115 mmHg and he has papilloedema, diplopia, nausea and vomiting. You begin an infusion of labetalol but he is still hypertensive. You consider trying a sodium nitroprusside infusion.

Which of the following fits best with use of sodium nitroprusside?

A	It can be used when there is suspected coarctation of the aorta
B	It leads to relaxation of gut smooth muscle as well as vascular smooth muscle
C	It should not be used where there is B_{12} deficiency
D	Blood pressure begins to fall after 5–10 min of infusion
E	Cyanide accumulation occurs in overdose

Submit

9:32

You review a 58-year-old man with severe hypertension who has presented to the Emergency Department with intractable headache, diplopia, nausea and vomiting.

On examination, his blood pressure (BP) is 195/115 mmHg and he has papilloedema, diplopia, nausea and vomiting. You begin an infusion of labetalol but he is still hypertensive. You consider trying a sodium nitroprusside infusion.

Which of the following fits best with use of sodium nitroprusside?

Your answer was incorrect

A. It can be used when there is suspected coarctation of the aorta

B. It leads to relaxation of gut smooth muscle as well as vascular smooth muscle

C. It should not be used where there is B_{12} deficiency

D. Blood pressure begins to fall after 5–10 min of infusion

E. Cyanide accumulation occurs in overdose

Explanation

E. Cyanide accumulation occurs in overdose

Sodium nitroprusside is a potent short-acting vasodilator, which acts via the nitric oxide pathway to increase cGMP

Rana Alnasser's screen

E Cyanide accumulation occurs in overdose

Sodium nitroprusside is a potent short-acting vasodilator, which acts via the nitric oxide pathway to increase cGMP within smooth muscle cells. Side effects include nausea, sweating, headache and twitching, and overdose may be associated with accumulation of cyanide.

B It leads to relaxation of gut smooth muscle as well as vascular smooth muscle

Although nitroprusside does lead to relaxation of vascular smooth muscle, it doesn't impact on GI smooth muscle – for example, in the duodenum.

A It can be used when there is suspected coarctation of the aorta

It should not be used in coarctation of the aorta because the marked reduction in preload could precipitate dangerous hypotension.

C It should not be used where there is B_{12} deficiency

Although historical papers recommended avoiding nitroprusside in B_{12} deficiency, there is no evidence that it significantly impacts on B_{12} levels when used at therapeutic dose.

D Blood pressure begins to fall after 5–10 min of infusion

Sodium nitroprusside has a rapid hypotensive effect that begins to appear within 30–60 s of commencing the infusion.

Rana Alnasser's screen

A 21-year-old man is brought to hospital by ambulance. The vehicle was called by his girlfriend who found him semiconscious and hyperventilating, surrounded by a number of empty packets of aspirins. Apparently, there had been a row that morning some 5 h earlier.

On examination, his blood pressure is 112/72 mmHg, pulse is 85 bpm and regular. He is hyperventilating with a respiratory rate of 27/min, with saturations of 96% on air. Abdomen is generally tender, particularly in the epigastrium.

Investigations (arterial blood gas):

Hb	13.1 g/dl
WCC	10.9×10^9/l
PLT	203×10^9/l
Na^+	142 mmol/l
K^+	3.1 mmol/l
Bicarbonate	15 mmol/l
Creatinine	132 μmol/l
pH	7.42
Salicylate	500 mg/l

Which of the following is the most appropriate next intervention?

A Haemodialysis

B Intravenous (iv) bicarbonate

C iv potassium

D iv normal saline with furosemide

is 85 bpm and regular. He is hyperventilating with a respiratory rate of 27/min, with saturations of 96% on air. Abdomen is generally tender, particularly in the epigastrium.

Investigations (arterial blood gas):

Hb	13.1 g/dl
WCC	10.9×10^9/l
PLT	203×10^9/l
Na^+	142 mmol/l
K^+	3.1 mmol/l
Bicarbonate	15 mmol/l
Creatinine	132 µmol/l
pH	7.42
Salicylate	500 mg/l

Which of the following is the most appropriate next intervention?

A Haemodialysis

B Intravenous (iv) bicarbonate

C iv potassium

D iv normal saline with furosemide

E iv magnesium

K^+	3.1 mmol/l
Bicarbonate	15 mmol/l
Creatinine	132 μmol/l
pH	7.42
Salicylate	500 mg/l

Which of the following is the most appropriate next intervention?

Your answer was correct

A Haemodialysis

B Intravenous (iv) bicarbonate

C iv potassium

D iv normal saline with furosemide

E iv magnesium

Explanation

C iv potassium

This man has a compensated metabolic acidosis, commonly known as the second stage of aspirin overdose. At this stage correction of potassium should be instigated, and post correction of potassium, urinary alkalinisation considered. The first stage of aspirin overdose is a respiratory acidosis, the second stage occurring at around the 4–5-hour stage after overdose is a compensated

9:35
594-042-7551
Leave
MyPastest
https://mypastest.pastest.com

A Haemodialysis

Haemodialysis should be considered primarily for patients with:

- Plasma concentrations greater than 700 mg/l (5.1 mmol/l)
- Acute kidney injury
- Congestive cardiac failure
- Non-cardiogenic pulmonary oedema
- Coma
- Convulsions
- CNS effects not resolved by correction of acidosis
- Persistently high salicylate concentrations unresponsive to urinary alkalinisation
- Severe metabolic acidosis (pH below 7.2).

B Intravenous (iv) bicarbonate

iv bicarbonate should only be considered after serum potassium has been corrected.

D iv normal saline with furosemide

Forced alkaline diuresis is not recommended in the management of aspirin overdose.

E iv magnesium

Although magnesium replacement may be required, correction of potassium and initiation of bicarbonate therapy are the initial most important steps.

Audio Video Share Participants More

9:35

A 62-year-old man is found confused by his friends holding an empty medication bottle with no label. His friends say he has a background of angina, chronic bronchitis on home oxygen, and osteoarthritis. The patient starts vomiting and has a seizure, which is controlled with diazepam.

His temperature is 36.8 °C, pulse 120/min regular, blood pressure 115/86 mmHg.

Investigations:

ECG	Sinus tachycardia
Sodium	144 mmol/l
Potassium	2.9 mmol/l
Urea	5.8 mmol/l
Creatinine	75 µmol/l
Calcium	2.63 mmol/l
Glucose	9.3 mmol/l
Theophylline	290 µmol/l (55–110 µmol/l)

While in the assessment unit he continues to have further seizures and vomiting episodes with decreased consciousness, so you electively intubate and ventilate him.

What is the most appropriate intervention?

A Intravenous (iv) phenytoin

B Sodium bicarbonate

C Gastric lavage

D Charcoal haemoperfusion

Rana Alnasser's screen

he has a background of angina, chronic bronchitis on home oxygen, and osteoarthritis. The patient starts vomiting and has a seizure, which is controlled with diazepam.

His temperature is 36.8 °C, pulse 120/min regular, blood pressure 115/86 mmHg.

Investigations:

ECG	Sinus tachycardia
Sodium	144 mmol/l
Potassium	2.9 mmol/l
Urea	5.8 mmol/l
Creatinine	75 µmol/l
Calcium	2.63 mmol/l
Glucose	9.3 mmol/l
Theophylline	290 µmol/l (55–110 µmol/l)

While in the assessment unit he continues to have further seizures and vomiting episodes with decreased consciousness, so you electively intubate and ventilate him.

What is the most appropriate intervention?

A Intravenous (iv) phenytoin

B Sodium bicarbonate

C Gastric lavage

D Charcoal haemoperfusion

E Peritoneal dialysis

D Charcoal haemoperfusion

The patient has overdosed on theophylline medication. This can cause cardiac arrhythmias, vomiting, confusion, seizures, hypokalaemia, hyperglycaemia and hypercalcaemia. In this patient, with high theophylline serum levels and persisting seizures, charcoal haemoperfusion is a reasonable option. Blood from the patient is passed through a charcoal resin, and this will remove protein-bound toxins. Seizure activity is difficult to control in this situation and the patient may need transfer to an intensive care unit. Peritoneal dialysis is ineffective. Sodium bicarbonate has a role in the treatment of tricyclic overdose.

A Intravenous (iv) phenytoin

iv phenytoin is a potential anti-arrhythmic used in the treatment of ventricular tachycardia for patients with digoxin overdose, particularly where digibind is not immediately available.

B Sodium bicarbonate

Sodium bicarbonate is used for patients with tricyclic antidepressant overdose where there is QRS prolongation.

C Gastric lavage

Gastric lavage is rarely instituted for the treatment of overdose. Where patients present early after overdose it may be considered for iron ingestion.

E Peritoneal dialysis

Peritoneal dialysis is less effective for the treatment of

haemoperfusion is a reasonable option. Blood from the patient is passed through a charcoal resin, and this will remove protein-bound toxins. Seizure activity is difficult to control in this situation and the patient may need transfer to an intensive care unit. Peritoneal dialysis is ineffective. Sodium bicarbonate has a role in the treatment of tricyclic overdose.

A Intravenous (iv) phenytoin

iv phenytoin is a potential anti-arrhythmic used in the treatment of ventricular tachycardia for patients with digoxin overdose, particularly where digibind is not immediately available.

B Sodium bicarbonate

Sodium bicarbonate is used for patients with tricyclic antidepressant overdose where there is QRS prolongation.

C Gastric lavage

Gastric lavage is rarely instituted for the treatment of overdose. Where patients present early after overdose it may be considered for iron ingestion.

E Peritoneal dialysis

Peritoneal dialysis is less effective for the treatment of theophylline overdose than charcoal haemoperfusion. Haemoperfusion allows potentially more rapid theophylline removal.

A 72-year-old man, who has suffered from chronic obstructive pulmonary disease (COPD) for some years, is admitted to the Emergency Department having suffered a grand mal seizure. According to his wife, he has also been vomiting for a couple of days.

Apparently, the general practitioner (GP) had started him on an antibiotic for a respiratory tract infection. Additional medication includes a high-dose salmeterol fluticasone inhaler for his COPD, and oral theophylline.

Investigations:

Haemoglobin (Hb)	12.1 g/dl
White cell count (WCC)	8.2×10^9/l
Platelets (PLT)	211×10^9/l
Sodium (Na^+)	139 mmol/l
Potassium (K^+)	3.1 mmol/l
Creatinine (Cr)	140 μmol/l

You suspect theophylline toxicity related to a drug interaction.

Which of the following is the most likely cause?

A Amoxicillin

B Co-amoxyclav

C Rifampicin

D Ciprofloxacin

E Trimethoprim

9:42
594-042-7551 Leave

Haemoglobin (Hb)	12.1 g/dl
White cell count (WCC)	8.2×10^9/l
Platelets (PLT)	211×10^9/l
Sodium (Na^+)	139 mmol/l
Potassium (K^+)	3.1 mmol/l
Creatinine (Cr)	140 μmol/l

You suspect theophylline toxicity related to a drug interaction.

Which of the following is the most likely cause?

A Amoxicillin

B Co-amoxyclav

C Rifampicin

D Ciprofloxacin

E Trimethoprim

Submit

Previous Q... Skip Questi...

Audio Video Share Participants More

9:43
594-042-7551 Leave

D Ciprofloxacin

Drugs known to reduce clearance of theophylline include allopurinol, cimetidine, ciprofloxacin, corticosteroids, diltiazem, erythromycin, frusemide, isoprenaline, oral contraceptives, thiabendazole and verapamil. Ciprofloxacin is an inhibitor of CYP 1A2 and this, coupled with some effect on 3A4 metabolism, may drive theophylline accumulation.

A Amoxicillin

Penicillins do not impact on theophylline metabolism.

B Co-amoxyclav

Clavulanic acid, like penicillins, does not impact on theophylline metabolism.

C Rifampicin

Rifampicin is a P450 enzyme inducer, which is likely to reduce theophylline levels.

E Trimethoprim

Case reports of hyponatraemia exist when trimethoprim and theophylline are co-administered, but theophylline toxicity itself isn't reported.

Rate this question:

Next Question

Audio Video Share Participants More

9:43
594-042-7551 Leave

A 27-year-old woman is admitted in a comatose state. She was found lying unconscious on the floor of her apartment by her boyfriend.
She had recently been fired by her employer for below-standard behaviour at work. She was taking regular amitriptyline at night, prescribed by her GP for low mood and trouble with sleeping.

On examination, she is comatose and receiving oxygen by mask. Her pulse is 130/min and blood pressure is 110/70 mmHg. Her pupils are 8 mm and unreactive to light. The fundi are normal. Her eyes are divergent and the oculocephalic reflex is sluggish. Painful stimuli lead to decortication of the upper limbs. Tendon reflexes are brisk and plantar responses are extensor on both sides. The bladder is full and she is catheterised.

Electrocardiogram (ECG) reveals QRS widening. While she is being examined she has a generalised seizure. An urgent computed tomography (CT) of the head is normal and cerebrospinal fluid (CSF) study reveals 5 lymphocytes, 0.3 g/l protein and 5.5 mmol of glucose with a random blood glucose of 6.5 mmol/l. Blood gases were abnormal, showing metabolic acidosis.

What one of the following represents the most important intervention for her?

A Dimercaprol

B Sodium bicarbonate

C Amiodarone

D Physiostigmine

E Charcoal haemoperfusion

Audio Video Share Participants More

9:47
594-042-7551 Leave

A 32-year-old woman, who is 32 weeks pregnant, is admitted as an emergency from the Antenatal Clinic with severe headaches, blurred vision and bilateral leg swelling.

On examination, she has a blood pressure (BP) of 180/130 mmHg. There is bilateral papilloedema, peripheral oedema, increased tone, reflexes and bilateral extensor plantars. Ultrasound reveals that the fetus is growing adequately and there is no imminent need for delivery from the point of view of fetal health.

Investigations;

Haemoglobin (Hb)	11.0 g/dl
White cell count (WCC)	5.9×10^9/l
Platelets (PLT)	130×10^9/l
Sodium (Na^+)	139 mmol/l
Potassium (K^+)	4.9 mmol/l
Creatinine (Cr)	110 μmol/l

What is the most appropriate next management step in controlling her BP?

A Immediate delivery

B Oral methyldopa

C Oral ramipril

D IV magnesium sulphate

E IV labetalol

Audio Video Share Participants More

9:48
594-042-7551 Leave

A 32-year-old woman, who is 32 weeks pregnant, is admitted as an emergency from the Antenatal Clinic with severe headaches, blurred vision and bilateral leg swelling.

On examination, she has a blood pressure (BP) of 180/130 mmHg. There is bilateral papilloedema, peripheral oedema, increased tone, reflexes and bilateral extensor plantars. Ultrasound reveals that the fetus is growing adequately and there is no imminent need for delivery from the point of view of fetal health.

Investigations;

Haemoglobin (Hb)	11.0 g/dl
White cell count (WCC)	5.9×10^9/l
Platelets (PLT)	130×10^9/l
Sodium (Na^+)	139 mmol/l
Potassium (K^+)	4.9 mmol/l
Creatinine (Cr)	110 µmol/l

What is the most appropriate next management step in controlling her BP?

Your answer was incorrect

A Immediate delivery

B Oral methyldopa

C Oral ramipril

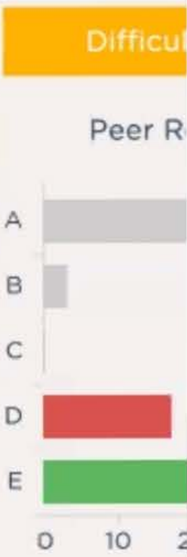

Audio Video Share Participants More

A 29-year-old Scandinavian woman is admitted to hospital with severe abdominal pain and vomiting. She has been investigated in the past for multiple admissions with abdominal pain, but no formal diagnosis has been reached. She suffers from constipation and occasional colicky abdominal pain.

A few days ago, the abdominal pain increased in severity and her flatmates convinced her to come to hospital when she started displaying aggressive behaviour. The patient also states she has been feeling generalised weakness in her lower limbs and she has noticed on occasion that her urine is a 'funny colour'.

Her temperature is 37.1 °C, pulse 102/min, blood pressure 142/81 mmHg.

Abdominal examination reveals generalised tenderness. She has generalised weakness of the lower limbs, with reduced reflexes. There is no visible rash on the body.

Investigations:

Hb	13.0 g/dl
WCC	12.0×10^9/l
PLT	310×10^9/l
Na^+	131 mmol/l
K^+	3.8 mmol/l
Creatinine	72 µmol/l
Urea	6.3 mmol/l
Glucose	6.9 mmol/l

What treatment will be most helpful?

A Trimethoprim

B Intravenous (iv) fluids

urine is a 'funny colour'.

Her temperature is 37.1 °C, pulse 102/min, blood pressure 142/81 mmHg.

Abdominal examination reveals generalised tenderness. She has generalised weakness of the lower limbs, with reduced reflexes. There is no visible rash on the body.

Investigations:

Hb	13.0 g/dl
WCC	12.0×10^9/l
PLT	310×10^9/l
Na^+	131 mmol/l
K^+	3.8 mmol/l
Creatinine	72 µmol/l
Urea	6.3 mmol/l
Glucose	6.9 mmol/l

What treatment will be most helpful?

A Trimethoprim

B Intravenous (iv) fluids

C Insulin

D Haematin

E Chloroquine

Rana Alnasser's screen

9:52
594-042-7551
Leave

urine is a 'funny colour'.

Her temperature is 37.1 °C, pulse 102/min, blood pressure 142/81 mmHg.

Abdominal examination reveals generalised tenderness. She has generalised weakness of the lower limbs, with reduced reflexes. There is no visible rash on the body.

Investigations:

Hb	13.0 g/dl
WCC	12.0×10^9/l
PLT	310×10^9/l
Na^+	131 mmol/l
K^+	3.8 mmol/l
Creatinine	72 µmol/l
Urea	6.3 mmol/l
Glucose	6.9 mmol/l

What treatment will be most helpful?

A Trimethoprim

B Intravenous (iv) fluids

C Insulin

D Haematin

E Chloroquine

Audio Video Share Participants More

D Haematin

The scenario is pointing towards a diagnosis of acute intermittent porphyria. The biosynthetic pathway for the manufacture of haemoglobin requires globin chain synthesis and haem synthesis. Haem is produced from protoporphyrin IX and a ferrous (Fe^{2+}) ion. The porphyrias result from defects in the porphyrin biosynthetic pathway. Acute intermittent porphyria results from a defect in the enzyme porphobilinogen deaminase. Symptoms include abdominal pain, peripheral neuropathy and psychiatric symptoms. There is sometimes an association with hyponatraemia and the syndrome of inappropriate anti-diuretic hormone secretion (SIADH). The urine darkens on standing and the diagnosis can be confirmed by analysing the urinary and faecal porphyrins. Haematin can help patients as it acts as a negative feedback operator on the porphyrin synthetic pathway. As a general rule, enzyme inducers exacerbate porphyria as they induce the pathway leading to increased production of porphyrins.

Porphyrias produce skin rashes except for acute intermittent prophyria. The porphyrias are inherited as autosomal dominant conditions, except for congenital erythropoetic porphyria that is autosomal recessive.

A Trimethoprim

Although the urine is discoloured, this is more likely to be due to porphyrins than a UTI. Note in particular that the patient is apyrexial and there are no signs of urinary tract infection.

B Intravenous (iv) fluids

iv 5% dextrose may exacerbate hyponatraemia in this situation, although there is evidence that higher levels of carbohydrate replacement can abort an acute episode.

Rana Alnasser's screen

Although the urine is discoloured, this is more likely to be due to porphyrins than a UTI. Note in particular that the patient is apyrexial and there are no signs of urinary tract infection.

B Intravenous (iv) fluids

iv 5% dextrose may exacerbate hyponatraemia in this situation, although there is evidence that higher levels of carbohydrate replacement can abort an acute episode.

C Insulin

Insulin has no role in the treatment of acute porphyria; carbohydrate replacement and haematin are the key interventions.

E Chloroquine

Chloroquine is a therapy for porphyria cutanea tarda, not for acute intermittent porphyrias.

Rate this question:

Next Question

Previous Q... Tag Questi... Feedback End Session

Blog About Pastest Contact Us Help

© Pastest 2019

A 27-year-old man comes to the Respiratory Clinic with active pulmonary tuberculosis. You ask him about contacts, and he mentions his girlfriend, a teacher, with whom he split up three months earlier.

She is reviewed in the clinic, looks well, is apyrexial and has no symptoms of infection. Her blood results are described below.

Investigations:

Hb	12.1 g/dl
WCC	5.7×10^9/l
PLT	209×10^9/l
Na^+	139 mmol/l
K^+	4.9 mmol/l
Creatinine	130 µmol/l
ESR	8.0 mm/hr
Quantiferon test	+
HIV test	-
Chest X-ray	Normal

Which of the following is the most appropriate way to manage her?

A Full anti-tuberculous therapy

B Rifampicin and isoniazid for three months

C Repeat chest X-ray in four weeks

D Reassure

and he mentions his girlfriend, a teacher, with whom he split up three months earlier.

She is reviewed in the clinic, looks well, is apyrexial and has no symptoms of infection. Her blood results are described below.

Investigations:

Hb	12.1 g/dl
WCC	5.7×10^9/l
PLT	209×10^9/l
Na^+	139 mmol/l
K^+	4.9 mmol/l
Creatinine	130 µmol/l
ESR	8.0 mm/hr
Quantiferon test	+
HIV test	-
Chest X-ray	Normal

Which of the following is the most appropriate way to manage her?

A Full anti-tuberculous therapy

B Rifampicin and isoniazid for three months

C Repeat chest X-ray in four weeks

D Reassure

E Rifampicin for one month

Rana Alnasser's screen

9:56

A 19-year-old woman is being investigated for epistaxis. She has noticed increased bruising and has suffered from menorrhagia almost since her periods began.

A recent dental procedure resulted in protracted postoperative bleeding which required review in the local Emergency Department. She said that other members of the family suffer from a bleeding tendency.

Investigations reveal:

Hb	12 g/dl
WCC	7×10^9/l
PLT	380×10^9/l
Activated partial thromboplastin time	45 s (30–40 s)
Prothrombin time	12 s (11–15.5 s)
Bleeding time	10 min (3–8 min)
Factor VIII level	45 IU/dl (50–150 IU/dl)

What treatment would be considered initially if further dental procedures are required?

A Platelet infusion

B Cryoprecipitate

C Mefanamic acid

D Vitamin K

E Desmopressin

Rana Alnasser's screen

postoperative bleeding which required review in the local Emergency Department. She said that other members of the family suffer from a bleeding tendency.

Investigations reveal:

Hb	12 g/dl
WCC	7×10^9/l
PLT	380×10^9/l
Activated partial thromboplastin time	45 s (30–40 s)
Prothrombin time	12 s (11–15.5 s)
Bleeding time	10 min (3–8 min)
Factor VIII level	45 IU/dl (50–150 IU/dl)

What treatment would be considered initially if further dental procedures are required?

Your answer was correct

A Platelet infusion

B Cryoprecipitate

C Mefanamic acid

D Vitamin K

E Desmopressin

Explanation

E Desmopressin

The patient has von Willebrand's disease (vWD). Von Willebrand's factor (vWf) is involved in stabilising factor VIII and in promoting platelet aggregation. In vWD, patients experience coagulopathy with prolonged bleeding time, prolonged activated partial thromboplastin time (APPT) and normal prothrombin time (PT). Their factor VIII assays can be low. Desmopressin, which is similar to antidiuretic hormone, can be used for treatment. As expected, a side-effect is hyponatraemia. For more serious bleeds or surgery, factor VIII concentrate can be used.

A Platelet infusion

It is not defective platelets that lead to bleeding in this case, but deficient aggregation due to a lack of factor VIII.

B Cryoprecipitate

Cryoprecipitate has a higher infectious risk than delivery of recombinant factor VIII; hence it is not a first-choice therapy in this situation.

C Mefanamic acid

Mefanamic acid is a non-steroidal anti-inflammatory drug which has a role in reducing the severity of menstrual bleeding where an underlying coagulopathy has been excluded.

D Vitamin K

Vitamin K is used to reverse the effect of warfarin therapy.

Rate this question:

9:58
594-042-7551
Leave

An 18-year-old man is brought by his mother for evaluation. He presents with anxiety, irritability and a persistent tremor. She is concerned that he is taking stimulants as he appears to sleep for only 1–2 h per night. These periods of hyperactivity are interspersed with periods of extreme tiredness. His teachers have mentioned a deterioration in his academic performance.

On examination, he is unkempt. His blood pressure is 150/100 mmHg and pulse is 110 bpm. He is alert and restless, and appears to be talking to someone who is not in the room. He tells you that his mother is jealous of him and is planning to kill him. His physical examination is otherwise unremarkable.

What is the most likely diagnosis?

A	Depression
B	Asperger's syndrome
C	Amphetamine abuse
D	Wilson's disease
E	Opiate abuse

9298

Submit

Previous Q...
Skip Questi...
Audio
Video
Share
Participants
More

An 18-year-old man is brought by his mother for evaluation. He presents with anxiety, irritability and a persistent tremor. She is concerned that he is taking stimulants as he appears to sleep for only 1–2 h per night. These periods of hyperactivity are interspersed with periods of extreme tiredness. His teachers have mentioned a deterioration in his academic performance.

On examination, he is unkempt. His blood pressure is 150/100 mmHg and pulse is 110 bpm. He is alert and restless, and appears to be talking to someone who is not in the room. He tells you that his mother is jealous of him and is planning to kill him. His physical examination is otherwise unremarkable.

What is the most likely diagnosis?

Your answer was correct

A Depression

B Asperger's syndrome

C Amphetamine abuse

D Wilson's disease

E Opiate abuse

Explanation

C Amphetamine abuse

These clinical features raise the possibility that the patient

C Amphetamine abuse

These clinical features raise the possibility that the patient is consuming central nervous system (CNS) stimulants which have significant hypertensive effects and are analeptics (eg amphetamine or methylphenidate). However, amphetamine is more likely in this patient as the latter drug does not lead to features of psychosis with prolonged use. When amphetamine is consumed chronically in high doses, it could lead to a state that is indistinguishable from paranoid schizophrenia. These drugs are capable of causing vasculitis and intracerebral or subarachnoid haemorrhages because of significant hypertension. Similar vascular complications could also be caused by over-the-counter 'cold medications' like ephedrine and phenylpropanolamine.

Withdrawal of the drug after sustained use can lead to a period of prolonged sleep, muscle pain, profound fatigue and depression.

Treatment includes discontinuation of amphetamine and administering anxiolytics and/or atypical antipsychotics if required.

A Depression

Depression would not fit with the features of sympathetic activation seen here.

B Asperger's syndrome

Asperger's syndrome is more likely to present with social withdrawal, and would not be associated with either the sympathetic activation or the features of psychosis present here.

D Wilson's disease

Treatment includes discontinuation of amphetamine and administering anxiolytics and/or atypical antipsychotics if required.

A Depression

Depression would not fit with the features of sympathetic activation seen here.

B Asperger's syndrome

Asperger's syndrome is more likely to present with social withdrawal, and would not be associated with either the sympathetic activation or the features of psychosis present here.

D Wilson's disease

Wilson's disease presents more commonly with asymmetrical cerebellar signs and is not associated with the sympathetic activation and acute psychosis seen here.

E Opiate abuse

Opiate abuse is more likely to present with listlessness and inactivity, rather than the hypertension and hyperactivity seen here.

Rate this question:

You are called to see a 38-year-old man in the Emergency Department. He was brought there by ambulance after his friend administered him a tablet that would apparently make him feel better after a heavy night out and a recent cold.

On examination, he looks very unwell. His blood pressure (BP) is 70/40 mmHg with a pulse of 104/min. He is cold and sweaty. He is stridorous and has marked wheeze on auscultation of the chest. There is an urticaria type skin rash in addition. The emergency staff have already started a 500 ml bag of normal saline.

How best would you initially manage him?

A	Glucagon IV
B	Further normal saline 1l IV stat
C	Hydrocortisone IV
D	Chlorpheniramine IV
E	Adrenalin IM

Submit

10:02
594-042-7551
Leave

C Hydrocortisone IV

D Chlorpheniramine IV

E Adrenalin IM

Explanation

E Adrenalin IM

Despite initial fluid resuscitation, this patient still has marked hypotension and tachycardia. He is in urgent need of circulatory support. The most likely diagnosis is anaphylaxis related to the unknown medication. Night nurse, a night time cold remedy contains dextromethorphan, to which anaphylactic reactions have been described. Treatment of choice in this situation is IM adrenalin (0.3-0.5 ml of 1:1000), which may be repeated every 15 min.

A Glucagon IV

Glucagon is of most potential use in beta-blocker overdose, and the tachycardia here is less suggestive of beta-blockade as the driver for his presentation.

B Further normal saline 1l IV stat

Although he may respond to further fluid loading, the imminent need is to improve blood pressure and stave off potential respiratory arrest; as such, adrenalin is the most important intervention.

C Hydrocortisone IV

Although hydrocortisone will positively impact on the

Audio Video Share Participants More

10:03
594-042-7551
Leave

E Adrenalin IM

Despite initial fluid resuscitation, this patient still has marked hypotension and tachycardia. He is in urgent need of circulatory support. The most likely diagnosis is anaphylaxis related to the unknown medication. Night nurse, a night time cold remedy contains dextromethorphan, to which anaphylactic reactions have been described. Treatment of choice in this situation is IM adrenalin (0.3-0.5 ml of 1:1000), which may be repeated every 15 min.

A Glucagon IV

Glucagon is of most potential use in beta-blocker overdose, and the tachycardia here is less suggestive of beta-blockade as the driver for his presentation.

B Further normal saline 1l IV stat

Although he may respond to further fluid loading, the imminent need is to improve blood pressure and stave off potential respiratory arrest; as such, adrenalin is the most important intervention.

C Hydrocortisone IV

Although hydrocortisone will positively impact on the inflammatory cascade, at this stage it is adrenalin that is the crucial next step (hydrocortisone can be given later).

D Chlorpheniramine IV

Although this will impact on histamine-driven inflammation, the impact would be delayed with respect to blood pressure and stridor versus giving adrenalin IM.

Audio Video Share Participants More

10:05

A 17-year-old girl presents to Accident and Emergency (A&E) complaining of nausea and admits to having taken an overdose of paracetamol about 4 h earlier. She denies having taken any other tablets, and denies alcohol use. Her only past medical history of note is epilepsy, for which she takes carbamazepine.

The overdose was a spur of the moment act, which the patient now regrets. She attributes the overdose to an argument with her boyfriend. She denies any suicidal ideation or intent. She is accompanied by her mother, who is happy to take her home.

On examination, she is alert and orientated. Pulse is 70 bpm, regular. Heart sounds are normal and her chest is clear. Her abdomen is soft and non-tender, with no organomegaly and normal bowel sounds. Neurological examination is unremarkable.

Observations:

Temperature	36.4 °C
Heart rate	70 bpm
Blood pressure	124/78 mmHg
BM	5.4 mmol/l
O_2 sats	98% air
ECG	Normal sinus rhythm 60 bpm

Her blood results are as follows:

WBC	5.2×10^9/l
Na^+	138 mmol/l
Bilirubin	14 µmol/l
HB	13.2 g/dl
K^+	4.1 mmol/l

Rana Alnasser's screen

MCV	88 fl
Urea	5.6 mmol/l
ALK-P	63 IU/l
Platelets	216 × 10^9/l
Creatinine	108 µmol/l
Albumin	39 g/l
INR	1.1
Glucose	5.2 mmol/l
APTT	38 s
4-h paracetamol level	140 mg/l
Salicylates	< 10

What is the most appropriate next step in your management?

A Discharge patient home and arrange outpatient psychiatric follow up

B Admit the patient for observation, repeat blood tests and paracetamol level in 4 hours

C Carry out gastric lavage

D Start *N*-acetylcysteine

E Arrange psychiatric review

10:08

D Start *N*-acetylcysteine

The 4-hour paracetamol level is above the level required for starting treatment with *N*-acetylcysteine and given this patient is taking long-term carbamazepine, a potent CYP450 enzyme inducer, it is prudent to start treatment as soon as possible because her risk of significant toxicity is further increased.

B Admit the patient for observation, repeat blood tests and paracetamol level in 4 hours

This 4-hour time window extension potentially misses the important time period where intervention may prevent or at least significantly reduce liver damage.

A Discharge patient home and arrange outpatient psychiatric follow up

Given this patient's paracetamol level they are at significant risk of hepatotoxicity.

C Carry out gastric lavage

Gastric lavage has only a very limited role in the treatment of overdoses, for example in the first few minutes after overdose of agents such as tricyclic antidepressants.

E Arrange psychiatric review

Although inpatient psychiatric review may be required, treatment for potential hepatotoxicity is the more urgent intervention.

Rana Alnasser's screen

A 40-year-old man visits an Infertility Clinic on account of inability to sustain an erection. He does have an early morning erection, but when he tries to penetrate his partner, the erection is either too short-lived or too soft to achieve adequate penetration. He has suffered from type 1 diabetes for 30 years.

On examination, his blood pressure (BP) is 155/90 mmHg. He has a normal distribution of pubic and axillary hair, and a normal penis and testes on examination.

Investigations:

Hb	13.1 g/dl
WCC	5.9×10^9/l
PLT	201×10^9/l
Na^+	139 mmol/l
K^+	4.9 mmol/l
Creatinine	110 µmol/l
Total chol	5.2 mmol/l
TG	2.1 mmol/l
HbA1c	57.38 mmol/mol (7.4%)

Which of the following is the most appropriate treatment for him?

A Sildenafil

B Transdermal testosterone

C Psychosexual counselling

D Additional blood glucose lowering therapy

A Sildenafil

Given the duration of this patient's diabetes, the most likely cause of his erectile dysfunction is microvascular disease. As such, moving to oral therapy to improve penile blood flow is an appropriate intervention. In diabetes, high doses of PDE5 inhibitors such as sildenafil may be needed to achieve a therapeutic effect.

C Psychosexual counselling

Although counselling has an important role in managing sexual dysfunction, he is also appropriate for medical intervention.

B Transdermal testosterone

Given this man is 40 and has morning erections and normal penis, testes and sexual hair, he is unlikely to be significantly testosterone deficient. Of course it is appropriate to assess testosterone levels as part of the work-up for him, but given it's likely these are in the normal range, an impact on sexual function wouldn't be expected.

D Additional blood glucose lowering therapy

Although tight glycaemic control can stay progression of microvascular disease, reversal of existing damage isn't seen.

E Referral for penile implant

This is obviously an intervention of last resort in patients who fail to respond to PDE5 inhibitors and prostaglandin-based therapies.

10:12

A 29-year-old woman presents to her general practitioner (GP) complaining of tiredness, lethargy, headaches and tremor. She received a renal transplant one year earlier and takes a ciclosporin-based immunosuppression regime.

One week prior to her visit to the GP she had been started on a prolonged course of fluconazole by a locum doctor in an attempt to clear up a long-standing fungal infection.

Investigations:

Haemoglobin (Hb)	9.2 g/dl
White cell count (WCC)	2.3×10^9/l
Platelet (PLT)	79×10^9/l
Sodium (Na^+)	139 mmol/l
Potassium (K^+)	4.5 mmol/l
Creatinine (Cr)	230 μmol/l

You suspect a probable drug interaction.

Which of the following is the most likely cause of her problems?

A Decreased fluconazole excretion

B Decreased ciclosporin excretion

C CYP450 induction leading to increased ciclosporin metabolism

D CYP450 inhibition leading to decreased ciclosporin metabolism

E Increased formation of 6-mercaptopurine

Rana Alnasser's screen

D CYP450 inhibition leading to decreased ciclosporin metabolism

Fluconazole is a CYP-P450 enzyme inhibitor, leading to an elevation of 50% or more in levels of ciclosporin, which is specifically metabolised by CYP-3A4. If fluconazole treatment is required, then a temporary reduction in ciclosporin dose is usually advised, the peak in levels occurring from around day 4 of fluconazole treatment onwards. Symptoms of ciclosporin toxicity include tremor and headache, nausea, vomiting and abdominal pain. Raised creatinine, anaemia and thrombocytopenia are also seen. In this situation, ciclosporin levels are a crucial part of the work-up in diagnosing the underlying cause of any elevation in creatinine.

A Decreased fluconazole excretion

Approximately 80% of fluconazole is excreted unchanged in the urine; it isn't directly nephrotoxic and this isn't therefore the cause of the clinical picture seen here.

B Decreased ciclosporin excretion

Only 6% of the oral dose of ciclosporin is excreted unchanged in the urine. It is extensively metabolised by the P450 system in the liver, meaning that the cause of ciclosporin toxicity is decreased biotransformation rather than decreased excretion.

C CYP450 induction leading to increased ciclosporin metabolism

Fluconazole is an enzyme inhibitor, not an inducer of the P450 system.

elevation of 50% or more in levels of ciclosporin, which is specifically metabolised by CYP-3A4. If fluconazole treatment is required, then a temporary reduction in ciclosporin dose is usually advised, the peak in levels occurring from around day 4 of fluconazole treatment onwards. Symptoms of ciclosporin toxicity include tremor and headache, nausea, vomiting and abdominal pain. Raised creatinine, anaemia and thrombocytopenia are also seen. In this situation, ciclosporin levels are a crucial part of the work-up in diagnosing the underlying cause of any elevation in creatinine.

A Decreased fluconazole excretion

Approximately 80% of fluconazole is excreted unchanged in the urine; it isn't directly nephrotoxic and this isn't therefore the cause of the clinical picture seen here.

B Decreased ciclosporin excretion

Only 6% of the oral dose of ciclosporin is excreted unchanged in the urine. It is extensively metabolised by the P450 system in the liver, meaning that the cause of ciclosporin toxicity is decreased biotransformation rather than decreased excretion.

C CYP450 induction leading to increased ciclosporin metabolism

Fluconazole is an enzyme inhibitor, not an inducer of the P450 system.

E Increased formation of 6-mercaptopurine

6-mercaptopurine is a metabolite of azathioprine responsible for azathioprine toxicity when it accumulates to excess; it isn't connected with ciclosporin metabolism.

10:14

A 45-year-old civil engineer is brought to the Emergency Department with a decreased level of consciousness and slurred speech. His past medical history includes a diagnosis of bipolar affective disorder, which has remained quiescent of late due to his regular medications.

Two weeks previously, he had developed a painful left knee, and had taken ibuprofen regularly since. His blood pressure is 122/82, pulse is 85 and regular. His Glasgow Coma Scale (GCS) score is 13. Bloods on admission reveal an elevated sodium of 148 mmol/l, creatinine of 152 μmol/l and a lithium level of 4.8.

Which of the following is the most appropriate intervention?

A	Multiple-dose activated charcoal
B	Forced alkaline diuresis
C	Haemodialysis
D	Flumazenil
E	Sodium bicarbonate

Submit

Previous Q... Skip Questi...

Rana Alnasser's screen

A 45-year-old civil engineer is brought to the Emergency Department with a decreased level of consciousness and slurred speech. His past medical history includes a diagnosis of bipolar affective disorder, which has remained quiescent of late due to his regular medications.

Two weeks previously, he had developed a painful left knee, and had taken ibuprofen regularly since. His blood pressure is 122/82, pulse is 85 and regular. His Glasgow Coma Scale (GCS) score is 13. Bloods on admission reveal an elevated sodium of 148 mmol/l, creatinine of 152 μmol/l and a lithium level of 4.8.

Which of the following is the most appropriate intervention?

Your answer was correct

A Multiple-dose activated charcoal

B Forced alkaline diuresis

C Haemodialysis

D Flumazenil

E Sodium bicarbonate

Explanation

C Haemodialysis

Lithium (usually given in the carbonate form) is prescribed for the prophylaxis and treatment of mania, bipolar

C Haemodialysis

Lithium (usually given in the carbonate form) is prescribed for the prophylaxis and treatment of mania, bipolar affective disorder and occasionally unipolar depression. It has a narrow therapeutic ratio, and therefore careful therapeutic drug monitoring is mandatory. Toxicity may be precipitated by sodium depletion, and therefore diuretics should be avoided. Non-steroidal anti-inflammatory drugs (NSAIDs) impair the renal excretion of lithium, also leading to potential toxicity. In this case, with a lithium level of 4.8, potentially severe toxicity is indicated. The treatment is therefore haemodialysis, which may be repeated as blood levels of lithium can re-bound due to widespread tissue distribution.

A Multiple-dose activated charcoal

There is no evidence that activated charcoal is effective at adsorbing lithium. Gastric lavage may be considered within the first hour of a potential overdose.

B Forced alkaline diuresis

This was formerly indicated in aspirin overdose, although it's now not used because of the risk of exacerbating pulmonary oedema.

D Flumazenil

Flumazenil is used as a reversal agent for patients with acute benzodiazepine overdose associated with short-term use.

E Sodium bicarbonate

Sodium bicarbonate is indicated for the treatment of

10:17

MyPastest
https://mypastest.pastest.com

Pastest+

A 58-year-old man currently receiving warfarin therapy for a deep vein thrombosis (DVT) presents for review. He has a past medical history of chronic obstructive pulmonary disease (COPD) and an inferior myocardial infarction some four years earlier. There is also a history of multiple previous urinary tract infection (UTI). He is concerned about how co-medications and eating could impact on his international normalised ratio (INR).

Which of the following does he need to be most concerned about while taking warfarin with respect to increased INR?

A	Cranberry juice
B	Grapefruit juice
C	Prednisolone
D	Amoxicillin
E	Amitriptyline

32797

Submit

Previous Q...

Skip Questi...

A Cranberry juice

It is p450 inhibitors that cause most concern when co-prescribed with warfarin, and cranberry juice is specifically recognised to inhibit CYP2C9, which is the main route for warfarin metabolism.

B Grapefruit juice

Grapefruit juice is an inhibitor of CYP3A4, and as such the major interactions for grapefruit juice are with agents such as simvastatin and ciclosporin.

C Prednisolone

Prednisolone is a hepatic enzyme inducer, and is likely therefore to reduce rather than increase INR.

D Amoxicillin

With respect to warfarin and antibiotics, ciprofloxacin and clarithromycin carry the most significant interaction risk because of P450 inhibition, although other antibiotics may also have more minor effects on INR because of modification of gut flora.

E Amitriptyline

This is recognised to have only minor effects on INR.

Rate this question:

Next Question

A 34-year-old woman has been admitted from clinic with severe rheumatoid arthritis (RA). She has symptoms of persistent synovitis, despite taking high-dose weekly methotrexate, non-steroidal anti-inflammatories and low-dose prednisolone. The consultant has discussed pros and cons of starting biological therapy.

What of the following criteria would rule out infliximab as an option for this patient?

A Coexistent psoriasis

B Coexistent multiple sclerosis

C Asthma

D Gout

E Glaucoma

Submit

© Pastest 2019

10:18
594-042-7551 Leave

A 34-year-old woman has been admitted from clinic with severe rheumatoid arthritis (RA). She has symptoms of persistent synovitis, despite taking high-dose weekly methotrexate, non-steroidal anti-inflammatories and low-dose prednisolone. The consultant has discussed pros and cons of starting biological therapy.

What of the following criteria would rule out infliximab as an option for this patient?

Your answer was correct

A Coexistent psoriasis

B Coexistent multiple sclerosis

C Asthma

D Gout

E Glaucoma

A
B
C
D
E
0

Res
Res
Res
Res

Explanation

B Coexistent multiple sclerosis

Evidence from intervention trials with anti-TNF agents in inflammatory bowel disease and arthritis have suggested increased risk of new demyelinating diseases in patients prescribed them. The mechanism as to why this happens is unclear, as it is not consistently reflected in animal models of multiple sclerosis.

Other contraindications for anti-TNF agents include:

Audio Video Share Participants More

10:18
594-042-7551 Leave

B Coexistent multiple sclerosis

Evidence from intervention trials with anti-TNF agents in inflammatory bowel disease and arthritis have suggested increased risk of new demyelinating diseases in patients prescribed them. The mechanism as to why this happens is unclear, as it is not consistently reflected in animal models of multiple sclerosis.

Other contraindications for anti-TNF agents include:

- Active infection
- Pregnancy
- Breastfeeding
- New York Heart Association grade 3–4 heart failure
- Active tuberculosis (patients should also be screened for previous infection before starting therapy).

A Coexistent psoriasis

Psoriasis is a target disease for treatment with anti-TNF agents and data show a consistent improvement in symptoms associated with therapy.

C Asthma

Although TNF is not a target for patients suffering from asthma, anti-TNF agents do not worsen symptoms of asthma.

D Gout

Anti-inflammatory agents may impact on the acute phase of gout, although anti-IL1-based agents probably have the greatest positive effect rather than anti-TNF.

Audio Video Share Participants More

A Coexistent psoriasis

Psoriasis is a target disease for treatment with anti-TNF agents and data show a consistent improvement in symptoms associated with therapy.

C Asthma

Although TNF is not a target for patients suffering from asthma, anti-TNF agents do not worsen symptoms of asthma.

D Gout

Anti-inflammatory agents may impact on the acute phase of gout, although anti-IL1-based agents probably have the greatest positive effect rather than anti-TNF.

E Glaucoma

Anti-TNF agents have no negative effect on intra-ocular pressure or symptoms of glaucoma.

Rate this question:

Next Question

Previous Q... Tag Questi... Feedback End Session

© Pastest 2019

You review a 72-year-old woman with urinary tract infection (UTI). Microscopy, culture and sensitivity demonstrate *E. coli* sensitive to ciprofloxacin.

Which of the following correctly describes the mode of action of ciprofloxacin?

A	It is an inhibitor of folate synthesis
B	It is an inhibitor of bacterial cell wall synthesis
C	It interferes with the functioning of bacterial ribosomes
D	It is an inhibitor of DNA gyrase
E	It is an inhibitor of DNA polymerase

Submit

Previous Q... Skip Questi...

© Pastest 2019

10:19

You review a 72-year-old woman with urinary tract infection (UTI). Microscopy, culture and sensitivity demonstrate *E. coli* sensitive to ciprofloxacin.

Which of the following correctly describes the mode of action of ciprofloxacin?

Your answer was correct

A	It is an inhibitor of folate synthesis
B	It is an inhibitor of bacterial cell wall synthesis
C	It interferes with the functioning of bacterial ribosomes
D	It is an inhibitor of DNA gyrase
E	It is an inhibitor of DNA polymerase

A B C D E 0

Res Res Res Res

Explanation

D It is an inhibitor of DNA gyrase

The quinolones, of which ciprofloxacin is a member, are inhibitors of bacterial DNA gyrase. Gyrase drives super-coiling of the circular double-stranded DNA found in bacteria.

A It is an inhibitor of folate synthesis

Inhibitors of bacterial folate synthesis include

Rana Alnasser's screen

10:19

D It is an inhibitor of DNA gyrase

The quinolones, of which ciprofloxacin is a member, are inhibitors of bacterial DNA gyrase. Gyrase drives super-coiling of the circular double-stranded DNA found in bacteria.

A It is an inhibitor of folate synthesis

Inhibitors of bacterial folate synthesis include sulphonamides and trimethoprim. Patients taking bacterial folate inhibitors rarely become folate deficient, although use of trimethoprim in early pregnancy is not recommended.

B It is an inhibitor of bacterial cell wall synthesis

Inhibitors of bacterial cell wall synthesis include penicillins, cephalosporins and vancomycin.

C It interferes with the functioning of bacterial ribosomes

Inhibitors of bacterial ribosome function include aminoglycosides, erythromycin and tetracyclines. Tetracyclines are bacteriostatic and hence may actually reduce the effectiveness of bactericidal antibiotics such as penicillins when used in combination.

E It is an inhibitor of DNA polymerase

Nalidixic acid is an example of an inhibitor of bacterial DNA polymerase.

Rate this question:

Rana Alnasser's screen

10:20

A 76-year-old woman with known vascular dementia is sent in to A&E by nursing home staff with a 2-day history of fever, reduced mobility and drowsiness. Four days earlier she was seen by the on-call GP as she had been agitated and hallucinating. He started her on haloperidol for this.

In A&E her temperature is 39.4 °C. She is drowsy with a Glasgow Coma Scale (GCS) 12/15 (E3 V4 M5). She has a sinus tachycardia of 116 bpm. Blood pressure is 112/56 mmHg and heart sounds are normal. Her chest is clear and her abdomen is soft and non-tender, with normal bowel sounds. Neurological examination reveals generalised hypertonia, but normal power and reflexes.

Investigations are as follows:

WBC	8.1×10^9/l
Hb	12.4 g/dl
MCV	82.4 fl
PLT	224×10^9/l
Na^+	136 mmol/l
K^+	5.4 mmol/l
Urea	9.6 mmol/l
Creatinine	167 µmol/l
Bilirubin	14 µmol/l
Aalanine aminotransferase (ALT)	35 U/l
Alkaline phosphatase	124 U/l
Albumin	38 g/l
ECG	Sinus tachycardia
Chest X-ray	Normal cardiac silhouette, no

Rana Alnasser's screen

MCV	82.4 fl
PLT	224 ×10⁹/l
Na^+	136 mmol/l
K^+	5.4 mmol/l
Urea	9.6 mmol/l
Creatinine	167 µmol/l
Bilirubin	14 µmol/l
Aalanine aminotransferase (ALT)	35 U/l
Alkaline phosphatase	124 U/l
Albumin	38 g/l
ECG	Sinus tachycardia
Chest X-ray	Normal cardiac silhouette, no focal consolidation

What of the following treatments is most important?

A Give IV antibiotics

B Give SC bromocriptine

C Give IV phenytoin

D Give IV naloxone

E Give IV flumazenil

B Give SC bromocriptine

This patient has neuroleptic malignant syndrome precipitated by the administration of haloperidol. Clinical features of neuroleptic malignant syndrome include:

- Muscular rigidity (sometimes with dysphagia and dysarthria)
- Extrapyramidal signs, tremor
- Catatonia/muteness
- Increased serum creatinine phosphokinase (CPK)/aspartate aminotransferase (AST)
- Pyrexia .

Other causative agents include phenothiazines, loxapine, thioxanthenes, metoclopramide and tetrabenazine. The syndrome can occur within hours of initiating drug therapy, but typically takes about 1 week. Complications include rhabdomyolysis, renal and hepatic failure, cardiovascular collapse, disseminated intravascular coagulation (DIC), and respiratory failure. Mortality is ~10%.

Treatment involves withdrawal of the causative agent, IV fluids, cooling measures and bromocriptine. Whilst dantrolene sodium was formerly recommended as monotherapy, case series suggest that when it is used in the absence of bromocriptine, mortality may actually be increased.

A Give IV antibiotics

The proximity to prescription of haloperidol and the normal white blood cell count are stronger pointers towards neuroleptic malignant syndrome rather than an acute infection.

C Give IV phenytoin

Rana Alnasser's screen

monotherapy, case series suggest that when it is used in the absence of bromocriptine, mortality may actually be increased.

A Give IV antibiotics

The proximity to prescription of haloperidol and the normal white blood cell count are stronger pointers towards neuroleptic malignant syndrome rather than an acute infection.

C Give IV phenytoin

The decreased consciousness and confusion seen here is unlikely to represent epilepsy in the absence of other features to suggest seizure activity.

D Give IV naloxone

Naloxone is utilised as the reversal agent for opiate overdose.

E Give IV flumazenil

IV flumazenil is used as a reversal agent for acute benzodiazepine overdose.

Rate this question:

Rana Alnasser's screen

10:22

A 32-year-old arable farmer is brought to A&E one evening having become increasingly confused over the previous 5 h. He had been feeling well at breakfast time before going out to work in the fields, but staggered into the house in the late afternoon complaining of nausea and vomiting, and feeling generally weak. He now has profuse diarrhoea with associated abdominal cramps.

On examination, he is diaphoretic and salivating profusely. He is disorientated regarding time, place and person. His pupils are equal and constricted. His temperature is 36.9 °C. His heart rate is 54 bpm, regular, jugular venous pressure (JVP) is not seen and blood pressure (BP) is 102/54 mmHg. Heart sounds are normal.

Respiratory examination reveals bilateral expiratory wheeze, but no crepitations. His oxygen saturations are 92% on air. His abdomen is soft and diffusely tender, but there is no guarding or rebound tenderness. Bowel sounds are present. Power is globally reduced in all four limbs (grade 4/5), with slightly depressed reflexes, but plantar response is flexor. A few fasciculations are noted in his legs. His coordination and sensation are unimpaired.

What is the likely diagnosis?

A	Botulism
B	Guillain–Barré syndrome
C	Organophosphate poisoning
D	Tetanus
E	Belladonna poisoning

Rana Alnasser's screen

10:28

MyPastest
https://mypastest.pastest.com

C Organophosphate poisoning

Organophosphate insecticides inhibit the enzyme acetylcholinesterase, allowing accumulation of excessive acetylcholine (ACh) at muscarinic and nicotinic receptors, and in the CNS. Signs and symptoms of acute organophosphate poisoning may occur within 1–2 h of exposure, but may also be delayed, especially after skin exposure. Sudden deterioration can occur in a patient with few initial symptoms.

Clinical manifestations may be classified into muscarinic, nicotinic and CNS effects, as follows:

Muscarinic: vomiting, diarrhoea, abdominal cramping, bronchospasm, miosis, bradycardia, excessive salivation and sweating. Severe diaphoresis can lead to dehydration with systemic hypovolaemia, resulting in shock.

Nicotinic: muscle fasciculations, tremor and weakness. Death is usually caused by respiratory muscle paralysis.

BP and pulse may be decreased due to muscarinic effects, or increased due to nicotinic effects.

CNS poisoning: agitation, seizures, coma.

Treatment is with supportive measures, which may include intubation and ventilation. Decontamination of skin and clothes, and reduction of enteral absorption with activated charcoal may be indicated. Intravenous (iv) atropine may reverse the muscarinic effects but not the nicotinic effects. Pralidoxime is a specific antidote that acts to regenerate the enzyme activity at all affected sites.

A Botulism

Botulism begins with CNS symptoms including blurred vision, difficulty in speaking and swallowing. Diarrhoea and

10:28

Pralidoxime is a specific antidote that acts to regenerate the enzyme activity at all affected sites.

A Botulism

Botulism begins with CNS symptoms including blurred vision, difficulty in speaking and swallowing. Diarrhoea and vomiting may be seen but are not necessarily a prominent feature, and there is a descending flaccid paralysis.

B Guillain–Barré syndrome

Guillain–Barré presents with gradually progressive ascending weakness, rather than the rapid onset of both CNS and PNS symptoms over a number of hours.

D Tetanus

Tetanus is associated with a pattern of descending upper motor neurone weakness, rather than the lower motor neurone symptoms seen here, accompanied by signs and symptoms of autonomic nervous system dysfunction.

E Belladonna poisoning

Some symptoms of belladonna poisoning may overlap here, including sweating, tachycardia and blurred vision, although other symptoms such as constipation are not features of the presentation as reported here.

Rate this question:

A 28-year-old woman is admitted to the surgical unit with an acute abdomen and a provisional diagnosis of appendicitis. During induction of anaesthesia, she had some stiffness of the jaw muscles. However, she later relaxed and surgery was commenced.

Within a few minutes, however, the stiffness of jaw had increased significantly and her limbs also became stiff. The surgical procedure had to be abandoned. Her body temperature rose to 42 °C. Her pulse was 120/min and thread, and blood pressure fell to 80/50 mmHg. Arterial blood gases revealed pCO_2 of 8.0 kPa, pH 7.1 and HCO_3^- 28mmol/l.

What is the most likely diagnosis?

A	Serotonin syndrome
B	Tonic status epilepticus
C	Acute dystonic reaction
D	Malignant hyperthermia
E	Tardive dyskinesia

32860

Submit

Previous Q...

Skip Questi...

594-042-7551 Leave

A 28-year-old woman is admitted to the surgical unit with an acute abdomen and a provisional diagnosis of appendicitis. During induction of anaesthesia, she had some stiffness of the jaw muscles. However, she later relaxed and surgery was commenced.

Within a few minutes, however, the stiffness of jaw had increased significantly and her limbs also became stiff. The surgical procedure had to be abandoned. Her body temperature rose to 42 °C. Her pulse was 120/min and thread, and blood pressure fell to 80/50 mmHg. Arterial blood gases revealed pCO_2 of 8.0 kPa, pH 7.1 and HCO_3^- 28mmol/l.

What is the most likely diagnosis?

Your answer was correct

A	Serotonin syndrome
B	Tonic status epilepticus
C	Acute dystonic reaction
D	Malignant hyperthermia
E	Tardive dyskinesia

Explanation

D	Malignant hyperthermia

This is a dramatic situation observed during general anaesthesia in individuals who are susceptible. The patient develops progressively increasing muscular rigidity rather than muscular relaxation, as inhaled anaesthetics or succinylcholine are introduced. Although halothane was

Audio Video Share Participants More

10:29
594-042-7551
Leave

D Malignant hyperthermia

This is a dramatic situation observed during general anaesthesia in individuals who are susceptible. The patient develops progressively increasing muscular rigidity rather than muscular relaxation, as inhaled anaesthetics or succinylcholine are introduced. Although halothane was identified originally as a cause of malignant hyperthermia, it is also reported with more modern anaesthetics such as isoflurane. Temperature rises steadily up to 42–43 °C. Respiratory and heart rates escalate. Arterial $paCO_2$ increases and creatinine phosphokinase rises to extraordinary levels and spills into the urine. Circulatory collapse and death occur in 10% of patients.
Other members of the family may have collapsed or died during anaesthesia,and hence a family history gives a clue Some susceptible patients have musculoskeletal features such as stature, ptosis, strabismus, high arched palate or dislocated patellae; kyphoscoliosis has also been seen in some families (King–Denborough syndrome). Certain congenital myopathies also predispose to malignant hyperthermia. Treatment is to immediately switch from volatile anaesthetics at the first hint of masseter spasm or rise of body temperature to alternative agents such as propofol. Intravenous dantrolene can be given as a bolus, and the patient should be cooled and hydrated; acidosis should be corrected.

A Serotonin syndrome

Serotonin syndrome is associated with agitation, muscular rigidity and hyper-reflexia, but occurs in patients prescribed an SSRI.

B Tonic status epilepticus

Given that anaesthesia is the intervention of choice for epilepsy resistant to conventional agents, tonic status is

Audio Video Share Participants More

10:33

A 72-year-old man is admitted via ambulance. You attend as part of the crash team when initial observations reveal that he has a pulse rate of 35 bpm and blood pressure of 82/40 mmHg. He is in cardiac failure.

On initial survey, members of the casualty staff have discovered a note explaining that he has taken an overdos after the recent death of his wife. One of the nurses calls the GP and it transpires he is on a range of blood pressure medications. You give him 1 mg of atropine IV.

Which of the following interventions would be the next most appropriate step in his management?

A	IV glucagon administration
B	IV dopamine administration
C	IV adrenaline administration
D	Cardiac pacing
E	IV salbutamol administration

32793

Submit

Previous Q...

Skip Questi...

10:34
594-042-7551
Leave

A 72-year-old man is admitted via ambulance. You attend as part of the crash team when initial observations reveal that he has a pulse rate of 35 bpm and blood pressure of 82/40 mmHg. He is in cardiac failure.

On initial survey, members of the casualty staff have discovered a note explaining that he has taken an overdos after the recent death of his wife. One of the nurses calls the GP and it transpires he is on a range of blood pressure medications. You give him 1 mg of atropine IV.

Which of the following interventions would be the next most appropriate step in his management?

Your answer was correct

A	IV glucagon administration
B	IV dopamine administration
C	IV adrenaline administration
D	Cardiac pacing
E	IV salbutamol administration

Explanation

A	IV glucagon administration

Key initial measures for this patient include establishment of IV access, electrocardiogram (ECG) and blood pressure recording. Apart from that, IV glucagon administration exerts an inotropic effect independent of ß-receptor

Audio Video Share Participants More

10:35

Explanation

A	IV glucagon administration

Key initial measures for this patient include establishment of IV access, electrocardiogram (ECG) and blood pressure recording. Apart from that, IV glucagon administration exerts an inotropic effect independent of β-receptor activation by raising myocardial cAMP levels: 50–150 μg/k is usually given as a bolus, followed by infusion at 1–5 mg/h. If hypoglycaemia develops in response to possible β blocker overdose, then 25 ml of 50% dextrose followed by dextrose infusion is recommended in addition to IV glucagon.

B	IV dopamine administration

Dopamine is most commonly used as an inotrope to preserve renal perfusion rather than to increase heart rate in β-blocker overdose.

C	IV adrenaline administration

IV adrenaline is not recommended because of the risk of precipitating a ventricular arrhythmia.

D	Cardiac pacing

This is the option in the event that enough glucagon to deliver repeated high doses is not available.

E	IV salbutamol administration

IV salbutamol is of most use where there is bronchospasm associated with β-blocker overdose.

10:36

A 26-year-old patient is admitted drowsy and confused. History from her friends reveals a past history of depression and previous suicide attempts. She was found with an empty bottle of phenobarbital, which she apparently obtained on the internet.

Examination reveals slurred speech, ataxia and nystagmus

What therapy will best aid elimination of phenobarbital?

A	Sodium bicarbonate
B	Ammonium chloride
C	Succinylated gelatine
D	Dicobalt edetate
E	Mannitol

7053

Submit

Previous Q... Skip Questi...

Blog About Pastest Contact Us Help

© Pastest 2019

10:38

Explanation

A Sodium bicarbonate

The barbiturates have largely been replaced by the benzodiazepines, but they are still used for induction anaesthesia and for patients with epilepsy resistant to conventional therapies. Barbiturate overdose causes drowsiness, respiratory depression, impaired coordination and coma. They are inducers of hepatic enzymes. As a dru they are acidic, and elimination through the kidneys is aided by forced alkaline diuresis with sodium bicarbonate. Other treatments include charcoal and haemodialysis. Forced alkaline diuresis is not routinely recommended.

C Succinylated gelatine

Succinylated gelatine is used as a volume expander for patients with acute blood loss, and doesn't therefore have a key role here.

B Ammonium chloride

Forced acid diuresis with ammonium chloride can be helpful in amphetamine poisoning. It is not useful here.

D Dicobalt edetate

Dicobalt edetate has a role in the treatment of cyanide poisoning. It forms stable complexes with cyanide and therefore can significantly impact on symptoms of poisoning.

E Mannitol

Mannitol has a role in the treatment of cerebral oedema related to ciguatera poisoning (which can occur in relatior

Rana Alnasser's screen

10:41
594-042-7551
Leave

A 19-year-old woman presents with an infected human bit on her left arm. She says that she was involved in a fight three days ago while drunk.

On examination, there is a bite affecting the left upper arm which is discharging pus, and there is a 3 cm radius of erythema around the wound. She is pyrexial (37.8 °C).

Investigations:

Haemoglobin (Hb)	12.1 g/dl
White cell count (WCC)	13.1×10^9/l
Platelets (PLT)	201×10^9/l
Sodium (Na^+)	140 mmol/l
Potassium (K^+)	4.9 mmol/l
Creatinine (Cr)	110 µmol/l

Which of the following is the most appropriate choice for antibiotic therapy?

A Amoxicillin

B Pencillin V

C Co-amoxiclav

D Oxytetracycline

E Metronidazole

Submit
Audio Video Share Participants More

10:43

Explanation

C	Co-amoxiclav

Co-amoxiclav is the antibiotic therapy of choice for human bite wounds. It is crucial that beta-lactamase-producing Staphylococci are covered, and clavulanic acid makes sure of this. A standard course is the 625 mg TDS dose for a period of 5–7 days. It is also crucially important to make sure that the patient is covered for tetanus infection. Commonly isolated organisms include *Streptococcus*, *Staphylococcus*, *Haemophilus*, *Bacteroides* and *Eikenella corrodens*.

A	Amoxicillin

Amoxicillin fails to cover against beta-lactamase-producin organisms and therefore cannot be used here.

B	Pencillin V

Penicillin V only covers a limited range of mouth commensals, and doesn't have activity against a range of anaerobes that may cause significant wound infection.

D	Oxytetracycline

Tetracyclines may be used as a treatment for human bites but only in combination with metronidazole.

E	Metronidazole

Metronidazole alone does not provide adequate coverage and should be used in combination with either a tetracycline or clarithromycin.

10:43
594-042-7551
Leave

A 27-year-old teacher is brought to the Emergency Department having suffered a tonic–clonic seizure, which was abated with 10 mg of intravenous (iv) diazepam en route in the ambulance. She had been discovered by her boyfriend, who had found an empty tablet container next to her convulsing body. He knows that she has recently been attending the general practitioner (GP) for management of very painful, heavy periods. He has not thought to bring it with him, but thinks that it had been fu earlier that morning.

On examination, her blood pressure (BP) is 122/82 mmHg, with pulse 84/min and regular. Pupils are equal and reactive to light. Her respiratory rate is 18/min.

What is she most likely to have taken?

A	Paracetamol
B	Dihydrocodeine
C	Co-amoxiclav
D	Mefenamic acid
E	Amitriptyline

Submit

Previous Q... Skip Questi...

Audio Video Share Participants 1 More

boyfriend, who had found an empty tablet container next to her convulsing body. He knows that she has recently been attending the general practitioner (GP) for management of very painful, heavy periods. He has not thought to bring it with him, but thinks that it had been fu earlier that morning.

On examination, her blood pressure (BP) is 122/82 mmHg, with pulse 84/min and regular. Pupils are equal and reactive to light. Her respiratory rate is 18/min.

What is she most likely to have taken?

Your answer was correct

A	Paracetamol
B	Dihydrocodeine
C	Co-amoxiclav
D	Mefenamic acid
E	Amitriptyline

Explanation

D	Mefenamic acid

Mefenamic acid (Ponstan™) is often prescribed in general practice for relief of pain and bleeding associated with menstruation. It has a relatively narrow therapeutic window, and overdoses have led to significant neurologica impairment when as little as 3 g is exceeded. These symptoms include drowsiness, headaches, seizures and, in some cases, coma. Activated charcoal, when used early, is potentially of benefit

10:47

Explanation

D	Mefenamic acid

Mefenamic acid (Ponstan™) is often prescribed in general practice for relief of pain and bleeding associated with menstruation. It has a relatively narrow therapeutic window, and overdoses have led to significant neurologica impairment when as little as 3 g is exceeded. These symptoms include drowsiness, headaches, seizures and, in some cases, coma. Activated charcoal, when used early, is potentially of benefit.

A	Paracetamol

Paracetamol is associated with a late deterioration in cognitive function related to hepatorenal syndrome (HRS) early neurological deterioration including seizures would not be expected.

B	Dihydrocodeine

Dihydrocodeine is associated with decreased consciousness and respiratory depression rather than seizures. Naloxone is the main reversal agent.

C	Co-amoxiclav

Penicillins are relatively safe in overdose, and risks of overdose are not significantly increased by the presence o clavulanic acid.

E	Amitriptyline

Amitriptyline is associated with seizures in overdose, although there is no suggestion as to how this patient would have gained access to the anti-depressant.

10:49

A 34-year-old man is admitted to the Emergency Department after being found by his estranged wife having drunk a quantity of paraquat and ingested an unknown quantity of codeine phosphate tablets. It is thought that he took the overdose some 3 h previously.

On examination in the department, his blood pressure (BP) is 112/74 mmHg, pulse is 74/min and regular and he is drowsy due to having taken the codeine phosphate tablets.

Which one of the following is an important step in the management of paraquat overdose?

A	15 ml/kg of Fuller's Earth
B	Dexamethasone IV
C	Cyclophosphamide IV
D	Oral- activated charcoal
E	N-Aacetylcysteine IV

Submit

Previous Q... Skip Questi...

Blog About Pastest Contact Us Help

Rana Alnasser's screen

10:50

A	15 ml/kg of Fuller's Earth

Fuller's earth is the preferred absorptive substance to be administered post-paraquat ingestion, at a dose of 15 ml/kg; if it is not available, then 2 g/kg of charcoal is an alternative. Plasma levels of paraquat >0.1 mg/l at 24 h are associated with a poor prognosis; ingestion of >10 g is associated with a mortality of 100%. Death has been associated with as little as 3 g of ingested paraquat. The cause of death is usually progressive pulmonary fibrosis, which begins during the second week after ingestion. Often the oliguric kidney disease seen with paraquat, which develops within 12 h of ingestion, is beginning to resolve at this stage.

B	Dexamethasone IV

Modest benefits only were seen for dexamethasone IV in a retrospective case series analysis. It may be more useful when combined with haemoperfusion.

C	Cyclophosphamide IV

There is no evidence to support the use of cyclophosphamide in paraquat poisoning. It is of course used as an induction immunosuppressive agent across a range of inflammatory conditions.

D	Oral- activated charcoal

2 g/kg of activated charcoal is an alternative to Fuller's earth if this is unavailable.

E	N-Aacetylcysteine IV

Although N-acetylcysteine has a role as an anti-oxidant

10:53

fuller earth

ALL SHOPPING IMAGES NEWS MAPS VIDEOS BOOKS FLIGHTS

Fuller's earth
Pharmaceutical

Fuller's earth is any clay material that has the capability to decolorize oil or other liquids with treatment. Fuller's earth typically consists of palygorskite or bentonite. Modern uses of fuller absorbents for oil, grease, and animal waste and as a carrier for pesticides and fertilizers. W

PEOPLE ALSO SEARCH FOR

Clay

Coal

Iron ore

Dolomite

PEOPLE ALSO ASK

What is fuller's earth powder used for?

Can fuller earth be used daily?

Is bentonite clay the same as Fullers Earth?

Discover Updates Search Recent

A 68-year-old man is seen in clinic because of increasing orthopnoea and exertional dyspnoea. He has a past medical history of atrial fibrillation, diabetes, hypertension and congestive cardiac failure. He tells you that his heart failure is so severe that he is barely able to climb one flight of stairs to bed.

On examination, he is noted to have gynaecomastia. His blood pressure is 115/72 mmHg, pulse is 72 bpm, atrial fibrillation, and there are bibasal crackles on auscultation of the chest and mild ankle swelling.

Investigations:

Hb	12.3 g/dl
WCC	8.1×10^9/l
PLT	192×10^9/l
Na^+	135 mmol/l
K^+	5.3 mmol/l
Creatinine	42 µmol/l

Which one of his current medications is most likely to be implicated in causing the gynaecomastia?

A	Furosemide
B	Ramipril
C	Carvedilol
D	Spironolactone
E	Simvastatin

10:55

A	Furosemide
B	Ramipril
C	Carvedilol
D	Spironolactone
E	Simvastatin

Explanation

D	Spironolactone

Spironolactone is well recognised as a cause of gynaecomastia. This is likely to be due to its action as an anti-androgen. This property is not shared by eplerenone, and in patients suffering from troublesome gynaecomastia, medication switching can resolve the problem.

A	Furosemide

Loop diuretics are not associated with increased risk of gynaecomastia.

B	Ramipril

Captopril and some calcium antagonists, not ramipril, are associated with increased risk of gynaecomastia.

C	Carvedilol

Beta-blockers are not thought to be associated with significant risk of gynaecomastia, although some case

10:55

anti-androgen. This property is not shared by eplerenone, and in patients suffering from troublesome gynaecomastia, medication switching can resolve the problem.

A Furosemide

Loop diuretics are not associated with increased risk of gynaecomastia.

B Ramipril

Captopril and some calcium antagonists, not ramipril, are associated with increased risk of gynaecomastia.

C Carvedilol

Beta-blockers are not thought to be associated with significant risk of gynaecomastia, although some case reports of an association with nebivulol, where symptoms resolved after medication discontinuation, have been described.

E Simvastatin

Simvastatin is rarely associated with gynaecomastia, but the frequency of reports of gynaecomastia are less than that for spironolactone; the mechanism is unclear.

Rate this question:

Next Question

Previous Q... Tag Questi... Feedback End Session

A 38-year-old man presents with a 6-week history of feeling unwell and very lethargic. He is a known hypertensive. His wife tells you he has been rather stressed at work recently and is drinking fairly heavily.

As a child, he was found to have an abnormality in the structure of his heart though she is not sure what this is, but she does know that he has had problems with palpitations.

In Accident and Emergency, he has two generalised tonic-clonic seizures, which are treated with intravenous lorazepam.

Investigations:

Hb	13.4 g/dl
WCC	12×10^9/l
PLT	122×10^9/l
Neutrophils	8.4×10^9/l
Bilirubin	44 µmol/l (3–17)
Cholesterol	6.0 mmol/l
ALP	647 U/l (30–300)
ALT	110 U/l (5–35)
GGT	540 U/l (11–51)
CRP	84 µg/l (< 2)
TP	50 g/l (60–80)
INR	1.4
Albumin	28 g/l (35–50)

Which of the following drugs is the best choice for the long-term treatment of his seizures?

10:56
594-042-7551 Leave

ALT	110 U/l (5–35)
GGT	540 U/l (11–51)
CRP	84 µg/l (< 2)
TP	50 g/l (60–80)
INR	1.4
Albumin	28 g/l (35–50)

Which of the following drugs is the best choice for the long-term treatment of his seizures?

A	Sodium valproate
B	Lamotrigine
C	Gabapentin
D	Vigabatrin
E	Carbamazepine

Submit

Previous Q... Skip Questi...

Blog About Pastest Contact Us Help
© Pastest 2019
Audio Video Share Participants More

10:58

B Lamotrigine

The most important intervention is for this patient to stop drinking, although this should take place under cover of a reducing course of benzodiazepines. Lamotrigine is an appropriate first-line intervention for seizures: it has the advantage of not being a CYP450 enzyme inducer or inhibitor, and has data suggesting it may reduce long-term alcohol dependence.

C Gabapentin

Gabapentin is a normal adjunctive therapy for patients with persistent seizures despite starting a first-line agent; as such, it's not the appropriate choice here.

A Sodium valproate

Sodium valproate should not be used in patients with hepatic dysfunction, because it is a CYP450 inhibitor.

D Vigabatrin

Vigabatrin is associated with peripheral visual field defects in up to 1/3 of users. It is also associated with suicidal ideation, and is therefore not an ideal option in a patient with alcoholism.

E Carbamazepine

Carbamazepine is a potent CYP450 enzyme inducer, and it may also be associated with AV conduction defects and is therefore not ideal in a patient with congenital heart disease.

Rate this question:

A 36-year-old man is seen in Chest Clinic for follow up of his pulmonary tuberculosis (TB). He was diagnosed with pulmonary TB 3 months earlier when he presented to A&E with anorexia, sweats, weight loss and haemoptysis. Sputum microscopy showed acid-fast bacilli, and a few weeks later *Mycobacterium tuberculosis* was cultured. He was started on therapy with rifampicin, isoniazid, pyridoxine and ethambutol, with an improvement in his symptoms. His past medical history includes hypertension, hypercholesterolaemia and epilepsy. The epilepsy is now controlled on sodium valproate. His other regular medications include simvastatin, bendroflumethiazide and atenolol. There is also a history of occasional NSAID use for joint pains. He is a non-smoker and does not drink alcohol. He recently started working as a landscape gardener.

When reviewed in the Chest Clinic the patient is noted to have a malar rash across his face.

His GP had sent off an autoantibody screen, which was as follows:

RF	Negative
ANA	Negative
Anti-dsDNA	Negative
Anti-sm antibodies	Negative
Anti-histone antibodies	Positive

Which one of the following medications is most likely to have caused his rash?

A	Simvastatin
B	Ethambutol

weeks later *Mycobacterium tuberculosis* was cultured. He was started on therapy with rifampicin, isoniazid, pyridoxine and ethambutol, with an improvement in his symptoms. His past medical history includes hypertension, hypercholesterolaemia and epilepsy. The epilepsy is now controlled on sodium valproate. His other regular medications include simvastatin, bendroflumethiazide and atenolol. There is also a history of occasional NSAID use for joint pains. He is a non-smoker and does not drink alcohol. He recently started working as a landscape gardener.

When reviewed in the Chest Clinic the patient is noted to have a malar rash across his face.

His GP had sent off an autoantibody screen, which was as follows:

RF	Negative
ANA	Negative
Anti-dsDNA	Negative
Anti-sm antibodies	Negative
Anti-histone antibodies	Positive

Which one of the following medications is most likely to have caused his rash?

A	Simvastatin
B	Ethambutol
C	Isoniazid
D	Pyridoxine
E	Bendroflumethiazide

11:01
594-042-7551 Leave

C Isoniazid

A number of drugs have been shown to cause drug-induced lupus, the most common of which are hydralazine, procainamide, primidone, isoniazid, phenytoin and chlorpromazine. Drug-induced lupus is usually associated with positive anti-histone antibodies. However, compared with idiopathic systemic lupus erythematosus (SLE), there is no female preponderance, renal and CNS involvement is uncommon, and anti-dsDNA & anti-sm antibodies are generally absent. Most cases of drug-induced lupus resolve on withdrawal of the causative agent. Patients with the HLA-DR3 antigen appear to be particularly at risk of developing drug-induced lupus.

A Simvastatin

Simvastatin is associated with the development of eczema, purpuric drug reactions and pustular folliculitis, rather than drug-induced lupus.

B Ethambutol

The main concern of ethambutol therapy is the development of optic neuritis.

D Pyridoxine

Pyridoxine is given with isoniazid to prevent isoniazid induced neuropathy due to pyridoxine deficiency.

E Bendroflumethiazide

Bendroflumethiazide is associated with exfoliative dermatitis rather than with drug-induced lupus.

32788
Rate this question:
Audio Video Share Participants 1 More

A 25-year-old man is admitted from the Accident and Emergency Department with increasing confusion over the past few weeks. He works as a demolition expert. He had recently attended his general practitioner (GP) with increasing headaches, hypersomnolence and abdominal pains.

Examination reveals pale conjunctivae and blue lines on his gums. No focal neurology, and abdominal examination is unremarkable.

Investigations:

Haemoglobin	10.2 g/dl
White cell count	9.8×10^9/l
Platelets	156×10^9/l
Mean cell volume (MCV)	79 fl
Lead level	61 µg/dl (< 10 µg/dl)

What is the best initial treatment?

A Dimercaptosuccinic acid

B Desferrioxamine

C Haemodialysis

D N-acetylcysteine

E Plasma exchange

5493

Submit

A 25-year-old man is admitted from the Accident and Emergency Department with increasing confusion over the past few weeks. He works as a demolition expert. He had recently attended his general practitioner (GP) with increasing headaches, hypersomnolence and abdominal pains.

Examination reveals pale conjunctivae and blue lines on his gums. No focal neurology, and abdominal examination is unremarkable.

Investigations:

Haemoglobin	10.2 g/dl
White cell count	9.8×10^9/l
Platelets	156×10^9/l
Mean cell volume (MCV)	79 fl
Lead level	61 µg/dl (< 10 µg/dl)

What is the best initial treatment?

Your answer was correct

A Dimercaptosuccinic acid

B Desferrioxamine

C Haemodialysis

D N-acetylcysteine

E Plasma exchange

Explanation

11:03

A	Dimercaptosuccinic acid

Lead poisoning occurs mainly in children and presents mainly in those adults with an occupational exposure risk. The heavy metal affects many enzymes including those involved in the production of haem. The symptoms are varied and patients can have abdominal pains, headaches, confusion, peripheral motor neuropathy and lethargy. Examination may reveal lead lines on the gums or signs consistent with anaemia. A plasma lead level confirms the diagnosis and chelation therapy can be achieved by dimercaptosuccinic acid (DMSA) or calcium disodium edetate. After treatment a cause must be found to prevent re-exposure when discharged.

B	Desferrioxamine

Desferrioxamine is a chelating agent primarily used in the treatment of iron toxicity.

C	Haemodialysis

In this context, with chronic lead poisoning, chelation therapy with DMSA or calcium disodium edetate is the most appropriate intervention.

D	N-acetylcysteine

N-acetylcysteine is used in the treatment of paracetamol overdose, and may have a role for some patients in the management of hepatic encephalopathy.

E	Plasma exchange

Plasma exchange is of most utility in the management of antibody mediated conditions.

11:03

A 25-year-old hairdresser is brought in via ambulance to the Emergency Department, and you have been asked to attend. She has ingested an unknown quantity of her father's dothiepin tablets in the previous few hours.

She has a Glasgow Coma Score (GCS) of 9 with dilated pupils, has a heart rate of 95 beats/min and a blood pressure of 110/65 mmHg. Her finger-prick blood glucose is 5.6 mmol/l. You are given a copy of her electrocardiogram (ECG), which shows broadening of the QRS complexes.

Which of the following is the most appropriate intervention?

A	Intravenous (iv) Glucagon 5 mg
B	iv Naloxone 800 mcg
C	iv Sodium bicarbonate 50 mmol
D	iv Flumazenil 200 mcg
E	iv Calcium chloride 10 ml of 10% solution

7565

Submit

Previous Q...

Skip Questi...

11:05

A 25-year-old hairdresser is brought in via ambulance to the Emergency Department, and you have been asked to attend. She has ingested an unknown quantity of her father's dothiepin tablets in the previous few hours.

She has a Glasgow Coma Score (GCS) of 9 with dilated pupils, has a heart rate of 95 beats/min and a blood pressure of 110/65 mmHg. Her finger-prick blood glucose is 5.6 mmol/l. You are given a copy of her electrocardiogram (ECG), which shows broadening of the QRS complexes.

Which of the following is the most appropriate intervention?

Your answer was correct

A Intravenous (iv) Glucagon 5 mg

B iv Naloxone 800 mcg

C iv Sodium bicarbonate 50 mmol

D iv Flumazenil 200 mcg

E iv Calcium chloride 10 ml of 10% solution

Explanation

C iv Sodium bicarbonate 50 mmol

Rana Alnasser's screen

11:05

Explanation

C	iv Sodium bicarbonate 50 mmol

QRS widening is a bad prognostic sign in patients who have taken a tricyclic antidepressant (TCA) overdose. Once QRS is greater than 100 ms, the risk of seizures and ventricular arrhythmias rises significantly and IV sodium bicarbonate is the intervention of choice. It works by reducing TCA binding to the myocardium.

A	Intravenous (iv) Glucagon 5 mg

High-dose glucagon, where available, is an intervention for beta blocker overdose, because it exerts a beta blocker-independent effect on increasing both heart rate and contractility.

B	iv Naloxone 800 mcg

Naloxone is a reversal agent for opiate overdose, and is a potential option for patients in peri-respiratory arrest who have suffered an iatrogenic opiate overdose or who are recreational users of heroin.

D	iv Flumazenil 200 mcg

Flumazenil is a reversal agent for benzodiazepine overdose. Use in patients who are habituated to benzodiazepines is, however, not recommended because rapid reversal may drive an increased risk of seizures.

E	iv Calcium chloride 10 ml of 10% solution

Calcium chloride is given for cardioprotection where there is significant hyperkalaemia.

A 22-year-old woman is admitted after taking an overdose of 30 × 300 mg aspirin tablets. She begins to suffer from severe tinnitus, feels light-headed and starts to vomit about 1 h after her overdose and attends the Emergency Department.

On examination, her blood pressure (BP) is 130/70 mmHg, her pulse is 85/min regular. She is very anxious and complains of a continuous ringing in her ears. Her respiratory rate is 36/min.

Which of the following sets of arterial blood gas results would fit best with her clinical picture?

A	pH 7.1; pCO_2 4.8 kPa; pO_2 7.1 kPa
B	pH 7.5; pCO_2 2.9 kPa; pO_2 12.1 kPa
C	pH 7.1; pCO_2 5.1 kPa; pO_2 13.1 kPa
D	pH 7.3; pCO_2 4.5 kPa; pO_2 12.1 kPa
E	pH 7.4; pCO_2 6.7 kPa; pO_2 8.1 kPa

Submit

Previous Q...

Skip Questi...

11:06

A 22-year-old woman is admitted after taking an overdose of 30 × 300 mg aspirin tablets. She begins to suffer from severe tinnitus, feels light-headed and starts to vomit about 1 h after her overdose and attends the Emergency Department.

On examination, her blood pressure (BP) is 130/70 mmHg, her pulse is 85/min regular. She is very anxious and complains of a continuous ringing in her ears. Her respiratory rate is 36/min.

Which of the following sets of arterial blood gas results would fit best with her clinical picture?

Your answer was correct

A	pH 7.1; pCO_2 4.8 kPa; pO_2 7.1 kPa
B	pH 7.5; pCO_2 2.9 kPa; pO_2 12.1 kPa
C	pH 7.1; pCO_2 5.1 kPa; pO_2 13.1 kPa
D	pH 7.3; pCO_2 4.5 kPa; pO_2 12.1 kPa
E	pH 7.4; pCO_2 6.7 kPa; pO_2 8.1 kPa

Explanation

B pH 7.5; pCO_2 2.9 kPa; pO_2 12.1 kPa

The early period of aspirin overdose is associated with respiratory alkalosis, as characterised by raised pH and hypocapnia. Late complications include encephalopathy and seizures, pancreatitis and acute kidney disease.

Rana Alnasser's screen

11:06

B	pH 7.5; pCO_2 2.9 kPa; pO_2 12.1 kPa

The early period of aspirin overdose is associated with respiratory alkalosis, as characterised by raised pH and hypocapnia. Late complications include encephalopathy and seizures, pancreatitis and acute kidney disease. Thankfully, however, the mortality rate associated with aspirin overdose is only around 1%. We are not given the results of other metabolic parameters, but given that the CO_2 values are low, the high pH represents respiratory alkalosis.

A	pH 7.1; pCO_2 4.8 kPa; pO_2 7.1 kPa

Given the CO_2 is in the normal range, the pH is consistent with a metabolic acidosis, which is seen only in the later stages of aspirin overdose.

C	pH 7.1; pCO_2 5.1 kPa; pO_2 13.1 kPa

Given the CO_2 is only 5.1, this blood gas result is also consistent with a metabolic acidosis, only seen in the later stages of aspirin overdose.

D	pH 7.3; pCO_2 4.5 kPa; pO_2 12.1 kPa

The pH is only slightly below the normal range at 7.3, and represents a metabolic acidosis given the CO_2 is 4.5.

E	pH 7.4; pCO_2 6.7 kPa; pO_2 8.1 kPa

The CO_2 is elevated here, meaning that the blood gas picture, including a normal pH, fits best with a compensated respiratory acidosis.

21218

Rate this question:

Rana Alnasser's screen

11:07

A 69-year-old woman had been referred from Medical Admissions to the Cardiology Ward after two episodes of syncope and palpitations.

She was admitted 3 days ago for cardioversion of her lone atrial fibrillation (AF). This had been successfully converted to sinus rhythm, and she was started on disopyramide 250 mg twice daily and discharged.

She has been readmitted today with palpitations; a standard 12-lead electrocardiogram (ECG) is shown below.

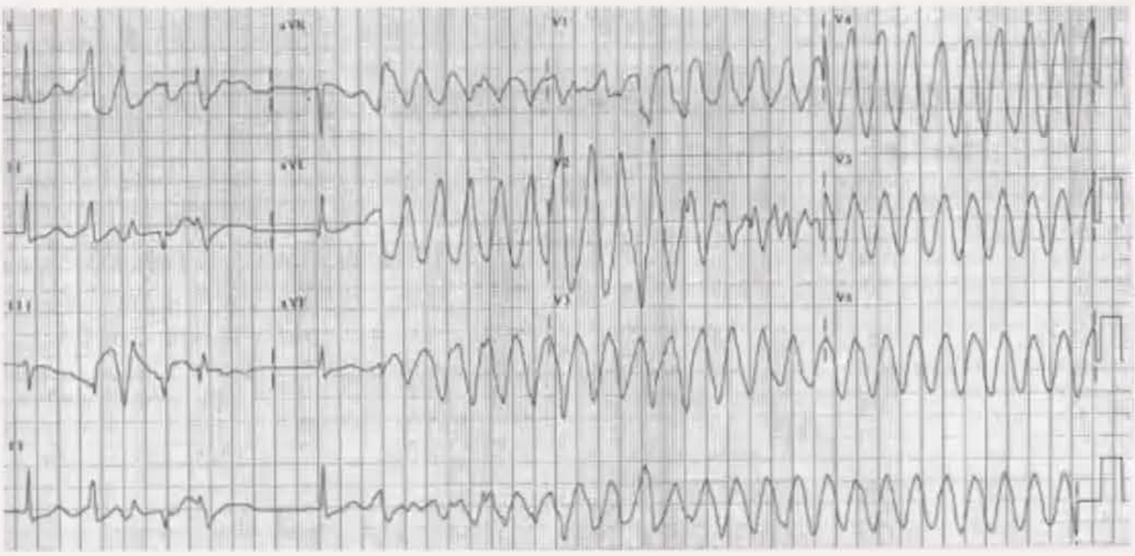

Following this, she was placed on telemetry, and an episode of palpitations was captured on the monitor. This is shown below.

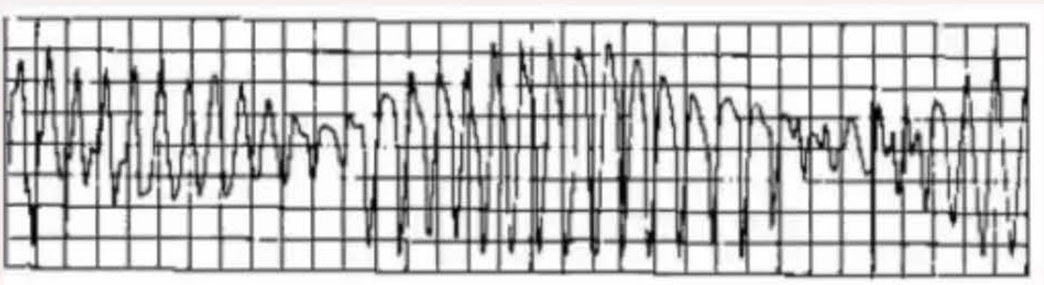

Her urea and electrolyte levels and full blood counts are within normal range.

What would be the most appropriate step in the immediate management of this patient?

A	Add in amiodarone

Rana Alnasser's screen

11:07

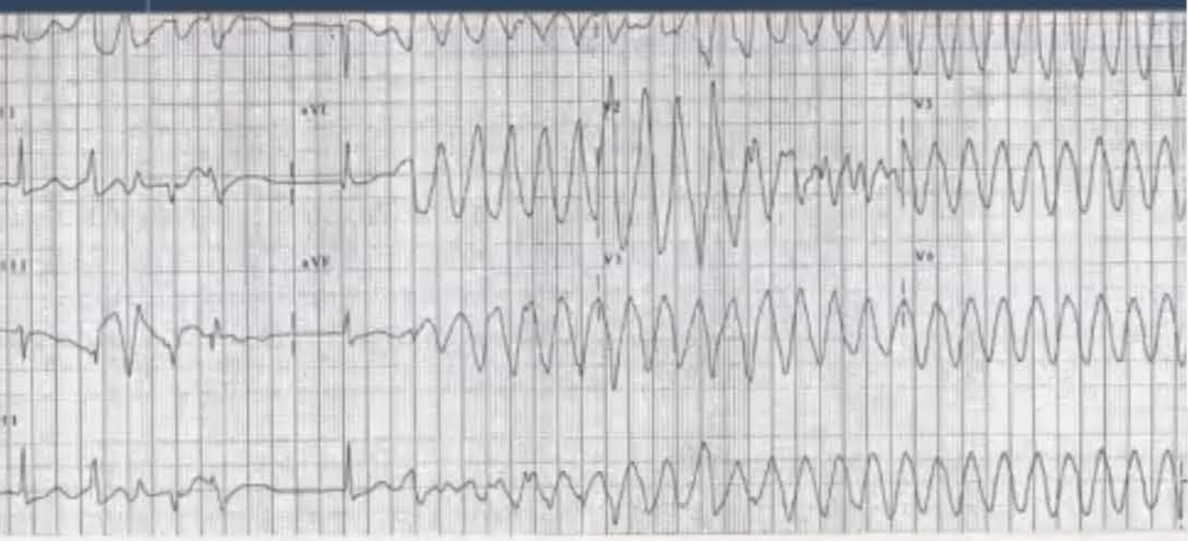

Following this, she was placed on telemetry, and an episode of palpitations was captured on the monitor. This is shown below.

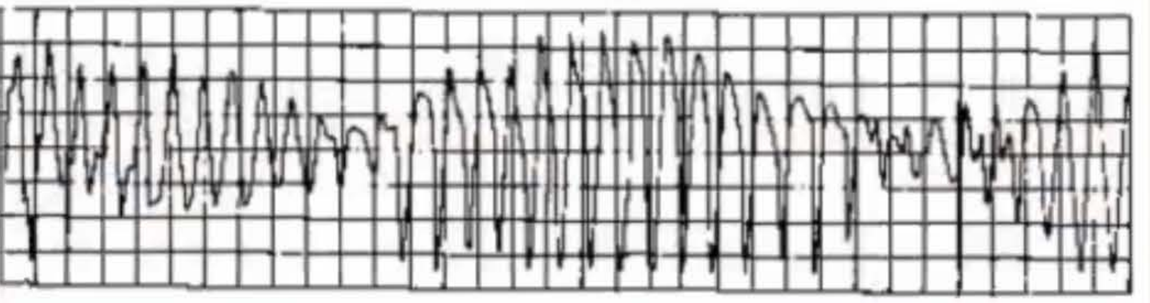

Her urea and electrolyte levels and full blood counts are within normal range.

What would be the most appropriate step in the immediate management of this patient?

A	Add in amiodarone
B	Stop the disopyramide
C	Add in digoxin
D	Increase the disopyramide to tds
E	Add in low-dose atenolol

Rana Alnasser's screen

11:08

B Stop the disopyramide

This woman had torsades de pointes, often translated as a 'twisting of the points', which refers to the beat-to-beat changes in the QRS axis. Although torsades de pointes can occur in many settings (such as heart block), it is usually seen in patients with one of the congenital long QT syndromes or in association with drug therapy. The drugs commonly involved are: disopyramide, procainamide, quinidine, sotalol and terfenadine. Other drugs where the risk is associated with the dose are: amiodarone, arsenic trioxide, cisapride, calcium channel blockers, clarithromycin, erythromycin, pentamidine, anti-emetic agents, antipsychotic agents and methadone.

The arrhythmia in this patient was provoked by disopyramide, and it is possible that she could have the subclinical form of a long QT syndrome (subclinical forms are often revealed by QT-prolonging drugs). This is why, in her case, the prolonged QT would not have been picked up on testing at the time of her cardioversion.

A Add in amiodarone

This risks further prolongation of the QT interval, leading to an increased risk of sustained ventricular tachycardia (VT).

C Add in digoxin

Digoxin has no effect on reducing the risk for torsades de pointes and has a limited role in the management of AF in patients where other options are not appropriate.

D Increase the disopyramide to tds

Disopyramide has precipitated the episode of torsades de pointes; therefore, increasing it will further increase the risk

Rana Alnasser's screen

syndromes or in association with drug therapy. The drugs commonly involved are: disopyramide, procainamide, quinidine, sotalol and terfenadine. Other drugs where the risk is associated with the dose are: amiodarone, arsenic trioxide, cisapride, calcium channel blockers, clarithromycin, erythromycin, pentamidine, anti-emetic agents, antipsychotic agents and methadone.

The arrhythmia in this patient was provoked by disopyramide, and it is possible that she could have the subclinical form of a long QT syndrome (subclinical forms are often revealed by QT-prolonging drugs). This is why, in her case, the prolonged QT would not have been picked up on testing at the time of her cardioversion.

A Add in amiodarone

This risks further prolongation of the QT interval, leading to an increased risk of sustained ventricular tachycardia (VT).

C Add in digoxin

Digoxin has no effect on reducing the risk for torsades de pointes and has a limited role in the management of AF in patients where other options are not appropriate.

D Increase the disopyramide to tds

Disopyramide has precipitated the episode of torsades de pointes; therefore, increasing it will further increase the risk for sustained VT.

E Add in low-dose atenolol

Low-dose atenolol prolongs the action potential and therefore further exacerbates the risk of torsades de pointes.

11:10

A 23-year-old woman presents two days after a paracetamol overdose. She complains of persistent vomiting.

On examination, she looks unwell, is markedly tender in the epigastrium, and she has a pulse of 100/min, regular, and a blood pressure (BP) of 115/60 mmHg.

Investigations:

Hb	10.9 g/dl
WCC	5.7×10^9/l
PLT	100×10^9/l
INR	2.7
Na^+	139 mmol/l
K^+	5.9 mmol/l
Creatinine	235 µmol/l
Ph	7.2
pO_2	8.5 kPa
pCO_2	3.9 kPa
Bicarb	14 mmol/l
Glucose	3.9 mmol/l
Urine output	35 ml in the past 4 h

She is admitted to the high-dependency unit. Which of the following other interventions is likely to have the biggest positive effect on her prognosis?

A Haemofiltration

B Haemodialysis

Rana Alnasser's screen

PLT	100×10^9/l
INR	2.7
Na^+	139 mmol/l
K^+	5.9 mmol/l
Creatinine	235 µmol/l
Ph	7.2
pO_2	8.5 kPa
pCO_2	3.9 kPa
Bicarb	14 mmol/l
Glucose	3.9 mmol/l
Urine output	35 ml in the past 4 h

She is admitted to the high-dependency unit. Which of the following other interventions is likely to have the biggest positive effect on her prognosis?

A Haemofiltration

B Haemodialysis

C Sodium bicarbonate IV

D N-acetylcysteine IV

E Activated charcoal via NG

Submit

11:11

MyPastest
https://mypastest.pastest.com

Pastest+

A 23-year-old woman presents two days after a paracetamol overdose. She complains of persistent vomiting.

On examination, she looks unwell, is markedly tender in the epigastrium, and she has a pulse of 100/min, regular, and a blood pressure (BP) of 115/60 mmHg.

Investigations:

Hb	10.9 g/dl
WCC	5.7×10^9/l
PLT	100×10^9/l
INR	2.7
Na^+	139 mmol/l
K^+	5.9 mmol/l
Creatinine	235 µmol/l
Ph	7.2
pO_2	8.5 kPa
pCO_2	3.9 kPa
Bicarb	14 mmol/l
Glucose	3.9 mmol/l
Urine output	35 ml in the past 4 h

She is admitted to the high-dependency unit. Which of the following other interventions is likely to have the biggest positive effect on her prognosis?

Your answer was incorrect

B Haemodialysis

Of most concern is the tailing-off of this woman's urine output, metabolic acidosis and elevated potassium. This is suggestive of acute tubular necrosis. Kidney disease associated with paracetamol overdose is recoverable, and even this woman has a reasonable chance of attaining normal renal function after the acute event, as such, haemodialysis is the most appropriate next step.

D N-acetylcysteine IV

N-acetylcysteine, even when used late, may reduce liver damage and hence it should be used even now, although the relative impact on outcome is less than that for haemodialysis.

A Haemofiltration

Haemofiltration is much less effective than haemodialysis in this situation, and her blood pressure would support haemodialysis, making this the preferred option.

C Sodium bicarbonate IV

This may promote fluid retention and not have a major impact on urine output or creatinine.

E Activated charcoal via NG

At this stage all of the paracetamol will have been absorbed from the GI tract, meaning there is little role for activated charcoal here.

Rate this question:

Rana Alnasser's screen

You are asked to urgently review a 27-year-old zookeeper. He has been bitten by a coral snake and has become acutely unwell.

He is hypotensive with a blood pressure of 85/60 mmHg, pulse is 95 bpm and regular. He is losing consciousness with obvious muscle weakness and difficulty swallowing his saliva.

Which of the following statements is most correct regarding acute treatment for this snake bite?

A	The affected part should be immobilised above the level of the heart
B	A tourniquet should be immediately applied
C	Any clothing should not be disturbed
D	Use of ice on a snake bite is discouraged
E	Patients should be given a warm drink

Submit

Previous Q... Skip Questi...

© Pastest 2019

D Use of ice on a snake bite is discouraged

Ice is discouraged in the management of snake bites because it has been associated with increased necrosis of the skin and soft tissue around the bite.

A The affected part should be immobilised above the level of the heart

The affected area should be immobilised below the level of the heart, to minimise venous return.

B A tourniquet should be immediately applied

As tourniquets may exacerbate tissue necrosis, their use should only be considered by an experienced physician.

C Any clothing should not be disturbed

Any constricting clothing should be removed.

E Patients should be given a warm drink

The victim should be kept warm, but caffeine-containing drinks and alcohol should be avoided.

Coral snake venom results in neurological symptoms such as ptosis, dysphagia, dysarthria, intense salivation and later loss of deep tendon reflexes and respiratory depression. In the USA there are around 9–15 snake bite fatalities per year, mostly in children and the elderly and where treatment has been delayed.

11:17

A 28-year-old woman has been given a course of iron supplements to correct iron deficiency anaemia, which has occurred after the birth of her second baby. She is known to be suffering from post-natal depression and presents to the Emergency Department having taken 28 iron sulphate tablets some 5 h previously. She is complaining of abdominal pain and vomiting and asks for assistance.

On examination, she looks unwell, but is maintaining her airway; she has a blood pressure of 90/60 mmHg and pulse 95/min regular. While in the department she becomes drowsier and suffers profuse diarrhoea.

Which one of the following would be an appropriate initial intervention in this case?

A	IV desferrioxamine
B	Oral- activated charcoal
C	Oral penicillamine
D	Haemodialysis
E	Exchange transfusion

Mowda joined

32822

Submit

Rana Alnasser's screen

A 28-year-old woman has been given a course of iron supplements to correct iron deficiency anaemia, which has occurred after the birth of her second baby. She is known to be suffering from post-natal depression and presents to the Emergency Department having taken 28 iron sulphate tablets some 5 h previously. She is complaining of abdominal pain and vomiting and asks for assistance.

On examination, she looks unwell, but is maintaining her airway; she has a blood pressure of 90/60 mmHg and pulse 95/min regular. While in the department she becomes drowsier and suffers profuse diarrhoea.

Which one of the following would be an appropriate initial intervention in this case?

A	IV desferrioxamine
B	Oral- activated charcoal
C	Oral penicillamine
D	Haemodialysis
E	Exchange transfusion

32822

Submit

Rana Alnasser's screen

A 28-year-old woman has been given a course of iron supplements to correct iron deficiency anaemia, which has occurred after the birth of her second baby. She is known to be suffering from post-natal depression and presents to the Emergency Department having taken 28 iron sulphate tablets some 5 h previously. She is complaining of abdominal pain and vomiting and asks for assistance.

On examination, she looks unwell, but is maintaining her airway; she has a blood pressure of 90/60 mmHg and pulse 95/min regular. While in the department she becomes drowsier and suffers profuse diarrhoea.

Which one of the following would be an appropriate initial intervention in this case?

Your answer was correct

A	IV desferrioxamine
B	Oral- activated charcoal
C	Oral penicillamine
D	Haemodialysis
E	Exchange transfusion

Explanation

A	IV desferrioxamine

Ingestion of large amounts of iron may lead to acute circulatory collapse accompanied by hypotension, as in this

Explanation

A IV desferrioxamine

Ingestion of large amounts of iron may lead to acute circulatory collapse accompanied by hypotension, as in this case. IV desferrioxamine at the rate of 15 mg/kg/h is an initial treatment of choice, and starting it as early as possible is important. If hypotension/circulatory collapse is not present, then it may be given IM at the rate of 2 g every 6–12 h.

B Oral- activated charcoal

Activated charcoal is a poor absorber of iron, and gastric lavage with instillation of desferrioxamine via the NG is the preferred approach.

C Oral penicillamine

Oral penicillamine is primarily used as a copper chelator in the treatment of Wilson's disease.

D Haemodialysis

This is used as an option for patients who fail to respond to fluid resuscitation and IV desferrioxamine alone.

E Exchange transfusion

Severe iron intoxication can be treated with exchange transfusion, although this is reserved for patients who fail to respond to other interventions first.

32827

Rate this question:

Tricyclic antidepressants (TCAs) like dothiepin and amitriptyline are mainly used for the treatment of depression. In overdose they can cause anticholinergic effects resulting in mydriasis, confusion, dry mouth, constipation and urinary retention. They can have a profound effect on cardiac conduction with resultant QT prolongation and torsades de pointes. Sodium bicarbonate is the mainstay of therapy, with many guidelines also recommending magnesium sulphate particularly when torsades, rather than QRS prolongation alone, is noted on the ECG.

A Charcoal haemoperfusion

Haemodialysis and haemoperfusion are not effective in removing TCAs.

C Amiodarone infusion

This leads to prolongation of the action potential; hence it actually increases the risk of arrhythmia here.

D Ammonium chloride

Alkalinisation of urine is not indicated in TCA overdose.

E Metoprolol

Prolongation of the action potential will increase the risk of VT occurring in this patient.

Rate this question:

Next Question

12:36

B Methylphenidate

The patient has narcolepsy with symptoms of excessive daytime somnolence, hypnological hallucinations and sleep paralysis. He currently doesn't show signs of cataplexy. There is a genetic predisposition to narcolepsy and it is strongly associated with HLA-DR2. The diagnosis is supported by overnight sleep studies and a multi-sleep latency test. The patient should first try non-pharmacological therapies such as creating a sleep timetable and decreasing alcohol intake. Central nervous system stimulants such as methylphenidate are used to treat narcolepsy.

A Temazepam

Benzodiazepines can actually worsen sleep disturbance and exacerbate symptoms of narcolepsy.

C Clomipramine

Low doses of clomipramine, (a tricyclic anti-depressant), are used in the treatment of cataplexy rather than narcolepsy.

D Fluoxetine

Fluoxetine, like clomipramine has been shown to reduce symptoms of cataplexy. Data exists to support a benefit for a range of SSRIs, used at a mid to high dose.

E Alcohol

Increased alcohol consumption has a negative effect on symptoms of narcolepsy because of interference with normal sleep patterns.

Rana Alnasser's screen

12:36

A 49-year-old woman known to have bronchial asthma of 10 years' duration presents to the Emergency Department. There is a history of incessant vomiting, agitation, polyuria and polydipsia.

On examination, she was hyperventilating and apprehensive. Blood pressure was 90/70 mmHg, pulse was 112/min. All her systems were otherwise unremarkable.

On further questioning she admits to having taken a large, mixed overdose of a number of tablets used for the treatment of her asthma and her depression.

Investigations:

pH	7.1
HCO_3^-	11 mmol/l
Chloride	108 mmol/l
$paCO_2$	4.7 kPa
paO_2	12 kPa
K^+	2.3 mmol/l
Na^+	135 mmol/l
Glucose	5.0 mmol/l

What is the most likely explanation for the clinical and biochemical picture?

A Diazepam overdose

B Theophylline overdose

C Citalopram overdose

D Monteleukast overdose

Rana Alnasser's screen

On examination, she was hyperventilating and apprehensive. Blood pressure was 90/70 mmHg, pulse was 112/min. All her systems were otherwise unremarkable.

On further questioning she admits to having taken a large, mixed overdose of a number of tablets used for the treatment of her asthma and her depression.

Investigations:

pH	7.1
HCO_3^-	11 mmol/l
Chloride	108 mmol/l
$paCO_2$	4.7 kPa
paO_2	12 kPa
K^+	2.3 mmol/l
Na^+	135 mmol/l
Glucose	5.0 mmol/l

What is the most likely explanation for the clinical and biochemical picture?

A Diazepam overdose

B Theophylline overdose

C Citalopram overdose

D Monteleukast overdose

E Olanazapine overdose

B Theophylline overdose

This asthmatic lady has gastrointestinal features associated with an agitated state, with metabolic acidosis, hypokalaemia, and tachycardia. She also has thirst and polyuria. These are the common features of toxicity from theophylline and related drugs. The other features, such as cardiac arrhythmias, hypotension, metabolic acidosis and convulsions, indicate severe poisoning and a poor prognosis, particularly in the elderly. An urgent gastric lavage can be performed, although this is most useful if in the first 1-2 h after overdose. Repeated activated charcoal can also be considered according to the prescribing information and overdose guidelines. Cardiac monitoring should be continued. Correction of hypokalaemia should be performed with electrocardiography (ECG) control, as large doses of potassium chloride may be required IV. Agitation and convulsions are treated with IV diazepam. In severe poisoning with a plasma level of theophylline >60 mg/l, haemoperfusion should be considered. During the recovery period hyperkalaemia may result, which can *per se* require treatment.

A Diazepam overdose

Diazepam overdose is associated with respiratory acidosis driven by hypoventilation and CO_2 retention.

C Citalopram overdose

Citalopram overdose isn't associated with hypokalaemia - it is associated with symptoms of tremor, agitation, hypertension and possible serotonin syndrome.

D Monteleukast overdose

Monteleukast overdose is not associated with symptoms in the majority of cases - in some cases patients report

A 52-year-old man with a history of COPD presents with jaundice. He has a history of hypertension for which he receives ramipril and amlodipine, and hypercholesterolaemia which is treated with a statin. He takes theophylline tablets for his COPD. He consulted his general practitioner (GP) two weeks earlier and was prescribed an antibiotic for two weeks for a lower respiratory tract infection.

On examination, he is jaundiced and has signs of scratch marks over his upper body. He tells you he has been passing dark urine.

Investigations:

Hb	13.1 g/dl
WCC	8.1×10^9/l
PLT	204×10^9/l
Na^+	139 mmol/l
K^+	4.4 mmol/l
Creatinine	110 μmol/l
Bilirubin	204 μmol/l
Alk Phos	320 U/l
ALT	95 U/l

Which of the following antibiotics is most likely to have been responsible?

A Ciprofloxacin

B Cephalexin

C Co-amoxiclav

12:43

prescribed an antibiotic for two weeks for a lower respiratory tract infection.

On examination, he is jaundiced and has signs of scratch marks over his upper body. He tells you he has been passing dark urine.

Investigations:

Hb	13.1 g/dl
WCC	8.1×10^9/l
PLT	204×10^9/l
Na^+	139 mmol/l
K^+	4.4 mmol/l
Creatinine	110 µmol/l
Bilirubin	204 µmol/l
Alk Phos	320 U/l
ALT	95 U/l

Which of the following antibiotics is most likely to have been responsible?

A Ciprofloxacin

B Cephalexin

C Co-amoxiclav

D Erythromycin

E Penicillin V

Rana Alnasser's screen

C Co-amoxiclav

Co-amoxiclav is strongly associated with obstructive jaundice, particularly when used for a period of 2 weeks or longer. It was the subject of a drug safety update from the MHRA specifically to discourage prolonged prescribing. It is also a recommended initial intervention for the treatment of respiratory infection.

A Ciprofloxacin

Ciprofloxacin is rarely used in conjunction with theophylline because as a CYP450 inhibitor it can lead to a marked increase in theophylline levels. Hence GPs are educated not to use it in this situation. It is associated with obstructive jaundice, but more rarely than co-amoxiclav.

B Cephalexin

Cephalexin is rarely associated with transient hepatitis and cholestatic jaundice. Elevation in transaminases is much more commonly seen.

D Erythromycin

Like ciprofloxacin, erythromycin is a P450 inhibitor, which means it is less likely to be used here given the prescription of theophylline. It is more likely to be associated with elevated transaminases rather than obstructive jaundice.

E Penicillin V

Penicillin V is usually reserved for treatment of *S. pyogenes* pharyngeal infection, rather than respiratory tract infection, and amoxicillin/co-amoxiclav are favoured under BTS guidelines.

A 40-year-old man attends clinic for investigation of heartburn symptoms. He has recently had an upper gastrointestinal (GI) endoscopy that has shown a shallow duodenal ulcer. The biopsies have shown the patient to be positive for *Helicobacter pylori*. He is currently only taking omeprazole and is allergic to penicillin.

Which two antibiotics should be used for eradication therapy?

A	Ciprofloxacin and metronidazole
B	Clarithromycin and metronidazole
C	Tobramycin and ciprofloxacin
D	Tetracycline and amoxicillin
E	Chloramphenicol and metronidazole

Submit

Previous Q... Skip Questi...

© Pastest 2019

A 40-year-old man attends clinic for investigation of heartburn symptoms. He has recently had an upper gastrointestinal (GI) endoscopy that has shown a shallow duodenal ulcer. The biopsies have shown the patient to be positive for *Helicobacter pylori*. He is currently only taking omeprazole and is allergic to penicillin.

Which two antibiotics should be used for eradication therapy?

Your answer was correct

A	Ciprofloxacin and metronidazole
B	Clarithromycin and metronidazole
C	Tobramycin and ciprofloxacin
D	Tetracycline and amoxicillin
E	Chloramphenicol and metronidazole

Explanation

B Clarithromycin and metronidazole

For patients who are penicillin allergic the recommended intervention for *H. pylori* eradication is a 1-week course of therapy with clarithromycin, metronidazole and a PPI. A post- treatment breath test may be used to confirm eradication in the event that symptoms continue. Two weeks of therapy is considered when a MALT lymphoma has been identified.

Rana Alnasser's screen

12:46

Explanation

B Clarithromycin and metronidazole

For patients who are penicillin allergic the recommended intervention for *H. pylori* eradication is a 1-week course of therapy with clarithromycin, metronidazole and a PPI. A post- treatment breath test may be used to confirm eradication in the event that symptoms continue. Two weeks of therapy is considered when a MALT lymphoma has been identified.

A Ciprofloxacin and metronidazole

Resistance rates of *H. pylori* are increasing to ciprofloxacin; this makes clarithromycin the preferred choice in patients who are penicillin allergic.

C Tobramycin and ciprofloxacin

Tobramycin is used in the ITU setting for gut decontamination of critically ill patients; it is not part of the standard approach to routine *H. pylori* eradication.

D Tetracycline and amoxicillin

This is not a standard approach to eradication, and penicillin allergy precludes use of amoxicillin.

E Chloramphenicol and metronidazole

Chloramphenicol is reserved for life-threatening infections where resistance exists to other antibiotics, and is not used in routine practice for *H. pylori* eradication.

Rate this question:

Rana Alnasser's screen

12:47
On
594-042-7551
Leave

A 72-year-old man with a history of Parkinson's-like symptoms, postural hypotension and urinary retention presents for review. Unfortunately, his condition has deteriorated to the extent that he can only walk a few yards at a time and he has become profoundly depressed. He is now hearing voices telling him that he is worthless and that he should kill himself. There has been one previous suicide attempt in the past week, involving a large overdose of his L-dopa tablets.

Which of the following would be the most appropriate treatment for his depression?

A Fluoxetine

B Amitryptilline

C Paroxetine

D Chlorpromazine

E Clozapine

Submit

Rana Alnassor's screen
Audio
Video
Share
Participants
More

E Clozapine

Given the prominent auditory hallucinations and one significant suicide attempt in the last week, an anti-psychotic is the most appropriate intervention. Clozapine is under-utilised because of the need for therapeutic drug monitoring, although in Parkinson's-related psychosis it is recognised to be the most effective agent with respect to relieving symptoms.

A Fluoxetine

SSRIs are likely to be inadequate here with respect to relieving symptoms, may exacerbate motor symptoms and are associated with increased risk of the serotonin syndrome in patients co-prescribed L-dopa.

B Amitryptilline

Tricyclic anti-depressants in this situation are not the preferred option because they won't impact on the psychotic symptoms seen here.

C Paroxetine

For the same reasons that fluoxetine is not advised in the treatment of Parkinson's disease (exacerbation of motor symptoms and risk of serotonin syndrome), paroxetine should also be avoided.

D Chlorpromazine

Chlorpromazine is not advised because traditional anti-psychotics can significantly worsen motor symptoms of Parkinson's disease.

12:48

You are asked to review some blood results by the House Officer on call with you one Saturday evening. He has seen a 30-year-old man in the Emergency Department who was brought in by a friend.

He tells you that the patient is generally unwell, with a heart rate of 120/min and a blood pressure of 139/58 mmHg, and is short of breath with a respiratory rate of 25/min.

His arterial blood gases on high-flow oxygen are:

pH	7.19
$p(CO_2)$	1.1 kPa
$p(O_2)$	29.6 kPa
HCO_3^-	7.8 mmol/l
Base excess	-22.0 mmol/l

Biochemistry Investigations:

Sodium	142 mmol/l
Potassium	4.0 mmol/l
Urea	5.2 mmol/l
Creatinine	169 µmol/l
Glucose	7.0 mmol/l
Bicarbonate	6.0 mmol/l
Chloride	89 mmol/l
Phosphate	1.19 mmol/l

It is considered that he may have been poisoned.

Which of the following is the most likely cause?

A Lisinopril

Rana Alnasser's screen

pH	7.19
$p(CO_2)$	1.1 kPa
$p(O_2)$	29.6 kPa
HCO_3^-	7.8 mmol/l
Base excess	-22.0 mmol/l

Biochemistry Investigations:

Sodium	142 mmol/l
Potassium	4.0 mmol/l
Urea	5.2 mmol/l
Creatinine	169 µmol/l
Glucose	7.0 mmol/l
Bicarbonate	6.0 mmol/l
Chloride	89 mmol/l
Phosphate	1.19 mmol/l

It is considered that he may have been poisoned.

Which of the following is the most likely cause?

A Lisinopril

B Methanol

C Metoprolol

D Amiodarone

E Acetazolamide

12:51

MyPastest
https://mypastest.pastest.com

Pastest+

B Methanol

This patient has a high anion gap metabolic acidosis with evidence of attempted respiratory compensation. Sodium and potassium make up the majority of the extracellular cations (95%), whereas chloride and bicarbonate constitute 85% of the extracellular anions. As more cations are measured, this will give a normal anion gap of around 12–16 mmol/l ($(Na^+ + K^+) - (Cl^- + HCO_3^-)$). In some cases of metabolic acidosis, this gap will be elevated. One can see that in the question the anion gap is (142 + 4) - (6 + 89) = 51. A number of causes of high anion gap metabolic acidosis exist, including methanol, metformin and isoniazid.

A Lisinopril

Lisinopril overdose can result in marked hypotension with kidney disease, but doesn't result in raised anion gap metabolic acidosis.

C Metoprolol

Metoprolol overdose is associated with marked hypotension and bradycardia rather than the picture seen here.

D Amiodarone

Overdose of amiodarone is associated with extreme bradycardia, heart block, hypotension and cardiogenic shock.

E Acetazolamide

You are reviewing a patient with hepatitis B and evidence of chronic active hepatitis, and you plan to instigate therapy with entecavir.

Which of the following correctly describes the mode of action of entecavir?

A	Non-nucleoside reverse transcriptase inhibitor (NNRTI)
B	M2 proton pump inhbitor
C	Interferon alpha-2a agonist
D	Nucleoside analogue
E	Protease inhibitor

36031

Submit

Previous Q... Skip Questi...

© Pastest 2019

12:52

D Nucleoside analogue

Entecavir is a pro-drug and requires phosphorylation to the triphosphate form before it becomes active. It works by inhibiting the priming of HBV polymerase, blocking reverse transcription of the negative-strand DNA and synthesis of the positive-strand DNA of the virus. Clinical trials suggest increased viral clearance versus lamivudine; it is now recommended as an option for initial treatment of hepatitis B by NICE.

E Protease inhibitor

Protease inhibitors are used in the treatment of hepatitis C and HIV, boceprevir being an example of an NS3/4A protease inhibitor used in the treatment of hepatitis C.

A Non-nucleoside reverse transcriptase inhibitor (NNRTI)

NNRTIs are used in the treatment of HIV, with nevirapine being an example of a first-generation NNRTI that works by inhibiting HIV reverse transcriptase.

B M2 proton pump inhbitor

Amantadine is an M2 proton pump inhibitor that was developed for the treatment of influenza, and has been used in the treatment of Parkinson's disease (although its mechanism of action in Parkinson's is unknown).

C Interferon alpha-2a agonist

Interferon alpha-2a is used in pegylated form for intermittent administration in the treatment of some patients with hepatitis B and C

Rana Alnasser's screen

12:53

A 69-year-old patient from India is admitted to hospital. The patient's relatives are concerned as over past few weeks he has become forgetful with increasing lethargy and weakness. They have noticed a scaly skin rash appearing on his face and scalp. His mouth and gums have become inflamed and as a result his oral intake has declined. He is currently on treatment for pulmonary tuberculosis and Parkinson's disease.

Neurological examination reveals cogwheel rigidity and decreased distal limb sensation in a stocking distribution.

His medication list, as written on a piece of paper by his wife, reads: "madopar, paracetamol, lansoprazole, gaviscon, fybogel, rifampicin, isoniazid, pyrazinamide, salbutamol inhaler".

Initial investigations reveal:

Haemoglobin	9.5 g/dl
White cell count	10.3×10^9/l
Platelets	212×10^9/l
Mean corpuscular volume (MCV)	76 fl (80–96 fl)
Sodium	142 mmol/l
Potassium	3.9 mmol/l
Urea	5.3 mmol/l
Creatinine	68 μmol/l
Serum iron	23 μmol/l (12–30 μmol/l)
Serum iron binding capacity	35 μmol/l (45–75 μmol/l)

The patient is commenced on appropriate treatment based on the above history, examination and blood results

What might be a consequence of treatment for his

Rana Alnasser's screen

Initial investigations reveal:

Haemoglobin	9.5 g/dl
White cell count	10.3×10^9/l
Platelets	212×10^9/l
Mean corpuscular volume (MCV)	76 fl (80–96 fl)
Sodium	142 mmol/l
Potassium	3.9 mmol/l
Urea	5.3 mmol/l
Creatinine	68 µmol/l
Serum iron	23 µmol/l (12–30 µmol/l)
Serum iron binding capacity	35 µmol/l (45–75 µmol/l)

The patient is commenced on appropriate treatment based on the above history, examination and blood results

What might be a consequence of treatment for his anaemia?

A Worsening of Tuberculosis

B Worsening of Parkinson's

C Hypocalcaemia

D Black discolouration of stools

E Reversible red-green colour blindness

12:56
On 594-042-7551 Leave
MyPastest
https://mypastest.pastest.com

and weakness. They have noticed a scaly skin rash appearing on his face and scalp. His mouth and gums have become inflamed and as a result his oral intake has declined. He is currently on treatment for pulmonary tuberculosis and Parkinson's disease.

Neurological examination reveals cogwheel rigidity and decreased distal limb sensation in a stocking distribution.

His medication list, as written on a piece of paper by his wife, reads: "madopar, paracetamol, lansoprazole, gaviscon, fybogel, rifampicin, isoniazid, pyrazinamide, salbutamol inhaler".

Initial investigations reveal:

Haemoglobin	9.5 g/dl
White cell count	10.3×10^9/l
Platelets	212×10^9/l
Mean corpuscular volume (MCV)	76 fl (80–96 fl)
Sodium	142 mmol/l
Potassium	3.9 mmol/l
Urea	5.3 mmol/l
Creatinine	68 µmol/l
Serum iron	23 µmol/l (12–30 µmol/l)
Serum iron binding capacity	35 µmol/l (45–75 µmol/l)

The patient is commenced on appropriate treatment based on the above history, examination and blood results

Audio Video Share Participants More

E Reversible red-green colour blindness

Explanation

B Worsening of Parkinson's

The patient has pyridoxine deficiency, most likely secondary to isoniazid therapy. The symptoms are confusion, seborrhoeic dermatitis, stomatitis and peripheral neuropathy. It can also cause a non-iron-deficient microcytic anaemia, as pyridoxine is required as a cofactor in the manufacture of porphyrins for the synthesis of haemoglobin. Pyridoxine is therefore the intervention of choice, although it does lead to an increase in the peripheral metabolism of levodopa and can therefore worsen symptoms of Parkinson's disease.

D Black discolouration of stools

Black discoloration of stools is seen with iron replacement therapy.

A Worsening of Tuberculosis

Pyridoxine is usually supplemented with isoniazid therapy and does not impact on its efficacy.

C Hypocalcaemia

Hypocalcaemia does not occur in conjunction with pyridoxine therapy.

E Reversible red-green colour blindness

Ethambutol, not pyridoxine, can cause red-green colour blindness.

12:59
On
594-042-7551
Leave

You are crash-called to the Emergency Department to review a 32-year-old fireman who has been involved in a fire at a polyurethane foam factory. The paramedics report that he was confused and complaining of chest tightness at the scene.

On transport, he appeared to rapidly develop pulmonary oedema, and soon after arrival in the Emergency Department he suffered respiratory arrest. His pulse is 77/min and regular; blood pressure (BP) is 90/70 mmHg.

He is intubated and ventilated; which of the following agents represents the next most appropriate intervention?

A	Atropine
B	2,3-dimercapto succinic acid (DMSA)
C	Dicobalt edetate
D	Fomepizole
E	Dimercaprol

Submit

Blog About Pastest Contact Us Help
Audio Video Share Participants More

You are crash-called to the Emergency Department to review a 32-year-old fireman who has been involved in a fire at a polyurethane foam factory. The paramedics report that he was confused and complaining of chest tightness at the scene.

On transport, he appeared to rapidly develop pulmonary oedema, and soon after arrival in the Emergency Department he suffered respiratory arrest. His pulse is 77/min and regular; blood pressure (BP) is 90/70 mmHg.

He is intubated and ventilated; which of the following agents represents the next most appropriate intervention?

Your answer was incorrect

A	Atropine
B	2,3-dimercapto succinic acid (DMSA)
C	Dicobalt edetate
D	Fomepizole
E	Dimercaprol

Explanation

C Dicobalt edetate

It is most likely that this patient has been exposed to cyanide fumes, which may be released from burning polyurethane foams. Cyanide acts by irreversibly blocking mitochondrial electron transport. Early signs of exposure

Explanation

C Dicobalt edetate

It is most likely that this patient has been exposed to cyanide fumes, which may be released from burning polyurethane foams. Cyanide acts by irreversibly blocking mitochondrial electron transport. Early signs of exposure include dizziness, chest tightness and confusion; later signs include pulmonary oedema, cardiovascular collapse, apnoea and paralysis; death occurs within minutes. Patients should be intubated and ventilated, and the antidote of choice is dicobalt edetate; sodium nitrite or sodium thiosulphate may be given as alternatives. Mouth-to-mouth resuscitation should not be attempted where there is a suspicion of cyanide exposure, due to risks to the resuscitator.

B 2,3-dimercapto succinic acid (DMSA)

DMSA is used to treat heavy metal poisoning, and is indicated for symptoms of lead, mercury or arsenic ingestion.

A Atropine

Atropine is an initial intervention for organophosphate poisoning, not for cyanide poisoning. In this situation it is highly unlikely to have any impact on supporting the circulation.

D Fomepizole

Fomepizole is an inhibitor of alcohol dehydrogenase, which does not lead to intoxication. It is used in the treatment of methanol and ethylene glycol overdose.

1:06
On 594-042-7551 Leave

DMSA is used to treat heavy metal poisoning, and is indicated for symptoms of lead, mercury or arsenic ingestion.

A Atropine

Atropine is an initial intervention for organophosphate poisoning, not for cyanide poisoning. In this situation it is highly unlikely to have any impact on supporting the circulation.

D Fomepizole

Fomepizole is an inhibitor of alcohol dehydrogenase, which does not lead to intoxication. It is used in the treatment of methanol and ethylene glycol overdose.

E Dimercaprol

Dimercaprol is an alternative chelating agent to DMSA for the treatment of heavy metal poisoning.

Rate this question:

Next Question

© Pastest 2019

Audio Video Share Participants More

1:06

A 42-year-old patient is referred to the clinic with left-sided back pain and weight loss. He was previously fit and well and is an ex-smoker of 20 pack-years.

Examination reveals a mass palpable in the left flank. A computed tomography (CT) scan confirms the presence of a lobulated left adrenal mass with irregular margins and areas of necrosis and mediastinal lymphadenopathy. Histology confirms appearances suggestive of an adrenal cortical carcinoma.

Investigations:

Overnight dexamethasone suppression test	30 nmol/l (< 50)
Serum aldosterone recumbent	220 pmol/l (135–400)
Serum aldosterone upright	530 pmol/l (330–830)
Serum renin recumbent	1.5 pmol/ml/h (1.1–2.7)
Serum renin upright	3.6 pmol/ml/h (3.0–4.3)
Serum androstenedione	6.2 nmol/l (1.6–8.4)

24-h urine collection:

Vanillyl mandelic acid	6.3 µmol/24 h (5–35)
Noradrenaline	220 nmol/24 h (< 570)
Adrenaline	105 nmol/24 h (< 144)
Dopamine	2100 nmol/24 h (< 3100)

What medication should he be started on?

A Phentolamine

Rana Alnasser's screen

Serum renin recumbent	1.5 pmol/ml/h (1.1–2.7)
Serum renin upright	3.6 pmol/ml/h (3.0–4.3)
Serum androstenedione	6.2 nmol/l (1.6–8.4)

24-h urine collection:

Vanillyl mandelic acid	6.3 µmol/24 h (5–35)
Noradrenaline	220 nmol/24 h (< 570)
Adrenaline	105 nmol/24 h (< 144)
Dopamine	2100 nmol/24 h (< 3100)

What medication should he be started on?

A Phentolamine

B Metyrapone

C Mitotane

D Aminoglutethimide

E Ketoconazole

Submit

C Mitotane

Mitotane is a cytostatic agent which also inhibits steroid hormone synthesis. It is of value in the treatment of adrenal cortical adenocarcinomas, including those which are non-functioning.

B Metyrapone

Metyrapone inhibits 11-beta hydroxylase, and it is therefore most useful in the treatment of hypercortisolaemia, not present here.

A Phentolamine

Phenoxybenzamine is the main alpha-adrenoceptor blocker used in the treatment of phaeochromocytoma.

D Aminoglutethimide

Aminoglutethimide blocks both aromatase and the cholesterol side-chain cleavage enzyme also known as P450scc. This means that it may be very useful in patients with virilising adrenal carcinomas.

E Ketoconazole

Ketoconazole is an alternative to metyrapone in blocking the synthesis of cortisol, so it doesn't have a major role here.

Rate this question:

3G 1:11

A 75-year-old woman is admitted with confusion and general deterioration. She was found in her flat in a state of self-neglect.

In hospital, she is diagnosed with a left lower lobe pneumonia and commenced on antibiotics. Her medical background includes angina, atrial fibrillation, osteoarthritis, asthma and diabetes.

Her medication is: glyceryl trinitrate spray, digoxin, warfarin, codeine phosphate, salbutamol inhaler, becotide inhaler and metformin. She is commenced on amoxicillin in hospital.

While an inpatient, she improves and the house physician on the ward notices a lesion on her scalp. It is a small, irregular, erythematous papule surrounded by pale, brittle hair. A dermatologist reviews the lesion and takes some hair samples for further examination.

After a microscopic examination, the dermatologist returns to the ward and prescribes a shampoo for the patient and an oral antifungal agent that works by inhibiting the mitotic spindle of the fungus.

What would be the most likely effect of the anti-fungal agent on this patient's blood tests?

A	Increased INR
B	Decreased INR
C	Pancytopenia
D	Hypoglycaemia
E	Increased serum creatinine

Rana Alnasser's screen

1:14
On
594-042-7551
Leave

B Decreased INR

The drug commenced in this patient is griseofulvin. This oral antifungal is thought to work by inhibiting the mitotic spindle of the fungus and is used for the treatment of dermatophytes. It is a liver enzyme inducer, resulting in increased metabolism of anticoagulants, and hence a decrease in the international normalised ratio (INR). The azoles work by inhibiting the conversion of lanosterol to ergosterol, which is a step required in the synthesis of fungal cell membrane. They tend to be liver enzyme inhibitors.

A Increased INR

Azole antifungals and a range of antibacterials, including macrolides and quinolones, are recognised to increase the INR.

C Pancytopenia

Mammalian cell membranes are composed of cholesterol rather than ergosterol, Griseofulvin therefore has no effect on cell maturation/production, and hence doesn't lead to pancytopenia.

D Hypoglycaemia

Metformin reduces hepatic glucose output. Its metabolism isn't significantly affected by griseofulvin, and even if levels of metformin were increased this wouldn't lead to hypoglycaemia.

E Increased serum creatinine

Amphotericin B, not griseofulvin, which is used for serious

Audio Video Share Participants More

1:14

A 62-year-old man is admitted with malignant hypertension, drowsiness and vomiting. He has grade 4 hypertensive retinopathy on fundoscopy. He is managed with intravenous (iv) sodium nitroprusside and initially has a good response to therapy, with a reduction in blood pressure (BP) from 212/120 to 185/100 mmHg.

The nurses ask you to review him a few hours later as he has become increasingly drowsy and confused; the nurses tell you that he has also been short of breath and complaining of abdominal pain. His BP is 175/90 mmHg and his pulse is 75/min and regular.

Investigations:

		Normal Values
Hb	13.5 g/dl	
WCC	6.4×10^9/l	
PLT	190×10^9/l	
Na^+	139 mmol/l	
K^+	4.5 mmol/l	
Bicarbonate	11 mmol/l	
Creatinine	135 µmol/l	
Lactate	10 mmol/l	0.6-1.8 mmol/l

Which diagnosis should be suspected?

A Cyanide toxicity

B Hypertensive encephalopathy

C Subarachnoid haemorrhage

Rana Alnasser's screen

with intravenous (IV) sodium nitroprusside and initially has a good response to therapy, with a reduction in blood pressure (BP) from 212/120 to 185/100 mmHg.

The nurses ask you to review him a few hours later as he has become increasingly drowsy and confused; the nurses tell you that he has also been short of breath and complaining of abdominal pain. His BP is 175/90 mmHg and his pulse is 75/min and regular.

Investigations:

		Normal Values
Hb	13.5 g/dl	
WCC	6.4×10^9/l	
PLT	190×10^9/l	
Na^+	139 mmol/l	
K^+	4.5 mmol/l	
Bicarbonate	11 mmol/l	
Creatinine	135 µmol/l	
Lactate	10 mmol/l	0.6-1.8 mmol/l

Which diagnosis should be suspected?

A Cyanide toxicity

B Hypertensive encephalopathy

C Subarachnoid haemorrhage

D Encephalitis

E Methaemoglobinaemia

A Cyanide toxicity

Improperly stored nitroprusside for infusion, or nitroprusside which has been exposed to sunlight on the ward, is subject to degradation which may result in the formation of sodium cyanide. Cyanide poisoning is associated with hypertension and bradycardia, followed later by hypotension and coma. Abdominal pain and shortness of breath are other prominent features. The characteristic finding on examination is a marked elevation in lactate. Sodium thiosulphate, dicobalt edetate or sodium nitrite are possible treatments for cyanide poisoning.

B Hypertensive encephalopathy

Given that there has been a slight fall in blood pressure, hypertensive encephalopathy is less likely and it isn't associated with abdominal pain.

C Subarachnoid haemorrhage

Significant subarachnoid haemorrhage is more likely to be associated with either a further rise in blood pressure or at least stabilisation at the higher level. Again it would not be associated with abdominal pain.

D Encephalitis

Against a background of marked hypertension and no clinical signs of infection, encephalitis is extremely unlikely to be the cause of the deterioration seen here.

E Methaemoglobinaemia

Methaemoglobinaemia is associated with tissue hypoxia; however, other signs such as cyanosis would be expected given the symptom picture seen here.

1:18
On
594-042-7551
Leave

A 54-year-old veterinarian attends the Emergency Department, having been bitten by a snake while out walking his dog. He is sure that it was an adder, and asks whether he requires the antidote.

On examination, his blood pressure (BP) is 125/60 mmHg, his pulse is 85 bpm and regular and he feels anxious. You can see the marks from the adder bite with some surrounding erythema on his left lower leg.

Which of the following is an indication for administration of antivenom?

A	Previous anaphylaxis to antivenom
B	History of ischaemic heart disease
C	Visible puncture mark at the bite site
D	History of asthma
E	Severe limb swelling

32805

Submit

Blog About Pastest Contact Us Help
Audio Video Share Participants More

E Severe limb swelling

The adder (*Vipera berus*) is the UK's indigenous venomous snake, although others, more poisonous, are kept in captivity. There is an available antivenom, but it must be remembered that there is a 1% chance of having an anaphylactic reaction to this, and so adrenaline should be available during its administration. Indications for its use include signs of systemic envenomation such as persistent hypotension, electrocardiogram (ECG) abnormalities, vomiting, haemostatic abnormalities, white cell count above 20×10^9/l, and severe localised swelling extending proximally up a limb within 2–4 hours of the bite occurring.

A Previous anaphylaxis to antivenom

Previous anaphylaxis to antivenom is of course a contraindication to future use.

B History of ischaemic heart disease

ECG changes in response to a viper bite are an indication for antivenom, but a history of ischaemic heart disease per se is not.

C Visible puncture mark at the bite site

Although this indicates that a bite has occurred, it does not necessarily relate to the amount of venom injected, nor is it indicative of the symptoms.

D History of asthma

Most patients suffer a vascular type reaction to an adder bite, including problems with haemostasis and localised limb swelling. A history of asthma is not an indication or contra-indication to antivenom administration.

1:22

MyPastest
https://mypastest.pastest.com

Pastest+

A 63-year-old woman is admitted with breathlessness. She has a background of diabetes.

A chest X-ray reveals a left-sided airspace infiltrates. She is commenced on antibiotics for a community-acquired pneumonia.

After 72 h, the patient has not responded to the antibiotics, both temperature and CRP are still raised, and her sputum has grown Nocardia asteroides.

What is the most appropriate antibiotic to use?

A	Trimethoprim
B	Ciprofloxacin
C	Sulphadiazine
D	Chloramphenicol
E	Gentamicin

6502

Submit

Previous Q...

Skip Questi...

Rana Alnasser's screen

C Sulphadiazine

Nocardia asteroides is an actinomycete infection responsible for pneumonia and cerebral abscess formation in the immunocompromised. Sulphonamides are the intervention of choice. These antibiotics act as inhibitors of bacterial dihydropteroate synthetase. Alternative antimicrobial agents with activity against *Nocardia* include amikacin, imipenem, meropenem, ceftriaxone, cefotaxime, minocycline, moxifloxacin, levofloxacin, linezolid, tigecycline, and amoxicillin-clavulanic acid.

E Gentamicin

Nocardia asteroides tends to be resistant to gentamicin, preventing it from being a treatment option here.

A Trimethoprim

Although trimethoprim is a component of co-trimoxazole, used as the first line therapy for Nocardia in the US, the benefit of the trimethoprim component of the drug is unclear.

B Ciprofloxacin

Next generation quinolones such as levofloxacin and moxifloxacin are preferred to ciprofloxacin for the treatment of Nocardia infection.

D Chloramphenicol

Chloramphenicol was a preferred agent for treating Nocardia until the 1990's, but is now considered when resistance to other options is identified

1:25

nocardia skin abscess

Figure 2. Tracking subcutaneous wounds after initial debridement.

Nocardia infection. Causes, symptoms ...
rugline.org

Soil-acquired cutaneous nocardiosis on ...
ovepress.com

Fungal Infections: Nocardiosis ...
he-dermatologist.com

Nocardiosis: Clinical and Pathological ...
intechopen.com

Nocardiosis - Causes, Symptoms ...
primehealthchannel.com

Sporotrichoid Skin Infection Caused ...
mdpi.com

Patient Case Cutaneous Nocardia

Dermato
emedicin

Relat
noca
myce
bacill
actin

dissemi
scielo.br

Discover
Updates
Search
Recent

1:25
On
594-042-7551
Leave

1: Photograph showing right
ndibular and parotid abscess by
oides.

Annotation
Stop S

nandibular and parotid abscess due to Nocardia ...

ght. Learn more

Figure 1: Right side submandibular swelling extending through the midline to involve the left submandibular area which is typical of Ludwig's angina in a 12 years old male.

Update
Search
Recent
More
Audio
Video
Share
Participants
More

1:27

A 48-year-old man is being managed on the HDU for severe hypertension associated with left ventricular failure and is currently being treated with intravenous (iv) sodium nitroprusside. His blood pressure (BP) is now 145/80 mmHg, his pulse 75/min and regular and he is improving. You are called back to see him a few hours later, just after the nursing shift change, because he has become acutely confused, short of breath and is complaining of central chest pain, abdominal pain and vomiting.

On examination his BP is now 100/60 mmHg, with pulse 90/min and regular.

Investigations:

Hb	12.1 g/dl
WCC	5.7×10^9/l
PLT	201×10^9/l
Na^+	140 mmol/l
K^+	4.5 mmol/l
Creatinine	160 μmol/l
pH	7.1
ECG	Widespread ST depression consistent with myocardial ischaemia

Given the suspected diagnosis, which of the following is the most appropriate treatment?

A	IV GTN
B	IV heparin
C	IV dicobalt edetate

Rana Alnasser's screen

chest pain, abdominal pain and vomiting.

On examination his BP is now 100/60 mmHg, with pulse 90/min and regular.

Investigations:

Hb	12.1 g/dl
WCC	5.7×10^9/l
PLT	201×10^9/l
Na^+	140 mmol/l
K^+	4.5 mmol/l
Creatinine	160 µmol/l
pH	7.1
ECG	Widespread ST depression consistent with myocardial ischaemia

Given the suspected diagnosis, which of the following is the most appropriate treatment?

A IV GTN

B IV heparin

C IV dicobalt edetate

D IV diamorphine

E IV TPA

Submit

A IV GTN

Although there is obvious myocardial ischaemia, it's related here to cyanide poisoning; as such, IV GTN won't improve cardiac ischaemia and by dropping blood pressure may actually worsen it.

B IV heparin

Whilst anticoagulation is indicated where there is coronary artery occlusion, that isn't the case here and it won't improve outcomes.

D IV diamorphine

Pain related to ischaemia here should resolve once the cyanide antidote is administered.

E IV TPA

Thrombolysis is indicated for massive PE and for ST-elevation myocardial infarction where PCI is unavailable. Neither of those situations is present here.

Rate this question:

Next Question

Previous Q... Tag Questi... Feedback End Session

Blog About Pastest Contact Us Help

A 34-year-old woman, who is eight weeks pregnant, comes in after an overdose of white tablets and is unable to remember how many she took. She refuses to wait for the results of her initial blood tests and leaves hospital, only to come back after a few hours complaining of feeling faint. At this point, her investigations are repeated. Salicylate levels are 4 mmol/l on the initial sample and 1.2 mmol/l on the subsequent one.

Investigations:

FBC, U&E, LFT	Normal
Initial ABG pH	7.6
pa(CO_2)	2.0 kPa
HCO_3^-	24 mmol/l

Repeat arterial blood gas (ABG) following return:

pH	7.35
pa(CO_2)	3.0 kPa
HCO_3^-	12 mmol/l

What metabolic abnormality is seen on first presentation?

A Metabolic acidosis

B Metabolic alkalosis

C Respiratory acidosis

D Respiratory alkalosis

E Mixed Metabolic and respiratory acidosis

1:29

A 34-year-old woman, who is eight weeks pregnant, comes in after an overdose of white tablets and is unable to remember how many she took. She refuses to wait for the results of her initial blood tests and leaves hospital, only to come back after a few hours complaining of feeling faint. At this point, her investigations are repeated. Salicylate levels are 4 mmol/l on the initial sample and 1.2 mmol/l on the subsequent one.

Investigations:

FBC, U&E, LFT	Normal
Initial ABG pH	7.6
pa(CO_2)	2.0 kPa
HCO_3^-	24 mmol/l

Repeat arterial blood gas (ABG) following return:

pH	7.35
pa(CO_2)	3.0 kPa
HCO_3^-	12 mmol/l

What metabolic abnormality is seen on first presentation?

Your answer was correct

A Metabolic acidosis

B Metabolic alkalosis

C Respiratory acidosis

A
B
C
D
E
O

Res
Res
Res
Res

Rana Alnasser's screen

1:29

D Respiratory alkalosis

The elevated pH with low CO_2 and normal HCO_3 seen here is consistent with a respiratory alkalosis, the initial presentation of aspirin overdose.

A Metabolic acidosis

By the time the patient re-presents, the second blood gas illustrates a metabolic acidosis with partial compensation, commonly known as the third stage of aspirin overdose.

B Metabolic alkalosis

The bicarbonate in the normal range effectively rules out a metabolic alkalosis here.

C Respiratory acidosis

A respiratory acidosis is associated with an elevated CO_2, which isn't seen here. An isolated respiratory acidosis is seen in respiratory failure due to COPD or acute lower respiratory tract infection, and in overdose of opiates or benzodiazepines.

E Mixed Metabolic and respiratory acidosis

In a mixed metabolic and respiratory acidosis, the bicarbonate is low and the CO_2 is elevated, which isn't the picture reported here. A mixed metabolic and respiratory acidosis may be seen after events such as a myocardial infarction, where there is cardiac failure and co-existent decreased tissue perfusion.

Rate this question:

Rana Alnasser's screen

1:29
On ...
594-042-7551
Leave

A 62-year-old woman presents to the surgery for follow-up after attending the Emergency Department with a left Colles fracture. She has a history of severe oesophagitis, for which she takes 40 mg omeprazole, a previous lumbar spine fracture, and a deep vein thrombosis on hormone replacement therapy (HRT) some 12 years earlier. She is interested in prophylaxis against osteoporosis.

Investigations:

Hb	13.1 g/dl
WCC	6.2×10^9/l
PLT	210×10^9/l
Na^+	139 mmol/l
K^+	4.9 mmol/l
Creatinine	130 µmol/l
T score	-4.2

Which of the following is the most appropriate therapy?

A Calcium and vitamin D

B Raloxifene

C Etidronate

D Strontium

E Teriparatide

21566
Audio
Video
Share
Participants
More

E Teriparatide

Teriparatide is a synthetic PTH analogue, given as a once a day subcutaneous injection. It is one of the few treatments for osteoporosis which is recognised to increase osteoblast activity. NICE guidance suggests that teriparatide is appropriate for patients with a T score of <4.0 who have two or more fractures.

D Strontium

Strontium is associated with increased cardiovascular events and potentially with increased risk of venous thromboembolism. As such it is reserved for patients where other options for treating osteoporosis are unsuitable.

A Calcium and vitamin D

Given the very low T score seen here, it is not appropriate to treat with calcium and vitamin D alone.

B Raloxifene

Raloxifene is a selective oestrogen receptor modulator. Although it is not associated with oesophagitis, it is less effective at preserving BMD than bisphosphonates, and is associated with increased risk of venous thromboembolism. As such it is not an appropriate option here.

C Etidronate

Although etidronate can be given in larger doses with decreased dosing frequency, it still has the propensity to cause oesophagitis, and should therefore be avoided here.

E Teriparatide

Teriparatide is a synthetic PTH analogue, given as a once a day subcutaneous injection. It is one of the few treatments for osteoporosis which is recognised to increase osteoblast activity. NICE guidance suggests that teriparatide is appropriate for patients with a T score of <4.0 who have two or more fractures.

D Strontium

Strontium is associated with increased cardiovascular events and potentially with increased risk of venous thromboembolism. As such it is reserved for patients where other options for treating osteoporosis are unsuitable.

A Calcium and vitamin D

Given the very low T score seen here, it is not appropriate to treat with calcium and vitamin D alone.

B Raloxifene

Raloxifene is a selective oestrogen receptor modulator. Although it is not associated with oesophagitis, it is less effective at preserving BMD than bisphosphonates, and is associated with increased risk of venous thromboembolism. As such it is not an appropriate option here.

C Etidronate

Although etidronate can be given in larger doses with decreased dosing frequency, it still has the propensity to cause oesophagitis, and should therefore be avoided here.

1:39
On
594-042-7551
Leave
404 — Not Found
404 — Not Found
Home Feed | Res
https://mypastest.pastest.com/Secure/TestMe/

Pastest+

A 30-year-old farmer is admitted with blurring of vision for the past 10 h; 4 h ago he noticed double vision and 2 h ago he noticed weakness of his limbs. His wife noticed that his voice had become hoarse and he was choking on and off.

She remembered that her husband had initially vomited several times after having had his favourite home-cured ham, a day ago.

On examination, he was alert and had a hoarse and nasal voice. BP was 125/72 mmHg, pulse 82/min, respiratory rate 18/min. A right-sided ptosis and bilateral lateral recti weakness were evident. Pupils were 3 mm and unreactive to light on both sides. Facial expression was normal and the gag reflex was also normal. He had a generalised weakness of his limbs and tendon reflexes were absent. Sensation was intact.

What is the most likely diagnosis?

A	Guillain-Barré syndrome
B	Lambert-Eaton syndrome
C	Myasthenia gravis
D	Botulism
E	Lafora body disease

32844

Submit
Audio
Video
Share
Participants
More

1:40

404 — Not Found × 404 — Not Found × Home Feed | Re ×

https://mypastest.pastest.com/Secure/TestMe/

She remembered that her husband had initially vomited several times after having had his favourite home-cured ham, a day ago.

On examination, he was alert and had a hoarse and nasal voice. BP was 125/72 mmHg, pulse 82/min, respiratory rate 18/min. A right-sided ptosis and bilateral lateral recti weakness were evident. Pupils were 3 mm and unreactive to light on both sides. Facial expression was normal and the gag reflex was also normal. He had a generalised weakness of his limbs and tendon reflexes were absent. Sensation was intact.

What is the most likely diagnosis?

Your answer was correct

A	Guillain-Barré syndrome
B	Lambert-Eaton syndrome
C	Myasthenia gravis
D	Botulism
E	Lafora body disease

Explanation

D Botulism

Botulism is a rare form of food-borne disease caused by

1:40
404 — Not Found
404 — Not Found
Home Feed | Re
https://mypastest.pastest.com/Secure/TestMe/
Pastest+

Explanation

D	Botulism

Botulism is a rare form of food-borne disease caused by the exotoxin of *Cl. botulinum*. It usually occurs from consumption of home-preserved food and vegetables. It is also rarely seen in injecting drug abusers. The toxin acts at the presynaptic endings of the neuromuscular junction and interferes with the release of acetylcholine. Symptoms usually appear within 12–36 h of ingestion of the contaminated food. In most patients the initial symptoms are anorexia, nausea and vomiting. This is followed by blurred vision, diplopia due to oculomotor muscle weakness. Pupils are often unreactive, differentiating this disease from myasthenia gravis, and mydriasis may be present. Subsequently the patient develops bulbar involvement followed by progressive weakness of the face, neck, trunk, limbs and respiratory muscles in quick succession. It is not unusual for the gag reflex to be retained, as in the present scenario. Clinical diagnosis is confirmed on repetitive nerve stimulation test, which shows a progressive increase in amplitude of the potentials. Treatment is by the use of the trivalent antiserum and guanidine hydrochloride (although this is unproven in the clinical trial setting).

A	Guillain-Barré syndrome

This syndrome is associated with ascending paralysis rather than the central symptoms of muscle weakness appearing first, as is seen here. The Miller-Fisher variant does, however, present with central weakness first and, in this case, nerve conduction studies/EMG may be helpful

1:40

404 — Not Found | 404 — Not Found | Home Feed | Re

https://mypastest.pastest.com/Secure/TestMe/

B Lambert-Eaton syndrome

Lambert-Eaton syndrome presents with gradual-onset muscle weakness over a number of weeks and is associated with underlying bronchial carcinoma.

C Myasthenia gravis

This is associated with gradual-onset proximal myopathy and is associated with other underlying autoimmune conditions.

E Lafora body disease

Lafora body disease is inherited progressive myoclonic epilepsy.

Rate this question:

Next Question

Previous Q... Tag Questi... Feedback End Session

Blog About Pastest Contact Us Help

© Pastest 2019

STC 10:52 PM 69%
594-042-7551
00:11
Leave
https://mypastest.pastest.com/Secure/TestMe/Browse

Pastest+

Question 1 of 83

You review a woman in the general practitioner (GP) surgery who is 24 weeks pregnant. She has a history of epilepsy, but presents today with a urinary tract infection.

Having suffered a respiratory tract infection only one month earlier, she asks you about which antibiotics are considered most safe for use in pregnancy.

Which of the following agents is safest for use in pregnancy?

A	Oxytetracycline
B	Gentamicin
C	Chloramphenicol
D	Amoxicillin
E	Ciprofloxacin

Submit

Unmute Start Video Share Content Participants More

NC ...
und × 404 — Not Found × Home Feed | Re × MyPastest
https://mypastest.pastest.com/Secure/TestMe/Browse

D Amoxicillin

Penicillin based antibiotics are generally considered safest for treating infections in pregnancy; however, because of prevalent resistance to amoxicillin in common pathogens causing urinary tract infection, sensitivity testing is considered before using this as a treatment option. At week 24 in pregnancy trimethoprim would generally be considered a safe alternative.

A Oxytetracycline

Tetracycline based antibiotics are not considered safe because of irreversible staining and deterioration of dentition.

B Gentamicin

Gentamicin is not considered an option because of the risk of vestibular nerve toxicity.

C Chloramphenicol

Chloramphenicol is associated with "grey baby" syndrome, and should therefore be avoided.

E Ciprofloxacin

Quinolone antibiotics are associated with tendon rupture in juvenile models of drug toxicity, and should therefore be avoided here.

Rana Alnasser's screen

STC 10:56 PM 69%
594-042-7551
04:32
Leave
https://mypastest.pastest.com/Secure/TestMe/Browse

A 56-year-old woman returns from a trip to America in May. During her stay, she became unwell with a high fever, headache and muscle pains. She consulted a local doctor who noticed a rash on the palms of her hands and soles of her feet. She was admitted to hospital where a diagnosis was made and she was commenced on antibiotics. The patient improved and was discharged and allowed to fly home with a course of oral antibiotics. She recalls the doctors in America telling her that the infection had been transmitted by a tick bite.

She currently takes medication for diabetes, ischaemic heart disease, gastro-oesophageal reflux disease and atrial fibrillation.

What medication would you stop till the antibiotic course is finished?

Your answer was incorrect

A	Metformin
B	Aluminium hydroxide
C	Gliclazide
D	Aspirin
E	Atorvastatin

Diff
Pee
A
B
C
D
E
0 10
Ses
Response
Response
Response
Response

Mute Start Video Share Content Participants 3 More

B Aluminium hydroxide

The patient is most likely to be taking a tetracycline antibiotic for a rickettsial infection. The diagnosis in this patient is Rocky Mountain spotted fever. It is caused by a tick bite that results in the above symptoms. The classic rash is described as occurring on the palms and soles. Treatment of choice is doxycyline, which is a tetracycline and acts on 30S ribosomes to prevent protein synthesis in the infecting organism. Aluminium hydroxide can complex with this antibiotic in the gastrointestinal tract, preventing absorption. Dairy products ingested at the same time can also cause this. Side effects of tetracyclines include discoloration of teeth in children, hepatoxicity and photosensitivity.

E Atorvastatin

The main concern with respect to atorvastatin prescription is use with CYP3A4 inhibitors, which may lead to an increase in atorvastatin exposure.

A Metformin

There are few significant drug interaction concerns for metformin. One of the main problems is bile salt malabsorption leading to diarrhoea, which can be worsened if the dose is increased too quickly in the early stages of therapy.

C Gliclazide

Concurrent use of gliclazide and doxycycline may increase the risk of hypoglycaemia and the patient should have been warned about this at the time of commencing antibiotic therapy, although there is no need to discontinue treatment.

Rana Alnasser's screen

A 17-year-old girl with a long history of epilepsy is admitted to the Emergency Department after taking a carbamazepine overdose following a row with her boyfriend. You understand that she took almost a full month's worth of her tablets around 2 h earlier.

On presentation to the Emergency Department, she is drowsy and vomiting. Additionally, she is complaining of slurred speech and blurred vision.

On examination, her blood pressure is 90/50 mmHg, pulse 61/min and there is obvious nystagmus, dystonia and athetosis. You are told that she suffered a generalised tonic-clonic seizure during the ambulance journey.

Investigations:

Haemoglobin (Hb)	13.0 g/dl
White cell count (WCC)	4.9×10^9/l
Platelets (PLT)	295×10^9/l
Sodium (Na^+)	139 mmol/l
Potassium (K^+)	4.8 mmol/l
Urea	7.9 mmol/l
Creatinine (Cr)	110 µmol/l
12 lead ECG	QRS prolongation

You commence activated charcoal and intravenous (iv) normal saline.

Which of the following would be the most appropriate management step in the event of further seizures?

A Sodium bicarbonate IV

B Intubate and ventilate

slurred speech and blurred vision.

On examination, her blood pressure is 90/50 mmHg, pulse 61/min and there is obvious nystagmus, dystonia and athetosis. You are told that she suffered a generalised tonic-clonic seizure during the ambulance journey.

Investigations:

Haemoglobin (Hb)	13.0 g/dl
White cell count (WCC)	4.9×10^9/l
Platelets (PLT)	295×10^9/l
Sodium (Na^+)	139 mmol/l
Potassium (K^+)	4.8 mmol/l
Urea	7.9 mmol/l
Creatinine (Cr)	110 µmol/l
12 lead ECG	QRS prolongation

You commence activated charcoal and intravenous (iv) normal saline.

Which of the following would be the most appropriate management step in the event of further seizures?

A	Sodium bicarbonate IV
B	Intubate and ventilate
C	Phenytoin IV
D	Lorazepam IV
E	Sodium valproate IV

D Lorazepam IV

In this situation, with a significant carbamazepine overdose, further seizures are possible and lorazepam IV is the intervention of choice. If this doesn't achieve control, or there is a deteriorating conscious level, intubation and ventilation is the most appropriate next step.

A Sodium bicarbonate IV

Sodium bicarbonate is indicated in the treatment of tricyclic anti-depressant overdose, where there is seizure activity, acidosis and evidence of QRS prolongation.

B Intubate and ventilate

Intubation and ventilation is appropriate in the event that lorazepam fails to achieve seizure control.

C Phenytoin IV

Phenytoin is more difficult to titrate than lorazepam, and given that seizure activity is likely to increase for a short period only, lorazepam is a more appropriate intervention.

E Sodium valproate IV

It would be more logical to consider loading with sodium valproate if a switch in epileptic medication is being considered. Given an increase in seizure activity is expected to be short term, lorazepam is the more appropriate option.

Rate this question:

Rana Alnasser's screen

A 27-year-old woman is brought to the Emergency Department after consuming a large number of 500 mg soluble aspirin tablets. She is thought to have taken 30 of them around 50 minutes earlier. She is distressed and hyperventilating on admission, complaining of severe tinnitus.

Her BP is 135/70 mmHg, pulse is 95/min and regular and her respiratory rate is 36/min. Weight is 75 kg.

Investigations:

Hb	13.2 g/dl
WCC	8.1×10^9/l
PLT	188×10^9/l
Na^+	138 mmol/l
K^+	3.8 mmol/l
Creatinine	112 micromol/l
Bicarbonate	28 mmol/l
Glucose	8.1 mmol/l
pH	7.54

Which of the following is the most appropriate initial intervention?

A Activated charcoal

B Gastric lavage

C IV fluids

D IV glucose

Her BP is 135/70 mmHg, pulse is 95/min and regular and her respiratory rate is 36/min. Weight is 75 kg.

Investigations:

Hb	13.2 g/dl
WCC	8.1×10^9/l
PLT	188×10^9/l
Na^+	138 mmol/l
K^+	3.8 mmol/l
Creatinine	112 micromol/l
Bicarbonate	28 mmol/l
Glucose	8.1 mmol/l
pH	7.54

Which of the following is the most appropriate initial intervention?

A Activated charcoal

B Gastric lavage

C IV fluids

D IV glucose

E IV diazepam

Submit

STC 11:03 PM 68%
594-042-7551
11:19
Leave

Explanation

A Activated charcoal

Guidelines recommend administering activated charcoal as soon as possible after presentation with aspirin overdose, and repeating it, particularly where the aspirin level is steadily rising. This would be considered a significant overdose (30 × 500 mg = 15 g aspirin, 15,000/75 = 200 mg/kg) with a mild-moderate risk of toxicity.

B Gastric lavage

Gastric lavage is now no longer recommended for aspirin overdose, unless the patient presents during the first hour after overdose and has consumed more than 500mg/kg of aspirin

C IV fluids

Although IV fluids are an essential part of the management of aspirin overdose, giving activated charcoal as early as possible impacts significantly on peak aspirin levels.

D IV glucose

Although hypoglycaemia does occur later in aspirin overdose, given that the glucose is 8.1 there is no need to currently intervene.

E IV diazepam

Diazepam is not recommended for the management of hyperventilation in this situation, because a compensated

Unmute Start Video Share Content Participants 3 More

NC ···

ınd × 404 — Not Found × Home Feed | Re: × MyPastest

https://mypastest.pastest.com/Secure/TestMe/Browse

A 25-year-old man presented to an inner-city general practitioner (GP) in a very agitated state. The GP suspected that he may have schizophrenia and has prescribed chlorpromazine and arranged an outpatients' clinic review.

He presents to the Emergency Department with a temperature of 38.8 °C, muscle rigidity, tachycardia and hypertension (blood pressure (BP) of 155/100 mmHg). Blood testing reveals a raised creatine kinase (CK) of 345 U/l and a raised alanine aminotransferase (ALT) of 115 U/l.

Which of the following is the most appropriate treatment for this man?

A	Diazepam
B	Methadone
C	Bromocriptine
D	Paroxetine
E	Fluoxetine

6571

Submit

C Bromocriptine

Neuroleptic malignant syndrome occurs in 0.2% of patients taking dopamine D2-receptor antagonist drugs, particularly the more potent ones such as haloperidol or chlorpromazine. Symptoms include hyperthermia, muscle rigidity, autonomic instability and fluctuating level of consciousness. Abnormal investigations include raised CK, raised white blood cell count and abnormal liver biochemistry. In patients presenting with the syndrome the neuroleptic should be discontinued and bromocriptine is the treatment of choice. Dantrolene was also considered previously as a treatment for neuroleptic malignant syndrome, and also as a treatment of malignant hyperthermia, but analyses suggest its use as monotherapy is associated with poorer prognosis than use of anticholinergics or dopamine agonists like bromocriptine.

A Diazepam

Although diazepam may have a role in reducing anxiety, it does not treat the underlying cause of his acute presentation.

B Methadone

Methadone is used in the treatment of opiate addiction, and does not have a role in the treatment of neuroleptic malignant syndrome.

D Paroxetine

Paroxetine is an SSRI used in the treatment of depression and may lower the seizure threshold, as such it is not recommended here. It may actually increase the risk of neuroleptic malignant syndrome occurring.

Rana Alnasser's screen

STC 11:05 PM 67%
594-042-7551
13:33
Leave

A 32-year-old garage manager, who has recently split from his wife, is admitted via ambulance. He was found virtually unarousable with a rapid respiratory rate by colleagues a few hours after he told them to go to a local parts supplier and leave him alone at the garage. There is no particular past medical history of note, and a recent routine blood screening test by an insurance company was normal.

Investigations:

Hb	14.1 g/dl
WCC	10.2×10^9/l
PLT	230×10^9/l
Na^+	140 mmol/l
K^+	5.0 mmol/l
Cl^-	104 mmol/l
Creatinine	230 µmol/l
Bicarb	13.0 mmol/l

Which of the following is the most likely diagnosis?

A	Diabetic ketoacidosis
B	Aspirin poisoning
C	Ethylene glycol poisoning
D	Ethanol poisoning
E	Lactic acidosis

Mute Start Video Share Content Participants 3 More

STC 11:07 PM 66%
594-042-7551
15:06
Leave

C Ethylene glycol poisoning

The most likely diagnosis is ethylene glycol poisoning; given that this man is a garage manager, it would be expected that he has easy access to the material. Ethylene glycol poisoning results in a high anion gap metabolic acidosis, accompanied by hyperventilation then Kussmaul respiration, decreased consciousness level and eventually coma, kidney disease and death. Management involves either sedation and infusion of ethanol, which is a competitive inhibitor of alcohol dehydrogenase, or the use of fomepizole. Kidney disease with this degree of creatinine elevation is likely to require haemodialysis.

A Diabetic ketoacidosis

Although this does result in raised anion gap metabolic acidosis, access to ethylene glycol and the motive for overdose make this the greater concern.

B Aspirin poisoning

At this point, compensated metabolic acidosis with hyperventilation would be expected in aspirin poisoning.

D Ethanol poisoning

Ethanol poisoning is much less likely to result in kidney disease and acidosis than ethylene glycol overdose.

E Lactic acidosis

Lactic acidosis is seen in metformin toxicity and where

Mute Start Video Share Content Participants 3 More

A 50-year-old builder has been referred as an emergency, having been rescued from his burning flat. He has evidence of smoke inhalation, with soot around his nostrils and on the roof of his mouth. He has a carboxyhaemoglobin level of 4%, and since arrival in the department has had a decreased level of consciousness. He has no evidence of a head injury, and 800 µg of naloxone have not caused any increase in his conscious level. You consider the diagnosis of hydrogen cyanide poisoning. His blood pressure is 85/40 mmHg, with a pulse of 95/min and regular.

Which of the following is the most appropriate intervention?

A	N-acetylcysteine 150 mg/kg intravenous (IV) over 15 min
B	Dicobalt edetate 300 mg IV over 1 min
C	Methylene blue 1–2 mg/kg IV over 5 min
D	Flumazenil 200 µg IV over 15 s
E	Pralidoxime 30 mg/kg IV over 5–10 min

Submit

Rana Alnasser's screen

B Dicobalt edetate 300 mg IV over 1 min

Cyanide can be produced in house fires, when materials such as polyurethane and rubber combust. Cyanide binds with high affinity to cytochrome a3 of the mitochondrial electron transport chain and thereby prevents the utilisation of oxygen at a cellular level. With low levels, the body is able to naturally detoxify cyanide compounds via the enzyme rhodanese (a sulphur transferase), which relies on the presence of sulphur-containing substrate. Dicobalt edetate, sodium thiosulphate and sodium nitrite are all recognised treatments for cyanide poisoning.

A N-acetylcysteine 150 mg/kg intravenous (IV) over 15 min

N-Acetylcysteine and methionine are glutathione donors used in the treatment of paracetamol poisoning.

C Methylene blue 1–2 mg/kg IV over 5 min

Methylene blue is used as a treatment for methaemoglobinaemia, with ascorbic acid a second-line therapy for methaemoglobinaemia.

D Flumazenil 200 µg IV over 15 s

Flumazenil is a benzodiazepine antagonist licensed for the treatment of iatrogenic overdose.

E Pralidoxime 30 mg/kg IV over 5–10 min

Pralidoxime is used in conjunction with atropine to reduce the parasympathetic effects of organophosphate poisoning.

STC 11:10 PM 65%
594-042-7551
18:30
Leave

A 22-year-old man is admitted to hospital with bone pain after a recent chest infection. He has sickle cell disease and over the past few years has had increased admissions to hospital with severe bone pain episodes.

The patient is interested in treatment that would decrease the frequency of admissions to hospital with these pain episodes.

What is the most appropriate treatment?

A	Morphine
B	Pethidine
C	Hydroxyurea
D	Penicillin
E	Frequent exchange transfusions

Submit

Previous Q... Skip Questi...

Mute Start Video Share Content Participants 3 More

C Hydroxyurea

Hydroxyurea is thought to act by increasing the production of fetal haemoglobin, which is less likely to sickle and it has been shown to decrease the frequency of admissions with pain episodes. It is also used in chronic myeloid leukaemia. Side-effects include bone marrow toxicity, gastrointestinal disturbance and skin rashes.

A Morphine

Although morphine is entirely appropriate used acutely for painful crisis, used over the longer term, chronically, it runs a high risk of driving addiction.

B Pethidine

Pethidine has a potentially more rapid onset of action than morphine, and therefore runs an even greater risk of addiction.

D Penicillin

Penicillin is recommended as prophylaxis for infection because of hyposplenism related to sickle cell, but will not significantly reduce the risk of painful chest crises.

E Frequent exchange transfusions

Exchange transfusion may be considered in patients with significant chest crisis, or where there is a vaso-occlusive event such as a stroke. It is a secondary intervention for the long term in patients who fail to respond to interventions such as hydroxyurea.

Rana Alnasser's screen

A 22-year-old woman, who is taking paroxetine for depression, has an argument with her mother and has been seen searching through the medications cupboard in the bathroom. She is later found unresponsive on her bed.

On examination, she is drowsy; her temperature is 40.3 °C, and she has tachycardia, with a pulse of 140 bpm, and dilated pupils.

Motor examination reveals a tremor, clonus, hypertonicity and hyperreflexia.

Which of the following medications is most likely to be responsible?

A	Citalopram
B	Thyroxine
C	Risperidone
D	Bisoprolol
E	Aspirin

Submit

Explanation

C	Risperidone

The correct answer is Risperidone (Option C).

Risperidone is the most likely medication from the options available to have been the culprit for the patient's symptoms. It is a well-recognised cause, particularly in combination with paroxetine, of serotonin syndrome.

A	Citalopram

Citalopram (Option A) is incorrect.

The patient has serotonin syndrome, as evidenced by hyperthermia, dilated pupils, muscular rigidity and hyperreflexia. Citalopram is relatively safe when taken in overdose, hence its common use as a first-line agent in the pharmacological treatment of depression.

B	Thyroxine

Thyroxine (Option B) is incorrect.

Thyroxine does not cause serotonin syndrome. In overdose, thyroxine typically causes tachycardia, agitation, sweating, diarrhoea and hypertension. It takes about 48 h for the symptoms to develop, as thyroxine must first be converted peripherally to its active form tri-iodothyronine.

D	Bisoprolol

Bisoprolol (Option D) is incorrect.

Beta-blocker toxicity can produce bradycardia, hypotension, arrhythmias, hypothermia and hypoglycaemia, as well as seizures. Depending on the severity, the clinical presentation may range from

You attend a fire at a large chemical factory as the first response doctor. The factory manufactures various types of polyurethane foams. A 45-year-old man is removed from the main part of the factory complaining of chest tightness and dizziness.

You examine him and there are signs of pulmonary oedema. A tight-fitting facemask and high-flow oxygen are applied. He quickly deteriorates and suffers a respiratory arrest. He is intubated and ventilated.

Given the likely cause for his deterioration, which of the following actions would be the most appropriate next step?

A	Give furosemide 80 mg IV bolus
B	Give dicobalt edetate 300 mg IV
C	Give sodium nitrate IV bolus
D	Give adrenalin IV
E	Start a glyceryl trinitrate (GTN) IV infusion

Submit

Rana Alnasser's screen

B Give dicobalt edetate 300 mg IV

This man is involved in a fire at a polyurethane foams factory. Presentation with this clinical scenario may fit with cyanide poisoning, either through inhalation or through substantial skin contamination. Dizziness and confusion may be rapidly followed by chest tightness, pulmonary oedema, paralysis and eventual cardiovascular collapse. Treatment of choice is dicobalt edetate 300 mg IV bolus, which may be repeated three times depending on response.

A Give furosemide 80 mg IV bolus

The signs of pulmonary oedema may be related to ARDS or due to circulatory failure as a result of cyanide poisoning, and furosemide will not be effective.

C Give sodium nitrate IV bolus

Sodium nitrite, not sodium nitrate, is utilised as a second-line intervention for cyanide poisoning.

D Give adrenalin IV

Adrenalin is ineffective in the presence of a metabolic poison such as cyanide. It is the time to delivery of dicobalt edetate that is most closely related to patient survival.

E Start a glyceryl trinitrate (GTN) IV infusion

Circulatory collapse as a result of cyanide poisoning is imminent; GTN is only really effective in the acute situation in managing hypertensive heart failure.

Rate this question:

Explanation

B IV Normal saline should be started

Where lithium levels are >3 mmol/l, normal saline should be instigated, particularly here given the hypotension and tachycardia.

A IV 5% dextrose should be started

In this situation normal saline is preferred as IV fluid replacement to 5% dextrose.

C Activated charcoal should be given

Activated charcoal is not effective after lithium overdose, although gastric lavage can be considered in some patients, European guidelines recommend within the first 1-2 h, although anecdotal reports suggest benefit up to 6-8 h.

D NSAIDs may be useful in reducing lithium levels

NSAIDs actually lead to an increase in lithium levels.

E Gastric lavage should be commenced

Given the time period elapsed, gastric lavage is not likely to be useful in this scenario.

Rate this question:

Next Question

B Dilated cardiomyopathy

Anthracycline cytotoxic agents such as doxorubicin are frequently used as antitumour agents to treat acute leukaemia, lymphomas and a variety of solid tumours. There is an association between overall dose given (cumulative effect) and dilated cardiomyopathy. Therefore, it is recommended that patients undergoing such treatments should have a baseline assessment of their heart with either an echocardiogram or a radionuclide ejection fraction measurement. According to the Summary of Product Characteristics, contraindications to doxorubicin include severe arrhythmia, heart failure, previous cardiac infarct and acute inflammatory heart disease. The negative effects on cardiac function may be synergistic when agents such as Herceptin, an HER-2 antagonist, are co-prescribed.

A Acute coronary syndrome

Her ECG shows non-specific ST segment changes and does not support a diagnosis of myocardial infarction.

C Neutropaenic sepsis

Neutropenia usually presents at 10–14 days post chemotherapy, and would not necessarily precipitate an episode of cardiac failure.

D Metastatic disease

Although metastatic disease may result in lymphangitis carcinomatosa, presenting with crackles on auscultation of the chest, the clinical picture here, is more consistent with cardiac failure.

Rana Alnasser's screen

STC 11:22 PM 60%
594-042-7551
30:02
Leave

A 32-year-old patient is admitted with a sudden onset severe headache in the occipital region followed by neck pain and neck stiffness. The patient is hypertensive with a blood pressure (BP) of 185/110, pulse is 95 and regular. He has marked meningism.

A computed tomography (CT) brain scan is normal and a lumbar puncture conducted a few hours after the pain began results in a bloody tap with xanthochromia.

What medical therapy should be commenced?

A	Labetalol
B	Nimodipine
C	Ticagrelor
D	Sodium nitroprusside
E	Doxazosin

Submit

Mute Start Video Share Content Participants 3 More

B Nimodipine

Nimodipine is a calcium-channel blocker that is used in the treatment of subarachnoid haemorrhage. It reduces cerebral artery vasospasm and has been shown in randomised controlled trials to be associated with reduced ischaemic neurological deficit.

A Labetalol

Labetalol is effective in blood pressure management of SAH and can be used in the event that BP is not controlled on nimodipine alone.

C Ticagrelor

Ticagrelor is an anti-platelet agent used to reduce the risk of myocardial infarction in high risk individuals.

D Sodium nitroprusside

Sodium nitroprusside has a greater effect in reducing peripheral vascular resistance versus cerebral vasospasm, hence it may actually worsen blood supply to compromised areas of the brain.

E Doxazosin

Calcium channel blockers and beta blockers are usually used in preference to alpha blockers for BP control in this instance.

Rate this question:

Next Question

A 34-year-old, schizophrenic newsagent has been transferred from the Psychiatric Unit to the Acute Medical Ward after staff became concerned with his physical state. His consciousness level has deteriorated through the day, he is rigid, has an axillary temperature of 38.5 °C, and is hypotensive with a systolic reading of 95 mmHg. You consider that the signs may be secondary to his medication.

Investigations:

Hb	13.2 g/dl
WCC	10.4×10^9/l
PLT	201×10^9/l
Na^+	144 mmol/l
K^+	6.0 mmol/l
Bicarbonate	19 mmol/l
Creatinine	192 µmol/l
Glucose	4.9 mmol/l
Calcium	2.1 mmol/l
Albumin	39 g/l
Electrocardiogram (ECG)	Sinus rhythm, no acute changes

Given the likely diagnosis, what would be the most appropriate initial management?

A 50 ml IV 50% dextrose

B 800 µg IV naloxone

Rana Alnasser's screen

C 10 ml IV calcium gluconate

Investigations:

Hb	13.2 g/dl
WCC	10.4×10^9/l
PLT	201×10^9/l
Na^+	144 mmol/l
K^+	6.0 mmol/l
Bicarbonate	19 mmol/l
Creatinine	192 µmol/l
Glucose	4.9 mmol/l
Calcium	2.1 mmol/l
Albumin	39 g/l
Electrocardiogram (ECG)	Sinus rhythm, no acute changes

Given the likely diagnosis, what would be the most appropriate initial management?

A 50 ml IV 50% dextrose

B 800 µg IV naloxone

C 10 ml IV calcium gluconate

D 1 litre IV normal saline

E 1 mg IV glucagon

Rana Alnasser's screen

STC 11:24 PM 59%
594-042-7551
32:25
Leave

D 1 litre IV normal saline

This patient's symptoms are consistent with neuroleptic malignant syndrome which is seen in 1% of patients receiving conventional antipsychotic medication; features include fluctuating consciousness levels, autonomic instability, pyrexia and muscle rigidity. Rhabdomyolysis can occur, leading to kidney disease due to myoglobin precipitation in the kidneys and direct toxicity causing acute tubular necrosis. Treatment is mainly supportive, with strict monitoring of fluid balance, monitoring urine output and correcting for insensible losses. In the first instance 1 litre of IV fluid will support his blood pressure and may well reduce potassium.

A 50 ml IV 50% dextrose

At this stage, with a glucose of 4.9 mmol/l, there is no need to replace glucose IV.

B 800 µg IV naloxone

Naloxone has a role in reversing symptoms of opiate overdose, and as such it does not have a significant part to play in the treatment of neuroleptic malignant syndrome.

C 10 ml IV calcium gluconate

Although calcium replacement may be required (related to rhabdomyolysis), in the first instance IV crystalloid to support blood pressure and renal function is the most important initial intervention.

Unmute Start Video Share Content Participants 3 More

Investigations:

Na^+	139 mmol/l
K^+	3.1 mmol/l
Creatinine	145 µmol/l

Potassium replacement is commenced.

Which of the following is the most appropriate next step?

A Switch antibiotics to ciprofloxacin

B Verapamil IV

C Propranolol IV

D Sotalol IV

E Oral- activated charcoal

© Pastest 2019

Rana Alnasser's screen

B Verapamil IV

This man has theophylline toxicity, most likely as a result of his course of clarithromycin. Macrolide and quinolone antibiotics are known to increase plasma theophylline levels because of CYP450 inhibition. Although beta blockers can be used in stable COPD, in this situation there may be some reversibility, making verapamil the better option for controlling his SVT than sotalol or propranolol.

A Switch antibiotics to ciprofloxacin

Ciprofloxacin is also recognised to increase theophylline levels, and it is therefore not of value to switch antibiotics here.

C Propranolol IV

Although propranolol will reduce the risk of further episodes of SVT, it may result in clinically significant bronchoconstriction in a patient with unstable airways disease.

D Sotalol IV

Like propranolol, sotalol may promote worsening of airways disease in this situation and should be avoided.

E Oral- activated charcoal

Activated charcoal is of value in the treatment of theophylline overdose, although treatment of the SVT is the most pressing next step, and vomiting may limit its effectiveness in this situation.

A 64-year-old man, who is taking long-term amiodarone therapy for recurrent episodes of ventricular tachycardia, presents to the clinic with symptoms of weight loss and heat intolerance. His daily medication is ramipril 10 mg, aspirin 75 mg and amiodarone 200 mg.

On examination, he is tachycardic with a pulse of 95/min, and his BP is 105/70 mmHg. He has evidence of mild left ventricular failure. There is no evidence of goitre.

Investigations:

Hb	11.5 g/dl
WCC	5.6×10^9/l
PLT	245×10^9/l
Na^+	139 mmol/l
K^+	5,0 mmol/l
Creatinine	135 mmol/l
TSH	< 0.05 U/l
Thyroid autoantibody	-
Thyroid isotope uptake scan	Low uptake
Thyroid Doppler ultrasound	Decreased blood flow

Which of the following represents the most likely diagnosis?

A Graves' disease

B Multinodular goitre

C Amiodarone-induced thyrotoxicosis (AIT) type 1

Rana Alnasser's screen

D Amiodarone-induced thyrotoxicosis (AIT) type 2

NC ···
ınd × 404 — Not Found × Home Feed | Re × MyPastest × Rana
https://mypastest.pastest.com/Secure/TestMe/Browse

Investigations:

Hb	11.5 g/dl
WCC	5.6×10^9/l
PLT	245×10^9/l
Na^+	139 mmol/l
K^+	5,0 mmol/l
Creatinine	135 mmol/l
TSH	< 0.05 U/l
Thyroid autoantibody	-
Thyroid isotope uptake scan	Low uptake
Thyroid Doppler ultrasound	Decreased blood flow

Which of the following represents the most likely diagnosis?

A Graves' disease

B Multinodular goitre

C Amiodarone-induced thyrotoxicosis (AIT) type 1

D Amiodarone-induced thyrotoxicosis (AIT) type 2

E Thyroid carcinoma

D Amiodarone-induced thyrotoxicosis (AIT) type 2

Amiodarone thyrotoxicity tends to result in two distinct patterns of disease associated with thyrotoxicosis. Type 2 is a destructive thyroiditis, and this explains the findings here with low thyroid uptake and decreased thyroid blood flow on Doppler ultrasound. AIT type 2 does not respond well to standard therapy for thyrotoxicosis. It may burn itself out after a course of corticosteroids; hence, as the amiodarone cannot be easily discontinued, a course of corticosteroids is most appropriate and is the therapy of choice.

A Graves' disease

Graves' disease is associated with positive thyroid auto-antibodies and increased thyroid uptake.

B Multinodular goitre

The lack of evidence of goitre effectively counts against a diagnosis of multinodular goitre here.

C Amiodarone-induced thyrotoxicosis (AIT) type 1

Type 1 is related to the excess iodine provided by amiodarone leading to excess production of thyroid hormone, often in the presence of latent thyroid disease related to another cause.

E Thyroid carcinoma

A specific thyroid mass would be elucidated on both the ultrasound scan and isotope investigation, and neither has raised a concern here.

Rana Alnasser's screen

Calculator

Normal Values

A 24-year-old patient with sarcoidosis is admitted with diarrhoea. She has been previously fit and well and her sarcoid has been stable. Currently, she is under the Dermatologists for the management of a painful rash on her left leg.

While an in-patient, the diarrhoea clears up and the stool cultures come back as negative. She recalls the Dermatologists commencing her on medication for the painful rash but cannot remember its name and didn't bring the tablets with her to hospital.

What is the most likely medication commenced by the Dermatology Department?

A Colchicine

B Prednisolone

C Aspirin

D Dapsone

E Potassium iodide

Submit

A Colchicine

Colchicine is occasionally used for the treatment of erythema nodosum where it is particularly painful or disfiguring. It is the only one of the options to cause significant diarrhoea, making it the most likely answer here. Other causes of erythema nodosum include streptococcal infection, tuberculosis, Salmonella, Campylobacter, histoplasmosis, ulcerative colitis and Crohn's disease, sulphonamides, Behçet's disease and pregnancy.

B Prednisolone

Although prednisolone is used for the treatment of sarcoidosis, it would not be expected to cause diarrhoea.

C Aspirin

Aspirin is not used as a treatment for erythema nodosum or in the treatment of sarcoidosis, it is therefore not the correct answer here.

D Dapsone

Dapsone is an alternative treatment for erythema nodosum but is not a prominent cause of diarrhoea.

E Potassium iodide

This is used as a topical therapy for the treatment of erythema nodosum and would therefore not lead to any GI toxicity.

Rate this question:

Calculator

Normal Values

A 55-year-old man is admitted to the ward with haematemesis. He has a background of diabetes, hypertension, angina and peripheral vascular disease. Over the past few days, he had been complaining of increasing lethargy and worsening angina.

Investigations:

Hb	7.8 g/dl
WCC	53×10^9/l
PLT	25×10^9/l
PT	38 s
APTT	70 s
Fibrinogen degradation products	700 mg/l (<100)
Blood film	Circulating blasts cells with a hypergranular cytoplasm
Cytogenics-t	15 : 17

A derivative of which vitamin would be most beneficial in this patient after the initial coagulopathy is managed with blood product replacement?

A Vitamin A

B Vitamin C

C Vitamin D

D Vitamin E

E Vitamin K

Rana Alnasser's screen

A Vitamin A

Acute promyelocytic leukaemia (APL) is a special subtype of AML, sometimes called 'M3'. APL differs from other subtypes of AML in that patients are, on average, younger (median age 40 years) and most often present with pancytopenia rather than with elevated WBC counts. In fact, WBC counts > 5000 cells/µl at presentation are associated with a poor prognosis. The DIC itself should be treated with platelet transfusion, FFP ± cryoprecipitate. Acute promyelocytic leukaemia can present with disseminated intravascular coagulation, as in the above case, and is indeed the form of AML most commonly associated with this phenomenon. The typical translocation t(15 : 17) involves the retinoic acid receptor gene and, as a result, this form of acute leukaemia responds to all-trans-retinoic acid (ATRA). A small percentage of patients with different cytogenetic forms of acute promyelocytic leukaemia can be resistant to ATRA treatment. ATRA is a derivative of vitamin A.

B Vitamin C

Vitamin C is used as a treatment for methaemoglobinaemia in patients who fail to respond to methylene blue, or where it is unavailable.

C Vitamin D

Vitamin D analogues are used for the treatment of psoriasis, and vitamin D itself is used as a treatment of osteomalacia.

D Vitamin E

Vitamin E is used in combination with pioglitazone for the treatment of non-alcoholic steatohepatitis.

Calculator

Normal Values

A 75-year-old woman, who lives in a nursing home, was found by her carers to have a sacral sore with a large slough on the base, and the surrounding skin was somewhat macerated.

A past history of dense, left-sided hemiplegia following a stroke has left her largely bed-bound.

MRSA swabs are positive.

Which of the following is the most appropriate dressing for the pressure sore?

A	Saline soaks
B	Hydrocolloid gel
C	Calcium alginate
D	Absorbent cotton
E	Silver- based dressing

Submit

Previous Q... Skip Questi...

Rana Alnasser's screen

C Calcium alginate

A few trials investigated hydrocolloid gel dressings alone versus calcium alginate followed by hydrocolloid. One such study is published in the *Journal of the American Geriatrics Society*, Volume 50, Issue 2 (269-274), and suggests that healing rates are significantly better when the alginate gel is used first. As such, this drives calcium alginate as the preferred choice here.

E Silver- based dressing

Silver-based dressings are a standard approach for the treatment of burns.

A Saline soaks

These will not deal with the significant slough overlying the pressure sore.

B Hydrocolloid gel

These dressings have been shown in trials to be less effective than alginate, and would therefore be an alternative rather than a preferred option.

D Absorbent cotton

This will not deal with the slough and should therefore be avoided here.

Rate this question:

Next Question

Calculator

Normal Values

A 22-year-old medical student is brought to the Emergency Department by ambulance. She was found collapsed in her bedroom the morning after a university freshers' ball.

On examination, she is drowsy and confused. Her temperature is 39.2 °C, blood pressure (BP) 145/80 mmHg. On further questioning, her friends admitted that she avoids alcohol but does take Ecstasy.

Investigations:

Sodium (Na^+)	148 mmol/l
Potassium (K^+)	5.6 mmol/l
Creatinine (Cr)	210 µmol/l
Urea	19.1 mmol/l
Alanine transaminase (ALT)	42 U/l
Bilirubin	48 µmol/l
Prothrombin time (PT)	12.1 s
Urine	Blood+++ on dipstick, microscopy no red cells

Which of the features noted is most associated with a poor outcome?

A Creatinine 210 µmol/l

B Temperature 39.2 °C

C ALT 42U/l

D Potassium 5.6 mmol/l

Rana Alnasser's screen

On further questioning, her friends admitted that she avoids alcohol but does take Ecstasy.

Investigations:

Sodium (Na^+)	148 mmol/l
Potassium (K^+)	5.6 mmol/l
Creatinine (Cr)	210 µmol/l
Urea	19.1 mmol/l
Alanine transaminase (ALT)	42 U/l
Bilirubin	48 µmol/l
Prothrombin time (PT)	12.1 s
Urine	Blood+++ on dipstick, microscopy no red cells

Which of the features noted is most associated with a poor outcome?

A Creatinine 210 µmol/l

B Temperature 39.2 °C

C ALT 42U/l

D Potassium 5.6 mmol/l

E BP 145/80 mmHg

Submit

A Creatinine 210 µmol/l

This woman is suffering from Ecstasy toxicity. Poor prognostic indicators in Ecstasy overdose include hyperpyrexia (>42 °C), rhabdomyolysis (as evidenced here by myoglobinuria), kidney disease and liver failure. In this case, the creatinine of 210 µmol/l already implies insipient kidney disease related to rhabdomyolysis.

Most deaths from Ecstasy are due to hyperthermia and complications of hypertension and DIC, such as cerebral infarction or haemorrhage. Management of the hyperpyrexia is with rapid convection cooling, in an attempt to reduce core temperature to below 38.3 °C. Agitation is managed with the use of benzodiazepines, IV rehydration is used to manage rhabdomyolysis, and IV agents such as nitroprusside, which can be easily titrated, are optimal in the management of hypertension.

B Temperature 39.2 °C

Although pyrexia is associated with increased risk of rhabdomyolysis, worsening kidney disease and neurological sequelae, aggressive rehydration and cooling measures can minimise the potential impact on outcome.

C ALT 42U/l

This ALT value is in the normal range and wouldn't be considered as influencing prognosis.

D Potassium 5.6 mmol/l

Potassium is likely to fall with aggressive rehydration, and the value quoted here is only just above the upper limit of normal.

Rana Alnasser's screen

NC ···
und × 404 — Not Found × Home Feed | Re × MyPastest × Rana
https://mypastest.pastest.com/Secure/TestMe/Browse

Calculator
Normal Values

A 24-year-old man presents to the clinic. He has a 2-year history of rheumatoid arthritis, has been attending the hospital clinic for 6 months and is taking weekly methotrexate with folic acid coverage and diclofenac. For the past few days he has had a sore throat. On examination he is thin and looks anaemic; there are joint changes consistent with severe active rheumatoid arthritis. There is clear evidence of severe pharyngitis. Abdominal examination is unremarkable.

Investigations:

Hb	10.2 g/dl
White cell count	0.5×10^9/l
Platelets	45×10^9/l

Which of the following diagnoses fits best with this clinical picture?

A Chronic myeloid leukaemia

B Acute myeloid leukaemia

C Felty's syndrome

D Methotrexate- related marrow suppression

E Diclofenac- related marrow suppression

Rana Alnasser's screen

D Methotrexate- related marrow suppression

Methotrexate even when used weekly may be associated with neutropenia. Few researchers have attempted to estimate the incidence of neutropenia, although one paper from the *Journal of Postgraduate Medicine* puts it at around 1 in 58 patient-years of therapy. Methotrexate should be discontinued at least temporarily, with folinic acid started as rescue; granulocyte colony-stimulating factor (GCSF) has been investigated as a therapy to allow more rapid recovery of white cell count. His dose should of course be reviewed, and the possibility of diclofenac as a cause of reduced methotrexate excretion investigated.

A Chronic myeloid leukaemia

Chronic myeloid leukaemia is associated with a more chronic disease course, and hepatosplenomegaly.

B Acute myeloid leukaemia

Acute myeloid leukaemia is unlikely in this scenario, given we're already told about exposure to methotrexate, and other symptoms such as night sweats, anorexia, weight loss and easy bruising are absent.

C Felty's syndrome

Felty syndrome is associated with splenomegaly, which is absent here.

E Diclofenac- related marrow suppression

Diclofenac reduces methotrexate excretion, leading to increased risk of methotrexate toxicity, but doesn't itself cause bone marrow suppression.

NC ···
ınd × | 404 — Not Found × | Home Feed | Re × | MyPastest × | Rana
https://mypastest.pastest.com/Secure/TestMe/Browse

A 32-year-old woman presented to the clinic with symptoms of inflammatory bowel disease. Rectal biopsy was consistent with a diagnosis of ulcerative colitis and she is commenced on treatment.

Other past history of note included mild epilepsy which is managed with lamotrigine, and hypertension, managed with amlodipine. She next presents to the Emergency room with severe acute epigastric pain and vomiting.

On examination, she is pyrexial 37.8 °C and has severe epigastric pain. Her blood pressure (BP) is 100/60 mmHg and her pulse is 105/min.

Investigations:

		Normal Values
Hb	11.9 g/dl	
WCC	13.1×10^9/l	
PLT	209×10^9/l	
Na^+	140 mmol/l	
K^+	4.5 mmol/l	
Creatinine	141 µmol/l	
Amylase	1230 u/l	60/180

Which of the following is the most likely cause?

A Amlodipine

B Lamotrigine

STC 11:49 PM 50%
594-042-7551
17:23
Leave

with severe acute epigastric pain and vomiting.

On examination, she is pyrexial 37.8 °C and has severe epigastric pain. Her blood pressure (BP) is 100/60 mmHg and her pulse is 105/min.

Investigations:

		Normal Values
Hb	11.9 g/dl	
WCC	13.1 × 10^9/l	
PLT	209 × 10^9/l	
Na^+	140 mmol/l	
K^+	4.5 mmol/l	
Creatinine	141 µmol/l	
Amylase	1230 u/l	60/180

Session Progres

Responses Correct:

Responses Incorrect:

Responses Total:

Responses - % Correct

Which of the following is the most likely cause?

Your answer was correct

A Amlodipine

B Lamotrigine

C Paracetamol

D Mesalazine

E Loperamide

Explanation

Mute Start Video Share Content Participants More

D Mesalazine

5-ASA compounds are associated with the development of acute pancreatitis, as are azathioprine, sodium valproate, furosemide, oestrogens, corticosteroids and octreotide. Other drugs thought to be associated include metronidazole, thiazide diuretics, cimetidine and cisplatin. In this case it is likely that she was started on mesalazine in conjunction with her diagnosis of ulcerative colitis, and this precipitated her presentation with pancreatitis.

A Amlodipine

Although cases of pancreatitis in association with amlodipine therapy have been reported, the risk is thought to be less than that for 5-ASA compounds.

B Lamotrigine

Sodium valproate, not lamotrigine, is associated with increased risk of acute pancreatitis.

C Paracetamol

Paracetamol is associated with hepatotoxicity when used to excess, not with pancreatitis.

E Loperamide

Loperamide is an opioid receptor agonist which does not significantly impact on risk of pancreatitis.

Rate this question:

Next Question

Rana Alnasser's screen

Calcu

Normal

A 50-year-old man with longstanding type 1 diabetes managed with NovoRapid tds and insulin glargine. He comes to the clinic for assessment, his HbA1c is not well managed at 67.21 mmol/mol (8.3%) and he has had a number of episodes of hypoglycaemia. Medication includes ramipril 10 mg daily and bendroflumethiazide 2.5 mg daily. Additionally, he has had three fainting attacks in the past three months.

You measure his lying and standing blood pressure: lying it is 155/102 mmHg, but this drops to 105/60 mmHg on standing. Routine U&E reveal a sodium of 138 mmol/l, and potassium of 4.5 mmol/l.

Which of the following is the most appropriate way to manage his blood pressure?

A	Oral hydrocortisone
B	Compression stockings
C	Oral fludrocortisone
D	Stop ramipril
E	Stop bendroflumethiazide

Submit

STC 11:51 PM 49%
594-042-7551
19:25
Leave

E Stop bendroflumethiazide

It seems that he has a significant postural drop in blood pressure (BP), which is almost certainly related to diabetic autonomic neuropathy. The fact that his standing blood pressure is normal puts him into a lower risk cardiovascular group, and stopping the bendroflumethiazide is likely to have a significant positive impact on his symptoms.

B Compression stockings

Compression stockings are the logical next intervention where the patient fails to respond to discontinuation of the bendroflumethiazide.

A Oral hydrocortisone

In this context long-term oral hydrocortisone would never be considered to have a positive benefit risk profile.

C Oral fludrocortisone

Oral fludrocortisone is only considered when postural hypotension persists despite discontinuing bendroflumethiazide and conservative measures such as compression stockings.

D Stop ramipril

Given that ramipril has proven outcome benefits in patients with diabetes, it should not be discontinued.

Rate this question:

Unmute Start Video Share Content Participants More

Calcu

Normal

A 45-year-old patient is referred from the rheumatology unit. He was being treated for gout. He gave a history of progressive weakness of his limbs over 2 months. He noticed that it was particularly difficult for him to get up from the toilet seat and to get out of his car. He also felt some tingling and numbness of his toes, which was distressing at night. He was taking several medications that included ibuprofen, perindropril, colchicine, vitamin supplements and indapamide.

On examination, his pulse was 85/min, blood pressure 140/90 mmHg and fundi revealed arteriovenous nipping. He had proximal lower limb weakness of 4/5 and absent ankle reflexes. Plantars were flexors. His serum creatinine phosphokinase level was 3 times the upper limit of normal.

What is the most likely diagnosis?

A	Thyroid myopathy
B	Limb girdle muscular dystrophy
C	Multiple sclerosis
D	Colchicine-related side effects
E	Perindopril- related side effects

Submit

STC 11:54 PM 48%
594-042-7551
22:09
Leave

D Colchicine-related side effects

This clinical scenario suggests a myoneuropathy and is most likely to be have been caused by colchicine. This drug gives rise to a subacute proximal muscle weakness and, on occasions, can lead to an acute necrotising myopathy. Creatine phosphokinase may be normal or elevated. In the former situation metabolic myopathies should be ruled out. The muscle biopsy shows elements of both myopathic and neuropathic disease. The special features in the histopathology are rimmed vacuoles in the muscle fibres on Gomori staining. The mechanism is not fully understood, but is attributable to probable interference of the drug with tubulin, a protein required for the polymerisation of microtubules in muscle and nerve tissues. Weakness resolves when the drug is discontinued, but the neuropathic features remain.

A Thyroid myopathy

Apart from proximal myopathy, there are no other features to suggest hypo- or hyperthyroidism.

B Limb girdle muscular dystrophy

Limb girdle muscular dystrophy is associated with proximal myopathy without the sensory changes seen here. Cardiomyopathy is also seen in some of the variants of limb girdle muscular dystrophy.

C Multiple sclerosis

Multiple sclerosis is more likely to be associated with patchy demyelination leading to both sensory and motor loss, rather than the symmetrical pattern of neuropathy

Unmute Start Video Share Content Participants More

Calcu

Normal

A 24-year-old woman presents to her general practitioner (GP) with a 4-day history of diarrhoea and vomiting. She has been unable to keep fluids down for four days and is given metoclopramide by her GP; she then suffers a dystonic reaction.

Which of the following drugs represents the most appropriate treatment for her?

A	Procyclidine
B	Prochlorperazine
C	Domperidone
D	Sumatriptan
E	Ondansetron

6569

Submit

Previous Q... Skip Questi...

© Pastest 2019

A Procyclidine

Acute dystonic reactions may follow administration of metoclopramide or prochlorperazine and neither is recommended for the treatment of nausea in young women. Spasmodic torticollis, trismus and oculogyric crises occur. These respond promptly to administration of procyclidine (an anti-cholinergic agent). Both the offending agent and those from the same group should be avoided subsequently.

B Prochlorperazine

Prochlorperazine is also associated with acute dystonic reactions, like metoclopramide; use in young women is therefore not recommended.

C Domperidone

Domperidone is a peripherally selective D2 receptor antagonist; it is therefore much more rarely associated with acute dystonic reactions.

D Sumatriptan

Sumatriptan is used as an intervention for migraine, and is a 5HT agonist.

E Ondansetron

Ondansetron is a 5HT antagonist used for the treatment of nausea in this patient group without risk of causing acute dystonia.

Rate this question:

Rana Alnasser's screen

Calcu

Normal

A 32-year-old woman has been referred to the General Medical Clinic with persisting dysuria.

Since returning from a long trip around Africa, she has continued pain on passing urine and has recently noticed haematuria towards the end of micturition. She otherwise feels well.

The general practitioner (GP) has tried a couple of antibiotics with no improvement of her symptoms.

Investigations reveal:

		Normal Values
Hb	13.4 g/dl	
WCC	11.5×10^9/l	
Neutrophils	7×10^9/l	$1.5–7.0 \times 10^9$/l
Lymphocytes	3.1×10^9/l	$1.5–4.0 \times 10^9$/l
Eosinophils	1.3×10^9/l	$0.04–0.4 \times 10^9$/l
Basophils	0.1×10^9/l	$0–0.1 \times 10^9$/l
PLT	252×10^9/l	
Urine sample microscopy	Schistosome eggs	

What is the appropriate treatment?

A Metronidazole

B Mebendazole

C Praziquantel

Rana Alnasser's screen

		Normal Values
Hb	13.4 g/dl	
WCC	$11.5 \times 10^9/l$	
Neutrophils	$7 \times 10^9/l$	$1.5–7.0 \times 10^9/l$
Lymphocytes	$3.1 \times 10^9/l$	$1.5–4.0 \times 10^9/l$
Eosinophils	$1.3 \times 10^9/l$	$0.04–0.4 \times 10^9/l$
Basophils	$0.1 \times 10^9/l$	$0–0.1 \times 10^9/l$
PLT	$252 \times 10^9/l$	
Urine sample microscopy	Schistosome eggs	

What is the appropriate treatment?

A Metronidazole

B Mebendazole

C Praziquantel

D Nifurtimox

E Niclosamide

Submit

Explanation

C Praziquantel

The patient has urinary schistosomiasis, most likely caused by *Schistosoma haematobium*. Diagnosis is made with the raised eosinophils and the schistosome eggs in the urine. Other forms of schistosomiasis (*Schistosoma mansoni*, *Schistosoma japonicum*) affect the portal venous system, the lung and the central nervous system. It is a disease of the tropics and treated with praziquantel. With urinary schistosomiasis there is an increased risk of bladder cancer.

A Metronidazole

It will treat amoebic dysentery and amoebic liver abscesses (*Entamoeba histolytica*) and is also used in the treatment of giardiasis.

B Mebendazole

This is used to treat the roundworm *Ascaris lumbricoides*; this remains asymptomatic in many cases.

D Nifurtimox

Nitrofurimox is used to treat *Trypanosoma cruzi*, the organism responsible for causing Chagas disease.

E Niclosamide

Niclosamide is used to treat tapeworm infections, which may be asymptomatic or present with iron deficiency anaemia ± GI disturbance.

Rate this question:

NC ···

und × | 404 – Not Found × | Home Feed | Re × | MyPastest ×

https://mypastest.pastest.com/Secure/TestMe/Browse

A 24-year-old school teacher has been admitted to the Emergency Medical Unit with diarrhoea and vomiting. Apparently, she became ill some two days earlier after eating a take-away burger and was unable to keep any food or water down at all. She was given an antiemetic intravenously by the paramedic crew, and is now having involuntary spasms of her head and neck, with upward rolling movements of her eyes.

On examination, she looks distressed. Her blood pressure is 145/82 mmHg and her pulse is 84 bpm. She looks to have a left-sided torticollis and her jaw is held in spasm.

Which of the following is the most appropriate treatment to resolve her symptoms?

A	Metoclopramide
B	Domperidone
C	Trihexyphenidyl hydrochloride
D	Clozapine
E	Olanzapine

Calcu

Normal

Submit

Previous Q... Skip Questi...

C Trihexyphenidyl hydrochloride

This patient is suffering an oculogyric crisis, which is an acute dystonic reaction secondary to dopaminergic blockade at the basal ganglia. In this case, the offending pharmaceutical agent is probably metoclopramide. These types of dystonic reaction are mainly seen in young women, and can be treated by withdrawal of the drug and administration of procyclidine hydrochroride or trihexyphenidyl hydrochloride (formerly known as benzhexol). These are antimuscarinic drugs, often used in the treatment of parkinsonism. Because of the risk of acute dystonia, metoclopramide and prochlorperazine are not recommended for use in young women, with other agents such as cyclizine or domperidone being the preferred options.

A Metoclopramide

This is a dopamine antagonist antiemetic and is most likely to be the cause of this patient's presentation with an oculogyric crisis.

B Domperidone

Reports of oculogyric crisis do exist for domperidone, although they are far less frequent than for metoclopramide. It is not a treatment for oculogyric crisis.

D Clozapine

Clozapine is used for resistant psychosis and is an atypical antipsychotic agent.

E Olanzapine

This is a first-line atypical antipsychotic agent used in the

Rana Alnasser's screen

NC ···

ınd × | 404 – Not Found × | Home Feed | Re × | MyPastest ×

https://mypastest.pastest.com/Secure/TestMe/Browse

A 49-year-old woman is admitted with nausea and vomiting. She had also noticed the development of a skin rash on her left arm and mouth sores. While on the ward she had an episode of haematemesis. She has a background of rheumatoid arthritis and has recently been commenced on methotrexate.

On further questioning, she tells you that she has been taking the methotrexate daily.

Which of the following treatments is likely to be most effective in treating her symptoms?

A	Vitamin K
B	Folic acid
C	Calcium folinate
D	Vitamin B_{12}
E	Prednisolone

Calcu

Normal

Submit

Previous Q...

Skip Questi...

C Calcium folinate

The most likely diagnosis here is severe bone marrow suppression due to the methotrexate. Methotrexate is a dihydrofolate reductase inhibitor, which converts dihydrofolate to tetrahydrofolate. Calcium folinate (Leucovorin™), a derivative of tetrahydrofolate, by-passes the folate step blocked by methotrexate and can be used in the management of an overdose.

B Folic acid

Folic acid is ineffective as a treatment for methotrexate-related bone marrow suppression, because production of tetrahydrofolate is prevented.

A Vitamin K

Vitamin K is an option for reversal of warfarin therapy, as warfarin blocks the production of vitamin K-dependent clotting factors.

D Vitamin B_{12}

In this case vitamin B_{12} is ineffective in promoting bone marrow recovery because the ability to produce tetrahydrofolate is still impaired.

E Prednisolone

Corticosteroids are only of value in treating a rash related to acute drug reaction, and the distribution of the rash here, coupled with other symptoms, counts against this being an acute drug reaction.

Rate this question:

Calcu

Normal

A 32-year-old patient is admitted to hospital with increasing shortness of breath, cough, wheeze and chest tightness. He has a background of testicular cancer and mild asthma.

A chest X-ray is shown below.

What is the most likely cause of his respiratory symptoms?

A	Bleomycin
B	Busulfan
C	Methotrexate
D	Cyclophosphamide
E	Daunorubicin

Submit

Rana Alnasser's screen

A Bleomycin

Bleomycin is an antimitotic agent used for the treatment of testicular tumours. It is associated with pulmonary fibrosis, which fits with the presentation and chest X-ray (which demonstrates diffuse interstitial changes). A typical regimen for testicular cancer includes bleomycin, etoposide and a platinum-based agent.

B Busulfan

Busulfan is an alkylating agent not usually used in the treatment of testicular tumours. It is more commonly used in the treatment of chronic myeloid leukaemia and can lead to pulmonary fibrosis.

C Methotrexate

Methotrexate is a folate antagonist and is used often in combination to treat a variety of tumours. Side effects are mainly myelosuppression, hepatic fibrosis and lung fibrosis. Methotrexate is usually part of the chemotherapy regimen in patients with human chorionic gonadotrophin (HCG)-producing tumours, which are a subset of testicular carcinomas.

D Cyclophosphamide

Cyclophosphamide is an alkylating agent used for Wegener's granulomatosis and a wide spectrum of tumours. Side-effects include alopecia, nausea, vomiting, bone marrow suppression and haemorrhagic cystitis.

E Daunorubicin

Daunorubicin, like doxorubicin, is an antimitotic agent used for acute leukaemias and lymphomas. The class causes

A 22-year-old man is admitted to the ward with an infective exacerbation of his asthma.

While on the ward, he develops pain in his left flank that radiates down to his groin with associated dysuria.

Sodium (Na^+)	138 mmol/l
Potassium (K^+)	4.3 mmol/l
Urea	6.2 mmol/l
Creatinine (Cr)	65 µmol/l
Urinalysis	Hexagonal crystals
Kidney-ureter-bladder (KUB) X-ray	Area suspicious of a renal stone calculus seen in the region of the left vesico-ureteric junction

The patient passes the stone and is diagnosed with cystinuria. He is advised on diet, alkalinization of the urine and adequate hydration therapy. He is discharged but returns a few weeks later with similar symptoms.

What is the next best medical therapy?

A Allopurinol

B Furosemide

C Penicillamine

D Bendroflumethiazide

E Desferrioxamine

C Penicillamine

Penicillamine is effective at treating cystinuria, although it is usually reserved for patients who suffer persistent stones despite urinary alkalinisation because of issues around tolerability.

A Allopurinol

Allopurinol is useful in reducing symptoms of urate nephropathy.

B Furosemide

Furosemide inhibits calcium reabsorption and therefore increases the risk of calcium containing renal stones.

D Bendroflumethiazide

Bendroflumethiazide reduces urinary calcium excretion and therefore is of most value in patients with recurrent calcium containing kidney stones.

E Desferrioxamine

Desferrioxamine is used as an iron chelator rather than in the treatment of cystinuria.

Rate this question:

Next Question

NC ···

ınd × | 404 — Not Found × | Home Feed | Re × | MyPastest ×

https://mypastest.pastest.com/Secure/TestMe/Browse

Calc

Norma

A 23-year-old woman with childhood-onset epilepsy is admitted with a history of progressive unsteadiness for the past two days. She had quarrelled with her mother over something trivial whilst watching her regular TV show just before the onset of her symptoms. She had vomited several times after supper that night and had gone early to bed, and from the next day onwards she was feeling unsteady.

On examination she was drowsy but oriented. Pupils were normal and reactive. Ocular movements were full and a horizontal nystagmus was noted. Speech was dysarthric and a coarse tremor was evident. Tendon reflexes were brisk and she had a wide-based gait. There was a mild degree of gum hypertrophy on examination of her mouth and teeth.

Which one of these diagnostic procedures should be carried out next?

A	Serum phenytoin level
B	Magnetic resonance (MRI) imaging of the brain
C	Positron emission tomography (PET), imaging of the brain
D	Cerebrospinal fluid (CSF) examination
E	Electroencephalography (EEG)

A Serum phenytoin level

While now less commonly used as maintenance therapy in epilepsy, phenytoin is still used for the control of seizures, especially when there is a history of uncontrolled flurry of attacks, and her gum hypertrophy raises the possibility that this is what she is taking. In overdose, absorption from the gastrointestinal tract may be delayed and continue for as long as 60 h. Nausea and vomiting occur within 1–2 h of a substantial ingestion of phenytoin. The level of consciousness may be relatively well preserved, unlike barbiturate poisoning where a profound depression of the level of consciousness would be expected. Horizontal nystagmus is the *sine qua non* of phenytoin toxicity in this group of patients. Nystagmus occurs with a concentration of at least 20 mg/l (80 mmol/l), and ataxia occurs at levels of 30–40 mg/l (120–160 mmol/l).
Gastric lavage and activated charcoal should be considered if the patient presents within 1 h of a significant overdose. Phenytoin is highly protein bound and hence neither haemodialysis, peritoneal dialysis nor plasmapheresis is of value. Other MRCP phenytoin questions have focused on protein binding of phenytoin in patients with renal impairment. In this case the free fraction of phenytoin increases, leading to normal total phenytoin levels but symptoms of toxicity.

B Magnetic resonance (MRI) imaging of the brain

The proximity to an argument, coupled with the timing of vomiting, later the same evening followed by the development of horizontal nystagmus fits much better with phenytoin toxicity rather than a brainstem injury.

C Positron emission tomography (PET), imaging of the brain

PET imaging in the context of epilepsy would be most

Calc

Norma

A 74-year-old woman with a history of atrial fibrillation (AF), for which she is anticoagulated with warfarin, is referred to the Emergency Department by her general practitioner (GP). She has been treated with ciprofloxacin for a few days for a urinary tract infection, and has reported some bleeding from her gums when she cleans her teeth. There have been three episodes of vomiting, which she puts down to the UTI.

On examination in the Emergency Department, her blood pressure is 121/80 mmHg, her pulse is 75 bpm (AF), her chest is clear and her abdomen is soft and non-tender. There is some minor bruising on her shins, but otherwise the clinical examination is unremarkable. The international normalised ratio, checked with a point-of-care test, is 8.2. C-reactive protein is 12 mg/l and urine testing is normal.

Which of the following is the most appropriate intervention?

A	Withhold warfarin and give 0.5 mg intravenous (IV) vitamin K
B	Withhold warfarin and give 10 mg oral vitamin K
C	Withhold warfarin and give fresh frozen plasma
D	Withhold warfarin and give prothrombin complex concentrate
E	Withhold warfarin, stop ciprofloxacin and observe

Submit

Rana Alnasser's screen

A Withhold warfarin and give 0.5 mg intravenous (IV) vitamin K

Withhold warfarin and give 0.5 mg IV vitamin K is the correct answer. Even in the presence of no bleeding or minor bleeding, a small dose of vitamin K is recommended, with warfarin re-start once INR has fallen below 5.0.

B Withhold warfarin and give 10 mg oral vitamin K

Withhold warfarin and give 10 mg oral vitamin K is incorrect. Oral vitamin K is normally not preferred in the treatment of warfarin overdose because of the unpredictability of dosing versus the intravenous option. The vomiting here particularly guides us away from oral delivery of vitamin K.

C Withhold warfarin and give fresh frozen plasma

Withhold warfarin and give fresh frozen plasma is incorrect. Fresh frozen plasma is usually considered for warfarin reversal where there is active bleeding if prothrombin complex concentrate is unavailable.

D Withhold warfarin and give prothrombin complex concentrate

Withhold warfarin and give prothrombin complex concentrate is incorrect. Prothrombin complex concentrate is the treatment of choice for rapid warfarin reversal where there is active bleeding or surgery is required imminently.

E Withhold warfarin, stop ciprofloxacin and observe

A watch and wait approach is not advised here according to NICE guidelines, where INR is > 8.0, even if there is no

NC ···

und × | 404 – Not Found × | Home Feed | Re × | MyPastest ×

https://mypastest.pastest.com/Secure/TestMe/Browse

A 52-year-old man is seen in Cardiology Clinic as follow-up after a recent admission with paroxysmal atrial fibrillation and a myocardial infarction. Since discharge, he has noticed a rash develop over his face and neck when he is out in the garden.

On examination, his pulse is 65 bpm and regular. His blood pressure is 123/82 mmHg. There is an erythematous rash on sun-exposed skin.

What is the most likely causative agent?

A	Simvastatin
B	Metoprolol
C	Amiodarone
D	Warfarin
E	Ramipril

Calc

Norma

Submit

Rana Alnasser's screen

STC 12:26 AM 35%
594-042-7551
13:57
Leave

C Amiodarone

Amiodarone therapy is associated with a 30–50% incidence of photosensitivity. Symptoms develop within two hours of sun exposure, followed by erythema. A minority of affected patients develop a slate-grey pigmentation on light-exposed areas. Photosensitivity may persist for up to four months after the drug is withdrawn. Cutaneous pigmentation slowly fades after amiodarone is stopped but may persist for months to years.

In affected patients, skin cells and the cells of other organs have been found to contain myelin-like lysosomal structures and membrane-bound granules. This generalised derangement of lysosomal storage may also be the basis for other adverse effects of amiodarone such as interstitial alveolitis, acute hepatitis and disturbed thyroid function.

A Simvastatin

This may be associated with a hypersensitivity rash, alopecia, myositis, hepatitis, pancreatitis and peripheral neuropathy.

B Metoprolol

Beta blockers are known to exacerbate psoriasis and may cause dry eyes.

D Warfarin

Warfarin, like statins, may cause alopecia; it is also associated with easy bruising and areas of skin necrosis.

E Ramipril

Mute Start Video Share Content Participants More

STC 12:28 AM 35%
594-042-7551
15:41
Leave

Calc

Norma

A 27-year-old male is brought to the Emergency Department after he suffered two seizures while he was dancing at a night club. His girlfriend tells you that he was in perfect health up until this incident.

On examination, his pulse is 130/min and regular. Blood pressure is 200/110 mmHg, temperature 38 °C. He is anxious and aggressive, and tells you that he doesn't trust anyone. He is tremulous and you note some myoclonic jerks. Right fundus revealed a sub-hyaloid haemorrhage. Mild meningeal signs are evident. Bibasal crackles are noted on chest auscultation.

Investigations:

WBC	11×10^9/l
Urea	18 mmol/l
Creatinine	280 mmol/l
Urine	Normal

What is the most likely diagnosis?

A	Hepatic encephalopathy
B	Post-ictal confusion
C	Cocaine overdose
D	Bacterial meningitis
E	Viral encephalitis

Mute Start Video Share Content Participants More

C Cocaine overdose

The hypertension, tachycardia, pyrexia and two seizures fit well with stimulant drug abuse, particularly in the context of admission from a night club where the events occurred. The elevated creatinine may be related to accelerated renovascular disease as a result of the cocaine abuse. Given the signs of cardiac failure, nitrates are preferred in this situation for blood pressure control versus beta blockade, and benzodiazepines can be utilised for the management of anxiety and aggression.

A Hepatic encephalopathy

Hepatic encephalopathy presents against a background of chronic alcoholism and is precipitated by an acute event such as infection or an upper GI bleed.

B Post-ictal confusion

Post-ictal confusion would not be associated with hypertension and pyrexia.

D Bacterial meningitis

Bacterial meningitis doesn't fit with the rapid deterioration here, nor with the marked hypertension at presentation.

E Viral encephalitis

This doesn't fit with the hypertension at presentation, nor with the rapid deterioration of his neurological status with seizures and confusion.

Rate this question:

Rana Alnasser's screen

A 58-year-old man, who takes warfarin for chronic atrial fibrillation, has returned from a holiday in the Seychelles. While there he has acquired a diarrhoeal illness and has been prescribed metronidazole.

He is admitted to the Emergency Department with some bruising on his arms, but has no significant bleeding, even when he cleans his teeth. His international normalised ratio (INR) is measured at 8.1.

Which of the following is the best way to manage him?

A	Observation
B	5 mg vitamin K IV
C	2.5mg oral vitamin K
D	Fresh frozen plasma
E	Prothrombin complex

Calc

Norma

Submit

Previous Q...

Skip Questi...

© Pastest 2019

Rana Alnasser's screen

C 2.5mg oral vitamin K

Interactions between warfarin and antibiotics, leading to an increase in INR, are a relatively common occurrence. An INR of 8.1 is significantly elevated, and although there is no active bleeding, reversal is indicated.

B 5 mg vitamin K IV

IV vitamin K will drive complete reversal of anticoagulation, and will make it difficult to calculate dosing once warfarin is restarted. As such, oral therapy with a smaller dose is preferred.

A Observation

The INR is significantly elevated and, although there is no evidence of active bleeding, a relatively minor event could result in significant haemorrhage.

D Fresh frozen plasma

Fresh frozen plasma is given as an urgent intervention for major bleeding in the event that prothrombin complex concentrate is unavailable.

E Prothrombin complex

PCC is the preferred option to reverse warfarin where there is major bleeding or where there is an urgent need to progress to surgery.

Rate this question:

A 17-year-old girl who is studying for A-Levels now presents with clumsiness and falls. Her mother reports that she frequently drops china and cutlery at home. Her schoolteacher has noticed odd behaviour over the past two months and her work has deteriorated, although previously she has been a straight A grade student. Her brothers and sisters have no health problems. Her father is epileptic.

On examination, she has horizontal nystagmus, dysdiadochokinesis, and a broad-based gait.

Which of the following represents the most likely diagnosis?

A	Phenytoin toxicity
B	Haemochromatosis
C	Wilson's disease
D	Meningioma
E	Multiple sclerosis

6508

A Phenytoin toxicity

It seems likely that this girl has suffered stress at school and has begun using her father's phenytoin tablets. Horizontal nystagmus dysdiadochokinesis and a broad-based gait are all features associated with phenytoin toxicity.

B Haemochromatosis

Haemochromatosis usually presents with abnormal liver function testing but without overt neurological signs, it is also less likely to present early in women because of the menstrual cycle.

C Wilson's disease

Although Wilson's disease may present with neurological dysfunction of this type in the patient's age group, given the history of parental epilepsy and good health in other siblings, abuse of phenytoin tablets is more likely.

D Meningioma

A meningioma would be more likely to present with lateralising neurological signs.

E Multiple sclerosis

First presentation with MS, only with cerebellar signs would be considered unusual.

Rate this question:

Rana Alnasser's screen

E Continue LMWH and observe

There are two forms of heparin-induced thrombocytopenia (HIT). Type 1 HIT usually occurs in the first 48 to 72 hours and the platelet count rarely falls below 100×10^9/l. The platelet count should return to normal over the next 4 days and there is no increased risk of thromboembolism. This case described here, therefore, corresponds to Type 1 HIT. Type 2 HIT is much rarer and usually occurs 5 to 10 days after treatment commencement and the platelet count usually drops below 100×10^9/l to about 50×10^9/l. The patient is at increased risk of thromboembolic events

B Stop LMWH and start danaparoid

This is an option for Type 2 HIT where all heparin products should be stopped and the patient commenced on alternative medication such as lepirudin or a heparinoid such as danaparoid.

A Stop low molecular weight heparin (LMWH) and start intravenous (iv) heparin

iv heparin is at greater risk of inducing Type 2 HIT and no more effective than LMWH, as such there is no advantage in changing here.

C Stop LMWH and start lepirudin

Like danaparoid, this is an option for the treatment of patients with Type 2 HIT.

D Add in warfarin

At this stage, there is no advantage in adding in warfarin therapy, the LMWH should merely be continued. Adding in

Calc

Norma

You review a 76-year-old man with moderate cognitive impairment who appears to have Alzheimer's dementia. There is a past medical history of ischaemic heart disease and hypertension, and medication includes ramipril, furosemide, isosorbide mononitrate, aspirin and atorvastatin.

On examination, his blood pressure is 110/72 mmHg, his pulse is 80 bpm and regular. His chest is clear and there is no peripheral ankle oedema. He is selected for a trial of donepezil therapy as he fulfils the NICE criteria for receiving it.

Which of the following would you warn him is most likely to happen?

A	Hyperphagia
B	Insomnia
C	Heart block
D	Hepatitis
E	Muscle pains

Submit

E Muscle pains

Explanation

B Insomnia

Donepezil (Aricept) is a cholinesterase inhibitor. Common adverse effects include anorexia, hallucinations, agitation, aggressive behaviour, syncope, dizziness and insomnia.

C Heart block

Cardiac side-effects associated with donepezil are rarer; they include both sino-atrial and atrioventricular block.

A Hyperphagia

Anorexia, rather than hyperphagia, is commonly seen in patients prescribed donepezil.

D Hepatitis

Significant liver dysfunction associated with donepezil is rare; both elevated transaminases and a cholestatic picture of liver dysfunction are seen.

E Muscle pains

Elevation in muscle creatine kinase is seen in association with donepezil therapy, although frank myositis is rarely reported.

Rate this question:

Next Question

A 42-year-old man presents to the Emergency Department with a second episode of angio-oedema. He takes treatments for hypertension.

Which of the following drugs is most likely to be the cause of his angioedema?

Calc

Norma

A	Enalapril
B	Amlodipine
C	Furosemide
D	Bendrofluazide
E	Atenolol

6567

Submit

Previous Q... Skip Questi...

© Pastest 2019

Incidence and
ncbi.nlm.nih.gov/

A Enalapril

Angiotensin-converting enzyme (ACE) inhibitors are associated with the development of angioedema. In this case the enalapril should be withdrawn and another blood pressure lowering agent substituted in its place. Episodes of angioedema may occur at any time, even many years after starting the ACE inhibitor. Angioedema may also be inherited; hereditary angioedema is a rare autosomal-dominant condition due to an inherited deficiency of C1 esterase inhibitor. Serum C2 and C4 levels are low.

B Amlodipine

Patients are approximately ten times less likely to report angioedema in association with calcium channel blockers versus ACE inhibitors.

C Furosemide

Furosemide is associated with allergic rashes, but is not commonly associated with episodes of angioedema. It is also very uncommonly used as a treatment for hypertension.

D Bendrofluazide

Thiazides are associated with angioedema, but in the ALLHAT study, patients were approximately five times less likely to report episodes versus ACE inhibitor used to manage hypertension.

E Atenolol

Beta blockers may cause bronchospasm in patients with a history of asthma, and are associated with increased risk of

Calc

Norma

A 17-year-old girl is brought to the Emergency Department by ambulance. She has been found by her mother, lying on the floor having taken an unidentified overdose and a quantity of alcohol. Her mother is known to be hypertensive, for which she takes medication.

On examination, she is obtunded and hypotensive with a blood pressure of 75/50 mmHg; her pulse is 38 bpm. Finger prick glucose is 3.2 mmol/l. She has been given atropine 3 mg by the ambulance crew with little effect.

Which of the following is the most appropriate initial management in this case after having assessed her airway?

A	Intravenous (iv) Glucagon
B	iv Adrenalin
C	iv Noradrenalin
D	Salbutamol nebuliser
E	Insertion of pacing wire

Submit

Explanation

A Intravenous (iv) Glucagon

Given the history and findings on examination, the most likely diagnosis is overdose of her mother's beta (β)-blockers. She presents with decreased conscious level, profound hypotension and bradycardia, features typical of β-blocker overdose. Bronchospasm rarely occurs in overdose of β-blockers, except where there is a history of asthma. Immediate management is to give IV glucagon (50–150 μg/kg) followed by a glucagon infusion to treat hypotension, and atropine if needed to treat bradycardia. Because of the large quantities of glucagon required to achieve therapeutic effect, a number of commentaries recommend moving rapidly to transcutaneous pacing. Patients should be monitored for occurrence of hypoglycaemia. If the patient is seen within the first 4 h of overdose, gastric lavage may be of value.

B iv Adrenalin

This runs the risk of driving significant rhythm disturbance versus glucagon as the alternative.

C iv Noradrenalin

Like adrenaline, this is best avoided because of the risk of precipitating VT.

D Salbutamol nebuliser

Although this may cause a small increase in heart rate it is unlikely to be effective versus iv glucagon.

E Insertion of pacing wire

Rana Alnasser's screen

Explanation

Pacemaker complications can be a common problem in the period following insertion and can be divided into early complications (<6 weeks) or late (>6 weeks). Lead dislodgement can occur following trauma or sporadically and can be either atrial or ventricular. Atrial dislodgment affects up to 3% of people whereas ventricular is less common affecting 1%. The ECG in atrial lead displacement would show an ECG with loss of atrial sensing and capture in a dual chamber or single chamber pacemaker.

Loss of sensing and capture around the QRS complex, in this case, describes ventricular lead displacement; this is not the case here as this patient has a single chamber pacemaker.

Twiddler's syndrome is when the patient intentionally or accidentally turns the pacemaker on its longitudinal axis which can cause lead dislodgement.

Reel's syndrome is Twiddler's syndrome but on the horizontal axis. There is no reason to suspect either of these syndromes above.

On occasion lead displacement can be seen on chest X-Ray, however, this is not the case here. A lateral chest X-Ray may be of use in this scenario.

Further Reading:

Types of pacemakers for Bradycardia

Pacemaker Lead Displacement: Mechanisms And Management

Common Pacemaker Problems: Lead and Pocket Complications

Incidence of lead dislodgement, malfunction and perforation during the first year following device implantation

Pre-excitation Syndromes

Annotation
Stop Share
283

11:29
On Pastest 594-042-7551 Question 1 of 128 Leave

An 18-year-old woman is admitted with a history of breathing difficulty for the past hour. She is taking carbamazepine 800 mg daily for recently diagnosed epilepsy with generalised tonic–clonic seizures. Her mother confesses at the consultation that her daughter had been a difficult child, has aggressive outbursts and often speaks to imaginary people. A psychiatrist has started her on haloperidol.

She had been admitted to the surgical unit a couple of months previously for suspected appendicitis and then discharged the following morning as the pain had spontaneously improved. On examination she is anxious, uncooperative and disoriented. Respiratory rate is 28/min, pulse 130/min and blood pressure 180/106 mmHg. Cranial nerves are normal. Limbs are profoundly weak (2–3/5). Tendon reflexes are absent, with equivocal plantars.

Investigations:

Hb	13 g/dl
WCC	10×10^9/l
Na^+	119 mmol/l
K^+	4.0 mmol/l
Urea	3.0 mmol/l
Glucose	6.0 mmol/l
paO_2	11 kPa
$paCO_2$	9 kPa
pH	7.2

She is moved to the intensive therapy unit and intubated.

Given the suspected diagnosis, what is the most appropriate next intervention?

A. Further carbamazepine

Audio Video Share Participants More

uncooperative and disoriented. Respiratory rate is 28/min, pulse 130/min and blood pressure 180/106 mmHg. Cranial nerves are normal. Limbs are profoundly weak (2–3/5). Tendon reflexes are absent, with equivocal plantars.

Investigations:

Hb	13 g/dl
WCC	10×10^9/l
Na^+	119 mmol/l
K^+	4.0 mmol/l
Urea	3.0 mmol/l
Glucose	6.0 mmol/l
paO_2	11 kPa
$paCO_2$	9 kPa
pH	7.2

She is moved to the intensive therapy unit and intubated.

Given the suspected diagnosis, what is the most appropriate next intervention?

A Further carbamazepine

B IV acyclovir

C IV 5% glucose in 0.9% sodium chloride

D IV phenytoin infusion

E IV furosemide

Rana Alnasser's screen

C IV 5% glucose in 0.9% sodium chloride

Abdominal pain with no tenderness and low sodium, peripheral neuropathy and epileptic seizures made worse by certain drugs (like carbamazepine) raises a strong possibility of acute intermittent porphyria, an autosomal dominant condition. Signs include tachycardia, hypertension and lower motor neuron weakness mimicking Guillain-Barré syndrome (axonal polyneuropathy). High doses of glucose (400 g/day) can inhibit haem synthesis and are useful for treatment of mild attacks. The patient should receive a high-carbohydrate diet during an acute episode. If the patient is unable to eat, IV glucose should be administered. Dextrose water solutions should not be given because of the risk of exacerbating hyponatraemia.

IV haematin can be started once available, and should be continued over 3-4 days.

A Further carbamazepine

Carbamazepine can provoke episodes of acute intermittent porphyria and is therefore contraindicated. Other drugs such as barbiturates, sulphonamides, phenytoin, valproic acid, alcohol, griseofulvin, synthetic oestrogens and progesterone, and ergots are unsafe.

B IV acyclovir

The chronic nature of this patient's symptoms makes a diagnosis of viral encephalitis very unlikely.

D IV phenytoin infusion

Phenytoin, like carbamazepine, may provoke episodes of AIP, and should therefore be avoided here.

A Further carbamazepine

Carbamazepine can provoke episodes of acute intermittent porphyria and is therefore contraindicated. Other drugs such as barbiturates, sulphonamides, phenytoin, valproic acid, alcohol, griseofulvin, synthetic oestrogens and progesterone, and ergots are unsafe.

B IV acyclovir

The chronic nature of this patient's symptoms makes a diagnosis of viral encephalitis very unlikely.

D IV phenytoin infusion

Phenytoin, like carbamazepine, may provoke episodes of AIP, and should therefore be avoided here.

E IV furosemide

Although this patient is hypertensive with hyponatraemia, diuretics have no role in the treatment of the condition.

Rate this question:

Rana Alnasser's screen

A Further carbamazepine

Carbamazepine can provoke episodes of acute intermittent porphyria and is therefore contraindicated. Other drugs such as barbiturates, sulphonamides, phenytoin, valproic acid, alcohol, griseofulvin, synthetic oestrogens and progesterone, and ergots are unsafe.

B IV acyclovir

The chronic nature of this patient's symptoms makes a diagnosis of viral encephalitis very unlikely.

D IV phenytoin infusion

Phenytoin, like carbamazepine, may provoke episodes of AIP, and should therefore be avoided here.

E IV furosemide

Although this patient is hypertensive with hyponatraemia, diuretics have no role in the treatment of the condition.

Rate this question:

Next Question

Rana Alnasser's screen

11:33

A 25-year-old patient is transferred from the Psychiatric Unit with rigors and pyrexia. She had been originally admitted with acute psychosis. The patient is confused and sweating profusely. Observations are shown below:

Temperature	38.5 °C
Pulse	120/min
BP	175/85 mmHg
Respiratory rate	30/min
Oxygen saturations	99%

She is drooling saliva and is tremulous with generalised muscle rigidity.

Initial investigations:

Hb	13.6 g/dl
WCC	12.7×10^9/l
PLT	390×10^9/l
pH	7.13
pa(O_2)	15.5 kPa
pa(CO_2)	3.5 kPa
HCO_3^-	14 mmol/l

What test would best confirm the most likely diagnosis?

A	Blood cultures
B	Creatine kinase

Rana Alnasser's screen

Respiratory rate	30/min
Oxygen saturations	99%

She is drooling saliva and is tremulous with generalised muscle rigidity.

Initial investigations:

Hb	13.6 g/dl
WCC	12.7×10^9/l
PLT	390×10^9/l
pH	7.13
pa(O_2)	15.5 kPa
pa(CO_2)	3.5 kPa
HCO_3^-	14 mmol/l

What test would best confirm the most likely diagnosis?

A Blood cultures

B Creatine kinase

C Clotting studies

D Serum Calcium

E Liver function tests

Submit

B Creatine kinase

Neuroleptic malignant syndrome is thought to arise from blockage of dopamine receptors or decrease in availability of dopamine. It typically occurs in patients who have recently been commenced on antipsychotic medications or had a recent dose change and it has been reported in patients who have had their antiparkinsonian treatment withdrawn. The mortality is between 10–20%. Patients are hyperthermic, diaphoretic with tremors and generalised muscle rigidity. Investigations will reveal a metabolic acidosis with a raised creatine kinase (or urinary myoglobin where urine dipstick is positive for blood but no cells are seen). Treatment includes close monitoring with intravenous hydration, cessation of neuroleptics and temperature control. In patients who fail to respond, anti-cholinergics are the next step.

A Blood cultures

Although this patient is pyrexial, the temperature is much more likely to be related to neuroleptic driven hyperthermia.

C Clotting studies

Clotting may be deranged in the context of neuroleptic malignant syndrome, but this won't reveal the underlying diagnosis.

D Serum Calcium

The muscle rigidity here is not driven by hypercalcaemia, but is instead driven by increased muscle tone related to decreased availability of dopamine.

seen). Treatment includes close monitoring with intravenous hydration, cessation of neuroleptics and temperature control. In patients who fail to respond, anti-cholinergics are the next step.

A Blood cultures

Although this patient is pyrexial, the temperature is much more likely to be related to neuroleptic driven hyperthermia.

C Clotting studies

Clotting may be deranged in the context of neuroleptic malignant syndrome, but this won't reveal the underlying diagnosis.

D Serum Calcium

The muscle rigidity here is not driven by hypercalcaemia, but is instead driven by increased muscle tone related to decreased availability of dopamine.

E Liver function tests

Transaminases as well as CK may be elevated as a result of muscle necrosis, but liver function tests won't differentiate their origin.

Rate this question:

Next Question

An 18-year-old female student is being investigated in the clinic for weight loss and diarrhoea. The symptoms started about one year ago and she has been progressively losing weight. She is in the clinic with her parents, who are extremely concerned for their daughter.

Investigations:

Hb	11.2 g/dl
WCC	4.2×10^9/l
PLT	160×10^9/l
Na+	132 mmol/l
K+	3.1 mmol/l
Creatinine	55 µmol/l
ESR	6.0 mm/h
MCV	83 fl
CRP	4.0 mg/l
Urea	2.5 mmol/l
Upper gastrointestinal (GI) endoscopy	Normal appearances with normal duodenal biopsies
Colonoscopy	Melanosis coli

What is the most likely cause of the symptoms?

A Senna abuse

B Lactulose abuse

C Sodium docusate abuse

11:35

ESR	6.0 mm/h
MCV	83 fl
CRP	4.0 mg/l
Urea	2.5 mmol/l
Upper gastrointestinal (GI) endoscopy	Normal appearances with normal duodenal biopsies
Colonoscopy	Melanosis coli

What is the most likely cause of the symptoms?

A Senna abuse

B Lactulose abuse

C Sodium docusate abuse

D Methylcellulose abuse

E Colchicine use

Submit

Rana Alnasser's screen

11:36

A Senna abuse

Anthraquinone laxative derivatives such as senna are absorbed in the large intestine, where they lead to cellular apoptosis, resulting in brown pigmentation of the colonic mucosa, so-called melanosis coli.

C Sodium docusate abuse

Sodium docusate, like lactulose, is primarily a stool softene and does not lead to colonic mucosal cell apoptosis and melanosis coli.

B Lactulose abuse

Lactulose is an osmotic laxative which increases intraluminal/stool water, resulting in softening; it does not lead to colonic pigmentation.

D Methylcellulose abuse

Methylcellulose is a bulk-forming laxative and must be taken with large amounts of fluids to achieve its laxative effect.

E Colchicine use

Colchicine is rarely used, normally for the treatment of gout in patients where other interventions are unsuitable. I is therefore doubtful as to how this patient would have gained access to the medication. It does not cause melanosis coli.

Rate this question:

Rana Alnasser's screen

11:36
On
594-042-7551
Leave

An 82-year-old patient has been diagnosed with metastatic lung cancer. He is on the ward and currently taking 30 mg of oral morphine sustained release twice a day with 60 mg per day of Oramorph PRN for breakthrough pain. Overall, he has taken 60 mg of PRN morphine on each of the last three days.

During the ward round, he complains of vomiting and difficulty keeping his medication down. It is decided to convert his analgesia to a diamorphine subcutaneous infusion pump.

What dose of diamorphine should be placed in the infusion pump over 24 h?

A	20 mg
B	40 mg
C	70 mg
D	90 mg
E	110 mg

6497

Submit

Previous Q...
Skip Questi...
Audio
Video
Share
Participants
More

An 82-year-old patient has been diagnosed with metastatic lung cancer. He is on the ward and currently taking 30 mg of oral morphine sustained release twice a day with 60 mg per day of Oramorph PRN for breakthrough pain. Overall, he has taken 60 mg of PRN morphine on each of the last three days.

During the ward round, he complains of vomiting and difficulty keeping his medication down. It is decided to convert his analgesia to a diamorphine subcutaneous infusion pump.

What dose of diamorphine should be placed in the infusion pump over 24 h?

Your answer was correct

A 20 mg

B 40 mg

C 70 mg

D 90 mg

E 110 mg

Explanation

B 40 mg

This patient is requiring 120 mg in total of oral morphine

B 40 mg

This patient is requiring 120 mg in total of oral morphine per day. The recommended conversion factor for oral morphine to s/c diamorphine is approximately one third of the mg dose. Hence, 40 mg is the correct answer.

A 20 mg

This risks significant under-dosing with respect to analgesia, and breakthrough pain.

C 70 mg

This risks significant over-dosing with respect to analgesia, with respiratory depression.

D 90 mg

Like 70 mg, 90 mg of s/c diamorphine risks significant overdosing and therefore respiratory depression.

E 110 mg

110 mg is nearly three times the required dose of s/c diamorphine and potentially risks respiratory arrest due to opiate overdose.

Rate this question:

Next Question

A 40-year-old, previously fit and well farmer is admitted to hospital with shortness of breath. Associated with the shortness of breath are nausea, vomiting and diarrhoea. The patient has widespread expiratory polyphonic wheeze and there are observable muscle fasciculations. According to his wife he has been out for most of the past two days crop spraying his fields.

On examination, there is bilateral pupillary constriction, his blood pressure (BP) is 95/50 mmHg with a pulse of 38 bpm.

Which of the following medications is likely to be most beneficial?

A Physostigmine

B Phenoxybenzamine

C Atropine

D Rocuronium

E Isoflurophate

Submit

A 40-year-old, previously fit and well farmer is admitted to hospital with shortness of breath. Associated with the shortness of breath are nausea, vomiting and diarrhoea. The patient has widespread expiratory polyphonic wheeze and there are observable muscle fasciculations. According to his wife he has been out for most of the past two days crop spraying his fields.

On examination, there is bilateral pupillary constriction, his blood pressure (BP) is 95/50 mmHg with a pulse of 38 bpm.

Which of the following medications is likely to be most beneficial?

Your answer was correct

A Physostigmine

B Phenoxybenzamine

C Atropine

D Rocuronium

E Isoflurophate

Explanation

C Atropine

This patient presents with organophosphate poisoning,

Explanation

C Atropine

This patient presents with organophosphate poisoning, probably due to unintentional exposure as a result of his crop-spraying activity. Organophosphates are strong cholinesterase inhibitors. Symptoms are mainly those of muscarinic and nicotinic overstimulation. Before arrival into hospital the patient should be decontaminated. Atropine is used as a muscarinic receptor antagonist; as well as treating bradycardia, it also relieves bronchospasm and diminishes excess respiratory secretions.

Pralidoxime is a cholinesterase activator and can reverse organophosphate-driven inhibition of cholinesterase. It should be given as soon as possible in addition to atropine. Time to admission of pralidoxime and atropine is closely linked to chances of survival.

A Physostigmine

Physostigmine is a cholinesterase inhibitor which will worsen symptoms of organophosphate poisoning, not improve them.

B Phenoxybenzamine

Phenoxybenzamine is an α-receptor blocker and is for treatment of hypertension caused by phaeochromocytomas.

D Rocuronium

Rocuronium is a competitive neuromuscular blocker and can be used to facilitate intubation.

A 21-year-old woman, who is eight weeks pregnant, presents for review with very difficult to control nausea and vomiting. She is very worried as she feels unable to eat and is concerned that she is losing weight. She has tried home remedies such as ginger, and has been resting as much as possible. She is tolerating oral fluids but very little solid foods. You are considering starting medication.

Investigations:

Hb	12.1 g/dl
WCC	5.4×10^9/l
PLT	201×10^9/l
Na^+	140 mmol/l
K^+	3.4 mmol/l
Creatinine	115 µmol/l

Which of the following would be the most appropriate medication for her?

A Domperidone

B Promethazine

C Metoclopramide

D Ondansetron

E Chlorpromazine

B Promethazine

NICE suggests that antihistamines such as cyclizine or promethazine are the recommended first line options for the medical management of nausea and vomiting in pregnancy. This is due to high levels of effectiveness, lack of extra-pyramidal side effects and good overall tolerability profile in this class of drugs.

A Domperidone

The dopamine antagonist domperidone can be used in the treatment of nausea and vomiting in pregnancy, however antihistamines are preferred as there is no risk of extra-pyramidal side effects with antihistamine use.

C Metoclopramide

Metoclopramide is not used as a first line agent in the management of nausea and vomiting in pregnancy due to the increased risk of extrapyramidal side effects. These side effects are particularly common in the younger population.

D Ondansetron

Ondansetron is thought to be safe for the treatment of nausea and vomiting in pregnancy, although exposure data are limited. Of the options available, promethazine is the most appropriate first line treatment.

E Chlorpromazine

Pyridoxine is not recommended in pregnancy induced nausea and vomiting as there is a lack of consistent evidence available for its effectiveness. High doses may be

of extra-pyramidal side effects and good overall tolerability profile in this class of drugs.

A Domperidone

The dopamine antagonist domperidone can be used in the treatment of nausea and vomiting in pregnancy, however antihistamines are preferred as there is no risk of extra-pyramidal side effects with antihistamine use.

C Metoclopramide

Metoclopramide is not used as a first line agent in the management of nausea and vomiting in pregnancy due to the increased risk of extrapyramidal side effects. These side effects are particularly common in the younger population.

D Ondansetron

Ondansetron is thought to be safe for the treatment of nausea and vomiting in pregnancy, although exposure data are limited. Of the options available, promethazine is the most appropriate first line treatment.

E Chlorpromazine

Pyridoxine is not recommended in pregnancy induced nausea and vomiting as there is a lack of consistent evidence available for its effectiveness. High doses may be required to treat symptoms however doses greater than 50mg a day can cause peripheral neuropathy.

Rate this question:

Next Question

A 32-year-old man is arrested after a flight from Jamaica and brought to the hospital for assessment as he becomes increasingly agitated.

Abdominal X-ray reveals evidence of ingestion of a number of packets of drugs, presumed to be cocaine.

What is the management of choice in this case?

A Gastric lavage and activated charcoal

B Urgent surgical referral

C Observation

D Colonic wash-out

E Laxative administration

Submit

Previous Q... Skip Questi...

© Pastest 2019

11:45
On
594-042-7551
Leave

A 32-year-old man is arrested after a flight from Jamaica and brought to the hospital for assessment as he becomes increasingly agitated.

Abdominal X-ray reveals evidence of ingestion of a number of packets of drugs, presumed to be cocaine.

What is the management of choice in this case?

Your answer was correct

A	Gastric lavage and activated charcoal
B	Urgent surgical referral
C	Observation
D	Colonic wash-out
E	Laxative administration

Explanation

B Urgent surgical referral

As this patient is symptomatic, following the royal college of Emergency medicine guidelines they should have an urgent surgical referral.

Audio
Video
Share
Participants
More

11:45
On
594-042-7551
Leave

B Urgent surgical referral

As this patient is symptomatic, following the royal college of Emergency medicine guidelines they should have an urgent surgical referral.

A Gastric lavage and activated charcoal

Institution of fluid and charcoal potentially increases the risk of package rupture and should therefore be avoided.

C Observation

Given one of the packages at least appears to be leaking, observation risks waiting too long for them to exit the body.

D Colonic wash-out

Colonic washout utilises quite large volumes of water, increasing the risk of packet rupture.

E Laxative administration

This practice is known as 'body packing' and is particularly associated with the smuggling of cocaine. The risk of toxicity from rupture or leakage of the package is not insignificant. Body packers and body stuffers may be asymptomatic when brought in by police. The body packers, also called mules, pack their gastrointestinal tract with bags of cocaine (or other illicit drugs) in order to smuggle the drug from one country to another. In contrast body stuffers hastily insert packages into the mouth, rectum, or vagina in order to conceal the evidence from police at the time of their arrest. Following the Royal College of Emergency Medicine guidelines if the patient is

Audio Video Share Participants More

C Observation

Given one of the packages at least appears to be leaking, observation risks waiting too long for them to exit the body.

D Colonic wash-out

Colonic washout utilises quite large volumes of water, increasing the risk of packet rupture.

E Laxative administration

This practice is known as 'body packing' and is particularly associated with the smuggling of cocaine. The risk of toxicity from rupture or leakage of the package is not insignificant. Body packers and body stuffers may be asymptomatic when brought in by police. The body packers, also called mules, pack their gastrointestinal tract with bags of cocaine (or other illicit drugs) in order to smuggle the drug from one country to another. In contrast body stuffers hastily insert packages into the mouth, rectum, or vagina in order to conceal the evidence from police at the time of their arrest. Following the Royal College of Emergency Medicine guidance, if the patient is asymptomatic then laxatives can be considered, but if they have developed symptoms either drug to package rupture or bowel obstruction then they require surgical referral.

Rate this question:

Next Question

Previous Q... Tag Questi... Feedback End Session

11:47

You review the pharmacokinetic and pharmacodynamic properties of a new agent for the treatment of epilepsy, and are aware that other agents used for the treatment of epilepsy may require therapeutic drug monitoring.

Which of the following is likely to drive a requirement for pharmacokinetic monitoring?

A	Zero-order kinetics
B	First-order kinetics
C	High first pass metabolism
D	Complementary mode of action to other antiepileptics
E	Inhibition of CYP3A4

Submit

Previous Q...

Skip Questi...

© Pastest 2019

Rana Alnasser's screen

11:50
On
594-042-7551
Leave

A Zero-order kinetics

With drugs that obey zero-order kinetics, such as phenytoin and ethanol, their enzyme metabolism is saturable, which means only a certain amount of the drug can be eliminated over a period of time. This means that fo relatively small increases in administered drug, relatively large increases in plasma concentration may occur, leading to potential drug toxicity. This makes zero-order kinetics a key driver for therapeutic drug monitoring.

E Inhibition of CYP3A4

Inhibition of CYP3A4 may require drug interaction studies looking at the effect of this drug on the metabolism of others, rather than studies looking at the concentration of the drug itself.

B First-order kinetics

Where drugs display first-order kinetics, the rate at which a drug is metabolised and eliminated is generally proportional to the dose given, with an exponential reduction in plasma concentration over time. Each half-life of a drug displaying first-order kinetics is associated with a 50% reduction in plasma concentration, and drugs may be considered eliminated after 3–5 half-lives. This predictable PK is associated with less need for therapeutic drug monitoring.

C High first pass metabolism

High first pass metabolism does not stratify a need for therapeutic drug monitoring, evaluation of active metabolites in this case is more important with respect to therapeutic monitoring or not.

Audio Video Share Participants More

11:51
On
594-042-7551
Leave

key driver for therapeutic drug monitoring.

E Inhibition of CYP3A4

Inhibition of CYP3A4 may require drug interaction studies looking at the effect of this drug on the metabolism of others, rather than studies looking at the concentration of the drug itself.

B First-order kinetics

Where drugs display first-order kinetics, the rate at which a drug is metabolised and eliminated is generally proportional to the dose given, with an exponential reduction in plasma concentration over time. Each half-life of a drug displaying first-order kinetics is associated with a 50% reduction in plasma concentration, and drugs may be considered eliminated after 3–5 half-lives. This predictable PK is associated with less need for therapeutic drug monitoring.

C High first pass metabolism

High first pass metabolism does not stratify a need for therapeutic drug monitoring; evaluation of active metabolites in this case is more important with respect to the need for monitoring or not.

D Complementary mode of action to other antiepileptics

This drives a requirement for PD interaction studies rather than for therapeutic drug monitoring.

Rate this question:
Audio Video Share Participants More

11:51
On
594-042-7551
Leave

Pastest+

An 18-year-old student has attended the Emergency Department of a district general hospital, having consumed a bottle of antifreeze for a bet. On arrival, he appears rather unwell, with bloods indicating that he has a high anion gap metabolic acidosis, and an elevated osmolar gap

On examination, his BP is 100/60 mmHg, pulse is 95 bpm and regular, and he is drowsy. Arterial blood gasses reveal a severe metabolic acidosis. He can currently be admitted to the high-dependency unit, but there are no ITU beds.

Which of the following would be the most appropriate treatment for his antifreeze poisoning?

A	Ethanol
B	Methanol
C	Fomepizole
D	Naloxone
E	Methylene blue

Submit

Audio
Video
Share
Participants
More

11:52
On
594-042-7551
Leave

An 18-year-old student has attended the Emergency Department of a district general hospital, having consumed a bottle of antifreeze for a bet. On arrival, he appears rather unwell, with bloods indicating that he has a high anion gap metabolic acidosis, and an elevated osmolar gap

On examination, his BP is 100/60 mmHg, pulse is 95 bpm and regular, and he is drowsy. Arterial blood gasses reveal a severe metabolic acidosis. He can currently be admitted to the high-dependency unit, but there are no ITU beds.

Which of the following would be the most appropriate treatment for his antifreeze poisoning?

Your answer was correct

A Ethanol

B Methanol

C Fomepizole

D Naloxone

E Methylene blue

Explanation

C Fomepizole

Ethylene glycol poisoning is one of the classic causes of a high anion gap metabolic acidosis. A few of the causes can

Audio Video Share Participants More

11:52
On
594-042-7551
Leave

Explanation

C Fomepizole

Ethylene glycol poisoning is one of the classic causes of a high anion gap metabolic acidosis. A few of the causes can be remembered using the mnemonic MUDPILES: methanol uraemia, diabetic ketoacidosis, paraldehyde, iron, lactate, ethylene glycol and salicylate. Ethylene glycol is metabolised by the enzyme alcohol dehydrogenase, initially to glycoaldehyde, then forming glycolic acid, glyoxylic acid and finally oxalic acid. Fomepizole is an inhibitor of alcohol dehydrogenase but does not lead to intoxication; it is therefore preferred here to ethanol.

Useful mnemonic

The mnemonic 'MUDPILES' (methanol, uraemia, diabetic ketoacidosis, paraldehyde, iron, lactate, ethylene glycol and salicylate) can be used to remember some of the causes of high anion gap metabolic acidosis.

A Ethanol

Ethanol is a competitive antagonist for alcohol dehydrogenase but has the disadvantage here that it increases intoxication.

B Methanol

Methanol has a significant negative toxicity profile, leading to metabolic acidosis and optic neuropathy; hence it is not an appropriate intervention here.

D Naloxone

Naloxone is a reversal agent for opiates.

Audio Video Share Participants More

11:52
On
594-042-7551
Leave

Pastes+

A 57-year-old man attends the outpatient clinic. He has a background of hypertension, hyperlipidaemia, diabetes, and gastroesophageal reflux disease. The patient has recently returned from a holiday in Europe.

While on vacation, he suffered a heart attack and was admitted to hospital. He states his heart went into a 'funny rhythm' which required medication to control it. The patient remembers a particularly bad stay in the coronary care unit when he had symptoms of vomiting, vertigo, tinnitus, headache and blurred vision.

What medication is most likely to have caused these symptoms?

A	Amiodarone
B	Digoxin
C	Quinidine
D	Lignocaine
E	Flecainide

Submit

Previous Q...
Skip Questi...
Audio
Video
Share
Participants
More

11:54
On
594-042-7551
Leave

Pastes+

A 57-year-old man attends the outpatient clinic. He has a background of hypertension, hyperlipidaemia, diabetes, and gastroesophageal reflux disease. The patient has recently returned from a holiday in Europe.

While on vacation, he suffered a heart attack and was admitted to hospital. He states his heart went into a 'funny rhythm' which required medication to control it. The patient remembers a particularly bad stay in the coronary care unit when he had symptoms of vomiting, vertigo, tinnitus, headache and blurred vision.

What medication is most likely to have caused these symptoms?

Your answer was incorrect

A Amiodarone

B Digoxin

C Quinidine

D Lignocaine

E Flecainide

Explanation

C Quinidine

Quinidine is a class 1A antiarrhythmic drug that slows the

Audio Video Share Participants More

11:55
On 594-042-7551 Leave

Explanation

C Quinidine

Quinidine is a class 1A antiarrhythmic drug that slows the rapid depolarisation that occurs during phase 0 of the cardiac action potential. It is used for the treatment of atrial and ventricular arrhythmias, and is related to the antimalarial quinine. The constellation of symptoms described are those of cinchonism. This can be brought on by both acute and chronic treatment with quinidine and quinine. It can also cause a prolonged QT interval on the electrocardiogram. (Cinchona is the name of the tree from which quinine can be obtained.)

B Digoxin

Digoxin toxicity is associated with vomiting and visual disturbance, but it is more likely to be associated with yellowing of vision.

A Amiodarone

Amiodarone therapy is associated with both pulmonary fibrosis and skin photosensitivity, rather than the symptoms seen here.

D Lignocaine

Lignocaine is not associated with symptoms of cinchonism it is associated with sensation of dizziness and tunnel vision.

E Flecainide

Flecainide is associated dizziness and blurred vision but

Audio Video Share Participants More

11:58
On
594-042-7551
Leave

electrocardiogram. (Cinchona is the name of the tree from which quinine can be obtained.)

B Digoxin

Digoxin toxicity is associated with vomiting and visual disturbance, but it is more likely to be associated with yellowing of vision.

A Amiodarone

Amiodarone therapy is associated with both pulmonary fibrosis and skin photosensitivity, rather than the symptoms seen here.

D Lignocaine

Lignocaine is not associated with symptoms of cinchonism, it is associated with sensation of dizziness and tunnel vision.

E Flecainide

Flecainide is associated dizziness and blurred vision, but not with the vomiting and tinnitus seen here.

Rate this question:

Next Question

Audio Video Share Participants More

11:58
On
594-042-7551
Leave

You are called to see a 26-year-old man on the ward. He was admitted for the treatment of cellulitis, and has a background of depression. He has become unwell with confusion, abdominal pain, vomiting and diarrhoea the morning after admission.

The nurses have also noticed that when he opened his bowels the stool was dark black. His pulse was 100 bpm, blood pressure 110/60 mmHg and respiratory rate 24/min.

Initial investigations:

Hb	14 g/dl
WCC	13.5×10^9/l
PLT	250×10^9/l
INR	1.1
Na^+	143 mmol/l
K^+	4.3 mmol/l
Urea	11 mmol/l
Glucose	7 mmol/l
Creatinine	100 µmol/l
Erect chest and abdominal X-rays	Multiple rounded radio-opacities in the small intestine
Iron level	90 µmol/l (12–30 µmol/l)

IV fluids are commenced, as is a laxative preparation.

What is the next appropriate management step?

A Oral activated charcoal

B Oral desferrioxamine

Audio Video Share Participants More

12:00

The nurses have also noticed that when he opened his bowels the stool was dark black. His pulse was 100 bpm, blood pressure 110/60 mmHg and respiratory rate 24/min.

Initial investigations:

Hb	14 g/dl
WCC	13.5×10^9/l
PLT	250×10^9/l
INR	1.1
Na^+	143 mmol/l
K^+	4.3 mmol/l
Urea	11 mmol/l
Glucose	7 mmol/l
Creatinine	100 µmol/l
Erect chest and abdominal X-rays	Multiple rounded radio-opacities in the small intestine
Iron level	90 µmol/l (12–30 µmol/l)

IV fluids are commenced, as is a laxative preparation.

What is the next appropriate management step?

A Oral activated charcoal

B Oral desferrioxamine

C Cautious venesection

D Haemodialysis

E Parenteral desferrioxamine

Rana Alnasser's screen

12:01

MyPastest
https://mypastest.pastest.com

Pastest+

Na^+	143 mmol/l
K^+	4.3 mmol/l
Urea	11 mmol/l
Glucose	7 mmol/l
Creatinine	100 µmol/l
Erect chest and abdominal X-rays	Multiple rounded radio-opacities in the small intestine
Iron level	90 µmol/l (12–30 µmol/l)

IV fluids are commenced, as is a laxative preparation.

What is the next appropriate management step?

Your answer was correct

A Oral activated charcoal

B Oral desferrioxamine

C Cautious venesection

D Haemodialysis

E Parenteral desferrioxamine

Explanation

E Parenteral desferrioxamine

E Parenteral desferrioxamine

This is a case of iron overdose. Initial stages are of abdominal pain, vomiting and diarrhoea with gastrointestinal blood loss. There can also be a lucid period where the person appears well and then becomes progressively drowsier. X-rays can reveal the tablets in the bowel. Serum iron indicates the severity of the overdose, with severe toxicity at >90 μmol/l. Parenteral desferrioxamine to chelate iron is the intervention of choice.

A Oral activated charcoal

Charcoal does not bind iron sulphate tablets and therefore has no value. As the pills in this case are in the small intestine it is recommended to cleanse the bowel with a polyethylene glycol electrolyte solution (Klean-Prep). Gastroscopy does not reach far enough to retrieve the tablets.

B Oral desferrioxamine

Oral absorption of desferrioxamine is too little and unpredictable to reliably treat iron overdose, as such IV delivery is preferred.

C Cautious venesection

Venesection is indicated in the treatment of haemochromatosis, but has no role in the treatment of iron overdose.

D Haemodialysis

Haemodialysis is indicated in patients where iron chelation therapy is inadequate and kidney disease and acidosis

A 32-year-old man is readmitted to the hospital some 14 days after his renal transplant. He has begun feeling very unwell with flu-like symptoms, a headache and sore throat. He has been checking his temperature at home and is now spiking fevers of 38.5 °C.

On examination, he looks poorly, with pyrexia of 38.2 °C in the Emergency room and evidence of pharyngitis. On reviewing his notes, you see that he was CMV-, Hep B- and Hep C- negative before his transplant.

Investigations:

Hb	11.9 g/dl
WCC	6.1×10^9/l
PLT	235×10^9/l
ESR	49 mm/hr
Na^+	139 mmol/l
K^+	5.0 mmol/l
Creatinine	105 µmol/l

Which of the following would be the most appropriate treatment for him?

A Intravenous (iv) ganciclovir

B iv Foscarnet

C iv Vancomcin and teicoplanin

D iv benzylpenicillin and gentamycin

E iv aciclovir

12:03
On
594-042-7551
Leave

A Intravenous (iv) ganciclovir

The most likely diagnosis here is one of CMV infection post-renal transplant, for which IV ganciclovir is the default treatment choice. It is very likely that the kidney has come from a CMV-positive donor. Symptoms of CMV infection post-transplant can appear any time from 6-60 days after surgery and are characterised by pyrexia, flu-like symptoms or an infectious mononucleosis-type picture as seen here. Indeed, transplant surgeons now consider the option of prophylactic ganciclovir in patients who are CMV- but their transplanted kidney comes from a CMV+ donor. The concern is that active CMV infection is associated with accelerated failure of the transplanted kidney.

B iv Foscarnet

Ganciclovir is preferred to foscarnet as a treatment option because of adverse events associated with foscarnet therapy, including marrow suppression.

C iv Vancomcin and teicoplanin

This would be an option for bacterial sepsis as a result of the transplant. The modest increase in ESR and normal white blood count make a viral infection more likely.

D iv benzylpenicillin and gentamycin

This would be a reasonable option for the treatment of bacterial endocarditis.

E iv aciclovir

Although acyclovir was previously used for CMV prophylaxis, valganciclovir is now preferred.

Audio Video Share Participants More

12:03
On
594-042-7551
Leave

B iv Foscarnet

Ganciclovir is preferred to foscarnet as a treatment option because of adverse events associated with foscarnet therapy, including marrow suppression.

C iv Vancomcin and teicoplanin

This would be an option for bacterial sepsis as a result of the transplant. The modest increase in ESR and normal white blood count make a viral infection more likely.

D iv benzylpenicillin and gentamycin

This would be a reasonable option for the treatment of bacterial endocarditis.

E iv aciclovir

Although acyclovir was previously used for CMV prophylaxis, valgancyclovir is now preferred.

Rate this question:

Next Question

Previous Q... Tag Questi... Feedback End Session

Blog About Pastest Contact Us Help

© Pastest 2019

Audio Video Share Participants More

12:03

A 34-year-old woman is seen in the Diabetic Clinic. She was diagnosed with type II diabetes 18 months previously, and has been on treatment with metformin. Her HbA1c is 50.82 mmol/mol (6.8%), and blood pressure (BP) is 136/75 mmHg. She has no microalbuminuria. In spite of dietary advice and modification, she remains obese, with a body mass index (BMI) of 35 kg/m^2.

Which of the following is the most appropriate intervention with respect to weight control?

A	Further diet and exercise
B	Albiglutide 30 mg
C	Canagliflozin
D	Orlistat
E	Liraglutide 3 mg

6401

Submit

Previous Q... Skip Questi...

© Pastest 2019

Rana Alnasser's screen

A 34-year-old woman is seen in the Diabetic Clinic. She was diagnosed with type II diabetes 18 months previously, and has been on treatment with metformin. Her HbA1c is 50.82 mmol/mol (6.8%), and blood pressure (BP) is 136/75 mmHg. She has no microalbuminuria. In spite of dietary advice and modification, she remains obese, with a body mass index (BMI) of 35 kg/m².

Which of the following is the most appropriate intervention with respect to weight control?

Your answer was incorrect

A	Further diet and exercise
B	Albiglutide 30 mg
C	Canagliflozin
D	Orlistat
E	Liraglutide 3 mg

Explanation

E Liraglutide 3 mg

This patient is obese with relatively good HbA1c control. As such rather than an intervention for glucose control, an intervention for weight loss is more appropriate. Liraglutide is licensed for weight loss at the 3 mg dose, and was shown in the SCALE diabetes study to drive significant weight loss (6% versus baseline over 52 weeks; see link for

12:05

E Liraglutide 3 mg

This patient is obese with relatively good HbA1c control. As such rather than an intervention for glucose control, an intervention for weight loss is more appropriate. Liraglutide is licensed for weight loss at the 3 mg dose, and was shown in the SCALE diabetes study to drive significant weight loss (6% versus baseline over 52 weeks; see link for JAMA article).

C Canagliflozin

Canagliflozin is primarily an SGLT-2 inhibitor which reduces glucose reabsorption in the kidney, promoting carbohydrate loss. It is licensed for control of blood glucose in type II diabetes, not for weight loss.

A Further diet and exercise

Given this patient has not lost a significant amount of weight with lifestyle intervention, further measures are required.

B Albiglutide 30 mg

Albiglutide 30 mg is used for glucose control in type II diabetes; it does not substantially impact on weight.

D Orlistat

Orlistat does achieve modest weight loss, but it is often poorly tolerated due to side effects related to fat malabsorption.

Rate this question:

Rana Alnasser's screen

A 76-year-old woman with known vascular dementia is sent in to the Accident and Emergency (A&E) Department by nursing home staff with a 2-day history of fever, reduced mobility and drowsiness.

Four days earlier, she had been seen by the on-call general practitioner (GP), as she had been agitated and hallucinating. He had started her on haloperidol for this.

In A&E, her temperature is 39.4 °C. She is drowsy with a Glasgow Coma Scale (GCS) score of 12/15 (E3 V4 M5). She has a sinus tachycardia 116 bpm. Blood pressure is 112/56 mmHg and heart sounds are normal. Her chest is clear and her abdomen is soft and non-tender, with normal bowel sounds.

Neurological examination reveals generalised hypertonia, but normal power and reflexes.

Investigations are as follows:

White blood cells (WBC)	8.1×10^9/l
Haemoglobin (Hb)	12.4 g/dl
Mean cell volume (MCV)	82.4 fl
Platelets	224×10^9/l
Na^+	136 mmol/l
K^+	5.4 mmol/l
Urea	9.6 mmol/l
Creatinine	167 µmol/l
Bilirubin	14 µmol/l
Alanine aminotransferase (ALT)	35 U/l
Alkaline phosphate	124 U/l

Na^+	136 mmol/l
K^+	5.4 mmol/l
Urea	9.6 mmol/l
Creatinine	167 µmol/l
Bilirubin	14 µmol/l
Alanine aminotransferase (ALT)	35 U/l
Alkaline phosphate	124 U/l
Albumin	38 g/l
Electrocardiogram (ECG)	Sinus tachycardia
Chest X-ray	Normal cardiac silhouette, no focal consolidation

What test would you request to confirm the diagnosis?

A Blood cultures

B Creatine phosphokinase

C Magnetic resonance imaging (MRI)

D Urine culture

E Renal ultrasound scan

Submit

Explanation

B Creatine phosphokinase

This patient has neuroleptic malignant syndrome precipitated by the administration of haloperidol. Clinical features of neuroleptic malignant syndrome include:

- Hypertension, tachycardia and pyrexia
- Muscular rigidity (sometimes with dysphagia and dysarthria)
- Extrapyramidal signs, tremor
- Catatonia–muteness
- Increased serum creatine phosphokinase/aspartate aminotransferase (AST)
- Urinary myoglobin.

A Blood cultures

Although this patient has a significant pyrexia, the normal white count and recent commencement of haloperidol steers us away from sepsis as the likely diagnosis.

C Magnetic resonance imaging (MRI)

Although there are extrapyramidal signs and tremor, they are more likely to be related to haloperidol rather than to an acute neurological event.

D Urine culture

Although urine dipstick is expected to be positive for blood (due to urinary myoglobin) culture is uninformative.

12:09

An 18-year-old school pupil is brought to the Emergency Department by his mother for evaluation of his progressive unsteadiness over the past two months. He has had a poor record of school attainment since entering the sixth form and has developed a progressively worsening habit of sniffing glue and aerosol deodorants over this time period.

Two years ago, he had jaundice which apparently recovered on its own. One year ago, he had a sudden severe pain in his lower back that radiated to his right groin. He had also complained of intermittent blurring of vision, impaired judgement, irritability and excitability.

On examination, he is pale and seems euphoric, he is hypotensive with a pulse of 90/min and a blood pressure (BP) of 100/60 mmHg. Fundus examination reveals pale optic discs, horizontal nystagmus and bilateral limb and gait ataxia. Distal muscles are weak and atrophic. Ankle jerks are absent and plantar reflexes are flexor.

Given the likely diagnosis, what long-term renal complication is of most concern?

A	Rhabdomyolysis
B	Rapidly progressive glomerulonephritis
C	Distal renal tubular acidosis
D	Focal proliferative glomerulonephritis
E	Mesangiocapillary glomerulonephritis

Submit

Rana Alnasser's screen

12:11

MyPastest
https://mypastest.pastest.com

Pastest+

Volatile substance abuse includes the intentional inhalation of organic solvents, vapours, gasoline, aerosol propellants, glues, etc. They are either 'bagged' (sprayed into a plastic bag and inhaled till the subject passes out) or 'huffed' (sprayed on to a cloth and held to the mouth). Features include euphoria, blurring of vision, ataxia, a feeling of omnipotence, delirium, convulsions and status epilepticus. Glue sniffing leads to nervous system problems including optic atrophy, encephalopathy, cerebellar degeneration and sensorimotor polyneuropathy.

Renal toxicity associated with solvent abuse includes proteinuria, distal renal tubular acidosis and renal calculi.

D Focal proliferative glomerulonephritis

FPG is seen in 20-30% of cases of lupus nephritis.

A Rhabdomyolysis

Rhabdomyolysis is seen in association with substance abuse, but it is associated with stimulants such as cocaine and MDMA, rather than solvents.

B Rapidly progressive glomerulonephritis

Causes of RPGN include SLE, Henoch-Schönlein purpura and post-infectious renal vasculitis.

E Mesangiocapillary glomerulonephritis

This is seen across a range of causes of renal vasculitis, but isn't seen in patients who abuse solvents.

12:13
On
594-042-7551
Leave

omnipotence, delirium, convulsions and status epilepticus. Glue sniffing leads to nervous system problems including optic atrophy, encephalopathy, cerebellar degeneration and sensorimotor polyneuropathy.

Renal toxicity associated with solvent abuse includes proteinuria, distal renal tubular acidosis and renal calculi.

D Focal proliferative glomerulonephritis

FPG is seen in 20-30% of cases of lupus nephritis.

A Rhabdomyolysis

Rhabdomyolysis is seen in association with substance abuse, but it is associated with stimulants such as cocaine and MDMA, rather than solvents.

B Rapidly progressive glomerulonephritis

Causes of RPGN include SLE, Henoch-Schönlein purpura and post-infectious renal vasculitis.

E Mesangiocapillary glomerulonephritis

This is seen across a range of causes of renal vasculitis, but isn't seen in patients who abuse solvents.

Rate this question:

Audio Video Share Participants More

12:13

A 71-year-old woman who takes regular digoxin for chronic atrial fibrillation comes to the Emergency Department with syncope. She has been unwell with gastroenteritis over the past few days and now feels very weak and faint.

On examination, her BP is 90/50 mmHg, with pulse 35/min; the 12-lead ECG shows atrial flutter with variable ventricular rate. There are no cardiac murmurs, and her chest appears clear with no signs of fluid overload. There is no peripheral oedema. Abdomen is soft and non-tender with no palpable masses.

She complains of nausea and yellow vision and vomits once whilst you are examining her.

Investigations:

Hb	110 g/l
WCC	7.9×10^9/l
PLT	210×10^9/l
Na^+	140 mmol/l
K^+	6.0 mmol/l
Creatinine	201 umol/l
Urea	15.1 mmol/l
Glucose	7.2 mmol/l

Given the suspected diagnosis, which of the following is the most appropriate next intervention?

A Calcium resonium

B Digibind (Digoxin Immune Fab)

C IV calcium gluconate

Rana Alnasser's screen

12:13

On examination, her BP is 90/50 mmHg, with pulse 55/min, the 12-lead ECG shows atrial flutter with variable ventricular rate. There are no cardiac murmurs, and her chest appears clear with no signs of fluid overload. There is no peripheral oedema. Abdomen is soft and non-tender with no palpable masses.

She complains of nausea and yellow vision and vomits once whilst you are examining her.

Investigations:

Hb	110 g/l
WCC	7.9×10^9/l
PLT	210×10^9/l
Na^+	140 mmol/l
K^+	6.0 mmol/l
Creatinine	201 umol/l
Urea	15.1 mmol/l
Glucose	7.2 mmol/l

Given the suspected diagnosis, which of the following is the most appropriate next intervention?

A Calcium resonium

B Digibind (Digoxin Immune Fab)

C IV calcium gluconate

D IV insulin and dextrose

E IV normal saline

Rana Alnasser's screen

Explanation

B Digibind (Digoxin Immune Fab)

In this situation digoxin toxicity has resulted in significant symptomatic bradycardia, which has undoubtedly contributed to the patient's hypotension. Although renal perfusion would be improved by fluid replacement, it is crucial to allow the ventricular rate to recover, restoring cardiac output. As such, Digibind to reverse digoxin toxicity is the most appropriate next step.

Indications for Digibind use include:

- Life-threatening or haemodynamically unstable arrhythmia (e.g. ventricular tachycardia; ventricular fibrillation; asystole; complete heart block; Mobitz II heart block; symptomatic bradycardia)
- Hyperkalaemia (serum potassium >5 to 5.5 meq/l [>5 to 5.5 mmol/l])
- Evidence of end-organ dysfunction from hypoperfusion (e.g. kidney disease).

A Calcium resonium

There is not yet a precipitous rise in potassium, and correction of ventricular rate, coupled with fluid replacement is likely to correct hyperkalaemia.

C IV calcium gluconate

Calcium gluconate is indicated for life-threatening hyperkalaemia with ECG changes.

D IV insulin and dextrose

12:16
On
594-042-7551
Leave

A 35-year-old woman attends the Gastroenterology Clinic. She has a history of alcohol abuse and has recently discovered she is pregnant.

The patient is concerned about fetal alcohol syndrome that she has read about in the newspapers and is asking about the detrimental effects her alcohol consumption would have on her baby.

What advice would you give her?

A	A thickened upper lip is a characteristic feature of the syndrome
B	Drinking up to 10 units of alcohol per week is potentially healthy for her pregnancy
C	Even drinking 1–2 units of alcohol per week confers increased risk
D	The IQ may be normal in children affected by the syndrome
E	Vitamin supplementation in pregnancy prevents cognitive deficits associated with fetal alcohol syndrome

70805

Submit

Audio
Video
Share
Participants
More

D The IQ may be normal in children affected by the syndrome

Fetal alcohol syndrome is associated with: (1) mental retardation and/or behavioural abnormalities, (2) growth retardation, and (3) mid-facial abnormalities.

The fetus relies on maternal hepatic detoxification of alcohol. Heavy drinking, including binge consumption of alcohol, is thought to be associated with particular risk. Alcohol appears to cross freely between mother and fetus, yet the fetal liver has only 10% of the capacity of the adult liver to detoxify alcohol. Unfortunately it appears that deficits remain throughout adulthood, with individuals who experience fetal alcohol syndrome much more likely to suffer from behavioural difficulties, alcoholism and to be involved in criminal activity. Of note however is that IQ may be normal or even elevated in some cases.

A A thickened upper lip is a characteristic feature of the syndrome

Thinning of the upper lip is characteristic of the condition.

B Drinking up to 10 units of alcohol per week is potentially healthy for her pregnancy

Drinking 1-2 units of alcohol up to 1-2 times per week is not thought to confer increased risk.

C Even drinking 1-2 units of alcohol per week confers increased risk

Modest alcohol consumption of 1-2 units of alcohol 1-2 times per week is not associated with increased risk of fetal alcohol syndrome.

12:19
On 594-042-7551 Leave

A 57-year-old man, who is taking long-term amiodarone therapy, comes to the clinic complaining of heat intolerance, anxiety, regular resting palpitations and diarrhoea.

On examination, his blood pressure (BP) is 145/82 mmHg, his resting pulse is elevated at 90/min. He appears to have a multinodular goitre.

Investigations;

		Normal Values
Hb	12.0 g/dl	
WCC	5.0×10^9/l	
PLT	178×10^9/l	
Na^+	138 mmol/l	
K^+	4.5 mmol/l	
Creatinine	142 µmol/l	
TSH	< 0.05 u/l	< 0.5-4.5
Free T3	8.5 pmol/l	5-10
Free T4	32 pmol/l	10-22
Thyroid autoantibodies	+	
Ultrasound	Multinodular goitre	

You discontinue his amiodarone.

Which of the following other treatments is the most appropriate treatment to control his thyrotoxicosis?

A Radiolodine

Audio Video Share Participants More

		Normal Values
Hb	12.0 g/dl	
WCC	5.0×10^9/l	
PLT	178×10^9/l	
Na^+	138 mmol/l	
K^+	4.5 mmol/l	
Creatinine	142 µmol/l	
TSH	< 0.05 u/l	< 0.5-4.5
Free T3	8.5 pmol/l	5-10
Free T4	32 pmol/l	10-22
Thyroid autoantibodies	+	
Ultrasound	Multinodular goitre	

You discontinue his amiodarone.

Which of the following other treatments is the most appropriate treatment to control his thyrotoxicosis?

A Radioiodine

B Corticosteroids

C Carbimazole

D Potassium perchlorate

E Thyroidectomy

Free T3	8.5 pmol/l	5-10
Free T4	32 pmol/l	10-22
Thyroid autoantibodies	+	
Ultrasound	Multinodular goitre	

You discontinue his amiodarone.

Which of the following other treatments is the most appropriate treatment to control his thyrotoxicosis?

Your answer was correct

A Radioiodine

B Corticosteroids

C Carbimazole

D Potassium perchlorate

E Thyroidectomy

Explanation

C Carbimazole

The picture seen here is very suggestive of amiodarone-induced thyrotoxicosis type 1, related to iodine excess and associated with more pronounced symptoms of thyroid disease, formation of a goitre and positive thyroid autoantibodies. Whilst changing the amiodarone to another appropriate anti-arrhythmic is a crucial first step in

Explanation

C Carbimazole

The picture seen here is very suggestive of amiodarone-induced thyrotoxicosis type 1, related to iodine excess and associated with more pronounced symptoms of thyroid disease, formation of a goitre and positive thyroid autoantibodies. Whilst changing the amiodarone to another appropriate anti-arrhythmic is a crucial first step in therapy, the long half-life of amiodarone means that symptoms do not immediately improve and carbimazole is only usually effective at high dose.

A Radioiodine

This patient is likely to be iodine overloaded because of amiodarone dosing, and hence radioiodine is highly unlikely to be successful in managing the thyrotoxicosis.

B Corticosteroids

Corticosteroids are of value in controlling amiodarone-related thyroiditis, which is less likely to be the cause of thyroid disease here.

D Potassium perchlorate

Perchlorate is designed to gain acute control of thyrotoxicosis in patients with life-threatening symptoms before progressing to surgery.

E Thyroidectomy

Thyroidectomy is usually undertaken once thyroid function has been stabilised, because of the risks of progressing to surgery in patients with ongoing cardiovascular morbidity.

A 35-year-old farm worker has been brought to the Emergency Department having attempted to kill himself by ingesting several mouthfuls of paraquat 2 h previously.

He is alert, and his main complaint is pain in his mouth and a retrosternal burning. His heart rate is 95 beats/min and his blood pressure is 135/70 mmHg. He has a respiratory rate of 18/min, with oxygen saturations reading 97% via a digital probe.

What is the most important step in his management?

A	Application of high-flow oxygen via a tight-fitting face mask
B	Confirm significant paraquat absorption via a urine test
C	Measure plasma paraquat concentration
D	Administer pralidoxime
E	Administer atropine

7576

Submit

B Confirm significant paraquat absorption via a urine test

Paraquat is a bipyridium herbicide used as a weedkiller, and if ingested can be incredibly toxic, affecting almost every organ system.

The qualitative urine test for paraquat is performed by adding 1 ml of urine to a solution of sodium dithionate and sodium hydroxide. If the solution turns blue, paraquat is present; a lighter green indicates diquat or low paraquat concentrations.

Local gastrointestinal irritation occurs initially, followed by hepatocellular dysfunction, kidney disease and chemical pneumonitis/acute respiratory distress syndrome. Perhaps the most well-known consequence of its ingestion is pulmonary fibrosis. This is thought to occur due to oxygen free radical damage, with initial destruction of type I and II alveolar cells and Clara cells, for which paraquat has a predilection, with an energy-dependent uptake via the polyamine pathway. Superoxide radicals are formed in the lungs in the presence of oxygen, which exacerbates lung damage, and therefore its application should be restricted unless absolutely necessary.

C Measure plasma paraquat concentration

If the urine test is positive then a plasma paraquat concentration is the next step. This will give an idea of prognosis and whether haemodialysis/haemoperfusion is warranted, although in practice a very small number of patients are likely to benefit.

A Application of high-flow oxygen via a tight-fitting face mask

Application of high-flow oxygen has no impact on prognosis with respect to pulmonary fibrosis.

pulmonary fibrosis. This is thought to occur due to oxygen free radical damage, with initial destruction of type I and II alveolar cells and Clara cells, for which paraquat has a predilection, with an energy-dependent uptake via the polyamine pathway. Superoxide radicals are formed in the lungs in the presence of oxygen, which exacerbates lung damage, and therefore its application should be restricted unless absolutely necessary.

C Measure plasma paraquat concentration

If the urine test is positive then a plasma paraquat concentration is the next step. This will give an idea of prognosis and whether haemodialysis/haemoperfusion is warranted, although in practice a very small number of patients are likely to benefit.

A Application of high-flow oxygen via a tight-fitting face mask

Application of high-flow oxygen has no impact on prognosis with respect to pulmonary fibrosis.

D Administer pralidoxime

Pralidoxime is an initial step in the treatment of organophosphate poisoning and doesn't have a role in the treatment of paraquat overdose.

E Administer atropine

Atropine is the other step, apart from use of pralidoxime, in the treatment of organophosphate poisoning.

Rate this question:

Next Question

predilection, with an energy-dependent uptake via the polyamine pathway. Superoxide radicals are formed in the lungs in the presence of oxygen, which exacerbates lung damage, and therefore its application should be restricted unless absolutely necessary.

C Measure plasma paraquat concentration

If the urine test is positive then a plasma paraquat concentration is the next step. This will give an idea of prognosis and whether haemodialysis/haemoperfusion is warranted, although in practice a very small number of patients are likely to benefit.

A Application of high-flow oxygen via a tight-fitting face mask

Application of high-flow oxygen has no impact on prognosis with respect to pulmonary fibrosis.

D Administer pralidoxime

Pralidoxime is an initial step in the treatment of organophosphate poisoning and doesn't have a role in the treatment of paraquat overdose.

E Administer atropine

Atropine is the other step, apart from use of pralidoxime, in the treatment of organophosphate poisoning.

Rate this question:

Next Question

12:29
On
594-042-7551
Leave

Pastest+

Question 20 of 128

You attend a lecture where you view data on a new beta-receptor agonist for the treatment of asthma.

According to your understanding of agonism and antagonism, which of the following agents is best described as a non-competitive antagonist drug?

A	Salmeterol
B	Noradrenaline
C	Prazosin
D	Salbutamol
E	Phenoxybenzamine

Submit

Previous Q...

Skip Questi...

Blog About Pastest Contact Us Help

© Pastest 2019

Audio Video Share Participants More

E Phenoxybenzamine

Phenoxybenzamine is a non-competitive α-adrenoreceptor antagonist, which cannot be displaced by endogenous α-receptor ligands. It is the most potent α-blocker available and is used in presurgical treatment of hypertension associated with phaeochromocytoma.

A Salmeterol

Salmeterol is an example of a partial beta agonist. It has a longer half-life than salbutamol and is therefore a component of preventer therapy in the treatment of asthma. When used to excess however it may blunt the effectiveness of salbutamol in the management of asthma exacerbations.

B Noradrenaline

Noradrenaline is a potent endogenous adrenoreceptor agonist, which accounts for its use as an inotropic agent.

C Prazosin

Prazosin is a competitive α-receptor antagonist and is commonly used as add-on therapy in the treatment of hypertension. It isn't used as a first line agent for phaeochromocytoma because of difficulties in obtaining full agonism.

D Salbutamol

Salbutamol is an example of an exogenous β_2-adrenoreceptor agonist. It is relatively short acting, which accounts for its use as a relieving agent in the treatment of asthma.

12:33
On ...
594-042-7551
Leave

A 33-year-old woman has been admitted via the Emergency Department with an overdose of dothiepin. She is drowsy and confused with dilated pupils and hyperreflexia. Her blood pressure is 100/60 mmHg with a pulse of 95 bpm.

Whilst you examine her, you notice that the cardiac monitor shows intermittent runs of ventricular tachycardia and torsades. This coincides with more severe episodes of hypotension.

Result of arterial blood gas are:

pH	7.30
$p_a(O_2)$	13.2 kPa
$p_a(CO_2)$	4.8 kPa
Base excess	-4

The Emergency Department consultant has already begun a magnesium infusion.

Which of the following is the next most appropriate management step?

A Charcoal haemoperfusion

B IV sodium bicarbonate

C Amiodarone infusion

D Ammonium chloride

E Metoprolol

Audio Video Share Participants More

A 25-year-old patient is referred to clinic with sleep disturbances. He describes attacks during the day when he would suddenly fall asleep and he has even suffered these episodes whilst walking. The patient has been getting hallucinations just before falling asleep and occasionally wakes up in the middle of the night unable to move. He has had no attacks in the day when he has consciously lost muscle tone.

On further questioning, he recalls his grandfather having similar problems. He is previously fit and well. Despite trying various methods to improve his sleeping timetable, he is still getting symptoms. Neurological examination is unremarkable.

What pharmacological therapy would best benefit this patient?

A Temazepam

B Methylphenidate

C Clomipramine

D Fluoxetine

E Alcohol

6503

Submit

1:40
404 — Not Found
404 — Not Found
Home Feed | Re
https://mypastest.pastest.com/Secure/TestMe/

succession. It is not unusual for the gag reflex to be retained, as in the present scenario. Clinical diagnosis is confirmed on repetitive nerve stimulation test, which shows a progressive increase in amplitude of the potentials. Treatment is by the use of the trivalent antiserum and guanidine hydrochloride (although this is unproven in the clinical trial setting).

A Guillain-Barré syndrome

This syndrome is associated with ascending paralysis rather than the central symptoms of muscle weakness appearing first, as is seen here. The Miller-Fisher variant does, however, present with central weakness first and, in this case, nerve conduction studies/EMG may be helpful (GBS showing conduction block, and botulism demonstrating abnormalities of neuromuscular transmission) and also CSF examination (which would show an elevated protein in GBS but would be normal in botulism).

B Lambert-Eaton syndrome

Lambert-Eaton syndrome presents with gradual-onset muscle weakness over a number of weeks and is associated with underlying bronchial carcinoma.

C Myasthenia gravis

This is associated with gradual-onset proximal myopathy and is associated with other underlying autoimmune conditions.

1:41

404 — Not Found × | 404 — Not Found × | Home Feed | Re ×

https://mypastest.pastest.com/Secure/TestMe/

A 24-year-old woman who is 8 weeks' pregnant suffers two generalised tonic-clonic seizures on awakening. There is a family history of epilepsy. She has no other past medical history of note and following brain imaging and electroencephalogram (EEG), a diagnosis of idiopathic epilepsy is made. You are considering treatment with an anti-epileptic drug.

Which of the following would prove the most appropriate option for her?

A	Topiramate
B	Sodium valproate
C	Lamotrigine
D	Levetiracetam
E	Sodium valproate/levetiracetam combination

18633

Submit

Previous Q... Skip Questi...

Rana Alnasser's screen

1:43
404 — Not Found × 404 — Not Found × Home Feed | Re
https://mypastest.pastest.com/Secure/TestMe/

A 24-year-old woman who is 8 weeks' pregnant suffers tw generalised tonic-clonic seizures on awakening. There is a family history of epilepsy. She has no other past medical history of note and following brain imaging and electroencephalogram (EEG), a diagnosis of idiopathic epilepsy is made. You are considering treatment with an anti-epileptic drug.

Which of the following would prove the most appropriate option for her?

Your answer was correct

A	Topiramate
B	Sodium valproate
C	Lamotrigine
D	Levetiracetam
E	Sodium valproate/levetiracetam combination

Explanation

C	Lamotrigine

According to 2016 data across 69 pregnancies, the rate of

C Lamotrigine

According to 2016 data across 69 pregnancies, the rate of congenital malformation used at low dose is approximately 2%. This puts it amongst the safest options for treatment c epilepsy in pregnancy.

A Topiramate

Across 17 reported pregnancies in 2016, rates of congenita malformation are estimated at between 4 and 7%.

B Sodium valproate

Rates for major congenital malformation for sodium valproate are as high as those seen for topiramate, at approximately 6%, across 74 pregnancies.

D Levetiracetam

Although low rates of congenital malformation are seen fo levetiracetam, exposure as reported for 2016 across only 11 pregnancies, this drives lamotrigine as the correct answer due to insufficient evidence for levetiracetam.

E Sodium valproate/levetiracetam combination

Combination therapy may have as a baseline the same risk as sodium valproate, or a potentially cumulative increased risk of malformations across the two compounds.

Rate this question:

Next Question

1:43
404 — Not Found
404 — Not Found
Home Feed | Re
On
594-042-7551
Leave
https://mypastest.pastest.com/Secure/TestMe/

Pastes+

A 24-year-old woman who is 8 weeks' pregnant suffers tw generalised tonic-clonic seizures on awakening. There is a family history of epilepsy. She has no other past medical history of note and following brain imaging and electroencephalogram (EEG), a diagnosis of idiopathic epilepsy is made. You are considering treatment with an anti-epileptic drug.

Which of the following would prove the most appropriate option for her?

A	Topiramate
B	Sodium valproate
C	Lamotrigine
D	Levetiracetam
E	Sodium valproate/levetiracetam combination

Submit

Previous Q...
Skip Questi...
Audio
Video
Share
Participants
More

A 52-year-old woman is brought in unconscious by ambulance. On admission to casualty, she has a Glasgow Coma Score (GCS) of 6. Her airway appears to be compromised. Her sister follows by car, and suggests the woman has taken a large overdose of temazepam tablets. She is known to use these on a regular basis and also takes amitriptyline.

Urea and electrolytes are unremarkable, but arterial blood gasses are suggestive of respiratory depression with both raised CO_2 and decreased O_2 levels.

What is the most appropriate management step?

Your answer was correct

A Observation on a high-dependency unit

B Anaesthetic review with consideration for intubation and ventilation

C Repeat dose intravenous (iv) flumazenil

D Repeat dose iv naloxone

E Continuous flumazenil infusion

Explanation

B Anaesthetic review with consideration for intubation and ventilation

In patients who are habituated to benzodiazepines and who also suffer overdose of tricyclic antidepressants, there

Rana Alnasser's screen

1:44
On 594-042-7551 Leave

Explanation

B Anaesthetic review with consideration for intubation and ventilation

In patients who are habituated to benzodiazepines and who also suffer overdose of tricyclic antidepressants, there is a markedly increased risk of seizure activity if flumazenil is used to reverse the benzodiazepine component. As such, with a GCS of < 8, intubation and ventilation is recommended.

A Observation on a high-dependency unit

Given the GCS is < 8, airway protection is essential, therefore intubation and ventilation is preferred.

C Repeat dose intravenous (iv) flumazenil

This may cause only short-term improvement in conscious level, and also increase seizure risk.

D Repeat dose iv naloxone

Naloxone is used for reversal of opiate overdose.

E Continuous flumazenil infusion

Although this will reverse benzodiazepine overdose, it substantially increases the risk of seizures.

Rate this question:

Next Question

Audio Video Share Participants More

A 32-year-old nursing student has been admitted to the Emergency Medical Unit having taken an impulsive overdose of paracetamol 5 h previously.

You have taken paracetamol levels, which indeed are above the treatment line, and have commenced N-acetyl cysteine (NAC) at the appropriate dose. A few minutes after the infusion begins, the patient complains of facial flushing and generalised pruritus. She has no orofacial swelling, and there is no evidence of airways compromise.

Which of the following is the most appropriate intervention?

A	Subcutaneous (sc) 1 mg adrenalin
B	Intramuscular (im) 5 mg adrenalin
C	Stop the infusion temporarily
D	Intravenous (iv) 200 mg hydrocortisone
E	Stop the infusion and switch to oral methionine

7569

Submit

1:47
On 594-042-7551 Leave

A 32-year-old nursing student has been admitted to the Emergency Medical Unit having taken an impulsive overdose of paracetamol 5 h previously.

You have taken paracetamol levels, which indeed are above the treatment line, and have commenced N-acetyl cysteine (NAC) at the appropriate dose. A few minutes after the infusion begins, the patient complains of facial flushing and generalised pruritus. She has no orofacial swelling, and there is no evidence of airways compromise.

Which of the following is the most appropriate intervention?

Your answer was correct

A	Subcutaneous (sc) 1 mg adrenalin
B	Intramuscular (im) 5 mg adrenalin
C	Stop the infusion temporarily
D	Intravenous (iv) 200 mg hydrocortisone
E	Stop the infusion and switch to oral methionine

Explanation

C Stop the infusion temporarily

It is not uncommon for individuals prescribed N-acetyl cysteine (NAC) to suffer a mild anaphylactoid reaction. This may occur in 5% of cases, and can usually be treated by temporarily halting the infusion and giving an antihistamine

Audio Video Share Participants More

C Stop the infusion temporarily

It is not uncommon for individuals prescribed N-acetyl cysteine (NAC) to suffer a mild anaphylactoid reaction. This may occur in 5% of cases, and can usually be treated by temporarily halting the infusion and giving an antihistamine if required. In most cases, the NAC can be recommenced at a slower infusion rate (usually 50 mg/kg over 4 h).

A Subcutaneous (sc) 1 mg adrenalin

Adrenalin is not required in this case as the anaphylactoid reaction is not severe. In any case, sc delivery drives unpredictable absorption. im delivery is usually warranted where adrenalin is required.

B Intramuscular (im) 5 mg adrenalin

Adrenalin im is warranted for patients with airway compromise. In this case, the symptoms will resolve rapidly once the NAC is temporarily discontinued.

D Intravenous (iv) 200 mg hydrocortisone

Adrenalin im is warranted for patients with airway compromise. In this case, the symptoms will resolve rapidly once the NAC is temporarily discontinued.

E Stop the infusion and switch to oral methionine

Patients often vomit after paracetamol overdose, particularly when they have also taken alcohol. This makes it difficult to achieve sufficient oral administration of methionine to be effective.

7569

Rat^ this question:

1:48
594-042-7551
Leave

A 75-year-old widow has been sent in to the Emergency Department by her general practitioner. She has been becoming increasingly confused of late, and it has been noted on a number of occasions that she has been taking her medication incorrectly.

Her atrial fibrillation has been rate-controlled with digoxin for 5 years, but on admission she has a heart rate of 34 beats/min and a systolic blood pressure of 90 mmHg. You suspect that she is digitoxic. Potassium is measured at 4.2 mmol/l on the blood gas analyser.

Which one of the following treatments would be of most benefit?

A	Atropine
B	Adenosine
C	Naloxone
D	Flumazenil
E	Methionine

Submit

Audio
Video
Share
Participants
More

1:49
594-042-7551
Leave

A 75-year-old widow has been sent in to the Emergency Department by her general practitioner. She has been becoming increasingly confused of late, and it has been noted on a number of occasions that she has been taking her medication incorrectly.

Her atrial fibrillation has been rate-controlled with digoxin for 5 years, but on admission she has a heart rate of 34 beats/min and a systolic blood pressure of 90 mmHg. You suspect that she is digitoxic. Potassium is measured at 4.2 mmol/l on the blood gas analyser.

Which one of the following treatments would be of most benefit?

A	Atropine
B	Adenosine
C	Naloxone
D	Flumazenil
E	Methionine

Submit

Audio
Video
Share
Participants
More

A 75-year-old widow has been sent in to the Emergency Department by her general practitioner. She has been becoming increasingly confused of late, and it has been noted on a number of occasions that she has been taking her medication incorrectly.

Her atrial fibrillation has been rate-controlled with digoxin for 5 years, but on admission she has a heart rate of 34 beats/min and a systolic blood pressure of 90 mmHg. You suspect that she is digitoxic. Potassium is measured at 4.2 mmol/l on the blood gas analyser.

Which one of the following treatments would be of most benefit?

Your answer was correct

A	Atropine
B	Adenosine
C	Naloxone
D	Flumazenil
E	Methionine

Explanation

A Atropine

Digoxin is a cardiac glycoside used in the treatment of atrial fibrillation to control the ventricular rate, and in the

1:50
404 — Not Found
404 — Not Found
Home Feed | Re
https://mypastest.pastest.com/Secure/TestMe/

A Atropine

Digoxin is a cardiac glycoside used in the treatment of atrial fibrillation to control the ventricular rate, and in the treatment of heart failure as it is positively inotropic. It acts by blocking the sodium/potassium ATPase pump, and toxicity may lead to bradycardia, atrioventricular blockade and ventricular tachycardia. Treatment consists of withdrawing its use, and treating any underlying metabolic or electrolyte disturbance, particularly hypokalaemia. Atropine and cardiac pacing may increase the ventricular rate, and toxicity may be treated via the administration of digoxin-specific antibody fragments (Digibind). Note that hypokalaemia may predispose to digitalis toxicity at therapeutic doses, and so if a patient is digitoxic and hypokalaemic, then this should also be corrected.

B Adenosine

Adenosine is used to induce transient AV block in patients with paroxysmal SVT to drive potential cardioversion.

C Naloxone

Naloxone is used as a reversal agent in opiate overdose, and has no role to play in the treatment of digoxin overdose.

D Flumazenil

Flumazenil is used as a reversal agent for acute benzodiazepine overdose. It isn't recommended for reversal of overdose in chronic users of benzodiazepines

1:51
404 — Not Found
404 — Not Found
Home Feed | Re
https://mypastest.pastest.com/Secure/TestMe/

Naloxone is used as a reversal agent in opiate overdose, and has no role to play in the treatment of digoxin overdose.

D Flumazenil

Flumazenil is used as a reversal agent for acute benzodiazepine overdose. It isn't recommended for reversal of overdose in chronic users of benzodiazepines because of the risk of inducing seizures.

E Methionine

Methionine is delivered orally and can be used to treat paracetamol overdose where N-acetylcysteine isn't tolerated.

Rate this question:

© Pastest 2019

Rana Alnasser's screen

1:51
404 — Not Found
404 — Not Found
Home Feed | Re
https://mypastest.pastest.com/Secure/TestMe/

Pastest+

A 32-year-old man with a history of HIV diagnosed some two years ago is admitted to the Emergency Department, with abdominal pain and a small increase in his serum creatinine.

He has apparently recently had an alteration made to his anti-retroviral medication. Abdominal examination reveals significant left loin pain consistent with renal colic.

Which of the following medications is recognised to cause the clinical picture seen here?

A	Abacavir
B	Efavirenz
C	Nevirapine
D	Nelfinavir
E	Stavudine

Submit

Previous Q...

Skip Questi...

Rana Alnasser's screen

1:53
594-042-7551 Leave
404 — Not Found | 404 — Not Found | Home Feed | Re
https://mypastest.pastest.com/Secure/TestMe/

Pastes+ Question 44 of 128

A	Abacavir
B	Efavirenz
C	Nevirapine
D	Nelfinavir
E	Stavudine

Resp
Resp
Resp
Resp

Explanation

D Nelfinavir

Although nephrolithiasis is rare with modern protease inhibitors, it is still reported in some patients taking nelfinavir. In contrast to indinavir, which is approximately 20% excreted into the urine, excretion of nelfinavir into urine is less than 3%.

C Nevirapine

Nevirapine is most commonly associated with rash and hepatitis, but not with adverse renal effects.

A Abacavir

Abacavir [illegible] ciated with acute interstitial nephritis, associated [illegible] eosinophilia, blood and proteinuria.

Audio Video Share Participants More

Explanation

D Nelfinavir

Although nephrolithiasis is rare with modern protease inhibitors, it is still reported in some patients taking nelfinavir. In contrast to indinavir, which is approximately 20% excreted into the urine, excretion of nelfinavir into urine is less than 3%.

C Nevirapine

Nevirapine is most commonly associated with rash and hepatitis, but not with adverse renal effects.

A Abacavir

Abacavir is associated with acute interstitial nephritis, associated with eosinophilia, blood and proteinuria.

B Efavirenz

Efavirenz is not thought to be associated with significant adverse renal effects; it is commonly associated with hypertriglyceridaemia.

E Stavudine

Stavudine is associated with proximal renal tubular dysfunction rather than the nephrolithiasis picture seen here.

70814

Rate this question:

1:54

404 — Not Found × | 404 — Not Found × | Home Feed | Re ×

https://mypastest.pastest.com/Secure/TestMe/

A 68-year-old man, drowsy and confused, is brought in to hospital during the night by his carer. He accidentally overdosed on his medication from his dosette box approximately 6 h ago. He has a background of Alzheimer's disease, hypertension, angina and glaucoma. From the dosette box card the patient's medication include temazepam, atenolol and bendrofluazide. Pulse 35 bpm, blood pressure 85/45 mmHg, respiratory rate 14/min, oxygen saturation 98%. There is no pulse response to 2 mg of atropine.

Initial investigations:

Blood gases on air:

pH	7.41
$p_a(O_2)$	9.8 kPa
$p_a(CO_2)$	4.9 kPa

Na^+	139 mmol/l
K^+	4.3 mmol/l
Urea	5.8 mmol/l
Creatinine	61 µmol/l
Bicarbonate	23 mmol/l
Glucose	2.1 mmol/l
Electrocardiogram	Sinus bradycardia 35 bpm

He is given intravenous dextrose; which of the following is the appropriate next intervention?

blood pressure 85/45 mmHg, respiratory rate 14/min, oxygen saturation 98%. There is no pulse response to 2 mg of atropine.

Initial investigations:

Blood gases on air:

pH	7.41
$p_a(O_2)$	9.8 kPa
$p_a(CO_2)$	4.9 kPa

Na^+	139 mmol/l
K^+	4.3 mmol/l
Urea	5.8 mmol/l
Creatinine	61 µmol/l
Bicarbonate	23 mmol/l
Glucose	2.1 mmol/l
Electrocardiogram	Sinus bradycardia 35 bpm

He is given intravenous dextrose; which of the following is the appropriate next intervention?

A Flumazenil

B Haemodialysis

C Activated charcoal

D Glucagon

E Atropine

Rana Alnasser's screen

Urea	5.8 mmol/l
Creatinine	61 µmol/l
Bicarbonate	23 mmol/l
Glucose	2.1 mmol/l
Electrocardiogram	Sinus bradycardia 35 bpm

He is given intravenous dextrose; which of the following is the appropriate next intervention?

Your answer was correct

A Flumazenil

B Haemodialysis

C Activated charcoal

D Glucagon

E Atropine

Explanation

D Glucagon

This man is most likely to have taken an overdose of β-blockers, for which repeated doses of glucagon are known to reverse hypotension and bradycardia; this is thought to be via a β receptor independent effect on cAMP levels and myocardial contractility. It will also help drive correction of his hypoglycaemia.

Explanation

D Glucagon

This man is most likely to have taken an overdose of β-blockers, for which repeated doses of glucagon are known to reverse hypotension and bradycardia; this is thought to be via a β receptor independent effect on cAMP levels and myocardial contractility. It will also help drive correction of his hypoglycaemia.

A Flumazenil

Flumazenil competitively inhibits the action of benzodiazepines. It is useful in reversal of their effect on the central nervous system, but can increase the risk of seizures. This patient does not have respiratory compromise and is at risk of seizures due to hypoglycaemia; as such flumazenil would not be recommended here.

B Haemodialysis

Atenolol overdose can be treated with haemodialysis, particularly when excretion of atenolol is reduced, for example where there is pre-existing chronic renal impairment.

C Activated charcoal

Activated charcoal does not have a role here as all of the atenolol dosed is already likely to have been absorbed.

E Atropine

Bradycardia associated with β-blocker overdose responds

9:47
594-042-7551
Leave
404 — Not Found
404 — Not Found
Home Feed | Re
https://mypastest.pastest.com/Secure/TestMe/Browse

Pastest+

A 70-year-old retired pharmacist is brought in by ambulance having ingested a massive quantity of atenolol tablets. His wife has recently died, and he had made it clear to his close friends that he would rather die than be left alone.

He has a Glasgow Coma Scale (GCS) score of 14/15, with confused conversation, a bradycardia of 30 beats/min and a systolic blood pressure of 85 mmHg. His blood glucose on finger-prick testing is 2.9 mmol/l.

What antidote would be of use in this scenario?

A Naloxone

B Methylene blue

C Glucagon

D Dicobalt edetate

E Pralidoxime

Submit

Previous Q...
Skip Questi...
Audio
Video
Share
Participants
More

9:48
404 — Not Found × 404 — Not Found × Home Feed | Re ×
https://mypastest.pastest.com/Secure/TestMe/Browse

Beta-blockers taken in overdose predictably can cause bradycardia and hypotension, as well as a decreased level of consciousness, seizures and hypoglycaemia. Glucagon can be used as an antidote, and works by increasing myocardial cAMP levels independently of the beta-receptor. This has beneficial inotropic and chronotropic effects.

A Naloxone

Naloxone is the reversal agent for opiates and is therefore not of value here.

B Methylene blue

This is titrated as a reversal agent in methaemoglobinaemia, which may be seen as a result of overdose of amyl nitrate and other potential oxidising agents.

D Dicobalt edetate

This is an agent used in the treatment of cyanide poisoning where, given as early as possible, it reduces tissue binding of cyanide.

E Pralidoxime

Pralidoxime acts by reactivating acetylcholinesterase in poisoning from organophosphate insecticides and nerve agents.

Rana Alnasser's screen

9:48
404 — Not Found × 404 — Not Found × Home Feed | Re ×
https://mypastest.pastest.com/Secure/TestMe/Browse

A 45-year-old bartender is admitted with a febrile illness and productive cough of one week's duration. X-ray of the chest revealed right-sided basal pneumonia and he was started on cephalosporin. On the third day, he was found to have repeated vomiting, following which he became confused.

On examination, temperature was 39 °C, pulse 120/min and blood pressure 130/80 mmHg. He was uncooperative and was plucking at his clothes and pointed in several directions as if he were seeing objects that were not present. He was tremulous and his ankle jerks were absent.

The patient was given chlordiazepoxide by the medical registrar for alcohol withdrawal. The next day, he became drowsy and unsteady. The consultant physician saw him and found that extra-ocular movements were restricted on lateral gaze, and a horizontal nystagmus was elicited. He was disoriented and confused and had gait ataxia. The consultant physician considered a new diagnosis.

What is the most likely diagnosis?

A	Benzodiazepine toxicity
B	Encephalitis
C	Wernicke's encephalopathy
D	Central pontine myelinolysis
E	Brain stem infarction

Rana Alnasser's screen

C Wernicke's encephalopathy

Alcohol abuse is common in persons who have easy access to it, as shown by high rates among those employed in the alcohol trade, among other factors such as cultural and genetic ones. The patient depicted above has features of delirium tremens initially. Laboratory parameters that are useful in confirming alcohol abuse in individual cases are the mean corpuscular volume gamma-glutamyl transferase, both of which are raised in problem drinkers. The patient then developed features of Wernicke's encephalopathy. This often has an abrupt onset with drowsiness, disorientation and an impaired ability to register and recall recent events. Physical examination reveals horizontal nystagmus, evidence of external ocular palsies, ataxia and peripheral neuropathy. Poor nutrition, associated with chronic alcoholism, prolonged vomiting, diarrhoea and severe starvation, are predisposing causes for thiamine deficiency, the cause. Immediate treatment with IV thiamine 50 mg is essential to minimise permanent damage and, given his profession, it might have been prudent to suspect impending Wernicke's and have started empirical treatment earlier.

A Benzodiazepine toxicity

Benzodiazepine toxicity should not be associated with the gaze palsy seen here, and administration of agents such as chlordiazepoxide is crucial to avoid significant morbidity and mortality associated with delirium tremens.

B Encephalitis

Encephalitis is more likely to be associated with memory loss rather than with the specific gaze palsy seen here

D Central pontine myelinolysis

9:54
404 – Not Found × 404 – Not Found × Home Feed | Re ×
https://mypastest.pastest.com/Secure/TestMe/Browse

A 45-year-old bartender is admitted with a febrile illness and productive cough of one week's duration. X-ray of the chest revealed right-sided basal pneumonia and he was started on cephalosporin. On the third day, he was found to have repeated vomiting, following which he became confused.

On examination, temperature was 39 °C, pulse 120/min and blood pressure 130/80 mmHg. He was uncooperative and was plucking at his clothes and pointed in several directions as if he were seeing objects that were not present. He was tremulous and his ankle jerks were absent.

The patient was given chlordiazepoxide by the medical registrar for alcohol withdrawal. The next day, he became drowsy and unsteady. The consultant physician saw him and found that extra-ocular movements were restricted on lateral gaze, and a horizontal nystagmus was elicited. He was disoriented and confused and had gait ataxia. The consultant physician considered a new diagnosis.

What is the most likely diagnosis?

Your answer was correct

A Benzodiazepine toxicity

B Encephalitis

C Wernicke's encephalopathy

D Central pontine myelinolysis

9:54

404 — Not Found | 404 — Not Found | Home Feed | Re

https://mypastest.pastest.com/Secure/TestMe/Browse

B Encephalitis

Encephalitis is more likely to be associated with memory loss rather than with the specific gaze palsy seen here

D Central pontine myelinolysis

Central pontine myelinolysis is associated with rapid correction of hyponatraemia and is associated with muscle paralysis.

E Brain stem infarction

We're given no indication of vascular risk factors, and a specific gaze palsy without other features of posterior territory infarction would be very unusual.

Rate this question:

Next Question

Previous Q... Tag Questi... Feedback End Session

Blog About Pastest Contact Us Help

© Pastest 2019

9:54

404 – Not Found × | 404 – Not Found × | Home Feed | Re ×

https://mypastest.pastest.com/Secure/TestMe/Browse

A 74-year-old man is admitted with urinary retention and symptoms of a urinary tract infection (UTI) to the Elderly Care Ward. He is commenced on intravenous (iv) co-amoxiclav, but remains confused on his second night in hospital. You are asked to review him with respect to intervening in his confusion.

On examination his blood pressure (BP) is 141/70 mmHg, pulse is 82 bpm and he is pyrexial - 37.8 °C. He is agitated and confused, telling you that the nurses are out to get him and trying to leave the ward.

Investigations:

Haemoglobin (Hb)	12.5 g/dl
White cell count (WCC)	14.4×10^9/l
Platelets (PLT)	301×10^9/l
Sodium (Na^+)	136 mmol/l
Potassium (K^+)	4.4 mmol/l
Creatinine (Cr)	149 µmol/l

Which of the following is the most appropriate initial step in managing him?

A Haloperidol

B Lorazepam

C Olanzapine

D Risperidone

9:55
404 – Not Found × 404 – Not Found × Home Feed | Re ×
https://mypastest.pastest.com/Secure/TestMe/Browse

intervening in his confusion.

On examination his blood pressure (BP) is 141/70 mmHg, pulse is 82 bpm and he is pyrexial - 37.8 °C. He is agitated and confused, telling you that the nurses are out to get him and trying to leave the ward.

Investigations:

Haemoglobin (Hb)	12.5 g/dl
White cell count (WCC)	14.4×10^9/l
Platelets (PLT)	301×10^9/l
Sodium (Na^+)	136 mmol/l
Potassium (K^+)	4.4 mmol/l
Creatinine (Cr)	149 µmol/l

Which of the following is the most appropriate initial step in managing him?

A Haloperidol

B Lorazepam

C Olanzapine

D Risperidone

E 1:1 nursing in a safe environment

Rana Alnasser's screen

E 1:1 nursing in a safe environment

Nursing in a well-lit room, with a named nurse (one specifically allotted to the patient) who takes time to explain what is happening to the patient, controlled noise and room temperature are all important initial steps in the management of delirium. This should pre-date pharmacological interventions.

A Haloperidol

Haloperidol is a recommended initial pharmacological intervention for the treatment of delirium, although changes in the nursing environment should form the initial basis for intervention.

B Lorazepam

Lorazepam is an initial pharmacological intervention for the treatment of delirium, particularly where there is a history of movement disorder, although, like haloperidol, it should be reserved for patients who fail to respond to changes in the environment alone.

C Olanzapine

Atypical antipsychotic agents are generally considered a second- or third-line option for the treatment of delirium in the elderly, because of concerns about their cardiovascular risk profile.

D Risperidone

Risperidone is only really considered in the event that patients fail to respond to treatment with haloperidol or lorazepam, or these agents are unsuitable or

A 45-year-old man with hypertension and dyslipidaemia is diagnosed with early type 2 diabetes and commenced on glitazone therapy. He has suffered from psoriasis for many years, which has been resistant to treatment and his dermatologist elects to commence ciclosporin therapy.

He is warned about the potential for drug interactions with ciclosporin and told to carry a card, but you warn him about a few of the common interactions he should be concerned about.

Which of the following drugs or foods should he be most concerned about with respect to increasing his ciclosporin levels?

A	Orange juice
B	Verapamil
C	Amoxicillin
D	Cranberry juice
E	Rifampicin

Submit

A 45-year-old man with hypertension and dyslipidaemia is diagnosed with early type 2 diabetes and commenced on glitazone therapy. He has suffered from psoriasis for many years, which has been resistant to treatment and his dermatologist elects to commence ciclosporin therapy.

He is warned about the potential for drug interactions with ciclosporin and told to carry a card, but you warn him about a few of the common interactions he should be concerned about.

Which of the following drugs or foods should he be most concerned about with respect to increasing his ciclosporin levels?

Your answer was incorrect

A Orange juice

B Verapamil

C Amoxicillin

D Cranberry juice

E Rifampicin

Explanation

B Verapamil

Verapamil is a CYP 450 enzyme inhibitor which leads to a potentially significant elevation in levels of cyclosporine. As such, if possible an alternative agent should be substituted.

Rana Alnasser's screen

B Verapamil

Verapamil is a CYP 450 enzyme inhibitor which leads to a potentially significant elevation in levels of cyclosporine. As such, if possible an alternative agent should be substituted.

A Orange juice

Grapefruit, not orange juice, is an inhibitor of CYP3A4 and can therefore drive an increase in ciclosporin levels. Examples of other agents that increase ciclosporin levels include antifungals, diltiazem, nicardipine, metoclopramide, oral contraceptives, danazol, methylprednisolone (high dose), allopurinol, amiodarone, ursodeoxycholic acid and protease inhibitors.

C Amoxicillin

Macrolides are inhibitors of CYP3A4 and lead to an increase in ciclosporin levels, but penicillins do not.

D Cranberry juice

Cranberry juice is an inhibitor of CYP 2C9, leading to an increase in exposure to warfarin.

E Rifampicin

Rifampicin is a potent CYP450 inducer, leading to a decrease in ciclosporin levels. Other agents known to decrease ciclosporin levels include barbiturates, carbamazepine and phenytoin, octreotide, orlistat and *Hypericum perforatum* (St John's wort).

Rate this question:

10:01
404 – Not Found × 404 – Not Found × Home Feed | Re ×
https://mypastest.pastest.com/Secure/TestMe/Browse

A 71-year-old woman presents to the Ear, Nose and Throat (ENT) Clinic with sensorineural deafness.

You are examining her medication history. This includes use of aciclovir, amoxicillin, co-amoxiclav, oral furosemide and intravenous (iv) erythromycin for a serious lower respiratory tract infection a few years ago, where she was admitted to the Intensive Care Unit (ICU) for a period of time.

Which of these agents would fall under suspicion as a possible contributory cause?

A iv aciclovir

B iv ciprofloxacin

C iv co-amoxiclav

D iv erythromycin

E Oral furosemide

Submit

D iv erythromycin

Like iv gentamycin and iv vancomycin, iv erythromycin is recognised as a rare cause of sensorineural hearing loss. This is likely to be related to overly rapid administration, with loss of hearing linked to the c_{max} of the drug. It has now largely been replaced by oral clarithromycin; absorption of macrolides is such that iv administration is rarely warranted in the conscious patient.

E Oral furosemide

Although iv furosemide is recognised as a cause of sensorineural deafness, particularly in the ITU setting; oral furosemide is not thought to lead to significant hearing loss.

A iv aciclovir

Aciclovir is recognised to cause dizziness and headache, although it does not lead to hearing loss.

B iv ciprofloxacin

The main concern with respect to quinolone use is increased risk of tendon rupture and P450 interaction potential.

C iv co-amoxiclav

Co-amoxiclav is recognised to increase the risk of obstructive jaundice, particularly when used for a period of more than 2 weeks.

A 62-year-old man returns to the Emergency Ward with confusion some two weeks after discharge post-anterior myocardial infarction.

He made a relatively good recovery and was started on a range of medications, including an antidepressant, as he said he was feeling really very depressed after his myocardial infarction. He did have depression which required medication a few years earlier, and felt that his old symptoms were returning. His wife tells you that he has become increasingly vague over the past three to four days.

On examination, his blood pressure (BP) is 125/75 mmHg, his pulse is 78/min and regular. He is euvolaemic.

Investigations:

Hb	13.1 g/dl
WCC	6.1×10^9/l
PLT	201×10^9/l
Na^+	127 mmol/l
K^+	4.9 mmol/l
Creatinine	110 µmol/l

Which of the following agents is most likely to be responsible for his low sodium?

A Ramipril

B Atenolol

C Spironolactone

D Citalopram

myocardial infarction.

He made a relatively good recovery and was started on a range of medications, including an antidepressant, as he said he was feeling really very depressed after his myocardial infarction. He did have depression which required medication a few years earlier, and felt that his old symptoms were returning. His wife tells you that he has become increasingly vague over the past three to four days.

On examination, his blood pressure (BP) is 125/75 mmHg, his pulse is 78/min and regular. He is euvolaemic.

Investigations:

Hb	13.1 g/dl
WCC	6.1×10^9/l
PLT	201×10^9/l
Na^+	127 mmol/l
K^+	4.9 mmol/l
Creatinine	110 µmol/l

Which of the following agents is most likely to be responsible for his low sodium?

A Ramipril

B Atenolol

C Spironolactone

D Citalopram

E Furosemide

Investigations:

Hb	13.1 g/dl
WCC	6.1×10^9/l
PLT	201×10^9/l
Na^+	127 mmol/l
K^+	4.9 mmol/l
Creatinine	110 µmol/l

Which of the following agents is most likely to be responsible for his low sodium?

Your answer was correct

A Ramipril

B Atenolol

C Spironolactone

D Citalopram

E Furosemide

Explanation

D Citalopram

He has been started on citalopram for his depression, and like other CNS-active agents, citalopram may cause syndrome of inappropriate ADH. Presentation with SIADH is unpredictable and may occur some time after starting

D Citalopram

He has been started on citalopram for his depression, and like other CNS-active agents, citalopram may cause syndrome of inappropriate ADH. Presentation with SIADH is unpredictable and may occur some time after starting therapy. Other CNS drug causes include carbamazepine, tricyclic antidepressants, thioridazine and nicotine. Management in this case would involve discontinuation of the citalopram and offering psychotherapy as an alternative, bearing in mind that other SSRIs and tricyclics may also cause SIADH. If citalopram is continued then fluid restriction is unlikely to be effective.

Evidence on the relative increase in risk of SIADH for a range of antidepressants comes from a Danish registry study. Confidence intervals for risk increase are: citalopram 7.8 (CI 7.42-8.20); clomipramine 4.93 (CI 2.72-8.94); duloxetine 2.05 (CI 1.44-292); venlafaxine 2.90 (CI 2.43-3.46); mirtazapine 2.95 (CI 2.71-3.21); and mianserin 0.90 (CI 0.71-1.14).

A Ramipril

Ramipril is not associated with SIADH; the main concern with respect to ACE inhibitor use is hyperkalaemia.

B Atenolol

Atenolol is not associated with hyponatraemia.

C Spironolactone

Spironolactone is used at low dose in the treatment of heart failure, and is therefore less likely to cause hyponatraemia.

study. Confidence intervals for risk increase are: citalopram 7.8 (CI 7.42-8.20); clomipramine 4.93 (CI 2.72-8.94); duloxetine 2.05 (CI 1.44-292); venlafaxine 2.90 (CI 2.43-3.46); mirtazapine 2.95 (CI 2.71-3.21); and mianserin 0.90 (CI 0.71-1.14).

A Ramipril

Ramipril is not associated with SIADH; the main concern with respect to ACE inhibitor use is hyperkalaemia.

B Atenolol

Atenolol is not associated with hyponatraemia.

C Spironolactone

Spironolactone is used at low dose in the treatment of heart failure, and is therefore less likely to cause hyponatraemia.

E Furosemide

Furosemide promotes both salt and water excretion, and it is therefore rarely associated with hyponatraemia in a patient who appears euvolaemic. Hyponatraemia is seen more commonly in patients taking loop diuretics combined with a thiazide, or where there is marked fluid overload.

Rate this question:

Next Question

Previous Q... Tag Questi... Feedback End Session

10:06
594-042-7551
Leave

A 52-year-old man is diagnosed with Parkinson's disease. He has recently started a second family with a new partner and is worried about dyskinesias associated with levodopa and complications of lung fibrosis that he has heard about with other drugs.

Which of the following agents would you recommend?

A	Ropinirole
B	Levodopa
C	Amantadine
D	Cabergoline
E	Apomorphine

20628

Submit

Previous Q... Skip Questi...

© Pastest 2019

Audio Video Share Participants More

10:07
594-042-7551
Leave

A 52-year-old man is diagnosed with Parkinson's disease. He has recently started a second family with a new partner and is worried about dyskinesias associated with levodopa and complications of lung fibrosis that he has heard about with other drugs.

Which of the following agents would you recommend?

Your answer was correct

- A Ropinirole
- B Levodopa
- C Amantadine
- D Cabergoline
- E Apomorphine

Explanation

A Ropinirole

Ropinirole is a non-ergot-derived dopamine agonist licensed for the treatment of Parkinson's disease and, most recently, for restless legs syndrome. Dopamine agonists may be associated with less on/off phenomena than L-dopa-based therapies, although they don't impact on long-term prognosis versus L-dopa. This reduced fluctuation in motor function is potentially more suitable for a patient with a young family.

Audio Video Share Participants More

10:07
594-042-7551
Leave

A Ropinirole

Ropinirole is a non-ergot-derived dopamine agonist licensed for the treatment of Parkinson's disease and, most recently, for restless legs syndrome. Dopamine agonists may be associated with less on/off phenomena than L-dopa-based therapies, although they don't impact on long-term prognosis versus L-dopa. This reduced fluctuation in motor function is potentially more suitable for a patient with a young family.

B Levodopa

This may be associated with greater dyskinesia versus ropinirole, driving this as the second-choice agent in this patient.

C Amantadine

Amantadine only has mild anti-parkinsonian effects and is less effective versus both L-dopa and ropinirole. As such it isn't the first-choice therapy here.

D Cabergoline

Cabergoline is an ergot-derived dopamine agonist which is associated with increased risk of fibrotic disease.

E Apomorphine

Apomorphine is delivered by subcutaneous pump. It is effective in advanced Parkinson's, but the mode of delivery means it isn't usually used early on in the time course of the disease.

Audio Video Share Participants More

10:08
594-042-7551
Leave

A 22-year-old woman is admitted with a paracetamol overdose. She has a background history of depression and is on a selective serotonin reuptake inhibitor (SSRI). Her friends and family are concerned she may have taken other medications beside paracetamol, as she had stockpiled at least three months' supply of her citalopram.

Which of the following findings might you find if the patient had overdosed on an SSRI?

A	Hyperreflexia
B	Upgoing plantars
C	Miosis
D	Bradykinesia
E	Apraxia

32798

Submit

Previous Q...
Skip Questi...

© Pastest 2019

Audio Video Share Participants More

A 22-year-old woman is admitted with a paracetamol overdose. She has a background history of depression and is on a selective serotonin reuptake inhibitor (SSRI). Her friends and family are concerned she may have taken other medications beside paracetamol, as she had stockpiled at least three months' supply of her citalopram.

Which of the following findings might you find if the patient had overdosed on an SSRI?

Your answer was correct

A Hyperreflexia

B Upgoing plantars

C Miosis

D Bradykinesia

E Apraxia

Explanation

A Hyperreflexia

Overdose of SSRIs can cause the serotonin syndrome, although toxicity is rarely seen unless a massive overdose of SSRI is taken. Examples of symptoms of toxicity include restlessness, hallucinations and sweating. Signs include hyperthermia, hyperreflexia, myoclonus, ataxia, mydriasis and tachycardia. Management of SSRI overdose is supportive, with benzodiazepines the drug of choice to

Explanation

A Hyperreflexia

Overdose of SSRIs can cause the serotonin syndrome, although toxicity is rarely seen unless a massive overdose of SSRI is taken. Examples of symptoms of toxicity include restlessness, hallucinations and sweating. Signs include hyperthermia, hyperreflexia, myoclonus, ataxia, mydriasis and tachycardia. Management of SSRI overdose is supportive, with benzodiazepines the drug of choice to reduce agitation, intervention may also be required for blood pressure control.

B Upgoing plantars

Upgoing plantars are seen in the serotonin syndrome and in neuroleptic malignant syndrome, although they are less likely to be present than hyperreflexia.

C Miosis

Mydriasis, not miosis, is seen in patients with the serotonin syndrome/where there is an SSRI overdose.

D Bradykinesia

Bradykinesia is a feature of the neuroleptic malignant syndrome.

E Apraxia

Apraxia is not commonly seen in association with SSRI overdose, but is seen in offspring of mothers treated with SSRIs.

10:10

A 28-year-old woman is admitted to the Emergency department in an unconscious state. She was found by her boyfriend, who informs you that they had a row that evening. He found an empty bottle of amitriptyline 75 mg tablets next to her. Apparently, the prescription had been filled three days earlier at the pharmacy.

On examination, she has a Glasgow Coma Scale (GCS) score of 6 and her blood pressure (BP) is 90/50 mmHg. Her pulse is weak and rapid and you glance at the electrocardiogram (ECG) monitor, which shows that she is in ventricular tachycardia.

Investigations:

Haemoglobin (Hb)	13.0 g/dl
White cell count (WCC)	5.0×10^9/l
Platelets (PLT)	25×10^9/l
Sodium (Na^+)	138 mmol/l
Potassium (K^+)	4.8 mmol/l
Creatinine (Cr)	110 µmol/l
pH	7.28
pO_2	8.0 kPa
pCO_2	5.4 kPa

Which of the following represents the most appropriate agent to manage her ventricular tachycardia (VT) (bicarbonate has already been administered)?

A Bretylium

B Amiodarone

Rana Alnasser's screen

score of 6 and her blood pressure (BP) is 90/50 mmHg. Her pulse is weak and rapid and you glance at the electrocardiogram (ECG) monitor, which shows that she is in ventricular tachycardia.

Investigations:

Haemoglobin (Hb)	13.0 g/dl
White cell count (WCC)	5.0×10^9/l
Platelets (PLT)	25×10^9/l
Sodium (Na^+)	138 mmol/l
Potassium (K^+)	4.8 mmol/l
Creatinine (Cr)	110 µmol/l
pH	7.28
pO_2	8.0 kPa
pCO_2	5.4 kPa

Which of the following represents the most appropriate agent to manage her ventricular tachycardia (VT) (bicarbonate has already been administered)?

A Bretylium

B Amiodarone

C Quinidine

D Procainamide

E Lignocaine

E Lignocaine

Lignocaine increases the electrical stimulation threshold of the ventricle, suppressing automaticity of conduction and terminating ventricular tachycardia. It is usually given as a bolus followed by a continuous infusion at lower dose. In contrast to the other agents, it does not lengthen the QT interval further and is therefore the optimal intervention in patients who fail to gain rhythm control with bicarbonate alone.

A Bretylium

Bretylium works by inhibiting voltage-gated potassium channels, and leads to QT prolongation; as such, it isn't an optimal intervention here.

B Amiodarone

Like the other incorrect options, amiodarone prolongs the action potential. It is thought to work by inhibiting sodium/potassium-activated myocardial ATP.

C Quinidine

Quinidine blocks the fast inward sodium channel, and therefore increases the duration of the action potential. It increases the risk of VT in this situation.

D Procainamide

The mode of action of procainamide is similar to quinidine; as such, it isn't an appropriate intervention here because it increases the duration of the action potential.

10:14
594-042-7551
Leave
404 — Not Found
404 — Not Found
Home Feed | Re
https://mypastest.pastest.com/Secure/TestMe/Brows

Pastest+

A 59-year-old man, who has spent a long period of time on the ITU after MRSA septicaemia, a myocardial infarction and subsequent left ventricular failure, attends the clinic for follow-up. He complains of dizziness and tinnitus; he says the dizziness is worse if he goes out at night or he turns his head quickly.

On examination, you can reproduce his dizziness on rapid movements of the head. The remainder of the clinical examination is unremarkable.

Which of the following is the most likely cause of his symptoms?

A	Vancomycin toxicity
B	Furosemide toxicity
C	Vestibular stroke
D	Aspirin toxicity
E	Vestibular neuronitis

Submit

Audio
Video
Share
Participants
More

A 59-year-old man, who has spent a long period of time on the ITU after MRSA septicaemia, a myocardial infarction and subsequent left ventricular failure, attends the clinic for follow-up. He complains of dizziness and tinnitus; he says the dizziness is worse if he goes out at night or he turns his head quickly.

On examination, you can reproduce his dizziness on rapid movements of the head. The remainder of the clinical examination is unremarkable.

Which of the following is the most likely cause of his symptoms?

Your answer was correct

A Vancomycin toxicity

B Furosemide toxicity

C Vestibular stroke

D Aspirin toxicity

E Vestibular neuronitis

Explanation

A Vancomycin toxicity

Vancomycin may be used as part of the treatment regime for MRSA. Given that this man has spent a considerable amount of time on the intensive therapy unit, it is likely that he has been treated with vancomycin. Several reports of

A Vancomycin toxicity

Vancomycin may be used as part of the treatment regime for MRSA. Given that this man has spent a considerable amount of time on the intensive therapy unit, it is likely that he has been treated with vancomycin. Several reports of toxicity exist, which is manifest primarily as tinnitus, but other vestibular symptoms may be reported, including dizziness. Adequate testing of vancomycin levels, aiming to maintain them within the target range, is crucial to avoid toxicity

B Furosemide toxicity

Furosemide toxicity is more commonly associated with hearing loss as the primary symptom and is very rarely seen as a result of awareness of the need for slow IV administration.

C Vestibular stroke

A vestibular stroke without other neurological signs would be highly unlikely.

D Aspirin toxicity

Aspirin toxicity is associated with acute tinnitus in the first few hours after overdose, not with chronic vestibular dysfunction of the type seen here.

E Vestibular neuronitis

Given the history of exposure to vancomycin, this is much more likely to be the underlying cause of symptoms than viral neuronitis.

10:15
404 – Not Found
404 – Not Found
Home Feed | Re
https://mypastest.pastest.com/Secure/TestMe/Brows

Pastest+

Question 51 of 83

A 26-year-old man with a history of psoriasis returns from a 3-week holiday to India with rapidly worsening psoriasis. He took antimalarials and antibiotics with him. His condition is normally mild and managed with topical therapies only.

On examination, he has widespread psoriasis, which is contiguous in many areas.

Which of the following is the most likely causative agent?

A	Ciprofloxacin
B	Metronidazole
C	Chloroquine
D	Amoxicillin
E	Oxytetracycline

Submit

Previous Q...

Skip Questi...

Rana Alnasser's screen

10:16
404 – Not Found × 404 – Not Found × Home Feed | Re ×
https://mypastest.pastest.com/Secure/TestMe/Brows

A 26-year-old man with a history of psoriasis returns from a 3-week holiday to India with rapidly worsening psoriasis. He took antimalarials and antibiotics with him. His condition is normally mild and managed with topical therapies only.

On examination, he has widespread psoriasis, which is contiguous in many areas.

Which of the following is the most likely causative agent?

Your answer was correct

A Ciprofloxacin

B Metronidazole

C Chloroquine

D Amoxicillin

E Oxytetracycline

Explanation

C Chloroquine

Whilst it is difficult to establish the link between

C Chloroquine

Whilst it is difficult to establish the link between antimalarials and psoriasis from clinical trials, case reports of psoriasis associated with antimalarial therapy have stimulated original discussion about drug-induced psoriasis. One paper from 1997 postulated that the effect of antimalarials on trans-glutaminase activity leads to stimulation of epidermal proliferation, and thus chloroquine is the appropriate answer here.

A Ciprofloxacin

Quinolones are not recognised as a cause of worsening psoriasis - they are associated with tendonopathy, which precludes their use in pregnant women.

B Metronidazole

Metronidazole is not a cause of psoriasis but is linked to the development of pustular skin rashes.

D Amoxicillin

Penicillins are not associated with increased risk of psoriasis, but are associated with pruritis and urticaria.

E Oxytetracycline

Although oxytetracycline may increase the risk of psoriasis, the impact on risk is not thought to be as great as that seen for antimalarials.

Rate this question:

A 48-year-old man who was previously seen in the clinic for abdominal obesity, hypertension and dyslipidaemia presents six months later for review after having lost 42 lbs in weight.

On examination in the clinic, his blood pressure (BP) is 155/92 mmHg and his body mass index (BMI) is 28.

Investigations:

Hb	13.9 g/dl
WCC	5.9×10^9/l
PLT	230×10^9/l
Na^+	139 mmol/l
K^+	4×10^9/l
Creatinine	100 micromol/l
LDL	4.4 mmol/l
TG	3.5 mmol/l
HDL	0.7 mmol/l
Fasting glucose	6.8 mmol/l (< 6.1)

Which of the following is true in this case?

A His cardiovascular risk is not increased

B He does not require anti-hypertensive therapy

C It would be reasonable to treat him with a statin

D He should be considered for gastric reduction surgery

Rana Alnasser's screen

On examination in the clinic, his blood pressure (BP) is 155/92 mmHg and his body mass index (BMI) is 28.

Investigations:

Hb	13.9 g/dl
WCC	5.9×10^9/l
PLT	230×10^9/l
Na^+	139 mmol/l
K^+	4×10^9/l
Creatinine	100 micromol/l
LDL	4.4 mmol/l
TG	3.5 mmol/l
HDL	0.7 mmol/l
Fasting glucose	6.8 mmol/l (< 6.1)

Which of the following is true in this case?

A His cardiovascular risk is not increased

B He does not require anti-hypertensive therapy

C It would be reasonable to treat him with a statin

D He should be considered for gastric reduction surgery

E He is not at increased risk of development of diabetes

C It would be reasonable to treat him with a statin

Of particular concern in this patient is the typical lipid pattern seen in insulin-resistant states, with low HDL cholesterol and high triglycerides. Given his increased lifetime risk of cardiovascular disease, it would therefore be sensible to treat him with a statin.

A His cardiovascular risk is not increased

This patient has signs of insulin resistance, and a low HDL which drives a raised LDL : HDL ratio; as such, cardiovascular risk is increased in this patient.

B He does not require anti-hypertensive therapy

A blood pressure (BP) of 155/92 in a patient with signs of insulin resistance means that intervention with anti-hypertensive therapy is warranted.

D He should be considered for gastric reduction surgery

This patient has already lost a significant amount of weight. As such, gastric reduction surgery isn't warranted.

E He is not at increased risk of development of diabetes

A fasting glucose of 6.8 is on the cusp of diabetes, meaning that conversion is likely over the next few years.

Rate this question:

Next Question

10:20
594-042-7551
Leave

A 24-year-old homeless man, well known to the Accident and Emergency Department, is admitted by ambulance after having a convulsive seizure in the street.

On examination, he is post-ictal and cannot be woken up. His BP is 95/60 mmHg, pulse is 90 and regular. You arrange a toxicology screen that demonstrates ethylene glycol levels of 8.2 mmol/l. He also has a metabolic acidosis with a pH of 7.15 and bicarbonate levels of 10 mmol/l. A bag of N saline to run over 1 h is commenced.

Which of the following is the most important next intervention for him?

A	Methanol infusion
B	IV 8.4% sodium bicarbonate
C	IV furosemide
D	IV disulfiram
E	IV N-acetylcysteine

Submit

Previous Q... Skip Questi...

Audio Video Share Participants More

A 24-year-old homeless man, well known to the Accident and Emergency Department, is admitted by ambulance after having a convulsive seizure in the street.

On examination, he is post-ictal and cannot be woken up. His BP is 95/60 mmHg, pulse is 90 and regular. You arrange a toxicology screen that demonstrates ethylene glycol levels of 8.2 mmol/l. He also has a metabolic acidosis with a pH of 7.15 and bicarbonate levels of 10 mmol/l. A bag of N saline to run over 1 h is commenced.

Which of the following is the most important next intervention for him?

Your answer was correct

A Methanol infusion

B IV 8.4% sodium bicarbonate

C IV furosemide

D IV disulfiram

E IV N-acetylcysteine

Explanation

B IV 8.4% sodium bicarbonate

Ethylene glycol toxicity is caused by its metabolites. The compound is metabolised by alcohol dehydrogenase; as such, competitive inhibition of alcohol dehydrogenase via

Explanation

B IV 8.4% sodium bicarbonate

Ethylene glycol toxicity is caused by its metabolites. The compound is metabolised by alcohol dehydrogenase; as such, competitive inhibition of alcohol dehydrogenase via ethanol infusion or using 4-methylpyrazole (fomepizole) represents the most appropriate treatment.
4-Methylpyrazole may be preferable where it is available, as it does not cause intoxication. Where pH is <7.2, correction with IV sodium bicarbonate is recommended.

A Methanol infusion

Methanol is metabolised to formic acid, which in itself is toxic, leading to metabolic acidosis and optic atrophy.

C IV furosemide

In this case aggressive fluid replacement, rather than diuresis, is the intervention of choice.

D IV disulfiram

Disulfiram inhibits aldehyde dehydrogenase, and is used as an adjunct to behavioural therapy in the treatment of chronic alcoholism.

E IV N-acetylcysteine

N-acetylcysteine etylecysteine is used in the treatment of paracetamol overdose, and in the treatment of hepatic encephalopathy.

Pate this question:

A 36-year-old woman is admitted to the Emergency Department having taken a combined overdose of amitriptyline, diazepam and codeine phosphate. She is known to the department with multiple previous admissions due to alcohol intoxication, and left a suicide note after a recent split from her partner.

On examination, her BP is 100/60 mmHg, with pulse 95/min and regular. GCS is 7. ECG reveals a QRS of 90 ms. Arterial blood gas reveals a pH of 7.29.

Which of the following is the most appropriate next step in her management?

A	IV sodium bicarbonate
B	IV flumazenil
C	Intubation and ventilation
D	IV naloxone
E	IV normal saline

Submit

amitriptyline, diazepam and codeine phosphate. She is known to the department with multiple previous admissions due to alcohol intoxication, and left a suicide note after a recent split from her partner.

On examination, her BP is 100/60 mmHg, with pulse 95/min and regular. GCS is 7. ECG reveals a QRS of 90 ms. Arterial blood gas reveals a pH of 7.29.

Which of the following is the most appropriate next step in her management?

Your answer was correct

A IV sodium bicarbonate

B IV flumazenil

C Intubation and ventilation

D IV naloxone

E IV normal saline

Explanation

C Intubation and ventilation

With a GCS of 7, which may fall further as the overdose continues to take effect, there is significant risk of airway compromise. Reversal agents may actually increase agitation or raise the risk of seizures, and should therefore be avoided here.

A IV sodium bicarbonate

Rana Alnasser's screen

C Intubation and ventilation

With a GCS of 7, which may fall further as the overdose continues to take effect, there is significant risk of airway compromise. Reversal agents may actually increase agitation or raise the risk of seizures, and should therefore be avoided here.

A IV sodium bicarbonate

IV sodium bicarbonate is indicated for QRS prolongation (>100 ms) and for significant acidosis.

B IV flumazenil

In patients who are habitual users of benzodiazepines, particularly in conjunction with tricyclic antidepressants, reversal should be avoided because it can significantly increase the risk of seizures.

D IV naloxone

Naloxone is short-acting, and therefore boluses have a limited impact on improving consciousness. It can be given as an infusion, but given the mixed nature of the overdose here, intubation and ventilation is the better option.

E IV normal saline

Although fluid resuscitation is important, airway protection is the most important next step.

Rate this question:

Rana Alnasser's screen

A 53-year-old civil servant has been referred to the medical team having suffered sudden onset of lip swelling. She is known to have hypertension, and her general practitioner has recently made a medication change for this.

On examination, she has swelling of her lips and tongue, but fortunately no evidence of airways compromise.

What is the most likely pharmacological culprit?

A Metoprolol

B Chlorthalidone

C Ramipril

D Doxazosin

E Amlodipine

71085

Submit

Previous Q... Skip Questi...

© Pastest 2019

10:24
594-042-7551
Leave

A 53-year-old civil servant has been referred to the medical team having suffered sudden onset of lip swelling. She is known to have hypertension, and her general practitioner has recently made a medication change for this.

On examination, she has swelling of her lips and tongue, but fortunately no evidence of airways compromise.

What is the most likely pharmacological culprit?

Your answer was correct

A	Metoprolol
B	Chlorthalidone
C	Ramipril
D	Doxazosin
E	Amlodipine

Explanation

C	Ramipril

Angiotensin-converting enzyme (ACE) inhibitors, like most drugs, have many side effects/adverse drug reactions. One well-recognised adverse effect is angioedema, with swelling of the lips and tongue, and this reaction may occur with variable delay after commencing the drug. It is thought to be related to inhibition of bradykinin metabolism and increased levels of substance P.

Audio Video Share Participants More

C Ramipril

Angiotensin-converting enzyme (ACE) inhibitors, like most drugs, have many side effects/adverse drug reactions. One well-recognised adverse effect is angioedema, with swelling of the lips and tongue, and this reaction may occur with variable delay after commencing the drug. It is thought to be related to inhibition of bradykinin metabolism and increased levels of substance P. Epidemiological data suggest an incidence of up to 0.7% in patients taking ACE inhibitors, and that the risk is 10 times higher in African Americans.

A Metoprolol

Although metoprolol may be associated with the development of angioedema, the incidence with hypertensives other than ACE inhibitors is approximately 10-fold lower.

B Chlorthalidone

Angioedema occurred in 0,05% of elderly patients prescribed chlorthalidone in the ALLHAT study versus 0.41% of patients allocated to lisinopril.

D Doxazosin

Data from ALLHAT also support low rates of angioedema in patients prescribed alpha blockers, running at 0.06%.

E Amlodipine

Although case reports exist which support a role for amlodipine in causing angioedema, rates were low at 0.03% in patients prescribed amlodipine as part of the

Rana Alnasser's screen

10:24

A 71-year-old woman presents to the Emergency Department some six days after being commenced on ciprofloxacin 500 mg BD for an MRSA-positive injection site abscess. Although she felt there was some initial improvement in erythema, over the past day the area of infection appears to have grown again and she feels feverish.

Examination reveals a temperature of 37.8 °C, BP is 132/80 mmHg and pulse is 80/min and regular.

Which of the following is the most likely cause of the worsening of symptoms?

A	Co-infection with other bacteria
B	Evolving resistance to ciprofloxacin
C	Inadequate ciprofloxacin dose
D	Inadequate tissue penetration
E	Inadequate treatment duration

Submit

Previous Q... Skip Questi...

Rana Alnasser's screen

A 71-year-old woman presents to the Emergency Department some six days after being commenced on ciprofloxacin 500 mg BD for an MRSA-positive injection site abscess. Although she felt there was some initial improvement in erythema, over the past day the area of infection appears to have grown again and she feels feverish.

Examination reveals a temperature of 37.8 °C, BP is 132/80 mmHg and pulse is 80/min and regular.

Which of the following is the most likely cause of the worsening of symptoms?

Your answer was correct

A Co-infection with other bacteria

B Evolving resistance to ciprofloxacin

C Inadequate ciprofloxacin dose

D Inadequate tissue penetration

E Inadequate treatment duration

Explanation

B Evolving resistance to ciprofloxacin

Use of fluoroquinolones to treat skin and soft tissue MRSA infections is not recommended. This is because of widespread resistance, and evolving resistance during

B Evolving resistance to ciprofloxacin

Use of fluoroquinolones to treat skin and soft tissue MRSA infections is not recommended. This is because of widespread resistance, and evolving resistance during therapy on an individual patient basis which has been described for the class. Even quinolones with enhanced anti-staphylococcal activity, such as levofloxacin, are not recommended.

A Co-infection with other bacteria

This is highly unlikely given that no other growth is reported in the scenario.

C Inadequate ciprofloxacin dose

500 mg BD is the usual high dose delivered orally for ciprofloxacin, and the drug has an absolute bioavailability of approximately 70-80%.

D Inadequate tissue penetration

Ciprofloxacin has good tissue penetration, where in areas of inflammation/infection, tissue concentrations higher than those measured in plasma are usually recorded.

E Inadequate treatment duration

Given that her symptoms are worsening despite 6 days of antibiotics, inadequate treatment duration is incorrect.

Rate this question:

Next Question

10:27

A 39-year-old woman with a history of manic-depressive disorder visits her general practitioner (GP) for review. She is currently treated with lithium therapy.

The GP has been monitoring her blood pressure for the last few months; it is 155/105 mmHg in the clinic and he is keen to commence pharmacotherapy.

Which of the following antihypertensives carries least risk when co-prescribed with lithium?

A	Bendroflumethiazide
B	Acetazolamide
C	Amlodipine
D	Enalapril
E	Valsartan

Submit

Previous Q... Skip Questi...

© Pastest 2019

Rana Alnasser's screen

A 39-year-old woman with a history of manic-depressive disorder visits her general practitioner (GP) for review. She is currently treated with lithium therapy.

The GP has been monitoring her blood pressure for the last few months; it is 155/105 mmHg in the clinic and he is keen to commence pharmacotherapy.

Which of the following antihypertensives carries least risk when co-prescribed with lithium?

Your answer was correct

A	Bendroflumethiazide
B	Acetazolamide
C	Amlodipine
D	Enalapril
E	Valsartan

Explanation

C Amlodipine

Diuretics, ARBs and ACE inhibitors lead to an increase in lithium concentration. Although the calcium channel antagonist class that includes amlodipine may lead to a syndrome of ataxia, confusion and sleepiness, this is uncommon, meaning that the balance of risk-benefit is positive in favour of amlodipine versus the other options

C Amlodipine

Diuretics, ARBs and ACE inhibitors lead to an increase in lithium concentration. Although the calcium channel antagonist class that includes amlodipine may lead to a syndrome of ataxia, confusion and sleepiness, this is uncommon, meaning that the balance of risk-benefit is positive in favour of amlodipine versus the other options given here.

A Bendroflumethiazide

Thiazide diuretics lead to paradoxical salt and water retention and are a recognised cause of lithium intoxication.

B Acetazolamide

Acetazolamide, like other carbonic anhydrase inhibitors, can drive increased lithium excretion, actually leading to increased symptoms of bipolar disorder.

D Enalapril

ACE inhibitors are recognised to decrease GFR on initiation, although over time they retard progression of renal disease. This is associated with a 7-fold increase in admission for lithium toxicity where they are co-prescribed.

E Valsartan

Like ACE inhibitors, ARBs increase the risk of retention of lithium, significantly raising the risk of lithium toxicity in patients where they are co-prescribed.

Rate this question:

A 42-year-old homeless man presents to the Emergency Department. Four hours previously, he had been seen in his normal state.

On admission, he has Glasgow Coma Scale (GCS) score of 4, is afebrile, pulse 80 bpm, blood pressure 60/30 mmHg and RR 24/min. his pupils are dilated and unreactive. His fundi have blurred disc edges, and his breath smells sweet.

Investigations:

Urinalysis	ketones +
Glucose	3.0 mmol/l
Lactate	4.0 mmol/l
Plasma osmolar gap	34
Na^+	141 mmol/l
K^+	3.2 mmol/l
Urea	9.0 mmol/l
Creatinine	250 µmol/l
Chloride	107 mmol/l
Bicarbonate	14 mmol/l
Calcium	2.28mmol/l
Prothrombin time	13.1 s
Salicylate	Not detected
Arterial blood gas (ABG)	$p_a(O_2)$ 13.0 kPa, $p_a(CO_2)$ 2.0 kPa

What is the most likely diagnosis?

A Lactic acidosis

B Methanol poisoning

Urinalysis	ketones +
Glucose	3.0 mmol/l
Lactate	4.0 mmol/l
Plasma osmolar gap	34
Na^+	141 mmol/l
K^+	3.2 mmol/l
Urea	9.0 mmol/l
Creatinine	250 µmol/l
Chloride	107 mmol/l
Bicarbonate	14 mmol/l
Calcium	2.28mmol/l
Prothrombin time	13.1 s
Salicylate	Not detected
Arterial blood gas (ABG)	$p_a(O_2)$ 13.0 kPa, $p_a(CO_2)$ 2.0 kPa

What is the most likely diagnosis?

A Lactic acidosis

B Methanol poisoning

C Paracetamol poisoning

D Ethylene glycol poisoning

E Diabetic ketosis

10:30
594-042-7551 Leave

B Methanol poisoning

This man has presented with sudden onset of collapse and a profound metabolic acidosis with a prolonged anion gap. The normal blood glucose precludes diabetic ketoacidosis, and lactic acidosis requires, by definition, a lactate of 5.0 mmol/l. Paracetamol poisoning can lead to coma and a metabolic acidosis, but here the rapidity of onset (with no evidence of encephalopathy 4 h previously) and normal coagulation are not supportive of the diagnosis. A high anion gap and high plasma osmolar gap point towards an ingested exogenous osmolar agent. The disc changes and normal calcium point towards methanol over ethylene glycol as a causative agent and this could be confirmed with methanol levels. The urgent treatment required is intravenous ethanol ± haemodialysis but even with rapid treatment sight loss is common. Where available, fomepizole is a reasonable alternative, and has the advantage that it does not lead to depression of consciousness.

A Lactic acidosis

Lactic acidosis is more likely to be associated with metformin use in the context of renal impairment.

C Paracetamol poisoning

A normal prothrombin time in the context of significant metabolic acidosis makes paracetamol overdose unlikely, as significant impairment of liver synthetic function would be expected.

D Ethylene glycol poisoning

Ethylene glycol poisoning, in contrast to methanol poisoning, is not associated with optic atrophy.

Audio Video Share Participants More

intravenous ethanol ± haemodialysis but even with rapid treatment sight loss is common. Where available, fomepizole is a reasonable alternative, and has the advantage that it does not lead to depression of consciousness.

A Lactic acidosis

Lactic acidosis is more likely to be associated with metformin use in the context of renal impairment.

C Paracetamol poisoning

A normal prothrombin time in the context of significant metabolic acidosis makes paracetamol overdose unlikely, as significant impairment of liver synthetic function would be expected.

D Ethylene glycol poisoning

Ethylene glycol poisoning, in contrast to methanol poisoning, is not associated with optic atrophy.

E Diabetic ketosis

Diabetic ketoacidosis presenting as a new diagnosis in a man of 42 would be less likely than a methanol overdose, particularly given the optic disc changes.

anion gap and high plasma osmolar gap point towards an ingested exogenous osmolar agent. The disc changes and normal calcium point towards methanol over ethylene glycol as a causative agent and this could be confirmed with methanol levels. The urgent treatment required is intravenous ethanol ± haemodialysis but even with rapid treatment sight loss is common. Where available, fomepizole is a reasonable alternative, and has the advantage that it does not lead to depression of consciousness.

A Lactic acidosis

Lactic acidosis is more likely to be associated with metformin use in the context of renal impairment.

C Paracetamol poisoning

A normal prothrombin time in the context of significant metabolic acidosis makes paracetamol overdose unlikely, as significant impairment of liver synthetic function would be expected.

D Ethylene glycol poisoning

Ethylene glycol poisoning, in contrast to methanol poisoning, is not associated with optic atrophy.

E Diabetic ketosis

Diabetic ketoacidosis presenting as a new diagnosis in a man of 42 would be less likely than a methanol overdose, particularly given the optic disc changes.

Rate this question:

10:32

A 64-year-old man is admitted to the Emergency Department with a cough productive of green sputum and a severe deterioration in cough and shortness of breath related to underlying chronic obstructive pulmonary disease (COPD). He normally takes tiotropium and high-dose Seretide® and, at best, his peak expiratory flow rate (PEFR) is 260. Today he is only able to manage 140. He continues to smoke 15 cigarettes per day.

On examination, his blood pressure (BP) is 152/72 mmHg and pulse 85 bpm and regular, and his temperature is 37.9 °C. There is poor air entry and wheeze throughout both lung fields, and an area of crackles at the right base. Oxygen saturation on pulse oximetry is 91%. He is allergic to penicillin.

Investigations:

Haemoglobin (Hb)	13.8 g/dl
White cell count (WCC)	14.1×10^9/l
Platelets (PLT)	200×10^9/l
Sodium (Na)	137 mmol/l
Potassium (K)	4.9 mmol/l
Creatinine (Cr)	115 µmol/l
C-reactive protein (CRP)	245 mg/l
Chest X-ray	Changes consistent with COPD and consolidation at the right base

He is treated with nebulisers and corticosteroids.

Which of the following is the most appropriate antibiotic therapy?

Rana Alnasser's screen

Investigations:

Haemoglobin (Hb)	13.8 g/dl
White cell count (WCC)	14.1×10^9/l
Platelets (PLT)	200×10^9/l
Sodium (Na)	137 mmol/l
Potassium (K)	4.9 mmol/l
Creatinine (Cr)	115 µmol/l
C-reactive protein (CRP)	245 mg/l
Chest X-ray	Changes consistent with COPD and consolidation at the right base

He is treated with nebulisers and corticosteroids.

Which of the following is the most appropriate antibiotic therapy?

A Piperacillin with tazobactam (Tazocin®)

B Co-amoxiclav

C Cephalexin

D Clarithromycin

E Ciprofloxacin

Rana Alnasser's screen

D Clarithromycin

The answer is Clarithromycin (Option D).

This man has evidence of a community-acquired pneumonia on top of underlying COPD. As he is penicillin-allergic, a macrolide, such as clarithromycin, is the next most logical step. Where clarithromycin is prescribed against a background of theophylline, this should be discontinued during the course of antibiotics. Another option would be doxycycline – not because of his underlying COPD, but rather due to a diagnosis of community-acquired pneumonia with a background of penicillin allergy.

A Piperacillin with tazobactam (Tazocin®)

Piperacillin with tazobactam (Tazocin®) (Option A) is incorrect.

Tazocin® contains a penicillin and would therefore be inappropriate. It is also not indicated for community-acquired pneumonia, unless there is evidence of *Pseudomonas*.

B Co-amoxiclav

Co-amoxiclav (Option B) is incorrect.

Co-amoxiclav is not appropriate because of the history of penicillin allergy reported here.

C Cephalexin

Cefalexin (Option C) is incorrect.

There is 20% cross-over between penicillin and cephalosporin allergy, and cephalosporins are not as effective as clarithromycin in this situation.

Rana Alnasser's screen

penicillin allergy.

A Piperacillin with tazobactam (Tazocin®)

Piperacillin with tazobactam (Tazocin®) (Option A) is incorrect.

Tazocin® contains a penicillin and would therefore be inappropriate. It is also not indicated for community-acquired pneumonia, unless there is evidence of *Pseudomonas*.

B Co-amoxiclav

Co-amoxiclav (Option B) is incorrect.

Co-amoxiclav is not appropriate because of the history of penicillin allergy reported here.

C Cephalexin

Cefalexin (Option C) is incorrect.

There is 20% cross-over between penicillin and cephalosporin allergy, and cephalosporins are not as effective as clarithromycin in this situation.

E Ciprofloxacin

Ciprofloxacin (Option E) is incorrect.

Ciprofloxacin is a potential therapy for COPD exacerbation but is not recommended for the treatment of pneumonia.

Rate this question:

Rana Alnasser's screen

10:35

You are reviewing what drug interaction trials are required for a new inhaled agent for the treatment of chronic obstructive pulmonary disease (COPD).

You feel that it has partial beta-agonist and partial anticholinergic activity.

When reviewing the list of agents which might require an interaction study, which of the following has a short persistence in plasma, but a much more prolonged duration of action?

A	Dopamine
B	Adenosine
C	Noradrenaline
D	Enalapril
E	Salbutamol

Submit

Previous Q... Skip Questi...

Rana Alnasser's screen

You are reviewing what drug interaction trials are required for a new inhaled agent for the treatment of chronic obstructive pulmonary disease (COPD).

You feel that it has partial beta-agonist and partial anticholinergic activity.

When reviewing the list of agents which might require an interaction study, which of the following has a short persistence in plasma, but a much more prolonged duration of action?

Your answer was correct

A	Dopamine
B	Adenosine
C	Noradrenaline
D	Enalapril
E	Salbutamol

Explanation

D Enalapril

Agents which are administered as a pro-drug and metabolised to an active agent fulfil this category. Enalapril is rapidly metabolised to enalaprilat, the active agent which lowers blood pressure. Highly tissue bound agents also have a short half-life in plasma but a much more prolonged

D Enalapril

Agents which are administered as a pro-drug and metabolised to an active agent fulfil this category. Enalapril is rapidly metabolised to enalaprilat, the active agent which lowers blood pressure. Highly tissue bound agents also have a short half-life in plasma but a much more prolonged duration of action; examples include omeprazole and benzodiazepines.

A Dopamine

Dopamine has a short half-life of approximately 2 minutes and a duration of action of 10 minutes.

B Adenosine

Adenosine has a half-life of only 10 seconds and a duration of action of only 2–3 seconds at most, accounting for its use as an agent to induce transient heart block.

C Noradrenaline

Noradrenaline has a half life of 2–2.5 minutes and a short duration of action, accounting for its administration as an infusion.

E Salbutamol

Salbutamol has a half life of 4–6 hours and a similar/slightly shorter duration of action.

Rate this question:

Next Question

A 46-year-old man, who you have seen begging outside the station, is brought to the Emergency Department by ambulance. He is unconscious and hyperventilating.

The nurses tell you that he is frequently admitted intoxicated, has a history of cataracts potentially related to previous methanol ingestion and has suffered epileptic seizures, which have precipitated several hospital admissions.

On examination is blood pressure (BP) is 100/70 mmHg, with pulse is 100/min regular. Unusually, there is no smell of alcohol. He has crackles on auscultation of both lung fields consistent with cardiac failure. When you try and wake him, he just groans and tries to turn over. You notice that he has nystagmus.

Investigations;

Hb	11.0 g/dl
WCC	11.0×10^9/l
PLT	190×10^9/l
Na^+	139 mmol/l
K^+	5.9 mmol/l
Creatinine	195 µmol/l
Cl^-	92 mmol/l
Bicarb	12 mmol/l
pH	7.1
Glucose	12.2 mmol/l

Which of the following is the most likely diagnosis?

A Diabetic ketoacidosis

B Phenytoin overdose

On examination is blood pressure (BP) is 100/70 mmHg, with pulse is 100/min regular. Unusually, there is no smell of alcohol. He has crackles on auscultation of both lung fields consistent with cardiac failure. When you try and wake him, he just groans and tries to turn over. You notice that he has nystagmus.

Investigations;

Hb	11.0 g/dl
WCC	11.0×10^9/l
PLT	190×10^9/l
Na^+	139 mmol/l
K^+	5.9 mmol/l
Creatinine	195 µmol/l
Cl^-	92 mmol/l
Bicarb	12 mmol/l
pH	7.1
Glucose	12.2 mmol/l

Which of the following is the most likely diagnosis?

A Diabetic ketoacidosis

B Phenytoin overdose

C Metformin overdose

D Ethanol intoxication

E Ethylene glycol intoxication

E Ethylene glycol intoxication

Ethylene glycol intoxication presents with decreased consciousness level, severe high anion gap metabolic acidosis and renal, respiratory and cardiac failure. Multi-organ failure is thought to occur at least in part due to widespread deposition of calcium oxalate crystals around 12 h after the initial insult. Inhibition of alcohol dehydrogenase by either ethanol or fomepizole, if available, is the mainstay of therapy. High-dose thiamine and pyridoxine should also be used as this reduces the formation of oxalate from glyoxylic acid. Because of the potential formation of calcium oxalate, calcium levels should also be assessed. Unfortunately, with delayed presentation, ingestion of relatively small amounts of ethylene glycol is fatal.

A Diabetic ketoacidosis

Given there is only a modest increase in glucose, this is inconsistent with a diagnosis of diabetic ketoacidosis.

B Phenytoin overdose

Although there is nystagmus, this is more likely to be related to chronic alcoholism and optic atrophy from methanol overdose.

C Metformin overdose

Because we aren't given a clear history of a previous diagnosis of diabetes mellitus, metformin overdose is unlikely as the driver for his presentation.

D Ethanol intoxication

widespread deposition of calcium oxalate crystals around 12 h after the initial insult. Inhibition of alcohol dehydrogenase by either ethanol or fomepizole, if available, is the mainstay of therapy. High-dose thiamine and pyridoxine should also be used as this reduces the formation of oxalate from glyoxylic acid. Because of the potential formation of calcium oxalate, calcium levels should also be assessed. Unfortunately, with delayed presentation, ingestion of relatively small amounts of ethylene glycol is fatal.

A Diabetic ketoacidosis

Given there is only a modest increase in glucose, this is inconsistent with a diagnosis of diabetic ketoacidosis.

B Phenytoin overdose

Although there is nystagmus, this is more likely to be related to chronic alcoholism and optic atrophy from methanol overdose.

C Metformin overdose

Because we aren't given a clear history of a previous diagnosis of diabetes mellitus, metformin overdose is unlikely as the driver for his presentation.

D Ethanol intoxication

The clue here is the lack of a smell of alcohol, which doesn't fit with alcohol intoxication.

21168

Rate this question:

Next Question

An 18-year-old male is brought to the Emergency Department from the beach in Cornwall where he had gone for a swim. While wading in the water he developed a sudden, agonising pain in his right sole. He immediately aborted his idea to swim as he had become nauseated and vomited. The paramedic found a hot, red swelling on his sole and a foreign body, which he could not remove, and hence rushed him to the hospital.

On examination, the patient was profusely sweating. Blood pressure was 90/60 mmHg, pulse rate was 42/min, respiratory rate was 28/min and he had drooling of saliva. During the evaluation, he suffered a generalised tonic–clonic seizure.

Which of the following is an important initial management step?

A	Antitoxin for Clostridium tetani
B	Immersion of the limb in cold water
C	Hyperbaric oxygen therapy
D	Local hydrogen peroxide application
E	Atropine for bradycardia

32850

Submit

An 18-year-old male is brought to the Emergency Department from the beach in Cornwall where he had gone for a swim. While wading in the water he developed a sudden, agonising pain in his right sole. He immediately aborted his idea to swim as he had become nauseated and vomited. The paramedic found a hot, red swelling on his sole and a foreign body, which he could not remove, and hence rushed him to the hospital.

On examination, the patient was profusely sweating. Blood pressure was 90/60 mmHg, pulse rate was 42/min, respiratory rate was 28/min and he had drooling of saliva. During the evaluation, he suffered a generalised tonic-clonic seizure.

Which of the following is an important initial management step?

Your answer was incorrect

A Antitoxin for Clostridium tetani

B Immersion of the limb in cold water

C Hyperbaric oxygen therapy

D Local hydrogen peroxide application

E Atropine for bradycardia

Explanation

E Atropine for bradycardia

The south-western British coast is well known for stings by

E Atropine for bradycardia

The south-western British coast is well known for stings by venomous fish like rays, weaver fish, etc. Most fish stings are inflicted on the soles of the feet of people wading near the shore. Fatalities are, however, rare. The sting causes an immediate sharp, agonising pain and the hot erythematous swelling extends up the limb. Local complications include tissue necrosis and secondary infection. This is more common if the spine remains embedded in the wound, as was seen in this patient. Patients stung by rays or stone fish may develop systemic symptoms with signs of autonomic stimulation and convulsions. Treatment includes immersion of the affected limb in warm water. The venomous spine has to be removed immediately. Severe hypotension may require atropine for bradycardia, and potentially SC or IM adrenalin if the initial response is poor.

A Antitoxin for Clostridium tetani

Tetanus is associated with slowly progressive muscular paralysis rather than the rapid deterioration with symptoms of hypotension and bradycardia seen here.

B Immersion of the limb in cold water

Immersion of the limb in warm water leads to denaturation of any toxin.

C Hyperbaric oxygen therapy

It's not hypoxia that is driving the circulatory symptoms seen here, but they are in fact related to the autonomic effects of any toxin.

D Local hydrogen peroxide application

fish may develop systemic symptoms with signs of autonomic stimulation and convulsions. Treatment includes immersion of the affected limb in warm water. The venomous spine has to be removed immediately. Severe hypotension may require atropine for bradycardia, and potentially SC or IM adrenalin if the initial response is poor.

A Antitoxin for Clostridium tetani

Tetanus is associated with slowly progressive muscular paralysis rather than the rapid deterioration with symptoms of hypotension and bradycardia seen here.

B Immersion of the limb in cold water

Immersion of the limb in warm water leads to denaturation of any toxin.

C Hyperbaric oxygen therapy

It's not hypoxia that is driving the circulatory symptoms seen here, but they are in fact related to the autonomic effects of any toxin.

D Local hydrogen peroxide application

Hydrogen peroxide is an oxidising agent used in wound cleaning. It doesn't have a significant role in the treatment of fish barb injury.

Rate this question:

Next Question

Rana Alnasser's screen

10:52
594-042-7551 Leave

A 70-year-old man has been admitted to the Coronary Care Unit late in the evening.

Past medical history includes diabetes, glaucoma, hypertension, angina, transient ischaemic attacks and peripheral vascular disease.

He had collapsed at home and, on arrival to hospital, was in complete heart block. After a few attempts, a transvenous pacing wire was inserted in the right internal jugular vein.

During the night shift, the ward staff become concerned as his condition has deteriorated. He is complaining of a severe left frontal headache with associated nausea and vomiting. He also has blurring of vision in his left eye and has noted some flecks of bright red blood in his vomit.

His temperature is 36.9 °C, pulse 90/min regular, blood pressure 180/94 mmHg, respiratory rate 22/min.

Examination reveals a fixed dilated pupil on the left side. There is no other focal neurology. His abdomen is soft.

What medication is likely to benefit this patient?

A	Nitroprusside
B	Labetalol
C	Acetazolamide
D	Omeprazole
E	Aspirin

Submit
Audio Video Share Participants More

10:55

404 — Not Found | 404 — Not Found | Home Feed | Re

https://mypastest.pastest.com/Secure/TestMe/

severe left frontal headache with associated nausea and vomiting. He also has blurring of vision in his left eye and has noted some flecks of bright red blood in his vomit.

His temperature is 36.9 °C, pulse 90/min regular, blood pressure 180/94 mmHg, respiratory rate 22/min.

Examination reveals a fixed dilated pupil on the left side. There is no other focal neurology. His abdomen is soft.

What medication is likely to benefit this patient?

Your answer was correct

A	Nitroprusside
B	Labetalol
C	Acetazolamide
D	Omeprazole
E	Aspirin

Explanation

C Acetazolamide

Acetazolamide is a carbonic anhydrase inhibitor and has found use in the treatment of glaucoma and mountain sickness. This patient has been admitted with symptomatic complete heart block and would most likely have received

Rana Alnasser's screen

C Acetazolamide

Acetazolamide is a carbonic anhydrase inhibitor and has found use in the treatment of glaucoma and mountain sickness. This patient has been admitted with symptomatic complete heart block and would most likely have received atropine till the temporary pacing wire could be placed. Atropine is an anti-muscarinic drug, and in the eye it causes dilation of the pupil (mydriasis) and cycloplegia of the ciliary body. As a result it increases the risk of glaucoma with symptoms of localised frontal headache, blurring of vision, nausea and vomiting. The eye affected will classically have a fixed, dilated pupil with corneal oedema and peri-corneal ciliary injection. The treatment includes topical beta-blockers (timolol), which can be systemically absorbed, acetazolamide and topical pilocarpine. Acetazolamide can cause a normal anion gap acidosis. The patient will require measurement and monitoring of the intraocular pressure by an ophthalmologist.

A Nitroprusside

Nitroprusside acts as a nitrate donor and is a vasodilator. As such, its main role is in the treatment of hypertension rather than acute glaucoma.

B Labetalol

Although labetolol will achieve some exposure when given systemically to the eye, it may precipitate a worsening of heart block when given so soon after the transient episode.

D Omeprazole

Omeprazole does not have a significant impact on acute

Rana Alnasser's screen

atropine till the temporary pacing wire could be placed.

Atropine is an anti-muscarinic drug, and in the eye it causes dilation of the pupil (mydriasis) and cycloplegia of the ciliary body. As a result it increases the risk of glaucoma with symptoms of localised frontal headache, blurring of vision, nausea and vomiting. The eye affected will classically have a fixed, dilated pupil with corneal oedema and peri-corneal ciliary injection. The treatment includes topical beta-blockers (timolol), which can be systemically absorbed, acetazolamide and topical pilocarpine. Acetazolamide can cause a normal anion gap acidosis. The patient will require measurement and monitoring of the intraocular pressure by an ophthalmologist.

A Nitroprusside

Nitroprusside acts as a nitrate donor and is a vasodilator. As such, its main role is in the treatment of hypertension rather than acute glaucoma.

B Labetalol

Although labetolol will achieve some exposure when given systemically to the eye, it may precipitate a worsening of heart block when given so soon after the transient episode.

D Omeprazole

Omeprazole does not have a significant impact on acute glaucoma, the most likely diagnosis here.

E Aspirin

Anti-platelet agents don't impact on acute glaucoma, and the patient is already likely to have been treated with an adequate dose of anti-platelet therapy.

A 44-year-old man with polycystic kidney disease underwent renal transplantation three months ago. He was receiving ciclosporin, prednisolone, ramipril, hydrochlothiazide and atorvastatin. He had also received tacrolimus (FK-506). He was admitted with a history of headache, vomiting, confusion and bilateral visual loss. One single generalised seizure was reported at the onset, 2 days ago.

On examination, his pulse was 112/min, blood pressure 220/120 mmHg. He was disoriented and uncooperative. Bilateral papilloedema was seen, with exudates and rounded haemorrhages. He had perception of light at about 10 cm. Pupils were 2.5 mm and reactive to light. Lateral gaze was restricted on both sides. He was moving all his limbs and plantars were extensor.

Magnetic resonance imaging (MRI) of the brain revealed a bilateral increase in T2 signal intensity in the white matter, concentrated in the posterior part of the hemispheres, and a corresponding reduced density on computed tomography (CT) scan.

What is the best term to describe this clinical syndrome?

A	Acute diffuse toxic encephalopathy
B	Acute toxic metabolic encephalopathy
C	Ischaemic encephalopathy
D	Reversible posterior leuko-encephalopathy
E	Necrotising leuko-encephalopathy

10:58

A 44-year-old man with polycystic kidney disease underwent renal transplantation three months ago. He was receiving ciclosporin, prednisolone, ramipril, hydrochlothiazide and atorvastatin. He had also received tacrolimus (FK-506). He was admitted with a history of headache, vomiting, confusion and bilateral visual loss. One single generalised seizure was reported at the onset, 2 days ago.

On examination, his pulse was 112/min, blood pressure 220/120 mmHg. He was disoriented and uncooperative. Bilateral papilloedema was seen, with exudates and rounded haemorrhages. He had perception of light at about 10 cm. Pupils were 2.5 mm and reactive to light. Lateral gaze was restricted on both sides. He was moving all his limbs and plantars were extensor.

Magnetic resonance imaging (MRI) of the brain revealed a bilateral increase in T2 signal intensity in the white matter, concentrated in the posterior part of the hemispheres, and a corresponding reduced density on computed tomography (CT) scan.

What is the best term to describe this clinical syndrome?

A	Acute diffuse toxic encephalopathy
B	Acute toxic metabolic encephalopathy
C	Ischaemic encephalopathy
D	Reversible posterior leuko-encephalopathy
E	Necrotising leuko-encephalopathy

Rana Alnasser's screen

D Reversible posterior leuko-encephalopathy

A posterior leuko-encephalopathy, which resembles hypertensive encephalopathy, may follow the use of several drugs like cyclophosphamide, ciclosporin, tacrolimus, cisplatin, cytarabine or IV methotrexate. It presents with headache, vomiting, seizures and cortical blindness. It has been suggested that ciclosporin alters the blood–brain barrier, and the fluid overload and hypertension that accompany the use of ciclosporin underlie the radiological changes. The imaging characteristics mentioned above are due to accumulation of fluid. It is, however, devoid of any mass effect. Review of his immunosuppressive therapy and substitution of an alternative regimen is the management of choice here.

A Acute diffuse toxic encephalopathy

Acute diffuse toxic encephalopathy is associated with generalised changes on the MRI, and is with exposure to organic solvents and heavy metals.

B Acute toxic metabolic encephalopathy

Given the history of multiple medications including immunosuppressants, acute metabolic encephalopathy, related to alcoholism or electrolyte disturbances is less likely versus reversible posterior leuko-encephalopathy.

C Ischaemic encephalopathy

Ischaemic encephalopathy is associated with a significant interruption in brain perfusion, due to substantial blood loss, cardiac arrest or hypoxia, and diffuse changes are noted rather than the specific posterior changes seen here.

been suggested that ciclosporin alters the blood–brain barrier, and the fluid overload and hypertension that accompany the use of ciclosporin underlie the radiological changes. The imaging characteristics mentioned above are due to accumulation of fluid. It is, however, devoid of any mass effect. Review of his immunosuppressive therapy and substitution of an alternative regimen is the management of choice here.

A Acute diffuse toxic encephalopathy

Acute diffuse toxic encephalopathy is associated with generalised changes on the MRI, and is with exposure to organic solvents and heavy metals.

B Acute toxic metabolic encephalopathy

Given the history of multiple medications including immunosuppressants, acute metabolic encephalopathy, related to alcoholism or electrolyte disturbances is less likely versus reversible posterior leuko-encephalopathy.

C Ischaemic encephalopathy

Ischaemic encephalopathy is associated with a significant interruption in brain perfusion, due to substantial blood loss, cardiac arrest or hypoxia, and diffuse changes are noted rather than the specific posterior changes seen here.

E Necrotising leuko-encephalopathy

Necrotising leuko-encephalopathy is associated with diffuse white matter changes, as opposed to the predominantly posterior hemisphere changes seen here.

Rate this question:

11:04
594-042-7551 Leave

A 47-year-old woman presents following a self-terminating tonic-clonic seizure. She admits to regularly abusing benzodiazepines and opiates. She recently changed her general practitioner (GP), as her previous one refused to prescribe her the 60 mg diazepam and 180 mg of dihydrocodeine she takes a day. She does not drink alcohol and has not been known to abuse other prescription medications.

Examination in the Emergency Department is unremarkable.

Which of the following is the most appropriate intervention?

A	Intravenous (iv) Lorazepam
B	Oral carbamazepine
C	iv Naloxone
D	iv diazepam
E	Oral methadone

Submit

Blog About Pastest Contact Us Help
Audio Video Share Participants More

D iv diazepam

This patient has suffered a seizure, most likely as a result of benzodiazepine withdrawal. Management of choice would be with a long acting benzodiazepam, such as diazepam, given intravenously initially and titrated to effect. It could then be switched to the oral preparation and a reducing dose regime established. In patients who have been using diazepam for a number of years, this may need to occur over as long a period as 8-12 weeks. Patients may well have to attend the pharmacy to collect a script on a number of occasions per week to prevent stock-piling or overdosing intentionally on the medication.

A Intravenous (iv) Lorazepam

iv lorazepam is usually reserved for refractory seizures associated with acute benzodiazepine withdrawal, and for patients suffering seizures who are withdrawing from alcohol.

B Oral carbamazepine

There is no indication for conventional anti-epileptic medication here, with a reducing dose of benzodiazepines the more appropriate option.

C iv Naloxone

iv Naloxone is used for acute opiate reversal in situations of respiratory arrest where airway support is not possible or not indicated.

E Oral methadone

Oral methadone is used in addiction programs to allow

11:08
404 — Not Found
404 — Not Found
Home Feed | Re
https://mypastest.pastest.com/Secure/TestMe/Browse

A 36-year-old woman presents to her 34-week midwife visit complaining of a severe headache and worsening indigestion. She has been relatively well during her pregnancy, her blood pressure (BP) at booking was 115/72 mmHg.

On review on this occasion, her BP was elevated at 145/92 mmHg.

Investigations:

Hb	11.0 g/dl
WCC	5.4×10^9/l
PLT	234×10^9/l
Na^+	140 mmol/l
K^+	5.0 mmol/l
Cr	115 µmol/l
Urine analysis	Protein ++

Which of the following is the most appropriate course of action to control her blood pressure?

A Methyldopa and outpatient review

B Nifedipine and outpatient review

C Admit for IV labetalol

D Ramipril and outpatient review

Rana Alnasser's screen

On review on this occasion, her BP was elevated at 145/92 mmHg.

Investigations:

Hb	11.0 g/dl
WCC	5.4×10^9/l
PLT	234×10^9/l
Na^+	140 mmol/l
K^+	5.0 mmol/l
Cr	115 µmol/l
Urine analysis	Protein ++

Which of the following is the most appropriate course of action to control her blood pressure?

A Methyldopa and outpatient review

B Nifedipine and outpatient review

C Admit for IV labetalol

D Ramipril and outpatient review

E Valsartan and outpatient review

Submit

C Admit for IV labetalol

This woman has clinical symptoms and signs consistent with pre-eclampsia and, as such, IV labetalol is the only appropriate option from those given here. Usual dose is via a bolus and then 1 mg/kg/h. Of course, the only way to resolve the pre-eclampsia is to consider delivering the baby, and that would be the next course of action.

A Methyldopa and outpatient review

Oral methyldopa is an alternative for controlling gestational hypertension when oral labetalol is unsuitable.

B Nifedipine and outpatient review

Nifedipine, like methyldopa, is recommended as an alternative to labetalol for patients who cannot tolerate it.

D Ramipril and outpatient review

ACE inhibitor use in pregnancy is associated with increased risk of renal and skeletal abnormalities in the fetus.

E Valsartan and outpatient review

Like ACE inhibitors, ARBs are contra-indicated for use in pregnancy.

20629

Rate this question:

11:12

An 18-year-old woman is bought to the Casualty Department by 'blue light' ambulance accompanied by her parents who are very concerned about her health. The problems began around 2 days ago when the patient was complaining of anorexia and nausea and had some vomiting. It was thought that she had a mild gastrointestinal infection, but over the next few days she started to complain of pain in her right upper abdomen and feeling very weak. The parents returned home from work an hour ago to find the patient unconscious, and immediately summoned an ambulance. The patient was previously medically fit and is not on any medications. She has no known allergies. She has just finished her A-level examinations and is currently awaiting the results, with offers from five universities.

On examination, she has a blood pressure of 80/40 mmHg, a pulse of 100/min, fullness and a response to pain in the right upper quadrant of her abdomen but no focal neurological signs. Urgent blood tests show raised deranged liver function tests characterised by a markedly raised AST, raised ALT and a raised ALP. Her coagulation tests show a raised APTT and a raised PT, but her sodium, potassium, urea and chloride levels are all normal; creatinine is elevated at 172 µmol//l.

What would be the most likely cause of these results?

A	Paracetamol overdose
B	Alcoholic hepatitis
C	Aspirin overdose
D	Acute viral hepatitis
E	Fulminant Wilson's disease

Rana Alnasser's screen

11:14
404 — Not Found
404 — Not Found
Home Feed | Re
https://mypastest.pastest.com/Secure/TestMe/Browse
Pastest+

vomiting. It was thought that she had a mild gastrointestinal infection, but over the next few days she started to complain of pain in her right upper abdomen and feeling very weak. The parents returned home from work an hour ago to find the patient unconscious, and immediately summoned an ambulance. The patient was previously medically fit and is not on any medications. She has no known allergies. She has just finished her A-level examinations and is currently awaiting the results, with offers from five universities.

On examination, she has a blood pressure of 80/40 mmHg, a pulse of 100/min, fullness and a response to pain in the right upper quadrant of her abdomen but no focal neurological signs. Urgent blood tests show raised deranged liver function tests characterised by a markedly raised AST, raised ALT and a raised ALP. Her coagulation tests show a raised APTT and a raised PT, but her sodium, potassium, urea and chloride levels are all normal; creatinine is elevated at 172 µmol//l.

What would be the most likely cause of these results?

A	Paracetamol overdose
B	Alcoholic hepatitis
C	Aspirin overdose
D	Acute viral hepatitis
E	Fulminant Wilson's disease

previously medically fit and is not on any medications. She has no known allergies. She has just finished her A-level examinations and is currently awaiting the results, with offers from five universities.

On examination, she has a blood pressure of 80/40 mmHg, a pulse of 100/min, fullness and a response to pain in the right upper quadrant of her abdomen but no focal neurological signs. Urgent blood tests show raised deranged liver function tests characterised by a markedly raised AST, raised ALT and a raised ALP. Her coagulation tests show a raised APTT and a raised PT, but her sodium, potassium, urea and chloride levels are all normal; creatinine is elevated at 172 µmol//l.

What would be the most likely cause of these results?

Your answer was correct

A Paracetamol overdose

B Alcoholic hepatitis

C Aspirin overdose

D Acute viral hepatitis

E Fulminant Wilson's disease

Explanation

A Paracetamol overdose

Paracetamol is widely and easily obtainable, and it seems likely that this patient has bought over-the-counter tablets and stockpiled them, which has led to significant toxicity

Paracetamol is widely and easily obtainable, and it seems likely that this patient has bought over-the-counter tablets and stockpiled them, which has led to significant toxicity following massive overdose. This possibility should always be considered in a patient presenting late with significant hepatic and renal dysfunction.

B Alcoholic hepatitis

Significant alcohol abuse doesn't fit with this patient's profile with a high level of school achievement, and earlier presentation with vomiting and liver dysfunction would be expected.

C Aspirin overdose

Aspirin overdose is usually associated with acute presentation a few hours after overdose with vomiting, tinnitus and hyperventilation.

D Acute viral hepatitis

Hepatitis A more usually presents with a flu-like illness and jaundice, accompanied by raised transaminases. Fulminant liver failure is virtually never reported.

E Fulminant Wilson's disease

Presentation with acute liver impairment associated with Wilson's disease is rare. Patients in this age group usually present with asymptomatic elevation in transaminases or with neuropsychiatric manifestations of the disease.

Rate this question:

11:15

An 18-year-old high-school student is seen as an emergency extra in your Neurology Outpatient Clinic. During the last week, she has had three falls at home and crashed the family car. Her mother, who accompanies her, is concerned because she 'has started to walk funny'.

She was previously fit and well and had a normal birth with no associated complications. She is on no medication and denies smoking or using alcohol or illicit drugs. Her father has epilepsy and her mother has type II diabetes mellitus and hypertension. One of her younger brothers had suffered from acute lymphoblastic leukaemia but is now in remission. She has recently broken up with her boyfriend of three years. She has a pet dog and a parrot. She is three weeks away from taking her A-level examinations.

On examination, she is restless and has a coarse tremor on movement. She is afebrile, pulse 64 bpm and regular, blood pressure (BP) 110/72 mmHg and respirations are 16 breaths/min at rest. Heart, chest and abdominal examinations are all normal.

On neurological examination, she has a broad ataxic gait, nystagmus, past-pointing and diplopia, which was not brought on with fatigue. The rest of the exam was normal.

Investigations:

Hb	12.6 g/dl
WCC	9.8×10^9/l
PLT	365×10^9/l
Na^+	129 mmol/l
K^+	4.5 mmol/l
Creatinine	84 µmol/l
Bilirubin	9.0 µmol/l
Urea	4.2 mmol/l

Rana Alnasser's screen

Ca^{++}	2.21 mmol/l
Glucose	5.2 mmol/l
Albumin	42 g/l
ALT	429 U/l
ALP	121 U/l
GGT	512 U/l
CRP	< 5 mg/l
PT	12 s
APTT	31 s
TSH	1.02 mU/l
Free T_4	16.1 nmol/l
MCV	95.3 fl

CT head demonstrates a normal brain. No abnormalities seen on U/S liver and bile ducts are of normal calibre.

Which of the following is the most likely diagnosis?

A Multiple sclerosis

B Paraneoplastic cerebellar degeneration

C Carbamazepine overdose

D Autoimmune hepatitis

E Chronic alcoholism

C Carbamazepine overdose

This young woman has had a couple of stressful life events. The clue in the history is that her father has epilepsy, so she has access to carbamazepine. Dose-dependent unwanted effects of carbamazepine include diplopia, nystagmus, ataxia and hyponatraemia. Hepatotoxicity, peripheral neuropathy (and, rarely, bone marrow depression) can occur.

A Multiple sclerosis

In MS, much more of a patchwork of symptoms would be seen, versus the specific cerebellar symptoms seen here. In addition, MS often presents with optic neuritis as the initial feature.

B Paraneoplastic cerebellar degeneration

PCD is a very rare condition associated with lung, ovarian and breast cancers, and Hodgkin's lymphoma. It is associated with anti-Yo antibodies.

D Autoimmune hepatitis

Autoimmune hepatitis may be associated with the abnormal liver function tests seen here, but would not usually be associated with the cerebellar signs which are reported.

E Chronic alcoholism

Chronic alcoholism seems unlikely given that she is a high academic achiever. The access to the carbamazepine, cerebellar signs and abnormal LFTs fit better with this as the cause of her symptoms.

11:21

A 52-year-old woman with a long history of anxiety and depression is brought into the Emergency Department at 0900 h by her husband, following a suspected overdose. He had found her slumped in a chair downstairs with two empty medication bottles on the floor. He had last seen her at 2300 h the previous night when they had gone to bed.

On examination, she was drowsy but rousable with a Glasgow Coma Scale (GCS) of 12/15. Her pulse was 130 bpm and her blood pressure was 90/60 mmHg. Her skin was hot and dry and she had dilated pupils. She had occasional jerky movements of her limbs and extensor plantar responses.

Results of investigations are below:

Arterial blood (on air):

pH	7.185
$p(O_2)$	7.2 kPa
$p(CO_2)$	3.2 kPa

Electrocardiogram (ECG)	Sinus tachycardia, widened QRS complex
Bicarbonate	15 mmol/l
Na^+	142 mmol/l
K^+	3.7 mmol/l
Urea	5.2 mmol/l
Creatinine	100 µmol/l

An IVI is commenced; which of the following is an appropriate next step?

A IV naloxone

Rana Alnasser's screen

occasional jerky movements of her limbs and extensor plantar responses.

Results of investigations are below:

Arterial blood (on air):

pH	7.185
$p(O_2)$	7.2 kPa
$p(CO_2)$	3.2 kPa

Electrocardiogram (ECG)	Sinus tachycardia, widened QRS complex
Bicarbonate	15 mmol/l
Na^+	142 mmol/l
K^+	3.7 mmol/l
Urea	5.2 mmol/l
Creatinine	100 µmol/l

An IVI is commenced; which of the following is an appropriate next step?

A	IV naloxone
B	Immediate intubation and transfer to the intensive therapy unit (ITU)
C	IV sodium bicarbonate
D	IV flumazenil
E	IV amiodarone

C IV sodium bicarbonate

This patient has the signs of tricyclic antidepressant (TCA) poisoning. Other features include dry mouth, urinary retention, skin blistering, hypothermia, ataxia, nystagmus and hyperreflexia. Seizures occur in 10% of cases. Deep coma and respiratory depression may ensue. Cardiac arrhythmias can occur due to a quinidine-like type Ia effect on myocardium. After clearing the airway and maintaining adequate ventilation, the most important initial steps are to correct acidosis with sodium bicarbonate and relieve hypoxia. These measures can help to prevent arrhythmias without the need for anti-arrhythmic drugs.

A IV naloxone

Naloxone is used to reverse the effects of opiate toxicity and does not have a role here.

B Immediate intubation and transfer to the intensive therapy unit (ITU)

Although this patient requires early ITU involvement and monitoring in a high-dependency area, immediate intubation is not indicated (no profound hypoxia or hypercapnia). In total, tricyclic coma may last 24–48 h. Delirium and hallucinations may persist for 2–3 days and often require sedation with diazepam.

D IV flumazenil

This is used to reverse benzodiazepine toxicity and in this situation may increase the risk of seizures; as such it should be avoided.

E IV amiodarone

You are called to the Emergency Department to assist in the management of a 30-year-old man who has been brought in by a friend.

On examination, he is agitated and confused, with dilated pupils, is rather tremulous, sweating and grinding his teeth. He has a regular heart rate of 120 beats/min and a temperature of 38.5 °C. There is little previous history, although the friend believes that he has suffered from depression for a number of years and recently had his medications changed by his general practitioner.

What is the most likely diagnosis?

A	Neuroleptic malignant syndrome
B	Serotonin syndrome
C	Malignant hyperthermia
D	Thyrotoxic crisis
E	Carcinoid syndrome

Submit

11:24

You are called to the Emergency Department to assist in the management of a 30-year-old man who has been brought in by a friend.

On examination, he is agitated and confused, with dilated pupils, is rather tremulous, sweating and grinding his teeth. He has a regular heart rate of 120 beats/min and a temperature of 38.5 °C. There is little previous history, although the friend believes that he has suffered from depression for a number of years and recently had his medications changed by his general practitioner.

What is the most likely diagnosis?

Your answer was correct

A Neuroleptic malignant syndrome

B Serotonin syndrome

C Malignant hyperthermia

D Thyrotoxic crisis

E Carcinoid syndrome

Explanation

B Serotonin syndrome

Serotonin syndrome is a cluster of symptoms and signs that occur usually when more than one drug is taken that increases the concentration of serotonin at the synaptic

Rana Alnasser's screen

B Serotonin syndrome

Serotonin syndrome is a cluster of symptoms and signs that occur usually when more than one drug is taken that increases the concentration of serotonin at the synaptic level, although it has been reported following overdose of selective serotonin reuptake inhibitors (SSRIs) alone. It may occur when SSRIs are taken in combination with monoamine oxidase inhibitors or tricyclic antidepressants. If changing from one drug to another, a washout period is often required to prevent the syndrome from occurring. Treatment initially is to stop the causative drug(s), and prevent complications such as kidney disease caused by rhabdomyolysis.

Severe cases may require a general anaesthetic and muscle paralysis, and dantrolene sodium has been used, which reduces calcium efflux from the sarcoplasmic reticulum, although more recent data no longer support its role in managing the condition.

A Neuroleptic malignant syndrome

Neuroleptic malignant syndrome is characterised by fever, muscle rigidity (lead pipe), altered mental status and autonomic dysfunction. The patient described here does not appear to have any generalised muscular stiffness, and so serotonin syndrome is much more likely than neuroleptic malignant syndrome.

C Malignant hyperthermia

Malignant hyperthermia is seen in response to inhalational anaesthetics, and is genetic in origin.

D Thyrotoxic crisis

Rana Alnasser's screen

If changing from one drug to another, a washout period is often required to prevent the syndrome from occurring. Treatment initially is to stop the causative drug(s), and prevent complications such as kidney disease caused by rhabdomyolysis.

Severe cases may require a general anaesthetic and muscle paralysis, and dantrolene sodium has been used, which reduces calcium efflux from the sarcoplasmic reticulum, although more recent data no longer support its role in managing the condition.

A Neuroleptic malignant syndrome

Neuroleptic malignant syndrome is characterised by fever, muscle rigidity (lead pipe), altered mental status and autonomic dysfunction. The patient described here does not appear to have any generalised muscular stiffness, and so serotonin syndrome is much more likely than neuroleptic malignant syndrome.

C Malignant hyperthermia

Malignant hyperthermia is seen in response to inhalational anaesthetics, and is genetic in origin.

D Thyrotoxic crisis

There are no symptoms of thyrotoxicosis which predate this acute presentation, and the recent change of medication is a better pointer to serotonin syndrome.

E Carcinoid syndrome

Carcinoid syndrome presents with gradually progressive diarrhoea, weight loss and episodes of flushing, usually in patients significantly older than 30 years of age.

11:25

404 — Not Found × | 404 — Not Found × | Home Feed | Re ×

https://mypastest.pastest.com/Secure/TestMe/

Pastest+

A top premier-league football manager recently expressed concern that some of the players had abnormally high red cell counts – a sign of using erythropoietin (EPO). He bemoaned the fact that EPO had been administered to some players by their former clubs outside the UK and they actually took the drug unknowingly.

What is the best way of detecting EPO abuse?

A	It can be detected in urine for a few weeks following the most recent injection
B	It increases muscle bulk
C	It can be detected in saliva for a few days after the most recent injection
D	It can be detected in blood up to a week after the most recent injection
E	It can be detected by reticulocyte count for a few days after recent injection

Submit

Previous Q... Skip Questi...

11:27

A It can be detected in urine for a few weeks following the most recent injection

Drug taking has become a big problem in all high-level sports: EPO was first introduced into the world of cycling in the late 1980s. By increasing the red cell mass, and hence the oxygen-carrying capacity of the blood, EPO should increase performance during an all-out exercise. Currently, EPO testing has been greatly refined, and levels may be detected in urine for some time after administration. It can lead to a dose-dependent increase in blood pressure or aggravation of hypertension; isolated patients have suffered a hypertensive crisis with encephalopathy-like symptoms and generalised tonic-clonic seizures. There is also a risk of thrombosis, and deaths have been reported from its use.

B It increases muscle bulk

EPO has a positive effect on the oxygen carrying capacity of the blood, not muscle bulk.

C It can be detected in saliva for a few days after the most recent injection

EPO testing from saliva is under development, although currently urine testing is more reliable.

D It can be detected in blood up to a week after the most recent injection

Although EPO can be detected via blood sampling, urine testing is preferred because of infection risks associated with blood sampling.

E It can be detected by reticulocyte count for a few

Rana Alnasser's screen

11:28

A 50-year-old farmer is admitted with nausea, vomiting and diarrhoea. He had used some spray in his potato field about 6 h ago.

On examination, he was drowsy, agitated and profusely salivating. Pupils were small. Limbs were weak and flaccid. A plantar response could not be elicited. Cyanosis was evident and auscultation of the lungs revealed coarse crackles all over. He has been given atropine by ambulance staff and has oxygen *in situ*.

Investigations:

WCC	12×10^9/l
Glucose	15 mmol/l
Urea	6.0 mmol/l
Na^+	130 mmol/l
K^+	3.6 mmol/l
Urine glucose	++

What initial step would you take in the management of this patient?

A Wash contaminated skin with soap and water

B Perform gastric lavage

C Consider immediate tracheostomy

D Give edrophonium 10 mg IV

E Give immunoglobulin IV

Rana Alnasser's screen

A Wash contaminated skin with soap and water

This farmer has inadvertently exposed himself to an insecticide which he had sprayed at his farm. He has developed features of inhibition of acetylcholinesterase and hence accumulation of acetylcholine at the central and peripheral nerve endings, including the neuromuscular junctions. Such an exposure is characterised by miosis, which remains an important sign associated with hypersalivation, chest tightness, sweating, nausea, vomiting and diarrhoea. Nicotinic effects follow, and include muscle fasciculation and flaccid weakness of limbs and respiratory muscles. Respiratory failure is exacerbated by pulmonary oedema. Coma and convulsions may occur. Glycosuria and hyperglycaemia also occur. Usually there is no ketonuria. Reduced plasma or preferably red cell cholinesterase activity confirms the diagnosis. Initial treatment includes removal of soiled clothing and washing the contaminated areas with soap and water. Injection of atropine 2 mg every 10–30 min until signs of atropinisation occur is useful, and this is accompanied by IV pralidoxime mesylate. This reactivates phosphorylated acetylcholinesterase and should be given to every symptomatic patient, along with atropine.

B Perform gastric lavage

Because the contamination here is via contaminated skin, gastric lavage has no value in the management of the condition.

C Consider immediate tracheostomy

Endotracheal intubation and mechanical ventilation may be needed, but this is only in the event that there is no response to atropine and pralidoxime.

should be given to every symptomatic patient, along with atropine.

B Perform gastric lavage

Because the contamination here is via contaminated skin, gastric lavage has no value in the management of the condition.

C Consider immediate tracheostomy

Endotracheal intubation and mechanical ventilation may be needed, but this is only in the event that there is no response to atropine and pralidoxime.

D Give edrophonium 10 mg IV

Edrophonium is a reversible cholinesterase inhibitor, which would actually worsen the symptoms of organophosphate poisoning seen here.

E Give immunoglobulin IV

IV immunoglobulin is the preferred intervention for Guillain-Barré syndrome, not the diagnosis here.

Rate this question:

Next Question

A 57-year-old man presents to the Emergency Department complaining of headache; his blood pressure is noted to be 210/100 mmHg.

Past history of note includes asthma, for which he takes a salmeterol/fluticasone combination inhaler and, apart from this, he has attended the general practitioner (GP) only infrequently.

Detailed examination reveals grade 3 hypertensive retinopathy, no focal neurological deficit and no blood pressure difference between arms. There are no heart murmurs. You elect to admit him for commencement of anti-hypertensive therapy.

Which of the following would be the most appropriate initial agent to trial him on?

A	IV labetalol
B	Oral metoprolol
C	Oral isosorbide dinitrate
D	Oral doxazosin
E	Oral amlodipine

Submit

A 57-year-old man presents to the Emergency Department complaining of headache; his blood pressure is noted to be 210/100 mmHg.

Past history of note includes asthma, for which he takes a salmeterol/fluticasone combination inhaler and, apart from this, he has attended the general practitioner (GP) only infrequently.

Detailed examination reveals grade 3 hypertensive retinopathy, no focal neurological deficit and no blood pressure difference between arms. There are no heart murmurs. You elect to admit him for commencement of anti-hypertensive therapy.

Which of the following would be the most appropriate initial agent to trial him on?

Your answer was correct

A	IV labetalol
B	Oral metoprolol
C	Oral isosorbide dinitrate
D	Oral doxazosin
E	Oral amlodipine

Explanation

E	Oral amlodipine

Explanation

E Oral amlodipine

Unfortunately, severe hypertension presenting acutely with headache ± other symptoms is an area that is poorly served by clinical trials. Most studies are inadequately powered to deliver a definitive result as to which class of therapy is most appropriate, and there are no trials that adequately compare the superiority of intravenous (iv) versus oral therapy. In this case, the aim should be to reduce blood pressure by around 25% over the first hour.

A IV labetalol

Given this patient's history of asthma, labetalol is best avoided given that alternatives exist.

B Oral metoprolol

Metoprolol is longer acting, more difficult to titrate and runs the risk of worsening asthma. As such it should be avoided here.

C Oral isosorbide dinitrate

Isosorbide dinitrate has limited effectiveness in the management of hypertension, and is more useful as an intervention for angina.

D Oral doxazosin

This is usually considered a third or fourth-line intervention for hypertension, and is therefore not useful here versus other first-line interventions such amlodipine.

Rate this question:

A 17-year-old girl is reviewed in the Dermatology Clinic. She is feeling quite tearful as her acne has been particularly severe over the past few months. You are considering treating her with oral retinoid therapy.

Past medical history of note includes epilepsy, for which she takes carbamazepine; she has also been treated with tetracyclines intermittently. She is currently using the combined oral contraceptive pill. You elect to begin therapy with isotretinoin.

Which of the following is the most important step before commencing isotretinoin?

A	Warn her she will need to reduce her dose of carbamazepine
B	Arrange a pregnancy test
C	Do baseline liver function tests
D	Do baseline renal function tests
E	Warn her about the possibility of mood changes

18521

Submit

11:37

A 17-year-old girl is reviewed in the Dermatology Clinic. She is feeling quite tearful as her acne has been particularly severe over the past few months. You are considering treating her with oral retinoid therapy.

Past medical history of note includes epilepsy, for which she takes carbamazepine; she has also been treated with tetracyclines intermittently. She is currently using the combined oral contraceptive pill. You elect to begin therapy with isotretinoin.

Which of the following is the most important step before commencing isotretinoin?

Your answer was correct

A	Warn her she will need to reduce her dose of carbamazepine
B	Arrange a pregnancy test
C	Do baseline liver function tests
D	Do baseline renal function tests
E	Warn her about the possibility of mood changes

Explanation

B Arrange a pregnancy test

Isotretinoin is highly effective for treating acne vulgaris. It is a synthetic 13-cis isomer of naturally occurring trans-retinoic acid. It decreases sebum production and sebaceous gland size. It is highly teratogenic, and female

Rana Alnasser's screen

11:37

B Arrange a pregnancy test

Isotretinoin is highly effective for treating acne vulgaris. It is a synthetic 13-cis isomer of naturally occurring trans-retinoic acid. It decreases sebum production and sebaceous gland size. It is highly teratogenic, and female patients using the drug must have a negative pregnancy test and commit to effective contraception for at least one month pre-treatment and for at least one month after the cessation of therapy.

A Warn her she will need to reduce her dose of carbamazepine

Isotretinoin has been known to reduce the plasma concentration of carbamazepine, so it is important to monitor impact on seizure control; however, still the most important intervention is to exclude pregnancy prior to starting treatment.

C Do baseline liver function tests

Both liver function tests and fasting lipids are recommended before starting therapy, although they are still trumped in importance by a pregnancy test.

D Do baseline renal function tests

Only baseline liver function tests and lipids are mandated before therapy.

E Warn her about the possibility of mood changes

Mood changes are possible, but pregnancy testing is still the crucial step before starting therapy.

Rana Alnasser's screen

11:37

A 65-year-old woman is admitted with a swollen left leg which, on venous Doppler, proved to be due to deep venous thrombosis (DVT). She was started on low-molecular weight heparin.

The next day, she had an episode of left-sided chest pain and coughed up blood. A ventilation–perfusion scan demonstrated an area of low perfusion.

Five days later (the day after discharge), she developed central chest discomfort and a painful swollen right lower limb.

Investigations:

WCC	$12 \times 10^9/l$
PLT	$45 \times 10^9/l$
APTT	30 s

What is the likely cause of this new problem?

A Spontaneous right limb DVT

B Cardiac embolism

C Ruptured right Baker's cyst

D Heparin-induced thrombocytopenia

E Rupture of the right calf muscle

Rana Alnasser's screen

Explanation

D Heparin-induced thrombocytopenia

Heparin-induced thrombosis is the most likely diagnosis here, although it occurs much more infrequently with low-molecular weight heparin than with unfractionated heparin. It is prudent not to miss this diagnosis since the treatment is to withhold heparin. Heparin-induced thrombocytopenia (HIT) with a new thrombosis is a clinical diagnosis and should be identified when the above clinical features are witnessed, failing which the patient may progress to a fatal thrombosis. Type 1 HIT usually occurs in the first 48-72 h, and the platelet count rarely falls below 100×10^9/l. The platelet count should return to normal over the next 4 days and there is no increased risk of thromboembolism. Type 2 HIT is much rarer and usually occurs 5-10 days after treatment commencement, and the platelet count usually drops below 100×10^9/l to about 50×10^9/l. This case is therefore in keeping with type 2 immune-mediated HIT. Heparin should be stopped and alternative forms of anticoagulation may be required; for advice regarding best management, a haematologist should be consulted. Possible alternative forms of anti-coagulation would include lepirudin, argatroban or danaparoid. With regard to the timing of events, it is likely the PE is related to the original DVT, and the limb thrombosis to the HIT.

A Spontaneous right limb DVT

Given the timing, five days after commencing low-molecular weight heparin, a new spontaneous DVT is much less likely versus one related to HIT.

B Cardiac embolism

Cardiac embolism is associated with a cold, pulseless lower limb, rather than the appearance consistent with a DVT

11:38

A 52-year-old woman is brought to the Emergency Department by ambulance after being discovered by a male friend.

On examination, she has a Glasgow Coma Scale (GCS) score of 8, blood pressure (BP) 90/55 mmHg and a supraventricular tachycardia (SVT) with a rate of 160 bpm. There are a number of bottles of amitriptyline 75 mg tablets found empty in the house.

Investigations:

pH	7.15
pa(CO_2)	6.2 kPa
pa(O_2)	6.1 kPa

She is intubated and ventilated and admitted to the Intensive Care Unit (ICU).

Which of the following other measures is most appropriate in the management of this tricyclic overdose?

A Verapamil IV

B Sodium bicarbonate IV

C Propranolol IV

D Flecainide IV

E Flumazenil IV

Rana Alnasser's screen

B Sodium bicarbonate IV

Death may follow as little as 1000 mg of tricyclic antidepressant overdose. QRS prolongation to >100 ms is an early sign of significant toxicity, while QRS prolongation >120 ms is associated with the risk of ventricular arrhythmias. Guidelines suggest that sodium bicarbonate is the most appropriate first-line intervention.

A Verapamil IV

Verapamil is associated with PR prolongation and is therefore not recommended for management of SVT in this situation.

C Propranolol IV

Propranolol is associated with QRS widening, which can actually increase the risk of arrhythmia in tricyclic anti-depressant overdose.

D Flecainide IV

Flecainide produces dose-related increases in the PR, QRS and QT intervals, again actually increasing the risk of rhythm disturbance in tricyclic anti-depressant overdose.

E Flumazenil IV

Flumazenil is used for reversal of benzodiazepine overdose, and in the situation of tricyclic antidepressant toxicity may actually increase the risk of seizures.

Rate this question:

Rana Alnasser's screen

A 48-year-old man attends an Outpatient Clinic. He has a background of angina, hyperlipidaemia and hypertension. He gives a history of right upper quadrant abdominal pain, which is made worse on eating fatty foods. The pain has been severe enough for him to vomit.

What medication is most likely to increase symptoms of gall bladder disease?

A	Fenofibrate
B	Cholestyramine
C	Simvastatin
D	Niacin
E	Omega-3 fish acid

7059

Submit

Previous Q... Skip Questi...

© Pastest 2019

A 48-year-old man attends an Outpatient Clinic. He has a background of angina, hyperlipidaemia and hypertension. He gives a history of right upper quadrant abdominal pain, which is made worse on eating fatty foods. The pain has been severe enough for him to vomit.

What medication is most likely to increase symptoms of gall bladder disease?

Your answer was incorrect

A Fenofibrate

B Cholestyramine

C Simvastatin

D Niacin

E Omega-3 fish acid

Explanation

A Fenofibrate

Fibrates activate lipoprotein lipase and lower triglyceride levels. They increase biliary excretion of cholesterol and predispose to the formation of cholesterol gallstones.

B Cholestyramine

Cholestyramine is a bile salt binder, preventing bile salts

11:41
https://mypastest.pastest.com/Secure/TestMe/Browse

A Fenofibrate

Fibrates activate lipoprotein lipase and lower triglyceride levels. They increase biliary excretion of cholesterol and predispose to the formation of cholesterol gallstones.

B Cholestyramine

Cholestyramine is a bile salt binder, preventing bile salts returning to the circulation via the enterohepatic circulation. This causes the liver to break down cholesterol. The main side effects are constipation and flatulence. It is now mainly used as a treatment for bile acid diarrhoea in patients with small bowel inflammatory disease.

C Simvastatin

Simvastatin is a HMG-CoA (3-hydroxy-3-methylglutaryl coenzyme A) reductase inhibitor. This enzyme catalyses the rate-limiting step in cholesterol synthesis of HMG-CoA to mevalonic acid. Side effects include myositis and deranged liver function tests.

D Niacin

Niacin inhibits adipose tissue lipolysis. Flushing and pruritus limit its use for many patients.

E Omega-3 fish acid

Omega-3 fatty acids either have no effect on the risk of gallstones or may slightly reduce the risk of them occurring.

You are asked to review gentamicin dosing in a 71-year-old man who is being treated post-abdominal surgery. He has a past medical history of hypertension and mild renal impairment. Current dose is 50 mg TDS.

Investigations:

		Normal Values
Haemoglobin (Hb)	12.1 g/dl	
White cell count (WCC)	12.2×10^9/l	
Platelets (PLT)	238×10^9/l	
Sodium (Na^+)	141 mmol/l	
Potassium (K^+)	4.8 mmol/l	
Creatinine (Cr)	142 µmol/l	
Pre-dose gentamicin (trough)	2.8 mg/l	0-2 mg/l
Post-dose gentamicin (peak)	7 mg/l	5-10 mg/l

Which of the following is the most appropriate course of action with respect to his gentamicin dosing?

A Stop the gentamicin

B Make the dose 50 mg BD

C Make the dose 75 mg BD

D Make the dose 150 mg OD

E Make the dose 25 mg TDS

D Make the dose 150 mg OD

The key points here are that there is scope to increase the dose of gentamicin, because the maximum peak level has not been reached, and that TDS dosing has resulted in trough levels which are too high. As such, the best option is potentially to keep the total daily dose the same but reduce the frequency of dosing to once per day.

B Make the dose 50 mg BD

This risks a fall in peak levels of gentamicin to below those for optimal drug exposure.

A Stop the gentamicin

Stopping the gentamicin risks a recrudescence of bacterial sepsis, and there is clear scope to manipulate the dosing regimen to achieve better trough levels.

C Make the dose 75 mg BD

BD dosing is unlikely to reduce trough levels of gentamicin to within target.

E Make the dose 25 mg TDS

Although this will reduce trough levels of gentamicin to within target, it will most likely mean that optimal peak levels are not achieved.

Rate this question:

Next Question

11:46
404 — Not Found × 404 — Not Found × Home Feed | Re ×
https://mypastest.pastest.com/Secure/TestMe/Browse

Haemoglobin (Hb)	12.1 g/dl	
White cell count (WCC)	12.2 × 10^9/l	
Platelets (PLT)	238 × 10^9/l	
Sodium (Na^+)	141 mmol/l	
Potassium (K^+)	4.8 mmol/l	
Creatinine (Cr)	142 µmol/l	
Pre-dose gentamicin (trough)	2.8 mg/l	0-2 mg/l
Post-dose gentamicin (peak)	7 mg/l	5-10 mg/l

Which of the following is the most appropriate course of action with respect to his gentamicin dosing?

Stop Annotation Spotlight Pen Highlighter Line Rectangle Oval Undo

Your answer was incorrect

A Stop the gentamicin

B Make the dose 50 mg BD

C Make the dose 75 mg BD

D Make the dose 150 mg OD

E Make the dose 25 mg TDS

B Make the dose 50 mg BD

This risks a fall in peak levels of gentamicin to below those for optimal drug exposure.

A Stop the gentamicin

Stopping the gentamicin risks a recrudescence of bacterial sepsis, and there is clear scope to manipulate the dosing regimen to achieve better trough levels.

C Make the dose 75 mg BD

BD dosing is unlikely to reduce trough levels of gentamicin to within target.

E Make the dose 25 mg TDS

Although this will reduce trough levels of gentamicin to within target, it will most likely mean that optimal peak levels are not achieved.

Rate this question:

Next Question

© Pastest 2019

You are asked to review a 24-year-old woman with a history of epilepsy and learning difficulties. She takes a range of antiepileptics drugs (AED) and mood stabilisers.

On examination, she has a rash on her lower limbs that consists of a number of erythematous indurated papules and nodules. Biopsy of the lesions reveals extensive T-lymphocyte infiltration.

Which of the following is the most likely diagnosis in this patient?

A	Drug-induced pseudolymphoma syndrome
B	Cutaneous T-cell lymphoma
C	Drug-induced lupus
D	Lymphomatoid papulosis
E	Dermatitis herpetiformis

Submit

Previous Q... Skip Questi...

© Pastest 2019

11:48
404 – Not Found × 404 – Not Found × Home Feed | Re
https://mypastest.pastest.com/Secure/TestMe/Bro

You are asked to review a 24-year-old woman with a history of epilepsy and learning difficulties. She takes a range of antiepileptics drugs (AED) and mood stabilisers.

On examination, she has a rash on her lower limbs that consists of a number of erythematous indurated papules and nodules. Biopsy of the lesions reveals extensive T-lymphocyte infiltration.

Which of the following is the most likely diagnosis in this patient?

Your answer was correct

A	Drug-induced pseudolymphoma syndrome
B	Cutaneous T-cell lymphoma
C	Drug-induced lupus
D	Lymphomatoid papulosis
E	Dermatitis herpetiformis

Explanation

A	Drug-induced pseudolymphoma syndrome

Causes include AED (phenytoin, carbamazepine, lamotrigine and a number of other agents). A number of

A Drug-induced pseudolymphoma syndrome

Causes include AED (phenytoin, carbamazepine, lamotrigine and a number of other agents). A number of antibiotics, antiarrhythmics, antidepressants and antihistamines have also been implicated. Treatment involves discontinuation of all possible causative drugs. It is necessary to monitor resolution of symptoms as malignant transformation of skin lesions has been reported.

B Cutaneous T-cell lymphoma

Cutaneous T-cell lymphoma is a disease of the elderly and presents with chronic itching and widespread erythema.

C Drug-induced lupus

At least initially, drug-induced lupus would be expected to lead to an erythematous rash over sun-exposed areas rather than the generalised picture seen here.

D Lymphomatoid papulosis

In the event that we were not given the history of mood stabiliser and anti-epileptic use, lymphomatoid papulosis would be considered the main differential diagnosis.

E Dermatitis herpetiformis

Dermatitis herpetiformis is more likely to present with a blistering skin rash associated with neutrophil, rather than lymphocyte, infiltration.

9277

Rate this question:

Rana Alnasser's screen

11:50

A patient is admitted for treatment of multi-drug resistant tuberculosis. The patient is currently taking rifampicin, isoniazid and pyrazinamide. He is commenced on streptomycin.

What is the main concern with respect to streptomycin use?

A Vestibular damage

B Hepatic dysfunction

C Optic neuropathy

D Autonomic neuropathy

E Peripheral motor neuropathy

Submit

Previous Q... Skip Questi...

© Pastest 2019

Audio Video Share Participants More

11:50

type b

pathology

type c

Lymphomatoid papulosis | De...
dermnetnz.org

Lymphomatoid Papulosis: Re...
jamanetwork.com

Lymphomatoid Papulosis - Cli...
clinicaladvisor.com

Multiple erythematous papul...
researchgate.net

Figure 4 from Lymphomatoid ...
semanticscholar.org

الد... = Lymphomatoid papulosis
dermaamin.com

Lymphomatoid Papulosis: Re...

Collections

11:50
594-042-7551
Leave
https://[illegible]pastest.com/Secure/Tests/[illegible]

A Vestibular damage

Streptomycin is an aminoglycoside bactericidal antibiotic. It is used in the treatment of tularaemia and resistant mycobacterial infections. The most common neurological side-effect is vestibular damage causing persistent vertigo and vomiting. For this reason, ethambutol is usually added to tuberculosis regimes in preference to streptomycin.

B Hepatic dysfunction

Aminoglycosides including streptomycin impact most on renal function and are a cause of neuropathy. They would not be expected to lead to significant hepatic dysfunction.

C Optic neuropathy

Ethambutol is the agent associated with optic neuropathy.

D Autonomic neuropathy

Isoniazid is recognised to result in peripheral, rather than autonomic neuropathy.

E Peripheral motor neuropathy

Isoniazid results in peripheral neuropathy, the risk of which is partially ameliorated by pyridoxine supplementation.

Rate this question:
Audio Video Share Participants More

A 68-year-old man woke up at 0800 h with right-sided weakness of his limbs and face. He was able to convey information by sign language and not able to speak. He was immediately brought to the Emergency Department by his wife within the next 15 min and is being assessed by you at 0900 h. He is treated with atenolol for hypertension

On examination, his pulse is 76/min and regular. All peripheral pulses are present, except both dorsalis pedis pulses. His blood pressure is 180/110 mmHg. He is drowsy and fundi reveal grade 2 hypertensive changes. He has an expressive dysphasia. Ocular movements are normal. A right-sided hemianopia is detected. The right-sided nasolabial fold is obliterated but he is able to close both eyes promptly. The right upper limb has power of 2/5 and lower limb 3/5. Right-sided tendon reflexes are sluggish with reduced muscle tone. The right plantar is extensor and the left is flexor. He has right-sided hemihypoaesthesia. There is no carotid bruit. S4 is audible on cardiac auscultation.

An urgent computed tomography (CT) of the head reveals a 'dot sign' in the left sylvian fissure. There is effacement of sulci over the left hemisphere.

What is the correct initial therapeutic approach for this patient?

A	Lower the blood pressure to 140/90 mmHg
B	Immediate IV thrombolysis
C	Intra-arterial thrombolysis
D	IV loading of heparin followed by a 24 hhr infusion
E	Aspirin 300 mg

11:54
404 — Not Found × 404 — Not Found × Home Feed | Re
https://mypastest.pastest.com/Secure/TestMe/Brov

A 68-year-old man woke up at 0800 h with right-sided weakness of his limbs and face. He was able to convey information by sign language and not able to speak. He was immediately brought to the Emergency Department by his wife within the next 15 min and is being assessed by you at 0900 h. He is treated with atenolol for hypertension.

On examination, his pulse is 76/min and regular. All peripheral pulses are present, except both dorsalis pedis pulses. His blood pressure is 180/110 mmHg. He is drowsy and fundi reveal grade 2 hypertensive changes. He has an expressive dysphasia. Ocular movements are normal. A right-sided hemianopia is detected. The right-sided nasolabial fold is obliterated but he is able to close both eyes promptly. The right upper limb has power of 2/5 and lower limb 3/5. Right-sided tendon reflexes are sluggish with reduced muscle tone. The right plantar is extensor and the left is flexor. He has right-sided hemihypoaesthesia. There is no carotid bruit. S4 is audible on cardiac auscultation.

An urgent computed tomography (CT) of the head reveals a 'dot sign' in the left sylvian fissure. There is effacement of sulci over the left hemisphere.

What is the correct initial therapeutic approach for this patient?

Your answer was incorrect

A Lower the blood pressure to 140/90 mmHg

B Immediate IV thrombolysis

Explanation

E Aspirin 300 mg

This patient has woken from sleep with symptoms of a stroke; as such, it's impossible to calculate the time since the stroke occurred, making it outside the window for thrombolysis. In this case, with the CT scan suggesting an embolic stroke and no sign of haemorrhage, moving to anti-platelet therapy is the next most important step.

B Immediate IV thrombolysis

Intravenous tissue plasminogen activator (t-PA) therapy is advocated only to patients within 4.5 h of the onset of a stroke; this recommendation comes from analysis of both the NINCDS and ECASS II studies.

A Lower the blood pressure to 140/90 mmHg

There is no evidence that benefit is derived from lowering blood pressure in this situation, and indeed it may cause harm because of extension of the infarcted area.

C Intra-arterial thrombolysis

For the same reason that IV thrombolysis isn't advocated here, intra-arterial thrombolysis doesn't have a role in the treatment of this patient.

D IV loading of heparin followed by a 24 hhr infusion

Heparin offers no advantage over aspirin with respect to neurological recovery, at the expense of increased risk of bleeding.

A 27-year-old woman, who is five months pregnant and allergic to penicillin, comes to the clinic complaining of a severe cough productive of rusty coloured sputum and marked shortness of breath.

On examination, she is pyrexial 38.3 °C, her blood pressure is 110/70 mmHg, her pulse is 89 bpm and her respiratory rate is 28/min. She has bronchial breathing over the right lower zone on auscultation.

Investigations:

Hb	11.6 g/dl
WCC	13.1×10^9/l
PLT	210×10^9/l
Na^+	138 mmol/l
K^+	4.3 mmol/l
Creatinine	90 µmol/l
Urea	8.3 mmol/l
Chest X-ray	Extensive right lower lobe consolidation

Which of the following is the most appropriate antibiotic choice for her?

A Doxycycline

B Clarithromycin

C Ciprofloxacin

D Cephalexin

E Olfloxacin

Explanation

B Clarithromycin

Macrolide antibiotics are the preferred first-line agents for pneumonia in patients who are allergic to penicillin, including pregnant women. Dose frequency and GI tolerability mean that newer agents such as clarithromycin are preferred to erythromycin in later pregnancy. In early pregnancy use of clarithromycin may be associated with early fetal loss.

https://www.ncbi.nlm.nih.gov/pubmed/23301061

A Doxycycline

Tetracyclines are not recommended for use in pregnancy because of the risk of significant and permanent tooth discolouration.

C Ciprofloxacin

Quinolones are associated with increased risk of tendon rupture in animal models and cartilage abnormalities; they are not therefore recommended for use in pregnancy.

D Cephalexin

There is some crossover of allergy between penicillins and cephalosporins, and they are generally considered less effective than macrolides in the treatment of pneumonia.

E Olfloxacin

Olfloxacin, although it is a second-generation quinolone, is still associated with increased risk of tendon rupture.

Rana Alnasser's screen

12:00
404 — Not Found × 404 — Not Found × Home Feed | Re
https://mypastest.pastest.com/Secure/TestMe/Bro

A 60-year-old woman comes to the clinic. She has a background of chronic atrial fibrillation and diabetes. She is taking digoxin, warfarin and metformin.

The patient tells you that she has been feeling low in mood since her husband died, and has started taking St John's wort.

What is the patient at increased risk from?

A	Embolic stroke
B	Bleeding
C	Pancreatitis
D	Increased blood glucose
E	Hypomania

7060

Submit

Previous Q...

12:01
404 — Not Found × 404 — Not Found × Home Feed | Re
https://mypastest.pastest.com/Secure/TestMe/Bro

Pastest+ Question 83 of 83

A 60-year-old woman comes to the clinic. She has a background of chronic atrial fibrillation and diabetes. She is taking digoxin, warfarin and metformin.

The patient tells you that she has been feeling low in mood since her husband died, and has started taking St John's wort.

What is the patient at increased risk from?

Your answer was correct

- A Embolic stroke
- B Bleeding
- C Pancreatitis
- D Increased blood glucose
- E Hypomania

Explanation

A Embolic stroke

St John's wort is a herbal remedy that is used by many for depression, anxiety or sleep disturbance. It is an enzyme inducer and will result in decreased prothrombin time in

A Embolic stroke

St John's wort is a herbal remedy that is used by many for depression, anxiety or sleep disturbance. It is an enzyme inducer and will result in decreased prothrombin time in patients taking warfarin. Hence the patient is at increased risk of embolic stroke. It can also cause photosensitivity and gastrointestinal upset. Young female patients who are also taking the combined oral contraceptive pill should be warned that St John's wort will interfere with their contraception.

B Bleeding

St John's wort is an enzyme inducer rather than inhibitor, and therefore results in a decrease rather than an increase in INR.

C Pancreatitis

Diabetes mellitus *per se* is associated with an increased risk of pancreatitis, and the use of St John's wort has no further impact on this level of risk.

D Increased blood glucose

Metformin is not metabolised via the P450 system, and St John's wort therefore has no effect with respect to increasing blood glucose.

E Hypomania

St John's wort is as effective as an SSRI in treating depression and does not increase the risk of hypomania in patients who take it.

٩:١٠ ص
STC
MyPastest
https://mypastest.pastest.com

Pastest+

Question 1 of 20

A 45-year-old man is referred with reduced energy levels, difficulty sleeping and low mood, symptoms he has been experiencing for several months. His wife divorced him last year on grounds of unreasonable behaviour, when he became withdrawn and refused to do anything around the house after losing his job.

On further questioning, he also admits to hearing voices telling him that he is useless.

What is the most likely diagnosis?

A	Depression
B	Personality disorder
C	Manic depression
D	Schizophrenia
E	Phobic anxiety

(7073)

Submit

Previous Q...

Skip Questi...

٩:١٥ ص
STC
MyPastest
https://mypastest.pastest.com

Explanation

A	Depression

This patient suffers key symptoms of depression such as persistent low energy levels, and low mood (for greater than at least two weeks) as described by the ICD-10. He also suffers associated symptoms of sleep disturbance. He has psychotic elements to his illness as evidenced by auditory hallucinations in the second person, which can occur in affective disorders. The constellation of these symptoms makes depression the most likely answer.

B	Personality disorder

A personality disorder is defined by the ICD-10 as a condition of 'deeply ingrained and enduring behaviour patterns, manifesting as inflexible responses to a broad range of personal and social situations'. As this patient's symptoms are consistent with depression and he has no history of any prior behavioural disturbance, the diagnosis of personality disorder is not likely.

C	Manic depression

The patient does have symptoms consistent with depression; however, with no prior history of mania or hypomania, a diagnosis of bipolar affective disorder is not warranted.

D	Schizophrenia

The patient does suffer from auditory hallucinations; however, these can occur in depressive disorders and, alongside his other symptoms, depression is the most likely diagnosis. The ICD-10 in their diagnostic criteria for schizophrenia advise that auditory hallucinations more likely to be suggestive of schizophrenia include: third-person hallucinations, running commentaries, voices discussing the patient between themselves or voices coming from some part of the body.

E	Phobic anxiety

The patient expresses no specific phobia or anxiety symptoms, making this diagnosis incorrect.

Rate this question:

٩:١٦ ص STC

Pastes+

Question 2 of 20

A 30-year-old man attends the Outpatient Clinic. He has an obsession with washing his hands and spends up to one hour doing this each morning and evening. He says he feels that he is dirty. He is also concerned about security and checks the doors at home a number of times before leaving the house.

On examination, he is of low mood. He is slowed up in speech but coherent.

Which of the follow diagnoses fit best with this clinical picture?

A	Acute schizophrenia
B	Major depressive illness
C	Obsessive-compulsive disorder
D	Bipolar affective disorder
E	Anxiety neurosis

70732

Submit

Previous Q... Skip Questi...

© Pastest 2019

٩:٢٠ ص
STC
MyPastest
https://mypastest.pastest.com

Pastes+

Question 2 of 20

A 30-year-old man attends the Outpatient Clinic. He has an obsession with washing his hands and spends up to one hour doing this each morning and evening. He says he feels that he is dirty. He is also concerned about security and checks the doors at home a number of times before leaving the house.

On examination, he is of low mood. He is slowed up in speech but coherent.

Which of the follow diagnoses fit best with this clinical picture?

Your answer was correct

A	Acute schizophrenia
B	Major depressive illness
C	Obsessive-compulsive disorder
D	Bipolar affective disorder
E	Anxiety neurosis

Explanation

C	Obsessive-compulsive disorder

Given this clinical picture of repetitive behaviour that is intrusive and consumes a significant amount of time during the day, OCD appears to be the most likely diagnosis. Associated depression is quite possible and is related to inability to overcome the repetitive cycles of behaviour. The incidence of OCD may be as high as 1-2% of the adult population and the condition occurs with roughly equal sex

٩:٢١ ص 4G STC

E Anxiety neurosis

Explanation

C Obsessive-compulsive disorder

Given this clinical picture of repetitive behaviour that is intrusive and consumes a significant amount of time during the day, OCD appears to be the most likely diagnosis. Associated depression is quite possible and is related to inability to overcome the repetitive cycles of behaviour. The incidence of OCD may be as high as 1–2% of the adult population and the condition occurs with roughly equal sex incidence. Cognitive therapy or selective serotonin reuptake inhibitors are effective treatments.

A Acute schizophrenia

This patient is coherent, and does not present with classical thought disorder, auditory hallucination or delusions associated with acute schizophrenia. His obsessive symptoms are much more in keeping with a diagnosis of OCD.

B Major depressive illness

The patient does have slowed speech and appears low in mood, making it likely he is suffering from an element of concomitant depression; however, his obsessive symptoms best fit the clinical picture of OCD.

D Bipolar affective disorder

This patient has no historical or current symptoms of mania or hypomania, and therefore a diagnosis of bipolar affective disorder is not warranted.

E Anxiety neurosis

Symptoms of anxiety, such as tension, worry and feelings of apprehension, are not described in this vignette, and his obsessive symptoms are much more in keeping with a diagnosis of OCD.

20752

Rate this question:

Next Question

٩:٢٢ ص STC

A 72-year-old man had been started on a selective serotonin reuptake inhibitor (SSRI) by his GP after presenting with symptoms of depression. He had responded well to treatment, but 3 months later returns to see you.

He is worried about things he has read in the newspaper saying that this medication could be harmful - in particular, that it may cause suicidal thoughts.

What should you do about his current antidepressant medication?

A	Reassure and continue current treatment
B	Reduce dose by 50%
C	Refer to psychiatrist
D	Change to tricyclic antidepressant
E	Stop antidepressant treatment

70753

Submit

Previous Q... Skip Questi...

© Pastest 2019

٩:٣١ ص
STC
MyPastest
https://mypastest.pastest.com

A 72-year-old man had been started on a selective serotonin reuptake inhibitor (SSRI) by his GP after presenting with symptoms of depression. He had responded well to treatment, but 3 months later returns to see you.

He is worried about things he has read in the newspaper saying that this medication could be harmful - in particular, that it may cause suicidal thoughts.

What should you do about his current antidepressant medication?

Your answer was correct

A	Reassure and continue current treatment
B	Reduce dose by 50%
C	Refer to psychiatrist
D	Change to tricyclic antidepressant
E	Stop antidepressant treatment

Explanation

A	Reassure and continue current treatment

SSRI is a first-line treatment for depression and is an appropriate agent to use in this patient. The fact that he is responding well further supports your decision to use this treatment. There are some case reports linking increased suicidal thoughts, though not suicidal acts, to SSRIs in teenagers and young adults, and this has been occasionally misreported or sensationalised in the media. There is no clear evidence of this in adults over 18 years of age. In this case, it is best to reassure the patient and continue his SSRI treatment to which he is responding (see weblink below)

٩:٣١ ص
STC
MyPastest
https://mypastest.pastest.com

Explanation

A	Reassure and continue current treatment

SSRI is a first-line treatment for depression and is an appropriate agent to use in this patient. The fact that he is responding well further supports your decision to use this treatment. There are some case reports linking increased suicidal thoughts, though not suicidal acts, to SSRIs in teenagers and young adults, and this has been occasionally misreported or sensationalised in the media. There is no clear evidence of this in adults over 18 years of age. In this case, it is best to reassure the patient and continue his SSRI treatment to which he is responding (see weblink below).

SSRIs are suitable for the vast majority of patients with depression. In a small number of cases it has been suggested that the may be linked to psychomotor agitation in the initial few days after commencing treatment. In addition, some patients may experience a return of symptoms after treatment withdrawal, so that abrupt cessation of treatment is not recommended. Significantly, patients who discontinue treatment after 3 months are at significantly higher risk of relapse. Tricyclic antidepressants would be associated with significantly more side effects, particularly in this age group.

B	Reduce dose by 50%

This patient is responding well to treatment and doesn't complain of any side effects. There is no indication to change his dose at this point. Gradual tapering of an SSRI is usually indicated when preparing to discontinue the drug, or when switching to another antidepressant medication.

C	Refer to psychiatrist

The patient has a simple query that can be managed in primary care. Minor to moderate to depression can by managed in the community by a general practitioner with a combination of pharmacological and psychological treatments. Reasons to refer would be if the diagnosis is unclear, failing to respond to treatment or rapid worsening of symptoms.

D	Change to tricyclic antidepressant

The patient is responding to his SSRI treatment, and therefore a switch to a tricyclic antidepressant (TCA) is not indicated. Even if the patient was failing to respond to an SSRI in terms of his depressive symptoms, an alternative SSRI would be the most likely second agent to switch to rather than a TCA treatment, which generally has more side effects (especially in an older person).

٩:٣٢ ص
STC
MyPastest
https://mypastest.pastest.com

Calculat

Normal Va

You are called to the Geriatric Psychiatry Ward to assess a new inpatient. A 66-year-old man was admitted yesterday for elective investigation of cognitive dysfunction. His wife describes a background of worsening memory problems and poor mobility. The pattern is one of 'good days' with minimal symptoms, followed by periods of sudden deterioration.

In the weeks prior to admission, he has suffered frequent falls. He has no psychiatric history, although he has recently complained of fleeting visual hallucinations. He had no regular medication prior to admission.

On the night of his admission, he became acutely distressed, complaining of 'seeing monsters' in his peripheral vision. His agitation was such that he required emergency sedation.

On examination, he is drowsy and unable to give a coherent history. Tone is increased in all four limbs, although power seems normal. He has symmetrical upper limb rigidity and bradykinesia. His wife claims the involuntary movements are new.

What is the most appropriate management for the underlying neurological condition that has precipitated his admission to hospital?

A	Selective serotonin reuptake inhibitor
B	Acetylcholinesterase inhibitors
C	Aspirin and statins
D	Copper-chelating agents
E	Dopamine agonists

70735

Submit

Previous Q...

Skip Questi...

٩:٣٥ ص STC

You are called to the Geriatric Psychiatry Ward to assess a new inpatient. A 66-year-old man was admitted yesterday for elective investigation of cognitive dysfunction. His wife describes a background of worsening memory problems and poor mobility. The pattern is one of 'good days' with minimal symptoms, followed by periods of sudden deterioration.

In the weeks prior to admission, he has suffered frequent falls. He has no psychiatric history, although he has recently complained of fleeting visual hallucinations. He had no regular medication prior to admission.

On the night of his admission, he became acutely distressed, complaining of 'seeing monsters' in his peripheral vision. His agitation was such that he required emergency sedation.

On examination, he is drowsy and unable to give a coherent history. Tone is increased in all four limbs, although power seems normal. He has symmetrical upper limb rigidity and bradykinesia. His wife claims the involuntary movements are new.

What is the most appropriate management for the underlying neurological condition that has precipitated his admission to hospital?

Your answer was correct

A	Selective serotonin reuptake inhibitor
B	Acetylcholinesterase inhibitors
C	Aspirin and statins
D	Copper-chelating agents
E	Dopamine agonists

Explanation

B Acetylcholinesterase inhibitors

This patient's underlying diagnosis is very suggestive of

٩:٣٧ ص STC

A 72-year-old woman visits the clinic feeling low. She has been feeling down for some time, and believes the problem has been confounded by an overactive bladder, previously assessed by the urology team, meaning that she is up and down to the toilet about ten times a day.

On further questioning, she admits that she is apprehensive most of the day, and cannot relax She she lives alone, her husband died five years ago and the only company she has is her cat. She has lost 5 kg in weight over the past year and wakes up at around 0430-0500 h.

Clinical examination is unremarkable.

Given the likely diagnosis, which of the following represents the most appropriate therapy for this woman?

A	Oxybutynin
B	Sertraline
C	Dothiepin
D	Tolterodine
E	Amitriptyline

70736

Submit

٩:٣٦ ص STC
MyPastest
https://mypastest.pastest.com

keeping with either of these diagnoses, and therefore this would not be the most appropriate agent to use in his management.

C	Aspirin and statins

This combination would be appropriate for a patient suffering from vascular dementia, a dementing illness caused by series of repeated cerebral infarctions, usually in the context of risk factors such as hypertension. The disease manifests in a step-wise manner, and so periods of stability between deterioration can appear as the fluctuant stage of DLB. Neurological symptoms may also occur in vascular dementia, making these conditions difficult to differentiate. However, the patient's tetrad symptoms of dementia, fluctuant course, parkinsonism and visual hallucination point more towards a diagnosis of DLB.

D	Copper-chelating agents

Wilson's disease, which is treated with copper-chelating agents, is a genetic disorder of copper metabolism that results in copper accumulation in body tissues, particularly the liver, brain, eyes and kidneys, and can present with neuro-psychiatric symptoms, including parkinsonism symptoms. However, it will usually also present with symptoms of liver disease and the classical Kayser-Fleischer rings on eye exam. The disease is most commonly diagnosed between the ages of 5 and 35 years.

E	Dopamine agonists

Acetylcholinesterase inhibitors can be seen as a first-line treatment in DLB as they can have an improvement on neuropsychiatric and motor symptoms. Dopamine agonists such as ropinirole and rotigotine are used in the treatment of Parkinson's disease. For the severe parkinsonian symptoms of DLB, dopamine agonists have been used but they have been associated with worsening psychotic and behavioural symptoms. For this reason, small doses of levodopa are generally the preferred treatment for motor symptoms, as this agent has a lower side effect profile.

20735
Rate this question:
Next Question

٩:٣٦ ص STC
MyPastest
https://mypastest.pastest.com

Explanation

B	Acetylcholinesterase inhibitors

This patient's underlying diagnosis is very suggestive of dementia with Lewy bodies (DLB). This is a neurodegenerative disease caused by deposition of Lewy bodies (abnormal protein aggregates) in the cerebral cortex and brain stem. The consortium on DLB international workshop diagnostic criteria suggests the diagnosis is likely if, in the context of dementia, there are also present two of the three following core features: fluctuating attention and concentration, recurrent well-formed visual hallucinations and spontaneous parkinsonian motor signs. Further suggestive features include rapid eye movement (REM) sleep behaviour disorder, and a severe sensitivity to the extra-pyramidal side effects of neuroleptics. There is some evidence in the form of a small number of randomised controlled trials and open label studies to suggest that acetyl cholinesterase inhibitors, such as rivastigmine, may reduce hallucinations, fluctuations and parkinsonian symptoms and improve attention.

A	Selective serotonin reuptake inhibitor

Selective serotonin reuptake inhibitors are a class of antidepressant drugs that are typically used to treat depression and anxiety. This patient's presentation is not in keeping with either of these diagnoses, and therefore this would not be the most appropriate agent to use in his management.

C	Aspirin and statins

This combination would be appropriate for a patient suffering from vascular dementia, a dementing illness caused by series of repeated cerebral infarctions, usually in the context of risk factors such as hypertension. The disease manifests in a step-wise manner, and so periods of stability between deterioration can appear as the fluctuant stage of DLB. Neurological symptoms may also occur in vascular dementia, making these conditions difficult to differentiate. However, the patient's tetrad symptoms of dementia, fluctuant course, parkinsonism and visual

٩:٤٠ ص 4G STC

Explanation

B	Sertraline

This lady is complaining of low mood and anxiety symptoms. She has somatic symptoms of depression including weight loss and early morning wakening, as well as symptoms of anxiety such as apprehension and an inability to relax. The most appropriate treatment for these symptoms would be a selective serotonin reuptake inhibitor (SSRI) in the first instance. Possible second-line agents to treat her symptoms would include the tricyclic antidepressants (TCAs) dothiepin and amitriptyline; however, bear in mind their anticholinergic side-effect profile could worsen her urinary symptoms by causing retention or obfuscating future urinary investigation.

A	Oxybutynin

Oxybutynin is an anticholinergic medication that can be used to treat symptoms of urinary frequency or urgency. This medication may help the patient's urinary symptoms, but it will not treat any symptoms of low mood and anxiety - the reasons why this lady attended clinic initially.

C	Dothiepin

In accordance with NICE guidelines, TCAs are not the first-line treatment of anxiety or depressive symptoms. They are an effective treatment for these symptoms, but their higher toxicity profile makes an SSRI a more appropriate agent to use as a primary treatment choice. Additionally, TCAs may further disturb the patient's urinary symptoms.

D	Tolterodine

Tolterodine is an antimuscarinic agent that can be used as a treatment for detrusor overactivity. It could potentially be used to treat this patient's symptoms of urinary frequency, but would not treat her symptoms of low mood and anxiety for which she had initially attended the clinic.

E	Amitriptyline

In accordance with NICE guidelines, TCAs are not the first-line treatment for anxiety or depressive symptoms. They are an effective treatment for these symptoms but their higher toxicity profile makes an SSRI a more appropriate agent to use as a primary treatment choice. Additionally, TCAs may further disturb the patient's urinary symptoms.

Calcu

Normal

A 62-year-old man, with a past medical history of hypertension, comes to the Emergency Department with his daughter, who is very concerned that he may be depressed.

He wakes very early in the morning, has been complaining of low mood and energy levels and seems not to have been eating for the past few weeks. Apparently, he has undergone some minor investigations for indigestion, which have proved unremarkable apart from some minor gastro-oesophageal reflux disease for which his GP has prescribed low-dose PPI.

On review, you become quite concerned because he tells you the reason he is depressed is that he thinks he is dying from stomach cancer and he has considered taking a paracetamol overdose (over the past two days), but has been dissuaded from doing this by his daughter.

Investigations:

Hb	12.1 g/dl
WCC	4.9×10^9/l
PLT	175×10^9/l
Na^+	141 mmol/l
K^+	4.2 mmol/l
Creatinine	100 µmol/l

Which of the following would be the most appropriate therapy choice for him?

A	Psychoanalysis
B	Amitriptyline
C	Electroconvulsive therapy
D	Citalopram
E	Venlafaxine

٩:٤٨ ص
STC
MyPastest
https://mypastest.pastest.com

A 62-year-old man, with a past medical history of hypertension, comes to the Emergency Department with his daughter, who is very concerned that he may be depressed.

He wakes very early in the morning, has been complaining of low mood and energy levels and seems not to have been eating for the past few weeks. Apparently, he has undergone some minor investigations for indigestion, which have proved unremarkable apart from some minor gastro-oesophageal reflux disease for which his GP has prescribed low-dose PPI.

On review, you become quite concerned because he tells you the reason he is depressed is that he thinks he is dying from stomach cancer and he has considered taking a paracetamol overdose (over the past two days), but has been dissuaded from doing this by his daughter.

Investigations:

Hb	12.1 g/dl
WCC	4.9 × 10^9/l
PLT	175 × 10^9/l
Na^+	141 mmol/l
K^+	4.2 mmol/l
Creatinine	100 µmol/l

Which of the following would be the most appropriate therapy choice for him?

Your answer was incorrect

A Psychoanalysis

B Amitriptyline

C Electroconvulsive therapy

٩:٤٨ ص STC

Explanation

D Citalopram

This patient is suffering from moderate to severe depression, as evidenced by his symptoms of low mood, low energy, anorexia, early morning wakening and suicidal ideation. ICD-10 lists 10 main symptoms of depression, with the three core symptoms being (1) persistent sadness or low mood, (2) loss of interests or pleasure and (3) fatigue or low energy; and the others being (4) disturbed sleep, (5) poor concentration, (6) low self-confidence, (7) poor appetite, (8) suicidal thoughts, (9) psychomotor agitation or retardation and (10) guilt or self-blame. Moderate depression is described as five or more symptoms, and severe as seven or more. This patient is also suffering a negative delusion regarding a diagnosis of cancer. The first-line pharmaceutical treatment for this illness would be citalopram, an SSRI, as per NICE guidelines.

C Electroconvulsive therapy

The first-line treatment of moderate to severe depression is an SSRI. Electroconvulsive therapy (ECT) is used in the UK for the rapid treatment of severe depression when it is life threatening or when it has failed to respond to other treatments. It is also used to treat resistant mania and catatonia.

A Psychoanalysis

This patient is suffering from moderate to severe depression. Psychological interventions are recommended as part of illness management, but cognitive behavioural therapy or interpersonal therapy is the mainstay of psychological treatment, rather than psychoanalysis.

B Amitriptyline

NICE guidelines recommend a selective serotonin reuptake inhibitor (SSRI) as a first-line treatment in moderate to severe depression, making this answer, amitriptyline, a TCA (tricyclic antidepressant) incorrect. TCAs have a higher toxicity profile and are potentially more harmful than SSRIs in an overdose scenario. They are also more likely to interact with medications that an older patient may be taking concurrently.

E Venlafaxine

Venlafaxine is a serotonin-norepinephrine reuptake inhibitor (SNRI) used in the treatment of depression. SSRIs remain the first-line treatment of depression in accordance with Nice Guidelines. Venlafaxine is listed as a drug to be used with caution in those suffering from hypertension, another reason why it might not be an appropriate treatment option for this patient.

٩:٥١ ص
STC
MyPastest
https://mypastest.pastest.com

An 18-year-old girl is admitted to the Emergency Department after slashing at her arms with a kitchen knife. She has had episodes of paracetamol overdose in the past, and says that this time was because of a row with her boyfriend.

Currently, she finds it difficult to hold down a job and has been in trouble with the police for alcohol abuse. She lives alone, having moved out of the family home due to domestic violence.

On examination, there are multiple, healed scars due to previous wrist and arm slashing. She is abusive and tearful but is otherwise normal.

Which of the following is the most likely diagnosis?

A	Depression
B	Schizophrenia
C	Borderline personality disorder
D	Bipolar disease
E	Post-traumatic stress disorder

70738

Submit

Previous Q... Skip Questi...

Blog About Pastest Contact Us Help
© Pastest 2019

٩:٥٥ ص STC

An 18-year-old girl is admitted to the Emergency Department after slashing at her arms with a kitchen knife. She has had episodes of paracetamol overdose in the past, and says that this time was because of a row with her boyfriend.

Currently, she finds it difficult to hold down a job and has been in trouble with the police for alcohol abuse. She lives alone, having moved out of the family home due to domestic violence.

On examination, there are multiple, healed scars due to previous wrist and arm slashing. She is abusive and tearful but is otherwise normal.

Which of the following is the most likely diagnosis?

Your answer was correct

A	Depression
B	Schizophrenia
C	Borderline personality disorder
D	Bipolar disease
E	Post-traumatic stress disorder

Explanation

C	Borderline personality disorder

Borderline or emotionally unstable personality disorder is a disorder characterised by an unpredictable and capricious mood, emotional outbursts and impulsivity. There is usually instability of interpersonal relationships, intense fear of abandonment, self-harm and suicidal gesture. The patient's behaviour is in keeping with a diagnosis of borderline personality disorder. Treatment usually involves risk assessment and psychological and behavioural interventions.

A	Depression

٩:٥٥ ص
STC
MyPastest
https://mypastest.pastest.com

E Post-traumatic stress disorder

Explanation

C Borderline personality disorder

Borderline or emotionally unstable personality disorder is a disorder characterised by an unpredictable and capricious mood, emotional outbursts and impulsivity. There is usually instability of interpersonal relationships, intense fear of abandonment, self-harm and suicidal gesture. The patient's behaviour is in keeping with a diagnosis of borderline personality disorder. Treatment usually involves risk assessment and psychological and behavioural interventions.

A Depression

Although this patient appears tearful and has evidence of self-harm, there are no other symptoms to suggest a depressive illness, and in fact, her social, forensic and relationship histories are more suggestive of an enduring disorder of the personality.

B Schizophrenia

There is no history here of hallucination, delusion or thought disorder that would suggest a diagnosis of schizophrenia.

D Bipolar disease

There is no history here of previous depressive or manic symptoms, which may include increased talkativeness, grandiosity, psychomotor acceleration or distractibility, and so a diagnosis of bipolar disease is not warranted.

E Post-traumatic stress disorder

There is no suggestion in the vignette of a stressor that has caused the patient distress of a pervasive nature, and no history of the patient 'reliving' the stressor (i.e. via dreams, flashbacks). The predominant symptoms of interpersonal difficulty, self-harm and emotional outbursts point more towards a diagnosis of borderline personality disorder.

70758
Rate this question:

٩:٥٦ ص
STC
MyPastest
https://mypastest.pastest.com

A 54-year-old woman with long-standing schizophrenia is admitted to the Emergency Department with pyrexia and decreased conscious level. Her home help reports that she has been increasingly thirsty over the past few weeks and seems to be drinking increasingly large amounts of tea, and is requesting a number of bottles of Coke as part of the weekly shop. She has struggled with her weight for many years, and has a history of hypertension for which she takes ramipril.

Calcul

Normal

On examination, her Glasgow Coma Sclale (GCS) score is 11. Her BP is 124/80 mmHg and her pulse is 100/min.

Investigations:

Hb	13.2 g/dl
WCC	11.1 × 10^9/l
PLT	247 × 10^9/l
Na^+	146 mmol/l
K^+	5.9 mmol/l
Creatinine	230 µmol/l
Bicarbonate	23 mmol/l
Glucose	41.2 mmol/l

Which of the following medications is most likely to have contributed to her presentation?

A	Flupenthixol
B	Haloperidol
C	Risperidone
D	Fluoxetine
E	Clozapine

Submit

١٠:٠٠ ص
STC
MyPastest
https://mypastest.pastest.com

E Clozapine

Atypical antipsychotics are associated with a risk of developing type 2 diabetes. A study by Nielsen et al. (see below) found that type 2 diabetes occurred most commonly with clozapine (odds ratio (OR) 2.37) and olanzapine (OR 1.57). It is thought that olanzapine and clozapine lead to increased weight gain and insulin resistance, and this may accelerate the development of impaired glucose tolerance and diabetes. Antagonism at the 5-HT2C and H1 receptors seems to be involved in antipsychotic-induced weight gain. Among the antipsychotics, clozapine and olanzapine, which have the highest weight gain/obesity risk, also have the highest affinities for 5-HT2C and H1 receptors.

A Flupenthixol

This lady has hyperglycaemia and polydipsia, suggesting the development of diabetes. Flupenthixol is a typical antipsychotic whose main side effects include extrapyramidal and anti-muscarinic symptoms. It may cause hyperglycaemia and the development of diabetes, but nowhere near at the same frequency as clozapine and other atypical antipsychotics.

B Haloperidol

Haloperidol is a typical antipsychotic whose main side effects include extrapyramidal and anti-muscarinic symptoms. It may cause hyperglycaemia and the development of diabetes, but nowhere near at the same frequency as clozapine and other atypical antipsychotics.

C Risperidone

The use of atypical antipsychotics is associated with the development of diabetes. However, risperidone is seen as one of these drugs with a lower risk of causing diabetes.

D Fluoxetine

Fluoxetine is a selective serotonin reuptake inhibitor (SSRI) and is not associated with significant risk of developing diabetes.

70759
Rate this question:
Next Question

MyPastest
https://mypastest.pastest.com

A 56-year-old woman with chronic back pain is reviewed at the pain clinic. The doctor who reviews her is concerned that there may be an element of depression that is worsening her symptoms, and decides to prescribe citalopram. However, she returns to the Emergency Department the following day feeling agitated and unwell.

On examination, she has globally increased rigidity and tremor. She is confused and agitated when questioned about her symptoms. Her temperature is elevated at 37.8 °C, her BP is 155/92 mmHg, with a RR of 25 and a pulse of 100/min.

Investigations:

Hb	13.2 g/dl
WCC	6.9×10^9/l
PLT	190×10^9/l
Na^+	141 mmol/l
K^+	5.1 mmol/l
Creatinine	130 µmol/l
Urea	13.2 mmol/l

Which of the following is the most likely diagnosis?

A Tardive dyskinesia

B Serotonin syndrome

C Tramadol toxicity

D Attention seeking behaviour

E Encephalitis

Submit

MyPastest
https://mypastest.pastest.com

A 56-year-old woman with chronic back pain is reviewed at the pain clinic. The doctor who reviews her is concerned that there may be an element of depression that is worsening her symptoms, and decides to prescribe citalopram. However, she returns to the Emergency Department the following day feeling agitated and unwell.

On examination, she has globally increased rigidity and tremor. She is confused and agitated when questioned about her symptoms. Her temperature is elevated at 37.8 °C, her BP is 155/92 mmHg, with a RR of 25 and a pulse of 100/min.

Investigations:

Hb	13.2 g/dl
WCC	6.9 × 10^9/l
PLT	190 × 10^9/l
Na^+	141 mmol/l
K^+	5.1 mmol/l
Creatinine	130 µmol/l
Urea	13.2 mmol/l

Which of the following is the most likely diagnosis?

Your answer was correct

A Tardive dyskinesia

B Serotonin syndrome

C Tramadol toxicity

١٠:٠٣ ص
STC
MyPastest
https://mypastest.pastest.com

B Serotonin syndrome

Serotonin syndrome is characterised by agitation, hyperthermia, tachycardia, labile blood pressure, hyper-reflexia and increased tone. It may be caused by any of the drug classes that result in increased serotonin, e.g. selective serotonin reuptake inhibitors (SSRIs) or monoamine oxidase inhibitors, and symptoms usually occur in close proximity to initiation of one of these drugs. Removal of the causative agent and supportive therapy, which may include administration of benzodiazepines, are the mainstay of treatment. Some case reports suggest that non-specific serotonin antagonists such as chlorpromazine may be helpful in some cases. Symptoms usually resolve over a period of 24–36 h.

A Tardive dyskinesia

Tardive dyskinesia describes the rapid, involuntary facial movements, and sometimes limb movements, associated with typical antipsychotics, and to a lesser extent the atypical antipsychotics and the anti-emetic, metoclopramide. It does not usually present with an acute destabilisation of the patient's vital signs as in this vignette.

C Tramadol toxicity

This lady may have accidentally overdosed on an opiate medication such as tramadol for her back pains, but symptoms of opiate toxicity - including reduced respiratory rate and constricted pupils - are not described. Opiate overdose can cause agitation and euphoria, but usually results in reduced mentation and drowsiness. Opiate toxicity may be associated with a small drop in blood pressure rather than hypertension, and is not associated with pyrexia.

D Attention seeking behaviour

This patient is confused with unstable observations, deranged renal function and recent initiation of a new medication, making this diagnosis incorrect.

E Encephalitis

Encephalitis can present with altered mental state and pyrexia, and there may also be focal neurological signs such as seizure activity. The clue in this vignette is the proximity of her SSRI treatment to the development of her symptoms, making the diagnosis of serotonin syndrome more likely.

١٠:٠٤ ص
STC
MyPastest
https://mypastest.pastest.com

Pastes+

Question 10 of 20

A 53-year-old man with long-standing schizophrenia is referred by his GP after three fasting blood glucoses of 11.2, 17.3 and 9.2 mmol/l during the same month. He is taking a number of anti-psychotic and anti-depressive medications. On examination his BP is 142/74 mmHg and his BMI is 32. Other physical examination is unremarkable.

Calcu

Normal

Investigations:

Hb	12.9 g/dl
WCC	5.9×10^9/l
PLT	190×10^9/l
Na^+	140 mmol/l
K^+	4.7 mmol/l
Creatinine	110 µmol/l
Glucose	9.2 mmol/l

Which one of the following medications should be avoided in the management of his condition as it may worsen his glucose tolerance?

A	Citalopram
B	Risperidone
C	Olanzapine
D	Amytriptline
E	Fluoxetine

Submit

١٠:٠٧ ص
STC
MyPastest
https://mypastest.pastest.com

C	Olanzapine

Olanzapine as an atypical anti-psychotic which has been shown in studies to be associated with increasing risk of developing type 2 diabetes with increasing dose; this is related to weight gain, insulin resistance and subsequent impaired glucose tolerance. A large study of real-life use of olanzapine suggested it was associated with an odds ratio of 3.1 for the development of type 2 diabetes.

Reference: Differential effects of risperidone, olanzapine, clozapine, and conventional antipsychotics on type 2 diabetes: findings from a large health plan database. Frank D. Gianfrancesco, Amy L. Grogg, Ramy A. Mahmoud, Ruey-hua Wang, Henry A. Nasrallah. *J Clin Psychiatry* 2002; 63(10):920–30.

A	Citalopram

Although use of SSRIs may promote weight gain, this isn't as marked as the weight gain seen with agents such as olanzapine and isn't associated with dysglycaemia in the majority of cases.

B	Risperidone

In the same epidemiological analysis as that for olanzapine, the odds ratio for developing type 2 diabetes was 0.88. Clozapine appears to be associated with the highest risk of development of type 2 diabetes (OR 7.44).

D	Amytriptline

Tricyclic anti-depressants are usually considered when patients also have significant sleep disorder as they are sedating. They aren't recognised to cause increased risk of diabetes mellitus.

E	Fluoxetine

Like citalopram it isn't associated with increased risk of diabetes development.

70741
Rate this question:
Next Question

١٠:٠٧ ص
STC
MyPastest
https://mypastest.pastest.com

A 57-year-old man is brought to the Emergency Department by his wife. He tells you that he is already dead and is in hell, that he does not exist in this world.

His wife tells you that he barely eats, sleeps for long periods in the day and wakes in the early hours of the morning. She says he became preoccupied and very low in mood after some problems at work. Most recently, he had tried to jump out of the car whilst they were driving to the hospital.

On examination, he stares continuously at the floor, mumbling only that he is in hell, the devil is on him and he's already dead. He looks unkempt and as if he has not been taking good care of himself.

Investigations:

Hb	13.1 g/dl
WCC	4.5×10^9/l
PLT	201×10^9/l
Na^+	139 mmol/l
K^+	4.9 mmol/l
Creatinine	110 µmol/l
TSH	3.9 U/l

Which of the following treatments is most likely to be effective in this case?

A	Amitriptyline
B	Fluoxetine
C	Citalopram
D	ECT
E	Haloperidol

Calcu
Normal

١٠:١١ ص
STC
MyPastest
https://mypastest.pastest.com

A 57-year-old man is brought to the Emergency Department by his wife. He tells you that he is already dead and is in hell, that he does not exist in this world.

His wife tells you that he barely eats, sleeps for long periods in the day and wakes in the early hours of the morning. She says he became preoccupied and very low in mood after some problems at work. Most recently, he had tried to jump out of the car whilst they were driving to the hospital.

On examination, he stares continuously at the floor, mumbling only that he is in hell, the devil is on him and he's already dead. He looks unkempt and as if he has not been taking good care of himself.

Investigations:

Hb	13.1 g/dl
WCC	4.5 × 10^9/l
PLT	201 × 10^9/l
Na^+	139 mmol/l
K^+	4.9 mmol/l
Creatinine	110 µmol/l
TSH	3.9 U/l

Which of the following treatments is most likely to be effective in this case?

Your answer was correct

A	Amitriptyline
B	Fluoxetine
C	Citalopram
D	ECT

١٠:١٢ ص
STC
MyPastest
https://mypastest.pastest.com

C	Citalopram
D	ECT
E	Haloperidol

Explanation

D	ECT

This man has delusional depression, with features consistent with Cotard syndrome, where patients have a belief that they have actually died and no longer really exist. Symptoms consistent with severe depression include the early morning waking and daytime somnolence and his poor appetite. In delusional depression, tricyclic antidepressants, SSRIs and major tranquillisers are less successful than ECT, which in this patient is likely to have rapid, positive impact on his symptoms.

A	Amitriptyline

In delusional depression, amitriptyline as monotherapy is not usually considered effective; it may be more effective in relieving symptoms when combined with an anti-psychotic.

B	Fluoxetine

In this situation, SSRIs may be ill-advised because they increase agitation during the initial stages of therapy, thus potentially increasing the risk of suicide.

C	Citalopram

Like fluoxetine, citalopram is potentially best avoided in the initial stages of treatment for this patient because of the risk of increasing agitation.

E	Haloperidol

In the event that anti-psychotics are used to manage delusions in patients with this form of depression, they are usually combined with a second anti-depressant medication.

70742
Rate this question:

١٠:١٥ ص
STC
MyPastest
https://mypastest.pastest.com

A 32-year-old woman with a history of severe bipolar disorder treated with lithium is in the midst of an extended period of psychotic depression.

She tells you that she has thought about suicide and had begun drafting a suicide note, but threw it away the preceding week, and that she was considering a number of methods and had researched them on the Internet.

She does not want to be admitted and tells you she will try to be compliant with drug therapy.

Which of the following regimes for her would carry the least risk in overdose?

A	Lithium and fluoxetine
B	Lithium and sodium valproate
C	Lithium
D	Sodium valproate
E	Amitriptyline

70743

Submit

© Pastest 2019

١٠:١٨ ص STC

D	Sodium valproate
E	Amitriptyline

Explanation

D	Sodium valproate

Sodium valproate overdose is rarely fatal, with a case fatality rate of only around 0.2% in a US case series. CNS depression is seen with hypotension and lactic acidosis in severe overdose. Repeat-dose activated charcoal may be given and haemodialysis may be considered in patients with very high valproate levels.

A	Lithium and fluoxetine

Although lithium and fluoxetine given in combination may be very effective in treating refractory depression, lithium carries significant risk in overdose and should therefore be avoided here.

B	Lithium and sodium valproate

Taken together in overdose, lithium and sodium valproate carry significant risk, particularly with respect to synergistic effects on CNS depression.

C	Lithium

Even when used as monotherapy, lithium carries significant risk of CNS toxicity and renal impairment in acute overdose. Haemodialysis is considered when levels of lithium breach 4 mmol/l and there is evidence of renal impairment, or when levels breach 5 mmol/l, even in the absence of kidney disease.

E	Amitriptyline

A number of deaths occur each year due to tricyclic anti-depressant overdose, particularly when taken with alcohol. Metabolic acidosis, QT prolongation and ventricular arrhythmias are common sequelae.

70743

Rate this question:

Next Question

١٠:٢١ ص 4G STC

Calc

Norma

An 18-year-old woman is transferred from the Intensive Psychiatric Care Unit. She was admitted with a four-week history of auditory hallucinations and paranoid ideation. At the time of admission, she was verbally and physically aggressive, limiting any physical examination. She remained difficult to manage all that day and needed rapid tranquilisation.

Two days later, she was found to be pyrexial, with tachycardia and tachypnoea, and was transferred to the Medical Unit for further investigation.

The patient is drowsy and no history is available. On examination, core temperature is 40 °C, pulse 110/min regular, blood pressure labile. She has lead pipe rigidity in all four limbs. There is no meningism, no papilloedema and plantar responses are flexor.

Investigations:

Urea	12 mmol/l
WCC	15×10^9/l
Creatinine	155 µmol/l
PLT	700×10^9/l
CSF	Normal biochemistry, nil on Gram stain
Urine dipstick	Blood +++
Urinalysis	Nil
Chest X-ray	Clear lung fields

Blood cultures have been sent from the unit before her transfer.

What is the investigation most likely to contribute to making the diagnosis?

A	EEG
B	CT brain
C	Serum and urinary porphyrins
D	Serum CK
E	Serum amylase

70744

١٠:٢٣ ص
STC
MyPastest
https://mypastest.pastest.com

An 18-year-old woman is transferred from the Intensive Psychiatric Care Unit. She was admitted with a four-week history of auditory hallucinations and paranoid ideation. At the time of admission, she was verbally and physically aggressive, limiting any physical examination. She remained difficult to manage all that day and needed rapid tranquilisation.

Two days later, she was found to be pyrexial, with tachycardia and tachypnoea, and was transferred to the Medical Unit for further investigation.

The patient is drowsy and no history is available. On examination, core temperature is 40 °C, pulse 110/min regular, blood pressure labile. She has lead pipe rigidity in all four limbs. There is no meningism, no papilloedema and plantar responses are flexor.

Investigations:

Urea	12 mmol/l
WCC	15×10^9/l
Creatinine	155 µmol/l
PLT	700×10^9/l
CSF	Normal biochemistry, nil on Gram stain
Urine dipstick	Blood +++
Urinalysis	Nil
Chest X-ray	Clear lung fields

Blood cultures have been sent from the unit before her transfer.

What is the investigation most likely to contribute to making the diagnosis?

Your answer was correct

A	EEG
B	CT brain

Difficulty
Peer Res
A
B
C
D
E
0 20 40
Session
Responses Co
Responses Inc
Responses Tot
Responses - %

١٠:٢٣ ص
STC
MyPastest
https://mypastest.pastest.com

E Serum amylase

Explanation

D Serum CK

The most likely diagnosis here is neuroleptic malignant syndrome and subsequent rhabdomyolysis. This is most often associated with older neuroleptic agents, although it can be caused by any drug with dopamine antagonist properties. Treatment is supportive, with antipyretics, fluid resuscitation and autonomic monitoring. Bromocriptine is now thought to be of most value (and preferable to dantrolene) in severe cases. The laboratory results given are typical of developing rhabdomyolysis. The positive dipstick and negative urine microscopy are suggestive of myoglobinuria. Measurement of creatine kinase (CK) will help confirm the diagnosis.

A EEG

Although non-convulsive status may be a possibility, it is less likely than neuroleptic malignant syndrome given the other findings seen here, such as labile blood pressure and pyrexia.

B CT brain

CT brain may show cerebral oedema as a cause of decreased consciousness, but it won't reveal the underlying cause.

C Serum and urinary porphyrins

Acute intermittent porphyria presents with episodes of abdominal pain, hypertension and anxiety/agitation. The auditory hallucinations and paranoid ideation would be inconsistent with AIP, as would other signs such as the haematuria seen on dipstick.

E Serum amylase

The haematuria seen here on dipstick analysis and the absence of abdominal pain or vomiting are very inconsistent with a diagnosis of acute pancreatitis.

70744
Rate this question:

١٠:٢٣ ص STC

You assess a 74-year-old woman at the Neurology Clinic who has been referred with memory loss. The patient is a difficult historian, answering most questions with 'yes' or 'no'. You manage to elicit a story of subacute onset memory difficulty. The patient describes herself as 'stupid'. She further volunteers symptoms of intermittent headache, abdominal pain and insomnia.

There is a family history of ischaemic heart disease, and her sister has recently died from a myocardial infarction. The referral letter describes gradual social withdrawal, such that the patient has been refusing to attend the general practitioner's surgery. Her doctor is also concerned about poor appetite and gradual weight loss.

Physical examination, including BP of 135/82 mmHg and pulse of 75/min and regular, is unremarkable. Her BMI is 23. She does not comply with formal mental state testing.

What initial management is indicated?

A	Lithium
B	Aspirin, statin and ACE inhibitor
C	Donepezil
D	Therapeutic lumbar puncture
E	Citalopram

70745

Submit

١٠:٣١ ص
STC
MyPastest
https://mypastest.pastest.com

You assess a 74-year-old woman at the Neurology Clinic who has been referred with memory loss. The patient is a difficult historian, answering most questions with 'yes' or 'no'. You manage to elicit a story of subacute onset memory difficulty. The patient describes herself as 'stupid'. She further volunteers symptoms of intermittent headache, abdominal pain and insomnia.

There is a family history of ischaemic heart disease, and her sister has recently died from a myocardial infarction. The referral letter describes gradual social withdrawal, such that the patient has been refusing to attend the general practitioner's surgery. Her doctor is also concerned about poor appetite and gradual weight loss.

Physical examination, including BP of 135/82 mmHg and pulse of 75/min and regular, is unremarkable. Her BMI is 23. She does not comply with formal mental state testing.

What initial management is indicated?

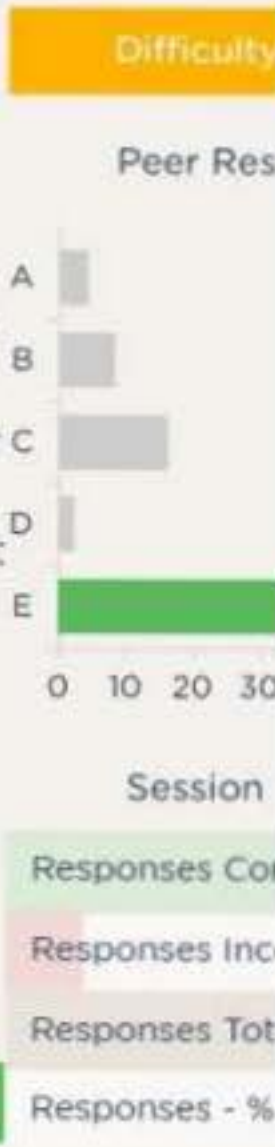

Your answer was correct

A	Lithium
B	Aspirin, statin and ACE inhibitor
C	Donepezil
D	Therapeutic lumbar puncture
E	Citalopram

Explanation

E Citalopram

Although the general practitioner was concerned about a neurodegenerative process, the clinical picture is more in keeping with a depressive 'pseudo-dementia'. Note the subjective complaint of memory loss, social withdrawal,

١٠:٣١ ص STC

Explanation

E	Citalopram

Although the general practitioner was concerned about a neurodegenerative process, the clinical picture is more in keeping with a depressive 'pseudo-dementia'. Note the subjective complaint of memory loss, social withdrawal, insomnia and poor appetite. There are a number of validated tools for measuring depression in the elderly. The Geriatric Depression Scale is often used in the UK. However, it has been shown that a simple question such as 'Are you depressed?' has a similar sensitivity for case detection. Exclusion of dementia with formal cognitive testing can be difficult. As shown in the above scenario, depressed patients may perform poorly for motivational reasons. In practice, if there is suspicion of depression, many clinicians will treat first and then reassess. There is no evidence of superiority of one anti-depressant in the elderly. The selective serotonin-reuptake inhibitor citalopram is often used because of an acceptable side effect profile and lack of interactions with other drugs. Secondary causes of depression should be considered. Alcohol and sedative use would be the most common; in a woman with disturbed sleep and weight gain, thyroid dysfunction should also be excluded.

A	Lithium

Lithium has a relatively unfavourable side effect profile in the elderly due to its narrow therapeutic range, potential nephrotoxicity and CNS depression. In the absence of evidence of bipolar disease versus depression alone, there is little to support its use.

B	Aspirin, statin and ACE inhibitor

Multi-infarct dementia presents with step-wise neurological deterioration, presumably due to discrete vascular events, rather than the gradual deterioration seen here. Hence, intensive management of cardiovascular risk factors isn't warranted in this case.

C	Donepezil

The refusal to comply with mental state testing rather than an established low score is more consistent with depression than dementia, although donepezil may be trialled if formal evidence of dementia is established later.

D	Therapeutic lumbar puncture

Therapeutic lumbar puncture is considered for patients with evidence of normal-pressure hydrocephalus who present with the triad of dementia, gait disturbance and urinary intoxication.

70745

Rate this question:

١٠:٣١ ص
STC
MyPastest
https://mypastest.pastest.com

Calculator

Normal Values

A 39-year-old woman presents to the First Seizure Clinic. She is accompanied by her community psychiatric nurse. The nurse provides a witness account of the attacks. Each episode has occurred in the community day hospital. The patient would fall to the floor screaming. She would then thrash around both her arms followed by her legs.

During the episodes, she is unresponsive, holding her eyes tightly shut. Afterwards, she is able to converse with staff in the centre. She has never injured herself, but often complains of headache post-event. The patient claims to have no memory of events.

Systems enquiry reveals no other symptoms.

Past medical history includes schizophrenia, well controlled on depot chlorpromazine. She is a lifetime smoker with mild airways disease. Physical examination reveals tar staining of fingers only.

Investigations:

Toxicology screen	Negative
Interictal electroencephalogram (EEG)	Formal report: 'Minor slowing of alpha waves, with increased voltage theta activity and diffuse fast activity'
Serum prolactin	900 IU/ml (59-619)

You reassure her that the seizures are unlikely to cause significant harm.

What other step would you advise?

A	Pregnancy testing
B	MRI pituitary fossa
C	Dynamic pituitary function testing
D	Lumbar puncture
E	Commence sodium valproate

Submit

١٠:٣٦ ص
STC
MyPastest
https://mypastest.pastest.com

A 39-year-old woman presents to the First Seizure Clinic. She is accompanied by her community psychiatric nurse. The nurse provides a witness account of the attacks. Each episode has occurred in the community day hospital. The patient would fall to the floor screaming. She would then thrash around both her arms followed by her legs.

During the episodes, she is unresponsive, holding her eyes tightly shut. Afterwards, she is able to converse with staff in the centre. She has never injured herself, but often complains of headache post-event. The patient claims to have no memory of events.

Systems enquiry reveals no other symptoms.

Past medical history includes schizophrenia, well controlled on depot chlorpromazine. She is a lifetime smoker with mild airways disease. Physical examination reveals tar staining of fingers only.

Investigations:

Toxicology screen	Negative
Interictal electroencephalogram (EEG)	Formal report: 'Minor slowing of alpha waves, with increased voltage theta activity and diffuse fast activity'
Serum prolactin	900 IU/ml (59-619)

You reassure her that the seizures are unlikely to cause significant harm.

What other step would you advise?

Your answer was correct

A	Pregnancy testing
B	MRI pituitary fossa
C	Dynamic pituitary function testing
D	Lumbar puncture
E	Commence sodium valproate

١٠:٣٦ ص STC
MyPastest
https://mypastest.pastest.com

Explanation

A	Pregnancy testing

The differentiation of true seizures from psychogenic non-epileptic seizures (NES) is challenging. It is usually detailed history from the patient and a witness, rather than laboratory testing, that will give the diagnosis. However, the gold standard investigation to confirm diagnosis is video-EEG recording of habitual events. In this scenario the story is highly suggestive of NES. Pointers to a 'non-organic' aetiology include rapid post-ictal recovery, bizarre limb movements and eye clenching, attacks in public places and lack of injury. Candidates should not be distracted by the interictal electroencephalogram (EEG) and prolactin results. The use of interictal EEG, especially in late-onset epilepsy, is limited by poor sensitivity and, to some degree, specificity. In this case the abnormalities detected would be in keeping with typical anti-psychotic use.

In this case other causes of raised prolactin which may influence the choice of anti-psychotic medication, namely pregnancy, should be excluded.

B	MRI pituitary fossa

The elevation in prolactin seen here is very modest, and MRI of the pituitary risks diagnostic confusion because of identification of an abnormality which may have nothing to do with the current presentation.

C	Dynamic pituitary function testing

Given the very modest increase in prolactin and absence of symptoms of pituitary dysfunction, dynamic pituitary function testing isn't indicated.

D	Lumbar puncture

There are no indications of an infective or inflammatory cause for these episodes, meaning that lumbar puncture is not of value here.

E	Commence sodium valproate

Given that these are most likely non-epileptic seizures, there is no value in using sodium valproate in this patient. It may actually lead to adverse effects on her behaviour in the context of previous psychiatric illness.

A 23-year-old computer engineer presents to his GP with symptoms suggestive of a mixed anxiety-depression disorder. His GP prescribes fluoxetine 20 mg daily and alprazolam 0.25 mg per day. The following day, the patient presents to the Emergency Department accompanied by his mother. She explains that he has become unduly euphoric and hyperactive.

On examination, he appeared confused and had frequent sudden, brief jerking in various parts of his body. On further questioning about his drug history, he admitted to self-medication with St John's wort as well as his prescribed medication. He brings a urine specimen to the Emergency Department which is positive for blood.

Which of the following is the most likely diagnosis?

A	Serotonin syndrome
B	Myoclonic epilepsy
C	Neuroleptic malignant syndrome
D	Psychogenic non-epileptic seizures
E	Bipolar disorder

Calculato
Normal Va
70747
Submit
Previous Q...
Skip Questi...
Blog About Pastest Contact Us Help
© Pastest 2019

١٠:٥٠ ص STC
MyPastest
https://mypastest.pastest.com

E Bipolar disorder

Explanation

A Serotonin syndrome

This patient has serotonin syndrome, an uncommon but potentially fatal complication of selective serotonin re-uptake inhibitors (SSRIs) especially when combined with other serotonin-enhancing agents, including tricyclic antidepressants, monoamine oxidase inhibitors and the herbal treatment St John's wort (hypericum). It develops over hours with characteristic hypomania, drowsiness, myoclonus, hyperthermia and pronounced autonomic symptoms (the 'happy drunk' state). It may resemble the neuroleptic malignant syndrome. Hyper-reflexia, not hyporeflexia, is typical. Conjunctival haemorrhage is not a typical feature. Support with IV fluid rehydration, and treatment of symptoms of anxiety with benzodiazepines are the therapies of choice.

B Myoclonic epilepsy

Myoclonic epilepsy presents for the first time in teenagers, and in the presence of potential precipitating factors such as use of SSRI and St John's wort, serotonin syndrome should be excluded first.

C Neuroleptic malignant syndrome

Neuroleptic malignant syndrome occurs in patients exposed to dopamine antagonists, rather than SSRIs.

D Psychogenic non-epileptic seizures

The discrete episodes of brief limb jerking coupled with confusion are more consistent with actual, rather than non-epileptic, seizures.

E Bipolar disorder

Bipolar disorder is associated with fluctuations between depression and hypomania/mania; the presentation here with intermittent seizures is inconsistent with bipolar disorder.

70747
Rate this question:
Next Question

Calculat

Normal Va

An 18-year-old man is admitted to Accident and Emergency after collapsing in a night club. He is drowsy but oriented and able to answer questions. This was his first week at university and he had decided to go out to a night club with his friends. He was given some 'tablets' in the night club to make him more relaxed and he was advised to drink a lot of fluids. All he remembers was that he went onto the dance floor and everything blacked out. When he came round, he was lying on the floor with people standing all around him and then he was brought to the hospital.

On examination, his temperature was 37.1 °C, blood pressure was 140/85 mmHg and his pulse was 104 bpm and regular. Apart from being slightly drowsy, his neurological examination was essentially normal.

Investigations:

Hb	12.0 g/dl
WCC	5.0×10^9/l
PLT	200×10^9/l
Na^+	123 mmol/l
K^+	3.2 mmol/l
Creatinine	67 µmol/l
Urea	1.8 mmol/l
MCV	90 fl

What is the most appropriate step in the immediate management of this patient?

A	Restrict fluid intake
B	Give dantrolene 1 mg/kg IV
C	IV hypertonic saline
D	Metoprolol 5-10 mg IV
E	Diazepam 0.1-0.3 mg/kg PO

Submit

١٠:٥٨ ص
STC
MyPastest
https://mypastest.pastest.com

An 18-year-old man is admitted to Accident and Emergency after collapsing in a night club. He is drowsy but oriented and able to answer questions. This was his first week at university and he had decided to go out to a night club with his friends. He was given some 'tablets' in the night club to make him more relaxed and he was advised to drink a lot of fluids. All he remembers was that he went onto the dance floor and everything blacked out. When he came round, he was lying on the floor with people standing all around him and then he was brought to the hospital.

On examination, his temperature was 37.1 °C, blood pressure was 140/85 mmHg and his pulse was 104 bpm and regular. Apart from being slightly drowsy, his neurological examination was essentially normal.

Investigations:

Hb	12.0 g/dl
WCC	5.0 × 10^9/l
PLT	200 × 10^9/l
Na^+	123 mmol/l
K^+	3.2 mmol/l
Creatinine	67 µmol/l
Urea	1.8 mmol/l
MCV	90 fl



What is the most appropriate step in the immediate management of this patient?

Your answer was correct

A	Restrict fluid intake
B	Give dantrolene 1 mg/kg IV
C	IV hypertonic saline
D	Metoprolol 5-10 mg IV
E	Diazepam 0.1-0.3 mg/kg PO

Explanation

A Restrict fluid intake

١٠:٥٨ ص
STC
MyPastest
https://mypastest.pastest.com

E	Diazepam 0.1-0.3 mg/kg PO

Explanation

A	Restrict fluid intake

Ecstasy is the common usage name for 3,4-methylenedioxymethamphetamine, which is a psychoactive drug. It is a class A drug and is illegal in the UK. It is commonly used at dance parties and changes the mood through its effects on dopaminergic and serotoninergic pathways. It has a short duration of action of about 4-6 h and is usually ingested in a dose of 75-150 mg orally.

Its effects are said to relax the users and make them more friendly to other people. Its side effects are unpredictable and include: nausea, sweating, hypertension, tachycardia, disseminated intravascular coagulation and liver failure. Deaths have been reported from heat stroke and water intoxication.

In this case, given the serum sodium, it is water intoxication which is the likely problem and fluid restriction is the intervention of choice.

B	Give dantrolene 1 mg/kg IV

Dantrolene was formerly used as a treatment for malignant hyperthermia, although now anti-cholinergics are the usual preferred intervention of choice.

C	IV hypertonic saline

Hypertonic saline is not required, given this patient's normal current neurological status. Only in the event that there was significant CNS depression with seizures would hypertonic saline, given in the ITU environment, be considered.

D	Metoprolol 5-10 mg IV

Metoprolol is only required in the event of significant hypertension or SVT related to ecstasy use. It isn't therefore required here.

E	Diazepam 0.1-0.3 mg/kg PO

This is the appropriate intervention where there is significant agitation or seizures associated with ecstasy use.

١٠:٥٩ ص
STC
MyPastest
https://mypastest.pastest.com

A 34-year-old builder is admitted with an acute inferior myocardial infarction and is immediately sent for percutaneous coronary intervention (PCI). His risk factors for ischaemic heart disease include smoking 40 cigarettes a day and hypercholesterolaemia. He is a heavy drinker but denies any illicit drug use.

The following day, he becomes anxious, tachycardic and sweaty. His BP is 155/72 mmHg, with pulse 105 and regular. Although his ECG shows no new ischaemic changes, there is a lot of baseline interference due to the development of a tremor.

What is the appropriate next step in his management?

A	Return to the catheter lab
B	IV fluid loading
C	IV metoprolol
D	IV thrombolysis
E	Reducing course of oral benzodiazepines

Calculato
Normal Va
70752
Submit
Previous Q...
Skip Questi...
Blog About Pastest Contact Us Help
© Pastest 2019

١١:٠٢ ص 4G STC

C	IV metoprolol
D	IV thrombolysis
E	Reducing course of oral benzodiazepines

Explanation

E	Reducing course of oral benzodiazepines

The most likely diagnosis, given this patient's admission of significant alcohol consumption, is alcohol withdrawal. As such, the most appropriate intervention, with signs of anxiety and sympathetic activation, is a reducing course of oral benzodiazepines.

A	Return to the catheter lab

Given there is no evidence of new ischaemia with an ECG showing now new changes, there is no reason to return to the catheter lab.

B	IV fluid loading

IV fluid loading is optimal with respect to maintaining right ventricular filling pressure. Given that BP is well preserved here at 155/72, and there are no new ECG changes, there isn't an indication for fluid loading.

C	IV metoprolol

Given that blood pressure is maintained with a pulse modestly increased to 105/min, and there are no indications of new ischaemia, there is no indication for IV metoprolol.

D	IV thrombolysis

In the absence of new ischaemia, there is no reason to move to IV thrombolysis.

70753

Rate this question:

Next Question

Previous Q... Tag Questi... Feedback End Session

STC

A 37-year-old man known to be in the early stages of Huntington's disease is admitted to the Emergency Department by ambulance. His wife found him unconscious on the floor with an empty bottle of codeine phosphate at his side. He had left a suicide note and on further questioning his wife admits that her husband has been depressed for a few weeks.

Calculato

Normal Va

On examination, his Glasgow Coma Scale (GCS) score is 7, with a respiratory rate of 10/min and BP of 100/60 mmHg.

Investigations:

pH	7.25
pO_2	6.8 kPa
pCO_2	7.5 kPa

Which of the following represents the most appropriate management in this case?

A	Ask his wife to decide whether he is to be treated
B	Make a decision that he has a terminal illness and should not be treated
C	Ask your senior to rule on whether resuscitation is appropriate
D	Contact the hospital solicitor to rule with respect to resuscitation
E	Treat with IV naloxone

7/071

Submit

Previous Q...

Skip Questi...

١١:٠٤ ص
STC
MyPastest
https://mypastest.pastest.com

E Treat with IV naloxone

Explanation

E Treat with IV naloxone

Depression is common in the early stages of Huntingdon's and responds very well to treatment. His wife has given a reliable history that he was depressed at the time of the overdose and, as such, he was not able to make a rational decision to end his life. As such, given the fact that you must act in his best interests, naloxone is the only appropriate next step.

A Ask his wife to decide whether he is to be treated

Although it is desirable to reach agreement with the patient's wife, the final decision to treat rests with you as his doctor. Given the history of depression, you should consider that the overdose was not taken against a background of rational decision making.

B Make a decision that he has a terminal illness and should not be treated

Given the history of depression, you cannot conclude that he made a rational decision to take an overdose of codeine.

C Ask your senior to rule on whether resuscitation is appropriate

This patient has severe respiratory depression, and is at risk of aspiration and type 2 respiratory failure. As such, it's inappropriate to wait for advice from your senior and you should instigate therapy.

D Contact the hospital solicitor to rule with respect to resuscitation

This risks an unacceptable delay, and the view of the solicitor is highly unlikely to be at variance from the need to treat in this patient's best interests.

7/371
Rate this question:
Next Question
Previous Q... Tag Questi... Feedback End Session

١١:٠٥ ص
STC
MyPastest
https://mypastest.pastest.com

A 66-year-old man presents to the clinic with his wife. He was started on a selective serotonin-reuptake inhibitor (SSRI) antidepressant 2 weeks ago because of severe depression. His depression appeared to have been triggered by the death of his pet dog, which he had for 15 years.

His wife complains that she has not seen any improvement in the 2 weeks he had been on the anti-depressant, and is further worried by the pronouncement in the press that there is an increased suicide rate among patients taking SSRIs.

How would you best advise this couple?

A	He should continue the SSRI
B	He should discontinue the SSRI
C	He should swap the SSRI for a tricyclic anti-depressant
D	There is no increased suicide rate amongst patients taking SSRIs
E	He should proceed to ECT

Calculato

Normal Va

71072

Submit

Previous Q...

© Pastest 2019

١١:٠٦ ص
STC
MyPastest
https://mypastest.pastest.com

C	He should swap the SSRI for a tricyclic anti-depressant
D	There is no increased suicide rate amongst patients taking SSRIs
E	He should proceed to ECT

Explanation

A	He should continue the SSRI

It is likely that a steady improvement in this patient's symptoms of depression will occur over the next 1-2 weeks. Although increased agitation may be seen, and this is associated with increased risk of suicide, it is usually seen in the first 2 weeks of treatment, and predominantly in adolescents who are treated with SSRIs.

B	He should discontinue the SSRI

There is no reason to discontinue the SSRI given that this patient's mood is likely to improve significantly over the next 1-2 weeks.

C	He should swap the SSRI for a tricyclic anti-depressant

Swapping to a different class of anti-depressant is not appropriate. It's important to counsel the patient and his wife that improvement is likely over the next 1-2 weeks.

D	There is no increased suicide rate amongst patients taking SSRIs

There may be an increase in suicide rate amongst patients under the age of 18 who are prescribed SSRIs.

E	He should proceed to ECT

ECT or swapping to an alternative anti-depressant such as an SNRI is the obvious next step, in the event that there is no improvement over the next 1-2 weeks.

71072
Rate this question:
End Session

٩:٣٥ 2G 2G
mypastest.pastest.com

A 24-year-old woman presents to the Emergency Department with sudden painless loss of vision affecting the upper portion of vision out of her right eye. She suffered a deep vein thrombosis (DVT) at age 18, but has no other significant past medical history.

An image of her right retina is shown below.

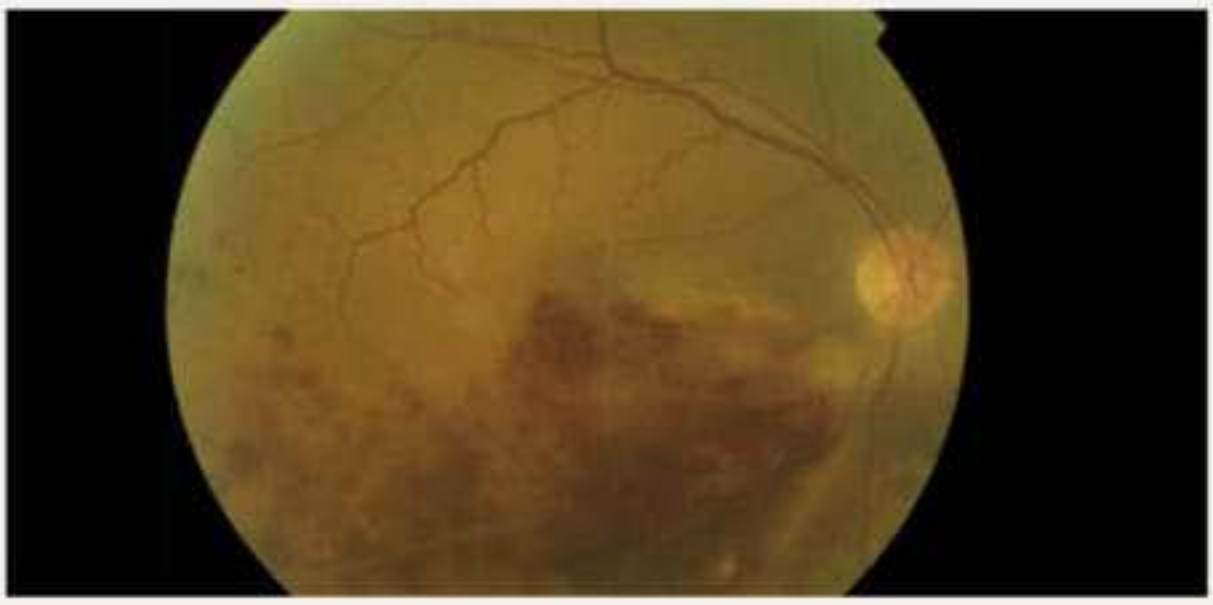

Her blood pressure is 132/82 mmHg, pulse is 88 bpm and regular, body mass index (BMI) is 24 kg/m^2.

Which of the following is the most appropriate intervention to prevent further acute episodes of vision loss?

A	Aspirin
B	Clopidogrel
C	High-dose atorvastatin
D	Intravitreal triamcinolone
E	Warfarin

71593

Submit

٩:٣٨ 2G 3G
mypastest.pastest.com

A 24-year-old woman presents to the Emergency Department with sudden painless loss of vision affecting the upper portion of vision out of her right eye. She suffered a deep vein thrombosis (DVT) at age 18, but has no other significant past medical history.

An image of her right retina is shown below.

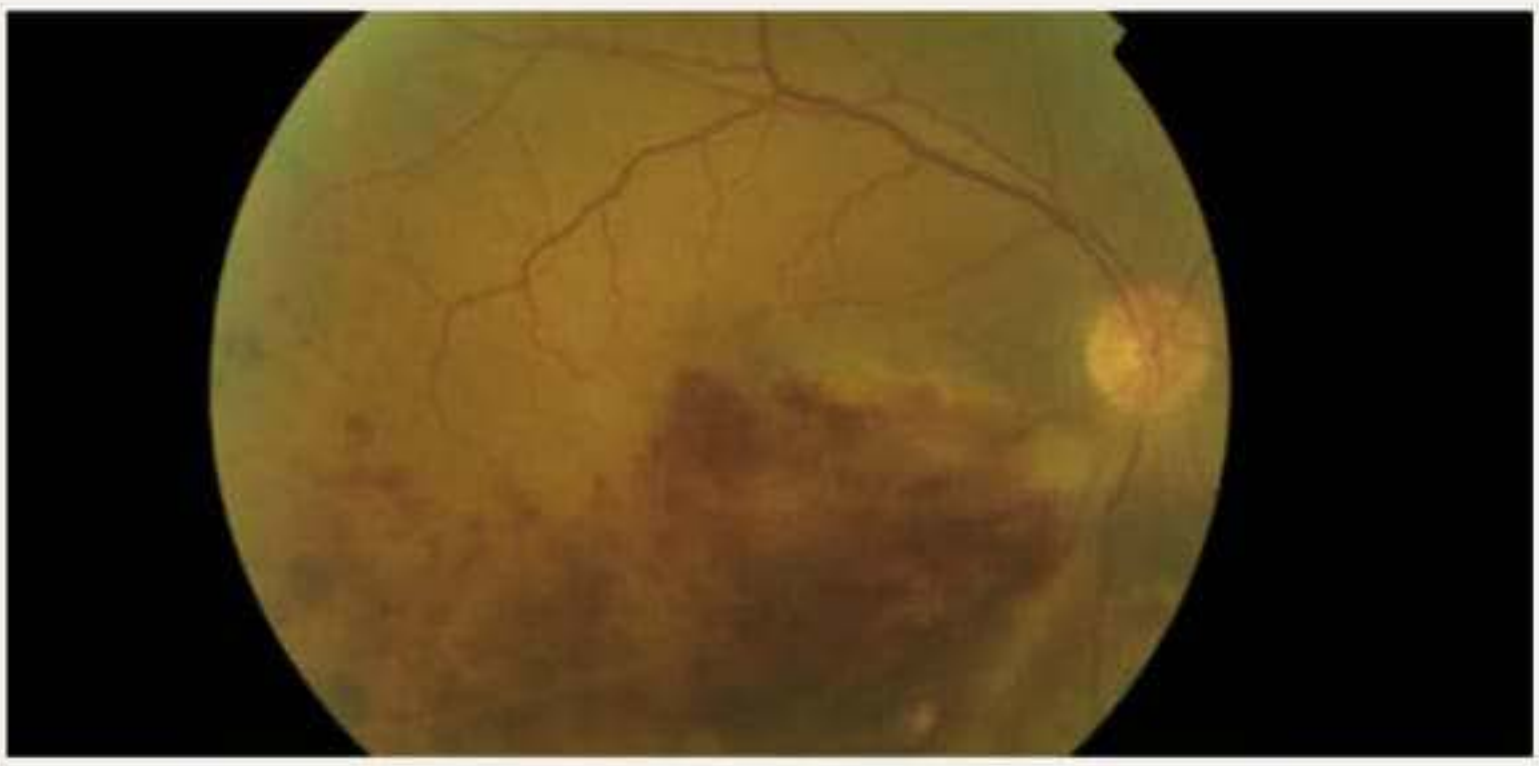

Her blood pressure is 132/82 mmHg, pulse is 88 bpm and regular, body mass index (BMI) is 24 kg/m^2.

Which of the following is the most appropriate intervention to prevent further acute episodes of vision loss?

A	Aspirin
B	Clopidogrel
C	High-dose atorvastatin
D	Intravitreal triamcinolone
E	Warfarin

Explanation

٩:٣٨ 2G 3G

E	Warfarin

This patient has branch retinal vein occlusion (BRVO), and the previous history of DVT in a young woman with no obvious risk factors raises the possibility of underlying thrombophilia. Assuming the thrombophilia screen is positive, then long-term warfarin therapy is indicated.

A	Aspirin

Antiplatelet therapy is ineffective in preventing further episodes of thrombosis in patients with thrombophilia.

B	Clopidogrel

Like aspirin, clopidogrel is not effective in preventing further episodes of venous thrombosis in patients with thrombophilia.

C	High-dose atorvastatin

High-dose atorvastatin reduces low-density lipoproteins (LDL) and triglycerides but, in this situation, would have no impact on the risk of further thrombotic episodes.

D	Intravitreal triamcinolone

Triamcinolone is a treatment option for patients with macular oedema, which is seen after retinal vein occlusion, although it has no impact on the risk of future thrombosis.

71593

Rate this question:

Next Question

٩:٣٩ 2G 3G

A 56-year-old man, who has had type 1 diabetes for 40 years, comes to the Emergency Department with blurring of vision affecting his right eye.

His most recent HbA1c is 69 mmol/mol and his blood pressure is 155/90 mmHg.

A retinal photograph of the right eye is shown below.

Which of the following is the most appropriate next intervention?

A	Focal laser therapy
B	Intensive insulin therapy
C	Intravitreal corticosteroids
D	Pan-retinal photocoagulation
E	Vitrectomy

71582

Submit

٩:٤١ 2G 3G

A 56-year-old man, who has had type 1 diabetes for 40 years, comes to the Emergency Department with blurring of vision affecting his right eye.

His most recent HbA1c is 69 mmol/mol and his blood pressure is 155/90 mmHg.

A retinal photograph of the right eye is shown below.

Which of the following is the most appropriate next intervention?

Your answer was correct

A	Focal laser therapy
B	Intensive insulin therapy
C	Intravitreal corticosteroids
D	Pan-retinal photocoagulation
E	Vitrectomy

Explanation

٩:٤١ 2G 3G

A	Focal laser therapy

This patient has a circinate of hard exudates adjacent to the macula, an indication of macular oedema. The duration of diabetes, poor glycaemic control and blurring of vision fit well with the diagnosis. Both focal laser therapy and anti-VEGF therapy are potential options for intervention to reduce the risk of vessel leakage/haemorrhage occurring. There is little difference between the two in terms of outcomes, although focal laser therapy is the National Institute for Health and Care Excellence (NICE) preferred intervention.

B	Intensive insulin therapy

Intensive insulin therapy can significantly worsen retinopathy in the short term, although over a longer period of follow-up, tighter glycaemic control can reduce the risk of new retinopathy events.

C	Intravitreal corticosteroids

Although intravitreal corticosteroids do reduce macular oedema in the short term, over the long term, outcomes may be less favourable versus laser therapy or anti-VEGF treatment.

D	Pan-retinal photocoagulation

Pan-retinal photocoagulation is considered for more extensive retinopathy; in this case, the pressing problem is the macular oedema, for which local laser therapy is more appropriate.

E	Vitrectomy

Vitrectomy is considered after vitreous haemorrhage occurring as a result of proliferative diabetic retinopathy.

71582

Rate this question:

An 82-year-old man presents to the Emergency Department with sudden loss of vision affecting the upper field of vision of his left eye. He says it came on suddenly and he is now having difficulty perceiving even light and dark in the upper field of vision. He suffered an anterior myocardial infarction some four years ago, and currently takes oral aspirin with a number of antihypertensive agents and a statin.

Over the past few months, he has suffered increasingly frequent temporal headaches for which he has self-medicated with paracetamol and ibuprofen. His blood pressure is 163/95 mmHg and his pulse is 85 bpm and regular. He is tender over both temporal arteries.

An image of his eye is shown below.

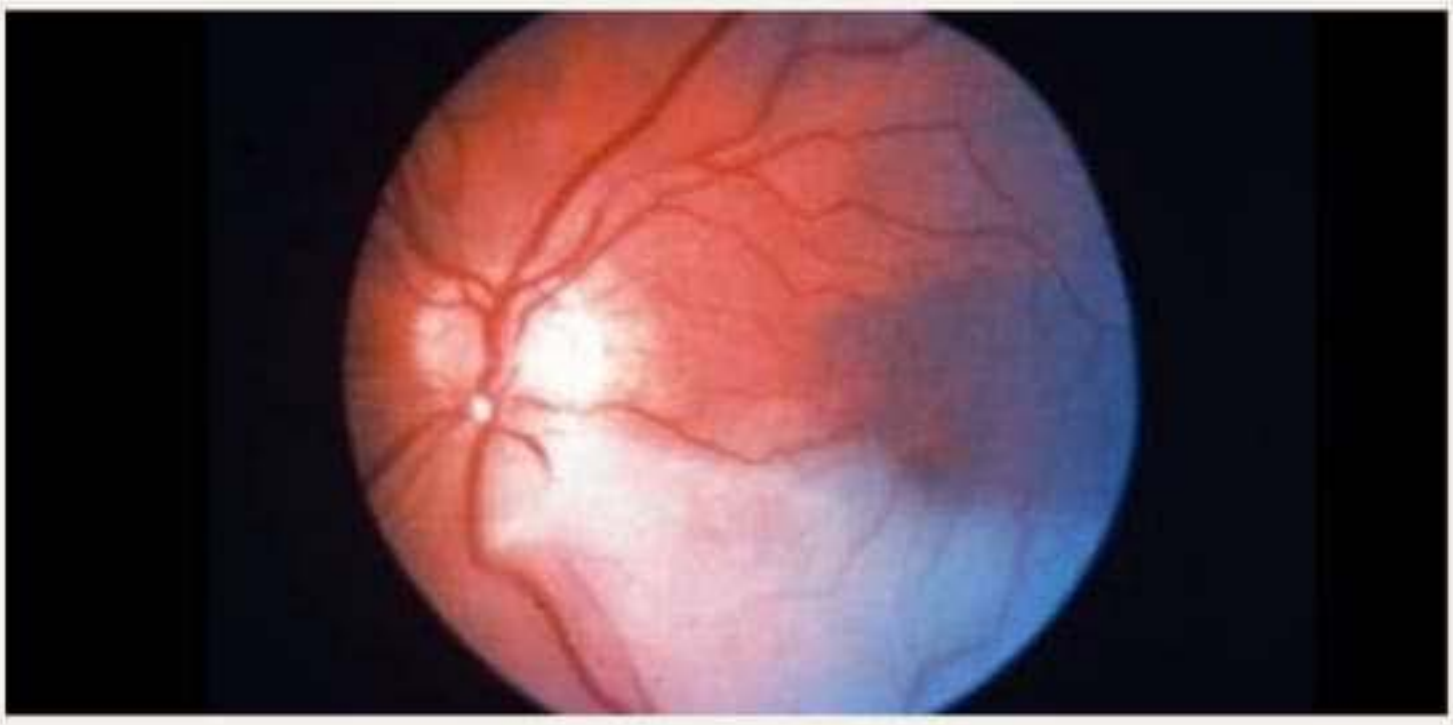

Which of the following is the most appropriate intervention to prevent further vascular events?

A	Azathioprine
B	Carotid endarterectomy
C	Clopidogrel
D	Methylprednisolone
E	Rivaroxaban

D	Methylprednisolone

This patient's symptoms with temporal artery headache, painless visual loss and evidence of branch retinal artery occlusion are consistent with temporal arteritis. Intravenous (IV) methylprednisolone is the intervention of choice because of the visual symptoms and this can be converted to oral therapy with prednisolone after a few days.

A	Azathioprine

Azathioprine is a potential steroid-sparing agent in temporal arteritis, although it is not used as initial monotherapy for the condition.

B	Carotid endarterectomy

Where branch retinal artery occlusion has occurred against a background of significant carotid stenosis then endarterectomy should be considered, although it is not of value here where temporal arteritis is the most likely cause.

C	Clopidogrel

Although antiplatelet agents do reduce the risk of acute cardiovascular events, they do not reduce the risk of vascular events in the context of temporal arteritis and should therefore not be used as an alternative to steroid therapy.

E	Rivaroxaban

Rivaroxaban is an anticoagulant which is effective in reducing the risk of embolic events associated with coagulation disorders or atrial fibrillation, but not where temporal arteritis is the underlying cause.

٩:٤٨ 3G 3G

A 22-year-old woman presents to the Emergency Department with sudden-onset, painless visual loss affecting her right eye. She awoke from sleep to find that she could not perceive more than light or dark and was unable to drive to work because of this.

She no past medical history of note. She is anxious and has a blood pressure of 134/89 mmHg; her pulse is 72 bpm and regular.

A picture of her right retina is shown below.

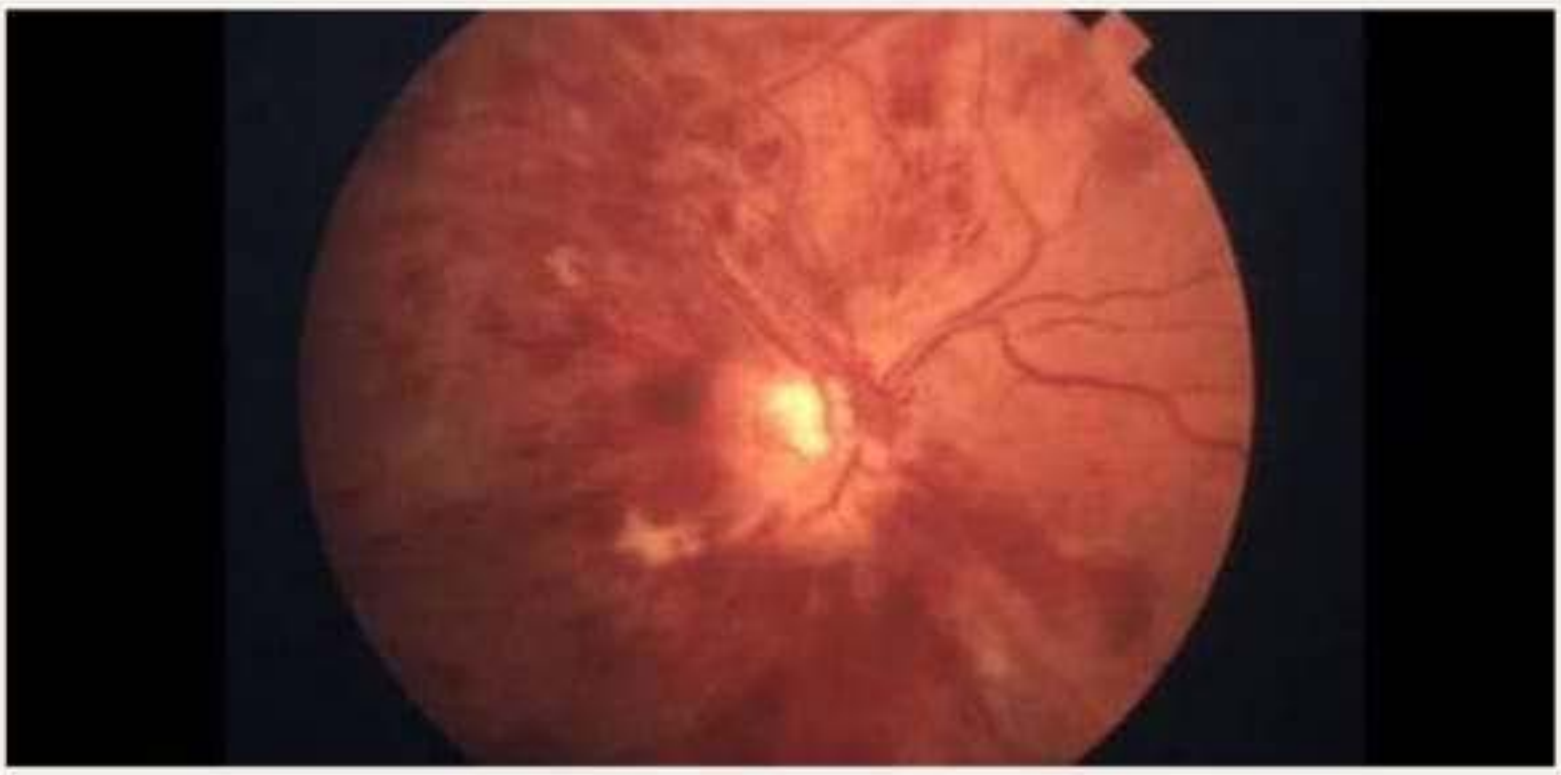

Investigation reveals that she has protein C deficiency.

Which of the following is the most appropriate long-term step to manage thrombosis risk in this patient?

A	Aspirin and clopidogrel for six months
B	Lifelong clopidogrel
C	Aspirin and low-molecular-weight heparin for six months
D	Lifelong warfarin
E	Rivaroxaban for six months

٩:٥٢ 3G 3G
mypastest.pastest.com

A 22-year-old woman presents to the Emergency Department with sudden-onset, painless visual loss affecting her right eye. She awoke from sleep to find that she could not perceive more than light or dark and was unable to drive to work because of this.

She no past medical history of note. She is anxious and has a blood pressure of 134/89 mmHg; her pulse is 72 bpm and regular.

A picture of her right retina is shown below.

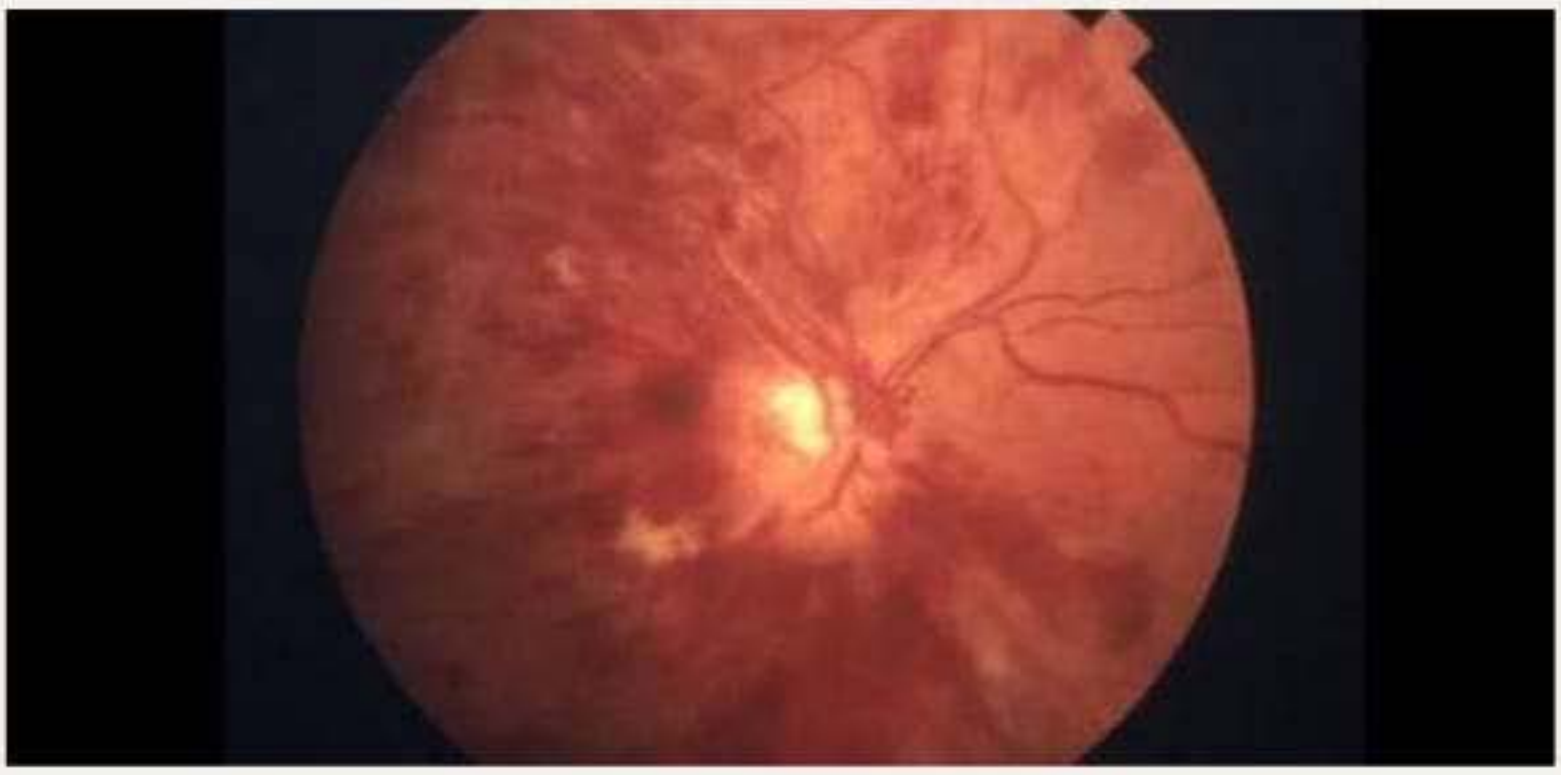

Investigation reveals that she has protein C deficiency.

Which of the following is the most appropriate long-term step to manage thrombosis risk in this patient?

Your answer was incorrect

A	Aspirin and clopidogrel for six months
B	Lifelong clopidogrel
C	Aspirin and low-molecular-weight heparin for six months

A
B
C
D
E
O
Re
Re
Re
Re

D	Lifelong warfarin

This patient has had a sight-threatening central retinal vein occlusion (CRVO) and protein C deficiency. As such, lifelong warfarin therapy is indicated as the next step. The other options listed here carry too much risk for a further venous thrombosis occurring.

E	Rivaroxaban for six months

Anticoagulation for six months is inadequate; given the central retinal vein thrombosis, the chance of a further clot occurring post-discontinuation of anticoagulation is very high. Lifelong use of a direct oral anticoagulation, such as rivaroxaban, could be used, instead of warfarin, however.

A	Aspirin and clopidogrel for six months

Antiplatelet therapy is ineffective in preventing venous thrombosis. Dual antiplatelet therapy is usually indicated post-coronary artery stenting.

B	Lifelong clopidogrel

Single antiplatelet therapy with clopidogrel is not effective in preventing venous thrombosis. It is usually considered for ischaemic stroke prevention.

C	Aspirin and low-molecular-weight heparin for six months

Aspirin and low-molecular-weight heparin is the intervention of choice for the prevention of miscarriage and venous thrombosis in patients who are pregnant and have a history of systemic lupus erythematosus (SLE) or antiphospholipid antibody syndrome.

٩:٥٢ 3G 3G

A 35-year-old woman comes to the Emergency Department with steadily worsening headaches over the last three months. The headaches are worse in the morning, when she lies flat and when she coughs or strains. They are often accompanied by short-lived episodes of blurred vision.

Her blood pressure is 149/89 mmHg, pulse is 70 bpm and regular. Her body mass index (BMI) is 35 kg/m^2.

An image of the right retina is shown below.

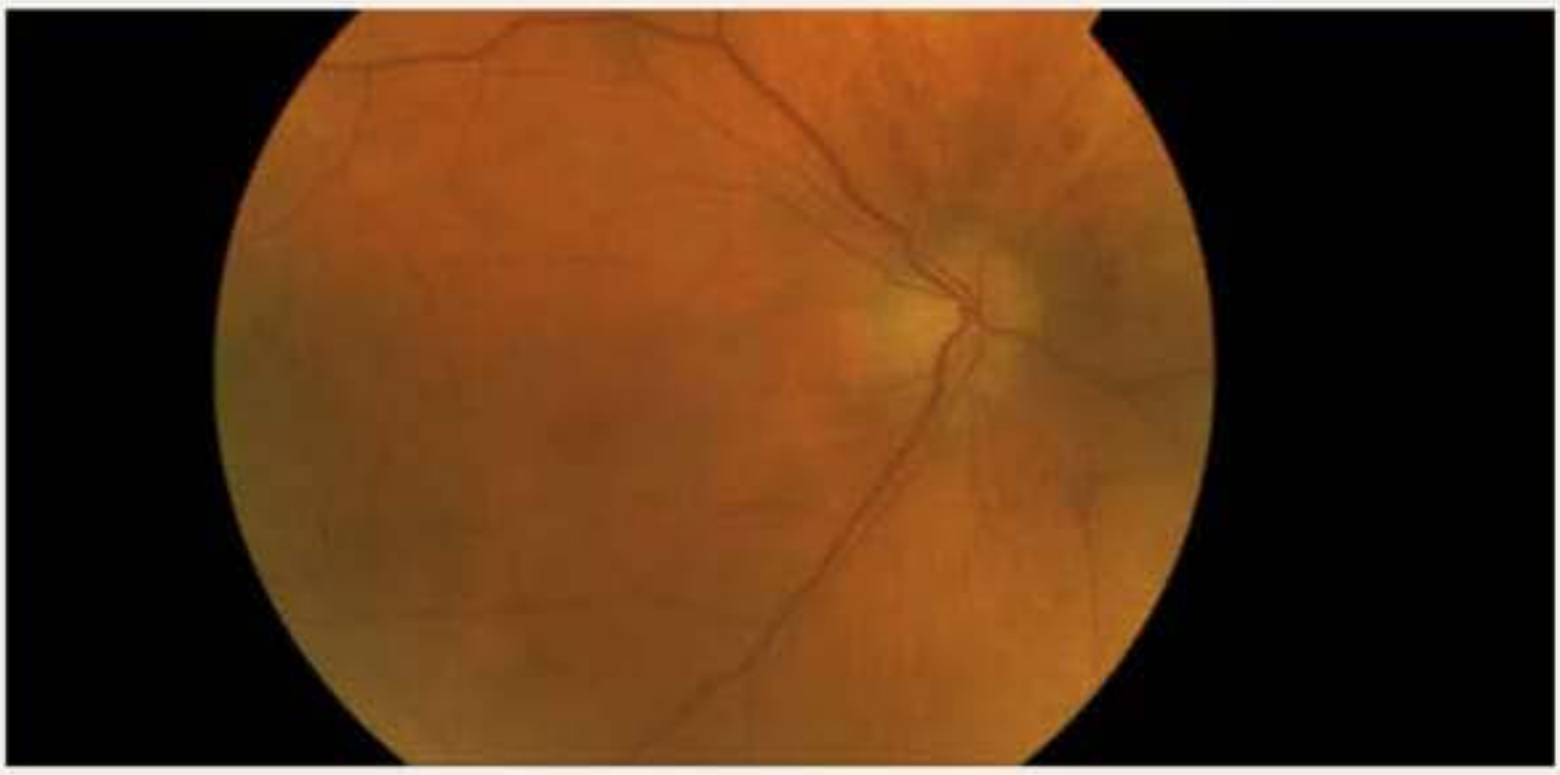

The left has a similar appearance.

Which of the following is the most likely diagnosis?

A	Atypical migraine
B	Normal pressure hydrocephalus (NPH)
C	Idiopathic intracranial hypertension (IIH)
D	Subdural haematoma
E	Tension headache

٩:٥٧ 3G 3G

C	Idiopathic intracranial hypertension (IIH)

IIH is more common in obese young women, and it fits with the headaches which are symptomatic of raises in intracranial pressure. The optic disc is blurred, which is consistent with papilloedema. Imaging to rule out a space-occupying lesion and cerebral venous sinus thrombosis is the most important next step. Following this, a lumbar puncture should be performed to measure cerebrospinal fluid (CSF) opening pressure, which has short-term therapeutic benefits if the closing pressure is reduced.

A	Atypical migraine

Atypical migraine is generally associated with unilateral headache and nausea, rather than the presentation here with positional headaches much more suggestive of IIH.

B	Normal pressure hydrocephalus (NPH)

NPH occurs in the elderly and is associated with dementia, incontinence and gait disturbance, rather than the presentation seen here.

D	Subdural haematoma

A subdural haematoma does present with headaches, but it is more likely to be associated with fluctuating consciousness and/or focal neurological signs. Subdural haematomas are more commonly seen in alcoholics and elderly patients prescribed anticoagulant or antiplatelet therapy.

E	Tension headache

Tension headaches are usually associated with frontal/bitemporal headaches and are not positional or made worse by activities which increase intracranial pressure.

٩:٥٧ 4G 3G

A 35-year-old woman comes to the Emergency Department with steadily worsening headaches over the last three months. The headaches are worse in the morning, when she lies flat and when she coughs or strains. They are often accompanied by short-lived episodes of blurred vision.

Her blood pressure is 149/89 mmHg, pulse is 70 bpm and regular. Her body mass index (BMI) is 35 kg/m^2.

An image of the right retina is shown below.

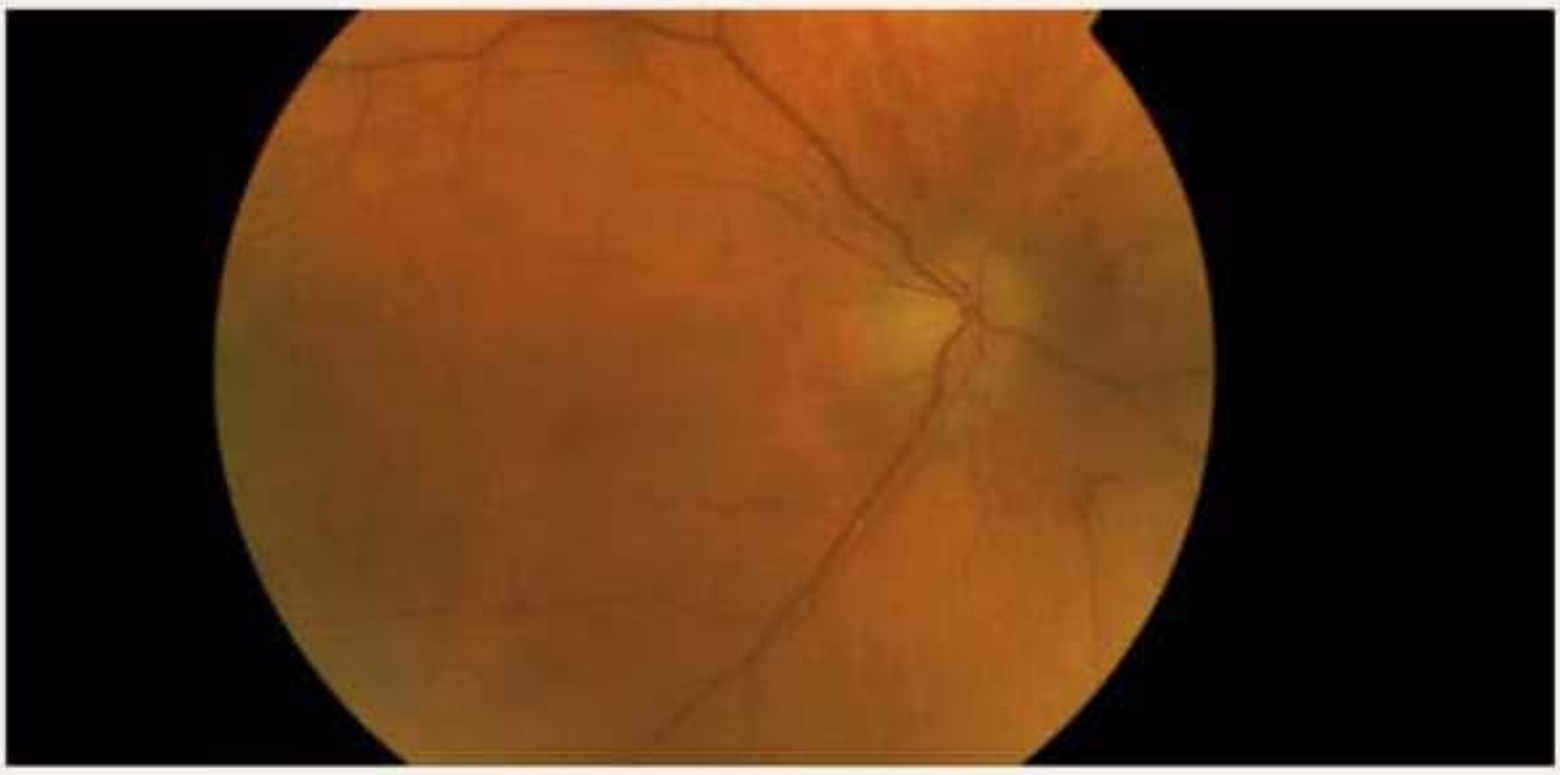

The left has a similar appearance.

Which of the following is the most likely diagnosis?

Your answer was correct

A	Atypical migraine
B	Normal pressure hydrocephalus (NPH)
C	Idiopathic intracranial hypertension (IIH)
D	Subdural haematoma
E	Tension headache

A 38-year-old city worker presents to the Emergency Department with a severe frontal headache, nausea and vomiting which has built up over the past week. On further questioning, he admits to worsening headaches over the past two to three months.

On examination, his blood pressure is 210/100 mmHg, pulse is 85 bpm and regular. His body mass index (BMI) is 23 kg/m^2 and there are no masses on palpation of the abdomen. His creatinine is elevated at 189 µmol/l.

A retinal photograph is shown below.

Which of the following is the most appropriate intervention?

A	Intravenous (IV) sodium nitroprusside
B	Oral amlodipine
C	Oral bendroflumethiazide
D	Oral ramipril
E	Sublingual nifedipine

١٠:٠٢ 4G 3G

Calculat

Normal Va

A 65-year-old overweight Asian woman was referred to Ophthalmology Outpatients with general malaise and a gradual reduction in vision of three months' duration, affecting both eyes.

Aided Snellen visual acuity was recorded as 6/18 right eye, 6/12 left eye, both eyes improving to 6/9 with a pinhole. Dilated examination revealed bilateral, moderate nuclear sclerosis, and widespread retinal changes as shown below.

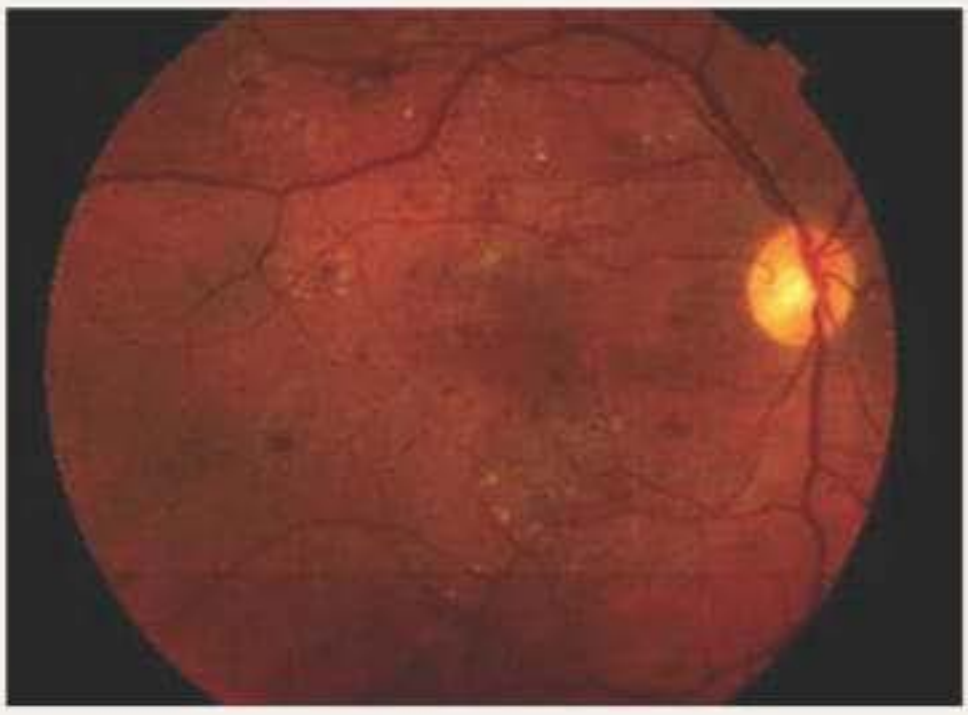

Her lipids were checked by her general practitioner (GP) four months before:

Cholesterol	6 mmol/l
HDL	0.79 mmol/l
LDL	4.0 mmol/l
Fasting triglycerides	4.6 mmol/l

Which of the following is the most likely underlying diagnosis?

A	Ankylosing spondylitis
B	Diabetes mellitus
C	Hyperlipidaemia
D	Multiple sclerosis
E	Sarcoidosis

70724

Submit

A 65-year-old overweight Asian woman was referred to Ophthalmology Outpatients with general malaise and a gradual reduction in vision of three months' duration, affecting both eyes.

Aided Snellen visual acuity was recorded as 6/18 right eye, 6/12 left eye, both eyes improving to 6/9 with a pinhole. Dilated examination revealed bilateral, moderate nuclear sclerosis, and widespread retinal changes as shown below.

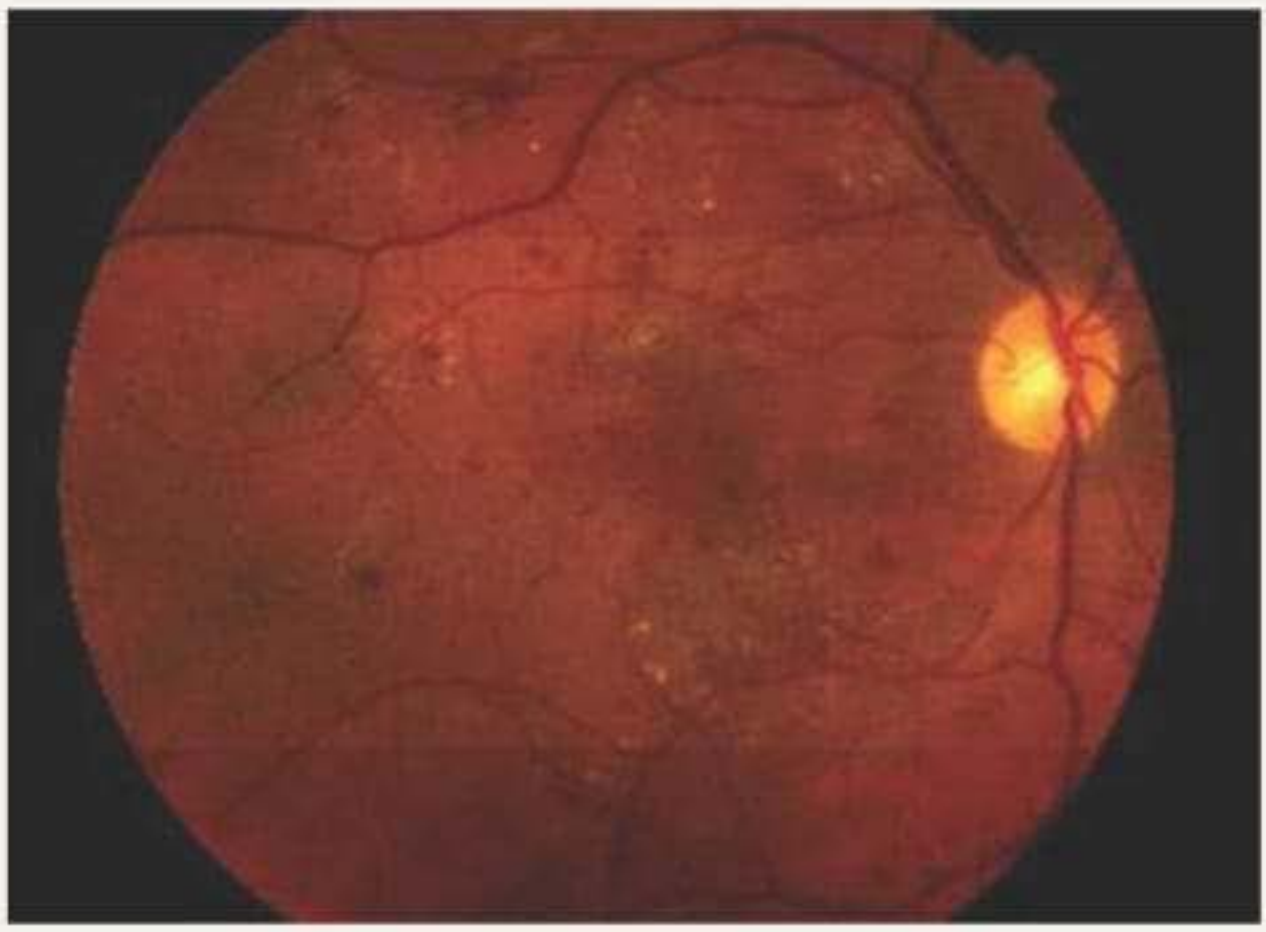

Her lipids were checked by her general practitioner (GP) four months before:

Cholesterol	6 mmol/l
HDL	0.79 mmol/l
LDL	4.0 mmol/l
Fasting triglycerides	4.6 mmol/l

Which of the following is the most likely underlying diagnosis?

Your answer was incorrect

A	Ankylosing spondylitis
B	Diabetes mellitus

١٠:٠٥ 4G 3G

B Diabetes mellitus

The slide shows a diabetic pre-proliferative diabetic retinopathy. There are extensive dot and blot haemorrhages and hard exudates (including a circinate exudates at 11 o'clock to the macula). Cotton-wool spots are seen superior to the macula and superotemporal vascular arcade. There is a large blot haemorrhage superiorly, the arteries are tortuous and fine, and the veins are irregular with beading.

None of this would affect acuity per se – in this case, as evidenced by the satisfactory acuity with pinhole correction, a loss of acuity would imply maculopathy.

A refractive error, or in this case lens opacity, is reducing visual acuity, which subsequently improves with pinhole correction. This is difficult to appreciate from direct fundoscopy but one can sometimes get a sense that the physiological foveal pit reflex is lost, and the macula appears boggy and oedematous.

Fluorescein angiography can demonstrate extensive capillary leak at the macula and show the true extent of the vascular abnormalities, including intra retinal micro aneurysms (another pre-proliferative feature). Retinal imaging with optical coherence tomography (OCT) allows precise measurement of macular oedema, if present. Direct fundoscopy is not always entirely satisfactory at detecting retinopathy. Fluorescein angiography is the gold standard.

Retinal photography should be performed for screening, and in the UK this is undertaken by opticians and optometrists. In this case, however, one should pick up the evident disease. The proximity of red disease (dots and blots) to the macula is not worrying, and can be followed up, but hard exudates (lipid-laden macrophages) and cotton-wool spots (retinal ischaemia – which stimulates new vessel formation) near the macula warrant a referral to an ophthalmologist, particularly if extensive. Any loss of acuity – even if the fundus looks normal – suggests maculopathy and warrants referral.

١٠:٠٦ 4G 3G

acuity – even if the fundus looks normal – suggests maculopathy and warrants referral.

D	Multiple sclerosis

Multiple sclerosis causes optic neuritis. If behind the eye – so-called "retrobulbar", this could only be appreciated as scotomas or loss of acuity and optic atrophy on fundoscopy. If at the eye, papillitis may occur where the eye is painful, with or without photophobia, and the disc looks swollen and pink.

A	Ankylosing spondylitis

Ankylosing spondylitis is associated with anterior uveitis.

C	Hyperlipidaemia

Hypertriglyceridaemia is rarely associated with the appearance of lipaemia retinal is where the vessels look milky. Hypercholesterolaemia, whether combined or solitary, can rarely be associated with retinal ischaemia, but only because of proximal arterial occlusion. These lipids are in keeping with a diabetic dyslipidaemia and the triglycerides are not high enough to cause lipaemia retinalis.

E	Sarcoidosis

Sarcoidosis can cause a retinal vasculitis or anterior uveitis.

70724

Rate this question:

Next Question

Previous Q... Tag Questi... Feedback End Session

The surgical registrar calls you at 2300 h to see a 72-year-old Chinese woman. She is under the general surgeons, being investigated for possible bowel obstruction because of severe nausea and vomiting. She is vomiting every half-hour and complains of progressive visual loss in the right eye during the course of the evening as well as redness and pain. She noticed that for the preceding few days she has seen halos round street lamps. She does not smoke, only drinks rarely and lives on her own except that recently she has purchased a cat. You do not have a Snellen or a Jaeger chart but on using a magazine, her acuity is better in the left than in the right eye.

On inspection there is a shallow anterior chamber, a semi-dilated, fixed pupil and the appearance is shown below. There is a little clear discharge.

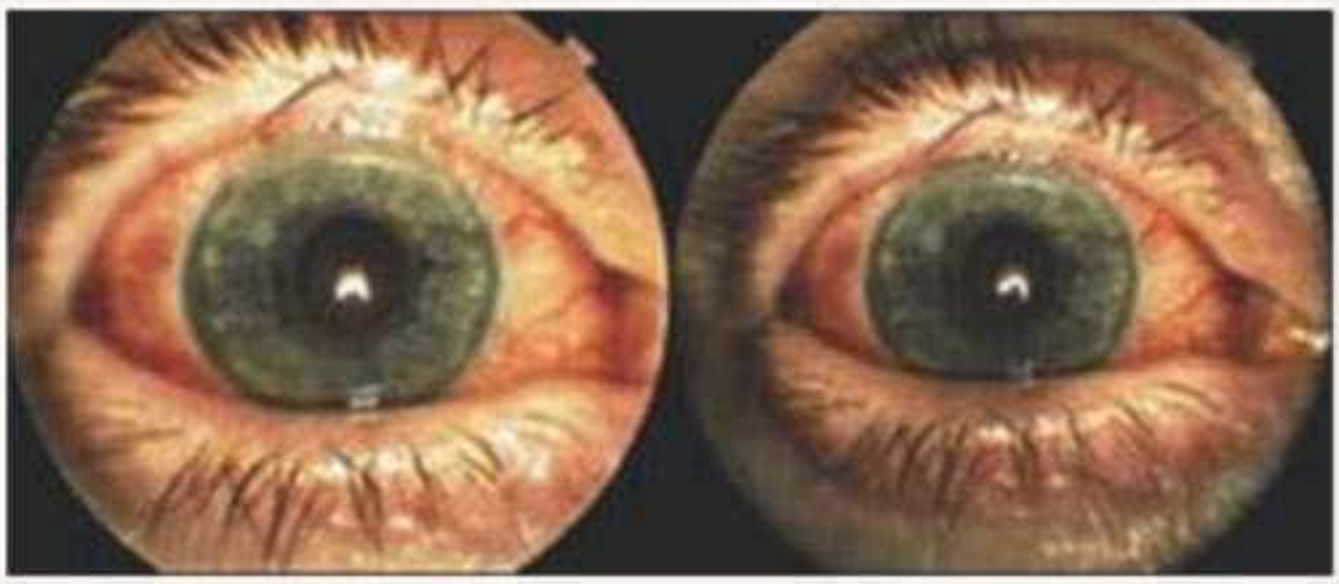

Her blood results were:

FBC	Normal
ESR	29 mm/1st hour
Sodium	131 mmol/l
Potassium	3.2 mmol/l
Bicarbonate	34 mmol/l
Chloride	99 mmol/l
Urea	6.9 mmol/l
Creatinine	110mmol/l

Which of the following is the most likely underlying diagnosis?

١٠:٠٦ 4G 3G

Her blood results were:

FBC	Normal
ESR	29 mm/1st hour
Sodium	131 mmol/l
Potassium	3.2 mmol/l
Bicarbonate	34 mmol/l
Chloride	99 mmol/l
Urea	6.9 mmol/l
Creatinine	110mmol/l

Which of the following is the most likely underlying diagnosis?

A	Conjunctivitis
B	Acute angle-closure glaucoma
C	Acute anterior uveitis
D	Primary open-angle glaucoma
E	Scleritis

70723

Submit

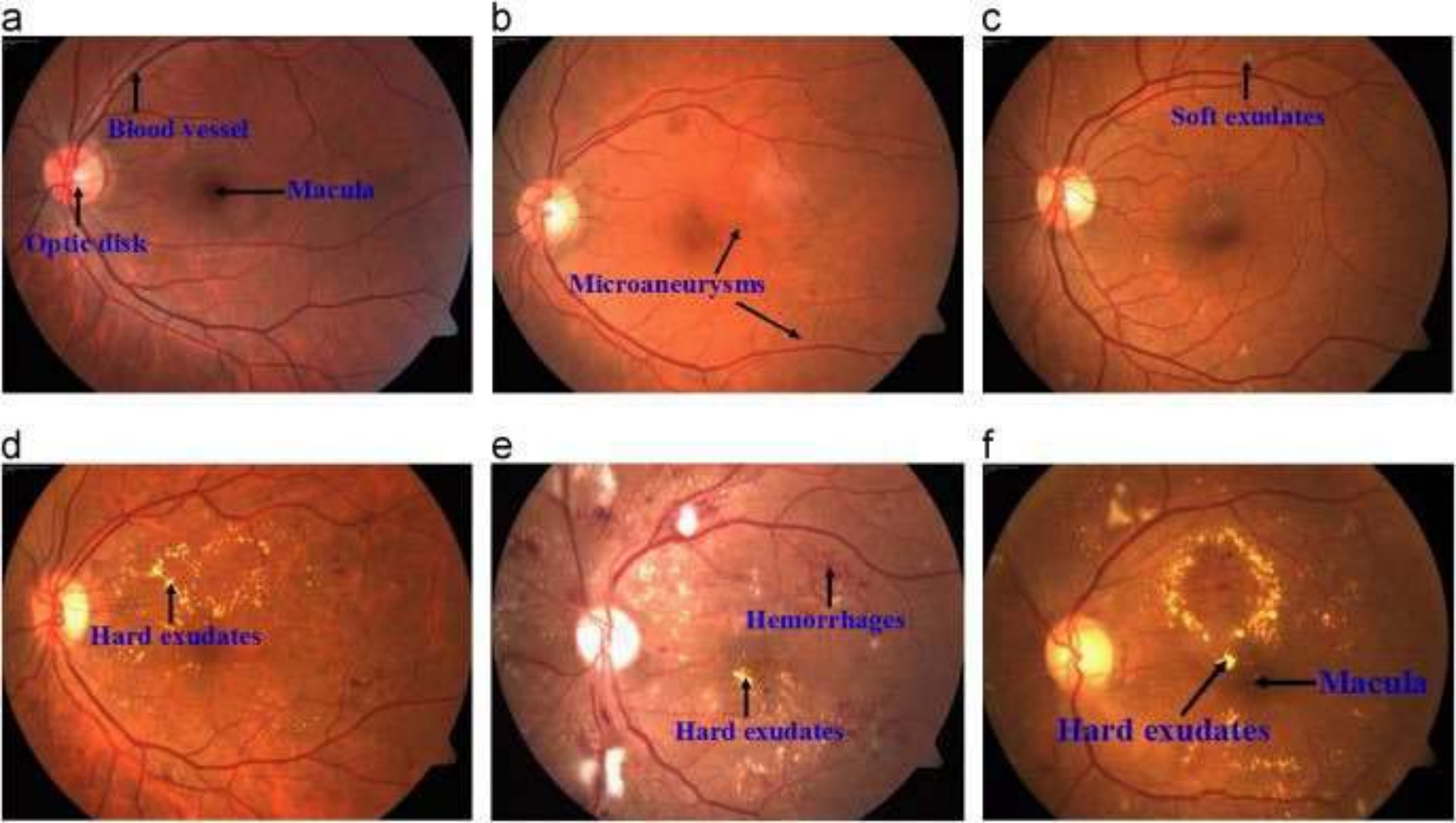
a
Blood vessel
Macula
Optic disk
b
Microaneurysms
c
Soft exudates
d
Hard exudates
e
Hemorrhages
Hard exudates
f
Macula
Hard exudates

١٠:١٢ 4G 3G
mypastest.pastest.com

being investigated for possible bowel obstruction because of severe nausea and vomiting. She is vomiting every half-hour and complains of progressive visual loss in the right eye during the course of the evening as well as redness and pain. She noticed that for the preceding few days she has seen halos round street lamps. She does not smoke, only drinks rarely and lives on her own except that recently she has purchased a cat. You do not have a Snellen or a Jaeger chart but on using a magazine, her acuity is better in the left than in the right eye.

On inspection there is a shallow anterior chamber, a semi-dilated, fixed pupil and the appearance is shown below. There is a little clear discharge.

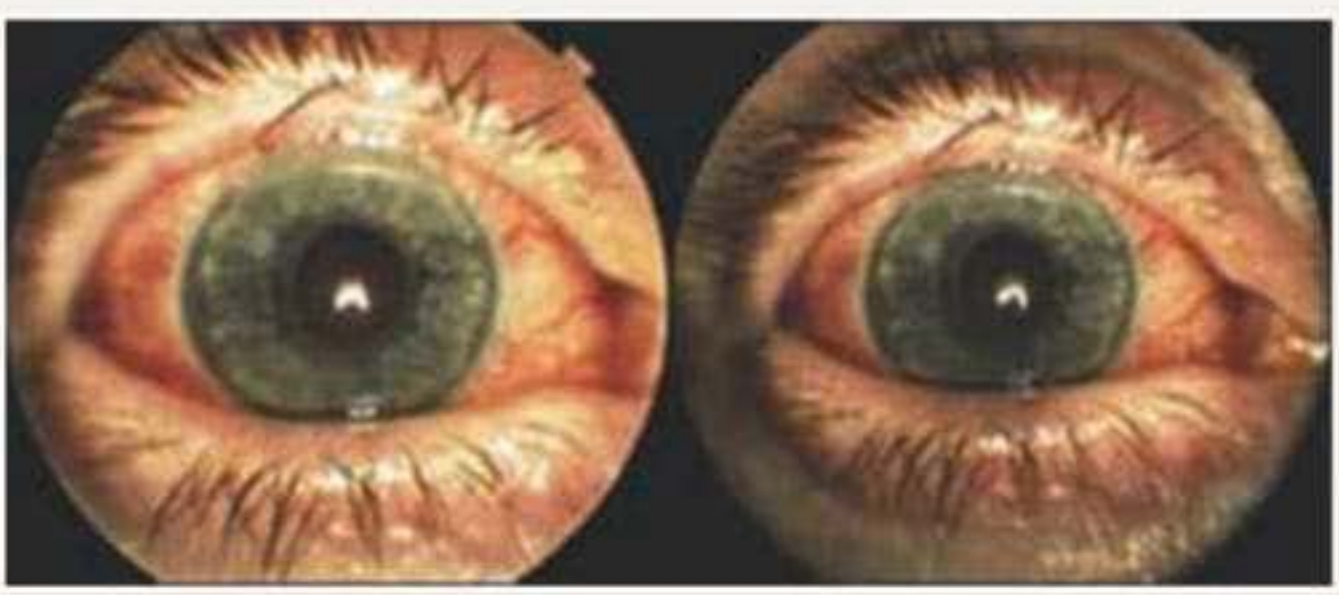

Her blood results were:

FBC	Normal
ESR	29 mm/1st hour
Sodium	131 mmol/l
Potassium	3.2 mmol/l
Bicarbonate	34 mmol/l
Chloride	99 mmol/l
Urea	6.9 mmol/l
Creatinine	110mmol/l

Which of the following is the most likely underlying diagnosis?

A
B
C
D
E
O
Re
Re
Re
Re

١٠:١٢ 4G 3G

B Acute angle-closure glaucoma

This is a classic story for acute angle-closure glaucoma. It is a disease of middle to later life. An acute uniocular attack like this is often preceded by a short period of blurred vision, often with halos round lights– particularly at night-time.

Pain is a variable feature–it can be so severe and, along with the elevation in the intraocular pressure, cause nausea and vomiting such that the patient is assumed to harbor gastrointestinal pathology, such as an obstruction.

Acuity is reduced, the cornea appears hazy due to oedema, there is often a ciliary flush, and the pupil is fixed, often midpoint/dilated and ovoid.

If the anterior chamber is viewed from the side with a torch or a slit lamp, half the iris may be seen to be in shadow and this suggests the iris is bulging forward due to the pressure in the posterior chamber resulting from the obstructed flow of aqueous - this is the shallow anterior chamber.

A 'ciliary flush' refers to dilatation of the deep conjunctival and episcleral vessels adjacent and circumferential to the corneal limbus. It is best seen in natural light. It suggests either anterior uveitis or glaucoma. If suspected, it requires immediate assessment by an ophthalmologist as the optic nerve can be permanently damaged by delay.

The pressure in the both eyes must be measured, and the elevated pressure reduced. This is done with pilocarpine 2–4% drops hourly (meiosis opens the blocked closed draining angle); Acetazolamide is given to stop the production of aqueous, usually orally, or intravascularly if they are vomiting (intramuscular injection is not favoured as it is alkaline and often painful).

Peripheral iridectomy (either by laser or surgically) is performed once the pressures are normal– it is rarely necessary as an emergency, if medical therapy fails to control the pressure. Mydriatics must not be used as these will further increase the block at the 'closed'angle.

A Conjunctivitis

١٠:١٣ 4G 3G

A	Conjunctivitis

Conjunctivitis does not cause perilimbic (within 3mm of the cornea) dilatation.It is usually itchy and is the only cause of a red eye that is so. It is not truly painful and neither vision, reflexes or movements are affected.

C	Acute anterior uveitis

Anterior uveitis tends to cause a deep boring pain, of acute onset, photophobia (because of iris spasm), blurred vision due to precipitates in the aqueous, lacrimation, circumcorneal redness (ciliary flush), and a small pupil (again because of iris spasm) that may in time become irregular or dilate irregularly due to adhesion formation. Pus may be seen in the anterior chamber (hypopyon) with a slit lamp. It tends to affect young or middle-aged patients, and is associated with arthritites, such as Still's disease and ankylosing spondylitis.

D	Primary open-angle glaucoma

Primary open-angle glaucoma is a chronic disease, which is usually asymptomatic. It is typically associated with a triad of:
1) raised intraocular pressure,
2) pathological changes in the optic disc,
3) visual field defects.

The anterior chamber of the eye is deep, with open-angles, and normal pupil reflexes.

E	Scleritis

Scleritis is inflammation of the sclera of the white, leading to a constant, deep, boring pain, which can often wake patients at night. The eye may be very tender to touch. It may be associated with focal or diffuse erythema of the sclera. It is commonly associated with underlying connectivetissue diseases (~50% of cases). In contrast to acute angle-closure glaucoma, the anterior chamber is typically deep and the pupil reflexes are typically normal.

70723

Rate this question:

١٠:١٣ 4G 3G
mypastest.pastest.com

A 76-year-old Asian woman presents to the Emergency Department. She complains of sudden-onset headache that began on leaving the cinema. She further describes altered vision and intractable vomiting.

Examination is difficult as she is so agitated; however, digital palpation of the globe through closed eyelids reveals a rock-hard eyeball. Positive findings are pallor and sweating and she has a fixed dilated right pupil with lacrimation and injected conjunctiva. Fundoscopy is impossible.

What is the optimal initial management?

A	Intravenous acetazolamide
B	Subcutaneous sumatriptan
C	Intravenous dexamethasone
D	Oral indomethacin
E	High-flow oxygen

70713

Submit

١٠:١٦ 4G 3G
mypastest.pastest.com

A 76-year-old Asian woman presents to the Emergency Department. She complains of sudden-onset headache that began on leaving the cinema. She further describes altered vision and intractable vomiting.

Examination is difficult as she is so agitated; however, digital palpation of the globe through closed eyelids reveals a rock-hard eyeball. Positive findings are pallor and sweating and she has a fixed dilated right pupil with lacrimation and injected conjunctiva. Fundoscopy is impossible.

What is the optimal initial management?



Your answer was correct

A	Intravenous acetazolamide
B	Subcutaneous sumatriptan
C	Intravenous dexamethasone
D	Oral indomethacin
E	High-flow oxygen

Explanation

A	Intravenous acetazolamide

This patient presents with acute angle closure glaucoma

١٠:١٦ 4G 3G

A	Intravenous acetazolamide

This patient presents with acute angle closure glaucoma. This is caused by a sudden rise in intraocular pressure secondary to impaired flow of aqueous humour triggered in dim light when the pupil dilates. This condition often presents to physicians and can be misdiagnosed because of associated headache and abdominal pain. Physical examination reveals decreased acuity, conjunctival injection and a fixed mid-position pupil, often oval in shape. Immediate treatment is necessary to preserve vision. Urgent ophthalmology referral is required. While waiting for specialist input, the carbonic-anhydrase inhibitor acetazolamide may be given to decrease aqueous humour production under ophthalmology instruction.

B	Subcutaneous sumatriptan

Sumatriptan is an intervention of choice for acute migraine; although migraine may present with frontal headache, the rock-hard eye ball effectively rules it out as the underlying diagnosis here.

C	Intravenous dexamethasone

Topical prednisolone, not intravenous dexamethasone, is the usual intervention in patients with acute angle closure glaucoma.

D	Oral indomethacin

Indomethacin is the drug of choice for treating paroxysmal hemicrania, which is excluded here by the condition of the eye itself.

E	High-flow oxygen

High-flow oxygen is the intervention of choice for patients suffering from cluster headache.

70713

Rate this question:

A 62-year-old man with type 2 diabetes, controlled with twice-daily mixed insulin and metformin, comes to the clinic with worsening visual acuity over the past week.

He admits to poor compliance with diet and use of insulin, and a recent HbA1c has been measured at 65 mmol/mol. His blood pressure is 149/88 mmHg.

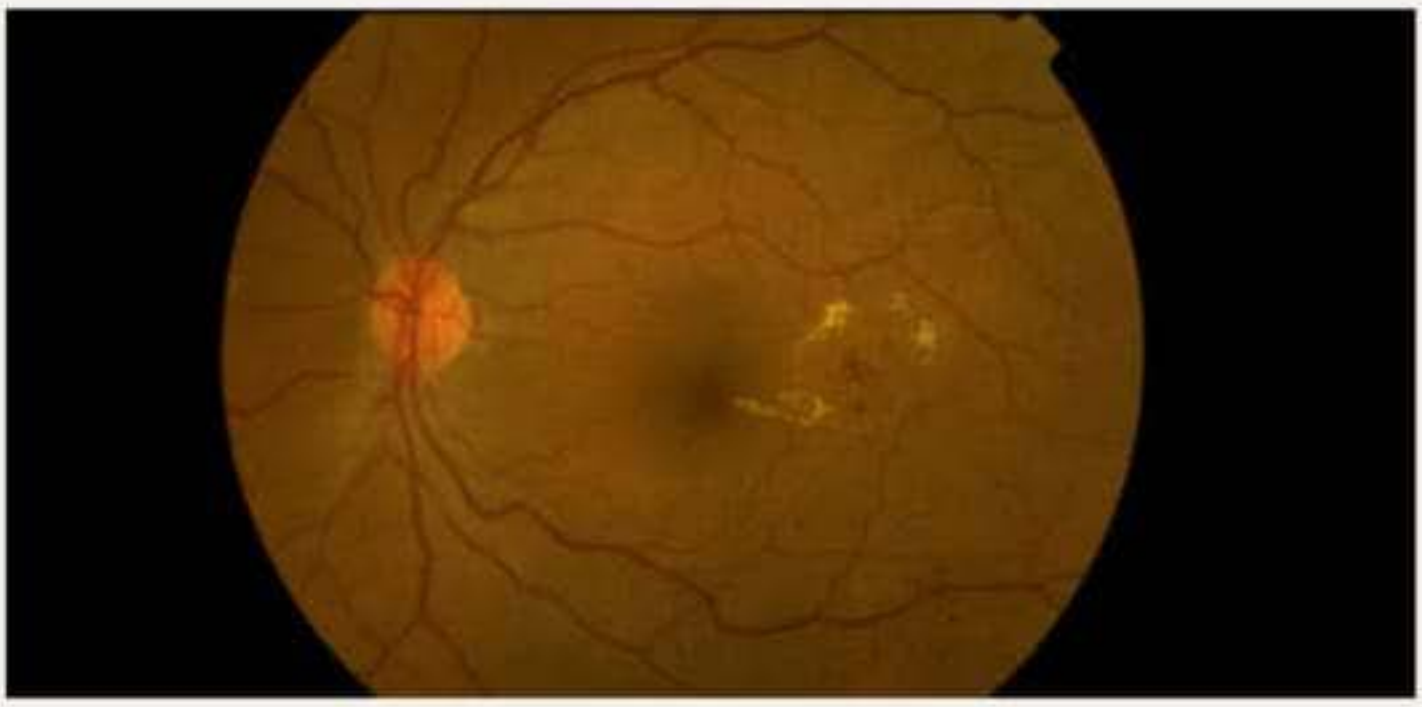

Which of the following is the most appropriate intervention?

A	Acetazolamide
B	Bevacizumab
C	Dexamethasone implant
D	Intravitreal triamcinolone
E	Switch to basal bolus insulin therapy

71586

Submit

B Bevacizumab

This presence of hard exudates and haemorrhages within one disc diameter of the macula is suggestive of macular oedema. This fits with poor compliance and deteriorating visual acuity in a patient with type 2 diabetes and retinal changes within one disc diameter of the macula. Bevacizumab is an anti-VEGF agent which has been proven to reduce retinal thickness, oedema and reduce growth of new vessels and risk of bleeding. Focal laser therapy is the alternative.

A Acetazolamide

Acetazolamide reduces intra-ocular pressure and has its main role in the treatment of acute glaucoma rather than diabetic macular oedema.

C Dexamethasone implant

Although corticosteroids do reduce macular oedema over the short term, they are usually considered a second-line option to anti-VEGF or laser therapy.

D Intravitreal triamcinolone

Corticosteroids are usually considered when laser or anti-VEGF therapy is unsuitable or ineffective in managing macular oedema.

E Switch to basal bolus insulin therapy

In the short term, improved glycaemic control may actually worsen retinopathy rather than having a positive impact on eye disease, although over the longer term it will reduce progression. Definitive local therapy is usually considered first before intensifying insulin treatment.

71586

Rate this question:

Next Question

١٠:١٩ 4G 3G
mypastest.pastest.com

A 62-year-old man with type 2 diabetes, controlled with twice-daily mixed insulin and metformin, comes to the clinic with worsening visual acuity over the past week.

He admits to poor compliance with diet and use of insulin, and a recent HbA1c has been measured at 65 mmol/mol. His blood pressure is 149/88 mmHg.

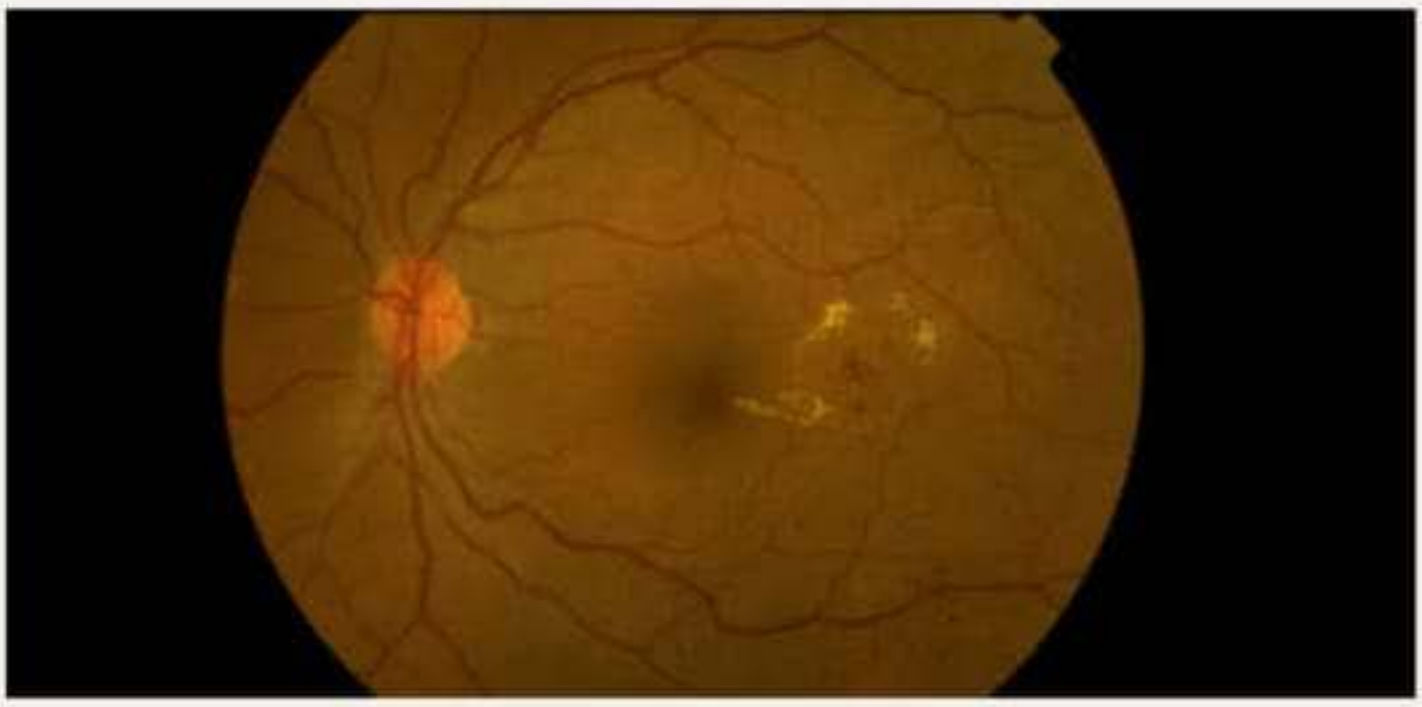

Which of the following is the most appropriate intervention?

Your answer was incorrect

A	Acetazolamide
B	Bevacizumab
C	Dexamethasone implant
D	Intravitreal triamcinolone
E	Switch to basal bolus insulin therapy

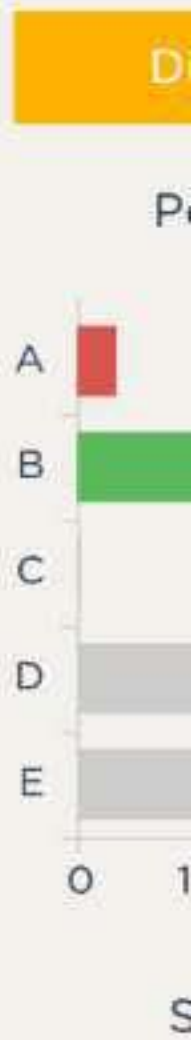

Explanation

١٠:٢٣ 4G 3G

E	Retinitis pigmentosa

The findings of fundoscopy are consistent with retinitis pigmentosa. The presence of bone spicules, which are black or brown concentrations of pigmentation, is pathognomonic. This is a hereditary condition of progressive dystrophy of photoreceptors and pigment epithelium which causes reduced night and peripheral vision, sparing central vision until progressing to blindness. It typically presents between the ages of 10 and 30 years.

A	Diabetic retinopathy

Diabetic retinopathy is caused by microvascular occlusions leading to retinal ischaemia and eventually neovascularisation. This can occur in people with type 1 or type 2 diabetes and can be present without a formal diagnosis of diabetes. This patient's fundoscopy is not consistent with diabetic changes, however.

Diabetic retinopathy is characterised by:

- microaneurysms
- hard exudates
- haemorrhages: appearance of red dots or flames
- cotton-wool spots
- neovascularisation.

B	Hypertensive retinopathy

High blood pressure causes damage in the eye due to arterial and arteriolar circulation in response to high blood pressure. This patient lacks these signs and they are an unlikely presentation at this age.

Signs on fundoscopy of hypertensive retinopathy include:

- arteriovenular nipping
- microaneurysms
- cotton-wool spots
- hard exudates
- silver wiring of arterioles.

A 19-year-old woman presents to Ophthalmology Clinic. She has attended because when practising for her driving test, her mother has noticed that she sometimes does not seem to notice cars coming up beside her when driving. They once tried driving in the evening, but this was very difficult.

The patient describes herself as clumsy but has not noticed any deterioration in vision.

Her fundoscopy is shown below.

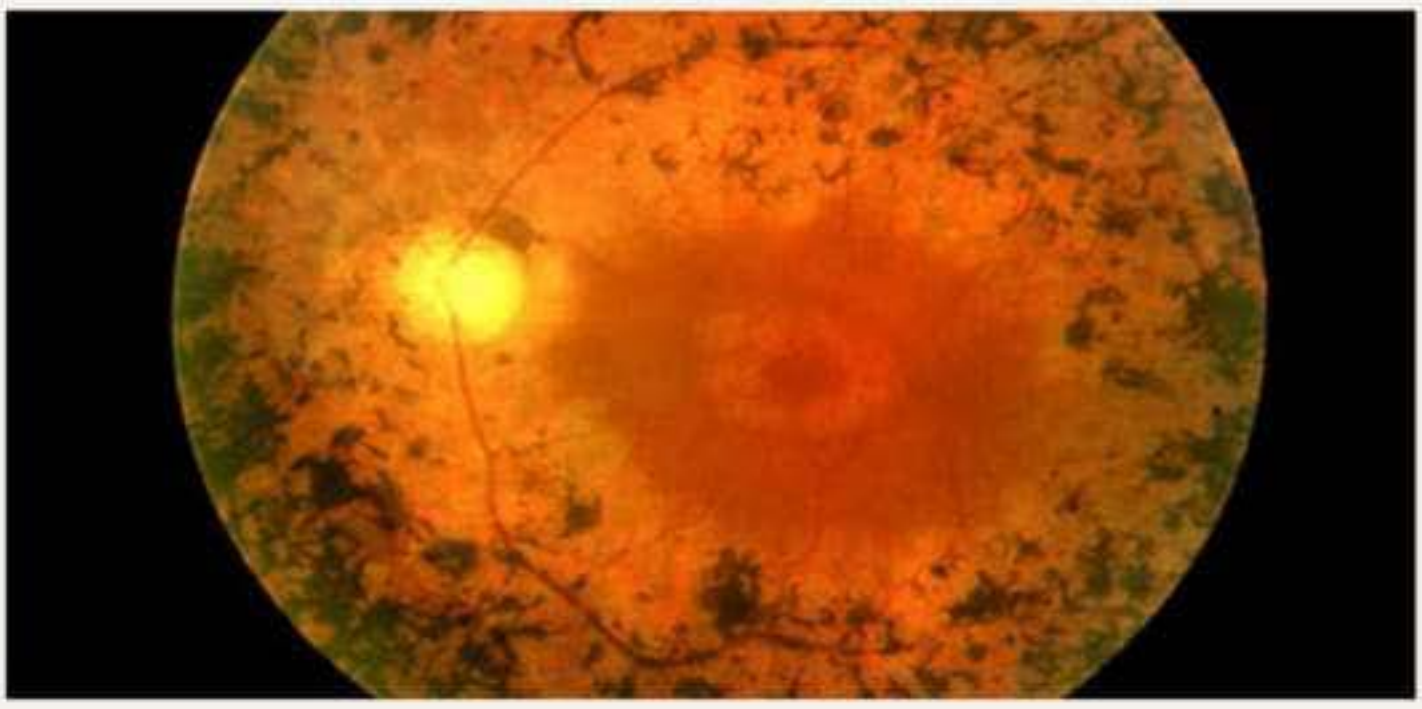

What is the likely diagnosis?

A	Diabetic retinopathy
B	Hypertensive retinopathy
C	Conjunctivitis
D	Multiple sclerosis
E	Retinitis pigmentosa

71599

Submit

۱۰:۲۳ 4G 3G
mypastest.pastest.com

A 19-year-old woman presents to Ophthalmology Clinic. She has attended because when practising for her driving test, her mother has noticed that she sometimes does not seem to notice cars coming up beside her when driving. They once tried driving in the evening, but this was very difficult.

The patient describes herself as clumsy but has not noticed any deterioration in vision.

Her fundoscopy is shown below.

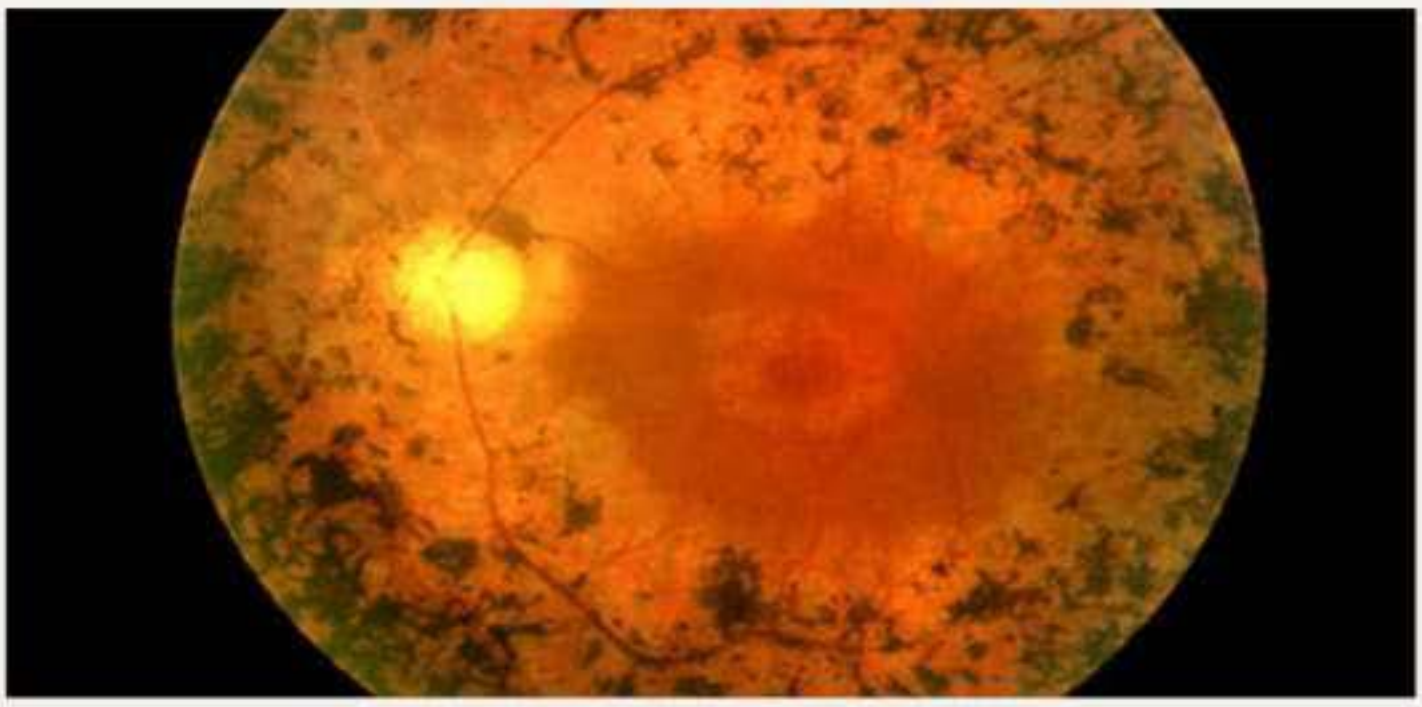

What is the likely diagnosis?

Your answer was correct

A	Diabetic retinopathy
B	Hypertensive retinopathy
C	Conjunctivitis
D	Multiple sclerosis
E	Retinitis pigmentosa

Explanation

١٠:٢٣ 4G 3G

B	Hypertensive retinopathy

High blood pressure causes damage in the eye due to arterial and arteriolar circulation in response to high blood pressure. This patient lacks these signs and they are an unlikely presentation at this age.

Signs on fundoscopy of hypertensive retinopathy include:

- arteriovenular nipping
- microaneurysms
- cotton-wool spots
- hard exudates
- silver wiring of arterioles.

C	Conjunctivitis

Conjunctivitis is inflammation of the conjunctiva, which can be infectious or non-infectious. Infectious causes include various viral and bacterial causes, while non-infectious causes include mechanical irritants and allergic reactions. Presentation is with red eye, which can be bilateral and feel gritty and uncomfortable, but without reduction in visual acuity and any differences on fundoscopy.

D	Multiple sclerosis

Multiple sclerosis is a potential explanation of optic neuritis, especially in younger women. Multiple sclerosis is a cell-mediated autoimmune disorder defined by lesions of the central nervous system separated by time and space. In terms of ophthalmic problems with multiple sclerosis, optic neuritis is a common presentation. This is a unilateral, acute painful cause of loss of vision. On fundoscopy in chronic optic neuritis, a pale optic disc can be seen. This is not the case for this patient, nor is the presentation consistent.

71599

Rate this question:

Next Question

An 18-year-old man who works in a boarding kennels for cats and dogs is referred by his general practitioner (GP) after he presented complaining of right ocular pain and blurred, 'hazy' vision for several weeks.

The fundal appearance is shown below:

What is the most likely cause of this appearance?

A	Toxoplasmosis
B	Retinitis pigmentosa
C	Retrobulbar neuritis
D	Cytomegalovirus (CMV)
E	Retinal detachment

70708

Submit

١٠:٢٧ 4G 3G

meat and dairy products, and direct or indirect ingestion of cat faeces.

Treatment is with at least four weeks of pyrimethamine/sulphadiazine/folinic acid clindamycin/sulphadiazine/atovaquone. Weekly full blood count would be required.

B	Retinitis pigmentosa

This is a chronic genetic retinal degeneration that does not cause pain and vitritis. Blindness is slowly progressive over a number of years. Peripheral visual field loss occurs first and is slowly progressive.

C	Retrobulbar neuritis

The man has no fundal signs and it is often a presenting feature of multiple sclerosis, for which other signs or symptoms are absent.

D	Cytomegalovirus (CMV)

The fundal changes are inconsistent; CMV causes a haemorrhagic retinitis. Furthermore, patients are usually immunosuppressed or suffer from a chronic illness such as HIV.

E	Retinal detachment

This usually occurs against a background of eye disease such as that related to diabetes mellitus. The area of detachment may be visualised on fundoscopy, including any area of retinal haemorrhage.

70708

Rate this question:

Next Question

Previous Q... Tag Questi... Feedback End Session

Explanation

A	Toxoplasmosis

The image shows chorioretinitis with vitritis, hence obscuring the optic disc, caused by *Toxoplasma gondii* infection. The symptoms associated with ocular toxoplasmosis include unilateral, mild ocular pain, blurred vision and new onset of floating spots. Patients often describe their vision as hazy. Clinical findings may include granulomatous iritis, optic disc swelling, neuroretinitis, vasculitis and retinal vein occlusion in the vicinity of the inflammation, in the actively involved eye.

Fundoscopically, active toxoplasmosis presents with white-yellow chorioretinal lesions and vitreous cells. There may be old, inactive lesions in the other eye. Congenital reactivation of toxoplasmosis accounts for the majority of cases encountered in clinical practice. Infection may also occur from ingestion of contaminated or undercooked meat and dairy products, and direct or indirect ingestion of cat faeces.

Treatment is with at least four weeks of pyrimethamine/sulphadiazine/folinic acid clindamycin/sulphadiazine/atovaquone. Weekly full blood count would be required.

B	Retinitis pigmentosa

This is a chronic genetic retinal degeneration that does not cause pain and vitritis. Blindness is slowly progressive over a number of years. Peripheral visual field loss occurs first and is slowly progressive.

C	Retrobulbar neuritis

The man has no fundal signs and it is often a presenting feature of multiple sclerosis, for which other signs or symptoms are absent.

D	Cytomegalovirus (CMV)

١٠:٢٧ 4G 3G
mypastest.pastest.com

An 18-year-old man who works in a boarding kennels for cats and dogs is referred by his general practitioner (GP) after he presented complaining of right ocular pain and blurred, 'hazy' vision for several weeks.

The fundal appearance is shown below:

What is the most likely cause of this appearance?

Your answer was correct

A	Toxoplasmosis
B	Retinitis pigmentosa
C	Retrobulbar neuritis
D	Cytomegalovirus (CMV)
E	Retinal detachment



Explanation

A 25-year-old woman presents to the clinic with gradually deteriorating vision over the past year. She is now unable to drive because of her eyesight. She also has muscle weakness with intermittent tingling affecting her hands and feet and has suffered one episode of tetany in the past three months.

Medical history of note includes post-partum thyroiditis which occurred after the birth of her first child some three years ago.

A photograph of one of her eyes is shown below.

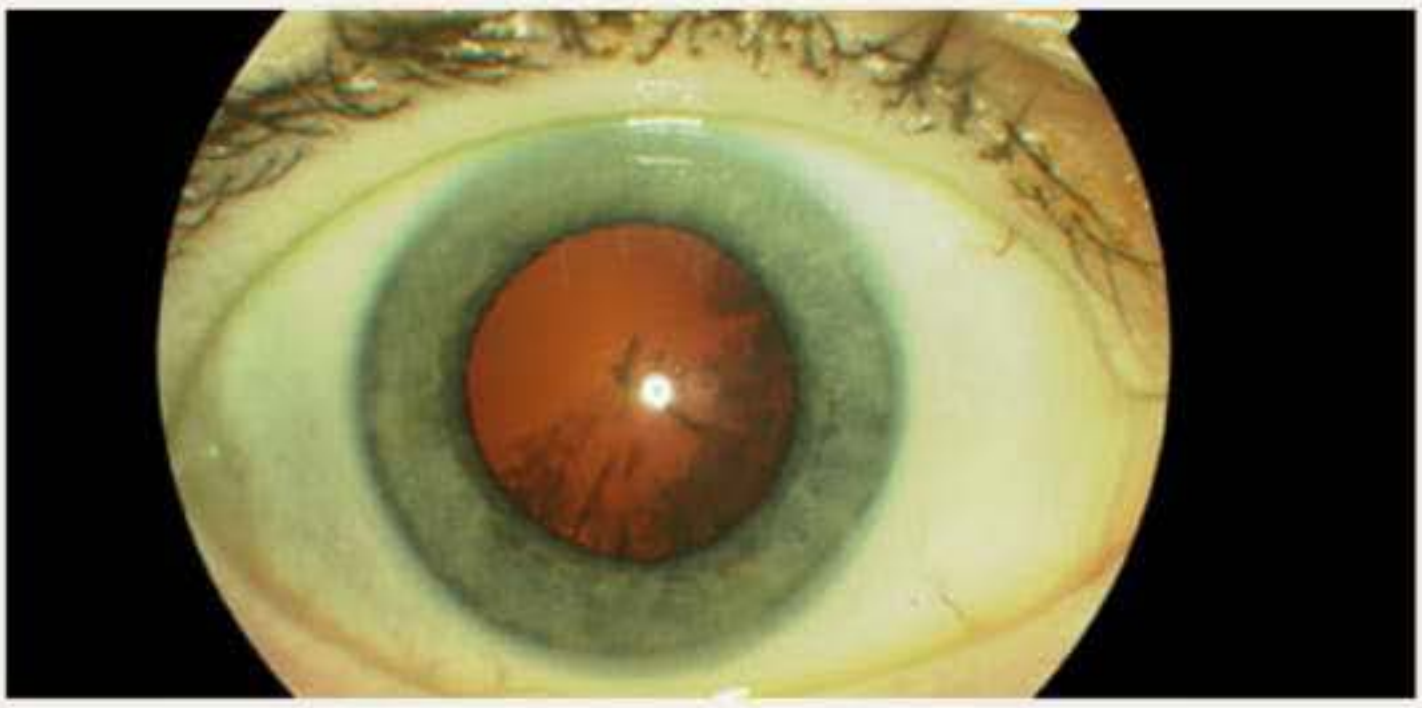

Which of the following is she most likely to benefit from?

A	Calcium and vitamin D
B	Calcitonin
C	Magnesium sulphate
D	Teriparatide
E	Thyroxine

71587

Submit

١٠:٣٢ 4G 3G

A 25-year-old woman presents to the clinic with gradually deteriorating vision over the past year. She is now unable to drive because of her eyesight. She also has muscle weakness with intermittent tingling affecting her hands and feet and has suffered one episode of tetany in the past three months.

Medical history of note includes post-partum thyroiditis which occurred after the birth of her first child some three years ago.

A photograph of one of her eyes is shown below.

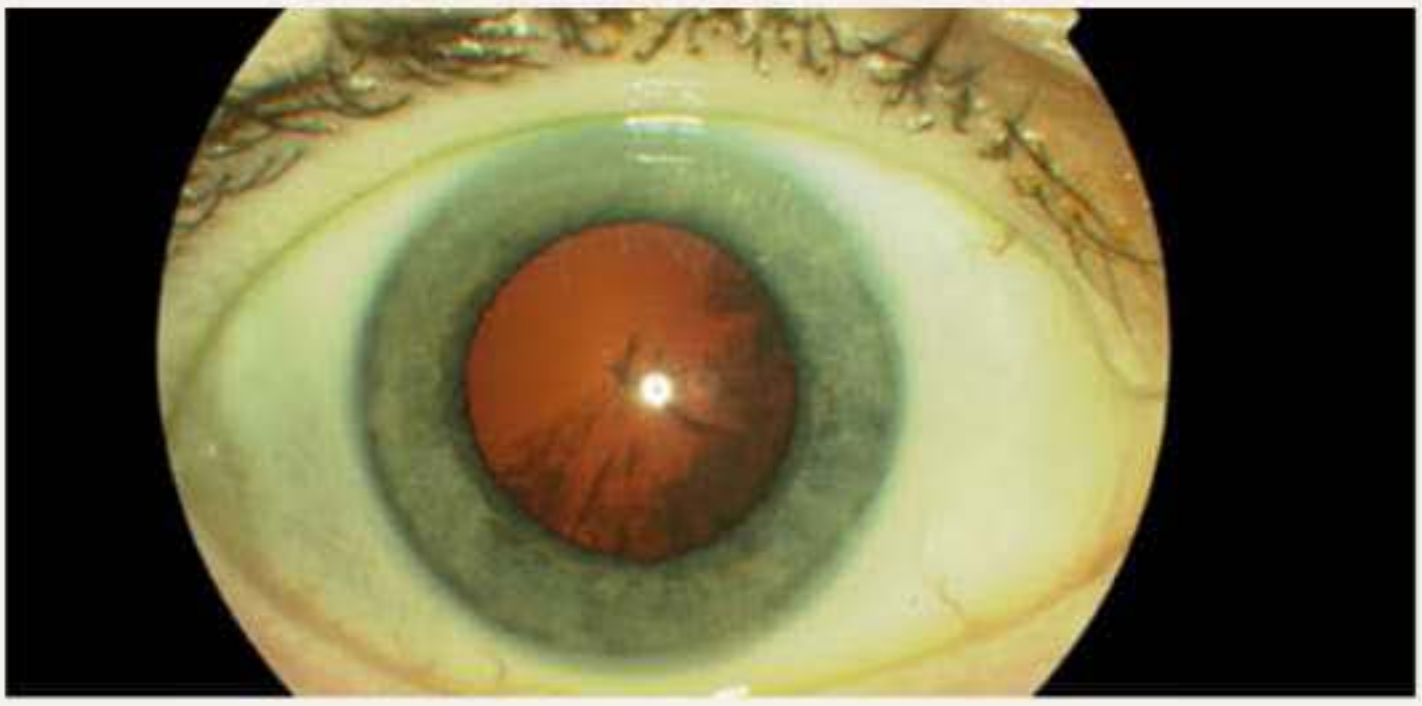

Which of the following is she most likely to benefit from?

Your answer was correct

A	Calcium and vitamin D
B	Calcitonin
C	Magnesium sulphate
D	Teriparatide
E	Thyroxine

Explanation

A	Calcium and vitamin D

۱۰:۳۲ 4G 3G

A	Calcium and vitamin D

This patient has a history of previous autoimmune disease (post-partum thyroiditis), with gradually deteriorating vision, muscle weakness and sensory loss. This is consistent with hypocalcaemia due to idiopathic primary hypoparathyroidism, which is thought to be autoimmune in origin. Laboratory studies would show a low calcium and a low or inappropriately normal parathyroid hormone (PTH). Calcium and vitamin D are the intervention of choice. The image shows clouding of the lens with cataract formation which tends to follow a radial pattern in hypoparathyroidism, as seen here. It is thought to result from both hypocalcaemia and hyperphosphataemia.

B	Calcitonin

Calcitonin is used as an acute treatment for hypercalcaemia and has no role in the treatment of hypoparathyroidism.

C	Magnesium sulphate

Magnesium replacement is useful when hypomagnesaemia drives parathyroid hormone resistance. In this case, primary hypoparathyroidism is much more likely to be the cause of the patient's symptoms.

D	Teriparatide

Teriparatide is a synthetic parathyroid hormone analogue used in the treatment of osteoporosis; it does not have a role in the treatment of hypoparathyroidism.

E	Thyroxine

Although hypothyroidism does occur following post-partum thyrotoxicosis, it does not fit with the symptoms reported here, which are much more consistent with hypoparathyroidism.

71587

Rate this question:

١٠:٣٢ 4G 3G
mypastest.pastest.com

A 26-year-old woman, who is previously fit and well, presents to the Emergency Department with pain behind the right eye, blurring and loss of colour vision since waking from sleep.

Visual acuity testing reveals deterioration from 6/6 to 6/18; visual fields are normal. There is a relative afferent pupillary defect, and fundoscopy suggests mild optic disc swelling. ESR is mildly raised at 48mm/1st hr, and other blood tests are unremarkable.

Which of the following is the most likely diagnosis?

A	Acute glaucoma
B	Central retinal artery occlusion
C	Central retinal vein occlusion
D	Meningioma
E	Optic neuritis

70721

Submit

١٠:٣٦ 4G 3G
mypastest.pastest.com

A 26-year-old woman, who is previously fit and well, presents to the Emergency Department with pain behind the right eye, blurring and loss of colour vision since waking from sleep.

Visual acuity testing reveals deterioration from 6/6 to 6/18; visual fields are normal. There is a relative afferent pupillary defect, and fundoscopy suggests mild optic disc swelling. ESR is mildly raised at 48mm/1st hr, and other blood tests are unremarkable.

Which of the following is the most likely diagnosis?

Your answer was correct

A	Acute glaucoma
B	Central retinal artery occlusion
C	Central retinal vein occlusion
D	Meningioma
E	Optic neuritis

Explanation

E	Optic neuritis

The rapid deterioration in vision, particularly the loss of colour vision, with no significant past medical history and

١٠:٣٦ 4G 3G

E	Optic neuritis

The rapid deterioration in vision, particularly the loss of colour vision, with no significant past medical history and mild optic disc swelling raises the possibility of optic neuritis. Normal fundoscopy or only minor changes (as here) may be seen in the initial stages of the condition.

Of note, with respect to treatment is that intravenous corticosteroids have not been shown to impact on visual outcomes versus observation only.

A	Acute glaucoma

Acute glaucoma is incorrect because the history is inconsistent with glaucoma. Furthermore, it would not be usual to find disc swelling in acute glaucoma.

B	Central retinal artery occlusion

Central retinal artery occlusion is incorrect. A central retinal artery occlusion would be characterised by a pale retina and cherry red spot at the macula.

C	Central retinal vein occlusion

Central retinal vein occlusion is incorrect because this is characterised by flame-shaped retinal haemorrhages.

D	Meningioma

Meningioma is incorrect because the history is of far too acute an onset to suggest meningioma, in which symptoms are likely to occur more gradually.

70721

Rate this question:

Next Question

A 21-year-old college student presents with pain in her right eye, which is increased on movement, of one week's duration. Over the past two days, she has also noted blurring of vision affecting the eye.

On examination, temperature is 37 °C, pulse rate is 84/min and blood pressure is 120/80 mmHg. Cognition is normal with a Glasgow Coma Scale (GCS) of 15. The visual acuity is 6/12 for the right eye and 6/6 for the left eye. Visual field examination by confrontation technique suggests a central scotoma. A relative afferent pupillary defect is also noted in the right eye. The right optic disc is swollen. Neurological examination is otherwise unremarkable.

Investigations revealed:

WCC	5.0×10^9/l
Erythrocyte sedimentation rate (ESR)	20 mm in 1 h
Alanine aminotransferase (ALT)	30 U/l
Blood urea	8.0 mmol/l
Serum creatinine	120 µmol/l
Antinuclear antibody	Mild positive
Magnetic resonance imaging (MRI) of the brain	Normal

Cerebrospinal fluid (CSF):

Opening pressure	15 cm H_2O
Lymphocytes	4/mm^3
Protein	400 mg/l
Glucose	5.0 mmol/l, with a random blood glucose of 7.0 mmol/l
Oligoclonal bands	Negative

What is the most likely diagnosis?

١٠:٤٠ 4G 3G

B	Optic neuritis

Optic neuritis is the inflammation of the optic nerve with swelling of the optic disc. In a proportion of such patients, no cause of optic neuropathy can be found. It can be associated with multiple sclerosis (MS), but a second neurological event is required separated in time. MRI brain can be performed to identify the presence of periventricular white matter changes which make the association of MS more likely. The typical situation is one in which an adolescent develops rapid diminution of vision in one eye which may progress to complete blindness. Pain on movement and tenderness of the globe, a central scotoma, a relative afferent pupillary defect and a profound visual loss are the features that distinguish it from papilloedema.

A	Idiopathic intracranial hypertension (IIH)

IIH is associated with gradual deterioration in vision and headaches, which are particularly severe in the morning and worsened by coughing or straining. IIH is most commonly seen in obese young women.

C	Anterior ischaemic optic neuropathy (AION)

AION occurs in a more elderly population (usually over the age of 50 years) and in patients with vascular risk factors. Neither is present here.

D	Central nervous system (CNS) lymphoma

CNS lymphoma is associated with gradual neurological impairment and lymphocytosis seen on lumbar puncture. The isolated visual field loss coupled with papilloedema does not fit with lymphoma.

E	Toxic optic neuritis

Similar features are seen on fundoscopy for toxic optic neuritis, although both eyes are of course affected.

70712

Rate this question:

١٠:٤٠ 4G 3G
mypastest.pastest.com

A 21-year-old college student presents with pain in her right eye, which is increased on movement, of one week's duration. Over the past two days, she has also noted blurring of vision affecting the eye.

On examination, temperature is 37 °C, pulse rate is 84/min and blood pressure is 120/80 mmHg. Cognition is normal with a Glasgow Coma Scale (GCS) of 15. The visual acuity is 6/12 for the right eye and 6/6 for the left eye. Visual field examination by confrontation technique suggests a central scotoma. A relative afferent pupillary defect is also noted in the right eye. The right optic disc is swollen. Neurological examination is otherwise unremarkable.

Investigations revealed:

WCC	5.0×10^9/l
Erythrocyte sedimentation rate (ESR)	20 mm in 1 h
Alanine aminotransferase (ALT)	30 U/l
Blood urea	8.0 mmol/l
Serum creatinine	120 µmol/l
Antinuclear antibody	Mild positive
Magnetic resonance imaging (MRI) of the brain	Normal

Cerebrospinal fluid (CSF):

Opening pressure	15 cm H_2O

A 32-year-old man comes to the Emergency Department with a severe headache, nausea and vomiting. He admits that he was diagnosed with hypertension some four years earlier but has refused to visit the general practitioner (GP) for follow-up. His brother has end-stage kidney disease.

His blood pressure is 190/110 mmHg, and there are ballotable masses in both flanks. His body mass index (BMI) is 23 kg/m^2.

A retinal photograph is shown below.

Which of the following is the most likely cause of his hypertension?

A	Adrenal carcinoma
B	Cushing syndrome
C	Phaeochromocytoma
D	Polycystic kidney disease (PKD)
E	Reflux nephropathy

D	Polycystic kidney disease (PKD)

The history of prolonged hypertension presenting now with grade 4 hypertensive retinopathy, coupled with signs of bilateral renal masses and end-stage kidney disease in his brother, fits with a diagnosis of autosomal dominant PKD. Although angiotensin-converting enzyme (ACE) inhibitors are the mainstay of therapy to control blood pressure in PKD, titratable intravenous (IV) therapy with nitroprusside or labetolol is likely to be more appropriate.

A	Adrenal carcinoma

Adrenal carcinoma is much more likely to be unilateral and is associated with features of Cushing syndrome and hyperandrogenism. The normal BMI and bilateral features count against Cushing syndrome as the cause of this patient's hypertension.

B	Cushing syndrome

Cushing syndrome may be associated with uncontrolled hypertension, although it is also associated with marked weight gain and dysglycaemia, which are not seen in this patient.

C	Phaeochromocytoma

Phaeochromocytoma may present with grade 4 hypertensive retinopathy, although the bilateral renal masses would not be seen in the context of an underlying phaeochromocytoma.

E	Reflux nephropathy

Reflux nephropathy does result in the development of hypertension, which may be severe, although it does not lead to bilateral renal masses.

71583

Rate this question:

Next Question

١٠:٤٥ 4G 3G

A 32-year-old man comes to the Emergency Department with a severe headache, nausea and vomiting. He admits that he was diagnosed with hypertension some four years earlier but has refused to visit the general practitioner (GP) for follow-up. His brother has end-stage kidney disease.

His blood pressure is 190/110 mmHg, and there are ballotable masses in both flanks. His body mass index (BMI) is 23 kg/m^2.

A retinal photograph is shown below.

Which of the following is the most likely cause of his hypertension?

Your answer was correct

A	Adrenal carcinoma
B	Cushing syndrome
C	Phaeochromocytoma
D	Polycystic kidney disease (PKD)
E	Reflux nephropathy

Explanation

١٠:٤٥ 4G 3G
mypastest.pastest.com

A 24-year-old woman comes to the clinic with painless visual loss affecting her left eye. She tells you that she suffered a rapid deterioration in colour vision and visual acuity in the eye, which progressed over the course of a few days. She has also suffered from ataxia, but has refused investigations for this in the past.

An image of her eye is shown below.

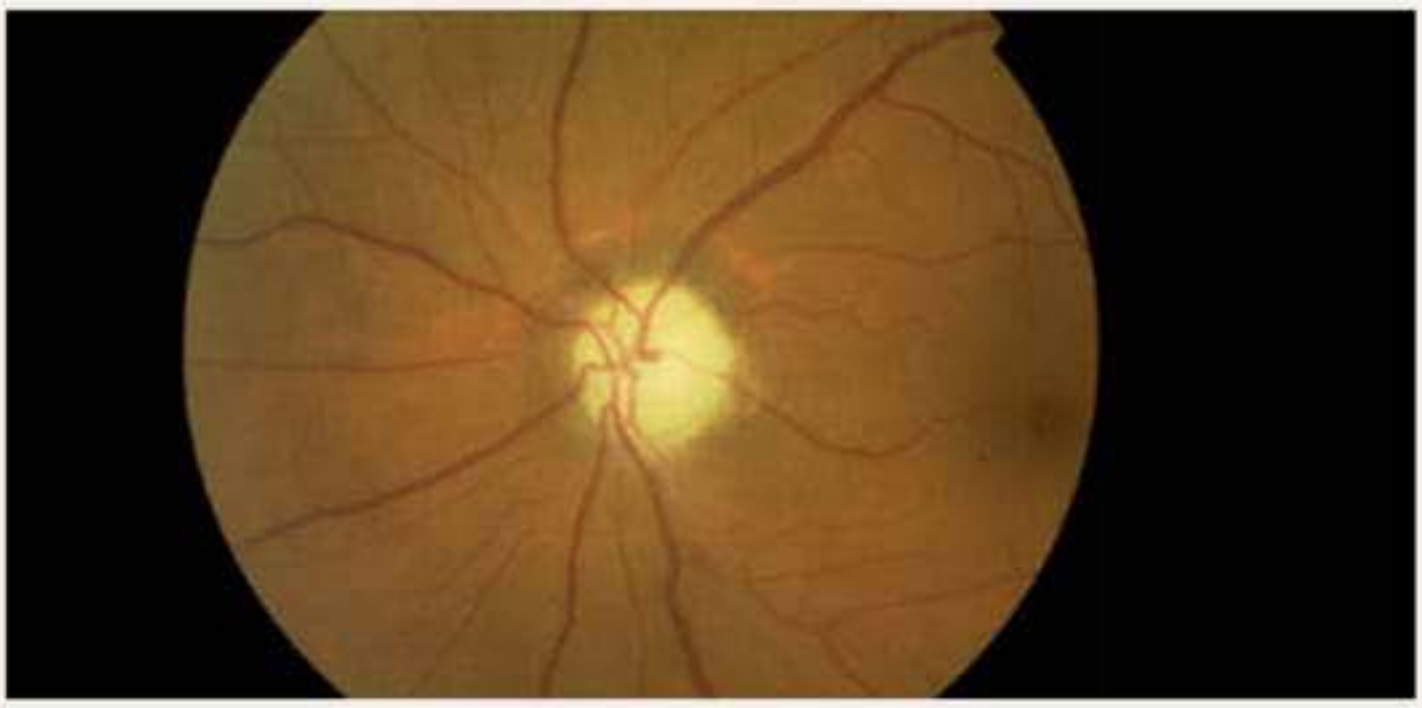

Which of the following is the most useful next investigation?

A	Autoimmune profile
B	Human immunodeficiency virus (HIV) serology
C	Lumbar puncture
D	Magnetic resonance imaging (MRI) brain with gadolinium
E	Visual evoked potentials

D	Magnetic resonance imaging (MRI) brain with gadolinium

This patient has symptoms suggestive of MS, with painless visual loss affecting the left eye and optic atrophy on the retinal image, and a history of ataxia. An MRI scan is likely to be abnormal, where 95% of patients with MS demonstrate periventricular lesions, and around 90% show discrete white matter abnormalities. It is non-invasive and is therefore the logical next step.

A	Autoimmune profile

Autoimmune profiling is unhelpful in the diagnosis of multiple sclerosis (MS), the likely diagnosis here. Autoimmune optic neuritis is seen in conjunction with vasculitides, particularly in systemic lupus erythematosus (SLE), although there are no other features here to suggest SLE as the underlying diagnosis.

B	Human immunodeficiency virus (HIV) serology

HIV can present as optic neuritis, although other features of HIV are absent from the scenario as described here.

C	Lumbar puncture

Although a rise in cerebrospinal fluid (CSF) immunoglobulins is seen in patients with MS, it is more appropriate to move to a non-invasive test such as magnetic resonance imaging (MRI) first.

E	Visual evoked potentials

Given the obvious left optic nerve atrophy, visual evoked potentials will be abnormal, but will not contribute as much to making the diagnosis as an MRI scan.

71590

Rate this question:

Next Question

A 77-year-old woman presents to the Clinical Pharmacology Clinic for review. Her general practitioner (GP) is concerned because he has noted the eye appearance shown below.

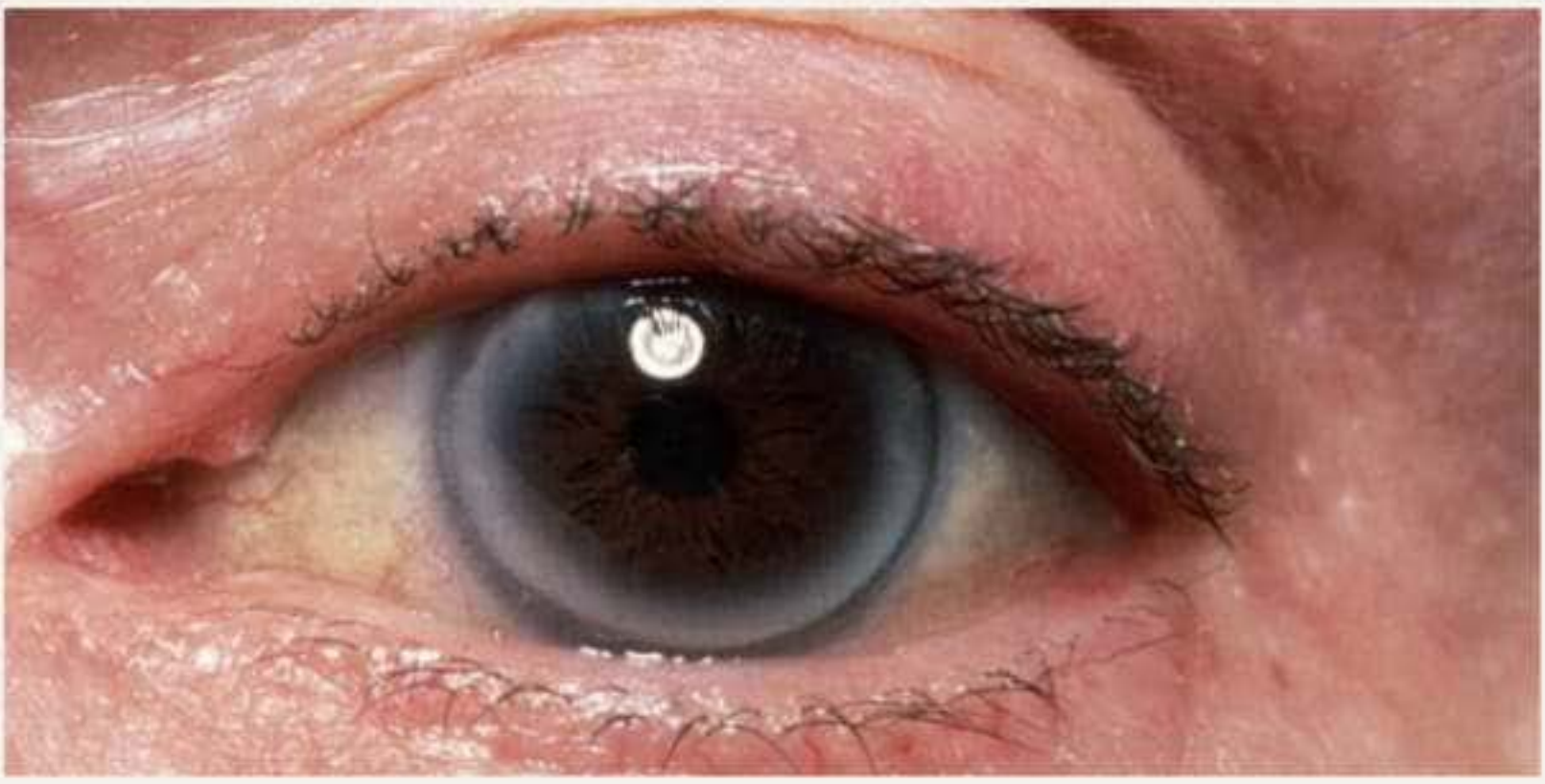

She has no significant past medical history.

Her blood pressure is 122/82 mmHg; her pulse is 70 bpm and regular. Her body mass index (BMI) is 24 kg/m^2. Her total cholesterol level is 4.5 mmol/l.

Which of the following is the most appropriate intervention?

A	Atorvastatin 10 mg
B	Fenofibrate 160 mg
C	Omega-3 supplement 1 g
D	Reassurance
E	Rosuvastatin 10 mg

71646

١٠:٥١ 4G 3G
mypastest.pastest.com

D	Reassurance

This patient has arcus senilis, also known as corneal arcus, which may be indicative of significant hypercholesterolaemia. Although in this case of an elderly patient with normal blood pressure and normal total cholesterol level without a history of cardiovascular disease, there should be no need to institute lipid-lowering therapy.

A	Atorvastatin 10 mg

Given this patient's normal total cholesterol level and a lack of a previous cardiovascular history, statin therapy is not appropriate here.

B	Fenofibrate 160 mg

Most evidence for the use of fibrates comes from its use in mixed dyslipidaemia and in patients with hypertriglyceridaemia. Evidence in this population supports their effectiveness in reducing triglyceride levels, although evidence to support an impact on outcomes is mixed, particularly against a background of statin use.

C	Omega-3 supplement 1 g

Omega-3 supplements are of most use in patients with hypertriglyceridaemia and low high-density lipoprotein (HDL) cholesterol levels. There is also evidence to support their use in secondary cardiovascular prevention. Here they are of limited value.

E	Rosuvastatin 10 mg

Rosuvastatin is not indicated here with a cholesterol level in the normal range and no history of previous cardiovascular disease.

A 75-year-old woman presents to the Emergency Department with sudden loss of vision affecting the upper field of vision of her left eye. She says it came on suddenly and she is now having difficulty perceiving even light and dark in the upper field of vision.

Over the past few months, she has suffered increasingly frequent temporal headaches, for which she has self-medicated with paracetamol and ibuprofen. Her blood pressure is 158/95 mmHg and her pulse is 75 bpm and regular. She is tender over both temporal arteries.

An image of her eye is shown below.

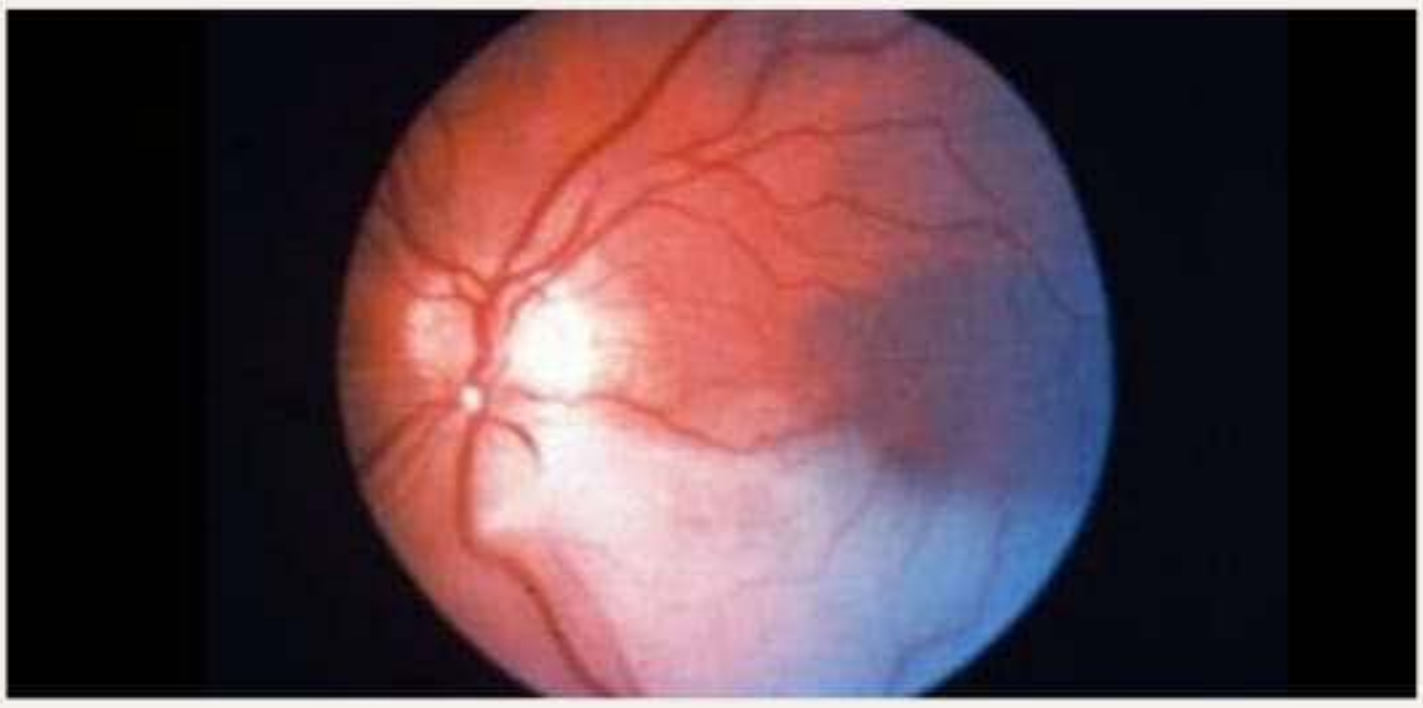

Which of the following is the most useful next investigation?

A	Autoimmune profile
B	24-hour electrocardiogram (ECG) recording
C	Erythrocyte sedimentation rate (ESR)
D	Thrombophilia screen
E	Transoesophageal echocardiogram (ECHO)

١٠:٥٥ 4G 3G

A 75-year-old woman presents to the Emergency Department with sudden loss of vision affecting the upper field of vision of her left eye. She says it came on suddenly and she is now having difficulty perceiving even light and dark in the upper field of vision.

Over the past few months, she has suffered increasingly frequent temporal headaches, for which she has self-medicated with paracetamol and ibuprofen. Her blood pressure is 158/95 mmHg and her pulse is 75 bpm and regular. She is tender over both temporal arteries.

An image of her eye is shown below.

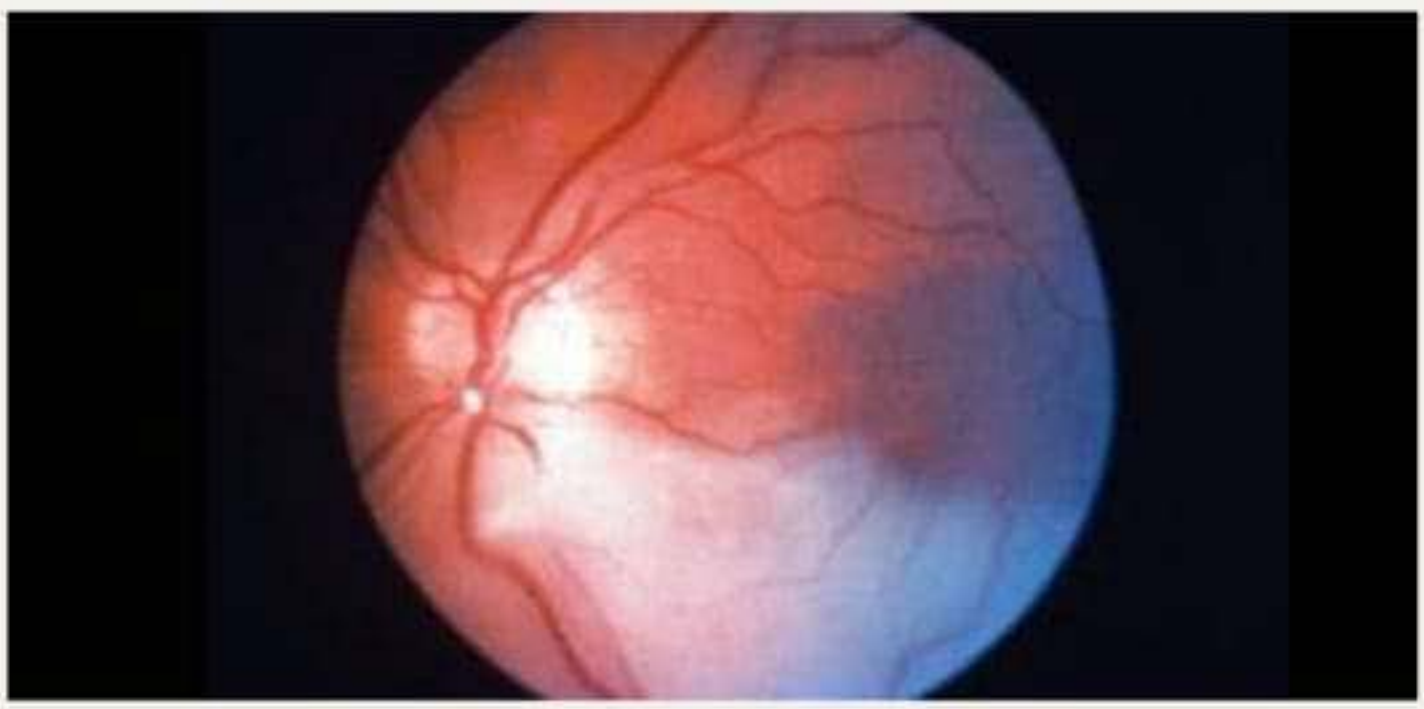

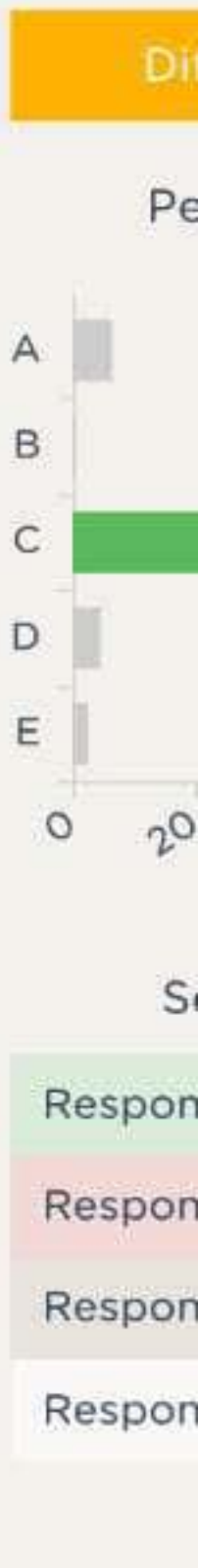

Which of the following is the most useful next investigation?

Your answer was correct

A	Autoimmune profile
B	24-hour electrocardiogram (ECG) recording
C	Erythrocyte sedimentation rate (ESR)
D	Thrombophilia screen
E	Transoesophageal echocardiogram (ECHO)

Explanation

Explanation

C	Erythrocyte sedimentation rate (ESR)

This patient's prolonged history of temporal headaches, coupled with a pale inferior retinal segment, is consistent with a branch retinal artery occlusion related to temporal arteritis. ESR is therefore the next investigation of choice in patients older than 50 years. In patients under 50 years, a thrombophilia screen is likely to be more useful.

A	Autoimmune profile

Autoantibodies are unhelpful in confirming a diagnosis of temporal arteritis. Both autoantibodies and complement levels are usually in the normal range when patients present with temporal arteritis.

B	24-hour electrocardiogram (ECG) recording

Embolism due to atrial fibrillation (AF) is less likely here, given that the patient presents in sinus rhythm and there is a history consistent with temporal arteritis.

D	Thrombophilia screen

Thrombophilia is more likely to be the cause of branch retinal artery occlusion in a younger patient; here, particularly given the history of headaches, temporal arteritis is much more likely.

E	Transoesophageal echocardiogram (ECHO)

Although intracardiac thrombus and subsequent embolism is a possible cause of branch retinal artery occlusion, in this patient temporal arteritis is more likely to be the cause.

71594

Rate this question:

Next Question

١٠:٥٥ 4G 3G
mypastest.pastest.com

A 26-year-old woman is referred by her general practitioner (GP) with a 24-h history of gradual deterioration in her right visual acuity, associated with pain on eye movement, to the extent that she can now only perceive light. She also complains of a general feeling of fatigue for the past few weeks. She has no other neurological symptoms.

There is nil to find on general examination but, on fundoscopy of her right eye, the optic disc appears to be swollen. Her left optic disc is normal in appearance.

What would be the most useful investigation to institute at this stage?

A	Lumbar puncture
B	Computed tomography (CT) scan head
C	Magnetic resonance imaging (MRI) scan head
D	Erythrocyte sedimentation rate (ESR) and C-reactive protein (CRP)
E	Visual evoked responses

70717

Submit

١١:٠٢ 4G 3G
mypastest.pastest.com

A 26-year-old woman is referred by her general practitioner (GP) with a 24-h history of gradual deterioration in her right visual acuity, associated with pain on eye movement, to the extent that she can now only perceive light. She also complains of a general feeling of fatigue for the past few weeks. She has no other neurological symptoms.

There is nil to find on general examination but, on fundoscopy of her right eye, the optic disc appears to be swollen. Her left optic disc is normal in appearance.

What would be the most useful investigation to institute at this stage?

Your answer was correct

A	Lumbar puncture
B	Computed tomography (CT) scan head
C	Magnetic resonance imaging (MRI) scan head
D	Erythrocyte sedimentation rate (ESR) and C-reactive protein (CRP)
E	Visual evoked responses

Explanation

C Magnetic resonance imaging (MRI) scan head

Explanation

C	Magnetic resonance imaging (MRI) scan head

The likely diagnosis here is optic neuritis (ON), which is a demyelinating inflammation of the optic nerve, and although it is strongly associated with multiple sclerosis (MS), it can also occur on its own.

Decreased visual acuity secondary to optic neuritis may be permanent. Optic neuritis affects Caucasians more commonly than other races and there is a male : female ratio of 1 : 2. Symptoms include a rapid decline in visual acuity in one eye (rarely both) associated with pain exacerbated by eye movement and dyschromatopsia (change in colour perception).

Typically, patients with first-time acute ON are otherwise healthy young adults. In some cases, a history of preceding viral illness may be present. In acute ON, the optic disc may appear normal since two-thirds of cases of ON are retrobulbar. However, the optic nerve may become pale over time.

Patients with MS may have recurrent attacks of ON. Therefore, a history of previous episodes of decreased vision in the same or the fellow eye must be sought. A previous history of neurological problems, such as transient episodes of extremity/facial numbness, weakness or pins and needles, suggests a diagnosis of MS. A family history of MS may exist.

In a typical case of ON without any clinical signs and symptoms of a systemic disease, the yield from blood tests is low and cerebrospinal fluid (CSF) examination is non-contributory to the diagnosis. MRI can be used to assess inflammatory changes in the optic nerves and helps exclude structural lesions.

A	Lumbar puncture

In a patient with unilateral papilloedema, imaging should be considered first before lumbar puncture is considered.

B	Computed tomography (CT) scan head

١١:٠٣ 4G 3G

over time.

Patients with MS may have recurrent attacks of ON. Therefore, a history of previous episodes of decreased vision in the same or the fellow eye must be sought. A previous history of neurological problems, such as transient episodes of extremity/facial numbness, weakness or pins and needles, suggests a diagnosis of MS. A family history of MS may exist.

In a typical case of ON without any clinical signs and symptoms of a systemic disease, the yield from blood tests is low and cerebrospinal fluid (CSF) examination is non-contributory to the diagnosis. MRI can be used to assess inflammatory changes in the optic nerves and helps exclude structural lesions.

A	Lumbar puncture

In a patient with unilateral papilloedema, imaging should be considered first before lumbar puncture is considered.

B	Computed tomography (CT) scan head

CT scanning, although useful in the acute situation to rule out a significant lesion, cannot achieve sufficient resolution to rule demyelination in or out as a potential diagnosis.

D	Erythrocyte sedimentation rate (ESR) and C-reactive protein (CRP)

These are non-specific indicators of inflammation and may not be elevated in patients with multiple sclerosis.

E	Visual evoked responses

These will confirm optic neuropathy, which is already suspected, although they will not contribute to determining the overall diagnosis.

70717

Rate this question:

Next Question

١١:٠٤ 4G 3G
mypastest.pastest.com

A 48-year-old woman presents to the Emergency Department with sudden-onset, painless visual loss affecting her right eye. She awoke from sleep to find that she could only perceive light and dark and was unable to drive to work because of this.

She has a history of recurrent miscarriage, although she has gone on to have one healthy child. Her medical history is otherwise unremarkable. She is anxious and has a blood pressure of 154/89 mmHg; her pulse is 78 bpm and regular.

A picture of her right retina is shown below.

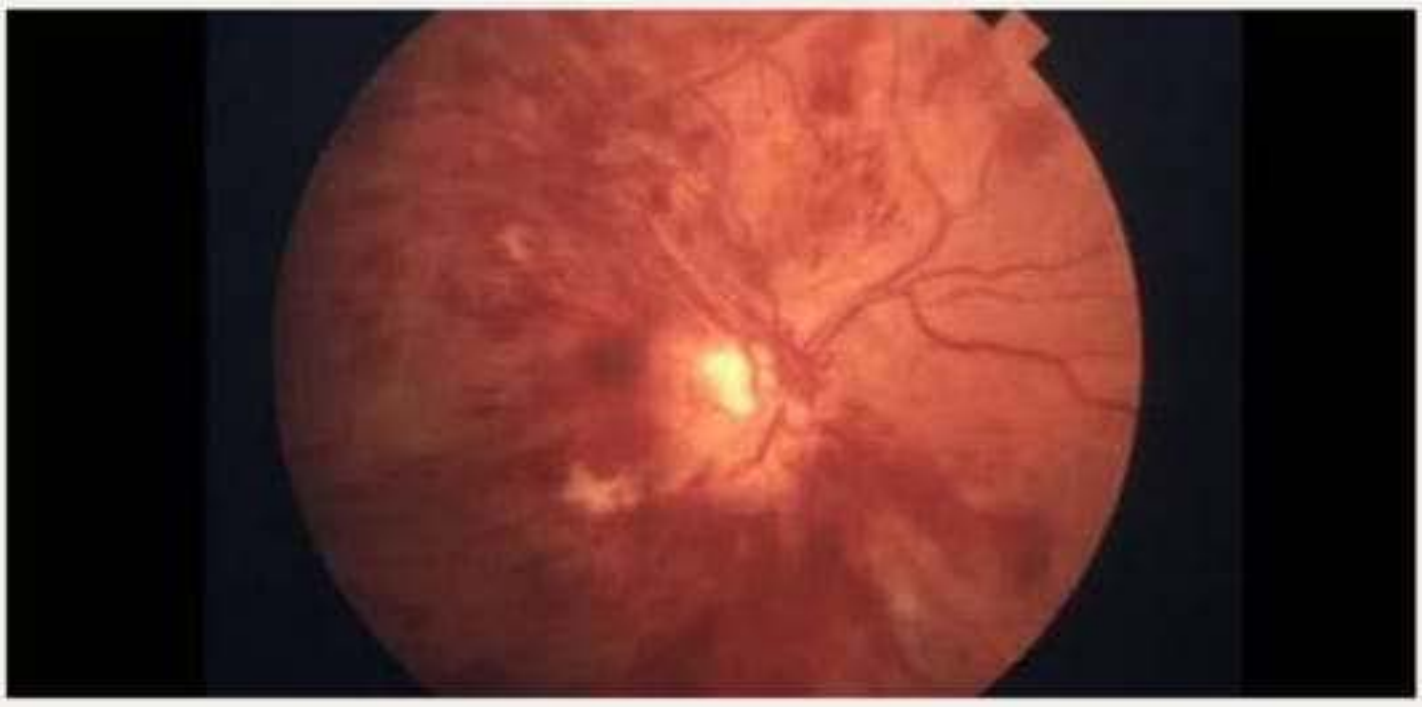

Which of the following is the most useful investigation?

A	Carotid angiography
B	Computed tomography (CT) renal angiogram
C	Intraocular pressure measurement
D	Thrombophilia screen
E	Ultrasound of both kidneys

A 48-year-old woman presents to the Emergency Department with sudden-onset, painless visual loss affecting her right eye. She awoke from sleep to find that she could only perceive light and dark and was unable to drive to work because of this.

She has a history of recurrent miscarriage, although she has gone on to have one healthy child. Her medical history is otherwise unremarkable. She is anxious and has a blood pressure of 154/89 mmHg; her pulse is 78 bpm and regular.

A picture of her right retina is shown below.

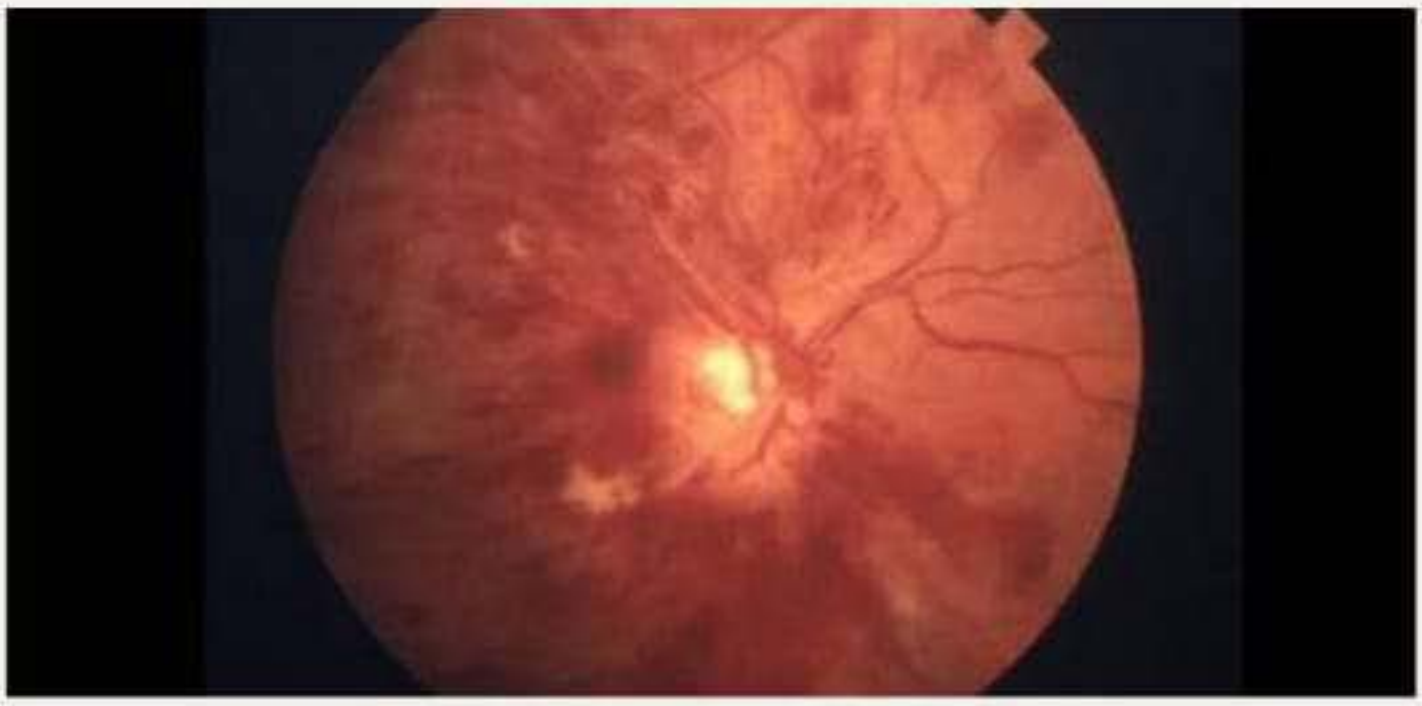

Which of the following is the most useful investigation?

Your answer was correct

A	Carotid angiography
B	Computed tomography (CT) renal angiogram
C	Intraocular pressure measurement
D	Thrombophilia screen
E	Ultrasound of both kidneys

Explanation

١١:٠٥ 4G 3G

Explanation

D	Thrombophilia screen

This patient has sudden visual loss, with extensive flame-shaped haemorrhages seen on the retinal photograph. This is consistent with CRVO, which fits with a history of recurrent miscarriage, which may be linked to an underlying thrombophilia. A screen for common causes of thrombophilia is therefore the most appropriate next step.

A	Carotid angiography

Carotid artery disease is suggested by central retinal vein occlusion (CRVO) associated with a pale retina, not with extensive haemorrhages as seen here.

B	Computed tomography (CT) renal angiogram

Although grade IV hypertensive retinopathy is associated with flame haemorrhages and may drive renal investigations, it is not suggested here by sudden visual loss. It is more likely to be associated by signs and symptoms of uncontrolled hypertension.

C	Intraocular pressure measurement

Visual loss with pain and a firm globe, consistent with raised intraocular pressure, is a sign of acute glaucoma. It is not associated with the retinal picture seen here; optic disc cupping is likely to be seen.

E	Ultrasound of both kidneys

The sudden visual loss is suggestive of CRVO, rather than hypertensive retinopathy as the cause of the flame haemorrhages seen on the retinal photograph. Only in the case of hypertensive retinopathy would an ultrasound be useful.

١١:٠٥ 4G 3G
mypastest.pastest.com

A 22-year-old woman presents to the Emergency Department complaining of conjunctivitis affecting her left eye. Apparently, she has suffered from multiple episodes of red eye over the past few years, which correspond to periods of stress or when she is run-down.

Examination reveals conjunctival injection with small vesicles around the lid margin. Fluorescein staining demonstrates a dendritic ulcer.

Which of the following is the most likely cause of her eye problem?

A	*Chlamydia trachomatis*
B	Herpes simplex infection
C	Herpes zoster infection
D	*Pseudomonas aeruginosa*
E	*Staphylococcus aureus*

71154

Submit

Previous Q... Skip Questi...

١١:٠٩ 4G 3G

plex keratitis | hsv keratitis | herpetic keratitis

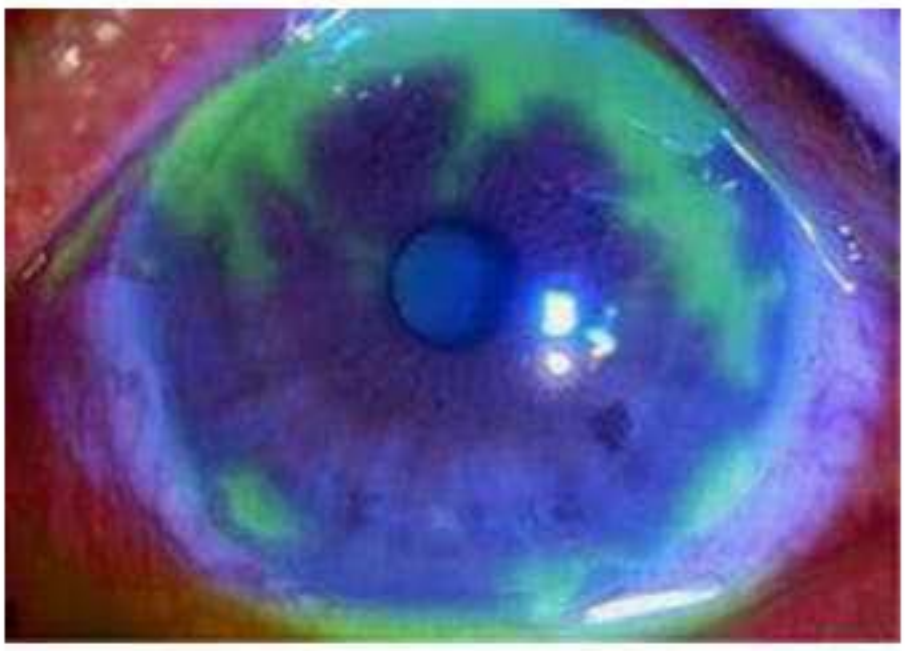

Herpes simplex keratitis - Wi...
en.wikipedia.org

Herpes simplex keratitis - Wi...
en.wikipedia.org

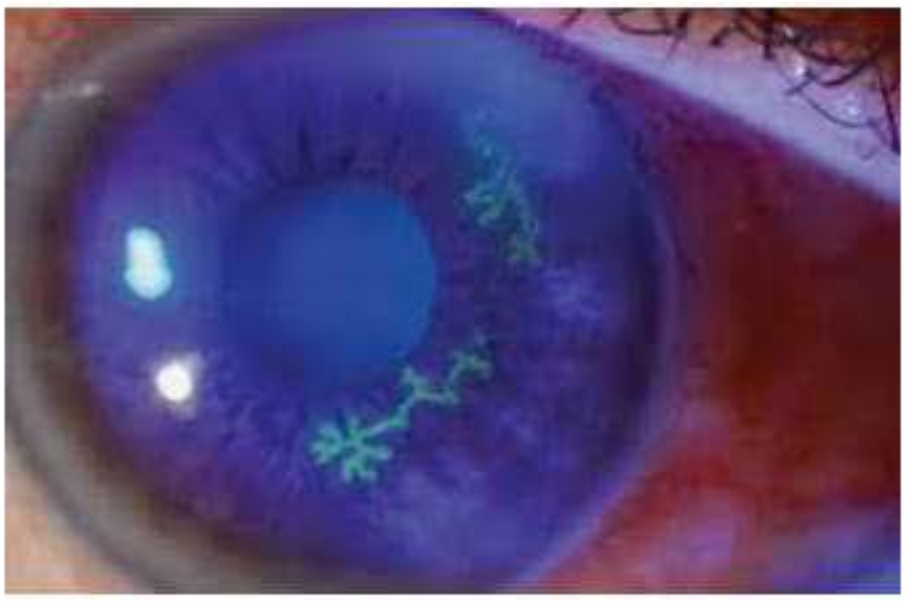

Photos For Herpes Simplex K...
medilinks.blogspot.com

Corneal ulcer - dendritic ulcer...
flickr.com

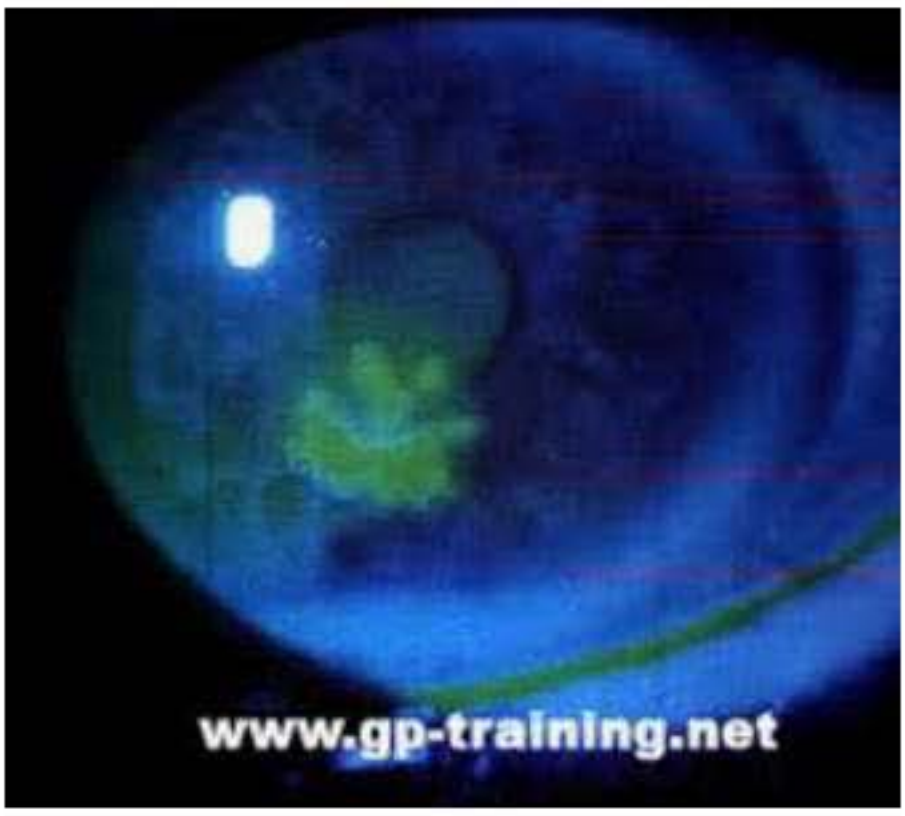

Herpetic keratitis
clinic.org.uk

المجموعات

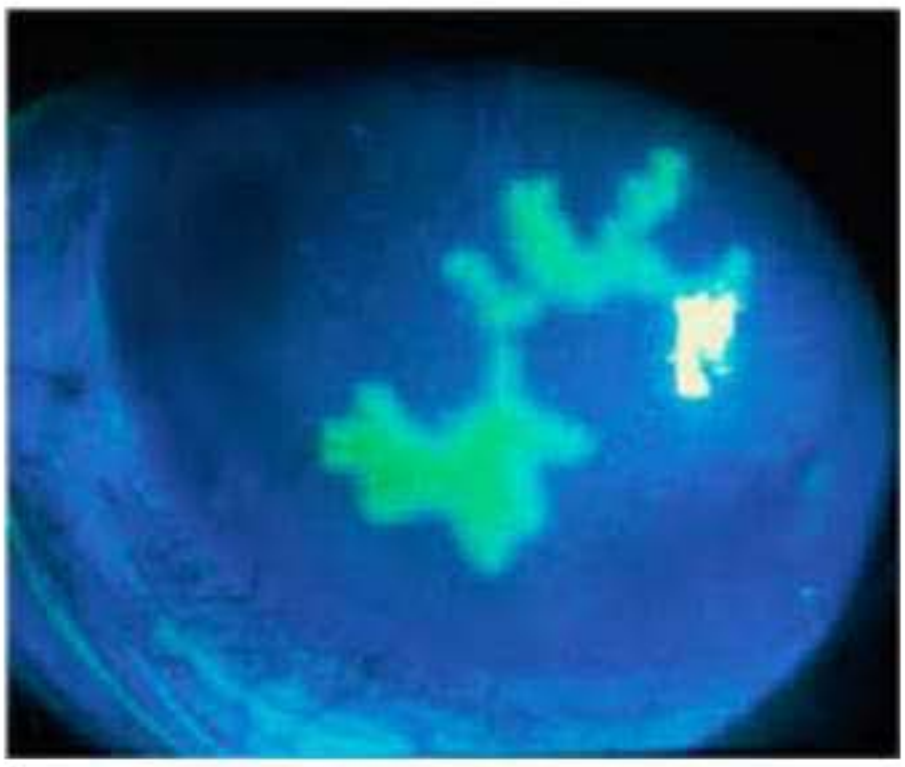

EyeWorld | Distinguishing den...
eyeworld.org

mypastest.pastest.com

A 22-year-old woman presents to the Emergency Department complaining of conjunctivitis affecting her left eye. Apparently, she has suffered from multiple episodes of red eye over the past few years, which correspond to periods of stress or when she is run-down.

Examination reveals conjunctival injection with small vesicles around the lid margin. Fluorescein staining demonstrates a dendritic ulcer.

Which of the following is the most likely cause of her eye problem?

Your answer was correct

A	*Chlamydia trachomatis*
B	Herpes simplex infection
C	Herpes zoster infection
D	*Pseudomonas aeruginosa*
E	*Staphylococcus aureus*

Explanation

B Herpes simplex infection

Recurrent conjunctivitis with formation of a dendritic ulcer raises the possibility of herpes simplex infection. Where there is epithelial keratitis and ulcer formation, topical antivirals such as aciclovir are the usual initial intervention.

Explanation

B	Herpes simplex infection

Recurrent conjunctivitis with formation of a dendritic ulcer raises the possibility of herpes simplex infection. Where there is epithelial keratitis and ulcer formation, topical antivirals such as aciclovir are the usual initial intervention.

A	*Chlamydia trachomatis*

Chlamydia leads to bacterial conjunctivitis rather than the picture here with ulcer formation.

C	Herpes zoster infection

Herpes zoster eye infection is associated with vesicle formation along the affected branch of the ophthalmic nerve, rather than infection being isolated to the eye.

D	*Pseudomonas aeruginosa*

Pseudomonas is a rare cause of bacterial conjunctivitis. It is an environmental pathogen and is usually only seen as a cause of conjunctivitis where there is an artificial implant within the eye.

E	*Staphylococcus aureus*

Staphylococcal conjunctivitis may be milder than bacterial conjunctivitis caused by Gram-negative pathogens; dendritic ulcers are not seen as a feature of the condition.

71154

Rate this question:

Next Question

mypastest.pastest.com

A 63-year-old, known to have poorly controlled type 2 diabetes, presented to the ophthalmologist on-call complaining of floaters and decreased vision. The ophthalmologist has recommended that the patient has treatment for proliferative diabetic retinopathy (PDR). There is evidence of macular oedema with extensive cotton wool spots, hard exudates and haemorrhages.

Which of the following interventions is most appropriate?

A	Dexamethasone
B	Infliximab
C	Ranibizumab
D	Toclizumab
E	Triamcinolone

71283

Submit

Previous Q... Skip Questi...

۱۱:۱۳ 4G 3G

C	Ranibizumab

Ranibizumab is a recombinant humanised antibody fragment which is active against all forms of vascular endothelial growth factor (VEGF)-A. It has been shown in a number of clinical trials to be effective in improving visual acuity and reducing progression of proliferative diabetic retinopathy.

A	Dexamethasone

Dexamethasone implants are used for patients with diabetic retinopathy who undergo cataract surgery, although steroid use in the general patient population may significantly increase intra-ocular pressure over time.

B	Infliximab

Infliximab is an anti-tumour necrosis factor (anti-TNF) antibody used in the treatment of inflammatory bowel disease and inflammatory arthritides. It is not used in the treatment of diabetic retinopathy.

D	Toclizumab

Toclizumab is an anti-IL6 monoclonal antibody used in the treatment of rheumatoid arthritis.

E	Triamcinolone

Intravitreal triamcinolone may be effective in relieving macular oedema in the short-term although, over the longer-term, it is associated with increased intra-ocular pressure.

71283

Rate this question:

Next Question

١١:١٩ 4G 3G
mypastest.pastest.com

A 38-year-old man, known to the Neurology Clinic with poorly controlled epilepsy, presents unscheduled to the Outpatient Department. He has defaulted from neurology follow-up, but tells you he has been seizure-free on his present medication. Attendance was prompted by recent optometrist assessment and the unexpected finding of reduced peripheral vision.

Past medical history is of epilepsy, substance abuse and tuberculosis. Current medication: sodium valproate, vigabatrin, lamotrigine and Rifater™ (isoniazid, rifampicin, pyrazinamide), and ethambutol.

On examination, he has severe constriction of visual fields; however, acuity, colour vision and fundoscopy are normal.

What change must you make to his medication?

A	Add pyridoxine
B	Stop sodium valproate
C	Stop ethambutol
D	Start thiamine supplements
E	Stop vigabatrin

70714

Submit

۱۱:۲۲ 4G 3G

optometrist assessment and the unexpected finding of reduced peripheral vision.

Past medical history is of epilepsy, substance abuse and tuberculosis. Current medication: sodium valproate, vigabatrin, lamotrigine and Rifater™ (isoniazid, rifampicin, pyrazinamide), and ethambutol.

On examination, he has severe constriction of visual fields; however, acuity, colour vision and fundoscopy are normal.

What change must you make to his medication?

Your answer was correct

A	Add pyridoxine
B	Stop sodium valproate
C	Stop ethambutol
D	Start thiamine supplements
E	Stop vigabatrin

Explanation

E	Stop vigabatrin

The anticonvulsant vigabatrin is now recognised to cause irreversible visual-field defects in up to 30% of users. The defect is often asymptomatic in the early stages, affecting only peripheral fields with no alteration in acuity. Changes can occur as early as one month into treatment. This side-effect was first noted in 1997 and, in recent years, the drug has been used only in cases of severe, treatment-resistant epilepsy, and Lennox–Gastaut syndrome in children. In cases where therapy is initiated, regular visual field screening is required. Other side-effects include depression, psychosis and sedation.

A	Add pyridoxine

E	Stop vigabatrin

The anticonvulsant vigabatrin is now recognised to cause irreversible visual-field defects in up to 30% of users. The defect is often asymptomatic in the early stages, affecting only peripheral fields with no alteration in acuity. Changes can occur as early as one month into treatment. This side-effect was first noted in 1997 and, in recent years, the drug has been used only in cases of severe, treatment-resistant epilepsy, and Lennox–Gastaut syndrome in children. In cases where therapy is initiated, regular visual field screening is required. Other side-effects include depression, psychosis and sedation.

A	Add pyridoxine

Pyridoxine is used to prevent peripheral neuropathy associated with isoniazid therapy.

B	Stop sodium valproate

Sodium valproate leads to weight gain and a polycystic ovarian syndrome-like picture in young women. It is not associated with significant ocular adverse effects.

C	Stop ethambutol

The antituberculous agent ethambutol causes optic neuritis and regular monitoring of acuity is required, particularly in patients with impaired renal function.

D	Start thiamine supplements

Thiamine is primarily utilised in patients with alcoholism and in pregnant women with hyperemesis gravidarum to prevent the development of Wernicke's encephalopathy.

70714

Rate this question:

Next Question

١١:٢٤ 4G 3G

A 24-year-old woman presents to the Emergency Department with sudden painless loss of vision affecting the upper portion of vision out of her right eye. She suffered a deep vein thrombosis (DVT) at age 18 years but has no other significant past medical history.

An image of her right retina is shown below.

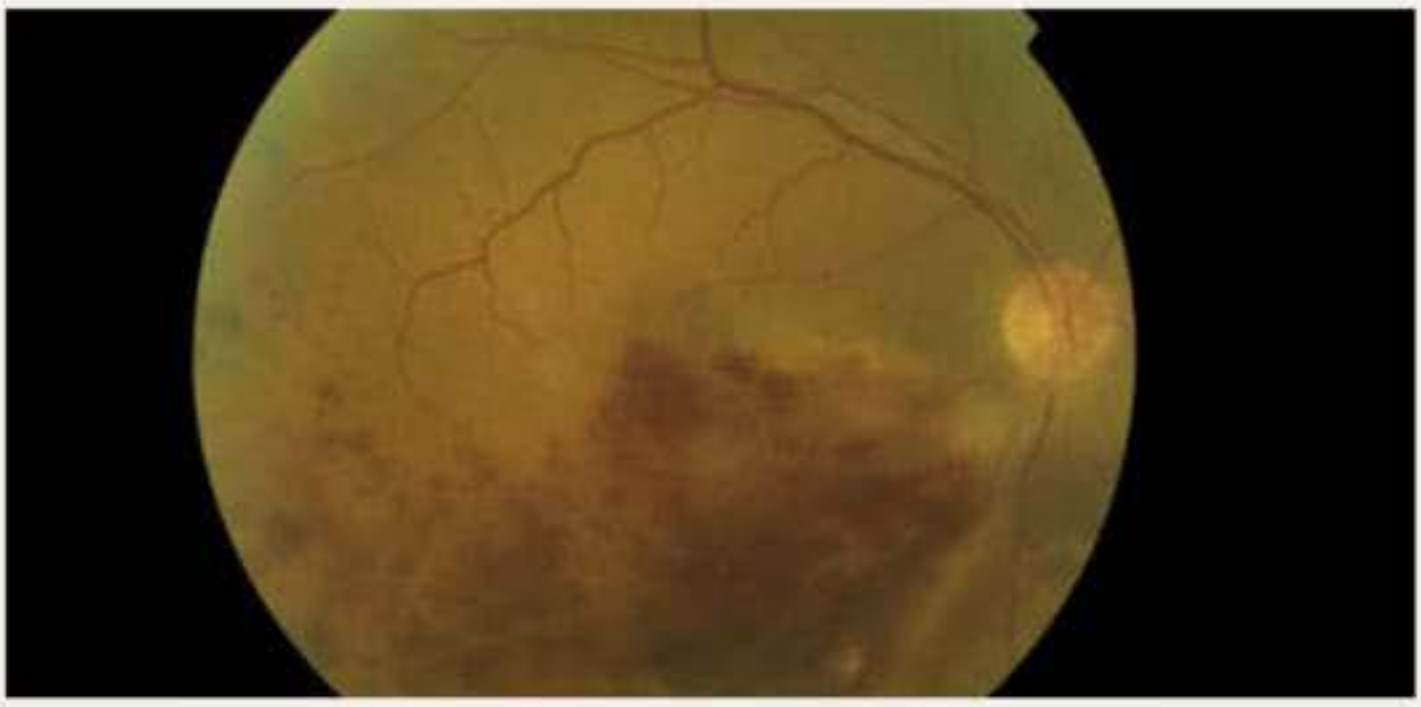

Her blood pressure is 132/82 mmHg, pulse is 88 bpm and regular, body mass index (BMI) is 24 kg/m^2.

Which is the best investigation for the underlying cause of this event?

A	24-hour ambulatory blood pressure monitoring
B	Fasting triglycerides
C	HbA1c
D	Immunoglobulin electrophoresis
E	Thrombophilia screen

71592

Submit

mypastest.pastest.com

A 24-year-old woman presents to the Emergency Department with sudden painless loss of vision affecting the upper portion of vision out of her right eye. She suffered a deep vein thrombosis (DVT) at age 18 years but has no other significant past medical history.

An image of her right retina is shown below.

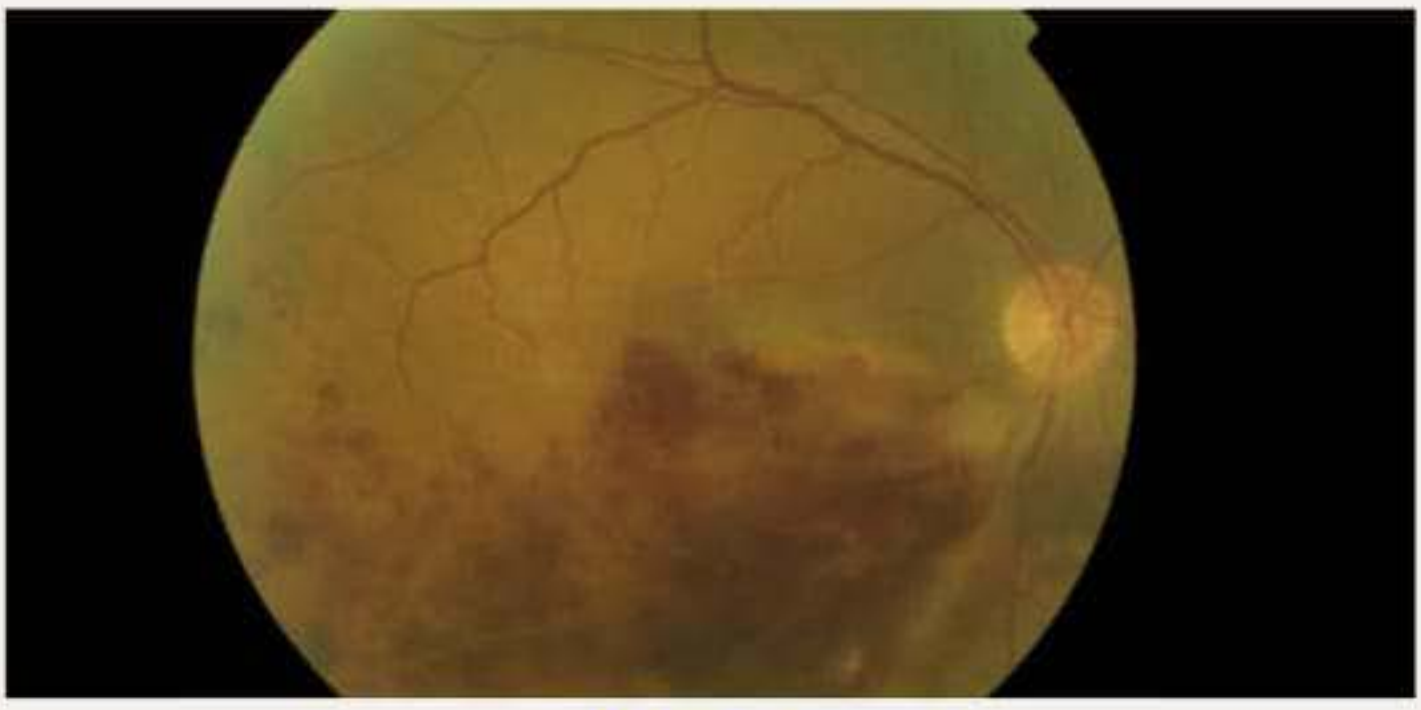

Her blood pressure is 132/82 mmHg, pulse is 88 bpm and regular, body mass index (BMI) is 24 kg/m².

Which is the best investigation for the underlying cause of this event?

Your answer was incorrect

A	24-hour ambulatory blood pressure monitoring
B	Fasting triglycerides
C	HbA1c
D	Immunoglobulin electrophoresis
E	Thrombophilia screen

Explanation

E	Thrombophilia screen

E Thrombophilia screen

The symptoms of loss of the upper portion of the field of vision, coupled with a previous history of DVT in a young woman, raise the possibility of an inherited thrombophilia leading to BRVO. Hence, a thrombophilia screen to rule out anti-phospholipid antibody syndrome, factor V Leiden mutation, protein C+S or antithrombin III deficiency is the most appropriate next step.

D Immunoglobulin electrophoresis

Haematological malignancy including myeloma is a recognised cause of retinal vein occlusion, although the age here makes myeloma unlikely, and there are no associated symptoms of haematological malignancy.

A 24-hour ambulatory blood pressure monitoring

This patient's blood pressure is in the normal range despite significant anxiety, and we are given no indication of hypertension as a cause for branch retinal vein occlusion (BRVO).

B Fasting triglycerides

Although hypertriglyceridaemia is associated with BRVO, this is usually in the presence of very high triglyceride levels (up to 10 mmol/l); the absence of other features of hypertriglyceridaemia counts against this as the underlying cause.

C HbA1c

Diabetes mellitus is a cause of thrombophilia but there is an absence of symptoms of hyperglycaemia here, and the BMI is in the normal range, making type 2 diabetes unlikely.

71592

Rate this question:

١١:٢٧ 4G 3G
mypastest.pastest.com

A 65-year-old woman with a past history of hypertension presents with progressive loss of vision and vague discomfort over the right eye during the last two days.

On examination, acuity is 6/36 in the affected eye, and 6/6 in the left eye. Blood pressure is 152/82 mmHg, pulse is 88/min and regular and she is anxious. Pupillary reactions are normal.

The fundoscopic appearance is shown below:

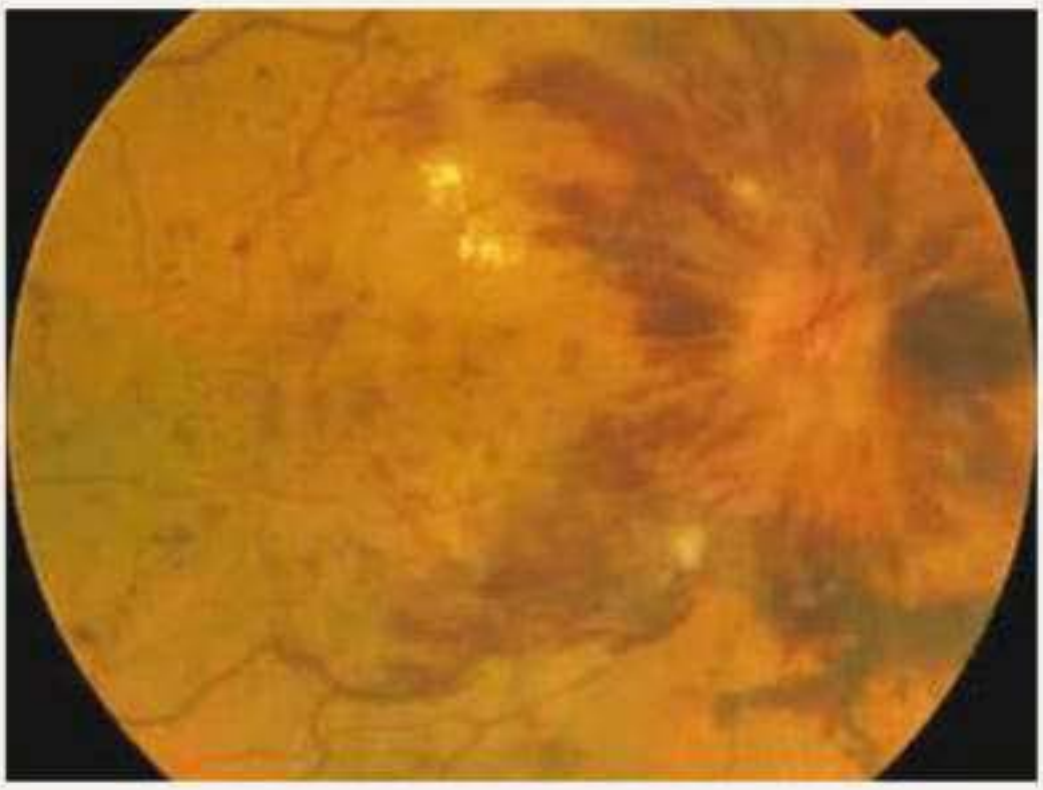

What is the most likely diagnosis?

A	Retinitis pigmentosa (RP)
B	Branch retinal artery occlusion (BRAO)
C	Branch retinal vein occlusion (BRVO)
D	Central retinal vein occlusion (CRVO)
E	Central retinal artery occlusion (CRAO)

١١:٢٨ 4G 3G

A 65-year-old woman with a past history of hypertension presents with progressive loss of vision and vague discomfort over the right eye during the last two days.

On examination, acuity is 6/36 in the affected eye, and 6/6 in the left eye. Blood pressure is 152/82 mmHg, pulse is 88/min and regular and she is anxious. Pupillary reactions are normal.

The fundoscopic appearance is shown below:

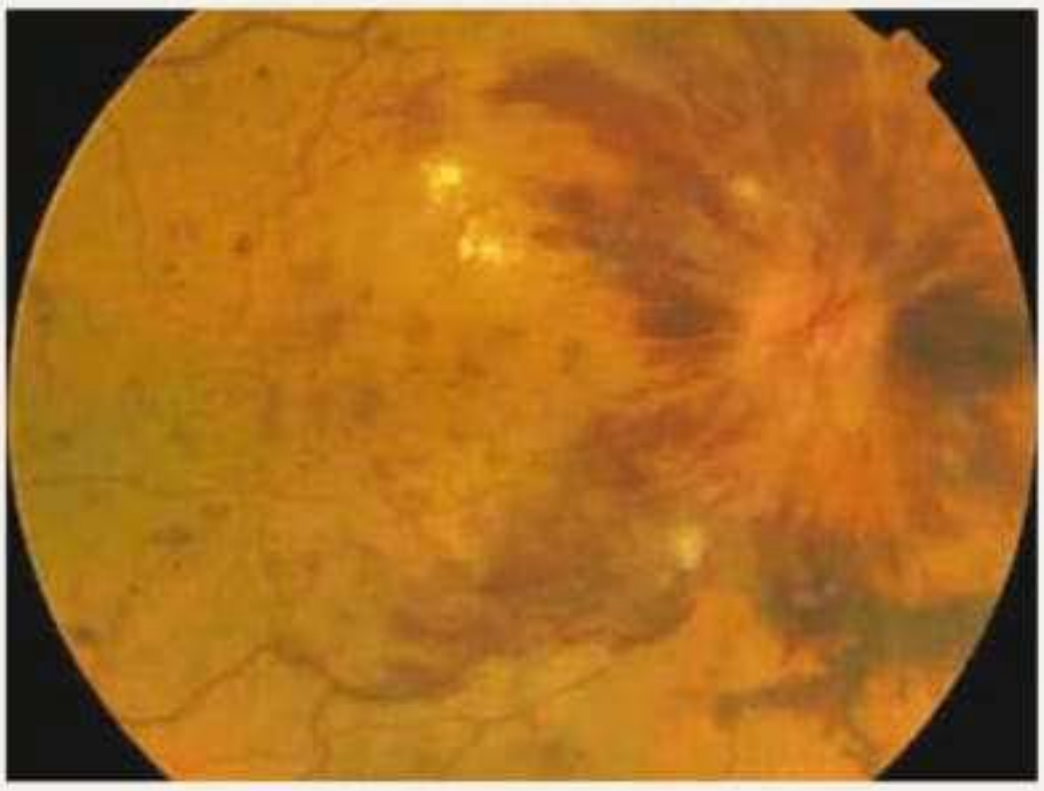

What is the most likely diagnosis?

Your answer was incorrect

A	Retinitis pigmentosa (RP)
B	Branch retinal artery occlusion (BRAO)
C	Branch retinal vein occlusion (BRVO)
D	Central retinal vein occlusion (CRVO)
E	Central retinal artery occlusion (CRAO)

Explanation

D	Central retinal vein occlusion (CRVO)

Explanation

D	Central retinal vein occlusion (CRVO)

This is an important cause of visual impairment in the middle-aged and elderly. A history of diabetes, hypertension, clotting disorders or vasculitis may predispose to CRVO. CRVO can be categorised into two types: ischaemic and non-ischaemic. However, this is not clear-cut in all patients and both types lead to visual loss. Fluorescein angiography can help to categorise patients into one of these subtypes rather than clinical examination, which can be inaccurate. Treatment can involve anti-vascular endothelial growth factor (anti-VEGF) intravitreal injections when associated with macular oedema and/or laser treatment. Treating the underlying hypertension is important to prevent recurrence of a similar event in the fellow eye.

C	Branch retinal vein occlusion (BRVO)

BRVO is associated with sectoral visual field loss and flame haemorrhages corresponding to the area of venous occlusion rather than the widespread changes seen here.

A	Retinitis pigmentosa (RP)

RP is associated with retinal pigment changes and progressive loss of peripheral vision at a much younger age than the patient presenting here.

B	Branch retinal artery occlusion (BRAO)

BRAO is associated with sectoral visual field loss with a pale area of retina corresponding to the arterial occlusion. There are usually associated risk factors for arterial embolism.

E	Central retinal artery occlusion (CRAO)

CRAO is associated with sudden loss of vision with a pale retina. There may be a cherry red spot corresponding to preserved blood supply from the posterior ciliary artery.

١:٣١ 3G 3G
mypastest.pastest.com

A 65-year-old man presents to the Emergency Department with reduced vision in the right eye noticed while taking a photograph.

On examination, he has a right afferent pupillary defect and the following appearance on fundoscopy:

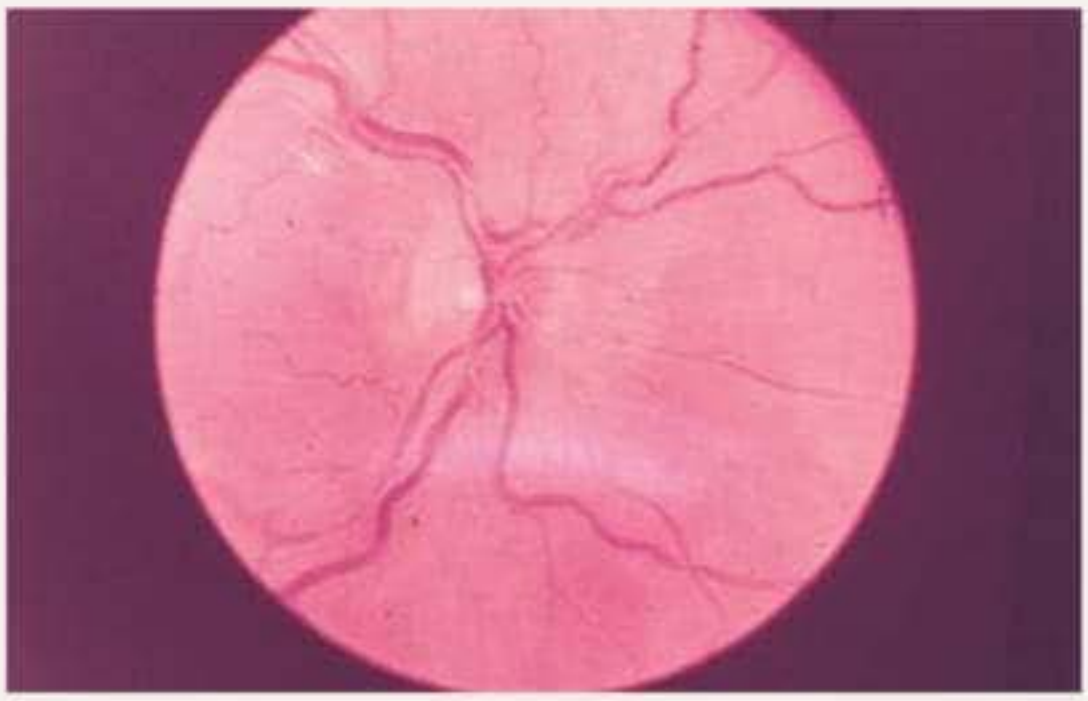

What is the most likely underlying diagnosis?

A	Toxoplasma chorioretinitis
B	Hypertensive retinopathy
C	Central retinal vein occlusion
D	Branch retinal artery occlusion
E	Multiple sclerosis

70725

Submit

١:٣٢ 3G 3G

Explanation

B	Hypertensive retinopathy

The slide shows a fundus with a grade 4 hypertensive retinopathy with optic disc oedema, cotton-wool spots and widespread A-V nipping. The retina looks oedematous. The other features one may see are flame-shaped retinal haemorrhages and hard exudate; which may collect around the fovea producing a 'macula star'. The presence of end-organ damage like this dictates the urgency with which this condition is managed. Obviously the blood pressure needs to be recorded and controlled. The diagnosis of hypertensive retinopathy is made by the presence of these retinal features in association with severely raised blood pressure.

D	Branch retinal artery occlusion

Branch retinal artery occlusions are also seen in patients with hypertension and other cardiovascular risk factors. Patients typically present with a sudden, painless altitudinal visual field defect. However, they are typically associated with whitish opacification of a region of the retina corresponding to the area of vascular occlusion. On careful examination, emboli can often be seen at the point of vascular occlusion - the commonest emboli are 1) cholesterol, 2) fibrinoplatelet, 3) calcific.

A	Toxoplasma chorioretinitis

This is not the appearance of chorioretinitis (which may be caused by Toxoplasma), or dysthyroid eye disease. The latter can cause optic atrophy from optic nerve compression if there is increased pressure in the orbit.

C	Central retinal vein occlusion

Although central retinal vein occlusions are commonly associated with high blood pressure, they have a different clinical appearance to that seen here. They typically present with severe unilateral visual loss associated with retinal haemorrhages distributed around all four quadrants

١:٣٢ 3G 3G

Branch retinal artery occlusions are also seen in patients with hypertension and other cardiovascular risk factors. Patients typically present with a sudden, painless altitudinal visual field defect. However, they are typically associated with whitish opacification of a region of the retina corresponding to the area of vascular occlusion. On careful examination, emboli can often be seen at the point of vascular occlusion - the commonest emboli are 1) cholesterol, 2) fibrinoplatelet, 3) calcific.

A	Toxoplasma chorioretinitis

This is not the appearance of chorioretinitis (which may be caused by Toxoplasma), or dysthyroid eye disease. The latter can cause optic atrophy from optic nerve compression if there is increased pressure in the orbit.

C	Central retinal vein occlusion

Although central retinal vein occlusions are commonly associated with high blood pressure, they have a different clinical appearance to that seen here. They typically present with severe unilateral visual loss associated with retinal haemorrhages distributed around all four quadrants of the retina (in severe cases, this is referred to as a "blood and thunder" fundus appearance).

E	Multiple sclerosis

Multiple sclerosis may cause papillitis, with blurring of the optic disc margins. However, it typically occurs in younger patients and is not commonly associated with retinal haemorrhages or exudates.

70725

Rate this question:

Next Question

Previous Q... Tag Questi... Feedback End Session

١:٣٢ 3G 3G

A 34-year-old man presents to the Emergency Department with general malaise and a red eye (see photograph below). He describes an intense, dull, aching sensation in the eye itself and around the orbital area, as well as blurred vision.

Over the past week, he has had a sore throat and intermittent fever and has had a course of antibiotics from his general practitioner (GP). He then developed bilateral swollen knees and ankles with a rash over both shins. Visual acuity is 6/6 in the right eye and 6/24 in the left (affected) eye.

Photograph courtesy of David Yorston and Marcia Zondervan, Community Eye Health Vol. 18 No. 53 2005 pp 72

What is the most likely ophthalmological diagnosis?

A	Acute anterior uveitis
B	Episcleritis
C	Bacterial conjunctivitis
D	Toxocara
E	Herpes zoster conjunctivitis

١:٤٤ 3G 3G
mypastest.pastest.com

A 34-year-old man presents to the Emergency Department with general malaise and a red eye (see photograph below). He describes an intense, dull, aching sensation in the eye itself and around the orbital area, as well as blurred vision.

Over the past week, he has had a sore throat and intermittent fever and has had a course of antibiotics from his general practitioner (GP). He then developed bilateral swollen knees and ankles with a rash over both shins. Visual acuity is 6/6 in the right eye and 6/24 in the left (affected) eye.

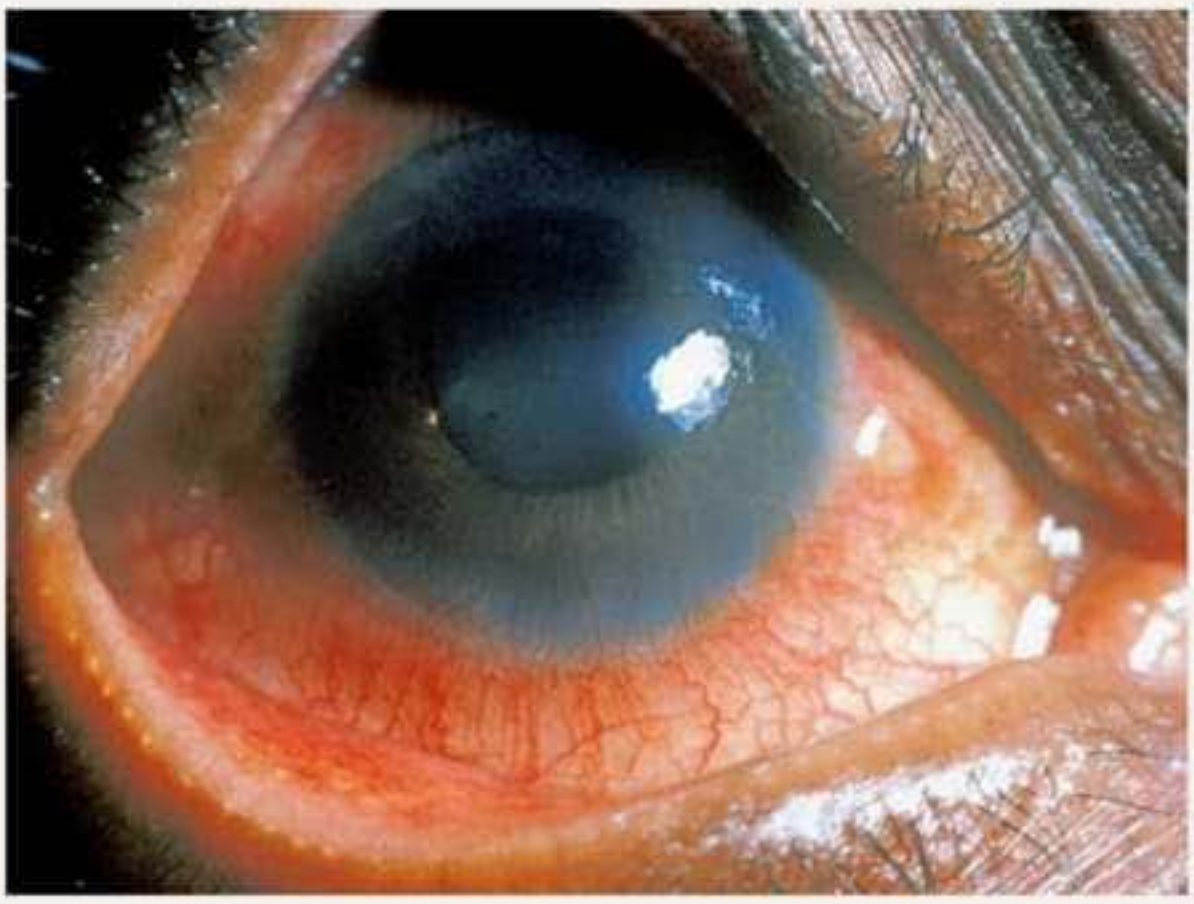

Photograph courtesy of David Yorston and Marcia Zondervan, Community Eye Health Vol. 18 No. 53 2005 pp 72

What is the most likely ophthalmological diagnosis?

Your answer was correct

A	Acute anterior uveitis
B	Episcleritis

D
P
A
B
C
D
E
0 10
S
Respo
Respo
Respo
Respo

١:٤٤ 3G 3G

Explanation

A	Acute anterior uveitis

This condition is seen mainly in young people and may occasionally be associated with systemic conditions such as a seronegative arthropathy (ankylosing spondylitis, reactive arthritis, inflammatory bowel disease or psoriatic arthropathy), sarcoidosis, syphilis, herpes and toxoplasmosis. Presentation is with a red, painful eye, and reduced visual acuity to a varying degree. The pupil may react poorly to light. The patient should be seen by an ophthalmologist within 24 hours for slit lamp diagnosis. Treatment is then with topical steroids and mydriatic drops. The majority of cases are idiopathic but, on the first episode, appropriate investigations for underlying systemic disease could be carried out if there is a suspicion of this.

B	Episcleritis

It is considered to have a much milder disease course and is not usually associated with any other ocular complications.

C	Bacterial conjunctivitis

It is usually bilateral with a pustular discharge and does not affect visual acuity. It is also not associated with the other extra-ocular features seen here.

D	Toxocara

It is a rare cause of isolated acute anterior uveitis and usually presents with a white pupil, coupled with evidence of retinal fibrosis and detachment.

E	Herpes zoster conjunctivitis

This case lacked associated cutaneous changes consistent with local herpes infection, where typical herpetic ulcers are seen along the ophthalmic branch of the trigeminal nerve.

Retinal Vein Occlusion

- BRVO

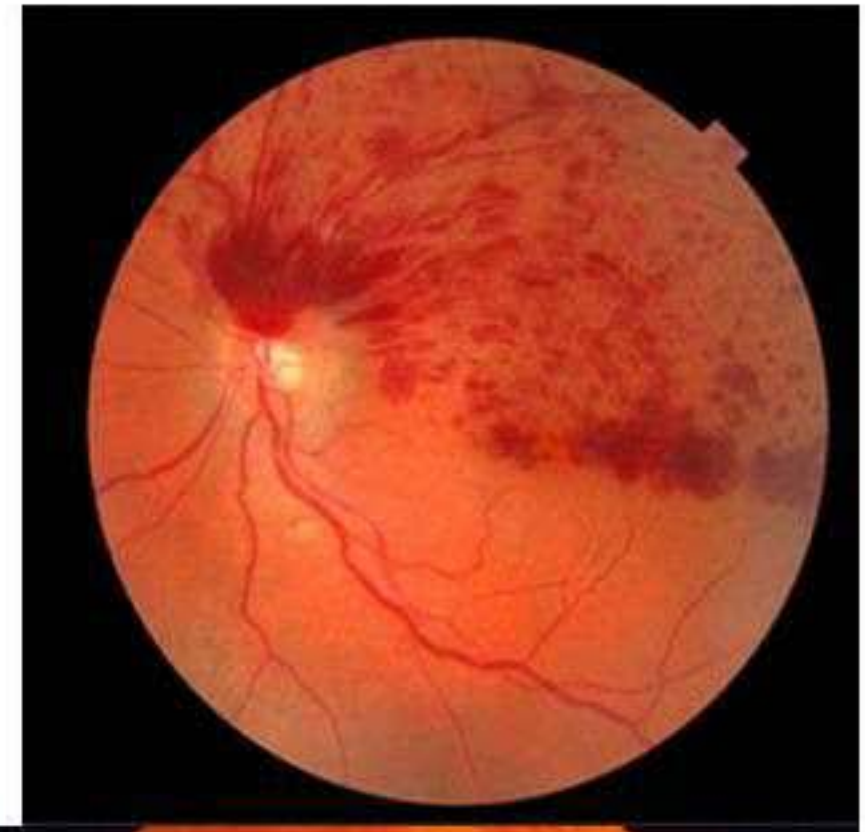

- CRVO

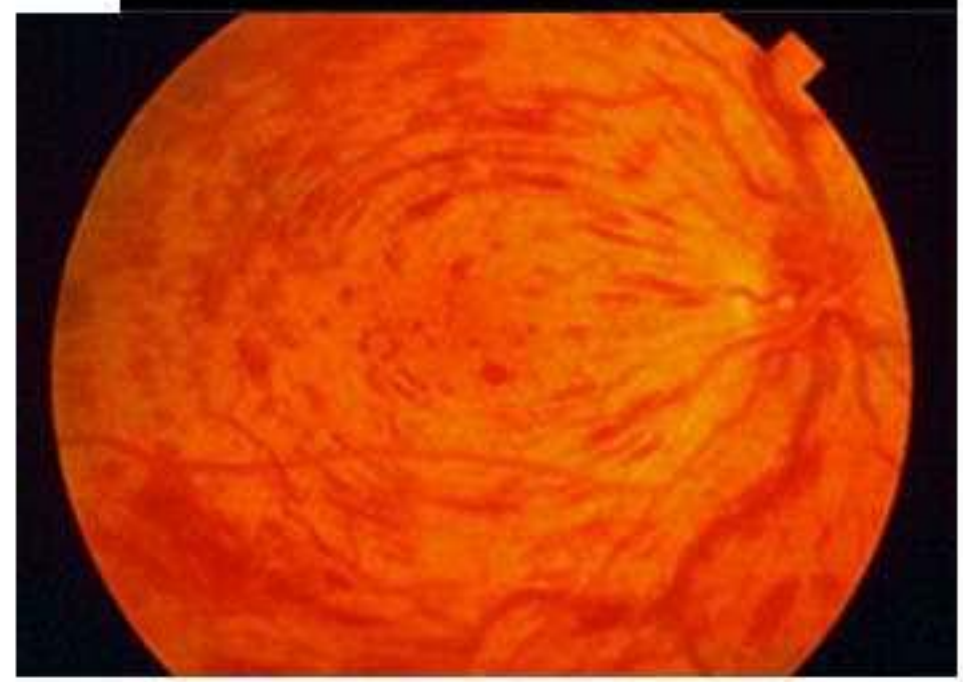

An 26-year-old woman presents to the Eye Clinic, following a referral from the optometrist. She presented with difficulty with the centre of her vision and at night. She tells you that her father progressively lost sight until he went blind at the age of 46.

General physical examination is unremarkable.

A picture of her left retina is shown below.

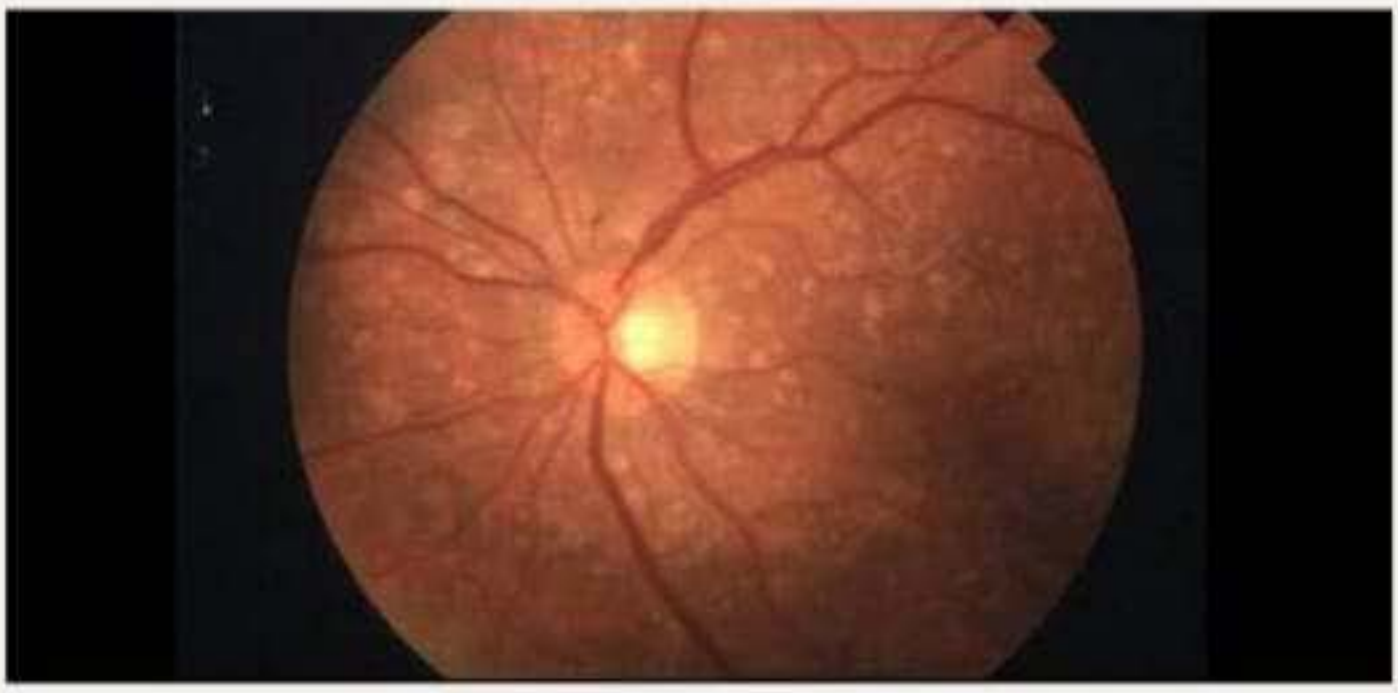

The right retina has similar changes.

Which of the following is the most appropriate next investigation?

A	Vitamin B_{12} levels
B	Fasting blood glucose
C	Folic acid levels
D	Genetic testing
E	Vitamin A levels

71637

Submit

Previous Q...

Skip Questi...

١:٤٩ 4G 3G
mypastest.pastest.com

An 26-year-old woman presents to the Eye Clinic, following a referral from the optometrist. She presented with difficulty with the centre of her vision and at night. She tells you that her father progressively lost sight until he went blind at the age of 46.

General physical examination is unremarkable.

A picture of her left retina is shown below.

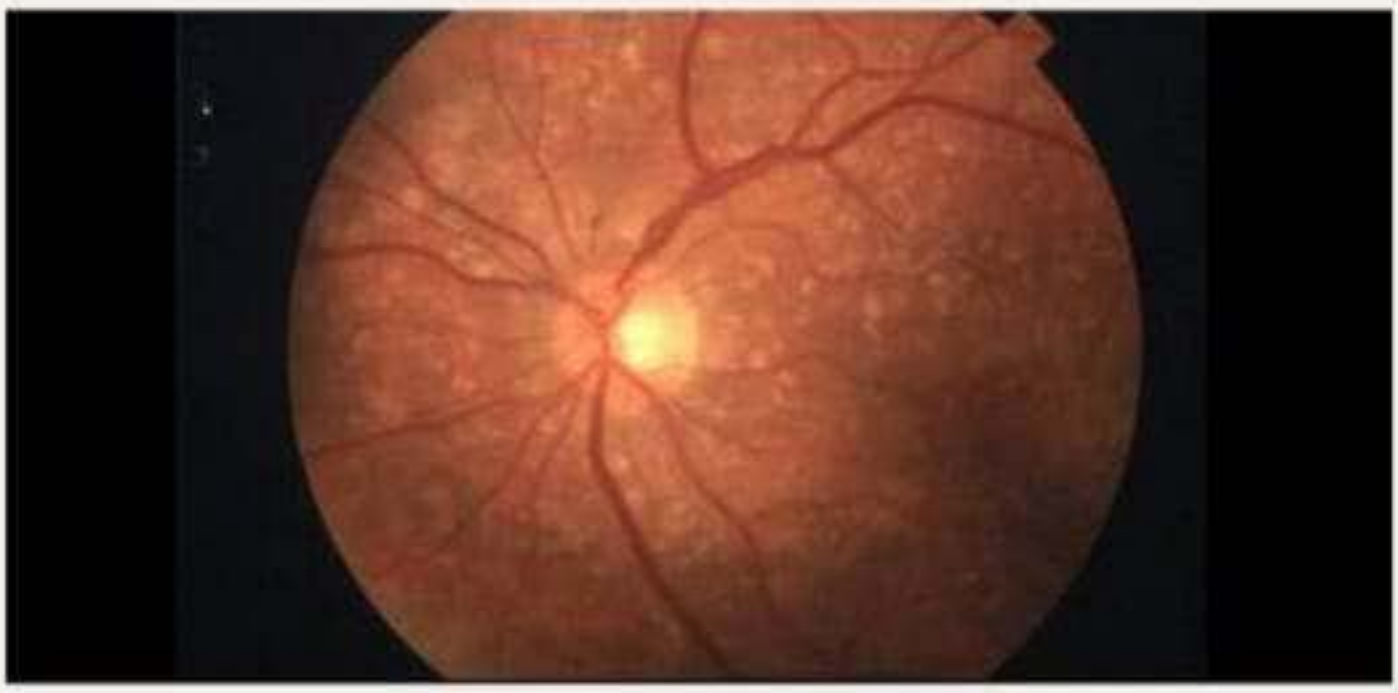

The right retina has similar changes.

Which of the following is the most appropriate next investigation?

Your answer was incorrect

A	Vitamin B_{12} levels
B	Fasting blood glucose
C	Folic acid levels
D	Genetic testing
E	Vitamin A levels

Explanation



١:٤٩ 4G 3G

Explanation

D	Genetic testing

The scenario here showing deteriorating visual acuity in an 18-year-old with extensive drusen and a history of blindness in the family fits with an autosomal dominant condition. The most likely diagnosis is malattia leventinese, an autosomal dominant cause of blindness which results in a deterioration of the Bruch's membrane. A mutation which causes the disease has been mapped to chromosome 2.

E	Vitamin A levels

Drusen are a feature of age-related macular degeneration, which may be positively impacted upon by vitamin A supplementation. However, the evidence here is for an autosomal dominant disorder such as malattia leventinese.

A	Vitamin B_{12} levels

Vitamin B_{12} deficiency results in optic neuropathy, with optic disc pallor and loss of visual acuity, rather than the picture seen here with extensive drusen.

B	Fasting blood glucose

Features of diabetic retinopathy include haemorrhages, hard exudates and cotton-wool spots, rather than the picture seen here with drusen.

C	Folic acid levels

Like vitamin B_{12} deficiency, folate deficiency results in the development of optic neuropathy, which is reversible on the introduction of folic acid replacement.

71637

Rate this question:

Next Question

١:٤٩ 4G 3G

A 31-year-old housewife attends the Diabetic Clinic for her annual review. She has been an insulin-dependent diabetic for eight years and her blood sugar level is usually between 5 and 9 mmol/l. She leads a sedentary lifestyle, is obese and smokes about 10 cigarettes/day.

On examination, her blood pressure is 140/95 mmHg and her pulse is 68 bpm and regular.

Blood results:

Hb	13.4 g/dl
WCC	5.2×10^9/l
MCV	78 fl
plts	214×10^9/l
Hb A_{1c}	8.5 mmol/mol
Na	135 mmol/l
K	4.0 mmol/l
urea	7.3 mmol/l
creatinine	131 mmol/l
24-hour urine protein	30 mg
Fundoscopy	Normal

How often would you screen this patient for retinopathy?

A	Every two years
B	Every six months
C	Annually
D	No need for screening for the next five years
E	Screening only when she has visual symptoms

١:٥٨ 4G 3G
mypastest.pastest.com

A 31-year-old housewife attends the Diabetic Clinic for her annual review. She has been an insulin-dependent diabetic for eight years and her blood sugar level is usually between 5 and 9 mmol/l. She leads a sedentary lifestyle, is obese and smokes about 10 cigarettes/day.

On examination, her blood pressure is 140/95 mmHg and her pulse is 68 bpm and regular.

Blood results:

Hb	13.4 g/dl
WCC	5.2×10^9/l
MCV	78 fl
plts	214×10^9/l
Hb A_{1c}	8.5 mmol/mol
Na	135 mmol/l
K	4.0 mmol/l
urea	7.3 mmol/l
creatinine	131 mmol/l
24-hour urine protein	30 mg
Fundoscopy	Normal

A
B
C
D
E
O

Re
Re
Re
Re

NH
nhs

How often would you screen this patient for retinopathy?

Your answer was correct

١:٥٨ 4G 3G

C	Annually

All people with type I and type II diabetes are offered annual retinal screening under the NHS Diabetic Retinopathy screening program. Those patients with diabetic retinopathy are followed up more frequently via the Ophthalmology Service.

A	Every two years

Every two years is incorrect. All people with type I and type II diabetes are offered annual retinal screening under the NHS Diabetic Retinopathy screening program.

B	Every six months

Every six months is incorrect. In the first instance, screening should be offered annually. If the patient is then found to have retinopathy, the Opthalmology Department may choose to review her more frequently.

D	No need for screening for the next five years

No need for screening for the next five years is incorrect because it does not follow the guidelines of the National Diabetic Retinopathy Screening program - it is recommended that diabetics are screened at least annually for retinopathy.

E	Screening only when she has visual symptoms

Screening only when she has visual symptoms is incorrect. All people with type I and type II diabetes are offered annual retinal screening under the NHS Diabetic Retinopathy screening program, regardless of their visual status/symptoms.

Rate this question:

١:٥٨ 4G 3G
mypastest.pastest.com

A 53-year-old woman presents to the accident and emergency department complaining of a reduction in her left vision noticed upon waking the same morning. She feels otherwise well. She reports no pain. Her past medical history is only significant for polymyalgia rheumatica for which she takes 2.5 mg prednisolone once daily and says this has been associated with a general reduction in the frequency of her headaches although they have not gone away completely.

On examination of her eyes, the Snellen visual acuity is recorded as 6/9 in her right eye and 6/36 in her left eye. The left fundus is pale and there is diffuse optic disc swelling. No cotton wool spots or haemorrhages were seen in the periphery. The right fundus appeared normal.

What is the most likely diagnosis of the visual loss?

A	Central retinal vein occlusion
B	Central retinal artery occlusion
C	Glaucoma
D	Papilloedema
E	Acute anterior ischaemic optic neuropathy

70720

Submit

٢:٠٨ 4G 3G

E	Acute anterior ischaemic optic neuropathy

A close association exists between giant cell arteritis (GCA) and polymyalgia rheumatica. Both diseases frequently affect the same individuals. GCA is a systemic inflammatory vasculitis of unknown aetiology that affects medium- and large-sized arteries. It occurs more commonly in women and almost exclusively in patients older than 50 years of age. Visual symptoms manifest in around 50% of patients with GCA with the commonest cause of visual loss being anterior ischaemic optic neuropathy (AION). This condition results from ischemia of the optic nerve head which is supplied by the posterior ciliary arteries and typically presents with a chalky white oedematous optic disc.

A	Central retinal vein occlusion

Central retinal vein occlusion is incorrect because it tends to have other signs evident in the fundus (eg haemorrhages, cotton wool spots). This patient's history of polymyalgia would also point towards temporal arteritis as the cause of her symptoms.

B	Central retinal artery occlusion

Central retinal artery occlusion is incorrect because in this condition, the fundus is pale with a cherry red spot at the macula and no disc swelling.

C	Glaucoma

Glaucoma is incorrect because the findings do not present a swollen disc. The patient's past history would make temporal arteritis a more likely diagnosis.

D	Papilloedema

Papilloedema is incorrect. The patient would be expected to have bilateral disc swelling with papilloedema; however, her right eye is normal.

70720

Rate this question:

٢:٠٨ 4G 3G
mypastest.pastest.com

A 53-year-old woman presents to the accident and emergency department complaining of a reduction in her left vision noticed upon waking the same morning. She feels otherwise well. She reports no pain. Her past medical history is only significant for polymyalgia rheumatica for which she takes 2.5 mg prednisolone once daily and says this has been associated with a general reduction in the frequency of her headaches although they have not gone away completely.

On examination of her eyes, the Snellen visual acuity is recorded as 6/9 in her right eye and 6/36 in her left eye. The left fundus is pale and there is diffuse optic disc swelling. No cotton wool spots or haemorrhages were seen in the periphery. The right fundus appeared normal.

What is the most likely diagnosis of the visual loss?

Your answer was correct

A	Central retinal vein occlusion
B	Central retinal artery occlusion
C	Glaucoma
D	Papilloedema
E	Acute anterior ischaemic optic neuropathy

A
B
C
D
E
0

Resp
Resp
Resp
Resp

Explanation

E	Acute anterior ischaemic optic neuropathy

٢:٠٩ 4G 3G
mypastest.pastest.com

A 27-year-old woman, who is taking the combined oral contraceptive pill (OCP), comes to the clinic with worsening headaches, particularly in the morning, when she lies flat, and when she strains. They are often associated with blurred vision or temporary loss of colour vision.

Her blood pressure is 152/82 mmHg, pulse is 68 bpm and regular, her body mass index (BMI) is 32 kg/m^2.

A picture of her right retina is shown below.

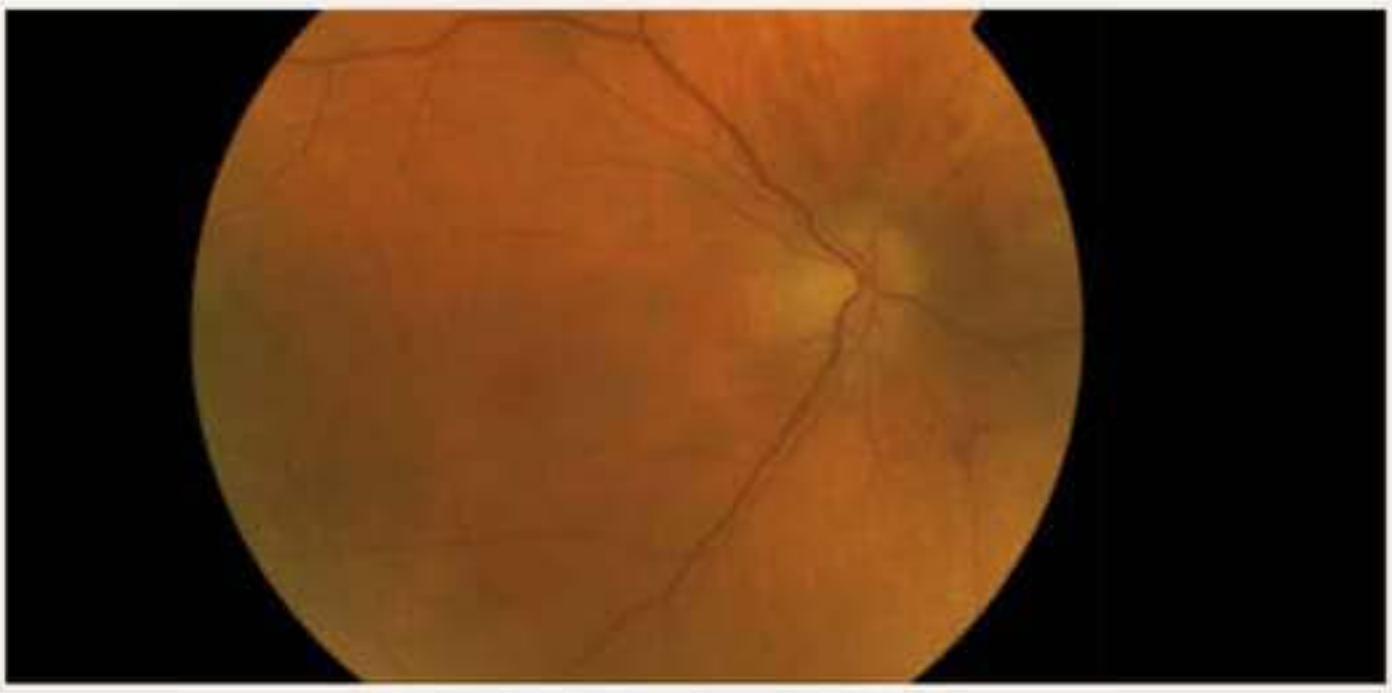

Changes on the left-hand side are similar in appearance.

A computed tomography (CT) head has been unremarkable; cerebrospinal fluid (CSF) opening pressure is 28 cmH_2O.

Visual acuity appears normal.

Which of the following is the most appropriate next intervention?

A	Acetazolamide
B	Bendroflumethiazide
C	Prednisolone
D	Stop the OCP
E	Serial therapeutic lumbar puncture

٢:١٢ 4G 3G
mypastest.pastest.com

A 27-year-old woman, who is taking the combined oral contraceptive pill (OCP), comes to the clinic with worsening headaches, particularly in the morning, when she lies flat, and when she strains. They are often associated with blurred vision or temporary loss of colour vision.

Her blood pressure is 152/82 mmHg, pulse is 68 bpm and regular, her body mass index (BMI) is 32 kg/m^2.

A picture of her right retina is shown below.

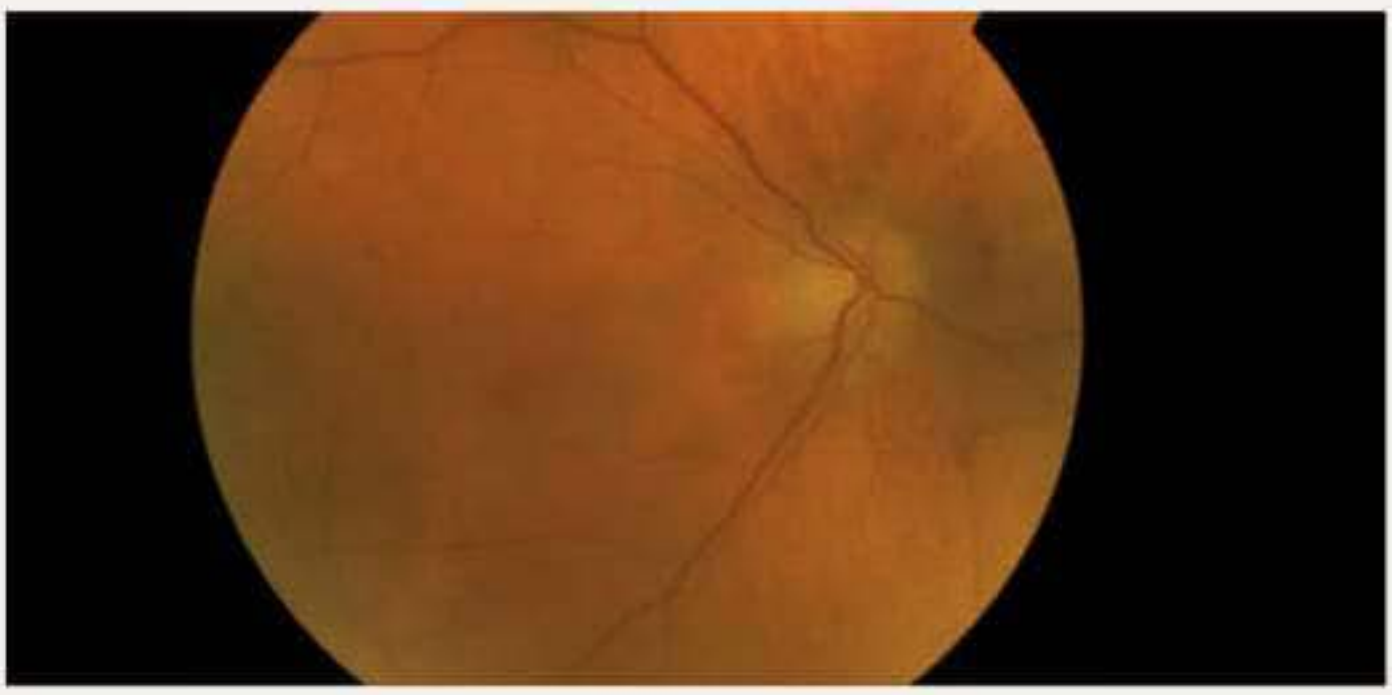

Changes on the left-hand side are similar in appearance.

A computed tomography (CT) head has been unremarkable; cerebrospinal fluid (CSF) opening pressure is 28 cmH_2O.

Visual acuity appears normal.

Which of the following is the most appropriate next intervention?

Your answer was incorrect

A	Acetazolamide
B	Bendroflumethiazide

A
B
C
D
E
0

Resp
Resp
Resp
Resp

٢:١٢ 4G 3G

A	Acetazolamide

This patient has symptoms of raised intracranial pressure, is obese, and uses the OCP. The most likely diagnosis is idiopathic intracranial hypertension (IIH). Diuretics are effective in reducing intracranial pressure in this situation; carbonic anhydrase inhibitors such as acetazolamide are a preferred first-line option, although others may also improve symptoms. Bendroflumethiazide is generally avoided because of the negative effect that thiazides have on insulin resistance. Acetazolamide used in this situation is associated with an improvement in papilloedema grade, CSF pressure and vision-related quality of life.

D	Stop the OCP

In this case, the OCP may both drive elevated intracranial pressure and significantly increase this patient's risk of venous thromboembolism, although risks need to be balanced against the fact that acetazolamide is teratogenic, as are other treatments used in this situation, such as topiramate. Acetazolamide is the preferred next intervention with encouragement to lose weight.

B	Bendroflumethiazide

Thiazides are generally avoided in this population because of negative effects on glucose tolerance. Acetazolamide is a preferred first-line agent for the treatment of IIH.

C	Prednisolone

Corticosteroids are used in the acute situation where there is severe headache, visual impairment and papilloedema, although, over the longer term, they are clearly not associated with a positive benefit versus risk profile.

E	Serial therapeutic lumbar puncture

Although intracranial pressure may be controlled by multiple therapeutic lumbar punctures, in this case stopping the OCP and instituting diuretic therapy may be enough to reduce symptoms and allow the patient to institute a weight loss programme. Cerebral spinal fluid begins to reform after six hours so any gains from performing a lumbar puncture tend to be short lived.

٢:١٦ 4G 3G
mypastest.pastest.com

A 65-year-old man presents to the Emergency Department with reduced vision in the right eye noticed while taking a photograph.

On examination, he has a right afferent pupillary defect and the following appearance on fundoscopy:

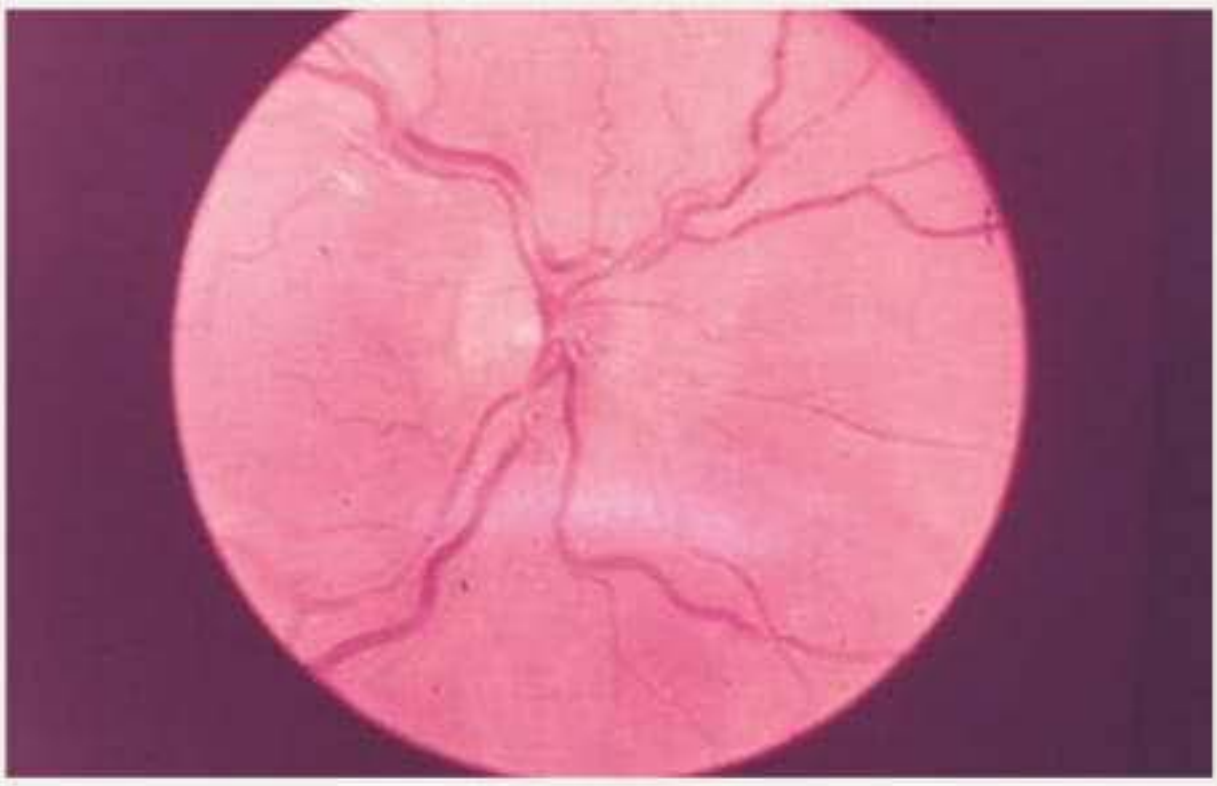

Which one of the following should be undertaken soon?

A	Blood pressure measurement
B	Thyroid function
C	Chest X-ray
D	Referral for fluorescein angiography
E	Carotid Doppler

70726

Submit

٢:١٧ 4G 3G

A	Blood pressure measurement

The slide shows a fundus with grade 4 hypertensive retinopathy with optic disc oedema, cotton-wool spots and widespread A-V nipping. The retina looks oedematous. The other features one may see are flame-shaped retinal haemorrhages and hard exudate; which may collect around the fovea producing a 'macula star'. The presence of end-organ damage like this dictates the urgency with which this condition is managed. Obviously, the blood pressure needs to be recorded and optimally controlled. The diagnosis of hypertensive retinopathy is made by the presence of these retinal features in association with severely raised blood pressure.

Considering the other consequences of hypertension the following ought also to be done: urinalysis, CXR, and ECG +/- echo to look for renal damage and LVH/strain respectively. More broadly one must consider not only the consequences of the hypertension but also its causes, such as renal or endocrine disease.

D	Referral for fluorescein angiography

Fluorescein angiography is not required to make the diagnosis.

B	Thyroid function

This is not the appearance chorioretinitis which may be caused by Toxoplasma, or dysthyroid eye disease. The latter can cause optic atrophy from optic nerve compression if there is increased pressure in the orbit.

C	Chest X-ray

A CXR needs to be done but not at the expense of everything else here.

E	Carotid Doppler

The presence of a carotid bruit does not dictate the need to do an urgent carotid doppler ultrasound.

70726

Rate this question:

A 22-year-old man presents to the Ophthalmology Clinic for review. He has suffered from a deterioration in vision, particularly at night over the past six months. He feels that he is now unable to drive. His mother, uncle and an older cousin are now registered blind.

His left retina is shown below.

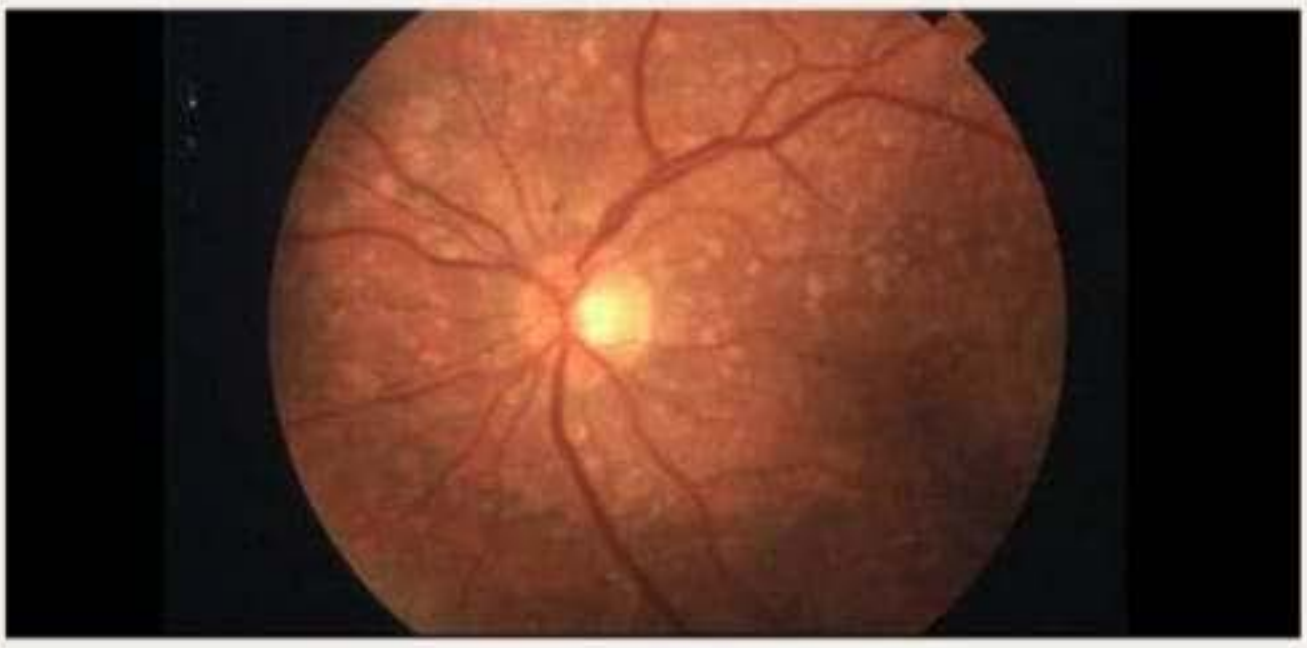

Appearances are similar on the right-hand side.

Which of the following is the most appropriate intervention?

A	Acetazolamide
B	Bevacizumab
C	Pan-retinal photocoagulation
D	Provision of low-vision aids
E	Triamcinolone

71638

Submit

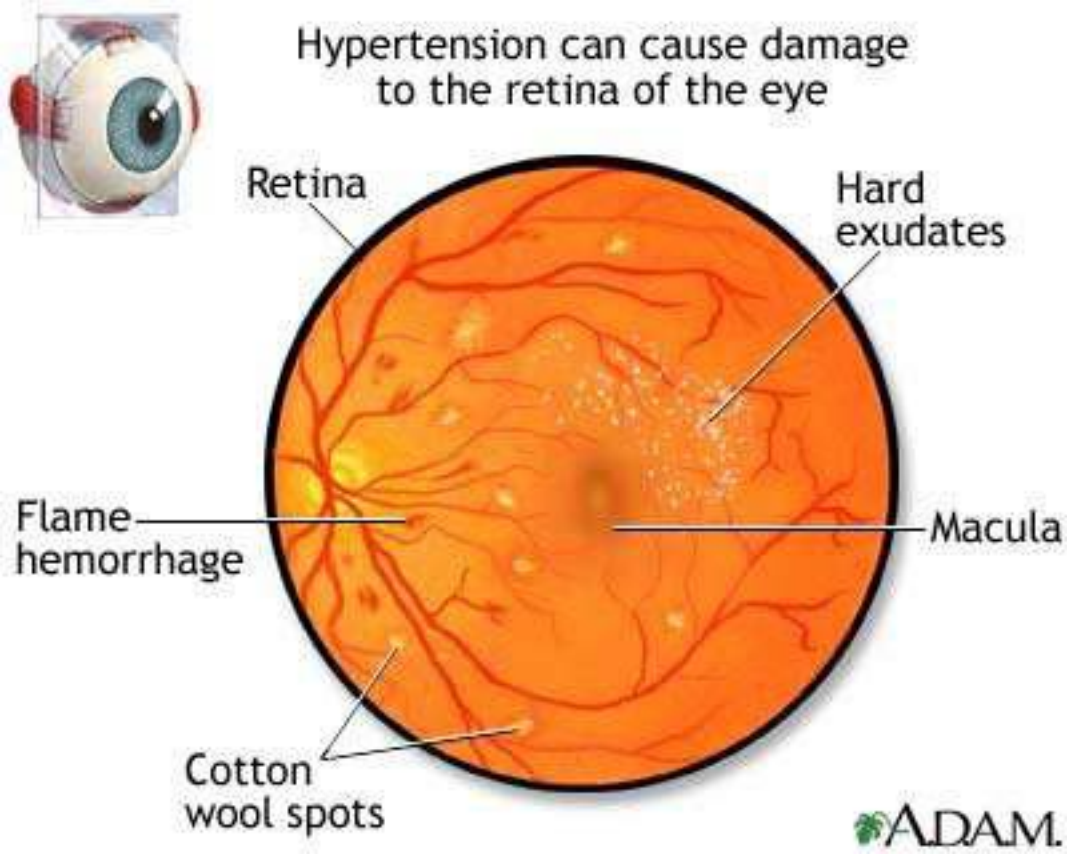
Hypertension can cause damage to the retina of the eye
Retina
Hard exudates
Flame hemorrhage
Macula
Cotton wool spots
A.D.A.M.

A 22-year-old man presents to the Ophthalmology Clinic for review. He has suffered from a deterioration in vision, particularly at night over the past six months. He feels that he is now unable to drive. His mother, uncle and an older cousin are now registered blind.

His left retina is shown below.

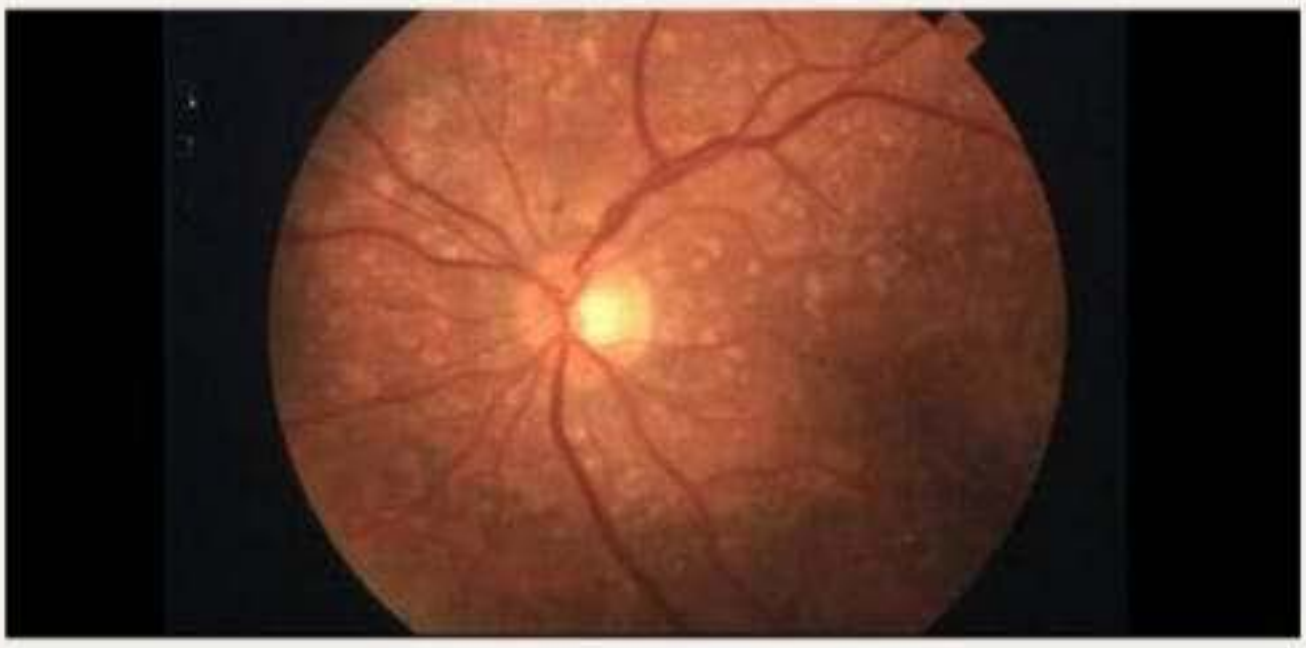

Appearances are similar on the right-hand side.

Which of the following is the most appropriate intervention?

A	Acetazolamide
B	Bevacizumab
C	Pan-retinal photocoagulation
D	Provision of low-vision aids
E	Triamcinolone



Explanation

D	Provision of low-vision aids

This patient potentially has malattia levantinese, a cause of autosomal dominant progressive visual loss in the presence of multiple drusen, which occurs because of a deterioration

٢:٢٣ 4G 3G
mypastest.pastest.com

D	Provision of low-vision aids

This patient potentially has malattia levantinese, a cause of autosomal dominant progressive visual loss in the presence of multiple drusen, which occurs because of a deterioration in the Bruch's membrane. There is currently no treatment which is recognised to be effective. Provision of low-vision aids is clearly the most appropriate intervention.

A	Acetazolamide

Acetazolamide is a carbonic anhydrase inhibitor used in the treatment of acute glaucoma; it does not have a role in the treatment of autosomal dominant retinal degeneration.

B	Bevacizumab

Bevacizumab is a vascular endothelial growth factor (VEGF) inhibitor which is used in the treatment of macular degeneration or macular oedema related to diabetic retinopathy; it does not have a role in the treatment of malattia levantinese.

C	Pan-retinal photocoagulation

Pan-retinal photocoagulation is used for the treatment of advanced retinopathy where there is a risk of bleeding or evidence of neovascularisation. It is not of value here.

E	Triamcinolone

Triamcinolone is a corticosteroid used in the treatment of macular oedema; it does not have value here in the treatment of malattia levantinese.

71638

Rate this question:

Study the Goldmann visual field test results shown below;

Left eye;



Right eye;

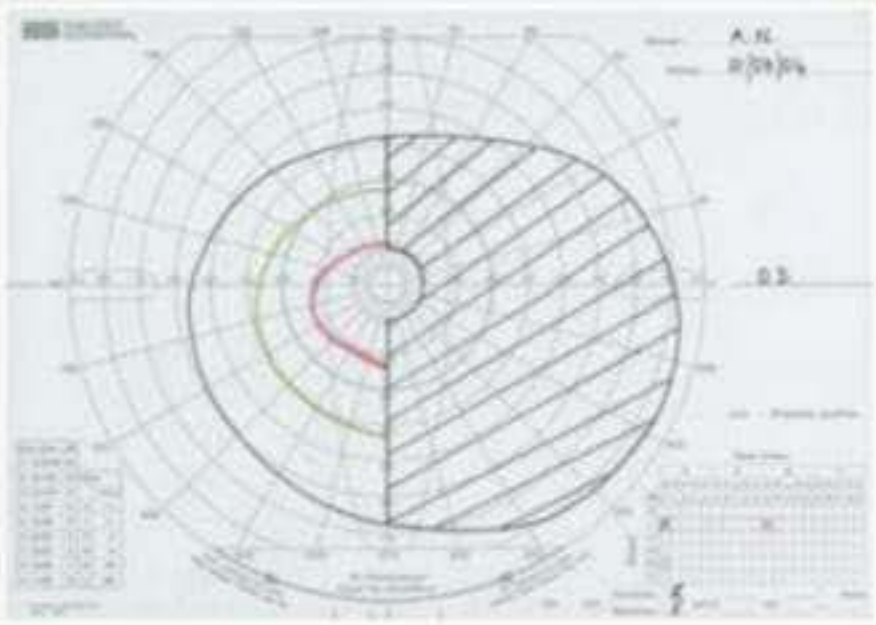

Where is the pathological lesion?

A	Left occipital cortex
B	Left temporal lobe (Meyer's loop)
C	Right occipital cortex
D	Right optic nerve
E	Right parietal lobe

CARL ZEISS MEDITEC

Normal Boundaries of the Visual Field

Superior
60 degrees

Temporal
100 degrees

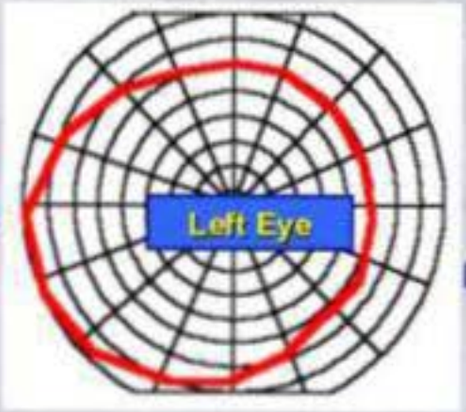

Inferior 75 Degrees

Nasal
60
Degrees

Superior
60 degrees

Temporal
100 degrees

Inferior 75 Degrees

٢:٢٧ 4G 3G

A	Left occipital cortex

By convention visual fields are recorded as what the patient sees. Therefore the right eye is on the right and the left eye on the left. They should be labelled to avoid confusion, but the position of the blind spots tells one which eye is which. Most other recordings of a clinical examination are recorded as if one is looking at the patient.

These fields show a homonymous hemianopia with macular sparing. The calcarine cortex, at the occipital lobe receives its blood supply from the two posterior cerebral arteries. The tip of the occipital pole, however, receives a dual blood supply via the middle cerebral artery. It is at the tip that macular vision is represented. Thus, with a stroke affecting the posterior cerebral artery (here on the left side) a homonymous hemianopia to all vision on the right occurs, but the patient will fortunately be able to read as macula vision is spared.

E	Right parietal lobe

Parietal lobe lesions are the converse of this and affect vision below the level of the eye, producing a left homonymous lower quadrantanopia.

B	Left temporal lobe (Meyer's loop)

A lesion in Meyer's loop the longer radiation that passes from the lateral geniculate nucleus into the temporal pole before passing back to the occipital cortex– affects the upper part of the field and thus the patient would have a right homonymous upper quadrantanopia.

C	Right occipital cortex

For reasons described above, a lesion affecting the right occipital cortex would cause a left homonymous hemianopia with macular sparing. If a patient with a left posterior cerebral artery occlusion subsequently develops a right posterior cerebral artery occlusion, the patient would be left with the peculiarity of 'gunbarrel' fields: the patient

٢:٢٧ 4G 3G
mypastest.pastest.com

Parietal lobe lesions are the converse of this and affect vision below the level of the eye, producing a left homonymous lower quadrantanopia.

B	Left temporal lobe (Meyer's loop)

A lesion in Meyer's loop the longer radiation that passes from the lateral geniculate nucleus into the temporal pole before passing back to the occipital cortex– affects the upper part of the field and thus the patient would have a right homonymous upper quadrantanopia.

C	Right occipital cortex

For reasons described above, a lesion affecting the right occipital cortex would cause a left homonymous hemianopia with macular sparing. If a patient with a left posterior cerebral artery occlusion subsequently develops a right posterior cerebral artery occlusion, the patient would be left with the peculiarity of 'gunbarrel' fields: the patient may not be able to see a door, but can see a pin– this may arouse suspicion of hysteria in the unwary physician.

D	Right optic nerve

Damage to the right optic nerve would cause unilateral blindness.

70722

Rate this question:

Next Question

Previous Q... Tag Questi... Feedback End Session

٢:٢٧ 4G 3G

A 54-year-old woman with type 2 diabetes mellitus has been referred to the Diabetic Clinic by her general practitioner (GP) for difficulty in reading small print. This visual problem has gradually developed over several months. She has been diabetic for 11 years and takes metformin monotherapy.

The patient is obese and smokes 15 cigarettes a day. She has a past medical history of hypertension and hyperlipidaemia and takes atenolol 50 mg once daily (od).

On examination, her blood pressure was 140/85 mmHg and her pulse was 66 bpm and regular.

Fundoscopy results are shown below.

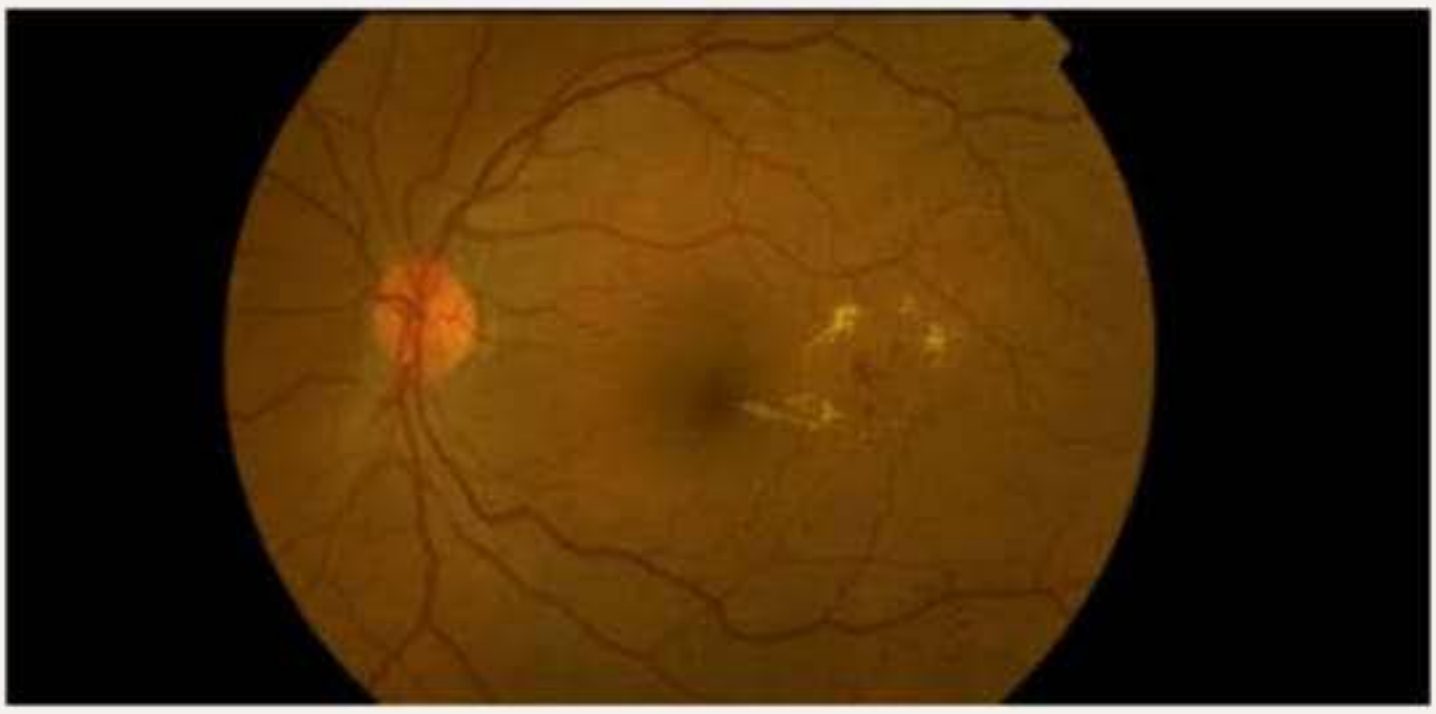

Her HbA1c was 63.9 mmol/mol (8.0%).

How would you best manage this patient with respect to the eye changes?

A	Referral to an ophthalmologist within 13 weeks for assessment
B	Screen the patient every 6 months for close follow-up
C	Screen the patient annually for early detection and treatment of proliferative retinopathy
D	Advise the patient to see an optician for spectacles
E	Add a sulphonylurea to the drug treatment

٢:٣٨ 4G 3G

A	Referral to an ophthalmologist within 10 weeks for assessment

The fundoscopic appearance of this patient shows moderate non-proliferative diabetic retinopathy with haemorrhages and some hard exudates which are close to, but not impeding on, the macula. There is also evidence of macula oedema. As such, and in light of her adverse risk profile (obesity and current smoker), this patient warrants a referral to an ophthalmologist for assessment for maculopathy and possible photocoagulation, which will help stabilise visual acuity. The ability to alter the course of visual loss in diabetic macular involvement favourably is a major advance. The patient should be cautioned that the most likely result of treatment is stabilisation, not improvement, of her visual acuity.

B	Screen the patient every 6 months for close follow-up

This advice does not follow the National Diabetic Screening Guidelines and runs the risk of significant deterioration in vision occurring, which may not be recoverable, between visits.

C	Screen the patient annually for early detection and treatment of proliferative retinopathy

With a gap of 1 year between appointments, there is significant risk of complications of diabetic retinopathy such as retinal haemorrhage, with possible detachment occurring.

D	Advise the patient to see an optician for spectacles

This patient has maculopathy and needs assessment. Although a prescription for spectacles might improve visual acuity in the short term, over the longer term, it will not prevent complications of retinopathy.

E	Add a sulphonylurea to the drug treatment

Although there is a need to improve glucose control, which may reduce the risk of retinopathy in the long term, over the short term, diabetic eye disease may actually worsen. Assessment by an ophthalmologist is therefore essential.

A 47-year-old man presents to the Emergency Department with bilateral red eyes which are associated with feelings of pain and grittiness. There is no significant exudate from the eyes.

His eyes are pictured below.

This is the second time he has presented with eye problems over the past four months. On the previous occasion, the pain and redness settled with use of artificial tears.

He has a history of inflammatory bowel disease which is currently managed with oral mesalazine.

Which of the following is the most appropriate intervention?

A	Oral co-amoxiclav
B	Oral naproxen
C	Oral prednisolone
D	Topical chloramphenicol
E	Topical corticosteroids

71645

Submit

A 47-year-old man presents to the Emergency Department with bilateral red eyes which are associated with feelings of pain and grittiness. There is no significant exudate from the eyes.

His eyes are pictured below.

This is the second time he has presented with eye problems over the past four months. On the previous occasion, the pain and redness settled with use of artificial tears.

He has a history of inflammatory bowel disease which is currently managed with oral mesalazine.

Which of the following is the most appropriate intervention?

Your answer was correct

A	Oral co-amoxiclav
B	Oral naproxen
C	Oral prednisolone
D	Topical chloramphenicol
E	Topical corticosteroids

Explanation

E	Topical corticosteroids

Explanation

E	Topical corticosteroids

The sudden onset of bilateral red eyes in a patient with a history of inflammatory bowel disease is consistent with a diagnosis of episcleritis. Although the first episode responded to artificial tears, on this occasion, topical corticosteroids are a more appropriate intervention to control symptoms.

A	Oral co-amoxiclav

Although this patient's eyes are red, there is no evidence of discharge, and the history of inflammatory bowel disease and recurrent eye symptoms drives us more towards a diagnosis of episcleritis.

B	Oral naproxen

Oral non-steroidal anti-inflammatory drugs (NSAIDs) are used for resistant episcleritis, although in this case, with a history of inflammatory bowel disease, topical therapy is the preferred option.

C	Oral prednisolone

Although systemic corticosteroids may be required for patients with resistant disease, in this case, a trial of topical corticosteroids is appropriate first.

D	Topical chloramphenicol

A second episode of red eyes without significant exudate is more consistent with episcleritis, especially given the history of inflammatory bowel disease; hence, chloramphenicol is not of value in this patient.

71645

Rate this question:

Next Question

Previous Q... | Tag Questi... | Feedback | End Session

٢:٤٣ 4G 3G
mypastest.pastest.com

A 56-year-old woman has been complaining of right-sided orbital pain for the last two weeks. Pain is much worse in evenings usually while she is reading and at that time she sees a halo around lights and gets a headache on the same side as the orbital pain. It resolves when she goes to bed. Her vision in the right eye has deteriorated significantly over the last day.

On examination, her BP is 144/72 mmHg, pulse is 75/min and regular. Visual acuity is 6/6 in the left eye, but hand movements only in the right eye. There is corneal and scleral injection on the right.

Which of the following is the most likely diagnosis?

A	Tension headache
B	Cluster head ache
C	Acute closed angle glaucoma
D	Episcleritis
E	Optic neuritis

70719

Submit

٢:٤٦ 4G 3G
mypastest.pastest.com

A 56-year-old woman has been complaining of right-sided orbital pain for the last two weeks. Pain is much worse in evenings usually while she is reading and at that time she sees a halo around lights and gets a headache on the same side as the orbital pain. It resolves when she goes to bed. Her vision in the right eye has deteriorated significantly over the last day.

On examination, her BP is 144/72 mmHg, pulse is 75/min and regular. Visual acuity is 6/6 in the left eye, but hand movements only in the right eye. There is corneal and scleral injection on the right.

Which of the following is the most likely diagnosis?

Your answer was correct

A	Tension headache
B	Cluster head ache
C	Acute closed angle glaucoma
D	Episcleritis
E	Optic neuritis

Explanation

C Acute closed angle glaucoma

Orbital pain and seeing haloed vision are typical features associated with acute closed angle glaucoma, as is corneal and scleral injection. The diagnosis is a clinical one, supported by the use of tonometry to measure intra-ocular

Explanation

C	Acute closed angle glaucoma

Orbital pain and seeing haloed vision are typical features associated with acute closed angle glaucoma, as is corneal and scleral injection. The diagnosis is a clinical one, supported by the use of tonometry to measure intra-ocular pressure. Acetazolamide, topical steroids and topical beta blockers are the initial therapies of choice. Whilst cluster headache can present with autonomic symptoms, it is not associated with visual loss. Symptoms are often reported as being worse in the evening; this may be a combination of increased eye strain, difficulty focusing in darker light, and the fact that one commonly reported symptom is visualising haloes around artificial light.

A	Tension headache

Tension headache is incorrect because the vision is unaffected in this condition. Also, the cornea and sclera are unlikely to be affected.

B	Cluster head ache

Cluster headache is unlikely because the vision is unaffected in this condition.

D	Episcleritis

Episcleritis is incorrect because the vision is unaffected in episcleritis, whereas this patient is presenting with reduced visual acuity. Halo signs are also typically associated with glaucoma.

E	Optic neuritis

Optic neuritis is incorrect. Both conditions due present with pain; however, the patient has a red eye and this is not present in optic neuritis.

70719

Rate this question:

Next Question

٢:٤٦ 4G 3G
mypastest.pastest.com

Three days after being admitted for a myocardial infarction, a man complains of sudden change in vision. The medical registrar examines the patient and finds that the patient's vision in both eyes is significantly reduced, although the patient still claims that he can see.

The pupils are equal in size and the pupil responses are normal with normal fundoscopy. Significantly, the patient has now developed atrial fibrillation.

A referral is made to the ophthalmologist who confirms bilateral blindness. Despite this, however, the patient fervently believes that he can see and has taken to describing objects that he has not seen previously in discriminating detail.

What is the most likely diagnosis?

A	Bilateral central retinal artery occlusion (BCRAO)
B	Bilateral central retinal vein occlusion (BCRVO)
C	Optic chiasm compression
D	Bilateral occipital cortex infarction
E	Bilateral parietal lobe infarction

7071

Submit

٢:٤٨ 4G 3G

Three days after being admitted for a myocardial infarction, a man complains of sudden change in vision. The medical registrar examines the patient and finds that the patient's vision in both eyes is significantly reduced, although the patient still claims that he can see.

The pupils are equal in size and the pupil responses are normal with normal fundoscopy. Significantly, the patient has now developed atrial fibrillation.

A referral is made to the ophthalmologist who confirms bilateral blindness. Despite this, however, the patient fervently believes that he can see and has taken to describing objects that he has not seen previously in discriminating detail.

What is the most likely diagnosis?

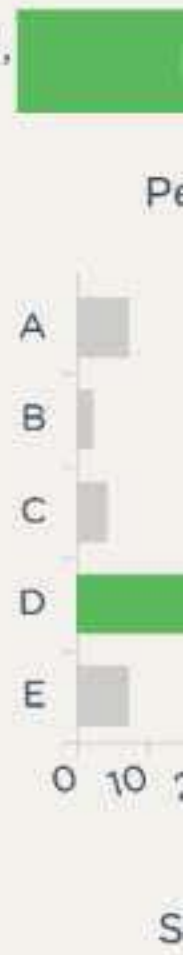

Your answer was correct

A	Bilateral central retinal artery occlusion (BCRAO)
B	Bilateral central retinal vein occlusion (BCRVO)
C	Optic chiasm compression
D	Bilateral occipital cortex infarction
E	Bilateral parietal lobe infarction

Explanation

D	Bilateral occipital cortex infarction

The supply of the posterior cerebral arteries includes the medial area of the occipital lobes and the inferior aspects of the temporal lobes. Bilateral infarctions of the primary visual cortex located in the occipital lobes produces varying degrees of cortical blindness depending upon the extent of the lesion. Cortically, blind patients have no vision, but their pupillary responses are intact and fundoscopy is also normal. However, both visual evoked potentials and optokinetic nystagmus are absent. If the

٢:٤٩ 4G 3G
mypastest.pastest.com

D	Bilateral occipital cortex infarction

The supply of the posterior cerebral arteries includes the medial area of the occipital lobes and the inferior aspects of the temporal lobes. Bilateral infarctions of the primary visual cortex located in the occipital lobes produces varying degrees of cortical blindness depending upon the extent of the lesion. Cortically, blind patients have no vision, but their pupillary responses are intact and fundoscopy is also normal. However, both visual evoked potentials and optokinetic nystagmus are absent. If the lesions are more extensive, patients may be in denial of their blindness, a condition termed Anton syndrome, a state in which patients fervently believe that they can see when they cannot.

A	Bilateral central retinal artery occlusion (BCRAO)

BCRAO is associated with changes on fundoscopy, including pale retinae and the presence of a 'cherry red spot'.

B	Bilateral central retinal vein occlusion (BCRVO)

BCRVO is associated with visual field loss and extensive retinal haemorrhages, not seen here on fundoscopy.

C	Optic chiasm compression

Optic chiasm compression leads to tunnel vision rather than the picture here of total visual loss.

E	Bilateral parietal lobe infarction

Bilateral parietal lobe infarction would imply extensive anterior territory cerebral infarcts, which would not fit with the picture seen here, as this would likely be a non-survivable event.

70711
Rate this question:

٢:٥١ 4G 3G
mypastest.pastest.com

Calculator

Normal Values

A 38-year-old city worker presents to the Emergency Department with a severe frontal headache, nausea and vomiting which has built up over the past week. On further questioning, he admits to worsening headaches over the past two to three months.

On examination, his blood pressure is 210/100 mmHg, pulse is 85 bpm and regular. His body mass index (BMI) is 23 kg/m^2 and there are no masses on palpation of the abdomen. His creatinine is elevated at 189 µmol/l.

A retinal photograph is shown below.

Which of the following is the most appropriate intervention?

A	Intravenous (IV) sodium nitroprusside
B	Oral amlodipine
C	Oral bendroflumethiazide
D	Oral ramipril
E	Sublingual nifedipine

21585

Submit

٢:٥٢ 4G 3G

A 38-year-old city worker presents to the Emergency Department with a severe frontal headache, nausea and vomiting which has built up over the past week. On further questioning, he admits to worsening headaches over the past two to three months.

On examination, his blood pressure is 210/100 mmHg, pulse is 85 bpm and regular. His body mass index (BMI) is 23 kg/m² and there are no masses on palpation of the abdomen. His creatinine is elevated at 189 µmol/l.

A retinal photograph is shown below.

Which of the following is the most appropriate intervention?

Your answer was correct

A	Intravenous (IV) sodium nitroprusside
B	Oral amlodipine
C	Oral bendroflumethiazide
D	Oral ramipril
E	Sublingual nifedipine

Explanation

A	Intravenous (IV) sodium nitroprusside

This patient has grade 4 hypertensive retinopathy against a background of steadily worsening headaches, marked hypertension with renal impairment and a BMI in the

٢:٥٢ 4G 3G

A	Intravenous (IV) sodium nitroprusside

This patient has grade 4 hypertensive retinopathy against a background of steadily worsening headaches, marked hypertension with renal impairment and a BMI in the normal range. In this situation, IV therapy with either sodium nitroprusside or labetolol is most appropriate as it can be titrated to achieve a gradual reduction in blood pressure without risk of rebound or overshooting any short-term target for blood pressure. Rapid correction in blood pressure could lead to cardiac and neurological compromise.

B	Oral amlodipine

Although calcium channel antagonists are effective in managing systolic hypertension, oral therapy should be avoided initially here so that the blood pressure can be gradually reduced.

C	Oral bendroflumethiazide

Thiazide diuretics are no longer recommended as a first-line option for treating hypertension, due to negative effects on glucose tolerance and risk of electrolyte imbalance associated with their use. IV therapy is also preferred in the initial stages of managing hypertension in this situation.

D	Oral ramipril

Given the creatinine is abnormal, some evaluation of the cause for renal impairment should be undertaken before angiotensin-converting enzyme (ACE) inhibitors are initiated. IV nitroprusside is also the better option initially to control blood pressure.

E	Sublingual nifedipine

Sublingual nifedipine can result in a rapid reduction in blood pressure, but when the effect wears off this can also drive significant rebound. In this situation there is increased risk of neurological impairment. For this reason, sublingual preparations of calcium antagonists should be avoided here.

A 54-year-old woman with type 2 diabetes mellitus has been referred to the Diabetic Clinic by her general practitioner (GP) for difficulty in reading small print. This visual problem had gradually developed over several months.

She has been diabetic for 11 years and has been controlled by diet alone. The patient is obese and smokes 15 cigarettes a day. She has a past medical history of hypertension and hyperlipidaemia and takes atenolol 50 mg od.

On examination, her blood pressure was 135/85 mmHg and her pulse was 66 bpm and regular. Fundoscopy reveals non-proliferative diabetic retinopathy (NPDR). Her FBC and U/Es are normal. Her HbA1c was 63.93 mmol/mol (8.0%).

What is the most likely outcome of replacing diet by drug treatment in this patient?

A	Intensive blood glucose control would significantly decrease the risk of macrovascular disease
B	Intensive blood glucose control would lead to a reduction in the progression of retinopathy and deterioration of visual acuity
C	Intensive blood glucose control would reverse the progression of the retinopathy and improve her vision
D	Metformin would increase fasting plasma insulin
E	Metformin would be associated with less weight gain but with frequent hypoglycaemic episodes

70729

Submit

because this was not found in the UKPDS study – which showed that intensive blood glucose control did not significantly decrease the risk of macrovascular disease or mortality at 10-year follow-up.

C	Intensive blood glucose control would reverse the progression of the retinopathy and improve her vision

Intensive blood glucose control would reverse the progression of the retinopathy and improve her vision is incorrect. The UKPDS showed that the control of hypertension in type II diabetics led to a reduction in diabetes-related deaths and complications, including progression to retinopathy and deterioration in visual acuity.

D	Metformin would increase fasting plasma insulin

Metformin would increase fasting plasma insulin is incorrect because it lowers fasting plasma insulin but enhances insulin sensitivity, thereby increasing peripheral uptake of glucose.

E	Metformin would be associated with less weight gain but with frequent hypoglycaemic episodes

Metformin would be associated with less weight gain but with frequent hypoglycaemic episodes is incorrect because a study comparing metformin with diet in overweight type II diabetics revealed a risk reduction in any diabetes-related endpoint, diabetes-related death or mortality from any cause in the metformin-treated group. Improved glucose control was achieved without weight gain.

70729

Rate this question:

Next Question

Previous Q... Tag Questi... Feedback End Session

B	Intensive blood glucose control would lead to a reduction in the progression of retinopathy and deterioration of visual acuity

The United Kingdom Prospective Diabetes Study (UKPDS) was designed to establish whether intensive blood glucose control was of benefit in reducing the microvascular and macrovascular complications of type II diabetes. It also studied the outcome with different treatments. Diabetic control was assessed by measurements of HbA1c and was found to be significantly better in drug treatment groups than those treated by diet alone. There was a 25% risk reduction of developing microvascular complications in the drug-treated groups compared to those on diet alone. However, intensive blood glucose control did not significantly decrease the risk of macrovascular disease or mortality at the original 10 year follow-up time point.

The UKPDS showed that the control of hypertension in type II diabetics led to a reduction in diabetes-related deaths and complications, including progression to retinopathy and deterioration in visual acuity.

A	Intensive blood glucose control would significantly decrease the risk of macrovascular disease

Intensive blood glucose control would significantly decrease the risk of macrovascular disease is incorrect because this was not found in the UKPDS study – which showed that intensive blood glucose control did not significantly decrease the risk of macrovascular disease or mortality at 10-year follow-up.

C	Intensive blood glucose control would reverse the progression of the retinopathy and improve her vision

Intensive blood glucose control would reverse the progression of the retinopathy and improve her vision is incorrect. The UKPDS showed that the control of hypertension in type II diabetics led to a reduction in diabetes-related deaths and complications, including progression to retinopathy and deterioration in visual acuity.

A 27-year-old woman presents to the Emergency Department for review. She has suffered from increasing frontal headaches over the past few months, which are preceded by a sensation of seeing wavy lines in the left eye. Occasionally, the headaches make her sick.

Her blood pressure is 122/82 mmHg, and her body mass index (BMI) is 22 kg/m^2. Neurological examination is normal.

A picture of the left fundus is shown below.

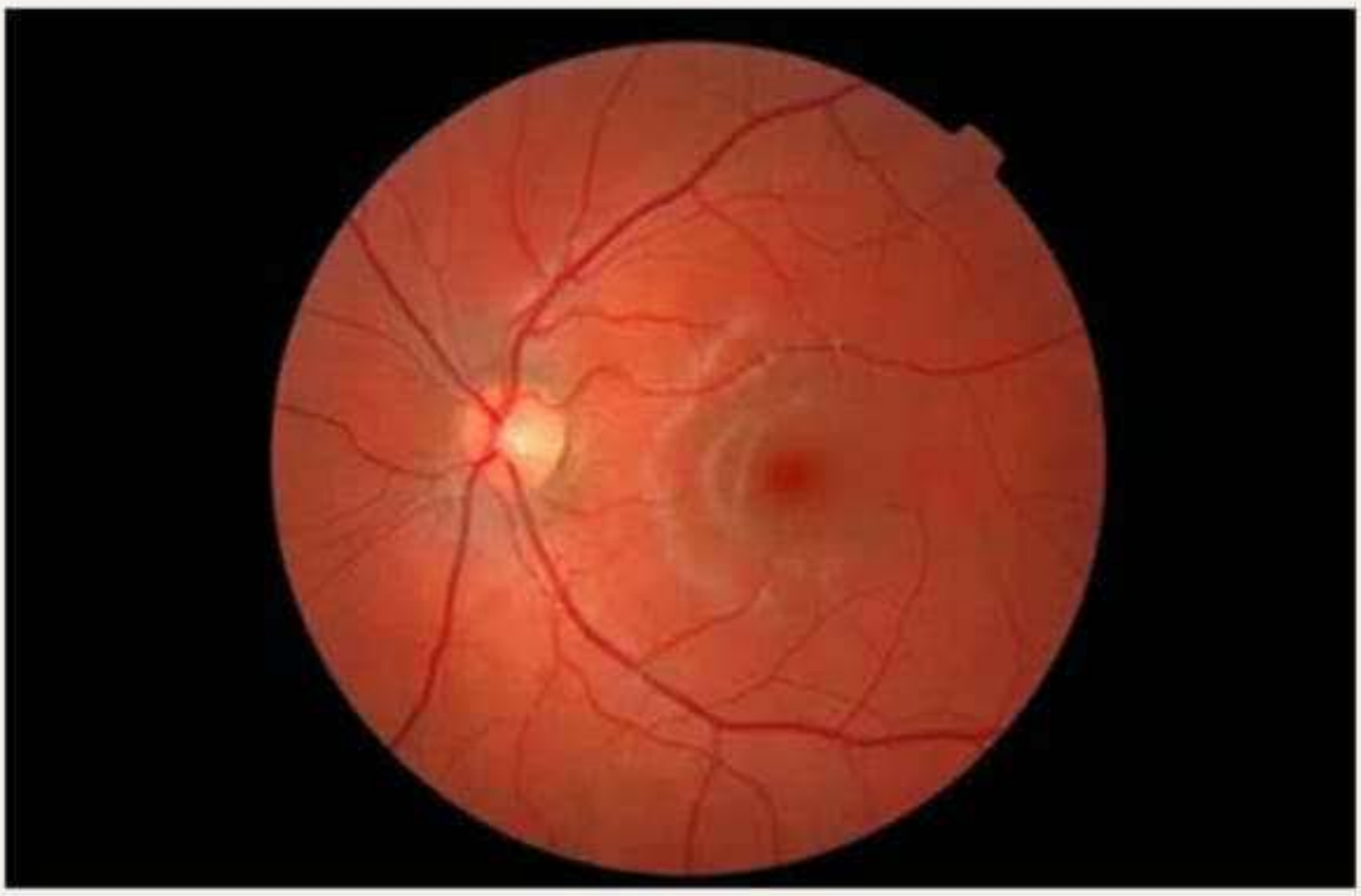

The image from the right eye is the same.

Which of the following is the most appropriate step?

A	Acetazolamide
B	Amitriptyline
C	Topiramate
D	Urgent computed tomography (CT) head
E	Urgent lumbar puncture

٣:٠٢ 3G 3G

B Amitriptyline

This patient's symptoms are consistent with migraine, and the lack of other features, including a normal neurological examination and normal fundoscopy, makes this the most likely diagnosis. Both tricyclic antidepressants and beta-blockers are appropriate options as first-line therapy for migraine prophylaxis.

E Urgent lumbar puncture

There is no evidence of papilloedema here and the history is very consistent with migraine. Therefore, there is no indication for an urgent lumbar puncture.

A Acetazolamide

Acetazolamide is a carbonic anhydrase inhibitor used in the treatment of acute glaucoma; it may also be used in the treatment of idiopathic intracranial hypertension.

C Topiramate

Topiramate is a second-line agent used in the prophylaxis of migraine. Sodium valproate is an alternative second-line agent but is now heavily restricted for use in women. Out of the antiepileptic options, gabapentin is not effective for migraine prophylaxis.

D Urgent computed tomography (CT) head

There is no indication for an urgent CT head, with a normal neurological examination, normal fundoscopy and strong evidence for migraine from the symptoms described here.

71639

Rate this question:

Next Question

Previous Q... Tag Questi... Feedback End Session

٣:٠٢ 3G 3G
mypastest.pastest.com

A 27-year-old woman presents to the Emergency Department for review. She has suffered from increasing frontal headaches over the past few months, which are preceded by a sensation of seeing wavy lines in the left eye. Occasionally, the headaches make her sick.

Her blood pressure is 122/82 mmHg, and her body mass index (BMI) is 22 kg/m^2. Neurological examination is normal.

A picture of the left fundus is shown below.

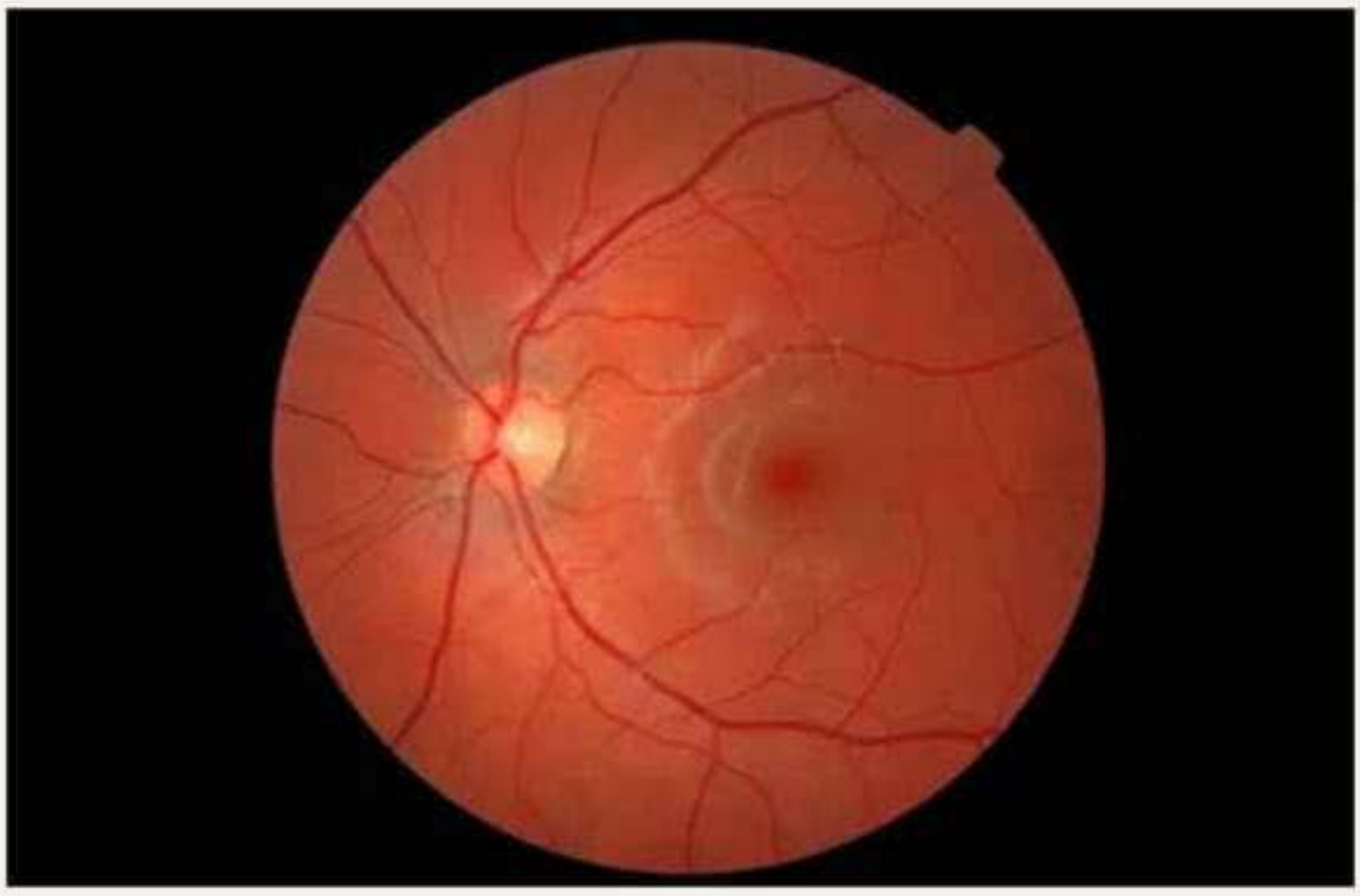

The image from the right eye is the same.

Which of the following is the most appropriate step?

Your answer was incorrect

A	Acetazolamide
B	Amitriptyline
C	Topiramate



٣:٠٢ 3G 3G
mypastest.pastest.com

A 24-year-old woman comes to the Neurology Clinic for review. She developed an ataxic gait, suffered vestibular nerve dysfunction, and has lost vision in her left eye over the past 18 months. Her symptoms have improved and she has recovered slightly in the past two months.

A magnetic resonance imaging (MRI) scan of her brain has demonstrated multiple white matter changes.

An image of her left retina is shown below.

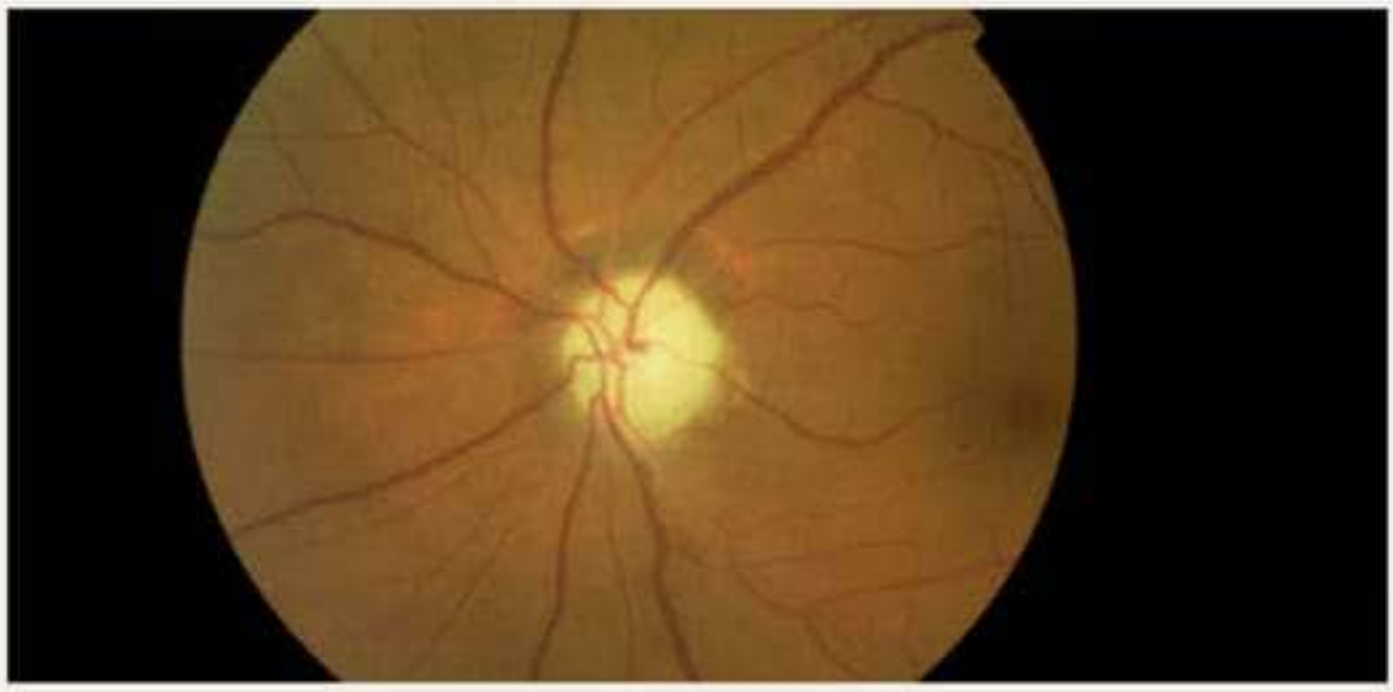

Which of the following is she most likely to benefit from?

A	Azathioprine
B	Dimethyl fumarate
C	Interferon alpha
D	Methylprednisolone
E	Natalizumab

٣:١١ 3G 3G
mypastest.pastest.com

A 24-year-old woman comes to the Neurology Clinic for review. She developed an ataxic gait, suffered vestibular nerve dysfunction, and has lost vision in her left eye over the past 18 months. Her symptoms have improved and she has recovered slightly in the past two months.

A magnetic resonance imaging (MRI) scan of her brain has demonstrated multiple white matter changes.

An image of her left retina is shown below.

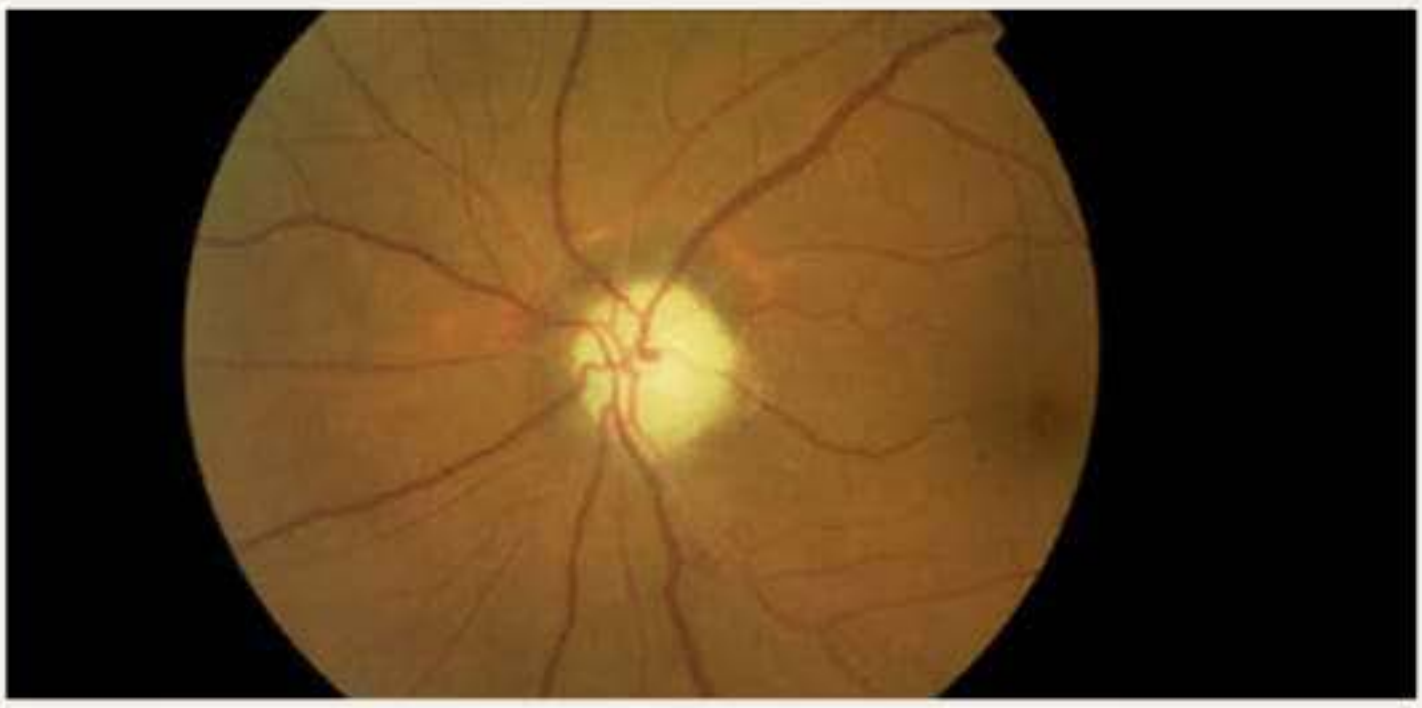

Which of the following is she most likely to benefit from?

Your answer was incorrect

A	Azathioprine
B	Dimethyl fumarate
C	Interferon alpha
D	Methylprednisolone
E	[illegible]

٣:١١ 3G 3G

B	Dimethyl fumarate

This patient has evidence of relapsing remitting multiple sclerosis (MS) with vestibular nerve dysfunction, optic atrophy, cerebellar dysfunction and changes on the MRI. Dimethyl fumarate is an oral disease-modifying agent which is recommended by the National Institute for Health and Care Excellence (NICE) as an option for treating adults with active relapsing-remitting MS (two clinically significant relapses in the previous two years), but only if they do not have highly active or rapidly evolving severe relapsing-remitting MS.

C	Interferon alpha

Interferon beta, not alpha, is indicated for the treatment of relapsing and remitting MS. Not all patients respond to interferon beta and a deterioration is observed in some individuals after starting therapy.

A	Azathioprine

There is limited evidence to support azathioprine use as a steroid-sparing agent in patients with frequent relapses, but as long-term maintenance it is less effective in comparison to other options.

D	Methylprednisolone

Intravenous (IV) methylprednisolone is used in MS relapses where it has been shown up to speed up recovery in the short term; however, evidence to support a long-term benefit on outcomes in MS is sparse.

E	Natalizumab

Natalizumab is a second-line disease-modifying therapy in MS, given by monthly IV infusion. There is a 68% reduction in MS relapses according to clinical trials, although it is associated with progressive multifocal leukoencephalopathy (PML) related to activation of the JC virus.

A 56-year-old woman with a history of type 2 diabetes and hypertension presents to the Emergency Department. She has taken up badminton to lose weight and presents with sudden loss of the upper field of vision in her right eye during a game.

On examination, the left eye shows evidence of hypertensive changes, the right reveals a swollen optic disc with retinal haemorrhages in all four quadrants, there is an afferent pupillary defect. Her blood pressure (BP) is 148/92 mmHg

Investigations:

Hb	13.1 g/dl
WCC	5.5×10^9/l
PLT	199×10^9/l
Na^+	140 mmol/l
K^+	4.9 mmol/l
Creatinine	130 µmol/l
Cholesterol	6.2 mmol/l
HbA1c	62.84 mmol/mol (7.9 %)

Which of the following is the most likely diagnosis?

A	Optic neuritis
B	Anterior ischaemic optic neuropathy
C	Branch retinal vein occlusion
D	Central retinal vein occlusion
E	Central retinal artery occlusion

٣:٢١ 3G 3G
mypastest.pastest.com

A 56-year-old woman with a history of type 2 diabetes and hypertension presents to the Emergency Department. She has taken up badminton to lose weight and presents with sudden loss of the upper field of vision in her right eye during a game.

On examination, the left eye shows evidence of hypertensive changes, the right reveals a swollen optic disc with retinal haemorrhages in all four quadrants, there is an afferent pupillary defect. Her blood pressure (BP) is 148/92 mmHg

Investigations:

Hb	13.1 g/dl
WCC	5.5×10^9/l
PLT	199×10^9/l
Na^+	140 mmol/l
K^+	4.9 mmol/l
Creatinine	130 µmol/l
Cholesterol	6.2 mmol/l
HbA1c	62.84 mmol/mol (7.9 %)

Which of the following is the most likely diagnosis?

Your answer was correct

A	Optic neuritis
B	Anterior ischaemic optic neuropathy
C	Branch retinal vein occlusion
D	Central retinal vein occlusion

٣:٢١ 3G 3G

D	Central retinal vein occlusion

The correct answer is central retinal vein occlusion which occurs with increased frequency in patients with a history of diabetes mellitus. Both retinal haemorrhages and oedema of the optic disc, with an afferent pupil defect are typical of the condition. The area of visual field loss may be variable, particularly during the early stages after retinal vein thrombosis occurs. Colour Doppler imaging is a non-invasive way to image the retrobulbar circulation, but the investigation of choice is fluorscein angiography. Blood work is targeted at identifying any underlying cause of hypercoagulability and consideration of either anti-platelet agents such as aspirin or anti-coagulation with warfarin. No effective treatments for central retinal vein occlusion have been identified although intra-ocular corticosteroids may have a role to play in associated macular oedema. Ischaemic optic neuropathy usually presents with a pale white oedematous optic disc.

A	Optic neuritis

Optic neuritis is incorrect because it does not cause flame haemorrhages in all four quadrants.

B	Anterior ischaemic optic neuropathy

Anterior ischaemic optic neuropathy is incorrect because ischaemic optic neuropathy usually presents with a pale white oedematous optic disc.

C	Branch retinal vein occlusion

Branch retinal vein occlusion is incorrect because it causes sectoral haemorrhages, and not haemorrhages in all four corners which is more likely to be caused by a central retinal vein occlusion.

E	Central retinal artery occlusion

Central retinal artery occlusion is incorrect because it causes a pale fundus with a cherry class red spot at the macula, rather than with flame haemorrhages in all four quadrants of the eye, like in this scenario.

Rate this question:

11:00
https://mypastest.pastest.com

A 35-year-old woman complained of sensitivity of the fingers and toes to the cold and associated with colour change from white to blue and then to red.

What is the name given to this condition?

A Raynaud's phenomenon

B Cold agglutinin disease

C Lupus pernio

D Cutaneous vasculitis

E Chilblains

Rana Alnasser's screen

A Raynaud's phenomenon

Raynaud's phenomenon can be primary (idiopathic) or secondary in patients with underlying connective tissue disorders (e.g. SLE, rheumatoid arthritis, and scleroderma) The classic picture of Raynaud's is of pain, discoloration and tingling in the peripheries. Typically, when exposed to cold weather the fingers or toes become pale in colour du to associated vasoconstriction. Subsequently, the skin turn blue due to lack of oxygen supply, erythematous due to reperfusion injury, and finally normalises. Long-standing Raynaud's phenomenon leads to ischaemic changes in the digits such as pulp atrophy, nail fold telangiectasia, and ulceration. Treatment of Raynaud's is with vasodilating agents in order to improve blood flow to the region.

B Cold agglutinin disease

Cold agglutinin disease is an autoimmune disorder that presents with episodes of haemolytic anaemia when exposed to cold weather. A common complaint among such patients is the development of painful fingers and toes with purplish discoloration associated with cold exposure that is known as cold agglutinin-mediated acrocyanosis. This differs from Raynaud's phenomenon an is not associated with a triphasic colour change (white to blue to red).

C Lupus pernio

Lupus pernio is the name given to the indurated purple-re plaques that can affect the skin of the nose, ears and cheeks in patients with cutaneous sarcoidosis.

D Cutaneous vasculitis

Cutaneous vasculitis is a group of disorders leading to

C Lupus pernio

Lupus pernio is the name given to the indurated purple-re plaques that can affect the skin of the nose, ears and cheeks in patients with cutaneous sarcoidosis.

D Cutaneous vasculitis

Cutaneous vasculitis is a group of disorders leading to inflammation of the vessels in the skin and subcutaneous tissues, but not those of internal organs. It presents as areas of purpura, petechiae, and even ulceration. Diagnosi is used confirmed but biopsy and immunohistochemistry i addition to lack of systemic symptoms, unremarkable blood tests and urinalysis.

E Chilblains

Chilblains (also known as perniosis) are a localised form o vasculitis that occurs several hours after exposure to the cold. They present as itchy or painful, purple-red nodules, and can also be associated with blistering and oedema.

40095

Rate this question:

Next Question

© Pastest 2019

A 32-year-old gentleman, who is known to suffer with anxiety and depression, presents with an intensely itchy, erythematous patch on his lower leg. He recognises and admits that the rash is worse after itching. There are no other skin problems noted elsewhere.

You plan to prescribe an occlusive treatment to help moisturise the skin over the leg.

Which of the following is likely to have the most occlusive effect?

A	Ointments
B	Gels
C	Creams
D	Lotions
E	Foam

Explanation

A Ointments

Ointments are 80% oil and 20% water. These products feel greasy, do not absorb well and are generally not easy to use on large areas. They are 'occlusive,' which means they trap moisture and heat in very well. Ointments promote medication absorption over all other formulations.

B Gels

Gels are emulsions that contain oil-in-water. They usually have an alcohol base. They dry into a thin, greaseless, film. Like lotions and foams, they are ideal for spreading on hairy areas and large areas.

C Creams

Creams are a semi-solid emulsion, half oil and half water. This formulation is typically the easiest to use and is preferred by most patients. They spread easily, absorb quickly and wash off with water. They have a medium viscosity, and are reasonably hydrating without feeling too heavy on your skin.

D Lotions

Lotions are thinner than creams, they absorb very quickly and feel very light on the skin. They are easier to distribute on hairy areas, but do not retain significant moisture over the skin surface.

E Foam

Foams are pressurised collections of gaseous bubbles in a matrix of liquid film. Foam preparations spread readily and

C Creams

Creams are a semi-solid emulsion, half oil and half water. This formulation is typically the easiest to use and is preferred by most patients. They spread easily, absorb quickly and wash off with water. They have a medium viscosity, and are reasonably hydrating without feeling too heavy on your skin.

D Lotions

Lotions are thinner than creams, they absorb very quickly and feel very light on the skin. They are easier to distribute on hairy areas, but do not retain significant moisture over the skin surface.

E Foam

Foams are pressurised collections of gaseous bubbles in a matrix of liquid film. Foam preparations spread readily and are easier to apply than other preparations.

Rate this question:

© Pastest 2019

A 32-year-old man, who is known to suffer with anxiety and depression, presents with a chronic, intensely itchy, erythematous patch on his lower leg. He recognises and admits that the rash is worse after itching.

There are no other skin problems noted elsewhere, and he has no other significant health problems.

Routine bloods are unremarkable.

What is the most likely diagnosis?

A	Dysmorphophobia
B	Delusional parasitosis
C	Lichen simplex et chronicus
D	Dermatitis artefacta
E	Shingles

American Academy of Dermatology

Lichen planus | American Academy of Dermatology

Lichen planus

Images may be subject to copyright. Learn more

RELATED IMAGES

التقران الغاقب__النموذ... = Porokeratosis linear type

Lichen planus, Skin Disesases in Panvel Mat...
indiamart.com

Discover Updates Search Recent

Rana Alnasser's screen

11:04
594-042-7551
Leave

Merck Manuals

Lichen Simplex Chronicus - Dermatologic Disorders - Merck Manuals ...

Lichen Simplex Chronicus - Dermatologic Disorders - Merck Manuals Professional Edition

Images may be subject to copyright. Learn more

RELATED IMAGES

Opinions on Lichen simplex chronicus
writeopinions.com

97+ Lichen Simplex Chronicus Neur
theendivechronicles.com

Discover Updates Search Recent More

Audio Video Share Participants More

11:05

C Lichen simplex et chronicus

Lichen simplex et chronicus occurs when the skin becomes thickened and leathery (lichenified) because of chronic rubbing – sometimes a stress related habit. It favours the calf, nape of the neck and vulval/peri-anal skin. The localised nature of this, coupled with the lack of other systemic features, further support the underlying diagnosis.

D Dermatitis artefacta

Dermatitis artefacta is associated with self-mutilation, usually denied by the patient, and may appear overnight.

A Dysmorphophobia

Dysmorphophobia is an altered perception of one's appearance and a belief that there is a flaw in appearance. In some cases, this may result in inappropriate plastic surgery to alter appearance.

B Delusional parasitosis

Delusional parasitosis is a fixed, false belief that there is an infestation with insect or parasite and is much more likely to result in generalised symptoms.

E Shingles

Shingles is an acutely painful vesicular rash, rather than the chronic itchy lesion seen here.

40085

Rate this question:

Rana Alnasser's screen

11:06
594-042-7551
Leave

A 21-year-old professional athlete presented with an itchy rash in his right axilla.

What is the most likely diagnosis?

A	Acanthosis nigricans
B	Tinea axillaris
C	Systemic lupus erythematosus (SLE)
D	Erythrasma
E	Epidermal naevus

39086

Submit

Audio
Video
Share
Participants
More

11:07

B Tinea axillaris

This is an annular, red lesion with a raised, scaly border, most in keeping with tinea. The rash may well be related to excess sweating linked to sporting activity. Topical azoles are the intervention of choice.

A Acanthosis nigricans

Acanthosis nigricans is associated with a velvety brown hyperpigmentation of the skin, it is associated with obesity, insulin resistance and gastric carcinoma.

C Systemic lupus erythematosus (SLE)

SLE is associated an erythematous rash which worsens on sun exposure.

D Erythrasma

Erythrasma is a superficial skin infection caused by Corynebacterium minutissimum and occurs in skin folds.

E Epidermal naevus

An epidermal nevus is a benign hamartomatous growth. It presents as a group of verrucous, closely grouped, skin-colored to brown papules and develops in childhood.

39086

Rate this question:

Next Question

Rana Alnasser's screen

11:07
594-042-7551
Leave

erythrasma

ALL IMAGES NEWS SHOPPING VIDEOS MAPS BOOKS FLIGHTS

Latest GIF HD Product

groin | wood's lamp | interdigital | corynebacteriu

Erythrasma: Symptoms, Causes, Treatment ...
healthline.com

Erythrasma | DermNet NZ
dermnetnz.org

Erythrasm
healthline

Causes, Symptoms, Treatment, Pictures ...
health9.org

Erythrasma (Skin Disorder) - Signs You ...
lybrate.com

Erythrasm
youtube.c

Erythrasm
diseasesp

Discover Updates Search Recent
Audio Video Share Participants More

11:07

erythrasma

ALL IMAGES NEWS SHOPPING VIDEOS MAPS BOOKS FLIGHTS

Latest GIF HD Product

groin | wood's lamp | interdigital | corynebacteriu

Erythrasma: Symptoms, Causes, Treatment ...
healthline.com

Erythrasma | DermNet NZ
dermnetnz.org

Erythrasm
healthline

Causes, Symptoms, Treatment, Pictures ...
health9.org

Erythrasma (Skin Disorder) - Signs You ...
lybrate.com

Erythrasm
youtube.c

Erythrasm
diseasesp

Discover Updates Search Recent

Rana Alnasser's screen

11:07

The image below shows the lips of a 19-year-old woman who has a family history of cancers, and has recently suffered from a gastrointestinal haemorrhage.

Which of the following features is most likely to be seen in this patient?

A	Coeliac disease
B	Hiatus hernia
C	Intestinal polyps
D	Meckel's diverticulum
E	Peptic ulcer disease

Rana Alnasser's screen

C Intestinal polyps

The presence of pigmented macules (lentigines) on the lips, around the mouth and buccal mucosa (not on the tongue), palm and soles is associated with intestinal polyposis (hamartomas that may occur in both small and large bowel), and describes Peutz–Jeghers syndrome. Malignant transformation of these polyps is rare, but it is associated with increased risk of breast, ovarian and pancreatic cancer. Co-existent gastric adenomas may occur, leading to an increased risk of gastric cancer. Patients may present with complications such as iron deficiency anaemia, frank GI haemorrhage, intestinal obstruction or intussusception, or recurrent abdominal pain.

A Coeliac disease

Coeliac disease can be associated with both angular chelitis and aphthous ulcers, but isn't associated with the pigmentation seen here.

B Hiatus hernia

A hiatus hernia would not usually present with a GI haemorrhage – symptoms of reflux oesophagitis would be the usual finding.

D Meckel's diverticulum

Meckel's diverticulum is not associated with Peutz–Jeghers syndrome, although both may be associated with GI bleeding.

E Peptic ulcer disease

Although peptic ulcer disease is a cause of GI bleeding

Coeliac disease can be associated with both angular chelitis and aphthous ulcers, but isn't associated with the pigmentation seen here.

B Hiatus hernia

A hiatus hernia would not usually present with a GI haemorrhage - symptoms of reflux oesophagitis would be the usual finding.

D Meckel's diverticulum

Meckel's diverticulum is not associated with Peutz-Jeghers syndrome, although both may be associated with GI bleeding.

E Peptic ulcer disease

Although peptic ulcer disease is a cause of GI bleeding, Peutz-Jeghers is associated with gastric adenomas rather than ulcer disease.

Rate this question:

© Pastest 2019

A 45-year-old woman presented with a rash in her lower legs, rigors, fever, and a sore throat. A throat swab revealed the presence of gram positive bacteria organised in chains.

Which of the following skin conditions is she most likely presenting with?

A	Erythema nodosum
B	Erythema annulare centrifugum
C	Erythema migrans
D	Erythema marginatum
E	Erythema induratum

11:10
594-042-7551
Leave

revealed the presence of gram positive bacteria organised in chains.

Which of the following skin conditions is she most likely presenting with?

Your answer was incorrect

A	Erythema nodosum
B	Erythema annulare centrifugum
C	Erythema migrans
D	Erythema marginatum
E	Erythema induratum

Audio Video Share Participants More

11:10
594-042-7551
Leave

A 45-year-old woman presented with a rash in her lower legs, rigors, fever, and a sore throat. A throat swab revealed the presence of gram positive bacteria organised in chains.

Which of the following skin conditions is she most likely presenting with?

Your answer was incorrect

A	Erythema nodosum
B	Erythema annulare centrifugum
C	Erythema migrans
D	Erythema marginatum

Audio Video Share Participants More

11:10
594-042-7551
Leave

A Erythema nodosum

Erythema nodosum is a type of panniculitis (inflammation of the adipose tissue) resulting in red, tender nodules, which commonly occur on the lower legs but may also occur anywhere. It is associated with throat infections due to streptococcus or viral infections (as in this case), sarcoidosis, inflammatory bowel disease, tuberculosis and leprosy.

D Erythema marginatum

Erythema marginatum consists of spreading erythematous rings that are associated with acute rheumatic fever (fever, carditis, migratory polyarthritis,) secondary to infection by group A beta-haemolytic streptococci.

B Erythema annulare centrifugum

Erythema annulare centrifugum is a chronic, recurrent, annular erythema that may be idiopathic or linked to a number of infections, medications and underlying conditions (e.g. Graves disease).

C Erythema migrans

Erythema chronicum migrans develops a few days following a tick bite and is a cutaneous pathognomonic sign of Lyme's disease. Expanding, erythematous lesions occur in a bull's-eye pattern and are associated with flu-like symptoms.

E Erythema induratum

Erythema induratum of Bazin is a rare nodular vasculitis (tender erythematous, indurated nodules and plaques)

Audio Video Share Participants More

11:11

Primary Care Dermatology Society

Erythema nodosum | Primary Care Dermatology Society | UK

Erythema nodosum

Images may be subject to copyright. Learn more

RELATED IMAGES

Erythema nodosum | Plastic Surgery Key
plasticsurgerykey.com

Discover Updates Search Recent

Rana Alnasser's screen

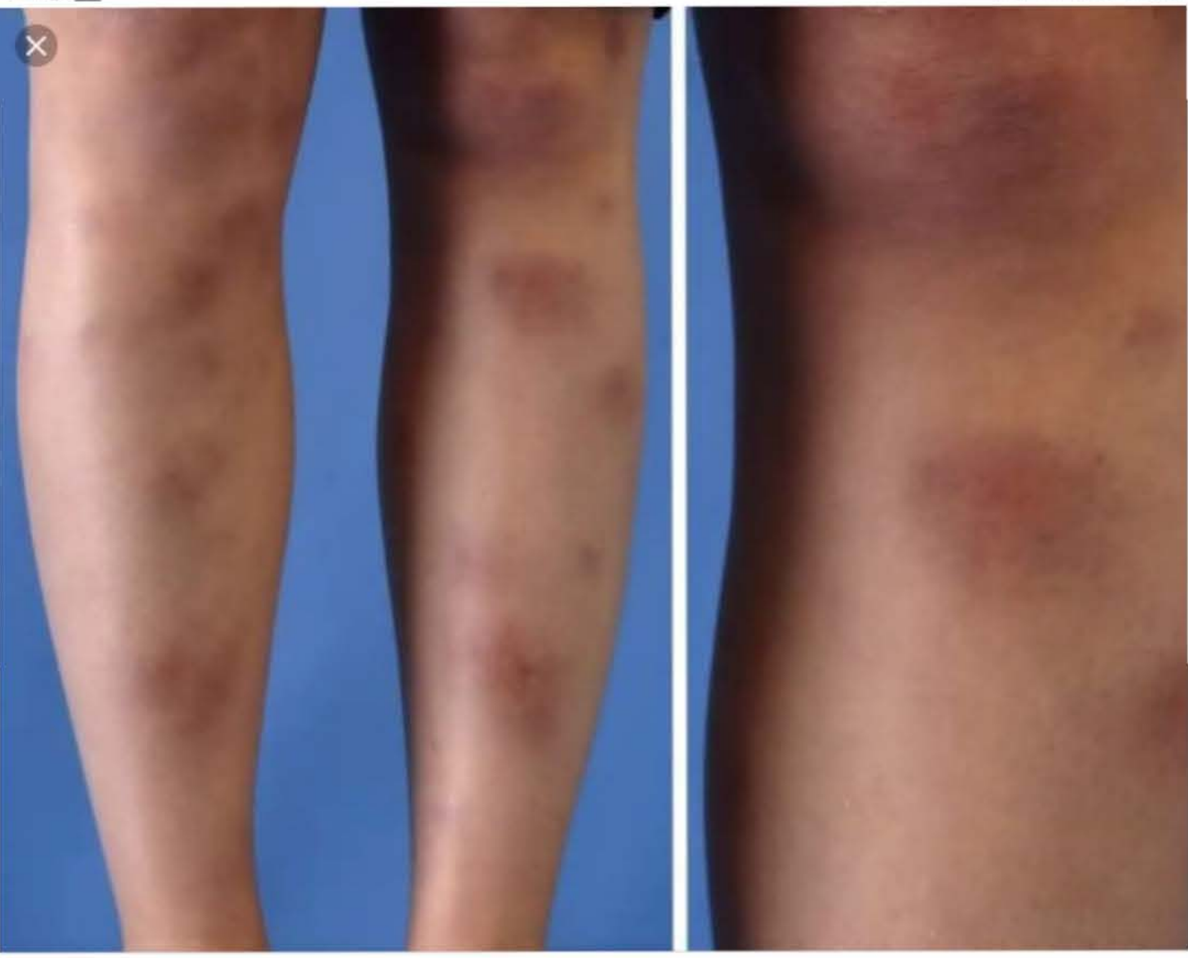

Primary Care Dermatology Society

Erythema nodosum | Primary Care Dermatology Society | UK

Download

Images may be subject to copyright. Learn more

RELATED IMANES

Discover Updates Search Recent More

Rana Alnasser's screen

11:12
594-042-7551
Leave
52%

erythema marginatum

Erythema Marginatum: Causes, Picture ...
healthline.com

Rheumatic fever | DermNet NZ
dermnetnz.org

6 days ago
Rheumatic fever | DermNet NZ
dermnetnz.org

Erythema Marginatum | Pictures, Causes ...
primehealthchannel.com

Erythema Marginatum - Causes, Diagnosis ...
patienthelp.org

Erythema Marginatum - Pictures ...
emedicalhub.com

Erythema marginatum
visualdx.com

Erythema Marginatum|Causes|Symptoms ...
epainassist.com

Erythema Marginatum Rash - YouTube
youtube.com

Erythema Marginatum |
clinicaladvisor.com

Collectio
Discover
Updates
Search
Recent
More
Audio
Video
Share
Participants
More

11:12
594-042-7551
Leave
52%

e Medical Hub

Erythema Marginatum - Pictures, Symptoms and Treatment - (2019 ...

Erythema marginatum picture

Images may be subject to copyright. Learn more

RELATED IMAGES

An erythematous and itchy rash in a child | E...
endocrinologytoday.com.au

Picture of Erythema Annulare Centrifugum
webmd.com

Discover
Updates
Search
Recent
More

Audio
Video
Share
Participants
More

11:13

594-042-7551

Leave

erythema annulare centrifugum

Latest GIF HD Product

pathology deep face trailing scale superficial

Erythema Annulare Centrifugum ...
aocd.org

Erythema Annulare Centrifugum - an ...
sciencedirect.com

Picture of Erythema Annulare Centrifugu
webmd.com

Erythema annulare centrifugum versus ...
gponline.com

Erythema annulare centrifugum
escholarship.org

Erythema Annulare Centrifugum Clinical
emedicine.medscape.com

Discover Updates Search Recent More

Audio Video Share Participants More

11:13
594-042-7551
Leave

erythema annulare centrifugum

My Erythema Annulare Centrifugum story ...
its-not-ringworm.blogspot.com

Erythema annulare centrifugum ...
standardofcare.com

Erythema annulare centrifugum | Lupus ...
pinterest.com

Erythema Annulare Centrifugum ...
medicine.uiowa.edu

Erythema annulare centrifugum - Stock ...
sciencephoto.com

Related Searches

- erythema annulare centrifugum causes
- erythema annulare centrifugum vs ringworm
- trailing scale erythema annulare centrifugum
- erythema marginatum rheumaticum

Erythema Annulare Centrifugum - an ...
sciencedirect.com

Stress-induced erythema annulare ...
escholarship.org

Erythema Annulare Centrifugum ...
consultant360.com

Discover Updates Search Recent More

Audio Video Share Participants More

11:13

A 47-year-old man presents with a lesion on his fourth finger, present for 3 years. It has grown slowly, is not painful and occasionally discharges a jelly-like, sticky fluid, sometimes tinged with blood.

What is the most likely diagnosis?

A	Squamous cell carcinoma
B	Myxoid cyst
C	Baker's cyst
D	Merkel cell carcinoma
E	Acral melanoma

Rana Alnasser's screen

11:14

painful and occasionally discharges a jelly-like, sticky fl
sometimes tinged with blood.

What is the most likely diagnosis?

Your answer was correct

A	Squamous cell carcinoma
B	Myxoid cyst
C	Baker's cyst
D	Merkel cell carcinoma
E	Acral melanoma

Explanation

B Myxoid cyst

Digital mucous (myxoid) cysts arise from degeneration

Rana Alnasser's screen

E Acral melanoma

Explanation

B Myxoid cyst

Digital mucous (myxoid) cysts arise from degeneration of the connective tissue. They may connect with the joint at the end of the finger. They may be found at the base of the nail, or within a centimetre of this. They can cause a nail groove (but not in this case).

A Squamous cell carcinoma

Over the course of 3 years, growth of squamous cell carcinoma would be expected, with increasing size of the lesion accompanied by central necrosis.

C Baker's cyst

Baker's cysts occur in the popliteal fossa and are related to osteoarthritic degeneration of the knee.

D Merkel cell carcinoma

Merkel cell carcinomas are rare, aggressive skin cancers often appearing on the face, head or neck, as flesh-coloured or blue/red nodules.

E Acral melanoma

Acral melanoma occurs on non-hair-bearing surfaces of the body such as the palms, soles, under nails and the oral mucosa. It is the most common melanoma type diagnosed in Asian and sub-Saharan ethnic groups.

Rana Alnasser's screen

A 21-year-old male presents with an itchy, erythematous rash on his back. He is usually fit and well and has no past medical history of note.

Which of the following words best describes the pattern of the skin rash on display?

A	Serpiginous
B	Nummular
C	Reticulated
D	Annular
E	Linear

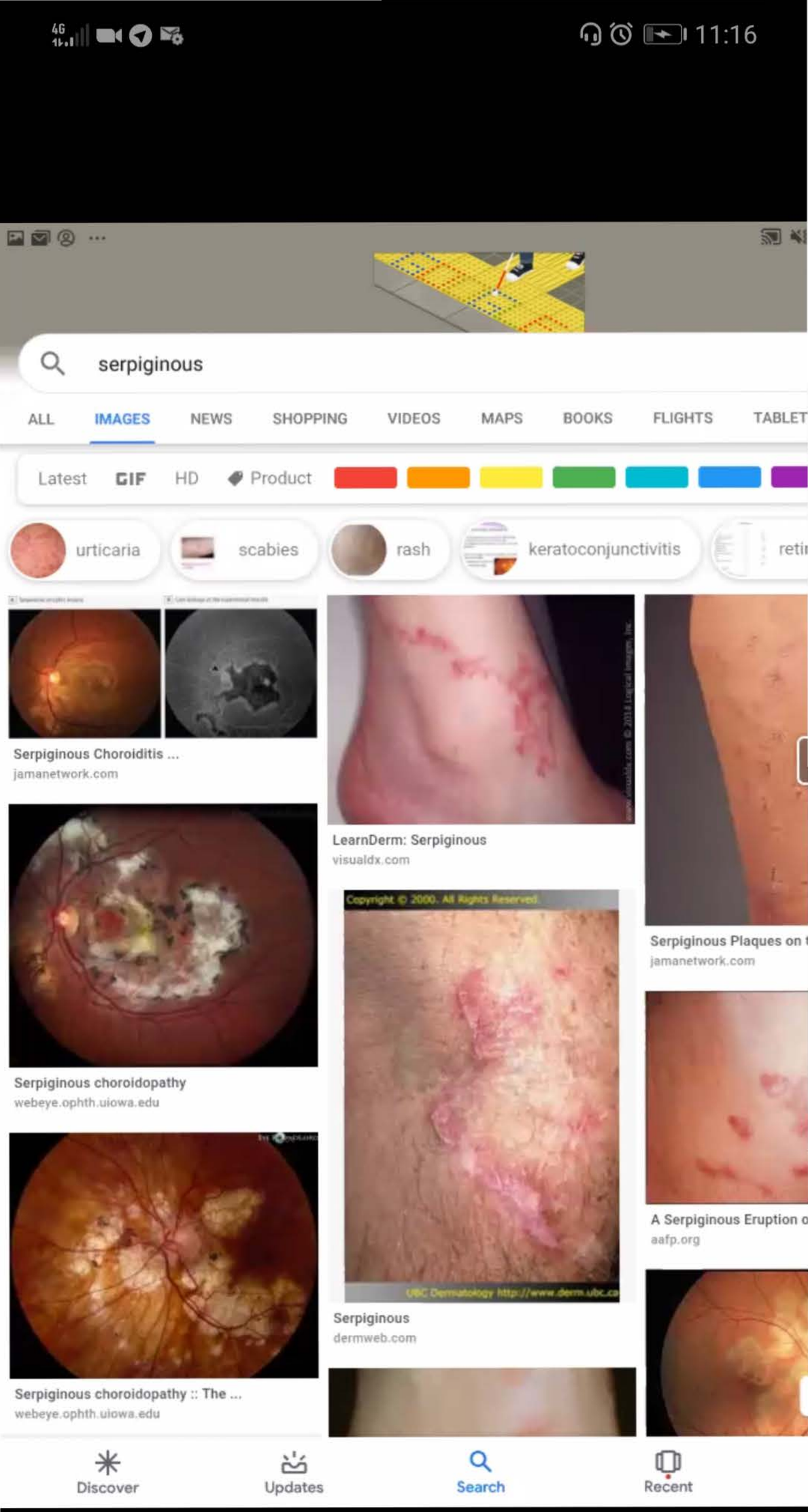
11:16
serpiginous
ALL
IMAGES
NEWS
SHOPPING
VIDEOS
MAPS
BOOKS
FLIGHTS
TABLET
Latest
GIF
HD
Product
urticaria
scabies
rash
keratoconjunctivitis
Serpiginous Choroiditis ...
jamanetwork.com
LearnDerm: Serpiginous
visualdx.com
Serpiginous Plaques on t
jamanetwork.com
Serpiginous choroidopathy
webeye.ophth.uiowa.edu
Copyright © 2000. All Rights Reserved.
Serpiginous
dermweb.com
A Serpiginous Eruption o
aafp.org
Serpiginous choroidopathy :: The ...
webeye.ophth.uiowa.edu
Discover
Updates
Search
Recent
Rana Alnasser's screen

11:16
594-042-7551
Leave

D Annular

The pattern here is of ring shaped areas of erythema with central clearing, which fits well with an annular rash.

A Serpiginous

Serpiginous rashes are curved, forming the shape of a serpent, (hence their name).

B Nummular

Nummular rashes are circular and coin shaped and do not have the central clearing seen here.

C Reticulated

A reticulated rash has a lace or networked pattern, rather than the picture seen here.

E Linear

Linear rashes occur in lines; an example is lichen striatus, which is most commonly seen in children.

Rate this question:

Next Question

Audio Video Share Participants More

11:19

A 56-year-old woman presents with the following lesion on her shoulder. She thinks that it has been present all of her life.

Her husband has noticed that it has grown in size over the last few months. It is not itchy nor has it ever bled.

She has no other medical problems and takes no regular medications.

What is the diagnosis?

A	Pigmented basal cell carcinoma (BCC)
B	Benign melanocytic naevus
C	Solar lentigo
D	Superficial spreading melanoma
E	Seborrhoeic keratosis

Rana Alnasser's screen

D Superficial spreading melanoma

A malignant melanoma is a tumour of the melanocytes. Two-thirds arise from normal skin, and one-third from pre-existing moles. Superficial spreading malignant melanomas occur as malignant melanocytes migrate laterally along the dermo-epidermal junction, and have a good prognosis. It is important to diagnose and treat melanomas while they are thin, so that removal may result in favourable prognostic outcomes.

A Pigmented basal cell carcinoma (BCC)

Pigmented BCCs are a less common variant of BCCs. They present with the typical features of a BCC (slow-growing, asymptomatic nodule with rolling edges and ulceration in sun-exposed sites) and a darker, rather than pearly, colour.

B Benign melanocytic naevus

Benign moles typically have a symmetrical appearance with smooth edges, regular borders and < 2 colours. Benign naevi do not usually grow in size after the age of 40, but may instead slowly involute.

C Solar lentigo

A solar lentigo, also known as liver spot, age spot and senile freckle, is a flat, well-circumscribed patch of darker skin. The size varies from a few millimetres to several centimetres in diameter. Solar lentigines are found on sun-exposed sites, particularly the face or the back of the hands, and tend to be more numerous in fair-skinned individuals.

E Seborrhoeic keratosis

11:21

solar lentigo

ALL IMAGES SHOPPING NEWS VIDEOS MAPS BOOKS FLIG

Latest GIF HD Product

dermoscopy inflamed large face

Solar lentigo | DermNet NZ
dermnetnz.org

5 days ago

Solar lentigo | DermNet NZ
dermnetnz.org

Solar
derm

Solar lentigo | DermNet NZ
dermnetnz.org

Solar Lentigo Picture Image on ...
medicinenet.com

Lenti
pcds.

Lentigo: Background, Pathophysiology ...
emedicine.medscape.com

Laser Treat Liver Spots (Solar Lentigo ...
phillipsaestheticdermatology.com

Solar
derm

Discover Updates Search Recen

Rana Alnasser's screen

11:21

MedicineNet

Solar Lentigo Picture Image on MedicineNet.com

Picture of Solar Lentigo

Images may be subject to copyright. Learn more

RELATED IMAGES

Hutchinson freckle melanoma | Blog
bordadelespubilles.com

Treatment of Facial Lentigines in Peutzâ·fiJ...
onlinelibrary.wiley.com

Frecl
abqjo

Discover Updates Search Recer

Rana Alnasser's screen

with smooth edges, regular borders and < 2 colours.
Benign naevi do not usually grow in size after the age of 40, but may instead slowly involute.

C Solar lentigo

A solar lentigo, also known as liver spot, age spot and senile freckle, is a flat, well-circumscribed patch of darker skin. The size varies from a few millimetres to several centimetres in diameter. Solar lentigines are found on sun-exposed sites, particularly the face or the back of the hands, and tend to be more numerous in fair-skinned individuals.

E Seborrhoeic keratosis

Seborrhoeic keratoses are benign, raised lesions that can occur on both sun-exposed and covered body parts. They have a characteristic warty, stuck-on, greasy appearance, with surface crypts and pits.

Rate this question:

Next Question

Previous Q... Tag Questi... Feedback End Session

Blog About Pastest Contact Us Help

© Pastest 2019

How would you describe the nail changes in the above image?

A	Onychogryphosis
B	Onychorrhexis
C	Koilonychia
D	Onychomadesis
E	Onycholysis

35037

Submit

Previous Q... Skip Questi...

E Onycholysis

Explanation

E Onycholysis

Onycholysis is a common condition where the nail plate separates from an abnormal nail matrix, and is associated with trauma, infection and a number of skin diseases, including cutaneous lupus and pemphigus.

A Onychogryphosis

Onychogryphosis, or ram's horn nails are hypertrophied nails resembling claws or a ram's horn and often seen in the elderly who fail to cut their nails.

B Onychorrhexis

Onychorrhexis is caused by diffuse damage to the nail bed resulting in thinning, longitudinal ridging and fissuring of the nail.

C Koilonychia

These are spoon-shaped nails related to iron deficiency anaemia.

D Onychomadesis

Onychomadesis occurs due to arrest of all matrix activity and causes nail shedding.

Rate this question:

11:23
594-042-7551
Leave

onychorrhexis

ALL IMAGES SHOPPING NEWS VIDEOS MAPS BOOKS FLIG

Latest GIF HD Product

treatment nail disorder definition dog onychoschizia di

Showing results for *onychorrhexis*
No results found for ***nychorhexis***

Onychorrhexis: Pictures, Causes ...
hxbenefit.com

Onychorrhexis: Pictures, Causes ...
hxbenefit.com

What Is Onychorrhexis? - Health - NAILS ...
nailsmag.com

15 Brittle Nails Home Remedies and ...
remedyland.com

Discover Updates Search Recen
Audio Video Share Participants More

11:24
594-042-7551
Leave

onychomadesis

Onychomadesis Following a Fish Pedicure ...
jamanetwork.com

Neonatal onychomadesis | ADC Fetal ...
fn.bmj.com

Idiop
jama

hand-foot-and-mouth disease ...
cmaj.ca

Onychomadesis - Causes, Pictures and ...
healthdiseases.org

Hand
mded

Hand-foot-and-mouth Disease ...
mdedge.com

Shedding Light on Onychomadesis ...
mdedge.com

Thre
resea

VIRTUAL GRAND ROUNDS IN DERMATOLOG...
vgrd.blogspot.com

Onyc
ijpd.

Related Searches

hand foot mouth onychomadesis

Discover Updates Search Recen
Audio Video Share Participants More

11:24
594-042-7551 Leave

A 33-year-old man returned 2 weeks ago from an 8-month business trip with colleagues to Peru. He noticed a few papules on his trunk. Two of these have evolved to form superficial ulcers.

He feels well in himself and denies fever, diarrhoea or headaches. He does remember having a flu-like illness while he was in Peru.

Routine bloods, including full blood count and white cell differential, are normal.

Which is the most likely diagnosis?

A	Cutaneous leishmaniasis
B	Cutaneous larva migrans
C	Tick typhus eschar
D	Dengue fever
E	Cutaneous tuberculosis

Submit

Audio Video Share Participants More

11:25
594-042-7551 Leave

A 33-year-old man returned 2 weeks ago from an 8-month business trip with colleagues to Peru. He noticed a few papules on his trunk. Two of these have evolved to form superficial ulcers.

He feels well in himself and denies fever, diarrhoea or headaches. He does remember having a flu-like illness while he was in Peru.

Routine bloods, including full blood count and white cell differential, are normal.

Which is the most likely diagnosis?

Your answer was correct

A	Cutaneous leishmaniasis
B	Cutaneous larva migrans
C	Tick typhus eschar
D	Dengue fever
E	Cutaneous tuberculosis

Explanation

A Cutaneous leishmaniasis

Cutaneous leishmaniasis (CL) is the most likely diagnosis

Audio Video Share Participants More

11:25
594-042-7551 Leave

A Cutaneous leishmaniasis

Cutaneous leishmaniasis (CL) is the most likely diagnosis from the history. The incubation time is 7 days to several months. In cutaneous larva migrans, worm-like lesions have an incubation period 1–4 days and are found mainly after holidays to Caribbean beaches. Treatment of CL is determined by species type and by the potential to develop into mucosal disease.

B Cutaneous larva migrans

Cutaneous larva migrans occurs as a result of hookworm infection caused by walking barefoot. The trails caused by the larvae are usually seen on the feet and ankles.

C Tick typhus eschar

The eschar of tick typhus is a papule, which evolves to a black scab. This condition is also found in southern Africa, and has an incubation period of fewer than 7 days.

D Dengue fever

Dengue fever occurs in tropical countries, with an incubation period of under two weeks and is associated with systemic features and a morbilliform rash.

E Cutaneous tuberculosis

Cutaneous lesions are relatively uncommon in TB infection, occurring in only 1-2% of infected patients. The clinical findings vary: inflammatory papules, verrucous plaques, suppurative nodules, chronic ulcers or other lesions may be seen. Superficial ulcers on the trunk are not a usual manifestation of TB.

Audio Video Share Participants More

holidays to Caribbean beaches. Treatment of CL is determined by species type and by the potential to develop into mucosal disease.

B Cutaneous larva migrans

Cutaneous larva migrans occurs as a result of hookworm infection caused by walking barefoot. The trails caused by the larvae are usually seen on the feet and ankles.

C Tick typhus eschar

The eschar of tick typhus is a papule, which evolves to a black scab. This condition is also found in southern Africa, and has an incubation period of fewer than 7 days.

D Dengue fever

Dengue fever occurs in tropical countries, with an incubation period of under two weeks and is associated with systemic features and a morbilliform rash.

E Cutaneous tuberculosis

Cutaneous lesions are relatively uncommon in TB infection, occurring in only 1-2% of infected patients. The clinical findings vary: inflammatory papules, verrucous plaques, suppurative nodules, chronic ulcers or other lesions may be seen. Superficial ulcers on the trunk are not a usual manifestation of TB.

Rate this question:

Next Question

A 29-year-old woman, who is 34 weeks' pregnant, presents with an erythematous, blistering rash on her upper thigh and abdomen. There is no history of systemic illness and the pregnancy has been unremarkable so far. She has no past medical history of note and took no regular medication before her pregnancy.

On examination, there are multiple small, irregularly shaped blisters over the lower abdomen and the tops of her thighs. Blood pressure and temperature are normal.

Investigations:

Hb	10.9 g/dl
WCC	5.8×10^9/l
PLT	190×10^9/l
Na^+	139 mmol/l
K^+	4.6 mmol/l
Creatinine	90 µmol/l
ESR	10 mm/hr

Given the likely dermatological diagnosis, which of the following represents the most appropriate initial treatment for this patient?

A Oral prednisolone

B Acyclovir ointment

C Corticosteroid ointment

D Oral antihistamines

E Intravenous immunoglobulins

11:27

medication before her pregnancy.

On examination, there are multiple small, irregularly shaped blisters over the lower abdomen and the tops of her thighs. Blood pressure and temperature are normal.

Investigations:

Hb	10.9 g/dl
WCC	5.8×10^9/l
PLT	190×10^9/l
Na^+	139 mmol/l
K^+	4.6 mmol/l
Creatinine	90 µmol/l
ESR	10 mm/hr

Given the likely dermatological diagnosis, which of the following represents the most appropriate initial treatment for this patient?

A Oral prednisolone

B Acyclovir ointment

C Corticosteroid ointment

D Oral antihistamines

E Intravenous immunoglobulins

Submit

Rana Alnasser's screen

11:27

Explanation

C Corticosteroid ointment

High-potency topical corticosteroids are indicated for localised disease, e.g. her lower abdomen and top of thighs.

A Oral prednisolone

This treatment line is indicated if topical steroids are not controlling the symptoms.

B Acyclovir ointment

This condition is not viral in nature and therefore will not respond to acyclovir.

D Oral antihistamines

This may only help with symptomatic pruritus control rather than treating the autoimmune condition.

E Intravenous immunoglobulins

This may be indicated only if the patient has severe persistent postpartum pemphigoid gestationis or does not respond to oral corticosteroids/corticosteroids, or these are not suitable (e.g. gestational diabetes).

This patient has pemphigoid gestationis (which was previously known as herpes gestationis). This is a rare autoimmune bullous disease that occurs during 2nd or 3rd trimester. It can be associated with increased fetal risk, such as preterm birth. It is caused by circulating autoantibodies directed against the BP 180 antigen, which

Rana Alnasser's screen

B Acyclovir ointment

This condition is not viral in nature and therefore will not respond to acyclovir.

D Oral antihistamines

This may only help with symptomatic pruritus control rather than treating the autoimmune condition.

E Intravenous immunoglobulins

This may be indicated only if the patient has severe persistent postpartum pemphigoid gestationis or does not respond to oral corticosteroids/corticosteroids, or these are not suitable (e.g. gestational diabetes).

This patient has pemphigoid gestationis (which was previously known as herpes gestationis). This is a rare autoimmune bullous disease that occurs during 2nd or 3rd trimester. It can be associated with increased fetal risk, such as preterm birth. It is caused by circulating autoantibodies directed against the BP 180 antigen, which is a transmembrane glycoprotein expressed in the basement membrane zone of the skin. Antibodies against the BP 180 antigens can be detected in the serum and can be used to monitor response to treatment.

Treatment of pemphigoid gestationis is to decrease blister formation, promote healing and relieve pruritis. Topical corticosteroids are usually indicated initially, especially if the condition is localised. Oral corticosteroids can be introduced if the rash is more widespread or if there is no response to the topical treatment. Immunosuppression agents, such as azathioprine, IVIG or cyclosporine, could also be used as alternatives in severe postpartum pemphigoid gestationis.

Rate this question:

11:28
594-042-7551
Leave

pemphigoid gestationis

ALL IMAGES NEWS VIDEOS SHOPPING MAPS BOOKS FL

Latest GIF HD Product

pregnancy immunofluorescence baby pa

Pemphigoid gestationis | DermNet NZ
dermnetnz.org

Pemphigoid gestationis | DermNet NZ
dermnetnz.org

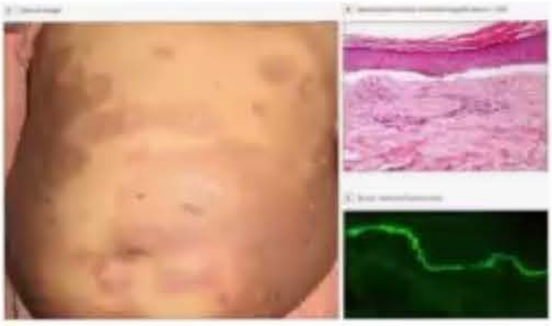

Patients With Pemphigoid Gestationis ...
jamanetwork.com

Pemphigoid gestationis | DermNet NZ
dermnetnz.org

Full text] Pemphigoid gestationis ...
dovepress.com

Full text] Pemphigoid gestationis ...
dovepress.com

Discover Updates Search Rec
Audio Video Share Participants More

A 45-year-old man has a long-standing rash. He thought it had cleared up, but it has recurred in a recent scar from minor surgery.

Which of the following conditions exhibits this phenomenon?

A Eczema

B Sarcoid

C Lichen planus

D Pemphigoid

E Acne

33392

Submit

Previous Q... Skip Questi...

© Pastest 2019

11:32

C Lichen planus

The appearance of a rash in a scar or in the site of an injury is known as Koebner's phenomenon. The Koebner reaction usually appears around 7–14 days after the injury. Skin disorders that show this reaction include psoriasis, lichen planus and vitiligo. The Koebner response occurs in up to 20% of patients with psoriasis. The term pseudo-Koebner is used for conditions such as molluscum contagiosum and viral warts, where the phenomenon arises from the spread of an infective agent. The reverse Koebner phenomenon also exists where trauma to a lesion results in it resolving.

A Eczema

Eczema doesn't exhibit the Koebner phenomenon, and occurs predominantly as an erythematous rash on flexural surfaces.

B Sarcoid

Sarcoidosis is associated with erythema nodosum, which is seen on the shins and isn't related to local injury.

D Pemphigoid

Bullous pemphigoid is an autoimmune skin condition where tense bullae occur, predominantly on areas where skin-to-skin contact may occur such as the upper thighs or the inside of the upper arms.

E Acne

Acne does not exhibit the Koebner phenomenon, although in individuals prone to acne, application of surgical dressings may lead to development of new lesions

Rana Alnasser's screen

Eczema doesn't exhibit the Koebner phenomenon, and occurs predominantly as an erythematous rash on flexural surfaces.

B Sarcoid

Sarcoidosis is associated with erythema nodosum, which is seen on the shins and isn't related to local injury.

D Pemphigoid

Bullous pemphigoid is an autoimmune skin condition where tense bullae occur, predominantly on areas where skin-to-skin contact may occur such as the upper thighs or the inside of the upper arms.

E Acne

Acne does not exhibit the Koebner phenomenon, although in individuals prone to acne, application of surgical dressings may lead to development of new lesions underneath where the dressing has been.

Rate this question:

© Pastest 2019

A 36-year-old male is referred by his GP with this lesion on his anterior shoulder. He feels it is unsightly and that it may need to be removed.

When did the lesion most likely appear?

A	At birth
B	At onset of puberty
C	In the last 2-3 years
D	Related to sun exposure in the last 10 years
E	Related to alcohol consumption

Submit

Explanation

B At onset of puberty

This is a late onset epidermal naevus or birthmark, which occurs mainly in males and is triggered to develop in puberty by circulating androgens. The linear nature of the lesions with evidence of increased pigmentation/keratosis is more typical of an adolescent onset lesion rather than one which presents at birth.

A At birth

Congenital naevi identified at birth tend not to follow the linear pattern seen here, making the lesion less likely to have been present at birth.

C In the last 2-3 years

As these lesions are related to the puberty related hormone surge and there is no evidence of use of unregulated androgens for body building, it's highly unlikely this man's naevus has worsened over the past 2-3 years.

D Related to sun exposure in the last 10 years

Excessive skin exposure may result in development of a skin cancer, but the picture here is much more consistent with a benign epidermal naevus.

E Related to alcohol consumption

Alcohol consumption and smoking have no impact on the growth of late onset epidermal naevi

B At onset of puberty

This is a late onset epidermal naevus or birthmark, which occurs mainly in males and is triggered to develop in puberty by circulating androgens. The linear nature of the lesions with evidence of increased pigmentation/keratosis is more typical of an adolescent onset lesion rather than one which presents at birth.

A At birth

Congenital naevi identified at birth tend not to follow the linear pattern seen here, making the lesion less likely to have been present at birth.

C In the last 2-3 years

As these lesions are related to the puberty related hormone surge and there is no evidence of use of unregulated androgens for body building, it's highly unlikely this man's naevus has worsened over the past 2-3 years.

D Related to sun exposure in the last 10 years

Excessive skin exposure may result in development of a skin cancer, but the picture here is much more consistent with a benign epidermal naevus.

E Related to alcohol consumption

Alcohol consumption and smoking have no impact on the growth of late onset epidermal naevi.

11:35

A 47-year-old man is referred to the Medical Clinic for investigation of microcytic anaemia. He has not noticed any symptoms of anaemia and no change to bowel habit, nor change in his weight.

He has a past medical history of frequent epistaxis and asthma. He takes no regular medication but has a salbutamol inhaler.

A photograph of his lip is shown below.

What investigation would be most appropriate to establis an underlying diagnosis?

A	Computed tomography (CT) angiogram bowel
B	Clotting screen
C	Liver function tests
D	Anti-nuclear antibodies
E	Human immunodeficiency virus (HIV) testing

Rana Alnasser's screen

A Computed tomography (CT) angiogram bowel

This patient has telangiectasia on his lips with a history of epistaxis, as well as microcytic anaemia suggestive of chronic blood loss. This makes the diagnosis of Osler–Weber–Rendu syndrome likely. It is necessary to use CT angiography, or MR angiography, to further identify lesions to establish a diagnosis. Osler–Weber–Rendu syndrome is also known as hereditary haemorrhagic telangiectasia, and is an autosomal dominant condition characterised by vascular dysplasia leading to telangiectasia, as well as increased frequency of arteriovenous malformations, particularly of the gastrointestinal tract, lungs, liver and brain.

B Clotting screen

A clotting screen would be more likely to be helpful in diagnosis in a patient with a haemophilia. That would be been suggested by a history of easy bruising or bleeding, or spontaneous internal bleeding such as haemarthrosis.

C Liver function tests

Liver function would be more useful if there were evidence of chronic liver failure or a cause of chronic liver disease. In patients with end-stage liver disease, there can be increased frequency towards bleeding and abnormal clotting. There can also be venous congestion, but this normally manifests as spider naevi.

D Anti-nuclear antibodies

Anti-nuclear antibodies would be a useful first-line investigation in various autoimmune conditions, such as

11:38

A 58-year-old man presents with progressive changes in his facial skin. He has noticed reddening with painful spots on his face and a gradual swelling and distortion of his nose.

In his past medical history, he had a renal transplant in 1989. He takes a list of medications but he cannot remember exactly what they are. He is a non-smoker and drinks 14 units of alcohol per week. He has no allergies. He tells you that since he went on holiday to Spain this year the symptoms have got worse. He lives with his wife.

On examination, the patient has numerous erythematous and yellowish papules and nodules as well as swelling of the nose. The skin over the trunk is covered with extensive seborrhoeic warts. There were a couple of actinic keratose on the scalp.

What diagnosis would best explain the appearance?

A	Acne vulgaris
B	Cutaneous lymphoma
C	Dyslipidaemia

Rana Alnasser's screen

In his past medical history, he had a renal transplant in 1989. He takes a list of medications but he cannot remember exactly what they are. He is a non-smoker and drinks 14 units of alcohol per week. He has no allergies. He tells you that since he went on holiday to Spain this year the symptoms have got worse. He lives with his wife.

On examination, the patient has numerous erythematous and yellowish papules and nodules as well as swelling of the nose. The skin over the trunk is covered with extensive seborrhoeic warts. There were a couple of actinic keratose on the scalp.

What diagnosis would best explain the appearance?

A Acne vulgaris

B Cutaneous lymphoma

C Dyslipidaemia

D Rosacea

E Uraemia

D Rosacea

This gentleman has rhinophyma – localised swelling of sof tissue with variable combinations of sebaceous hyperplasia, fibrosis and lymphoedema. Sebaceous hyperplasia is a recognised side effect of ciclosporin treatment, particularly on the skin of renal transplant patients when exposed to sunlight.
Rosacea is a rash which, although more common in females, occurs also in males and is associated with rhinophyma. It is an erythema of the face with telangiectasia. It is similar to acne in that there are papules and pustules but no comedones. Complications such as blepharitis, chronic lymphoedema of the face and rhinophyma occur more commonly in men.

Steroid rosacea usually occurs as a result of topical steroids applied to the face. Unfortunately, a large number of people use other family members' creams and ointment without seeking advice from the doctor first. It is importan to ensure that you question the patient about use of all topical treatments.
Contrary to popular belief, it is not associated with excessive alcohol intake. Skin cancers, despite being more common in renal transplant patients, always present as ulcerative nodular lesions before infiltrating deeper. Active rosacea should be treated with oral antibiotics in the first instance. Treatment of the rhinophyma by surgical excisio or physical ablation of excess tissue may improve cosmeti appearance.

A Acne vulgaris

Acne vulgaris occurs as a more generalised papular and pustular rash, not only affecting the face but affecting the back and chest as well.

without seeking advice from the doctor first. It is importar to ensure that you question the patient about use of all topical treatments.
Contrary to popular belief, it is not associated with excessive alcohol intake. Skin cancers, despite being more common in renal transplant patients, always present as ulcerative nodular lesions before infiltrating deeper. Active rosacea should be treated with oral antibiotics in the first instance. Treatment of the rhinophyma by surgical excisior or physical ablation of excess tissue may improve cosmeti appearance.

A Acne vulgaris

Acne vulgaris occurs as a more generalised papular and pustular rash, not only affecting the face but affecting the back and chest as well.

B Cutaneous lymphoma

Cutaneous lymphoma occurs as a generalised erythematous rash, is intensely itchy and is usually seen in more elderly patients.

C Dyslipidaemia

Painless yellow papules (eruptive xanthomas) are seen in groups on the torso, elbows and buttocks, and are associated with hypertriglyceridaemia.

E Uraemia

Uraemia is associated with dermatitis and itching, rather than the rash largely confined to skin folds around the nos seen here.

11:41

A 39-year-old woman, who has a history of sarcoid and is currently managed with a tapering dose of steroids, is worried about going to Spain on holiday because she feels that the spots at the sides of her nose may significantly worsen in the sun. The picture is shown below.

Which of the following is the most appropriate advice / intervention?

A	Add azathioprine
B	Increase the dose of systemic corticosteroids again
C	Local 5-FU cream
D	Sun block
E	Thalidomide

Rana Alnasser's screen

Explanation

B Increase the dose of systemic corticosteroids again

The papules around the edges of both nostrils are consistent with lupus pernio, a recognised cutaneous manifestation of sarcoid which is associated with more severe disease. It responds poorly to topical agents, and therefore an increase in systemic therapy is the treatment of choice.

D Sun block

Although sun exposure worsens the rash of lupus pernio, avoidance of sun alone won't resolve the condition versus an increase in steroid dose.

A Add azathioprine

Azathioprine is the default second-line agent in the event that the acute increase in corticosteroid dose fails to control symptoms.

C Local 5-FU cream

Topical agents such as 5-FU have little effect on symptoms of lupus pernio.

E Thalidomide

Thalidomide is used as a third-line agent for patients who fail to respond to corticosteroids, and a conventional second-line agent such as azathioprine.

34149

Rate this question:

11:43

A 44-year-old woman presents with progressive swelling of both hands. She has noticed them becoming whiter at times. She also complains of dyspnoea on exertion of up to 400 yards. She denies any palpitations or chest pain. She smokes 25 cigarettes a day and drinks 14 units of alcohol a week.

She currently takes lansoprazole prescribed by her general practitioner (GP) for gastro-oesophageal reflux disease.

Examination of her hands reveals evidence of calcinosis.

Which of the following investigations is most likely to point to the underlying diagnosis?

A	ESR
B	Eosinophil count
C	c-ANCA testing
D	Anti-mitochondrial antibody testing
E	Anti-centromere antibody testing

33383

Submit

Previous Q... Skip Questi...

Rana Alnasser's screen

A 44-year-old woman presents with progressive swelling of both hands. She has noticed them becoming whiter at times. She also complains of dyspnoea on exertion of up to 400 yards. She denies any palpitations or chest pain. She smokes 25 cigarettes a day and drinks 14 units of alcohol a week.

She currently takes lansoprazole prescribed by her general practitioner (GP) for gastro-oesophageal reflux disease.

Examination of her hands reveals evidence of calcinosis.

Which of the following investigations is most likely to point to the underlying diagnosis?

Your answer was correct

A ESR

B Eosinophil count

C c-ANCA testing

D Anti-mitochondrial antibody testing

E Anti-centromere antibody testing

Explanation

E Anti-centromere antibody testing

Scleroderma is a rare multi-system chronic condition of unknown cause. It is characterised by tissue fibrosis, small [illegible] (Raynaud's phenomenon) and

Rana Alnasser's screen

associated with CREST (specificity 90%+).

A ESR

Elevated ESR is a non-specific marker of inflammation, and won't pinpoint the nature of any underlying vasculitis.

B Eosinophil count

Eosinophilic vasculitis, formerly known as Churg-Strauss syndrome, is associated with symptoms of uncontrolled asthma, a purpuric skin rash and mononeuritis multiplex, rather than the picture seen here.

C c-ANCA testing

C-ANCA positivity is associated with microscopic polyangiitis with granuloma formation, features of which include midline sinusitis and pulmonary and renal vasculitis.

D Anti-mitochondrial antibody testing

Anti-mitochondrial antibodies are specific for primary biliary cirrhosis, but are not associated with the features of systemic sclerosis seen here.

Rate this question:

Next Question

Previous Q... Tag Questi... Feedback End Session

Rana Alnasser's screen

E Anti-centromere antibody testing

Scleroderma is a rare multi-system chronic condition of unknown cause. It is characterised by tissue fibrosis, small blood vessel vasculopathy (Raynaud's phenomenon) and autoimmunity. Diffuse scleroderma is characterised by both cutaneous and visceral involvement, with rapid skin thickening on the extremities, face and trunk. Limited scleroderma has a lower risk of early visceral involvement. The features of calcinosis, Raynaud's phenomenon, oesophageal dysmotility and telangiectasia meant that it was historically referred to as CREST. In scleroderma, anti-topoisomerase antibody is positive in up to 60% of patients. Anti-centromere antibodies are most strongly associated with CREST (specificity 90%+).

A ESR

Elevated ESR is a non-specific marker of inflammation, and won't pinpoint the nature of any underlying vasculitis.

B Eosinophil count

Eosinophilic vasculitis, formerly known as Churg–Strauss syndrome, is associated with symptoms of uncontrolled asthma, a purpuric skin rash and mononeuritis multiplex, rather than the picture seen here.

C c-ANCA testing

C-ANCA positivity is associated with microscopic polyangiitis with granuloma formation, features of which include midline sinusitis and pulmonary and renal vasculitis.

D Anti-mitochondrial antibody testing

Rana Alnasser's screen

Anti-mitochondrial antibodies are specific for primary

11:44
594-042-7551 Leave

Elevated ESR is a non-specific marker of inflammation, and won't pinpoint the nature of any underlying vasculitis.

B Eosinophil count

Eosinophilic vasculitis, formerly known as Churg–Strauss syndrome, is associated with symptoms of uncontrolled asthma, a purpuric skin rash and mononeuritis multiplex, rather than the picture seen here.

C c-ANCA testing

C-ANCA positivity is associated with microscopic polyangiitis with granuloma formation, features of which include midline sinusitis and pulmonary and renal vasculitis.

D Anti-mitochondrial antibody testing

Anti-mitochondrial antibodies are specific for primary biliary cirrhosis, but are not associated with the features of systemic sclerosis seen here.

Rate this question:

© Pastest 2019

Audio Video Share Participants More

11:44
594-042-7551
Leave

A 36-year-old man presented to the Emergency Department with the following rash, which appeared 3 days ago.

Which of the following is most associated with this skin rash?

A	Crohn's disease
B	Mycoplasma infection
C	Orf
D	Tuberculosis
E	Alcoholism

Submit

Previous Q...
Skip Questi...
Audio
Video
Share
Participants
More

B Mycoplasma infection

This man has erythema multiforme. He shows the classical target lesions. These have three zones: a central area of dusky erythema, a middle paler zone of oedema and an outer erythematous ring. The lesions preferentially involve the extremities and trunk. They usually appear in successive crops and fade in 1–2 weeks. There are multiple triggering factors, although the cause is not determined in up to 50% of cases. The most common association is with preceding herpes simplex or mycoplasma infection, although drugs such as sulphonamides and penicillins are also frequently implicated.

A Crohn's disease

Crohn's disease is associated with a number of skin manifestations, including erythema nodosum and pyoderma gangrenosum.

C Orf

Orf is a parapox virus transmitted by sheep and goats; although it is a cause of erythema multiforme, it is a less common cause than mycoplasma infection.

D Tuberculosis

Like Crohn's disease, tuberculosis is associated with erythema nodosum rather than the erythema multiforme seen here.

E Alcoholism

Alcoholism is associated with guttate psoriasis, which leads [illegible] ling lesions rather than the

Rana Alnasser's screen

A 38-year-old accountant presents with a 5-week history of a painless ulcer on his lower lip. He was given aciclovir by his general practitioner (GP), with little improvement, and has also been using chlorhexidine mouthwash.

Over the last week, he has been feeling tired, with a sore throat and flu-like symptoms. He tells you that he is homosexual and has had at least ten male sexual partners over the last 3 months, with some of whom he has had unprotected sexual intercourse. He is a smoker of 30 cigarettes a day and drinks 25 units of alcohol per week.

On examination, there is an ulcerated lesion on the inner lower lip. There are two other smaller ulcers on the inner right cheek. There are no other skin lesions; he has palpable cervical lymph nodes and a small patch of occipital alopecia.

Respiratory, abdominal, neurological and genital examinations are unremarkable.

Which of the following diagnoses is most likely?

A	Chancroid
B	Secondary syphilis
C	Primary herpes simplex virus (HSV) infection
D	Gonorrhoea
E	Behçet's disease

33384

Rana Alnasser's screen

has also been using chlorhexidine mouthwash.

Over the last week, he has been feeling tired, with a sore throat and flu-like symptoms. He tells you that he is homosexual and has had at least ten male sexual partners over the last 3 months, with some of whom he has had unprotected sexual intercourse. He is a smoker of 30 cigarettes a day and drinks 25 units of alcohol per week.

On examination, there is an ulcerated lesion on the inner lower lip. There are two other smaller ulcers on the inner right cheek. There are no other skin lesions; he has palpable cervical lymph nodes and a small patch of occipital alopecia.

Respiratory, abdominal, neurological and genital examinations are unremarkable.

Which of the following diagnoses is most likely?

Your answer was correct

A Chancroid

B Secondary syphilis

C Primary herpes simplex virus (HSV) infection

D Gonorrhoea

E Behçet's disease

Explanation

B Secondary syphilis

The answer is Secondary syphilis (Option B).

The patient's symptoms are due to secondary syphilis but

B Secondary syphilis

The answer is Secondary syphilis (Option B).

The patient's symptoms are due to secondary syphilis but could also be accounted for by human immunodeficiency virus (HIV) seroconversion. Secondary syphilis usually commences 4–10 weeks after the primary chancre (which can also occur in the oral cavity). Patients usually present with maculopapular rashes affecting the entire trunk, but any form of rash may occur. Alopecia is well recognised, as are multiple painless aphthous ulcers. Sore throat, myalgia, fever and weight loss are also common.

A Chancroid

Chancroid (Option A) is incorrect.

This is a sexually transmitted infection due to the bacterium *Haemophilus ducreyi*. It presents with painful ulcers in the genital area and lymphadenopathy.

C Primary herpes simplex virus (HSV) infection

Primary herpes simplex virus (HSV) infection (Option C) is incorrect.

Primary infection with HSV can lead to a flu-like illness reminiscent of the above description. However, the presence of a painless ulcer in a high-risk patient is indicative of syphilis.

D Gonorrhoea

Gonorrhoea (Option D) is incorrect.

A significant number of patients may be asymptomatic. Those with symptoms may present with a combination of urethral discharge, dysuria, fatigue and lower abdominal pain.

11:49
594-042-7551
Leave

B Secondary syphilis

The answer is Secondary syphilis (Option B).

The patient's symptoms are due to secondary syphilis but could also be accounted for by human immunodeficiency virus (HIV) seroconversion. Secondary syphilis usually commences 4–10 weeks after the primary chancre (which can also occur in the oral cavity). Patients usually present with maculopapular rashes affecting the entire trunk, but any form of rash may occur. Alopecia is well recognised, as are multiple painless aphthous ulcers. Sore throat, myalgia, fever and weight loss are also common.

A Chancroid

Chancroid (Option A) is incorrect.

This is a sexually transmitted infection due to the bacterium *Haemophilus ducreyi*. It presents with painful ulcers in the genital area and lymphadenopathy.

C Primary herpes simplex virus (HSV) infection

Primary herpes simplex virus (HSV) infection (Option C) is incorrect.

Primary infection with HSV can lead to a flu-like illness reminiscent of the above description. However, the presence of a painless ulcer in a high-risk patient is indicative of syphilis.

D Gonorrhoea

Gonorrhoea (Option D) is incorrect.

A significant number of patients may be asymptomatic. Those with symptoms may present with a combination of urethral discharge, dysuria, fatigue and lower abdominal pain.

Audio Video Share Participants More

ulcers in the genital area and lymphadenopathy.

C	Primary herpes simplex virus (HSV) infection

Primary herpes simplex virus (HSV) infection (Option C) is incorrect.

Primary infection with HSV can lead to a flu-like illness reminiscent of the above description. However, the presence of a painless ulcer in a high-risk patient is indicative of syphilis.

D	Gonorrhoea

Gonorrhoea (Option D) is incorrect.

A significant number of patients may be asymptomatic. Those with symptoms may present with a combination of urethral discharge, dysuria, fatigue and lower abdominal pain.

E	Behçet's disease

Behçet's disease (Option E) is incorrect.

This inflammatory condition of unknown aetiology can lead to numerous signs and symptoms such as mouth and genital ulceration, uveitis, abdominal pain, nausea and diarrhoea, as well as cardiovascular and neurological symptoms.

A 35-year-old man presents to his general practitioner (GP) with a rash affecting most of his body. It started with dry skin which became tender and, a few hours later, small spots started to appear. He has been feeling unwell with fever, nausea and chills since the onset of these symptoms.

He has a past medical history of psoriasis and depression. He normally uses topical vitamin D therapy to control his psoriasis. This normally affects his elbows, knees and umbilicus.

A photograph of his rash is shown below.

What is the most appropriate management plan?

A	Arrange for urgent hospital admission
B	Refer for ultraviolet (UV) light therapy
C	Start oral corticosteroids
D	Arrange for outpatient intravenous (IV) antibiotics
E	Start topical treatment with potent corticosteroids and vitamin D

A Arrange for urgent hospital admission

This patient is complaining of rapidly developing systemic symptoms with a new, wide, pustular rash with a background of known psoriasis. Patients with generalised pustular psoriasis may have history of preceding psoriasis. Triggers can include sudden withdrawal of systemic corticosteroid therapy, or treatment with lithium, aspirin, indomethacin, iodide or beta-blockers. Other possible triggers include infection. The condition is characterised by recurrent acute flares of skin changes:

- The skin first becomes erythematous and tender.
- Pustules appear within hours.
- Pustules coalesce into pools within a day.
- Pustules then peel to leave a smooth surface and a new crop may appear.
- Systemic features include fever, headache, nausea and weakness.

Diagnosis is by skin biopsy which can show subcorneal pustules and neutrophilic infiltration.

Treatment should be in hospital as this is a life-threatening condition. Treatment should be topical with emollients and low-potency steroid creams. Systemic therapy may include antibiotics, cautious use of systemic corticosteroids, and treatment with anti-inflammatory agents such as methotrexate or biologicals.

B Refer for ultraviolet (UV) light therapy

UV treatment is appropriate in plaque psoriasis and also in palmoplantar psoriasis. However, it is not appropriate treatment in pustular psoriasis.

C Start oral corticosteroids

UV treatment is appropriate in plaque psoriasis and also in palmoplantar psoriasis. However, it is not appropriate treatment in pustular psoriasis.

C	Start oral corticosteroids

Systemic corticosteroids are should only be used with high levels of caution in pustular psoriasis due to the high risk of rebound after completion of treatment. It can be considered as a treatment, but this should be done with monitoring as an inpatient.

D	Arrange for outpatient intravenous (IV) antibiotics

This could be appropriate for patients with severe cellulitis who are systemically well. This patient does not have cellulitis, and the ongoing systemic symptoms and rapidly evolving nature of his symptoms means that he would not be suitable for this therapy.

E	Start topical treatment with potent corticosteroids and vitamin D

This would be first-line treatment for plaque psoriasis and is not appropriate for pustular psoriasis.

Rate this question:

Next Question

Previous Q... Tag Questi... Feedback End Session

An 18-year-old man presents with a 2-day history of a non-blanching rash down his legs and buttocks, and abdominal pain. He has recently been started on antibiotics for a sore throat.

Given the likely diagnosis, which of the following is NOT seen in this condition?

A	Mouth ulcers
B	Haematuria
C	Arthralgia
D	Gastrointestinal bleeding
E	Deposition of immunoglobulin A (IgA) immune complexes on histology

Submit

11:54

pain, which is a common association. Mouth ulceration is not associated with this condition.

B Haematuria

Renal involvement is common (30–90%), although it is usually mild with microscopic haematuria and/or minimal proteinuria.

C Arthralgia

Arthralgia is also common in HSP, affecting 75% of patients.

D Gastrointestinal bleeding

Gastrointestinal bleeding is present in 50–75% of patients with HSP.

E Deposition of immunoglobulin A (IgA) immune complexes on histology

Perivascular deposits of IgA are characteristic and help to differentiate HSP from other vasculitic disorders.

Rate this question:

Next Question

Previous Q... Tag Questi... Feedback End Session

Rana Alnasser's screen

Explanation

A Mouth ulcers

This man has a purpuric rash over his legs and buttocks, which is most likely to be Henoch-Schönlein purpura (HSP). This is reinforced by his symptom of abdominal pain, which is a common association. Mouth ulceration is not associated with this condition.

B Haematuria

Renal involvement is common (30–90%), although it is usually mild with microscopic haematuria and/or minimal proteinuria.

C Arthralgia

Arthralgia is also common in HSP, affecting 75% of patients.

D Gastrointestinal bleeding

Gastrointestinal bleeding is present in 50–75% of patients with HSP.

E Deposition of immunoglobulin A (IgA) immune complexes on histology

Perivascular deposits of IgA are characteristic and help to differentiate HSP from other vasculitic disorders.

Rate this question:

Rana Alnasser's screen

A 32-year-woman presents to the Dermatology Clinic due to pain on the inside of her cheeks and tenderness of her gums. A visit to her dentist did not reveal any problems with her dental health. Her symptoms have been getting worse over a few weeks.

She has been systemically well without any other medical problems but has been having increased stress at work.

A photograph of the inside of her mouth is shown below.

No other dermatological involvement can be found.

What is the most appropriate management plan?

A	Aciclovir
B	Anti-retroviral treatment
C	Topical retinoids
D	Oral corticosteroids
E	Topical corticosteroids

E Topical corticosteroids

This patient has lichen planus with oral involvement only. The image shows white streaks in a fern-like pattern which is very distinctive of lichen planus. Other oral features of the condition include painful and persistent erosions and ulcers, as well as diffusely red and tender gums. Cutaneous lichen planus is characterised by violaceous polygonal plaques which can show Wickham's striae, white lines crossing them, or hypertrophic plaques. Diagnosis is usually by biopsy. Management is topical steroids as first-line treatment, topical calcineurin inhibitors as second-line, and oral steroids with immunosuppression for systemic illness.

A Aciclovir

Aciclovir can be used for infections such as the herpes simplex virus in the early stages. However, this presents as very painful cold sores rather than the presentation seen above.

B Anti-retroviral treatment

This would be appropriate if the image demonstrated an acquired immune deficiency syndrome (AIDS)-defining illness suggestive of underlying human immunodeficiency virus (HIV). In terms of oral lesions, this could be widespread oral thrush and oral hairy cell leukoplakia, but this appears as white lesions on the side of the tongue, like a film that will not come off despite rubbing it.

C Topical retinoids

Topical retinoids would be considered a second-line treatment for lichen planus.

11:57

MyPastest
https://mypastest.pastest.com

illness.

A Aciclovir

Aciclovir can be used for infections such as the herpes simplex virus in the early stages. However, this presents as very painful cold sores rather than the presentation seen above.

B Anti-retroviral treatment

This would be appropriate if the image demonstrated an acquired immune deficiency syndrome (AIDS)-defining illness suggestive of underlying human immunodeficiency virus (HIV). In terms of oral lesions, this could be widespread oral thrush and oral hairy cell leukoplakia, but this appears as white lesions on the side of the tongue, like a film that will not come off despite rubbing it.

C Topical retinoids

Topical retinoids would be considered a second-line treatment for lichen planus.

D Oral corticosteroids

Oral corticosteroids are reserved for severe or systemic lichen planus and should be used in conjunction with a disease-modifying treatment or therapy to help maintain remission.

Rate this question:

Rana Alnasser's screen

11:57
594-042-7551
Leave

A 35-year-old woman, who has just had her first baby, attended the clinic with striae across her abdomen, which developed in the last trimester.

Which of the following hormones causes striae?

A	Cortisol
B	Human chorionic gonadotrophin
C	Progesterone
D	Thyroxin
E	Parathyroid hormone

40098
Audio
Video
Share
Participants
More

Which of the following hormones causes striae?

Your answer was incorrect

A	Cortisol
B	Human chorionic gonadotrophin
C	Progesterone
D	Thyroxin
E	Parathyroid hormone

Explanation

A Cortisol

Striae are caused by rapid stretching of connective tissue. They are common in adolescence and pregnancy, where they are likely to develop in the 3rd trimester. They may also occur with topical or oral corticosteroid use or in Cushing's syndrome due to reduced skin pliability.

C Progesterone

Progesterone is a crucial hormone that is implicated in multiple biological functions, such as the menstrual cycle and embryogenesis. Even though lack of progesterone is thought to cause acceleration of skin aging, the hormone itself has not been associated with the development of striae.

Rana Alnasser's screen

A Cortisol

Striae are caused by rapid stretching of connective tissue. They are common in adolescence and pregnancy, where they are likely to develop in the 3rd trimester. They may also occur with topical or oral corticosteroid use or in Cushing's syndrome due to reduced skin pliability.

C Progesterone

Progesterone is a crucial hormone that is implicated in multiple biological functions, such as the menstrual cycle and embryogenesis. Even though lack of progesterone is thought to cause acceleration of skin aging, the hormone itself has not been associated with the development of striae.

B Human chorionic gonadotrophin

Human chorionic gonadotrophin (hCG) is produced by the placenta and is not associated with the development of striae. The detection of hCG in test strips is a commonly used over-the-counter diagnostic method of identifying pregnancy.

D Thyroxin

Thyroxine is implicated in multiple aspects of human metabolism but is not thought to influence the development of striae.

E Parathyroid hormone

Parathyroid hormone regulates serum calcium, phosphate and is implicated in the synthesis of vitamin D. It has not been associated however with the development of striae.

11:59
594-042-7551
Leave

A 58-year-old woman presents with a rash around her eyes and over her hands. She also complains of difficulty brushing her hair.

Which of the following results is associated with this condition?

A	Raised angiotensin-converting enzyme (ACE) levels
B	Anti-double-stranded DNA antibodies
C	Giant cell identification on biopsy of the temporal artery
D	Anti-centromere antibodies
E	Anti-Jo antibodies

Submit
Audio
Video
Share
Participants
More

Explanation

E	Anti-Jo antibodies

A heliotrope rash around the eyes and violaceous papules (Gottron's papules) over the hands is characteristic of dermatomyositis. The disorder is associated with the development of anti-Jo antibodies in roughly 30% of patients, and can also commonly cause polymyositis that affects proximal muscles (e.g. causing difficulties in brushing hair, standing up from a chair).

There are two peaks of onset, one in childhood and the other between the ages of 40 and 60 years. Dermatomyositis occurs twice as frequently in women as it does in men. There is an association with malignancy, commonly of the lung, breast, female genital tract, stomach and rectum. Dermatomyositis precedes neoplasm occurrence in 40% of cases, both conditions occur together in 26%, and in 30% the neoplasm occurs first.

A	Raised angiotensin-converting enzyme (ACE) levels

Raised ACE levels are associated with a diagnosis of sarcoidosis. Cutaneous findings include erythema nodosum, and indurated purple-red plaques (theplaques are termed lupus pernio when affecting the nose, ears, and cheeks).

B	Anti-double-stranded DNA antibodies

Anti-double-stranded DNA antibodies are associated with systemic lupus erythematosus (SLE). SLE is also associated with a facial rash, in a pathognomonic butterfly distribution, but not with the development of Gottron's papules.

Rana Alnasser's screen

n on biopsy of the temporal

12:00
594-042-7551
Leave

since she could not see any abnormalities, she did not do anything about it. However, over the last 3 days, some itchy spots have begun appearing in the same area.

On examination, the left eyelid shows erythematous skin with papular lesions and vesicles, which are weeping. The eyeball itself is white and does not appear to be involved. No proptosis is identified and eye movements are found to be equal in both eyes.

The patient is otherwise fit and well and not on any medications.

What is the likely diagnosis?

A	Pre-septal cellulitis
B	Orbital cellulitus
C	Impetigo
D	Eyrsipelas
E	Herpes simplex infection

Submit

Blog About Pastest Contact Us Help
© Pastest 2019
Audio Video Share Participants More

12:00
594-042-7551
Leave

A 19-year-old woman presents to the GP concerned about the appearance of the skin around her left eye. She reports having had some pain around her left eye 3 days ago but since she could not see any abnormalities, she did not do anything about it. However, over the last 3 days, some itchy spots have begun appearing in the same area.

On examination, the left eyelid shows erythematous skin with papular lesions and vesicles, which are weeping. The eyeball itself is white and does not appear to be involved. No proptosis is identified and eye movements are found to be equal in both eyes.

The patient is otherwise fit and well and not on any medications.

What is the likely diagnosis?

A	Pre-septal cellulitis
B	Orbital cellulitus
C	Impetigo
D	Eyrsipelas
E	Herpes simplex infection

Submit

Previous Q...
Skip Questi...
Audio
Video
Share
Participants
More

A 19-year-old woman presents to the GP concerned about the appearance of the skin around her left eye. She reports having had some pain around her left eye 3 days ago but since she could not see any abnormalities, she did not do anything about it. However, over the last 3 days, some itchy spots have begun appearing in the same area.

On examination, the left eyelid shows erythematous skin with papular lesions and vesicles, which are weeping. The eyeball itself is white and does not appear to be involved. No proptosis is identified and eye movements are found to be equal in both eyes.

The patient is otherwise fit and well and not on any medications.

What is the likely diagnosis?

Your answer was correct

A Pre-septal cellulitis

B Orbital cellulitus

C Impetigo

D Eyrsipelas

E Herpes simplex infection

Explanation

E Herpes simplex infection

E Herpes simplex infection

Herpes simplex virus (HSV) infection can cause a variety of clinical symptoms. HSV type 1 is normally associated with orofacial infections. It typically presents as vesicular rash that may be preceded by a prodrome of pain, tingling, burning or itching. Vesicles become pustular or ulcerative with formation of crusts within 72–96 hours and heal over 8–10 days.

It is important to ask if the patient has had a recent cold sore infection of the mouth or has been in contact with anyone who has had a cold sore infection, since direct spread from the mouth to the eye can occur via contact with infected saliva.

It is imperative that the eye is also examined, both externally (the cornea looking for the classic dendritic ulcer on the surface) and internally (to exclude acute retinal necrosis, a rare complication of HSV infection that may result in blindness).

A Pre-septal cellulitis

Pre-septal cellulitis (also known as periorbital cellulitis) is an infection of the eyelids or skin around the eyes. Symptoms include: erythema, oedema, discharge, loss of visual acuity, and pain. Pre-septal cellulitis must be differentiated from orbital cellulitis, which is an emergency and requires urgent medical intervention.

B Orbital cellulitus

Orbital cellulitis is a dangerous infection that affects the fat and muscles around the eye. It usually occurs due to acute spread of infection into the eye socket from either the adjacent sinuses or through the blood. Symptoms include painful eye movement, opthalmoplegia, loss of vision, discharge, proptosis, oedema and erythema of the eyelids. Urgent ophthalmological assessment and treatment with

It is important to ask if the patient has had a recent cold sore infection of the mouth or has been in contact with anyone who has had a cold sore infection, since direct spread from the mouth to the eye can occur via contact with infected saliva.

It is imperative that the eye is also examined, both externally (the cornea looking for the classic dendritic ulcer on the surface) and internally (to exclude acute retinal necrosis, a rare complication of HSV infection that may result in blindness).

A Pre-septal cellulitis

Pre-septal cellulitis (also known as periorbital cellulitis) is an infection of the eyelids or skin around the eyes. Symptoms include: erythema, oedema, discharge, loss of visual acuity, and pain. Pre-septal cellulitis must be differentiated from orbital cellulitis, which is an emergency and requires urgent medical intervention.

B Orbital cellulitus

Orbital cellulitis is a dangerous infection that affects the fat and muscles around the eye. It usually occurs due to acute spread of infection into the eye socket from either the adjacent sinuses or through the blood. Symptoms include painful eye movement, opthalmoplegia, loss of vision, discharge, proptosis, oedema and erythema of the eyelids. Urgent ophthalmological assessment and treatment with antibiotics is paramount. In some patients surgical intervention may also be required in order to drain the presence of abscesses.

C Impetigo

Impetigo is an acute and highly contagious superficial infection of the skin that commonly occurs in children, and consequently outbreaks in nurseries and schools are not rare. There are two forms of the condition, bullous and

12:04
594-042-7551
Leave

herpes simplex periocular

stromal keratitis | dermatitis | herpes zoster | tinea | eye

Index - Home
eyeplastics.com

ATLAS OF OCULAR HERPES SIMPLEX ...
tuyenlab.net

Atlas of Pediatric Emergency Medicine ...
accesspediatrics.mhmedical.com

Common Features of Periocular Tinea ...
jamanetwork.com

Common features of periocular tinea ...
semanticscholar.org

Periorbital and Orbital Cellulitis ...
pedsinreview.aappublications.org

Audio Discover Video Updates Share Participants Search More

12:04

MyPastest
https://mypastest.pastest.com

Impetigo is an acute and highly contagious superficial infection of the skin that commonly occurs in children, and consequently outbreaks in nurseries and schools are not rare. There are two forms of the condition, bullous and non-bullous, with the former being caused almost exclusively by Staphylococcus aureus whereas the latter can be caused by S. aureus, group A streptococcus (Streptococcus pyogenes), or a combination of both. Culture of the skin lesions is required to confirm the diagnosis and determine the causative organism. Treatment consists of topical therapy (topical mupirocin) alone or in combination with systemic therapy.

D	Eyrsipelas

Erysipelas is a superficial bacterial skin infection caused by *S. pyogenes* and characterized by well demarcated erythema. Lymphatic involvement is common and manifests by streaking of the overlying skin and local lymphadenopathy.

Rate this question:

Next Question

Previous Q... Tag Questi... Feedback End Session

Blog About Pastest Contact Us Help

© Pastest 2019

Rana Alnasser's screen

12:04

He is a non-smoker and drinks no alcohol. He takes no medications regularly and has no allergies. Physical examination, apart from the rash, is normal. He is keen to improve the appearance.

What is the best management option?

A	Wash with ketoconazole shampoo
B	Referral to a dermatologist for skin biopsy
C	Moderate-potency topical corticosteroid
D	Reassure the patient and advise no treatment is available
E	Oral prednisolone

6329

Submit

Previous Q... Skip Questi...

© Pastest 2019

Rana Alnasser's screen

A 34-year-old man is admitted to hospital feeling breathless on minimal exertion.

While examining him, you notice the rash in the image – he tells you that occasionally it is itchy, but it has been there for at least 4 years. He has a family history of vitiligo.

He is a non-smoker and drinks no alcohol. He takes no medications regularly and has no allergies. Physical examination, apart from the rash, is normal. He is keen to improve the appearance.

What is the best management option?

A	Wash with ketoconazole shampoo
B	Referral to a dermatologist for skin biopsy
C	Moderate-potency topical corticosteroid
D	Reassure the patient and advise no treatment is available

Rana Alnasser's screen

He is a non-smoker and drinks no alcohol. He takes no medications regularly and has no allergies. Physical examination, apart from the rash, is normal. He is keen to improve the appearance.

What is the best management option?

A	Wash with ketoconazole shampoo
B	Referral to a dermatologist for skin biopsy
C	Moderate-potency topical corticosteroid
D	Reassure the patient and advise no treatment is available
E	Oral prednisolone

Submit

12:05
594-042-7551
Leave
MyPastest
https://mypastest.pastest.com

A 34-year-old man is admitted to hospital feeling breathless on minimal exertion.

While examining him, you notice the rash in the image – he tells you that occasionally it is itchy, but it has been there for at least 4 years. He has a family history of vitiligo.

He is a non-smoker and drinks no alcohol. He takes no medications regularly and has no allergies. Physical examination, apart from the rash, is normal. He is keen to improve the appearance.

What is the best management option?

Your answer was correct

A Wash with ketoconazole shampoo

B Referral to a dermatologist for skin biopsy

Audio
Video
Share
Participants
More

12:06
594-042-7551
Leave

A Wash with ketoconazole shampoo

This diagnosis here is pityriasis versicolor. This is caused by overgrowth of the (usually) commensal yeast, *Malassezia furfur*. It typically presents in young adults in warm weather or after a sunny holiday, with asymptomatic hypo- or sometimes hyperpigmented macules with very fine peripheral scaling. It is usually confined to the trunk. The diagnosis should be confirmed mycologically on a skin scraping. It may respond to topical antifungal treatment, such as washing with ketoconazole shampoo. Other options include antifungal creams, or itraconazole 200 mg once daily for a week. Patients should be advised that the pigmentation may take months to return to normal after successful treatment.

Pityriasis versicolor is sometimes confused with vitiligo. The latter causes depigmentation rather than hypopigmentation, usually affecting much larger areas than the 1 cm lesions of pityriasis versicolor. The hands, face and genitalia are fairly commonly affected in vitiligo, but not in pityriasis versicolor. Scaling does not occur in vitiligo.

B Referral to a dermatologist for skin biopsy

This condition is usually a simple clinical diagnosis which can be confirmed via a skin scraping.

C Moderate-potency topical corticosteroid

Topical steroids are ineffective for this condition and might make it worse.

D Reassure the patient and advise no treatment is available

Whilst reassurance is appropriate, pityriasis versicolor can

Audio Video Share Participants More

successful treatment.

Pityriasis versicolor is sometimes confused with vitiligo. The latter causes depigmentation rather than hypopigmentation, usually affecting much larger areas than the 1 cm lesions of pityriasis versicolor. The hands, face and genitalia are fairly commonly affected in vitiligo, but not in pityriasis versicolor. Scaling does not occur in vitiligo.

B Referral to a dermatologist for skin biopsy

This condition is usually a simple clinical diagnosis which can be confirmed via a skin scraping.

C Moderate-potency topical corticosteroid

Topical steroids are ineffective for this condition and might make it worse.

D Reassure the patient and advise no treatment is available

Whilst reassurance is appropriate, pityriasis versicolor can usually be treated fairly simply, though it may recur.

E Oral prednisolone

This has no role in the treatment of a yeast infection.

Rate this question:

Rana Alnasser's screen

12:07
594-042-7551
Leave
MyPastest
https://mypastest.pastest.com

Pastest+

A 19-year-old student has a palpable purpuric rash affecting his legs and buttocks. He describes a recent flu-like illness and generalised mild arthralgia.

What is the appropriate next step in his management?

A	Lumbar puncture
B	Renal biopsy
C	Urine dipstick
D	Oral corticosteroids
E	Urethral swab

33399

Submit

Previous Q... Skip Questi...

© Pastest 2019

Audio Video Share Participants More

C Urine dipstick

The answer is Urine dipstick (Option C).

Henoch–Schönlein purpura can include a combination of polyarthralgia (but rarely true arthritis), abdominal pain, per rectal blood and renal involvement with nephrotic syndrome. In adults, up to one-quarter will develop rapidly progressive glomerulonephritis, and nephritic syndrome will occur in half of these patients. More commonly, there is just glomerulonephritis with microscopic haematuria and without significant impairment of renal function. Urine dipstick will help confirm or refute the presence of haematuria.

A Lumbar puncture

Lumbar puncture (Option A) is incorrect.

This rash is typical of Henoch–Schönlein purpura and does not require a lumbar puncture for the diagnosis to be made.

B Renal biopsy

Renal biopsy (Option B) is incorrect.

About 20% of children that exhibit nephrotic or nephritic features experience permanent renal impairment. The findings on renal biopsy correlate with the severity of symptoms and can be used to determine whether a patient will develop chronic renal disease.

D Oral corticosteroids

Oral corticosteroids (Option D) is incorrect.

Most patients with Henoch–Schönlein purpura resolve spontaneously, without the need for any therapy other than

made.

B	Renal biopsy

Renal biopsy (Option B) is incorrect.

About 20% of children that exhibit nephrotic or nephritic features experience permanent renal impairment. The findings on renal biopsy correlate with the severity of symptoms and can be used to determine whether a patient will develop chronic renal disease.

D	Oral corticosteroids

Oral corticosteroids (Option D) is incorrect.

Most patients with Henoch–Schönlein purpura resolve spontaneously, without the need for any therapy other than analgesics. Oral steroids are generally avoided.

E	Urethral swab

Urethral swab (Option E) is incorrect.

Urethral swab is useful for Reiter's syndrome, which usually presents with mono-arthritis, a typical rash (keratoderma blenorrhagica) and conjunctivitis.

Rate this question:

Next Question

Previous Q... Tag Questi... Feedback End Session

Blog About Pastest Contact Us Help

12:09
594-042-7551
Leave

A 24-year-old woman was admitted with a flu-like illness, which has worsened over the past 2 days, and she now has a productive cough, shortness of breath and fever. A presumed diagnosis of community-acquired pneumonia was made, and the patient was started on oral co-amoxiclav 625 mg three times daily.

Two days later, she developed a non-pruritic macular rash over both legs and arms (described as pink-red blotches with a paler centre), which was associated with a burning sensation.

What is the most likely cause of the rash?

A	Pityriasis rosea
B	Erythema nodosum
C	Erythema multiforme (EM)
D	Urticaria
E	Dercum's disease

Submit

Previous Q... Skip Questi...

Audio Video Share Participants More

12:10
594-042-7551
Leave

A 24-year-old woman was admitted with a flu-like illness, which has worsened over the past 2 days, and she now has a productive cough, shortness of breath and fever. A presumed diagnosis of community-acquired pneumonia was made, and the patient was started on oral co-amoxiclav 625 mg three times daily.

Two days later, she developed a non-pruritic macular rash over both legs and arms (described as pink-red blotches with a paler centre), which was associated with a burning sensation.

What is the most likely cause of the rash?

Your answer was correct

A Pityriasis rosea

B Erythema nodosum

C Erythema multiforme (EM)

D Urticaria

E Dercum's disease

Explanation

C Erythema multiforme (EM)

The answer is Erythema multiforme (EM) (Option C).

The patient has a symmetrical erythematous, non-pruritic rash affecting the upper and lower limbs, following a

Audio Video Share Participants More

Explanation

C	Erythema multiforme (EM)

The answer is Erythema multiforme (EM) (Option C).

The patient has a symmetrical erythematous, non-pruritic rash affecting the upper and lower limbs, following a community-acquired pneumonia. The diagnosis is most likely EM, and the rash may be drug-related or a consequence of infection with *Mycoplasma* pneumonia. EM is an acute mucocutaneous hypersensitivity reaction of variable severity, characterised by a symmetrically distributed skin eruption, with or without mucous involvement. The more common form (EM minor) consists of skin lesions with involvement of no more than one mucosal surface. EM major, or Stevens-Johnson syndrome, is more severe, involving two or more mucous membranes, with more variable skin involvement. EM can be triggered by a variety of stimuli such as viral and bacterial infections and medications. Approximately 50% of cases are idiopathic, with no identifiable cause.

A	Pityriasis rosea

Pityriasis rosea (Option A) is incorrect.

Pityriasis rosea is an acute exanthem that initially presents with a primary plaque (herald patch), followed, 1–2 weeks later, by a generalised rash, which can last up to 6 weeks. It is associated with reactivation of herpesviruses 6 and 7. Prodromal flu-like symptoms may precede the herald patch. The herald patch measures 1–2 cm in diameter and is usually located on the trunk. The secondary rash is symmetric and again localised to the trunk and the adjacent areas of the neck and limbs. The rash distribution follows the relaxed skin tension lines and is typically described as a 'Christmas tree' pattern.

Rana Alnasser's screen

patch. The herald patch measures 1–2 cm in diameter and is usually located on the trunk. The secondary rash is symmetric and again localised to the trunk and the adjacent areas of the neck and limbs. The rash distribution follows the relaxed skin tension lines and is typically described as a 'Christmas tree' pattern.

B	Erythema nodosum

Erythema nodosum (Option B) is incorrect.

Erythema nodosum presents with tender, red lumps on the front of the shins. It is thought to be a hypersensitivity reaction to a number of causes such as: tonsillitis, sarcoidosis, tuberculosis, pregnancy, the contraceptive pill and other medications. Treatment consists of managing the underlying pathology and providing with anti-inflammatory medication to reduce the discomfort.

D	Urticaria

Urticaria (Option D) is incorrect.

Urticaria may be acute or chronic and is characterised by itchy wheals (hives), angio-oedema or both. Chronic forms of urticaria may be further grouped into spontaneous and inducible forms.

E	Dercum's disease

Dercum's disease (Option E) is incorrect.

This condition (also known as adiposis dolorosa) is of unknown aetiology and characterised by a combination of lipomas, painful subcutaneous plaques and non-traumatic ecchymoses.

A 35-year-old woman was reviewed by her general practitioner (GP) with a recent history of unusual-looking, excoriated marks on her shins. The lesions had appeared suddenly, were clearly demarcated from the surrounding normal skin and had a geometric pattern.

Her family had urged her to seek medical input regarding the lesions; however, the patient herself had not noticed them before and reported them as being asymptomatic.

The patient is unemployed and lives alone. She is always at home, does not seem to socialise and appears to have very few friends.

What would be the most likely diagnosis in this case?

A Atopic dermatitis

B Dermatitis artefacta

C Scabies

D Lichen planus

E Urticaria

Submit

A 35-year-old woman was reviewed by her general practitioner (GP) with a recent history of unusual-looking, excoriated marks on her shins. The lesions had appeared suddenly, were clearly demarcated from the surrounding normal skin and had a geometric pattern.

Her family had urged her to seek medical input regarding the lesions; however, the patient herself had not noticed them before and reported them as being asymptomatic.

The patient is unemployed and lives alone. She is always at home, does not seem to socialise and appears to have very few friends.

What would be the most likely diagnosis in this case?

A Atopic dermatitis

B Dermatitis artefacta

C Scabies

D Lichen planus

E Urticaria

7614

normal skin and had a geometric pattern.

Her family had urged her to seek medical input regarding the lesions; however, the patient herself had not noticed them before and reported them as being asymptomatic.

The patient is unemployed and lives alone. She is always at home, does not seem to socialise and appears to have very few friends.

What would be the most likely diagnosis in this case?

Your answer was correct

A Atopic dermatitis

B Dermatitis artefacta

C Scabies

D Lichen planus

E Urticaria

Explanation

B Dermatitis artefacta

Dermatitis artefacta is a condition where the skin lesions are self-inflicted and tend to be on exposed skin that is readily accessible to the patient's hands. It may be due to an underlying psychological problem, a form of emotional release from distressful situations, or attention-seeking behaviour particularly when the patient is socially isolated. It is more common in women than in men. The lesions tend to have unusual shapes and a linear or geometric pattern. They are well demarcated and of sudden onset. Different methods may be used to injure the skin (nails, caustic soda

B Dermatitis artefacta

Dermatitis artefacta is a condition where the skin lesions are self-inflicted and tend to be on exposed skin that is readily accessible to the patient's hands. It may be due to an underlying psychological problem, a form of emotional release from distressful situations, or attention-seeking behaviour particularly when the patient is socially isolated. It is more common in women than in men. The lesions tend to have unusual shapes and a linear or geometric pattern. They are well demarcated and of sudden onset. Different methods may be used to injure the skin (nails, caustic soda, cigarettes).

A Atopic dermatitis

Atopic dermatitis (also known as eczema) is a chronic, itchy condition that occurs due to complex genetic and environmental factors and is associated with other forms of atopy such as hay fever and asthma. It typically affects flexural skin leading to inflamed, dry and erythematous lesions, often showing signs of excoriation. Atopic dermatitis commonly presents in childhood but can also affect patients of any age.

C Scabies

Scabies is an infection of the skin with the microscopic mite Sarcoptes scabei. Scabies spreads rapidly under crowded conditions where there is frequent skin-to-skin contact between people. Lesions are linear and typically found in the webbing between the fingers and the skin folds on the wrist, elbow or knee. The rash is intensely itchy, especially at night.

D Lichen planus

Lichen planus is an inflammatory cutaneous disorder of

atopy such as hay fever and asthma. It typically affects flexural skin leading to inflamed, dry and erythematous lesions, often showing signs of excoriation. Atopic dermatitis commonly presents in childhood but can also affect patients of any age.

C Scabies

Scabies is an infection of the skin with the microscopic mite Sarcoptes scabei. Scabies spreads rapidly under crowded conditions where there is frequent skin-to-skin contact between people. Lesions are linear and typically found in the webbing between the fingers and the skin folds on the wrist, elbow or knee. The rash is intensely itchy, especially at night.

D Lichen planus

Lichen planus is an inflammatory cutaneous disorder of unknown aetiology. It causes itchy, polygonal, violaceous plaques which are often crossed by white lines (Wickham striae).

E Urticaria

Urticaria is a skin disease that causes itchy wheals (hives) and/or angioedema (mucosal swelling). It can be classified as spontaneous or inducible. Common causes of inducible Urticaria include heat, pressure, sunshine and cold.

Rate this question:

Next Question

Previous Q... Tag Questi... Feedback End Session

A 22-year-old lorry driver attended with a rash on his right lower leg. It is confined to the right shin and is intensely itchy.

He had no skin conditions prior to this rash, which started after a period of financial stress caused by losing money through gambling.

What is the likely cause?

A	Lichen striatus
B	Lichen simplex et chronicus
C	Lichen planus
D	Lichen sclerosus et atrophicans
E	Lichen aureus

Explanation

B Lichen simplex et chronicus

Lichen simplex is a form of neurodermatitis, caused by a vicious 'itch-scratch' cycle where scratching causes feedback from the brain to trigger the feeling of itchiness. It is triggered and exacerbated by stress. Interfering with the itch-scratch cycle using agents such as anti-histamines can lead to resolution of the condition.

C Lichen planus

Lichen planus appears as small purple papules on the skin and may also be seen as white lacy patches in the mouth.

A Lichen striatus

This is associated with scaly linear bands.

D Lichen sclerosus et atrophicans

This gives a white, shiny appearance to the skin rather than the papules seen here.

E Lichen aureus

Lichen aureus is a pigmented dermatosis which is associated with a golden discoloration to the area of affected skin.

Rate this question:

Next Question

A 40-year-old woman attends for her first annual review in the Gastroenterology Clinic; her diarrhoea has been an increasing problem over the past few months. She complains bitterly of an intensely itchy rash.

On examination, there are groups of blisters and excoriations on her knees, elbows and back. She has been applying emollients with little effect.

Investigations:

Hb	9.8 g/dl (MCV 103 fl)
WCC	7.2×10^9/l
PLT	203×10^9/l
Na^+	138 mmol/l
K^+	4.5 mmol/l
Creatinine	90 µmol/l
Albumin	27 g/l
ALT	32 U/l
Bilirubin	9.0 µmol/l

Given the likely underlying cause of her rash, which of the following is the definitive intervention?

A Topical corticosteroids

B Oral dapsone

C Regular chlorpheniramine

D Dietician referral

E Oral acyclovir

Explanation

D	Dietician referral

This rash describes dermatitis herpetiformis (immunobullous disease with itchy blisters), which occurs with coeliac disease. The anaemia with elevated MCV and low albumin would also indicate that her coeliac is poorly controlled. Review of her diet and reinforcement of the need to remain gluten free is crucial with respect to her long-term health.

A	Topical corticosteroids

Although topical corticosteroids may bring some symptom relief, they are not an appropriate long-term option for control of the rash.

B	Oral dapsone

Although oral dapsone is the most appropriate intervention for symptom relief with respect to her itching, it won't treat her underlying coeliac disease.

C	Regular chlorpheniramine

Symptomatic intervention with anti-histamines is not effective in dermatitis herpetiformis, and won't improve her GI symptoms.

E	Oral acyclovir

Although the condition is termed dermatitis herpetiformis because of the intensely itchy, blistering rash, it has no connection with herpes infection.

A 27-year-old man presented to his GP complaining of a rash in his groin. He had recently returned from a long trip overseas and had been treated for this rash by a cream given to him by a pharmacist in Bangkok. The patient thought it was an allergic reaction and so had asked for an appropriate cream but application of this cream had only made the rash worse. The patient reports that the rash has been quite itchy from the start.

On examination, the rash has a scaly and raised sharp red border and spreads asymmetrically down the inner aspect of the thighs but does not involve the scrotum. The rash is slightly raised and is clearer centrally.

What would be the most appropriate clinical investigation, if any, to perform in order to aid the diagnosis?

A	Skin prick testing
B	RAST test
C	Bacterial skin swab
D	Direct microscopic examination of KOH-treated skin scrapings
E	Autoimmune profiling

Submit

12:19
594-042-7551
Leave

A 27-year-old man presented to his GP complaining of a rash in his groin. He had recently returned from a long trip overseas and had been treated for this rash by a cream given to him by a pharmacist in Bangkok. The patient thought it was an allergic reaction and so had asked for an appropriate cream but application of this cream had only made the rash worse. The patient reports that the rash has been quite itchy from the start.

On examination, the rash has a scaly and raised sharp red border and spreads asymmetrically down the inner aspect of the thighs but does not involve the scrotum. The rash is slightly raised and is clearer centrally.

What would be the most appropriate clinical investigation, if any, to perform in order to aid the diagnosis?

Your answer was correct

A Skin prick testing

B RAST test

C Bacterial skin swab

D Direct microscopic examination of KOH-treated skin scrapings

E Autoimmune profiling

Explanation

D Direct microscopic examination of KOH-treated skin scrapings

Tinea cruris, also known as ringworm of the groin, is a

Audio Video Share Participants More

D Direct microscopic examination of KOH-treated skin scrapings

Tinea cruris, also known as ringworm of the groin, is a dermatophyte infection that is more commonly seen in men. It is transmitted via both direct contact between infected individuals and indirect contact with contaminated objects such as towels, bed linens and clothing. The affected area is sharply demarcated and has a scaly raised red border that spreads down the inner thighs from the groin in a symmetrical fashion, but asymmetrical involvement may also occur. The scrotum is usually spared in distinct contrast with infections of this area by Candida. In acute infections, the rash may be moist and exudative and patients may complain of intense pruritus. Microscopic examination of a potassium hydroxide (KOH) treated skin scraping is diagnostic and reveals the typical long branch-like structure of the fungus. This patient was given a steroid cream from the pharmacist that exacerbated the fungal infection.

A Skin prick testing

Skin prick testing is performed by piercing the skin with a needle or pin containing a small amount of allergen. It is conventionally used to investigate immediate type hypersensitivity to allergens in patients with rhinoconjunctivitis, contact urticaria, asthma, atopic eczema, and suspected food allergy. It has the advantage of being relatively inexpensive, providing immediate results compared with measurement of serum allergen specific IgE by RAST. In this case, symptoms are typical of dermatophyte infection and therefore initial investigations should reflect that.

B RAST test

A radioallergosorbent test (RAST) is a blood test used to

12:21
594-042-7551
Leave

A 26-year-old man has been complaining of severe itching over his elbows (see figure), lower back and his scalp. He has noticed some weeping lesions on his scalp. When questioned, he also admits to feeling more tired recently.

What is the diagnosis?

A	Bullous pemphigoid
B	Scabies
C	Atopic eczema
D	Dermatitis herpetiformis
E	Psoriasis

6319

Submit

Audio
Video
Share
Participants
More

12:22
594-042-7551
Leave

A 26-year-old man has been complaining of severe itching over his elbows (see figure), lower back and his scalp. He has noticed some weeping lesions on his scalp. When questioned, he also admits to feeling more tired recently.

What is the diagnosis?

Your answer was incorrect

A Bullous pemphigoid

B Scabies

C Atopic eczema

D Dermatitis herpetiformis

E Psoriasis

Explanation

Audio Video Share Participants More

12:22
594-042-7551
Leave

Explanation

D Dermatitis herpetiformis

This can present at any age, typically with severe itching. Lesions begin as vesicles. These are quickly excoriated, so the usual finding is of excoriated papules. These can appear anywhere, though the classical distribution is over extensor surfaces such as the elbows and buttocks. The condition is closely linked with coeliac disease. The diagnosis should be confirmed by histology and immunofluorescence (showing IgA deposition) on skin biopsies. Patients should then be investigated for coeliac disease. Treatment is with a strict gluten-free diet. Resistant cases usually respond to dapsone.

B Scabies

This is characteristically intensely pruritic, but does not localise to the sites mentioned in the scenario and almost always spares the scalp.

A Bullous pemphigoid

This is an immunobullous disorder which mostly affects the elderly. It presents with tense bullae and associated erosions.

C Atopic eczema

This is not incompatible with the history and image shown, but one would expect a history of atopy and it classically affects flexural rather than extensor surfaces.

E Psoriasis

Although the distribution described would fit very well with

Audio Video Share Participants More

12:23

A picture of a patient's finger nails is shown below:

Which of the following conditions are they most likely to suffer from?

A	Psoriasis
B	Rheumatoid arthritis
C	Iron deficiency anaemia
D	Idiopathic pulmonary fibrosis
E	Subacute bacterial endocarditis

Rana Alnasser's screen

Explanation

A Psoriasis

The photograph shows nail pitting, which occurs in psoriasis, eczema and alopecia areata. It may pre-date the development of the typical psoriatic rash.

B Rheumatoid arthritis

Rheumatoid arthritis may be associated with nail ridging o longitudinal splitting, not with the pitting seen here.

C Iron deficiency anaemia

Iron deficiency anaemia is associated with koilonychias or spoon shaped nails.

D Idiopathic pulmonary fibrosis

Idiopathic pulmonary fibrosis is associated with nail clubbing rather than nail pitting.

E Subacute bacterial endocarditis

This is associated with clubbing and / or splinter haemorrhages.

Rate this question:

Next Question

Rana Alnasser's screen

12:24

A 54-year-old man comes to the Dermatology Clinic for review; he has suffered from an increasingly troublesome rash over the past few months. He has a symmetrical, erythematous scaly rash affecting the fingers, hands, feet, his nose and the helices of the ears. There is also nail dystrophy with horizontal and vertical ridging.

On further questioning, he admits to problems with indigestion and food sticking, that he puts down to drinking too much whisky and smoking 10 cigarettes per day.

Which of the following is he most likely to have?

A	Gastric carcinoma
B	Nasopharyngeal carcinoma
C	Small cell lung cancer
D	Squamous cell lung cancer
E	Squamous cell oesophageal carcinoma

38309

Submit

Previous Q... Skip Questi...

Audio Video Share Participants More

12:27

A 54-year-old man comes to the Dermatology Clinic for review; he has suffered from an increasingly troublesome rash over the past few months. He has a symmetrical, erythematous scaly rash affecting the fingers, hands, feet, his nose and the helices of the ears. There is also nail dystrophy with horizontal and vertical ridging.

On further questioning, he admits to problems with indigestion and food sticking, that he puts down to drinking too much whisky and smoking 10 cigarettes per day.

Which of the following is he most likely to have?

Your answer was correct

A	Gastric carcinoma
B	Nasopharyngeal carcinoma
C	Small cell lung cancer
D	Squamous cell lung cancer
E	Squamous cell oesophageal carcinoma

Explanation

E	Squamous cell oesophageal carcinoma

A widespread psoriatic-type rash involving the ears is suggestive of acrokeratosis paraneoplastica. Most acrokeratosis paraneoplastica cases are associated with squamous cell carcinoma of the upper one third of the

Audio Video Share Participants More

E Squamous cell oesophageal carcinoma

A widespread psoriatic-type rash involving the ears is suggestive of acrokeratosis paraneoplastica. Most acrokeratosis paraneoplastica cases are associated with squamous cell carcinoma of the upper one third of the respiratory or GI tract, i.e. the oropharynx, larynx, lungs or oesophagus. The symptoms of indigestion and food sticking fit best with a diagnosis of oesophageal carcinoma.

A Gastric carcinoma

Acrokeratosis paraneoplastica is not usually associated with gastric carcinoma. Gastric carcinoma is associated with acanthosis nigricans.

B Nasopharyngeal carcinoma

Nasopharyngeal carcinoma is primarily associated with symptoms of upper airway/nasal obstruction rather than symptoms of food sticking.

C Small cell lung cancer

SIADH is the main paraneoplastic phenomenon associated with small cell lung cancer.

D Squamous cell lung cancer

Squamous cell lung cancer is associated with acrokeratosis paraneoplastica, but the food sticking fits better with a primary oesophageal tumour.

Rate this question:

12:28

acrokeratosis paraneoplastica

ALL IMAGES SHOPPING NEWS MAPS VIDEOS BOOKS

Latest GIF HD Product

bazex syndrome | syndrome acrokeratosis | symptoms | neopla

Acrokeratosis Paraneoplastica | NEJM
nejm.org

Acrokeratosis Paraneoplastica ...
emedicine.medscape.com

Bazex syndrome ...
escholarship.org

Acrokeratosis Paraneoplastica ...
emedicine.medscape.com

Acrokeratosis paraneoplastica (Bazex ...

Acrokeratosis Paraneoplastica ...
jamanetwork.com

Discover Updates Search

12:29
tylosis
594-042-7551
Leave

Hereditary tylosis syndrome and ...
scielo.br

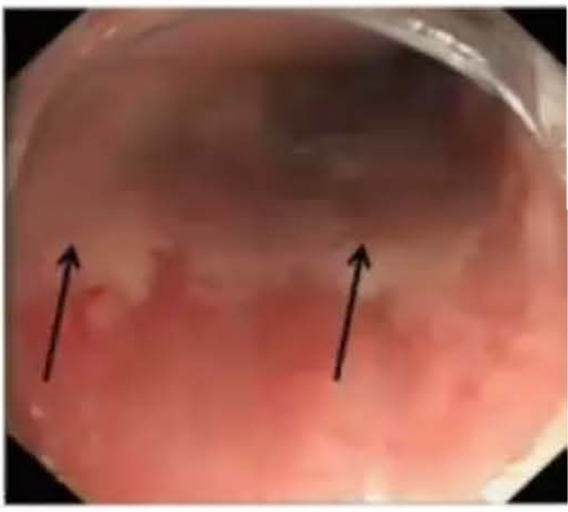

Tylosis with oesophageal cancer ...
ojrd.biomedcentral.com

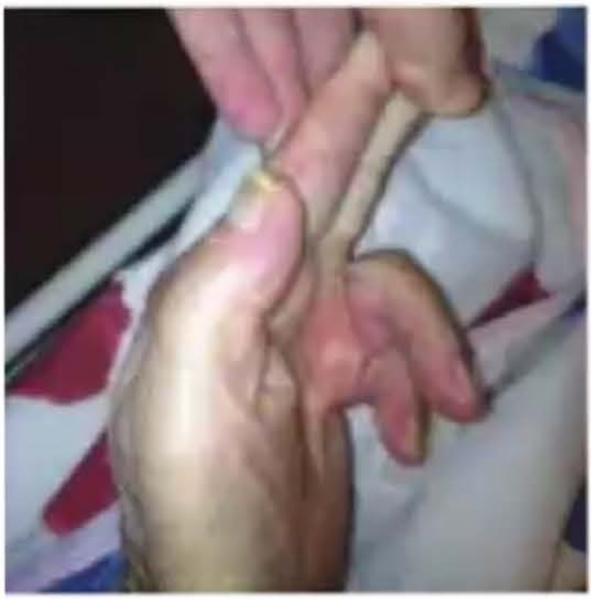

tylosis palmaris et plantaris ...
researchgate.net

A thorny problem...
ueg.eu

Tylosis of lower lid with slight ...
eyerounds.org

Audio
Discover
Video
Updates
Share
Participants
Search
More

12:30

A 50-year-old man presented with bilateral itchy legs, which he has found increasingly difficult to manage over the past 2-3 months. He has a background of kidney disease, secondary to type 2 diabetes mellitus, and is undergoing haemodialysis.

Which of the following is most likely?

A	Xerosis
B	Lipodermatosclerosis
C	Lichen simplex chronicus
D	Pre-tibial myxoedema
E	Scurvy

Submit

Audio Video Share Participants More

A 50-year-old man presented with bilateral itchy legs, which he has found increasingly difficult to manage over the past 2-3 months. He has a background of kidney disease, secondary to type 2 diabetes mellitus, and is undergoing haemodialysis.

Which of the following is most likely?

Your answer was correct

A	Xerosis
B	Lipodermatosclerosis
C	Lichen simplex chronicus
D	Pre-tibial myxoedema
E	Scurvy

Explanation

A Xerosis

Rana Alnasser's screen

A Xerosis

'Xerosis' simply means dry skin and is a common complication of uraemia secondary to chronic kidney disease and dialysis. Uraemic patients commonly suffer from pruritus.

B Lipodermatosclerosis

Lipodermatosclerosis is often associated with pain and causes tapering of the skin above the ankles, forming a constricting band resembling an inverted champagne bottle. There may be redness, induration and pigmentation

C Lichen simplex chronicus

Lichen simplex chronicus (neurodermatitis) is caused by idiopathic scratching, and commonly occurs in anxious or depressed patients. It looks like distinct patches of thick, brown leathery skin.

D Pre-tibial myxoedema

Pre-tibial myxoedema, or Graves' dermopathy, is an infiltrative dermopathy resulting in a peau d'orange appearance and non-pitting oedema.

E Scurvy

Scurvy results in purpura or ecchymoses (bruises) and corkscrew hairs rather than the picture of dry scaling skin seen here.

Rate this question:

An 18-year-old woman attends her general practitioner (GP), complaining of an itchy rash over her back and abdomen that has been present for about 4 days. She recalls that about 2 weeks previously, she had noticed an oval pink area, about 2 cm across, on the right upper part of her abdomen, surrounded by a dark red border. She had thought it was an area of dryness since it was quite itchy. The rash appeared 10 days after this area of 'dryness' in crops over her trunk. She is normally fit and well but does complain of having a few 'flu-like' symptoms recently. She is on no medications.

On examination, the patient has a rash localised mainly to the trunk and adjacent areas of the neck and limbs. The rash itself follows the skin tension lines and is composed of small oval patches with a salmon pink colour, with each area being surrounded by a collarette of fine scale.

What is the most likely diagnosis?

A	Pityriasis rosea
B	Pityriasis alba
C	Pityriasis versicolor
D	Erythema multiforme
E	Psoriasis vulgaris

7615

Submit

An 18-year-old woman attends her general practitioner (GP), complaining of an itchy rash over her back and abdomen that has been present for about 4 days. She recalls that about 2 weeks previously, she had noticed an oval pink area, about 2 cm across, on the right upper part of her abdomen, surrounded by a dark red border. She had thought it was an area of dryness since it was quite itchy. The rash appeared 10 days after this area of 'dryness' in crops over her trunk. She is normally fit and well but does complain of having a few 'flu-like' symptoms recently. She is on no medications.

On examination, the patient has a rash localised mainly to the trunk and adjacent areas of the neck and limbs. The rash itself follows the skin tension lines and is composed of small oval patches with a salmon pink colour, with each area being surrounded by a collarette of fine scale.

What is the most likely diagnosis?

Your answer was incorrect

A Pityriasis rosea

B Pityriasis alba

C Pityriasis versicolor

D Erythema multiforme

E Psoriasis vulgaris

Explanation

A Pityriasis rosea

Pityriasis rosea is an acute exanthem that initially presents

Rana Alnasser's screen

A Pityriasis rosea

Pityriasis rosea is an acute exanthem that initially presents with a primary plaque (herald patch), followed, 1–2 weeks later, by a generalised rash, which can last up to 6 weeks. I is associated with reactivation of herpesviruses 6 and 7. Prodromal flu-like symptoms may precede the herald patch. The herald patch measures 1–2 cm in diameter and i usually located on the trunk. The secondary rash is symmetric and again localised to the trunk and the adjacent areas of the neck and limbs. The rash distribution follows the relaxed skin tension lines and is typically described as a 'Christmas tree' pattern.

E Psoriasis vulgaris

Despite the mention of scaling (which is also seen in psoriasis), the description presented above is very typical of pityriasis rosea.

B Pityriasis alba

Pityriasis alba is a hypopigmented dermatitis that primarily occurs in school-aged children. The exact cause is unknown. However, it is believed that the condition may be associated with eczema.

C Pityriasis versicolor

Pityriasis versicolor is a superficial cutaneous fungal infection characterised by hypo- or hyperpigmented macules on the chest and the back. It is caused by *Malassezia furfur*. Mild pruritus is commonly present in the affected areas.

D Erythema multiforme

12:38

pityriasis rosea

ALL IMAGES VIDEOS NEWS SHOPPING MAPS BOOKS

Latest GIF HD Product

herald patch rash christmas tree

Pityriasis rosea - NHS
nhs.uk

Pityriasis rosea - Symptoms and causes ...
mayoclinic.org

Psoriasis vs. pityriasis rosea ...
medicalnewstoday.com

How common is pityriasis rosea ...
chemistanddruggist.co.uk

Pityriasis rosea | American Academy of ...
aad.org

Discover Updates Search

o Get Rid of Pityriasis Rosea - NaturallyDaily

d of Pityriasis Rosea

yright. Learn more

asis rosea. It'...

10 Tips for Identifying and Treating Skin Ras...
health.howstuffworks.com

Clinical features of pityriasis r
researchgate.net

Updates Search Recent

12:39

594-042-7551

Leave

84% 10:39

Make Life Natural

9 Natural Remedies for Christmas Tree Rash (Pityriasis Rosea)

Images may be subject to copyright. Learn more

RELATED IMAGES

Pityriasis Rosea – Toronto Notes

torontonotes.ca

Christmas Tree Rash Pityriasis Rosea Christ...

lincshomeimprovementsltd.com

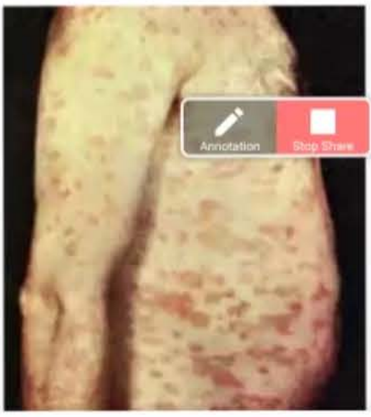

Discover Updates Search Recent More

Audio Video Share Participants More

12:42
594-042-7551 Leave

E 3 Years

Manufacturer's guidelines state that the time required to avoid pregnancy with acitretin is 3 years. The prescribing information states that pregnancy must be reliably prevented 4 weeks before, during and for 3 years after the completion of therapy. Advice on contraception is also given to males starting therapy who are sexually active. Isotretinoin and alitretinoin must be discontinued at least 1 month before pregnancy.

D 6 Months

Six months is the recommended period of pregnancy avoidance after methotrexate therapy.

A 1 Week

For any medication with potential effects on pregnancy, contraceptive precautions must be continued for at least one cycle. As such, 1 week is considered too short.

B 2 Weeks

Two weeks is less than the duration of a single menstrual cycle and is therefore inappropriate advice with respect to avoidance of conception for any medication which may impact on successful pregnancy.

C 1 Month

One month is the length of a single menstrual cycle; like 1 week and 2 weeks, 1 month is therefore considered too short a period of avoidance of conception.

Rate this question:
Audio Video Share Participants More

12:42
594-042-7551 Leave

A 60-year-old man complains of a 2-day history of a painful right knee. He has previously complained of several episodes of excruciating pain in his left big toe.

He has a past history of recent peptic ulceration and hypertension, for which he is taking omeprazole 40 mg and bendroflumethiazide 2.5 mg once daily (od), respectively.

Which of the following steps is the most appropriate first step in management?

A	Naproxen
B	Serum urate levels
C	Allopurinol
D	Regular aspirin
E	Stop bendrofluazide

Submit

Previous Q... Skip Questi...

© Pastest 2019

Audio Video Share Participants More

12:44

A 60-year-old man complains of a 2-day history of a painful right knee. He has previously complained of several episodes of excruciating pain in his left big toe.

He has a past history of recent peptic ulceration and hypertension, for which he is taking omeprazole 40 mg and bendroflumethiazide 2.5 mg once daily (od), respectively.

Which of the following steps is the most appropriate first step in management?

Your answer was incorrect

A Naproxen

B Serum urate levels

C Allopurinol

D Regular aspirin

E Stop bendrofluazide

Explanation

E Stop bendrofluazide

The answer is Stop bendroflumethiazide (Option E).

Like aspirin and alcohol, diuretics may precipitate acute attacks.

A Naproxen

Naproxen (Option A) is incorrect

Rana Alnasser's screen

12:44
594-042-7551 Leave

E Stop bendrofluazide

The answer is Stop bendroflumethiazide (Option E).

Like aspirin and alcohol, diuretics may precipitate acute attacks.

A Naproxen

Naproxen (Option A) is incorrect.

This scenario shows multiple gouty tophi. Acute gout should be treated with non-steroidal anti-inflammatory drugs (NSAIDs) or colchicine. Colchicine is associated with diarrhoea but, given the history of peptic ulceration, would be considerably safer than NSAIDs. Synovial fluid microscopy for negatively birefringent crystals may be helpful in cases of diagnostic uncertainty.

B Serum urate levels

Serum urate levels (Option B) is incorrect.

Serum urate levels are not useful during an acute attack or for diagnosis, but can be used to titrate long-term therapy with allopurinol.

C Allopurinol

Allopurinol (Option C) is incorrect.

Allopurinol is used in the long-term management of gout but should not be commenced during an acute attack, as it may worsen the situation.

D Regular aspirin

Regular aspirin (Option D) is incorrect.

Aspirin and excessive alcohol may precipitate acute attacks

Audio Video Share Participants More

A 56-year-old woman presents with a spot on her right leg which, over the last 9 months, has become erythematous and has broken down to form a painful, rapidly spreading ulcer. She currently takes diclofenac and lansoprazole for arthritis.

She had a similar episode 2 years ago and was given a reducing course of oral prednisolone, which completely cleared the lesion. She was seen by her general practitioner (GP) who prescribed oral antibiotics, and after a week there has been no improvement.

On examination, the temperature is 37.1 °C. There is a large necrotic ulcer on the right shin, with an undermined edge. There are no other skin changes seen. There is no neurological deficit in the lower limbs. Pedal pulses are present and bounding in nature.

Which is the most likely diagnosis?

A	Arterial ulcer
B	Vasculitic ulcer
C	Venous ulcer
D	Pyogenic granuloma
E	Pyoderma gangrenosum

6285

Submit

and has broken down to form a painful, rapidly spreading ulcer. She currently takes diclofenac and lansoprazole for arthritis.

She had a similar episode 2 years ago and was given a reducing course of oral prednisolone, which completely cleared the lesion. She was seen by her general practitioner (GP) who prescribed oral antibiotics, and after a week there has been no improvement.

On examination, the temperature is 37.1 °C. There is a large necrotic ulcer on the right shin, with an undermined edge. There are no other skin changes seen. There is no neurological deficit in the lower limbs. Pedal pulses are present and bounding in nature.

Which is the most likely diagnosis?

Your answer was correct

A	Arterial ulcer
B	Vasculitic ulcer
C	Venous ulcer
D	Pyogenic granuloma
E	Pyoderma gangrenosum

Explanation

E	Pyoderma gangrenosum

Pyoderma gangrenosum occurs when an inflamed nodule or pustule breaks down centrally to form an expanding ulcer with a characteristic undermined bluish edge. The [illegible] origin, but its pathogenesis

Rana Alnasser's screen

E Pyoderma gangrenosum

Explanation

E Pyoderma gangrenosum

Pyoderma gangrenosum occurs when an inflamed nodule or pustule breaks down centrally to form an expanding ulcer with a characteristic undermined bluish edge. The condition is not bacterial in origin, but its pathogenesis (probably immunological) is not fully understood. It can occur in the absence of an underlying disease but tends to be associated with:

- ulcerative colitis
- conditions causing polyarthritis, eg rheumatoid arthritis
- Crohn's disease
- monoclonal gammopathies
- leukaemia.

Lesions can be single or multiple. The condition tends to respond to systemic steroids, but not to antibiotics, and heals, leaving scars.

A Arterial ulcer

Arterial ulcers are punched out and may be painful. They occur in areas of poor arterial circulation and are therefore associated with cold, atrophic limbs and a lack of peripheral pulses.

B Vasculitic ulcer

Vasculitic ulcers are usually punched out and develop in areas of purpura.

Lesions can be single or multiple. The condition tends to respond to systemic steroids, but not to antibiotics, and heals, leaving scars.

A Arterial ulcer

Arterial ulcers are punched out and may be painful. They occur in areas of poor arterial circulation and are therefore associated with cold, atrophic limbs and a lack of peripheral pulses.

B Vasculitic ulcer

Vasculitic ulcers are usually punched out and develop in areas of purpura.

C Venous ulcer

Venous ulcers are usually chronic and have sloped edges. They occur in areas of venous hypertension, ie lipodermatosclerosis, venous eczema, haemosiderin deposition and atrophie blanche.

D Pyogenic granuloma

Despite the similar sounding name, this lesion is of different pathology, compared to pyoderma gangrenosum. Pyogenic granuloma is a benign growth of blood vessels. It presents as a growing fleshy lump, which may bleed easily. It is often the product of physical trauma, infection or hormonal changes (such as pregnancy).

6285

Rate this question:

12:52

pyoderma granulosum

Latest GIF HD Product

pustular scar cribriform early healing superficial gra

Pyoderma gangrenosum - Symptoms and ...
mayoclinic.org

Pyoderma Gangrenosum. | Dermatology ...
jamanetwork.com

Pyoderma Gangrenosum - Skin Disorders ...
merckmanuals.com

Ulcerative Pyoderma Gangrenosum ...
jamanetwork.com

Discover Updates Search

12:52

pyogenic granuloma

Search instead for pyoderma granuloma

Pyogenic granuloma | DermNet NZ
dermnetnz.org

Pyogenic granuloma | DermNet NZ
dermnetnz.org

Pyogenic granuloma | DermNet NZ
dermnetnz.org

Pyogenic granuloma | Primary Care ...
pcds.org.uk

Pyogenic Granuloma
childrens.com

Pyogenic Granuloma: Causes, Diagnosis ...
healthline.com

Discover Updates Search
Rana Alnasser's screen

12:53
594-042-7551
Leave
MyPastest
https://mypastest.pastest.com

Pastest+

This 28-year-old gentleman presented with hyperpigmented patches in his mouth (shown). He has been feeling increasingly unwell with lethargy, nausea and vomiting over the past few days.

What other findings would you expect?

A Hypotension

B Hypokalaemia

C Hypernatraemia

D Hyperglycaemia

E Metabolic alkalosis

Submit

Audio Video Share Participants More

12:54
594-042-7551
Leave

This 28-year-old gentleman presented with hyperpigmented patches in his mouth (shown). He has been feeling increasingly unwell with lethargy, nausea and vomiting over the past few days.

What other findings would you expect?

Your answer was correct

A	Hypotension
B	Hypokalaemia
C	Hypernatraemia
D	Hyperglycaemia
E	Metabolic alkalosis

Explanation

A Hypotension

Audio Video Share Participants More

Explanation

A Hypotension

This patient has buccal pigmentation which raises the possibility of adrenal insufficiency, supported by the histor of nausea and lethargy over the past few days. It's likely that he will be suffering from postural hypotension, driving the correct answer here.

B Hypokalaemia

Adrenal insufficiency is associated with hyperkalaemia, not hypokalaemia, and hyporeninaemic hyperaldosteronism, a cause of hypokalaemia isn't associated with buccal pigmentation.

C Hypernatraemia

Hyponatraemia is seen in adrenal insufficiency, hypernatraemia is seen in other conditions such as diabetes insipidus where free water is lost.

D Hyperglycaemia

Diabetes mellitus may co-exist with adrenal insufficiency, although reduced production of counter-regulatory hormones makes hypo rather than hyperglycaemia more likely.

E Metabolic alkalosis

Metabolic acidosis is seen in association with adrenal insufficiency.

39079

Rana Alnasser's screen

Rate this question:

A 33-year-old man presents to the General Medical Clinic. He complains of intermittent symptoms of bloating and diarrhoea. He has found that his symptoms are particularly worse after drinking alcohol. He feels that his abdomen sometimes feels uncomfortable. He does not think he has passed any blood in his stool. He denies any family history of bowel cancer.

He is fully examined. His abdomen is soft and non-tender, but his nails appear abnormal.

A photograph of one of his nails is shown below.

His general practitioner (GP) has already requested routine blood tests, and you can see a full blood count, urea and liver function tests, but electrolytes and coeliac screen are pending.

What further investigations would be appropriate at this point?

A	Nailfold dermatoscopy
B	X-rays of hands
C	Haematinics
D	Computed tomography (CT) scan of the chest,

but his nails appear abnormal.

A photograph of one of his nails is shown below.

His general practitioner (GP) has already requested routine blood tests, and you can see a full blood count, urea and liver function tests, but electrolytes and coeliac screen are pending.

What further investigations would be appropriate at this point?

A	Nailfold dermatoscopy
B	X-rays of hands
C	Haematinics
D	Computed tomography (CT) scan of the chest, abdomen and pelvis
E	Human immunodeficiency virus (HIV) serology

Submit

Explanation

C	Haematinics

This patient has koilonychia. This is a nail deformity most commonly seen due to iron deficiency anaemia. Other potential causes include regular contact with petroleum-based substances, haemochromatosis and trauma. Koilonychia can also be idiopathic. In the first instance, investigation should confirm iron deficiency anaemia and attempt to determine an underlying cause. In a patient wit a history of bowel problems, coeliac disease should be excluded. If the history was suggestive of it, then inflammatory bowel disease should also be excluded.

A	Nailfold dermatoscopy

Nailfold dermatoscopy is an investigation which can be useful in distinguishing between primary and secondary Raynaud's disease. Secondary Raynaud's is suggestive of systemic sclerosis. This patient does not have features of Raynaud's: colour changing between blue, white and red i response to cold.

B	X-rays of hands

This could have been considered an appropriate investigation if the patient had psoriatic nail changes as these can affect hand joints and would be demonstrated on X-ray. Psoriatic arthritis X-ray features include:

- enthesitis and marginal bone erosions; may develop 'pencil-in-cup' appearance
- joint subluxation
- periostitis: may appear as a thickened cortex or new layer of bone.

Rana Alnasser's screen

'pencil-in-cup' appearance

- joint subluxation
- periostitis: may appear as a thickened cortex or new layer of bone.

Psoriatic nail changes include onycholysis, separation of the nail plate from the nail bed, leukonychia, pitting and ridging. These signs are not seen in this patient, therefore excluding an X-ray as a choice for investigation.

D	Computed tomography (CT) scan of the chest, abdomen and pelvis

A CT scan would be appropriate if this patient had a diagnosis of malignancy and a staging scan would be necessary to assess for metastatic disease and lymphadenopathy. While the nail changes may suggest underlying iron deficiency anaemia, which can in some patients be caused by gastrointestinal malignancy, this investigation would not be appropriate without further evidence of malignancy due to the high radiation exposure and potential for contrast-induced nephropathy.

E	Human immunodeficiency virus (HIV) serology

Neither HIV infection nor an immunodeficiency disease is likely to be a cause in this patient. There is no evidence of behaviour which would lead to HIV exposure and there is no evidence of any opportunistic infection.

12:57

A 25-year-old woman attends your clinic for review. She has attended the Emergency Department on three occasions, having suffered episodes of angioedema, on tw occasions after sexual intercourse and on one occasion after having a filling at the dentist. She denies any fever or rash, although there was some associated shortness of breath.

Examination in the clinic is entirely normal.

Which of the following is the most likely cause?

A	Type 1 hypersensitivity to latex
B	Type 4 hypersensitivity to latex
C	C1 esterase inhibitor deficiency
D	Chronic idiopathic
E	Contact allergic dermatitis

58613

Submit

Previous Q... Skip Questi...

Audio Video Share Participants More

A 25-year-old woman attends your clinic for review. She has attended the Emergency Department on three occasions, having suffered episodes of angioedema, on two occasions after sexual intercourse and on one occasion after having a filling at the dentist. She denies any fever or rash, although there was some associated shortness of breath.

Examination in the clinic is entirely normal.

Which of the following is the most likely cause?

Your answer was correct

A	Type 1 hypersensitivity to latex
B	Type 4 hypersensitivity to latex
C	C1 esterase inhibitor deficiency
D	Chronic idiopathic
E	Contact allergic dermatitis

Explanation

C	C1 esterase inhibitor deficiency

C1 esterase inhibitor deficiency is an inherited or acquired cause of recurrent angio-oedema, without urticaria, often triggered by trauma to mucous membranes, such as sexual intercourse or dental work. It will not respond to adrenaline and should instead be treated with a C1 esterase inhibitor.

E Contact allergic dermatitis

Explanation

C C1 esterase inhibitor deficiency

C1 esterase inhibitor deficiency is an inherited or acquired cause of recurrent angio-oedema, without urticaria, often triggered by trauma to mucous membranes, such as sexual intercourse or dental work. It will not respond to adrenaline and should instead be treated with a C1 esterase inhibitor.

A Type 1 hypersensitivity to latex

Type 1 hypersensitivity reactions are more likely to result in shortness of breath and to cause significant itching and urticaria.

B Type 4 hypersensitivity to latex

Type 4 hypersensitivity reactions are delayed and lead to a contact dermatitis-type skin rash.

D Chronic idiopathic

The absence of a skin rash rules out chronic idiopathic urticaria, which can be managed with the use of regular antihistamines.

E Contact allergic dermatitis

Here again, the absence of skin rash rules out contact allergic dermatitis, considered a type 4 hypersensitivity reaction.

A 32-year-old woman presents to the Acute Medical Clinic for review. She is concerned due to eruption of multiple lesions over her chest back over the last few weeks.

She has no past medical history, but on questioning she reveals that she had a fever three weeks ago alongside a sore throat. This improved within a week.

She takes no regular tablets but was taking ibuprofen for her sore throat.

A photograph of her back is shown below.

Which treatment would be the most appropriate to accelerate recovery?

A	Refer for tonsillectomy
B	Antibiotics
C	Phototherapy
D	Systemic corticosteroids
E	Methotrexate

C Phototherapy

This patient has guttate psoriasis. Guttate psoriasis is heavily associated with a preceding streptococcal infection, usually pharyngitis or tonsillitis typically 2–3 weeks before a rash is noticed. Presentation is an acute popular rash of the trunk and proximal extremities. These are often described as droplets. There may be a family history of psoriasis. Prognosis is generally good, with the condition running a self-limiting course taking weeks to a few months to resolve. Previously affected areas may show changes in levels of inflammation. Recovery can be hastened by using phototherapy or topical steroids, with emollients to provide symptom relief.

A Refer for tonsillectomy

Tonsillectomy may be considered in chronic guttate psoriasis as this may be a source of recurrent streptococcal infection. However, this patient is likely to improve with minimal intervention.

B Antibiotics

Antibiotics are often prescribed for guttate psoriasis due to the association with streptococcal infection, but studies have failed to demonstrate any improvement in the recovery or avoidance of complications when given. In acute infections, this would be warranted, but this patient's infection has already resolved.

D Systemic corticosteroids

As this patient has a condition which is largely self-limiting, systemic steroids are not indicated. The side-effects would likely outweigh any benefits.

B Antibiotics

Antibiotics are often prescribed for guttate psoriasis due to the association with streptococcal infection, but studies have failed to demonstrate any improvement in the recovery or avoidance of complications when given. In acute infections, this would be warranted, but this patient's infection has already resolved.

D Systemic corticosteroids

As this patient has a condition which is largely self-limiting, systemic steroids are not indicated. The side-effects would likely outweigh any benefits.

E Methotrexate

This patient has guttate psoriasis which is self-limiting in most patients. It would be unreasonable to start methotrexate due to the potential side-effects of this treatment.

Rate this question:

Previous Q... Tag Questi... Feedback End Session

Blog About Pastest Contact Us Help

© Pastest 2019

A 26-year-old builder attended the clinic, concerned that he may have 'skin cancer' under his nail. He could not recall any previous trauma to the nail.

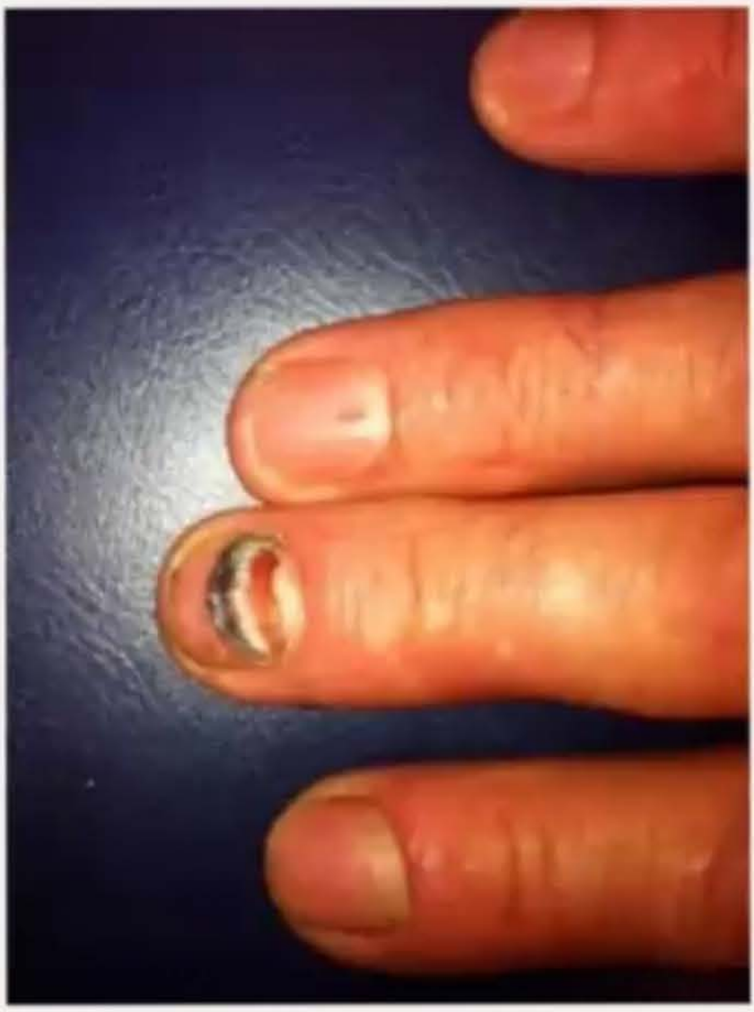

What is the most likely diagnosis?

A	Subungual melanoma
B	Traumatic nail change
C	Pseudomonas infection
D	Onychomycosis
E	Argyria

Explanation

B Traumatic nail change

Traumatic nail change is suggested by the occupation of the patient. (Patients often don't recall an episode of trauma.) Also the different colours lined symmetrically and longitudinally suggest anold haematoma. Hutchinson's sign is negative, (hyperpigmentation of the nail bed and matrix).

A Subungual melanoma

In subungual melanomas are associated with a positive Hutchinson's sign, (hyperpigmentation, (usually blue / black) of the nail bed and matrix).

C Pseudomonas infection

Pseudomonas causes black or green nail discoloration versus the band of pigment change across the nail related to trauma.

D Onychomycosis

This causes yellow or brown nail discoloration, with brittle, crumbling nails.

E Argyria

Argyria is silver poisoning, and leads to blue nail discoloration, not cofinedto a single nail as is seen here.

Rate this question:

Next Question

Facebook

Hutchinson's nail sign is an important... - RGV Footcare, P.A...

Facebook

Images may be subject to copyright. Learn More

RELATED IMAGES

DISEASES OF THE HAIR & NA...

Pseudo-Hutchinson's sign in ...

openi.nlm.nih.gov

1:27
https://mypastest.pastest.com

A 62-year-old man presents to his GP having noticed white patches on his tongue when cleaning his teeth. These do not dislodge when he tries to brush them away. The patient does not report any associated symptoms.

The patient is otherwise fit and well and is only on one tablet for control of his blood pressure. He has been a pipe smoker for 40 years and admits to liking his alcohol, consuming about 15 glasses of spirits per week.

On examination of the patient's mouth, localised, opaque elevated plaques with an irregular outline are seen on the buccal mucosa. There appears to be ulceration on the base of one of these areas. The teeth appear healthy. General clinical examination is normal.

What is the most likely diagnosis?

A	Lichen planus
B	Oral candidiasis
C	Oral leukoplakia
D	White sponge naevi of Cannon
E	Multiple aphthous ulcers

Submit

Rana Alnasser's screen

A 62-year-old man presents to his GP having noticed white patches on his tongue when cleaning his teeth. These do not dislodge when he tries to brush them away. The patient does not report any associated symptoms.

The patient is otherwise fit and well and is only on one tablet for control of his blood pressure. He has been a pipe smoker for 40 years and admits to liking his alcohol, consuming about 15 glasses of spirits per week.

On examination of the patient's mouth, localised, opaque elevated plaques with an irregular outline are seen on the buccal mucosa. There appears to be ulceration on the base of one of these areas. The teeth appear healthy. General clinical examination is normal.

What is the most likely diagnosis?

Your answer was correct

A Lichen planus

B Oral candidiasis

C Oral leukoplakia

D White sponge naevi of Cannon

E Multiple aphthous ulcers

Explanation

C Oral leukoplakia

Oral leukoplakia is a condition characterised by well demarcated, asymptomatic white patches that cannot be

unknown aetiology that typically appears as patches of fine, white, lace-like lines. Mainstay of treatment is with topical corticosteroids in the form of sprays, lozenges or mouthwashes.

B Oral candidiasis

Oral candidiasis (thrush) is a yeast infection of the mouth mucosae by the species *Candida albicans*. Common predisposing factors include smoking, immunodeficiency, dentures, and sicca. Treatment is by topical anti-fungal agents such as nystatin.

D White sponge naevi of Cannon

White sponge naevus (naevus of Canon) is an autosomal dominant condition that causes thick, white and velvety lesions on mouth mucosae. Lesions are usually present from birth or develop during childhood. The condition is entirely benign, and requires no treatment.

E Multiple aphthous ulcers

Aphthous ulcers are painful and hence the patients are symptomatic.

7613

Rate this question:

Next Question

Previous Q... Tag Questi... Feedback End Session

Blog About Pastest Contact Us Help

A 65-year-old woman, with multiple medical problems including ischaemic heart disease, chronic kidney disease, treated hypothyroidism, SLE and a 60 pack/year smoking history, presents with exquisitely painful, necrotic ulcers on her abdomen, thighs and shins. She says that these ulcers usually begin as areas of blue/black discoloured skin before they break down. A diagnosis of calciphylaxis is confirmed.

Which of the following is the most important risk factor for development of her calciphylaxis?

A	Venous insufficiency
B	Chronic kidney disease
C	Smoking
D	Hypothyroidism
E	Systemic lupus erythematosus (SLE)

Submit

A 65-year-old woman, with multiple medical problems including ischaemic heart disease, chronic kidney disease, treated hypothyroidism, SLE and a 60 pack/year smoking history, presents with exquisitely painful, necrotic ulcers on her abdomen, thighs and shins. She says that these ulcers usually begin as areas of blue/black discoloured skin before they break down. A diagnosis of calciphylaxis is confirmed.

Which of the following is the most important risk factor for development of her calciphylaxis?

Your answer was correct

A	Venous insufficiency
B	Chronic kidney disease
C	Smoking
D	Hypothyroidism
E	Systemic lupus erythematosus (SLE)

Explanation

B Chronic kidney disease

Calciphylaxis is a life-threatening condition most often seen in late-stage chronic kidney disease on dialysis. Calcium deposits in the cutaneous arteries lead to thrombosis and ischaemic necrosis, with refractory ulcers often in the lower extremities, abdomen or buttocks.

1:31

calciphylaxis

ALL IMAGES NEWS VIDEOS MAPS SHOPPING BOOKS

Latest GIF HD Product

skin early warfarin pathophysiology

Symptoms, Treatment ...
healthline.com

Calciphylaxis - Wikipedia
en.wikipedia.org

Sodium Thiosulfate for Calciphylaxis ...
renalfellow.org

Calciphylaxis in a Hemodialysis Patient
austinpublishinggroup.com

Calciphylaxis in chronic, non-dialysis ...
bmcnephrol.biomedcentral.com

Clinical images of calciphylaxis in the ...
researchgate.net

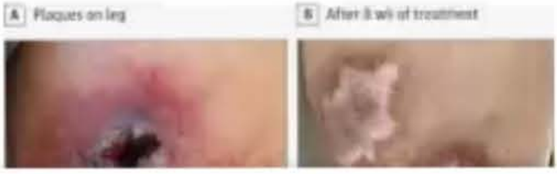

Discover Updates Search

1:31

MyPastest
https://mypastest.pastest.com

Calciphylaxis is a life-threatening condition most often seen in late-stage chronic kidney disease on dialysis. Calcium deposits in the cutaneous arteries lead to thrombosis and ischaemic necrosis, with refractory ulcers often in the lower extremities, abdomen or buttocks.

A Venous insufficiency

Venous insufficiency is most strongly associated with varicose eczema and ulceration over the medial malleolus.

C Smoking

Although smoking increases the risk of necrotic ulcer formation, it isn't the primary cause of calciphylaxis.

D Hypothyroidism

Hypothyroidism may be associated with hair loss and skin oedema, but isn't associated with ulceration.

E Systemic lupus erythematosus (SLE)

Although SLE is associated with skin ulceration, with respect to calciphylaxis it is kidney disease that is the most important predisposing factor.

Rate this question:

Next Question

Previous Q... Tag Questi... Feedback End Session

What is the most likely diagnosis?

A	Scabies
B	Polymorphic Eruption of Pregnancy
C	Chronic spontaneous urticaria
D	Lichen planus
E	Eczema

Submit

Previous Q... Skip Questi...

© Pastest 2019

A 30-year-old woman, in her third trimester of pregnancy, presented with an intensely itchy rash that is keeping her awake at night. The rash started in the stretch marks of her abdomen and is spreading across her buttocks and thighs.

What is the most likely diagnosis?

A	Scabies
B	Polymorphic Eruption of Pregnancy
C	Chronic spontaneous urticaria
D	Lichen planus
E	Eczema

Submit

1:33
On
594-042-7551
Leave

B Polymorphic Eruption of Pregnancy

Polymorphic Eruption of Pregnancy also known as Pruritic Urticarial Papules and Plaques of Pregnancy (PUPPP) is an itchy eruption that starts in the last 3 months of pregnancy and clears with delivery. It consists of small, pink papules that appear in the stretch marks around the umbilicus. These papules coalesce to form urticarial patches which can spread to involve the buttocks and thighs.

A Scabies

Scabies is an itchy skin condition that occurs due to infection with the mite *Sarcoptes scabiei* following prolonged physical contact with an infected person. Scabies is diagnosed clinically due to the presence of burrows, often in typical areas such as the wrists and interdigital spaces of the hands. Treatment is with application of topical permethrin cream.

C Chronic spontaneous urticaria

Chronic spontaneous urticaria refers to the idiopathic condition where urticarial lesions or angioedema occur in an individual without any inducible cause. Urticaria is usually intensely itchy and may last from a few minutes to 24 hours. The mainstay of treatment is with combinations of oral antihistamines.

D Lichen planus

Lichen planus is a chronic inflammatory condition of unknown aetiology that typically appears as violaceous plaques with fine, white, lace-like lines (Wickham's striae).

E Eczema

Audio Video Share Participants More

1:34
On 594-042-7551 Leave

A 55-year-old man comes to the clinic for review, following admission with a third episode of right lower lobe pneumonia in the past two years. He has received several rotating courses of antibiotics from the Community Respiratory Nursing Service and still has a chronic cough, productive of thick, yellow sputum.

Examination reveals coarse crackles at both lung bases on auscultation, with wheeze throughout. There is lymphoedema affecting both lower limbs.

A picture of his hands is shown below.

Which of the following is the most likely cause of his recurrent respiratory tract infections?

A	Chronic obstructive pulmonary disease (COPD)
B	Bronchiectasis
C	Wegener's granulomatosis
D	Sarcoidosis
E	Idiopathic pulmonary fibrosis (IPF)

Audio Video Share Participants More

B Bronchiectasis

This patient has yellow nail discoloration with nail dystrophy. Coupled with evidence of recurrent lower respiratory tract infections, persistent crackles on auscultation and lymphoedema, the most likely cause of his recurrent respiratory tract infections is bronchiectasis, related to underlying yellow nail syndrome. Pleural effusions are also seen in the condition.

A Chronic obstructive pulmonary disease (COPD)

We are not given a history of smoking here, and nail dystrophy and lymphoedema, as seen here, are inconsistent with a diagnosis of COPD.

C Wegener's granulomatosis

Wegener's granulomatosis is associated with pulmonary infiltration, coupled with evidence of renal vasculitis. It carries an acute presentation, often with evidence of haemoptysis.

D Sarcoidosis

Sarcoidosis is associated with hilar lymphadenopathy and, over the longer term, with pulmonary fibrosis in active disease. It does not fit with nail dystrophy, lymphoedema and recurrent respiratory tract infections seen here.

E Idiopathic pulmonary fibrosis (IPF)

IPF is associated with crackles on auscultation of the chest, but with finger clubbing, rather than nail dystrophy as seen here.

1:35
On
594-042-7551
Leave

A 50-year-old man was being treated with intravenous co-trimoxazole in the high-dependency unit. His condition appeared to be improving but he developed further pyrexia, generalised arthralgia, vesicles in his oral mucosa and genital ulceration. Symmetrical, target-like lesions with concentric macules and papules were noticed originally on palms and soles, then face and trunk.

Since then, erythema has become confluent, tender with raised flaccid blisters which spread with lateral pressure, causing erosions.

What is the first management step?

A	Intravenous fluid supplementation
B	Systemic corticosteroids
C	Debridement
D	Stop co-trimoxazole
E	Topical steroids

Submit

Audio
Video
Share
Participants
More

1:37
On 594-042-7551 Leave

A 50-year-old man was being treated with intravenous co-trimoxazole in the high-dependency unit. His condition appeared to be improving but he developed further pyrexia, generalised arthralgia, vesicles in his oral mucosa and genital ulceration. Symmetrical, target-like lesions with concentric macules and papules were noticed originally on palms and soles, then face and trunk.

Since then, erythema has become confluent, tender with raised flaccid blisters which spread with lateral pressure, causing erosions.

What is the first management step?

Difficu

Peer R

Sessio

Responses
Responses
Responses
Responses

Your answer was correct

A	Intravenous fluid supplementation
B	Systemic corticosteroids
C	Debridement
D	Stop co-trimoxazole
E	Topical steroids

Explanation

D Stop co-trimoxazole

Drug triggers are the most common cause of Stevens-Johnson syndrome, and prompt withdrawal of the suspected drug can improve prognosis.

Medications are the leading trigger of Stevens-Johnson syndrome, and therefore early diagnosis and withdrawal of suspected drugs are very important. In a large multinational case-control study involving 379 cases (see

Audio Video Share Participants More

1:37
On 594-042-7551 Leave

Explanation

D	Stop co-trimoxazole

Drug triggers are the most common cause of Stevens-Johnson syndrome, and prompt withdrawal of the suspected drug can improve prognosis.

Medications are the leading trigger of Stevens-Johnson syndrome, and therefore early diagnosis and withdrawal of suspected drugs are very important. In a large multinational case-control study involving 379 cases (see weblink 1, below), the most commonly associated drugs were:

- Allopurinol
- Aromatic anticonvulsants: carbamazepine, phenobarbital, lamotrigine, phenytoin
- Antibacterial sulphonamides: co-trimoxazole
- Oxicam NSAIDs
- Also, less frequently, cephalosporins, fluoroquinolones, vancomycin, rifampicin.

High doses and rapid introduction of medications can also be a risk factor.

A	Intravenous fluid supplementation

Supportive care in Stevens-Johnson syndrome is the same as for major burns and wound care. Although intravenous fluid supplement would be beneficial for the patient, withdrawing the suspected drug will improve prognosis.

B	Systemic corticosteroids

The use of systemic corticosteroids in patients has not been evaluated in clinic trials, but a systematic review of case series and a mortality analysis of the RegiSCAR

Audio Video Share Participants More

1:37
On 594-042-7551 Leave

using the SCORTEN score (see reference below). The ICU/burns unit setting is dependent on the extent of skin involvement and presence of co-morbidites. The SCORTEN score can be used to determine whether the clinic setting is appropriate for the patient.

Lymphopenia, anaemia, hypoalbuminaemia, high urea and creatinine, electrolyte imbalances as well as raised glucose and ALT can be seen in SJS.

Other aspects of management to consider after withdrawing the suspected drug include the following:

- Fluids and nutrition
- Pain control
- Wound care
- Prevention and treatment of infections
- Ocular management

N.B. Intravenous immune globulin (IVIG): there is no high-quality evidence supporting the use of IVIG, but this could be used in the early phase of the disease in severe cases.

Reference:

SCORTEN: a severity-of-illness score for toxic epidermal necrolysis. DOI: 10.1046/j.1523-1747.2000.00061.x.

Rate this question:

Next Question

Previous Q... Tag Questi... Feedback End Session

Blog About Pastest Contact Us Help

© Pastest 2019

Audio Video Share Participants More

1:37
On 594-042-7551 Leave

A 32-year-old woman presents with a 1-week history of cellulitis of the middle finger of her left hand. This has occurred twice before in the last year and resolved after 2–3 weeks. On each occasion, she presented with cellulitis and painful lymphadenopathy of the left axilla, and was treated with intravenous antibiotics. Wound swabs, blood cultures and fungal cultures were negative.

On examination, the patient had a vesiculo-pustular plaque on the distal phalanx, with lesions on the ulnar border of the middle phalanx.

There was ascending lymphangitis on the dorsum of the left hand extending proximally to the mid-forearm, and painful lymphadenopathy.

Prolonged tissue culture for acid-fast bacilli is sent.

X-ray of the left finger shows no bony abnormality.

Magnetic resonance imaging (MRI) of the left hand shows high signal within the soft tissue of the middle finger consistent with oedema.

What is the best management option?

A Aciclovir 800 mg 5 times/day

Audio Video Share Participants More

There was ascending lymphangitis on the dorsum of the left hand extending proximally to the mid-forearm, and painful lymphadenopathy.

Prolonged tissue culture for acid-fast bacilli is sent.

X-ray of the left finger shows no bony abnormality.

Magnetic resonance imaging (MRI) of the left hand shows high signal within the soft tissue of the middle finger consistent with oedema.

What is the best management option?

A	Aciclovir 800 mg 5 times/day
B	Anti-tuberculous therapy
C	Benzyl penicillin 1.2 g qds + flucloxacillin 1 g intravenously qds
D	Prednisolone 60 mg od
E	Surgical debridement

A Aciclovir 800 mg 5 times/day

The clinical features and recurrent nature at the same site are diagnostic for *Herpes simplex* infection, known on a digit as herpetic whitlow. This may cause secondary cellulitis, lymphangitis and lymphadenitis. Rarely, lymphoedema may follow. The diagnosis should be confirmed on a viral swab, usually via culture or PCR. Uncomplicated disease may not require treatment, but given the complications in the scenario, aciclovir should be commenced. In recurrent disease, prophylaxis (aciclovir 400 mg bd) is appropriate.

D Prednisolone 60 mg od

This would risk worsening *Herpes simplex* infection, the diagnosis of which is clear from the photograph.

B Anti-tuberculous therapy

Cutaneous lesions of tuberculosis would not be episodic and the appearance in the photograph is characteristic of *Herpes simplex* infection.

C Benzyl penicillin 1.2 g qds + flucloxacillin 1 g intravenously qds

This might be appropriate for super-added bacterial infection, but the symptoms and signs are fully compatible with *Herpes simplex* infection.

E Surgical debridement

This has no place in the management of herpetic whitlow, the diagnosis of which is clear from the photograph.

Rana Alnasser's screen

cellulitis of the middle finger of her left hand. This has occurred twice before in the last year and resolved after 2–3 weeks. On each occasion, she presented with cellulitis and painful lymphadenopathy of the left axilla, and was treated with intravenous antibiotics. Wound swabs, blood cultures and fungal cultures were negative.

On examination, the patient had a vesiculo-pustular plaque on the distal phalanx, with lesions on the ulnar border of the middle phalanx.

There was ascending lymphangitis on the dorsum of the left hand extending proximally to the mid-forearm, and painful lymphadenopathy.

Prolonged tissue culture for acid-fast bacilli is sent.

X-ray of the left finger shows no bony abnormality.

Magnetic resonance imaging (MRI) of the left hand shows high signal within the soft tissue of the middle finger consistent with oedema.

What is the best management option?

Your answer was incorrect

A Acyclovir 800 mg 5 times/day

A
B
C
D
E
O

Re
Re
Re
Re

1:43
On
594-042-7551
Leave

A 55-year-old woman was admitted under the Liver Team with alcoholic liver disease. She was commenced on primary prophylaxis for spontaneous bacterial peritonitis and discharged from hospital five days later.

A week later, she developed well-demarcated erythema over the front of her legs and large blisters over her knees and dorsum of her feet, and on her lower arms after a short sunbathing spree in the park.

On examination, there are no other abnormalities on the skin elsewhere.

Which is the most likely diagnosis?

A	Porphyria cutanea tarda
B	Polymorphic light eruption
C	Pemphigus vulgaris
D	Phototoxic reaction
E	Sunburn reaction

Submit

Previous Q...

Skip Questi...

Audio
Video
Share
Participants
More

1:45

A 55-year-old woman was admitted under the Liver Team with alcoholic liver disease. She was commenced on primary prophylaxis for spontaneous bacterial peritonitis and discharged from hospital five days later.

A week later, she developed well-demarcated erythema over the front of her legs and large blisters over her knees and dorsum of her feet, and on her lower arms after a short sunbathing spree in the park.

On examination, there are no other abnormalities on the skin elsewhere.

Which is the most likely diagnosis?

Your answer was incorrect

A Porphyria cutanea tarda

B Polymorphic light eruption

C Pemphigus vulgaris

D Phototoxic reaction

E Sunburn reaction

Explanation

D Phototoxic reaction

Phototoxic drug reactions have been described for all quinolones including ciprofloxacin, a common antibiotic choice for the treatment of spontaneous bacterial peritonitis. Phototoxic skin reactions *per se* are associated with confluent areas of erythema.

Rana Alnasser's screen

Phototoxic drug reactions have been described for all quinolones including ciprofloxacin, a common antibiotic choice for the treatment of spontaneous bacterial peritonitis. Phototoxic skin reactions *per se* are associated with confluent areas of erythema.

A Porphyria cutanea tarda

Porphyria cutanea tarda could account for the blisters seen here, although patients tend to have other skin manifestations, e.g. blisters, erosions and milia on exposed parts of the face and backs of the hand in response to sunlight.

B Polymorphic light eruption

Polymorphic light eruptions affect exposed areas and often result in blistering, although the face is often spared. They are usually preceded by a long history of sun intolerance. Polymorphic light eruption appears some hours after sun exposure and a number of features may be seen, including papules and erythematous plaques.

C Pemphigus vulgaris

Pemphigus vulgaris is a painful, blistering rash that isn't confined to sun-exposed areas, particularly affecting the buccal cavity.

E Sunburn reaction

A short sunbathing spree in an English park would be unlikely to lead to severe sunburn; a phototoxic drug reaction related to quinolone use is much more likely.

Phototoxicity has been described for all quinolones including ciprofloxacin. Porphyria cutanea tarda could

1:46
On
594-042-7551
Leave

milia skin

ALL IMAGES SHOPPING VIDEOS NEWS MAPS BOOKS

Latest GIF HD Product

baby chin african american skin eye

How to Get Rid of Milia: Is Home ...
healthline.com

Milia: Definition, Causes, and Removal
healthline.com

Milia: Definition, Causes, and Removal
healthline.com

Removal of Tiny White Facial Bumps ...
allure.com

How to get rid of milia: Treatment ...
medicalnewstoday.com

Discover Updates Search
Audio Video Share Participants More

Source: Goldsmith LA, Katz SI, Gilchrest BA, Paller AS, Leffell DJ, Wo
in General Medicine, 8th Edition: www.accessmedicine.com

Copyright © The McGraw-Hill Companies, Inc. All rights reserved.

AccessMedicine - McGraw-Hill Medical

Chapter 132. The Porphyrias | Fitzpatrick's Dermatology in

Image not available.

Images may be subject to copyright. Learn more

RELATED IMAGES

Discover Updates Search Re

A 61-year-old woman with end-stage kidney disease presents with a 6-week history of progressive, painful tightening of the skin leading to disabling joint contractures. She denies having any difficulty swallowing, but admits to progressively worsening shortness of breath since the onset of her symptoms. She also complains of severe bone pain. She had a contrast-enhanced MRI 2 months earlier to rule out a slipped disc.

On examination, she has symmetrically distributed, indurated, woody plaques on the trunk and lower limbs. Her face, neck and nails are normal.

Which one of the following is the most likely diagnosis?

A	Systemic sclerosis
B	Plaque morphoea
C	Scleromyxoedema
D	Pre-tibia myxoedema
E	Nephrogenic systemic fibrosis

38518

Submit

Previous Q... Skip Questi...

1:49
On
594-042-7551
Leave

A 61-year-old woman with end-stage kidney disease presents with a 6-week history of progressive, painful tightening of the skin leading to disabling joint contractures. She denies having any difficulty swallowing, but admits to progressively worsening shortness of breath since the onset of her symptoms. She also complains of severe bone pain. She had a contrast-enhanced MRI 2 months earlier to rule out a slipped disc.

On examination, she has symmetrically distributed, indurated, woody plaques on the trunk and lower limbs. Her face, neck and nails are normal.

Which one of the following is the most likely diagnosis?

Your answer was correct

A Systemic sclerosis

B Plaque morphoea

C Scleromyxoedema

D Pre-tibia myxoedema

E Nephrogenic systemic fibrosis

Explanation

E Nephrogenic systemic fibrosis

Nephrogenic systemic fibrosis is a devastating cutaneous dermopathy seen in patients with end-stage kidney disease, and who have been exposed to gadolinium-based

Audio Video Share Participants More

1:51

scleromyxedema

doughnut sign | histopathology | face | histology | papular muci

Successful Treatment of Scleromyxedema ...
jamanetwork.com

Scleromyxedema: nodular lesions on the ...
researchgate.net

Scleromyxedema (generalized and ...
clinicaladvisor.com

KEY POINTS

- Scleromyxedema shares cutaneous and extracutaneous features with scleroderma, including skin tightness, dysphagia and musculoskeletal symptoms.
- Subsets of patients with scleromyxedema may have systemic features, namely CNS involvement, which are associated with poor outcome.
- Scleromyxedema does respond to therapy with the most commonly reported success with IVIG; also, there are reports of response to thalidomide, bortezomib and autologous stem cell transplantation.
- The connection between the clinical manifestations of the disease and the almost uniformly present monoclonal gammopathy is poorly understood.

Scleromyxedema : Current Opinion in ...
journals.lww.com

PDF) Single Case Scleromyxedema without ...
researchgate.net

Discover Updates Search Re
Rana Alnasser's screen

Indian Journal of Dermatology, Venereology and Leprology

Scleromyxedema

Figure 1: Numerous firm papules and nodules distributed on the neck, trunk, and lim
arrangement. Diffuse induration and thickening ...

Images may be subject to copyright. Learn more

RELATED IMAGES

Discover Updates Search Re
Rana Alnasser's screen

1:52

E Nephrogenic systemic fibrosis

Nephrogenic systemic fibrosis is a devastating cutaneous dermopathy seen in patients with end-stage kidney disease, and who have been exposed to gadolinium-based contrast agents seen in MRI. Metformin may also be a potential trigger, although the exact pathophysiological mechanism for the condition is unknown. Complications include pulmonary fibrosis, cardiomyopathy and pulmonary hypertension.

A Systemic sclerosis

In systemic sclerosis a more prolonged course of symptoms would be expected, with other features such as Raynaud's, telangiectasia and nail changes not seen here.

B Plaque morphoea

Morphea is usually asymptomatic, with asymmetrical areas of cutaneous fibrosis consistent with scleroderma developing over a period of many months, without the proximity, as here to gadolinium contrast material.

C Scleromyxoedema

Scleromyxoedema is a rare progressive cutaneous mucinosis associated with progressive deposition of mucin within connective tissue, and often a paraproteinaemia.

D Pre-tibia myxoedema

Pre-tibial myxoedema is confined to the shins and is associated with oedema and fibrosis, and with thyroid dysfunction.

38318

Rana Alnasser's screen

1:52

A 45-year-old man presents to the General Medical Clinic with a rash. This has been gradually developing over the last few weeks. It has been affecting his scalp and causing fine flakes. It is itchy. He has not had anything similar in the past.

He has had acne has a teenager as well as eczema, but both of these problems have not been a cause for concern in decades.

On examination, there is a patchy rash, as shown in the photograph below.

What is the most appropriate management?

A	Hydrocortisone 1%
B	Ketaconazole shampoo
C	Dapsone
D	Flucloxacillin
E	Zinc replacement

Rana Alnasser's screen

B Ketaconazole shampoo

This is correct as this patient has seborrhoeic dermatitis. Seborrhoeic dermatitis is inflammation of the skin in areas rich in sebaceous glands. It therefore commonly affects the scalp, chest and face and can present from puberty onwards. It typically occurs in immunocompromised or stressed states, and especially in those with neurological conditions. The latter association is thought to be due to association with reduced movement. The inflammatory reaction is thought to be linked to the yeast *Malassezia*. The rash itself appears as an inflamed and greasy area with fine scaling. Scalp involvement can be managed with a shampoo containing ketoconazole 2% or selenium sulfide. Alternatives include shampoos containing zinc pyrithione – which is found in over-the-counter products such as anti-dandruff shampoo – used twice a week for a month. For the body, intermittent use of a ketaconazole cream and topical hydrocortisone is effective.

A Hydrocortisone 1%

Topical corticosteroid treatment would be appropriate for scalp eczema. This would be characterised by dryness and itching with other areas affected as well; typically extensor surfaces of the limb and the face in acute episodes. This would be typically appropriate in combination with topical emollients.

C Dapsone

This would be the correct answer for dermatitis herpetiformis refractory to dietary changes. Dermatitis herpetiformis is a dermatological condition heavily associated with coeliac disease. It presents as a very itchy bullous rash with groups of vesicles on a backdrop of erythema, and typically presents on the scalp, buttocks, elbows and knees. Without the presence of coeliac disease

1:55
On ...
594-042-7551
Leave

C Dapsone

This would be the correct answer for dermatitis herpetiformis refractory to dietary changes. Dermatitis herpetiformis is a dermatological condition heavily associated with coeliac disease. It presents as a very itchy bullous rash with groups of vesicles on a backdrop of erythema, and typically presents on the scalp, buttocks, elbows and knees. Without the presence of coeliac disease, dermatitis herpetiformis is very unlikely, although this rash can precede coeliac disease. Management is with a gluten-free diet and, if that fails, dapsone.

D Flucloxacillin

Flucloxacillin would have been an appropriate treatment plan for cellulitis and erysipelas. Cellulitis is an infection of the dermis and the subcutaneous tissues just below the dermis. Erysipelas is a more superficial infection. The primary cause for both is *Staphylococcus aureus* and beta-haemolytic streptococci. Presentation is erythematous, painful and raised skin, with potential for systemic involvement. The presentation of this patient and the appearance of the rash are not consistent with cellulitis or erysipelas.

E Zinc replacement

Zinc deficiency can lead to alopecia and dermatitis, as well as intellectual disability, nerve damage and hypogonadism; however, it would not explain the sudden onset of a rash in a patient with no risk factors for zinc deficiency or causes of malabsorption. Alopecia can occur with zinc deficiency, as can a generalised dermatitis.

Rate this question:
Audio Video Share Participants More

1:55

A 79-year-old woman presents with a 6-month history of a widespread itchy rash.

It mainly affects the forearms and hands, but there are similar ill-defined, erythematous lesions on the trunk, particularly around the nipples. Her face is unaffected.

She lives in a residential home. She feels well in herself otherwise.

In addition to her long-term medications, simvastatin and felodipine, she has been taking zopiclone tablets recently prescribed by her general practitioner, to help her sleep.

What is the diagnosis?

A	Folliculitis
B	Drug eruption
C	Atopic eczema
D	Scabies

Rana Alnasser's screen

Explanation

D	Scabies

The widespread, itchy eruption, which is worst on the hands, best fits with this diagnosis. Scabies is an infestation with the human scabies mite, *Sarcoptes scabiei*. It is transmitted by close contact so is often spread between family members, at nurseries and in care institutions. Symptoms occur 4-6 weeks after initial infestation, when hypersensitivity occurs to the mite or its waste products. Scabies is characterised by intense itching, particularly at night. This can lead to prominent excoriation. Burrows (linear crusted lesions of a few millimetres in length) are pathognomonic and penile papules are also highly suggestive, though not always evident. It has a predilection for the web-spaces and around the nipples. Secondary eczematisation is not uncommon, as in this case. Scalp involvement only occurs in young babies and very debilitated adults. Treatment is usually with permethrin; close contacts should be treated concurrently.

A	Folliculitis

This infection, usually due to *Staphylococcus aureus*, is characterised by pustules.

B	Drug eruption

The rash does not look suggestive of this. Drug eruptions are typically exanthematous (with a maculopapular morphology), and eczematous features are unusual.

C	Atopic eczema

Eczema (in general) may appear at any age, but with no specific pointers to atopy (e.g. history of asthma, childhood eczema, hay fever) and no suggestion of flexural

Rana Alnasser's screen

1:58
On 594-042-7551 Leave

close contacts should be treated concurrently.

A Folliculitis

This infection, usually due to *Staphylococcus aureus*, is characterised by pustules.

B Drug eruption

The rash does not look suggestive of this. Drug eruptions are typically exanthematous (with a maculopapular morphology), and eczematous features are unusual.

C Atopic eczema

Eczema (in general) may appear at any age, but with no specific pointers to atopy (e.g. history of asthma, childhood eczema, hay fever) and no suggestion of flexural accentuation of the rash, this option is not likely.

E Cutaneous T-cell lymphoma

This may present in a variety of ways, including an eczematous eruption. It usually gives rise to well-defined plaques rather than the much more diffuse picture seen here. Sézary syndrome tends to present with erythroderma, in which the skin is deeply erythematous.

Rate this question:

Audio Video Share Participants More

1:59
On
594-042-7551
Leave

characterised by pustules.

B Drug eruption

The rash does not look suggestive of this. Drug eruptions are typically exanthematous (with a maculopapular morphology), and eczematous features are unusual.

C Atopic eczema

Eczema (in general) may appear at any age, but with no specific pointers to atopy (e.g. history of asthma, childhood eczema, hay fever) and no suggestion of flexural accentuation of the rash, this option is not likely.

E Cutaneous T-cell lymphoma

This may present in a variety of ways, including an eczematous eruption. It usually gives rise to well-defined plaques rather than the much more diffuse picture seen here. Sézary syndrome tends to present with erythroderma, in which the skin is deeply erythematous.

Rate this question:

Next Question

© Pastest 2019

Audio Video Share Participants More

1:59
On
594-042-7551
Leave

cutaneous t cell lymphoma

face

leg

staging

treatment

Cutaneous T-cell lymphoma | American ...
aad.org

Cutaneous T-Cell Lymphomas. | Allergy ...
jamanetwork.com

Cutaneous T-cell lymphoma | American ...
aad.org

Cutaneous T-Cell Lymphoma | NEJM
nejm.org

Mycosis fungoides - Wikipedia
en.wikipedia.org

Cutaneous T-cell lymphoma | American ...
aad.org

Cutaneous Gamma-Delta T-Cell Lymphoma ...
jamanetwork.com

Discover
Updates
Search
Audio
Video
Share
Participants
More

2:00

MyPastest
https://mypastest.pastest.com

Pastest+

A 68-year-old woman is attending Dermatology Outpatients with an enlarging, asymptomatic mole on her abdomen. She is otherwise fit and healthy and does not take any regular medications.

Examination revealed the lesion which measures 8 mm in maximum diameter. It has an irregular edge and irregularities of colour.

How should this lesion be managed best?

A	Re-assurance
B	Incisional biopsy through the centre of the lesion
C	Excisional biopsy with 5mm clinical margins
D	Excisional biopsy with at least 1cm clinical margins
E	Excisional biopsy, followed by chemotherapy

40097

Submit

Previous Q...

Skip Questi...

Touc... 00:27 2:02

A 68-year-old woman is attending Dermatology Outpatients with an enlarging, asymptomatic mole on her abdomen. She is otherwise fit and healthy and does not take any regular medications.

Examination revealed the lesion which measures 8 mm in maximum diameter. It has an irregular edge and irregularities of colour.

How should this lesion be managed best?

A	Re-assurance
B	Incisional biopsy through the centre of the lesion
C	Excisional biopsy with 5mm clinical margins
D	Excisional biopsy with at least 1cm clinical margins
E	Excisional biopsy, followed by chemotherapy

40097

Submit

Previous Q... Skip Questi...

Rana Alnasser's screen

2:04

MyPastest
https://mypastest.pastest.com

A 68-year-old woman is attending Dermatology Outpatients with an enlarging, asymptomatic mole on her abdomen. She is otherwise fit and healthy and does not take any regular medications.

Examination revealed the lesion which measures 8 mm in maximum diameter. It has an irregular edge and irregularities of colour.

How should this lesion be managed best?

Your answer was incorrect

A	Re-assurance
B	Incisional biopsy through the centre of the lesion
C	Excisional biopsy with 5mm clinical margins
D	Excisional biopsy with at least 1cm clinical margins
E	Excisional biopsy, followed by chemotherapy

Explanation

D	Excisional biopsy with at least 1cm clinical margins

This lesion represents a melanoma. The extent of tumour invasion may not be uniform within a lesion. Complete excision allows for accurate assessment of Breslow thickness that determines the subsequent management

Explanation

D Excisional biopsy with at least 1cm clinical margins

This lesion represents a melanoma. The extent of tumour invasion may not be uniform within a lesion. Complete excision allows for accurate assessment of Breslow thickness that determines the subsequent management and prognosis.

E Excisional biopsy, followed by chemotherapy

Not all melanomas require treatment with chemotherapy. Management is variable and depends on Breslow thickness. Decisions should be taken by the local multidisciplinary team meeting. Patients with high-risk melanomas or those with evidence of local lymphadenopathy should be investigated with CT scanning and may be considered for treatment with chemotherapy or immunotherapy.

A Re-assurance

The lesion displayed shows features suggestive of a melanoma (asymmetry, shape irregularity, multiple colours, diameter larger than 6mm, and associated with a history of growth) and should not be left untreated.

B Incisional biopsy through the centre of the lesion

Suspicious lesions, such as the one shown here, need to be excised rather than sampled with incisional biopsy. However, sampling suspicious areas may be indicated in large lesions, particularly those on the face.

C Excisional biopsy with 5mm clinical margins

2:05

A Re-assurance

The lesion displayed shows features suggestive of a melanoma (asymmetry, shape irregularity, multiple colours, diameter larger than 6mm, and associated with a history of growth) and should not be left untreated.

B Incisional biopsy through the centre of the lesion

Suspicious lesions, such as the one shown here, need to be excised rather than sampled with incisional biopsy. However, sampling suspicious areas may be indicated in large lesions, particularly those on the face.

C Excisional biopsy with 5mm clinical margins

Following histological diagnosis of a melanoma further wide local excision is recommended with surgical margins dependant on Breslow thickness. In order to minimise unnecessarily large defects and ensure complete removal of the lesion, 1cm clinical margins are recommended.

Rate this question:

© Pastest 2019

Rana Alnasser's screen

2:05

A 23-year-old woman has recently emigrated from Romania. She presents for the first time to the medical clinic in the UK. She does not have a complete medical history but has been concerned with nodules on her back. These have been present for a long time but have not significantly bothered her.

She was separated from her family at a young age and so is unsure if any other family member has a similar problem. She has no medical history as far as she is aware. She has had one child, who is healthy. She does not take any regular tablets.

A photograph of the nodules on her back is shown below.

Further examination of her skin reveals no other abnormalities.

What would be the most appropriate step to help establish a diagnosis at this stage?

A	Computed tomography (CT) head
B	Magnetic resonance imaging (MRI) head
C	Fundoscopy

Rana Alnasser's screen

Romania. She presents for the first time to the medical clinic in the UK. She does not have a complete medical history but has been concerned with nodules on her back. These have been present for a long time but have not significantly bothered her.

She was separated from her family at a young age and so is unsure if any other family member has a similar problem. She has no medical history as far as she is aware. She has had one child, who is healthy. She does not take any regular tablets.

A photograph of the nodules on her back is shown below.

Further examination of her skin reveals no other abnormalities.

What would be the most appropriate step to help establish a diagnosis at this stage?

A	Computed tomography (CT) head
B	Magnetic resonance imaging (MRI) head
C	Fundoscopy
D	Human immunodeficiency virus (HIV) testing
E	Karyotyping

C Fundoscopy

This patient likely has neurofibromatosis type 1 as there are multiple neurofibromas on her back. The lack of previous medical involvement explains the lack of a diagnosis at her age. There are seven cardinal clinical features of neurofibromatosis type 1 (NF-1) defined by the National Institutes of Health (NIH). These require two of the following features:

- café-au-lait spots: six or more of 15 mm in diameter
- neurofibromas: two or more
- axillary or inguinal freckling
- optic glioma
- Lisch nodules: two or more
- osseous lesion
- family history: first-degree relative with established diagnosis.

Fundoscopy could help establish Lisch nodules and optic glioma which would help establish a diagnosis with the NIH criteria. Neurofibromatosis type 2 typically presents with progressively worsening hearing loss, tinnitus or balance problems, as well as tumours of the central nervous system. Neurofibromatosis type 2 is subtler than type 1 as there is greater paucity of café-au-lait spots and neurofibromas are less common.

E Karyotyping

Neurofibromatosis is not a chromosomal disorder and therefore this would not be a useful investigation.

A Computed tomography (CT) head

Patients with neurofibromatosis type 1 are prone to several

2:06

A 35-year-old butcher presents to his GP with several small 'spots' on his right hand. He says these 'spots' have been present for several months and have increased in number. He is sure that there was only one at the very start but that adjacent fingers became involved with time. He is otherwise fit and well and is not on any medications.

Examination of the patient's hand shows several skin-coloured exophytic nodules that are not inflamed. There is minimal scaling, but the lesions tend to be found on adjacent skin surfaces.

What would be the most likely diagnosis?

A	Human papilloma virus (HPV) type 2
B	Molluscum contagiousum
C	Pompholyx eczema
D	Squamous cell carcinoma
E	Keratoacanthoma

Submit

Previous Q... Skip Questi...

Rana Alnasser's screen

2:10

A 35-year-old butcher presents to his GP with several small 'spots' on his right hand. He says these 'spots' have been present for several months and have increased in number. He is sure that there was only one at the very start but that adjacent fingers became involved with time. He is otherwise fit and well and is not on any medications.

Examination of the patient's hand shows several skin-coloured exophytic nodules that are not inflamed. There is minimal scaling, but the lesions tend to be found on adjacent skin surfaces.

What would be the most likely diagnosis?

Your answer was incorrect

A	Human papilloma virus (HPV) type 2
B	Molluscum contagiousum
C	Pompholyx eczema
D	Squamous cell carcinoma
E	Keratoacanthoma

Explanation

A	Human papilloma virus (HPV) type 2

Such infections cause benign, self-limiting warts that are usually found on the hands and fingers. The term 'kissing warts' has been applied to this kind of infection due to the autoinoculation that may occur from a wart on one finger

Rana Alnasser's screen

A Human papilloma virus (HPV) type 2

Such infections cause benign, self-limiting warts that are usually found on the hands and fingers. The term 'kissing warts' has been applied to this kind of infection due to the autoinoculation that may occur from a wart on one finger causing the occurrence of warts on an adjacent finger. The virus can be spread by direct or indirect contact and can resist desiccation, freezing and prolonged storage outside of host cells. The diagnosis is made primarily on clinical findings.

E Keratoacanthoma

Keratoacanthomas are thought to be a variant of SCC. They are rapidly enlarging lesions with central keratin plugging that enlarge over months and may then resolve spontaneously. They should be treated as SCCs.

B Molluscum contagiousum

Molluscum contagiosum is a common viral skin infection that causes localised clusters of round, pearly papules with a central pit. It is commonly seen in children and is spread by direct skin-to-skin contact, indirect contact (e.g. via shared towels), and auto-inoculation via scratching.

C Pompholyx eczema

Pompholyx is a type of eczema that causes tiny blisters to develop across the fingers, palms of the hands and sometimes the soles of the feet. Treatment is with topical steroids and avoidance of contact with allergens.

D Squamous cell carcinoma

2:10

keratoacanthoma

eyelid | histology | pathology | early

Primary Care Dermatology ...
pcds.org.uk

Keratoacanthoma - Wikipedia
en.wikipedia.org

Keratoacanthoma - ACD
dermcoll.edu.au

Keratoacanthoma - South East Skin Clinic
skincheck.com.au

Keratoacanthoma
bccancer.bc.ca

Keratoacanthoma - Dermatologic ...

Discover | Updates | Search | Rec

Rana Alnasser's screen

E Keratoacanthoma

Keratoacanthomas are thought to be a variant of SCC. They are rapidly enlarging lesions with central keratin plugging that enlarge over months and may then resolve spontaneously. They should be treated as SCCs.

B Molluscum contagiousum

Molluscum contagiosum is a common viral skin infection that causes localised clusters of round, pearly papules with a central pit. It is commonly seen in children and is spread by direct skin-to-skin contact, indirect contact (e.g. via shared towels), and auto-inoculation via scratching.

C Pompholyx eczema

Pompholyx is a type of eczema that causes tiny blisters to develop across the fingers, palms of the hands and sometimes the soles of the feet. Treatment is with topical steroids and avoidance of contact with allergens.

D Squamous cell carcinoma

SCC is a common type of non-melanoma skin cancer that present as enlarging, often tender, scaly or ulcerated lesions. SCCs are particularly prevalent in elderly. Risk factors include: sun exposure, smoking, fair skin, blue eyes and blond or red hair.

6797

Rate this question:

Rana Alnasser's screen

2:13

pompholyx eczema

Sunlight to Treat Dyshidrotic Eczema ...
jamanetwork.com

Symptoms, Treatment, Diagnosis, Causes ...
hubpages.com

Vesicular hand dermatitis | DermNet NZ
dermnetnz.org

Related Searches

- dyshidrotic eczema contagious
- pompholyx eczema toes
- finger dyshidrotic eczema
- mild eczema on fingers

Pompholyx Eczema – Eczema Life
eczemalife.com

Pompholyx Eczema: what is Dyshidrotic ...
allrash.com

How I Treated My Pompholyx Eczema ...
pinterest.com

Discover Updates Search Rec

2:14

MyPastest
https://mypastest.pastest.com

A 45-year-old man presented with a 3-month history of an exquisitely painful ulcer on his right shin. This started after an insect bite and rapidly developed into an ulcer. He has a background of inflammatory bowel disease. The other leg was entirely normal.

Which of the following initial treatments is most appropriate?

A Topical tacrolimus

B High-dose oral prednisolone

C Oral cyclosporine

D Infliximab

Rana Alnasser's screen

2:14

A 45-year-old man presented with a 3-month history of an exquisitely painful ulcer on his right shin. This started after an insect bite and rapidly developed into an ulcer. He has a background of inflammatory bowel disease. The other leg was entirely normal.

Which of the following initial treatments is most appropriate?

A Topical tacrolimus

B High-dose oral prednisolone

C Oral cyclosporine

D Infliximab

E Silver nitrate dressing

Rana Alnasser's screen

A Topical tacrolimus

Topical calcineurin inhibitors such as tacrolimus result in resolution of limited pyoderma gangrenosum (PG) in up to 50% of patients. It is therefore an appropriate first option for therapy of PG.

B High-dose oral prednisolone

Systemic corticosteroids are an option for patients with more extensive disease, at daily doses between 0.5 and 1.5 mg/kg. The risk benefit profile of systemic corticosteroids means that topical therapies are the usual preferred initial option.

C Oral cyclosporine

Systemic cyclosporine is used as an adjunct to oral corticosteroids in patients who fail to gain an adequate response to therapy.

D Infliximab

Infliximab is an effective biological option for patients who fail to respond to systemic corticosteroids and a conventional DMARD such as cyclosporine.

E Silver nitrate dressing

Due to the phenomenon of pathergy, use of dressings that may adhere to the area of inflammation, such as silver nitrate, should be avoided.

Rate this question:

Rana Alnasser's screen

2:15

A 32-year-old man presents with polyuria and malaise. He also complains of a three-week history of an erythematous rash in the groin as shown below, which appears to be getting worse.

He tells you he has had it intermittently for years but he feels each time he gets it the symptoms are worse. It is very itchy and he is complaining of dysuria. He denies urethral discharge or irritation. He has a regular girlfriend. He is a non-smoker and drinks very little alcohol.

Which of the following investigations would be most useful in assessing why he is susceptible to infection?

A	Syphilis serology
B	Urine dipstick
C	Serum fasting glucose
D	Urethral swab
E	Skin biopsy

33381

Submit

Rana Alnasser's screen

He tells you he has had it intermittently for years but he feels each time he gets it the symptoms are worse. It is very itchy and he is complaining of dysuria. He denies urethral discharge or irritation. He has a regular girlfriend. He is a non-smoker and drinks very little alcohol.

Which of the following investigations would be most useful in assessing why he is susceptible to infection?

Your answer was correct

A Syphilis serology

B Urine dipstick

C Serum fasting glucose

D Urethral swab

E Skin biopsy

Explanation

C Serum fasting glucose

This gentleman's symptoms are suggestive of diabetes, and

C Serum fasting glucose

This gentleman's symptoms are suggestive of diabetes, and *Candida albicans* infections are common in diabetics. A serum fasting glucose of >7 or single random plasma glucose of >11.1 can confirm the diagnosis of diabetes in symptomatic patients. Furthermore, HBA1c can be a diagnostic test; a cut-off point of HBA1c 6.5% (48 mmol/mol) is recommended for diagnosing type 2, but it is not suitable for the diagnosis of suspected type 1 diabetes, which is more likely in this case.

This gentleman has intertrigo. *Candida* skin infections usually present with soreness and itching and are caused by *Candida* species.

Risk factors for mucocutaneous candidiasis are:

- Pregnancy or high-oestrogen contraceptive pill
- Iron deficiency
- Underlying skin disease, e.g. psoriasis, dermatitis
- General debility, e.g. cancer or malnutrition
- Local factors: heat, moisture, skin maceration, topical corticosteroids, poor dental care
- Extremes of age
- Immunocompromised patients, e.g. HIV, chemotherapy, corticosteroid treatment, Cushing's disease
- Diabetes mellitus.

General management of *Candida* skin infections includes the following: avoiding occlusion of skin, avoiding obesity, keeping skin dry, washing with emollients as soap substitutes and drying thoroughly after washing.

First-line treatment is usually a topical imidazole cream, e.g. clotrimazole, econazole, ketoconazole or miconazole. Topical terbinafine is an alternative.

2:18
On
594-042-7551
Leave

General management of *Candida* skin infections includes the following: avoiding occlusion of skin, avoiding obesity, keeping skin dry, washing with emollients as soap substitutes and drying thoroughly after washing.

First-line treatment is usually a topical imidazole cream, e.g. clotrimazole, econazole, ketoconazole or miconazole. Topical terbinafine is an alternative.

If there is problematic itch or inflammation, consider adding a mild corticosteroid cream for 7-14 days.

Oral fluconazole 50 mg/day for 2-4 weeks if: topical treatment is ineffective or there is widespread infection or if the patient is immunocompromised (depending on the severity of infection and the level of immunocompromise). Review after 2 weeks of fluconazole treatment.

Reference: Eyerich K, Eyerich S, Hiller J, et al; Chronic mucocutaneous candidiasis, from bench to bedside. *Eur J Dermatol*. 2010 May/Jun 20(3):260-265. Epub 2010 Feb 5.

A Syphilis serology

The rash is not suggestive of syphilis, which can present as a painless genital ulcer or a diffuse macular/popular rash involving the whole trunk and extremities.

B Urine dipstick

Urine dipstick may confirm glycosuria but will not confirm the diagnosis of diabetes mellitus.

D Urethral swab

If the skin breaks down, this can be associated with dysuria in the absence of a urinary tract infection. There is also no indication that there is any urethral pus.

E Skin biopsy

Audio Video Share Participants More

2:18
On
594-042-7551
Leave

A Syphilis serology

The rash is not suggestive of syphilis, which can present as a painless genital ulcer or a diffuse macular/popular rash involving the whole trunk and extremities.

B Urine dipstick

Urine dipstick may confirm glycosuria but will not confirm the diagnosis of diabetes mellitus.

D Urethral swab

If the skin breaks down, this can be associated with dysuria in the absence of a urinary tract infection. There is also no indication that there is any urethral pus.

E Skin biopsy

Candida albicans (thrush) is usually a clinical diagnosis and does not require skin biopsies.

Rate this question:

© Pastest 2019

Audio Video Share Participants More

A 29-year-old man with a background of NIDDM (non insulin dependent diabetes mellitus) presented with an oozing eruption in his axillae and groins. He described it as smelly and uncomfortable.

On examination, he had a raised BMI of 35 and fluctuant nodules, abscesses and sinus tracts.

Which of the following is the most likely diagnosis?

A Pyoderma gangrenosum

B Acanthosis nigricans

C Erythrasma

D Hidradenitis suppurativa

E Necrobiosis lipoidica

D Hidradenitis suppurativa

Hidradenitis suppurativa (HS) is a chronic, debilitating inflammatory disorder. The pathogenesis is uncertain but 'follicular occlusion' (follicular plugging with dilatation and rupture of the follicle with secondary inflammation of the apocrine glands) has been implicated in the pathogenesis. HS causes recurrent 'boils' in flexural areas. Skin signs can include comedones, subcutaneous nodules, abscesses, scars and sinus tracts. It is associated with insulin resistance, obesity and polycystic ovaries. Other related disorders, of follicular occlusion that may co-exist include acne conglobata, pilonidal abscess and dissecting cellulitis of the scalp.

A Pyoderma gangrenosum

Pyoderma gangrenosum is typically painful, consists of a deep, undermined ulcer with a purplish hue, and heals with scarring. Associations include inflammatory bowel disease, rheumatoid arthritis and myeloid blood dyscrasias.

B Acanthosis nigricans

Acanthosis nigricans is a velvety, brownish hyperpigmentation of the skin, which may be due to obesity, endocrine disease or malignancy.

C Erythrasma

Erythrasma is a common skin infection by the bacterium *corynebacerium minutissimum* that commonly affects the skin folds (groin, axilla). It is usually asymptomatic but may also present as a slowly enlarging, slightly scaly pink or brown patch.

E Necrobiosis lipoidica

2:22

hidradenitis suppurativa

jamanetwork.com

Figure 1. Painful inflammatory nodules are present in HS.

Hidradenitis Suppurativa ...
the-dermatologist.com

Hidradenitis Suppurativa Refractory ...
nature.com

Hidradenitis suppurativa | American ...
aad.org

Hidradenitis suppurativa - ACD
dermcoll.edu.au

Bacteria in Hidradenitis Suppurativa ...
medscape.com

Related Searches

- groin area hidradenitis suppurativa
- hidradenitis suppurativa face
- hidradenitis suppurativa treatment
- hidradenitis suppurativa surgery

Treatments for Hidradenitis Suppurativa ...
ipharminc.com

Discover Updates Search

2:22
On
594-042-7551
Leave

A 60-year-old smoker presented with a 2-week history of an intensely itchy rash over his arms, legs and trunk. He had developed poor appetite and had lost half a stone in weight. He lives in the New Forest and was previous fit and healthy, with no significant past medical history.

On examination, a distinctive rash was noted over the legs, arms and trunk. It had a wood-grain appearance created by concentric, mildly scaling bands of flat to raised erythema.

Given the presentation, what is the most likely diagnosis of the rash?

A Granuloma annulare

B Erythema chronicum migrans

C Tinea corporis

D Erythema gyratum repens (EGR)

E Erythema annulare centrifugum

Submit

Audio Video Share Participants More

A 60-year-old smoker presented with a 2-week history of an intensely itchy rash over his arms, legs and trunk. He had developed poor appetite and had lost half a stone in weight. He lives in the New Forest and was previous fit and healthy, with no significant past medical history.

On examination, a distinctive rash was noted over the legs, arms and trunk. It had a wood-grain appearance created by concentric, mildly scaling bands of flat to raised erythema.

Given the presentation, what is the most likely diagnosis of the rash?

Your answer was incorrect

A	Granuloma annulare
B	Erythema chronicum migrans
C	Tinea corporis
D	Erythema gyratum repens (EGR)
E	Erythema annulare centrifugum

Explanation

D Erythema gyratum repens (EGR)

The answer is Erythema gyratum repens (EGR) (Option D).

EGR is believed to be paraneoplastic in origin. Characteristic concentric, erythematous bands, forming a wood-grain appearance, help distinguish EGR from other rashes. EGR is associated with malignancy in up to 80% of patients. Lung cancer is the most common association, and the smoking history is a strong pointer to this. EGR is also

Twitter

dr_kevinlee on Twitter: "Erythema gyratum repens woodgrain rash ...

@dr_kevinlee on Twitter: "Erythema gyratum repens woodgrain rash= paraneoplastic #dermpath https://t.co/IqaV1gH0eL"

Images may be subject to copyright. Learn more

Discover Updates Search Recent More

Rana Alnasser's screen

2:26

On 594-042-7551 Leave

12:26

erythema gyratum repens

ALL IMAGES SHOPPING NEWS VIDEOS MAPS BOOKS FLIGHTS TABLET

Latest GIF HD Product

cancer dermnet leg stomach livedo reticulari dermatitis figurate neutrophilic

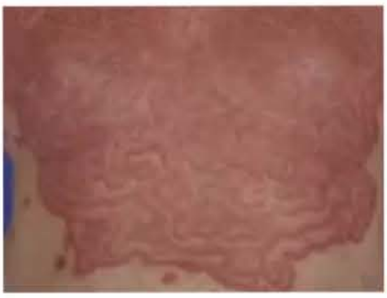

Erythema gyratum repens | DermNet NZ
dermnetnz.org

Erythema Gyratum Repens Clinical ...
emedicine.medscape.com

Erythema Gyratum Repens Associated with ...
nejm.org

Erythema gyratum repens woodgrain rash ...
twitter.com

Erythema gyratum repens | Download ...
researchgate.net

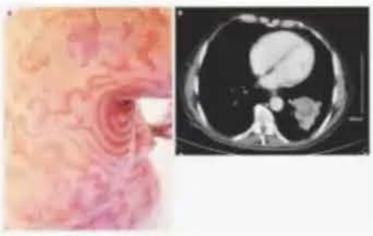

Erythema Gyratum Repens | NEJM
nejm.org

Discover Updates Search Recent More

Audio Video Share Participants More

D Erythema gyratum repens (EGR)

The answer is Erythema gyratum repens (EGR) (Option D).

EGR is believed to be paraneoplastic in origin. Characteristic concentric, erythematous bands, forming a wood-grain appearance, help distinguish EGR from other rashes. EGR is associated with malignancy in up to 80% of patients. Lung cancer is the most common association, and the smoking history is a strong pointer to this. EGR is also associated with breast, bladder, cervical, stomach and prostate cancers.

Most patients with EGR develop the eruption before the symptoms of an underlying malignancy, with a time difference of up to 6 years. EGR is also associated with certain non-malignant conditions, including pulmonary tuberculosis, systemic lupus erythematosus (SLE) and CREST syndrome (calcinosis, Raynaud's phenomenon, oesophageal dysmotility, sclerodactyly and telangiectasia).

E Erythema annulare centrifugum

Erythema annulare centrifugum (Option E) is incorrect.

This is a chronic annular and erythematous eruption, associated with a wide range of conditions such as infections, medications and autoimmune disorders.

A Granuloma annulare

Granuloma annulare (Option A) is incorrect.

Granuloma annulare is a benign inflammatory dermatosis that can affect patients of all ages. It is characterised clinically by papules and annular plaques.

B Erythema chronicum migrans

Erythema chronicum migrans (Option B) is incorrect.

Rana Alnasser's screen

Granuloma annulare is a benign inflammatory dermatosis that can affect patients of all ages. It is characterised clinically by papules and annular plaques.

B	Erythema chronicum migrans

Erythema chronicum migrans (Option B) is incorrect.

This appears at the site of the tick bite in about 90% of patients, on average, around 9 days after the inoculation as a result of infection with *Borrelia burgdorferi*. It presents as an enlarging ring formation, which may clear in the centre, leaving a target-like morphology. Dissemination may lead to arthritis (57%), neural involvement (18%) and heart disease, in particular conduction defects (10%). Most non-disseminated disease responds well to oral antibiotics.

C	Tinea corporis

Tinea corporis (Option C) is incorrect.

Tinea corporis usually presents with annular areas of itchy, erythematous, and scaly skin.

Rate this question:

Next Question

Previous Q... Tag Questi... Feedback End Session

Blog About Pastest Contact Us Help

© Pastest 2019

2:28

erythema annulare centrifugum

ALL IMAGES SHOPPING NEWS VIDEOS MAPS BOOKS FLI

Latest GIF HD Product

pathology deep face trailing scale

Erythema Annulare Centrifugum ...
aocd.org

Erythema Annulare Centrifugum - an ...
sciencedirect.com

Pict
webr

Erythema annulare centrifugum versus ...
gponline.com

Erythema annulare centrifugum
escholarship.org

Eryt
eme

Discover Updates Search Rece

2:29

On 594-042-7551 Leave

12:29

granuloma annulare

diabetes | hand | subcutaneous | histology | perforating | generaliz

Granuloma annulare - Symptoms and ...
mayoclinic.org

Picture of Granuloma Annulare
webmd.com

Granuloma annulare | American Academy ...
aad.org

Product
Online Dermatology - Granuloma Annulare
firstderm.com

Granuloma annulare - ACD
dermcoll.edu.au

Granuloma annulare | DermNet NZ
dermnetnz.org

Granuloma annulare - NHS
nhs.uk

granuloma annulare Picture Image on ...
medicinenet.com

Annotation Stop Share

Granuloma annulare | DermNet NZ
dermnetnz.org

Collections

Discover Updates Search Recent More

Audio Video Share Participants More

2:29
On
594-042-7551
Leave

81% 12:29

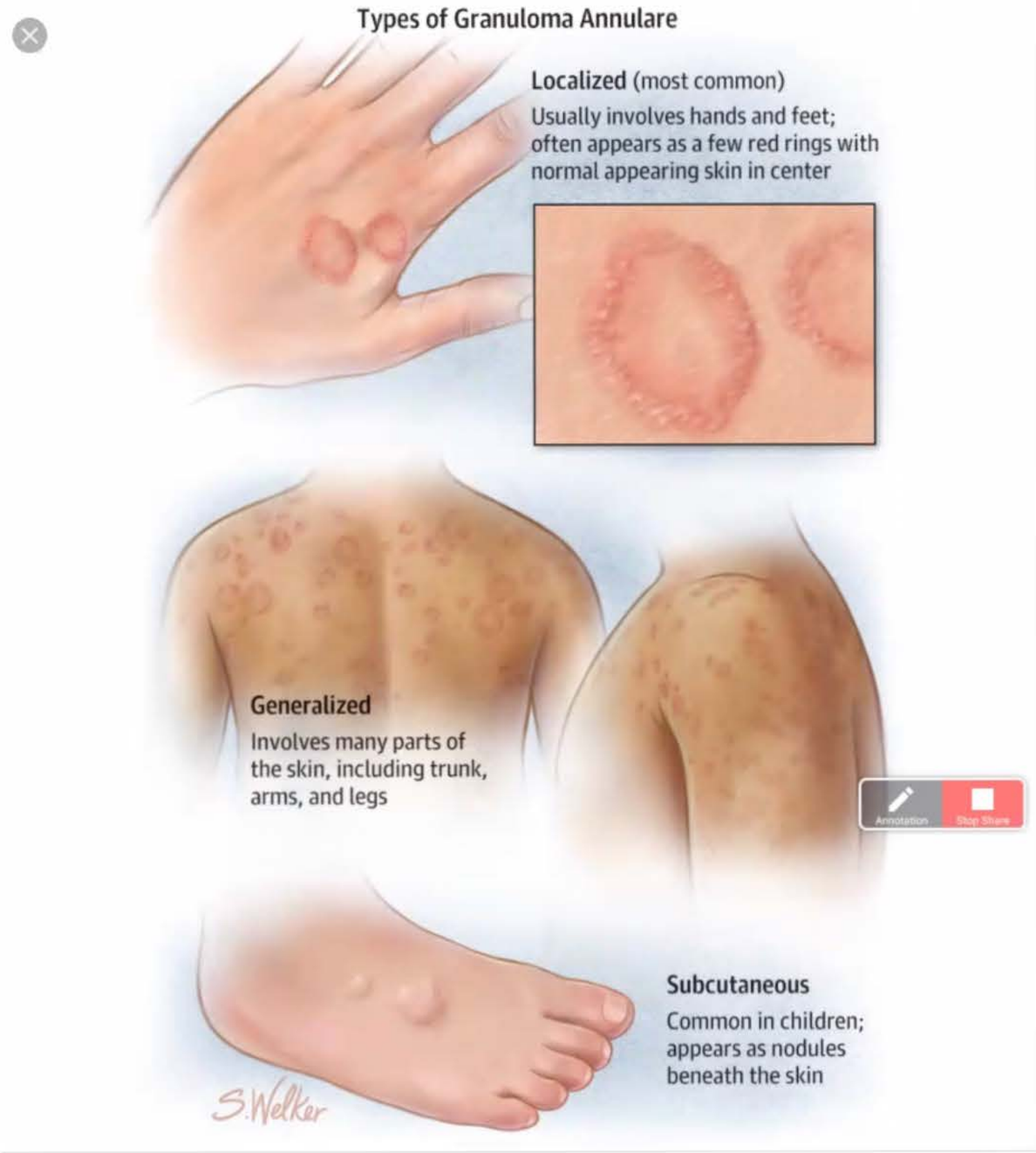

JAMA Network
Granuloma Annulare. | Allergy and Clinical Immunology | JAMA ...
Discover
Updates
Search
Recent
More
Audio
Video
Share
Participants
More

Calcu

Normal

A 36-year-old woman presents with widespread pruritus and scaling skin changes all over her body. She tells you they have been there since childhood.

There is a widespread skin rash, part of which is shown in the picture.

Which of the following is the most likely diagnosis?

A	Atopic eczema
B	Psoriasis vulgaris
C	Ichthyosis vulgaris
D	Seborrhoeic dermatitis
E	Systemic sclerosis

2:31
On
594-042-7551
Leave

Explanation

C Ichthyosis vulgaris

Ichthyosis vulgaris is an inherited, autosomal dominant, causing widespread, scaly skin. It is caused by a mutation in the gene encoding profilaggrin (a protein which is converted into filaggrin, and has a vital role in skin structure) and is one of the most common genetic disorders caused by a single gene.

A Atopic eczema

Atopic eczema is associated with areas of erythema, particularly on flexural skin surfaces, rather than the picture of skin scaling seen here.

B Psoriasis vulgaris

Psoriasis is associated with erythematous plaques and skin scaling, primarily on extensor skin surfaces.

D Seborrhoeic dermatitis

This is particularly associated with papules and pustular inflammation, primarily affecting the scalp.

E Systemic sclerosis

Systemic sclerosis is associated with skin thickening and calcinosis affecting the fingers in particular, tightening of the skin around the mouth (xerostomia), and development of telangiectasia.

Rana Alnassor's screen
Audio Video Share Participants More

9:03

A 45-year-old man presented with a 3-month history of an exquisitely painful ulcer on his right shin. This started after an insect bite and rapidly developed into an ulcer. He has a background of inflammatory bowel disease. The other leg was entirely normal.

Which of the following is the most likely diagnosis?

A	Venous ulcer
B	Arterial ulcer
C	Neuropathic ulcer
D	Pyoderma gangrenosum
E	Leishmaniasis

D Pyoderma gangrenosum

The clues are in the history. Pyoderma gangrenosum usually starts suddenly, often at the site of a minor injury (known as the Koebner phenomenon). The skin rapidly breaks down into a very painful, purple, undermined ulcer. It can affect any part of the skin, but the lower legs are a common site. The name pyoderma (infection) gangrenosum (gangrene) is misleading as it is neither an infection nor gangrene. It is associated with a range of underlying systemic illnesses, including IBD (Crohn's/ulcerative colitis), rheumatoid arthritis, myeloid blood dyscrasias and Wegener's granulomatosis.

A Venous ulcer

Venous ulcers tend to occur as a result of chronic venous stasis, are associated with varicose eczema and are most commonly seen over the medial malleolus.

B Arterial ulcer

Arterial ulcers are most commonly seen on the lateral surface of the ankle and the toes, rather than the position seen over the shin.

C Neuropathic ulcer

Neuropathic ulcers are seen over points of pressure that may not be detected due to abnormal sensation, such as on the soles of the feet.

E Leishmaniasis

A Venous ulcer

Venous ulcers tend to occur as a result of chronic venous stasis, are associated with varicose eczema and are most commonly seen over the medial malleolus.

B Arterial ulcer

Arterial ulcers are most commonly seen on the lateral surface of the ankle and the toes, rather than the position seen over the shin.

C Neuropathic ulcer

Neuropathic ulcers are seen over points of pressure that may not be detected due to abnormal sensation, such as on the soles of the feet.

E Leishmaniasis

There is no history of potential exposure to leishmaniasis, but ulcers are potentially seen on the shins because these are areas accessible to sand flies.

39068

Rate this question:

Next Question

Previous Q... Tag Questi... Feedback End Session

Blog About Pastest Contact Us Help

A 19-year-old woman presents with a rash over her left buttock, which has been present for about 2 months. She finds it terribly itchy and it has been increasing in size recently.

She has just returned from a gap year travelling around the USA. She has a history of atopic eczema as a child. She feels well in herself otherwise.

She is a non-smoker and drinks alcohol socially. She takes no regular medications and has no allergies.

What is the best treatment option in the first instance?

A	Moderately potent topical steroids
B	Dithranol ointment
C	Terbinafine cream
D	Oral doxycycline
E	Oral itraconazole

Explanation

C Terbinafine cream

This lady has tinea corporis. This is due to dermatophyte fungi of the *Microsporum*, *Trichophyton* or *Epidermophyton* species. It typically presents with a unilateral annular plaque. The border is scaly with occasional small pustules. Pruritus can range from minimal to severe. Skin scrapings should be taken to allow mycological confirmation of the diagnosis before starting treatment. Fungicidal drugs such as terbinafine or imidazoles (e.g. ketoconazole, itraconazole) are effective. For localised disease as seen here, topical treatment is preferred due to a lower risk of adverse effects. Oral treatment is usually reserved for widespread, complicated or resistant cases.

A Moderately potent topical steroids

Fungal infection may worsen on application of topical corticosteroids due to their locally immunosuppressive effects. The classical appearance may also be lost, leading to so-called 'tinea incognito'. This can make the diagnosis more difficult and further delay appropriate treatment.

B Dithranol ointment

This is an antimitotic agent used in the treatment of psoriasis. This condition is usually symmetrical and rarely presents with a solitary plaque. Its scaling is much coarser and an annular configuration is not usually observed.

D Oral doxycycline

This antibiotic can be used for acne, rosacea and bacterial skin infections. However, the features in the photograph suggest none of these diagnoses.

9:09
594-042-7551
Leave

A 27-year-old woman presents with a thickened erythema over the right shoulder. She has noticed the skin becoming darker. New areas have also appeared on the trunk and right thigh. The skin has become thicker in these areas, too. Six weeks earlier, she was admitted to hospital following an accident on her boyfriend's motorcycle.

She is otherwise fit and well. She takes antacids occasionally, which she buys over the counter. She is a non-smoker and drinks approximately 20 units a week.

On examination, the temperature is 36.8 °C; blood pressure is 120/85 mmHg; pulse 70 bpm. Respiratory, cardiovascular, abdominal and neurological examinations are unremarkable.

What is the most likely diagnosis?

A	Diffuse systemic sclerosis
B	Morphoea
C	Limited systemic sclerosis
D	Eosinophilic fasciitis
E	Shoulder-hand syndrome

Submit

Previous Q...
Skip Questi...
Audio
Video
Share
Participants
More

A 27-year-old woman presents with a thickened erythema over the right shoulder. She has noticed the skin becoming darker. New areas have also appeared on the trunk and right thigh. The skin has become thicker in these areas, too. Six weeks earlier, she was admitted to hospital following an accident on her boyfriend's motorcycle.

She is otherwise fit and well. She takes antacids occasionally, which she buys over the counter. She is a non-smoker and drinks approximately 20 units a week.

On examination, the temperature is 36.8 °C; blood pressure is 120/85 mmHg; pulse 70 bpm. Respiratory, cardiovascular, abdominal and neurological examinations are unremarkable.

What is the most likely diagnosis?

Your answer was incorrect

A	Diffuse systemic sclerosis
B	Morphoea
C	Limited systemic sclerosis
D	Eosinophilic fasciitis
E	Shoulder-hand syndrome

Explanation

B Morphoea

B Morphoea

Morphoea, or localised scleroderma, usually presents as a plaque of indurated mauve skin which later becomes waxy and either pale or hyperpigmented, with absent hair and sweating. Young adults aged 20-40 years are affected commonly. The cause is unknown but may be provoked by trauma or infection. Extensive morphoea may mimic systemic sclerosis, but differs in the absence of systemic disease, Raynaud's phenomenon and hand lesions. Autoantibodies are usually negative. Plaque morphoea may improve spontaneously, but local steroids, topical and oral vitamin D analogues and light therapy can be used.

C Limited systemic sclerosis

Limited systemic sclerosis was formerly known as CREST syndrome (Calcinosis, Raynaud's disease, (o)Esophageal dysmotility, Sclerodactyly, Telangiectasia). This patient has symptoms of skin involvement only.

A Diffuse systemic sclerosis

The absence of significant gastro-oesophageal reflux disease, hand signs, hypertension, renal impairment and any significant shortness of breath indicating pulmonary fibrosis, counts against diffuse systemic sclerosis.

D Eosinophilic fasciitis

Eosinophilic fasciitis is characterised by peripheral blood eosinophilia and fibrosis, although skin changes typical of those in systemic sclerosis are not seen.

E Shoulder-hand syndrome

This is also known as reflex sympathetic dystrophy, where

A 52 year old man presents to the dermatology clinic for review. He has trialed methotrexate and acitretin for his psoriasis and failed to gain adequate benefit from phototherapy. You plan a trial of ustekinumab.

What is the mode of action of Ustekinumab?

A	Anti IL12 and anti IL23 monoclonal antibody
B	Anti-TNF monoclonal antibody
C	Anti-CD20 monoclonal antibody
D	Anti-VEGF monoclonal antibody
E	Anti-IgE monoclonal antibody

39034

Submit

A Anti IL12 and anti IL23 monoclonal antibody

Ustekinumab is a fully human IgG1κ monoclonal antibody that binds with specificity to the shared p40 protein subunit of human cytokines interleukin (IL)-12 and IL-23. It inhibits the bioactivity of human IL-12 and IL-23 by preventing p40 from binding to the IL-12Rβ1 receptor protein expressed on the surface of immune cells.

B Anti-TNF monoclonal antibody

A range of monoclonal antibodies inhibit the TNF-alpha pathway; examples include infliximab and adalimumab. These are also used in the management of psoriasis.

C Anti-CD20 monoclonal antibody

Rituximab is an example of an anti-CD20 monoclonal antibody used in the treatment of a range of inflammatory diseases and haematological malignancies.

D Anti-VEGF monoclonal antibody

Bevacizumab is an example of an anti-VEGF monoclonal antibody, used in the treatment of colon cancer.

E Anti-IgE monoclonal antibody

Omalizumab binds to IgE and prevents binding of IgE to FcεRI (high-affinity IgE receptor) on basophils and mast cells, thereby reducing the amount of free IgE that is available to trigger the allergic cascade. Omalizumab is used in asthma and severe eczema which is resistant to other interventions.

9:18

A 45-year-old office worker presents with a sudden onset of itchy, raised lesions all over her body affecting her arms, legs and face for the last 3 weeks. It was partially relieved by desloratidine (antihistamine). Her GP prescribed 30 mg prednisolone for 3 days, which has afforded little benefit.

Routine blood tests checked by the GP are unremarkable apart from a slight increase in her eosinophil count. You make a diagnosis of urticaria.

What is your next management option?

A	Refer for skin-prick testing
B	Refer for RAST testing
C	Increase prednisolone to 60 mg for 6 days
D	Switch desloratidine to cetirizine
E	Screen for anti-TTG antibodies

Submit

Previous Q... Skip Questi...

© Pastest 2019

Rana Alnasser's screen

D Switch desloratidine to cetirizine

Blood testing including allergy screening is not routinely recommended in the management of urticaria, which may occur as part of an allergic or non-allergic process. Most patients find that antihistamines, at a regular dose, give some relief. Cetirizine may have greater pharmacodynamic effect in certain individuals than desloratidine.

C Increase prednisolone to 60 mg for 6 days

The benefit risk of using high-dose steroids in the treatment of urticaria is not positive because of a slow and limited response in terms of the rash, and side effects of therapy.

A Refer for skin-prick testing

Studies suggest that the prevalence of positive skin prick tests in patients with urticaria is high, but there is little link to avoidance of triggers or exposure to them and response in terms of resolution or worsening of the skin rash.

B Refer for RAST testing

RAST testing is an antibody-based test conducted using a blood sample where a specific allergen is either known or strongly suspected. This isn't the case in idiopathic urticaria.

E Screen for anti-TTG antibodies

The rash of dermatitis herpetiformis, associated with gluten intolerance, is a blistering rash rather than the wheal and flair-type reaction seen here.

Rate this question:

Rana Alnasser's screen

9:20

A 52-year-old woman presents with an asymptomatic rash which has been progressing over several months, primarily as a rash surrounding the face, but also as a reddish-blue, patchy rash over sun-exposed areas of the arms and shoulders. It is not itchy and causes no pain.

She has a past medical history of hypertension, previous coronary artery bypass graft, type 2 diabetes and depression. She currently takes ramipril, atorvastatin, aspirin, lansoprazole, amlodipine, bisoprolol and metformin.

On further questioning, she also describes increased difficulty in lifting objects and raising her arms.

A photograph of her left eye is shown below.

Blood tests are requested.

What treatment should be offered after the tests are done and reviewed?

A Flucloxacillin

B Topical corticosteroids

C Oral corticosteroids

D Topical antifungals

Rana Alnasser's screen

shoulders. It is not itchy and causes no pain.

She has a past medical history of hypertension, previous coronary artery bypass graft, type 2 diabetes and depression. She currently takes ramipril, atorvastatin, aspirin, lansoprazole, amlodipine, bisoprolol and metformin.

On further questioning, she also describes increased difficulty in lifting objects and raising her arms.

A photograph of her left eye is shown below.

Blood tests are requested.

What treatment should be offered after the tests are done and reviewed?

A	Flucloxacillin
B	Topical corticosteroids
C	Oral corticosteroids
D	Topical antifungals
E	Calcium channel blocker

C Oral corticosteroids

This patient has a heliotrope rash visible in the picture. A heliotrope rash is an erythematous and violaceous rash on the upper eyelids pathognomonic for dermatomyositis. The presence of a rash over the sun-exposed areas, typically described as a shawl rash because of its distribution, with features of muscle involvement, is supportive of a diagnosis of dermatomyositis. This is inflammation of voluntary muscles in association with a rash which can be painful, itchy or asymptomatic. It is a connective tissue disease which can be due to genetic predisposition, or can be triggered by toxins, drugs or infections. It can also be associated with an underlying malignancy, especially in the elderly. Treatment is with high-dose oral steroids, with further maintenance options possible.

A Flucloxacillin

Flucloxacillin would be an appropriate treatment for cellulitis in conjunction with additional antibiotics. The symmetrical distribution of this violaceous rash is unlikely to be cellulitis.

B Topical corticosteroids

Topical steroids are unlikely to have any effect on this as there is evidence of both dermal and muscular involvement. This would be far more appropriate for purely inflammatory conditions such as eczema.

D Topical antifungals

This rash and distribution of rash is unlikely to be due to a fungal infection. Fungal rashes commonly have a progressive edge which is well defined, are erythematous, and can cause changes in pigmentation. Fungal infections

muscles in association with a rash which can be painful, itchy or asymptomatic. It is a connective tissue disease which can be due to genetic predisposition, or can be triggered by toxins, drugs or infections. It can also be associated with an underlying malignancy, especially in the elderly. Treatment is with high-dose oral steroids, with further maintenance options possible.

A Flucloxacillin

Flucloxacillin would be an appropriate treatment for cellulitis in conjunction with additional antibiotics. The symmetrical distribution of this violaceous rash is unlikely to be cellulitis.

B Topical corticosteroids

Topical steroids are unlikely to have any effect on this as there is evidence of both dermal and muscular involvement. This would be far more appropriate for purely inflammatory conditions such as eczema.

D Topical antifungals

This rash and distribution of rash is unlikely to be due to a fungal infection. Fungal rashes commonly have a progressive edge which is well defined, are erythematous, and can cause changes in pigmentation. Fungal infections also do not cause muscle involvement.

E Calcium channel blocker

Calcium channel blockers can be used in Raynaud's phenomenon where they improve peripheral circulation and help prevent episodes. However, this is a characteristic colour change of blue, white and red in fingers.

A 35-year-old man presents to Dermatology Clinic. He has a history of hypothyroidism and is currently taking levothyroxine.

He complains of sudden hair thinning, having occurred over several days.

A photograph of his hair is shown below.

What is the most appropriate management plan in the first instance?

A	Systemic corticosteroids
B	Phototherapy
C	Methotrexate
D	Flucloxacillin
E	Monitor for return of hair growth

Submit

A 35-year-old man presents to Dermatology Clinic. He has a history of hypothyroidism and is currently taking levothyroxine.

He complains of sudden hair thinning, having occurred over several days.

A photograph of his hair is shown below.

What is the most appropriate management plan in the first instance?

Your answer was correct

A Systemic corticosteroids

B Phototherapy

C Methotrexate

D Flucloxacillin

E Monitor for return of hair growth

Explanation

E Monitor for return of hair growth

This patient has alopecia areata. This is the appearance of round bald patches, mostly on the scalp as seen in the photograph. It normally presents before the age of 40 and is sometimes familial. It is more common in people with thyroid disease, vitiligo and atopic eczema. It is an autoimmune disorder which can be triggered by viral infection, trauma, hormonal change or emotional stressors.

Prognosis is usually good with spontaneous regrowth of hair, in around half of patients, which may take months. Treatment can be with topical steroids, dithranol or intralesional injections of triamcinolone acetonide, but mostly management is to watch, as such treatments are normally unnecessary.

A Systemic corticosteroids

In alopecia areata, systemic intravenous (IV) steroids can cause a return of hair growth, but hair may fall out again when steroid treatment stops. Most physicians consider the side-effects of systemic corticosteroid treatment to outweigh the benefits of less drastic options.

B Phototherapy

Phototherapy is not indicated in hair loss due to alopecia areata. Had there been hair loss due to psoriasis, this would have been a more appropriate option.

C Methotrexate

Methotrexate shows no benefit in alopecia areata but would be a useful systemic treatment in psoriasis.

D Flucloxacillin

9:26

An 18-year-old man has multiple salmon-coloured papules on the face, particularly concentrated in the nasolabial fold. On his trunk, there are also several hypopigmented macules that can be visualised with an ultraviolet (UV) lamp. He thinks that these have been present since birth, as he remembers doctors looking at them when he was a child.

Which of the following medications is he likely to be taking as a consequence of the disorder that underlies his skin complaint?

A Minocycline

B Hydroxychloroquine

C Carbamazepine

D Penicillamine

E Amiodarone

Submit

Previous Q... Skip Questi...

Rana Alnasser's screen

9:28

An 18-year-old man has multiple salmon-coloured papules on the face, particularly concentrated in the nasolabial fold. On his trunk, there are also several hypopigmented macules that can be visualised with an ultraviolet (UV) lamp. He thinks that these have been present since birth, as he remembers doctors looking at them when he was a child.

Which of the following medications is he likely to be taking as a consequence of the disorder that underlies his skin complaint?

Your answer was correct

A	Minocycline
B	Hydroxychloroquine
C	Carbamazepine
D	Penicillamine
E	Amiodarone

Explanation

C Carbamazepine

This patient has tuberous sclerosis with adenomata sebaceum. These are angiofibromata usually affecting the malar area and nasolabial folds. The hypopigmented areas are ash-leaf macules, seen easily with a Wood's lamp. Other features of tuberous sclerosis include shagreen patches (flesh-coloured, leathery patches) and periungual fibromata, seen in approximately 40% of patients. The

Rana Alnasser's screen

C Carbamazepine

This patient has tuberous sclerosis with adenomata sebaceum. These are angiofibromata usually affecting the malar area and nasolabial folds. The hypopigmented areas are ash-leaf macules, seen easily with a Wood's lamp. Other features of tuberous sclerosis include shagreen patches (flesh-coloured, leathery patches) and periungual fibromata, seen in approximately 40% of patients. The condition is associated with epilepsy (hence carbamazepine) and mild or severe cognitive impairment (although one-third of patients have normal intelligence).

A Minocycline

Minocycline is used in the treatment of susceptible infections and acne, as well as some auto-inflammatory conditions.

B Hydroxychloroquine

Hydroxychloroquine is used against systemic lupus erythematosus (SLE), rheumatoid arthritis and a number of photo-aggravated skin disorders.

D Penicillamine

This is primarily used in the management of Wilson's disease.

E Amiodarone

Amiodarone is an antiarrhythmic that may cause blue-grey pigmentation in sun-exposed areas.

Rate this question:

9:29
594-042-7551
Leave

Merck Manual

Image: Adenoma Sebaceum in Tuberous Sclerosis Complex

Adenoma Sebaceum in Tuberous Sclerosis Complex. Adenoma Sebaceum

Images may be subject to copyright. Learn more

RELATED IMAGES

Tuberose (tuberous) sclerosis: Pringle's Dise...
webeye.ophth.uiowa.edu

www.lineaysalud.com/wp-content/uploads/...
lineaysalud.com

1. a.
tsallia

Discover
Updates
Search
Recen
Audio
Video
Share
Participants
More

9:29

62% 19:29

sebaceum tuberous sclerosis

ALL IMAGES NEWS VIDEOS SHOPPING MAPS BOOKS FLIGHTS TABLET

Latest GIF HD Product

skin dermatology adenoma sclerosis complex sclerosis adenoma sebaceous adenoma

Tuberous Sclerosis (Adenoma Sebaceum ...
medicinenet.com

Pringle's Disease (adenoma sebaceum) in ...
webeye.ophth.uiowa.edu

Pringle's Disease (adenoma sebaceum) in ...
webeye.ophth.uiowa.edu

Picture of Adenoma Sebaceum of the Nose ...
ghorayeb.com

Tuberose (tuberous) sclerosis: Pringle ...
webeye.ophth.uiowa.edu

Tuberous Sclerosis Complex ...
merckmanuals.com

57 Best Tuberous Sclerosis images ...
pinterest.com

Tuberous sclerosis - Wikipedia
en.wikipedia.org

Collections

Discover Updates Search Recent More

Rana Alnasser's screen

MedicineNet

Tuberous Sclerosis (Adenoma Sebaceum) Picture Image on MedicineNet.com

Picture of Tuberous Sclerosis (Adenoma Sebaceum)

Images may be subject to copyright. Learn more

RELATED IMAGES

This Antibacterial Agent In Soap Could Be C...
medicaldaily.com

Beautiful Makeup Ideas with Acne Scars wit...
mamiskincare.net

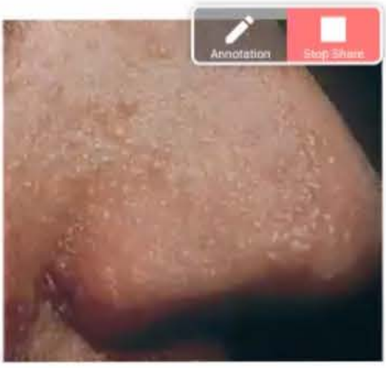

Rana Alnasser's screen

9:29

594-042-7551 Leave

62% 19:29

subungual fibroma tuberous sclerosis

ALL IMAGES NEWS VIDEOS SHOPPING MAPS BOOKS FLIGHTS TABLET

Latest GIF HD Product

periungual fibroma | shagreen patch | ungual | toe | symptom | skin | tubular | koenen's

Showing results for subungual *fibroma* tuberous sclerosis
Search instead for subungual *fibromata* tuberous sclerosis

Subungual Fibromas ...
jamanetwork.com

Chapter 140. Tuberous Sclerosis Complex ...
accessmedicine.mhmedical.com

Cutaneous manifestations of tuberous ...
adc.bmj.com

Tuberous sclerosis | DermNet NZ
dermnetnz.org

Annotation Stop Share

Tuberous sclerosis | DermNet NZ
dermnetnz.org

Our Dermatology Online journal
odermatol.com

Chapter 140. Tuberous Sclerosis Complex ...
accessmedicine.mhmedical.com

Collections

Discover Updates Search Recent More

Audio Video Share Participants More

9:29
594-042-7551
Leave
62% 19:29

Annotation
Stop Share

Our Dermatology Online

2014.2-13.Tuberous | Our Dermatology Online journal

Tuberous | Our Dermatology Online journal

Images may be subject to copyright. Learn more

RELATED IMAGES

(PDF) Tuberous Sclerosis Complex in a Family

Figure 2 from Neurocutaneous Disorders in ...
semanticscholar.org

Neurocutaneous Disorders in Children | Artic...
pedsinreview.aappublications.org

Discover
Updates
Search
Recent
More

Audio
Video
Share
Participants
More

biopsy is taken.

What is the most likely histology for this lesion on her shin?

A	Granuloma with prominent epithelioid cells with sparse lymphocytic infiltrate at the margins.
B	Necrotising granuloma with few immune cells and evidence of haemorrhage
C	Necrotic granulomas with a cuff of lymphocytes
D	Necrobiotic granuloma (altered collagen surrounded by histiocytes and some multinucleated giant cells)
E	Suppurative granuloma with central neutrophil infiltration

Rana Alnasser's screen

Explanation

A	Granuloma with prominent epithelioid cells with sparse lymphocytic infiltrate at the margins.

This is typical of sarcoid granuloma, the most likely diagnosis.

C	Necrotic granulomas with a cuff of lymphocytes

This is typical of the picture seen in tuberculoid granulomas, seen in TB and leprosy.

B	Necrotising granuloma with few immune cells and evidence of haemorrhage

This is the picture you would expect to see with Wegener's granulomatosis.

D	Necrobiotic granuloma (altered collagen surrounded by histiocytes and some multinucleated giant cells)

This is the picture seen in rheumatoid nodules and necrobiosis lipoidica.

E	Suppurative granuloma with central neutrophil infiltration

Suppurative granulomas with central neutrophil inflammation are associated with chronic infection due to diseases such as blastomycosis and cat scratch disease.

39098

Rate this question:

Next Question

9:33

A 78-year-old war veteran is admitted for plastic surgery for a 3 cm nodular basal cell carcinoma (BCC) on the left side of his face.

Past medical history of note includes hypertension, which is managed with amlodipine 10 mg daily and AF without demonstrable valvular disease, although he is warfarinised. He omits his warfarin for 5 days before surgery, he is given low-molecular weight heparin and his INR is 1.3.

Which of the following is the most appropriate way to manage the BCC?

A	Electrodessication and curettage
B	Excision
C	Topical 5-FU
D	Radiation therapy
E	Cryotherapy

21533

Submit

Blog About Pastest Contact Us Help
Audio Video Share Participants More

Explanation

B Excision

Excision is the most appropriate treatment for nodular, infiltrative and morpheoic BCCs. Cryotherapy, curettage and other treatment methods are second to excision for sensitive areas such as the face. Excision of BCCs is a low-risk procedure when the warfarin has been stopped some 5 days prior to surgery and he is now managed with low-molecular weight heparin. Wafarin may be recommenced at the surgeon's discretion, a few days after surgery.

C Topical 5-FU

This is used to treat small superficial BCCs rather than nodular ones. 5-FU interferes with DNA synthesis by inhibiting thymidylate synthetase. Long-term favourable cosmetic results are one of the main advantages of topical 5-FU. Topical 5-FU is usually used twice daily and is applied for up to 12 weeks.

Reference: Gross K, Kircik L, Kricorian G. 5% 5-Fluorouracil cream for the treatment of small superficial basal cell carcinoma: efficacy, tolerability, cosmetic outcome, and patient satisfaction. *Dermatologic Surgery*. 2007 Apr 1;33(4):433-440.

A Electrodessication and curettage

This is a fast and easily performed treatment for BCCs, but the procedure does not allow histological confirmation, is highly operator dependent and requires considerable experience to achieve low recurrence rates. This is most appropriate for low-risk superficial or nodular BCCs on the trunk or extremities.

Reference: Blixt E, Nelsen D, Strathan E. Recurrence rates of aggressive histologic types of basal cell carcinoma after

incomplete excision, recurrent BCC, nodular BCC of the head and neck (<2 cm) and BCC with invasion of bone/cartilage. It is used if surgery is not suitable, but this gentleman's warfarin has been stopped and his INR is 1.3 (and he has omitted warfarin for 5 days).

E	Cryotherapy

Cryosurgery is cost effective and requires minimal anaesthesia, but the procedure is contraindicated in patients with lesions with features associated with a high risk for recurrence, those who are concerned about a poor cosmetic outcome (as it can lead to permanent hypopigmentation and scarring), and those with a physiologic intolerance to cold. Furthermore, recurrence rates for primary BCCs range from 4-17%.

Cryotherapy, curettage and other treatment methods are second to excision on sensitive areas such as the face. Excision of BCC is a low risk procedure when the warfarin has been stopped some 5 days prior to surgery and he is now managed with low molecular weight heparin. Wafarin may be recommenced at the surgeon's discretion, a few days after surgery.

Rate this question:

© Pastest 2019

A 17-year-old boy presents with a spreading rash affecting his lower face.

He feels unwell and his mother tells you that he has been irritable over the last few days, with reduced appetite. He has no previous history of skin disease. He takes no regular medications.

On examination, he has crusting lesions over his chin and left cheek. There is no oral involvement. General examination reveals no abnormalities.

What is the most likely microbial cause?

A	*Haemophilus influenzae*
B	Herpes simplex
C	*Pseudomonas aeruginosa*
D	*Staphylococcus aureus*
E	Viridans streptococci

He feels unwell and his mother tells you that he has been irritable over the last few days, with reduced appetite. He has no previous history of skin disease. He takes no regular medications.

On examination, he has crusting lesions over his chin and left cheek. There is no oral involvement. General examination reveals no abnormalities.

What is the most likely microbial cause?

Your answer was correct

A	*Haemophilus influenzae*
B	Herpes simplex
C	*Pseudomonas aeruginosa*
D	*Staphylococcus aureus*
E	Viridans streptococci

Explanation

D	*Staphylococcus aureus*

The diagnosis here is impetigo, a superficial infection of the

D *Staphylococcus aureus*

The diagnosis here is impetigo, a superficial infection of the epidermis due to *Staphylococcus aureus*, group A beta-haemolytic streptococcus or a mixture of both. Children are mainly affected. It is very contagious. Typically it starts as macules, vesicles or pustules. These evolve into superficial erosions which then form honey-coloured crusts. The bullous variant presents with flaccid bullae and erosions. Alongside cleansing the affected areas and removing the crusts, topical antibiotics (eg fusidic acid or mupirocin) may be sufficient for localised disease, whereas systemic treatment is generally used for more widespread involvement. This should cover both staphylococci and streptococci, so flucloxacillin or a macrolide would be appropriate.

A *Haemophilus influenzae*

This does not produce impetigo, though sometimes causes cellulitis in babies, particularly affecting the head and neck.

B Herpes simplex

The somewhat punctate crusts in this example of impetigo might be mistaken for eczema herpeticum. There is, however, no history of eczema.

C *Pseudomonas aeruginosa*

P aeruginosa is a common coloniser of ulcers, but is not associated with impetigo.

E Viridans streptococci

This includes several species of commensal bacteria mostly

9:40

MyPastest
https://mypastest.pastest.com

Pastest+

A 35-year-old man presented with red plaques on his legs. His GP had prescribed betamethasone and calcipotriol ointment. He has no past medical history of note apart from two episodes of previous depression, but admits to drinking 10 pints of beer per week and smokes 10 cigarettes per day. The topical treatment gave limited benefit. He is willing to take systemic therapy, but doesn't want to use oral corticosteroids.

Examination reveals the lesions shown below, nail changes on both hands and painful DIP joints.

Which of the following is the most appropriate intervention?

A Methotrexate

B Acitretin

C Adalimumab

D Dithranol

ointment. He has no past medical history of note apart from two episodes of previous depression, but admits to drinking 10 pints of beer per week and smokes 10 cigarettes per day. The topical treatment gave limited benefit. He is willing to take systemic therapy, but doesn't want to use oral corticosteroids.

Examination reveals the lesions shown below, nail changes on both hands and painful DIP joints.

Which of the following is the most appropriate intervention?

A	Methotrexate
B	Acitretin
C	Adalimumab
D	Dithranol
E	Infliximab

A Methotrexate

This gentleman has chronic plaque psoriasis, and has partially responded to topical steroid and vitamin D analogue treatment. With extensive changes including early possible psoriatic arthritis, methotrexate is the most appropriate next step.

B Acitretin

Acitretin is an appropriate intervention for psoriasis but is potentially not the optimal choice here given the signs of psoriatic arthritis.

C Adalimumab

Adalimumab is a biological option where patients fail to respond adequately to methotrexate.

D Dithranol

Topical dithranol is an option for the lesions on the lower limbs, but won't impact on the early features of psoriatic arthritis in the hands.

E Infliximab

Like adalimumab, infliximab is a biological option for patients who fail to respond to methotrexate or other traditional DMARDs.

38523

Rate this question:

9:42

A 45-year-old man presented with a 3 month history of an exquisitely painful ulcer on his right shin. This started after an insect bite and rapidly developed into an ulcer. He has a background of inflammatory bowel disease. The other leg was entirely normal.

Which inflammatory cells are most likely to be seen in the ulcer on histological analysis?

A Neutrophils

B Lymphocytes

C Eosinophils

D Red blood cells

E Basophils

Rana Alnasser's screen

A Neutrophils

The diagnosis is pyoderma gangrenosum, which is a neutrophilic dermatosis. Pyoderma gangrenosum is a type of 'neutrophilic dermatosis'. These are conditions characterised by dense infiltrate of neutrophils in the affected tissue. They often arise as a reaction to an underlying systemic illness. They may arise at the site of injury, e.g. insect bite or needle prick. Other examples of neutrophilic dermatoses include Sweet syndrome, neutrophilic eccrine hidradenitis and erythema elevatum diutinum. Pyoderma gangrenosum is seen with increasing frequency in patients with inflammatory bowel disease.

B Lymphocytes

Lymphocytic infiltration occurs in a number of other inflammatory dermatoses, including psoriasis and atopic dermatitis.

C Eosinophils

Eosinophils are seen across a range of inflammatory skin diseases, including allergic drug eruptions, urticaria, allergic contact dermatitis, atopic dermatitis and eczema.

D Red blood cells

Haematoma formation with bleeding isn't a primary feature of pyoderma gangrenosum, and red cells are unlikely to be a prominent feature of a biopsy taken from round the edge of a lesion.

E Basophils

Basophils are not a prominent feature of biopsy in

9:45
On 594-042-7551 Leave

A 56-year-old man is referred with a recent history of weight loss and worsening constipation.

Clinical examination is unremarkable, other than a rash in his axillae, and blood investigations which reveal a mild anaemia.

Which one of the following test results is likely to be encountered?

A	Raised T3/T4 and low TSH
B	Positive direct immunofluorescence
C	Low Vitamin D levels
D	Raised levels of carcinoembryonic antigen (CEA)
E	Positive patch testing to common antiperspirant agents

Submit

Audio Video Share Participants More

9:46

D Raised levels of carcinoembryonic antigen (CEA)

Acanthosis nigricans is linked with obesity and various endocrine disorders associated with insulin resistance such as diabetes, acromegaly and Cushing's syndrome. More rarely it is a paraneoplastic manifestation particularly of the gastrointestinal tract. The CEA test measures the amount of this protein in the serum and is often raised in people with certain kinds of cancers, especially cancer of the large intestine (colon and rectum).

A Raised T3/T4 and low TSH

Acanthosis nigricans is a diffuse velvety thickening and hyperpigmentation of the skin. It occurs mainly in the axillae and other intertriginous areas. It is linked to various endocrine disorders including hypothyroidism, but not hyperthyroidism.

B Positive direct immunofluorescence

Direct immunofluorescence is a technique that involves the application of fluorescent antibodies to samples of patient tissue obtained from biopsies, and is used in dermatological practice in order to confirm the diagnosis of suspected autoimmune bullous diseases, connective tissue diseases and vasculitides.

C Low Vitamin D levels

Acanthosis nigricans is not linked to vitamin D deficiency.

E Positive patch testing to common antiperspirant agents

Patch testing is used to help confirm the presence of contact allergic reactions. These typically cause itchy

Rana Alnasser's screen

9:46

A 45-year-old man with severe psoriasis which is refractory to treatment with topical steroids is commenced on ciclosporin therapy. He attends the Emergency Department with a lower respiratory tract infection.

Which of the following antibiotics should be avoided with respect to his treatment?

A	Cephalexin
B	Ciprofloxacin
C	Clarithromycin
D	Co-amoxiclav
E	Doxycycline

Submit

Previous Q... Skip Questi...

© Pastest 2019

Rana Alnasser's screen

9:47

A 45-year-old man with severe psoriasis which is refractory to treatment with topical steroids is commenced on ciclosporin therapy. He attends the Emergency Department with a lower respiratory tract infection.

Which of the following antibiotics should be avoided with respect to his treatment?

Your answer was correct

A Cephalexin

B Ciprofloxacin

C Clarithromycin

D Co-amoxiclav

E Doxycycline

Explanation

C Clarithromycin

Macrolide antibiotics can significantly increase ciclosporin concentration and may drive nephrotoxicity in some cases because of inhibition of CYP3A4. Erythromycin can increase ciclosporin exposure 4- to 7-fold, sometimes resulting in nephrotoxicity. Clarithromycin has been reported to double the exposure of ciclosporin. Azitromycin increases ciclosporin levels by around 20%.

A Cephalexin

Rana Alnasser's screen

9:47

Explanation

Neoral S
medicine

C Clarithromycin

Macrolide antibiotics can significantly increase ciclosporin concentration and may drive nephrotoxicity in some cases because of inhibition of CYP3A4. Erythromycin can increase ciclosporin exposure 4- to 7-fold, sometimes resulting in nephrotoxicity. Clarithromycin has been reported to double the exposure of ciclosporin. Azitromycin increases ciclosporin levels by around 20%.

A Cephalexin

Cephalexin is renally excreted and has no interaction with the CYP3A4 enzyme system.

B Ciprofloxacin

Ciprofloxacin is a weak inhibitor of CYP-1A2, which doesn't interfere with ciclosporin metabolism.

D Co-amoxiclav

Co-amoxiclav is a penicillin and is therefore not metabolised via the P450 system.

E Doxycycline

Doxycycline is excreted primarily in bile but does not interfere with drugs metabolised by the CYP 3A4 enzyme system.

Rate this question:

Next Question

Rana Alnasser's screen

9:48

A 29-year-old woman presents to the Dermatology Clinic for review. She complains of persistent problems with cracking of the skin at the corners of her mouth. She follows a vegan diet.

The cracking at the corners of her mouth is shown below.

Which of the following is the most likely cause of her skin changes?

A	Riboflavin
B	Vitamin A
C	Vitamin C
D	Vitamin D
E	Vitamin K

Submit

9:48

follows a vegan diet.

The cracking at the corners of her mouth is shown below.

Which of the following is the most likely cause of her skin changes?

Your answer was correct

A	Riboflavin
B	Vitamin A
C	Vitamin C
D	Vitamin D
E	Vitamin K

Explanation

A	Riboflavin

Although most vegans are aware of potential vitamin deficiencies and are careful to adequately replace animal sources of B vitamins in their diet, riboflavin deficiency is a

Rana Alnasser's screen

Explanation

A Riboflavin

Although most vegans are aware of potential vitamin deficiencies and are careful to adequately replace animal sources of B vitamins in their diet, riboflavin deficiency is a possibility and a well-recognised cause of angular stomatitis. Dietary modification with oral supplementation is the most appropriate intervention.

B Vitamin A

Vitamin A deficiency leads to impaired dark adaptation of vision and dry, scaling skin, which can lead to permanent corneal scarring (keratomalacia) and increased risk of respiratory infection.

C Vitamin C

Vitamin C deficiency results in the development of scurvy, with follicular keratosis, coiling of hair and perifollicular haemorrhages. There is also an increased risk of lower limb haemorrhage.

D Vitamin D

Vitamin D deficiency results in the development of osteomalacia, which is manifest in long bone pain and proximal muscle weakness. It is more common in individuals who follow a vegetarian diet.

E Vitamin K

Vitamin K deficiency in adults is rare, as it is ubiquitous in

A 40-year-old man presented with an asymptomatic, rash of the dorsum of his foot.

On examination, he had multiple pin-point macules and 'cayenne pepper spots'. He tells you he took part in a long-distance run a few days earlier.

What is the likely pathology?

A Lipodermatosclerosis

B Necrobiosis lipoidica

C Capillaritis

D Livedo reticularis

E Erythromelalgia

C Capillaritis

Capillaritis (otherwise known as progressive pigmented purpura, or Schamberg's disease) can arise due to exercise, for no known cause, and due to venous insufficiency. It is asymptomatic and has no systemic associations. In this case itis likely to be due to the long-distance run and will resolve over a few days.

A Lipodermatosclerosis

Lipodermatosclerosis is painful indurated erythema and occurs in people with chronic venous insufficiency.

B Necrobiosis lipoidica

Necrobiosis lipoidica consist of well-defined yellow plaques with telangiectasia, atrophic or ulcerated centre and a raised erythematous rim, associated with insulin dependent diabetes.

D Livedo reticularis

Livedo reticularis occurs in a net-like, mottled pattern, is more marked in cold weather, and is seen on both upper and lower limbs.

E Erythromelalgia

Erythromelalgia is a painful, burning erythema associated with thrombocythaemia.

Rate this question:

Next Question

A 56-year-old woman has symmetrical, elevated dark pink lesions over both shins. The lesions have a shiny, orange peel appearance. She has lost 4 kg in weight over the past 6 months and has recently developed atrial fibrillation.

Which of the following is most likely to be found on hand examination?

A	Nail pitting
B	Koilonychia
C	Acropachy
D	Deforming hand arthritis
E	Leukonychia

Submit

Previous Q... Skip Questi...

© Pastest 2019

A 56-year-old woman has symmetrical, elevated dark pink lesions over both shins. The lesions have a shiny, orange peel appearance. She has lost 4 kg in weight over the past 6 months and has recently developed atrial fibrillation.

Which of the following is most likely to be found on hand examination?

Your answer was correct

A Nail pitting

B Koilonychia

C Acropachy

D Deforming hand arthritis

E Leukonychia

Explanation

C Acropachy

These lesions describe pretibial myxoedema, which occurs in 5% of patients with Graves' disease. It is almost always accompanied by exophthalmos and occasionally thyroid acropachy.

A Nail pitting

Nail pitting and onycholysis are most likely to be associated with psoriasis, although onycholysis may also be

Explanation

C Acropachy

These lesions describe pretibial myxoedema, which occurs in 5% of patients with Graves' disease. It is almost always accompanied by exophthalmos and occasionally thyroid acropachy.

A Nail pitting

Nail pitting and onycholysis are most likely to be associated with psoriasis, although onycholysis may also be seen in patients with thyroid disease.

B Koilonychia

Koilonychia is derived from the Greek, denoting spoon-shaped nails, seen as a result of iron deficiency anaemia.

D Deforming hand arthritis

Deforming hand arthritis is seen in rheumatoid disease and in psoriasis, neither of which are associated with pre-tibial myxoedema.

E Leukonychia

Leukonychia is seen in patients suffering from hypoalbuminaemia – for example, in chronic liver disease.

Rate this question:

Next Question

9:53

ResearchGate

Acropachy in a male with hyperthyroidism. | Download S

Acropachy in a male with hyperthyroidism.

Images may be subject to copyright. Learn more

RELATED IMAGES

Discover Updates Search

9:54
On
594-042-7551
Leave

MLE

JSMLE — radiologysigns: Thyroid acropachy - a rare...

roid acropachy - a rare consequence of autoimmune thyroid disease occurring in ap

to copyright. Learn more

Thyroid Status Examination - OSCE Guide ...

Audio
Updates
Video
Search
Share
Participants
1
Recent
More

9:54
On
594-042-7551
Leave

LearningRadiology

arningRadiology - Thyroid, Acropachy, foot, hand, clubbing .

more information ...

es may be subject to copyright. Learn more

ATED IMAGES

Audio
Video
Share
Participants
More

9:54
On
594-042-7551
Leave
MyPastest
https://mypastest.pastest.com

An 80-year-old woman is referred from her nursing home with increasing itch. The itch can be severe and becomes worse at night. There is no prior history of skin problems.

On examination, she has erythematous papules over her wrists and hands. She has recently been treated with amoxicillin by her general practitioner (GP) but is otherwise taking no medications.

What is the most likely diagnosis?

A	Drug reaction
B	Scabies
C	Eczema
D	Lichen planus
E	Psoriasis

Submit

Previous Q...

Skip Questi...

Audio
Video
Share
Participants
1
More

9:55
On
594-042-7551
Leave

An 80-year-old woman is referred from her nursing home with increasing itch. The itch can be severe and becomes worse at night. There is no prior history of skin problems.

On examination, she has erythematous papules over her wrists and hands. She has recently been treated with amoxicillin by her general practitioner (GP) but is otherwise taking no medications.

What is the most likely diagnosis?

Your answer was correct

A	Drug reaction
B	Scabies
C	Eczema
D	Lichen planus
E	Psoriasis

Explanation

B Scabies

The story is very typical of scabies. Scabies is generally most common in children and young adults; however, in recent years, the incidence has been increasing in the elderly in nursing and residential homes. Itch is the most common manifestation of scabies and occurs at night when the patient is warm. The characteristic lesions of scabies are burrows; however, people also develop a

Audio Video Share Participants More

9:55
On
594-042-7551
Leave

Explanation

B Scabies

The story is very typical of scabies. Scabies is generally most common in children and young adults; however, in recent years, the incidence has been increasing in the elderly in nursing and residential homes. Itch is the most common manifestation of scabies and occurs at night when the patient is warm. The characteristic lesions of scabies are burrows; however, people also develop a hypersensitivity reaction in the form of papules.

A Drug reaction

The history of a rash preceding newly started medications is against a drug reaction. There are several different types of drug eruptions, which may range from mild to life-threatening. Typical symptoms include erythema, macules and papules, blisters, wheals, itching, desquamation and sometimes pain.

C Eczema

Acutely itchy skin in otherwise fit and healthy elderly individuals is often seen due discoid eczema. However, the presentation above is not typical of that. Discoid eczema presents with scattered, round/oval patches of eczema and is often precipitated by a bacterial infection in susceptible individuals.

D Lichen planus

Lichen planus can also be very itchy and affect the wrists. Clinically, however, it is typified by small, violaceous, polygonal lesions and may coalesce. The surface may also display a fine white, net-like lattice (Wickham's striae).

Audio Video Share Participants 1 More

9:55
On
594-042-7551
Leave

A 53-year-old patient with a history of type 2 diabetes, cardiovascular disease and rosacea comes to the clinic because of a blistering skin rash on sun-exposed areas. He is not sure which of his medications may be responsible.

On examination, he has an erythematous blistering rash on his face, upper chest and both arms.

Which of the following medications is the most likely cause?

A	Amlodipine
B	Metformin
C	Oxytetracycline
D	Ramipril
E	Vildagliptin

Submit

Previous Q... Skip Questi...

© Pastest 2019

Audio Video Share Participants 1 More

9:56
On
594-042-7551
Leave

A 53-year-old patient with a history of type 2 diabetes, cardiovascular disease and rosacea comes to the clinic because of a blistering skin rash on sun-exposed areas. He is not sure which of his medications may be responsible.

On examination, he has an erythematous blistering rash on his face, upper chest and both arms.

Which of the following medications is the most likely cause?

Your answer was correct

A	Amlodipine
B	Metformin
C	Oxytetracycline
D	Ramipril
E	Vildagliptin

Explanation

C Oxytetracycline

A number of drugs are commonly implicated in photosensitive skin reactions, including:

- Antibiotics: tetracyclines, fluoroquinolones, sulphonamides
- NSAIDs

Audio
Video
Share
Participants
1
More

9:56
On
594-042-7551
Leave

C Oxytetracycline

A number of drugs are commonly implicated in photosensitive skin reactions, including:

- Antibiotics: tetracyclines, fluoroquinolones, sulphonamides
- NSAIDs
- Diuretics: e.g. furosemide, bumetanide
- Sulphonylureas
- Neuroleptics: e.g. chlorpromazine
- Antifungals: e.g. terbinafine, itraconazole
- Other drugs: e.g. amiodarone, diltiazem.

Where the causative agent cannot be discontinued, for example amiodarone, then the patient should be advised to stay out of the sun and wear an effective sun block. Topical corticosteroids are the treatment of choice for drug-induced skin reactions; systemic corticosteroids can be used in severe cases. Varying subtypes of skin reactions are seen; these include photo-allergic reactions, lichenoid reactions, lupus-like reactions and pseudo-porphyria.

A Amlodipine

Amlodipine can result in alopecia and a purpuric rash, but isn't normally associated with a photosensitive rash.

B Metformin

Erythema and urticarial rashes are very rarely reported in association with metformin therapy, and photosensitisation isn't a feature.

D Ramipril

Audio Video Share Participants More

9:56
On 594-042-7551 Leave

A Amlodipine

Amlodipine can result in alopecia and a purpuric rash, but isn't normally associated with a photosensitive rash.

B Metformin

Erythema and urticarial rashes are very rarely reported in association with metformin therapy, and photosensitisation isn't a feature.

D Ramipril

Ramipril is associated with photosensitivity, but it is listed as very rare on the datasheet (much less commonly than oxytetracycline).

E Vildagliptin

Vildagliptin has been reported in post-marketing surveillance to be associated with urticaria and bullous skin reactions, rather than photosensitivity.

Rate this question:

© Pastest 2019

Audio Video Share Participants 1 More

9:56
On
594-042-7551
Leave

A 19-year-old man attends with a 9-month history of a lesion on the head of his penis. He is very embarrassed by the appearance. He tells you that he has a skin condition affecting various other parts of his body.

The lesion does not cause severe symptoms, but can be a little sore and itchy at times.

What is the most likely diagnosis?

A	Psoriasis
B	Discoid eczema
C	Lichen planus
D	Lichen sclerosus
E	Vitiligo

Audio
Video
Share
Participants
1
More

A Psoriasis

This condition is relatively common in the genital area. It gives rise to well-defined, erythematous scaly plaques. Eczema can appear very similar, though the discoid form tends to be very itchy. In this situation, skin changes should be sought elsewhere. A mild- or moderate-potency topical corticosteroid cream would be appropriate initial treatment on the genital area.

C Lichen planus

This condition classically presents with violaceous pruritic papules.

B Discoid eczema

Whilst this also presents with well-defined, scaly plaques, it is unusual on the genital area and tends to be intensely pruritic.

D Lichen sclerosus

Urologists often refer to this condition as balanitis xerotica obliterans. It is usually confined to genital skin but almost never occurs after circumcision. It usually presents with pale, atrophic skin. Pruritus is variable; painful fissures may occur.

E Vitiligo

Whilst the penis is a common site for this condition, it manifests as asymptomatic, depigmented macules.

Rate this question:

A 50-year-old man presented to the Emergency Department with an enlarging rash over his shin, which was associated with significant swelling and discomfort. Four days earlier, he had undergone a surgical procedure to his varicose veins.

On examination, he was sweaty and anxious. He had a low-grade fever and a tachycardia of 130 bpm, with a blood pressure of 120/80 mmHg. There was an extensive brownish red discoloration over the whole shin and significant associated swelling. There was a crackly sensation when the swollen area was palpated, and a pungent discharge from an open site at the distal end of the affected area.

What is the most important treatment option?

A	Hyperbaric oxygen
B	Surgical debridement
C	Intravenous (IV) penicillin
D	Tetanus toxoid
E	IV immunoglobulin

Submit

A 50-year-old man presented to the Emergency Department with an enlarging rash over his shin, which was associated with significant swelling and discomfort. Four days earlier, he had undergone a surgical procedure to his varicose veins.

On examination, he was sweaty and anxious. He had a low-grade fever and a tachycardia of 130 bpm, with a blood pressure of 120/80 mmHg. There was an extensive brownish red discoloration over the whole shin and significant associated swelling. There was a crackly sensation when the swollen area was palpated, and a pungent discharge from an open site at the distal end of the affected area.

What is the most important treatment option?

Your answer was correct

A Hyperbaric oxygen

B Surgical debridement

C Intravenous (IV) penicillin

D Tetanus toxoid

E IV immunoglobulin

Explanation

B Surgical debridement

The answer is Surgical debridement (Option B)

B Surgical debridement

The answer is Surgical debridement (Option B).

Gas gangrene is a medical emergency. It is caused, in the vast majority of cases, by *Clostridium perfringens* infection, and the clinical presentation fits best with this diagnosis. Rapid onset of muscle necrosis, gas production and sepsis are the hallmarks of this disease. *C. perfringens* is an exotoxin-producing clostridial species (large, Gram-positive, spore-forming bacillus), which is normally found in soil and the gastrointestinal tract.

The most common clinical presentation is with post-traumatic gas gangrene, which occurs through direct inoculation of contaminated ischaemic wounds.

Spontaneous gas gangrene may be caused through the haematogenous spread of toxin-producing bacteria (often in patients who are immunocompromised or those with diabetes).

Immediate management involves resuscitation with oxygen and intravenous fluids to stabilise the patient. Surgical debridement is the definitive treatment.

A Hyperbaric oxygen

Hyperbaric oxygen (Option A) is incorrect.

This is used in multiple situations such as decompression sickness, air emboli and the healing of chronic wounds. It is also used against severe soft tissue infections, like gas gangrene and necrotising fasciitis, but its role is supportive.

C Intravenous (IV) penicillin

Intravenous (IV) penicillin (Option C) is incorrect.

Certain antibiotics (including penicillin) alone are not effective enough treatment because they cannot penetrate

gangrene and necrotising fasciitis, but its role is supportive.

C Intravenous (IV) penicillin

Intravenous (IV) penicillin (Option C) is incorrect.

Certain antibiotics (including penicillin) alone are not effective enough treatment because they cannot penetrate the affected tissues sufficiently enough to be effective.

D Tetanus toxoid

Tetanus toxoid (Option D) is incorrect.

Tetanus toxoid is a vaccine given in childhood for the prevention of tetanus. In immune patients, additional tetanus toxoid can be given in adulthood to booster immunity following high-risk injuries. In non-immunised individuals with high-risk injuries, tetanus antitoxin may also be administered.

E IV immunoglobulin

IV immunoglobulins (Option E) is incorrect.

Immunoglobulin therapy is used in a wide variety of conditions such as immune-mediated thrombocytopenia and Guillain–Barré syndrome. Some evidence is available that supports its use in severe sepsis as an add-on treatment.

Rate this question:

Next Question

Previous Q... Tag Questi... Feedback End Session

A 65-year-old lady complained of localised hair loss in the vertex of her scalp, associated with itching irritation.

What is the likely diagnosis?

A Cicatricial alopecia

B Alopecia areata

C Androgenetic alopecia

D Trichotillomania

E Telogen effluvium

40088

Submit

Previous Q... Skip Questi...

A 65-year-old lady complained of localised hair loss in the vertex of her scalp, associated with itching irritation.

What is the likely diagnosis?

Your answer was correct

A Cicatricial alopecia

B Alopecia areata

C Androgenetic alopecia

D Trichotillomania

E Telogen effluvium

Explanation

A Cicatricial alopecia

In cicatricial alopecia (also known as scarring alopecia) inflammation injures hair follicles resulting in permanent bald patches with no visible follicles. In this case the

A Cicatricial alopecia

In cicatricial alopecia (also known as scarring alopecia) inflammation injures hair follicles resulting in permanent bald patches with no visible follicles. In this case the presence of inflammation can be seen as redness, scaling and crusting. Common causes for cicatricial alopecia include discoid lupus erythematosus, and lichen planopilaris (a variant of lichen planus). Treatment is dependent on the underlying causes but often requires topical corticosteroids. Given the fact some hair follicles have been destroyed and no regeneration is possible, treatment is aimed at reducing the amount of inflammation and minimising further hair loss

B Alopecia areata

Alopecia areata (AA) is a condition characterised by recurrent non-scarring patches of hair loss that can affect any hair-bearing area of skin. In the areas affected, the skin is normal in appearance. In the periphery there may be short, broken hairs that taper at the proximal end (exclamation point hairs) — this is a pathognomonic sign but is not always present. Patients may also complain of pruritus or a burning sensation in the affected skin areas. AA can occur at any age and affects both sexes equally. The natural history of the condition is unpredictable with no correlation existing between the number of patches at onset and the subsequent severity of the disease. Precipitating factors can be found in some patients but not all patients, and include: stressful events, febrile illnesses, drugs and pregnancy.

C Androgenetic alopecia

Androgenetic alopecia (also known as pattern hair loss) does not cause erythema, scale and crusting. It occurs due to genetic factors and hormonal influences. Androgenetic

to genetic factors and hormonal influences. Androgenetic alopecia is apparent is about 50% of individual; by the age of 50 years. Typically, in men it affects the vertex and temporal scalp, whereas in women it is more diffuse and worst on the anterior scalp.

D Trichotillomania

Trichotillomania describes a psychological disorder where patients are compelled to pull their own hair, resulting in alopecia. It is typically encountered in teenage females and children, leading to irregular patches of alopecia that are not commonly associated with a scarring process unless encountered in chronic, severe forms.

E Telogen effluvium

Telogen effluvium is a diffuse, temporary, non-scarring form of alopecia where hair is lost 2-3 months following stressful events such as severe illnesses, accidents, and childbirth. Telogen effluvium is self-limiting and requires no medical interventions.

40088

Rate this question:

Next Question

Previous Q... Tag Questi... Feedback End Session

Blog About Pastest Contact Us Help

© Pastest 2019

www.sciencephoto.com

Scarring alopecia (hair loss)

Discover Updates Search Recent

10:08

NZ

anopilaris | DermNet NZ

ilaris

subject to copyright. Learn more

is - Clinical Advisor

Dr. Bloxham Discusses Lichen ...
fellermedical.com

Lichen Planopilaris Treated

er Updates Search Recent

5 days ago

DermNet NZ

Lichen planopilaris | DermNet NZ

Lichen planopilaris

Images may be subject to copyright. Learn more

Lichen Planopilaris - Clinical Advisor
clinicaladvisor.com

Dr. Bloxham Discusses Lichen ...
fellermedical.com

Lichen Planopilaris Treated With a ...

Discover Updates Search Recent More

10:09
On
594-042-7551
Leave

This 24-year-old man is distressed by his appearance. He has recently started gaining weight and being easily fatigable.

Which of the following is the most appropriate way to manage this patient?

A	Thyroid function tests (TFTs)
B	Oral griseofulvin
C	Oral antibiotics
D	Ketoconazole shampoo
E	Topical minoxidil

Submit
Audio
Video
Share
Participants
More

A Thyroid function tests (TFTs)

The answer is Thyroid function tests (TFTs) (Option A).

This is alopecia areata (AA), which is associated with other autoimmune diseases such as Hashimoto's thyroiditis (hence the importance of checking the TFTs), vitiligo and myasthenia gravis. Currently, no curative treatment is available, but the condition may spontaneously remit. Systemic and topical steroids may induce remission but do not alter the long-term outcome. Patients often find this condition very distressing, and psychological support from family, doctors and support groups is extremely important.

B Oral griseofulvin

Oral griseofulvin (Option B) is incorrect.

The differential diagnosis of annular alopecia includes tinea capitis. Treatment is with antifungals such as griseofulvin.

C Oral antibiotics

Oral antibiotics (Option C) is incorrect.

Antibiotics are not used against AA.

D Ketoconazole shampoo

Ketoconazole shampoo (Option D) is incorrect.

This is widely used against seborrhoeic dermatitis.

E Topical minoxidil

Topical minoxidil (Option E) is incorrect.

Topical minoxidil may be of limited help against male pattern baldness.

10:11

A 23-year-old nurse has an itchy, sore, erythematous rash affecting both palms and, less severely, on the dorsum of both hands. The skin shows evidence of lichenification with dry, leathery thickened areas and prominent skin markings. There is no rash elsewhere.

The rash appears to have worsened despite regular hand washing and application of emollients.

Which of the following is the most appropriate long-term intervention?

A	Oral corticosteroids
B	Referral to the occupational health department
C	Regular antihistamines
D	Patch testing
E	Topical corticosteroids

Submit

Previous Q... Skip Questi...

© Pastest 2019

Rana Alnasser's screen

A 23-year-old nurse has an itchy, sore, erythematous rash affecting both palms and, less severely, on the dorsum of both hands. The skin shows evidence of lichenification with dry, leathery thickened areas and prominent skin markings. There is no rash elsewhere.

The rash appears to have worsened despite regular hand washing and application of emollients.

Which of the following is the most appropriate long-term intervention?

Your answer was incorrect

A	Oral corticosteroids
B	Referral to the occupational health department
C	Regular antihistamines
D	Patch testing
E	Topical corticosteroids

Explanation

B Referral to the occupational health department

Irritant contact dermatitis is the most common form of occupational skin disease (up to 80%). Abrasives and cleaning agents (soaps, detergents and water-free hand cleansers as used often by medical workers) and excessive exposure to water are common causes in predisposed individuals – usually a history of atopic dermatitis. Management involves prevention (avoidance of irritant product/barrier creams, etc.) and treatment with topical corticosteroids and emollients. In this case, over the longer

B Referral to the occupational health department

Irritant contact dermatitis is the most common form of occupational skin disease (up to 80%). Abrasives and cleaning agents (soaps, detergents and water-free hand cleansers as used often by medical workers) and excessive exposure to water are common causes in predisposed individuals – usually a history of atopic dermatitis. Management involves prevention (avoidance of irritant product/barrier creams, etc.) and treatment with topical corticosteroids and emollients. In this case, over the longer term it's likely that the most appropriate intervention is use of low-irritant washing materials and gloves, which could be obtained through the occupational health service

D Patch testing

Patch testing may be performed if there is uncertainty about the allergen, but must be done in an unaffected area and at least 2 weeks after the dermatitis has subsided.

A Oral corticosteroids

Oral corticosteroids may be indicated to speed resolution of contact dermatitis, but only once any precipitant allergen has been removed.

C Regular antihistamines

Regular antihistamines will not resolve any dermatitis, but will affect the scratch–itch cycle.

E Topical corticosteroids

Topical steroids are appropriate in resolution of the rash, but aren't a long-term solution versus removal/identification of any potential trigger for the

Patch testing may be performed if there is uncertainty about the allergen, but must be done in an unaffected area and at least 2 weeks after the dermatitis has subsided.

A Oral corticosteroids

Oral corticosteroids may be indicated to speed resolution of contact dermatitis, but only once any precipitant allergen has been removed.

C Regular antihistamines

Regular antihistamines will not resolve any dermatitis, but will affect the scratch–itch cycle.

E Topical corticosteroids

Topical steroids are appropriate in resolution of the rash, but aren't a long-term solution versus removal/identification of any potential trigger for the dermatitis.

Rate this question:

Next Question

Previous Q... Tag Questi... Feedback End Session

Blog About Pastest Contact Us Help

© Pastest 2019

A 43-year-old man with a longstanding skin disorder presents as an emergency as his skin has become markedly erythematous and has spread to involve most of his body. He complains of feeling generally shivery and unwell.

Apparently, he has just started propranolol treatment for benign essential tremor.

Which of the following is the most likely underlying skin condition?

A	Pemphigus vulgaris
B	Pityriasis rubra pilaris
C	Psoriasis
D	Acne vulgaris
E	Rosacea

Submit

Previous Q... Skip Questi...

© Pastest 2019

A 43-year-old man with a longstanding skin disorder presents as an emergency as his skin has become markedly erythematous and has spread to involve most of his body. He complains of feeling generally shivery and unwell.

Apparently, he has just started propranolol treatment for benign essential tremor.

Which of the following is the most likely underlying skin condition?

Your answer was correct

A	Pemphigus vulgaris
B	Pityriasis rubra pilaris
C	Psoriasis
D	Acne vulgaris
E	Rosacea

Explanation

C Psoriasis

Erythroderma is the term applied to any inflammatory skin disease that affects more than 90% of the body surface. It is often accompanied with fever, shivering and malaise. Forty per cent of erythroderma is secondary to eczema and 25% secondary to psoriasis. These are the two most common causes. Erythroderma is often associated with metabolic disturbances, and patients may develop

C Psoriasis

Erythroderma is the term applied to any inflammatory skin disease that affects more than 90% of the body surface. It is often accompanied with fever, shivering and malaise. Forty per cent of erythroderma is secondary to eczema and 25% secondary to psoriasis. These are the two most common causes. Erythroderma is often associated with metabolic disturbances, and patients may develop hypothermia or high-output cardiac failure. Treatment in hospital is advisable, with careful monitoring of fluid balance and temperature. Propranolol is well recognised as a trigger for worsening of psoriasis.

A Pemphigus vulgaris

Pemphigus may be associated with extensive bullae, although this doesn't result in the confluent areas of erythema known as erythroderma seen here.

B Pityriasis rubra pilaris

Pityriasis rubra pilaris is a cause of erythroderma, although it is much rarer than psoriasis and doesn't worsen in patients who are prescribed a beta blocker.

D Acne vulgaris

Acne vulgaris may become more extensive, for example in response to hormonal triggers, but it isn't usually associated with erythroderma.

E Rosacea

Rosacea is associated with an erythematous pustular rash primarily affecting the nasolabial folds. It doesn't lead to generalised erythroderma

10:16
On ···
594-042-7551
Leave

A 22-year-old woman with severe nodulocystic acne has had multiple courses of antibiotics with no benefit. After discussion it is agreed to start her on isotretinoin (Roaccutane™).

What must be put in place prior to starting treatment?

A	Urea and electrolytes testing
B	Blood pressure monitoring
C	Full blood count testing
D	Beta-HCG testing
E	Autoantibody screening

33594

Submit

Previous Q... Skip Questi...

© Pastest 2019

Audio Video Share Participants 2 More

10:16

D Beta-HCG testing

Isotretinoin is the most clinically effective treatment for acne, and frequently produces long-term remission. It significantly reduces elevated sebum production, comedogenesis and colonisation with *Propionibacterium acnes*. Isotretinoin should be prescribed for patients with moderate acne who are failing to respond to conventional therapy. It does, however, have many side effects. In particular, it is very teratogenic. A negative pregnancy test must be obtained prior to treatment, and counselling must be given regarding contraception. Liver function tests and lipids should also be checked in patients, as these frequently become elevated with treatment. Patients generally complain of dryness of the mouth and lips, and should be advised to use regular moisturisers.

A Urea and electrolytes testing

Although isotretinoin may impact on liver function, it doesn't significantly impact on renal function; regular urea and electrolytes testing is not therefore indicated.

B Blood pressure monitoring

Since isotretinoin doesn't significantly impact on salt and water balance, blood pressure monitoring is therefore not required before starting therapy.

C Full blood count testing

Anaemia isn't a significant problem with respect to isotretinoin prescription. Full blood count testing is not therefore usually required.

E Autoantibody screening

Rana Alnasser's screen

Touc... 00:07 10:17

A 40-year-old biology professor attended the Emergency Department with a very distressing itch. This started 9 months ago, after the patient moved to a new house. It has been resistant to both hydrocortisone 1% cream and terbinafine cream, given to her by the GP.

On examination, there are excoriations, crusts and erosions. The patient insists that her new house is 'infested' and shows you 'tracks' on her skin from which she has extracted insects and insect parts, which she brings to show you (see image).

Given the suspected diagnosis, what is the best next management step?

A	Two treatments with permethrin cream, one week apart
B	Oral mebendazole
C	Hibiscrub washes and mupirocin nasal ointment

Rana Alnasser's screen

Given the suspected diagnosis, what is the best next management step?

A	Two treatments with permethrin cream, one wee apart
B	Oral mebendazole
C	Hibiscrub washes and mupirocin nasal ointment for one week
D	Oral risperidone and psychiatry referral
E	Oral fexofenadine

Submit

Previous Q...

Skip Quest

10:18
On
MyPastest
https://mypastest.com
594-042-7551
Leave

A 40-year-old biology professor attended the Emerger Department with a very distressing itch. This started 9 months ago, after the patient moved to a new house. It been resistant to both hydrocortisone 1% cream and terbinafine cream, given to her by the GP.

On examination, there are excoriations, crusts and eros The patient insists that her new house is 'infested' and shows you 'tracks' on her skin from which she has extracted insects and insect parts, which she brings to show you (see image).

Given the suspected diagnosis, what is the best next management step?

Audio
Video
Share
Participants
2
More

10:20

Explanation

D	Oral risperidone and psychiatry referral

The history and picture point to a diagnosis of delusional parasitosis, a psychiatric condition where patients acquire a strong delusional belief that they are infested with parasites. Often the imaginary parasites are described as bugs or insects that are crawling on or under the skin. Any marking on the skin, or particle found on the person or his/her clothing, can be interpreted by the patient as evidence for the parasitic infestation. Sufferers commonly compulsively gather such samples and present them to medical professionals. This behaviour of evidence gathering is known as the 'matchbox' sign because matchboxes are often used as the container in which samples are being kept by patients. The diagnosis of delusional parasitosis is supported by the fixed views of infestation, even when presented with strong evidence against it. Atypical antipsychotics such as olanzapine or risperidone are currently used as first line treatment in addition to input from the psychiatric services.

A	Two treatments with permethrin cream, one week apart

Permethrin cream is used in the treatment of scabies. Patients must also take appropriate measures to eradicate the mite from their clothes and bed linen in order to avoid being re-infected.

B	Oral mebendazole

Mebendazole is used to treat parasitic worm infection such as hookworm.

C	Hibiscrub washes and mupirocin nasal ointment for one week

Rana Alnasser's screen

samples are being kept by patients. The diagnosis of delusional parasitosis is supported by the fixed views of infestation, even when presented with strong evidence against it. Atypical antipsychotics such as olanzapine or risperidone are currently used as first line treatment in addition to input from the psychiatric services.

A	Two treatments with permethrin cream, one week apart

Permethrin cream is used in the treatment of scabies. Patients must also take appropriate measures to eradicate the mite from their clothes and bed linen in order to avoid being re-infected.

B	Oral mebendazole

Mebendazole is used to treat parasitic worm infection such as hookworm.

C	Hibiscrub washes and mupirocin nasal ointment for one week

The combination of hibiscrub washes and mupirocin nasal ointment is a commonly used treatment against colonisation by *methicillin-resistant Staphylococcus aureus (MRSA)*.

E	Oral fexofenadine

Fexofenadine is a non-sedating antihistamine, commonly used in the treatment of chronic urticaria and allergic rhinitis.

Rate this question:

Next Question

This 68-year-old patient is reviewed in the Dermatology Clinic. She has a number of underlying medical conditions and takes a range of medications including ramipril, thyroxine, metformin, azathioprine and naproxen.

The photograph below shows a skin lesion:

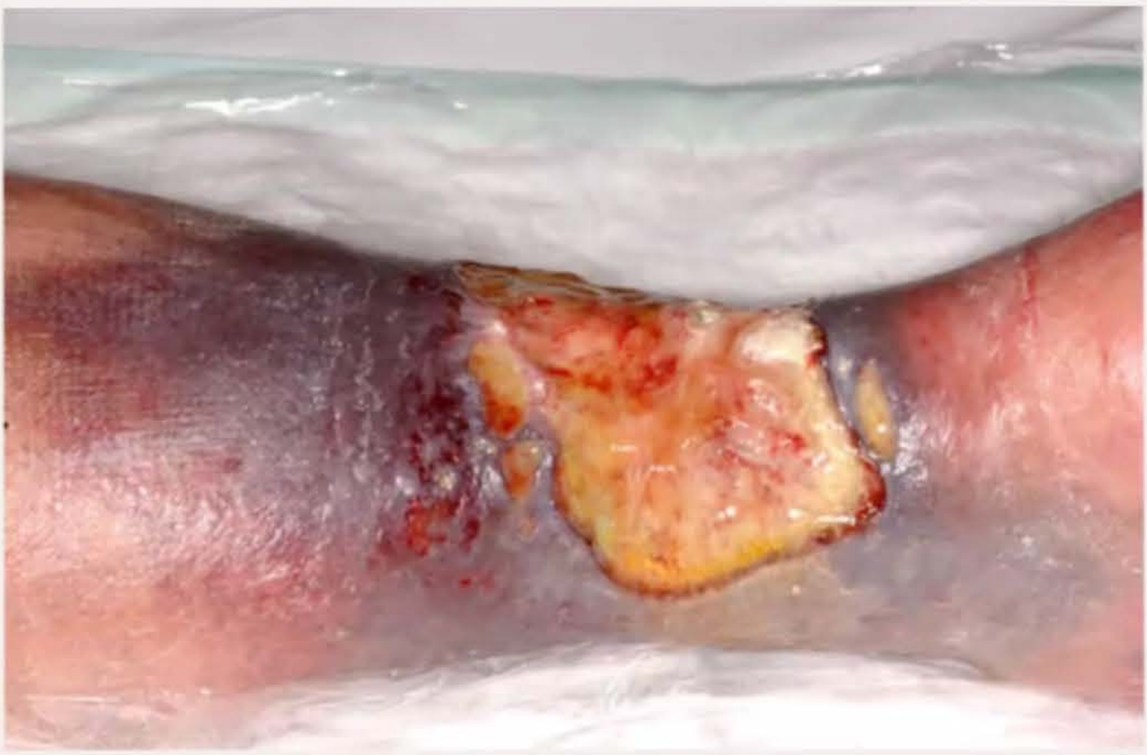

Which of the following is the most likely cause of her skin condition?

A	Type 2 diabetes mellitus
B	Hypothyroidism
C	Naproxen use
D	Ulcerative colitis
E	Microscopic colitis

9191

Submit

10:23
On
594-042-7551
Leave

and takes a range of medications including ramipril, thyroxine, metformin, azathioprine and naproxen.

The photograph below shows a skin lesion:

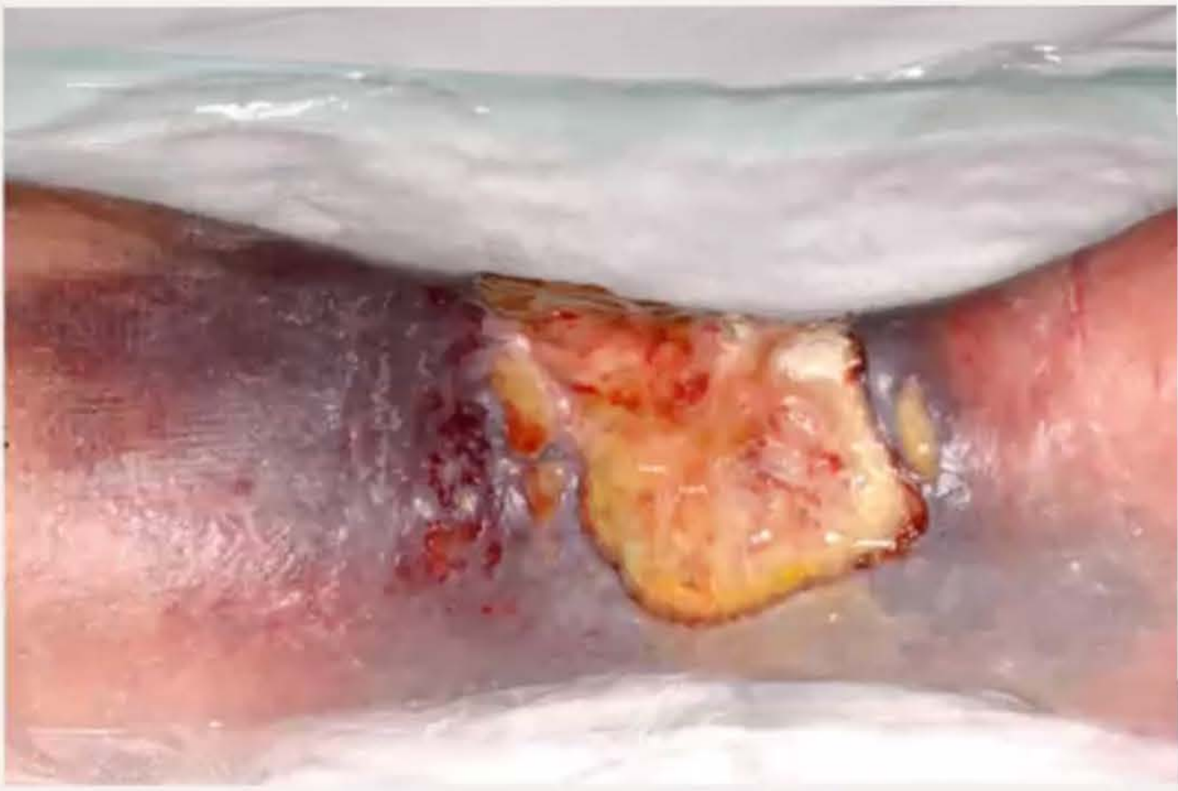

Which of the following is the most likely cause of her skin condition?

Your answer was correct

A	Type 2 diabetes mellitus
B	Hypothyroidism
C	Naproxen use
D	Ulcerative colitis
E	Microscopic colitis

Explanation

Audio
Video
Share
Participants
More

10:23

D	Ulcerative colitis

This patient is suffering from pyoderma gangrenosum, with an extensive area of skin loss that has a tender, red/blue necrotic edge, and there is some central healing and scarring. Pyoderma gangrenosum is most strongly associated with inflammatory bowel disease, but is also seen in rheumatoid arthritis, systemic vasculitis, myeloma and type 1 diabetes.

A	Type 2 diabetes mellitus

Although this patient is taking metformin, type 2 diabetes isn't a cause of pyoderma gangrenosum. It does increase the risk of bacterial skin infection, which is most commonly seen to affect the soles of the feet.

B	Hypothyroidism

Hypothyroidism is associated with rough dry skin and scaling, rather than with pyoderma gangrenosum.

C	Naproxen use

Naproxen, like other NSAIDs, is associated with the development of microcytic colitis and it is associated with allergic skin rashes rather than with pyoderma.

E	Microscopic colitis

Although inflammatory bowel disease including ulcerative colitis and Crohn's is associated with pyoderma gangrenosum, microcytic colitis is not strongly associated with the condition.

Rate this question:

Rana Alnasser's screen

10:24
On
594-042-7551
Leave

A 23-year-old, previously fit and well Turkish man presents with a history of painful oral and genital ulceration. More recently he has also developed gritty eyes and a sore knee.

Examination reveals areas of mucosal ulceration and scaring in addition to knee synovitis and eye erythema. He is investigated with repeated blood tests after which he develops blistering at the sites of venepuncture.

Which of the following is the most likely diagnosis?

A	Behçet's syndrome
B	Reiter's syndrome
C	HIV seroconversion
D	Herpes simplex virus (HSV) infection
E	Primary syphilis

8567

Submit

Previous Q... Skip Questi...

Blog About Pastest Contact Us Help
© Pastest 2019
Audio Video Share Participants More

10:25
On
594-042-7551
Leave

A 23-year-old, previously fit and well Turkish man presents with a history of painful oral and genital ulceration. More recently he has also developed gritty eyes and a sore knee.

Examination reveals areas of mucosal ulceration and scaring in addition to knee synovitis and eye erythema. He is investigated with repeated blood tests after which he develops blistering at the sites of venepuncture.

Which of the following is the most likely diagnosis?

Your answer was correct

A	Behçet's syndrome
B	Reiter's syndrome
C	HIV seroconversion
D	Herpes simplex virus (HSV) infection
E	Primary syphilis

Explanation

A	Behçet's syndrome

Behçet's syndrome is most common in young Turkish males and presents with recurrent oral and genital ulcers. It is also associated with eye problems e.g. anterior and posterior uveitis and an asymmetrical migratory non-erosive oligoarthritis. Patients may also present with neurological complications, and in particular meningoencephalitis.

Audio Video Share Participants More

10:25
On
594-042-7551
Leave

A Behçet's syndrome

Behçet's syndrome is most common in young Turkish males and presents with recurrent oral and genital ulcers. It is also associated with eye problems e.g. anterior and posterior uveitis and an asymmetrical migratory non-erosive oligoarthritis. Patients may also present with neurological complications, and in particular meningoencephalitis.

B Reiter's syndrome

Reiter's syndrome consists of the triad of conjunctivitis, urethritis and arthritis. Patients also develop erosions in the mouth and also on the penis where they are known as circinate balanitis. The distinguishing feature in this history is the development of a pustule after skin puncture. This phenomenon known as pathergy is characteristic of Behçet's syndrome.

C HIV seroconversion

HIV seroconversion occurs at the time that patients develop antibodies to the HIV virus and manifests as a flu-like illness.

D Herpes simplex virus (HSV) infection

Symptoms of HSV recurrence manifest as vesicles and punched-out ulcers around the mouth or genitals, whereas primary HSV infection may also be associated with fever and malaise.

E Primary syphilis

Syphilis is a sexually transmitted infection caused by the

Audio Video Share Participants More

10:25

An 18-year-old man comes to the Dermatology Clinic having recently returned from a charity visit to a northern Thai beach resort. He has a very itchy 'creeping' eruption on the soles of both his feet.

On examination, he has linear tracks on the feet, some of which have secondary blistering, crusting and bacterial infection. A diagnosis of cutaneous larva migrans is made.

Which of the following is most likely to harbour the infection?

A	Dog
B	Fish
C	Sand fly
D	Red ant
E	Turkey

Submit

Previous Q... Skip Questi...

Blog About Pastest Contact Us Help

© Pastest 2019

Rana Alnasser's screen

An 18-year-old man comes to the Dermatology Clinic having recently returned from a charity visit to a northern Thai beach resort. He has a very itchy 'creeping' eruption on the soles of both his feet.

On examination, he has linear tracks on the feet, some of which have secondary blistering, crusting and bacterial infection. A diagnosis of cutaneous larva migrans is made.

Which of the following is most likely to harbour the infection?

Your answer was correct

A	Dog
B	Fish
C	Sand fly
D	Red ant
E	Turkey

Explanation

A	Dog

Cutaneous larva migrans is a parasitic skin infection cause by hookworm that usually infect domestic animals such as dogs, cats and sometimes cattle. In the animal host, the larvae penetrate the skin and reach the blood. They matur in the intestine and lay eggs, which are excreted in the feces. The larvae are found in beaches and moist soils

Rana Alnasser's screen

10:27

Explanation

A Dog

Cutaneous larva migrans is a parasitic skin infection cause by hookworm that usually infect domestic animals such as dogs, cats and sometimes cattle. In the animal host, the larvae penetrate the skin and reach the blood. They matur in the intestine and lay eggs, which are excreted in the faeces. The larvae are found in beaches and moist soils contaminated with animal faeces. Albendazole and ivermectin are potential interventions.

B Fish

Fish tapeworm leads to intestinal infection from uncooked freshwater fish, and is a potential problem with respect to eating sushi.

C Sand fly

Sand fly bites lead to the development cutaneous leishmaniasis, rather than cutaneous larva migrans.

D Red ant

Allergic dermatitis may be rarely seen in patients bitten by red ants, although it doesn't lead to the development of cutaneous larva migrans.

E Turkey

Turkeys suffer from caecal worms, which carry the protozoan parasite *Histomonas*; this leads to death in the turkeys, but isn't a cause of human disease.

Rate this question:

10:27

cutaneous larva migrans

ALL IMAGES NEWS VIDEOS MAPS BOOKS SHOPPING FL

Latest GIF HD Product

hookworm life cycle pathogenesis treat

Cutaneous larva migrans | DermNet NZ
dermnetnz.org

Cutaneous larva migrans | DermNet NZ
dermnetnz.org

Pediatric Cutaneous Larva Migrans ...
emedicine.medscape.com

Cutaneous Larva Migrans Diagnosis and ...
news-medical.net

Cutaneous Larva Migrans - Dermatologic ...
msdmanuals.com

Cutaneous Larva Migrans - Dermatology ...

Discover Updates Search Rec

10:28

cutaneous larva migrans

Pediatric Cutaneous Larva Migrans ...
emedicine.medscape.com

Cutaneous Larva Migrans Diagnosis and ...
news-medical.net

Cutaneous Larva Migrans - Dermatologic ...
msdmanuals.com

Cutaneous Larva Migrans - Dermatology ...
step2.medbullets.com

Cutaneous larva migrans infection ...
sciencephoto.com

Cutaneous larva migrans - WikEM
wikem.org

Cutaneous larva migrans in children: A ...
ijpd.in

Cutaneous Larva Migrans ...
mdedge.com

Discover
Updates
Search

An 18-year-old woman presents with painful lesions on her face. They have been spreading in size over the last few days. She has been suffering from rhinorrhoea and flu-like symptoms over the last week and has been 'off' her food.

What diagnosis should be considered?

A	Erythema infectiosum
B	Impetigo
C	Perioral dermatitis
D	Herpes zoster infection
E	Erysipelas

33386

Submit

10:30

B Impetigo

Impetigo is a common superficial infection of the epidermis, occurring mainly in children. It is usually due to *Staphylococcus aureus*, a group A beta-haemolytic *Streptococcus* or a mixture of both. It is very contagious. It typically starts as vesicles which then break down to form honey-coloured crusts.

A Erythema infectiosum

Erythema infectiosum is associated with an erythematous rash affecting both cheeks, rather than the vesicles and crusting seen here.

C Perioral dermatitis

Perioral dermatitis is associated with groups of small red papules around the mouth rather than the vesicles and crusting seen here.

D Herpes zoster infection

Herpes zoster infection occurs with a generalised vesicular rash in chicken pox, or is confined to single dermatomes in shingles.

E Erysipelas

Erysipelas occurs as a generalised area of erythema, rather than the vesicular crusting rash seen here. It is related to group A streptococcal infection.

Rate this question:

Next Question

10:31

A 37-year-old Turkish man is referred by his general practitioner (GP) with the 'warty' skin lesion seen below.

His girlfriend is worried that it has worsened over the last 9 months. He feels that sometimes it completely clears up spontaneously. He has not tried any treatments. It has recently become itchy, and he has been finding sexual intercourse painful.

More recently, he has noticed an itchy lesion on the dorsum of his big toe, too.

What is the diagnosis?

A	Lichen planus
B	Lichen sclerosus
C	Psoriasis
D	Genital warts
E	Primary syphilis

Rana Alnasser's screen

10:32
594-042-7551 Leave



His girlfriend is worried that it has worsened over the last 9 months. He feels that sometimes it completely clears up spontaneously. He has not tried any treatments. It has recently become itchy, and he has been finding sexual intercourse painful.

More recently, he has noticed an itchy lesion on the dorsum of his big toe, too.

What is the diagnosis?

A	Lichen planus
B	Lichen sclerosus
C	Psoriasis
D	Genital warts
E	Primary syphilis

Submit

Previous Q... Skip Questi...

Blog About Pastest Contact Us Help

© Pastest 2019

Audio Video Share Participants 3 More

10:32



His girlfriend is worried that it has worsened over the last 9 months. He feels that sometimes it completely clears up spontaneously. He has not tried any treatments. It has recently become itchy, and he has been finding sexual intercourse painful.

More recently, he has noticed an itchy lesion on the dorsum of his big toe, too.

What is the diagnosis?

Your answer was incorrect

A	Lichen planus
B	Lichen sclerosus
C	Psoriasis
D	Genital warts
E	Primary syphilis

Explanation

A	Lichen planus

Lichen planus is of unknown aetiology. Its association with autoimmune diseases, like vitiligo, alopecia areata and ulcerative colitis, suggests that it too can be mediated immunologically. Typical lesions are violaceous, intensely itchy, flat-topped papules arising on the extremities. The condition can affect the skin and genitalia. In 50% of patients, there are oral lesions, eg white, asymptomatic, [illegible] In 10% of patients, there are nai

Rana Alnasser's screen

10:32

A Lichen planus

Lichen planus is of unknown aetiology. Its association with autoimmune diseases, like vitiligo, alopecia areata and ulcerative colitis, suggests that it too can be mediated immunologically. Typical lesions are violaceous, intensely itchy, flat-topped papules arising on the extremities. The condition can affect the skin and genitalia. In 50% of patients, there are oral lesions, eg white, asymptomatic, lacy lines, dots or plaques. In 10% of patients, there are nai changes, eg longitudinal ridging and destruction of the nai bed. Potent topical steroids are the treatment of choice, but response is variable.

D Genital warts

Warts can occur on any part of the anogenital area, including the urethra and anus. Unlike warts at other sites that may have a hard, keratinous surface, the genitals present as flesh-coloured papules that may coalesce to form plaques. A tiny black dot may be observed on the surface due to the presence intracorneal haemorrhage.

B Lichen sclerosus

Male genital lichen sclerosus is generally a disease of the uncircumcised, with the weight of evidence indicating that it is due to chronic, intermittent, occluded exposure of a susceptible epithelium to urine. Dyspareunia, itch and a rash are the predominant symptoms. Phimosis is common. Signs can range from subtle to florid and can manifest as shiny, sclerotic patches or patches with telangiectasia and sparse purpura. Circumcision is commonly required when treatment with topical super-potent steroids proves inadequate.

C Psoriasis

10:34

You are asked to review a 70-year-old man on haemodialysis for tubular-interstitial nephritis. He has had failed renal transplant.

Six months ago, he had an MRI with contrast for back pain He presents with a 3-month history of 'woody' skin around the abdomen and distal limbs. His umbilicus has become inverted and smaller. He denies having any difficulty swallowing, shortness of breath or other systemic symptoms.

On palpation of his skin, it had lost its elasticity and was hard.

What is the most likely diagnosis?

A	Plaque morphoea
B	Systemic sclerosis
C	Intra-abdominal carcinomatosis
D	Pre-tibial myxoedema
E	Nephrogenic systemic sclerosis

Rana Alnasser's screen

10:35

E	Nephrogenic systemic sclerosis

Nephrogenic systemic sclerosis is a devastating cutaneous dermopathy, seen in patients with chronic kidney disease who have been exposed to gadolinium-based contrast agents seen in MRI. The skin becomes wood-like and hard.

A	Plaque morphoea

Plaque morphoea is asymmetrical and involves the skin only, and usually doesn't progress as rapidly as the picture seen here.

B	Systemic sclerosis

In systemic sclerosis, nail changes, calcinosis of the fingers and telangiectasia would be expected.

C	Intra-abdominal carcinomatosis

Intra-abdominal carcinomatosis would be associated with the progressive development of ascites and abdominal distension.

D	Pre-tibial myxoedema

Pre-tibial myxoedema is characterised by infiltration of the skin over the shins, and is associated with positive thyroid antibodies and Graves' disease.

Rate this question:

Next Question

Rana Alnasser's screen

10:35

A 30-year-old teacher attends with a 7-day history of malaise, fatigue, dry cough and shortness of breath on exertion. Three days ago, she developed an itchy rash. She is asthmatic and takes salbutamol inhalers regularly.

On examination, she has cold sores on her upper lip. There are annular plaques present on the forearms, trunk and lower limbs. Some are clearing in the centre. There are a few vesicles. The throat is inflamed and the tonsils enlarged. The chest is clinically clear, but there are striking changes on X-ray suggestive of right lower lobe consolidation.

Investigations:

Hb	10.0 g/dl
WCC	8.2×10^9/l
PLT	500×10^9/l
Na^+	139 mmol/l
K^+	4.9 mmol/l
Creatinine	100 µmol/l
Coomb's test	+

What is the most likely cause of her respiratory symptoms?

A	Pneumococcal pneumonia
B	*Haemophilus influenzae* type B pneumonia
C	Chicken pox
D	Pulmonary vasculitis

Rana Alnasser's screen

10:37

What is the most likely cause of her respiratory symptoms?

Your answer was correct

A	Pneumococcal pneumonia
B	*Haemophilus influenzae* type B pneumonia
C	Chicken pox
D	Pulmonary vasculitis
E	*Mycoplasma* pneumonia

Explanation

E	*Mycoplasma* pneumonia

Mycoplasma pneumonia can present with dermatologic manifestations, which can range from a mild erythematous maculo-papular or vesicular rash (which is most commonly seen accompanying respiratory tract infections) to Stevens-Johnson syndrome. Subclinical haemolytic anaemia can present in patients with *Mycoplasma*, which are suggested by a positive Coomb's test. WCC can be normal in up to 90% of cases and can be accompanied by thrombocytosis, most likely due to an acute phase response.

This lady has a rash consistent with erythema multiforme, with symptoms of an upper respiratory tract infection preceding the eruption. She may well have suffered *Mycoplasma* pneumonia that has begun to resolve after antibiotic therapy.

10:37

E *Mycoplasma* pneumonia

Mycoplasma pneumonia can present with dermatologic manifestations, which can range from a mild erythematous maculo-papular or vesicular rash (which is most commonly seen accompanying respiratory tract infections) to Stevens-Johnson syndrome. Subclinical haemolytic anaemia can present in patients with *Mycoplasma*, which are suggested by a positive Coomb's test. WCC can be normal in up to 90% of cases and can be accompanied by thrombocytosis, most likely due to an acute phase response.

This lady has a rash consistent with erythema multiforme, with symptoms of an upper respiratory tract infection preceding the eruption. She may well have suffered *Mycoplasma* pneumonia that has begun to resolve after antibiotic therapy.

Around 90% of erythema multiforme cases are usually associated with infections.

The single most common trigger for developing erythema multiforme is herpes simplex virus (HSV) infection, and usually precedes the skin eruption by 3–14 days. *Mycoplasma* pneumonia is the next most common trigger.

Other viral infections include:

- Parapoxvirus (orf and milkers' nodules)
- Herpes varicella zoster (chickenpox, shingles)
- Adenovirus
- Hepatitis viruses
- Human immunodeficiency virus (HIV)
- Cytomegalovirus
- Viral vaccines.

The initial lesions are sharply demarcated, round, red/pink and flat (macules), which become raised (papules/palpable) and gradually enlarge to form plaques (flat raised patches) up to several centimetres in diameter.

- Hepatitis viruses
- Human immunodeficiency virus (HIV)
- Cytomegalovirus
- Viral vaccines.

The initial lesions are sharply demarcated, round, red/pink and flat (macules), which become raised (papules/palpable) and gradually enlarge to form plaques (flat raised patches) up to several centimetres in diameter. The centre of the papule/plaque darkens in colour and develops surface (epidermal) changes such as blistering or crusting. Lesions usually evolve over 72 h. The typical target lesion (also called iris lesion) of erythema multiforme has a sharp margin, regular round shape and three concentric colour zones: the centre is dark red, the next ring is paler and raised due to oedema and the outermost ring is bright red.

Mycoplasma pnuemonia usually presents with vague and slow-onset history over a few days or weeks of constitutional upset, fever, headache, dry cough with tracheitic ± pleuritic pain, myalgia, malaise and sore throat. Raynaud's phenomenon may also be seen in *M. pneumoniae* infection, possibly secondary to cold agglutinin formation. *Mycoplasma* and *Chlamydophila* spread by person-to-person contact, and spread is most common in closed populations - e.g. schools, offices. This is like many of the common viral illnesses, but the persistence and progression of symptoms is what helps to mark it out.

A	Pneumococcal pneumonia

This usually presents with abrupt illness with rigors, cough and myalgia in young patients similar to this case. It is not commonly associated with erythema multiforme.

B	*Haemophilus influenzae* type B pneumonia

This patient is likely to have been vaccinated for *H.*

10:37

Haemophilus influenza is likely, especially if she is not immunosuppressed. Furthermore, *Haemophilus* influenza is more likely to affect the oldest and youngest groups.

C	Chicken pox

Varicella-zoster infection manifests first as macules and then as vesicles, which then become crusted papules rather than the annular plaques seen in this case.

D	Pulmonary vasculitis

Pulmonary vasculitis, such as granulomatosis with polyangiitis (GPA) and microscopic polyangiitis (MPA), is likely to manifest with a mixture of both upper and lower respiratory tract symptoms and signs. Upper respiratory symptoms and signs include rhinosinusitis, nasal discharge and nasal crusting. Lower respiratory tract symptoms and signs include cough, haemoptysis, dyspnoea and pleuritic chest pain.

This lady has a rash consistent with erythema multiforme with symptoms of an upper respiratory tract infection preceding the eruption. She may well have suffered mycoplasma pneumonia, which has begun to resolve after antibiotic therapy. Clinical signs which are out of kilter when compared to x-ray appearance are also a feature of mycoplasma. Individual target lesions last several days resolving with transient hyperpigmentation. Erythema multiforme has also been described as occurring some 1–2 weeks after a herpes virus infection. Treatment of any underlying infection, in this case with a macrolide antibiotic, leads to a resolution of the rash.

Rate this question:

Next Question

A 60-year-old woman presented with a sudden onset, widespread, erythematous rash, covering 95% of her body

Which of the following best describes this pattern of rash

A	Icthyosis
B	Erythroderma
C	Pustular
D	Urticarial
E	Follicular

39065

Submit

10:38

B Erythroderma

The diagnosis here is exfoliative rash. Erythroderma refers to an erythematous, (red) scaly/exfoliative dermatitis, involving 90% or more of the skin surface. This may develop suddenly. Addressing temperature regulation and fluid balance is essential. Causes of erythroderma include eczema, especially atopic or seborrhoeic, psoriasis, drug eruption and cutaneous T-cell lymphoma.

A Icthyosis

Icthyosis is associated with widespread, dry, skin thickenin with fish scale-like skin.

C Pustular

Pustular rashes consist of multiple bullae or vesicles containing purulent material.

D Urticarial

Urticaria is associated with erythematous welts and wheals rather than the contiguous rash seen here.

E Follicular

Folliculitis is characterised by inflammation or infection of hair follicles, rather than the generalised inflammation seen in this patient.

Rate this question:

Next Question

A 34-year old woman is due to be discharged from hospital. She was admitted one week ago due to infected digital ulcers in the context of systemic sclerosis.

A photograph of her hands is shown below.

Her infection has now settled, and she feels well. It is noticed on her blood tests that she had an elevated creatinine. She has also been found to have proteinuria. This has not settled despite rehydration.

What is the most appropriate management to prevent renal disease?

A	Regular corticosteroids
B	Angiotensin-converting enzyme (ACE) inhibitor
C	Nifedipine
D	Sildenafil
E	Creon

10:40

B Angiotensin-converting enzyme (ACE) inhibitor

Patients with systemic sclerosis are at risk of developing renal crisis and of chronic renal disease. This is particularly the case for patients with the following:

- diagnosis of systemic sclerosis less than four years ago
- rapidly progressive skin thickening
- new anaemia
- new cardiac event
- anti-ribonucleic acid (RNA) polymerase antibodies
- corticosteroid therapy.

Patients who develop renal impairment, hypertension and proteinuria are likely to develop renal crisis. They need treatment with an ACE inhibitor as primary management. I addition, any hypertension needs to be aggressively treated to prevent further deterioration.

A Regular corticosteroids

Using corticosteroids is associated with worsening renal function rather than improving renal function in systemic sclerosis. This may be due to the increasing blood pressure with the use of corticosteroids.

C Nifedipine

Calcium channel blockers, such as nifedipine, are used in patients with systemic sclerosis to help treat Raynaud's phenomenon as well as prevention of duodenal ulceration. Calcium channel blockers can also be used as an antihypertensive to control blood pressure, but ACE inhibitors remain first-line.

10:40

MyPastest
https://mypastest.pastest.com

treated to prevent further deterioration.

A Regular corticosteroids

Using corticosteroids is associated with worsening renal function rather than improving renal function in systemic sclerosis. This may be due to the increasing blood pressure with the use of corticosteroids.

C Nifedipine

Calcium channel blockers, such as nifedipine, are used in patients with systemic sclerosis to help treat Raynaud's phenomenon as well as prevention of duodenal ulceration. Calcium channel blockers can also be used as an antihypertensive to control blood pressure, but ACE inhibitors remain first-line.

D Sildenafil

Sildenafil is a phosphodiesterase inhibitor which can be used in systemic sclerosis as treatment of Raynaud's phenomenon and duodenal ulceration, but this remains second-line to calcium channel blockers.

E Creon

Creon can be used in malabsorption in systemic sclerosis when there is malabsorption and diarrhoea due to bacteria overgrowth and intestinal stasis and can improve symptoms for such patients.

Rate this question:

Rana Alnasser's screen

A 54-year-old woman presents to the Dermatology Clinic with a dry rash on her back. This has recently become more irritable and itchy. She has not suffered from similar rashes previously.

She has a past medical history of hysterectomy for menorrhagia, asthma and type 2 diabetes mellitus. She currently takes salbutamol as required (prn) and metformin.

A photograph of the rash on her back is shown below.

What is the most appropriate management plan for this patient?

A	Coal tar
B	Topical steroid and topical vitamin D preparation
C	Topical salicylic acid
D	Methotrexate
E	Systemic corticosteroids

10:42

Explanation

B	Topical steroid and topical vitamin D preparation

This patient has typical plaque psoriasis. This is characterised by a silver, scaly plaque on a salmon-pink background, typically occurring at the extensor surfaces as well as the natal cleft (as in this patient), groin and umbilicus. Management advised by NICE is:

- Potent topical corticosteroid and vitamin D preparation applied separately at different times of the day
- Review at four weeks; if responding continue, if treatment fails either continue or change vitamin D to twice a day and stop corticosteroid
- Review at eight weeks; treat with vitamin D twice a day only. If not improving after 8–12 weeks of treatment, then use coal tar preparations or a potent corticosteroid.

In ongoing treatment failure then consider combination treatment with topical corticosteroid and vitamin D. Patients should be advised to have corticosteroid treatment breaks after eight weeks of corticosteroid treatment to one area.

A	Coal tar

Coal tar would be an appropriate treatment option if topical steroids and vitamin D treatments fail.

C	Topical salicylic acid

Topical salicylic acid is most appropriate if scale is problematic. This patient has some scale, but this has not

10:42

treatment with topical corticosteroid and vitamin D. Patients should be advised to have corticosteroid treatment breaks after eight weeks of corticosteroid treatment to one area.

A Coal tar

Coal tar would be an appropriate treatment option if topical steroids and vitamin D treatments fail.

C Topical salicylic acid

Topical salicylic acid is most appropriate if scale is problematic. This patient has some scale, but this has not created a thick layer that would need salicylic acid to breakdown.

D Methotrexate

Methotrexate is a systemic treatment option for refractory or systemic psoriasis. It would not be indicated at this stage as the condition is limited in area and in systemic effect.

E Systemic corticosteroids

Systemic corticosteroids are best to be avoided in psoriasi due to risk of severe withdrawal flares when they are stopped.

Rate this question:

Next Question

Previous Q... Tag Questi... Feedback End Session

A 45-year-old woman complains of a 5-year history of intermittent watery, pale diarrhoea, with stool frequency 5-8 times a day. She has noted a stone in weight loss over the last months.

Her BP is 112/80, with pulse 80 and regular. She is thin with a BMI of 20, and there are erythematous excoriated papules with herpetiform vesicles symmetrically distributed over extensor surfaces of the elbows and knees.

Investigations:

Hb	9.4 g/dl
WCC	11×10^9/l
PLT	440×10^9/l
MCV	85 fl
Vitamin B12	150 ng/l
Serum folate	4 µg/l
Ferritin	3 ng/ml
Bilirubin	10 µmol/l
ALP	175 IU/l
AST	14 IU/l
ALT	14 IU/l
Total protein	50 g/l
Albumin	25 g/l
Globulins	27 g/l
C-reactive protein	2 mg/l
Erythrocyte sedimentation rate	17 mm/1st hr
Urine dipstick	Trace protein

What is the most likely diagnosis for her skin rash?

10:43
594-042-7551
Leave

Vitamin B12	150 ng/l
Serum folate	4 µg/l
Ferritin	3 ng/ml
Bilirubin	10 µmol/l
ALP	175 IU/l
AST	14 IU/l
ALT	14 IU/l
Total protein	50 g/l
Albumin	25 g/l
Globulins	27 g/l
C-reactive protein	2 mg/l
Erythrocyte sedimentation rate	17 mm/1st hr
Urine dipstick	Trace protein

What is the most likely diagnosis for her skin rash?

A Vitamin B_{12} deficiency

B Herpes simplex

C Dermatitis herpetiformis

D Transient acantholytic dermatosis

E Linear IgA dermatosis

Audio Video Share Participants 5 More

10:44
594-042-7551
Leave

C Dermatitis herpetiformis

Dermatitis herpetiformis (DH) is an autoimmune blistering disorder associated with gluten-sensitive enteropathy (coeliac disease). It is characterised by grouped excoriations, erythematous, urticarial plaques and papules with vesicles. These are located on the extensor surfaces o the elbows, knees, buttocks and back. The lesions are extremely itchy and as a consequence the vesicles are often excoriated to erosions.
Diagnosis requires direct immunofluorescence of a skin biopsy specimen showing deposition of immunoglobulin A in a granular pattern in the upper papillary dermis. It is treated with dapsone and with maintenance of a gluten-free diet.

Coeliac disease is a chronic autoimmune disorder of the small intestine caused by gluten intolerance in genetically predisposed individuals. It is characterised by mucosal lesions of the small bowel that result in malabsorption. Les than 10% of patients with DH exhibit symptoms of an underlying gluten-sensitive enteropathy, although more than 90% of patients show abnormalities upon endoscopic examination.

A Vitamin B_{12} deficiency

Skin manifestations of B_{12} deficiency include angular stomatitis, hyperpigmentation and hair changes.

B Herpes simplex

Herpes simplex is associated with cold sores or genital ulceration depending upon which type of HSV is implicate in infection.

D Transient acantholytic dermatosis

5
Audio Video Share Participants More

10:44
594-042-7551 Leave

treated with dapsone and with maintenance of a gluten-free diet.

Coeliac disease is a chronic autoimmune disorder of the small intestine caused by gluten intolerance in genetically predisposed individuals. It is characterised by mucosal lesions of the small bowel that result in malabsorption. Les than 10% of patients with DH exhibit symptoms of an underlying gluten-sensitive enteropathy, although more than 90% of patients show abnormalities upon endoscopic examination.

A Vitamin B_{12} deficiency

Skin manifestations of B_{12} deficiency include angular stomatitis, hyperpigmentation and hair changes.

B Herpes simplex

Herpes simplex is associated with cold sores or genital ulceration depending upon which type of HSV is implicated in infection.

D Transient acantholytic dermatosis

This occurs as a truncal rash characterised by acantholysis on histology, rather than the peripheral pattern of skin changes seen here.

E Linear IgA dermatosis

Linear IgA dermatosis is a bullous disease, predominantly of the elderly, and doesn't fit with the age of this patient.

33406

Rate this question:

Next Question

Audio Video Share Participants 5 More

10:44
594-042-7551
Leave

A 31-year-old nursery worker with a history of periorbital eczema presents to her GP complaining of a rash on her right cheek. The rash has been present for about a week but began as a small blister which subsequently ruptured. The patient had thought that it had been an insect bite but became more concerned as the area affected began to increase in size.

Although the lesion is painless, the patient does complain of burning and itching over the rash. The patient is otherwise fit and well and is not on any medications. She lives alone and does not recall being in contact with anyone with a similar rash.

On examination, the patient has a weeping area measuring 4 cm across her right cheek with golden, crusted edges. General examination of the patient was otherwise normal and no other lesions were identified.

What is the most likely diagnosis?

A	Erysipelas
B	Impetigo
C	Herpes simplex infection
D	Herpes zoster infection
E	Atopic dermatitis

Submit
Audio
Video
Share
Participants
5
More

10:47

What is the most likely diagnosis?

Your answer was correct

A	Erysipelas
B	Impetigo
C	Herpes simplex infection
D	Herpes zoster infection
E	Atopic dermatitis

Explanation

B	Impetigo

Atopic skin is prone to acquiring superimposed bacterial and viral infections. Impetigo is an acute and highly contagious superficial infection of the skin that commonly occurs in children, and consequently outbreaks in nurserie and schools are not rare. There are two forms of the condition, bullous and non-bullous, with the former being caused almost exclusively by Staphylococcus aureus whereas the latter can be caused by S. aureus, group A streptococcus (Streptococcus pyogenes), or a combinatio of both. Culture of the skin lesions is required to confirm the diagnosis and determine the causative organism. Treatment can consist of topical therapy (topical mupirocin) alone or in combination with systemic therapy.

A	Erysipelas

10:47

B Impetigo

Atopic skin is prone to acquiring superimposed bacterial and viral infections. Impetigo is an acute and highly contagious superficial infection of the skin that commonly occurs in children, and consequently outbreaks in nurserie and schools are not rare. There are two forms of the condition, bullous and non-bullous, with the former being caused almost exclusively by Staphylococcus aureus whereas the latter can be caused by S. aureus, group A streptococcus (Streptococcus pyogenes), or a combinatio of both. Culture of the skin lesions is required to confirm the diagnosis and determine the causative organism. Treatment can consist of topical therapy (topical mupirocin) alone or in combination with systemic therapy.

A Erysipelas

Erysipelas is a superficial bacterial skin infection caused by *S. pyogenes* and characterized by well demarcated erythema. Lymphatic involvement is common and manifests by streaking of the overlying skin and local lymphadenopathy.

C Herpes simplex infection

Herpes simplex virus (HSV) infection can cause a variety o clinical symptoms. HSV type 1 is normally associated with orofacial infections. It typically presents as vesicular rash that may be preceded by a prodrome of pain, tingling, burning or itching. Vesicles become pustular or ulcerative with formation of crusts within 72–96 hours and heal over 8–10 days.

D Herpes zoster infection

Primary herpes zoster infection causes chickenpox. The

10:48

C Herpes simplex infection

Herpes simplex virus (HSV) infection can cause a variety o clinical symptoms. HSV type 1 is normally associated with orofacial infections. It typically presents as vesicular rash that may be preceded by a prodrome of pain, tingling, burning or itching. Vesicles become pustular or ulcerative with formation of crusts within 72–96 hours and heal over 8–10 days.

D Herpes zoster infection

Primary herpes zoster infection causes chickenpox. The virus becomes latent and upon reactivation causes shingle (a painful, vesicular rash in a dermatomal distribution).

E Atopic dermatitis

AD is a chronic pruritic condition with characteristic skin changes (inflamed, red, and sometimes weepy patches) that occurs due to a complex interaction between genetic and environmental factors. It usually begins in infancy, but may also occur at any age. Atopic skin is prone to acquiring superimposed infections, commonly with either HSV (eczema herpeticum) or *S. Aureus* (impetigo).

7612

Rate this question:

Previous Q... Tag Questi... Feedback End Session

Blog About Pastest Contact Us Help

10:48

A 33-year-old woman presents with 2-day history of a generalised papular rash affecting the face, trunk and arms

Over the last 24 h, she has been complaining of fever and swelling of her face. She was recently diagnosed with a brain tumour and is receiving radiotherapy at another hospital.

Her current medications include phenytoin, paroxetine, diazepam and lansoprazole.

On examination, temperature is 37.9 °C. There are partially confluent papules on the trunk, upper arms and face, whic blanch with pressure. There is some facial oedema and cervical lymphadenopathy.

Respiratory examination is unremarkable.

Neurological examination:

Cranial nerves:	Partial right-sided ptosis; lower R VII n palsy
Peripheral nervous system:	Right lower limb weakness proximally; brisk reflexes throughout; right extensor plantar

Haematological investigations:

Hb	12.4 g/dl
WCC	13.0×10^9/l
PLT	420×10^9/l
Na^+	132 mmol/l
K^+	4.9 mmol/l
Creatinine	125 µmol/l
Lymphocytes	4.0×10^9/l
Neutrophils	7.5×10^9/l
Eosinophils	0.7×10^9/l

10:49
On
594-042-7551
Leave

system:	plantar

Haematological investigations:

Hb	12.4 g/dl
WCC	13.0×10^9/l
PLT	420×10^9/l
Na^+	132 mmol/l
K^+	4.9 mmol/l
Creatinine	125 µmol/l
Lymphocytes	4.0×10^9/l
Neutrophils	7.5×10^9/l
Eosinophils	0.7×10^9/l
Urea	6.9 mmol/l

What is the most likely diagnosis?

A Bacterial meningitis

B Erythema multiforme

C Drug hypersensitivity syndrome

D Fixed drug eruption

E Toxic epidermal necrolysis

Submit
Audio Video Share Participants More

10:54
594-042-7551
Leave

A 33-year-old woman presents with 2-day history of a generalised papular rash affecting the face, trunk and arms

Over the last 24 h, she has been complaining of fever and swelling of her face. She was recently diagnosed with a brain tumour and is receiving radiotherapy at another hospital.

Her current medications include phenytoin, paroxetine, diazepam and lansoprazole.

On examination, temperature is 37.9 °C. There are partially confluent papules on the trunk, upper arms and face, whic blanch with pressure. There is some facial oedema and cervical lymphadenopathy.

Respiratory examination is unremarkable.

Neurological examination:

Cranial nerves:	Partial right-sided ptosis; lower R VII n palsy
Peripheral nervous system:	Right lower limb weakness proximally; brisk reflexes throughout; right extensor plantar

Haematological investigations:

Hb	12.4 g/dl
WCC	13.0 × 10^9/l
PLT	420 × 10^9/l
Na^+	132 mmol/l
K^+	4.9 mmol/l
Creatinine	125 μmol/l
Lymphocytes	4.0 × 10^9/l
Neutrophils	7.5 × 10^9/l

Audio Video Share Participants More

10:53
594-042-7551
Leave

Explanation

C Drug hypersensitivity syndrome

Also known as DRESS, drug hypersensitivity with eosinophilia and systemic symptoms, this is a serious hypersensitivity reaction pattern that tends to occur 3–6 weeks after commencing the causative drug. Well-recognised culprits include anticonvulsants, antimicrobials and dapsone. Clinical features include fever, facial oedema a generalised exanthematous rash and lymphadenopathy. The liver and kidneys are the most common sites for extra-cutaneous involvement, though pneumonitis and myocarditis can also occur. Eosinophilia and atypical lymphocytosis occur. Drug hypersensitivity syndrome usually responds well to oral steroid treatment. It should b noted that in patients already taking steroids, the signs of drug hypersensitivity may be masked to some degree.

E Toxic epidermal necrolysis

This is the most severe form of drug eruption and leads to extensive skin loss with mucosal involvement. Whilst anticonvulsants are one of the most common precipitants, the clinical picture does not fit with this diagnosis.

A Bacterial meningitis

One would expect symptoms and signs such as headache, neck stiffness and photophobia in true meningitis, and the classical associated rash is purpuric. It should be noted tha meningococcal septicaemia may present without meningitis with a much less specific rash. A high fever and neutrophilia would be expected to accompany this.

B Erythema multiforme

Audio Video Share Participants 1 More

signs such as headache, neck stiffness and photophobia in true meningitis, and the classical associated rash is purpuric. It should be noted that meningococcal septicaemia may present without meningitis with a much less specific rash. A high fever and neutrophilia would be expected to accompany this.

B	Erythema multiforme

This presents with target lesions mostly at acral sites. It commonly affects the oral mucosa. It is a reactive condition but is most closely associated with infection rather than a drug cause.

D	Fixed drug eruption

This leads to one or more discrete macules or plaques, sometimes with central blistering, following exposure to the causative drug; on re-challenge, the lesions reappear at exactly the same site.

11:28

MyPastest
https://mypastest.pastest.com

Pastest+

On examination, he had a raised body mass index (BMI) of 35 and fluctuant nodules, abscesses and sinus tracts.

Which of the following skin structures are present in the axillary and anogenital region and are involved in the pathogenesis of this condition?

A Arrector pili muscles

B Sebaceous glands

C Apocrine glands

D Meibomian glands

E Eccrine glands

11:29

C	Apocrine glands

The answer is Apocrine glands (Option C).

Apocrine glands are found mainly in the axillae, anogenital region, breast, eyelids and external auditory canal. They produce an oily secretion of protein, carbohydrate, ammonia and lipids. They become active in puberty and are innervated by sympathetic nerves. The action of bacteria on these secretions produces body odour.

B	Sebaceous glands

Sebaceous glands (Option B) is incorrect.

Sebaceous glands secrete lipid-rich sebum with emollient, as well as antimicrobial properties. The size of the gland varies in different body parts, being biggest on the face, chest and back. Blockage of the ducts of these glands causes acne.

A	Arrector pili muscles

Arrector pili muscles (Option A) is incorrect.

The suspected diagnosis in this patient is hidradenitis suppurativa (HS). It presents with boils and abscesses, rope-like scarring, sinus-tract formation, pain and discharge.

Arrector pili are small muscles attached to hair follicles that cause erection of the hairs on exposure to cold or fear.

D	Meibomian glands

Meibomian glands (Option D) is incorrect.

Meibomian glands are a kind of sebaceous gland found at the rim of the eyelids inside the tarsal plate, responsible for the supply of meibum, an oily substance that prevents

suppurativa (HS). It presents with boils and abscesses, rope-like scarring, sinus-tract formation, pain and discharge.

Arrector pili are small muscles attached to hair follicles that cause erection of the hairs on exposure to cold or fear.

D	Meibomian glands

Meibomian glands (Option D) is incorrect.

Meibomian glands are a kind of sebaceous gland found at the rim of the eyelids inside the tarsal plate, responsible for the supply of meibum, an oily substance that prevents evaporation of the eye's tear film.

E	Eccrine glands

Eccrine glands (Option E) is incorrect.

Eccrine glands cover most of the body surface but are most numerous on the palms and soles. They consist of a secretory coil, deep in the dermis, attached to a duct that conveys sweat to the surface of the skin. They are innervated by the sympathetic nervous system and secrete water, electrolytes, lactate, ammonia and urea. Sweat helps to regulate body temperature and may have antimicrobial properties.

Rate this question:

A 17-year-old boy presents with a 6-month history of an itchy scalp. It began as a few discrete, scaly lesions on his scalp. He was then prescribed griseofulvin by his general practitioner, which he took for a month. Since then, he has continued to have itching and scaling over the scalp.

His mother is very anxious as she thinks his hair is thinning in places. More recently, his 8-year-old sister has been scratching her scalp, too.

On examination, there is extensive scaling with excoriations in some areas. There is associated mild, patchy alopecia, but no visible inflammation. There are no rashes elsewhere, nor nail changes.

What is the correct diagnosis?

A	Eczema
B	Head lice
C	Psoriasis
D	Scabies
E	Tinea capitis

6325

Submit

Previous Q... Skip Questi...

11:32
On
594-042-7551
Leave

A 17-year-old boy presents with a 6-month history of an itchy scalp. It began as a few discrete, scaly lesions on his scalp. He was then prescribed griseofulvin by his general practitioner, which he took for a month. Since then, he has continued to have itching and scaling over the scalp.

His mother is very anxious as she thinks his hair is thinning in places. More recently, his 8-year-old sister has been scratching her scalp, too.

On examination, there is extensive scaling with excoriations in some areas. There is associated mild, patchy alopecia, but no visible inflammation. There are no rashes elsewhere, nor nail changes.

What is the correct diagnosis?

Your answer was incorrect

A Eczema

B Head lice

C Psoriasis

D Scabies

E Tinea capitis

Explanation

Audio Video Share Participants More

11:33

tinea capitis

ALL IMAGES NEWS SHOPPING VIDEOS BOOKS MAPS FL

Latest GIF HD Product

scalp ringworm black dot alopecia

Tinea capitis - Wikipedia
en.wikipedia.org

Tinea capitis | DermNet NZ
dermnetnz.org

Tinea Capitis: Background ...
emedicine.medscape.com

Ringworm - NHS
nhs.uk

Tinea Capitis: Background ...
emedicine.medscape.com

Discover Updates Search Rec

E Tinea capitis

The presentation is typical of tinea capitis or scalp ringworm. This dermatophyte infection mostly occurs in younger children. Pruritus is variable. The level of inflammation depends to some extent on the causative organism. Scaling and alopecia are typical features. The infection is contagious so it is not surprising that a sibling has been affected. Topical treatment is ineffective for tinea capitis, though ketoconazole shampoo is used to reduce the chances of transmission. Griseofulvin is fungistatic, so a prolonged course of 2-4 months is required. Although not licensed in young children, a four-week course of the fungicidal drug terbinafine is often preferred.

C Psoriasis

This presents with marked erythema or very pronounced scaling; alopecia is very unusual.

A Eczema

It would be unusual for this to affect only the scalp and it does not give rise to alopecia.

B Head lice

Whilst this is a common infestation in children and associated with much pruritus, it does not give rise to focal alopecia.

D Scabies

This presents with much more widespread pruritus and, except in young babies or very incapacitated adults, spares the scalp.

11:35

A 26-year-old woman, currently in the second trimester of pregnancy, presented with a lesion on her right thumb. This started 5 weeks ago and has grown rapidly. She remembers getting her thumb caught on a rose bush in the garden. The lesion is not particularly painful, but is a nuisance as it gets caught on clothes and bleeds profusely.

What is the likely diagnosis?

A	Pyoderma gangrenosum
B	Pyogenic granuloma
C	Squamous cell carcinoma
D	Keloid scar
E	Viral wart

38521

Submit

Rana Alnasser's screen

11:37
On 594-042-7551 Leave

E	Viral wart

Explanation

B	Pyogenic granuloma

Pyogenic granuloma (PG) is a benign vascular skin tumour that commonly presents at the site of a penetrating injury. Pregnancy is a risk factor. There is a history of rapid growth on previously normal skin. A history of a 'mole' at the site, where the lesion arose should alert the clinician to the possibility of alternative diagnoses such as amelanotic malignant melanoma, is common. Commonly used options for treatment include curettage with cautery and cryotherapy.

A	Pyoderma gangrenosum

Pyoderma gangrenosum is a condition associated with the development of painful, ulcerated, necrotic lesions, seen on the legs and around surgical wounds.

C	Squamous cell carcinoma

Squamous cell carcinoma (SCC) is rarer and very unlikely to present in a young woman with type 6 skin (Fitzpatrick scale).

Fitzpatrick skin type classification:

Skin Type	Typical Features	Tanning Ability
1	Pale white skin, blue/hazel eyes, blonde/red hair	Always burns, does not tan
2	Fair skin, blue eyes	Burns easily, tans poorly

Audio Video Share Participants More

11:38
On 594-042-7551 Leave

3	Darker white skin	Tans after initial burn
4	Light brown skin	Burns minimally, tans easily
5	Brown skin	Rarely burns, tans darkly easily
6	Dark brown or black skin	Never burns, always tans darkly

D Keloid scar

Keloid scars don't protrude and a significant increase in size wouldn't be expected so long after the initial insult.

E Viral wart

The degree of protuberance seen here would be unusual for a viral wart, as would the speed of growth seen here over only 5 weeks.

Rate this question:

Next Question

Previous Q... Tag Questi... Feedback End Session

© Pastest 2019

Audio Video Share Participants More

11:38

An 18-year-old woman presents with a weepy, itchy flexural rash. She has been using potent topical steroids for 6 months, without much benefit.

She thinks she may be allergic to her washing powder. The itching is keeping her awake at night.

What is the next management step?

A	Oral Prednisolone
B	Topical calcineurin inhibitors
C	Skin prick testing
D	Counselling to help break the scratch itch cycle
E	Topical Calcipotriol

Rana Alnasser's screen

Explanation

B Topical calcineurin inhibitors

Topical calcineurin inhibitors e.g. tacrolimus/pimecrolimus are often used as a steroid alternative, when steroids have stopped working (often due to steroid resistance). They should not be used in pregnancy because of systemic toxicity shown in patients receiving them by the oral route.

D Counselling to help break the scratch itch cycle

Counselling alone is very unlikely to improve this patients' severe atopic eczema.

A Oral Prednisolone

Given the efficacy of steroid sparing topical therapies such as tacrolimus, the benefit risk profile of oral prednisolone versus other options is not considered positive.

C Skin prick testing

Skin prick testing is not usually helpful in identifying a precipitating allergen in atopic eczema.

E Topical Calcipotriol

Calcipotriol is a standard therapy for the treatment of psoriasis, not for eczema.

39054

Rate this question:

Next Question

11:42

contact dermatitis

Allergic Contact Dermatitis (Arm ...
medicinenet.com

medicalnewstoday.com

Contact Dermatitis - YouTube
youtube.com

What Is Contact Dermatitis|Irritant ...
allergystore.com

Allergic Contact Dermatitis Treatment ...
norrisderm.com

Picture of Nickel Contact Dermatitis
webmd.com

Contact Dermatitis | Symptoms ...
aaaai.org

Related Searches

- face contact dermatitis ›
- hand contact dermatitis ›
- contact dermatitis mild ›
- contact dermatitis treatment ›

Rana Alnasser's screen

Search

11:42

Google

contact dermatitis hands

ALL IMAGES SHOPPING VIDEOS NEWS BOOKS MAPS

Latest GIF HD Product

irritant | allergic reaction | rash | irritant contact | dry hands

Management of contact dermatitis | GPonline
gponline.com

Dry Hands, Peel, Contact Dermatitis ...
123rf.com

Contact Dermatitis: Causes, Symptoms ...
healthline.com

Irritant contact dermatitis (ICD) - ACD
dermcoll.edu.au

Health& - Contact dermatitis
healthand.com

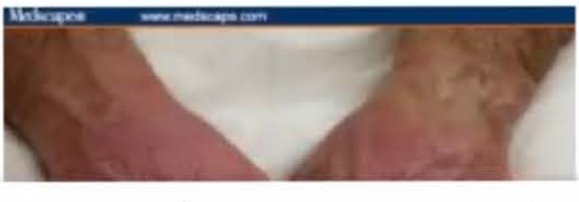

Hand Dermatitis: Clinical Features ...
medscape.com

Discover Updates Search

11:43
On
594-042-7551
Leave

contact dermatitis hands

Hand Dermatitis – exederm
exederm.com

Hand dermatitis | DermNet NZ
dermnetnz.org

Contact Dermatitis - Rash On Skin ...
rashonskin.com

Contact Dermatitis | New Health Guide

Preventing Occupational Skin Disorders ...
lhsfna.org

Product

Dry Hands, Peel, Contact Dermatitis ...
123rf.com

Product

Dry Hands, Peel, Contact Dermatitis ...
123rf.com

Audio
Discover
Video
Updates
Share
Participants
Search
More

11:44
On
594-042-7551
Leave

contact dermatitis flexures

Treatment Options for Atopic Dermatitis ...
aafp.org

Contact Dermatitis, Devices/Implants ...
clinicaladvisor.com

Eczema and Atopic Dermatitis | World ...
worldallergy.org

dermatitis from safety boots ...
researchgate.net

Pediatric Atopic Dermatitis: Background ...
emedicine.medscape.com

Intertrigo | DermNet NZ
dermnetnz.org

Related Searches

- eczema elbow
- atopic dermatitis treatment
- atopic eczema

Discover
Updates
Search
Audio
Video
Share
Participants
More

11:44
On
594-042-7551
Leave

A 45-year-old gentleman presented with flat pigmented patches over his flanks and gums. He has been treated over the past few months for a pustular rash around his nose.

Which of the following drugs is most likely to be responsible?

A	Minocycline
B	Erythromycin
C	Prednisolone
D	Co-trimoxazole
E	Flucloxacillin

Submit

Audio
Video
Share
Participants
More

B Erythromycin

Erythromycin may be associated with skin eruptions, itching and urticaria, not with skin pigmentation.

C Prednisolone

Prednisolone use over a chronic period is associated with weight gain and skin thinning, rather than the hyperpigmentation seen here.

D Co-trimoxazole

Co-trimoxazole is associated with skin rashes and photosensitivity, rather than the hyperpigmentation seen here.

E Flucloxacillin

Flucloxacillin is associated with non-specific skin rashes, urticarial and purpura, rather than the blue/black/grey discoloration seen here.

Rate this question:

Next Question

© Pastest 2019

Rana Alnasser's screen

11:45

A 69-year-old man with non-Hodgkin's lymphoma, currently in remission, was admitted with pneumonia. He was given tazocin IV. Two days later, he developed an erythematous maculo-papular rash all over his body.

The next day, a student nurse fast bleeps you to the ward as she noticed that his skin was 'falling off' as she was turning him over. You arrive to see him in a puddle of fluid, with sheets of skin loss and other areas of dusky skin necrosis. His conjunctivae are red and his mouth has multiple blisters.

What is the most likely underlying pathophysiology of this mucocutaneous drug reaction?

A	Cytotoxic IgG or IgM antibodies
B	Drug-antibody immune complex
C	T cell mediated delayed hypersensitivity
D	Cytotoxic T cells and apoptosis
E	IgE-mediated reaction involving release of histamine from mast cells

58315

Submit

Rana Alnasser's screen

11:46

A 69-year-old man with non-Hodgkin's lymphoma, currently in remission, was admitted with pneumonia. He was given tazocin IV. Two days later, he developed an erythematous maculo-papular rash all over his body.

The next day, a student nurse fast bleeps you to the ward as she noticed that his skin was 'falling off' as she was turning him over. You arrive to see him in a puddle of fluid, with sheets of skin loss and other areas of dusky skin necrosis. His conjunctivae are red and his mouth has multiple blisters.

What is the most likely underlying pathophysiology of this mucocutaneous drug reaction?

Your answer was incorrect

A	Cytotoxic IgG or IgM antibodies
B	Drug-antibody immune complex
C	T cell mediated delayed hypersensitivity
D	Cytotoxic T cells and apoptosis
E	IgE-mediated reaction involving release of histamine from mast cells

Explanation

D	Cytotoxic T cells and apoptosis

toxic epidermal necrolysis

Rana Alnasser's screen

11:49
On 594-042-7551 Leave

A Cytotoxic IgG or IgM antibodies

B Drug-antibody immune complex

C T cell mediated delayed hypersensitivity

D Cytotoxic T cells and apoptosis

E IgE-mediated reaction involving release of histamine from mast cells

Explanation

D Cytotoxic T cells and apoptosis

The description is of classic toxic epidermal necrolysis (TEN), which is mediated by an early cytotoxic T-cell response followed by Fas ligand binding to Fas (death receptors) on keratinocytes, which trigger apoptosis.

C T cell mediated delayed hypersensitivity

T-cell-mediated delayed hypersensitivity is a so-called type 4 hypersensitivity reaction, the prime example of which is contact dermatitis.

A Cytotoxic IgG or IgM antibodies

These lead to a type 2 hypersensitivity reaction such as thrombocytopaenic purpura.

B Drug-antibody immune complex

Audio Video Share Participants More

11:49
Calls

D Cytotoxic T cells and apoptosis

The description is of classic toxic epidermal necrolysis (TEN), which is mediated by an early cytotoxic T-cell response followed by Fas ligand binding to Fas (death receptors) on keratinocytes, which trigger apoptosis.

C T cell mediated delayed hypersensitivity

T-cell-mediated delayed hypersensitivity is a so-called type 4 hypersensitivity reaction, the prime example of which is contact dermatitis.

A Cytotoxic IgG or IgM antibodies

These lead to a type 2 hypersensitivity reaction such as thrombocytopaenic purpura.

B Drug-antibody immune complex

Drug-antibody immune complexes lead to a type 3 hypersensitivity reaction such as serum sickness.

E IgE-mediated reaction involving release of histamine from mast cells

This leads to a type 1 hypersensitivity reaction and an anaphylaxis-type reaction.

36315
Rate this question:

Next Question

Audio Video Share Participants More

D Cytotoxic T cells and apoptosis

The description is of classic toxic epidermal necrolysis (TEN), which is mediated by an early cytotoxic T-cell response followed by Fas ligand binding to Fas (death receptors) on keratinocytes, which trigger apoptosis.

C T cell mediated delayed hypersensitivity

T-cell-mediated delayed hypersensitivity is a so-called type 4 hypersensitivity reaction, the prime example of which is contact dermatitis.

A Cytotoxic IgG or IgM antibodies

These lead to a type 2 hypersensitivity reaction such as thrombocytopaenic purpura.

B Drug-antibody immune complex

Drug-antibody immune complexes lead to a type 3 hypersensitivity reaction such as serum sickness.

E IgE-mediated reaction involving release of histamine from mast cells

This leads to a type 1 hypersensitivity reaction and an anaphylaxis-type reaction.

36315

Rate this question:

Rana Alnasser's screen

Explanation

D	Erythema annulare centrifugum

EAC is an idiopathic, chronic, recurrent erythema, which is often seasonal. Triggers can be drugs or infections. Topical steroids usually cause involution of the treated lesions, but they do not prevent the occurrence of new lesions or recurrence of lesions at the original site.

A	Erythema marginatum

Erythema marginatum is characterised by macules that spread into patches associated with acute rheumatic fever (fever, carditis, migratory polyarthritis) caused by group A beta-haemolytic streptococcal infection.

B	Erythema migrans

Erythema migrans develops 7 days after a tick bite and is a sign of Lyme disease. Lesions range from 10-50 cm in diameter and flu-like symptoms are common. Lyme serology is a key investigation when this is identified.

C	Erythema induratum

Erythema induratum of Bazin is a nodular vasculitis (tender erythematous, indurated nodules and plaques), especially on the lower legs, associated with *Mycobacterium tuberculosis*. Further investigations including chest X-ray and sputum culture are recommended when this is identified.

E	Erythema gyratum repens

Erythema gyratum repens is a paraneoplastic skin rash [illegible] erythematous bands like

Rana Alnasser's screen

B Erythema migrans

Erythema migrans develops 7 days after a tick bite and is a sign of Lyme disease. Lesions range from 10-50 cm in diameter and flu-like symptoms are common. Lyme serology is a key investigation when this is identified.

C Erythema induratum

Erythema induratum of Bazin is a nodular vasculitis (tender erythematous, indurated nodules and plaques), especially on the lower legs, associated with *Mycobacterium tuberculosis*. Further investigations including chest X-ray and sputum culture are recommended when this is identified.

E Erythema gyratum repens

Erythema gyratum repens is a paraneoplastic skin rash consisting of urticated, wavy erythematous bands like 'grains of wood' most often associated with carcinoma of the lung. These expand quickly at a rate of up to 1 cm/day.

Rate this question:

Next Question

Previous Q... Tag Questi... Feedback End Session

Blog About Pastest Contact Us Help

© Pastest 2019

A 72-year-old woman attends for results of a recent gastroscopy examination and barium enema. She mentions a rash on her armpit.

On examination, both her axillae have pigmented, velvety, thickened areas.

What is the likely result from her investigations?

A	Coeliac disease
B	Crohn's disease
C	Gastric adenocarcinoma
D	*Helicobacter pylori* infection
E	Ulcerative colitis

Submit

Previous Q... Skip Questi...

© Pastest 2019

11:51
On
594-042-7551
Leave

A 72-year-old woman attends for results of a recent gastroscopy examination and barium enema. She mentions a rash on her armpit.

On examination, both her axillae have pigmented, velvety, thickened areas.

What is the likely result from her investigations?

Your answer was correct

A Coeliac disease

B Crohn's disease

C Gastric adenocarcinoma

D *Helicobacter pylori* infection

E Ulcerative colitis

Explanation

C Gastric adenocarcinoma

The above is a typical description of acanthosis nigricans, which is most commonly associated with gastric adenocarcinoma. Other associations include obesity and diabetes mellitus.

A Coeliac disease

Coeliac disease is not associated with the above rash but is

Audio Video Share Participants More

11:51

C Gastric adenocarcinoma

The above is a typical description of acanthosis nigricans, which is most commonly associated with gastric adenocarcinoma. Other associations include obesity and diabetes mellitus.

A Coeliac disease

Coeliac disease is not associated with the above rash but is closely linked with dermatitis herpetiformis (an intensely itchy vesicular eruption).

B Crohn's disease

Crohn's disease is associated with erythema nodosum and pyoderma gangrenosum, as well as extraintestinal Crohn's deposits.

D *Helicobacter pylori* infection

Neither *H. pylori* infections nor any associated gastric ulcers are linked with any specific cutaneous manifestations.

E Ulcerative colitis

Like Crohn's disease, ulcerative colitis is also associated with erythema nodosum and pyoderma gangrenosum, but not with acanthosis nigricans.

Rate this question:

Next Question

Rana Alnasser's screen

11:51

A 33-year-old Afro-Caribbean woman presents with a history of hair loss on her scalp without any regrowth. She is systemically well and denies any other symptoms.

Clinical examination revealed several patches of alopecia associated with scarring. There is no loss of hair anywhere else on her body but some erythematous plaques are also noted on the patient's ears and cheeks.

Which of the following is the most likely diagnosis?

A	Alopecia areata
B	Hypothyroidism
C	Trichotillomania
D	Female-pattern alopecia
E	Discoid lupus erythematosus

Submit

Previous Q... Skip Questi...

© Pastest 2019

Rana Alnasser's screen

A 33-year-old Afro-Caribbean woman presents with a history of hair loss on her scalp without any regrowth. She is systemically well and denies any other symptoms.

Clinical examination revealed several patches of alopecia associated with scarring. There is no loss of hair anywhere else on her body but some erythematous plaques are also noted on the patient's ears and cheeks.

Which of the following is the most likely diagnosis?

Your answer was correct

A	Alopecia areata
B	Hypothyroidism
C	Trichotillomania
D	Female-pattern alopecia
E	Discoid lupus erythematosus

Explanation

E	Discoid lupus erythematosus

In scarring alopecia destruction of the hair follicles has occurred and therefore hair loss is permanent. Common causes include discoid lupus erythematosus, lichen planus/frontal fibrosing alopecia, and kerion from fungal infection.

Explanation

E	Discoid lupus erythematosus

In scarring alopecia destruction of the hair follicles has occurred and therefore hair loss is permanent. Common causes include discoid lupus erythematosus, lichen planus/frontal fibrosing alopecia, and kerion from fungal infection.

A	Alopecia areata

Alopecia areata is an autoimmune condition associated with non-scarring, localised hair loss in circular patterns. Alopecia totalis describes widespread involvement of the same process with loss of all scalp hair and eyebrows, while alopecia universalis describes complete loss of all body hair.

B	Hypothyroidism

Hypothyroidism is a cause of sparse and brittle hair and nails, and is also linked to hair loss in the lateral third of the eyebrows.

C	Trichotillomania

Trichotillomania describes a psychological disorder where patients are compelled to pull their own hair, resulting in alopecia. It is typically encountered in teenage females, leading to irregular patches of alopecia that are not commonly associated with a scarring process unless encountered in chronic, severe forms.

D	Female-pattern alopecia

Female-pattern (androgen-dependant) alopecia is

Alopecia areata is an autoimmune condition associated with non-scarring, localised hair loss in circular patterns. Alopecia totalis describes widespread involvement of the same process with loss of all scalp hair and eyebrows, while alopecia universalis describes complete loss of all body hair.

B Hypothyroidism

Hypothyroidism is a cause of sparse and brittle hair and nails, and is also linked to hair loss in the lateral third of the eyebrows.

C Trichotillomania

Trichotillomania describes a psychological disorder where patients are compelled to pull their own hair, resulting in alopecia. It is typically encountered in teenage females, leading to irregular patches of alopecia that are not commonly associated with a scarring process unless encountered in chronic, severe forms.

D Female-pattern alopecia

Female-pattern (androgen-dependant) alopecia is associated with diffuse thinning of hair on the scalp due to increased hair shedding or a reduction in hair volume, or both.

85%

Rate this question:

A 62-year-old man presents with this nail lesion, which is diagnosed as a squamous cell carcinoma of the nail.

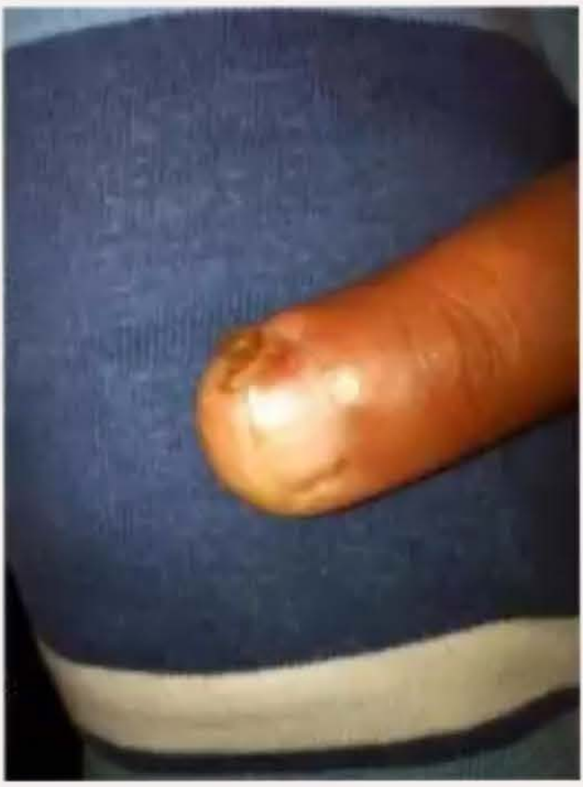

Which of the following viruses is most likely to be the cause?

A HPV 2

B HPV 16

C HPV 4

D Pox virus

E Coxsackie B virus

Submit

11:54

A 62-year-old man presents with this nail lesion, which is diagnosed as a squamous cell carcinoma of the nail.

Which of the following viruses is most likely to be the cause?

Your answer was correct

A HPV 2

B HPV 16

C HPV 4

D Pox virus

E Coxsackie B virus

Explanation

Rana Alnasser's screen

squamous cell carcinoma, the diagnosis here. Other high risk cancer HPV subtypes include 18, 31 and 45.

A HPV 2

HPV 2 is responsible for common and plantar warts, but is less likely to be a cause of squamous cell carcinoma.

C HPV 4

HPV 4 is the primary cause of plantar warts.

D Pox virus

Pox viruses are responsible for development of molluscum contagiosum, not for nail related squamous cell carcinoma.

E Coxsackie B virus

Coxsackie B is a pathogenic enterovirus and is not linked to the development of nail changes.

Rate this question:

Next Question

Previous Q... Tag Questi... Feedback End Session

Blog About Pastest Contact Us Help

© Pastest 2019

A 19-year-old woman presents with a lower gastrointestinal (GI) haemorrhage. On colonoscopy, she is found to have multiple colonic polyps. An upper GI tract endoscopy reveals no significant abnormality.

She has increased pigmentation on her face, as shown on the image below.

How often should upper GI endoscopy be repeated in this patient?

A	6-monthly
B	Yearly
C	3-yearly
D	5-yearly
E	Only if she has symptoms

Submit

C 3-yearly

In this patient with no significant upper GI tract abnormality, repeat screening for the development of an upper GI tract cancer is only necessary every three years. The peri-oral pigmentation here is consistent with a diagnosis of Peutz–Jeghers syndrome. Peutz–Jeghers is caused by mutations in either the *SMAD4* or the *BMPR1A* gene, and *SMAD4* mutations are less likely to lead to upper GI cancers. In this case, a colonoscopy should be performed yearly due to the presence of lower GI polyps.

A 6-monthly

Even if polyps were identified on upper GI tract endoscopy, 6-monthly endoscopy is excessively frequent and may drive inappropriate use of resources while increasing patient anxiety.

B Yearly

Yearly endoscopy is only indicated if there are abnormalities identified on upper GI endoscopy, which is not the case here. In contrast, the polyps identified on lower GI endoscopy should drive yearly colonoscopy.

D 5-yearly

Given the aetiology of Peutz–Jeghers, waiting five years for a repeat upper GI endoscopy risks the development of a gastric or oesophageal cancer in the intervening period.

E Only if she has symptoms

Given late presentation of upper GI cancers, and the

11:58

A 25-year-old female patient attends your surgery with severe nodular-cystic acne. She has tried multiple courses of antibiotics, and topical solutions and has read about Roaccutane (isotretinoin) on the Internet. She is concerned about the side effects and wishes to discuss them with you.

Which of the following would you warn her about?

A	Hair loss is commonly seen in association with therapy
B	LDL cholesterol is commonly increased
C	Low mood is commonly seen in association with therapy
D	She must control her weight because benign intracranial hypertension is commonly seen
E	Patients taking the drug very commonly become anaemic

Submit

Rana Alnasser's screen

12:00
https://mypastest.pastest.com

E Patients taking the drug very commonly become anaemic

Thrombocytopenia, anaemia, thrombocytosis and an increase in ESR are commonly associated with isotretinoin therapy.

D She must control her weight because benign intracranial hypertension is commonly seen

BIH, decreased consciousness and seizures are reported in association with isotretinoin, but these are very rare occurrences.

A Hair loss is commonly seen in association with therapy

Alopecia is seen in association with isotretinoin treatment, but thankfully it is rarely seen.

B LDL cholesterol is commonly increased

An insulin-resistant picture of lipid abnormalities is seen in patients taking isotretinoin, with an increase in triglycerides and a decrease in HDL cholesterol.

C Low mood is commonly seen in association with therapy

Low mood is seen in association with isotretinoin, as is frank depression, but thankfully these are rarely associated with treatment.

Rate this question:

Rana Alnasser's screen

A 27-year-old woman presents with a 9-month history of headaches and a worsening rash on her face. Her appetite has increased a little, and although she has always been overweight, she is concerned that this has further increased over the past year or so.

Her BMI is 31. Blood pressure is 152/89 mmHg, pulse is 74 bpm and regular. A fasting blood glucose is 6.0 mmol/l. She has severe facial acne, as shown in the photograph below:

Which underlying diagnosis should you consider?

A	Congenital adrenal hyperplasia
B	Systemic lupus erythematosus (SLE)
C	Hypothyroidism
D	Sarcoidosis
E	Polycystic ovarian syndrome (PCOS)

12:04

MyPastest
https://mypastest.pastest.com

A Congenital adrenal hyperplasia

B Systemic lupus erythematosus (SLE)

C Hypothyroidism

D Sarcoidosis

E Polycystic ovarian syndrome (PCOS)

Explanation

E Polycystic ovarian syndrome (PCOS)

Acne presenting at beyond aged 20 years should always prompt investigation of a possible secondary cause. Acne accompanying polycystic ovarian syndrome is caused by modestly raised circulating androgen levels. It should always be considered in obese females with oligomenorrhoea, secondary amenorrhoea or infertility. Glucose intolerance, (note the glucose is at the very upper end of the normal fasting range), dyslipidaemia and hypertension may be other features. Weight loss is the most important intervention.

A Congenital adrenal hyperplasia

Non-classical adrenal hyperplasia can present with later features of hyperandrogenism rather than the usual salt wasting in infancy, but it is significantly rarer than PCOS.

Explanation

E	Polycystic ovarian syndrome (PCOS)

Acne presenting at beyond aged 20 years should always prompt investigation of a possible secondary cause. Acne accompanying polycystic ovarian syndrome is caused by modestly raised circulating androgen levels. It should always be considered in obese females with oligomenorrhoea, secondary amenorrhoea or infertility. Glucose intolerance, (note the glucose is at the very uppe end of the normal fasting range), dyslipidaemia and hypertension may be other features. Weight loss is the most important intervention.

A	Congenital adrenal hyperplasia

Non-classical adrenal hyperplasia can present with later features of hyperandrogenism rather than the usual salt wasting in infancy, but it is significantly rarer than PCOS.

B	Systemic lupus erythematosus (SLE)

SLE is associated with a photosensitive erythematous ras rather than the acneiform picture seen here.

C	Hypothyroidism

Hypothyroidism is associated with a 'peaches and cream' complexion and brittle hair with areas of hair loss, rather than the picture seen here.

D	Sarcoidosis

Sarcoidosis is associated with erythema nodosum rather than an acneiform skin rash like that seen here. The

Rana Alnasser's screen

E Polycystic ovarian syndrome (PCOS)

Acne presenting at beyond aged 20 years should always prompt investigation of a possible secondary cause. Acne accompanying polycystic ovarian syndrome is caused by modestly raised circulating androgen levels. It should always be considered in obese females with oligomenorrhoea, secondary amenorrhoea or infertility. Glucose intolerance, (note the glucose is at the very uppe end of the normal fasting range), dyslipidaemia and hypertension may be other features. Weight loss is the most important intervention.

A Congenital adrenal hyperplasia

Non-classical adrenal hyperplasia can present with later features of hyperandrogenism rather than the usual salt wasting in infancy, but it is significantly rarer than PCOS.

B Systemic lupus erythematosus (SLE)

SLE is associated with a photosensitive erythematous ras rather than the acneiform picture seen here.

C Hypothyroidism

Hypothyroidism is associated with a 'peaches and cream' complexion and brittle hair with areas of hair loss, rather than the picture seen here.

D Sarcoidosis

Sarcoidosis is associated with erythema nodosum rather than an acneiform skin rash like that seen here. The absence of other features of sarcoidosis, such as a dry cough or hypercalcaemia, also counts against this as the underlying diagnosis.

Rana Alnasser's screen

12:06
On
PasTest
594-042-7551

A 52 year old man comes to the Dermatology Clinic for review. He has severe psoriasis which has failed to respor adequately to topical steroids, calcipotriol and acitretin.

On examination of his hands, you note nail pitting and evidence of distal inflammatory arthritis. His back and arn are shown below.

Which of the following is the most appropriate next step

A	Oral prednisolone
B	Oral methotrexate
C	Subcutaneous infliximab
D	Oral cyclosporine
E	Oral azathioprine

3909

Submit
Audio
Video
Share
Participants
More

12:06

594-042-7551

A 52 year old man comes to the Dermatology Clinic for review. He has severe psoriasis which has failed to respor adequately to topical steroids, calcipotriol and acitretin.

On examination of his hands, you note nail pitting and evidence of distal inflammatory arthritis. His back and arn are shown below.

Which of the following is the most appropriate next step

Your answer was correct

A	Oral prednisolone
B	Oral methotrexate
C	Subcutaneous infliximab
D	Oral cyclosporine
E	Oral azathioprine

Explanation

Audio Video Share Participants More

594-042-7551

A Oral prednisolone

Oral prednisolone may impact on the inflammatory component of psoriasis, although the benefit risk of systemic steroids isn't favourable versus other potential second line agents such as methotrexate.

C Subcutaneous infliximab

Biologicals targeting TNF-alpha, such as infliximab are th intervention of choice where control of psoriasis isn't gained with a typical second line agent.

D Oral cyclosporine

Oral cyclosporine is more commonly used in the treatmen of atopic dermatitis which fails to respond to corticosteroids alone.

E Oral azathioprine

Azathioprine is an alternative agent to methotrexate for t treatment of psoriasis but may be less effective in managing psoriatic arthritis.

Rate this question:

Next Question

12:06
On
PasTest
594-042-7551

Leave

A 23-year-old hiker has returned from a recent holiday in Austria with a spreading rash. He also complains of achin knee joints. He suffered at least two tick bites where he removed the parasites himself.

Given the likely diagnosis, what would be the most appropriate treatment?

A	Doxycycline 100 mg twice daily (bd)
B	Ciprofloxacin 500 mg once daily (od)
C	Prednisolone 50 mg od
D	Topical hydrocortisone 1%
E	No treatment

Audio
Video
Share
Participants
More

12:07
On
594-042-7551
Leave

A 23-year-old hiker has returned from a recent holiday in Austria with a spreading rash. He also complains of aching knee joints. He suffered at least two tick bites where he removed the parasites himself.

Given the likely diagnosis, what would be the most appropriate treatment?

A	Doxycycline 100 mg twice daily (bd)
B	Ciprofloxacin 500 mg once daily (od)
C	Prednisolone 50 mg od
D	Topical hydrocortisone 1%
E	No treatment

Submit
Audio
Video
Share
Participants
More

12:07
On
594-042-7551
Leave

Pastest+

A 23-year-old hiker has returned from a recent holiday in Austria with a spreading rash. He also complains of aching knee joints. He suffered at least two tick bites where he removed the parasites himself.

Given the likely diagnosis, what would be the most appropriate treatment?

Your answer was correct

A	Doxycycline 100 mg twice daily (bd)
B	Ciprofloxacin 500 mg once daily (od)
C	Prednisolone 50 mg od
D	Topical hydrocortisone 1%
E	No treatment

Explanation

Audio
Video
Share
Participants
More

A Doxycycline 100 mg twice daily (bd)

The diagnosis is Lyme disease as a result of infection by *Borrelia burgdorferi*, which is transmitted to humans by tick bites. The associated diagnostic rash is erythema chronicum migrans. This appears at the site of the tick bite in about 90% of patients, on average around 9 days after the inoculation. There is an enlarging ring formation, which may clear in the centre, leaving a target-like morphology. Dissemination may lead to arthritis (57%), neural involvement (18%) and heart disease, in particular conduction defects (10%). Most non-disseminated disease responds well to oral antibiotics.

B Ciprofloxacin 500 mg once daily (od)

Ciprofloxacin is not used in the treatment of Lyme disease. Antibiotics used for erythema migrans include doxycycline, amoxicillin and cefuroxime. Second-line treatments are the macrolides azithromycin and erythromycin. Intravenous (IV) penicillins and cephalosporins may be used for more advanced Lyme disease.

C Prednisolone 50 mg od

Oral steroids are not used in the management of Lyme disease. Instead, steroidal therapy can suppress the immune system, allowing the bacteria to flourish, rather than attacking the infection.

D Topical hydrocortisone 1%

Topical steroids, such as hydrocortisone (mild potency), are not of help in the treatment of this infectious condition.

E No treatment

12:09

ema migrans

HD Product

lyme disease

multiple

erythema multiforme

dentification ...

Erythema migrans - Wikipedia
en.wikipedia.org

Erythema migrans
en.wikipedia.org

m) migrans - the ...

Erythema Migrans - Lyme Disease Community
lymeforums.org


9-year-old boy afte
researchgate.net

dentification ...

Lyme Disease Rash
cdc.gov

Erythema migrans in Lyme disease | CMAJ

Rana Alnasser's screen

Search

Recent

12:09
On
594-042-7551
Leave

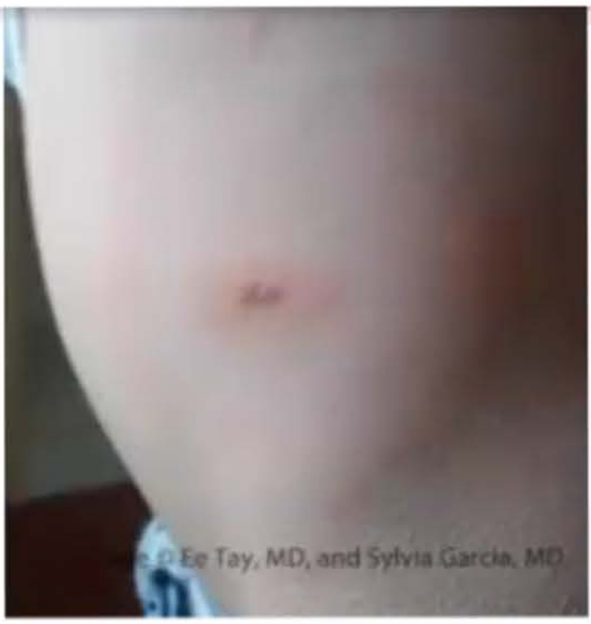

Erythema migrans | Visual Diagnosis
ebmedicine.net

Lyme Disease Action Rashes | Lyme ...
lymediseaseaction.org.uk

Erythema Chronicum Migrans - an ...
sciencedirect.com

Erythema migrans. | Download Scientifi
researchgate.net

Related Searches

erythema multiforme erythema migrans

erythema migrans tongue

erythema migrans causes

disseminated erythema migran

Erythema migrans refers to the rash ...
pinterest.com

Erythema migrans of Lyme's Disease
sciencephoto.com

Collecti
Audio
Video
Share
Participants
More

12:09
On
MyPastest
https://mypastest.com/
594-042-7551
Leave

C Prednisolone 50 mg od

Oral steroids are not used in the management of Lyme disease. Instead, steroidal therapy can suppress the immune system, allowing the bacteria to flourish, rather than attacking the infection.

D Topical hydrocortisone 1%

Topical steroids, such as hydrocortisone (mild potency), are not of help in the treatment of this infectious condition

E No treatment

Erythema chronicum migrans disappears spontaneously within 3–4 weeks. If left untreated, the disease may disseminate, affect other organs and progress to the next stage, which can include neurological symptoms and arthritis.

Rate this question:

Next Question

© Pastest 2019

Audio Video Share Participants More

12:09
On
Pastest
594-042-7551

Leave

A 41-year-old man presents to the General Medical Clinic complaining of changes to his nose which are not subsiding. He has noticed his nose changing in colour without any other symptoms over a few months. Other than this, he has been feeling well in himself.

He has a past medical history of a prolapsed lumbar disc and type 2 diabetes. He takes no regular medications.

A photograph of his nose is shown below.

Multiple investigations are requested, including routine blood tests, a chest X-ray, electrocardiogram (ECG) and echocardiogram, but no abnormalities are detected.

What is the most appropriate medical treatment for this patient?

A Topical metronidazole

B Corticosteroids

C Flucloxacillin

D Metformin

Audio
Video
Share
Participants
More

He has a past medical history of a prolapsed lumbar disc and type 2 diabetes. He takes no regular medications.

A photograph of his nose is shown below.

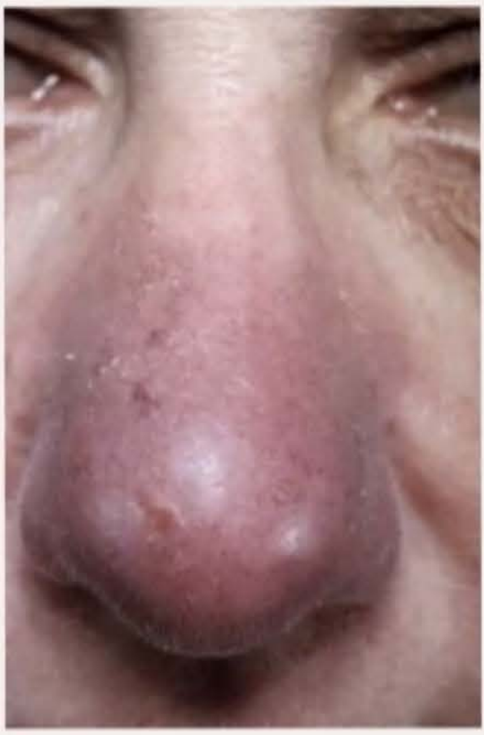

Multiple investigations are requested, including routine blood tests, a chest X-ray, electrocardiogram (ECG) and echocardiogram, but no abnormalities are detected.

What is the most appropriate medical treatment for this patient?

A	Topical metronidazole
B	Corticosteroids
C	Flucloxacillin
D	Metformin
E	Surgical referral

Rana Alnasser's screen

12:10

MyPastest
https://mypastest.pastest.com

A 41-year-old man presents to the General Medical Clinic complaining of changes to his nose which are not subsiding. He has noticed his nose changing in colour without any other symptoms over a few months. Other than this, he has been feeling well in himself.

He has a past medical history of a prolapsed lumbar disc and type 2 diabetes. He takes no regular medications.

A photograph of his nose is shown below.

Multiple investigations are requested, including routine blood tests, a chest X-ray, electrocardiogram (ECG) and echocardiogram, but no abnormalities are detected.

What is the most appropriate medical treatment for this patient?

Your answer was incorrect

A Topical metronidazole

Rana Alnasser's screen

Explanation

B Corticosteroids

This patient has lupus pernio without any other evidence of systemic sarcoidosis. Lupus pernio is a form of cutaneous sarcoidosis which typically presents with an asymptomatic violaceous set of nodules and plaques over the nose, cheek and/or ears. It more commonly affects women and patients of African American descent. Sarcoidosis is a chronic cell-mediated response to an unknown antigen in which macrophages and CD4 cells release cytokines that cause granulomas to form. Biopsy reveals non-caseating granulomas. In 75% of patients, there is pulmonary involvement, making respiratory investigations important. Treatment for lupus pernio can involve topical or systemic steroids, but sometimes requires systemic treatment such as methotrexate, hydroxychloroquine and biological therapy.

E Surgical referral

Surgical referral would be an appropriate consideration if this lesion had appeared malignant. However, such lesions usually present as a single nodule, which is likely to ulcerate. The lack of a specifically defined lesion makes a malignant cause less likely.

A Topical metronidazole

This would have been an appropriate management option for rhinophyma. Rhinophyma is a condition in which the sebaceous glands of the nose are enlarged with erythema of the nose, as well as overlying telangiectasia.

C Flucloxacillin

12:12

lupus pernio

Latest GIF HD Product

sarcoidosis face nose mild

Lupus pernio - Wikipedia
en.wikipedia.org

5 days ago
Lupus pernio | DermNet NZ
dermnetnz.org

What is lupus pernio? - Quora
quora.com

Lupus Pernio - an overview ...
sciencedirect.com

Successful Treatment of Lupus Pernio ...
jamanetwork.com

Lupus pernio | Download Scientific Diagram
researchgate.net

Discover Updates Search

This would have been an appropriate management option for rhinophyma. Rhinophyma is a condition in which the sebaceous glands of the nose are enlarged with erythema of the nose, as well as overlying telangiectasia.

C Flucloxacillin

Flucloxacillin could be considered for cellulitis or simple bacterial dermatological infections. However, this is typically characterised by an acutely inflamed rash arising over a short time, often with systemic involvement. The appearance and history do not match this.

D Metformin

Metformin is a first-line medical treatment for type 2 diabetes mellitus. Diabetes can present with various dermatological complications such as increase in frequency of cellulitis and necrobiosis lipoidica. The latter is characterised by waxy lesions, but even in such cases improving diabetic control does not remove the lesion.

Rate this question:

Previous Q... Tag Questi... Feedback End Session

Blog About Pastest Contact Us Help

© Pastest 2019

A 27-year-old African-American man presents to the Dermatology Clinic for review. He has a disfiguring scar over his upper abdomen, following a laparotomy some six months earlier. The scar is causing him to be severely depressed, and he is currently managed with counselling and antidepressants.

An image of the scar is shown below.

Which of the following is the most appropriate initial intervention?

A	Cryotherapy
B	Intralesional triamcinolone
C	Intralesional 5-fluorouracil (5-FU)
D	Surgical excision
E	Targeted radiotherapy

716-49

Submit

Explanation

B Intralesional triamcinolone

This patient has an extensive keloid scar on his upper abdomen. These are said to occur in up to 16% of patients of African descent. Intralesional steroids flatten and soften the keloid scar and have response rates of > 50%. Where patients fail to respond, other options include 5-FU, and surgery combined with steroid therapy.

A Cryotherapy

Cryotherapy may be used for keloid scars which do not respond to corticosteroids, either alone or in combination. Direct delivery of liquid nitrogen to the scar itself has improved the effectiveness of cryotherapy, and it is now used earlier in the management of keloid tissue.

C Intralesional 5-fluorouracil (5-FU)

Intralesional 5-FU is a second-line medical option for patients who fail to respond to intralesional steroids.

D Surgical excision

Patients who have suffered a keloid scar are much more likely to endure a second episode. Hence surgery is a later treatment option in patients who fail to respond to medical therapy and is combined with steroids in most patients.

E Targeted radiotherapy

Targeted radiotherapy is effective in reducing keloiding, but in a young man, there is concern about its ability to lead to the development of local skin tumours. It is usually

Rana Alnasser's screen

B Intralesional triamcinolone

This patient has an extensive keloid scar on his upper abdomen. These are said to occur in up to 16% of patients of African descent. Intralesional steroids flatten and soften the keloid scar and have response rates of > 50%. Where patients fail to respond, other options include 5-FU, and surgery combined with steroid therapy.

A Cryotherapy

Cryotherapy may be used for keloid scars which do not respond to corticosteroids, either alone or in combination. Direct delivery of liquid nitrogen to the scar itself has improved the effectiveness of cryotherapy, and it is now used earlier in the management of keloid tissue.

C Intralesional 5-fluorouracil (5-FU)

Intralesional 5-FU is a second-line medical option for patients who fail to respond to intralesional steroids.

D Surgical excision

Patients who have suffered a keloid scar are much more likely to endure a second episode. Hence surgery is a later treatment option in patients who fail to respond to medical therapy and is combined with steroids in most patients.

E Targeted radiotherapy

Targeted radiotherapy is effective in reducing keloiding, but in a young man, there is concern about its ability to lead to the development of local skin tumours. It is usually reserved for patients who have undergone surgery for an underlying cancer.

Rana Alnasser's screen

12:16

This 48-year-old woman presented with the rash shown. She has had it for many years, been too embarrassed to come to the doctors and has never shown her skin to anyone, except her GP.

She has been using topical creams including Calcipotriol and topical steroids. She has a history of breast cancer, in remission, type 2 diabetes and chronic kidney disease stage 3.

What would be the next most appropriate management step?

A Ciclosporin

B Methotrexate

C Narrow band UVB

D Skin biopsy

Rana Alnasser's screen

anyone, except her GP.

She has been using topical creams including Calcipotriol and topical steroids. She has a history of breast cancer, in remission, type 2 diabetes and chronic kidney disease stage 3.

What would be the next most appropriate management step?

A	Ciclosporin
B	Methotrexate
C	Narrow band UVB
D	Skin biopsy
E	Skin swab for microscopy, culture and sensitivity

C Narrow band UVB

Narrow band UVB (phototherapy) is the most commonlyused second line treatment for psoriasis, after topical treatment, providing there is no past history of skin cancer. It carries less liability than systemic treatments given this patient's past medical history and is therefore the preferred next therapy choice.

A Ciclosporin

Cyclosporine is an anti-T cell immunosuppressive which can accumulate in renal impairment. Given the history of both cancer and chronic renal impairment, it is best avoided here.

B Methotrexate

Methotrexate interferes with DNA synthesis, as such, like cyclosporine, use in a patient with a past history of cancer should be avoided if possible.

D Skin biopsy

The rash is entirely consistent with psoriasis. As such moving to biopsy risks scarring without adding significantly to the underlying diagnosis.

E Skin swab for microscopy, culture and sensitivity

The image is of typical psoriatic plaques, as such there is no value in MCS in the management of this case.

Rate this question:

A 55-year-old woman complains of painful, sore, erythematous, weeping skin over the right nipple and areola. She has used a potent topical steroid for 2 weeks with no improvement.

On examination of both breasts and axillae, there were no lumps and the left nipple was normal. She said she recently changed her body wash and thinks it may be an allergic reaction.

What is the most appropriate management step?

A	Reassure her that this is contact dermatitis and she should stop using the body wash
B	Prescribe a soap substitute and review in 6 weeks
C	Take a swab for microbiology and prescribe flucloxacillin
D	Refer for skin biopsy
E	Refer for patch testing

38314

Submit

12:24
On MyPastest 594-042-7551 Leave
https://mypastest.pastest.com

step?

Your answer was incorrect

A Ciclosporin

B Methotrexate

C Narrow band UVB

D Skin biopsy

E Skin swab for microscopy, culture and sensitivity

Explanation

C Narrow band UVB

Narrow band UVB (phototherapy) is the most commonlyused second line treatment for psoriasis, after topical treatment, providing there is no past history of skin cancer. It carries less liability than systemic treatments given this patient's past medical history and is therefore the preferred next therapy choice.

A Ciclosporin

Cyclosporine is an anti-T cell immunosuppressive which can accumulate in renal impairment. Given the history of both cancer and chronic renal impairment, it is best avoided here.

Audio Video Share Participants More

12:24

A 60-year-old woman presented with a sudden-onset, widespread, erythematous rash, covering 95% of her body. The rash was precipitated by a course of intravenous (IV) vancomycin which has now been discontinued.

What would you now expect to happen to this rash?

A	Ulceration
B	Desquamation followed by post-inflammatory pigmentation
C	Lichenification
D	Complete resolution to normal skin within 3 weeks
E	Induration and fibrosis

Rana Alnasser's screen

B Desquamation followed by post-inflammatory pigmentation

The diagnosis here is exfoliative dermatitis. The erythematous skin begins to desquamate around days 2-6, and this is followed by pigmentation (similar to tanning after sunburn). The pigmentary change (usually hyper- but can be hypo-) can be permanent, or may resolve after a few months.

D Complete resolution to normal skin within 3 weeks

Pigmentary changes seen after exfoliative dermatitis usually takes a few months to completely resolve.

A Ulceration

Ulceration is seen in Stevens-Johnson syndrome as it progresses, which doesn't fit with the presentation seen here.

C Lichenification

Lichenification is a manifestation of chronic pruritic skin disorders driven by recurrent scratching and epidermal hypertrophy, not with the acute erythroderma seen here.

E Induration and fibrosis

Induration and fibrosis is seen primarily in fibrotic skin diseases such as systemic sclerosis.

Rate this question:

12:26

Google

red man syndrome vancomycin

ALL IMAGES NEWS SHOPPING VIDEOS MAPS BOOKS

Latest GIF HD Product

rash reaction rash early stage sjogren's syndrome drug

Red man syndrome: Symptoms, treatment ...
medicalnewstoday.com

Red man syndrome: Symptoms, treatment ...
medicalnewstoday.com

Rare case of "red man" syndrome in a ...
casereports.bmj.com

Red man" syndrome. | Download ...
researchgate.net

Red Man Syndrome: Causes, Symptoms and ...
doctorshealthpress.com

The diagnosis here is exfoliative dermatitis. The erythematous skin begins to desquamate around days 2-6, and this is followed by pigmentation (similar to tanning after sunburn). The pigmentary change (usually hyper- but can be hypo-) can be permanent, or may resolve after a few months.

D Complete resolution to normal skin within 3 weeks

Pigmentary changes seen after exfoliative dermatitis usually takes a few months to completely resolve.

A Ulceration

Ulceration is seen in Stevens-Johnson syndrome as it progresses, which doesn't fit with the presentation seen here.

C Lichenification

Lichenification is a manifestation of chronic pruritic skin disorders driven by recurrent scratching and epidermal hypertrophy, not with the acute erythroderma seen here.

E Induration and fibrosis

Induration and fibrosis is seen primarily in fibrotic skin diseases such as systemic sclerosis.

A 25-year-old male lawyer attends the Emergency Department with a sudden onset rash. He claims he has been 'run down' recently with a sore mouth and throat and a cough. He is a smoker of 15 cigarettes/day.

On examination, he has several painful erosions on the inside of his lips, an engorged, erythematous throat and a diffuse wheeze. On his palms and forearms, he has several oedematous papules, some of which have small vesicles in their centre, forming a target lesion.

Which of the following is the most likely trigger for his condition?

A	EBV
B	HSV 1
C	Parvovirus B19
D	Influenza
E	Varicella-zoster virus

Submit

12:30

A 25-year-old male lawyer attends the Emergency Department with a sudden onset rash. He claims he has been 'run down' recently with a sore mouth and throat and a cough. He is a smoker of 15 cigarettes/day.

On examination, he has several painful erosions on the inside of his lips, an engorged, erythematous throat and a diffuse wheeze. On his palms and forearms, he has several oedematous papules, some of which have small vesicles in their centre, forming a target lesion.

Which of the following is the most likely trigger for his condition?

Your answer was incorrect

A	EBV
B	HSV 1
C	Parvovirus B19
D	Influenza
E	Varicella-zoster virus

Explanation

B	HSV 1

The targetoid rash described here is classic for erythema multiforme minor. The most common cause is HSV 1. EM minor is considered to be a type 4 hypersensitivity reaction

Rana Alnasser's screen

B HSV 1

The targetoid rash described here is classic for erythema multiforme minor. The most common cause is HSV 1. EM minor is considered to be a type 4 hypersensitivity reaction to a viral or bacterial trigger.
A previous history of EM and male sex are also considered as risk factors. Other common causes are mycoplasma pneumonia, pneumococci, tuberculosis and *Mycobacterium avium* complex. EM minor is acute and self-limiting, but has a tendency to recur. It should be distinguished from EM major, or Stevens-Johnson syndrome, which is most commonly due to a drug cause and is more rapidly progressive and severe.

E Varicella-zoster virus

Chicken pox is associated with a widespread vesicular rash, and shingles with a rash confined to a particular dermatome, neither of which fits with the picture seen here.

A EBV

EBV is associated with pharyngitis and severe tonsillitis rather than the picture seen here.

C Parvovirus B19

Parvovirus B19 is associated with coryzal symptoms and an erythematous facial rash, which leads to its description as 'slapped cheek' disease.

D Influenza

Influenza is associated with upper respiratory tract

Rana Alnasser's screen

A previous history of EM and male sex are also considered as risk factors. Other common causes are mycoplasma pneumonia, pneumococci, tuberculosis and *Mycobacterium avium* complex. EM minor is acute and self-limiting, but has a tendency to recur. It should be distinguished from EM major, or Stevens-Johnson syndrome, which is most commonly due to a drug cause and is more rapidly progressive and severe.

E Varicella-zoster virus

Chicken pox is associated with a widespread vesicular rash, and shingles with a rash confined to a particular dermatome, neither of which fits with the picture seen here.

A EBV

EBV is associated with pharyngitis and severe tonsillitis rather than the picture seen here.

C Parvovirus B19

Parvovirus B19 is associated with coryzal symptoms and an erythematous facial rash, which leads to its description as 'slapped cheek' disease.

D Influenza

Influenza may be associated with upper respiratory tract symptoms but isn't associated with the vesicles and erosions seen here.

Touc... 00:34 12:33

MyPastest
https://mypastest.pastest.com

Pastest+

A 32-year-old man attends the Dermatology Clinic for review as he has become troubled by itchy new lesions on his hands. These have progressed over several weeks. He has had flares of eczema since he was a child, and these have decreased in frequency since.

He currently applies emollient four times each day and is not using any topical steroids. He works in human resources and, as far as he is aware, has not been exposed to any new substances.

A photograph of his hand is shown below.

What is the most appropriate management plan?

A Oral prednisolone

B Coal tar

C Start methotrexate

D Start topical steroids and oral flucloxacillin

E Increase emollient frequency and start topical

12:34

A 32-year-old man attends the Dermatology Clinic for review as he has become troubled by itchy new lesions on his hands. These have progressed over several weeks. He has had flares of eczema since he was a child, and these have decreased in frequency since.

He currently applies emollient four times each day and is not using any topical steroids. He works in human resources and, as far as he is aware, has not been exposed to any new substances.

A photograph of his hand is shown below.

What is the most appropriate management plan?

A Oral prednisolone

B Coal tar

C Start methotrexate

D Start topical steroids and oral flucloxacillin

E Increase emollient frequency and start topical steroids

Rana Alnasser's screen

E Increase emollient frequency and start topical steroids

This patient has a flare of atopic dermatitis of his hands. This is hyperkeratotic hand lesions of chronic palmar dermatitis. First-line management includes increasing emollient frequency to roughly 20 times per day, avoiding irritants such as soap and water, and wearing gloves. Topical steroids are the first-line treatment to help control these lesions.

A Oral prednisolone

Systemic steroid therapy is an appropriate treatment for severe acute flares. With this patient, the extent of the rash is not extensive enough to need systemic steroids.

B Coal tar

Coal-based preparations are useful for chronic plaque psoriasis and would not be suitable for this patient.

C Start methotrexate

Methotrexate is indicated as an option for chronic intractable hand dermatitis. This patient has not yet been optimally managed on first-line therapy and therefore this option would be premature at this stage. Other options when steroids and emollients fail include azathioprine, ciclosporin, alitretinoin and phototherapy.

D Start topical steroids and oral flucloxacillin

Antibiotics such as flucloxacillin should be used promptly, but only when there is clinical evidence of a secondary infection. This can be signs of local infection such as

E Increase emollient frequency and start topical steroids

This patient has a flare of atopic dermatitis of his hands. This is hyperkeratotic hand lesions of chronic palmar dermatitis. First-line management includes increasing emollient frequency to roughly 20 times per day, avoiding irritants such as soap and water, and wearing gloves. Topical steroids are the first-line treatment to help control these lesions.

A Oral prednisolone

Systemic steroid therapy is an appropriate treatment for severe acute flares. With this patient, the extent of the rash is not extensive enough to need systemic steroids.

B Coal tar

Coal-based preparations are useful for chronic plaque psoriasis and would not be suitable for this patient.

C Start methotrexate

Methotrexate is indicated as an option for chronic intractable hand dermatitis. This patient has not yet been optimally managed on first-line therapy and therefore this option would be premature at this stage. Other options when steroids and emollients fail include azathioprine, ciclosporin, alitretinoin and phototherapy.

D Start topical steroids and oral flucloxacillin

Antibiotics such as flucloxacillin should be used promptly, but only when there is clinical evidence of a secondary infection. This can be signs of local infection such as purulent discharge or purulent blisters, spreading erythema and tenderness, or can be systemic features such as fever

Rana Alnasser's screen

12:38
On
594-042-7551
Leave

A 55-year-old woman complains of painful, sore, erythematous, weeping skin over the right nipple and areola. She has used a potent topical steroid for 2 weeks with no improvement.

On examination of both breasts and axillae, there were no lumps and the left nipple was normal. She said she recently changed her body wash and thinks it may be an allergic reaction.

What is the most appropriate management step?

Your answer was correct

A	Reassure her that this is contact dermatitis and she should stop using the body wash
B	Prescribe a soap substitute and review in 6 weeks
C	Take a swab for microbiology and prescribe flucloxacillin
D	Refer for skin biopsy
E	Refer for patch testing

Explanation

D	Refer for skin biopsy

A weepy, unilateral erythematous eruption affecting one nipple should raise the suspicion of Paget's disease, i.e. direct extension of a mammary intraductal adenocarcinoma into the nipple or areola. For this reason, skin biopsy to rule out an underlying carcinoma is essential.

Audio Video Share Participants More

D Refer for skin biopsy

A weepy, unilateral erythematous eruption affecting one nipple should raise the suspicion of Paget's disease, i.e. direct extension of a mammary intraductal adenocarcinoma into the nipple or areola. For this reason, skin biopsy to rule out an underlying carcinoma is essential.

A Reassure her that this is contact dermatitis and she should stop using the body wash

Unilateral nipple symptoms do not support contact dermatitis as the underlying diagnosis.

B Prescribe a soap substitute and review in 6 weeks

This risks a significant delay in treating an underlying carcinoma.

C Take a swab for microbiology and prescribe flucloxacillin

The subacute presentation is unlikely to represent an acute bacterial infection, and prescribing antibiotics, like prescribing a soap substitute, risks delay in treating an underlying carcinoma.

E Refer for patch testing

Patch testing is ideal for evaluating a possible type IV hypersensitivity reaction, where bilateral changes would be expected.

Rate this question:

A Reassure her that this is contact dermatitis and she should stop using the body wash

Unilateral nipple symptoms do not support contact dermatitis as the underlying diagnosis.

B Prescribe a soap substitute and review in 6 weeks

This risks a significant delay in treating an underlying carcinoma.

C Take a swab for microbiology and prescribe flucloxacillin

The subacute presentation is unlikely to represent an acute bacterial infection, and prescribing antibiotics, like prescribing a soap substitute, risks delay in treating an underlying carcinoma.

E Refer for patch testing

Patch testing is ideal for evaluating a possible type IV hypersensitivity reaction, where bilateral changes would be expected.

38314

Rate this question:

12:40

A 35-year-old woman comes to the clinic for review. Her main complaint is of unsightly skin changes affecting her neck and axillae.

She is under follow-up with the ophthalmologists after angioid streaks were identified affecting both retinae, and she has been feeling increasingly tired over the past few months.

A picture of her right axilla is shown below.

Which of the following is she most likely to be suffering from?

A	Aortic stenosis
B	Gastrointestinal haemorrhage
C	Hypothyroidism
D	Interstitial cystitis
E	Lens dislocation

Rana Alnasser's screen

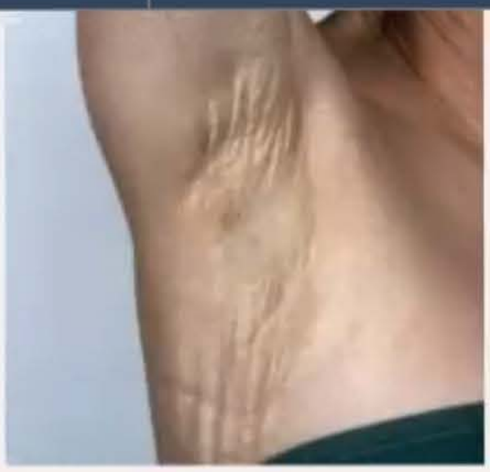

Which of the following is she most likely to be suffering from?

Your answer was incorrect

A Aortic stenosis

B Gastrointestinal haemorrhage

C Hypothyroidism

D Interstitial cystitis

E Lens dislocation

Explanation

B Gastrointestinal haemorrhage

The axillary changes seen in this patient are consistent with pseudoxanthoma elasticum (PXE), which is also associated with angioid streaks affecting the retina. It is caused by a mutation in the *ABCC6* gene, which leads to accumulation of calcium and other minerals in elastic fibres of the skin, eyes and blood vessels. Increasing fragility of blood vessels in the gastrointestinal tract can lead to gastrointestinal

B Gastrointestinal haemorrhage

The axillary changes seen in this patient are consistent with pseudoxanthoma elasticum (PXE), which is also associated with angioid streaks affecting the retina. It is caused by a mutation in the *ABCC6* gene, which leads to accumulation of calcium and other minerals in elastic fibres of the skin, eyes and blood vessels. Increasing fragility of blood vessels in the gastrointestinal tract can lead to gastrointestinal haemorrhage, which may account for the tiredness seen here.

E Lens dislocation

Lens dislocation is associated with Marfan syndrome. Features of Marfan syndrome, including arachnodactyly and recurrent joint dislocation, are absent from this scenario, although angioid streaks are seen in patients with the disease.

A Aortic stenosis

Aortic stenosis is not a feature of PXE, although both mitral valve prolapse and coronary artery calcification are noted in patients with long-standing disease.

C Hypothyroidism

Hypothyroidism is not associated with PXE, although PXE may be seen in patients with Down syndrome, which is also associated with hypothyroidism.

D Interstitial cystitis

Rana Alnasser's screen

Urinary tract haemorrhage is seen in patients with PXE.

12:42

28% 10:42

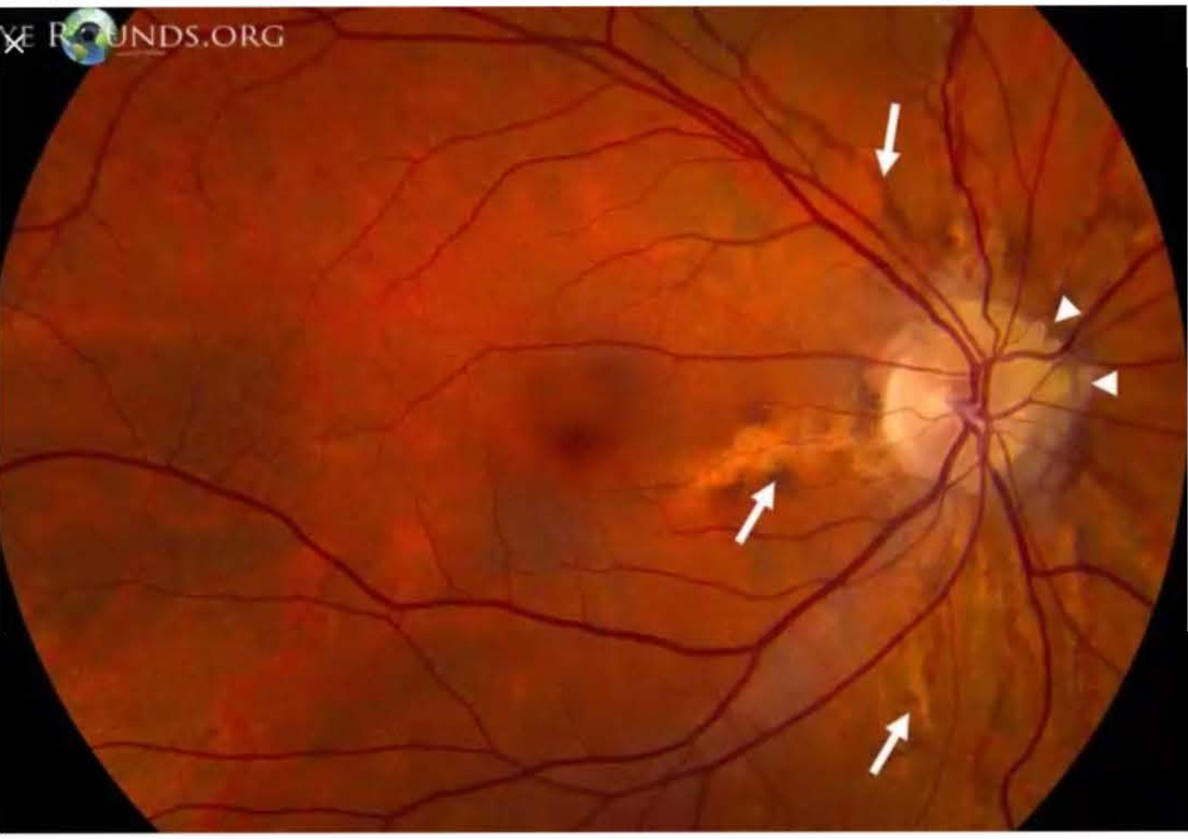

Department of Ophthalmology and Visual Sciences - University of Iowa

Angioid Streaks and Optic Disc Drusen in Pseudoxanthoma Elasticum ...

Angioid streaks · Angioid streaks

Images may be subject to copyright. Learn more

Annotation Stop Share

RELATED IMAGES

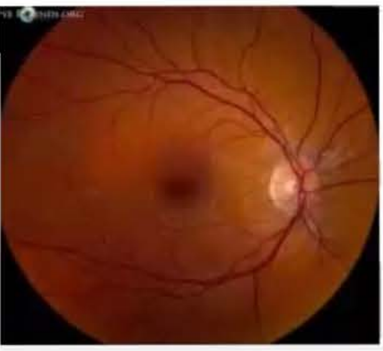

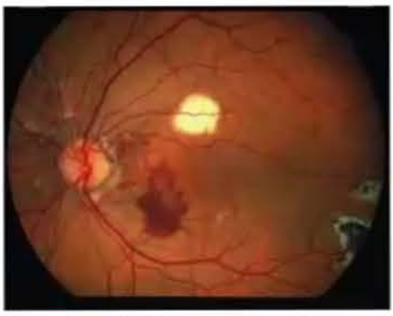

Angioid streaks - PXE case 4 image 3 - Retin...

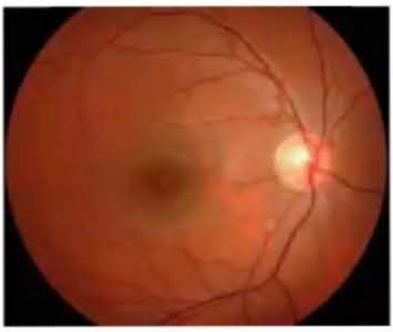

Angioid Streaks Louisville | Retina Florence ...

Discover Updates Search Recent More

Rana Alnasser's screen

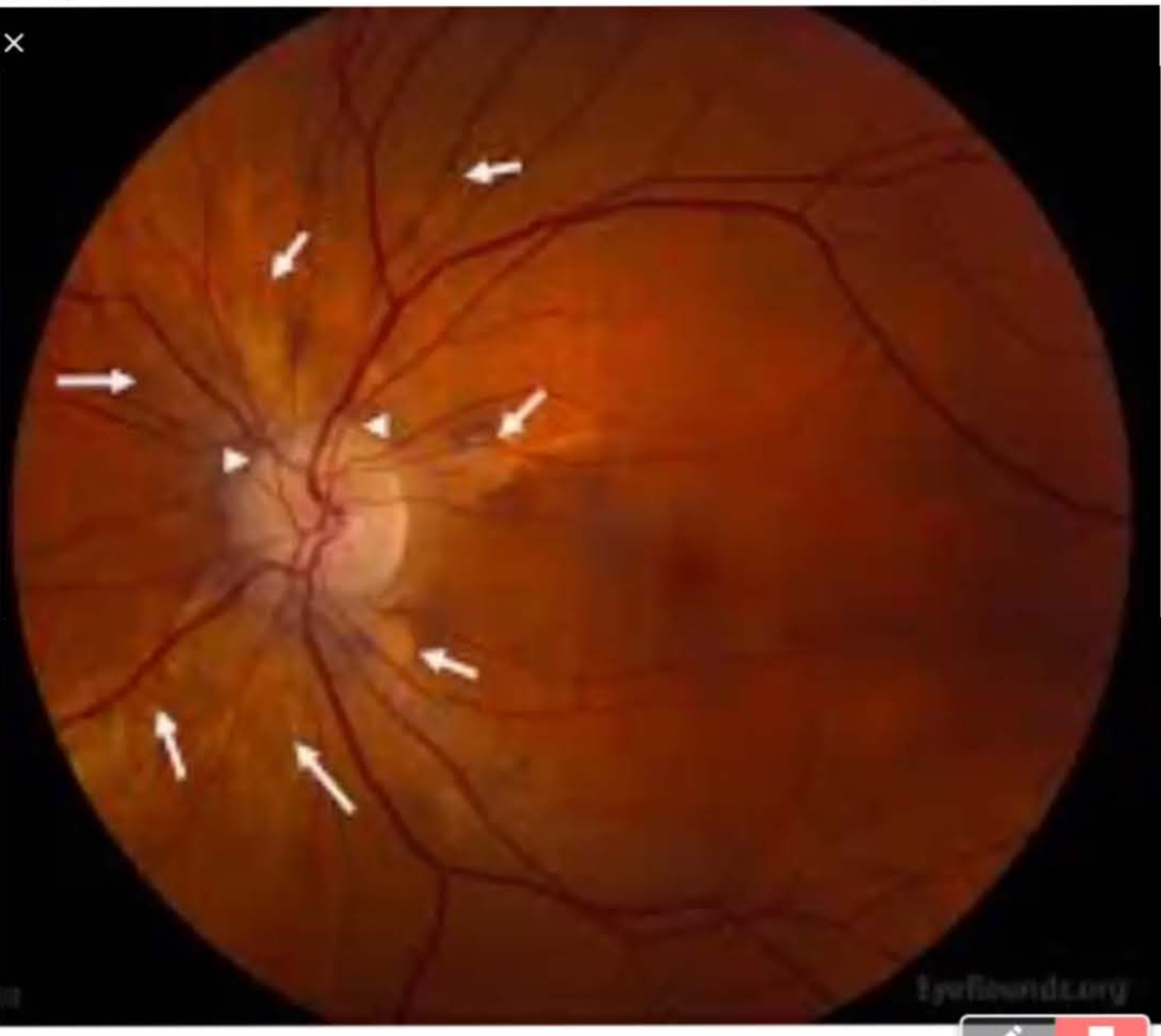

Department of Ophthalmology and Visual Sciences - University of Iowa

Angioid Streaks and Optic Disc Drusen in Pseudoxanthoma Elasticum ...

Angioid Streaks and Associated Conditions

Images may be subject to copyright. Learn more

RELATED IMAGES

Discover Updates Search Recent More

Rana Alnasser's screen

12:43

On 594-042-7551 Leave

28% 10:43

Google

pseudoxanthoma elasticum

ALL IMAGES NEWS VIDEOS SHOPPING MAPS BOOKS FLIGHTS TABLET

Latest GIF HD Product

angioid streaks | skin | plucked chicken skin | neck | pathology

Pseudoxanthoma elasticum - Wikipedia
en.wikipedia.org

File:Pseudoxanthoma elasticum 1.JPG ...
en.wikipedia.org

Pseudoxanthoma elasticum | Primary Care ...
pcds.org.uk

Pseudoxanthoma Elasticum - Pediatrics ...
msdmanuals.com

pseudoxanthoma elasticum. The re
researchgate.net

Annotation Stop Share

Groenblad Strandberg Syndrome ...
clinicaladvisor.com

Pseudoxanthoma Elasticum
flipper.diff.org

Collections

Angioid Streaks and Optic Disc Drusen ...

Discover Updates Search Recent More

Audio Video Share Participants More

12:43

On 594-042-7551 Leave

28% 10:43

MSD Manuals

Pseudoxanthoma Elasticum - Pediatrics - MSD Manual Professional ...

Pseudoxanthoma Elasticum - Pediatrics - MSD Manual Professional Edition

Images may be subject to copyright. Learn more

RELATED IMAGES

Annotation Stop Share

144 Pseudoxanthoma Elasticum | Plastic Sur...
plasticsurgerykey.com

Pseudoxanthoma Elasticum (Groenblad Stra...
clinicaladvisor.com

Internet Scientific Publications
ispub.com

Discover Updates Search Recent More

Audio Video Share Participants More

12:45
On
594-042-7551
Leave

Explanation

B Gastrointestinal haemorrhage

The axillary changes seen in this patient are consistent with pseudoxanthoma elasticum (PXE), which is also associated with angioid streaks affecting the retina. It is caused by a mutation in the *ABCC6* gene, which leads to accumulation of calcium and other minerals in elastic fibres of the skin, eyes and blood vessels. Increasing fragility of blood vessels in the gastrointestinal tract can lead to gastrointestinal haemorrhage, which may account for the tiredness seen here.

E Lens dislocation

Lens dislocation is associated with Marfan syndrome. Features of Marfan syndrome, including arachnodactyly and recurrent joint dislocation, are absent from this scenario, although angioid streaks are seen in patients with the disease.

A Aortic stenosis

Aortic stenosis is not a feature of PXE, although both mitral valve prolapse and coronary artery calcification are noted in patients with long-standing disease.

C Hypothyroidism

Hypothyroidism is not associated with PXE, although PXE may be seen in patients with Down syndrome, which is also associated with hypothyroidism.

D Interstitial cystitis

Urinary tract haemorrhage is seen in patients with PXE. This is not due to interstitial nephritis; it is usually as a

Audio Video Share Participants More

A 35-year-old woman attended with 3 naevi in her axillae. They have been present since early childhood. She feels they have been growing outwards recently, causing protuberance.

What are the naevi called?

A	Junctional
B	Intradermal
C	Compound
D	Congenital
E	Spitz

12:46

C Compound

A compound naevus has nests of naevus cells at the epidermal-dermal junction as well as within the dermis. They are raised and brown and may also be surrounded by a flat pigmented patch.

B Intradermal

Intradermal (also known as dermal) naevi occur due to melanocyte clustering in the dermis. They are raised and have the same degree of pigmentation as the surrounding skin. Melanocytes usually start off in the dermo-epidermal junction and then travel downwards, deeper into the dermis. Clinically, whilst in the dermo-epidermal junction, the mole appears flat and brown (junctional naevi). As the melanocytes descend and form nests, the mole becomes raised but stays brown on colour (compound naevi). However when they continue to descend deeper into the dermis the brown pigment is no longer visible and the mole appears colourless (intradermal naevi). This cycle can take years, or the mole may never undergo any change and remain a junctional mole for the duration of the patient's lifetime.

A Junctional

Junctional naevi are flat, brown naevi that occur due to the proliferation of melanocytes at dermo-epidermal junction.

D Congenital

Congenital naevi are pigmented and may be any size or shape, but notably are present at birth.

E Spitz

Rana Alnasser's screen

a flat pigmented patch.

B Intradermal

Intradermal (also known as dermal) naevi occur due to melanocyte clustering in the dermis. They are raised and have the same degree of pigmentation as the surrounding skin. Melanocytes usually start off in the dermo-epidermal junction and then travel downwards, deeper into the dermis. Clinically, whilst in the dermo-epidermal junction, the mole appears flat and brown (junctional naevi). As the melanocytes descend and form nests, the mole becomes raised but stays brown on colour (compound naevi). However when they continue to descend deeper into the dermis the brown pigment is no longer visible and the mole appears colourless (intradermal naevi). This cycle can take years, or the mole may never undergo any change and remain a junctional mole for the duration of the patient's lifetime.

A Junctional

Junctional naevi are flat, brown naevi that occur due to the proliferation of melanocytes at dermo-epidermal junction.

D Congenital

Congenital naevi are pigmented and may be any size or shape, but notably are present at birth.

E Spitz

Spitz naevi are dome-shaped nodules that are rapidly growing and range in colour from reddish to brown or even black. Spitz naevi are uncommon and benign in nature. However, clinically they often resemble melanomas and are therefore excised.

12:49

28% 10:49

Junctional Nevus

Intradermal Nevus

Compound Nevus

AIM at Melanoma

Types of Moles and Skin Lesions - AIM at Melanoma Foundation

Junctional Melanocytic Nevi

Images may be subject to copyright. Learn more

RELATED IMAGES

Moles & Warts Removal Treatment Services ...
indiamart.com

Index of /blog/wp-content/uploads/2010/02
theintellectualdevotional.com

Lentigo Treatment | Psoriasis Treatment | Ro...
uplandlaserdermatology.com

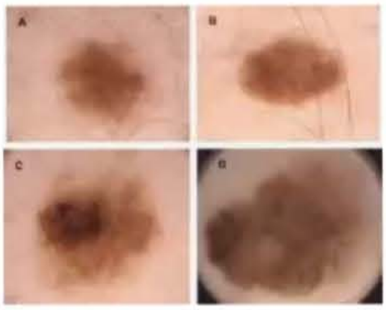

Digital dermoscopy (20X) ... - Yale Image Fin...
sprout038.sprout.yale.edu

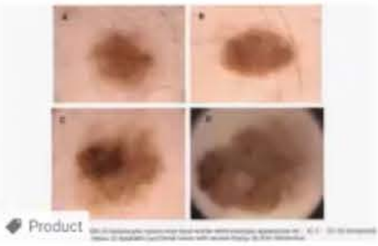

Product

Die Bilder -> Dysplastischer Nävus Vs Melan

Types of Pimple
shaamli.com

Annotation Stop Share
Discover Updates Search Recent More

Rana Alnasser's screen

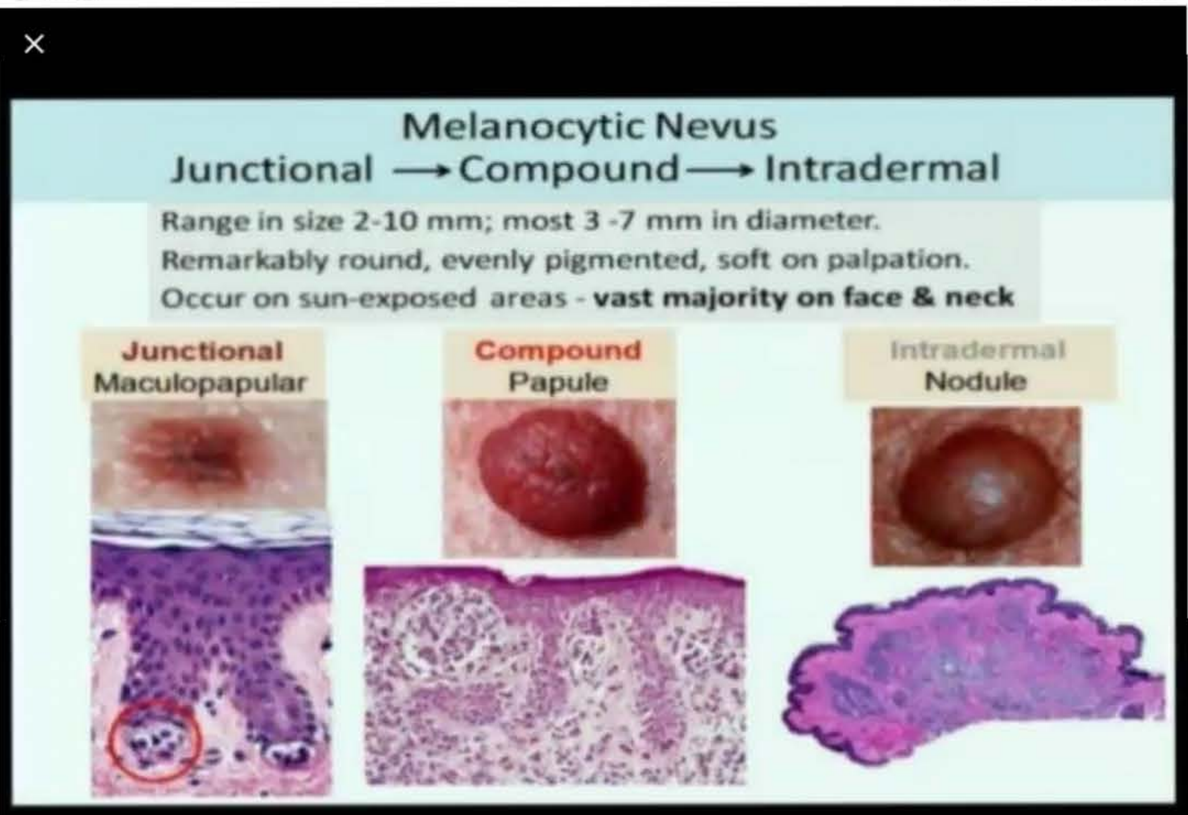

SlideShare

Disorders of pigmentation

... 75.

Images may be subject to copyright. Learn more

RELATED IMAGES

Discover Updates Search Recent More

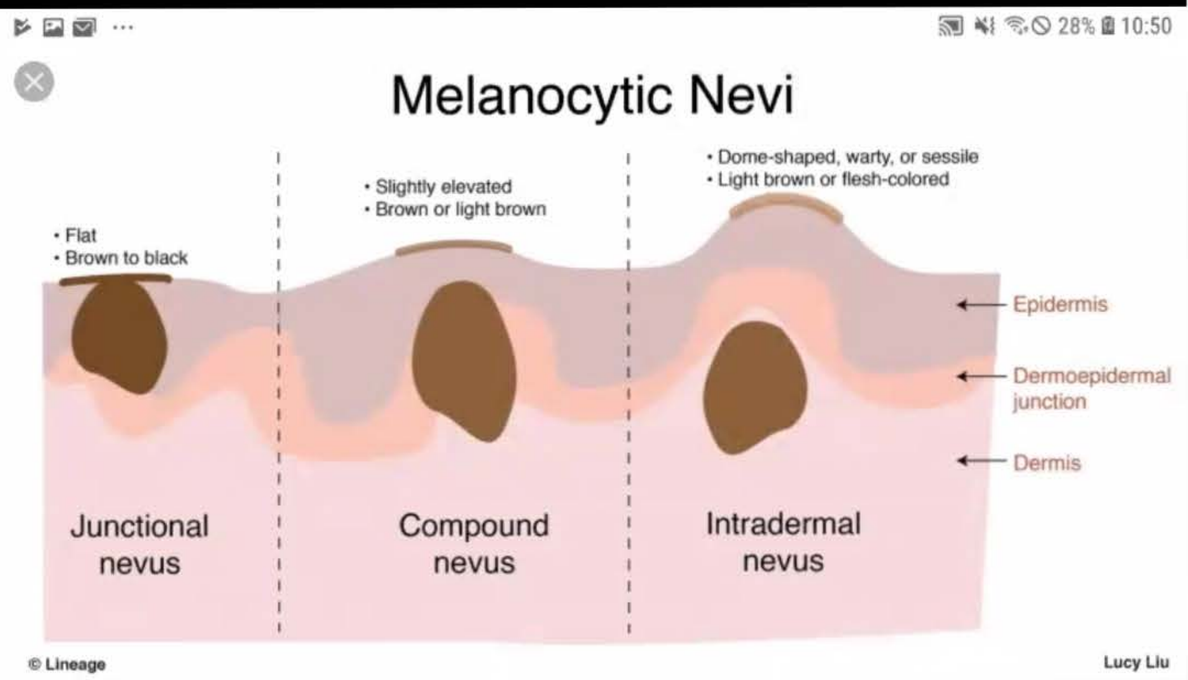

Medbullets

Nevus - Dermatology - Medbullets Step 1

junctional nevi are located at the dermoepidermal junction; compound ...

Images may be subject to copyright. Learn more

RELATED IMAGES

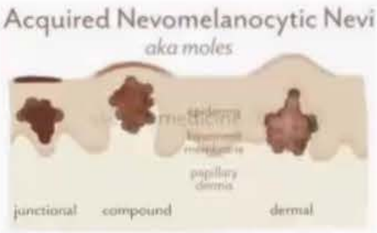

Acquired Nevomelanocytic Nevi (aka moles) ...
sketchymedicine.com

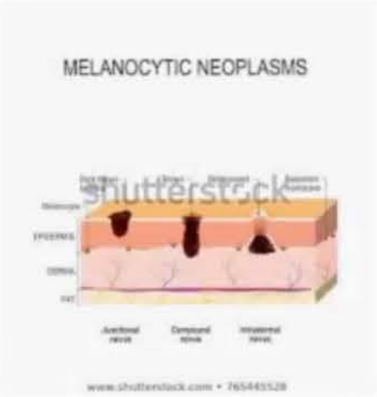

Melanocytic Nevus Junctional Compound Int...
shutterstock.com

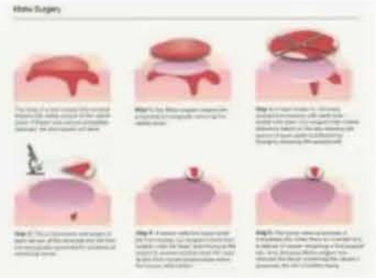

illust_mohs2 - Dermatology Specialists
mydermspecialists.com

Discover Updates Search Recent More

12:52

A 58-year-old man has an asymptomatic rash on his face, which has been present for years. He is well in himself, though has a history of iron deficiency anaemia.

He says that he feels fit and well. He takes amlodipine, pravastatin and ferrous sulphate regularly.

What is the diagnosis?

A	Hereditary haemorrhagic telangiectasia
B	Peutz–Jegher syndrome
C	Limited systemic sclerosis
D	Idiopathic thrombocytopenia purpura
E	Rosacea

Submit

Rana Alnasser's screen

12:53

A 58-year-old man has an asymptomatic rash on his face, which has been present for years. He is well in himself, though has a history of iron deficiency anaemia.

He says that he feels fit and well. He takes amlodipine, pravastatin and ferrous sulphate regularly.

What is the diagnosis?

Your answer was correct

A	Hereditary haemorrhagic telangiectasia
B	Peutz-Jegher syndrome
C	Limited systemic sclerosis
D	Idiopathic thrombocytopenia purpura
E	Rosacea

Explanation

Rana Alnasser's screen

12:53

A Hereditary haemorrhagic telangiectasia

This is an autosomal, dominantly inherited condition. Small dilated blood vessels manifest as red macules and papules, visible around the mouth, and on the lips and fingers. Lesions also occur on mucous membranes and in the gastrointestinal tract: these may be associated with severe epistaxis and gastrointestinal bleeding. Anaemia due to bleeding is treated with oral iron. The cutaneous involvement does not need any treatment, although vascular lasers are usually effective for symptomatic lesions.

B Peutz–Jegher syndrome

This is another rare, genetically determined condition that is characterised by pigmented macules on the lips, the skin around the mouth and the fingers and toes, occurring early in childhood. It is associated with small bowel polyps, which can cause intussusception. The gene confers a high risk of developing internal cancers, not only developing from intestinal polyps, but also in many other organs.

C Limited systemic sclerosis

This used to be termed CREST syndrome (calcinosis, Raynaud's phenomenon, oesophageal dysmotility, sclerodactyly or telangiectasia). Facial telangiectasia, including of the oral mucosa, is a feature, but the absence of other symptoms or signs in this case makes HHT a better response.

D Idiopathic thrombocytopenia purpura

Any cause of thrombocytopenia may result in purpura, but the discrete, fixed lesions confined to the face seen here are more in keeping with telangiectasia.

Rana Alnasser's screen

12:53

MyPastest
https://mypastest.pastest.com

Pastest+

A 56-year-old woman presents to the Dermatology Clinic with a small (0.6 cm), poorly defined, pearly nodule with overlying arborising telangiectasia located in the medial canthus, 5 mm from her left lower eyelid. She is otherwise fit and well.

What would be the most favourable treatment option for avoiding recurrence and achieving the best cosmetic outcome?

A	Excision with 5mm margin and flap repair
B	Moh's micrographic surgery
C	Radiotherapy
D	Curette and cautery
E	Treatment with Vismodegib

38304

Submit

Previous Q...

Skip Questi...

Blog About Pastest Contact Us Help

12:54

A 56-year-old woman presents to the Dermatology Clinic with a small (0.6 cm), poorly defined, pearly nodule with overlying arborising telangiectasia located in the medial canthus, 5 mm from her left lower eyelid. She is otherwise fit and well.

What would be the most favourable treatment option for avoiding recurrence and achieving the best cosmetic outcome?

Your answer was correct

A	Excision with 5mm margin and flap repair
B	Moh's micrographic surgery
C	Radiotherapy
D	Curette and cautery
E	Treatment with Vismodegib

Explanation

B	Moh's micrographic surgery

The clinical scenario describes a typical basal cell carcinoma (BCC). All of the above are treatment options for BCCs.

The indication for Moh's surgery are as follows:

- Recurrent or incompletely excised BCC
- Primary BCC with indistinct borders

Rana Alnasser's screen

12:54

B	Moh's micrographic surgery

The clinical scenario describes a typical basal cell carcinoma (BCC). All of the above are treatment options for BCCs.

The indication for Moh's surgery are as follows:

- Recurrent or incompletely excised BCC
- Primary BCC with indistinct borders
- Lesions located in or near high-risk areas such as eyelids, nose, ear, nasolabial folds
- Cosmetic and functionally important areas, e.g. head and neck
- Aggressive clinical evolution or histological subtype.

A	Excision with 5mm margin and flap repair

Although this is an acceptable intervention for BCC, it risk the possibility of a poor cosmetic result.

C	Radiotherapy

Radiotherapy may be undertaken in patients who do not wish, or are too frail, to have surgery.

D	Curette and cautery

Curette and cautery is an option for small nodular or superficial lesions.

E	Treatment with Vismodegib

Vismodegib is a cyclopamine-competitive antagonist of th smoothened receptor (SMO), which is part of the [illegible] ay. It is indicated in metastatic

Rana Alnasser's screen

12:57

An 18-year-old, fit and healthy woman of normal body weight is about to be treated with isotretinoin for scarring acne.

Which of the following is most important before starting therapy?

A	Low-cholesterol diet
B	Monitoring of renal function
C	Use of sun screen
D	Negative pregnancy testing
E	Weight control

71467

Submit

Previous Q... Skip Questi...

© Pastest 2019

Rana Alnasser's screen

12:57

MyPastest
https://mypastest.pastest.com

Pastest+

pregnant while on therapy should be offered a termination

A Low-cholesterol diet

Although treatment with isotretinoin may precipitate elevations in LDL and triglycerides, no dietary intervention is required. Baseline testing of lipid profile is recommended.

B Monitoring of renal function

Renal function does not affect metabolism of isotretinoin and no dose adjustment is recommended. Liver function testing, in contrast, is recommended for patients commencing isotretinoin therapy.

C Use of sun screen

Intense sun exposure can lead to hypersensitivity rashes in patients taking isotretinoin, and sun screen is advised, although this clearly is not as crucial an intervention as pregnancy testing.

E Weight control

Isotretinoin may precipitate benign intracranial hypertension in some patients who use it. We are told this patient is fit and well with a normal body weight, and measures to control weight gain are therefore unlikely to be needed.

Rate this question:

12:58
On
594-042-7551
Leave

A 30-year-old man presents to the clinic for review. He wa
diagnosed with an inherited condition when he was 9 year
old.

Which of the following complications should one look for

A	Optic glioma
B	Retinal hamartomas
C	Facial angiofibromas
D	Connective tissue naevi
E	Cardiac rhabdomyoma

Submit

Audio
Video
Share
Participants
More

12:59

E Cardiac rhabdomyoma

Explanation

A Optic glioma

The pictures show multiple neurofibromas and a very large café-au-lait patch consistent with neurofibromatosis type 1. Diagnostic criteria for NF1 are well established and include:

- At least six café-au-lait spots or hyperpigmented macules. They must be at least 5 mm wide in children younger than 10 years and 15 mm in adults.
- Axillary or inguinal freckles.
- Two or more typical neurofibromas or one plexiform neurofibroma.
- Optic nerve glioma.
- Two or more iris hamartomas. They are called Lisch nodules and are seen by slit-lamp examination.
- Sphenoid dysplasia or typical long-bone abnormalities such as arthrosis.

B Retinal hamartomas

Retinal hamartomas are associated with tuberous sclerosis, not with NF1.

C Facial angiofibromas

Facial angiofibromas are also associated with tuberous sclerosis, may be cosmetically disfiguring and are often amenable to laser therapy.

Rana Alnasser's screen

1:00

- At least six café-au-lait spots or hyperpigmented macules. They must be at least 5 mm wide in children younger than 10 years and 15 mm in adults.
- Axillary or inguinal freckles.
- Two or more typical neurofibromas or one plexiform neurofibroma.
- Optic nerve glioma.
- Two or more iris hamartomas. They are called Lisch nodules and are seen by slit-lamp examination.
- Sphenoid dysplasia or typical long-bone abnormalities such as arthrosis.

B Retinal hamartomas

Retinal hamartomas are associated with tuberous sclerosis, not with NF1.

C Facial angiofibromas

Facial angiofibromas are also associated with tuberous sclerosis, may be cosmetically disfiguring and are often amenable to laser therapy.

D Connective tissue naevi

Connective tissue naevi are associated with tuberous sclerosis and other diseases such as Cowden disease and proteus syndrome.

E Cardiac rhabdomyoma

Cardiac rhabdomyomas are the most common tumours of the heart in children, and are associated with tuberous sclerosis.

Rana Alnasser's screen

1:01
On ...
594-042-7551
Leave

Latest GIF HD Product

neurofibromatosis iris neurofibromatosis type 1

Lisch nodule - Wikipedia
en.wikipedia.org

Lisch nodules
webeye.ophth.uiowa.edu

Lisch
webey

Neurofibromatosis Type ...
emedicine.medscape.com

Iris hamartomas (Lisch nodules) in a ...
researchgate.net

Lisch
ocular

Head and Neck: Iris Hamartomas
atlasgeneticsoncology.org

Name: Josef Tamory Description ...
pinterest.com

lisch

Discover Updates Search Recent
Audio Video Share Participants More

1:01
On
594-042-7551
Leave

ape eMedicine

mologic Manifestations of Neurofibromatosis Type 1 (NF-1 ...

earance of multiple Lisch nodules in a

e subject to copyright. Learn more

AGES

Black Hat Iris Biometrics Attacks Don't Tell T...

Gas Bubble in Anterior C

imagebank.asrs.org

ver
Updates
Search
Recent
Audio
Video
Share
Participants
More

1:01

On 594-042-7551 Leave

32%

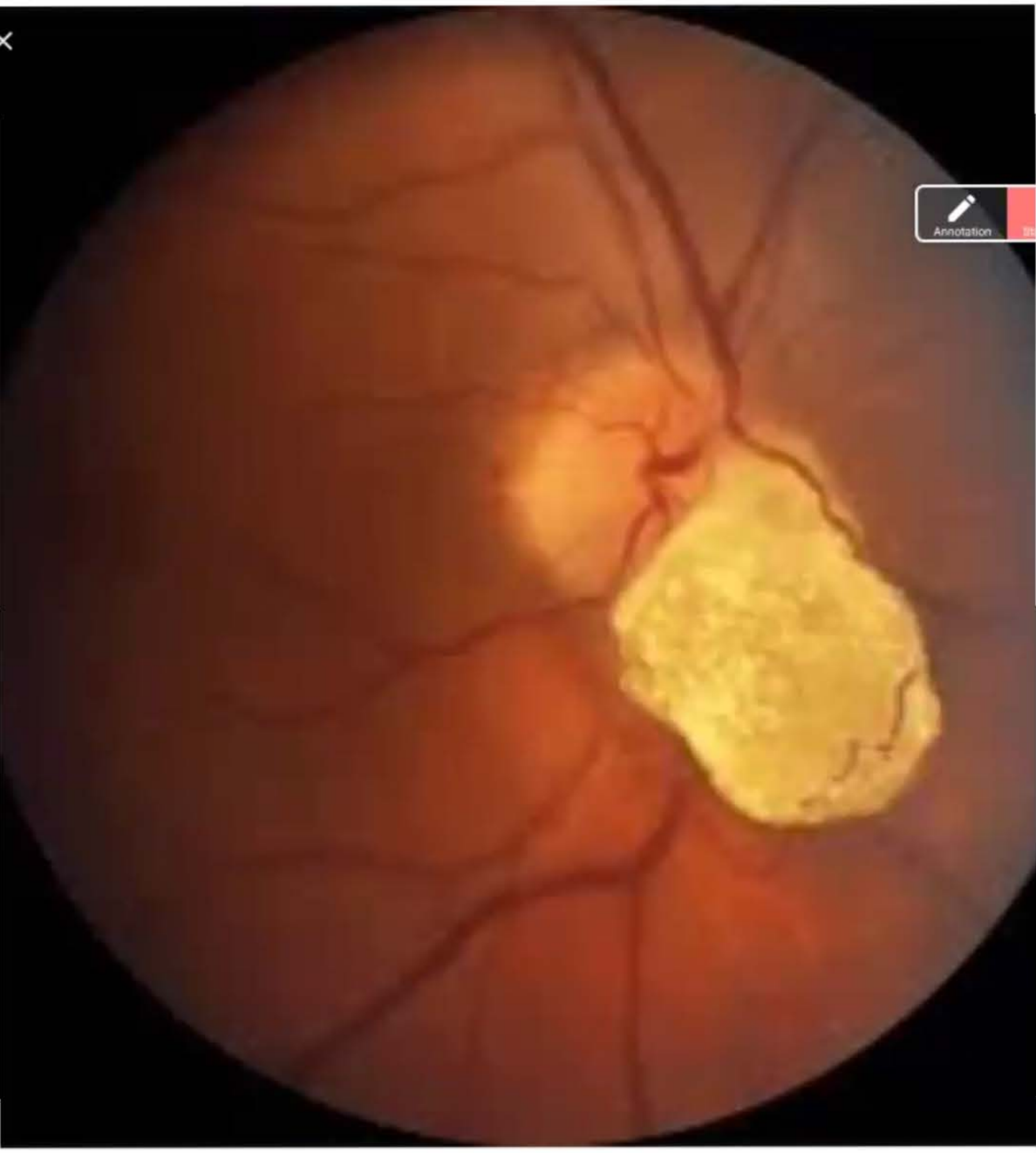

Webvision

Retinal Astrocytic Hamartoma – Webvision

Retinal Astrocytic Hamartoma

Images may be subject to copyright. Learn more

RELATED IMAGES

Discover Updates Search Recent More

Audio Video Share Participants More

1:02

On 594-042-7551 Leave

32% 11:02

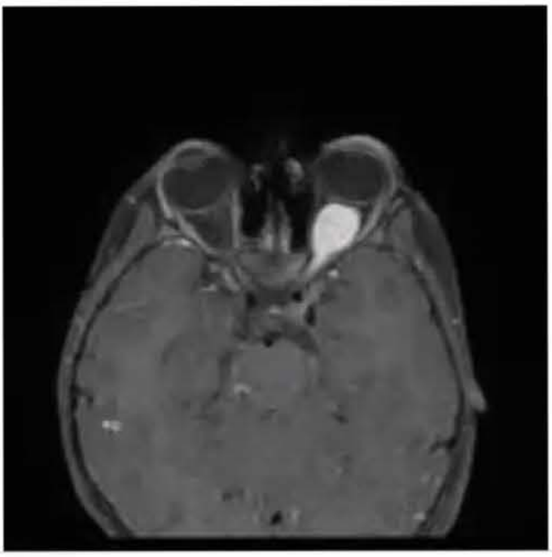

Radiopaedia

Optic pathway glioma | Radiology Reference Article | Radiopaedia.org

Case 5Case 5

Images may be subject to copyright. Learn more

RELATED IMAGES

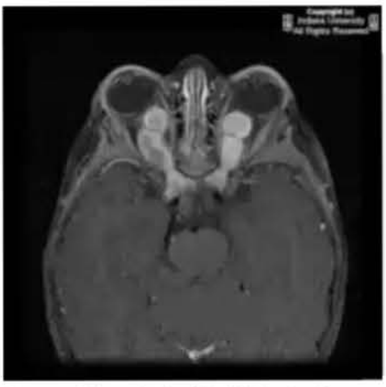

Neuroradiology On the Net: Bilateral optic ne...
neuroradiologyonthenet.blogspot.com

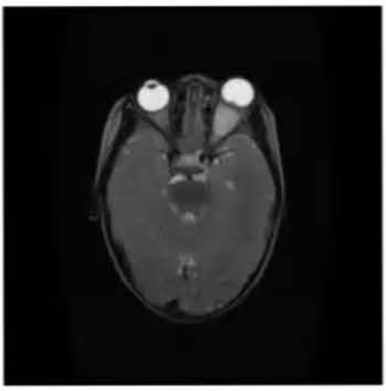

Optic nerve glioma | Radiology Case | Radiop...
radiopaedia.org

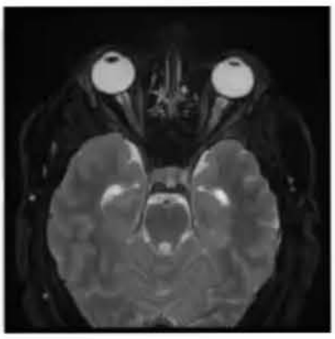

Viewing playlist: Sclerosis multiplex | Radiop...
radiopaedia.org

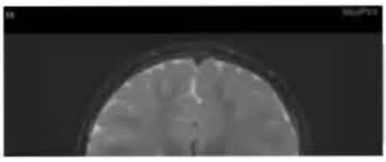

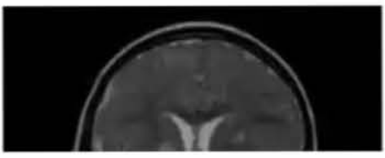

Discover Updates Search Recent More

Audio Video Share Participants More

1:02

A 45-year-old woman presented with sudden onset tender nodules on her legs (see photo), fever, joint pains, and shortness of breath.

A chest X-ray in the Emergency Department revealed the presence of bilateral hilar lymphadenopathy.

What is a skin biopsy from one of the nodules most likely to show?

A Prominence of mast cells

B Nests of melanocytes

C Neutrophilic panniculitis

D Spongiosis and oedema

E Vasculitis

Rana Alnasser's screen

1:03

Explanation

C Neutrophilic panniculitis

The lesions represent erythema nodosum. A typical skin biopsy from one of the lesions would show evidence of panniculitis, i.e. the presence of neutrophils and inflammation around lobules of fat in the subcutaneous tissue.

E Vasculitis

Vasculitis occurs due to inflammation surrounding the blood vessels. Cutaneous vasculitis presents clinically with purpura and ulceration.

A Prominence of mast cells

Mast cells are a type of leucocytes that contain granules of histamine and have an important role in allergic reactions. Aggregates of mast cells in the skin are seen in urticaria pigmentosa.

B Nests of melanocytes

Nests of melanocytes are a common histological finding of melanocytic naevi.

D Spongiosis and oedema

Spongiosis and oedema are typical histological findings of eczema.

40103

Rate this question:

Next Question

Rana Alnasser's screen

A 53-year-old white man, who previously lived in Australia, is referred with a large naevus on his back that has been getting darker in colour. He mentions that his brother was recently diagnosed with a malignant melanoma.

Subsequent excision and histology confirmed the diagnosis of malignant melanoma with a Breslow thickness of 4 mm. He wishes to know what his prognosis might be.

What is the ONE feature that will most affect his prognosis?

A	Family history of melanoma
B	Location of melanoma on the back
C	Thickness of melanoma at excision
D	Previous marked sun exposure
E	Change in colour

Submit

Previous Q... Skip Questi...

Blog About Pastest Contact Us Help

© Pastest 2019

1:04

A 53-year-old white man, who previously lived in Australia, is referred with a large naevus on his back that has been getting darker in colour. He mentions that his brother was recently diagnosed with a malignant melanoma.

Subsequent excision and histology confirmed the diagnosis of malignant melanoma with a Breslow thickness of 4 mm. He wishes to know what his prognosis might be.

What is the ONE feature that will most affect his prognosis?

Your answer was correct

A Family history of melanoma

B Location of melanoma on the back

C Thickness of melanoma at excision

D Previous marked sun exposure

E Change in colour

Explanation

C Thickness of melanoma at excision

The thickness of the melanoma, or Breslow thickness, is the

Rana Alnasser's screen

The thickness of the melanoma, or Breslow thickness, is the single most important prognostic feature and impacts significantly on management decisions.

Eight-year survival rates for melanoma based on tumour thickness are as follows:

< 0.76 mm	93%
0.76–1.69 mm	85%
1.70–3.60 mm	60%
> 3.60 mm	33%

A Family history of melanoma

A family history of melanoma is a well recognised risk factor for developing melanoma; however, it does not affect the prognosis once the disease is established.

B Location of melanoma on the back

In males, the back is the most common area to develop a melanoma, while in women the legs are most commonly affected. The location does not, however, affect prognosis.

D Previous marked sun exposure

By having lived in Australia, this man has a history of marked sun exposure, which is a well-recognised risk factor for developing melanoma. However, it does not affect the prognosis once the disease is established.

E Change in colour

In order to aid in the diagnosis of melanomas, the ABCDE rule is commonly used. Features that indicate the presence

Rana Alnasser's screen

A 55-year-old woman comes to the Emergency Department for review. She has cellulitis affecting her left lower leg and says that the area of redness has spread up her leg over the past 24 h.

On examination, she is pyrexial (38 °C), her BP is 155/82 mmHg and pulse is 85 bpm and regular. There is erythema over the foot and to the mid-shin on the left leg, with popliteal and inguinal lymphadenopathy. Her BMI is 32.

Investigations:

Hb	12.9 g/dl
WCC	13.1×10^9/l
PLT	207×10^9/l
Na^+	137 mmol/l
K^+	4.2 mmol/l
Creatinine	102 μmol/l
Fasting glucose	4.9 mmol/l

Which of the following is the most appropriate antibiotic therapy?

A Ciprofloxacin

B Co-amoxiclav

C Doxycycline

D Erythromycin

E Flucloxacillin

1:06

E Flucloxacillin

Guidelines recommend the use of flucloxacillin in the first instance for uncomplicated cellulitis, in this patient who is non-diabetic.

A Ciprofloxacin

Ciprofloxacin is added if there is exposure to freshwater at the time of infection because of the risk of infection with organisms such as *Pseudomonas*.

B Co-amoxiclav

Co-amoxiclav is the recommended first-line option in cellulitis related to bite injury because of activity against common oral bacteria, and is the default choice in many guidelines for the treatment of cellulitis against a background of diabetes mellitus.

C Doxycycline

Doxycycline is considered an option for cellulitis where there is significant exposure to salt water.

D Erythromycin

Macrolides such as erythromycin are the optimal intervention for patients with cellulitis who are allergic to flucloxacillin.

34148

Rate this question:

Next Question

Rana Alnasser's screen

1:06

A 40-year-old woman developed pale, pink-yellowish plaques on her right leg 6 months ago, as shown in the photograph below. She denies any associated symptoms, although she gives a history of trauma-related, superficial ulcers.

On examination of this plaque, there are overlying telangiectasias and atrophy of the surrounding skin. She is healthy, with no prior significant medical history. Her family history is significant for type 2 diabetes. She has tried topical steroids before, with minimal improvement.

A blood count, urea and electrolytes and urinalysis were normal.

What is the most likely diagnosis?

A	Granuloma annulare
B	Pyoderma gangrenosum
C	Pretibial myxoedema
D	Necrobiosis lipoidica (NL)

Rana Alnasser's screen

1:06

telangiectasias and atrophy of the surrounding skin. She is healthy, with no prior significant medical history. Her family history is significant for type 2 diabetes. She has tried topical steroids before, with minimal improvement.

A blood count, urea and electrolytes and urinalysis were normal.

What is the most likely diagnosis?

A	Granuloma annulare
B	Pyoderma gangrenosum
C	Pretibial myxoedema
D	Necrobiosis lipoidica (NL)
E	Acanthosis nigricans

8584

Submit

Rana Alnasser's screen

1:06

Explanation

D Necrobiosis lipoidica (NL)

NL usually occurs more often in people with diabetes and rheumatoid arthritis. However, the exact cause of NL in not known. NL remains a disease of questionable aetiology, despite extensive studies. Most cases of NL occur in the pretibial area, but cases have been reported on the face, scalp, trunk and upper extremities where the diagnosis is more likely to be missed. Topical and intralesional steroids have been used for therapy, but the lesions are notoriously difficult to treat. Inhibition of platelet aggregation with aspirin may be helpful. Biologics agents, ciclosporin and psoralen and ultraviolet A (PUVA) are also being used.

A Granuloma annulare

Granuloma annulare is a benign, chronic annular and erythematous eruption that can affect patients of all ages. It is characterised clinically by papules and annular plaques and is associated with a wide range of conditions such as infection, medications and autoimmune disorders.

B Pyoderma gangrenosum

Pyoderma gangrenosum is a neutrophilic condition causing painful skin ulceration with characteristic violaceous, undermined borders. The diagnosis should always be considered in non-healing sterile ulcers, particularly when other risk factors (such as rheumatoid arthritis, inflammatory bowel disease and haematological malignancies) are present.

C Pretibial myxoedema

Pretibial myxoedema is nearly always associated with Graves's disease. Clinically, there are bilateral firm plaques

Rana Alnasser's screen

A 66-year-old woman is admitted under the cardiologists with chest pain. While awaiting invasive investigations the team has become increasingly concerned by the striking changes affecting the woman's lower legs.

Of note, the patient is a known hypertensive and tells you that in the past she had eczema of her legs, which was treated using bandages. She lives alone and her daughter attends weekly to change the bandages. Over the last 3 weeks however, her daughter has been on holiday abroad and so hasn't managed to change them.

The patient denies any pain. She is afebrile. The pedal pulses are palpable. The lower legs look as though they are encased in cardboard. There is little oedema but no serous exudate. It smells offensive. The skin on the legs above the knees is entirely normal. Her blood tests on admission are unremarkable. She feels well in herself now that she has been given some analgesia for her chest pain.

Which of the following management options is most preferable?

A	Moderately potent topical steroids
B	Potassium permanganate soaks
C	Compression stockings
D	Gentle debridement

Of note, the patient is a known hypertensive and tells you that in the past she had eczema of her legs, which was treated using bandages. She lives alone and her daughter attends weekly to change the bandages. Over the last 3 weeks however, her daughter has been on holiday abroad and so hasn't managed to change them.

The patient denies any pain. She is afebrile. The pedal pulses are palpable. The lower legs look as though they are encased in cardboard. There is little oedema but no serous exudate. It smells offensive. The skin on the legs above the knees is entirely normal. Her blood tests on admission are unremarkable. She feels well in herself now that she has been given some analgesia for her chest pain.

Which of the following management options is most preferable?

A	Moderately potent topical steroids
B	Potassium permanganate soaks
C	Compression stockings
D	Gentle debridement
E	Oral antibiotics

Submit

Previous Q... Skip Questi...

1:10

D	Gentle debridement

This lady has a common condition found on elderly care wards – retention hyperkeratosis. The treatment for varicose eczema in the past with bandages that were changed infrequently interferes with the normal process of desquamation and results in this condition – a build-up of keratin. It is a benign but malodorous condition that can be treated very well with gentle debridement after soaking in arachis oil, revealing normal skin underneath. Recurrence can be prevented by skin care with emollients.

A	Moderately potent topical steroids

Given the degree of hyperkeratosis here, there is likely to be limited absorption of topical steroids, and debridement is much more appropriate as an initial intervention.

B	Potassium permanganate soaks

Potassium permanganate soaks are normally used as moist dressings to blistering wounds with ulceration or where there is local abscess formation.

C	Compression stockings

Compression stockings are used in the treatment of chronic venous stasis, but they won't resolve the hyperkeratosis seen here.

E	Oral antibiotics

Oral antibiotics are not required, since once the areas of skin slough have been debrided it is likely that healthy skin will remain underneath.

Rana Alnasser's screen

1:12

varicose eczema

Latest GIF HD Product

stasis dermatitis early mild leg

Varicose eczema - NHS
nhs.uk

Varicose Eczema : National Eczema Society
eczema.org

Gravitational eczema, varicose eczema ...
pcds.org.uk

Lower leg eczema: differential ...
gponline.com

venous eczema - Treatment -
collegeofphlebology.com

Discover Updates Search Rece

1:12
On ...
594-042-7551
Leave

Google

retention hyperkeratosis

ALL IMAGES SHOPPING NEWS VIDEOS BOOKS MAPS FLI

Latest GIF HD Product

mild foot severe follicular fac

retention hyperkeratosis occurring ...
escholarship.org

retention hyperkeratosis occurring ...
escholarship.org

retention hyperkeratosis occurring ...
escholarship.org

Hormonal Acne Management - Marijuana
acnetraining.com

Amr Gohar FRCP UK: Quiz
dvkeywords.blogspot.com

Discover Updates Search Rece
Audio Video Share Participants More

1:12
On ...
594-042-7551
Leave

A mother attends with her 2-year-old son. They both have had a rash for several days, which is extremely itchy and worse at night.

The son has a papular rash, mainly affecting his trunk and thighs, but there are also small, palpable red nodules on his penis and in finger-web spaces.

Which is the most appropriate treatment?

A	Antihistamines
B	Topical emollients
C	Topical clotrimoxazole
D	Oral corticosteroids
E	Topical malathion for the whole family

9189

Submit

Blog About Pastest Contact Us Help
Audio Video Share Participants More

1:13

MyPastest
https://mypastest.pastest.com

Pastest+

A mother attends with her 2-year-old son. They both have had a rash for several days, which is extremely itchy and worse at night.

The son has a papular rash, mainly affecting his trunk and thighs, but there are also small, palpable red nodules on his penis and in finger-web spaces.

Which is the most appropriate treatment?

Your answer was correct

A	Antihistamines
B	Topical emollients
C	Topical clotrimoxazole
D	Oral corticosteroids
E	Topical malathion for the whole family

Explanation

E	Topical malathion for the whole family

This mother and son have scabies – red/brown papules and nodules on the penis and scrotum are pathognomonic for this condition. The whole household should be treated and

1:13
On ...
594-042-7551
Leave

Explanation

E	Topical malathion for the whole family

This mother and son have scabies – red/brown papules and nodules on the penis and scrotum are pathognomonic for this condition. The whole household should be treated and linen etc. washed at 60°C. Treatment may worsen the itch for a few days and itching may persist for up to 2 weeks post-effective treatment – antihistamines and calamine lotion may help.

A	Antihistamines

Antihistamines will provide very limited symptomatic relief, and won't relieve the underlying infection.

B	Topical emollients

Topical emollients are not effective given that these patients have an infective skin rash.

C	Topical clotrimoxazole

Topical clotrimoxazole is used for the treatment of fungal disease, which is usually confined to flexural creases rather than the generalised itchy rash seen here.

D	Oral corticosteroids

An infective cause for the rash in this family rather than an inflammatory one is suggested by the fact both the mother and young child are affected.

Rate this question:
Audio Video Share Participants More

A 78-year-old man presents to the Dermatology Clinic with an erythematous rash which has gradually increased in severity over the past 7 months. The rash forms concentric erythematous bands, very much like the wood grains you would see on a tree. He has a chronic cough, thought to be related to previous cigarette smoking, although he gave up some 30 years earlier, and has had an operation for an inguinal hernia some 5 years earlier.

Which of the following is the most likely underlying malignancy?

A	Gastric carcinoma
B	Oesophageal carcinoma
C	Pancreatic carcinoma
D	Small cell lung cancer
E	Squamous cell carcinoma of the bronchus

Submit

Previous Q... Skip Questi...

A 78-year-old man presents to the Dermatology Clinic with an erythematous rash which has gradually increased in severity over the past 7 months. The rash forms concentric erythematous bands, very much like the wood grains you would see on a tree. He has a chronic cough, thought to be related to previous cigarette smoking, although he gave up some 30 years earlier, and has had an operation for an inguinal hernia some 5 years earlier.

Which of the following is the most likely underlying malignancy?

Your answer was incorrect

A	Gastric carcinoma
B	Oesophageal carcinoma
C	Pancreatic carcinoma
D	Small cell lung cancer
E	Squamous cell carcinoma of the bronchus

Explanation

E	Squamous cell carcinoma of the bronchus

This rare skin condition is erythema gyratum repens, which is most often seen in association with squamous cell carcinoma of the bronchus. It may also be seen in association with oesophageal and breast cancer, although the difficulty with a cough is a stronger pointer towards

1:14

E Squamous cell carcinoma of the bronchus

This rare skin condition is erythema gyratum repens, which is most often seen in association with squamous cell carcinoma of the bronchus. It may also be seen in association with oesophageal and breast cancer, although the difficulty with a cough is a stronger pointer towards lung cancer.

C Pancreatic carcinoma

Pancreatic carcinoma is associated with thrombophlebitis migrans.

A Gastric carcinoma

Gastric cancer is associated with acanthosis nigricans.

B Oesophageal carcinoma

Although oesophageal carcinoma is associated with erythema gyratum repens, it is less likely here given the absence of symptoms of indigestion.

D Small cell lung cancer

Skin rashes are not a usual phenomenon associated with small cell lung cancer.

Rate this question:

Next Question

1:15

A 68-year-old woman presents to the General Medical Clinic after having developed a change in colour aroun her eyes. She has not had any symptoms with this. It ha slowly progressed over two months. She does not have other current symptoms.

She has a past medical history of hysterectomy due to heavy periods and chronic obstructive pulmonary disea (COPD). She normally has inhalers but takes no regular tablets.

A photograph of her left eye is shown below.

Blood tests are requested, including full blood count, r profile, liver function and autoantibodies. An electromyography (EMG) is also requested.

Which of the following conditions would it be most appropriate to screen her for?

A	Malignancy
B	Diabetes
C	Chromosomal abnormalities
D	Human immunodeficiency virus (HIV)

Rana Alnasser's screen

1:15

She has a past medical history of hysterectomy due to heavy periods and chronic obstructive pulmonary disea (COPD). She normally has inhalers but takes no regular tablets.

A photograph of her left eye is shown below.

Blood tests are requested, including full blood count, re profile, liver function and autoantibodies. An electromyography (EMG) is also requested.

Which of the following conditions would it be most appropriate to screen her for?

A	Malignancy
B	Diabetes
C	Chromosomal abnormalities
D	Human immunodeficiency virus (HIV)
E	Hepatitis C

Rana Alnasser's screen

1:16

A 56-year-old woman presents with the skin lesion sho below on the anterior aspect of her shin. She thinks tha increasing in size. She also attends another hospital for diabetes mellitus, for which she takes a combination of metformin and sitagliptin.

Over the past few months, she admits to increasing tiredness and vague joint pains. Her blood pressure is 149/82 mmHg, pulse is 72 and regular and her BMI is 2

Which is the most likely cause of her skin lesion?

A	Psoriasis
B	Sarcoidosis
C	Basal cell carcinoma
D	Systemic lupus erythematosus
E	Necrobiosis lipoidica diabeticorum

Rana Alnasser's screen

1:17

E Necrobiosis lipoidica diabeticorum

Explanation

E Necrobiosis lipoidica diabeticorum

Early necrobiosis lipoidica diabeticorum is often difficu diagnose as it may appear psoriatic in nature, and telangiectasia are seen on the waxy surface. Less than of diabetic patients have this, but most patients with th condition have diabetes mellitus (60%). Lesions appear one or more discoloured areas on the fronts of the shir shiny, atrophic and brown-red or slightly yellow. The margin may be erythematous or violet. Treatment is difficult, although anti-platelet agents and immunomodulators appear to show at least some effec progression.

A Psoriasis

A single lesion on the shin is unlikely to be due to psori and the size increase is consistent with necrobiosis lipoidica.

B Sarcoidosis

Sarcoidosis is associated with erythema nodosum, with multiple raised red/purple nodules on the shins, rather the single enlarging lesion seen here.

C Basal cell carcinoma

Sun-exposed areas of skin, such as the head and neck, the commonest areas for basal cell carcinomas to occu They may resemble necrobiosis in the early stages, although a more nodular appearance versus that seen

1:18
On 594-042-7551 Leave

A 26-year-old, male body builder presents to the Dermatology Clinic with an itchy rash on his upper left chest.

He maintains that he takes no medication and works ou for many hours per day.

What is the most likely cause of the rash?

A	Dermatitis herpetiformis
B	Tinea corporis
C	Body wash
D	Anabolic steroid abuse
E	Impetigo

Submit
Audio Video Share Participants More

A 26-year-old, male body builder presents to the Dermatology Clinic with an itchy rash on his upper left chest.

He maintains that he takes no medication and works out for many hours per day.

What is the most likely cause of the rash?

Your answer was correct

A Dermatitis herpetiformis

B Tinea corporis

C Body wash

D Anabolic steroid abuse

E Impetigo

Explanation

D Anabolic steroid abuse

This is an acneiform eruption consisting of pustules, papules and nodules, and a localised folliculitis on the upper chest. Anabolic steroids are a common cause of iatrogenic acne, and given his body building must be considered a possibility.

A Dermatitis herpetiformis

Dermatitis herpetiformis is associated with generalised papules and blisters and often with symptoms of gluten sensitive enteropathy, rather than the localised rash in an otherwise well patient seen here.

B Tinea corporis

Tinea corporis is seen as a scaly erythematous lesion which gradually enlarges, associated with clearance from the centre.

C Body wash

Although an allergic reaction to body wash is possible, a generalised rash rather than the localised changes seen here would be expected.

E Impetigo

Impetigo is a common skin infection usually occurring on the face, and is associated with honey coloured crusted plaques of infection.

Rate this question:

Rana Alnasser's screen

1:21
On
Pastest
594-042-7551
Question 39 of 169
Leave

A 57-year-old woman reports the presence of an asymptomatic skin lesion on her left lower leg.

Examination reveals a 4-mm firm nodule that dimples when pinched.

What would be the best way to manage this lesion?

A	Excision with 4mm surgical margins
B	Curettage and cautery
C	Re-assurance
D	Offer follow-up in 4 months time in order to re-assess
E	Intralesional injection of corticosteroids

Submit

Previous Q... Skip Questi...

Blog About Pastest Contact Us Help

© Pastest 2019

Audio Video Share Participants More

C Re-assurance

Dermatofibromas are benign and therefore require no treatment unless they become symptomatic.

B Curettage and cautery

Dermatofibromas are benign lesions that do not require any surgical intervention unless they become symptomatic.

A Excision with 4mm surgical margins

The papule shown above represents a dermatofibroma. A benign fibrous lesion thought to occur following local tissue injury, often due to an insect bite. Dermatofibromas require no intervention unless they become bothersome to the patent (painful or itchy). An excision with 4mm surgical margins is the commonest used surgical method in the treatment of nodulocystic basal cell carcinomas. For dermatofibromas, excision should be reserved for cases of diagnostic uncertainty, symptomatic lesions (itchy), or for cosmetic purposes. In both cases, narrow excision with 2mm surgical margins should be employed

D Offer follow-up in 4 months time in order to re-assess

Given the benign nature of this lesion there is no need to offer further follow-up and the patient can be safely discharged. Follow-up of skin lesions is usually reserved for cases where the clinical diagnosis of melanoma is not clear-cut. A high quality photo of the lesion should be obtained and compared with the lesion at the time of follow-up for signs of change. If any changes are noted the lesion should then be excise as it carried a high risk of malignancy.

1:23
On dermatofibroma 594-042-7551 Leave

Dermatofibroma: Causes, images, and ...
medicalnewstoday.com

Dermatofibroma: Causes, images, and ...
medicalnewstoday.com

Dermatofibroma, histiocytoma | Primary ...
pcds.org.uk

Dermatofibroma | DermNet NZ
dermnetnz.org

Picture of Dermatofibroma
webmd.com

Dermatofibroma | DermNet NZ
dermnetnz.org

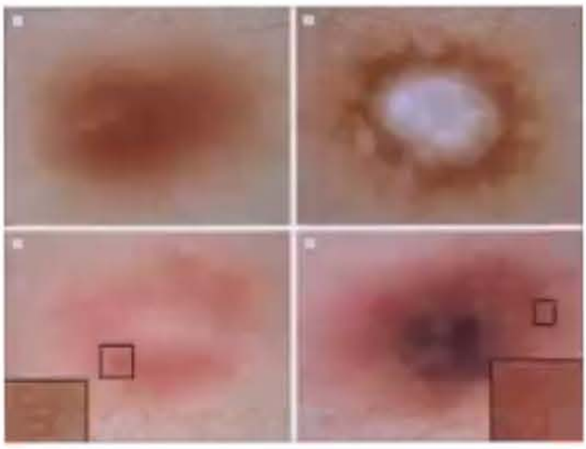

Dermoscopy of Dermatofibromas: A ...
jamanetwork.com

Dermatofibroma Management and Prognosis
news-medical.net

Related Searches

Audio Discover Video Updates Share Participants Search More

1:27
On ...
594-042-7551
Leave

A 57-year-old woman presented with hair loss, distributed on the front and crown of her scalp but sparing the sides.

She denied using braids, straighteners, tongs or wearing a ponytail. She had no other significant medical problems.

What is the most appropriate initial intervention to treat her hair loss?

Your answer was correct

A	Topical Minoxidil
B	Oral Minoxidil
C	Laser therapy
D	Topical steroids
E	Antifungal shampoo

Explanation

Audio
Video
Share
Participants
More

Explanation

A Topical Minoxidil

This patient has hair loss in a pattern either related to androgen excess or to increased sensitivity to androgens. Topical treatment of choice is minoxidil, which promotes hair re-growth. Other options include systemic anti-androgens such as finasteride.

B Oral Minoxidil

Oral minoxidil is a vasodilator used for resistant hypertension, and it was found in clinical trials to stimulate hair growth as a side-effect of therapy.

C Laser therapy

Laser therapy is of course used for hair removal rather than to stimulate hair growth.

D Topical steroids

Topical steroids are used in scarring alopecia to reduce inflammation.

E Antifungal shampoo

Anti-fungal shampoo is used to treat seborrheic dermatitis and pityriasis versicolor.

Rate this question:

Next Question

8:32
594-042-7551
Leave
MyPastest
https://mypastest.pastest.com

You are called to see a 25-year-old man who was admitted almost 2 weeks ago for a neurosurgical procedure. He was started on carbamazepine post-operatively.

He is due to go home tomorrow, but today has been feeling unwell and is complaining that his skin has become red and painful. He noticed some blistering on the arms over the last couple of hours and also reports soreness in the mouth.

In the last few hours, his pulse rate has increased to 130 bpm, with blood pressure 105/62 mmHg. Temperature is 38.3 °C.

Which of the following is most likely to improve prognosis?

A	Intravenous (IV) hydrocortisone
B	Ciclosporin
C	Broad-spectrum antibiotics
D	Stopping carbamazepine
E	Oral prednisolone

6294
Audio
Video
Share
Participants
More

8:33
594-042-7551
Leave

D Stopping carbamazepine

This presentation is suggestive of Stevens–Johnson syndrome (SJS) or toxic epidermal necrolysis (TEN) secondary to carbamazepine. SJS/TEN is a potentially life-threatening skin disorder which is almost always drug-induced. Common precipitants include anticonvulsants, sulfonamides and allopurinol. The HLA-B*1502 phenotype is associated with an increased risk of SJS/TEN from carbamazepine: Han Chinese and Thai individuals should be screened for this prior to initiation of the drug. SJS and TEN are seen as parts of the same disease: it is termed SJS in cases with up to 10% epidermal detachment, SJS/TEN overlap with 10–30% detachment and TEN with more than 30%. Key clinical features include confluent macular erythema and/or an exanthematous eruption, with areas or blistering or epidermal sloughing. Mucosal involvement is universal. Patients are usually very unwell and pyrexial. The affected skin tends to be painful rather than itchy.

The risk of death in patients with TEN can be accurately predicted by the toxic epidermal necrolysis-specific severity-of-illness score (SCORTEN). A score of 0–1 indicates a mortality risk of 3.2%; score of 2, 12.1%; score of 3, 35.3%; score of 4, 58.3%; and a score of 5 or more, 90%. Each of the following independent prognostic factors is given a score of 1: age greater than 40 years; heart rate greater than 120 beats per minute; cancer/haematological malignancy; involved body surface area greater than 10%; serum urea level of more than 10 mmol/l; serum bicarbonate level of less than 20 mmol/l; serum glucose level of more than 14 mmol/l.

The key initial management step is to stop any possible causative drugs. One observational study showed a reduction in mortality from 26 to 5% when the implicated drugs with short-elimination half-lives were withdrawn no later than the day the blisters or erosions first developed. The condition requires intensive therapy with nursing on air-fluidised mattresses, liberal application of greasy emollients, analgesia, fluid resuscitation, eye and mouth

Audio Video Share Participants More

serum urea level of more than 10 mmol/l; serum bicarbonate level of less than 20 mmol/l; serum glucose level of more than 14 mmol/l.

The key initial management step is to stop any possible causative drugs. One observational study showed a reduction in mortality from 26 to 5% when the implicated drugs with short-elimination half-lives were withdrawn no later than the day the blisters or erosions first developed. The condition requires intensive therapy with nursing on air-fluidised mattresses, liberal application of greasy emollients, analgesia, fluid resuscitation, eye and mouth care, and nutritional support. This is usually best achieved on a Burns Unit, though some patients require ventilation on Intensive Care. The use of specific therapy, such as corticosteroids, antibiotics, ciclosporin and intravenous immunoglobulin, remains controversial in the absence of strong evidence.

A Intravenous (IV) hydrocortisone

There is no clear evidence that parenteral corticosteroids are useful in SJS/TEN, and the key management step is to stop the causative drug.

B Ciclosporin

There is no clear evidence that ciclosporin is useful in SJS/TEN, and the key management step is to stop the causative drug.

C Broad-spectrum antibiotics

Whilst patients with SJS/TEN are susceptible to super-added infection, there is no evidence that prophylactic antibiotics affect prognosis and their use is not recommended. The key management step is to stop the causative drug.

Rana Alnasser's screen

A 36-year-old man presents with a widespread rash. He has been feeling unwell and has a poor appetite.

On examination, he is found to have an erythematous rash with areas of blistering (see figure). The lips are eroded, and multiple aphthous ulcers are noticed in the mouth. The eyes are injected.

How should the oral ulcers be managed?

A	Chlorhexidine mouthwash
B	Topical steroids
C	Intravenous (IV) flucloxacillin
D	IV immunoglobulins
E	Azathioprine

8:36

A	Chlorhexidine mouthwash

The answer is Chlorhexidine mouthwash (Option A)

This patient has Stevens-Johnson syndrome and ma require hospital admission for nutritional support ar adequate skin care. The causes of Stevens-Johnson syndrome are as for erythema multiforme, but with rather than infections, being the most common culp therefore imperative to stop any recently started medications. Management is supportive. Use of chlorhexidine mouthwash may be helpful in prevent secondary infections.

B	Topical steroids

Topical steroids (Option B) is incorrect.

There is no evidence that topical steroids are helpfu achieving faster resolution of the erosions and rash.

C	Intravenous (IV) flucloxacillin

Intravenous (IV) flucloxacillin (Option C) is incorrec

Antibiotics are not useful in Steven-Johnson syndro unless used to treat secondary bacterial infections. swabs for the detection of *Streptococcus* and chest looking for evidence of *Mycoplasma pneumoniae* m use.

D	IV immunoglobulins

IV immunoglobulins (Option D) is incorrect.

IV immunoglobulins should be considered in the idermal necrolysis (TEN). In

Rana Alnasser's screen

8:38
594-042-7551 Leave
MyPastest
https://mypastest.pastest.com

syndrome are as for erythema multiforme, but with drugs, rather than infections, being the most common culprit. It is therefore imperative to stop any recently started medications. Management is supportive. Use of chlorhexidine mouthwash may be helpful in preventing secondary infections.

B Topical steroids

Topical steroids (Option B) is incorrect.

There is no evidence that topical steroids are helpful in achieving faster resolution of the erosions and rash.

C Intravenous (IV) flucloxacillin

Intravenous (IV) flucloxacillin (Option C) is incorrect.

Antibiotics are not useful in Steven-Johnson syndrome, unless used to treat secondary bacterial infections. Throat swabs for the detection of *Streptococcus* and chest X-rays looking for evidence of *Mycoplasma pneumoniae* may be of use.

D IV immunoglobulins

IV immunoglobulins (Option D) is incorrect.

IV immunoglobulins should be considered in the management of toxic epidermal necrolysis (TEN). In Stevens-Johnson syndrome, supportive care and cessation of the offending agents form the mainstay of care.

E Azathioprine

Azathioprine (Option E) is incorrect.

Audio Video Share Participants More

8:38

A 45-year-old man is reviewed in the clinic with a 1-month history of worsening flaking skin and areas of erythema on his feet which have only partially responded to topical antifungals. He has suffered from increasing tiredness over the past four months and wakes twice per night to pass urine.

He has a blood pressure of 145/82 mmHg and a body mass index (BMI) of 32 kg/m^2. He is continuing to use topical antifungal preparations.

Which of the following is the most appropriate next step?

A	Fasting blood glucose testing
B	Oral flucloxacillin
C	Oral fluconazole
D	Topical hydrocortisone
E	Topical mupirocin

71608

Rana Alnasser's screen

A Fasting blood glucose testing

The highlighted features here, including partial response to antifungals of tinea pedis, increasing tiredness and nocturia in a middle-aged obese man, are consistent with an underlying type 2 diabetes. A fasting blood glucose level of over 7 mmol/l is appropriate to confirm the diagnosis in the presence of symptoms; HbA1c can be used as an alternative.

B Oral flucloxacillin

Although concomitant staphylococcal infection is common in patients with tinea pedis, it is not likely to be the primary driver for recurrent and resistant infection here.

C Oral fluconazole

In the presence of ongoing untreated type 2 diabetes, systemic antifungals are unlikely to achieve clearance of tinea infection. They may be of value in some patients, although penetration of flaking, cracked skin on the feet is likely to be limited.

D Topical hydrocortisone

Topical hydrocortisone is not effective in patients with fungal skin infection.

E Topical mupirocin

Topical antibiotics may be useful in patients with superficial bacterial infection, in addition to evidence of tinea, but in this case, it is more important to rule out underlying diabetes mellitus. Mupirocin is more commonly used in the treatment of impetigo or to achieve clearance of meticillin-resistant *Staphylococcus aureus* (MRSA) where there is

C Oral fluconazole

In the presence of ongoing untreated type 2 diabetes, systemic antifungals are unlikely to achieve clearance of tinea infection. They may be of value in some patients, although penetration of flaking, cracked skin on the feet is likely to be limited.

D Topical hydrocortisone

Topical hydrocortisone is not effective in patients with fungal skin infection.

E Topical mupirocin

Topical antibiotics may be useful in patients with superficial bacterial infection, in addition to evidence of tinea, but in this case, it is more important to rule out underlying diabetes mellitus. Mupirocin is more commonly used in the treatment of impetigo or to achieve clearance of meticillin-resistant *Staphylococcus aureus* (MRSA) where there is long-term skin carriage.

Rate this question:

Next Question

Previous Q... Tag Questi... Feedback End Session

Blog About Pastest Contact Us Help

© Pastest 2019

A 54-year-old man with severe, widespread, chronic plaque psoriasis and arthritis in both hands has failed to respond adequately to treatment with increasing doses of oral methotrexate.

He has previously failed treatment with phototherapy, cyclosporine and multiple topical agents.

Which of the following is the most appropriate treatment?

A	Switch to subcutaneous methotrexate
B	Switch to treatment with acitretin
C	Repeat course of phototherapy
D	Switch to adalimumab
E	Switch to oral prednisolone

Submit

Previous Q... Skip Questi...

© Pastest 2019

8:41

A 54-year-old man with severe, widespread, chronic plaque psoriasis and arthritis in both hands has failed to respond adequately to treatment with increasing doses of oral methotrexate.

He has previously failed treatment with phototherapy, cyclosporine and multiple topical agents.

Which of the following is the most appropriate treatment?

Your answer was correct

A	Switch to subcutaneous methotrexate
B	Switch to treatment with acitretin
C	Repeat course of phototherapy
D	Switch to adalimumab
E	Switch to oral prednisolone

Explanation

D Switch to adalimumab

In severe plaque psoriasis, treatment with biologic agents is available in patients that have previously failed treatment with methotrexate, ciclosporin and phototherapy. Adalimumab is a biologic agent that has been used in the treatment of rheumatoid arthritis, inflammatory bowel disease, psoriasis and psoriatic arthritis. It acts as a TNF-α (tumour necrosis factor-alpha) antagonist with a good safety profile. However, TNF-α antagonists have been

Rana Alnasser's screen

D Switch to adalimumab

In severe plaque psoriasis, treatment with biologic agents is available in patients that have previously failed treatment with methotrexate, ciclosporin and phototherapy. Adalimumab is a biologic agent that has been used in the treatment of rheumatoid arthritis, inflammatory bowel disease, psoriasis and psoriatic arthritis. It acts as a TNF-α (tumour necrosis factor-alpha) antagonist with a good safety profile. However, TNF- α antagonists have been linked to a risk of reactivation of TB and therefore it is important to exclude cases of TB prior to commencing therapy. This is usually done with a chest X-ray and a quantiferon test.

A Switch to subcutaneous methotrexate

Subcutaneous methotrexate is thought to have comparable efficacy to that of oral methotrexate and is often used in an attempt to bypass the gastrointestinal side effects that can be associated by taking oral methotrexate.

B Switch to treatment with acitretin

Acitretin is an oral retinoid (vitamin-A derivative) that is used in the treatment of severe psoriasis, and in particular pustular psoriasis, erythrodermic psoriasis and psoriasis affecting hands and feet. However, it is not effective against psoriatic arthritis and therefore an alternative agent should be sought in this particular instance.

C Repeat course of phototherapy

This patient has previously failed to respond to phototherapy and therefore repeated courses are unlikely to mount an improved response.

E Switch to oral prednisolone

A 56-year-old woman presented with a 3-month history of itching in the groin region. Her GP had prescribed topical steroids for presumed 'eczema'. This has not been of any benefit.

The rash is shown below:

What is the most likely diagnosis?

A	Tinea incognito
B	*Pthirus pubis*
C	*Pediculus humanus humanus*
D	*Malassezia furfur*
E	*Candida albicans*

8:44
594-042-7551
Leave

The rash is shown below:

What is the most likely diagnosis?

Your answer was correct

A	Tinea incognito
B	*Pthirus pubis*
C	*Pediculus humanus humanus*
D	*Malassezia furfur*
E	*Candida albicans*

Explanation

A Tinea incognito

Tinea is an infection with a dermatophyte fungus. Tinea incognito is the name given to tinea when the clinical

Audio Video Share Participants More

8:44
594-042-7551 Leave

A Tinea incognito

Tinea is an infection with a dermatophyte fungus. Tinea incognito is the name given to tinea when the clinical appearance has been altered by inappropriate treatment, usually a steroid cream. Compared with untreated tinea corporis, tinea incognito has a less raised margin, is less scaly and more pustular. Treatment with a topical anti-fungal and loose-fitting cotton underwear is likely to resolve the problem.

B *Pthirus pubis*

Pubic crabs produce itching and the bites result in wheals and erythematous or bluish macules.

C *Pediculus humanus humanus*

This is the body louse, where the lice themselves or their eggs (nits) may be visible.

D *Malassezia furfur*

This is the yeast infection thought to be responsible for seborrheic dermatitis and pityriasis versicolor, presenting with a rash on the face or the trunk most commonly.

E *Candida albicans*

Candida albicans is more likely to present as an erythematous moist rash with evidence of adherent white discharge. Vulval candidiasis is more likely to be seen than the skin fold/perineal infection seen here.

Rate this question:
Audio Video Share Participants More

You are asked to consult on a patient who is on the Care of the Elderly Ward by a colleague. She has been identified as having zinc deficiency.

Which of the following would you expect to find?

A	Beau's lines
B	Bruising
C	Follicular hyperkeratosis
D	Pellagra
E	Pallor

36519

Submit

Previous Q... Skip Questi...

© Pastest 2019

You are asked to consult on a patient who is on the Care of the Elderly Ward by a colleague. She has been identified as having zinc deficiency.

Which of the following would you expect to find?

Your answer was correct

A Beau's lines

B Bruising

C Follicular hyperkeratosis

D Pellagra

E Pallor

Explanation

A Beau's lines

Zinc deficiency causes dermatitis, alopecia and diarrhoea, as well as failure to thrive in infants; this clinical tableau is otherwise known as acrodermatitis enteropathica. It also causes nail dystrophy with Beau's lines (deep, grooved lines that run from side to side on the fingernails).

B Bruising

Bruising and petechiae are commonly seen in vitamin K deficiency.

D Pellagra

E Pallor

Explanation

A Beau's lines

Zinc deficiency causes dermatitis, alopecia and diarrhoea, as well as failure to thrive in infants; this clinical tableau is otherwise known as acrodermatitis enteropathica. It also causes nail dystrophy with Beau's lines (deep, grooved lines that run from side to side on the fingernails).

B Bruising

Bruising and petechiae are commonly seen in vitamin K deficiency.

C Follicular hyperkeratosis

Follicular hyperkeratosis is seen in vitamin C and E deficiency.

D Pellagra

Pellagra (dermatitis, diarrhoea and dementia) are features seen in vitamin B3 deficiency.

E Pallor

Pallor is seen related to anaemia, causes of which include iron deficiency, B12 deficiency and folate deficiency.

Rate this question:

8:47

beau's lines

ALL IMAGES NEWS SHOPPING VIDEOS BOOKS MAPS FLIC

Latest GIF HD Product

nail kawasaki kawasaki disease thumb

Slide show: 7 fingernail problems not ...
mayoclinic.org

Beau's lines - Causes, symptoms ...
beautyhealthtips.in

Beau's Lines |
clinicalexams.co.uk

Transverse Lines of the Nails | The ...
amjmed.org

What Are Beau's Lines? - Health - NAILS ...
nailsmag.com

Discover Updates Search Recei

8:47

beau's lines

Latest GIF HD Product

nail kawasaki kawasaki disease thumb

Slide show: 7 fingernail problems not ...
mayoclinic.org

Beau's lines - Causes, symptoms ...
beautyhealthtips.in

Beau's Lines |
clinicalexams.co.uk

Transverse Lines of the Nails | The ...
amjmed.org

Beau's Lines: How to Treat, Causes, and ...
nailpro.com

What Are Beau's Lines? - Health - NAILS ...
nailsmag.com

Discover Updates Search Recen

8:47
594-042-7551 Leave

Pastest+ Question 7 of 69

A 51-year-old woman presents with a 6-month history of facial flushing. She is known to be hypertensive and is a type 2 diabetic.

Her current medications include bisoprolol, diltiazem, metformin and aspirin.

She says the flushing only affects her face. It can occur at any time and lasts for hours; there is no rash associated with the flushing, and there are no other associated symptoms. It became much more noticeable after her blood pressure medication was changed.

Clinical examination is unremarkable.

Which of the following is the most likely explanation for this patient's flushing?

A	Rosacea
B	Menopause
C	Iatrogenic
D	Anxiety
E	Mitral insufficiency

Submit

Previous Q... Skip Questi...

Audio Video Share Participants 1 More

8:48
594-042-7551 Leave

A 51-year-old woman presents with a 6-month history of facial flushing. She is known to be hypertensive and is a type 2 diabetic.

Her current medications include bisoprolol, diltiazem, metformin and aspirin.

She says the flushing only affects her face. It can occur at any time and lasts for hours; there is no rash associated with the flushing, and there are no other associated symptoms. It became much more noticeable after her blood pressure medication was changed.

Clinical examination is unremarkable.

Which of the following is the most likely explanation for this patient's flushing?

Your answer was incorrect

A Rosacea

B Menopause

C Iatrogenic

D Anxiety

E Mitral insufficiency

Explanation

C Iatrogenic

Calcium channel blockers (such as diltiazem) are a

Audio Video Share Participants More

8:49
594-042-7551 Leave

Explanation

C Iatrogenic

Calcium channel blockers (such as diltiazem) are a common cause of facial flushing, which can often be continuous and persistent. The typical history of exacerbated flushing after a change in antihypertensive medications gives the answer away.

A Rosacea

Rosacea is of largely unknown cause. Other than facial flushing, it is typically associated with a rash. This is in the form of persistent redness, telangiectasia and pustules. Severe chronic cases can develop rhinophyma (enlarged, bulbous nose) due to granulomatous infiltration. Treatment includes oral tetracycline antibiotics and topical agents (such as metronidazole, azelaic acid and ivermectin). Resistant disease may require treatment with isotretinoin.

B Menopause

Most women who complain of flushing do suspect the transition to menopause, but it is important to remember the other causes. Patients complaining of associated symptoms of sweating waking them at night are likely to be menopausal. Other common symptoms include irregular menstruation, atrophic vaginitis, mood swings and lack of energy.

D Anxiety

Anxiety is a well-recognised cause of flushing. Severe anxiety attacks are usually associated with palpitations

Audio Video Share Participants More

the other causes. Patients complaining of associated symptoms of sweating waking them at night are likely to be menopausal. Other common symptoms include irregular menstruation, atrophic vaginitis, mood swings and lack of energy.

D Anxiety

Anxiety is a well-recognised cause of flushing. Severe anxiety attacks are usually associated with palpitations, sweating, light-headedness and even chest discomfort. The lack of these symptoms and the fact that she is on treatment with bisoprolol (beta-blockers are commonly used in the management of severe anxiety) make this an unlikely diagnosis.

E Mitral insufficiency

Mitral regurgitation can present with a wide range of symptoms, including facial erythema. However, the lack of other associated symptoms (such as breathlessness, oedema and orthopnoea), as well as a normal clinical examination, points away from this diagnosis.

Rate this question:

Next Question

Previous Q... Tag Questi... Feedback End Session

Blog About Pastest Contact Us Help

© Pastest 2019

An 85-year-old man who lives alone was admitted following a fall at home. He is noted to have a rash to his lower legs which consists of petechiae, follicular hyperkeratosis and perifollicular haemorrhages. His gums bleed easily on performing oral hygiene, and the remaining teeth are loose.

Investigations:

Hb	12.1 g/dl
WC	7.0×10^9 /l
PLT	180×10^9/l
MCV	90 fl

What is the likely diagnosis?

A Zinc deficiency

B Myelodysplasia

C Ascorbic acid deficiency

D Folliculitis

E Keratosis pilaris

Submit

8:50

Explanation

C Ascorbic acid deficiency

This scenario describes scurvy, vitamin C (ascorbic acid) deficiency, which leads to reduction in collagen formation and associated capillary fragility. It occurs in people with poor dietary intake who eat little or no fruit and vegetables, commonly alcoholics and elderly people existing on a 'tea and toast' diet. Pregnancy, lactation and thyrotoxicosis increase ascorbic acid requirements and may precipitated scurvy. The normochromic, normocytic anaemia reflects bleeding into tissues, while the normal platelet count excludes the differential of thrombocytopenia.

A Zinc deficiency

Zinc deficiency leads to well-demarcated psoriasiform and eczematous-like plaques, initially occurring in perioral and anogenital areas.

B Myelodysplasia

Myelodysplasia is likely to result in significant anaemia and decreased white cell and platelet counts, rather than the relatively normal blood picture seen here.

D Folliculitis

The bleeding gums seen here are inconsistent with a diagnosis of folliculitis.

E Keratosis pilaris

Keratosis pilaris is a common and harmless condition associated with rough skin affecting the backs of the upper arms, front of the thighs and the buttocks.

Rana Alnasser's screen

8:51

A 32-year-old woman presents to the General Medical Clinic with a rash affecting her shins. It has grown slowly over months and causes no pain. She has no past medical history. She denies any systemic symptoms.

The rash is pictured below.

She undergoes blood tests including full blood count, renal profile, fasting blood glucose and fasting cholesterol. All investigations are normal.

What is the most appropriate management plan?

A	Metformin
B	Insulin
C	Topical steroids
D	No treatment available
E	Aspirin

71604

Rana Alnasser's screen

C Topical steroids

This patient has necrobiosis lipoidica. This is an inflammatory dermatological condition which presents with callous lesions, red-to-brown colour and central atrophy over months to years, typically on the shins of people who are in their 30s and who have diabetes. It does not correlate with level of diabetic control. Management should generally be with potent topical steroids which reduce inflammation but do not help atrophy. If this fails, then immunomodulating drugs can be used.

D No treatment available

While there is no definitive treatment for necrobiosis lipoidica, there are several options. Topical steroids are useful in reducing inflammation and immunomodulating drugs can help healing, and laser treatments can stabilise erythema and telangiectasia.

A Metformin

Metformin would be the first-line treatment for patients with type 2 diabetes mellitus. The rash is consistent with necrobiosis lipoidica, but not all cases are seen in people with diabetes. The normal investigations and lack of symptoms such as polyuria and polydipsia exclude this as an answer.

B Insulin

Insulin would be the first-line treatment for patients with type 1 diabetes mellitus or poorly controlled type 2 diabetes, failing other treatments. The rash is consistent with necrobiosis lipoidica, but not all cases are seen in people with diabetes. The normal investigations and lack of symptoms exclude type 1 diabetes, and the age of

An 18-year-old man from a travelling family presents to the Dermatology Clinic for review. He has a number of yellowish papules in the axilla and groin and over the lateral part of the neck. He has been told by a friend that it looks like 'chicken skin'.

He tells you he feels chronically tired, and a haemoglobin checked by his GP is 99 with a microcytic picture.

Ophthalmological examination shows angioid streaks and maculopathy. A skin biopsy confirmed the presence of calcification of dermal elastic fibres.

Which of the following diagnoses is most likely?

A	Psedoxanthoma elasticum
B	Marfan syndrome
C	Ehlers-Danlos syndrome
D	Familial hypercholesterolaemia
E	Homocystinuria

32317

Submit

An 18-year-old man from a travelling family presents to the Dermatology Clinic for review. He has a number of yellowish papules in the axilla and groin and over the lateral part of the neck. He has been told by a friend that it looks like 'chicken skin'.

He tells you he feels chronically tired, and a haemoglobin checked by his GP is 99 with a microcytic picture.

Ophthalmological examination shows angioid streaks and maculopathy. A skin biopsy confirmed the presence of calcification of dermal elastic fibres.

Which of the following diagnoses is most likely?

Your answer was correct

A	Psedoxanthoma elasticum
B	Marfan syndrome
C	Ehlers-Danlos syndrome
D	Familial hypercholesterolaemia
E	Homocystinuria

Explanation

A Psedoxanthoma elasticum

Pseudoxanthoma elasticum (PXE) is a rare, inherited disorder in which elastic fibres become fragmented and calcified.

8:53

Explanation

A	Psedoxanthoma elasticum

Pseudoxanthoma elasticum (PXE) is a rare, inherited disorder in which elastic fibres become fragmented and calcified.

Patients with the following three diagnostic criteria definitely have PXE:

- Characteristic skin signs (yellow papules in flexural areas)
- Characteristic skin histology fragmentation, clumping and calcification of dermal elastic fibres
- Ophthalmic features (angioid streaks, mottled peau d'orange retinal pigmentation, maculopathy).

B	Marfan syndrome

Marfan syndrome skin changes include striae, particularly affecting the thoracolumbar and sacral region, rather than the plucked skin appearance seen here. It is also associated with the Marfan body habitus and recurrent joint and lens dislocation.

C	Ehlers-Danlos syndrome

Characteristic features of Ehlers-Danlos include bruising, bleeding from the gastrointestinal tract, dissecting thoracic aortic aneurysm, widening of scars related to surgery and injury, laxity of joints, hernias and skin hyperelasticity.

D	Familial hypercholesterolaemia

Familial hypercholesterolaemia is associated with corneal arcus and tendon xanthomata, rather than the skin.

Rana Alnasser's screen

with the Marfan body habitus and recurrent joint and lens dislocation.

C Ehlers-Danlos syndrome

Characteristic features of Ehlers-Danlos include bruising, bleeding from the gastrointestinal tract, dissecting thoracic aortic aneurysm, widening of scars related to surgery and injury, laxity of joints, hernias and skin hyperelasticity.

D Familial hypercholesterolaemia

Familial hypercholesterolaemia is associated with corneal arcus and tendon xanthomata, rather than the skin appearance seen here.

E Homocystinuria

Homocystinuria is associated with similar features to Marfan, including lens dislocation and joint dislocation, although parents often suffer from a degree of learning difficulty.

Rate this question:

Next Question

© Pastest 2019

A 34-year-old woman presents to the Dermatology Clinic for review. She has a history of coeliac disease, for which she follows a gluten-free diet, but is otherwise well. She has noticed non-scarring hair loss which began as a small area on the posterior aspect of her scalp, but has increased over the past few months.

An image of her hair is shown below.

Which of the following is the most likely diagnosis?

A	Alopecia areata
B	Androgenic alopecia
C	Dermatitis herpetiformis
D	Lichen planus
E	Tinea capitis

71580

Explanation

A Alopecia areata

This patient has non-scarring hair loss against a history of pre-existing treated autoimmune disease – the coeliac disease reported here. The pattern of hair loss shown on the image is consistent with alopecia areata, rather than other causes of non-scarring hair loss such as androgenic alopecia. Spontaneous regrowth does occur in around half of patients, but many patients will experience relapses. Intralesional and topical corticosteroids are used in the treatment of alopecia, although the response is often very poor.

B Androgenic alopecia

Androgenic alopecia results in bitemporal and central recession of hair, rather than the irregularly shaped area of posterior hair loss seen here.

C Dermatitis herpetiformis

Dermatitis herpetiformis is associated with an intensely itchy rash with small vesicles, which affect extensor surfaces of the arms and legs, buttocks and upper thighs.

D Lichen planus

Lichen planus is associated with smooth white patches where there is hair loss; there may also be signs of erythema and skin scaling around hair follicles at the margins of an area of hair loss.

E Tinea capitis

Tinea capitis fungal infection results in a circular area of

recession of hair, rather than the irregularly shaped area of posterior hair loss seen here.

C Dermatitis herpetiformis

Dermatitis herpetiformis is associated with an intensely itchy rash with small vesicles, which affect extensor surfaces of the arms and legs, buttocks and upper thighs.

D Lichen planus

Lichen planus is associated with smooth white patches where there is hair loss; there may also be signs of erythema and skin scaling around hair follicles at the margins of an area of hair loss.

E Tinea capitis

Tinea capitis fungal infection results in a circular area of hair loss with scaling and erythema around the margin of the circle. There are also broken-off hairs 1–3 mm above the level of the scalp.

Rate this question:

© Pastest 2019

A 41-year-old woman presented with fatigue, joint aches and dry, painful, red eyes.

Routine blood testing reveals a calcium level just above the upper end of the normal range. A biopsy of one of her skin lesions was taken.

Which enzyme is activated by macrophages in this condition?

A	Lactate dehydrogenase
B	1-alpha hydroxylase
C	Lysozyme
D	Glucose-6-phosphate dehydrogenase
E	Acid phosphatase

B 1-alpha hydroxylase

1-alpha hydroxylase is activated by macrophages in sarcoid granulomas (the diagnosis here), and converts 25-hydroxyvitamin D3 to 1,25-dihydroxyvitamine D3, the active form of the vitamin. Absorption of calcium from the gut increases as a consequence as does renal calcium reabsorption from the distal tubule.

A Lactate dehydrogenase

Lactate dehydrogenase is raised in myonecrosis, haematological malignancies and in patients with haemolysis.

C Lysozyme

Lysozyme is an enzyme which drives bacterial cell wall lysis, it is not involved in the pathogenesis of sarcoidosis.

D Glucose-6-phosphate dehydrogenase

Deficiency of G-6PD leads to red cell haemolysis in the presence of drugs which act as oxidising agents.

E Acid phosphatase

Acid phosphatase is used as a marker for prostate cancer.

Rate this question:

Next Question

A 24-year-old, Japanese city banker presents with recurrent mouth ulcers. He was seen by the oral surgeons, who prescribed chlorhexidine mouthwashes and oral aciclovir. He has used prednisolone lozenges in the past with good effect. More recently, the ulcers have been occurring more frequently.

In the last 2 days, he has felt pain at the tip of his penis, particularly when having sexual intercourse. He has also felt increasingly tired recently, to the point that he has given up playing football.

He denies any weight loss and his appetite is unchanged. He has a history of irritable bowel disease. He also remembers treating an eye condition with steroid drops a year or two previously.

He is currently taking oxytetracycline prescribed by his general practitioner (GP) for acne.

On examination, there are multiple aphthous ulcers in the oral cavity. There is also a small aphthous ulcer on the tip of the penis.

Cardiovascular, respiratory and neurological examinations are unremarkable.
Abdominal examination reveals mild, diffuse tenderness but no masses. Rectal examination reveals no abnormality.

Investigations:

Hb	12 g/dl
WCC	9.0×10^9/l
PLT	400×10^9/l
Na^+	140 mmol/l
K^+	4.0 mmol/l
Urea	6.8 mmol/l
Creatinine	100 μmol/l
ESR	[illegible] mm/h

but no masses. Rectal examination reveals no abnormality.

Investigations:

Hb	12 g/dl
WCC	9.0×10^9/l
PLT	400×10^9/l
Na^+	140 mmol/l
K^+	4.0 mmol/l
Urea	6.8 mmol/l
Creatinine	100 μmol/l
ESR	20 mm/h
Anti-nuclear antibody	-
Anti-dsDNA antibody	-

What is the most likely diagnosis?

A Crohn's disease

B Behçet's syndrome

C Reiter's disease

D Herpes simplex type I infection

E Systemic lupus erythematosus

Submit

Rana Alnasser's screen

B Behçet's syndrome

This is a chronic multi-system disease, most prevalent in the Mediterranean, Middle East and Japan. It has been associated with various HLA types including B12, -B51 and -B5. There is no specific diagnostic test, making it a diagnosis of exclusion. Its features can overlap with those of Crohn's disease, and therefore the latter must be excluded. It is a systemic vasculitic disorder involving arteries and veins, with a tendency to thrombosis. In over 90% of cases there are painful oral aphthous ulcers, in over 70% genital aphthous ulcers and in over 50% ocular inflammation occurs. Other features include arthritis, central nervous system involvement, skin lesions (e.g. erythema nodosum, folliculitis and acneiform lesions) and pathergy (abnormal response to tissue injury, e.g. skin ulceration following trauma or venepuncture). It commonly runs a relapsing and remitting course. Treatment is largely symptomatic in mild cases, but systemic corticosteroids or immunosuppressants may be required by some.

A Crohn's disease

Oral aphthous ulceration is a feature of Crohn's, but genital ulcers are not. Uveitis, which is suggested in the scenario, can be associated with a wide variety of conditions including Crohn's, but is one of the commoner features of Behçet's disease. Acne, whilst extremely common, is another feature supportive of Behçet's. Overall, the constellation of findings in a Japanese patient, with no specific features of inflammatory bowel disease, make Behçet's disease the best answer.

C Reiter's disease

Reactive arthritis (previously known as Reiter syndrome) usually follows a sexually transmitted infection (especially chlamydia) or gastroenteritis; arthritis is a key feature

another feature supportive of Behçet's. Overall, the constellation of findings in a Japanese patient, with no specific features of inflammatory bowel disease, make Behçet's disease the best answer.

C Reiter's disease

Reactive arthritis (previously known as Reiter syndrome) usually follows a sexually transmitted infection (especially chlamydia) or gastroenteritis; arthritis is a key feature which is lacking here; otherwise, there may be urethritis (rather than discrete genital ulcers) and conjunctivitis.

D Herpes simplex type I infection

This tends to cause peri-oral rather than genital disease. Steroid treatment is likely to worsen it. Whilst it can be recurrent as in this scenario, there are many features here which it would not explain.

E Systemic lupus erythematosus

Oral ulceration is a common feature of SLE, but genital ulcers are not. Lupus antibodies are negative and Behçet's disease is a much more likely explanation for the multiple features described.

6295

Rate this question:

A 48-year-old man from Brazil, who has been visiting his sister in England, attends the Neurology Clinic with a left-sided foot drop.

On examination, you note a number of hypopigmented lesions on his upper and lower limbs within which there is decreased sensation. The superficial nerves in his limbs are palpable and tender. He also has a non-tender ulcer on the palmar region of his hand.

Investigations:

Haemoglobin (Hb)	12.0 g/dl
White cell count (WCC)	6.7×10^9/l
Platelets (PLT)	201×10^9/l
Sodium (Na^+)	141 mmol/l
Potassium (K^+)	4.9 mmol/l
Creatinine (Cr)	120 µmol/l

Which of the following is the most useful test to confirm the diagnosis?

A Lepromin test

B Skin biopsy

C Heaf test

D *Mycobacterium leprae* serology

E Culture of skin scrapings

8:58

B Skin biopsy

The answer is Skin biopsy (Option B).

Skin biopsy is the most specific investigation. It can reveal the presence of granuloma, neuritis and the presence of acid-alcohol-fast bacilli. Treatment is defined by the morphologic index, a measure of the number of viable bacilli per 100 bacilli seen in the lepromatous tissue.

A Lepromin test

Lepromin test (Option A) is incorrect.

The features above are highly suggestive of leprosy. While the lepromin test may be used to determine the type of leprosy a person has contracted, it is not used in confirming the diagnosis of leprosy.

C Heaf test

Heaf test (Option C) is incorrect.

The Heaf test used to be performed to determine whether a person has been previously exposed to infection with tuberculosis (TB).

The test required the injection of multiple areas on the forearm with tuberculin purified protein derivative. Interpretation was performed a few days later and graded on a scale ranging from negative to strongly positive. The production line of the Heaf test was discontinued in 2005, and the Mantoux test is now used instead.

D *Mycobacterium leprae* serology

Mycobacterium leprae serology (Option D) is incorrect.

While serology and polymerase chain reaction (PCR) may be useful in making the diagnosis, they are not always positive, especially in early disease.

Rana Alnasser's screen

8:58
594-042-7551 Leave
MyPastest
https://mypastest.pastest.com

Heaf test (Option C) is incorrect.

The Heaf test used to be performed to determine whether a person has been previously exposed to infection with tuberculosis (TB).

The test required the injection of multiple areas on the forearm with tuberculin purified protein derivative. Interpretation was performed a few days later and graded on a scale ranging from negative to strongly positive. The production line of the Heaf test was discontinued in 2005, and the Mantoux test is now used instead.

D	*Mycobacterium leprae* serology

Mycobacterium leprae serology (Option D) is incorrect.

While serology and polymerase chain reaction (PCR) may be useful in making the diagnosis, they are not always positive, especially in early disease.

E	Culture of skin scrapings

Culture of skin scrapings (Option E) is incorrect.

This is used in the diagnosis of superficial fungal infections of the skin with both dermatophytes (such as *Trichophyton* and *Microsporum* species) and yeasts (such as *Candida* and *Malassezia* species).

Rate this question:

Next Question

Previous Q... Text Questi... Feedback End Session
Audio Video Share Participants More

8:59
594-042-7551
Leave

Pastest+

A 36-year-old woman presents with fragile skin, blistering, milia and hyperpigmentation over her hands, which occurred after a recent summer holiday to Cyprus.

What is the most likely diagnosis?

A	Porphyria cutanea tarda (PCT)
B	Acute intermittent porphyria
C	Cutaneous lupus erythematosus
D	Dermatitis herpetiformis
E	Pompholyx

Submit

Previous Q...
Skip Questi...
Audio
Video
Share
Participants
More

8:59
594-042-7551 Leave

Pastest+ Question 15 of 69

A 36-year-old woman presents with fragile skin, blistering, milia and hyperpigmentation over her hands, which occurred after a recent summer holiday to Cyprus.

What is the most likely diagnosis?

Your answer was correct

A	Porphyria cutanea tarda (PCT)
B	Acute intermittent porphyria
C	Cutaneous lupus erythematosus
D	Dermatitis herpetiformis
E	Pompholyx

Explanation

A Porphyria cutanea tarda (PCT)

Audio Video Share Participants More

8:59
594-042-7551 Leave

A Porphyria cutanea tarda (PCT)

PCT is the most common of the porphyrias. It is characterised by fragility and blistering of exposed skin following exposure to sunlight. A pathognomonic finding is the presence of milia at sites of healing blisters. PCT is generally acquired and is the result of deficiency of uroporphyrinogen decarboxylase. Other features include scarring alopecia following resolution of bullae on the scalp, hypertrichosis and hyperpigmentation. Risk factors for the development of PCT include alcohol, oestrogens and sunshine, all of which this lady may have been exposed to in Cyprus.

B Acute intermittent porphyria

Acute intermittent porphyria is a metabolic genetic disorder affecting the production of haem. It may present with a wide range of symptoms (such as abdominal pain, dark urine, anxiety and confusion) but is not associated with cutaneous manifestations.

C Cutaneous lupus erythematosus

Systemic lupus erythematosus (SLE) is an autoimmune connective tissue disorder. About 80% of patients with SLE have skin involvement (cutaneous lupus erythematosus), and it is the first sign of SLE in about one-quarter of these patients. SLE-specific lesions tend to be induced or aggravated by exposure to ultraviolet light and are localised in sun-exposed sites such as the face, neck and upper back. It may present with a variety of cutaneous signs (such as a malar or butterfly rash, blistering and alopecia) and can take both acute and chronic forms.

D Dermatitis herpetiformis

Audio Video Share Participants 1 More

8:59
594-042-7551 Leave

and it is the first sign of SLE in about one-quarter of these patients. SLE-specific lesions tend to be induced or aggravated by exposure to ultraviolet light and are localised in sun-exposed sites such as the face, neck and upper back. It may present with a variety of cutaneous signs (such as a malar or butterfly rash, blistering and alopecia) and can take both acute and chronic forms.

D Dermatitis herpetiformis

Dermatitis herpetiformis occurs in close association with coeliac disease and presents with very itchy grouped vesicles, most frequent on the extensor surface of the knees, elbows, buttocks and shoulders. Treatment is with dapsone and a gluten-free diet.

E Pompholyx

This is a subtype of eczema that occurs in the hands and feet due to the presence of sweat. It presents with recurrent crops of vesicles and blisters which cause intense itch.

Rate this question:

Next Question

Previous Q... Tag Questi... Feedback End Session

Blog About Pastest Contact Us Help

© Pastest 2019

Audio Video Share Participants More

9:01

A 36-year-old man presents with a painful, blistering rash affecting his body. He has recently commenced a course of carbamazepine for idiopathic epilepsy.

There is no history of previous skin lesions.

The lesions are very itchy and fragile. He has been feeling unwell, and his appetite has reduced remarkably.

What is the most likely diagnosis?

A	Pemphigus vulgaris
B	Erythema multiforme
C	Bullous pemphigoid
D	Erythema nodosum
E	Guttate psoriasis

Submit

Rana Alnasser's screen

B Erythema multiforme

The typical target lesions of erythema multiforme have a sharp margin, a round shape and three concentric zones of colours and possibly a blister in the middle. Erythema multiforme may involve the mouth, with multiple irregular erosions. Extensive involvement of the mouth, lips, conjunctivae and genitalia is called Stevens–Johnson syndrome. Skin reactions are thought more likely to occur with carbamazepine in patients with the B1502 allele when they are of Chinese or Thai ethnic origin, and in patients with the A3101 allele when they are of European or Japanese descent.

A Pemphigus vulgaris

This is an autoimmune cause of blistering that may also affect the eyes and mucous membranes. Presentation is with areas of flaccid blistering or erosions. Diagnosis is with immunofluorescence studies on skin tissue and serum. Treatment is with immunosuppressive medications such as prednisolone, azathioprine and ciclosporin.

C Bullous pemphigoid

This is another immune-mediated blistering disorder that presents with tense blisters in the elderly. It uncommonly affects the mucosae and may be preceded by an itchy rash lasting from days to weeks (pre-bullous pemphigoid). The rash associated with carbamazepine may progress to formation of bullae, but this is not due to underlying pemphigoid.

D Erythema nodosum

Erythema nodosum presents with tender, red lumps on the front of the shins. It is thought to be a hypersensitivity

Treatment is with immunosuppressive medications such as prednisolone, azathioprine and ciclosporin.

C Bullous pemphigoid

This is another immune-mediated blistering disorder that presents with tense blisters in the elderly. It uncommonly affects the mucosae and may be preceded by an itchy rash lasting from days to weeks (pre-bullous pemphigoid). The rash associated with carbamazepine may progress to formation of bullae, but this is not due to underlying pemphigoid.

D Erythema nodosum

Erythema nodosum presents with tender, red lumps on the front of the shins. It is thought to be a hypersensitivity reaction to a number of causes such as: tonsillitis, sarcoidosis, tuberculosis, pregnancy, the contraceptive pill and other medications. Treatment consists of managing the underlying pathology and anti-inflammatory medication to reduce the discomfort.

E Guttate psoriasis

Guttate psoriasis may be triggered by an infection such as tonsillitis or a stressful event. It presents with multiple, small and widespread teardrop-like psoriatic plaques in a widespread distribution. Management is usually in the form of topical agents or phototherapy.

Rate this question:

A 32-year-old Nigerian man presents with the intensely itchy rash on his neck, shown in the photograph below. He has similar lesions on the trunk and small, hyperpigmented papules on his forearms and wrists.

He gives a 6-month history of these lesions and recently he returned from a trip to Nigeria. He feels well in himself otherwise. He remembers having tuberculosis as a child and was treated for it in Nigeria.

What is the diagnosis?

A	Nodular prurigo
B	Cutaneous tuberculosis infection
C	Lichen planus
D	Kaposi's sarcoma

itchy rash on his neck, shown in the photograph below. He has similar lesions on the trunk and small, hyperpigmented papules on his forearms and wrists.

He gives a 6-month history of these lesions and recently he returned from a trip to Nigeria. He feels well in himself otherwise. He remembers having tuberculosis as a child and was treated for it in Nigeria.

What is the diagnosis?

A	Nodular prurigo
B	Cutaneous tuberculosis infection
C	Lichen planus
D	Kaposi's sarcoma
E	Keloid scars

594-042-7551 Leave
MyPastest
https://mypastest.pastest.com

A 32-year-old Nigerian man presents with the intensely itchy rash on his neck, shown in the photograph below. He has similar lesions on the trunk and small, hyperpigmented papules on his forearms and wrists.

He gives a 6-month history of these lesions and recently he returned from a trip to Nigeria. He feels well in himself otherwise. He remembers having tuberculosis as a child and was treated for it in Nigeria.

What is the diagnosis?

Your answer was incorrect

A Nodular prurigo

Audio Video Share Participants More

C Lichen planus

Classical lichen planus is characterised by itchy, violaceous, polygonal, flat-topped papules most commonly developing over the wrists and ankles. A pale, lacy network is often found in the mouth, though this may be asymptomatic. The presence of Wickham's striae – a fine, white lacy pattern over the papules – is characteristic. The Koebner phenomenon is typically seen in lichen planus (whereby the rash 'colonises' sites of trauma a few days later). Lichen planus has been associated with liver disease including hepatitis C, primary biliary cirrhosis and chronic active hepatitis. It usually resolves in 6–18 months. It often responds to potent or very potent topical steroid, but some patients will require oral prednisolone. Lesions tend to resolve to leave deep post-inflammatory hyperpigmentation, especially in darker skin-types.

The hypopigmentation seen in this case is attributable to scratching.

A Nodular prurigo

This condition is sometimes associated with underlying eczema. Like lichen planus, it is intensely itchy. Nodular lesions are found most commonly on the legs but can occur anywhere on the body. The lesions on the image are plaques rather than nodules; papules on the wrists are often seen in lichen planus.

B Cutaneous tuberculosis infection

There are various possible manifestations of tuberculosis infection in the skin, but none would be expected to be intensely pruritic.

D Kaposi's sarcoma

9:05
594-042-7551
Leave

C Lichen planus

Classical lichen planus is characterised by itchy, violaceous, polygonal, flat-topped papules most commonly developing over the wrists and ankles. A pale, lacy network is often found in the mouth, though this may be asymptomatic. The presence of Wickham's striae – a fine, white lacy pattern over the papules – is characteristic. The Koebner phenomenon is typically seen in lichen planus (whereby the rash 'colonises' sites of trauma a few days later). Lichen planus has been associated with liver disease including hepatitis C, primary biliary cirrhosis and chronic active hepatitis. It usually resolves in 6–18 months. It often responds to potent or very potent topical steroid, but some patients will require oral prednisolone. Lesions tend to resolve to leave deep post-inflammatory hyperpigmentation, especially in darker skin-types.

The hypopigmentation seen in this case is attributable to scratching.

A Nodular prurigo

This condition is sometimes associated with underlying eczema. Like lichen planus, it is intensely itchy. Nodular lesions are found most commonly on the legs but can occur anywhere on the body. The lesions on the image are plaques rather than nodules; papules on the wrists are often seen in lichen planus.

B Cutaneous tuberculosis infection

There are various possible manifestations of tuberculosis infection in the skin, but none would be expected to be intensely pruritic.

D Kaposi's sarcoma

This presents with red, purple or brown cutaneous nodules

Audio Video Share Participants More

patients will require oral prednisolone. Lesions tend to resolve to leave deep post-inflammatory hyperpigmentation, especially in darker skin-types.

The hypopigmentation seen in this case is attributable to scratching.

A Nodular prurigo

This condition is sometimes associated with underlying eczema. Like lichen planus, it is intensely itchy. Nodular lesions are found most commonly on the legs but can occur anywhere on the body. The lesions on the image are plaques rather than nodules; papules on the wrists are often seen in lichen planus.

B Cutaneous tuberculosis infection

There are various possible manifestations of tuberculosis infection in the skin, but none would be expected to be intensely pruritic.

D Kaposi's sarcoma

This presents with red, purple or brown cutaneous nodules or plaques, which are usually asymptomatic.

E Keloid scars

Although spontaneous keloids are recognised, the eruption here is too widespread for this and involves sites such as the wrists, where keloids would be most unexpected. Keloids usually have a smooth surface and form nodules or very thickened plaques. Associated itching is not usually severe.

Rate this question:

9:06

Google

nodular prurigo

ALL IMAGES NEWS SHOPPING VIDEOS MAPS BOOKS FLIGHT

Latest GIF HD Product

infected arm mild atopic back scalp face leg

Nodular prurigo | DermNet NZ
dermnetnz.org

Nodular prurigo | DermNet NZ
dermnetnz.org

Prurigo |
pcds.org

Prurigo | Primary Care Dermatology ...
pcds.org.uk

Product

Dr P. Marazzi/science ...
fineartamerica.com

Nodular
dermnetn

Nodular
skinpick.

Discover Updates Search Recent

Rana Alnasser's screen

Indian Journal of Dermatology, Venereology and Leprology

Cutaneous tuberculosis due to multidrug-resistant tubercle bacilli ...

Figure 2: Erythematous plaque over right cheek (a) before and (b) subsidence following treatment for a year

Images may be subject to copyright. Learn more

RELATED IMAGES

View Image
ijdvl.com

photo163-3
pathos223.com

Scrofuloderma involving cervical, submandi...
researchgate.net

Discover Updates Search Recent More

Rana Alnasser's screen

9:09

verrucosa cutis

ociated with tuberculosis verrucosa ...
anticscholar.org

neous tuberculosis, tuberculosis ...
dypu.org

rculosis verrucosa cutis - Pictures
dermatologico.com.br

Tuberculosis verrucosa cutis: - MEDGAG
medgag.com

Tuberculosis verrucosa cutis | Download ...
researchgate.net

tuberculosis verrucosa cutis ...
openi.nlm.nih.gov



Tuberculosis verrucosa cu
pinterest.com

Tuberculosis verrucosa cu
researchgate.net

Tuberculosis verrucosa cu
en.wikipedia.org

Discover Updates Search Recent

9:09
594-042-7551 Leave

A young woman is being investigated for an erythematous, scaly malar rash. She feels generally unwell, with frequent mouth ulcers and intermittent arthralgia of the metacarpophalangeal (MCP) and proximal interphalangeal (PIP) joints for the past few months. She also reports lack of appetite and has lost 5 kg in weight over the last 6 weeks.

Calcu

Normal

Which of the following tests is the most specific to the likely diagnosis?

A	Erythrocyte sedimentation rate (ESR)
B	C-reactive protein (CRP)
C	dsDNA antibodies
D	Antinuclear antibodies (ANAs)
E	Serum complement

Submit

Previous Q... Skip Questi...

Audio Video Share Participants More

9:10

MyPastest
https://mypastest.pastest.com

Explanation

C dsDNA antibodies

This patient already describes three criteria for SLE (> 4/11 are required to make a diagnosis, although these do not have to be present simultaneously). A high titre of dsDNA antibodies is virtually exclusive to SLE and would confirm this diagnosis. Titres can be used to measure disease activity.

A Erythrocyte sedimentation rate (ESR)

Raised ESR values are not diagnostic of SLE, but seen across multiple inflammatory conditions. ESR values can be used to monitor disease activity in SLE.

B C-reactive protein (CRP)

CRP is not particularly useful in SLE, as levels may remain low in active disease.

D Antinuclear antibodies (ANAs)

ANAs are autoantibodies that bind to contents of the cell nucleus. They are encountered in many conditions such as SLE, rheumatoid arthritis, scleroderma, dermatomyositis, autoimmune hepatitis and primary biliary cirrhosis.

E Serum complement

Complement levels, ESR and dsDNA titres can be used to monitor disease activity in SLE.

Rana Alnasser's screen

9:10

Consider the following image;

Which of the following is the most appropriate treatment for the affected nail?

A	Psoralen plus UVA treatment
B	Nail bed triamcinolone
C	Cutting the nail short
D	Removal of the nail
E	Topical corticosteroid ointment

Submit

Previous Q... Skip Questi...

Rana Alnasser's screen

9:12

Explanation

C Cutting the nail short

This patient has onycholysis, where the nail plate has separated from an abnormal nail matrix. There is no obvious skin disease affecting this or the other fingers, trauma would therefore be considered a possible cause. Cutting the nail short is the best way to avoid further damage.

A Psoralen plus UVA treatment

Similar to nail bed triamcinolone, this is usually considered for patients with psoriatic disease.

B Nail bed triamcinolone

Nail bed triamcinolone is considered in patients with severe nail dystrophy related to psoriasis.

D Removal of the nail

This runs the risk of the nail growing back in a more abnormal shape and should be avoided if possible.

E Topical corticosteroid ointment

This may have a role in onycholysis related to eczema.

Rate this question:

Next Question

Rana Alnasser's screen

9:12
594-042-7551 Leave
MyPastest
https://mypastest.pastest.com

Pastest+ Question 20 of 69

A 21-year-old man presents with multiple lesions over his torso.

Which of the following is not part of this disorder?

A	Café-au-lait patches
B	Periungual fibroma
C	Lisch nodules
D	Axillary freckling
E	Autosomal dominant inheritance

Submit

Audio Video Share Participants More

9:13

B Periungual fibroma

Periungual fibromas are not seen in neurofibromatosis, but are part of the characteristic lesions for tuberous sclerosis.

A Café-au-lait patches

Multiple neurofibromas are part of neurofibromatosis type 1 or von Recklinghausen's disease. It is characterised by the presence of six or more café-au-lait spots, axillary freckling and Lisch nodules (pigmented iris hamartomas). Neurological manifestations are seen in around 40% of patients, most commonly an optic nerve glioma. Neurofibromatosis type 2 (NF2) is characterised by bilateral acoustic neuromas and other central nervous system tumours. Café-au-lait spots and cutaneous neurofibromas are much less common in NF2 and are usually fewer in number.

C Lisch nodules

This is a well-recognised clinical feature of neurofibromatosis.

D Axillary freckling

Axillary freckling, along with café-au-lait spots, Lisch nodules and neurofibromas, is part of the diagnostic criteria for neurofibromatosis.

E Autosomal dominant inheritance

The inheritance of neurofibromatosis type 1 is autosomal dominant, and the gene is located on chromosome 17.

The following table displays key differences between neurofibromatosis and tuberous sclerosis:

Rana Alnasser's screen

9:13

The inheritance of neurofibromatosis type 1 is autosomal dominant, and the gene is located on chromosome 17.

The following table displays key differences between neurofibromatosis and tuberous sclerosis:

Syndrome	Frequency	Genotype	Types of endocrine tumours
Neurofibromatosis type 1	Prevalence of 1 per 4000–5000	*NF2* (17q11.2)	Somatostatin-/insulin-producing neuroendocrine tumour (NET) Duodenal NET Gastrointestinal stromal tumour (GIST)
Tuberous sclerosis	Prevalence of 1 per 5000–10 000	*TSC1* (9q34) *TSC2* (16p13)	Pancreatic NET

Rate this question:

Next Question

Previous Q... Tag Questi... Feedback End Session

Rana Alnasser's screen

A 21-year-old man presents with a painful right knee. He does not recall any injury. He is also found to have a non-itchy rash on his hands and feet, as well as reddened conjunctivae.

On questioning, he has had some mild dysuria and a painless penile rash.

What is the most likely cause?

A *Candida albicans*

B *Chlamydia trachomatis*

C *Helicobacter pylori*

D *Borrelia burgdorferi*

E Gluten-sensitive enteropathy

Submit

Previous Q... Skip Questi...

Rana Alnasser's screen

B *Chlamydia trachomatis*

This is reactive arthritis, and the rash is termed keratoderma blenorrhagica. It occurs secondary to *C. trachomatis* (which may also cause circinate balanitis, as i this case), *Salmonella*, *Shigella*, *Campylobacter jejuni* and *Yersinia*. Stool should be cultured if diarrhoea is present, and a urethral swab/sexual review should be performed, a urethritis may be asymptomatic. Arthritis is managed with rest, non-steroidal anti-inflammatory drugs (NSAIDs) and steroids, as it does not tend to respond to treatment of th underlying infection.

A *Candida albicans*

In immunocompromised individuals, *Candida* can affect a wide spectrum of systems. In immunocompetent hosts, infections are usually (but not always) limited to the mout or vagina (thrush).

C *Helicobacter pylori*

Even though other gastrointestinal infections are closely linked with reactive arthritis, *H. pylori* has only rarely been implicated in this process.

D *Borrelia burgdorferi*

Infections with this pathogen are transmitted via the Ixod tick and lead to Lyme disease. The disease starts with a rash (erythema chronicum migrans) and can progress to arthritis, neural involvement and heart disease. Non-disseminated disease responds well to treatment with doxycycline.

Rana Alnasser's screen

C *Helicobacter pylori*

Even though other gastrointestinal infections are closely linked with reactive arthritis, *H. pylori* has only rarely been implicated in this process.

D *Borrelia burgdorferi*

Infections with this pathogen are transmitted via the Ixode tick and lead to Lyme disease. The disease starts with a rash (erythema chronicum migrans) and can progress to arthritis, neural involvement and heart disease. Non-disseminated disease responds well to treatment with doxycycline.

E Gluten-sensitive enteropathy

This is associated with dermatitis herpetiformis, an itchy vesicular rash most frequently seen on the extensor surfac of the knees, elbows, buttocks and shoulders. Treatment i with dapsone and a gluten-free diet.

Rana Alnasser's screen

A 36-year-old woman presented with a receding frontal hair line and loss of eyebrows. Closer inspection of the hair follicles revealed hyperkeratosis within the hair follicles (shown) and perifollicular inflammation.

The black line on the image below denotes the original hair line.

She also had white, lacy streaks in her mouth and painless white streaks on the vulva.

Which of the following is the most likely diagnosis?

A	Lichen planopilaris
B	Discoid lupus erythematosus
C	Alopecia areata
D	Hypothyroidism
E	Lichen sclerosis

Explanation

A Lichen planopilaris

LPP is a variant of lichen planus. It causes inflammation around hair follicles with destruction of hair follicles and eventually a scarring alopecia. There is central horn plugging in the ostium of the follicle. Wickham's striae occur in lichen planus as do vulval lesions.

B Discoid lupus erythematosus

This is associated with an erythematous rash which is worse on sun exposure and potential scarring alopecia.

C Alopecia areata

This is associated with patches of non-scarring hair loss.

D Hypothyroidism

This is associated with brittle hair and non-scarring hair loss.

E Lichen sclerosis

This most commonly affects the vulva and is associated with pale skin changes and inflammation, which may eventually lead to fibrosis.

Rate this question:

Next Question

9:18

Google

wickham striae

ALL IMAGES NEWS SHOPPING VIDEOS MAPS BOOKS FLI

Latest GIF HD Product

lichen planus mouth skin dermoscopy adalah tongue

Wickham Striae - an overview ...
sciencedirect.com

Wickham striae - Wikipedia
en.wikipedia.org

Wick
youtu

Wickham striae in Oral lichen planus ...
medweiser.com

The Handheld Dermatoscope Improves the ...
jamanetwork.com

Wick
rese

Dermoscopic signs of lichen planus ...
casereports.bmj.com

Lich
derm

Figure 4. Reticular oral lichen planus: characteristic lacy white striae (Wickham's striae) and surrounding border of erythema.

Discover Updates Search Rece

Rana Alnasser's screen

This 31-year-old man presented with asymptomatic lesions on his knees, noticed by his general practitioner (GP) while doing a knee exam for knee pain. They are occasionally itchy. They are also present on his chest, elbows and buttocks.

He suffered an episode of acute pancreatitis which occurred whilst he lived in Kenya, which was put down to excess alcohol consumption.

What are the lesions found on his legs?

A	Xanthelasma palpebrum
B	Tuberous xanthomas
C	Tendinous xanthomas
D	Eruptive xanthomas
E	Xanthoma disseminatum

39080

Submit

9:20

This 31-year-old man presented with asymptomatic lesions on his knees, noticed by his general practitioner (GP) while doing a knee exam for knee pain. They are occasionally itchy. They are also present on his chest, elbows and buttocks.

He suffered an episode of acute pancreatitis which occurred whilst he lived in Kenya, which was put down to excess alcohol consumption.

What are the lesions found on his legs?

Your answer was correct

A	Xanthelasma palpebrum
B	Tuberous xanthomas
C	Tendinous xanthomas
D	Eruptive xanthomas
E	Xanthoma disseminatum

Explanation

D	Eruptive xanthomas

Eruptive xanthomas appear on extensor surfaces as crops

Rana Alnasser's screen

9:20

D Eruptive xanthomas

Eruptive xanthomas appear on extensor surfaces as crops of small red-yellow papules, and are associated with hypertriglyceridaemia, a potential cause of acute pancreatitis.

A Xanthelasma palpebrum

These are common, and exist as soft, yellow flattened lipid plaques over the eyelids, and are associated with mixed hyperlipidaemia.

B Tuberous xanthomas

Tuberous xanthomas are associated with elevated LDL cholesterol and mixed dyslipidaemia. They are firm painless nodules which occur over pressure areas.

C Tendinous xanthomas

Tendon xanthomas are slowly enlarging subcutaneous nodules over tendons, and are associated with familial hypercholesterolaemia.

E Xanthoma disseminatum

Xanthoma disseminatum is associated with hundreds of small yellow-brown papules due to a rare form of histiocytosis, not due to abnormalities in lipid metabolism.

39080

Rate this question:

Next Question

Rana Alnasser's screen

A patient presented with the following rash. His mother also suffers from a similar skin condition.

What is the probable diagnosis?

A	Eruptive xanthomas
B	Tuberous sclerosis
C	Neurofibromatosis
D	Dercum's disease
E	Keratosis pilaris

9:21
MyPastest
https://mypastest.pastest.com

Explanation

C	Neurofibromatosis

The answer is Neurofibromatosis (Option C).

The picture shows multiple cutaneous neurofibromata.

Criteria for the diagnosis of neurofibromatosis are:

- six or more café-au-lait spots
- two or more neurofibromas
- axillary freckling
- two or more Lisch nodules (iris hamartomata)
- optic glioma
- a parent or sibling with neurofibromatosis.

Associated abnormalities include:

- skeletal rib notching and other bony defects
- honeycomb lung
- intellectual disability
- kyphoscoliosis

hypertension (renal artery stenosis, phaeochromocytoma).

A	Eruptive xanthomas

Eruptive xanthomas (Option A) is incorrect.

These are rapidly occurring crops of small, red-yellow papules that commonly occur over the buttocks, shoulders, arms and legs. Lesions may be tender and itchy and are associated with hypertriglyceridaemia.

hypertension (renal artery stenosis, phaeochromocytoma).

A Eruptive xanthomas

Eruptive xanthomas (Option A) is incorrect.

These are rapidly occurring crops of small, red-yellow papules that commonly occur over the buttocks, shoulders, arms and legs. Lesions may be tender and itchy and are associated with hypertriglyceridaemia.

B Tuberous sclerosis

Tuberous sclerosis (Option B) is incorrect.

Features of tuberous sclerosis include angiofibromata, ash-leaf macules, shagreen patches and periungual fibromata. The condition may also be associated with epilepsy and cognitive impairment.

D Dercum's disease

Dercum's disease (Option D) is incorrect.

This condition (also known as adiposis dolorosa) is of unknown aetiology and characterised by a combination of lipomas, painful subcutaneous plaques and non-traumatic ecchymoses.

E Keratosis pilaris

Keratosis pilaris (Option E) is incorrect.

Keratosis pilaris is a very common form of dry skin, characterised by hair follicle plugging due to excess keratin. It most often affects the outer aspect of the forearms but may also occur in other sites in a symmetrical distribution.

Rana Alnasser's screen

9:21
594-042-7551 Leave

An 18-year-old Moroccan woman, who returned to the UK 4 months previously, attends with a 2-day history of the following painful 'lumps' on her forearms and shins.

She gives a 6-week history of intermittent night sweats, fever and general malaise. During this time, she has had intermittent lower abdominal pain and heavy periods. She has taken aspirin for the pain. She has no drug allergies and has no past medical history of note.

On examination, she is pyrexial (38 °C) and thin. Respiratory, cardiovascular, abdominal and neurological examinations are unremarkable. Vaginal examination reveals tenderness in the right adnexa.

Investigations:

Chest X-ray	Left upper lobe calcification
Abdominal X-ray	NAD
Antinuclear antibody	Negative
Hepatitis B surface antigen	Negative
Sputum: Ziehl–Neelsen (ZN) stain	Negative

Audio Video Share Participants More

She gives a 6-week history of intermittent night sweats, fever and general malaise. During this time, she has had intermittent lower abdominal pain and heavy periods. She has taken aspirin for the pain. She has no drug allergies and has no past medical history of note.

On examination, she is pyrexial (38 °C) and thin. Respiratory, cardiovascular, abdominal and neurological examinations are unremarkable. Vaginal examination reveals tenderness in the right adnexa.

Investigations:

Chest X-ray	Left upper lobe calcification
Abdominal X-ray	NAD
Antinuclear antibody	Negative
Hepatitis B surface antigen	Negative
Sputum: Ziehl–Neelsen (ZN) stain	Negative
High vaginal swab	Pus cells ++; ZN stain and culture pending

What is the most likely diagnosis?

A Sarcoidosis

B Tuberculosis

C Polyarteritis nodosa

D Toxic shock syndrome

E Crohn's disease

9:25

B Tuberculosis

This patient has erythema nodosum, which may affect parts of the body other than the shins. She is from Morocco and so tuberculosis is high on the differential diagnosis. The only other physical finding is the tenderness on vaginal examination, and this pathology in the ovarian tubes suggests a diagnosis of unilateral salpingitis secondary to tuberculosis. This can occur in the absence of respiratory infection or signs, although the apical calcification on CXR raises the possibility of previous pulmonary tuberculosis.

A Sarcoidosis

The marked pyrexia and adnexal tenderness are more in keeping with infection rather than an inflammatory process, although sarcoid is of course a recognised cause of erythema nodosum.

C Polyarteritis nodosa

Polyarteritis nodosa (PAN) is usually associated with gastrointestinal pathology, hepatitis B infection and may be associated with low-level positive ANA (anti-nuclear antibody) titres. Because there is no significant history of bowel disturbance, and hepatitis B is negative, PAN is unlikely.

D Toxic shock syndrome

Toxic shock syndrome is usually related to a retained tampon, rather than to fallopian tube infection as is hinted at here.

E Crohn's disease

Crohn's disease can present with abdominal pain and

Rana Alnasser's screen

A 42-year-old Egyptian man presents with changes on his nose for over 10 years.

Further examination reveals no further skin lesions or regional lymphadenopathy.

He was seen when in Cairo by his usual doctor, who told him that there was little he could do about the end of his nose, which had considerably worsened in appearance over the past few months. It does not give him any trouble, but he finds it unsightly.

What is the diagnosis?

A	Tularaemia
B	Lupus pernio
C	Lupus vulgaris
D	Basal cell carcinoma
E	Squamous cell carcinoma

9:27

A 42-year-old Egyptian man presents with changes on his nose for over 10 years.

Further examination reveals no further skin lesions or regional lymphadenopathy.

He was seen when in Cairo by his usual doctor, who told him that there was little he could do about the end of his nose, which had considerably worsened in appearance over the past few months. It does not give him any trouble, but he finds it unsightly.

What is the diagnosis?

Your answer was incorrect

A Tularaemia

B Lupus pernio

C Lupus vulgaris

D Basal cell carcinoma

E Squamous cell carcinoma

Rana Alnasser's screen

9:27

now very rare in developed countries. It presents as a slowly enlarging, infiltrated plaque. Diagnosis may be possible on histology or via tissue culture. Treatment is the same as that for pulmonary tuberculosis.

B Lupus pernio

This is a subtype of sarcoidosis. The nose and ears are common sites, but it is usually associated with deep-seated inflammation. The colour is violaceous or mauve and there is little surface change.

A Tularaemia

This tick-borne bacterial infection is endemic in Egypt. There are various types of presentation, including chronic skin ulceration. Over time, this tends to heal with scarring. Lymphadenopathy tends to be prominent in this condition.

D Basal cell carcinoma

This is commoner in lighter skin types. It does usually progress very slowly if untreated. The lesion in the image lacks specific features of this diagnosis (pearly, rolled edge; telangiectasia).

E Squamous cell carcinoma

The history is too long for this, as SCC would likely have become more nodular or ulcerated by this time, as well as probably metastasising to local lymph nodes. The tissue distortion would not be compatible with SCC-in situ (Bowen's disease).

Rate this question:

Next Question

Rana Alnasser's screen

An 18-year-old man presents with a 7-day history of rash, affecting his whole body. He had a cold sore, a sore throat and fever 10 days ago and was given erythromycin by the GP. The rash is not particularly itchy and there are no mucosal lesions.

Routine bloods reveal a small increase in ESR and a white blood count just above the upper limit of the normal range.

The rash is seen below:

Which of the following is the most likely diagnosis?

A	Scabies
B	Secondary syphilis
C	Varicella zoster virus
D	Erythema multiforme
E	Hand, foot and mouth disease

D Erythema multiforme

Erythema multiforme is an acute, self-limiting illness triggered by infections including HSV and CMV. Less than 10% of cases are triggered by drugs. It causes erythematous macules, papules and target lesions on the palms and soles.

Clinical criteria for diagnosis:
1) Acute, self-limiting illness with duration <4weeks
2) Symmetrical, discrete, round, red papules that persist at the same site for at least 7 days
3) Some papules evolve into target lesions
4) No mucosal involvement (or mucosal involvement is limited to one mucosal surface, usually oral).

A Scabies

Scabies is associated with an intensely itchy, crusting skin rash, particularly in the web spaces on the hands.

B Secondary syphilis

Although the rash of secondary syphilis can mimic almost any rash, it's much more likely with modern sexual health counselling that an 18-year-old would have presented to health services at the time of the primary lesion.

C Varicella zoster virus

VZV is a vesicular rash (vesicles on an erythematous base), classically described as 'dew drops on a rose petal'. It's most likely that primary chicken pox infection would also have occurred at an earlier stage in life than age 18.

E Hand, foot and mouth disease

B Secondary syphilis

Although the rash of secondary syphilis can mimic almost any rash, it's much more likely with modern sexual health counselling that an 18-year-old would have presented to health services at the time of the primary lesion.

C Varicella zoster virus

VZV is a vesicular rash (vesicles on an erythematous base), classically described as 'dew drops on a rose petal'. It's most likely that primary chicken pox infection would also have occurred at an earlier stage in life than age 18.

E Hand, foot and mouth disease

Hand, foot and mouth disease is associated with infection by coxsackie viruses A10 and A16 and with enterovirus 71, and produces vesicles and pustules on the hands and feet and mucosal ulcers. Enterovirus is also rarely associated with a polio-like syndrome.

Rate this question:

Next Question

Previous Q... Tag Questi... Feedback End Session

Blog About Pastest Contact Us Help

© Pastest 2019

A 37-year-old woman presented with hair loss, distributed on the front and crown of her scalp but sparing the sides.

She denied using braids, straighteners, tongs or wearing a ponytail.

She had no other significant medical problems.

How would you best describe this type of alopecia?

A	Cicatricial alopecia
B	Androgenetic alopecia
C	Telogen effluvium
D	Traction alopecia
E	Alopecia areata

9:30

A 37-year-old woman presented with hair loss, distributed on the front and crown of her scalp but sparing the sides.

She denied using braids, straighteners, tongs or wearing a ponytail.

She had no other significant medical problems.

How would you best describe this type of alopecia?

Your answer was correct

A Cicatricial alopecia

B Androgenetic alopecia

C Telogen effluvium

D Traction alopecia

E Alopecia areata

Explanation

Rana Alnasser's screen

9:30

E Alopecia areata

Explanation

B Androgenetic alopecia

Hair loss in this pattern in females may be associated with increased androgens, for example in a patient with polycystic ovarian syndrome, (PCOS). It results in gradual, diffuse thinning over the crown and frontal scalp. A rim of hair is preserved along the frontal margin (in males, this may not be maintained), back and sides of the scalp. (Occipital follicles are not dependent on androgens and are a source for hair transplant.)

A Cicatricial alopecia

In cicatricial (scarring) alopecia, one would expect to see erythema, scaling, pustules and hyperkeratosis as well as fibrosis.

C Telogen effluvium

Telogen effluvium occurs because of sudden entry of hair follicles into the resting phase, resulting in increased hair loss. It is usually associated with acute illness.

D Traction alopecia

Traction alopecia occurs when hair is styled by tightly pulling it back, for example into a pony tail.

E Alopecia areata

Alopecia areata is autoimmune in origin and results in localised non-scarring alopecia.

Rana Alnasser's screen

9:30

B Androgenetic alopecia

Hair loss in this pattern in females may be associated with increased androgens, for example in a patient with polycystic ovarian syndrome, (PCOS). It results in gradual, diffuse thinning over the crown and frontal scalp. A rim of hair is preserved along the frontal margin (in males, this may not be maintained), back and sides of the scalp. (Occipital follicles are not dependent on androgens and are a source for hair transplant.)

A Cicatricial alopecia

In cicatricial (scarring) alopecia, one would expect to see erythema, scaling, pustules and hyperkeratosis as well as fibrosis.

C Telogen effluvium

Telogen effluvium occurs because of sudden entry of hair follicles into the resting phase, resulting in increased hair loss. It is usually associated with acute illness.

D Traction alopecia

Traction alopecia occurs when hair is styled by tightly pulling it back, for example into a pony tail.

E Alopecia areata

Alopecia areata is autoimmune in origin and results in localised non-scarring alopecia.

39072

Rate this question:

Rana Alnasser's screen

A 24-year-old woman comes to the Dermatology Clinic for review. She has an intensely itchy rash with vesicles and blisters, which she says waxes and wanes from week to week. She has suffered from irritable bowel syndrome symptoms in the past and anti-TTG antibodies are positive.

Despite following a gluten-free diet and being prescribed dapsone, she is still suffering from the rash.

Which of the following is the most appropriate next step?

A Oral azathioprine

B Oral methotrexate

C Oral prednisolone

D Topical high-potency steroids

E Oral sulfapyridine

Submit

Previous Q... Skip Questi...

© Pastest 2019

9:32

A 24-year-old woman comes to the Dermatology Clinic for review. She has an intensely itchy rash with vesicles and blisters, which she says waxes and wanes from week to week. She has suffered from irritable bowel syndrome symptoms in the past and anti-TTG antibodies are positive.

Despite following a gluten-free diet and being prescribed dapsone, she is still suffering from the rash.

Which of the following is the most appropriate next step?

Your answer was correct

A	Oral azathioprine
B	Oral methotrexate
C	Oral prednisolone
D	Topical high-potency steroids
E	Oral sulfapyridine

Explanation

E Oral sulfapyridine

Although following a gluten-free diet ±dapsone does improve the rash of dermatitis herpetiformis significantly in many patients, some still suffer resistant symptoms. In those adult patients, sulfapyridine may be given at a starting dose of 0.5 g three times per day, which may be increased to up to 6 g per day if necessary to control patient symptoms. Risks of therapy include agranulocytosis

Rana Alnasser's screen

9:32

Explanation

E Oral sulfapyridine

Although following a gluten-free diet ±dapsone does improve the rash of dermatitis herpetiformis significantly in many patients, some still suffer resistant symptoms. In those adult patients, sulfapyridine may be given at a starting dose of 0.5 g three times per day, which may be increased to up to 6 g per day if necessary to control patient symptoms. Risks of therapy include agranulocytosis and hypersensitivity.

A Oral azathioprine

Although some patients gain a response to azathioprine, it is less effective vs dapsone and sulfa-based compounds.

B Oral methotrexate

Methotrexate isn't used for the treatment of dermatitis herpetiformis; in rare cases it is recognised to cause a coeliac disease-like syndrome with a dermatitis herpetiformis-type rash.

C Oral prednisolone

Oral steroids should be avoided in the treatment of dermatitis herpetiformis if possible because of the benefit risk profile associated with systemic therapy.

D Topical high-potency steroids

Topical high-potency steroids are an alternative to sulfapyridine, but given the often extensive nature of the rash, cumulative systemic absorption of steroids may be quite high.

Rana Alnasser's screen

Although some patients gain a response to azathioprine, it is less effective vs dapsone and sulfa-based compounds.

B Oral methotrexate

Methotrexate isn't used for the treatment of dermatitis herpetiformis; in rare cases it is recognised to cause a coeliac disease-like syndrome with a dermatitis herpetiformis-type rash.

C Oral prednisolone

Oral steroids should be avoided in the treatment of dermatitis herpetiformis if possible because of the benefit risk profile associated with systemic therapy.

D Topical high-potency steroids

Topical high-potency steroids are an alternative to sulfapyridine, but given the often extensive nature of the rash, cumulative systemic absorption of steroids may be quite high.

Rate this question:

Next Question

Previous Q... Tag Questi... Feedback End Session

Blog About Pastest Contact Us Help

© Pastest 2019

9:32

An elderly woman is admitted to hospital, following a fall, and is noted by the nursing staff to have a brown-coloured, reticular, pigmented rash to both shins.

On examination, pedal pulses are present, sweat visible, thin hair and a tremor is visible.

Which of the following features would you expect to find?

A	Exopthalmos
B	Erythematous malar rash
C	Striae
D	Slow relaxing reflexes
E	Mild hypothermia

Submit

Previous Q... Skip Questi...

© Pastest 2019

B	Erythematous malar rash
C	Striae
D	Slow relaxing reflexes
E	Mild hypothermia

Explanation

A	Exopthalmos

This woman's rash is pretibial myxoedema; therefore, exophthalmos is the correct answer, given the patient has thin hair and tremor, which is suggestive of the diagnosis of hyperthyroidism.

B	Erythematous malar rash

Also known as butterfly rash, this is a facial rash that is typically seen in systemic lupus erythematosus (SLE).

C	Striae

Striae start by looking red in colour (striae rubra) and progress over time to look white (striae alba). Causes are multiple and include rapid growth spurts, pregnancy, Cushing syndrome and treatment with corticosteroids.

D	Slow relaxing reflexes

Slow relaxing reflexes are seen in hypothyroidism; however, this patient's rash along with a tremor and visible sweat points towards hyperthyroidism.

Explanation

A Exopthalmos

This woman's rash is pretibial myxoedema; therefore, exophthalmos is the correct answer, given the patient has thin hair and tremor, which is suggestive of the diagnosis of hyperthyroidism.

B Erythematous malar rash

Also known as butterfly rash, this is a facial rash that is typically seen in systemic lupus erythematosus (SLE).

C Striae

Striae start by looking red in colour (striae rubra) and progress over time to look white (striae alba). Causes are multiple and include rapid growth spurts, pregnancy, Cushing syndrome and treatment with corticosteroids.

D Slow relaxing reflexes

Slow relaxing reflexes are seen in hypothyroidism; however, this patient's rash along with a tremor and visible sweat points towards hyperthyroidism.

E Mild hypothermia

This would be more likely associated with hypothyroidism, especially in the elderly population.

Rate this question:

Next Question

A 56-year-old woman develops flaccid blistering over her face, axillae and groins, which rupture to leave painful erosions. She also complains of a painful mouth.

Biopsy with immunofluorescence shows immunoglobulin deposition throughout the epidermis.

Given the likely diagnosis, what is the most appropriate treatment?

A	Prednisolone 0.5-1.5 mg/kg od
B	Prednisolone 10 mg od
C	Topical steroids
D	Methotrexate 15 mg weekly
E	Amoxicillin 500 mg tds

Explanation

A	Prednisolone 0.5-1.5 mg/kg od

This woman has classic features of pemphigus vulgaris. The blisters are flaccid and commonly affect mucosal membranes. In contrast, bullous pemphigoid presents with tense blisters and immunofluorescence along the basement membrane. Patients require high-dose oral steroids to induce remission; however, the optimal steroid dosing has not been fully validated yet. Patients often also require long-term lower dose steroids for maintenance, usually for around two years. The severity and history of the condition are variable. Prior to the use of steroids the condition used to have a high mortality, which has now been reduced to 5–15%.

B	Prednisolone 10 mg od

Higher doses of oral steroids are required in order to induce remission; however, lower doses may be used in long-term in order to maintain remission.

C	Topical steroids

Oral, and not topical, steroids are the recommended treatment against pemphigus vulgaris.

D	Methotrexate 15 mg weekly

Methotrexate is an immune suppressant commonly used to treat several dermatological conditions including psoriasis and eczema. However, it is not commonly used in the treatment of pemphigus vulgaris due to a series of publications that linked it to high rates of morbidity and mortality.

long-term lower dose steroids for maintenance, usually for around two years. The severity and history of the condition are variable. Prior to the use of steroids the condition used to have a high mortality, which has now been reduced to 5-15%.

B Prednisolone 10 mg od

Higher doses of oral steroids are required in order to induce remission; however, lower doses may be used in long-term in order to maintain remission.

C Topical steroids

Oral, and not topical, steroids are the recommended treatment against pemphigus vulgaris.

D Methotrexate 15 mg weekly

Methotrexate is an immune suppressant commonly used to treat several dermatological conditions including psoriasis and eczema. However, it is not commonly used in the treatment of pemphigus vulgaris due to a series of publications that linked it to high rates of morbidity and mortality.

E Amoxicillin 500 mg tds

Amoxicillin is an antibiotic and not indicated in the treatment of pemphigus vulgaris. In the case of acquiring a superimposed skin infection, alternative antibiotics such as flucloxacillin are commonly used.

Rate this question:

Next Question

A 68-year-old man is under the care of the haematologists. He is undergoing chemotherapy for non-Hodgkin's lymphoma. He has been extensively investigated for left-sided chest pain and a recent angiogram demonstrated normal coronaries.

On the ward, the nursing staff noticed this rash on his back the previous day.

Which of the following medications should be prescribed?

A	Flucloxacillin 500 mg QDS
B	Aciclovir 800 mg five times daily
C	Topical acyclovir QDS
D	Morphine sulphate tablets 30 mg BD
E	Prednisolone 30 mg OD

This gentleman has herpes zoster infection affecting a thoracic dermatome. Herpes zoster occurs in people who have previously had chickenpox. The herpes varicella zoster virus lies dormant in the dorsal root ganglion following chickenpox, and later travels down the cutaneous nerves to infect the epidermal cells. The prodromal period is followed by a rash consisting of a group of vesicles on an erythematous background, followed by weeping and crusting; healing takes 3–4 weeks. The rash is nearly always unilateral and confined to one or two dermatomes. Oral antiviral agents such as aciclovir at a high dose are only beneficial if given in the first 48 h of the development of blisters. Regular analgesics are important, but in the elderly – particularly if given as soon as the rash appears – prophylactic amitriptyline at night starting at 25 mg and increasing to 75 mg can help prevent post-herpetic neuralgia.

A Flucloxacillin 500 mg QDS

This patient's rash is viral in origin, and flucloxacillin therefore has no value in its management.

C Topical acyclovir QDS

Topical acyclovir is ineffective in the treatment of herpes zoster, and thus it isn't an optimal intervention here.

D Morphine sulphate tablets 30 mg BD

Pain relief alone is not appropriate, given that this man is undergoing treatment for Hodgkin's lymphoma and is likely to be immunosuppressed.

E Prednisolone 30 mg OD

Corticosteroids in this situation may drive persistent or

have previously had chickenpox. The herpes varicella zoster virus lies dormant in the dorsal root ganglion following chickenpox, and later travels down the cutaneous nerves to infect the epidermal cells. The prodromal period is followed by a rash consisting of a group of vesicles on an erythematous background, followed by weeping and crusting; healing takes 3–4 weeks. The rash is nearly always unilateral and confined to one or two dermatomes. Oral antiviral agents such as aciclovir at a high dose are only beneficial if given in the first 48 h of the development of blisters. Regular analgesics are important, but in the elderly – particularly if given as soon as the rash appears – prophylactic amitriptyline at night starting at 25 mg and increasing to 75 mg can help prevent post-herpetic neuralgia.

A Flucloxacillin 500 mg QDS

This patient's rash is viral in origin, and flucloxacillin therefore has no value in its management.

C Topical acyclovir QDS

Topical acyclovir is ineffective in the treatment of herpes zoster, and thus it isn't an optimal intervention here.

D Morphine sulphate tablets 30 mg BD

Pain relief alone is not appropriate, given that this man is undergoing treatment for Hodgkin's lymphoma and is likely to be immunosuppressed.

E Prednisolone 30 mg OD

Corticosteroids in this situation may drive persistent or more generalised zoster infection.

33390

Rate this question:

9:35
594-042-7551 Leave

A 45-year-old woman presented with sudden onset tender nodules on her legs (see photo) as well as fever and joint pains.

Auscultation of the chest appears unremarkable.

Which histocompatibility antigen is present in approximately 65% of patients with the skin rash seen here?

A	HLA DR2
B	HLA DR3
C	HLA DR4
D	HLA DQ2
E	HLA B27

Audio Video Share Participants 2 More

Explanation

E HLA B27

The clinical picture and findings are typical of erythema nodosum. There is an association with the HLA B27 histocompatibility antigen, which is present in 65% of patients with erythema nodosum.

A HLA DR2

HLA DR2 serotypes are associated with a number of conditions such as: autoimmune hepatitis, primary biliary cirrhosis, systemic lupus erythematosus, and Goodpasture syndrome.

B HLA DR3

HLA-DR3 is associated with the development of multiple conditions such as: myasthenia gravis, Hashimoto's thyroiditis, primary sclerosing cholangitis, and membranous glomerulonephritis.

C HLA DR4

HLA-DR4 is associated with a number of conditions, including: rheumatoid arthritis, systemic lupus erythematosus, pemphigoid gestationis, pemphigus foliaceus, IgA nephropathy, and polymyalgia rheumatica.

D HLA DQ2

HLA DQ2 serotype has been linked to the development of coeliac disease.

Rate this question:

9:37
594-042-7551 Leave

An 18-year-old woman presents with circular lesions on her hands. They have a raised, palpable border. She also has similar lesions on her feet:

Which one of the following investigations is most important?

A	Thyroid function tests
B	Anti-endomysial antibodies
C	Prolactin levels
D	Glycated haemoglobin levels (HbA1c)
E	Urine levels of 2-pyridone and 2-methyl nicotinamide

71330

Submit

Audio Video Share Participants 2 More

D Glycated haemoglobin levels (HbA1c)

Diabetes mellitus is commonly thought to be associated with the development of granuloma annulare. Other skin disorders associated with diabetes include necrobiosis lipoidica, and insulin injection-related lipodystrophy.

E Urine levels of 2-pyridone and 2-methyl nicotinamide

Urine metabolite tests can be used to aid the diagnosis of pellagra, however the condition is not commonly associated with developing granuloma annulare. Skin signs that point towards a diagnosis of pellagra include: symmetrical, itchy areas of dermatitis in sun exposed sites, mucosal exfoliation and areas of thickened, darkened skin.

A Thyroid function tests

Granuloma annulare presents as ring-like lesions with raised edges that enlarge centrifugally. Lesions may be solitary or multiple and usually present on the dorsal aspect of the hands and feet. They are usually asymptomatic and are more common in females under the age of 30 years. Hypothyroidism is not typically associated with developing granuloma annulare. Cutaneous signs commonly associated with hypothyroidism include: loss of hair in the outer third of eyebrows, brittle nails, and myxoedema.

B Anti-endomysial antibodies

Detection of anti-endomysial antibodies is used in the diagnosis of coeliac disease which is not commonly associated with developing granuloma annulare. Dermatitis herpetiformis (an intensely itchy vesicular rash) on the other hand, is a well recognised cutaneous eruption encountered in patients with coeliac disease.

9:38

A 67-year-old woman undergoes a right total hip operation under the Orthopaedic Surgeons. They contact you when she is seen in the Follow-up Clinic with a necrotic, violaceous ulcer over the operation scar. Wound swabs and blood cultures showed no growth.

Over the last week, the ulcer has grown in size despite the patient taking flucloxacillin 250 mg four times daily (qds). The patient is now also taking potent analgesics to manage the pain.

In her past medical history, she has suffered from hypertension and rheumatoid arthritis. She is a non-smoker and drinks almost no alcohol. She has no allergies.

The dermatologist is contacted, and a skin biopsy is taken.

What is the next step in her management?

A	Revision of operation
B	Flucloxacillin 500 mg qds orally (po)
C	Benzylpenicillin 1.2 g qds and flucloxacillin 1 g qds intravenously (IV)
D	Prednisolone 60 mg once daily (od)
E	Conservative measures only

Submit

9:40

A 67-year-old woman undergoes a right total hip operation under the Orthopaedic Surgeons. They contact you when she is seen in the Follow-up Clinic with a necrotic, violaceous ulcer over the operation scar. Wound swabs and blood cultures showed no growth.

Over the last week, the ulcer has grown in size despite the patient taking flucloxacillin 250 mg four times daily (qds). The patient is now also taking potent analgesics to manage the pain.

In her past medical history, she has suffered from hypertension and rheumatoid arthritis. She is a non-smoker and drinks almost no alcohol. She has no allergies.

The dermatologist is contacted, and a skin biopsy is taken.

What is the next step in her management?

Your answer was correct

A	Revision of operation
B	Flucloxacillin 500 mg qds orally (po)
C	Benzylpenicillin 1.2 g qds and flucloxacillin 1 g qds intravenously (IV)
D	Prednisolone 60 mg once daily (od)
E	Conservative measures only

Explanation

D Prednisolone 60 mg once daily (od)

Rana Alnasser's screen

D Prednisolone 60 mg once daily (od)

High-dose steroids are usually enough to lead to resolution. If that treatment fails, alternative pharmacological interventions, such as ciclosporin or tumour necrosis factor alpha inhibitors, may be required.

A Revision of operation

This patient has developed pyoderma gangrenosum (PG) over the site of surgery – demonstrating pathergy. PG is a neutrophilic condition causing painful skin ulceration with characteristic violaceous, undermined borders. Its association with conditions such as rheumatoid arthritis and haematological malignancies is well documented. The diagnosis should always be considered in non-healing sterile ulcers, particularly when other risk factors are present. Operating further on the affected area is likely to increase the size of the ulcer and is best avoided.

B Flucloxacillin 500 mg qds orally (po)

Antibiotics are often prescribed before making the correct diagnosis. These may be continued if bacteria are cultured in the wound or there is surrounding cellulitis, but they are not helpful for uncomplicated PG.

C Benzylpenicillin 1.2 g qds and flucloxacillin 1 g qds intravenously (IV)

Given the negative swab results and the typical PG presentation, escalating the course of antibiotics is unlikely to be of any benefit.

E Conservative measures only

PG is an auto-inflammatory, neutrophilic condition of

A 36-year-old male was referred by the GP with this lesion on his anterior shoulder. He has a new partner who finds it unsightly and he wants it treated.

What is the abnormal area of pigmentation over his shoulder?

A	Benign epidermal naevus
B	Naevus flameus
C	Mongolian blue spot
D	Café au lait spot
E	Haemangioma

39096

Submit

A 36-year-old male was referred by the GP with this lesion on his anterior shoulder. He has a new partner who finds it unsightly and he wants it treated.

What is the abnormal area of pigmentation over his shoulder?

Your answer was incorrect

A Benign epidermal naevus

B Naevus flameus

C Mongolian blue spot

D Café au lait spot

E Haemangioma

Explanation

A Benign epidermal naevus

C Mongolian blue spot

D Café au lait spot

E Haemangioma

Explanation

A Benign epidermal naevus

Benign epidermal naevi, (formerly known as Becker's naevi), have a characteristic appearance with linear pigmentation, often located around the shoulder. They carry a brown pigment due to melanocytes and may also be hairy.

B Naevus flameus

This is a vascular naevus or port wine stain. When these occur on the head, patients are usually investigated for the presence of leptomeningeal angiomas.

C Mongolian blue spot

Mongolian blue spots are located over the sacrum, are blue in colour and identified at birth.

D Café au lait spot

These are flattened macular pigmented areas identified at birth and associated with neurofibromatosis Type 1.

E Haemangioma

9:43

carry a brown pigment due to melanocytes and may also be hairy.

B Naevus flameus

This is a vascular naevus or port wine stain. When these occur on the head, patients are usually investigated for the presence of leptomeningeal angiomas.

C Mongolian blue spot

Mongolian blue spots are located over the sacrum, are blue in colour and identified at birth.

D Café au lait spot

These are flattened macular pigmented areas identified at birth and associated with neurofibromatosis Type 1.

E Haemangioma

Haemangiomas are benign vascular tumours identified in childhood, they are known as strawberry naevi because of their colour.

Rate this question:

Next Question

Rana Alnasser's screen

9:43

A 56-year-old woman presents with painful and itchy swellings on her knuckles. These are worse after exposure to sunlight and have been problematic for her for several weeks. She has a past medical history of type 2 diabetes, two pregnancies, one miscarriage and hypertension. She currently takes metformin and ramipril.

Apart from the changes on her knuckles, she has not noticed any other changes. She denies any other rashes, joint stiffness or breathing problems.

A photograph of her right hand is shown below.

What is the most likely diagnosis?

A	Psoriasis
B	Dermatomyositis
C	Atopic dermatitis
D	Lichen planus
E	Dermatitis herpetiformis

Rana Alnasser's screen

A Psoriasis

B Dermatomyositis

C Atopic dermatitis

D Lichen planus

E Dermatitis herpetiformis

Explanation

B Dermatomyositis

The photograph shows Gottron's papules on the patient's right hand. This is a clinical sign pathognomonic for dermatomyositis. Dermatomyositis is a chronic, autoimmune condition which affects proximal muscles and skin primarily, but can also cause cardiac, pulmonary and rheumatological complications. Peak onset is at 50 years old with a slow but steady progression, causing diffuse weakness in proximal muscles, fatigue and myalgia. Distal muscles are spared. There can be systemic upset with fever, malaise and weight loss. A heliotrope rash is pathognomonic, and there can be also a photosensitive rash. Investigation is with autoantibodies: ANA, anti-Mi and anti-Jo antibodies can help establish diagnosis, but muscle biopsy may be necessary as a diagnostic investigation. Steroid treatment may be successful, but immunosuppressive therapy can be used as secondary treatment.

A Psoriasis

Psoriasis is chronic inflammatory dermatological condition

biopsy may be necessary as a diagnostic investigation. Steroid treatment may be successful, but immunosuppressive therapy can be used as secondary treatment.

A Psoriasis

Psoriasis is chronic inflammatory dermatological condition defined by salmon-red rash with silvery plaques. It has several types. The most common pattern of presentation affects extensor areas over limbs with involvement of scalp, umbilicus, natal cleft and groin. The pattern of this patient's rash is different in distribution and the appearance is not consistent with psoriasis.

C Atopic dermatitis

Atopic dermatitis is a chronic skin condition characterised by itchy, dry and red skin, which comes out in flares of acutely inflamed, red and sometimes blistered skin. It affects particularly the flexural surfaces. It does not cause plaques as this patient has, except in very chronic cases. The association with sun exposure also makes this less likely.

D Lichen planus

Lichen planus is a pruritic skin condition with polygon-shaped purple plaques on the lower back, wrists and ankles, as well as evidence of Wickham striae, white lines near sites of erosion. The location of this patient's lesions does not match this diagnosis. Also, lichen planus is not worsened by sunlight. The mainstay of treatment for lichen planus is topical steroid treatment but can also include retinoids and UV light therapy.

E Dermatitis herpetiformis

9:43

A 25-year-old lady, currently breast-feeding, is prescribed prednisolone for a particularly severe flare of her eczema.

Which of the following is the correct advice with respect to her breast feeding?

A	Prednisolone is not excreted in breast milk so there is no concern
B	The infant should always be monitored for signs of adrenal suppression
C	Doses of less than 40 mg prednisolone per day are likely to be safe
D	She must not breast-feed
E	Prednisolone must be restricted to doses of less than 20 mg per day

Submit

© Pastest 2019

9:44

C Doses of less than 40 mg prednisolone per day are likely to be safe

The BNF states that doses of up to 40 mg daily are unlikely to cause systemic effects in the infants of breast-feeding mothers, but infants of mothers taking daily doses higher than 40 mg should be monitored for signs of steroid withdrawal.

A Prednisolone is not excreted in breast milk so there is no concern

Doses above 40 mg per day may be secreted in significant quantities in breast milk, and caution therefore with respect to high dose corticosteroids is advised.

B The infant should always be monitored for signs of adrenal suppression

Infants should be monitored for signs of steroid withdrawal in the event that doses above 40 mg per day are used.

D She must not breast-feed

Breast feeding is only of significant concern when doses of prednisolone greater than 40 mg per day, hence breast feeding may well be safe for the majority of patients taking prednisolone.

E Prednisolone must be restricted to doses of less than 20 mg per day

Doses of up to 40 mg per day are unlikely to cause a significant problem with respect to breast-feeding.

Rate this question:

Rana Alnasser's screen

9:45
594-042-7551 Leave

A 25-year-old man presented with a 3-year history of red, itchy nodules on his left shoulder. He had a previous history of acne vulgaris. He is concerned about the appearance of the lesions.

What is the next management step?

A	Biopsy one of the lesions
B	Oral antihistamine
C	Intra-lesional triamcinolone
D	Topical steroid creams
E	Reassurance they will resolve over time

Submit
Audio Video Share Participants More

C Intra-lesional triamcinolone

The lesions in the photograph are keloid scars, secondary to acne. From the options given, only intra-lesional corticosteroids are likely to drive resolution of the lesions, although there are risks of local bleeding, infection and skin atrophy.

E Reassurance they will resolve over time

There is evidence of permanent scarring from the previous acne, which won't resolve over time.

A Biopsy one of the lesions

A biopsy is not necessary to confirm the diagnosis, and may worsen any scarring.

B Oral antihistamine

Although oral antihistamines may reduce itching local irritation, they won't impact on the cosmetic appearance of the lesions.

D Topical steroid creams

Topical steroid creams only poorly penetrate overlying scarring from the acne.

9:47

This 52-year-old man has been struggling with psoriasis for most of his life.

He is keen to trial alternative topical agents, and you decide that he requires a strong keratolytic agent to combat the scale.

Which topical treatment would be the best choice for him?

A	Calcipotriol
B	Topical tacrolimus
C	Topical capsaicin
D	Topical salicylic acid
E	Topical menthol

39093

Submit

Rana Alnasser's screen

9:49

D Topical salicylic acid

E Topical menthol

Explanation

D Topical salicylic acid

The answer is Topical salicylic acid (Option D).

Salicylic acid is a keratolytic agent, meaning it decreases cell-to-cell cohesion in the stratum corneum, thereby reducing hyperkeratosis and increasing absorption of other topical preparations.

A Calcipotriol

Calcipotriol (Option A) is incorrect.

Calcipotriol is a synthetic vitamin D analogue. It is commonly used in the treatment of psoriasis, particularly in combination with potent topical corticosteroids.

B Topical tacrolimus

Topical tacrolimus (Option B) is incorrect.

Tacrolimus is a calcineurin antagonist. Topically, it is commonly used in the treatment of eczema, in a similar way to topical steroids, but with the advantage of not causing steroid-related side-effects like skin atrophy.

C Topical capsaicin

Topical capsaicin (Option C) is incorrect.

Topical capsaicin is used to treat neuropathic and muscular pains

Rana Alnasser's screen

9:49

cell-to-cell cohesion in the stratum corneum, thereby reducing hyperkeratosis and increasing absorption of other topical preparations.

A Calcipotriol

Calcipotriol (Option A) is incorrect.

Calcipotriol is a synthetic vitamin D analogue. It is commonly used in the treatment of psoriasis, particularly in combination with potent topical corticosteroids.

B Topical tacrolimus

Topical tacrolimus (Option B) is incorrect.

Tacrolimus is a calcineurin antagonist. Topically, it is commonly used in the treatment of eczema, in a similar way to topical steroids, but with the advantage of not causing steroid-related side-effects like skin atrophy.

C Topical capsaicin

Topical capsaicin (Option C) is incorrect.

Topical capsaicin is used to treat neuropathic and muscular pains.

E Topical menthol

Topical menthol (Option E) is incorrect.

Topical menthol is used to provide a sensation of 'cooling' to the skin and reduce itching.

39093

Rate this question:

Next Question

Rana Alnasser's screen

9:49
594-042-7551 Leave

A 58-year-old self-employed man presents with a 4-month history of progressive dyspnoea and fatigue. He complains of a painful rash on the backs of his hands. He also reports redness on the face and the central upper chest. The rash worsens after sun exposure. He has not noticed any blisters.

On further questioning, he has noticed a significant weight loss with reduced appetite. He takes regular analgesics for migraines. He is allergic to penicillin. He is a non-smoker and drinks alcohol socially.

Investigations:

Hb	10.0 g/dl
WCC	8.0×10^9/l
PLT	490×10^9/l
CRP	40 mg/l
ESR	30 mm/h
Liver enzymes	Normal
CK	360 IU/l (17–148)
ANA	+

Audio Video Share Participants More

PLT	490 × 10^9/l
CRP	40 mg/l
ESR	30 mm/h
Liver enzymes	Normal
CK	360 IU/l (17–148)
ANA	+
Chest examination	Unremarkable
Abdomen examination	Unremarkable

CNS examination:

Cranial nerves	Intact
Tone	Normal throughout
Reflexes	Intact
Power	5/5 except hip flexors 4/5
Other	Downgoing plantars bilaterally; no sensation deficits

What is the most likely diagnosis?

A	Systemic lupus erythematosus (SLE)
B	Porphyria cutanea tarda
C	Polymyalgia rheumatica
D	Guillain-Barré syndrome
E	Dermatomyositis

- Violaceous 'Gottron's papules' over the knuckles.
- Linear violaceous changes over the dorsal surfaces of the fingers.
- Nail-fold inflammation with dilated capillaries.
- The 'shawl sign' describes erythema over the upper back and posterior neck.
- Weakness of the major proximal muscle groups, although some patients will have skin involvement alone ('amyopathic dermatomyositis').
- Rarely, involuntary muscles may be involved, leading to potentially dangerous or even fatal difficulties in swallowing or breathing.

- Calcification can occur in juvenile dermatomyositis, but is uncommon in adults.
- Investigations should include creatine kinase, antinuclear antibody and skin biopsy; electromyography and/or muscle biopsy can confirm myositis.
- Screening for underlying neoplasia (such as CT chest, abdomen and pelvis) is generally advised in adult cases.

A Systemic lupus erythematosus (SLE)

Although ANA positivity and photosensitivity would fit with this, and SLE frequently involves the skin, the eruption in the photograph is very suggestive of dermatomyositis.

B Porphyria cutanea tarda

This is another photosensitive disorder, but it typically leads to blistering at sun-exposed sites. There is usually a history of chronic liver disease. ANA positivity and raised

Although ANA positivity and photosensitivity would fit with this, and SLE frequently involves the skin, the eruption in the photograph is very suggestive of dermatomyositis.

B Porphyria cutanea tarda

This is another photosensitive disorder, but it typically leads to blistering at sun-exposed sites. There is usually a history of chronic liver disease. ANA positivity and raised inflammatory markers would not be expected.

C Polymyalgia rheumatica

This causes muscle pains and stiffness, but is not associated with rash.

D Guillain-Barré syndrome

This is a disorder of the peripheral nervous system which presents with weakness and paraesthesia, usually beginning in the legs. It usually follows an infection and is not associated with a rash.

© Pastest 2019

9:51
NC
MyPastest
https://mypastest.pastest.com

A 47-year-old man is referred with a 1-year history of a lesion developing on the right upper lip, which has steadily enlarged. There is no history of itching or bleeding. He was noted to be a keen user of sun beds.

Examination revealed a firm, nodular lesion below the right nasolabial fold.

What is the most likely diagnosis?

A	Nodular melanoma
B	Basal cell carcinoma (BCC)
C	Squamous cell carcinoma (SCC)
D	Atypical fibroxanthoma (AFX)
E	Pyogenic granuloma

Submit

Previous Q... Skip Questi...

Rana Alnasser's screen

9:52
MyPastest
https://mypastest.pastest.com
594-042-7551
Leave

A 47-year-old man is referred with a 1-year history of a lesion developing on the right upper lip, which has steadily enlarged. There is no history of itching or bleeding. He was noted to be a keen user of sun beds.

Examination revealed a firm, nodular lesion below the right nasolabial fold.

What is the most likely diagnosis?

Your answer was correct

A	Nodular melanoma
B	Basal cell carcinoma (BCC)
C	Squamous cell carcinoma (SCC)
D	Atypical fibroxanthoma (AFX)
E	Pyogenic granuloma

Explanation

B Basal cell carcinoma (BCC)

The most likely diagnosis is that of a BCC. This is the most common non-melanoma skin malignancy. BCCs (or rodent ulcers) most commonly occur in middle-aged or elderly fair-skinned individuals with significant sun exposure. Most occur on the face but can also occur on the limbs and trunk. BCCs usually start as small, translucent papules with

Audio Video Share Participants More

D Atypical fibroxanthoma (AFX)

E Pyogenic granuloma

Explanation

B Basal cell carcinoma (BCC)

The most likely diagnosis is that of a BCC. This is the most common non-melanoma skin malignancy. BCCs (or rodent ulcers) most commonly occur in middle-aged or elderly fair-skinned individuals with significant sun exposure. Most occur on the face but can also occur on the limbs and trunk. BCCs usually start as a small, translucent papule with telangiectasia over the surface. They gradually increase in size, developing into firm, tethered nodules, with a centre that may ulcerate and crust. The most common treatment is with surgical excision or radiotherapy.

A Nodular melanoma

A malignant melanoma is a tumour of the melanocytes. Two-thirds arise from normal skin, and one-third from pre-existing moles. Even though commonly encountered, melanomas are more rare than non-melanoma skin cancers. It is important to diagnose and treat melanomas while they are thin, so that removal may result in favourable prognostic outcomes.

C Squamous cell carcinoma (SCC)

Cutaneous SCC is the second most common types of non-melanoma skin cancer. They present as enlarging scaly or crusted lumps which often arise within pre-existing actinic keratoses or areas of Bowen's disease.

D Atypical fibroxanthoma (AFX)

B Basal cell carcinoma (BCC)

The most likely diagnosis is that of a BCC. This is the most common non-melanoma skin malignancy. BCCs (or rodent ulcers) most commonly occur in middle-aged or elderly fair-skinned individuals with significant sun exposure. Most occur on the face but can also occur on the limbs and trunk. BCCs usually start as a small, translucent papule with telangiectasia over the surface. They gradually increase in size, developing into firm, tethered nodules, with a centre that may ulcerate and crust. The most common treatment is with surgical excision or radiotherapy.

A Nodular melanoma

A malignant melanoma is a tumour of the melanocytes. Two-thirds arise from normal skin, and one-third from pre-existing moles. Even though commonly encountered, melanomas are more rare than non-melanoma skin cancers. It is important to diagnose and treat melanomas while they are thin, so that removal may result in favourable prognostic outcomes.

C Squamous cell carcinoma (SCC)

Cutaneous SCC is the second most common types of non-melanoma skin cancer. They present as enlarging scaly or crusted lumps which often arise within pre-existing actinic keratoses or areas of Bowen's disease.

D Atypical fibroxanthoma (AFX)

An AFX is an uncommon type of skin cancer, accounting for < 0.2% of all skin cancers. It occurs mainly on the head or neck of older people with significant sun exposure. Typically, AFX is a red, juicy, dome-shaped nodule that may be bleeding, ulcerated or crusted.

existing moles. Even though commonly encountered, melanomas are more rare than non-melanoma skin cancers. It is important to diagnose and treat melanomas while they are thin, so that removal may result in favourable prognostic outcomes.

C Squamous cell carcinoma (SCC)

Cutaneous SCC is the second most common types of non-melanoma skin cancer. They present as enlarging scaly or crusted lumps which often arise within pre-existing actinic keratoses or areas of Bowen's disease.

D Atypical fibroxanthoma (AFX)

An AFX is an uncommon type of skin cancer, accounting for < 0.2% of all skin cancers. It occurs mainly on the head or neck of older people with significant sun exposure. Typically, AFX is a red, juicy, dome-shaped nodule that may be bleeding, ulcerated or crusted.

E Pyogenic granuloma

Pyogenic granuloma is a benign growth of blood vessels. It presents as a growing fleshy lump, which may bleed easily. It is often the product of physical trauma, infection or hormonal changes such as pregnancy.

A 24-year-old woman is brought to the Emergency Department with malaise, fatigue, and night sweats. She denies any past medical history but agrees to drinking excessively and having no fixed abode.

On examination, she has a temperature of 37.7 °C and tiny black streaks on her nails. The cutaneous lesion seen in the photograph below was also noted on examination:

What is the most likely cause for her symptoms?

A Cerebral vasculitis

B Infective endocarditis

C Toxic shock syndrome

D Heroin overdose

E Meningococcal sepsis

6354

Submit

A 24-year-old woman is brought to the Emergency Department with malaise, fatigue, and night sweats. She denies any past medical history but agrees to drinking excessively and having no fixed abode.

On examination, she has a temperature of 37.7 °C and tiny black streaks on her nails. The cutaneous lesion seen in the photograph below was also noted on examination:

What is the most likely cause for her symptoms?

Your answer was correct

A Cerebral vasculitis

B Infective endocarditis

C Toxic shock syndrome

D Heroin overdose

E Meningococcal sepsis

Explanation

B Infective endocarditis

C Toxic shock syndrome

Toxic shock syndrome is a potentially fatal illness caused by bacterial toxins. Patients are pyrexic with signs of haemodynamic compromise (tachypnoea, hypotension, and tachycardia).

D Heroin overdose

The skin lesions represent needle marks from intravenous (iv) injections (track marks) that indicate intravenous drug use. However, the patient doesn't have any more signs of opiate overdose such as miosis or drowsiness. Non-fatal overdose is common among heroin injectors and is strongly related to the misuse of multiple other substances such as methadone, benzodiazepines, and alcohol.

E Meningococcal sepsis

Meningococcal sepsis causes generic signs of infection (fever, malaise, haemodynamic instability) in addition to focal signs depending on the organ that has been affected (i.e. photosensitivity in meningitis or cough in pneumonia).

Rate this question:

Next Question

© Pastest 2019

9:54
NC
MyPastest
https://mypastest.pastest.com

What is the most likely cause for her symptoms?

Your answer was correct

A Cerebral vasculitis

B Infective endocarditis

C Toxic shock syndrome

D Heroin overdose

E Meningococcal sepsis

Explanation

B Infective endocarditis

Infective endocarditis is a well known association in patients who inject heroin as in this case. Common symptoms include: fever, malaise, heart murmurs, and septic emboli (splinter haemorrhages, Janeway lesions).

A Cerebral vasculitis

Cerebral vasculitis leads to a wide range of symptoms, such as headaches, skin rashes, tiredness, joint pains, weakness, and alterations in behaviour. In addition, in 10% it can lead to intracranial haemorrhage.

C Toxic shock syndrome

9:54
NC
594-042-7551
Leave

A 55-year-old man of Chinese ethnic origin presents with a discoloration on his back which has been present for 3 years. It is intensely itchy. He has no significant past medical history, apart from mild hypertension.

What is the most likely diagnosis?

A	Malignant melanoma
B	Lichen amyloidosis
C	Lichen sclerosis
D	Lichen simplex chronicus
E	Erythema ab igne

Submit

Audio
Video
Share
Participants
More

9:55
NC
MyPastest
https://mypastest.pastest.com

Pastest+

A 55-year-old man of Chinese ethnic origin presents with a discoloration on his back which has been present for 3 years. It is intensely itchy. He has no significant past medical history, apart from mild hypertension.

What is the most likely diagnosis?

A	Malignant melanoma
B	Lichen amyloidosis
C	Lichen sclerosis
D	Lichen simplex chronicus
E	Erythema ab igne

Submit

Rana Alnasser's screen

9:55
NC
594-042-7551
Leave

A 55-year-old man of Chinese ethnic origin presents with a discoloration on his back which has been present for 3 years. It is intensely itchy. He has no significant past medical history, apart from mild hypertension.

What is the most likely diagnosis?

Your answer was incorrect

A Malignant melanoma

B Lichen amyloidosis

C Lichen sclerosis

D Lichen simplex chronicus

E Erythema ab igne

Explanation

B Lichen amyloidosis

Lichen amyloidosis is a primary, localised cutaneous

Audio Video Share Participants More

9:56
NC
594-042-7551
Leave

Explanation

B Lichen amyloidosis

Lichen amyloidosis is a primary, localised cutaneous amyloidosis (amyloid deposition in the skin). It results in intensely itchy shiny or hyperkeratotic, pigmented macules and occurs most commonly in South East Asia. It appears that itching drives further amyloid deposition, and treatments are therefore directed at reducing the sensation of itching - for example, with the use of antihistamines and intra-lesional/topical corticosteroids.

E Erythema ab igne

Erythema ab igne would require a history of back pain/hot water bottle use and is a reticulate dermatosis.

A Malignant melanoma

Melanoma is a discrete lesion, rather than a diffuse pigmentation as seen here. A primary melanoma would also be less likely to occur on the lower back as it is less likely to be a sun-exposed area.

C Lichen sclerosis

Lichen sclerosis results in whitening, thinning and atrophy of the skin, rather than the thickening seen here.

D Lichen simplex chronicus

Lichen simplex chronicus (neurodermatitis) commonly occurs in areas where the patient is easily able to scratch (such as the shins) and thereby perpetuate the itch/scratch cycle.

Audio Video Share Participants More

9:57

A 34-year-old man with rapidly worsening psoriasis comes to the clinic for review. He has been given some topical steroid creams by his general practitioner (GP) but these have not improved his condition.

On examination, he has contiguous patches of psoriasis.

Which of the following would be the most appropriate next-stage therapy?

A	Adalimumab
B	Methotrexate
C	Isotretinoin
D	Topical retinoid cream
E	Hydroxychloroquine

Submit

Previous Q... Skip Questi...

© Pastest 2019

Rana Alnasser's screen

A 34-year-old man with rapidly worsening psoriasis comes to the clinic for review. He has been given some topical steroid creams by his general practitioner (GP) but these have not improved his condition.

On examination, he has contiguous patches of psoriasis.

Which of the following would be the most appropriate next-stage therapy?

Your answer was incorrect

A	Adalimumab
B	Methotrexate
C	Isotretinoin
D	Topical retinoid cream
E	Hydroxychloroquine

Explanation

B Methotrexate

The answer is Methotrexate (Option B).

The use of methotrexate is indicated in patients with psoriasis who require systemic interventions. Other commonly used systemic treatments include ciclosporin, acitretin and dimethyl fumarate.

C Isotretinoin

Explanation

B Methotrexate

The answer is Methotrexate (Option B).

The use of methotrexate is indicated in patients with psoriasis who require systemic interventions. Other commonly used systemic treatments include ciclosporin, acitretin and dimethyl fumarate.

C Isotretinoin

Isotretinoin (Option C) is incorrect.

This is a vitamin A analogue used in the management of acne vulgaris, but not psoriasis.

A Adalimumab

Adalimumab (Option A) is incorrect.

This is a monoclonal antibody against tumour necrosis factor (TNF) alpha that is effective against both psoriasis and psoriatic arthritis. Its use is limited to those with moderate to severe psoriasis who have failed (or are intolerant of or contraindicated to) first-line systemic agents such a methotrexate and ciclosporin.

D Topical retinoid cream

Topical retinoid cream (Option D) is incorrect.

Topical retinoids, such as tarazotene can be used in the management of psoriasis. Although the large area of affected skin means that topical therapies may be impractical.

E Hydroxychloroquine

10:00
NC
MyPastest
https://mypastest.pastest.com

This is a vitamin A analogue used in the management of acne vulgaris, but not psoriasis.

A Adalimumab

Adalimumab (Option A) is incorrect.

This is a monoclonal antibody against tumour necrosis factor (TNF) alpha that is effective against both psoriasis and psoriatic arthritis. Its use is limited to those with moderate to severe psoriasis who have failed (or are intolerant of or contraindicated to) first-line systemic agents such a methotrexate and ciclosporin.

D Topical retinoid cream

Topical retinoid cream (Option D) is incorrect.

Topical retinoids, such as tarazotene can be used in the management of psoriasis. Although the large area of affected skin means that topical therapies may be impractical.

E Hydroxychloroquine

Hydroxychloroquine (Option E) is incorrect.

Hydroxychloroquine is used against systemic lupus erythematosus (SLE), rheumatoid arthritis and a number of other photo-aggravated skin disorders.

Rate this question:

Next Question

10:00
NC

An 80-year-old homeless man presents with punctuate haemorrhage around the hair follicles, and coiling of the hair on his upper arms. He appears to be malnourished and lethargic, with a weight of 70 kg and a blood pressure of 110/70 mmHg.

His blood results are as follows:

Haemoglobin (Hb)	9.3 g/dl
White cell count (WCC)	9.2×10^9/l
Platelets	322×10^9/l
Na^+	138 mmol/l
K^+	3.6 mmol/l
Urea	3.4 μmol/l
Creatinine	133 μmol/l
Prothrombin time	15 s
Activated partial thromboplastin time	32 s
Bleeding time	3 min (3–10 min)

Which of the following is the most likely diagnosis?

A Ehlers–Danlos syndrome

B von Willebrand's disease

C Disseminated intravascular coagulation (DIC)

D Scurvy

E Thrombotic thrombocytopenic purpura

Rana Alnasser's screen

10:02

D Scurvy

E Thrombotic thrombocytopenic purpura

Explanation

D Scurvy

Humans are unable to synthesise ascorbic acid (vitamin C), and its deficiency leads to a condition known as scurvy. The initial typical skin changes are of follicular keratosis with coiling of the hair. Later, patients develop perifollicular haemorrhages, bleeding gums and purpura over the legs. Patients often have an associated anaemia and their plasma ascorbic acid levels will be low. There is rapid clinical improvement following vitamin C replacement.

A Ehlers-Danlos syndrome

Ehlers-Danlos syndrome refers to a group of inherited disorders in collagen and connective tissue synthesis and structure, resulting in hyperelastic skin, unstable and hypermobile joints, and fragile tissue and blood vessels.

B von Willebrand's disease

von Willebrand's disease is a hereditary clotting disorder associated with an increased bleeding tendency and easy bruising.

C Disseminated intravascular coagulation (DIC)

DIC is a coagulation disorder characterized by the widespread activation of the clotting cascade that results in the formation of clots in the small blood vessels throughout the body. Common causes include sepsis

Rana Alnasser's screen

10:02

Explanation

D Scurvy

Humans are unable to synthesise ascorbic acid (vitamin C), and its deficiency leads to a condition known as scurvy. The initial typical skin changes are of follicular keratosis with coiling of the hair. Later, patients develop perifollicular haemorrhages, bleeding gums and purpura over the legs. Patients often have an associated anaemia and their plasma ascorbic acid levels will be low. There is rapid clinical improvement following vitamin C replacement.

A Ehlers-Danlos syndrome

Ehlers-Danlos syndrome refers to a group of inherited disorders in collagen and connective tissue synthesis and structure, resulting in hyperelastic skin, unstable and hypermobile joints, and fragile tissue and blood vessels.

B von Willebrand's disease

von Willebrand's disease is a hereditary clotting disorder associated with an increased bleeding tendency and easy bruising.

C Disseminated intravascular coagulation (DIC)

DIC is a coagulation disorder characterized by the widespread activation of the clotting cascade that results in the formation of clots in the small blood vessels throughout the body. Common causes include sepsis, malignancies, and large injuries.

E Thrombotic thrombocytopenic purpura

Rana Alnasser's screen

A 60-year-old woman develops a sudden onset, widespread, erythematous rash, covering 95% of her body after commencing a course of intravenous (IV) vancomycin for an MRSA positive lesion on her hand following IV cannulation.

The rash is shown below.

Emollients are initiated and the vancomycin is discontinued.

Which of the following is the most appropriate additional intervention?

A	Infliximab
B	Topical corticosteroids
C	Oral cyclosporine
D	Oral prednisolone
E	Vorinostat

Your answer was incorrect

A Infliximab

B Topical corticosteroids

C Oral cyclosporine

D Oral prednisolone

E Vorinostat

Explanation

B Topical corticosteroids

This patient has generalised exfoliative dermatitis, or 'red man syndrome', which is well known to be associated with vancomycin prescription. Potent topical steroids combined with emollient dressings are the initial intervention of choice, coupled with careful attention to maintenance of fluid balance.

D Oral prednisolone

Given the extent of tissue inflammation in erythroderma, topical steroids are actually very effective and are therefore preferred.

A Infliximab

Infliximab is primarily an intervention for the treatment of severe psoriasis, rather than for exfoliative dermatitis.

10:03
NC
MyPastest
https://mypastest.pastest.com

A Infliximab

B Topical corticosteroids

C Oral cyclosporine

D Oral prednisolone

E Vorinostat

Explanation

B Topical corticosteroids

This patient has generalised exfoliative dermatitis, or 'red man syndrome', which is well known to be associated with vancomycin prescription. Potent topical steroids combined with emollient dressings are the initial intervention of choice, coupled with careful attention to maintenance of fluid balance.

D Oral prednisolone

Given the extent of tissue inflammation in erythroderma, topical steroids are actually very effective and are therefore preferred.

A Infliximab

Infliximab is primarily an intervention for the treatment of severe psoriasis, rather than for exfoliative dermatitis.

Explanation

B Topical corticosteroids

This patient has generalised exfoliative dermatitis, or 'red man syndrome', which is well known to be associated with vancomycin prescription. Potent topical steroids combined with emollient dressings are the initial intervention of choice, coupled with careful attention to maintenance of fluid balance.

D Oral prednisolone

Given the extent of tissue inflammation in erythroderma, topical steroids are actually very effective and are therefore preferred.

A Infliximab

Infliximab is primarily an intervention for the treatment of severe psoriasis, rather than for exfoliative dermatitis.

C Oral cyclosporine

Cyclosporine can be used to treat both severe eczema and psoriasis not responsive to other interventions.

E Vorinostat

Vorinostat is an intervention for cutaneous T-cell lymphoma, which is also associated with erythroderma.

Rate this question:

Next Question

10:04

A 22-year-old woman is reviewed annually in clinic. She has multiple skin-coloured and pink–tan soft papules and nodules on her back and several darker brown large macules on her trunk. There are tiny, freckle-like lesions in both axillae.

Which of the following is most likely to be found on further investigations or further physical examination?

A	Acoustic neuroma
B	Phaeochromocytoma
C	Lisch nodules
D	Charcot's joints
E	Astrocytoma

Submit

Previous Q... Skip Questi...

© Pastest 2019

10:04

A 22-year-old woman is reviewed annually in clinic. She has multiple skin-coloured and pink–tan soft papules and nodules on her back and several darker brown large macules on her trunk. There are tiny, freckle-like lesions in both axillae.

Which of the following is most likely to be found on further investigations or further physical examination?

A	Acoustic neuroma
B	Phaeochromocytoma
C	Lisch nodules
D	Charcot's joints
E	Astrocytoma

9202

Submit

Previous Q... Skip Questi...

© Pastest 2019

10:06

A 22-year-old woman is reviewed annually in clinic. She has multiple skin-coloured and pink-tan soft papules and nodules on her back and several darker brown large macules on her trunk. There are tiny, freckle-like lesions in both axillae.

Which of the following is most likely to be found on further investigations or further physical examination?

Your answer was correct

A	Acoustic neuroma
B	Phaeochromocytoma
C	Lisch nodules
D	Charcot's joints
E	Astrocytoma

Explanation

C Lisch nodules

This patient has neurofibromas, several café-au-lait macules and axillary freckling. This describes neurofibromatosis type 1 (von Recklinghausen's) chromosome 17. Pigmented harmartomas in the iris (Lisch nodules), which do not occur in NF2, are found in 95% of patients.

Rana Alnasser's screen

10:06

Explanation

C Lisch nodules

This patient has neurofibromas, several café-au-lait macules and axillary freckling. This describes neurofibromatosis type 1 (von Recklinghausen's) chromosome 17. Pigmented harmartomas in the iris (Lisch nodules), which do not occur in NF2, are found in 95% of patients.

A Acoustic neuroma

Acoustic neuroma is not classically described in patients with NF1; although case reports exist of it occurring, bilateral acoustic neuromas are seen in NF2 due to a mutation on chromosome 22.

B Phaeochromocytoma

Phaeochromocytomas occur in about 5% of patients and optic gliomas, astrocytomas and meningiomas may also occur.

D Charcot's joints

Spinal nerve root involvement may lead to cord compression, muscle wasting and sensory loss (Charcot's joints), although this is relatively rarely seen and is less likely to occur in a young woman of 22.

E Astrocytoma

Astrocytomas are seen in NF1, but they are rare.

Rana Alnasser's screen

10:07

A 32-year-old man, a smoker of one packet of cigarettes per day, is referred by his dentist. He has noticed whitish areas over the side of the tongue, as shown in the photograph below, which do not come away when the tongue is brushed.

What is the most likely diagnosis?

A	Oral hairy leucoplakia
B	Candidiasis
C	Squamous cell carcinoma
D	Lichen planus
E	Syphilitic mucous patch

Submit

Rana Alnasser's screen

10:08

Explanation

A Oral hairy leucoplakia

This is an oral mucosal disease first described in 1984; it is associated with Epstein–Barr virus (EBV) and occurs almost exclusively in patients who are immunocompromised, particularly those infected with HIV. As well as being a sign of AIDS, it has also been described in association with inflammatory bowel disease and Behçet's disease. It is non-painful, and the appearance of the white plaque may change slightly from day to day. Smoking more than a pack of cigarettes a day is correlated positively with development of OHL in men who are HIV-positive. The risk of developing OHL doubles with each 300-unit decrease in CD4 count. Diagnosis is clinical, though biopsy may be helpful in some cases to exclude dysplasia or malignancy. Treatment is of the underlying disorder, most often with anti-retroviral therapy.

B Candidiasis

This is associated with more extensive adherent white plaques. Typically, these can be removed by brushing to leave an eroded, red area.

C Squamous cell carcinoma

Whilst smoking is an important risk factor for oral cancer, it usually presents with a discrete lesion, which may be ulcerated.

D Lichen planus

The Wickham's striae of oral lichen planus form a reticular white network rather than the solid plaques seen here.

Rana Alnasser's screen

B Candidiasis

This is associated with more extensive adherent white plaques. Typically, these can be removed by brushing to leave an eroded, red area.

C Squamous cell carcinoma

Whilst smoking is an important risk factor for oral cancer, it usually presents with a discrete lesion, which may be ulcerated.

D Lichen planus

The Wickham's striae of oral lichen planus form a reticular white network, rather than the solid plaques seen here.

E Syphilitic mucous patch

This occurs in secondary syphilis, typically presenting as a grey or white plaque. It may be solitary or multiple. Coalescence may result in classical 'snail-track' ulceration.

Rate this question:

Next Question

Previous Q... Tag Questi... Feedback End Session

Blog About Pastest Contact Us Help

© Pastest 2019

10:08

A 62-year-old woman presents to the General Medical Clinic as she has noticed itchiness of her scalp. She has previously had eczema as a child but has not suffered from any dermatological problems in adulthood. She has previously had a wide local excision for breast cancer and has maintained remission. She has never smoked.

A photograph of her scalp is shown below.

What is the most appropriate treatment?

A	Coal-tar-based shampoo
B	Salicylic-acid-based shampoo
C	Oral corticosteroids
D	Potent topical corticosteroids
E	Oral griseofulvin

71630

Submit

Rana Alnasser's screen

10:11

D	Potent topical corticosteroids

This patient has scalp psoriasis. This is seen as a salmon-pink rash with silvery scales which is usually itchy in nature. Treatment advised by NICE is to first try topical high-potency corticosteroids. Second-line treatment is with topical vitamin D therapy.

A	Coal-tar-based shampoo

The National Institute for Health and Care Excellence (NICE) has found that coal-tar-based shampoos are less effective than a placebo for scalp psoriasis and are unlikely to be helpful.

B	Salicylic-acid-based shampoo

Salicylic acid is a keratolytic therapy. It can be used to reduce thick scales to allow other treatments to reach the scalp. In the absence of multiple thick scales, it should not be used. It is also not of use as monotherapy.

C	Oral corticosteroids

Oral corticosteroids should be avoided in psoriasis. This is because systemic therapy tends to cause rebound psoriasis.

E	Oral griseofulvin

Oral griseofulvin is effective for fungal infections of the scalp such as tinea capitis. These infections show dry scaling with black dots and smooth areas of hair loss. The clinical picture does not match this description.

71630

Rate this question:

Rana Alnasser's screen

10:12

NC ...

seborrheic dermatitis

ALL IMAGES SHOPPING NEWS VIDEOS MAPS BOOKS FLIG

Latest GIF HD Product

scalp hair loss treatment face

Psoriasis vs. Seborrheic Dermatitis ...
healthline.com

Seborrheic Dermatitis | National Eczema ...
nationaleczema.org

Psoriasis vs. Seborrheic Dermatitis ...
healthline.com

Seborrheic Dermatitis: Symptoms ...
en.the-health-site.com

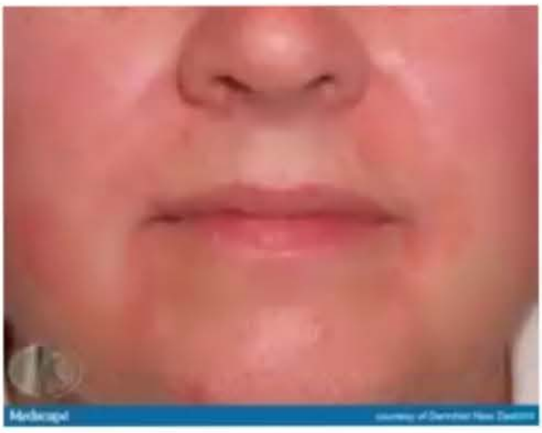

I Can't Take This Rash Anymore!'
medscape.com

Psoriasis vs. Seborrheic Dermatitis ...
healthline.com

Discover Updates Search Recen

Rana Alnasser's screen

10:14
594-042-7551
Leave

A 26-year-old woman presents with an enlarging 6 cm indurated, hypopigmented plaque at the umbilicus which had appeared shortly after she had her belly-button pierced the previous year. She is anxious as it appears to be enlarging and now she cannot wear any jewellery at the site.

She has no other skin lesions elsewhere and no other medical problems. She takes no medications regularly and has no allergies. She is smoker of 20 cigarettes per day and drinks alcohol occasionally.

What is the diagnosis?

A	Tinea corporis
B	Post-inflammatory hypopigmentation
C	Vitiligo
D	Lichen planus
E	Morphoea

Submit

Audio
Video
Share
Participants
More

E Morphoea

- The cause of morphoea is uncertain.
- It typically presents with one or more indurated plaques and is more common in females.
- These are usually initially inflamed, especially around the border leading to an annular appearance.
- As the sclerotic process progresses, plaques go from thickened to atrophic.
- Eventually, the inflammation usually subsides and the plaque turns brown or ivory white.
- Some patients describe tightness of the skin, itching or discomfort, though the condition may be asymptomatic.
- The linear variant of morphoea is more common in children: on the forehead, this is known as morphoea en coup de sabre.
- Linear morphoea over a joint can result in restriction of movement if not treated effectively.
- Treatment options for morphoea in general include potent or very potent topical corticosteroids, oral corticosteroids, phototherapy and methotrexate.

A Tinea corporis

Whilst this might present with an enlarging plaque on the abdomen, it is a superficial process without induration. Peripheral scaling and an annular appearance would be expected.

B Post-inflammatory hypopigmentation

This follows an episode of inflammation, which is not

of movement if not treated effectively.

- Treatment options for morphoea in general include potent or very potent topical corticosteroids, oral corticosteroids, phototherapy and methotrexate.

A Tinea corporis

Whilst this might present with an enlarging plaque on the abdomen, it is a superficial process without induration. Peripheral scaling and an annular appearance would be expected.

B Post-inflammatory hypopigmentation

This follows an episode of inflammation, which is not mentioned in the history. It is macular.

C Vitiligo

This condition can appear at sites of trauma, but is macular and causes depigmentation (complete loss of pigment) rather than hypopigmentation (partial reduction in pigmentation).

D Lichen planus

There are many forms of this condition, the commonest (classical lichen planus) presenting with pruritic violaceous papules. There are annular and atrophic variants that might possibly appear similar to morphoea, but these do not cause significant induration.

Rate this question:

Next Question

A 30-year-old man presents with the following rash. It started as a lesion on the knuckles a year ago. Over the last 6 months, it has spread to the arm, trunk and back. He has also noticed some weight loss and malaise.

He works as an entertainment officer on a cruise ship, is single, and has recently spent the past year cruising around the Far East.

His blood pressure is 122/72 mmHg, pulse is 65 bpm and regular and his BMI is 23. Cardiovascular, respiratory and abdominal examination is unremarkable. There is no tremor.

Which of the following is the disease most likely to be the underlying his skin appearance?

A	Hodgkin's lymphoma
B	Hyperthyroidism
C	HIV infection
D	Non-Hodgkin's lymphoma
E	Systemic lupus erythematosus

10:17
NC

A	Hodgkin's lymphoma
B	Hyperthyroidism
C	HIV infection
D	Non-Hodgkin's lymphoma
E	Systemic lupus erythematosus

Explanation

C	HIV infection

The skin rash shown here is disseminated granuloma annulare. The cause is unknown, although there are numerous reports of the association of granuloma annu with HIV infection and lymphoma; given what we know this man's age and lifestyle, HIV is the likelier of the two diagnoses. Clinically, lesions lie over the knuckles and ar composed of dermal nodules fused into a rough ring sh On the trunk, many lesions may have a purple tinge to them. Lesions usually resolve over 2–3 years. Stubborn lesions respond to intra-lesional trimacinolone or systen immunosuppressants. Some resolution occurs when the diagnosis of HIV is made and HAART is instituted.

A	Hodgkin's lymphoma

Although Hodgkin's lymphoma is a recognised cause of granuloma annulare, the history fits better with a potent infectious agent as the cause of his presentation, rather than haematological malignancy.

B	Hyperthyroidism

10:18

Google

ninated granuloma annulare

VIDEOS NEWS SHOPPING MAPS BOOKS FLIGHTS TABLET

HD Product

pediatric mild trunk diabetes foot ankle ge

NHS

Disseminated Granuloma Annulare ...
jamanetwork.com

granuloma annulare-dis
atlasdermatologico.com.b

DermNet NZ



granuloma annulare. b C
researchgate.net

Granuloma annulare - Symptoms and ...
mayoclinic.org

NHS

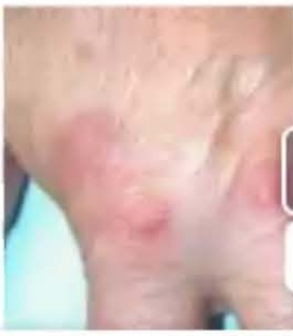

Updates Search Recent

The skin rash shown here is disseminated granuloma annulare. The cause is unknown, although there are numerous reports of the association of granuloma annulare with HIV infection and lymphoma; given what we know of this man's age and lifestyle, HIV is the likelier of the two diagnoses. Clinically, lesions lie over the knuckles and are composed of dermal nodules fused into a rough ring shape. On the trunk, many lesions may have a purple tinge to them. Lesions usually resolve over 2–3 years. Stubborn lesions respond to intra-lesional trimacinolone or systemic immunosuppressants. Some resolution occurs when the diagnosis of HIV is made and HAART is instituted.

A Hodgkin's lymphoma

Although Hodgkin's lymphoma is a recognised cause of granuloma annulare, the history fits better with a potential infectious agent as the cause of his presentation, rather than haematological malignancy.

B Hyperthyroidism

BMI, pulse and blood pressure are in the normal range, and there is no tremor, making significant thyrotoxicosis less likely as the underlying diagnosis here.

D Non-Hodgkin's lymphoma

Generalised granuloma annulare is associated with non-Hodgkin's lymphoma, although NHL presents at an older median age and is associated with other symptoms not present here such as lymphadenopathy, weight loss and night sweats.

E Systemic lupus erythematosus

SLE is commonly associated with an erythematous rash on sun-exposed areas rather than the generalised

A 45-year-old man is unable to sleep because of an extremely itchy rash.

On examination in the Dermatology Clinic, you note violaceous, shiny, flat-topped papules on both wrists, which are particularly marked around an old scar on the flexor aspect of his right forearm.

He has recently commenced beta-blocker therapy for control of blood pressure and to help manage two recent episodes of paroxysmal SVT.

Which of the following is the most likely cause of his skin rash?

A	Guttate psoriasis
B	Lichen planus
C	Contact dermatitis
D	Lichen sclerosis
E	Eruptive xanthomatosis

Submit

10:21
NC
594-042-7551
Leave

On examination in the Dermatology Clinic, you note violaceous, shiny, flat-topped papules on both wrists, which are particularly marked around an old scar on the flexor aspect of his right forearm.

He has recently commenced beta-blocker therapy for control of blood pressure and to help manage two recent episodes of paroxysmal SVT.

Which of the following is the most likely cause of his skin rash?

Your answer was correct

A Guttate psoriasis

B Lichen planus

C Contact dermatitis

D Lichen sclerosis

E Eruptive xanthomatosis

Explanation

B Lichen planus

Lichen planus (LP) characteristically affects flexor surfaces, particularly the wrists. There are fine, white streaks on the surface of the lesions if viewed through a hand lens (Wickham's striae). It demonstrates the Koebner phenomenon (as does psoriasis) – a linear pattern along scratch marks or scars. There are often asymptomatic lacy, white lesions in the buccal mucosa. Certain drugs may cause an LP-like eruption, particularly thiazides, β-blockers, phenothiazines, antimalarials and methyldopa. LP usually

Audio Video Share Participants 2 More

10:22

Respons
Respons
Respons
Respons

A Guttate psoriasis

B Lichen planus

C Contact dermatitis

D Lichen sclerosis

E Eruptive xanthomatosis

Explanation

B Lichen planus

Lichen planus (LP) characteristically affects flexor surfaces, particularly the wrists. There are fine, white streaks on the surface of the lesions if viewed through a hand lens (Wickham's striae). It demonstrates the Koebner phenomenon (as does psoriasis) – a linear pattern along scratch marks or scars. There are often asymptomatic lacy, white lesions in the buccal mucosa. Certain drugs may cause an LP-like eruption, particularly thiazides, β-blockers, phenothiazines, antimalarials and methyldopa. LP usually resolves spontaneously in a few months, but steroids may be required if pruritus is severe.

A Guttate psoriasis

Guttate psoriasis is associated with multiple plaques of psoriasis [illegible]ng over the upper body, rather than the limited skin disease seen here.

Annotation Stop Share
Rana Alnasser's screen

10:22

A Guttate psoriasis

Guttate psoriasis is associated with multiple plaques of psoriasis including over the upper body, rather than the limited skin disease seen here.

C Contact dermatitis

Contact dermatitis is associated with a rash on skin exposed to the allergen, and hence it's most likely to occur on areas such as the hands.

D Lichen sclerosis

Lichen sclerosis is an itchy scarring rash which most commonly affects the genital area and appears to occur more commonly in women.

E Eruptive xanthomatosis

Eruptive xanthomas occur on extensor surfaces and are associated with severe hypertriglyceridaemia.

Rate this question:

Next Question

Previous Q... Tag Questi... Feedback End Session

Blog About Pastest Contact Us Help

Annotation Stop Share

10:22

A 45-year-old woman presented with sudden onset tender nodules on her legs (see photo), fever, joint pains, and shortness of breath.

A chest X-ray in the Emergency Department revealed bilateral hilar lymphadenopathy.

Which of the following syndromes is she most likely presenting with?

A	Lofgren's syndrome
B	Felty's syndrome
C	Caplan's syndrome
D	Loffler's syndrome
E	Sjogren's syndrome

Annotation Stop Share

Explanation

A Lofgren's syndrome

Lofgren's syndrome is a form of acute sarcoidosis that presents with erythema nodosum, bilateral hilar lymphadenopathy and is additionally often accompanied by joint symptoms.

B Felty's syndrome

Felty's syndrome consists of the following triad: rheumatoid arthritis, splenomegaly and neutropenia.

C Caplan's syndrome

Caplan's syndrome is classified as the combination of rheumatoid arthritis and pneumoconiosis.

D Loffler's syndrome

Loffler's syndrome occurs due to the accumulation of eosinophils in the lung as a result of parasitic infections, ascaris lumbricoides is the commonest cause.

E Sjogren's syndrome

Sjogren's syndrome is an autoimmune condition resulting in the destruction of secretory glands in the eyes and mouth resulting in ulceration, and sicca.

40102

Rate this question:

10:23

A 55-year-old woman has noticed unusual growths on her toes and has started to become concerned. They are not painful and do not cause any itching. She denies any trauma.

She had a past medical history of chronic kidney disease, type 2 diabetes mellitus and hysterectomy.

A photograph of her toes is shown below.

What is the most likely diagnosis?

A	Subungual fibromas
B	Subungual warts
C	Squamous cell carcinoma (SCC)
D	Seborrhoeic warts
E	Keratoacanthoma

71605

Rana Alnasser's screen

10:24

What is the most likely diagnosis?

Your answer was incorrect

A Subungual fibromas

B Subungual warts

C Squamous cell carcinoma (SCC)

D Seborrhoeic warts

E Keratoacanthoma

Explanation

A Subungual fibromas

Subungual fibromas are slow-growing, painless tumours seen in the nail fold. They can be round and feel elastic. They cause complications when elevating the nail and can cause erosion of the distal phalanx.

B Subungual warts

Rana Alnasser's screen

Explanation

A	Subungual fibromas

Subungual fibromas are slow-growing, painless tumours seen in the nail fold. They can be round and feel elastic. They cause complications when elevating the nail and can cause erosion of the distal phalanx.

B	Subungual warts

Subungual warts are caused by human papillomavirus infections and can lead to swellings around the toes as well as on any other skin surfaces. They are more common in children. They present with a cauliflower-like, firm growth which can lead to nail displacement and are often slightly discoloured. It is unusual to develop many warts unless there is evidence of immunocompromise.

C	Squamous cell carcinoma (SCC)

An SCC is a malignant tumour of keratinised cells and is locally invasive with potential for metastatic spread. It occurs with increasing frequency with high UV exposure, especially to fair skin, radiation exposure and following human papillomavirus infections. Presentation is as a single indurated nodular crusted tumour which may ulcerate, especially in areas of high sun exposure or in chronic ulcers. The absence of such appearance makes this an unlikely differential.

D	Seborrhoeic warts

Seborrhoeic warts are benign hyperkeratotic skin lesions usually associated with the elderly, sometimes following sunburn. They are typically flat-topped and stuck-on in appearance with a well-circumscribed border and they have visible keratin dots. The absence of such an

10:25

subungual warts

dying | mild | healed | minor | small | finger | toe

Subungual wart. | Download Scientific ...
researchgate.net

Subungual wart: MedlinePlus Medical ...
medlineplus.gov

Subungual And Periungual Warts Are The Sa...
wartstreatmentguide.com

a: Subungual warts: pretreatment ...
researchgate.net

topical treatment of periungual warts ...
escholarship.org

Discover
Updates
Search

A 50-year-old lady is admitted for resection of a frontal lobe tumour.

The lesion shown in the image was noted on her back by the admitting doctor.

What is the likely diagnosis?

A	Melanoma
B	Seborrhoeic keratoses
C	Café au lait macule
D	Neurofibroma
E	Acanthosis nigricans

Submit

10:26

A 50-year-old lady is admitted for resection of a frontal lobe tumour.

The lesion shown in the image was noted on her back by the admitting doctor.

What is the likely diagnosis?

Your answer was incorrect

A	Melanoma
B	Seborrhoeic keratoses
C	Café au lait macule
D	Neurofibroma
E	Acanthosis nigricans

Explanation

B	Seborrhoeic keratoses

This is an extremely common, harmless skin lesion that first appears during adult life. It is the commonest benign tumour in older individuals. It has also been referred to as

Rana Alnasser's screen

B Seborrhoeic keratoses

This is an extremely common, harmless skin lesion that first appears during adult life – it is the commonest benign tumour in older individuals. It has also been referred to as basal cell papilloma, senile wart or brown wart. Seborrhoeic keratosis is often initially flat, but becomes raised over time. It may be seen as cosmetically unattractive. Most are asymptomatic, though some itch. Elevated lesions may become traumatised, causing local discomfort. The number of such lesions tends to increase with age. Some individuals have hundreds. The cause is unknown. In terms of the appearance, colour can range from skin-coloured to very dark brown. They are very well defined, and elevated lesions develop a cobblestoned or verrucous surface, as shown in the image. Treatment is not usually necessary, though cryotherapy or curettage may be performed for symptomatic lesions.

A Melanoma

Although this lesion is hyperpigmented, it has typical features of seborrhoeic keratosis.

C Café au lait macule

In accordance with the term macule, these are impalpable lesions of tan hyperpigmentation.

D Neurofibroma

Whilst these may be numerous in neurofibromatosis, they may present as a solitary, sporadic lesion. They are skin-coloured, soft and fleshy, with a smooth surface.

E Acanthosis nigricans

Rana Alnasser's screen

10:27

A Melanoma

Although this lesion is hyperpigmented, it has typical features of seborrhoeic keratosis.

C Café au lait macule

In accordance with the term macule, these are impalpable lesions of tan hyperpigmentation.

D Neurofibroma

Whilst these may be numerous in neurofibromatosis, they may present as a solitary, sporadic lesion. They are skin-coloured, soft and fleshy, with a smooth surface.

E Acanthosis nigricans

This causes velvety hyperpigmentation in the flexures, rather than the discrete lesion seen here.

Rate this question:

© Pastest 2019

Audio Video Share Participants 2 More

10:27

A GP has referred a 19-year-old man, a refugee, to the General Medical Clinic for an opinion.

The patient's use of English is limited and no obvious medical history is elicited from the patient. The patient is on no medication. The patient appears to be developmentally normal.

On examination, the patient is noted to be fair skinned with white hair, he has white eyelashes and both irises have a pink hue.

What is the likely diagnosis?

A	Ocular albinism
B	Oculocutaneous albinism, type 1
C	Oculocutaneous albinism, type 3
D	Homocystinuria
E	Phenylketonuria

6796

Submit

Previous Q... Skip Questi...

Audio Video Share Participants 2 More
Blog About Pastest Contact Us Help

A GP has referred a 19-year-old man, a refugee, to the General Medical Clinic for an opinion.

The patient's use of English is limited and no obvious medical history is elicited from the patient. The patient is on no medication. The patient appears to be developmentally normal.

On examination, the patient is noted to be fair skinned with white hair, he has white eyelashes and both irises have a pink hue.

What is the likely diagnosis?

Your answer was correct

A	Ocular albinism
B	Oculocutaneous albinism, type 1
C	Oculocutaneous albinism, type 3
D	Homocystinuria
E	Phenylketonuria

Explanation

B	Oculocutaneous albinism, type 1

Oculocutaneous albinism type 1 (OCA 1) presents with the complete absence of melanin in the hair, skin and eyes (subtype OCA 1A). Other symptoms and signs include photophobia, loss of visual acuity, and nystagmus. A

10:30
albinism pink hue
594-042-7551
Leave

Latest GIF HD Product

eyes cat dog white red fitzpatrick oculocuta

albino people with pink eyes - Google ...
pinterest.com

Albino with violet eyes ...
pinterest.com

Demystifying Albinism: Seeing Red ...
positivespecialneedsparenting.com

ALBINISM - ALBINISMO
pinterest.com



Audio Discover Video Updates Share Participants 2 Search More

10:31
NC
MyPastest
https://mypastest.pastest.com

B Oculocutaneous albinism, type 1

Oculocutaneous albinism type 1 (OCA 1) presents with the complete absence of melanin in the hair, skin and eyes (subtype OCA 1A). Other symptoms and signs include photophobia, loss of visual acuity, and nystagmus. A different subgroup of OCA 1 (OCA 1B) can present with some pigmentation in these same tissues and therefore fewer eye problems. The remaining forms of oculocutaneous albinism reflect an increased presence of melanin in tissues.

A Ocular albinism

Albinism is a hypopigmentation disorder that results from a defect in the production of melanin. Types of albinism include: oculocutaneous albinism types 1-4, ocular albinism, Chediak-Higashi syndrome, Hermansky-Pudlak syndrome and Griscelli syndrome.

Ocular albinism patients usually have almost normal skin and hair colour. However, their skin and hair tend to be lighter than their siblings (this feature becomes particularly apparent in darker-skinned populations). Almost all of these patients have iris transillumination defects and present with congenital nystagmus that may be accompanied by reduced visual acuity, refractive errors, fundus hypopigmentation, lack of foveal reflex and strabismus.

C Oculocutaneous albinism, type 3

Affected individuals typically have reddish hair, and blue or gray eyes.

Rana Alnasser's screen

include: oculocutaneous albinism types 1-4, ocular albinism, Chediak-Higashi syndrome, Hermansky-Pudlak syndrome and Griscelli syndrome.

Ocular albinism patients usually have almost normal skin and hair colour. However, their skin and hair tend to be lighter than their siblings (this feature becomes particularly apparent in darker-skinned populations). Almost all of these patients have iris transillumination defects and present with congenital nystagmus that may be accompanied by reduced visual acuity, refractive errors, fundus hypopigmentation, lack of foveal reflex and strabismus.

C	Oculocutaneous albinism, type 3

Affected individuals typically have reddish hair, and blue or gray eyes.

D	Homocystinuria

Homocystinuria is an inherited autosomal recessive disorder resulting from defective methionine metabolism. These patients tend to have a typical physical appearance (long thin extremities, arachnodactyly, pale skin and hair), Unless the condition is diagnosed early and appropriate dietary restrictions started, patients develop a multitude of additional symptoms from early childhood (neurological, psychiatric, ocular, and cardiovascular).

E	Phenylketonuria

Phenylketonuria is another inherited autosomal recessive condition characterised by a defect in the pathway of phenylalanine metabolism. Patients tend to be of fair hair and skin. This condition is now routinely screened for at birth and appropriate dietary restrictions implemented in order to avoid complications.

10:33
594-042-7551 Leave

A 29-year-old woman presented with itchy, pigmented macules on her trunk and limbs, for the last 5 years. She says they become particularly itchy and red when they are rubbed and when she has a bath or exercises.

She denies any wheezing, flushing, diarrhoea, abdominal pain or any other systemic symptoms. She has no significant past medical history.

Which of the following is the most likely diagnosis?

A	Vasculitis
B	Systemic mastocytosis
C	Urticaria pigmentosa
D	Carcinoid syndrome
E	Leukaemia cutis

38520

Submit

Audio Video Share Participants More

10:33

A 29-year-old woman presented with itchy, pigmented macules on her trunk and limbs, for the last 5 years. She says they become particularly itchy and red when they are rubbed and when she has a bath or exercises.

She denies any wheezing, flushing, diarrhoea, abdominal pain or any other systemic symptoms. She has no significant past medical history.

Which of the following is the most likely diagnosis?

Your answer was incorrect

A Vasculitis

B Systemic mastocytosis

C Urticaria pigmentosa

D Carcinoid syndrome

E Leukaemia cutis

Explanation

C Urticaria pigmentosa

Rana Alnasser's screen

10:33
NC
MyPastest
https://mypastest.pastest.com

C Urticaria pigmentosa

Urticaria pigmentosa (UP) or cutaneous mastocytosis is part of a group of conditions called 'mastocytosis', in which mast cells proliferate and accumulate in the skin and other organs. UP is a localised form of mastocytosis confined to the skin. It manifests in brown, freckle-like macules that urticate (become erythematous and raised) if rubbed.

B Systemic mastocytosis

In systemic mastocytosis, mast cells disseminate widely in the skin and there may be systemic symptoms of mast cell release including wheezing, flushing, diarrhoea, hypotension, syncope, dyspnoea and anaphylaxis. Serum tryptase may be raised.

A Vasculitis

Vasculitis is limited to the skin only, and without progression over the course of 5 years to involve other organs such as the kidneys would be very unusual.

D Carcinoid syndrome

Carcinoid syndrome may cause episodic facial flushing eventually leading to persistent facial erythema and telangiectasia.

E Leukaemia cutis

Leukaemia cutis would normally present with more pronounced, raised lesions (papules/nodules or plaques) and one would expect symptoms and signs of bone

organs. UP is a localised form of mastocytosis confined to the skin. It manifests in brown, freckle-like macules that urticate (become erythematous and raised) if rubbed.

B Systemic mastocytosis

In systemic mastocytosis, mast cells disseminate widely in the skin and there may be systemic symptoms of mast cell release including wheezing, flushing, diarrhoea, hypotension, syncope, dyspnoea and anaphylaxis. Serum tryptase may be raised.

A Vasculitis

Vasculitis is limited to the skin only, and without progression over the course of 5 years to involve other organs such as the kidneys would be very unusual.

D Carcinoid syndrome

Carcinoid syndrome may cause episodic facial flushing eventually leading to persistent facial erythema and telangiectasia.

E Leukaemia cutis

Leukaemia cutis would normally present with more pronounced, raised lesions (papules/nodules or plaques) and one would expect symptoms and signs of bone marrow failure.

Rate this question:

Next Question

A 30-year-old overweight mechanic, who is otherwise well with no other symptoms, presents with an intensely itchy rash over both elbows. He denies any significant past medical history but admits to drinking 2 pints of lager on a daily basis.

What is the best initial management for relief of his symptoms?

A	Beclomethasone cream
B	Dapsone
C	Dithranol
D	Patch testing for occupational allergy
E	Narrow-band UVB phototherapy

Submit

with no other symptoms, presents with an intensely itchy rash over both elbows. He denies any significant past medical history but admits to drinking 2 pints of lager on a daily basis.

What is the best initial management for relief of his symptoms?

Your answer was correct

A Beclomethasone cream

B Dapsone

C Dithranol

D Patch testing for occupational allergy

E Narrow-band UVB phototherapy

Explanation

B Dapsone

The picture shows dermatitis herpetiformis (DH), an

B Dapsone

The picture shows dermatitis herpetiformis (DH), an immune-mediated blistering skin disease with an associated, commonly asymptomatic, gluten-sensitive enteropathy (GSE). The rash is characteristically very itchy with blistering lesions over the extensor surfaces. Although all patients with DH by definition have gluten-sensitive enteropathy, fewer than 10% of patients have gastrointestinal symptoms.

Histologically there is granular deposition of immunoglobulin A (IgA) at the dermal–epidermal junction of the skin. IgA-circulating immune complexes are present in 25–35% of patients with DH, although no association with disease severity has been noted. These immune complexes also have been noted in patients with isolated GSE, and are likely linked to the presence of enteric disease.

First-line treatment is with dapsone, which brings rapid improvement in most A gluten-free diet may also improve or control the symptoms in some patients with DH, especially as a long-term measure (eventually allowing discontinuation of dapsone). However, it requires motivation, as the diet may be unpalatable and difficult to adhere to.

A Beclomethasone cream

Topical corticosteroids are not used in the treatment of DH.

C Dithranol

Dithranol is a topical agent, commonly used in the treatment of plaque psoriasis, and is not used in the management of DH.

D Patch testing for occupational allergy

10:35

A 60-year-old man presented with a 1-week history of painful mouth ulcers and blistering lesions over the face and upper body. He also complained of some general malaise.

On examination, he had evidence of gingival erosions and bullae over the scalp and chest. The lesions were friable, and some had crusted over. Nikolsky sign was positive.

What is the most likely cause of the presentation?

A Erythema multiforme

B Bullous pemphigoid

C Dermatitis herpetiformis

D Pemphigus vulgaris (PV)

E Bullous impetigo

Submit

Previous Q... Skip Questi...

© Pastest 2019

Rana Alnasser's screen

10:36

A 60-year-old man presented with a 1-week history of painful mouth ulcers and blistering lesions over the face and upper body. He also complained of some general malaise.

On examination, he had evidence of gingival erosions and bullae over the scalp and chest. The lesions were friable, and some had crusted over. Nikolsky sign was positive.

What is the most likely cause of the presentation?

Your answer was correct

A	Erythema multiforme
B	Bullous pemphigoid
C	Dermatitis herpetiformis
D	Pemphigus vulgaris (PV)
E	Bullous impetigo

Explanation

D Pemphigus vulgaris (PV)

The answer is Pemphigus vulgaris (PV) (Option D).

PV is an autoimmune intra-epithelial, blistering disease, affecting the skin and mucous membranes, that is mediated by circulating autoantibodies directed against keratinocyte cell surfaces. It can present with erosions in the mouth and flaccid blisters on the skin. The cause of PV

10:36

D Pemphigus vulgaris (PV)

The answer is Pemphigus vulgaris (PV) (Option D).

PV is an autoimmune intra-epithelial, blistering disease, affecting the skin and mucous membranes, that is mediated by circulating autoantibodies directed against keratinocyte cell surfaces. It can present with erosions in the mouth and flaccid blisters on the skin. The cause of PV remains unknown, but there is a recognised association with the human leukocyte antigen DR4 (DRB1*0402) and human leukocyte antigen DRw6 (DQB1*0503) alleles. Patients often also have other autoimmune diseases, particularly myasthenia gravis and thymoma.

A Erythema multiforme

Erythema multiforme (Option A) is incorrect.

The typical target lesions of erythema multiforme have a sharp margin, a round shape and three concentric zones of colours (and possibly a blister in the middle). Erythema multiforme may involve the mouth with multiple irregular erosions. Extensive involvement of the mouth, lips, conjunctivae and genitalia is called Stevens–Johnson syndrome. Infections are probably associated with at least 90% of cases of erythema multiforme, with the most common infections being herpes simplex virus and *Mycoplasma pneumoniae*. Management is supportive.

B Bullous pemphigoid

Bullous pemphigoid (Option B) is incorrect.

This is an immune-mediated blistering disorder that presents with tense blisters in the elderly. It uncommonly affects the mucosae and may be preceded by an itchy rash lasting from days to weeks (pre-bullous pemphigoid).

C Dermatitis herpetiformis

Rana Alnasser's screen

Erythema multiforme (Option A) is incorrect.

The typical target lesions of erythema multiforme have a sharp margin, a round shape and three concentric zones of colours (and possibly a blister in the middle). Erythema multiforme may involve the mouth with multiple irregular erosions. Extensive involvement of the mouth, lips, conjunctivae and genitalia is called Stevens-Johnson syndrome. Infections are probably associated with at least 90% of cases of erythema multiforme, with the most common infections being herpes simplex virus and *Mycoplasma pneumoniae*. Management is supportive.

B	Bullous pemphigoid

Bullous pemphigoid (Option B) is incorrect.

This is an immune-mediated blistering disorder that presents with tense blisters in the elderly. It uncommonly affects the mucosae and may be preceded by an itchy rash lasting from days to weeks (pre-bullous pemphigoid).

C	Dermatitis herpetiformis

Dermatitis herpetiformis (Option C) is incorrect.

Dermatitis herpetiformis occurs in close association with coeliac disease and presents with very itchy, grouped vesicles, most frequent on the extensor surface of the knees, elbows, buttocks and shoulders. Treatment is with dapsone and a gluten-free diet.

E	Bullous impetigo

Bullous impetigo (Option E) is incorrect.

This uncommon form of impetigo presents with small vesicles that evolve into flaccid, transparent bullae. It is due to staphylococcal exfoliative toxins, which target desmoglein 1 and cleave off the superficial epidermis.

10:38

A 49-year-old man presents with a 3-month history of painful mouth ulcers. He also mentions intermittent diarrhoea, and occasional colicky abdominal pain.

Until a year ago, his general health had been good, but he has felt generally unwell recently with diffuse aches and pains.

Six months ago, he required ophthalmological investigation and treatment for anterior uveitis. At this time, he also developed superficial venous thrombophlebitis at two different venepuncture sites.

Oral lesions noted on examination are shown in the photograph below:

What is the most likely diagnosis?

A	Behçet's disease
B	Crohn's disease
C	Ulcerative colitis
D	Coeliac disease
E	Sarcoidosis

10:39
NC ...

two conditions is the phenomenon of pathergy (a condition in which minor trauma can lead to the development of further blistering lesions), which is characteristic of Behçet's syndrome.

Ocular involvement is seen in about 70% of patients; most often in the form of anterior or posterior uveitis. Other manifestations include musculoskeletal (arthralgias/arthritis in 50%); skin (erythema nodosum, acneiform lesions, thrombophlebitis, and cutaneous hypersensitivity); central and peripheral nervous system lesions; and vascular lesions. The vascular involvement in Behçet's syndrome is unique in that it is the only vasculitic disease that involves both the arterial and venous systems, and typically presents as superficial thrombophlebitis or deep venous thrombosis. The cause and pathogenesis of Behçet's disease remain unknown, but the tumour necrosis factor alpha (TNF-alpha) pathway is likely implicated.

B Crohn's disease

Extraintestinal involvement of Crohn's could lead to similar symptoms; however bowel symptoms would be the predominant feature and superficial thrombophlebitis would not be typical.

C Ulcerative colitis

As with Crohn's disease, the symptoms of ulcerative colitis (UC) may be similar but are usually intestine predominant. Additional commonly encountered extraintestinal symptoms of UC and Crohn's disease include arthritis, erythema nodosum, and pyoderma gangrenosum.

D Coeliac disease

Coeliac disease is associated with diarrhoea, abdominal cramping and bloating. The commonest cutaneous manifestation is of dermatitis herpetiformis.

Rana Alnasser's screen

10:39

A 23-year-old man presents to the General Medical Clinic with a new itchy rash. He has no previous medical problems. He has not had any previous skin problems. He denies any intravenous (IV) drug abuse.

A photograph of his skin is shown below.

What is the most appropriate management plan?

A	Topical ketoconazole
B	Oral terbinafine
C	Topical corticosteroids
D	Topical vitamin D
E	Refer to oncology

Submit

Previous Q... Skip Questi...

© Pastest 2019

Rana Alnasser's screen

A 23-year-old man presents to the General Medical Clinic with a new itchy rash. He has no previous medical problems. He has not had any previous skin problems. He denies any intravenous (IV) drug abuse.

A photograph of his skin is shown below.

What is the most appropriate management plan?

A	Topical ketoconazole
B	Oral terbinafine
C	Topical corticosteroids
D	Topical vitamin D
E	Refer to oncology

Submit

10:39

A Topical ketoconazole

This patient has a typical rash of tinea corpis. Tinea corpis, commonly known as ringworm, is a dermatophyte fungal infection of the trunk, legs or arms. Different species cause this infection depending on the part of the world the patient is in. Clinically, there may be an acute or chronic rash, spreading from the infected site. The rash is characterised by itchy, inflamed red patches which may be pustular, in oval shape. There are characteristic rings as the rash spreads. Treatment should be with topical antifungal agents in the first instance, and if there is treatment failure then oral antifungal treatment can be considered.

B Oral terbinafine

Oral antifungal treatment would be effective, but generally topical treatment should be first-line. Terbinafine and other antifungals can cause liver injury, as well as gastrointestinal upset.

C Topical corticosteroids

The pattern of this patient's rash is consistent with a fungal infection. Steroid treatment would cause immunosuppression and make the infection worse, causing further spread. Had this been a condition such as eczema or psoriasis, then corticosteroids would have been appropriate. The key differentiating factor is the spreading element of the rash, the ring-like appearance and the location.

D Topical vitamin D

Topical vitamin D is used in conjunction with topical corticosteroids for psoriasis. Psoriasis typically presents as plaques of silvery scales on top of a salmon-pink rash.

Rana Alnasser's screen

Oral antifungal treatment would be effective, but generally topical treatment should be first-line. Terbinafine and other antifungals can cause liver injury, as well as gastrointestinal upset.

C Topical corticosteroids

The pattern of this patient's rash is consistent with a fungal infection. Steroid treatment would cause immunosuppression and make the infection worse, causing further spread. Had this been a condition such as eczema or psoriasis, then corticosteroids would have been appropriate. The key differentiating factor is the spreading element of the rash, the ring-like appearance and the location.

D Topical vitamin D

Topical vitamin D is used in conjunction with topical corticosteroids for psoriasis. Psoriasis typically presents as plaques of silvery scales on top of a salmon-pink rash.

E Refer to oncology

This would have been appropriate for patients with a malignant melanoma. Melanomas are typically pigmented lesions characterised by irregular edge, change in colour, symptoms of bleeding, itching and sensation, as well as ongoing change. In such patients, an urgent two-week referral is warranted.

Rate this question:

Next Question

10:39

A 73-year-old woman who has suffered a dense, left-sided hemiplegia is admitted from the care home where she lives because the GP has noticed a severe sacral pressure ulcer.

On examination, you can see a stage 3 pressure ulcer with a great deal of exudative material.

Which of the following is the most appropriate management?

A	Hydrocolloid dressing
B	Gauze dressing
C	Foam based dressing
D	Alginate based dressing
E	Leave the sore open to the air

Submit

Previous Q... Skip Questi...

© Pastest 2019

Explanation

D Alginate based dressing

This lady has exudate material within her pressure ulcer, and therefore she needs an absorptive dressing to avoid build-up of chronic exudate fluid which will affect wound healing. This is the most appropriate option as this dressing forms a gel when it comes into contact with the exudative material. Dressings serve to protect the wound from contamination and facilitate healing by absorbing exudate and protecting healing surfaces. Excess fluid causes wound maceration, while desiccation will slow epithelial cell migration. An absorptive dressing should be used to avoid build-up of chronic wound fluid that can macerate the wound and inhibit cell proliferation and wound healing.

C Foam based dressing

Foam-based dressing will absorb the exudate, but the alginate-based dressing will form a gel that is more likely to promote a warm, moist wound healing environment for grade 2-4 pressure ulcers (as suggested by NICE).

A Hydrocolloid dressing

Hydrocolloid dressings are useful to prevent bacterial contamination, reduce friction and shear and encourage a moist environment for more rapid healing, but only when there is no substantial exudate. Desiccated wounds lack wound fluids, which provide tissue growth factors to facilitate re-epithelialisation. Healing of pressure-induced injuries is promoted by dressings that maintain a moist wound environment while keeping the surrounding intact skin dry. Choices for a dry wound include saline-moistened gauze, transparent films, hydrocolloids and hydrogels.

B Gauze dressing

10:43

B	Gauze dressing

NICE has specifically mentioned that gauze dressing are not to be used to treat pressure ulcers in adults.

E	Leave the sore open to the air

This will lead to an infection risk and potentially to a build-up of exudate material.

Wound management as advised by NICE:

Consider using a dressing for adults that promotes a warm, moist wound healing environment to treat grade 2, 3 and 4 pressure ulcers. Do not offer gauze dressings to treat a pressure ulcer in adults. Do not routinely use topical antiseptics or antimicrobials to treat a pressure ulcer in adults.

GENERAL CARE - The general approach to management of a patient with pressure ulcers should include the following.

- Reduce or eliminate underlying contributing factors by providing pressure redistribution with proper positioning and support surfaces.
- Provide appropriate local wound care, which may include debridement for patients with necrotic tissue, based on the ulcer's characteristics.
- Consider adjunctive therapies, such as negative pressure wound therapy.
- Monitor and document the patient's progress.
- Provide appropriate psychosocial support.

Reference:

Treatment of pressure ulcers: a systematic review. *JAMA* 2008 Dec 10;300(22):2647-2462. doi: 10.1001/jama.2008.778

Rana Alnasser's screen

10:43

A 45-year-old man presented with fever, widespread rash and confusion. His only past history of note was Sydenham's chorea and a number of recent dental extractions.

While in hospital, his rash, which initially looked like petechial haemorrhages, worsened and developed into a purpuric rash heavily concentrated on his trunk and lower limbs, and he was started on cefuroxime and aciclovir. Over the weekend, he developed an episode of ataxic hemiparesis that resolved. When he was seen on the Monday morning ward round, he complained of incoordination of his right arm.

A CT head showed evidence of small infarcts in a number of areas. A lumbar puncture was performed. The only abnormality is a raised protein of 0.7 g/l (normal < 0.5 g/l). HSV PCR is negative. He is still spiking temperatures of up to 39 °C and the rash is not subsiding despite antibacterial and antiviral treatment.

What is the most useful examination to confirm the cause of his neurological symptoms?

A	MRI brain
B	Trans-oesophageal echocardiography (TOE)
C	Cryoglobulins
D	Serum antiphospholipid antibodies
E	Blood cultures

Rana Alnasser's screen

10:46
594-042-7551 Leave

A 20-year-old man, who has just returned from holidays in Canada, has developed the following rash:

Given the suspected diagnosis, what is the correct treatment choice if he feels otherwise well?

A Clotrimazole cream

B Topical beclomethasone cream

C Oral ketoconazole

D Oral doxycycline

E Intravenous (IV) benzylpenicillin

Submit
Audio Video Share Participants More

10:46

A 20-year-old man, who has just returned from holidays in Canada, has developed the following rash:

Given the suspected diagnosis, what is the correct treatment choice if he feels otherwise well?

Your answer was correct

A	Clotrimazole cream
B	Topical beclomethasone cream
C	Oral ketoconazole
D	Oral doxycycline
E	Intravenous (IV) benzylpenicillin

Explanation

14–21 days of treatment is necessary.

A Clotrimazole cream

Clotrimazole cream (Option A) is incorrect.

The rash represents erythema chronicum migrans. This starts as a small papule and develops into a slow-enlarging ring with a raised border and central clearance. It is pathognomonic of Lyme disease and is caused by the spirochaete *Borrelia burgdorferi*.

Clotrimazole cream is an antifungal agent commonly used in the treatment of superficial fungal infections.

B Topical beclomethasone cream

Topical beclomethasone cream (Option B) is incorrect.

Topical steroids do not have a role in the management of erythema chronicum migrans.

C Oral ketoconazole

Oral ketoconazole (Option C) is incorrect.

Like clotrimazole, this is an antifungal agent and would not be effective against Lyme disease.

E Intravenous (IV) benzylpenicillin

Intravenous (IV) benzylpenicillin (Option E) is incorrect.

If the patient has any late complications (meningitis, cranial nerve palsies, heart block, arthropathy), then high-dose IV benzylpenicillin or cefotaxime is warranted.

Rate this question:

Next Question

10:46

This 48-year-old woman presented with the rash shown. She has had it for many years, been too embarrassed to come to the doctors and has never shown her skin to anyone, except her GP.

She has been using topical creams including Calcipotriol and topical steroids. She has a history of breast cancer, in remission, type 2 diabetes and chronic kidney disease stage 2.

Gentle rubbing of the skin over a plaque to remove scales reveals punctate bleeding spots.

What is this sign known as?

A	Russell's sign
B	Kehr's sign
C	Hutchinson's sign
D	Nickolsky's sign

10:47

She has been using topical creams including Calcipotriol and topical steroids. She has a history of breast cancer, in remission, type 2 diabetes and chronic kidney disease stage 2.

Gentle rubbing of the skin over a plaque to remove scales reveals punctate bleeding spots.

What is this sign known as?

A	Russell's sign
B	Kehr's sign
C	Hutchinson's sign
D	Nickolsky's sign
E	Auspitz's sign

Rana Alnasser's screen

10:48

Gentle rubbing of the skin over a plaque to remove scales reveals punctate bleeding spots.

What is this sign known as?

Your answer was correct

A Russell's sign

B Kehr's sign

C Hutchinson's sign

D Nickolsky's sign

E Auspitz's sign

Explanation

E Auspitz's sign

Auspitz's sign. Auspitz's sign, where punctate bleeding spots are seen when scales are scraped away from the

Rana Alnasser's screen

10:49

E Auspitz's sign

Explanation

E Auspitz's sign

Auspitz's sign. Auspitz's sign, where punctate bleeding spots are seen when scales are scraped away from the surface of a plaque, is typical of psoriasis.

A Russell's sign

Russell's sign is callous formation over the knuckles on the back of the hand due to repeated self induced vomiting.

B Kehr's sign

Kehr's sign is the presence of shoulder tip pain as a result of blood or irritation within the peritoneal cavity.

C Hutchinson's sign

Hutchinson's sign (hyperpigmentation of the nail bed and matrix) is important in diagnosing subungual melanoma.

D Nickolsky's sign

Nickolsky's sign is important when diagnosing TEN (toxic epidermal necrolysis). Slight rubbing of the skin results in exfoliation of the epidermis causing a blister.

Rate this question:

Next Question

10:50

A 35-year-old farmer presents with a rash over his back, face, neck and forearms. He has a history of pulmonary TB as a child, but no other medical history of note.

In the last week, he has felt that his knees and hands have been stiff and painful.

The appearance of the rash is shown in the photograph below:

What is the most likely diagnosis?

A	Lyme disease
B	Lupus vulgaris
C	Discoid lupus erythematosus
D	Psoriasis
E	Cattle ringworm

Submit

A 35-year-old farmer presents with a rash over his back, face, neck and forearms. He has a history of pulmonary TB as a child, but no other medical history of note.

In the last week, he has felt that his knees and hands have been stiff and painful.

The appearance of the rash is shown in the photograph below:

What is the most likely diagnosis?

Your answer was incorrect

A Lyme disease

B Lupus vulgaris

C Discoid lupus erythematosus

D Psoriasis

E Cattle ringworm

Explanation

C Discoid lupus erythematosus

This is a chronic, scarring, photosensitive dermatosis. Up to 28% of patients with DLE may later develop systemic lupus erythematosus (SLE), and DLE can occur as a feature of SLE. DLE usually presents without significant systemic features. The findings are typically of erythematous, scaly plaques on sun-exposed areas, particularly the face and scalp. Lesions heal with scarring and can result in significant alopecia on the scalp. Dyspigmentation can be prominent, especially in darker skin types. Pruritus and a stinging sensation are variable and some individuals are asymptomatic. The diagnosis can be confirmed on skin biopsy. In the absence of SLE, autoantibodies are usually negative. Treatment is with sun protection and very potent topical corticosteroids; refractory cases will require oral antimalarial agents and sometimes systemic immunosuppressive therapy.

D Psoriasis

The distribution described in this scenario suggests a photosensitive eruption rather than psoriasis. The lesions in the photograph are more irregular than would be expected in psoriasis. A closer view would help to confirm that there is no silvery scale.

A Lyme disease

The initial skin manifestation of Lyme disease is erythema chronicum migrans, which presents as an expanding annular lesion centred around the site of the infecting tick bite.

B Lupus vulgaris

This presents as a solitary, very slowly enlarging, infiltrating plaque, rather than the multifocal eruption in the image.

10:55

in psoriasis. A closer view would help to confirm that there is no silvery scale.

A Lyme disease

The initial skin manifestation of Lyme disease is erythema chronicum migrans, which presents as an expanding annular lesion centred around the site of the infecting tick bite.

B Lupus vulgaris

This presents as a solitary, very slowly enlarging, infiltrating plaque, rather than the multifocal eruption in the image.

E Cattle ringworm

Animal ringworm (dermatophyte infection) tends to be more inflammatory than the usual strains causing disease in humans. It would still usually present as a solitary plaque at the site of inoculation and not the more widespread eruption described in the scenario.

Rate this question:

© Pastest 2019

Rana Alnasser's screen

10:55

A 52-year-old woman who has Raynaud's phenomenon and gastro-oesophageal reflux disease (GORD) comes to the clinic for review. She is very concerned about the cosmetic appearance of her neck, which is shown in the image below.

Current medications of note include amlodipine and lisinopril, which she takes for control of high blood pressure.

Examination reveals thickening of the skin over her hands and several telangiectasia over the upper chest.

Which of the following is the most likely diagnosis?

A	Acquired ichthyosis (AI)
B	Lupus vulgaris
C	Morphoea
D	Systemic lupus erythematosus (SLE)
E	Systemic sclerosis

Rana Alnasser's screen

E Systemic sclerosis

The picture shows significant skin thickening over the anterior neck, which is consistent with systemic sclerosis. The Raynaud's phenomenon, skin changes over the hands, telangiectasia, reflux and hypertension also support the diagnosis.

A Acquired ichthyosis (AI)

AI is associated with dry skin and severe skin scaling, rather than thickening as seen here. It is associated with the development of lymphoma in older adults.

B Lupus vulgaris

Lupus vulgaris is the skin manifestation of *Mycobacterium tuberculosis* infection, which appears as painful nodular skin lesions. They are seen around the neck and may also be seen on the face.

C Morphoea

Morphoea is localised scleroderma, which would not fit with the generalised symptoms this patient has, including Raynaud's phenomenon, hypertension and GORD.

D Systemic lupus erythematosus (SLE)

SLE is associated with small joint polyarthritis and photosensitive rash, as opposed to the picture seen here with predominant skin thickening.

71612

Rate this question:

A 34-year old woman is due to be discharged after being admitted for iloprost infusion for systemic sclerosis. She was admitted due to poorly controlled digital ulceration.

A photograph of her hands is shown below.

This is a new diagnosis for her and it is explained that she will need ongoing monitoring annually for systemic complications.

Other than an electrocardiogram (ECG), which of the following investigations should be requested annually?

A	Oesophageal manometry
B	High-resolution computed tomography (HR CT) chest
C	Pulmonary function tests and echocardiogram
D	Cardiac magnetic resonance imaging (MRI)
E	Right heart catheterisation

This is a new diagnosis for her and it is explained that she will need ongoing monitoring annually for systemic complications.

Other than an electrocardiogram (ECG), which of the following investigations should be requested annually?

Your answer was incorrect

A	Oesophageal manometry
B	High-resolution computed tomography (HR CT) chest
C	Pulmonary function tests and echocardiogram
D	Cardiac magnetic resonance imaging (MRI)
E	Right heart catheterisation

Explanation

C	Pulmonary function tests and echocardiogram

This patient has systemic sclerosis and is at risk of developing complications. Complications of systemic

Explanation

C Pulmonary function tests and echocardiogram

This patient has systemic sclerosis and is at risk of developing complications. Complications of systemic sclerosis include:

- respiratory: pulmonary fibrosis, pulmonary hypertension, aspiration pneumonia and pulmonary haemorrhage
- gastrointestinal: gastroesophageal reflux disease (GORD), peptic strictures, dysphagia, bacterial overgrowth and malabsorption
- renal: malignant hypertension, angiopathic haemolytic anaemia and intermittent renal crisis.

Systemic sclerosis should be monitored in terms of skin and complications. Skin monitoring is done by measuring skin tightness and interlabial distance which can be combined into the Rodnan skin score. Annual monitoring for internal organ pathology includes screening for interstitial lung disease and pulmonary artery hypertension, and therefore requires pulmonary function tests, transthoracic echocardiogram and ECG on an annual basis.

E Right heart catheterisation

Right heart catheterisation is the gold-standard investigation to assess pulmonary arterial hypertension, a complication of systemic sclerosis. However, echocardiogram is done to screen for pulmonary hypertension and then patients who are suspected of pulmonary hypertension are further investigated with right heart catheterisation.

A Oesophageal manometry

E Right heart catheterisation

Right heart catheterisation is the gold-standard investigation to assess pulmonary arterial hypertension, a complication of systemic sclerosis. However, echocardiogram is done to screen for pulmonary hypertension and then patients who are suspected of pulmonary hypertension are further investigated with right heart catheterisation.

A Oesophageal manometry

Patients with systemic sclerosis may develop oesophageal reflux and swallowing problems. If the patient develops symptoms then they should be investigated with oesophageal manometry to assess dysphagia, and they may also need barium swallow to further assess them. Without symptoms, these investigations are not needed.

B High-resolution computed tomography (HR CT) chest

HR CT scan of the chest is indicated in patients with systemic sclerosis if pulmonary function tests demonstrate a restrictive picture. HR CT can then help diagnose and characterise the extent of pulmonary fibrosis.

D Cardiac magnetic resonance imaging (MRI)

Cardiac MRI can be useful in the assessment of cardiac scleroderma, which is cardiomyopathy of the heart in the context of systemic sclerosis. This can present with shortness of breath, decreased exercise tolerance, chest pain and palpitations. Cardiac MRI is useful for patients presenting with these symptoms in the context of systemic sclerosis but is not generally used as annual monitoring.